

## PDF hosted at the Radboud Repository of the Radboud University Nijmegen

The following full text is a publisher's version.

For additional information about this publication click this link.

<http://hdl.handle.net/2066/155257>

Please be advised that this information was generated on 2017-12-05 and may be subject to change.



## Case report

# Facioscapulohumeral muscular dystrophy and respiratory failure; what about the diaphragm?



A. Hazenberg<sup>a,b,\*</sup>, N. van Alfen<sup>c</sup>, N.B.M. Voet<sup>d</sup>, H.A.M. Kerstjens<sup>a,b</sup>, P.J. Wijkstra<sup>a,b</sup>

<sup>a</sup> University of Groningen, University Medical Center Groningen, Department of Pulmonology and Tuberculosis, Department of Home Mechanical Ventilation, Groningen, The Netherlands

<sup>b</sup> University of Groningen, University Medical Center Groningen, GRIAC Research Institute, The Netherlands

<sup>c</sup> Department of Neurology and Clinical Neurophysiology, Donders Centre for Neuroscience, Radboud University Nijmegen Medical Centre, Nijmegen, The Netherlands

<sup>d</sup> Department of Rehabilitation, Nijmegen Centre for Evidence Based Practice, Radboud University Nijmegen Medical Centre, Nijmegen, RMC Groot Klimmendaal, Arnhem, The Netherlands

## A B S T R A C T

### Keywords:

Non invasive positive pressure ventilation  
Diaphragm paralysis  
Facioscapulohumeral muscular dystrophy  
Chronic respiratory failure  
Sleep

**Introduction:** We present a case of facioscapulohumeral muscular dystrophy (FSHD) with a diaphragm paralysis as the primary cause of ventilatory failure. FSHD is an autosomal dominant inherited disorder with a restricted pattern of weakness. Although respiratory weakness is a relatively unknown in FSHD, it is not uncommon.

**Methods:** We report on the clinical findings of a 68-year old male who presented with severe dyspnea while supine.

**Results:** Supplementing our clinical findings with laboratory, electrophysiological and radiological performances led to the diagnosis of diaphragm paralysis. Arterial blood gas in sitting position without supplemental oxygen showed a mild hypercapnia. His sleep improved after starting non-invasive ventilation and his daytime sleepiness disappeared.

**Discussion:** We conclude that in patients with FSHD who have symptoms of nocturnal hypoventilation, an adequate assessment of the diaphragm is recommended. This is of great importance as we know that nocturnal hypoventilation can be treated effectively by non-invasive ventilation.

© 2014 The Authors. Published by Elsevier Ltd. This is an open access article under the CC BY-NC-ND license (<http://creativecommons.org/licenses/by-nc-nd/4.0/>).

## Introduction

Facioscapulohumeral muscular dystrophy (FSHD) is an autosomal dominant inherited disorder with a restricted pattern of weakness and is the third most common form of dystrophy [1]. In over 95% of the patients a deletion of a 3.3 kb tandem repeat, D4Z4, on chromosome 4q35 is present (FSHD type 1). In some cases (FSHD type 2), D4Z4 chromatin relaxation and stable double homeobox (DUX4) expression occur in the absence of D4Z4 array contraction [2]. FSHD type 1 and 2 are clinically characterized by

asymmetric involvement of muscles in the facial, upper extremity, trunk and lower extremity region with variable severity (Table 1).

Although respiratory weakness is a relatively unknown feature of FSHD, it is not uncommon; one study reported that almost all of the patients will develop restrictive lung disease and 10–20% will suffer from pulmonary complications (Table 2).

Patients with FSHD may become respiratory insufficient if they have progressive weakness of respiratory muscles and/or a scoliosis, most likely when there are other signs of functionally severe impairment such as the need to use a wheelchair [4]. In this case report we present a patient with FSHD who had a diaphragm paralysis as the primary cause of ventilatory failure.

He was treated successfully with non-invasive positive pressure ventilation.

## Case report

In 2008, at the age of 68, this man was diagnosed with Facioscapulohumeral muscular dystrophy (FSHD) type 1 (5 units 4A161).

**Abbreviations:** FSHD, facioscapulohumeral muscular dystrophy; DUX4, double homeobox; PSG, polysomnography; FVC, forced vital capacity; kPa, kilopascal; pH, acidity level; paCO<sub>2</sub>, partial pressure of arterial carbon dioxide; paO<sub>2</sub>, partial pressure of arterial oxygen; HCO<sub>3</sub>, bicarbonate; tcpCO<sub>2</sub>, transcutaneous carbon dioxide; SpO<sub>2</sub>, oxygen saturation; NIPPV, non-invasive positive pressure ventilation.

\* Corresponding author. University Medical Center Groningen, Department of Home Mechanical Ventilation, Internal code AA 62, Hanzeplein 1, 9700 RB Groningen, The Netherlands.

E-mail address: [a.hazenberg@umcg.nl](mailto:a.hazenberg@umcg.nl) (A. Hazenberg).

<http://dx.doi.org/10.1016/j.rmcr.2014.12.006>

2213-0071/© 2014 The Authors. Published by Elsevier Ltd. This is an open access article under the CC BY-NC-ND license (<http://creativecommons.org/licenses/by-nc-nd/4.0/>).

**Table 1**  
Ricci score, muscle strength was evaluated by using the Manual Muscle Testing Scale [3].

0.5	Facial weakness
1	Mild scapular involvement without limitation of arm abduction; no awareness of disease symptoms is possible
1.5	Moderate involvement of scapular and arm muscles or both (arm abduction $>60^\circ$ and strength $\geq 3$ in arm muscles); no involvement of pelvic and leg muscles
2	Severe scapular involvement (arm abduction $<60^\circ$ on at least one side); strength $<3$ in at least one muscular district of the arms; no involvement of pelvic and leg muscles
2.5	Tibioperoneal weakness; no weakness of pelvic and proximal leg muscles
3	Mild weakness of pelvic and proximal leg muscles or both (strength $\geq 4$ in all these muscles); able to stand up from a chair without support
3.5	Moderate weakness of pelvic and proximal leg muscles or both (strength $\geq 3$ in all these muscles); able to stand up from a chair with monolateral support
4	Severe weakness of pelvic and proximal leg muscles or both (strength $<3$ in at least one of these muscles); able to stand up from a chair with double support; able to walk unaided
4.5	Unable to stand up from a chair; walking limited to several steps with support; may use wheelchair for most activities
5	Wheelchair bound

**Table 2**  
Main clinical findings [1].

Respiratory symptoms of hypoventilation	Hypercapnia Dyspnea while in supine position Fatigue
Neuromuscular symptoms	Morning head ache Facial muscle weakness Shoulder girdle weakness Abdominal muscle weakness
Extramuscular symptoms	Lower-extremity muscle weakness High-frequency hearing loss Retinal telangiectasias Atrial arrhythmias Pain

His medical history mentioned also psoriasis, high blood pressure for which he used bisoprolol, irbesartan, methotrexate and folate. He had also undergone surgery for penis carcinoma. His first complaints of muscle weakness were noticed at the age of 20 during a physical exam test. Exercise tolerance had been decreasing

over the last 3–5 years. The last year he experienced severe dyspnea when lying in supine position. He was referred to our hospital to evaluate his respiratory impairment. Normally he slept from 11 PM till 7 AM, did not snore and because of breathlessness in supine position he preferred to sleep on his side with the top of the bed in uplift position. In the morning he woke up reasonably fit without a headache. During daytime he experienced fatigue and sleepiness, as do many FSHD patients [5,6], and he had to take a nap every afternoon.

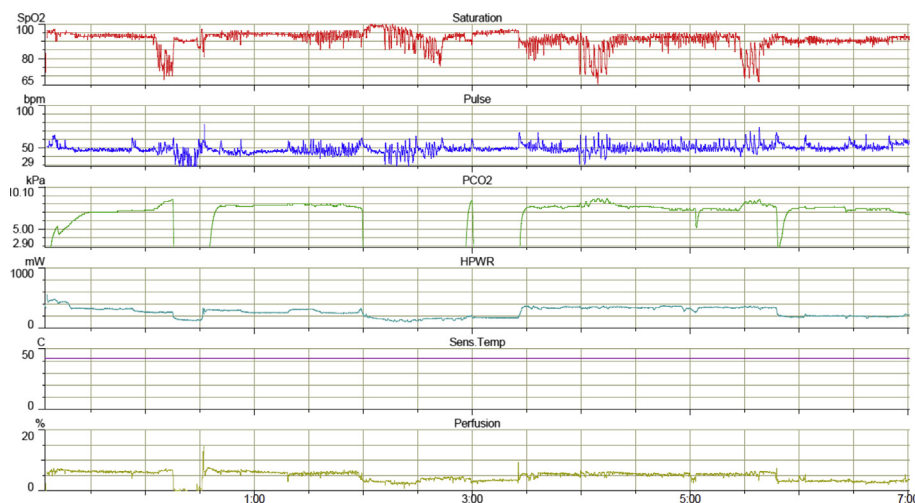
The patient could still walk a short distance and up a flight of stairs, but this caused shortness of breath, and a mild tachypnea.

On physical examination, his weight was 97 kg, length 1.79 m, Body Mass index 29.7 kg/m<sup>2</sup>. He could not lift his arms above shoulder height. There was atrophy and muscle weakness of proximal as well as distal upper and lower extremities, back and abdominal muscles, but no signs of scoliosis. The Ricci score for clinical severity of FSHD was 3 [3]. Resting heart rate: 70 beats/minute and resting respiratory rate 18 breaths/minute. In supine position there was paradoxical abdominal breathing and his respiratory rate increased. Arterial blood gas in sitting position without supplemental oxygen: acidity level (pH) 7.41, partial pressure of arterial carbon dioxide (paCO<sub>2</sub>) 6.1 kilopascal (kPa), partial pressure of oxygen (paO<sub>2</sub>) 9.7 kPa, bicarbonate (HCO<sub>3</sub>) 28.6 mmol/l, oxygen-saturation 95%. Nocturnal registration with the Tosca<sup>®</sup> transcutaneous monitor, before starting the chronic ventilatory support, showed a mean transcutaneous carbon dioxide (tcpCO<sub>2</sub>) of 7.8 kPa (4–6 kPa is normal) and a mean oxygen saturation (SpO<sub>2</sub>) of 91% ( $>92\%$  is normal) [7]. The lowest saturation was 65% (Fig. 1).

To exclude that the patient had an obstructive sleep apnea syndrome a polysomnography (PSG) was performed [5,8,9]. The PSG showed a disturbed sleep with short awakenings and an apnea/hypopnea index of 2/hour ( $<5$  is normal). Pulmonary function tests showed a decline in forced vital capacity (FVC) of 1.5 L when moving from sitting to supine position: FVC sitting 2.60 L (59% predicted), in supine position 1.10 L (25% predicted). Fluoroscopy of the diaphragm in supine position during a sniff maneuver revealed paradoxical diaphragm movement on both sides.

## Results

To relieve his physical complaints and improve his alveolar hypoventilation he started non-invasive positive pressure



**Fig. 1.** Nocturnal transcutaneous registration of carbon dioxide (mean 7.8 kPa) and oxygen saturation (mean 91%) before starting ventilation.

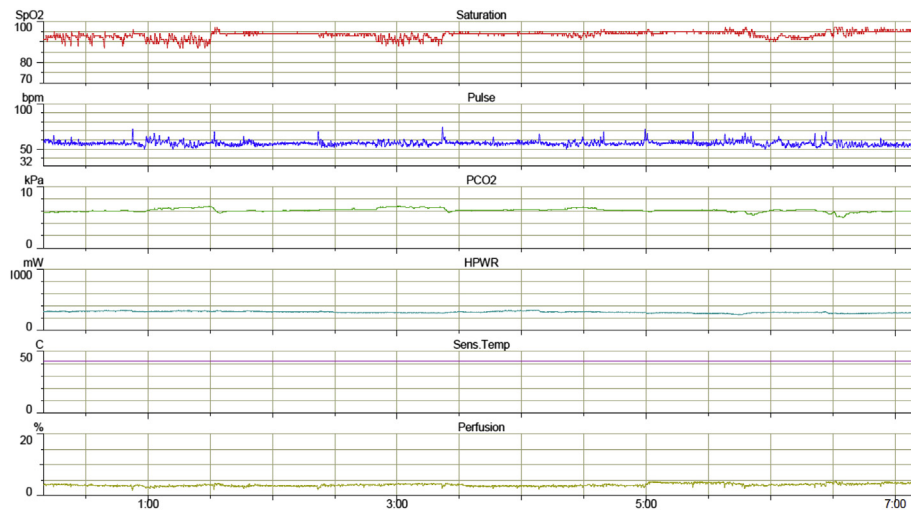


Fig. 2. There is a relevant improvement in carbon dioxide (mean 6.1 kPa) and oxygen saturation levels (mean 94%) during ventilatory support.

ventilation (NIPPV) during the night. The ventilator was set in the pressure assisted controlled mode with an inspiratory pressure of 24 cm H<sub>2</sub>O, a positive end expiratory pressure of 8 cm H<sub>2</sub>O and a frequency of 15 per minute. The patient used the ventilator every night with a mean usage of 7 h per night. His relationship with the ventilator was dual; he thought of it as an enemy because he had problems accepting the necessity to be ventilated, but also as a friend because it provided him better sleep and more energy during the day. While the vital capacity did not change after starting NIPPV, the arterial blood gas during the day at rest without ventilation did improve: pH 7.41, pCO<sub>2</sub> 5.9 kPa, pO<sub>2</sub> 11 kPa, HCO<sub>3</sub><sup>-</sup> 28 mmol/l, oxygen-saturation 97%. Nocturnal registration one year after starting the NIPPV showed a mean tcpCO<sub>2</sub> of 6.1 kPa and a mean SpO<sub>2</sub> of 94% (Fig. 2).

By using NIPPV the patient could now sleep in supine position. He slept better and he experienced more energy during daily activities. In addition he did not fall asleep anymore during daytime hours.

## Discussion

This patient with FSHD had respiratory failure due to bilateral diaphragm paralysis as shown by the large drop in the vital capacity when changing from sitting to supine position in combination with paradoxical diaphragm movement during the sniff maneuver. A recent study concluded that the diaphragm should in principle not be paralyzed in patients with FSHD and therefore the authors did not recommend an evaluation of the diaphragm [10]. However, in that study patients were included who did not have symptoms of hypoventilation like morning headache, fatigue and daytime sleepiness, so it could be expected that the lung function was only mildly impaired. It is known that patients with FSHD can have complaints due to hypoventilation [4]. As an assessment of the vital capacity in both sitting and supine position and fluoroscopy of the diaphragm was not mentioned in that study, a paralysis of the diaphragm could have been missed as the primary cause of hypoventilation. Actual search and documentation of nocturnal hypoventilation is relevant since it can be treated effectively by NIPPV. We conclude that in patients with FSHD, who have symptoms of nocturnal hypoventilation such as morning headache, fatigue and

daytime sleepiness, an adequate assessment of the diaphragm is recommended.

## Author contribution to the manuscript

A. Hazenberg – writing and submitting the manuscript.

Dr. N. van Alfen – revision of the manuscript for important intellectual content.

N.B.M. Voet – acquisition and interpretation of data.

Prof. H.A.M. Kerstjens – critical revision of the manuscript for important intellectual content.

Dr. P.J. Wijkstra – final approval of the version to be submitted and supervision.

## References

- [1] Tawil R. Facioscapulohumeral muscular dystrophy. *Neurotherapeutics* 2008;5:601–6.
- [2] Lemmers RJ, Tawil R, Petek LM, Balog J, Block GJ, Santen GW, et al. Digenic inheritance of an SMCHD1 mutation and an FSHD-permissive D4Z4 allele causes facioscapulohumeral muscular dystrophy type 2. *Nat Genet* 2012;44:1370–4.
- [3] Ricci E, Galluzzi G, Deidda G, Cacurri S, Colantoni L, Merico B, et al. Progress in the molecular diagnosis of facioscapulohumeral muscular dystrophy and correlation between the number of KpnI repeats at the 4q35 locus and clinical phenotype. *Ann Neurol* 1999;45:751–7.
- [4] Wohlgemuth M, van der Kooij EL, van Kesteren RG, van der Maarel SM, Padberg GW. Ventilatory support in facioscapulohumeral muscular dystrophy. *Neurology* 2004;63:176–8.
- [5] Della Marca G, Frusciantè R, Dittoni S, Vollono C, Buccarella C, Iannaccone E, et al. Sleep disordered breathing in facioscapulohumeral muscular dystrophy. *J Neurol Sci* 2009;285:54–8.
- [6] Kalkman JS, Schillings ML, van der Werf SP, Padberg GW, Zwarts MJ, van Engelen BG, et al. Experienced fatigue in facioscapulohumeral dystrophy, myotonic dystrophy, and HMSN-I. *J Neurol Neurosurg Psychiatr* 2005;76:1406–9.
- [7] Hazenberg A, Zijlstra JG, Kerstjens HA, Wijkstra PJ. Validation of a transcutaneous CO(2) monitor in adult patients with chronic respiratory failure. *Respiration* 2011;81:242–6.
- [8] Della Marca G, Frusciantè R, Dittoni S, Vollono C, Losurdo A, Testani E, et al. Decreased nocturnal movements in patients with facioscapulohumeral muscular dystrophy. *J Clin Sleep Med* 2010;6:276–80.
- [9] Della Marca G, Frusciantè R, Vollono C, Dittoni S, Galluzzi G, Buccarella C, et al. Sleep quality in facioscapulohumeral muscular dystrophy. *J Neurol Sci* 2007;263:49–53.
- [10] Stubgen JP, Schultz C. Lung and respiratory muscle function in facioscapulohumeral muscular dystrophy. *Muscle Nerve* 2009;39:729–34.