

PDF hosted at the Radboud Repository of the Radboud University Nijmegen

The following full text is a publisher's version.

For additional information about this publication click this link.

<http://hdl.handle.net/2066/153215>

Please be advised that this information was generated on 2017-12-05 and may be subject to change.

Retrospective Study

Intragastric band erosion: Experiences with gastrointestinal endoscopic removal

Edo Oscar Aarts, Bas van Wageningen, Frits Berends, Ignace Janssen, Peter Wahab, Marcel Groenen

Edo Oscar Aarts, Bas van Wageningen, Frits Berends, Ignace Janssen, Department of Bariatric Surgery, Rijnstate Hospital, 6800 TA Arnhem, The Netherlands

Peter Wahab, Marcel Groenen, Department of Gastroenterology, Rijnstate Hospital, 6800 TA Arnhem, The Netherlands

Author contributions: Aarts EO, van Wageningen B and Berends F made the study set up and wrote the initial article; Aarts EO gathered all data prospectively; Janssen I, Wahab P and Groenen M corrected the article and helped shaping the final article.

Open-Access: This article is an open-access article which was selected by an in-house editor and fully peer-reviewed by external reviewers. It is distributed in accordance with the Creative Commons Attribution Non Commercial (CC BY-NC 4.0) license, which permits others to distribute, remix, adapt, build upon this work non-commercially, and license their derivative works on different terms, provided the original work is properly cited and the use is non-commercial. See: <http://creativecommons.org/licenses/by-nc/4.0/>

Correspondence to: Edo Oscar Aarts, MD, PhD, Departments of Bariatric Surgery, Rijnstate Hospital, Vitalys Clinics, Postal No. 1190, PO box 9555, 6800 TA Arnhem,

The Netherlands. eaarts@rijnstate.nl

Telephone: +31-8-80058888

Fax: +31-8-80058888

Received: June 13, 2014

Peer-review started: June 13, 2014

First decision: June 27, 2014

Revised: August 11, 2014

Accepted: September 16, 2014

Article in press: September 16, 2014

Published online: February 7, 2015

Abstract

AIM: To remove the migrated bands using a gastrointestinal endoscopic approach. Little is published on complications that can occur.

METHODS: From June 2006 to June 2010, eight patients developed intragastric band migration. Two patients had received their AGB in a different hospital, the

remaining six were operated by the same surgeon. In all patients gastrointestinal endoscopic removal of the band was attempted by two individual gastroenterologists. Clinical signs of band migration were: persisted nausea, abdominal pain, weight gain, recurrent infection of the port and tubing system and hematemesis.

RESULTS: In four patients removal was performed without complications. In two patients extracting the cleaved gastric band into the stomach appeared impossible. The two remaining patients presented with acute hematemesis and melena. One of these patients was readmitted with hematemesis. The other patient started bleeding during the gastroscopy and was converted to a laparoscopy in which one of the branches of the left gastric artery was oversewn.

CONCLUSION: Band migration after gastric banding can be life threatening. Gastrointestinal endoscopic removal is a feasible technique that holds the promise of fast reconvalescence.

Key words: Morbid obesity; Adjustable gastric band; Migration; Gastroscopy; Gastrointestinal endoscopic device removal

© The Author(s) 2015. Published by Baishideng Publishing Group Inc. All rights reserved.

Core tip: Band migration after gastric banding can be life threatening. Gastrointestinal endoscopic removal is a feasible technique that holds the promise of fast reconvalescence. However, there is a risk for fulminant hemorrhage from the extraction site, even a few weeks after the procedure. It is inadvisable to postpone re-intervention when bleeding is suspected when a patient presents with hematemesis or melena.

Aarts EO, van Wageningen B, Berends F, Janssen I, Wahab

P, Groenen M. Intra-gastric band erosion: Experiences with gastrointestinal endoscopic removal. *World J Gastroenterol* 2015; 21(5): 1567-1572 Available from: URL: <http://www.wjgnet.com/1007-9327/full/v21/i5/1567.htm> DOI: <http://dx.doi.org/10.3748/wjg.v21.i5.1567>

INTRODUCTION

Adjustable gastric banding (AGB) is one of the surgical treatment modalities for morbid obesity. Over the years popularity for this treatment increased it has been by far the most performed bariatric procedure for years in Europe and increasingly so in the United States. AGB combines moderate excess weight loss with low post operative morbidity and mortality. Despite low complication rates, some failures do occur and as the total number of patients increase, so does its complications^[1-3].

Complications after AGB are not uncommon and consist mainly of hernias, gastroesophageal reflux disease, pouch dilatation and leakage of the band^[1-3]. Intra-gastric migration of the band is perhaps one of the gravest complications. Migration is regularly reported in literature and prevalence ranges from 0.3% to 4.8% and in one study even in 11% within the first two years after surgery^[3-13]. When migration occurs, band removal is mandatory to prevent intra abdominal infection, gastrointestinal obstruction or life threatening hemorrhage. Although the introduction of the pars flaccid technique might have lowered the risk for developing band migration, the increased number of AGB procedures worldwide makes migration a complication to be reckoned with^[1,2,6].

In our hospital the removal of migrated AGB is most often performed by gastrointestinal endoscopy. This approach is less demanding for the patient while for removal of the migrated gastric band surgery is, in theory, not required. The stomach heals in the months after removal and then patients are offered a second procedure. This approach reduces the number of surgical interventions from two to one. During this endoscopic procedure the band is cut and removed transorally. Gastrointestinal endoscopic removal is promoted as a relatively safe alternative for laparoscopic removal of the band and mortality has not yet been reported^[12,14]. We present eight patients with migrated gastric bands in whom gastrointestinal endoscopic removal was attempted.

MATERIALS AND METHODS

From June 2006 to June 2010, eight patients developed intra-gastric band migration. Two patients had received their AGB in a different hospital, the remaining six were operated by the same surgeon. In all patients gastrointestinal endoscopic removal

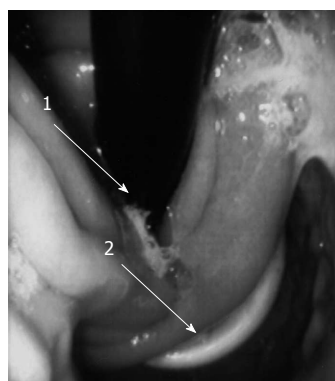


Figure 1 Endoscopic view of migrated gastric band. 1: Gastroscopist through esophagus; 2: Migrated gastric band.

of the band was attempted by two individual gastroenterologists. Clinical signs of band migration were: persisted nausea, abdominal pain, weight gain, recurrent infection of the port and tubing system and hematemesis. Demographics and preoperative data are shown in Table 1. This study was approved by the medical Ethics Committee of the Rijnstate Hospital in Arnhem.

Preoperative

When an AGB migration was suspected all patients underwent an upper gastrointestinal gastrograffin study (UGI) and a gastroscopy (Figure 1). In most cases the AGB has to be completely migrated into the stomach to reveal a migrated band on a UGI. Therefore a gastroscopy is imminent in most cases to diagnose a possible migration, so that when suspicion is high, the gastrograffin swallow can be left out^[14]. When migration was confirmed, proton pump inhibitors were prescribed and the patient was scheduled for gastrointestinal endoscopic removal of the AGB.

Operative technique

The gastrointestinal endoscopic removal of a migrated gastric band is an interdisciplinary procedure in our hospital. Although the procedure was carried out under general anesthesia in all cases, conscious sedation for gastrointestinal endoscopic band removal and local anesthesia for port removal is possible. The removal of the AGB is divided into two stages: First the removal of the port and the connecting tube and secondly the gastrointestinal endoscopic removal of the band.

After insertion of the gastroscopist and insufflation of the stomach the migrated band is identified. Figure 2 shows the gastric band cutter. A metal cutting wire (1 in Figure 2) is guided in between the protruded portion of the band and the stomach wall. Then the tip of the wire is retracted outside the patient so that the wire is looped around the band

Table 1 Demographics and preoperative data

Patient No.	Age (yr)	Sex	Symptoms	Migration (months after placement)	Band type and placement	BMI prior to AGB (kg/m ²)	BMI prior to removal (kg/m ²)	Possible cause of migration
1	34	F	Abdominal pain and vomiting	2	SAGB, 11 cm ³ , Pars flaccid	46.1	35.8	Peroperative trauma
2	43	F	Abdominal pain	99	SAGB, 9 cm ³ , Perigastric	42.9	25.5	Hyperinflation of band (12 cm ³)
3	35	F	Infection after port revision	4	SAGB, 11 cm ³ , Pars flaccid	39.7	33.4	Infection
4	44	F	Anemia, melena and collaboration	10	SAGB, 11 cm ³ , Pars flaccid	40.6	33.2	Infection
5	38	F	Abdominal pain and weight gain	34	Bioring, 9 cm ³ , Pars flaccid	44.7	35.8	Hyperinflation of the band (11.5 cm ³)
6	31	F	Acute hematemesis	4	SAGB, 11 cm ³ , Pars flaccid	43.5	35.7	Preoperative trauma
7	47	F	Abdominal pain	47	SAGB, 9 cm ³ , Pars flaccid	42.4	30.2	Fibrous capsule
8	51	F	Weight gain	107	LAP-BAND®, Perigastric	45.3	38.1	Infection

F: Female; SAGB: Swedish adjustable gastric band; BMI: Body mass index; AGB: Adjustable gastric band.

Table 2 Pre- and post-operative data

Patient No.	Band removed	Complications preoperative	Postoperative course	Months after removal	Current complaints
1	Laparoscopic	Conversion to laparoscopy	Gastric bypass	12	Little restriction
2	Endoscopic	No complications	Gastric sleeve	11	Too much weight loss
3	Endoscopic	No complications	Gastric bypass	3	Weight regain
4	Endoscopic	No complications	Collabated; bleeding ulcer. Refuses further bariatric treatment	-	Back to initial weight
5	Endoscopic	No complications	Gastric bypass	10	No complaints
6	Endoscopic	Conversion to laparoscopy	Died due to gastric bleeding	-	-
7	Laparoscopic	Conversion to laparoscopy	Gastric bypass	5	No complaints
8	Endoscopic	No complications	Scopinaro	4	Weight regain

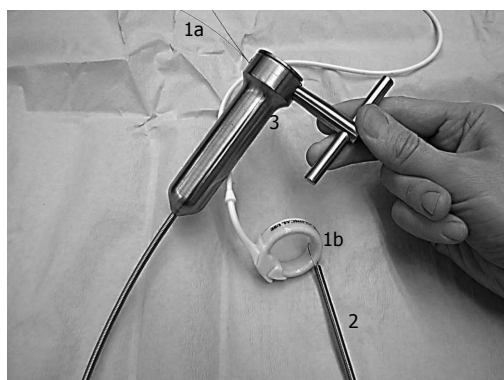


Figure 2 Endoscopic gastric band cutter. 1a: Metal cutting wire; 1b: Metal cutting wire looped around adjustable gastric band; 2: Flexible metal overtube; 3: Toggle device.

with both ends coming out by mouth. A flexible metal overtube (2 in Figure 2) is inserted over the wires to provide counterforce to the band. When wire-ends pulled tight using the special Toggle device (3 in Figure 2), the band is easily cut through (Gastric Band Cutter System Surgical Company). The loose end of the cutted band can now be caught with a polypectomy loop and pulled free into the

stomach and out by mouth. The migration defect in the stomach wall is not closed.

Postoperative

All patients were reexamined gastroscopically a few days after the removal of their AGB to confirm adequate closure of the migration defect and to exclude apparent bleeding. While these patients received their AGB to achieve weight loss, removing the AGB will lead to weight gain in most cases^[9]. All patients were evaluated to decide which bariatric procedure was most appropriated to replace the AGB and were followed in time.

RESULTS

All eight patients agreed on attempting a gastrointestinal endoscopic removal of their AGB. Results are shown in Table 2.

Four patients had their bands removed gastroscopically without any complications. Almost all complaints caused by the migrated band vanished immediately and patients could leave the following day. These patients received a different bariatric procedure after a mean of nine months (months

3-12). Five patients will eventually receive a gastric bypass, one patient received a gastric sleeve and one will receive a biliopancreatic division with duodenal switch (BPD-DS).

In one patient the AGB was cut, but dislocation into the stomach failed. The surgeon performed a laparoscopy and found that tissue had grown into the buckle of the AGB making gastrointestinal endoscopic extraction impossible. The tissue capsule in which AGB was located was cleaved and the AGB removed. Gastrointestinal endoscopic removal in patient seven also failed. In this case the band had only partially migrated and the gastroenterologist was unable to loop the guide wire over the band. Eventually this procedure was converted to an uncomplicated laparoscopic removal of the band.

Two patients suffered from melena and hematemesis prior to the procedure. Both patients did not use any medication. In patient number four, no complications occurred during the initial gastrointestinal endoscopic removal of the AGB. This patient was readmitted after four days with significant hematemesis. Gastroscopy revealed an ulcer with signs of recent bleeding just below the migration site. After coagulation no more bleeding occurred and the patient was discharged after six days. This patient refused further operations for the treatment of her morbid obesity, and currently has reached her initial body mass index.

In patient number six bleeding occurred when the band was dislocated into the stomach and this procedure was converted to laparoscopy while the bleeding site could initially not be located. The bleeding arose from a branch of the left gastric artery and was oversewn. Follow up gastroscopy after a few days showed no more signs of bleeding and this patient was discharged after three days without any symptoms. However nine weeks thereafter she was acutely readmitted in another hospital with hematemesis and hypovolemic shock. Urgent gastroscopy showed a large blood clot inside the stomach, but an active bleeding could not be located. She was transferred to a university hospital to attempt angiographic embolisation. However, one day later the patients situation suddenly worsened during another gastroscopy and a computed tomography was made, which showed an active bleeding on the site where the AGB had been located. Unfortunately the patient developed an abdominal compartment syndrome and died during an emergency laparotomy.

DISCUSSION

Migration of the AGB is a complication which can occur shortly after placement, but is more often a long-term complication. Incidences of band migration greatly vary in literature, with a range from 0.3% to

11%. However, larger series describe an average rate as low as 1% or even less^[5-13,15-17]. The percentage of migrated bands is possibly higher, as a prospective study showed a great number of migrated gastric bands (7.5%) when patients were screened routinely during the first years after placement^[18]. The prevalence of migration increases over time because patients often remain asymptomatic for long periods or even will never become symptomatic. For this reason a great number of migrated bands will not be discovered unless a gastroscopy is performed routinely^[15,18]. In recent years, gastric bands placed around the pouch of a Roux-en-Y gastric bypass as redo surgery have been introduced, however also these seem to be migrating^[19].

There are several possible mechanisms for band migration into the gastric lumen. The first is early erosion or trauma of the gastric wall during the laparoscopic insertion of the band. More specifically during cannulation of the retrogastric route or when the band is pulled behind the stomach using a hooked retraction device, the dorsal serosal portion of the cardia is easily lacerated. This may be the cause of early perforation and subsequent migration.

Secondly, chronic shear stress of the band on the stomach wall due to physiological movement of the gastric wall and diaphragm can lead to microperforation and infection. These infections are most likely due to a microperforation of the gastric wall, giving microorganisms a chance to colonize the gastric band and migrate to the port site. An infected port is therefore always a reason to perform a gastroscopy^[2]. Another factor is the pressure applied by simply filling the adjustable band in order to get enough restriction to meals. Chronic overfilling of the band or inclusion of too much gastric wall within the gastric band during placement can add to this pressure problem. The fourth mechanism for migration lies in the fact that a gastric band is recognized by the immune system as a foreign body leading to a rejection reaction against the silicon material. This causes formation of a fibrous capsule that leads to contraction^[1,2,8,14,20]. The suggested mechanisms can play a role in AGB migration. It is however likely in our opinion that the etiology of most migrations is multifactorial.

Due to the tissue capsule formed around the band most patients are asymptomatic, because it seals off the peritoneal cavity. However, a number of clinical signs and symptoms can occur when a gastric band has migrated. These include the inability to regulate the stomach diameter with inflation, a sudden stop in weight loss or even weight regain, recurrent port site infection and life-threatening gastrointestinal bleeding^[5,10-12,14]. When a band has completely eroded into the gastric lumen it may lead to life threatening complications such as peritonitis or upper intestinal hemorrhage^[4,21,22]. Even acute bowel

obstruction or thrombophlebitis of the portal vein after migration have been reported^[23-26].

A number of endoscopic and surgical methods for removing a partially migrated band have been described in published articles. The first is a perigastric laparoscopic division^[2,7,27,28], the second a transgastric approach^[5,9,16]. These techniques have the advantage of being relative safe, allow gastric wall repair and omental patching. Several other groups have reported endoscopic methods using traditional endoscopic devices or the gastric band cutter (Agency for Medical Innovation)^[8,12,20,29,30]. The latter has the advantage to be minimal invasive, but is only advised when performed by experienced surgeons or gastroenterologists.

The ideal momentum of endoscopic extraction of the migrated band is matter of debate. Some articles using the gastrointestinal endoscopic technique advise to wait until complete migration, so that the band can be easier removed^[14,20]. Other authors stress the serious risk of peritonitis and advise to remove the band rapidly after an endoscopic confirmation of migration^[7,10,11,23,30,31]. In our hospital the migrated AGB is removed shortly after the diagnosis to minimize the risk of complications. This implicates that removal in some cases is performed when the AGB has only partially migrated, which makes the procedure more difficult.

A number of complications occurred during and after gastrointestinal endoscopic removal of the AGB. Gastrointestinal endoscopic extraction failed in two patients due to tissue overgrowth into the buckle in one case, and minimal migration in a second of the AGB. This is a known complication and has been described earlier in 20% of patients where gastrointestinal endoscopic removal is attempted^[8].

Although AGB is a relatively safe procedure with mortality rates less than 0.1% there are two major complications leading to grave morbidity and the risk of death. One is early or late perforation leading to peritonitis, sepsis and organ failure. The other is massive bleeding due to iatrogenic trauma or erosion of a vessel by the band. Band migration holds the risk of both^[6,21-23]. In our series we had two patients with significant bleeding after the gastrointestinal endoscopic removal. One of them was easily controlled, in the second case a conversion to laparoscopy was necessary to locate and stop the hemorrhage. Although both patients were discharged in good health, one patient eventually died due to a massive rebleeding at the AGB location two months after the gastrointestinal endoscopic removal.

Band migration is a serious complication after AGB that can be potentially life threatening and should be treated accordingly. Gastrointestinal endoscopic removal of the migrated AGB is a feasible technique that holds the promise of fast

reconvalescence. However, there is a serious risk for fulminant hemorrhage from the extraction site, even a few weeks after the procedure. It is inadvisable to postpone re-intervention when bleeding is suspected or to try a gastrointestinal endoscopic approach when a patient presents with hematemesis or melena.

COMMENTS

Background

With a prevalence of 1%, gastric band migration is an uncommon complication after gastric banding. Migrated bands can be removed using a gastrointestinal endoscopic approach which has, according to the current literature, a low complication rate. In our series we show that this procedure is not without risk.

Research frontiers

Due to a growing number of patients undergoing bariatric surgery both short and long term complications will occur more often. One of the most grave complications is gastric band migration. In order to treat these patients in a safe way one should know the risks of the available treatment options.

Innovations and breakthroughs

This article shows that patients with hematemesis or melena due to gastric band migration are not suitable for gastroscopic band removal.

Applications

Patients with hematemesis or melena due to gastric band migration require a laparoscopic band removal.

Peer-review

This is a very interesting clinical study, which may be interesting for bariatrists and gastroenterologists who in their practice meet such practical problems as described in this article. Only need to supplement bibliography with recent literature of topic.

REFERENCES

- 1 **Allen JW.** Laparoscopic gastric band complications. *Med Clin North Am* 2007; **91**: 485-497, xii [PMID: 17509391]
- 2 **Angus LD,** Rizvon K, Zhou D, Seitelman E, Cardoza S. Intra-gastric band erosion from an un-inflated Lap-Band: a case report. *Obes Surg* 2008; **18**: 1636-1639 [PMID: 18636302 DOI: 10.1007/s11695-008-9618-4]
- 3 **Brethauer SA,** Kothari S, Sudan R, Williams B, English WJ, Brengman M, Kurian M, Hutter M, Stegemann L, Kallies K, Nguyen NT, Ponce J, Morton JM. Systematic review on reoperative bariatric surgery: American Society for Metabolic and Bariatric Surgery Revision Task Force. *Surg Obes Relat Dis* 2014; **10**: 952-972 [PMID: 24776071 DOI: 10.1016/j.soard.2014.02.014]
- 4 **Gagner M,** Milone L, Yung E, Broseus A, Gumbs AA. Causes of early mortality after laparoscopic adjustable gastric banding. *J Am Coll Surg* 2008; **206**: 664-669 [PMID: 18387472 DOI: 10.1016/j.jamcollsurg.2007.11.014]
- 5 **Basa NR,** Dutton E, Lewis C, Derezin M, Han S, Mehran A. Laparoscopic transgastric removal of eroded adjustable band: a novel approach. *Surg Obes Relat Dis* 2008; **4**: 194-197 [PMID: 18359458 DOI: 10.1016/j.soard.2007.12.012]
- 6 **Bueter M,** Thalheimer A, Meyer D, Fein M. Band erosion and passage, causing small bowel obstruction. *Obes Surg* 2006; **16**: 1679-1682 [PMID: 17217647]
- 7 **Chousleb E,** Szomstein S, Lomenzo E, Higa G, Podkamani D, Soto F, Zundel N, Rosenthal R. Laparoscopic removal of gastric band after early gastric erosion: case report and review of the literature. *Surg Laparosc Endosc Percutan Tech* 2005; **15**: 24-27 [PMID: 15714152]
- 8 **Lattuada E,** Zappa MA, Mozzi E, Fichera G, Granelli P, De Ruberto F, Antonini I, Radaelli S, Roviario G. Band erosion following gastric banding: how to treat it. *Obes Surg* 2007; **17**: 329-333 [PMID: 17546840]
- 9 **Meir E,** Van Baden M. Adjustable silicone gastric banding and

- band erosion: personal experience and hypotheses. *Obes Surg* 1999; **9**: 191-193 [PMID: 10340777]
- 10 **Niville E**, Dams A, Vlasselaers J. Lap-Band erosion: incidence and treatment. *Obes Surg* 2001; **11**: 744-747 [PMID: 11775574]
 - 11 **Niville E**, Dams A, Van Der Speeten K, Verhelst H. Results of lap rebanding procedures after Lap-Band removal for band erosion -- a mid-term evaluation. *Obes Surg* 2005; **15**: 630-633 [PMID: 15946452]
 - 12 **Regusci L**, Groebli Y, Meyer JL, Walder J, Margalith D, Schneider R. Gastroscopic removal of an adjustable gastric band after partial intragastric migration. *Obes Surg* 2003; **13**: 281-284 [PMID: 12740139]
 - 13 **Vertruyen M**, Paul G. 11-cm Lap-Band System placement after history of intragastric migration. *Obes Surg* 2003; **13**: 435-438 [PMID: 12841907]
 - 14 **Baldinger R**, Mluench R, Steffen R, Ricklin TP, Riedtmann HJ, Horber FF. Conservative management of intragastric migration of Swedish adjustable gastric band by endoscopic retrieval. *Gastrointest Endosc* 2001; **53**: 98-101 [PMID: 11154501]
 - 15 **Hainaux B**, Agneessens E, Rubesova E, Muls V, Gaudissart Q, Moschopoulos C, Cadière GB. Intragastric band erosion after laparoscopic adjustable gastric banding for morbid obesity: imaging characteristics of an underreported complication. *AJR Am J Roentgenol* 2005; **184**: 109-112 [PMID: 15615959]
 - 16 **Karmali S**, Sweeney JF, Yee K, Brunicardi FC, Sherman V. Transgastric endoscopic rendezvous technique for removal of eroded Molina gastric band. *Surg Obes Relat Dis* 2008; **4**: 559-562 [PMID: 18586561 DOI: 10.1016/j.soard.2008.03.248]
 - 17 **Chevallier JM**, Zinzindohoué F, Douard R, Blanche JP, Berta JL, Altman JJ, Cugnenc PH. Complications after laparoscopic adjustable gastric banding for morbid obesity: experience with 1,000 patients over 7 years. *Obes Surg* 2004; **14**: 407-414 [PMID: 15072664]
 - 18 **Silecchia G**, Restuccia A, Elmore U, Polito D, Perrotta N, Genco A, Bacci V, Basso N. Laparoscopic adjustable silicone gastric banding: prospective evaluation of intragastric migration of the lap-band. *Surg Laparosc Endosc Percutan Tech* 2001; **11**: 229-234 [PMID: 11525366]
 - 19 **Suppiah A**, Hamed M, Millson C, Pollard S. Caution in using a unique technique of banded revision gastric bypass: Successful endoscopic and surgical management of a rare complication. *Int J Surg Case Rep* 2013; **4**: 554-557 [PMID: 23624361 DOI: 10.1016/j.ijscr.2013.02.020]
 - 20 **Ventienen B**, Vaneerdeweg W, D'Hoore A, Hubens G, Chapelle T, Eyskens E. Intragastric erosion of laparoscopic adjustable silicone gastric band. *Obes Surg* 2000; **10**: 474-476 [PMID: 11054255]
 - 21 **Iqbal M**, Manjunath S, Seenath M, Khan A. Massive upper gastrointestinal hemorrhage: an unusual presentation after laparoscopic adjustable gastric banding due to erosion into the celiac axis. *Obes Surg* 2008; **18**: 759-760 [PMID: 18392905 DOI: 10.1007/s11695-007-9359-9]
 - 22 **Campos J**, Ramos A, Galvão Neto M, Siqueira L, Evangelista LF, Ferraz A, Ferraz E. Hypovolemic shock due to intragastric migration of an adjustable gastric band. *Obes Surg* 2007; **17**: 562-564 [PMID: 17608275]
 - 23 **De Roover A**, Detry O, Coimbra C, Hamoir E, Honoré P, Meurisse M. Pylephlebitis of the portal vein complicating intragastric migration of an adjustable gastric band. *Obes Surg* 2006; **16**: 369-371 [PMID: 16545171]
 - 24 **Tyrell R**, Kukar M, Dring R, Gadaleta D. Simultaneous gastric and colonic erosion of gastric band. *Am Surg* 2014; **80**: E14-E16 [PMID: 24401501]
 - 25 **Gómez-Senent S**, Froilán-Torres C, Adán-Merino L, De Parga JM. Silastic silicone rubber band migration: an unusual complication resolved by endoscopy. *Gastrointest Endosc* 2008; **68**: 150 [PMID: 18402954 DOI: 10.1016/j.gie.2008.01.003]
 - 26 **Taskin M**, Zengin K, Unal E. Intraluminal duodenal obstruction by a gastric band following erosion. *Obes Surg* 2001; **11**: 90-92 [PMID: 11361175]
 - 27 **Ayloo S**, Bueno R. Band erosion: laparoscopic removal of lap-band. *Surg Endosc* 2009; **23**: 657-658 [PMID: 19057961 DOI: 10.1007/s00464-008-0194-4]
 - 28 **Nocca D**, Frering V, Gallix B, de Seguin des Hons C, Noël P, Foulonge MA, Millat B, Fabre JM. Migration of adjustable gastric banding from a cohort study of 4236 patients. *Surg Endosc* 2005; **19**: 947-950 [PMID: 15920690]
 - 29 **Evans JA**, Williams NN, Chan EP, Kochman ML. Endoscopic removal of eroded bands in vertical banded gastroplasty: a novel use of endoscopic scissors (with video). *Gastrointest Endosc* 2006; **64**: 801-804 [PMID: 17055879]
 - 30 **Weiss H**, Nehoda H, Labeck B, Peer R, Aigner F. Gastroscopic band removal after intragastric migration of adjustable gastric band: a new minimal invasive technique. *Obes Surg* 2000; **10**: 167-170 [PMID: 10782179]
 - 31 **Wylezol M**, Sitkiewicz T, Gluck M, Zubik R, Pardela M. Intra-abdominal abscess in the course of intragastric migration of an adjustable gastric band: a potentially life-threatening complication. *Obes Surg* 2006; **16**: 102-104 [PMID: 16417767]

P- Reviewer: Bugaj AM, Kumaran SV, Lorenzo-Zuniga V
S- Editor: Gou SX **L- Editor:** A **E- Editor:** Wang CH





Published by **Baishideng Publishing Group Inc**

8226 Regency Drive, Pleasanton, CA 94588, USA

Telephone: +1-925-223-8242

Fax: +1-925-223-8243

E-mail: bpgoffice@wjgnet.com

Help Desk: <http://www.wjgnet.com/esps/helpdesk.aspx>

<http://www.wjgnet.com>



ISSN 1007-9327

