1087

THE AUTONOMIC INNERVATION OF THE NASAL MUCOSA

J. J. Grote

THE AUTONOMIC INNERVATION OF THE NASAL MUCOSA

THE AUTONOMIC INNERVATION OF THE NASAL MUCOSA

PROEFSCHRIFT TER VERKRIJGING VAN DE GRAAD VAN DOCTOR IN DE GENEESKUNDE AAN DE KATHOLIEKE UNIVERSITEIT TE NIJMEGEN, OP GEZAG VAN DE RECTOR MAGNIFICUS PROF. MR. F. J. F. M. DUYNSTEE VOLGENS BESLUIT VAN HET COLLEGE VAN DE DECANEN IN HET OPENBAAR TE VERDEDIGEN OP VRIJDAG 1 NOVEMBER 1974, DES NAMIDDAGS TE 4 UUR, DOOR

JOHANNES JAKOBUS GROTE
GEBOREN TE UITHUIZEN

1974
KRIPS REPRO – MEPPEL

Promotor: PROF. DR. W. F. B. BRINKMAN
Co-Referent: DR. W. KUIJPERS

ACKNOWLEDGEMENTS

The author is extremely grateful to Dr. P. L. M. Huygen, Miss D. P. C. Wilberts and Mr. T. H. W. Janssen from the research laboratory of the ENT Department for all their help throughout the course of this investigation.

I am particularly indebted to Drs. A. A. J. Verhofstad and Mr. H. W. J. Joosten from the department of anatomy (Head: Prof. Dr. H. J. Lammers) for their help and advice in preparing tissues for the demonstration of noradrenaline and in making micrographs with the fluorescence microscope.

I am also greatly indebted to Dr. P. H. K. Jap and Mr. G. Beukenkamp from the department of cyto-histology (Head: Prof. Dr. C. R. Jerusalem) for the performance of the E.M. part of this study. The assistance of Mr. P. Spaan and coworkers from the central animal laboratory. (Head: Dr. W. J. v.d. Gulden) was greatly appreciated. The diagrams were prepared by Mr. J. Konings from the department of medical illustration (Head: Mr. J. de Becker). I am very grateful to Mr. F. H. A. Bruggeman for taking care of the styling and lay-out of the manuscript.

This investigation was carried out under the direction of Dr. W. Kuijpers, head of the research laboratory of the ENT Department of the University of Nijmegen (Head: Prof. Dr. W. F. B. Brinkman).

The financial support from the foundation 'De drie lichten' for the publication of this thesis was greatly appreciated.

CONTENTS

GENERAL INTRODUCTION

Apart from its olfactory function the nose has an important function in filtering, thermal regulation and humidification of inspired air.

The autonomic nervous system is supposed to play an important role in this regulatory mechanism of the respiratory part of the nasal mucous membrane. 'Vasomotor rhinitis' – characterised by symptoms such as nasal obstruction, watery rhinorrhoea and sneezing which are not caused by anatomical deformities, allergy or infection – is suggested to originate from an 'imbalance' of the autonomic nervous system of the nose through a predominance of parasympathetic innervation.

The autonomic ganglion from which the autonomic fibres course to the respiratory part of the nasal mucosa is the pterygopalatine ganglion. Various methods directed towards inactivation of this ganglion have been attempted in the treatment of vasomotor rhinitis.

In the last decade transection of the vidian nerve (n canalis pterygoidei), the main pathway through which parasympathetic fibres reach the pterygopalatine ganglion and thence the nose, has been advocated as the surgical therapy of choice for vasomotor rhinitis and even for allergic rhinitis. Good results have been reported with this method (Golding-Wood, 1961, 1962, 1963, 1973; Hiranandani, 1966; Montgomery, 1970; Wentges, 1973). However there is little basic physiological knowledge of the behaviour of the nasal mucosa both under normal circumstances and after denervation.

The purpose of this study was to trace the precise course of the autonomic nerve fibres both inside and outside the nasal cavity and their effect on the behaviour of the nasal mucosa by means of selective denervation of the nerves involved. The first part of this thesis consists of a survey of the literature. The second part describes the anatomy and histology of the nasal structures in the rat and the third part, the effect of selective transection of the appropriate nerves on the behaviour of the nasal mucous membrane.

CHAPTER I

HISTORICAL REVIEW

After the observation of Galen (ca. 130–200 AD) that the nose was not only the organ of smell but also a very important part of the respiratory system, little interest was taken in the physiology of the nose, until, in the nineteenth century, considerable progress was made in discovering the function of the autonomic nervous system especially through the work of Bichat (1802), Claude Bernard (1853) and Gaskell (1886) and Langley (1903).

The studies of Prévost (1868) on the physiology of the pterygopalatine ganglion concurred with the results of fundamental research of the autonomic nervous system. He concluded from his experiments in dogs the existence of autonomic fibres in the vidian nerve running to the pterygopalatine ganglion and thence to the nose. After electric stimulation of this ganglion he demonstrated a temperature rise in the homolateral nasal cavity and increased serous secretion. No trophic changes in the nasal mucosa were observed after extirpation of the pterygopalatine ganglion.

At the end of the nineteenth century the work of Zwaardemaker (1889) focused new interest on nasal physiology. He developed a method by which the patency of the nasal cacity could be measured (the 'mirror technique'). Sluder described in a series of reports (1908, 1909, 1910a, b, 1911, 1927) the conception, derived from clinical observations, that certain types of headache were caused by a neuralgia of the pterygopalatine ganglion. This autonomic syndrome, called 'the sphenopalatine ganglion neurosis syndrome' is characterised by sneezing, narrowing of the nasal cavity, watery rhinorrhoea, epiphora and widening of the pupil. Referring to this publication a great number of reports were published, in which blockage of the pterygopalatine ganglion was advocated as a cure for a wide range of diseases, including different types of headaches, glaucoma, blepharospasm, itching of the auditory canal, otalgia, dizziness, glossodynia, cricodynia, neuralgia of the trigeminal nerve, lumbago, etc. This development towards using blockage of the pterygopalatine ganglion as a 'miracle cure' was criticized by Ramadier (1924) and Burger (1927a, b).

The first experiments on the nervous control of nasal blood vessels were carried out by Tschallussow in 1913. In order to show changes in the size of the nasal vessels he converted the nose into a closed chamber by blocking its anterior and posterior openings, the change in the enclosed volume being recorded with a tambour In this way he studied the effect of stimulation of the autonomic nerves as well as the reflex responses elicited by stimulating afferent nerves in other parts of the body He demonstrated that stimulation of fibres in the whole sympathetic chain resulted in vasoconstriction in the nose, while stimulation of the parasympathetic fibres in the vidian nerve gave rise to vasodilatation of the nasal vessels If nicotine was applied to the pterygopalatine ganglion the vasodilatation was converted to vasoconstriction

Martin and Mendenhall (1915), inspired by the work of Tschallussow, investigated the effect of sensory stimuli on nasal volume They investigated the patency of the nasal cavity in the cat after electrical stimulation of peripheral sensory nerves from the branches of the brachial and sciatic trunks A weak stimulus appeared to cause vasodilatation in the nose, registered by rhinomanometry as a decrease in patency, while a stronger stimulus caused vasoconstriction, with an increase in the patency of the nose

Tatum (1923) demonstrated that asphyxia caused reflex vasoconstriction, resulting in an increase of the patency of the nose The same observation was made by Stemberg in 1925

Jung et al (1925) were able to confirm the results of Prevost (1868) that stimulation of the pterygopalatine ganglion caused hypersecretion in the nose

Blier (1930) reviewed the experiments of Tschallussow (1913) and concluded in the dog the presence of vasoconstrictive fibres in the posterior nasal nerve, as well as in the vidian nerve No vasoconstriction could be elicited after extirpation of the superior cervical ganglion He stated that sympathetic fibres in the dog run to the nose from the superior cervical ganglion via the carotid nerve plexus A minor part was concluded to pass by way of the deep petrosal nerve to the vidian nerve and thence to the nose, the major portion, however, reaching the nose via the maxillary nerve He suggested that the contact between the perivascular sympathetic plexus and the trigeminus probably occurred in the cavernous sinus

From a histological study of the pterygopalatine ganglion and the afferent and efferent nerves after denervation, Christensen (1934) concluded that the vidian nerve contains both sympathetic and parasympathetic fibres Fowler (1943) described a patient with a Horner syndrome on the left side, caused by a cervival sympathectomy This patient also complained of sneezing, nasal obstruction and watery rhinorrhoea on the same side In examining the nose Fowler also observed hyperaemia and swelling of the nasal mucosa and eosinophilia, the symptoms of a vasomotor rhinitis. After resection of the greater petrosal nerve in the treatment of unilateral headache, Gardner et al. (1947) observed excessive dryness and crusting in the nose while the mucous membrane was shrunken compared with the control side. However, no clear answer could be given concerning the mechanism underlying the nasal symptoms occurring in vasomotor rhinitis.

Malcolmson (1959) made an important contribution to the physiology of the nose with his rhinomanometric investigation of the effect of electrical stimulation on the nerves supplying the nasal cavity in cats. He demonstrated the existence of preganglionic fibres coursing to the pterygopalatine ganglion in the greater superficial petrosal nerve, as well as the origin of the postganglionic sympathetic fibres in the superior cervical ganglion. Moreover the conclusion was drawn that the vidian nerve was a mixed nerve consisting of parasympathetic and sympathetic fibres. Weak stimulation of this nerve appeared to result in vasodilation and increased resistance of the nose, suggesting dominance of the parasympathetic fibres. Stronger stimulation resulted in vasoconstriction and reduction of nasal resistance suggesting dominance of the sympathetic fibres. According to these experimental findings, suggesting predominance of the parasympathetic fibres in the vidian nerve, Malcolmson (1959) performed a neurectomy of the vidian nerve in a patient with vasomotor rhinitis. Although immediate postoperative relief was observed, the unsatisfactory results after a longer period lead to the conclusion that vidian nerve transection, in spite of the physiological basis presented, should be regarded as a last expedient in this condition until experience has defined its precise indications and limitations.

Inspired by the work of Malcolmson, Golding-Wood (1961, 1963, 1973) developed the surgery of the pterygopalatine fossa via the maxillary sinus in order to transect the vidian nerve in cases of severe vasomotor rhinitis and even in cases of allergic rhinitis. Good results have been reported with this method in the treatment of vasomotor rhinitis in the last decade. However, the results obtained in cases of allergic rhinitis are less convincing (Hiranandani, 1966; Chandra, 1969; Montgomery et al., 1970; Gregson, 1970; Krajina, 1973; Wentges, 1973).

This surgical development again aroused interest in the physiology of the respiratory part of the nose. Jackson and Rooker (1969, 1971) repeated the experiments of Malcolmson (1959) in dogs. From their experiments they concluded that the vidian nerve contains only or almost only parasympathetic fibres, while the sympathetic fibres were supposed to reach the nasal mucous membrane via the blood vessels and the maxillary nerve. The biphasic reaction observed in the cat by Malcolmson after stimulation of the vidian nerve was explained by the fact that with larger electrical stimuli sympathetic fibres outside the vidian nerve must be activated. Krajina et al. (1972) reported clinical symptoms typical of vasomotor rhinitis after cervical sympathectomy in dogs, while morphological changes in the mucosal vessels and glands were observed on biopsy specimens five days after cervical sympathectomy in a few animals.

In recent years the innervation pattern of the structures of the nasal mucous membrane has been investigated by means of histochemical and fluorescence techniques. Dahlström and Fuxe (1965) demonstrated the presence of adrenergic nerve fibres in the wall of the nasal vessels. Ishii and Toriyama (1972) and Nomura and Matsuura (1972) showed the presence of acetylcholinesterase-containing fibres around the mucosal vessels and glands.

In summary, the results reported indicate that the autonomic nervous system plays a very important role in the behavior of the respiratory part of the nasal mucous membrane. Elimination of the sympathetic system or stimulation of the parasympathetic system gives rise to symptoms comparable to those observed in vasomotor rhinitis, and elimination of the parasympathetic system shows the opposite effect. It is mainly from these physiological observations that the present model of the course of the autonomic nerve supply of the nose is derived. The pterygopalatine ganglion is thought to be the autonomic ganglion from which the autonomic nerve fibres course to the nose. The superior cervical ganglion is assumed to be the main source of the sympathetic nerve fibres, and the greater superficial petrosal nerve to be the main parasympathetic nerve trunk. However, anatomical data on the precise course of the autonomic nerve supply and its distribution in the nasal mucosa are extremely scarce, as are the postoperative effects of selective transection of the autonomic nerve supply.

The present study was undertaken to elucidate the precise course of the autonomic nerve fibres, their innervation pattern of the nasal mucosa and their role on the behaviour of the mucosa. These problems were studied in normal rats and in rats in which the appropriate nerve supply was selectively transected.

CHAPTER II

METHODS

1. SURGICAL

The experiments were performed on Wistar rats (about 200 g body weight). The animals were anaesthetised with nembutal (30 mg/kg body weight) administered intraperitoneally. A diagram of the generally accepted course of the autonomic nerve supply of the nose in mammals, mainly composed from previous physiological observations, is shown in Fig. 1. The Arabic numerals in this diagram refer to the places where the nerves were severed. Denervation was performed unilaterally and bilaterally. The following operations were carried out.

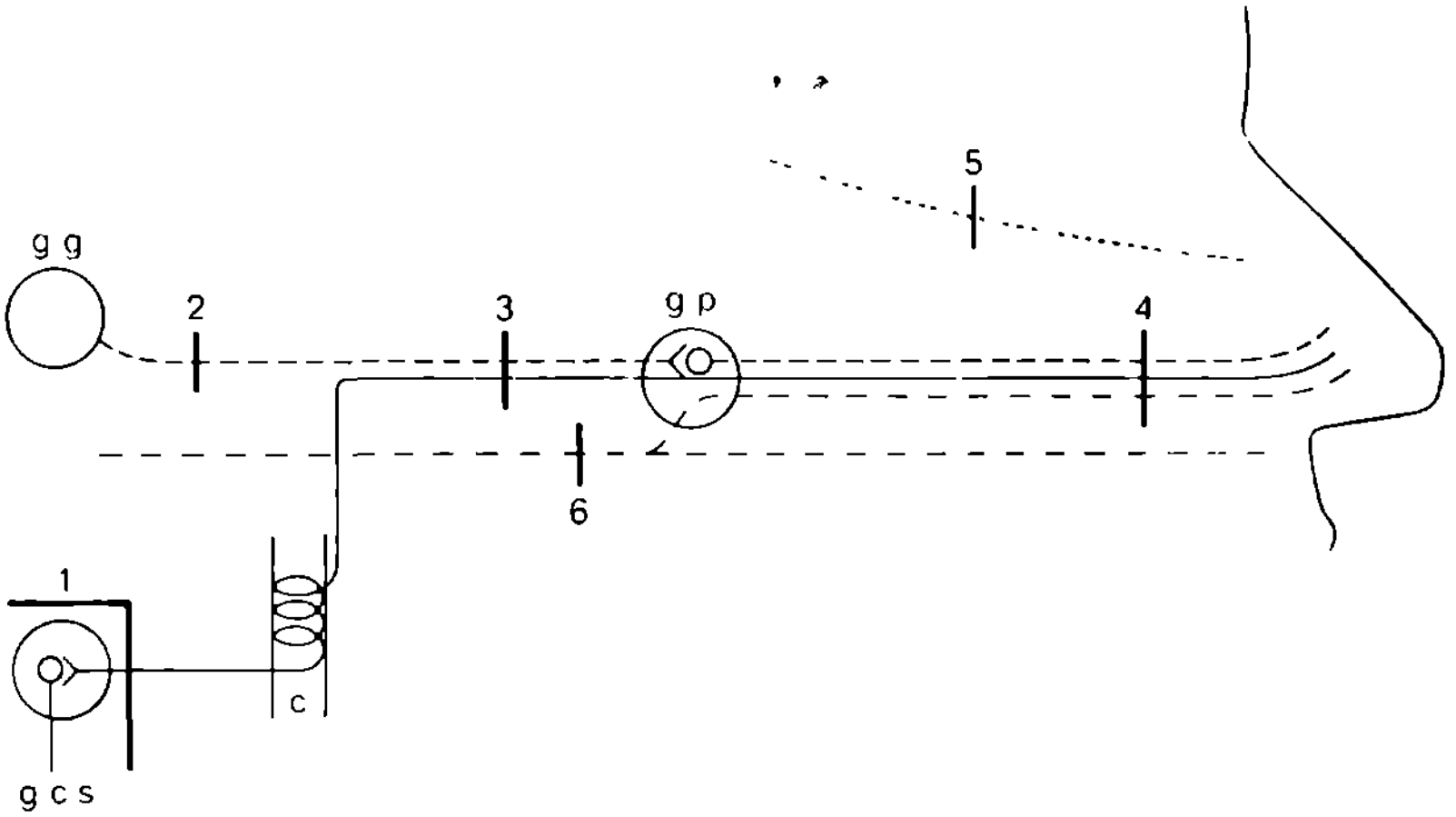

Fig. 1. Diagrammatic representation of the generally accepted course of the autonomic nerve supply to the nose. g.g.: geniculate ganglion; g.c.s.: superior cervical ganglion; c: carotid artery, g.p.: pterygopalatine ganglion.

The Arabic figures refer to the places where the nerves were transected (see text). – – – – – – parasympathetic fibres; ———— sympathetic fibres; — — — — — sensory fibres; - - - - - - ethmoidal nerve.

(a) Extirpation of the superior cervical ganglion (1)

This ganglion is considered to be the main source of sympathetic innervation to the nose. The superior cervical ganglion, situated near the bifurcation of the carotid artery, was reached by a ventral incision in the neck. The ganglion was extirpated and the carotid plexus, which originates from this ganglion, was stripped.

(b) Transection of the greater petrosal nerve (2)

This nerve is thought to contain the preganglionic parasympathetic nerve fibres coursing to the pterygopalatine ganglion. The greater superficial petrosal nerve was transected in the middle ear anterior to the geniculate ganglion (Fig. 2). The middle ear was reached by a supra-auricular skin incision. The muscles were separated from the external meatus until the bony annulus was reached. After removal of the tympanic membrane the ossicular chain and tensor tympani, a full view was obtained in the middle ear cavity. The ganglion is situated between the oval window and the fossa

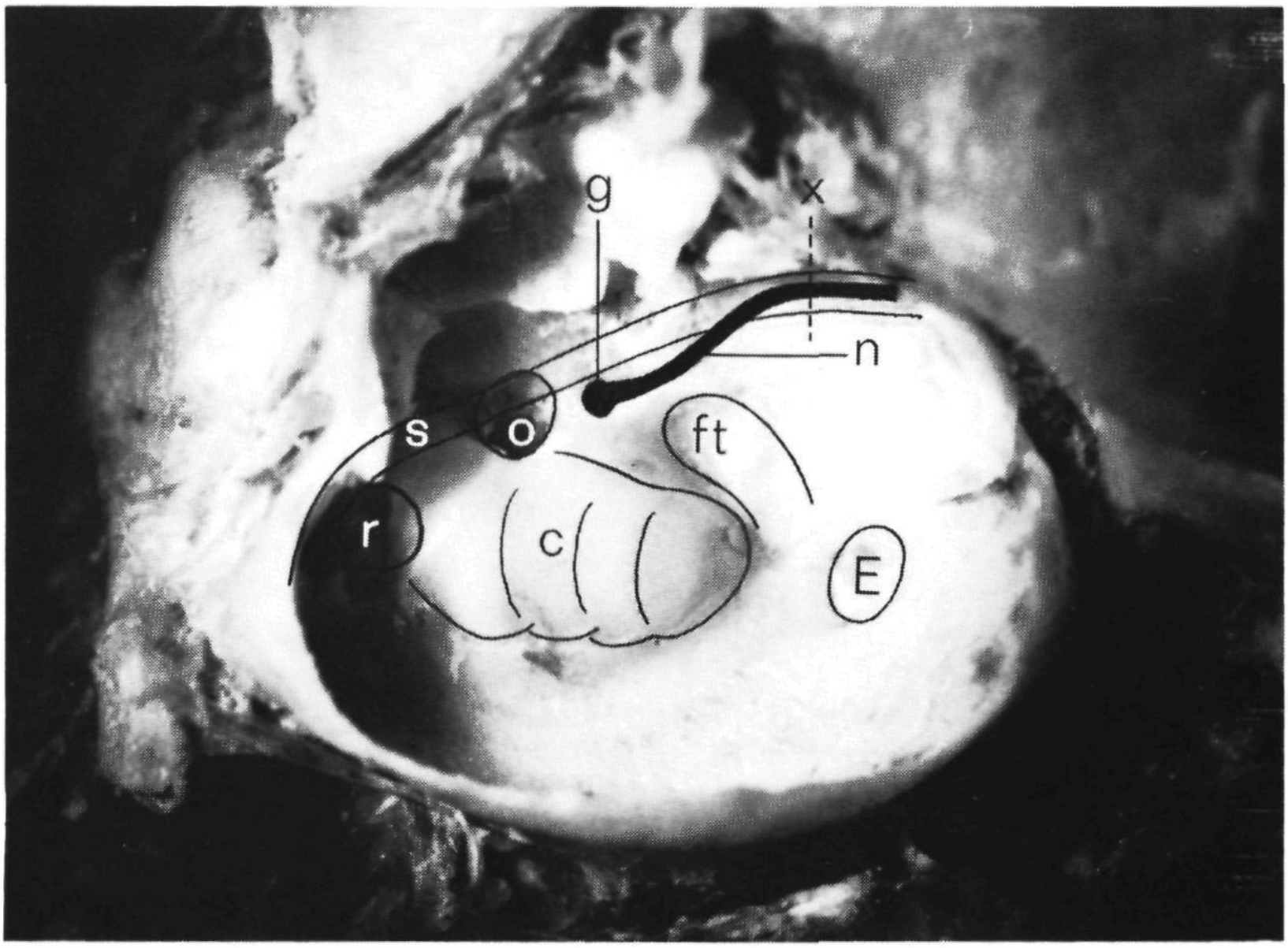

Fig. 2. Survey of the middle ear cavity after removal of the lateral wall in order to show the location of the geniculate ganglion and the course of the greater petrosal nerve. c.: cochlea; g.: geniculate ganglion; n.: greater petrosal nerve; E.: Eustachian tube; r.: round window; o.: oval window; s.: stapedial artery; ft: fossa of the tensor tympani muscle; x: place of transection.

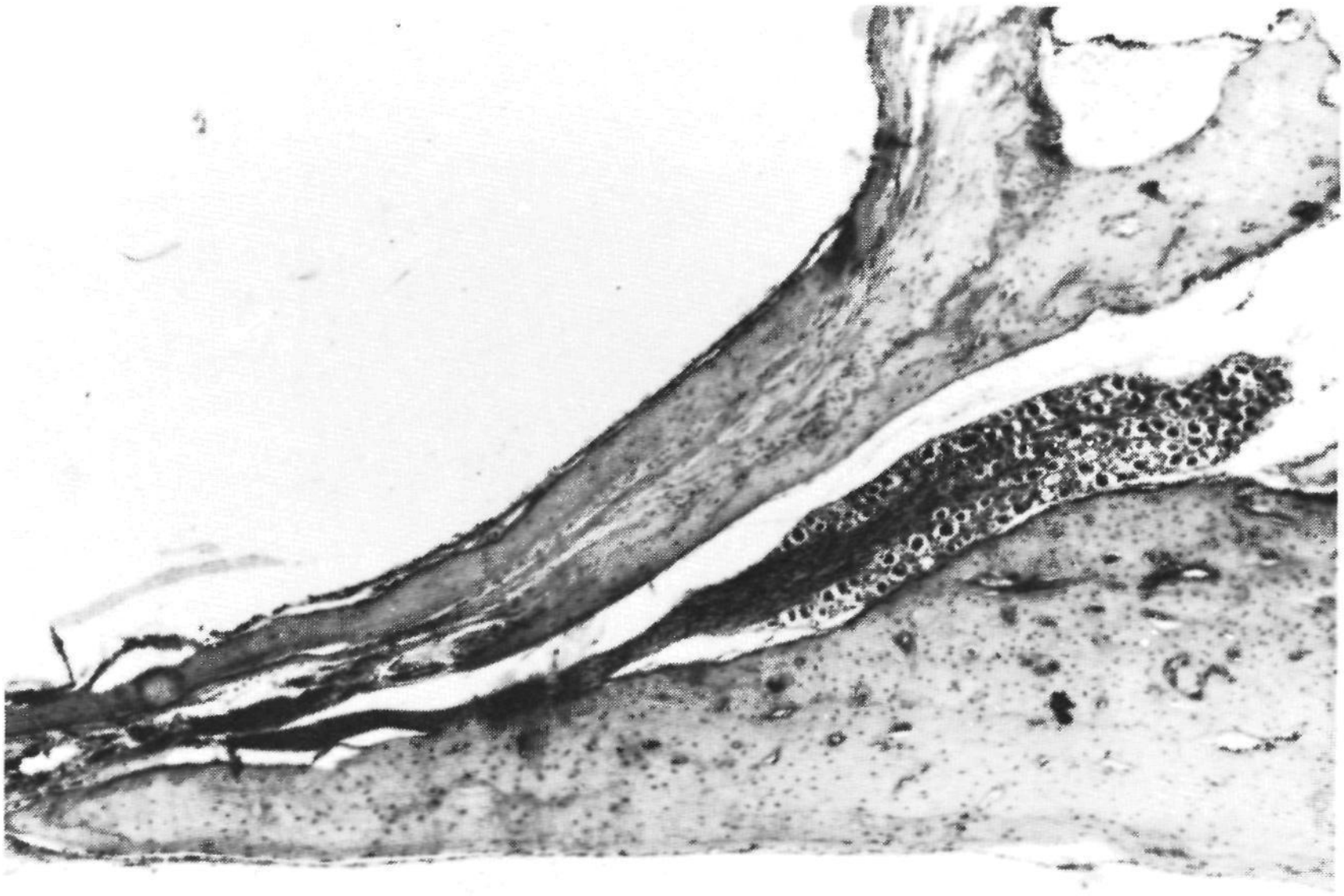

Fig. 3. Section through the dorsomedial part of the wall of the middle ear, showing the greater petrosal nerve leaving the geniculate ganglion.

of the muscle of the tensor tympani (Fig. 2). The greater petrosal nerve leaves the ganglion and runs forward with the stapedial artery. Fig. 3 shows a section through the dorsomedial wall of the middle ear including the superficial petrosal nerve leaving the geniculate ganglion.

(c) Transection of the vidian nerve (n. canalis pterygoidei) (3)

This nerve is thought to contain the parasympathetic preganglionic fibres originating from the greater superficial nerve (Tschallussow, 1913), about the sympathetic content of which there is some diversity of opinions. According to Blier (1930), and Jackson and Rooker (1971) only a minor part, if any, of the postganglionic sympathetic fibres should run to the nose via the vidian nerve. Christensen (1934) and Malcolmson (1959) were of the opinion that the vidian nerve contains the main part of the postganglionic sympathetic fibres coursing to the nose, as well as the preganglionic parasympathetic fibres. The postganglionic sympathetic fibres originating in the superior cervical ganglion are supposed to reach the vidian nerve via the deep petrosal nerve, however, we were unable to identify this nerve in the rat. In this animal the vidian nerve is situated in the pterygopalatine groove

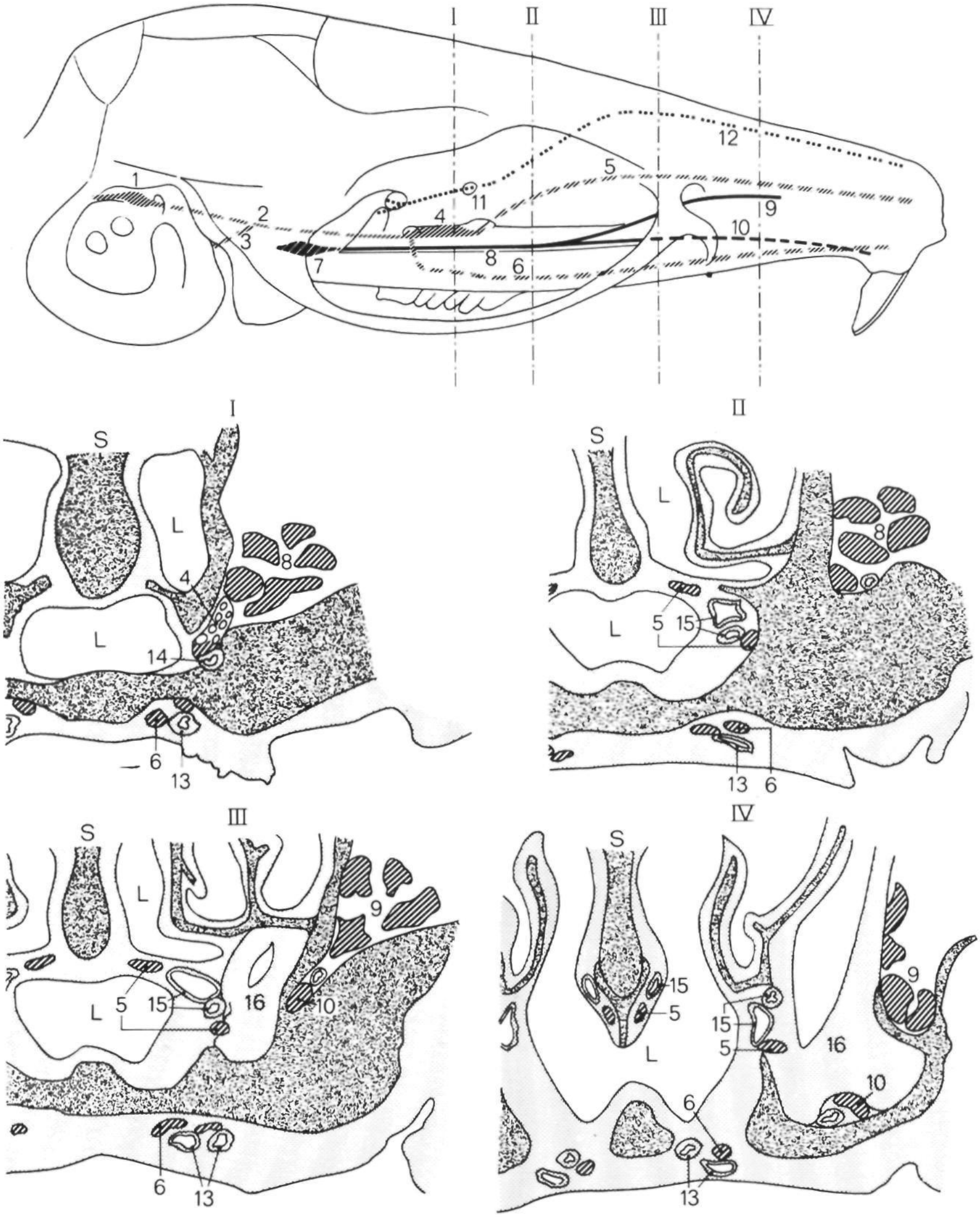

Fig. 4. Schematic drawing of the course of the nerves innervating the nasal mucosa and adjacent structures. The Roman numerals indicate the region from which the coronal sections originate. For technical reasons the ethmoidal nerve is not indicated in the sections.

1. Greater petrosal nerve leaving the geniculate ganglion; 2. vidian nerve (n. canalis pterygoidei); 3. deep petrosal nerve (not demonstrated experimentally); 4. pterygopalatine ganglion; 5. pterygopalatine nerve; 6. posterior superior alveolar nerve; 7. Gasserian ganglion; 8. maxillary nerve; 9. infraorbital nerve; 10. anterior superior alveolar nerve; 11. ethmoidal foramen; 12. ethmoidal nerve; 13. descending palatine artery and accompanying vein; 14. pterygopalatine artery; 15. sphenopalatine artery and accompanying vein; 16. gland of Steno; L.: nasal lumen; S.: nasal septum.

(the nerve content of which is shown in Fig. 4). Transection of the vidian nerve was carried out through the orbit. Therefore a midline incision was made in the orbital region down to the bony skull. The soft tissues were separated from the skull and then from the medial wall of the orbit. Subsequently the orbital contents were retracted until the maxillary nerve was seen. The vidian nerve situated immediately inferior to the maxillary nerve, was identified and transected proximal to the pterygopalatine ganglion.

(d) Transection of the pterygopalatine nerve (4)

The pterygopalatine nerve is assumed to contain postganglionic parasympathetic and sympathetic fibres originating from the pterygopalatine ganglion, as well as sensory fibres from the maxillary nerve (Blier, 1930; Malcolmson, 1959; Jackson and Rooker, 1971). This nerve was approached in the same way as the vidian nerve. Transection was carried out just proximal to where this nerve enters the sphenopalatine foramen (Figs. 4 and 5).

(e) Transection of the ethmoidal nerve (5)

In the rat the ethmoidal nerve supplies a minor portion of the anterosuperior part of the nasal mucosa. According to Mitchell (1954), this nerve mainly comprises sensory fibres from the trigeminal nerve with a small proportion of autonomic fibres. It is not yet clear which autonomic fibres run through

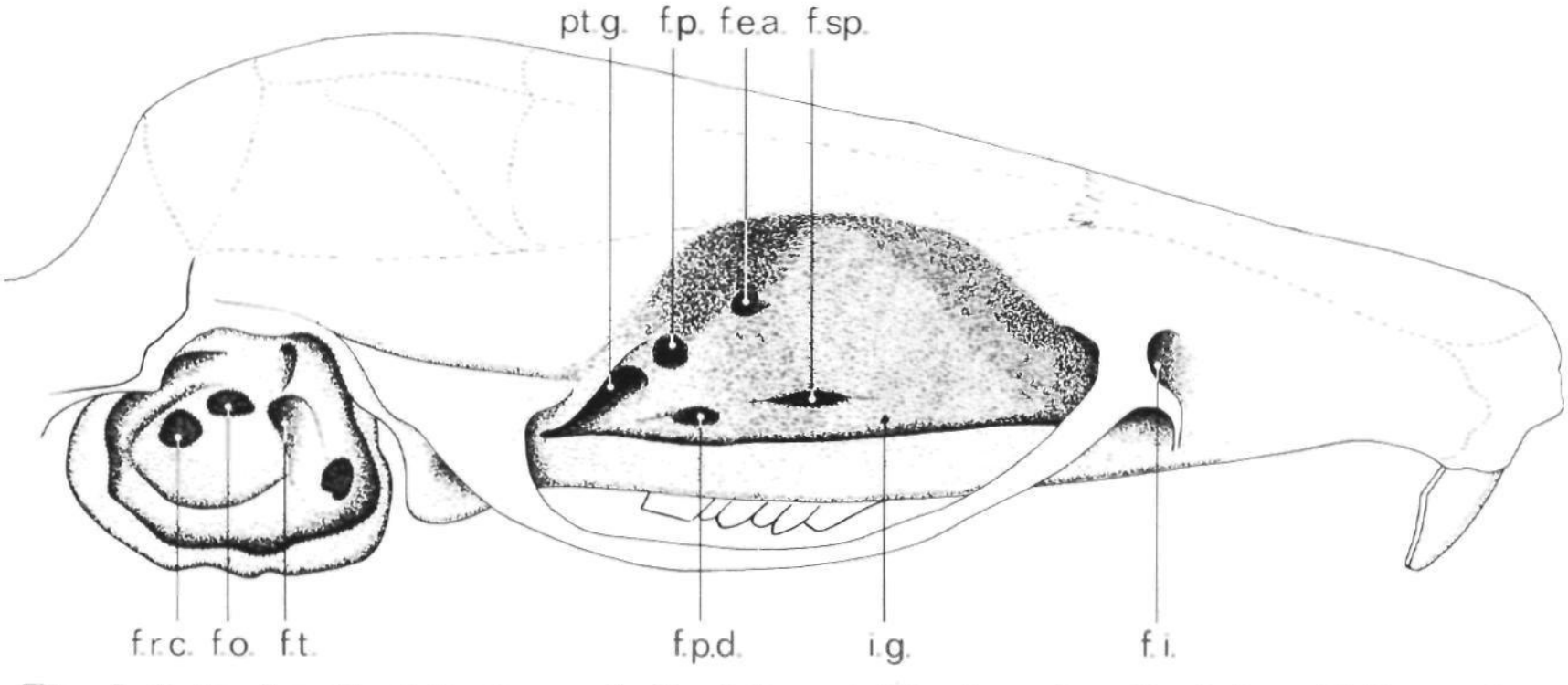

Fig. 5. Lateral wall of the bony skull of the rat. The lateral wall of the middle ear is removed. In this drawing the foramina and other structures related to the course of the autonomic nerve supply to the nose are indicated. f.r.c.: cochlear round window; f.o.: oval window; f.t.: fossa of the tensor tympani; pt.g.: pterygopalatine groove; f.p.: optical foramen; f.e.a.: anterior ethmoidal foramen; f.sp.: sphenopalatine foramen; f.p.d.: foramen of the posterior superior alveolar nerve; i.g.: infraorbital groove; f.i.: infraorbital foramen.

this nerve but undoubtedly sensory fibres from the tip of the nose belonging to the ophthalmic nerve take this course. This nerve was divided on the medial orbital wall at the level of the ethmoidal foramen (Figs. 4 and 5).

(f) The maxillary nerve (6)

Besides sensory fibres this nerve is thought to contain sympathetic fibres (Blier, 1930; Jackson and Rooker, 1971). It is postulated that these fibres enter the pterygopalatine ganglion and reach the nose via the pterygopalatine nerve. The maxillary nerve was therefore divided proximal to the pterygopalatine ganglion in the pterygopalatine groove.

2. HISTOLOGICAL

The animals were killed by an intracardial injection of nembutal and subsequently decapitated. A tissue block containing the nasal structures was dissected and fixed in formaldehyde 4%. Decalcification was performed in a mixture of equal parts of formic acid (8 N), and sodium formate (1 N) for 3 weeks. After rinsing in tap water (24 hours) the specimens were dehydrated in graded alcohols, embedded in paraffin and serially sectioned (10 μ). From each three adjacent sections one was stained with haematoxylin-eosin, one with alcian blue-neutral red and one with PAS.

In order to study the effect of fixation and dissection on the dilated state of the nasal mucosa two different methods were tested. With the first method formaldehyde solution was dropped into the nares, immediately after killing by an intracardial injection of nembutal, for about 5 minutes and then decapitated. With the second method the animals were anaesthetized with nembutal (30 mg/kg body weight) and a thoracotomy was performed. Fixation was carried out by intracardiac perfusion of Ringer's solution and subsequently of formaldehyde 4% solution. No significant differences in the dilated state of the vessels in the nasal mucosa could be observed in comparing these two methods after unilateral application of adrenalin. On the side where adrenalin was applied significant shrinkage of the nasal mucosa was observed in comparison to the normal side.

The vascular pattern of the nasal mucosa in the normal animals and after selective transection of the appropriate vessels was visualised by means of intracardiac perfusion of the anaesthetized animal with Ringer's solution and subsequently with a mixture of Indian ink and Ringer's solution (1:3). After complete perfusion the animals were decapitated and the nasal structures dissected, fixed in formaldehyde, dehydrated in alcohol and cleared with methylbenzoate.

In order to establish the localisation of the nasal glands the following method was used. The freshly dissected specimens of nasal mucosa were fixed in neutralised formaldehyde solution for one hour, rinsed for 15 minutes in tap water and stained for one hour in a saturated solution of Sudan Black B in 70% alcohol. Thereafter the specimens were rinsed in 70% alcohol for one hour, dehydrated, and cleared in glycerol.

3. PHYSIOLOGICAL

To measure the patency of the nasal cavity, the air flow through the nasal cavities was registered with the mirror technique described by Zwaardemaker (1889). This method is based on the relationship between the patency of the nasal cavity and the size of the condensation patches produced by the expired air. In order to avoid mouth breathing the lips of the animals were fixed to each other with glue one hour before the measuring procedure was started. The animals were tranquilized with diazepam (5 mg/kg body weight administered intramuscularly). To measure the size of the condensation patches, the nose of the animal was placed at the distance of about 1 cm from a mirror. The mirror was kept at a constant temperature of 14 °C, while the relative humidity of the experimental room was kept at about 70%. The size of the condensation patches produced by the air expired through both nares was compared. Each animal was tested for 105 minutes. With a test interval of 15 minutes seven consecutive tests were done. Only the data obtained from animals which failed to show any sign of an infective disease of the respiratory mucosa were used.

4. HISTOMETRICAL

In order to measure the grade of swelling of the erectile tissue of the mucosa in both halves of the nasal cavity in normal animals and after transection of the autonomic nerve supply the following method was used. Coronal serial sections were made from the respiratory region of the nose. From both halves the size of the mucosa and lumen was measured at three fixed places in the area of the erectile tissue containing parts of the maxillo- and nasoturbinates. The ratio between lumen, and lumen and mucosa was calculated. Comparison of the right and left half of the nose was performed using a lateralisation ratio (LARA) derived from the Lorenz diagram (1905)

$$\text{LARA} = \frac{2 \times \dfrac{\text{lumen R}}{\text{lumen R} + \text{mucosa R}}}{\dfrac{\text{lumen R}}{\text{lumen R} + \text{mucosa R}} \qquad \dfrac{\text{lumen L}}{\text{lumen L} + \text{mucosa L}}}$$

This parameter appeared to be normally distributed. The animals were selected using the same criteria, as described in the preceding paragraph

5. NEUROHISTOCHEMICAL

(a) Acetylcholinesterase

For the neurohistochemical studies the animals were killed by an intracardial injection of nembutal and subsequently decapitated. For the demonstration of ACh-esterase the nasal septum and the mucosa of the lateral walls were immediately frozen in liquid nitrogen. Cryostat sections (7 μ) were picked up on microscopical slides and allowed to dry at room temperature for 5 minutes. Fixation was performed in neutralized 4% formaldehyde at 4 °C for 10 minutes. Subsequently the sections were rinsed in tap water (15 minutes) and incubated in the incubation mixture described by Karnovsky and Roots (1965) at 40 °C for one hour. Unspecific cholinesterase activity was inhibited by the addition of 0 4 mM iso-OMPA (tetraisopropylpyrophosphoramide, Bayliss and Todrick, 1956) to the incubation mixture. After incubation the sections were rinsed for 10 minutes in tap water, stained for 6 minutes in Mayer's haematoxylin, dehydrated in alcohol, cleared in xylol and mounted in DPX.

For the demonstration of ACh-esterase activity in whole mount specimens the following method was developed. Immediately after decapitation the nasal mucosa was carefully separated from the nasal septum and from the lateral nasal walls with the use of a dissecting microscope. Subsequently the mucosa was squeezed between two slides, frozen and stored at −25 °C for at least 15 minutes. Thereafter the specimens were fixed with neutralized formaldehyde at 4 °C for 10 minutes, rinsed in tap water (10 minutes) and incubated for 3 hours and rinsed as outlined for sections After rinsing, the specimens were dehydrated in acetone without counterstaining, cleared in methylbenzoate and mounted in DPX. Whole mount specimens of the supplying arteries were processed in the same way.

(b) Catecholamines

Noradrenaline was demonstrated by the fluorescence technique described by Falck et al. (1962). The mucosal specimens were frozen in isopentane by liquid nitrogen and lyophilized. The lyophilized tissues were exposed to formaldehyde vapour at 60 °C for one hour in a closed vessel Paraformaldehyde powder (kept at a relative humidity of 55%) was used as the source of formaldehyde vapour. The specimens, after drying with phosphorpentoxide, were embedded in paraffin and sectioned. The sections were floated on n-butanol and blotted dry. Dewaxing was performed by exposing the sections to xylol vapour at 60 °C for one hour. The sections were mounted in DPX or fluormount and examined with the fluorescence microscope using a mercury vapour lamp (HBO 200 W), in combination with a BG 12 excitation filter to excite green fluorescence from the adrenergic elements, and studied through a yellow barrier filter.

To demonstrate noradrenaline activity in whole mount specimens of the mucosa and vessels, the freshly dissected tissues were squeezed between two slides, dried with P_2O_5, exposed to formaldehyde vapour for one hour at 85 °C, cleared with xylol and mounted in DPX.

6. ELECTRON MICROSCOPIC

The animals were killed in the same way for electron microscopic as for the neurohistochemical studies. Immediately after killing, a solution of 2.3% glutaraldehyde in 0.1 M cacodylate buffer (pH 7.0–7.2) was instilled in the nasal cavity. After decapitation the lower jaw and brain tissue was removed, and subsequently the nasal cavity opened. Thereafter the nasal septum was dissected and the respiratory area isolated and fixed in the buffered glutaraldehyde solution for 4 hours at 4 °C. After fixation the tissue was rinsed in cacodylate buffer at 4 °C for another 4 hours. Postfixation was performed in 2% osmic acid in veronal-acetate buffer for 1 hour at 4 °C. After dehydration in graded alcohols the tissue was embedded in Epon 812 (Luft, 1961). In order to select the appropriate areas for electron microscopic studies, sections of 0.5 μ were made and either studied with the phase-contrast microscope or stained with toluidine blue (2%) and studied with the normal microscope. From the blocks selected in this way, ultra-thin sections were prepared (using a Reichert OmU3 microtome), picked up with copper grids and contrasted with a saturated solution of uranyl acetate (Watson, 1958) and subsequently with lead citrate (Reynolds, 1963). The ultra-thin sections were studied and photographed with a Philips EM 300 electron microscope.

CHAPTER III

ANATOMY OF THE RAT NOSE

1. INTRODUCTION

The rat was chosen as an experimental animal because a large series of experiments could then be performed on a homogeneous population of animals and a technique was developed by which the supplying nerves could easily be traced and transected selectively. In this chapter the anatomy and the innervation of the nose of the rat is described. The morphology of the nasal structures and the course of the supplying nerves were studied in 20 animals, using careful dissecting techniques. In addition, serial sections stained with haematoxylin-eosin, alcian blue-neutral-red and PAS were studied. The vascular pattern was investigated by filling the vessels with Indian ink in normal animals after selective transection of the appropriate arteries.

2. GROSS ANATOMY

The nasal septum divides the nasal space into two equal cavities. Each cavity can be divided into three zones with a different function, characterised by different types of epithelium on the septum and the lateral walls. The vestibule is lined by stratified squamous epithelium, forming the entrance to the nasal cavity. The respiratory area is lined with pseudostratified ciliated columnar epithelium with many goblet cells. Its main function is to protect the lower airways by filtering and conditioning the inspired air. The mucosa in this area contains many vessels and glands in order to perform this task. The olfactory area contains the olfactory epithelium with the mucous glands of Bowman.

While the nasal septum has a rather flat surface, the lateral walls have many bony extensions (turbinates) covered by the various types of epithelium related to the functional zones as previously mentioned. The inferior maxilloturbinate and the superior nasoturbinate are covered with pseudostratified epithelium and the ethmoidal turbinates with olfactory epithelium (Fig. 6). In the anteroventral part of the septum the organ of Jacobson (organum vomero-nasale) is situated. This organ consists of two paired tubes. The lumen of these tubes is lined with sensory epithelium which is innervated by branches of the olfactory nerve (Negus, 1958).

3. NERVOUS SYSTEM

In this section the generally accepted origin and course of the autonomic nerve supply of the respiratory part of the nasal mucosa in mammals (shown in Fig. 1) will be described together with findings in the rat. These findings are shown in Figs. 2–5. Fig. 5 shows the lateral surface of the bony skull with the appropriate foramina. In Fig. 4 the course of the nerve fibres is demonstrated together with diagrams of coronal sections at various levels.

The nerves supplying the nasal mucous membrane in the rat are situated in a deep groove in the ventroposterior part of the large orbitotemporal fossa, the pterygopalatine groove. This groove is the equivalent of the pterygopalatine fossa in human beings. The cranial continuation of this groove is called the infraorbital groove. The nerve bundles enter the pterygopalatine groove through the lacerated foramen, which represents a combination of the superior orbital fissure and the foramen rotundum in humans. From this area the nerve fibres course to the nose through the sphenopalatine foramen and the ethmoidal foramen.

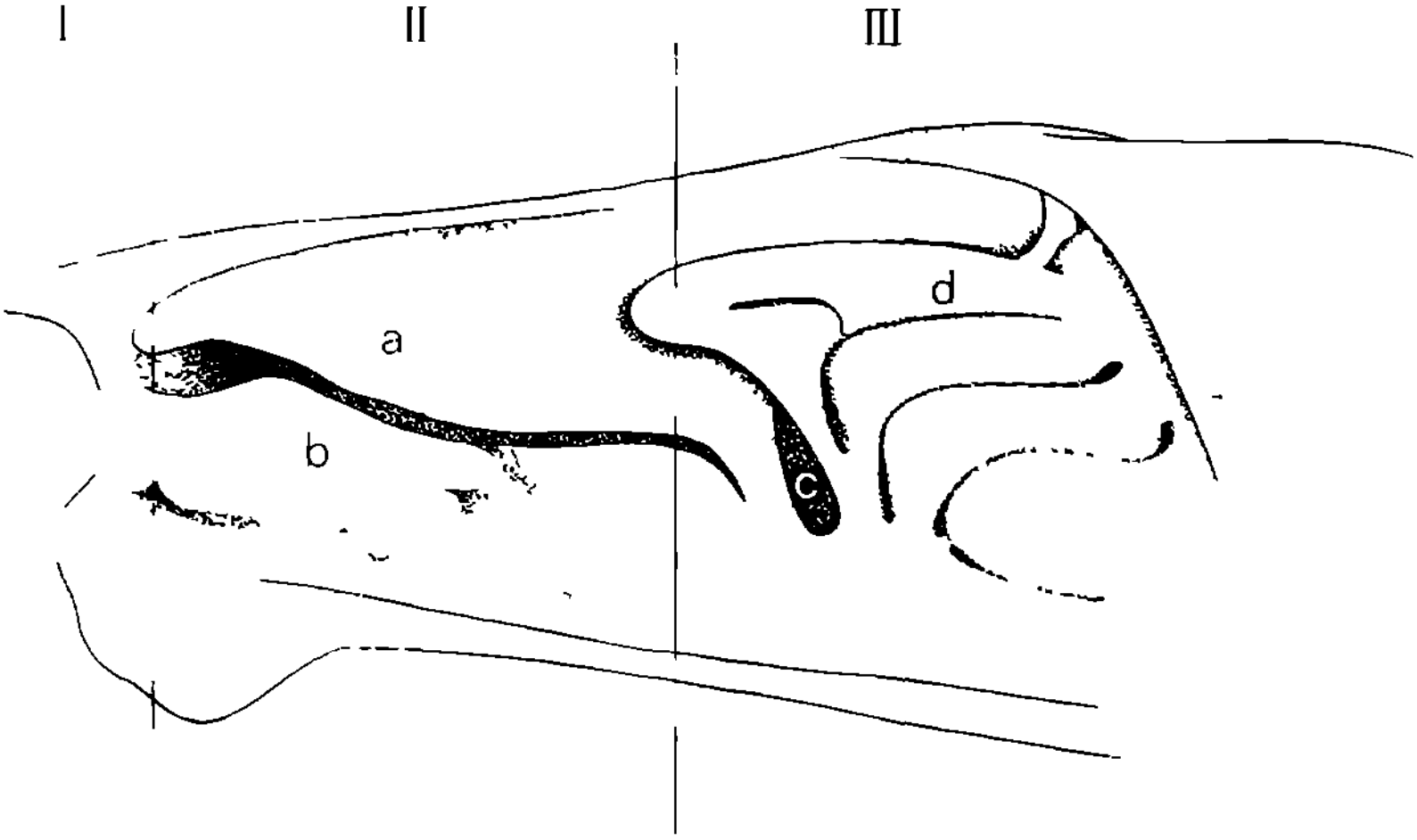

Fig. 6a. Lateral surface of the nasal cavity of the rat showing the nasal turbinates and the three different functional areas. I: Vestibular; II: Respiratory; III: Olfactory. a: nasal turbinal; b: maxilloturbinal; c: entrance of the maxillary sinus; d: ethmoidal turbinals.

6b. Coronal section through the rat nose, showing the maxillo- (M) and nasoturbinals (N). S: nasal septum; O: organ of Jacobson; I: incisor.

The peripheral ganglion of the autonomic nerve supply to the nose is the pterygopalatine ganglion. In the rat this ganglion is situated in the pterygopalatine groove, immediately inferior to the maxillary nerve, extending forward in the orbital groove as far as the sphenopalatine foramen. The pterygopalatine ganglion has three roots.

The sensory fibres are thought to come from the maxillary division of the trigeminal nerve, crossing via a few small rami from the maxillary nerve to the pterygopalatine ganglion (Christensen 1934; Malcolmson, 1959). The sensory fibres run through the ganglion to the posterior nasal nerve and thence to the nose without known synaptic interruption. In the rat the maxillary nerve enters the pterygopalatine groove through the lacerated foramen. After leaving the rami towards the ganglion, this nerve runs forward in the infraorbital groove as the infraorbital nerve, together with the anterior superior alveolar nerve, also part of the maxillary nerve (Fig. 4).

The sympathetic fibres are thought to originate in the superior cervical ganglion (Christensen, 1934). This ganglion is situated at the level where the common carotid splits into the external and internal carotid artery. This ganglion is a part of the sympathetic paravertebral chain situated dorsally from the common carotid artery and the vagus nerve. From the superior cervical ganglion fibres cross to the carotid artery, forming a plexus around this artery. This perivascular plexus has been suggested to give off fibres to the deep petrosal nerve (Malcolmson, 1959). The deep petrosal nerve joins the greater petrosal nerve to form the vidian nerve running to the pterygopalatine ganglion. However, as stated previously, we were unable to identify the deep petrosal nerve in the rat.

The parasympathetic fibres find their origin in the brainstem and leave the skull, accompanying the facial nerve up to the geniculate ganglion. These fibres leave this ganglion in order to form the greater petrosal nerve (Fig. 3). The geniculate ganglion of the rat is situated dorsally from the cochlea between the oval window and the fossa of the tensor tympani muscle (Fig. 2). The greater petrosal nerve runs forward with the stapedial artery in the dorsal bony part of the bulla of the middle ear. Together with the stapedial artery (the pterygopalatine artery) the greater petrosal nerve passes through the petrotympanic fissure and continues its course to the lacerated foramen as the vidian nerve (n. canalis pterygoidei). The vidian nerve ends in the pterygopalatine ganglion.

The pterygopalatine ganglion gives rise to the posterior superior alveolar nerve, innervating the palate and to the pterygopalatine nerve which courses to the nose. This nerve innervates the main portion of the nasal mucous membrane of the rat. After leaving the pterygopalatine ganglion, the pterygopalatine nerve runs through the sphenopalatine foramen to the nasal cavity, dividing in a medial or septal branch and a lateral branch. The anterosuperior part of the nasal mucosa in the rat is innervated by the ethmoidal nerve. This nerve splits off from the nasociliary nerve, which originates from the ophthalmic nerve. The ethmoidal nerve enters the orbit through the lacerated foramen and passes through the ethmoidal foramen to enter the cranial cavity and thence to the cribriform plate It enters the nasal cavity dorsally and runs to the tip of the nose.

4. VASCULARISATION

The origin and course of the vascular supply of the nasal mucosa of the rat is shown in Fig. 7. The vascular network in the mucosa of the nasal septum, visualised with Indian ink perfusion, is demonstrated in Fig. 8a, b. Whereas the blood supply of the nasal cavity in man originates both from the internal and external carotid artery (Montgomery et al., 1970), the blood supply of the nasal mucosa of the rat comes from the internal carotid artery alone (Greene, 1959). The internal carotid artery upon reaching the tympanic bulla gives off the pterygopalatine artery (stapedial artery). The pterygopalatine artery has two branches: a pterygoid and a palatine portion.

The artery of the pterygoid canal (vidian artery) is a continuation of the pterygoid portion of the pterygopalatine artery. This artery runs forward on the lateral surface of the internal pterygoid process through the pterygoid canal to the surface of the basisphenoid bone through the pterygopalatine foramen. It enters the posterior nares to supply the nasopharynx and the inferior part of the nasal cavity (Greene, 1959).

The palatine portion gives off two branches: the ophthalmic artery and the sphenopalatine artery. The ophthalmic artery gives rise to the ethmoidal artery. This artery runs to the dorso-anterior part of the nose through the ethmoidal foramen together with the ethmoidal nerve. The sphenopalatine artery enters the nasal cavity through the sphenopalatine foramen. It supplies the main part of the mucous membrane of the septum and the lateral walls. One of its branches has been shown to anastomose with the descending palatine artery by way of the incisive canal (Greene, 1959).

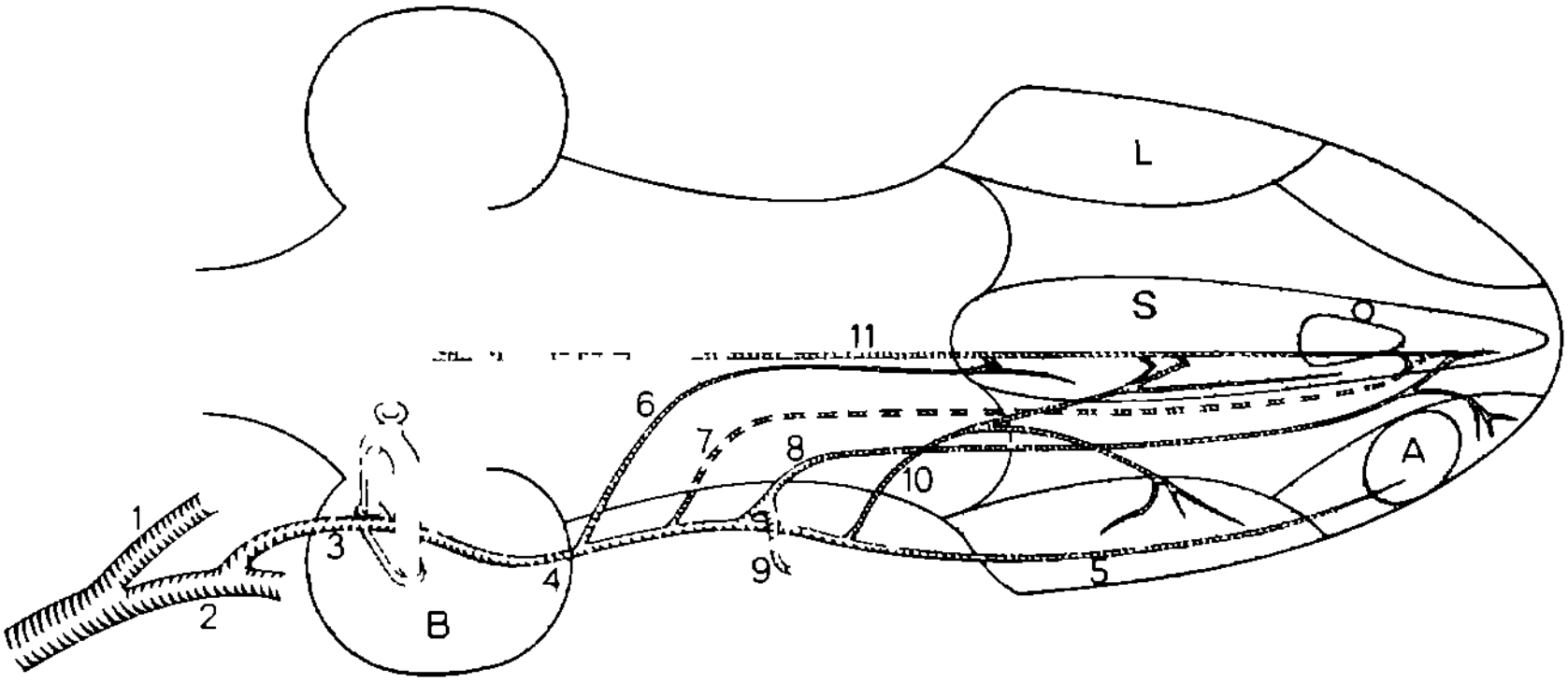

Fig. 7. Schematic drawing of the vascular supply of the nasal mucosa and adjacent structures. 1: external carotid artery; 2: internal carotid artery; 3: stapedial artery; 4: pterygopalatine artery; 5: anterior superior alveolar artery; 6: vidian artery; 7: descending palatine artery; 8: ethmoidal artery; 9: ophthalmic artery; 10: sphenopalatine artery; 11: meningeal artery; A: alveolus; S: septum; L. lateral nasal wall; O: organ of Jacobson; B: middle ear cavity.

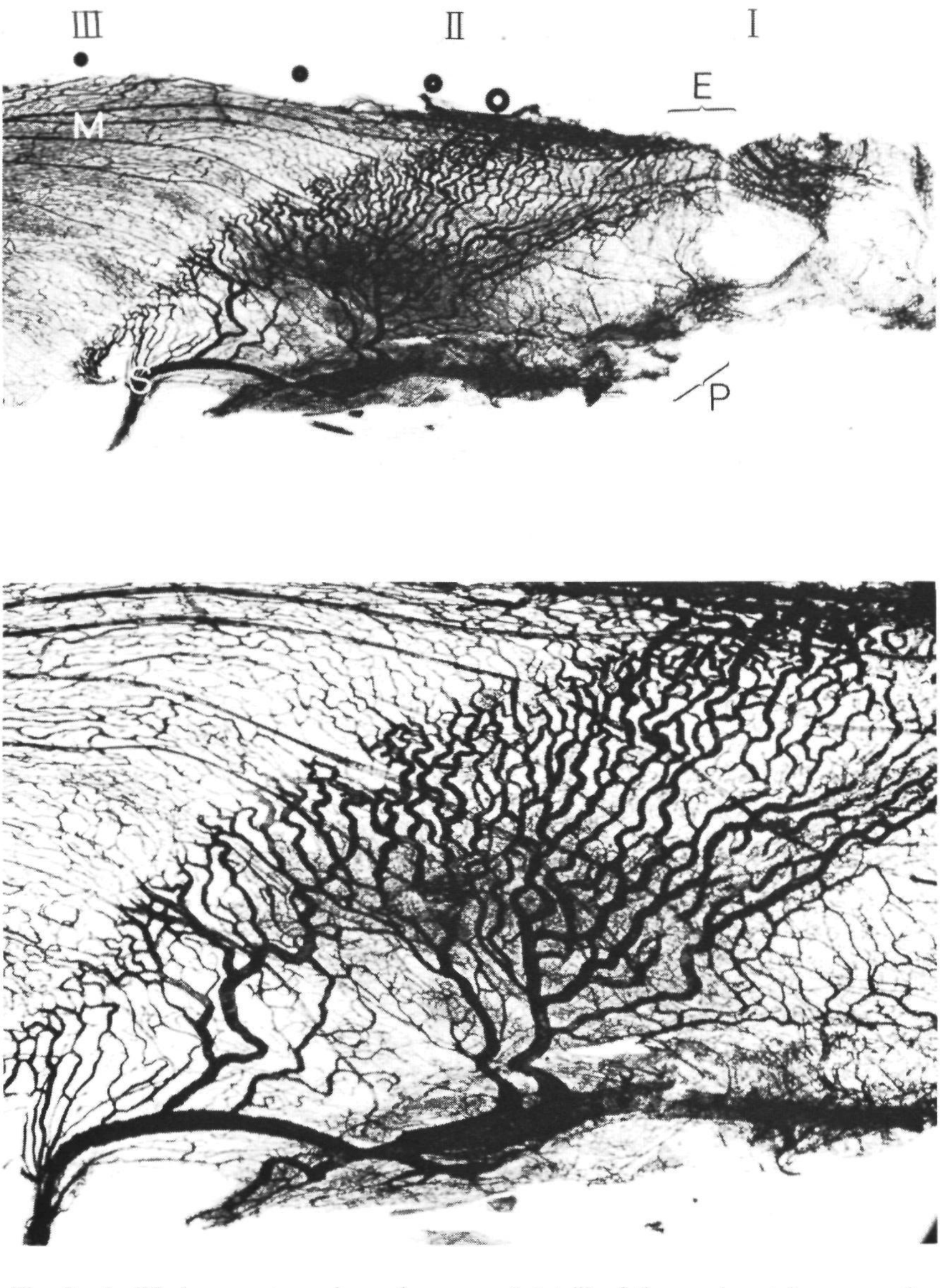

Fig. 8a, b. Whole mount specimen (survey and detail) of the nasal septal mucosa of the rat, demonstrating the vascular pattern of the three areas. I: vestibular; II: respiratory; III: ethmoidal or olfactory. M: arteries originating from the meningeal artery; S: sphenopalatine artery; E: area mainly supplied by the ethmoidal artery; P: area mainly supplied by the descending palatine artery.

Vessels originating from the meningeal arteries penetrate the nasal cavity through the cribriform plate. They run along the septum, anastomosing with branches from the vascular network of the ethmoidal and sphenopalatine artery

The interconnections between the supplying arteries of the nasal mucosa of the rat were investigated by severing the appropriate arteries selectively. Transections were performed at the level of the sphenopalatine foramen, the anterior ethmoidal foramen and in the middle ear (stapedial artery). No changes in the vascular pattern of the nasal mucosa were observed after unilateral transection of these vessels. Even after the same procedure on both sides no changes were found. In an attempt to obtain complete devascularisation on one side the common carotid artery was transected unilaterally. Also in this case no changes in the vascular pattern of the nasal mucosa could be observed in comparison to the normal animal In summary, the findings described in this chapter confirm that the vascular supply of the nasal mucosa of the rat originates in the internal carotid artery, the sphenopalatine artery appearing to be the most important branch. A very rich collateral network appears to exist between the vessels on one side, and between the vessels of the right and the left sides of the nose.

5. EPITHELIUM

The epithelium in the respiratory part of the nose is a pseudo-stratified ciliated columnar epithelium with a large number of goblet cells This epithelium is continuous with the stratified squamous epithelium of the nasal vestibule and with the olfactory epithelium. The surface of the nasal cavity is usually covered with mucus. The lamina propria of the respiratory portion contains many vessels and glands The vascular structures show many arteries, capillaries and veins and in some places venous-like sinuses. These sinuses, forming the so-called erectile tissue, consist of large irregular endothelium-lined spaces and are mainly confined to the respiratory epithelium of the internal ostium. The glands in the submucosa may be divided into a medial group on the septum and a lateral group on the lateral wall of the nasal cavity. The latter group includes a large gland around the ostium of the maxillary sinus (Fig. 6a). This lateral nasal gland, or Steno's gland (Fig. 4) described by the Danish anatomist Steno (1664), consists of a mucous and a serous part and empties through a long excretory duct at the nostril. The glands on the septum also appeared mixed (Fig 9). Between the acini of the glands there are many secretory ducts which empty into large excretory ducts which end in the anterior part of the nasal cavity (Fig. 10). In the lamina propria of the septum large nerve bundles course from the

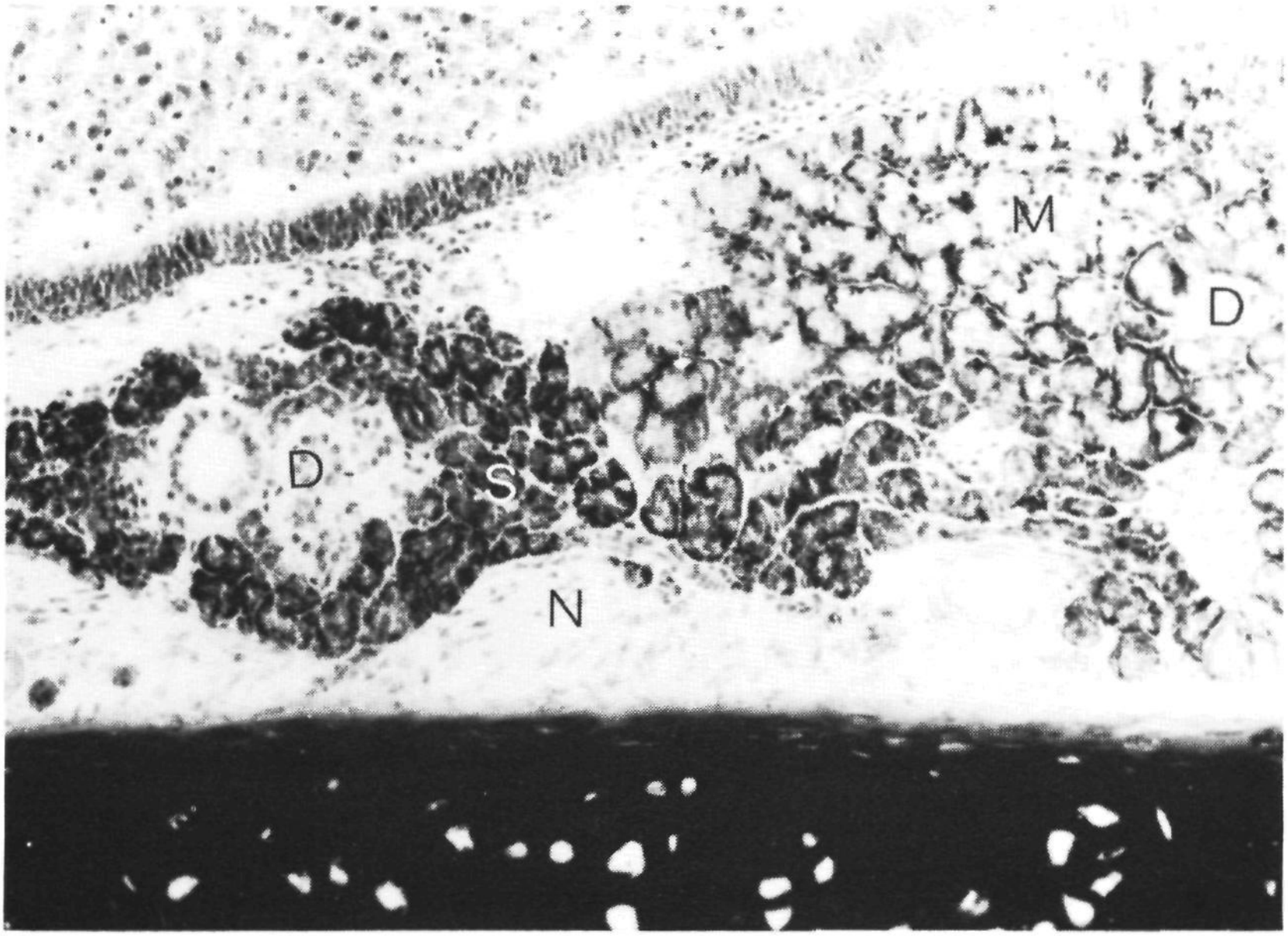

Fig. 9. Section of the nasal mucosa, showing serous (S) and mucous glands (M) with secretory ducts (D). N.: transverse section of nerve bundle coursing to the organ of Jacobson (methylgreen-pyronin).

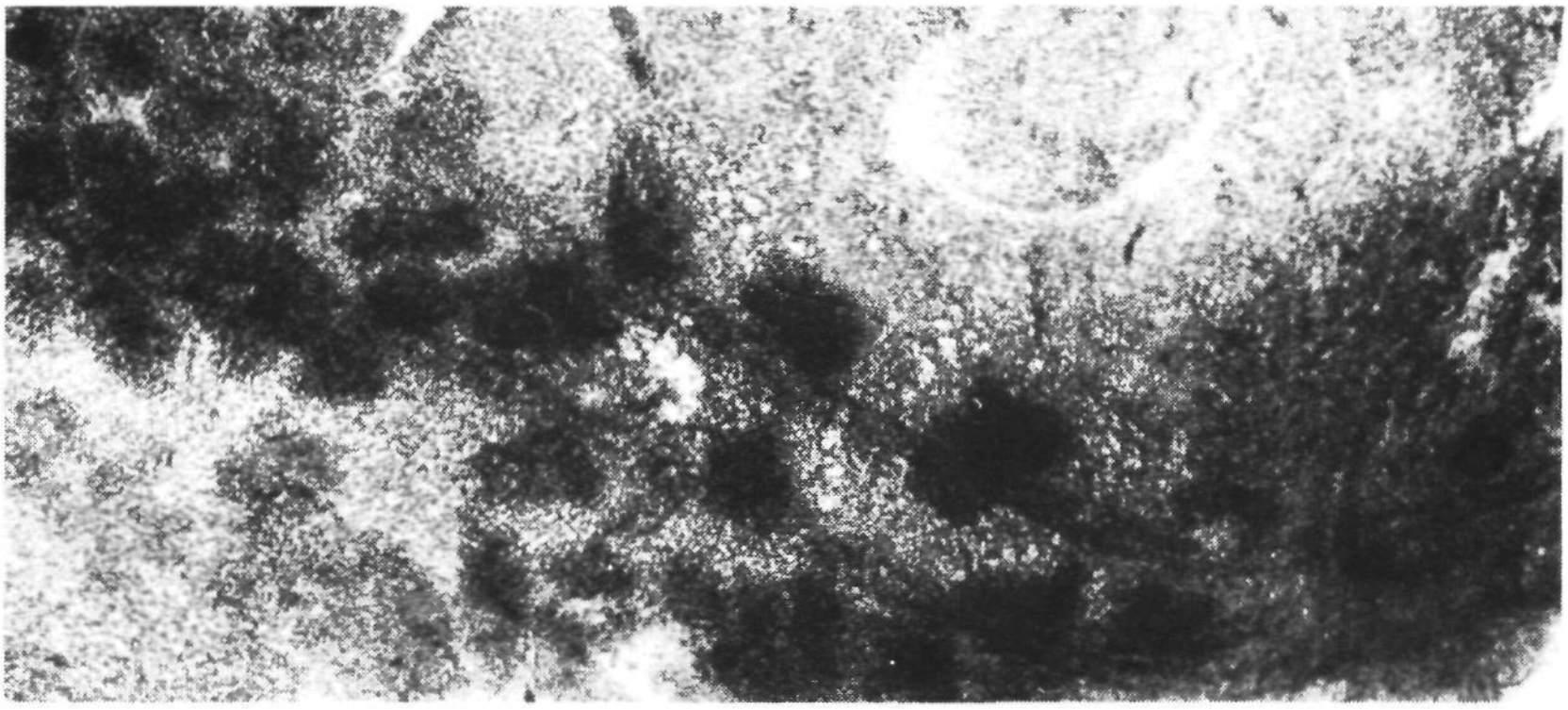

Fig. 10. Whole mount specimen of the septal mucosa showing glands with secretory ducts (Sudan Black B).

cribriform plate to the organ of Jacobson (Fig. 9).

These findings are in accordance with the observations made by Bojsen Møller (1964, 1965).

6. CONCLUSION

These findings clearly indicate that the gross anatomy, vascular and nerve supply of the respiratory part of the nasal mucosa in the rat does not differ fundamentally from that described in other mammals and humans except for the origin of the arterial supply from the internal carotid artery.

CHAPTER IV

NEUROHISTOCHEMICAL AND ELECTRON MICROSCOPIC INVESTIGATION OF THE NASAL MUCOSA

1. INTRODUCTION

In this chapter the course and location of both adrenergic and cholinergic nerve fibres in the nasal mucosa of the normal rat are described. Also, an account is given of the behaviour of the autonomic nerve endings following selective transection of the appropriate autonomic nerves after postoperative periods varying from 2 weeks to 18 months.

In addition, in a few cases, the innervation pattern in the septal mucosa was studied electron microscopically in normal animals and in animals in which the pterygopalatine nerve was transected or the superior cervical ganglion extirpated (9 days postoperatively). These experiments were undertaken firstly in order to trace the origin, course and contribution of the various nerve bundles to the innervation of the nasal mucosa, and secondly to study systematically the events occurring in the nasal mucosa after 'autonomic denervation' in short and long term experiments, in view of the use of this nerve transection as therapy in cases of vasomotor rhinitis.

The dissecting, staining and microscopical techniques used for studying the innervation pattern and the structures of the nasal mucosa are described in Chapter III.

2. THE NORMAL RAT

In the normal animal both noradrenaline- and acetylcholinesterase-containing fibres were apparent in walls of the nasal vessels. The venous sinuses in particular showed a very dense network of both types of fibres (Fig. 11a, b).

Periacinar acetylcholinesterase-containing fibres were present in the nasal glands (Fig. 12). Both serous and mucous glands appeared to be innervated, although the periacinar plexus of the mucous glands stained less intensive than that of serous glands. No cholinergic fibres were observed in relation to the excretory ducts. Adrenergic fibres could not be demonstrated in connection with the glandular tissue. In some sections clear interconnections a

b

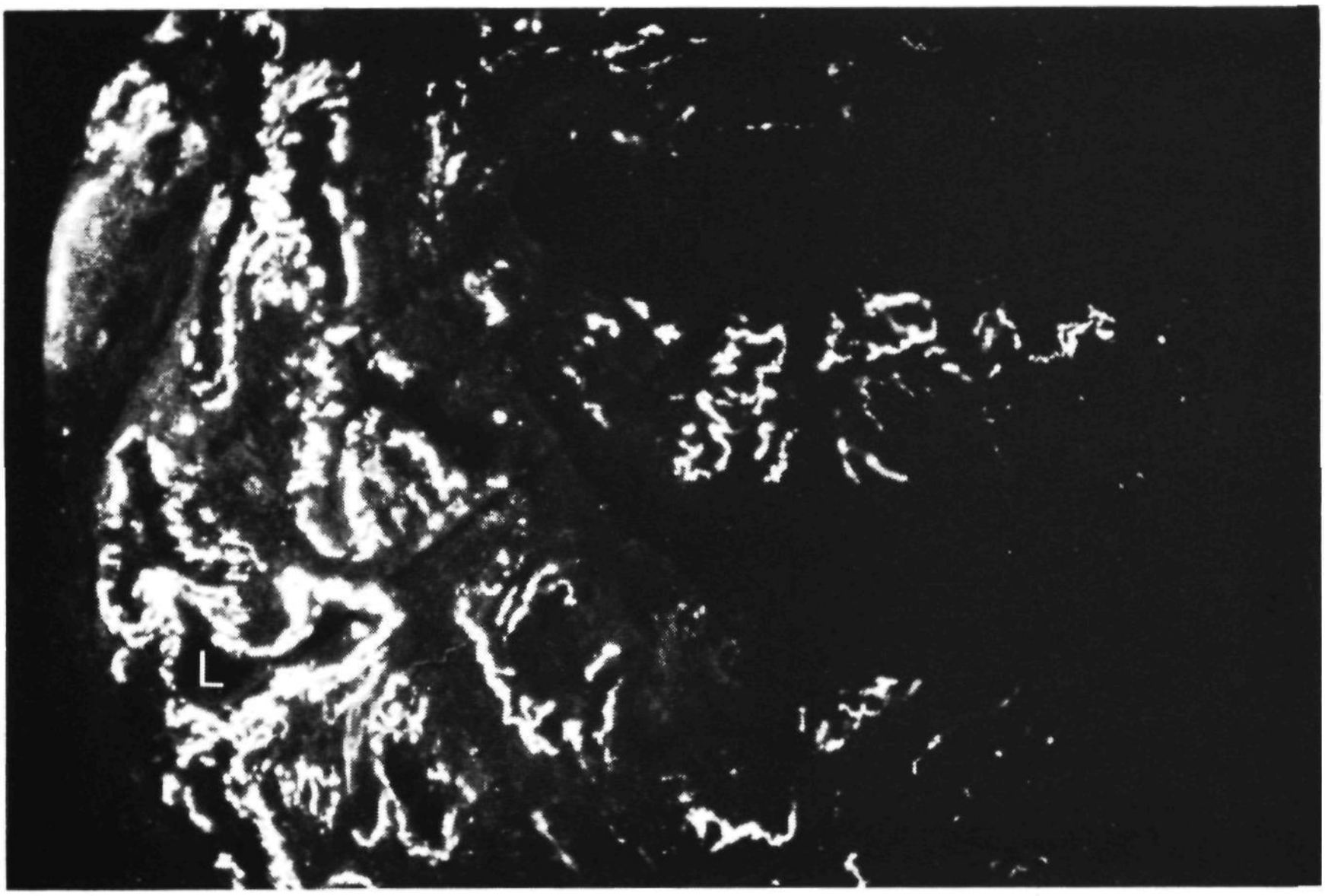

Fig. 11a. Whole mount specimen of the nasal mucosa showing the acetylcholinesterase-containing nerve plexus in the wall of the venous sinuses.

11b. Section of the nasal mucosa from the lateral wall showing noradrenaline containing nerve plexus in the wall of the venous sinuses. L: vascular lumen.

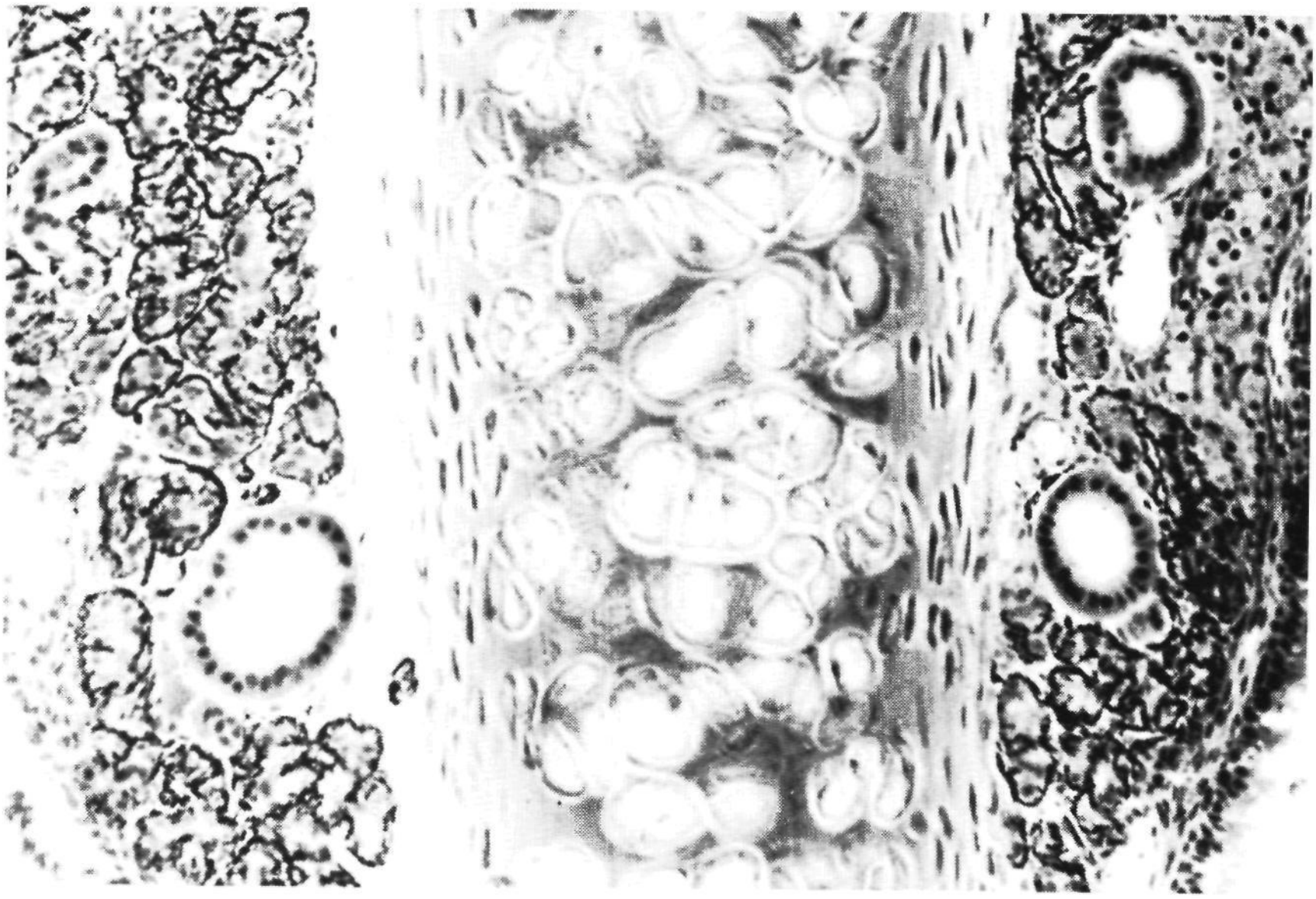

Fig. 12. Coronal section of the nasal septum with the acetylcholinesterase containing periacinar nerve plexus. Note the large secretory ducts.

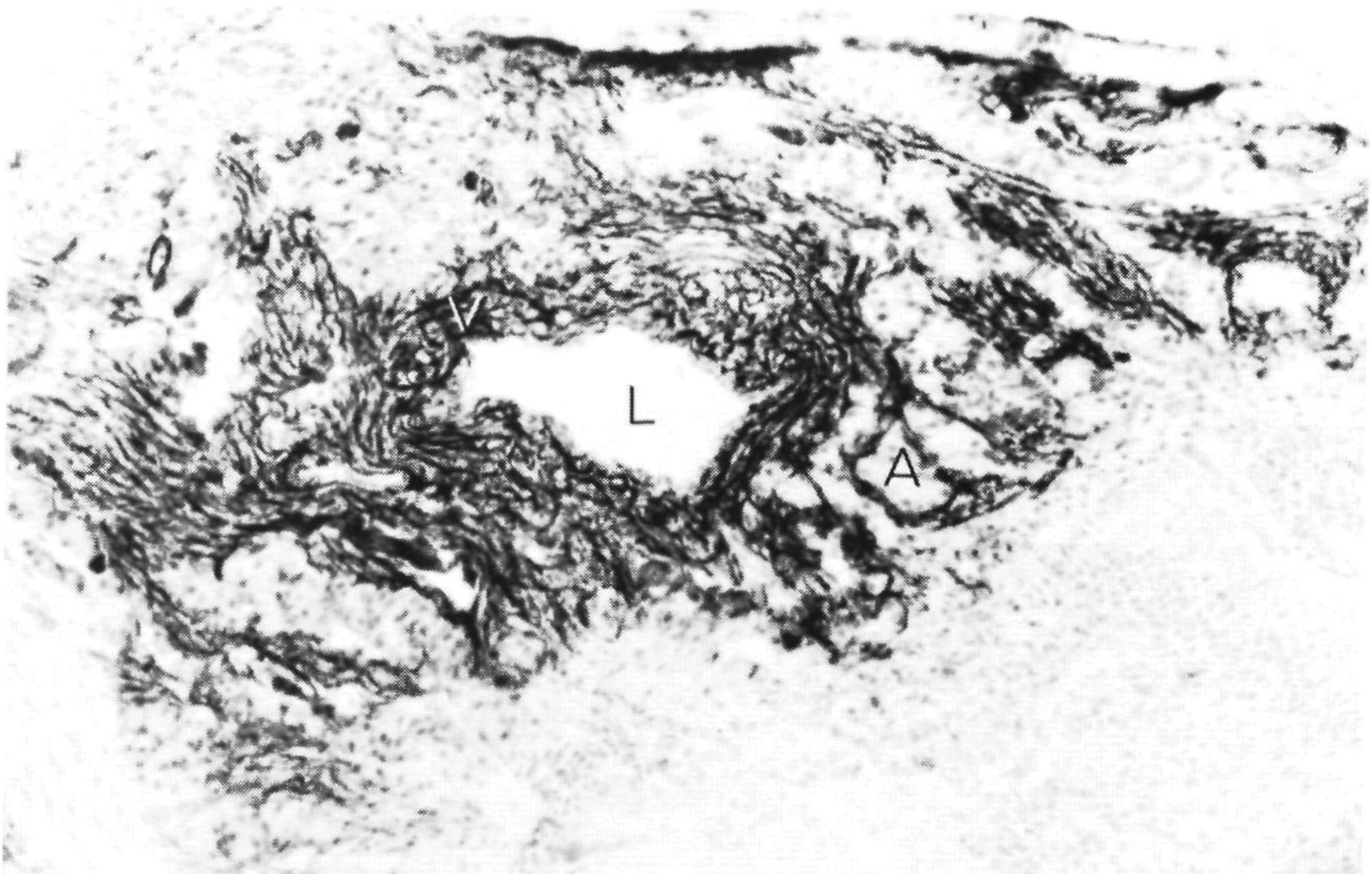

Fig. 13. Section of the nasal mucosa showing interconnections between the acetylcholinesterase containing nerve plexus of a venous sinus and the periacinar plexus. L: lumen; A: periacinar plexus; V: perivascular plexus.

between the cholinergic vascular plexus and the periacinar plexus could be observed. Fig. 13 shows this relationship between the extensive plexus in the wall of a venous sinus and the periacinar plexus. In Fig. 14 the same relationship is shown between a periarteriolar and a periacinar plexus.

Apart from the periacinar and perivascular plexus a subepithelial plexus of both acetylcholinesterase- and noradrenaline-containing fibres was found in the whole-mount specimens.

Electron microscopic observations showed the presence of large nerve fascicles in the submucosal layer (Fig. 15). The main part of the axons appeared to be unmyelinated. Along their course these nerve fascicles, showing many ramifications, progressively become smaller.

The smaller branches were found in close association with the nasal glands, in the muscular layer of the vessels, in cell-free areas and between the epithelial cells. The latter axon endings were situated just superficial to the basement membrane (Fig. 22a).

Whole-mount specimens of the ethmoidal and sphenopalatine arteries revealed the presence of a plexus of both noradrenaline- and acetylcholinesterase-containing fibres (Fig. 16a, b). Serial sections and whole-mount

Fig. 14. Section of the nasal mucosa from the lateral wall showing interconnections between the acetylcholinesterase containing periarterial nerve plexus and the periacinar nerve plexus.

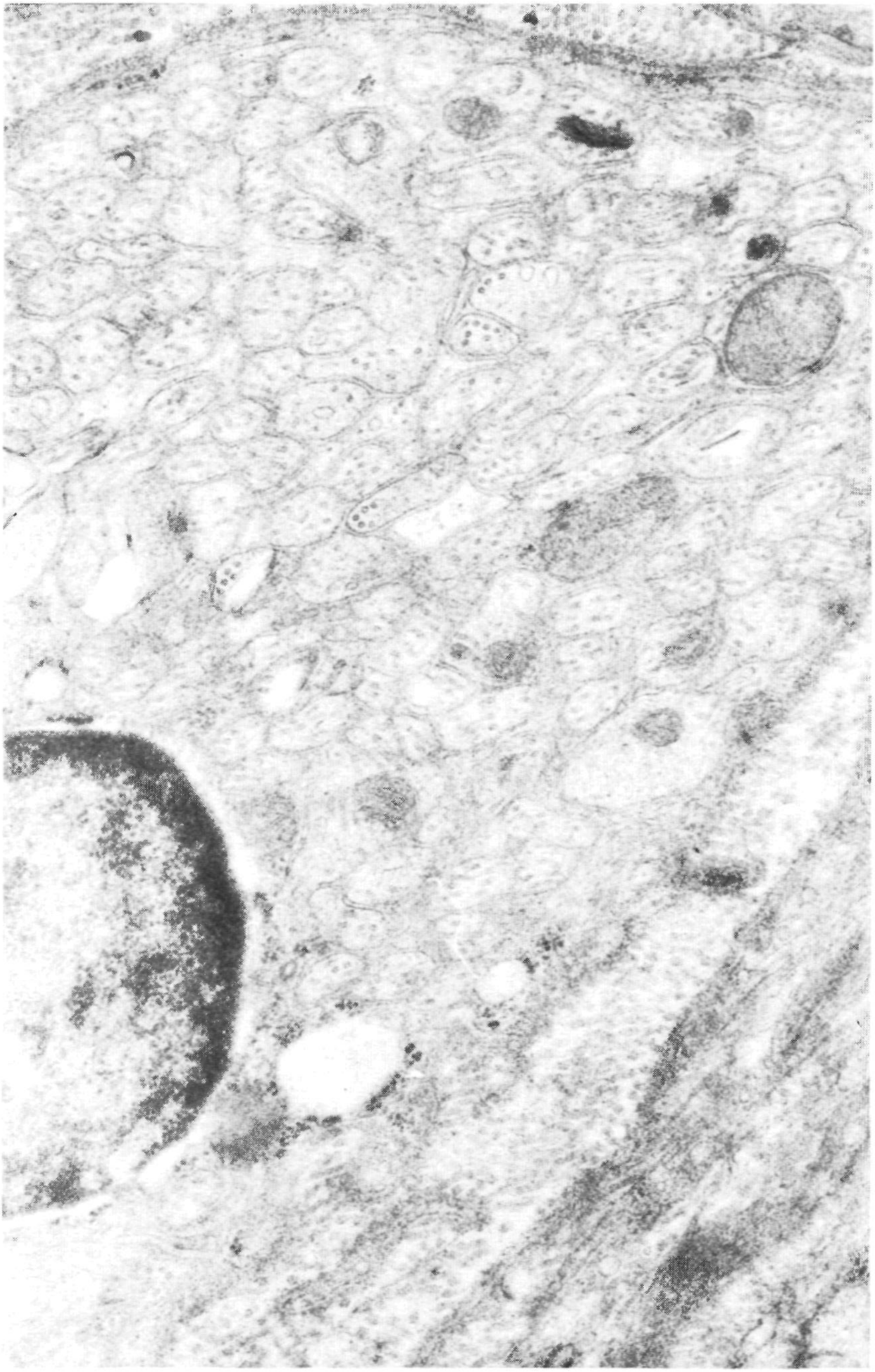

Fig. 15. Unmyelinated nerve in the nasal mucosa of a normal rat showing many cross sectioned axons. On the left side Schwann cell nucleus (X 34,000).

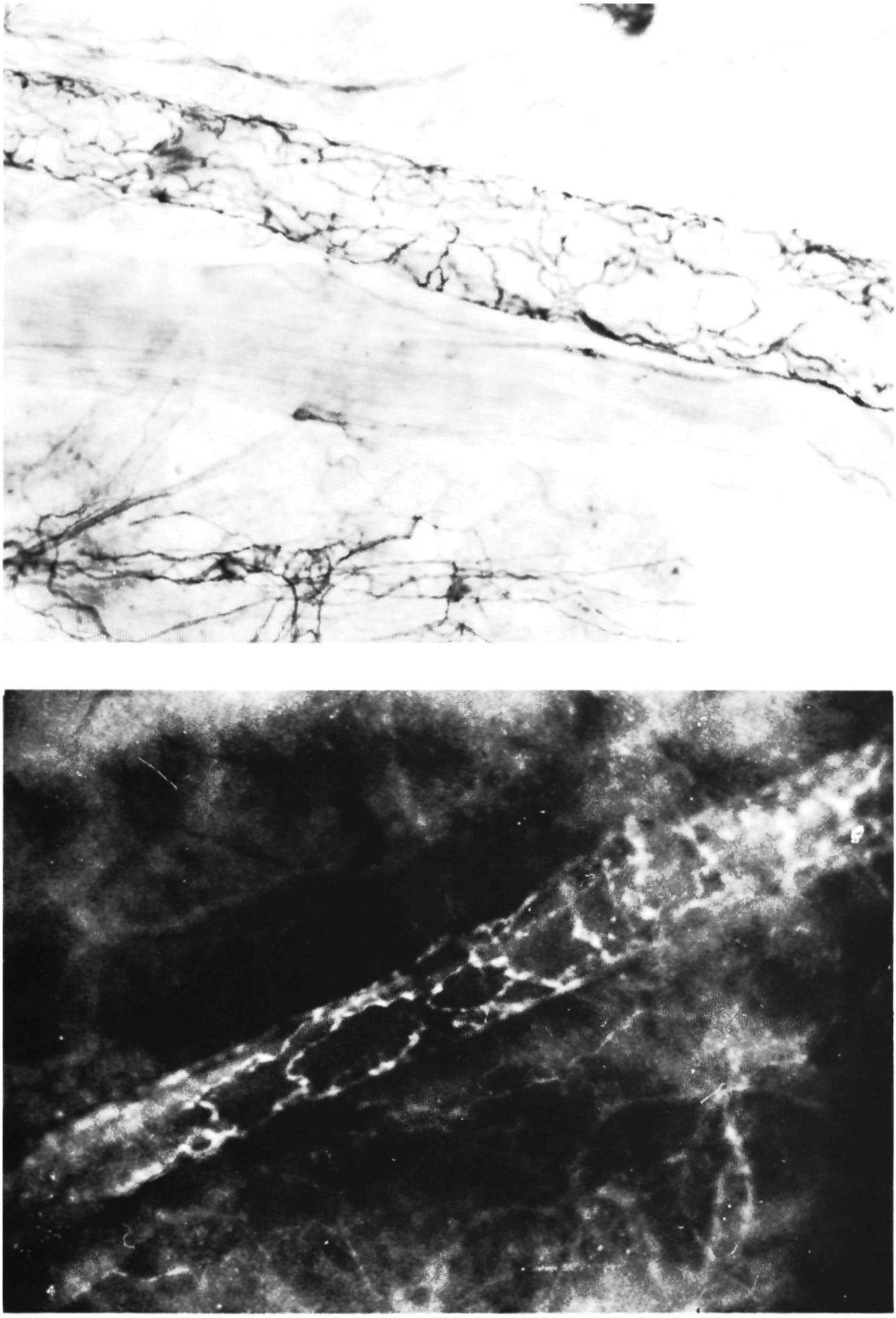

Fig. 16,a, b. Whole mount specimen of the sphenopalatine artery demonstrating the acetylcholinesterase (a) and noradrenaline (b) containing periarterial nerve plexus.

specimens of the stapedial artery and the common carotid artery showed the presence of a noradrenaline-containing perivascular plexus. No significant acetylcholinesterase-containing fibre plexus could be demonstrated in the wall of the stapedial artery.

3 AFTER SELECTIVE DENERVATION

(a) Superior cervical ganglion

The effects of unilateral and bilateral extirpation of the superior cervical ganglion on the distribution of nerve fibres in the nasal mucosa are summarised in Table 1.

Table 1

Effect of cervical ganglion extirpation on the nerve fibres in the nasal mucosa

Side of extirpation	Survival time	ACh-esterase-containing fibres		Noradrenaline-containing fibres	
		Left	Right	Left	Right
right	2 weeks	+	+	+	–
right	4 weeks	+	+	+	±
both sides	7 weeks	+	+	–	–
both sides	2 months			–	–
right	2 months			+	–
right	4 months*	+	+	+	–
right	5 months*			+	–
right	9 months*	+	+	+	±
right	9 months*	+	+	+	+
right	12 months	+	+	+	+
both sides	12 months	+	+	+	–

* In these animals the greater petrosal nerve was also transected

After 2 weeks the main part of the sympathetic fibres had disappeared and they remained absent for about one year on the denervated sides (Fig. 17). In one animal about half of the normal adrenergic activity was observed 4 weeks after unilateral ganglionectomy on the denervated side. Nine months to one year after the extirpation of the ganglion reinnervation was apparent in most cases, however, in one of the bilateral denervated animals, noradrenaline-containing fibres were still absent on one side after 12 months. No change in acetylcholinesterase activity relative to normals could be observed after extirpation of the superior cervical ganglion, even in those animals in which the greater petrosal nerve was also transected

Fig. 17. Coronal section of the nasal septum two weeks after unilateral extirpation of the superior cervical ganglion, demonstrating the absence of the noradrenaline containing nerve fibres in the vascular wall on the denervated side (right). L: vascular lumen

Electron microscopic observations 9 days after extirpation of the superior cervical ganglion showed the disappearance of a small number of axons in the large nerve fascicles as well as in the muscular layer of the vessels. Some axons had a swollen appearance, sometimes containing swollen mitochondria, multivesicular bodies, vacuoles and lysosomes.

Fig. 18 shows a nerve fascicle with a large number of axons in the septal mucosa 9 days after the extirpation of the superior cervical ganglion demonstrating the disappearance and degenerative changes in a minor part of the axons as compared to Fig. 15.

(b) The vidian nerve (n. canalis pterygoidei)

The results of vidian nerve transection are shown in Table 2, with adrenergic fibres absent two weeks later.

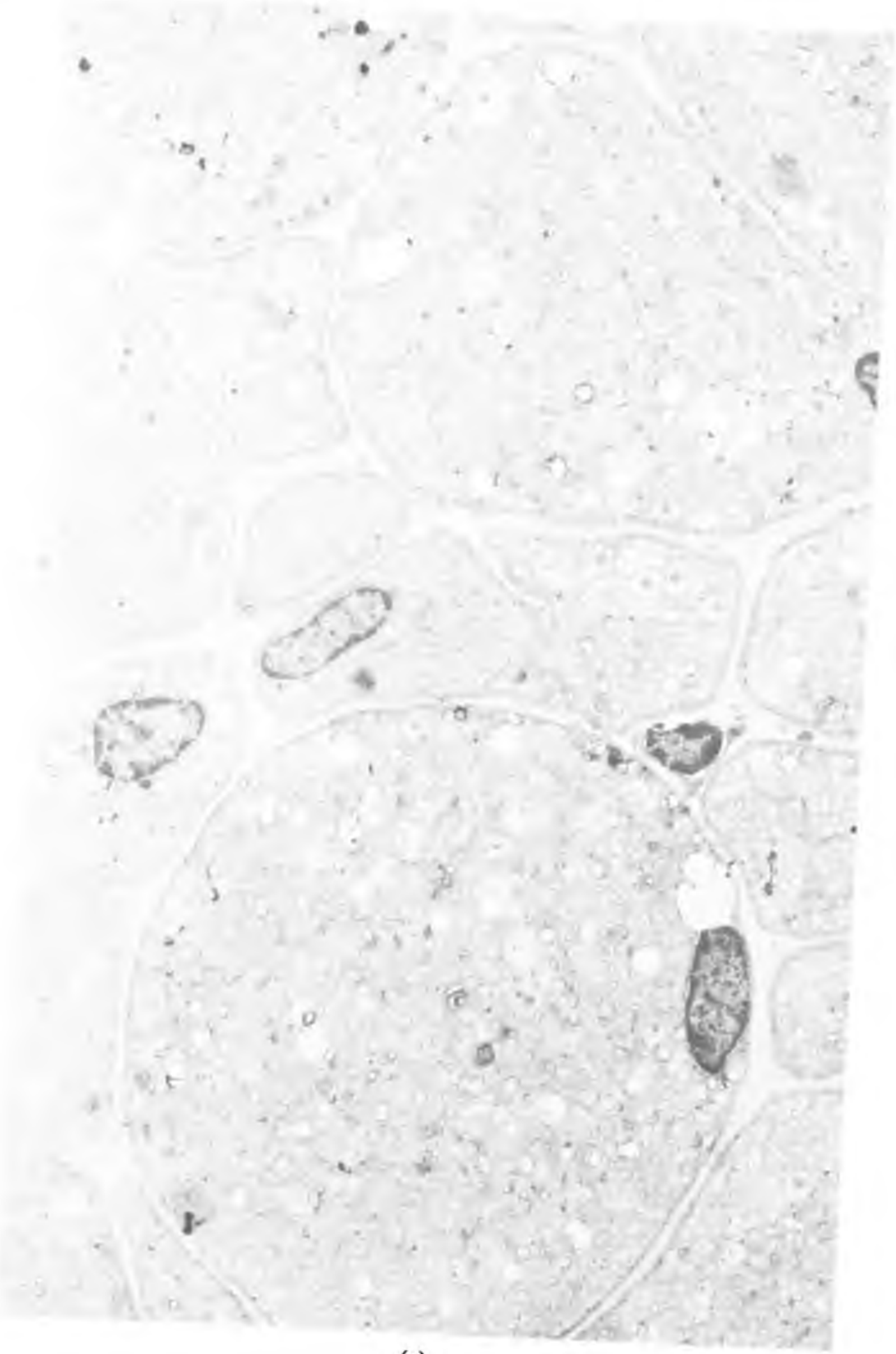

(a)

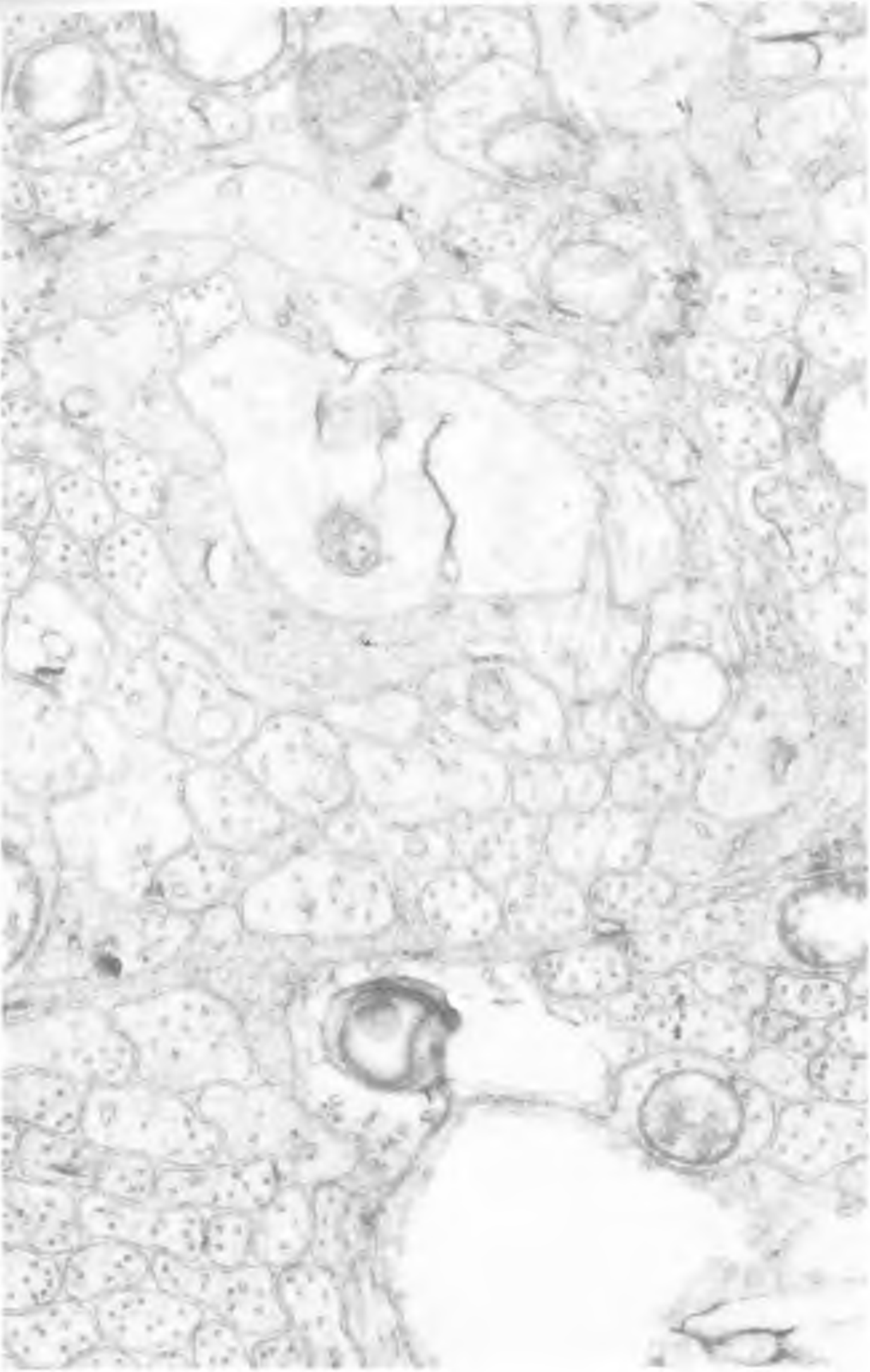

Fig. 18a, b. Survey (a) (×6300) and detail (b) (×34,000) of a large unmyelinated nerve in the mucosa of the nasal septum 9 days after the extirpation of the superior cervical ganglion. Note, the presence of many degenerating axons. The majority of the axons however seems normal.

Table 2

Effect of vidian nerve transection.

Side of transection	Survival time	ACh-esterase-containing fibres		Noradrenaline-containing fibres	
		Left	Right	Left	Right
right	2 weeks	+	+	+	–
right	3½ weeks	+	+	+	±
right	2 months			+	±
right	8 months			+	+
right	16 months	+	+	+	+

Half of the normal adrenergic activity was observed in the animals which survived for 3½ weeks and 2 months. After longer survival times a restoration to normal level of activity was found. No change in the number of acetylcholinesterase-containing fibres was observed during the observation period.

(c) The pterygopalatine nerve

The effects of pterygopalatine nerve transection on autonomic fibre distribution in the nasal mucosa are summarised in Table 3.

Table 3

Effect of pterygopalatine nerve transection.

Side of transection	Survival time	ACh-esterase-containing fibres		Noradrenaline-containing fibres	
		Left	Right	Left	Right
right	2 weeks	+	–	+	–
right	2 weeks	+	–	+	–
right	2 weeks	+	–	+	–
both sides	2 weeks	–	–		
both sides	2 weeks	–	–		
both sides	2 weeks	–	–		
right	3 weeks	+	–	+	–
right	3 weeks	+	–	+	–
right	3 weeks	+	–		
both sides	2 months	+	+	±	±
right	4 months	+	+	+	±
right	4 months	+	+	+	±
both sides	14 months	+	+	+	+
both sides	14 months	+	+	+	+
right	11 months	+	+	+	+
right	18 months	+	+		
right	18 months	+	+		

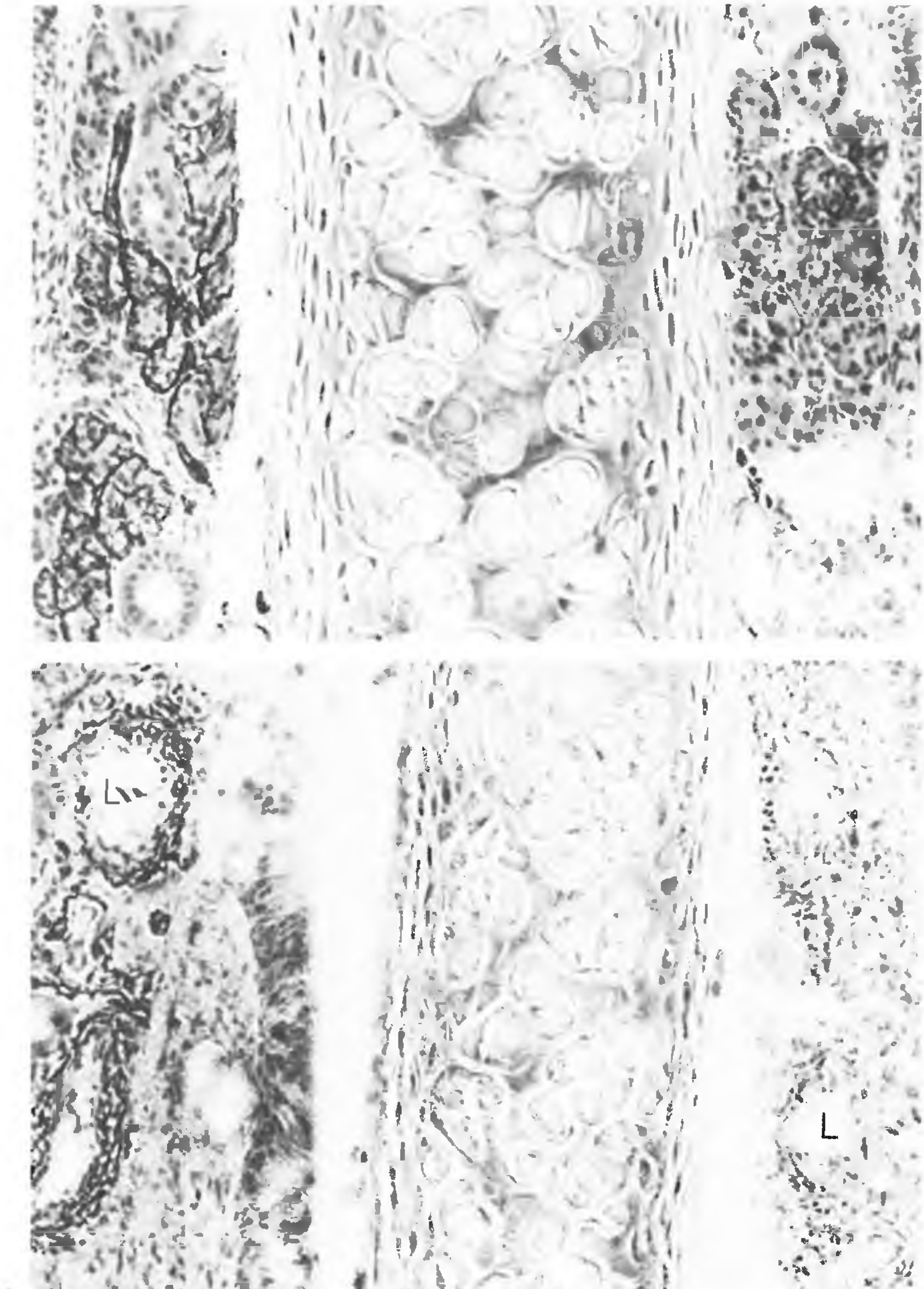

Fig. 19a, b. Coronal sections of the nasal septum two weeks after unilateral pterygopalatine nerve transection. The periacinar (a) and perivascular (b) acetylcholinesterase containing nerve fibres are absent on the denervated side (right). Note the small amount of residual acetylcholinesterase activity on the denervated side. L: vascular lumen.

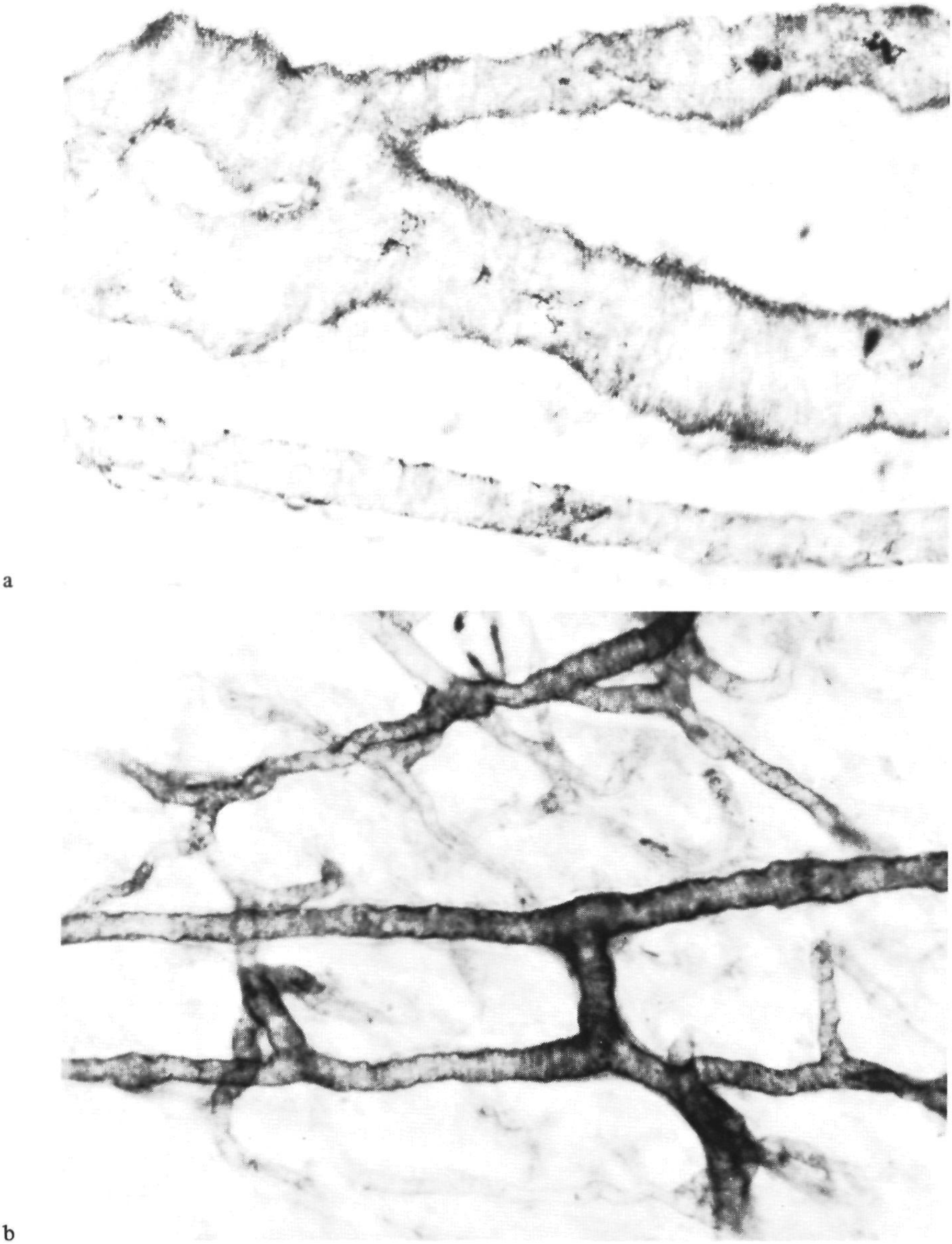

Fig. 20a, b. Whole mount specimens of the venous sinuses (a) and small vessels (b) in the nasal mucosa 2 weeks after transection of the pterygopalatine nerve showing the absence of the acetylcholinesterase containing perivascular nerve plexus.

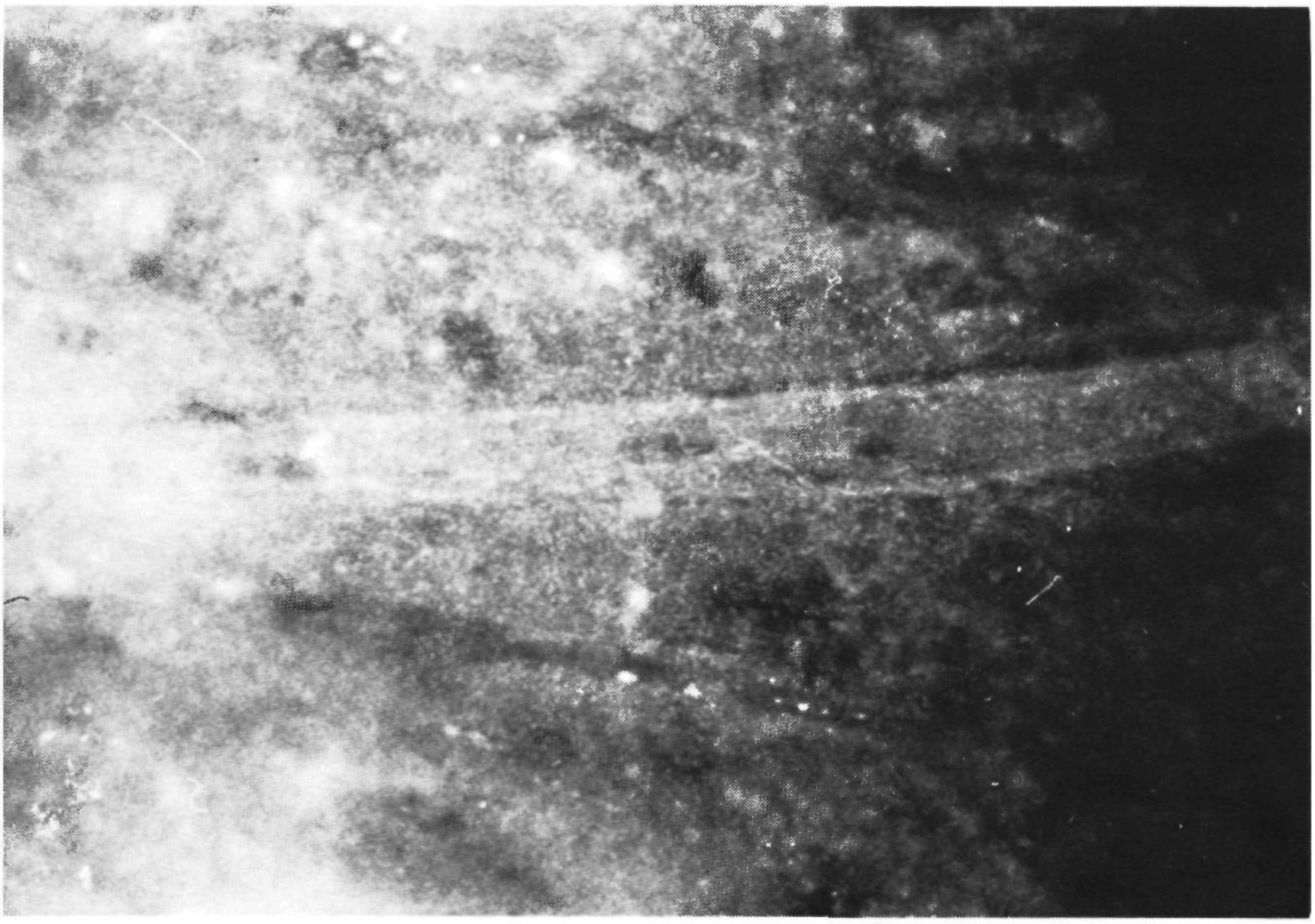

Fig. 20c. Whole mount specimen of the sphenopalatine artery two weeks after pterygopalatine nerve transection demonstrating the absence of the periarterial noradrenaline containing nerve plexus.

Two weeks after transection of the pterygopalatine nerve both acetylcholinesterase- and noradrenaline-containing fibres were absent on the denervated sides. Fig. 19 shows a coronal section of the septum two weeks after unilateral denervation. Acetylcholinesterase-containing periacinar and perivascular plexuses appeared to be absent. Fig. 20a, b shows the venous-like sinuses and small vessels 14 days after denervation, the acetylcholinesterase-containing plexus having disappeared. Fig. 20c shows the disappearance of the noradrenaline-containing nerve plexus from the wall of the sphenopalatine artery after the same period.

In Fig. 21a a transverse section of a small artery in the nasal mucosa is shown before and two weeks after pterygopalatine nerve transection, demonstrating the disappearance of the noradrenaline-containing fibres. Electron microscopic observations revealed a sharp decrease in the number of nerve fascicles and free axons 9 days after pterygopalatine nerve transection. The main part of the remaining fibres had a swollen appearance, while the number of neurotubuli was decreased. The number of neurofilaments was enhanced and dark lysosomal structures were present. In the epithelial

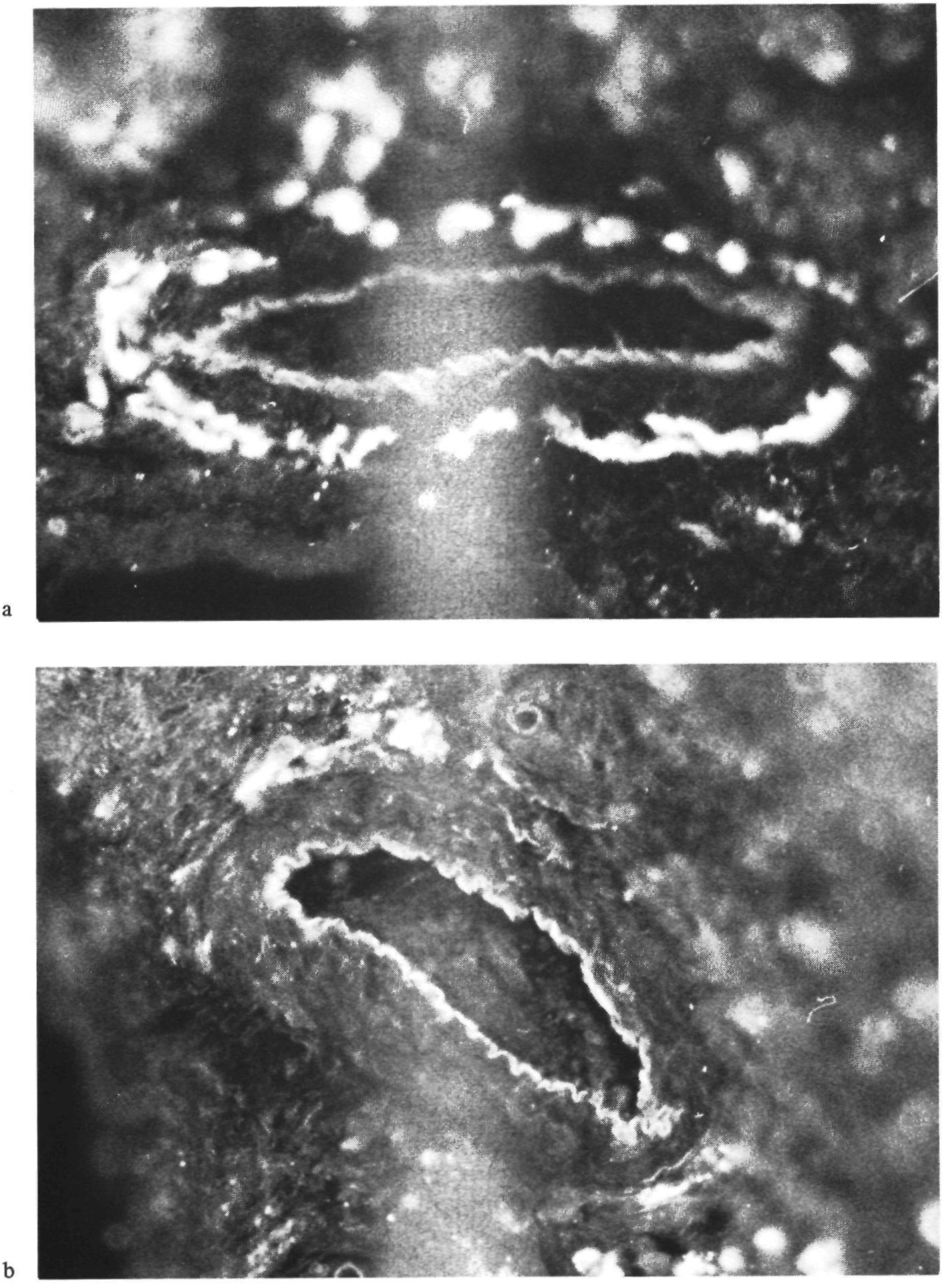

Fig. 21a, b. Transverse section of an artery in the nasal mucosa before (a) and two weeks after (b) transection of the pterygopalatine nerve. Noradrenaline containing nerve fibres are disappeared from the vascular wall two weeks after transection.

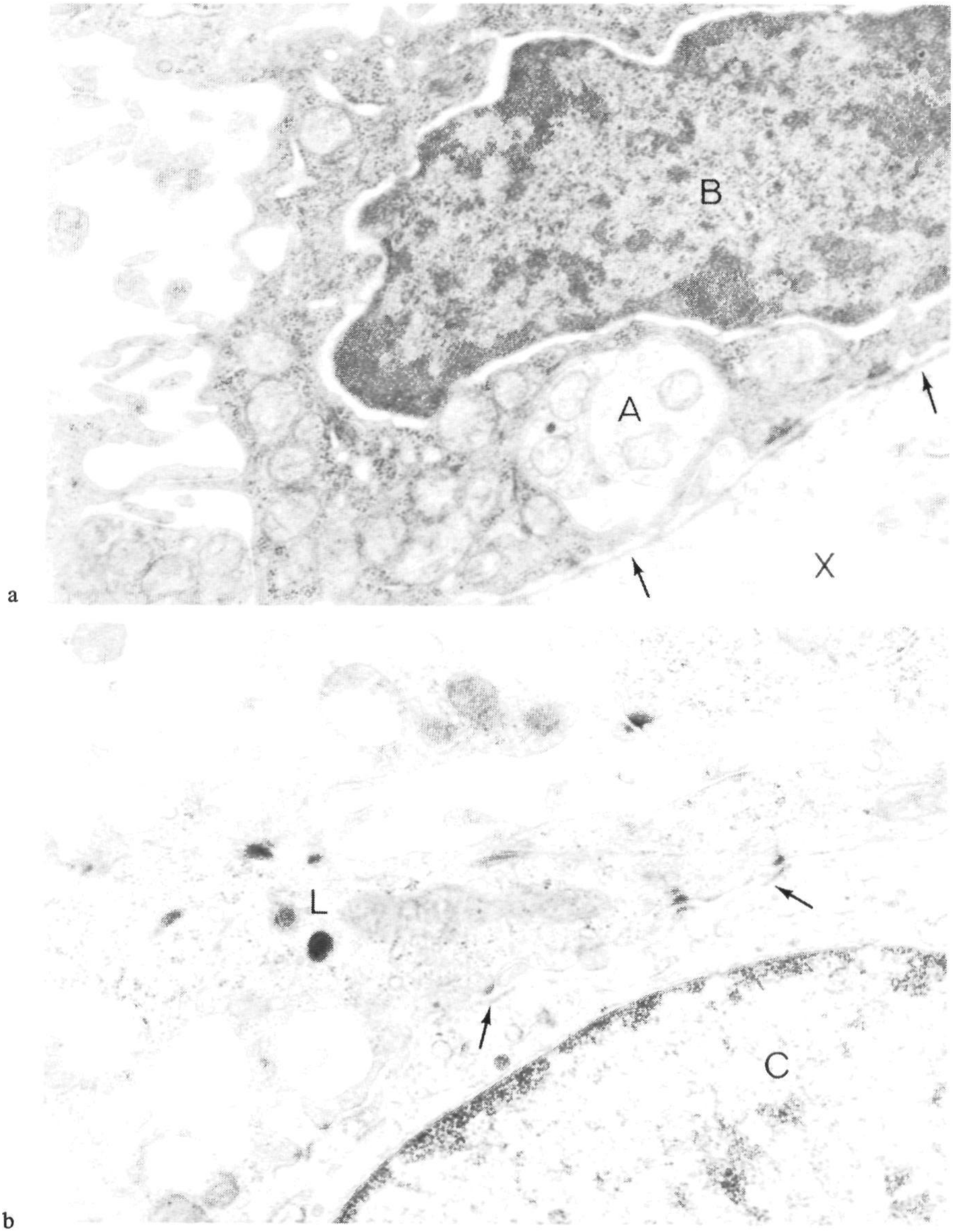

Fig. 22. Basal part of the respiratory epithelium from the nasal septum in a normal rat (a) and 9 days after transection of the pterygopalatine nerve (b). Note the disappearance of the free axons just above the basilar membrane after transection. A: axons; B: basal cells; L: lysosomes; C: part of lymphoid cell infiltrated into the lamina propria; X: cell free space of the lamina propria; ↑↑: basement membrane. Note the collagen fibres associated with the b.m. (×20,000).

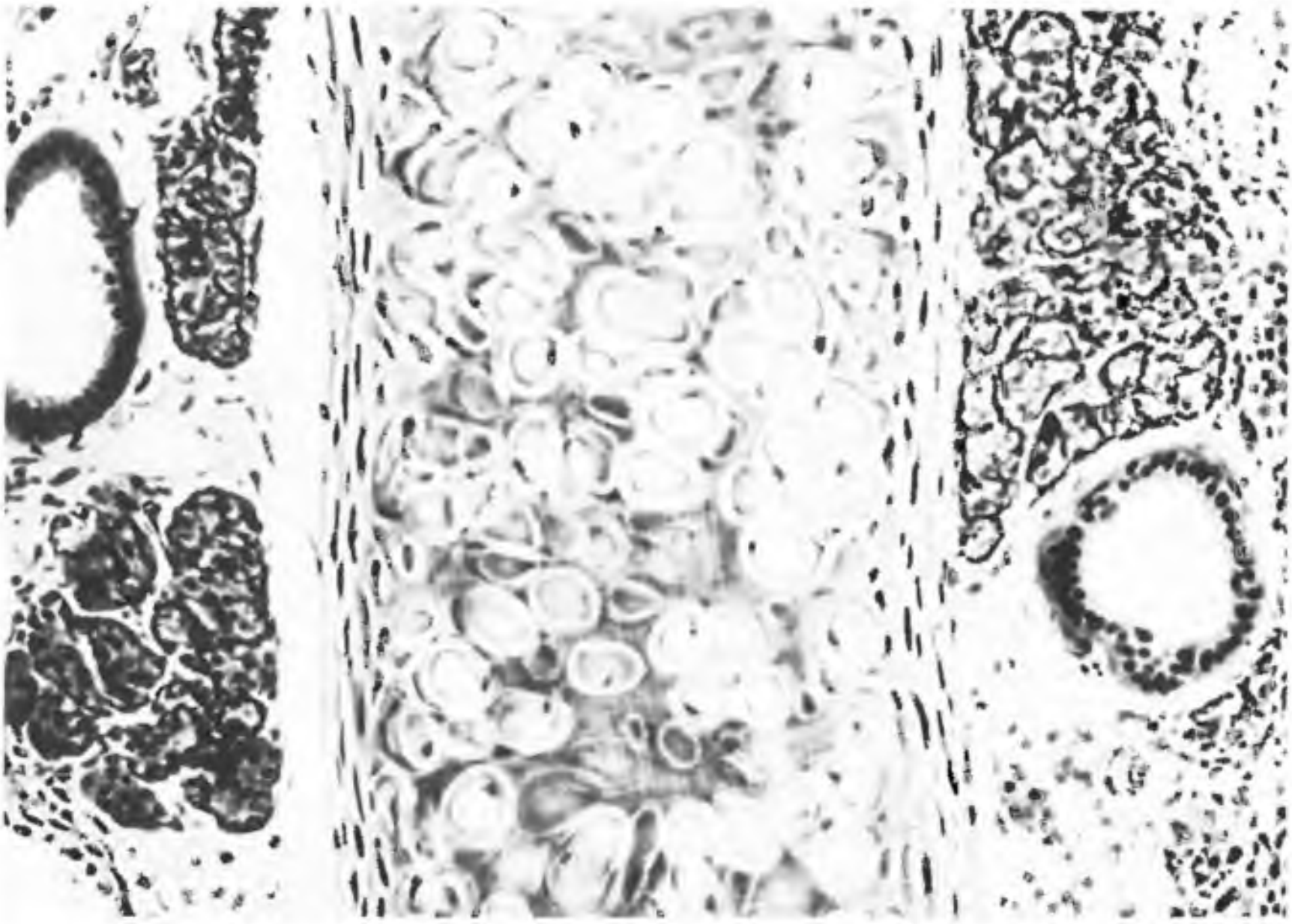

Fig. 23. Coronal section of the nasal septum showing the reappearance of the acetylcholinesterase containing nerve plexus 14 months after bilateral pterygopalatine nerve transection.

layer no nerve endings could be observed (Fig. 22b). The two to four months survivals showed a normal pattern of the acetylcholinesterase-containing fibres on the operated side, while the noradrenaline-containing fibres showed only half of the normal activity. The animals which survived for more than 11 months showed a normal pattern of both acetylcholinesterase- and noradrenaline-containing fibres on the denervated side (Fig. 23).

(d) Ethmoidal nerve and maxillary nerve

After transection of these nerves no changes in the number of acetylcholinesterase- and noradrenaline-containing fibres could be observed in the nasal mucosa.

It should be noted that some of the mucosal specimens (indicated as negative in the tables) appeared neurohistochemically to contain small remnants of positively reacting nerve fibres as well as a few intact nerve fibres in electron microscopic pictures. Because the previously noted nerve plexuses in the wall of the supplying arteries (Fig. 16) might be responsible for this phenomenon, a new series of experiments was performed. In these experiments not only the pterygopalatine nerve and ethmoidal nerve were transected but also the sphenopalatine and ethmoidal arteries No observable change in residual nerve activity could be found however.

(e) Transection of the greater petrosal nerve

Transection of the greater petrosal nerve failed to reveal any change in the number of acetylcholinesterase- and noradrenaline-containing fibres, after survival times varying from 2 weeks to 8 months

(f) Transection of the stapedial artery

Although we were unable to demonstrate the presence of parasympathetic fibres in the walls of the stapedial artery a final experiment was performed in which the stapedial artery was transected. No change in the number of autonomic fibres being observed in the nasal mucosa after survival times from 2 weeks to 2 months.

4. HISTOLOGICAL OBSERVATIONS

Besides neurohistochemical investigation, adjacent sections were stained with haematoxylin-eosin, PAS and methylgreen-pyronin. With these methods no significant change could be observed in glandular activity and the number of eosinophils present after unilateral denervation of the nerves involved in comparison to the normal side. Because of the dissecting and fixation techniques used we were unable to study the swelling state of the erectile tissue. This problem will be discussed in Chapter VI.

Apart from the reported changes in the nerve axons, the electron microscopic studies revealed a change in the glandular tissue both after transection of the pterygopalatine nerve and after extirpation of the superior cervical ganglion. Nine days after denervation the acinar cells appeared to contain fewer secretory granules, the intercellular spaces were widened and the shape of the acinar lumina was very irregular. In the acinar cells vacuolisation was observed

Moreover, the lamina propria showed an increase in collagen fibre content and of the number of lymphocytes, macrophages and mast cells

5. DISCUSSION AND CONCLUSIONS

The results presented in this chapter clearly demonstrate the existence of a well developed autonomic nervous system in the respiratory part of the nasal mucosa of the rat, the vascular structures and the subepithelial region appearing to be innervated by both acetylcholinesterase- and noradrenaline-containing fibres. The innervation of the nasal glands however appeared to consist of only acetylcholinesterase containing fibres (Figs. 12–14). These findings are in agreement with the observations in other mammals by Dahlstrom and Fuxe (1965), Nomura and Matsuura (1972) and Ishii and Toriyama (1972). From the vascular structures especially the venous-like structures in the swelling bodies of the mucosa showed a very dense network of autonomic fibres (Fig. 11). This might be related to the regulating role of these structures in the patency of the nasal cavity (Dahlstrom and Fuxe, 1965).

The electron microscopic studies showed the presence of an intra-epithelial nerve plexus, this is in agreement with the observations of Cauna et al. (1969). It can be concluded from the denervation studies that these fibres course through the pterygopalatine nerve, and that, because of their location, they are probably sensory fibres coursing from the nasal mucosa to the maxillary nerve, which, it has been suggested, contains these fibres (Christensen, 1934). Apart from this the presence of sensory nerve endings in the wall of the vessels cannot be excluded. Because they are also cholinergic they cannot be distinguished from the parasympathetic fibres with the technique used. However, the lack of any observable effect on the cholinergic fibre content after maxillary nerve transection might suggest that the contribution of the sensory fibres must be a minor one.

The disappearance of noradrenaline activity in the nasal mucosa after extirpation of the superior cervical ganglion gives histochemical evidence for the assumption that this ganglion is the main source of the sympathetic nerve supply to the nasal mucosa (Blier, 1930, Christensen, 1934). The complete abscence of both adrenergic and cholinergic nerve fibres in the nasal mucosa after transection of the pterygopalatine nerve indicates that this nerve constitutes the main pathway through which both postganglionic sympathetic and parasympathetic fibres course to the nose.

The observed disappearance of adrenergic activity after transection of the vidian nerve confirms the assumption that this nerve contains postganglionic sympathetic fibres. This finding is in accordance with the suggestion of Christensen (1934) and Malcolmson (1959). Christensen observed in the cat using the pyridine silver method, in sections of the vidian nerve small myelinated fibres originating from the greater petrosal nerve and many unmyelinated fibres These latter fibres were thought to be mainly sympathetic since they degenerated after extirpation of the superior cervical ganglion. Malcolmson (1959) concluded the presence of sympathetic and parasympathetic fibres in the vidian nerve after electrical stimulation of this nerve A weak stimulus produced a vasodilatation of the nasal vessels while a stronger stimulus resulted in vasoconstriction and reduction of the nasal resistance. This conclusion was disputed by Jackson and Rooker (1971) who suggested that the vasocontrictive effect found by Malcolmson was due to stimulation of sympathetic fibres in the neighbourhood of the vidian nerve (the perivascular plexus and maxillary nerve). The vidian nerve was concluded to contain less or even no sympathetic fibres, which were thought to reach the nose via the blood vessels and the maxillary nerve. No sympathetic fibre content of the maxillary nerve could be demonstrated by us.

Blier (1930) concluded, by measuring the nose resistance during stimulation of the various autonomic nerves, that the major portion of the sympathetic fibres must reach the nose via the maxillary nerve and a minor part via the vidian nerve.

Our denervation studies failed to show a measurable contribution from the nerve plexuses in the wall of the supplying arteries and from the maxillary nerve to the sympathetic innervation of the nasal mucosa. In view of the observed nerve plexus in the wall of the supplying arteries (Fig. 16) such a contribution cannot be completely excluded (the same applies for the parasympathetic fibres in the perivascular plexus). However, this contribution must be a minor one in comparison with that of the fibres coursing through the vidian and the pterygopalatine nerves, because no differences could be demonstrated following transection of the ethmoidal and pterygopalatine nerves alone and after combined transection of these nerves and the supplying arteries. The failure to demonstrate such a contribution of the vascular plexus might be due to the choice of the survival times and/or the limitations of techniques used, otherwise a close anatomical interrelationship between the sympathetic nerves in the vascular plexus and in the autonomic nerves might explain this. With respect to the origin and course of the sympathetic fibres it can be stated that, in view of the lack of any observable effect on the adrenergic fibre distribution in the nasal mucosa after transection of the stapedial artery, the sympathetic fibres must cross to the vidian nerve from the carotid plexus via the deep petrosal nerve. This latter nerve we were unable to localise with dissecting and histological techniques.

The lack of any observable change in the number of cholinergic fibres in the nasal mucosa after transection of the vidian nerve or the greater petrosal nerve, on the one hand, and the complete disappearance of these fibres after transection of the pterygopalatine nerve on the other provides confirmation of the presynaptic nature of these fibres proximally from the pterygopalatine ganglion. This is in accordance with the assumption made by Tschallussow (1913) and Malcolmson (1959).

Apart from this no detectable contribution of the ethmoidal nerve to the autonomic nerve supply of the nose was found, as suggested by Mitchell (1954) and Malcolmson (1959).

The small amount of residual nerve activity observed after denervation in those experiments in which the arterial plexuses were also transected is not clearly understood. Because we were unable to establish exactly the time course of denervation and reinnervation, this phenomenon might represent either residual nerve activity after denervation or evidence of reinnervation in some cases. Furthermore a contribution from the posterior superior alveolar nerve to the innervation of the nasal mucosa might be at least in part responsible for these observations.

Serial sections from the nose showed penetration of branches of this nerve into the septal mucosa.

The observed changes in the mucosa with the electron microscope after transection of the pterygopalatine nerve and the extirpation of the superior cervical ganglion indicate that the role of the autonomic nerve supply is more complicated than only a regulatory one on the size of the erectile tissue discussed in Chapters V and VI.

The increase in the number of lymphocytic cells, also observed by Whicker et al. (1973) after sympathectomy in dogs, and macrophagic cells can be attributed to degenerative changes in the glandular tissue, resulting in a decreased thickness of the protective mucous layer on the epithelial lining.

These findings disagree with those of Krajina et al. (1972), who observed in dogs oedema and an increase in the volume of glandular tissue a few days after ganglionectomy. Even with electron microscopy, we were not able to confirm these changes except for submicroscopic changes in the acinar cells and an increase in the collagen content of the interstitial space. Their observations might be due to the techniques they used: taking biopsies instead of studying the whole septum and the choice of the postoperative period of only four days.

Although the histological and histochemical used techniques enabled us to obtain a rough impression of the metabolic activity of the various mucosal structures, the use of more sophisticated methods like radioautography and microchemical techniques, as well as more systematic electron microscopic studies is necessary in order to study the metabolic activity of these structures more extensively in normal animals and after denervation.

The long term experiments showed a reinnervation of both sympathetic and parasympathetic systems, although with these experiments we were unable to trace the actual mode of reinnervation. It seems likely that severed postganglionic nerve fibres will regenerate from the proximal stump. The appearance of new sympathetic fibres after extirpation of the superior cervical ganglion is less easy to explain. After unilateral ganglion extirpation the nerve fibres from one side might cross to the other side, but reinnervation after bilateral ganglionectomy must involve other sources. Reinnervation after extirpation of the superior cervical ganglion takes longer than after postganglionic transection of the nerves as can be concluded from the data in Tables 1–3.

In conclusion, these results in the rat highlight the importance of obtaining more insight into the events occurring in man after vidian neurectomy, particularly in the long run.

CHAPTER V

PHYSIOLOGY OF THE RAT NOSE

1. INTRODUCTION

The function of the respiratory part of the nose is to protect the deeper airways by filtering, humidification and thermogulation of the inhaled air. The importance of this protective function is demonstrated by the existence of a nasopulmonary reflex arch (Krajina, 1970; Ogura, 1970). This regulatory function of the nasal mucosa involves fluctuation in the vasomotor and secretory activity of the nasal mucosa (Proetz, 1953) related to the environmental conditions. This mechanism has been shown to be controlled by the autonomic nervous system. Adrenergic activity results in vasoconstriction of the mucosal vessels (increased patency of the nasal lumen). Cholinergic activity however results in vasodilatation (decreased patency and presumably an enhancement of the secretory activity of the nasal glands as well as an increase of vascular permeability).

Apart from these adaptive fluctations in the vasomotor and secremotor activity of the nasal mucosa, regular rhythmic activity in the dilated state of the mucosa, alternating between both nares, has been shown to exist in humans (Stocksted and Thomsen, 1953). The driving force for this mechanism is still unclear.

In previous chapters the existence of a rich autonomic nerve supply to the nasal mucosa in the rat was remarked upon. This nerve plexus disappeared shortly after transection of the appropriate nerves, but reinnervation appeared to take place after longer postoperative periods.

Because of the observed influence of the autonomic nervous system on the condition of the nasal mucosa (Tschallussow, 1913; Blier, 1930, Fowler, 1943; Malcolmson, 1959), the effect of selective transection of this nerve system on nasal patency was investigated. The patency of both halves of the nose (closely related to the swelling condition of the mucosa) was measured in normal animals and after denervation with the mirror technique according to Zwaardemaker (1889), as described in Chapter III. This mirror test turned out to be less complicated than the use of a rhinomanometer, the development of which to make it suitable for rats gave large problems. The patency of the two halves of the nose was determined from the size of the condensation patches produced by the expired air. Possible changes in the secretory activity of the glands could not be determined by this method.

2. THE NORMAL RAT

Each animal was measured 7 times in one session, the interval between each measurement being 15 minutes. In order to evaluate the usefulness of the Zwaardemaker method in rats, the effect of application of a small amount of adrenalin solution (1:1000) in the right nasal cavity was registered shortly after administration. Increased patency of the right nasal cavity was observed in comparison with the untreated side (Table 4). Fig. 24 shows a photograph of the condensation patches produced on the mirror after adrenalin application. The record of a normal cycle is shown in Fig. 25. The cycle period (T) in this experiment was determined in the following way. The first transition from effect A (the condensation patch on the right side larger than on the left) to B (the condensation patch on the left side larger than on the right) was defined as the starting point for the half period ($\frac{1}{2}$T).

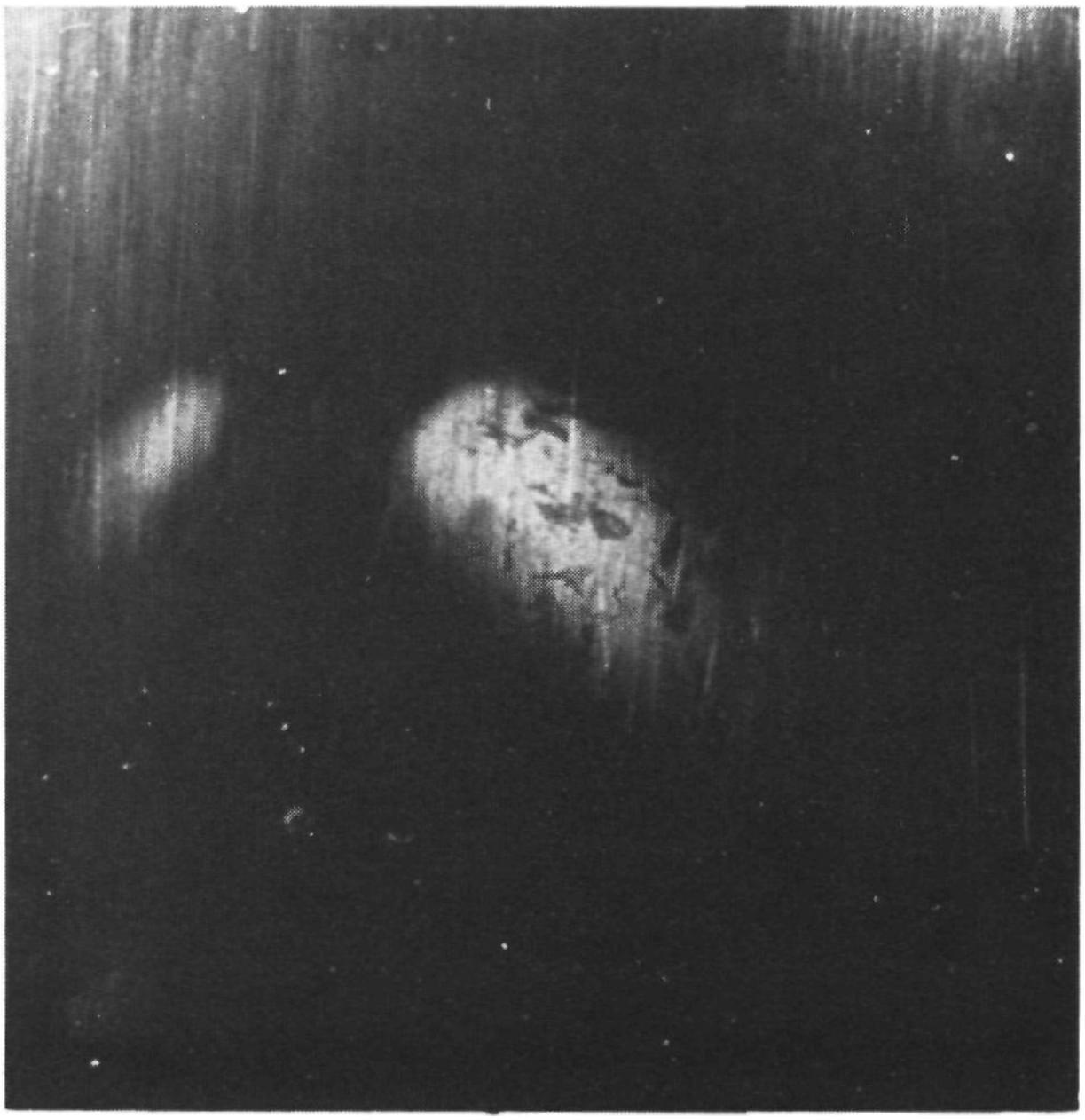

Fig. 24. Photograph of the condensation patches produced by the outflowing air from the nose of the rat after application of adrenalin in the right nasal cavity. Adrenalin application revealed an increase of the nasal patency.

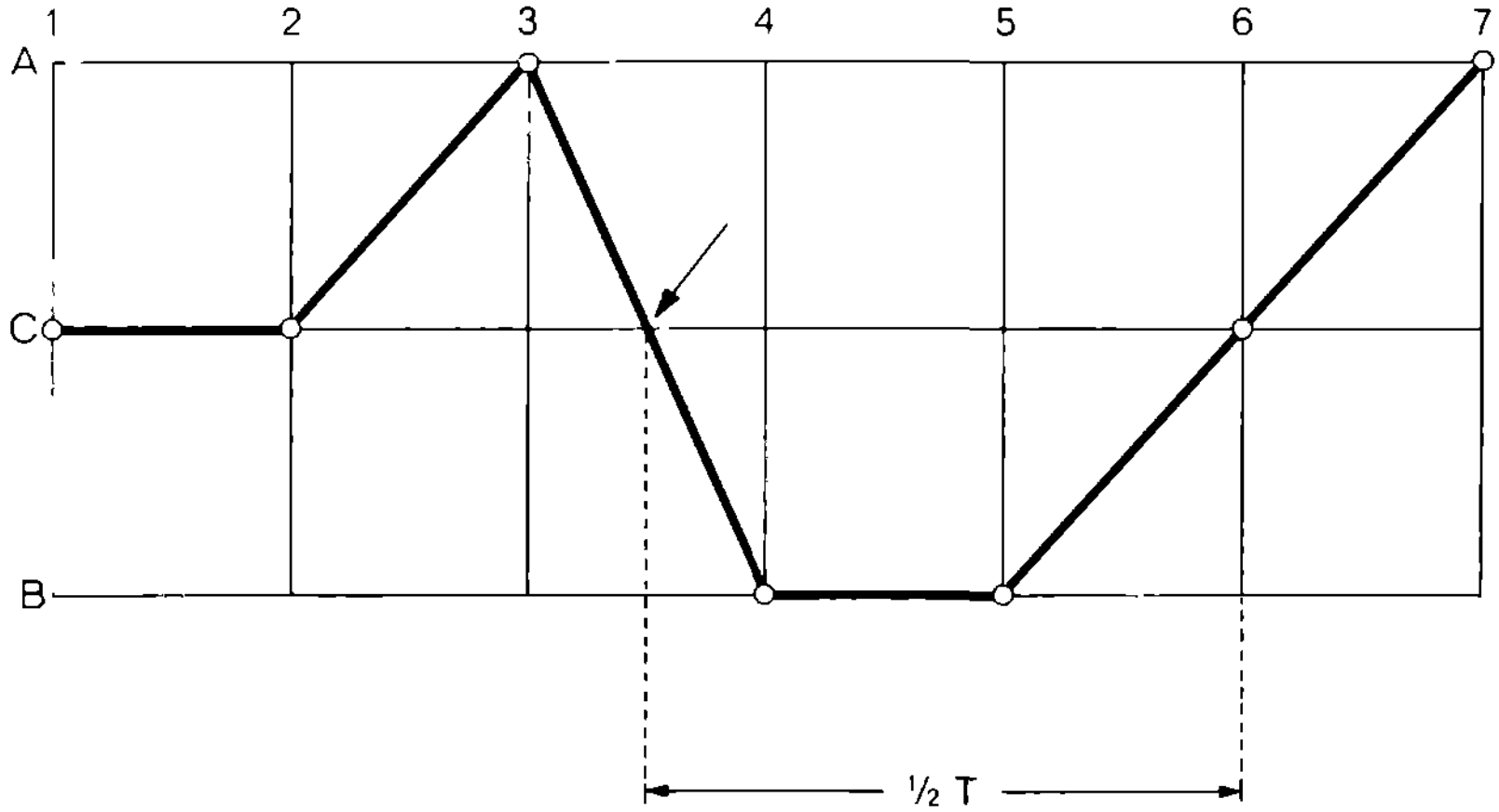

Fig. 25. Record of the nasal cycle of a normal rat. The patency of the nasal cavities was measured 7 times (Arabic figures) every 15 minutes by comparing the size of the condensation patches of both halves of the nasal cavity. A: patch on the right side larger than on the left side; B: left side larger than right side; C: both sides equal. ½T = 5/8 hour = half period.

This starting point for the half period, as indicated in Fig. 25, lies between measurements 3 and 4. This point indicates a real or virtual effect C (both sides equal). The end point of the half period is the next effect C (measurement 6). In this experiment $\frac{1}{2}T = 2\frac{1}{2} \times \frac{1}{4} = \frac{5}{8}$ hour. In this way $\frac{1}{2}T$ was determined from all normal animals (N = 21). The average value of T appeared to be 61 minutes (SE: 20 min.). The overall score from this group of normal animals is 38A; 33B; 76C. According to χ^2 test this is compatible with the relationship A:B:C = 1:1:2. Testing of the transitions in the same way showed that transitions to A or B are each half as likely as transitions to C. According to these results the existence of a one hour cycle ACBC can be considered as the average nasal cycle in the rat. The test interval and the test period in these experiments turned out to be valid.

3. DENERVATED RAT

The observations made on the denervated animals were registered in the same way as in the case of the normal rats (represented in Fig. 25). The results obtained at various times after denervation are summarized in Table 4. These observations were tested against those in normal animals in contingency tables using the χ^2 test. This test could not be applied in those cases where only 3 or less animals were available. The P-value indicated in

Table 5 gives the probability of the frequencies observed for the codes A, B and C tested against the frequencies in the normal animals.

Apart from testing the frequencies of the codes, the frequency of the various transitions of the codes were tested. No fundamental differences appeared to exist between the results obtained with these two methods. Two weeks after extirpation of the cervical ganglion the nasal cycle was significantly different from normal with decreased nasal patency on the operated side (effect B). One year after ganglionectomy a tendency towards normal nasal cycle was observed.

Transection of the greater petrosal nerve showed a nasal cycle significantly different from normal with increased nasal patency on the operated side (effect A). No indication of this effect was observed after one year.

A significant disappearance of the periodic lateralisation of the nasal cycle (effect C) was observed 2 weeks after transection of the pterygopalatine nerve and the vidian nerve. Although transection of the maxillary and ethmoidal nerves failed to show a significant change in the nasal two weeks after the operation, the results obtained indicate a smoothing of the normal nasal cycle. Those animals which survived for one year after transection of the ethmoidal nerve showed a nasal cycle not significantly different

Table 4

The patency of the nasal cavity in the normal rat and after selective unilateral transection of the autonomic nerves measured with the Zwaardemaker mirror technique.

Category	Survival time	No. of animals	Effect A	B	C	P-value in range	
Normal		21	38	33	76		
Sup. cerv.	2 weeks	5	0	15	20	0.001	S
ganglion	1 year	3	4	8	9		
Greater	2 weeks	5	26	0	9	0.0005	S
petr. nerve	1 year	3	3	13	5		
Pterygopalatine nerve	2 weeks	7	9	5	35	0.025–0.05	S
Vidian nerve	2 weeks	6	3	9	30	0.01–0.02	S
Maxillary nerve	2 weeks	3	1	4	16		
Ethm. nerve	2 weeks	2	2	1	11		
	1 year	5	8	6	21	0.60–0.70	

S = significant deviation from normal cycle.
A = patch right side larger than left side.
B = patch left side larger than right side.
C = both patches of equal size.

from normal, as, after only two weeks, did sham operated animals in which only the autonomic nerve fibres were exposed.

4 DISCUSSION

From the results obtained with the unilateral application of adrenalin resulting in an increase in size of the nasal lumen, the conclusion can be drawn that the Zwaardemaker mirror test is a reliable method for measuring the relative patency of the nasal cavities in the rat. This method enabled us to establish the existence of a cyclic activity (nasal cycle) in the patency of both halves of the nose in normal animals (Table 4). The calculated phase length of 61 minutes of this cycle is within the range of 30–85 minutes as reported by Bojsen-Møller (1971). The pattern of this cycle appears to be fully comparable to that observed in humans as described by Stocksted and Thomsen (1953).

The results of unilateral extirpation of the superior cervical ganglion and transection of the greater petrosal, pterygopalatine and vidian nerves clearly demonstrate significant disturbance of the normal cycle. These nerves have in common that they contain autonomic nerve fibres, sympathetic or parasympathetic or both types of fibres supplying the respiratory part of the nasal mucosa as described in Chapter IV.

From the short-term effects of transection of these nerves on this cyclic activity (Table 5) it can be concluded that the existence of a normal nasal cycle is strongly dependent on the integrity of the autonomic nerve supply, a conclusion supported by the observations of Keuning (1968). He observed disappearance of the nasal cycle in patients who underwent transection of the greater petrosal nerve to treat Horner's syndrome. Although the effect of ethmoidal and maxillary nerve transection on the nasal cycle could not be tested statistically because of the low number of experimental animals, the short term results indicate a smoothing effect on the cycle. This disturbance is difficult to explain because we were unable to demonstrate an observable contribution of these nerves to the autonomic nerve plexus in the nasal mucosa. This smoothing effect might be attributed to severing of the sensory fibres of the nasal mucosa, suggested to course through the maxillary nerve (Jackson and Rooker, 1971) and the ethmoidal nerve (Mitchell, 1954).

Extirpation of the superior cervical ganglion showed a significant narrowing of the nasal lumen. The superior cervical ganglion has been shown to be the main source of the sympathetic nerve supply of the nasal mucosa (Chapter IV, Table 1), extirpation of which leads to a predominance of the parasympathetic nerve supply, resulting in the observed narrowing of the nasal lumen. These findings agree closely with the observations of Fowler (1943) and Malcolmson (1959). The same applies for transection of the greater petrosal nerve (parasympathetic) which leads to a predominance of the sympathetic system resulting in the observed widening of the nasal lumen on the denervated side.

Transection of the pterygopalatine nerve and vidian nerve shows no real predominance of one of the autonomic nerve systems, i.e. no lateralisation effect, but a smoothing of the nasal cycle. In view of our findings, presented in Chapter IV, that these nerves contain both sympathetic and parasympathetic fibres no predominance of one of the systems can be expected.

Unfortunately we were unable to measure nasal patency one year after selective transection of all the different types of autonomic nerve transection, because the majority of the animals which survived for one year after selective nerve transection showed acute inflammation or signs of a past inflammatory disease, although we have no reason to suggest any relationship between this and the transection of the autonomic nerves. Inflammation of the respiratory epithelium is not unknown in older rats, as confirmed by the same observations being reported by v.d. Broek (1968) concerning the mucosa of the middle ear. Therefore only animals who underwent superior cervical ganglionectomy and ethmoidal nerve and greater petrosal nerve transection could be tested one year postoperatively. These animals showed a nasal cycle not significantly different from normal. From the observations presented in Chapter IV (Tables 1–3) revealing a reestablishment of the autonomic nerve plexus after transection, the conclusion seems justified that this reinnervation involves a tendency towards restoration of the normal nasal cycle.

CHAPTER VI

HISTOMETRICAL STUDY OF THE NASAL MUCOUS MEMBRANE

1. INTRODUCTION

The results presented in Chapter V clearly demonstrate that the nasal patency is highly dependent on the autonomic nerve supply of the nasal mucosa. In view of these physiological observations we decided to study the dilation of the respiratory part of the nasal mucosa in histological sections, according to the methods described in Chapter III.

2. RESULTS

The results obtained after unilateral transection of the autonomic nerves are summarized in Table 5.

After the administration of adrenalin (1:1000) in the right nasal cavity the lumen on this side appeared to be significantly wider than that on the untreated left side. After unilateral transection of the various branches of the autonomic nerve supply the lateralisation ratio was within the normal range. Only transection of the greater petrosal nerve had an almost significant decongestive effect.

The results obtained after bilateral denervation are shown in Table 6. In this table the width of the nasal lumen from both sides is added. Four hours after the adinistration of reserpine (2 mg/200 g body weight, administered intramuscularly) a significant congestive effect was found.

Bilateral extirpation of the superior cervical ganglion resulted in a significant congestive effect 2 weeks after operation. After 5 months however the width of the lumina of both halves was within the normal range.

Two weeks after bilateral transection of the greater petrosal nerve the patency of the nasal cavity was clearly increased approaching the level of significance. As in the cases of unilateral transection, no significant changes in the lumen of the nasal cavities could be observed after bilateral transection of the pterygopalatine nerve, the vidian nerve and the ethmoidal nerve.

In addition to the determination of the size of the nasal lumen and mucosa, the structures of the nasal mucosa were more thoroughly investi-

Table 5
Dimensions of nasal mucosa and lumen after transection of the autonomic nerves on the right side.

Category	Survival time	No of animals	R	L	LARA		P-value in range	
			Mean	Mean	Mean	SE		
Normal		15	0 75	0 77	0 989	(0 021)	reference	
Adrenalin		2	0 77	0 72	1 038	(0 009)	0 001–0 01	S
Sup cerv	2 weeks	6	0 74	0 76	0 982	(0 036)	0 50–0 60	
ganglion	5 months	4	0 71	0 73	0 984	(0 025)	0 60–0 70	
Greater petr n	3 weeks	7	0 77	0 76	1 008	(0 021)	0 05–0 10	(S)
Pterygopalatine	4 weeks	7	0 72	0 73	0 993	(0 015)	0 60–0 70	
nerve	5 months	2	0 80	0 79	1 010	(0 040)	0 20–0 30	
Vidian nerve	2 weeks	3	0 72	0 74	0 984	(0 008)	0 60–0 70	
Maxillary nerve	2 weeks	3	0 78	0 77	1 007	(0 023)	0 20	
	5 months	2	0 77	0 76	1 007	(0 019)	0 20–0 30	
Ethm nerve	2 weeks	3	0 75	0 78	0 980	(0 013)	0 50	

$L = R = \frac{\text{Lumen}}{\text{Lumen + mucosa}}$ of left or right side

LARA = Lateralisation ratio $\frac{2\,R}{R + R}$

S = significant deviation from normal (Student's t-test)

Table 6
Dimensions of nasal mucosa and lumen after transection of the autonomic nerves on both sides.

Category	Survival time	No. of animals	R+L		P-value in range	
			Mean	SE		
Normal		15	1.52	0.097	reference	
Reserpine bilaterally		2	1.31	0.16	0.01–0.02	S
Sup. cerv. gang.	2 weeks	2	1.34	0.099	0.02–0.05	S
	5 months	2	1.44	0.085	0.30–0.40	
Greater petr. nerve	2 weeks	2	1.66	0.021	0.05–0.10	(S)
Pterygopalatine nerve	1 month	4	1.44	0.024	0.30	
Vidian nerve	2 weeks	3	1.43	0.090	0.10–0.20	
Maxillary nerve	2 weeks	3	1.49	0.159	0.70–0.80	
Ethm. nerve	2 weeks	3	1.50	0.095	0.80–0.90	

S = significant deviation from normal (Student's t-test).
For R and L see legends to Table 5.

gated. In none of the animals quoted in Tables 5 and 6 were changes other than swelling or shrinkage of the erectile tissue observed, possibly due to transection of the autonomic nerves.

3. DISCUSSION

The results presented in Table 5 and 6 give anatomical evidence for the physiological observations reported in Chapter V. The increase in patency of the nasal lumen after adrenalin application appears to be due to shrinkage of the erectile tissue of the nasal mucous membrane. In contrast to the sympathomimetic effect of adrenalin, a significant parasympathomimetic effect, swelling of the erectile tissue, was displayed after reserpine injection, demonstrating the reliability of the method used to study the dilated state of the nasal mucosa under various circumstances. However, summation of the effects on both halves of the nose after bilateral denervation seems to give more discrimination power, as might be concluded from the effects of cervical ganglion extirpation. Unilateral extirpation failed to show any significant effect, while summation of the effects from both sides after bilateral ganglion extirpation revealed significant dilation of the mucosa compared with normal.

The results obtained agree very well with the physiological and the neurohistochemical observations. The superior cervical ganglion is the main source of the sympathetic fibres and the greater petrosal nerve is the main parasympathetic nerve. Transection of one of these systems results in a predominance of the antagonist, revealing a swelling or shrinkage of the erectile tissue.

Because of the high frequence of the inflammatory disease in the nasal mucosa of the older animals no reliable data could be obtained from the animals which survived for one year postoperatively. Only in two animals which survived for 5 months after bilateral sympathectomy could return to normal be established. This finding gives morphological evidence for the tendency to a return to a normal nasal cycle (Chapter V) and the concomitant reinnervation after longer survival times (Chapter IV).

Transection of the pterygopalatine, maxillary, vidian and ethmoidal nerves failed to show any significant alteration from normal in the dilated state of the nasal mucosa, both after unilateral and bilateral denervation. These findings agree with the physiological observations 2 weeks after transection of these nerves, showing a smoothing of the nasal cycle (effect C, i.e. both sides equal patency).

In conclusion, these observations give morphological evidence for the nasal mucosa functioning as a regulator of nasal patency. The governing mechanism performing this task is highly dependent on the presence of the sympathetic and parasympathetic nerve systems. Selective transection of the main route of one of these systems results in dominance of the antagonist (congestion or decongestion). Transection of both systems and presumably also of the sensory nerve supply does not result in a significant change in the dilated state of the nasal mucosa from normal although the cyclic activity disappears.

From the results obtained from Chapters III to VI a model can be constructed of the autonomic nerve supply to the nasal mucosa of the rat. This model is represented in Fig. 26.

The main source of the sympathetic nerve supply to the nasal mucosa is the superior cervical ganglion, since the adrenergic fibres disappeared after

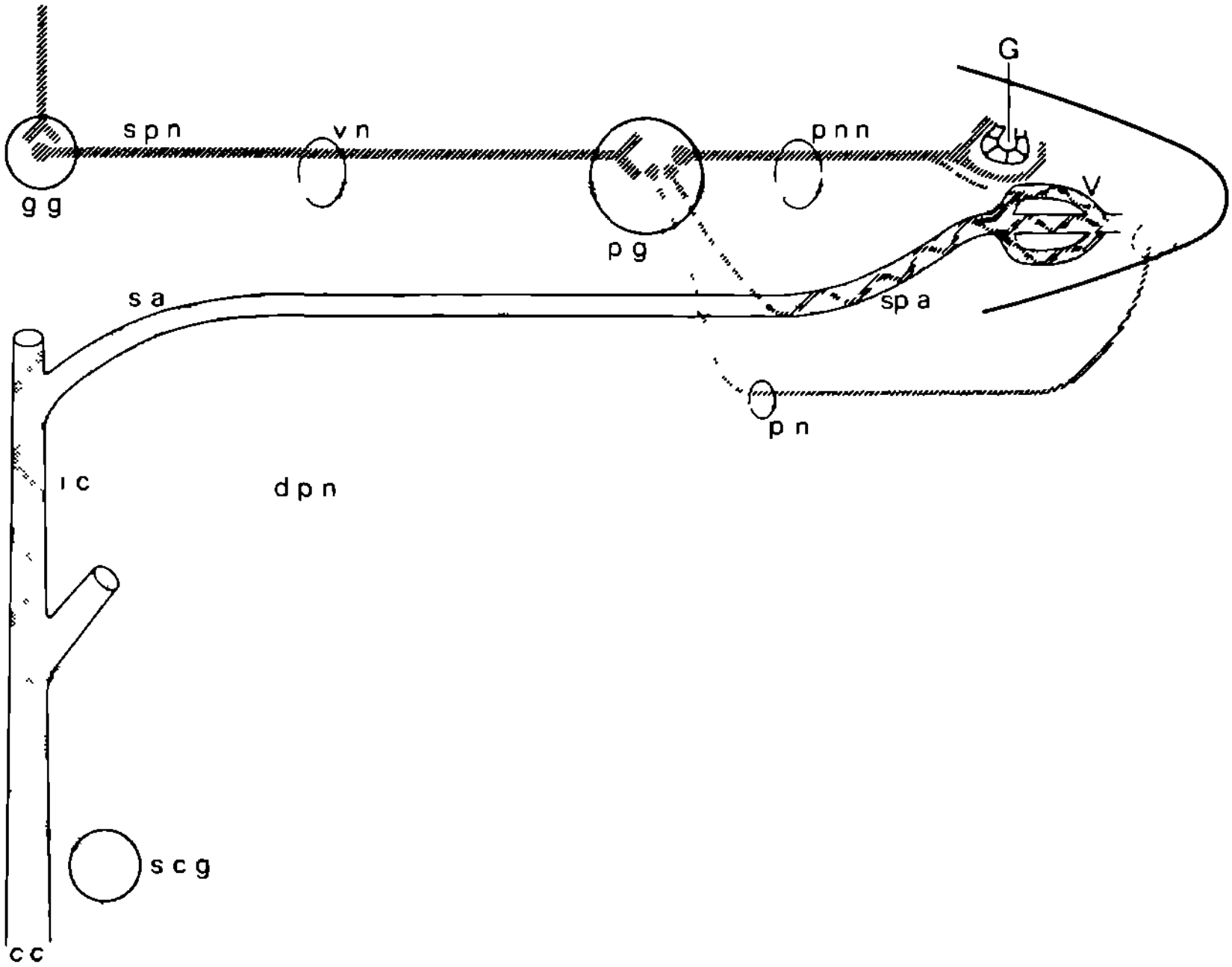

Fig. 26. Diagram of the course of the autonomic nerve fibres supplying the nasal mucosa in rats. s.c.g.: superior cervical ganglion; g.g.: geniculate ganglion; p.g.: pterygopalatine ganglion; c.c.: common carotid artery; i.c.: internal carotid artery; s.e.: stapedial artery; d.p.n.: deep petrosal nerve; s.p.n.: greater petrosal nerve; v.n.: vidian nerve; p.n.: posterior superior alveolar nerve; sp. a.: sphenopalatine artery; p.n.n.: pterygopalatine nerve; G: Glands; V. Vessels; /////// parasympathetic fibres; ▨ sympathetic fibres.

extirpation of this ganglion (Chapter IV). Moreover extirpation of this ganglion resulted in a decrease in nasal patency, indicating the absence of a sympathetic nerve supply and a predominance of the parasympathetic system. From this ganglion the sympathetic fibres cross to the carotid artery, creating a periarterial nerve plexus. Via the internal carotid artery, the stapedial artery, the pterygopalatine artery and its ramifications, sympathetic fibres reach the vascular structures of the nasal mucosa. However the contribution of this vascular plexus must be a minor one because transection of the stapedial artery failed to show any significant change in the adrenergic nerve fibre content of the nasal mucosa. Moreover no difference in the adrenergic fibre content was observed after transection of the pterygopalatine nerve alone or after combined transection of this nerve and the accompanying artery. Therefore the major part of the sympathetic fibres must reach the nose via the autonomic nerves, the vidian and the pterygopalatine nerves, transection of which induced complete disappearance of the adrenergic nerve fibres in the nasal mucosa. The only possibility is that the sympathetic fibres cross from the carotid artery to the vidian nerve via the deep petrosal nerve, as described by Christensen (1934), although we were unable to identify this nerve in rats by dissecting procedures.

The route of the main parasympathetic nerve supply of the nose between the geniculate ganglion and the vidian nerve is suggested to be along the greater petrosal nerve. These fibres have synapses in the pterygopalatine ganglion and thence travel to the nose via the pterygopalatine nerve. The lack of any change in the cholinergic nerve fibre content of the nasal mucosa after transection of the greater petrosal nerve and the vidian nerve confirms the preganglionic nature. Transection of the greater petrosal nerve resulted in an increase in nasal patency, showing a lack of parasympathetic and a predominance of sympathetic influence.

The lack of a real sympathomimetic or parasympathomimetic effects on nasal patency after transection of the vidian nerve confirms the mixed fibre content of this nerve. The postganglionic nature of the sympathetic and parasympathetic nerve fibres in the pterygopalatine nerve was concluded from the disappearance of both adrenergic and cholinergic nerve fibres and the lack of sympathomimetic or parasympathomimetic effects after transection of this nerve. Although the parasympathetic nerve fibres coursing through the pterygopalatine nerve must constitute the major part of this part of the autonomic nerve supply, a minor part will reach the nose via the observed nerve plexus in the wall of the sphenopalatine artery. These fibres must originate in the pterygopalatine ganglion because no cholinergic nerve fibres were observed in the wall of the stapedial artery. Additional support for this assumption can be derived from the lack of any effect on cholinergic nerve fibre content after transection of the stapedial artery and from the fact that no differences in the cholinergic nerve fibre content were observed after transection of the pterygopalatine nerve alone and transection of this nerve and the sphenopalatine artery. In contrast to the sympathetic the parasympathetic fibres innervate both vascular structures and glands. Moreover a close relationship appears to exist between the perivascular and periglandular nerve plexus (Figs. 13 and 14). These findings do not support the assumption made by Ishii and Toriyama (1972) that the vasomotor and secremotor nerve fibres in the nasal mucosa should originate from different sources.

In view of the lack of neurohistochemical evidence for a measurable contribution of the maxillary and ethmoidal nerve to the autonomic innervation of the nasal mucosa, the observed smoothing effect after transection of these nerves might be attributed to transection of sensory fibres suggested to course from the nasal mucosa through these nerves (Mitchell, 1954; Jackson and Rooker, 1971). Although the palatine branch (posterior superior alveolar nerve) of the pterygopalatine ganglion mainly supplies the palatine structures, a small contribution to the autonomic nerve system of the nasal mucosa seems likely as discussed in Chapter IV.

Reinnervation of the nasal mucosa measured by neurohistochemical techniques in rats appeared to occur between 2 and 12 months after transection of the appropriate nerves. This reinnervation appeared to involve, as can be concluded from the behaviour of the erectile tissue, a restoration of functional activity.

In view of the use of transection of the autonomic nerve supply of the nasal mucosa in case of 'vasomotor rhinitis', i.e. vidian neurectomy, the observed reinnervation raise the question of whether this therapy is long-lived. Apart from our observations, reinnervation of the autonomic nerve system has been established in other organs by various authors in recent years (Malmfors and Olson, 1967; Jacobowitz and Laties, 1970; Garett, 1971).

These findings stress the importance of obtaining more insight into the events occurring after vidian neurectomy used in humans to cure severe cases of vasomotor and atopic rhinitis, especially in the long term.

SUMMARY

The origin, course and function of the autonomic nerve supply of the respiratory part of the nasal mucosa in rats is traced, using the results of histological, electron microscopic, neurohistochemical and physiological investigations in normal animals and in those in which the appropriate autonomic nerves had been selectively transected.

The experimental methods used, anatomy and the main features of the vascularisation of the nasal mucosa are described, concentrating on the distribution and origin of the autonomic nerve fibres, in both normal and selectively denervated rats.

The vascular structures of the nasal mucosa appear to be innervated by both adrenergic and cholinergic nerve fibres. The mucosal glands, however, display only cholinergic innervation. Close interconnection appears to exist between the perivascular and periacinar nerve plexuses. The main source of the sympathetic fibres is the superior cervical ganglion, the main parasympathetic nerve trunk being the greater petrosal nerve. The autonomic fibres reach the nose mainly via the pterygopalatine nerve and along the supplying blood vessels

Transection of the supplying nerves showed after an initial disappearance of the autonomic nerve endings in the nasal mucosa, a reinnervation between 2 and 12 months postoperatively.

In the normal animal cyclic changes in the patency of the nasal lumen occur with a cyclus time of 61 minutes, disturbances being observed in this rythm a few weeks after transection of the various autonomic nerves, although after longer postoperative periods reinnervation brought with it a tendency to return to normal

A model of the origin and course of the autonomic nerve supply was constructed from the histochemical and physiological findings

SAMENVATTING

Het verloop en de functie van de autonome zenuwvoorziening van het respiratoire deel van het neusslijmvlies werden bestudeerd met behulp van histologische, neurohistochemische en physiologische methodieken Hiertoe werd gebruik gemaakt van normale ratten en ratten waarbij de autonome zenuwen selectief waren doorgesneden

In hoofdstuk I wordt een overzicht gegeven van de litteratuur aangaande de functie van het autonome zenuwstelsel op het gedrag van het neusslijmvlies

De gebruikte technieken zijn beschreven in hoofdstuk II

In hoofdstuk III wordt de anatomie, de innervatie en de vascularisatie van de neus bij de rat beschreven

De resultaten van het neurohistochemisch en electronenmicroscopisch onderzoek (hoofdstuk IV) tonen aan dat de bloedvaten in het neusslijmvlies zowel door cholinerge als adrenerge vezels geinnerveerd worden. De klieren blijken alleen een cholinerge innervatie te hebben Er blijkt een nauw contact te bestaan tussen de perivasculaire en de periglandulaire zenuwplexus Het ganglion cervicale superior is de belangrijkste bron van de adrenerge vezels De parasympathische vezels blijken uit de nervus petrosus superficialis major te komen Beide soorten zenuwvezels bereiken het neusslijmvlies via de nervus pterygopalatinus en de bloedvaten Na een aanvankelijke verdwijning van de perifere zenuwuiteinden in het neusslijmvlies na doorsnijding van de verschillende autonome zenuwen bleek een reinnervatie op te treden na een periode varierend van 2–12 maanden

In de hoofdstukken V en VI wordt de doorgankelijkheid van de neus beschreven bij normale ratten en na denervatie Bij normale dieren werd een cyclische verandering in de doorgankelijkheid van de neus aangetoond (cyclustijd 61 min) Doorsnijding van de verschillende autonome zenuwen blijkt een verstoring van de cyclus tot gevolg te hebben Enkele maanden na doorsnijding werd een tendens naar een herstel van de normale cyclische activiteit waargenomen

Naar aanleiding van de resultaten verkregen met neurohistochemische en physiologische methoden werd een model gemaakt over het verloop van de autonome vezels

REFERENCES

Bayliss, B J and A Todrick (1956) The use of selective acetylcholinesterase inhibitor in the estimation of pseudocholinesterase activity in rat brain Biochem. J 62 62

Bernard, C (1853) Leçons sur la physiologie et la pathologie du système nerveux Ed J B Baillière, Paris

Bichat, M F X (1802) Traité d'anatomie descriptive Gabon & Cie, Paris

Blier, Z (1930) Physiology of the sphenopalatine ganglion Am J Physiol 93 398

Bojsen-Møller, F (1964) Topography of the nasal glands in rats and some other mammals. Anat Record 150 11

Bojsen-Møller, F (1965) The anterior nasal glands Int Rhinol 3 117

Bojsen-Møller, F (1971) Nasal swell-bodies and cyclic changes in the air passage of the rabbit nose J Anat 110 25

Broek, P van den (1968) The fate of incus grafts Thesis, Nijmegen

Burger, H (1927a) Das Ganglion Sphenopalatinum Acta Otolaryngol 11 221

Burger, H (1927b) Het syndroom van het ganglion sphenopalatinum Ned T Geneeskunde 71 205

Cauna, N , K H Hinderer and R T Wentges (1969) Sensory receptor organs of the human nasal respiration mucosa Amer J Anat 124 187

Chandra, R (1969) Transpalatine approach for vidian neurectomy Arch Otolaryngol 89 542

Christensen, K (1934) The innervation of the nasal mucosa with special reference to its afferent supply Ann Otol Rhinol Laryngol 43 1066

Dahlstrom, A and K Fuxe (1965) The adrenergic innervation of the nasal mucosa of certain mammals Acta Otolaryngol 59 65

Falck, B (1962) Observations on the possibilities of the cellular localization of the monoamines by a fluorescence method Acta Physiol Scand Suppl 197 1

Falck, B , N A Hillarp, G Thieme and A Torp (1962) Fluorescence of catecholamines and related compounds condensed with formaldehyde J Histochem Cytochem 10 348

Fowler, E P (1943) Unilateral vasomotor rhinitis due to interference with cervical sympathetic system Arch Otolaryngol 37 710

Gardner, W J , A Stowell and R Dutlinger (1947) Resection on the greater superficial petrosal nerve in the treatment of unilateral headache J Neurosurg 4 105

Garett, J R (1971) Changes in autonomic nerves of salivary glands on degeneration and regeneration Progr in Brain Res 34 475

Gaskell, W H (1886) On the structure, distribution and function of the nerves which innervate the visceral and vascular systems J Physiol 7 1

Golding Wood, P H (1961) Observations on petrosal and vidian neurectomy in chronic vasomotor rhinitis J Laryngol 75 232

Golding-Wood, P H (1962) Pathology and surgery of chronic vasomotor rhinitis J Laryngol 76 969

Golding-Wood P H (1963) The surgery of nasal allergy Int Rhinol 1 188

Golding-Wood, P. H. (1973) Vidian neurectomy: Its results and complications. Laryngoscope 83:1673.

Greene, E. (1959): Anatomy of the rat. Ed. Hafner Publishing Co., New York.

Gregson, A. E. W. (1970): Experiences with vidian neurectomy. J. Laryngol. 84:221.

Hiranandani, N. C. (1966): Treatment of chronic vasomotor rhinitis with clinicopathological study of vidian nerve section in 150 cases. J. Laryngol. 80:902.

Ishii, T. and M. Toriyama (1972): Acetylcholinesterase activity in vasomotor and secretory fibres of the nose. Arch. Klin. exp. Ohr-Nasen und Kehlkopfheilk. 201:1.

Jackson, R. T. and D. W. Rooker (1969): The effects of certain drugs, cervical sympathetic stimulation and section on nasal patency. Ann. Otol. Rhinol. Laryngol. 78:403.

Jackson, R. T. and D. W. Rooker (1971): Stimulation and section of the vidian nerve in relation to autonomic control of the nasal vasculature. The Laryngoscope 81:565.

Jacobowitz, D. and M. Laties (1970): Adrenergic reinnervation of the cat ovary, transplanted to the anterior chamber of the eye. Endocrinology 86:921.

Jung, L., R. Tagand and F. Chavanne (1925): Recherches expérimentales sur la physiologie du ganglion spheno-palatin. Otorhinolaryngologic Int. 9:449.

Keuning, J. (1968): On the nasal cycle. Thesis, Leiden.

Karnovsky, M. J. and Roots, L. (1965): A 'direct-coloring' thiocholine method for localizing cholinesterase activity. J. Histochem. Cytochem. 12:219.

Krajina, Z. (1970): The relationships between upper and lower respiratory tracts in bronchial asthma. Ann. Otol. Rhinol. Laryngol. 79:506.

Krajina, Z., J. E. Harvey and J. H. Ogura (1972): Experimental vasomotor rhinitis. Acta Otolaryngol. 73:212.

Krajina, Z. (1973): Vidian neurectomy in vasomotor rhinitis. Acta Otolaryngol. 76:366.

Langley, J. N. (1903): The autonomic nervous system. Brain 26:1.

Lorenz, M. O. (1905): Methods of measuring the concentration of wealth. Quarterly publications. Ann. Stat. Ass. June: 209.

Luft, J. H. (1961): Improvements in epoxy resin embedding methods. J. Biophys. Biochem. Cytol. 9:409.

Malcolmson, K. G. (1959): The vasomotor activities of the nasal mucous membrane. J. Laryngol. 73:73.

Malmfors, T. and L. Olson (1967): Adrenergic reinnervation of anterior chamber transplants. Acta Physiol. Scand. 71:401.

Martin, E. G. and W. L. Mendenhall (1915): The response of the vasodilator mechanism to weak intermediate and strong sensory stimulation. Am. J. Physiol. 38:98.

Mendenhall, W. L. (1915): Studies of autonomic thresholds. Am. J. Physiol. 36:57.

Mitchell, G. A. G. (1954): The autonomic nerve supply of the throat, nose and ear. J. Laryngol. 495.

Montgomery, W. W., R. Katz and J. F. Gamble (1970): Anatomy and surgery of the pterygopalatine fossa. Ann. Otol. Rhinol. Laryngol. 79:606.

Negus, V. (1958): Comparative anatomy and physiology of the nose and paranasal sinuses. Ed. Livingstone Ltd., Edinburgh.

Nomura, Y. and T. Matsuura (1972): Distribution and clinical significance of the autonomic nervous system in the human nasal mucosa. Acta Otolaryngol 73:493.

Ogura, J H (1970) Physiologic relationships of the upper and lower airways Ann Otol Rhinol Laryngol 79 495

Prevost, J L (1868) Recherches anatomiques et physiologiques sur le ganglion sphenopalatin Arch Physiol Norm Pathol 1 7, 207

Proetz, A W (1953) Applied physiology of the nose Ed Mosby, St Louis

Ramadier, J (1924) Discussion Ann Mal Oreille 42 604

Reynolds, E S (1963) The use of lead citrate at high PH as an electronopaque stain in electron microscopy J Cell Biol 17 208

Sluder, G (1908) The role of the sphenopalatine ganglion in nasal headaches N Y Med J 87 989

Sluder, G (1909) The anatomical and clinical relations of the sphenopalatine (Meckel's) ganglion to the nose and its accesory sinuses N Y Med J Tr Am Laryngol Ass August 1909

Sluder, G (1910a) Further clinical observations on the sphenopalatine ganglion (motor, sensory, gustatory) N Y Med J 16 850

Sluder, G (1910b) The syndrome of the sphenopalatine ganglion neurosis Am J Med Sci 140 868

Sluder, G (1911) A phenol (carbolic acid) injection treatment for sphenopalatine ganglion neuralgia JAMA 61 1201

Sluder, G (1927) Nasal neurology headaches and eye disorders Ed Mosby, St Louis

Steno, N (1664) De musculis et glandulis Edited by W Meyer, in Kenntnis der Anatomie und Histologie der lateralen Nasendrusen Zurich (1903)

Sternberg (1925) Beitrage zur Physiologie und Pathologie der Schleimhaut der Luftwege Z Hals Nas und Ohrenheilkunde 12 340

Stocksted, P and K A Thomsen (1953) Changes in the nasal cycle under stellate ganglion block Acta Otolaryngol suppl 109 176

Tatum, A L (1923) The effect of deficient and excessive pulmonary ventilation on nasal slime Am J of Physiol 65 229

Tschallussow, M A (1913) Die Innervation der Gefasse der Nasenschleimhaut Pflug Arch 151 523

Watson, M C (1958) Staining tissue sections for electronmicroscopy with heavy metals J Biophys Biochem Cytol 4 475

Wentges, R Th R (1973) De chirurgie van de fossa pterygopalatina Thesis, Nijmegen

Whicker, J H , H B Neel and E B Kern (1973) A model for experimental vasomotor rhinitis Laryngoscope 83 915

Zwaardemaker, H (1889) Ademaanslag als diagnosticum der nasale stenose Ned T Geneeskunde 25 297

CURRICULUM VITAE

De promovendus werd geboren op 30 augustus 1942 te Uithuizen Na het behalen van het H B S -B diploma, begon hij in 1960 de studie aan de Medische Faculteit van de R U te Groningen Het doctoraal examen werd aldaar afgelegd in 1966 Hierna volgden co-assistentschappen te Deventer

In 1968 behaalde hij het artsexamen te Groningen, waarna hij enkele maanden assistent was in de Algemene Chirurgie aan het St Jozefziekenhuis te Deventer Na het volbrengen van de militaire dienstplicht begon hij in 1970 zijn opleiding in de Keel-, Neus- en Oorheelkunde aan de kliniek voor Keel-, Neus- en Oorziekten van het St. Radboudziekenhuis te Nijmegen

Gedurende zijn opleiding verbleef hij drie maanden aan de ENT Department van de Dundee Royal Infirmary te Dundee, Schotland Sinds juli 1974 is hij werkzaam als Keel-, Neus-, Oorarts aan het St Laurentiusziekenhuis te Roermond

Stellingen

1. De doorsnijding van de nervus vidianus als therapie voor rhinitis vasomotoria berust op onvoldoende fundamentele gegevens.

2. De spiegeltest volgens Zwaardemaker is een bruikbare methode voor een snelle bepaling van de neusdoorgankelijkheid.

3. Voor het bewaren van homologe trommelvlies- en ketentransplantaten verdient alcohol 70% of cialit de voorkeur boven formaldehyde 4%.

4. Gezien het gedrag van de op verschillende wijzen gepreserveerde gehoorbeentjes na transplantatie bij dierexperimenteel onderzoek is het niet te voorspellen wat het lot van getransplanteerde gehoorbeentjes op de lange duur zal zijn.

   van den Broek P. en Kuijpers W. (1974)
   Acta Otolaryng. 77:335

5. Het verdient aanbeveling om bij patiënten met een asthmatische bronchitis als routine röntgenonderzoek van de neusbijholten te verrichten.

6. Toename van de luchtverontreiniging en verbetering van het longfunctieonderzoek maken het gedeelte van de bevolking dat voldoet aan de criteria voor CARA dermate groot, dat men zich moet afvragen of dit laatste een kwantitatief dan wel een kwalitatief begrip is.

7. Om het uiteengroeien van de eerste- en tweedelijnsgeneeskunde te voorkomen verdient het aanbeveling om de huisarts bij de opleiding van de specialist evenzeer een plaats te geven als de specialist bij de opleiding van de huisarts.

8. Het ontbreken van regionale onderzoekingen is een van de oorzaken waarom meerjarenplannen in de ontwikkelingslanden mislukken.

9. De schilder H. N. Werkman kan als 'drukker van het paradijs' niet ingedeeld worden bij het Dadaisme in Nederland.

   K. Schippers
   Holland Dada, Querido, 1974.

10. De duidelijkheid in de Nederlandse politiek is niet gebaat bij een twee partijenstelsel.

11. Bij het oplossen van het probleem wie van de partners in een voltooid gezin gesteriliseerd moet worden, verdient het aanbeveling gebruik te maken van het aftelrijmpje 'iene, miene mutte . . .'

Stellingen behorende bij het proefschrift van J. J. Grote.
1 nov. 1974.