

PDF hosted at the Radboud Repository of the Radboud University Nijmegen

The following full text is a publisher's version.

For additional information about this publication click this link.

<http://hdl.handle.net/2066/136408>

Please be advised that this information was generated on 2017-12-05 and may be subject to change.

Novel compound heterozygous *NMNATI* variants associated with Leber congenital amaurosis

Anna M. Siemiatkowska,¹ L. Ingeborgh van den Born,² Maria M. van Genderen,³ Mette Bertelsen,^{4,5,6} Ditta Zobor,⁷ Klaus Rohrschneider,⁸ Ramon A.C. van Huet,⁹ Siska Nurohmah,^{1,10} B. Jeroen Klevering,⁹ Susanne Kohl,⁷ Sultana M.H. Faradz,¹⁰ Thomas Rosenberg,^{4,6} Anneke I. den Hollander,^{1,9,11} Rob W.J. Collin,^{1,11} Frans P.M. Cremers^{1,11}

¹Department of Human Genetics, Radboud University Medical Center, Nijmegen, The Netherlands; ²The Rotterdam Eye Hospital, Rotterdam, The Netherlands; ³Bartiméus Institute for the Visually Impaired, Zeist, The Netherlands; ⁴Kennedy Center Eye Clinic, Glostrup Hospital, Glostrup, Denmark; ⁵Department of Ophthalmology, Glostrup Hospital, Glostrup, Denmark; ⁶Faculty of Health and Medical Sciences, University of Copenhagen, Copenhagen, Denmark; ⁷Institute for Ophthalmic Research, Centre for Ophthalmology, University of Tuebingen, Tuebingen, Germany; ⁸Department of Ophthalmology, University of Heidelberg, Heidelberg, Germany; ⁹Department of Ophthalmology, Radboud University Medical Center, Nijmegen, The Netherlands; ¹⁰Division of Human Genetics, Center for Biomedical Research, Faculty of Medicine, Diponegoro University, Semarang, Indonesia; ¹¹Radboud Institute for Molecular Life Sciences, Radboud University Medical Center, Nijmegen, The Netherlands

Purpose: The gene encoding nicotinamide nucleotide adenylyltransferase 1 (*NMNATI*) was recently found to be mutated in a subset of patients with Leber congenital amaurosis (LCA) with macular atrophy. The aim of this study was to determine the occurrence and frequency of *NMNATI* mutations and associated phenotypes in different types of inherited retinal dystrophies.

Methods: DNA samples of 161 patients with LCA without genetic diagnosis were analyzed for variants in *NMNATI* using Sanger sequencing. Variants in exon 5 of *NMNATI*, which harbors the majority of the previously identified mutations, were screened in 532 additional patients with retinal dystrophies. This cohort encompassed 108 persons with isolated or autosomal recessive cone-rod dystrophy (CRD), 271 with isolated or autosomal recessive retinitis pigmentosa (RP), and 49 with autosomal dominant RP, as well as 104 persons with LCA in whom the causative mutation was previously identified.

Results: Compound heterozygous alterations were found in six patients with LCA and in one person with early-onset RP. All except one carried the common p.E257K variant on one allele. Macular atrophy was absent in one patient, who carried this variant in combination with a truncating mutation on the other allele. The p.E257K alteration was also found in a heterozygous state in five individuals with LCA and one with RP while no mutation was detected on the other allele. Two individuals with LCA carried other *NMNATI* variants in a heterozygous state, whereas no *NMNATI* variants in exon 5 were identified in individuals with CRD. The p.E257K variant was found to be enriched in a heterozygous state in individuals with LCA (0.94%) compared to Caucasian controls (0.18%), although the difference was statistically insignificant ($p=0.12$).

Conclusions: Although macular atrophy can occur in LCA and CRD, no *NMNATI* mutations were found in the latter cohort. *NMNATI* variants were also not found in a large group of patients with sporadic or autosomal recessive RP. The enrichment of p.E257K in a heterozygous state in patients with LCA versus controls suggests that this allele could act as a modifier in other genetic subtypes of LCA.

Inherited retinal dystrophies (IRDs) represent a heterogeneous group of disorders characterized by the degeneration of photoreceptor cells. Variable ages of onset and diverse grades of involvement of rod and cone photoreceptor cells divide these disorders into various clinical subsets [1]. The most severe form of retinal degeneration is Leber congenital amaurosis (LCA, OMIM #204000), with severely impaired visual function from birth and strongly reduced or undetectable

electroretinogram (ERG) responses within the first year of life [2]. Another form of retinal dystrophy, involving initially rod photoreceptor degeneration which is followed by cone cell death, is retinitis pigmentosa (RP, OMIM #268000) [3]. RP is characterized by night blindness, progressive visual field deterioration, and eventual loss of central vision. In persons with cone-rod dystrophy (CRD, OMIM #120970) [4], cones are primarily involved whereas rods are concomitantly or later affected. One of the additional symptoms that may occur in LCA or CRD is macular atrophy (also called pseudocoloboma), which is not related to embryonic fissure closure [5]. Until now, mutations in 204 genes were found to be involved

Correspondence to: Frans P.M. Cremers, Department of Human Genetics, Radboud University Medical Center, P.O. Box 9101, 6500 HB Nijmegen, The Netherlands; Phone: +31-24-3613750; FAX: +31-24-3668752; email: Frans.Cremers@radboudumc.nl

in the pathogenesis of IRDs (RetNet). Recently, *NMNAT1*, a gene involved in nicotinamide adenine dinucleotide (NAD) synthesis, was found to be responsible for a subset of LCA cases, mainly with macular lesions [6-9].

Earlier studies described three nicotinamide mononucleotide adenylyltransferases catalyzing the reaction of nicotinamide mononucleotide with ATP to form NAD⁺ [10], a crucial agent in many redox reactions especially important in the central nervous system. Whereas NMNAT2 and NMNAT3 localize to the Golgi apparatus and mitochondria, respectively, NMNAT1 is a nuclear isoform that was previously studied in the Wallerian degeneration, slow (Wlds) mouse model. In these mice, a fusion protein (Wlds) was identified, consisting of Ube4b and the complete coding sequence of *Nmnat1*. Subsequently, this fusion protein was found to have a protective effect on axonal degeneration after neuronal injury [11,12], and *Nmnat1* activity was found to be required for this phenomenon [13-15]. Homozygous null mutations in this gene in *Drosophila melanogaster* and murine models result in early lethality. Heterozygous knockout mice displayed normal development [16], and a retinal knockout in the fruit fly resulted in progressive retinal degeneration [17]. NAD⁺ levels rapidly decreased in axons before their degeneration. However, retinal degeneration cannot probably be attributed to enzymatic activity of NMNAT1. An inactive *Nmnat1* in *Drosophila* prevented photoreceptor degeneration [17]. Therefore, Perrault et al. hypothesized that this protein may have an additional chaperone function [9].

The *NMNAT1* mutations reported thus far were found throughout the entire coding sequence. Most of the mutations (58%), however, are clustered in exon 5. Most variants identified in patients with LCA (31/39) are missense mutations. Only six mutations result in C-terminal truncations of *NMNAT1*, one extends the protein, and one abolishes the start codon. The most common mutation, p.E257K, was reported in 27 cases (in one case homozygously) and proven via an NAD/NADH assay to impede NMNAT1 activity when present in homozygous state in vivo and in a mutant construct in vitro [8]. The purpose of this study was to assess the prevalence of *NMNAT1* mutations in a mixed ethnicity LCA cohort and to investigate the involvement in other progressive retinal degenerations.

METHODS

Patient cohorts: A cohort of 693 patients with inherited retinal dystrophies participating in this study was collected over a period of 17 years. DNA was extracted from 8 ml of peripheral blood using standard salting-out procedure [18], and the aliquots were stored at -20°C. The group consisted of

265 LCA patients (104 with and 161 without a genetic diagnosis). In addition, an extended cohort with no established causative mutation was included in the study: 271 isolated or autosomal recessive RP probands, 49 unrelated cases with autosomal dominant RP, as well as 108 persons with isolated or autosomal recessive CRD. The patients were of mixed ethnic and geographic origin (European, African, or Asian). At least 204 healthy, unrelated individuals from the Western European population were included in this study as controls. Written informed consent was obtained from all participants. The study was approved by the local Ethics Committee and adhered to the tenets of the Declaration of Helsinki. Ophthalmic examination in seven patients with *NMNAT1* variants included best corrected visual acuity, ophthalmoscopy, and fundus photography, if feasible.

Nicotinamide nucleotide adenylyltransferase 1 sequence analysis: DNA samples of genetically unsolved patients with LCA were screened for mutations in all coding exons of *NMNAT1*. Samples underwent amplification by PCR and were analyzed with Sanger sequencing. In addition, RP and CRD samples, as well as LCA cases with previously established genetic diagnosis, were subjected to sequence analysis of exon 5 of *NMNAT1*. In this group, after a mutation was identified in exon 5, all exons of *NMNAT1*, including the non-coding exon 1, were tested with sequencing. All identified mutations were assessed for pathogenicity using the nucleotide conservation score in 44 vertebrate species (PhyloP), as well as amino acid substitution prediction programs (SIFT, PolyPhen2). To detect the p.E257K mutation in the control individuals, *BspCNI* restriction of amplified genomic DNA fragments was performed, followed by agarose gel electrophoresis. The other mutations were assessed in the control group using either amplification refractory mutation system (ARMS) PCR (p.H206R, p.V244A) or restriction fragment length analysis with appropriate enzymes: *BsmFI* (p.N18S), *CviAII* (p.W85R), *BaeGI* (p.D158H), and *AseI* (p.E199*). All enzymes were purchased from New England Biolabs (Hitchin, UK). All PCR reactions were performed in a volume of 20 µl containing 40 ng genomic DNA, 0.2 µM of each primer, 2 mM MgCl₂, 1 mM dNTPs, PCR buffer provided by the manufacturer, and 0.5 U Taq polymerase (Invitrogen, Breda, The Netherlands). Primers are listed in Appendix 1. Statistical analysis was performed using IBM SPSS Statistics version 20 software (IBM, New York, NY).

Segregation analysis: To ensure that the two compound heterozygous mutations in exon 5 were located on different alleles, and since DNA samples of the parents of the affected individuals were not available, both allelic copies of exon 5 were tested by cloning. The PCR products encompassing

TABLE 1. MUTATIONS IN *NMNAT1* DETECTED IN LCA PATIENTS.

Patient	Variants	Segregation
1	c.53A>G (p.N18S)/c.472G>C (p.D158H)	n.d.
2	c.769G>A (p.E257K)/ c.253T>C (p.W85R)	n.d.
3.1	c.769G>A (p.E257K)/ c.617A>G (p.H206A)	yes
3.2	c.769G>A (p.E257K)/ c.617A>G (p.H206A)	yes
4	c.769G>A (p.E257K)/ c.595G>T (p.E199*)	yes
5	c.769G>A (p.E257K)/ c.731T>C (p.V244A)	yes
6	c.769G>A (p.E257K)/c.619C>T (p.R207W)	yes

LCA, Leber congenital amaurosis; n.d., not determined. Novel mutations are marked with bold font.

both mutations were cloned in the TOPO vector containing an ampicillin resistance cassette using the TOPO TA cloning kit according to the manufacturer's instructions (Invitrogen, Breda, The Netherlands). Plasmid DNA was isolated using the Roti Prep plasmid Mini kit (Carl Roth, Karlsruhe, Germany), and the vector was sequenced using the *NMNAT1* exon 5 specific primer.

RESULTS

Among all patients in this study, compound heterozygous mutations were found in six families. All patients carrying *NMNAT1* mutations were of European origin. Six of the identified mutations, five missense and one nonsense variant, had not been previously reported (Table 1). Two other variants were described earlier: p.R207W and p.E257K. The pathogenicity assessment is presented in Table 2. Single heterozygous c.769G>A (p.E257K) alleles were present in seven probands with LCA. None of the patients with RP or CRD, as well as genetically diagnosed patients with LCA, carried *NMNAT1* exon 5 mutations. The control population

did not show the presence of any of these alleles, with the exception of p.E257K, which was present in a heterozygous state in 1/271 persons. In all cases containing two mutations in exon 5, segregation was confirmed with allelic cloning. All sequencing results are presented in Table 1.

All patients with compound heterozygous variants were legally blind and displayed only light or hand movements perception, depending on their age. Patient 4, the only one who did not have macular atrophy, did not retain any light perception when he was 6 years old. His fundus pictures are unavailable, since the right eye was enucleated because of corneal pain, and examination of the left eye was impossible due to corneal damage. In patient 6, macular atrophy was suspected but not possible to determine, since the degeneration was too far advanced; on funduscopy, panretinal chorioretinal atrophy was visible. In sibship 3, the boy (3.1) had distinct macular atrophy at the age of 6 months, while his sister (3.2) developed macular atrophy within the first two years of life. In all patients in whom electroretinography was performed, the signals were not detectable. Abnormal

TABLE 2. MUTATIONS IN *NMNAT1*: PATHOGENICITY PREDICTIONS AND POPULATION FREQUENCIES.

Variant	PhyloP	SIFT	PolyPhen2	Heterozygous exome variant server occurrence (European American) per 4,289 persons
c.53A>G (p.N18S)	4.08	tolerated	probably damaging	0
c.115+3A>G (p.?)	0.53	-	-	46
c.253T>C (p.W85R)	4.81	deleterious	probably damaging	0
c.472G>C (p.D158H)	6.02	deleterious	probably damaging	0
c.595G>T (p.E199*)	2.79	-	-	0
c.617A>G (p.H206R)	4.89	deleterious	probably damaging	0
c.619C>T (p.R207W)	1.90	deleterious	benign	2
c.731T>C (p.V244A)	4.48	deleterious	probably damaging	0
c.769G>A (p.E257K)	3.84	tolerated	benign	11

peripheral fundus pigmentation was visible in six patients. Patient 1 had subcapsular cataracts, whereas patient 6 already underwent cataract extraction. The results of all clinical examinations are presented in Table 3.

DISCUSSION

Due to high energy consumption, the retina may be sensitive to deficiencies in substrates associated with cellular energy supply. NAD⁺, the product of a reaction catalyzed by NMNAT1, is such a substrate. NAD⁺ is also indirectly responsible for posttranslational covalent modifications of key proteins (such as mono- and poly-ADP ribosylation) [19]. Therefore, it is not surprising that *NMNAT1* mutations cause a severe form of hereditary retinal degeneration (Figure 1). In this study, none of the patients with RP or CRD carried *NMNAT1* exon 5 mutations. A separate question is the origin of the macular atrophy. Atrophic macular lesions may arise secondary to photoreceptor death, as it has been described in CRD [4], but also in blue cone monochromacy [20] and achromatopsia [21]. In LCA, the macular lesions may evolve in time: patient 3.2 showed abnormal central pigmentations at the age of 4 months, which developed into macular atrophy at the age of 2 years. In our study, one of the seven patients (patient 4) in whom we identified *NMNAT1* mutations did not exactly display this feature, but parafoveal atrophy. The genetic data gathered from our study, as well as other research, suggest that patients with LCA with *NMNAT1* variants have significant residual NMNAT1 activity. Most of the variants represent combinations of nonsense mutations or missense mutations predicted by in silico prediction programs to be severe, with other alterations that are presumed to exert a milder effect on the protein. Only one patient with a homozygous null mutation (p.W169*) has been reported [9]. The lethality of *Nmnat1* knockout mice suggests that human embryos with such a genotype would not be viable [16]. It is not clear how the p.W169* variant would retain any NMNAT1 activity; however, it was suggested that this phenomenon can be ascribed to NMNAT1 chaperone function, which is predicted to remain intact [9].

The p.E257K mutation is of particular interest. Deemed to be neutral by prediction programs SIFT and PolyPhen2, this missense alteration also displays a low level of nucleotide conservation, and the physicochemical difference between these amino acids, measured with the Grantham score is only marginal. Nevertheless, a previous study showed that this mutation not only disrupts NMNAT1 activity but also has the most profound impact of all five mutations identified in that study [8]. The mechanism of this negative effect is yet unknown. Perrault and colleagues speculated that

the p.E257K variant is in linkage disequilibrium with a yet undiscovered regulatory variant in the same gene, causing mRNA to be expressed at a low level. However, the experiments in question were performed by expressing recombinant NMNAT1 protein in cell lines, using constructs that did not contain regulatory parts of the gene. Another peculiar finding is the enrichment of heterozygotes for this mutation in patients with LCA compared to control groups, which was previously found to be present in 4.4% of the patient alleles versus none in 400 control alleles in one study [9], which was a statistically significant difference. Nonetheless, the considered group consisted only of prescreened, unsolved LCA probands. In this study, we also screened our LCA cohort with patients in whom causal mutations had been previously identified. In this cohort, the p.E257K variant was present heterozygously in five LCA proband alleles (0.94%; Table 2) versus only one in 271 Caucasian control alleles (0.18%; Fisher's exact test, p=0.12). Moreover, when the LCA cohort was compared to European American frequency in [Exome Variant Server](#) data, a statistically significant difference was observed between the patients with LCA and the controls (0.13%, Fisher's exact test, p=0.002). It can be inferred that this variant is specific for the Western European population; however, the enrichment in patients with LCA may indicate that this variant acts as a modifier in one or several other genetic subtypes of LCA. Whole exome sequencing of these cases may further shed light on a potential modifier effect of this *NMNAT1* allele on other genetic subtypes of LCA.

In addition to the p.E257K change, one other mutation, p.R207W, was detected in multiple patients. The combination of p.R207W and p.E257K variants was by far (8/311 prescreened cases from our and two other studies) the most prevalent among *NMNAT1*-mutated patients with LCA. Eight individuals of French origin were found to carry this combination of variants [8,9], which may indicate that p.R207W is a founder mutation in this population.

Two additional, potentially harmful mutations were identified only heterozygously in patients with LCA: c.12dup (p.E5Rfs*4) and a putative splice site mutation c.115+3A>G (p.?). Since they were identified in cases with LCA and RP, these mutations may be present in a compound heterozygous state with a missing "second hit" on the other allele; for example, an unidentified alteration either deep within an intron or in a regulatory sequence. The c.115+3A>G alteration, although predicted to diminish the strength of the splice site, may however be a benign alteration, since it is rather frequent in the Caucasian population (Table 2). All other mutations were predicted to have a deleterious effect. Functional studies are required to evaluate the potential effect

TABLE 3. CLINICAL CHARACTERISTICS OF PATIENTS WITH TWO *NMNAT1* VARIANTS.

Patient ID	1	2	3.1	3.2	4	5	6
Age	23	25	7	2	64	16	72
Variants	c.53A>G (p.N18S) c.472G>C (p.D158H)	c.769G>A (p.E257K) c.253T>C (p.W85R)	c.769G>A (p.E257K) c.617A>G (p.H206A)	c.769G>A (p.E257K) c.617A>G (p.H206A)	c.769G>A (p.E257K) c.595G>T (p.E199*)	c.769G>A (p.E257K) c.731T>C (p.V244A)	c.769G>A (p.E257K) c.619C>T (p.R207W)
Gender	M	F	M	F	M	F	M
Origin	German / French	German	Dutch	Dutch	Danish	German	Dutch
Age at diagnosis	~4 months	~6 months	~6 months	~4 months	~12 months	~18 months	1-8 years*
Refraction	RE: S+7.0 LE: S+7.5	NP	RE: S+4.0=C-2.25 LE: S+4.0=C-1.0	RE: S+8.50=C-4.0 LE: S+8.50=C-4.0	NP	RE: S-0.25 LE: S-0.25	NP
Visual acuity	Light perception	Light perception	2/60	Light perception	No light perception	Light perception	RE: Light perception LE: Hand movements
Macular atrophy	Present	Present	Present	Present	Absent	Present	Panretinal chorio-retinal atrophy
Funduscopy	Peripheral pigmentation	Macular pseudocoloboma, large atrophic optic discs, attenuated vessels, RPE-atrophy and mild pigmentary changes in periphery	Macular pseudocoloboma with hyperpigmented border, pink optic discs, subtle RPE changes in periphery	Abnormal pigmentation of the macula at diagnosis, RPE changes in periphery; macular atrophy at age 2	Temporal parapapillary chorioretinal lacunar atrophies, heavy pigmentations in periphery	Periphery normal	Pallor of the optic disc, severely attenuated vessels, abundant pigmentations in midperiphery and macula
Full field ERG	Non-detectable (7 years)	Non-detectable	Non-detectable (6 months)	NP	NP	Non-detectable (2 years)	Non-detectable (31 years)
Remarks	Subcapsular cataract LE>RE	None	None	None	Keratoconus in both eyes, RE enucleated due to corneal pain	None	RE: aphakia and corneal edema after cataract extraction LE: IOL

ERG, electroretinography; F, female; IOL, intraocular lens; LE, left eye; M, male; NP, not performed; RE, right eye; RPE, retinal pigment epithelium; * the accurate time of diagnosis could not be established. Individuals 3.1 and 3.2 are siblings.

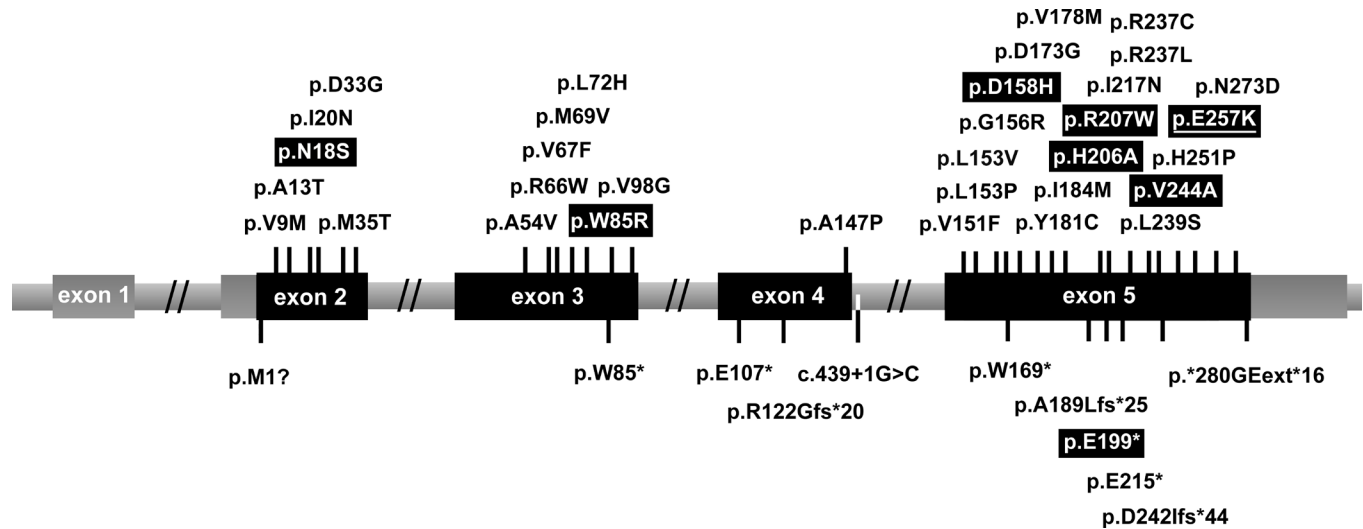


Figure 1. Schematic representation of the location of mutations reported in nicotinamide mononucleotide adenylyltransferase 1 gene (*NMNAT1*). On top are shown missense and in-frame mutations, whereas the mutations below the gene have a truncating or extending effect. Variants identified in this study are indicated by white letters in black boxes. The most common mutation, p.E257K, is underlined.

of these alterations on the protein. The indirect assessment of *NMNAT1* activity by NAD measurement in patients' erythrocytes and lymphoblast cells was previously used for evaluating the pathogenicity of a given mutation. Since other tissues appear to be unaffected by *NMNAT1* mutations, it cannot be certain whether the results of these measurement reflect the *in vivo* situation in the retina.

In conclusion, there is a strong association between *NMNAT1* mutations and macular atrophy, although this feature is not always present. *NMNAT1* seems to be involved in a small subset of LCA cases, since it is responsible for 2.3% of the cases in our cohort of 265 patients with LCA. Although the difference was not significant, the p.E257K mutation was enriched in a heterozygous state in individuals with LCA compared to ethnically matched controls, suggesting that this allele potentially acts as a modifier in other genetic subtypes of LCA.

APPENDIX 1. PRIMER SEQUENCES FOR THE AMPLIFICATION OF THE *NMNAT1* GENE.

F: forward primer; mut: mutant-specific; R: reverse primer; wt: wild-type-specific. To access the data, click or select the words "[Appendix 1](#)."

ACKNOWLEDGEMENTS

The research of A.M.S. and R.W.J.C. was supported by the Netherlands Organization for Scientific Research (TOP-grant 91209047, to F.P.M.C. and A.I.d.H.). The research of F.P.M.C. and A.I.d.H. was supported by the Algemene

Nederlandse Vereniging ter Voorkoming van Blindheid, the Gelderse Blinden Stichting, the Landelijke Stichting voor Blinden en Slechtzienden, the Macula Degeneratie Fonds, the Rotterdamse Stichting Blindenbelangen, and the Stichting Blinden-Penning.

REFERENCES

- Berger W, Kloeckener-Gruissem B, Neidhardt J. The molecular basis of human retinal and vitreoretinal diseases. *Prog Retin Eye Res* 2010; 29:335-75. [PMID: 20362068].
- den Hollander AI, Black A, Bennett J, Cremers FPM. Lighting a candle in the dark: advances in genetics and gene therapy of recessive retinal dystrophies. *J Clin Invest* 2010; 120:3042-53. [PMID: 20811160].
- Sahel J, Bonnel S, Mrejen S, Paques M. Retinitis pigmentosa and other dystrophies. *Dev Ophthalmol* 2010; 47:160-7. [PMID: 20703049].
- Hamel CP. Cone rod dystrophies. *Orphanet J Rare Dis* 2007; 2:7-[PMID: 17270046].
- Heckenlively JR, Foxman SG, Parelhoff ES. Retinal dystrophy and macular coloboma. *Doc Ophthalmol* 1988; 68:257-71. [PMID: 3042323].
- Chiang PW, Wang J, Chen Y, Fu Q, Zhong J, Chen Y, Yi X, Wu R, Gan H, Shi Y, Chen Y, Barnett C, Wheaton D, Day M, Sutherland J, Heon E, Weleber RG, Gabriel LA, Cong P, Chuang K, Ye S, Sallum JM, Qi M. Exome sequencing identifies *NMNAT1* mutations as a cause of Leber congenital amaurosis. *Nat Genet* 2012; 44:972-4. [PMID: 22842231].
- Falk MJ, Zhang Q, Nakamaru-Ogiso E, Kannabiran C, Fonseca-Kelly Z, Chakarova C, Audo I, Mackay DS, Zeitz C, Borman AD, Staniszewska M, Shukla R, Palavalli L,

- Mohand-Said S, Waseem NH, Jalali S, Perin JC, Place E, Ostrovsky J, Xiao R, Bhattacharya SS, Consugar M, Webster AR, Sahel JA, Moore AT, Berson EL, Liu Q, Gai X, Pierce EA. *NMNAT1* mutations cause Leber congenital amaurosis. *Nat Genet* 2012; 44:1040-5. [PMID: 22842227].
8. Koenekoop RK, Wang H, Majewski J, Wang X, Lopez I, Ren H, Chen Y, Li Y, Fishman GA, Genead M, Schwartztruber J, Solanki N, Traboulsi EI, Cheng J, Logan CV, McKibbin M, Hayward BE, Parry DA, Johnson CA, Nageeb M. Finding of Rare Disease Genes (FORGE) Canada Consortium, Poulter JA, Mohamed MD, Jafri H, Rashid Y, Taylor GR, Keser V, Mardon G, Xu H, Inglehearn CF, Fu Q, Toomes C, Chen R. Mutations in *NMNAT1* cause Leber congenital amaurosis and identify a new disease pathway for retinal degeneration. *Nat Genet* 2012; 44:1035-9. [PMID: 22842230].
 9. Perrault I, Hanein S, Zanlonghi X, Serre V, Nicouleau M, Defoort-Delhemmes S, Delphin N, Fares-Taie L, Gerber S, Xerri O, Edelson C, Goldenberg A, Duncombe A, Le Meur G, Hamel C, Silva E, Nitschke P, Calvas P, Munnich A, Roche O, Dollfus H, Kaplan J, Rozet JM. Mutations in *NMNAT1* cause Leber congenital amaurosis with early-onset severe macular and optic atrophy. *Nat Genet* 2012; 44:975-7. [PMID: 22842229].
 10. Berger F, Lau C, Dahlmann M, Ziegler M. Subcellular compartmentation and differential catalytic properties of the three human nicotinamide mononucleotide adenylyltransferase isoforms. *J Biol Chem* 2005; 280:36334-41. [PMID: 16118205].
 11. Coleman MP, Freeman MR. Wallerian degeneration, wld(s), and nmnat. *Annu Rev Neurosci* 2010; 33:245-67. [PMID: 20345246].
 12. Mack TG, Reiner M, Beirowski B, Mi W, Emanuelli M, Wagner D, Thomson D, Gillingwater T, Court F, Conforti L, Fernando FS, Tarlton A, Andressen C, Addicks K, Magni G, Ribchester RR, Perry VH, Coleman MP. Wallerian degeneration of injured axons and synapses is delayed by a Ube4b/*Nmnat* chimeric gene. *Nat Neurosci* 2001; 4:1199-206. [PMID: 11770485].
 13. Avery MA, Sheehan AE, Kerr KS, Wang J, Freeman MR. Wld S requires *Nmnat1* enzymatic activity and N16-VCP interactions to suppress Wallerian degeneration. *J Cell Biol* 2009; 184:501-13. [PMID: 19237597].
 14. Conforti L, Fang G, Beirowski B, Wang MS, Sorci L, Asress S, Adalbert R, Silva A, Bridge K, Huang XP, Magni G, Glass JD, Coleman MP. NAD(+) and axon degeneration revisited: *Nmnat1* cannot substitute for Wld(S) to delay Wallerian degeneration. *Cell Death Differ* 2007; 14:116-27. [PMID: 16645633].
 15. Yahata N, Yuasa S, Araki T. Nicotinamide mononucleotide adenylyltransferase expression in mitochondrial matrix delays Wallerian degeneration. *J Neurosci* 2009; 29:6276-84. [PMID: 19439605].
 16. Conforti L, Janeckova L, Wagner D, Mazzola F, Cialabrini L, Di Stefano M, Orsomando G, Magni G, Bendotti C, Smyth N, Coleman M. Reducing expression of NAD⁺ synthesizing enzyme *NMNAT1* does not affect the rate of Wallerian degeneration. *FEBS J* 2011; 278:2666-79. [PMID: 21615689].
 17. Zhai RG, Cao Y, Hiesinger PR, Zhou Y, Mehta SQ, Schulze KL, Verstreken P, Bellen HJ. *Drosophila* *NMNAT* maintains neural integrity independent of its NAD synthesis activity. *PLoS Biol* 2006; 4:e416-[PMID: 17132048].
 18. Miller SA, Dykes DD, Polesky HF. A simple salting out procedure for extracting DNA from human nucleated cells. *Nucleic Acids Res* 1988; 16:1215-[PMID: 3344216].
 19. Sorci L, Cimadamore F, Scotti S, Petrelli R, Cappellacci L, Franchetti P, Orsomando G, Magni G. Initial-rate kinetics of human *NMN*-adenylyltransferases: substrate and metal ion specificity, inhibition by products and multisubstrate analogues, and isozyme contributions to NAD⁺ biosynthesis. *Biochemistry* 2007; 46:4912-22. [PMID: 17402747].
 20. Ayyagari R, Kakuk LE, Coats CL, Bingham EL, Toda Y, Felius J, Sieving PA. Bilateral macular atrophy in blue cone monochromacy (BCM) with loss of the locus control region (LCR) and part of the red pigment gene. *Mol Vis* 1999; 5:13-[PMID: 10228186].
 21. Thiadens AAHJ, Slingerland NW, Roosing S, van Schooneveld MJ, van Lith-Verhoeven JJC, van Moll-Ramirez NG, van den Born LI, Hoyng CB, Cremers FPM, Klaver CCW. Genetic etiology and clinical consequences of complete and incomplete achromatopsia. *Ophthalmology* 2009; 116:1984-9. [PMID: 19592100].

Articles are provided courtesy of Emory University and the Zhongshan Ophthalmic Center, Sun Yat-sen University, P.R. China. The print version of this article was created on 2 June 2014. This reflects all typographical corrections and errata to the article through that date. Details of any changes may be found in the online version of the article.