



Submit a Manuscript: <http://www.wjgnet.com/esps/>  
 Help Desk: <http://www.wjgnet.com/esps/helpdesk.aspx>  
 DOI: 10.3748/wjg.v20.i25.8011

*World J Gastroenterol* 2014 July 7; 20(25): 8011-8017  
 ISSN 1007-9327 (print) ISSN 2219-2840 (online)  
 © 2014 Baishideng Publishing Group Inc. All rights reserved.

TOPIC HIGHLIGHT

WJG 20<sup>th</sup> Anniversary Special Issues (10): Alcoholic liver disease

## Extracorporeal liver support in severe alcoholic hepatitis

Albert Parés, Antoni Mas

Albert Parés, Antoni Mas, Liver Unit, Hospital Clínic, University of Barcelona, IDIBAPS, CIBERehd, 08036 Barcelona, Spain  
 Author contributions: Parés A and Mas A reviewed and published data on therapy of alcoholic hepatitis and the effects of extracorporeal liver support in these patients, performed previous studies with this therapy, and wrote the manuscript.

Correspondence to: Albert Parés, MD, Liver Unit, Hospital Clínic, University of Barcelona, IDIBAPS, CIBERehd, C/ Villarroel 170, 08036 Barcelona, Spain. pares@ub.edu

Telephone: +34-93-2275753 Fax: +34-93-2271779

Received: November 1, 2013 Revised: February 27, 2014

Accepted: April 28, 2014

Published online: July 7, 2014

**Key words:** Acute alcoholic hepatitis; Alcoholic liver disease; Extracorporeal liver support; Molecular Adsorbents Recirculating System; Hepatorenal syndrome; Treatment of alcoholic hepatitis

**Core tip:** The elevated number of proposals reported for more than forty years reveals the lack of efficacy of a particular therapeutic modality for severe alcoholic hepatitis. This review summarizes data regarding the favorable effects of extracorporeal liver support, particularly with respect to the improvement of systemic hemodynamics, hepatic encephalopathy and renal function, thus sustaining that the procedure used alone or in combination with pharmacological therapies may have a role in this clinical condition.

### Abstract

The severity of alcoholic hepatitis (AH) which may coexist with cirrhosis varies greatly, from asymptomatic forms which are detected in alcoholic patients without any sign of liver disease, except laboratory abnormalities, to severe forms characterised by deep jaundice, ascites, hepatic encephalopathy and low prothrombin index. In hospitalized patients the mortality could be as high as 75%. The elevated number of therapeutic proposals reported for more than forty years reveals the lack of efficacy of a particular modality. Even in the most favorable trials, the survival is already very poor and in some cases related to the development of renal failure or hepatorenal syndrome. There are some motivating reports concerning albumin dialysis as a support treatment in patients with severe AH, either alone or in combination with other pharmacological therapies. The favorable effects of albumin dialysis in patients with severe AH suggest that the procedure used alone or in combination with other therapies may have a role in this clinical condition. This will be particularly relevant to offer an alternative therapy in these patients, thus being a potential bridge to recovery or to be listed for liver transplantation.

Parés A, Mas A. Extracorporeal liver support in severe alcoholic hepatitis. *World J Gastroenterol* 2014; 20(25): 8011-8017 Available from: URL: <http://www.wjgnet.com/1007-9327/full/v20/i25/8011.htm> DOI: <http://dx.doi.org/10.3748/wjg.v20.i25.8011>

### ALCOHOLIC HEPATITIS

Alcoholic hepatitis (AH) is a clinical condition characterised by hepatocellular injury with associated inflammation, necrosis and varied extent of fatty changes and fibrosis, particularly prominent in the zone 3 of the hepatic acinus<sup>[1]</sup>. The lesion typically shows focally intense lobular infiltration with polymorphonuclear leukocytes, although periportal mononuclear inflammation also occurs. Some injured hepatocytes contain eosinophilic and fibrillar material resulting from condensed cytoskeletal intermediary filaments. The extent of fibrosis varies in AH, but usually collagen is placed in a typical pericellular and perivenular distribution, resulting in a pattern of interstitial fibrosis<sup>[2]</sup>.

AH may be observed alone, but may coexist with liver cirrhosis<sup>[3,4]</sup>. As a single lesion it is considered pre-

© 2014 Baishideng Publishing Group Inc. All rights reserved.

**Table 1** Prognostic factor in severe alcoholic hepatitis according to different scores

Ref.	Score	N	Bilirubin	PT/INR	Creatinine/ renal failure	Leukocytes/ infection	HE	Age	Albumin	Bilirubin change day 7
Parés <i>et al</i> <sup>[7]</sup> 1978	NN <sup>1</sup>	105 <sup>1</sup>	Yes	Yes	Yes	Yes	Yes	No	No	No
Maddrey <i>et al</i> <sup>[9]</sup> 1978	Maddrey <sup>2,3</sup>	55 <sup>2,3</sup>	Yes	Yes	No	No	No	No	No	No
Dunn <i>et al</i> <sup>[11]</sup> 2005	MELD <sup>3</sup>	73 <sup>3</sup>	Yes	Yes	Yes	No	No	No	No	No
Forrest <i>et al</i> <sup>[10]</sup> 2005	GAHS <sup>2</sup>	241 <sup>2</sup>	Yes	Yes	Yes	yes	No	Yes	No	No
Louvet <i>et al</i> <sup>[13]</sup> 2007	Lille <sup>2,3</sup>	295	Yes	Yes	Yes	No	No	Yes	Yes	Yes
Dominguez <i>et al</i> <sup>[12]</sup> 2008	ABIC <sup>1,3</sup>	103	Yes	Yes	Yes	No	No	Yes	Yes	No

<sup>1</sup>Histologic diagnosis; <sup>2</sup>Clinical diagnosis; <sup>3</sup>Treated with corticosteroids; NN: No name.

cirrhotic, since a high percentage of patients who continue drinking alcohol eventually develop cirrhosis<sup>[5]</sup>. The severity of AH varies greatly, from asymptomatic forms which are detected in alcoholic patients without any sign of liver disease<sup>[6]</sup>, except laboratory abnormalities, to severe forms of liver damage characterised by intense jaundice, ascites, hepatic encephalopathy and low prothrombin index<sup>[7]</sup>. In hospitalized patients the mortality rate ranges from 5% to 25% in most series; however mortality could be much higher when the patient has severe liver failure with deep jaundice and hepatic encephalopathy as well as low prothrombin index. In these AH subjects mortality could be as high as 75%, but is generally around 50%<sup>[3,4,7,8]</sup>. Actually, the variables associated with low survival are bilirubin, prothrombin time and the presence of hepatic encephalopathy, ascites, renal failure and concomitant bacterial infection<sup>[7]</sup>. In this concern, Maddrey *et al*<sup>[9]</sup> described a score for establishing the severity of AH. Since then, other scores have been proposed, all including bilirubin, and most of them with prothrombin time, renal function and the presence of hepatic encephalopathy as the main components (Table 1)<sup>[7,9-12]</sup>. The purpose of these scoring systems is to estimate the short-term survival, and to determine if the patient should be treated with specific treatments, mainly corticosteroids. The Lille's group has described another score, which defines whether corticosteroid therapy should be stopped after a week, or continued for 28 d<sup>[13]</sup>.

## STANDARD TREATMENT OF ALCOHOLIC HEPATITIS

Stop drinking alcohol is the unique therapy that constantly improves the outcome of AH<sup>[1,3-5]</sup>. Therefore, measures addressed at establishing and maintaining abstinence are critical for the management of these patients, although some patients can progress to cirrhosis even remaining abstinent<sup>[5]</sup>.

The development of specific treatments for AH has been difficult by a poor understanding of its pathogenesis. A number of treatments have been proposed, including corticosteroids, enteral or parenteral nutrition and other agents that are able to modify the hypermetabolic state as propylthiouracil, or decreasing fibrosis such as colchicine or d-penicillamine<sup>[1,3,4]</sup>. Different antioxidants and hepatoprotective agents, as well as hepatotropic

agents have also been used. More recently, some results have been published concerning the effect of pentoxifylline, anti-tumor necrosis factor alpha (TNF $\alpha$ ) antibodies, and N-acetyl cysteine.

Despite the lack of consistent results, recent analysis and the conclusions of the most well performed studies advocate for the use of corticosteroids in patients with AH and severe liver failure<sup>[9,13-17]</sup>. The AASLD guidelines recommends for a four week course of prednisolone (40 mg/d for 28 d, typically followed by discontinuation or a 2-wk taper) in patients without contraindications to steroid use, and a Maddrey's score above 32<sup>[9]</sup>. The EASL guidelines also consider corticosteroid therapy with the same approach, but with the use of the different prognostic scores and with early identification of non-responders to corticosteroids to limit unnecessary exposure to complications<sup>[2]</sup>.

Pentoxifylline, a nonselective phosphodiesterase inhibitor that increases intracellular concentrations of adenosine monophosphate and guanosine monophosphate and ultimately inhibits TNF $\alpha$  production, has been evaluated in AH. In the prospective, randomized, double-blind clinical trial in patients with severe disease, pentoxifylline resulted in better survival, mainly because improvement of hepatorenal syndrome<sup>[18]</sup>. Certainly, no effects of pentoxifylline were observed on liver function and changes in cytokines. In the largest randomized controlled trial of 270 patients with severe AH assessing the combination of prednisolone and pentoxifylline failed to show any benefit over corticosteroids alone<sup>[19]</sup>, but still pentoxifylline therapy (400 mg orally 3 times daily for 4 wk) could be considered, especially if there are contraindications to steroid therapy, since apparently the drug reduces the risk of hepatorenal syndrome and has some potential in decreasing short-term mortality because of renal failure.

Nutritional supplementation provided via oral or enteral routes has been also assessed in patients with severe AH. In summary, dietary supplementation improves nutritional status and nitrogen balance without significant side effects in these patients. Moreover, nutritional supplementation improves liver function tests more rapidly than standard treatment but no definite results were reported concerning survival improvement<sup>[20,21]</sup>. On the other hand, a randomized controlled trial comparing enteral nutrition versus corticosteroids did not show any difference in 28-d mortality rate<sup>[21]</sup>. Nevertheless, deaths

**Table 2 Extracorporeal liver support systems**

Plasma exchange and Albumin dialysis	Bioartificial
Plasma exchange (PE)	HepatAssist
Single pass albumin dialysis (SPAD)	Extracorporeal liver assist device (ELAD)
Molecular adsorbent recirculating system (MARS)	Modular extracorporeal liver support (MELS)
Fractionated plasma separation and adsorption (PROMETHEUS)	Bioartificial liver support system (BLSS)
	Amsterdam Medical Center-bioartificial liver (AMC-BAL)

occurred earlier with enteral nutrition while treatment with corticosteroids was associated with higher mortality in the weeks following the treatment period.

Anti-TNF $\alpha$  agents have also been assessed in patients with severe AH with promising results regarding to the improvement of the indices of liver failure. However, development of severe infections is the main inconvenient for using such treatment in these patients, who are already prone to develop very important adverse events<sup>[22-24]</sup>. N-acetylcysteine is an antioxidant agent that replenishes the hepatocyte glutathione stores, with clear favorable effect in patients with acute liver failure. The intravenous administration for 14 d to patients with severe AH diagnosed with liver biopsy had no significant impact on 1-or 6-mo survival in patients receiving enough nutritional support, but more recently, it has been reported that patients treated with combination therapy (corticosteroids and N-acetylcysteine) had better 1-mo survival than patients treated with corticosteroids alone<sup>[25]</sup>.

The elevated number of proposals reported for more than forty years reveals the lack of efficacy of a particular modality. Even in the most favorable trials, the survival is still very poor and in some cases related to the development of renal failure or hepatorenal syndrome. There are some motivating reports concerning albumin dialysis as a support treatment in patients with severe AH, either alone or in combination with other pharmacological treatments.

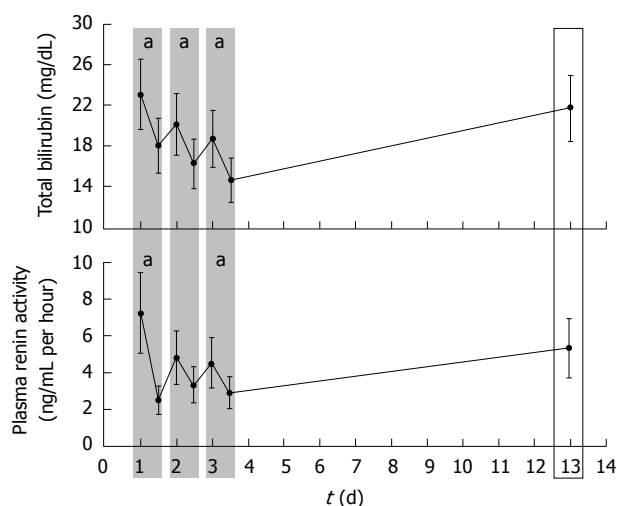
## EXTRACORPOREAL LIVER SUPPORT

In recent years significant advances have been achieved in the treatment of the complications of liver disease, but, in general, there is no definitive method for improving short and long-term outcomes. The only treatment that has shown real efficacy is liver transplantation, which notably increases the rate of survival in patients with fulminant hepatitis<sup>[26]</sup> as well as in those with end-stage chronic liver disease, mainly with cirrhosis<sup>[27]</sup>. It is, therefore, reasonable to attempt to find therapeutic methods which are able, albeit transitorily, to maintain patients with severe decompensated liver disease in a situation which will allow them to undergo liver transplantation or to recover and avoid transplantation.

New extracorporeal liver support systems have appeared based on the use of complex procedures using liver cells integrated into the system<sup>[28,29]</sup>. These devices, known as bioartificial livers, consist of biologic components (pig hepatocytes freshly isolated, human hepato-

blastoma cell lines or human hepatocytes obtained from cadaveric livers not useful for liver transplantation) in a synthetic framework. In the extracorporeal bioreactor, the blood of the patient with liver failure is in close contact with the cultured cells through an ex vivo perfusion system. Since these devices include liver cells, they theoretically have both the ability to synthesize and remove toxic substances. Some results show that the procedure may be useful in patients with acute liver failure, particularly when it is due to paracetamol poisoning<sup>[30]</sup>. Despite great efforts, no clear effects have been proved using these complicated devices, which additionally are very expensive and with many issues to be answered before the utilization in the clinical setting.

These biological or bio-hybrid systems are extremely complex and hardly available in clinical practice. By contrast, the nonbiological systems are essentially based on existing technologies such as hemodialysis, hemofiltration and adsorption<sup>[31,32]</sup>, and can thus be more feasible to integrate in the routine management of patients with severe acute or chronic liver failure (Table 2). Three different nonbiological artificial liver support systems are currently available, on the adsorbent and binding capacity of circulating albumin, in addition to high volume plasmapheresis: (1) single pass albumin dialysis consists on a continuous renal replacement therapy device, in which the blood of the patient is dialyzed, through a high flux dialyzer, against an albumin-containing dialyzate, allowing the removal of small molecules and water-soluble toxins<sup>[33]</sup>; (2) molecular adsorbent recirculating system (MARS) combines hemodialysis against albumin solution, with a conventional dialysis or hemofiltration method. The procedure consists of a hollow fiber dialysis module in which the blood of the patient is dialyzed across a high-flux polysulfone membrane impregnated with albumin, while maintaining a constant flow of albumin-rich dialysate (20% albumin) in the extracapillary compartment<sup>[34]</sup>. The circulating toxins from the blood of the patients are adsorbed in the binding sites on the membrane, and hence pass to the free albumin-binding sites in the dialysate. The albumin dialysate is then cleansed by standard dialysis or filtration and by the sequentially perfusion over two columns (an activated charcoal and an anion exchange resin column which removes the toxins bound to albumin), in order to regenerate the albumin solution. Since the pore size of the membrane is 50 KD, larger substances and the albumin from the patient are not removed; and (3) fractionated plasma separation and adsorption (FPSA) system uses a plasma separation



**Figure 1** Changes in circulating levels of total bilirubin and plasma renin activity before and after each 7-h molecular adsorbent recirculating system session performed on 10 patients with severe alcoholic hepatitis (gray shaded bars). Ten days later there was a recovery of these levels although they were lower than before treatment ( $P = NS$ ).  $^aP < 0.05$  vs before and after each molecular adsorbent recirculating system (MARS) session.

technique combined with adsorption. It consists on a membrane with a pore size of 250 kDa, which lets the separation of blood cells and large proteins from plasma. The albumin with the bound toxins is filtered through the membrane and passes over an absorber with a neutral resin and after that to an anion exchanger. Both the filtered plasma and blood are afterwards combined and dialyzed to remove water-soluble toxins<sup>[35]</sup>.

## MANAGEMENT OF SEVERE ALCOHOLIC HEPATITIS WITH EXTRACORPOREAL LIVER SUPPORT

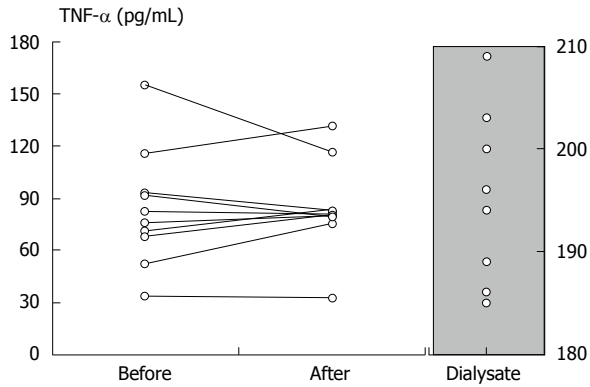
Extracorporeal liver support procedures, which have the ability to remove some potential damaging circulating molecules may, therefore, have a role in patients with severe AH, either alone or in combination with other treatments. This is particularly relevant taking into account that despite the best favorable effects of corticosteroids in recent clinical trials, there is already a short-term survival rate in this condition. Since now, not many patients with AH have been treated with this procedure. In one study 8 patients with severe acute AH and a precipitating decompensation event (mainly upper gastrointestinal bleeding or severe infection) on a background of alcoholic cirrhosis, MARS therapy was associated with improved liver biochemical abnormalities, systemic haemodynamics, renal function and encephalopathy. Actually, there was a marked reduction in the bilirubin level following the first treatments, which then remained stable and did not return to the baseline level even after stopping MARS therapy. Hepatic synthetic function also improved, since there was a significant decrease of prothrombin time (INR), as well as a recovery from hepatic encephalopathy

and renal function, which ameliorated in all the patients according to the circulating creatinine levels<sup>[36]</sup>. In a subsequent analysis, the same group also reported a sharp decrease in portal pressure with MARS, effect that was persistent for up to 18 h after finishing the therapy<sup>[37]</sup>. Favorable effects of albumin dialysis on decreasing portal pressure were also shown in four patients with acute-on-chronic liver failure<sup>[38]</sup>.

Favorable effects on liver function tests and systemic hemodynamics were also reported in alcoholic patients with acute decompensation who were treated with MARS or FPSA, and compared with a group managed with standard medical therapy. Bilirubin and bile acids levels, which are relevant albumin bound toxins, decreased after both MARS and FPSA<sup>[39]</sup>. Moreover, improvement in the mean arterial pressure, stroke volume and systemic vascular resistance index (SVRI) was only observed in the 6 patients treated with MARS, but not in those treated with FPSA. These different consequences of the two therapeutic procedures were associated with significant decreases of vasoactive hormones in patients under MARS with no changes in patients treated with FPSA.

In our center, the effects of albumin dialysis on systemic hemodynamics and vasoactive agents were evaluated in 29 MARS treatments performed in 10 patients (seven males, age:  $48.4 \pm 2.0$  years) with clinical and histologic diagnosis of severe AH defined by a total bilirubin higher than 10 mg/dL, and prothrombin index lower than 50%. The mean MELD score was 26 (range: 20-42). Standard hematological and liver function tests, systemic hemodynamics and vasoactive agents such as plasma renin activity (PRA), angiotensin II and the catabolic products of nitric oxide ( $NO_x$ ) were determined before and after each treatment. Current infection or upper gastrointestinal bleeding were excluded in these patients<sup>[40]</sup>. In addition to the favorable and significant effects on decreasing serum bilirubin (Figure 1), MARS therapy was associated with increases in the mean arterial pressure (MAP) and SVRI. These circulatory effects resulted in significant decreases in PRA, angiotensin II and  $NO_x$ . MAP increased in 21 MARS sessions (group I) and decreased in 8 (group II). PRA, angiotensin II and  $NO_x$  decreased predominantly in patients from group I, which were those with a significantly lower leukocyte count at baseline. At baseline no other differences were observed between the two groups. Apart from a decrease of PRA, a significant drop in circulating renin concentration after the MARS treatment was also observed (from  $195 \pm 35$  to  $110 \pm 29$  pg/mL,  $P = 0.01$ ), with very low concentrations of this hormone in the dialyate ( $11 \pm 3$  pg/mL). Contrarily, no changes in  $TNF\alpha$  concentration were observed after treatment (from  $84 \pm 11$  to  $84 \pm 9$  pg/mL,  $P = NS$ ), while high amounts of this cytokine were identified in the albumin dialyate ( $195 \pm 3$  pg/mL) (Figure 2). This can be explained by the permanent release of  $TNF\alpha$  as a consequence of the systemic inflammatory response. We concluded that albumin dialysis using MARS results in prominent changes in systemic



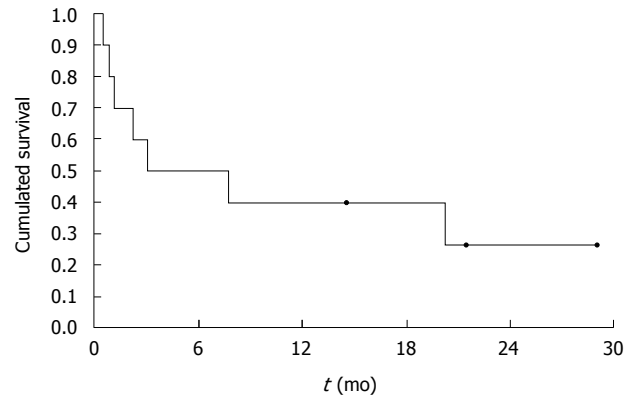


**Figure 2** Tumor necrosis factor- $\alpha$  (TNF- $\alpha$ ) levels before and after molecular adsorbent recirculating system treatment in patients with severe alcoholic hepatitis. Although no significant decrease was observed in the circulating TNF- $\alpha$ , the dialysate was enriched with this cytokine, thus indicating that albumin dialysis is able to remove some substances related to the pathogenesis of the disease.

hemodynamics, which in turn are associated with clear decreases in vasoactive substances. These changes may partially explain the positive effects of this therapy in patients with AH and severe liver failure.

Besides the hemodynamic effects, albumin dialysis resulted in a marked effect on hepatic encephalopathy as well<sup>[41]</sup>. Actually, in these patients eight episodes of encephalopathy were recorded before MARS. Albumin dialysis resulted in a considerable decrease in the degree of hepatic encephalopathy. Moreover, no encephalopathy was present after treatment in 5 of the 8 episodes. Improvement of hepatic encephalopathy was associated with clear attenuations in serum bilirubin and a significant raise in albumin concentration, along with clear recoveries in creatinine and electrolyte concentrations. Moreover, total amino acid, phenolic aromatic amino acid concentrations and tryptophan levels were significantly greater in patients with AH than in patients with pruritus and normal liver function who served as controls. Baseline branched amino acid between the two groups of patients were similar, but the Fischer ratio was appreciably lower in patients with AH. Circulating ammonia levels were higher in patients with AH than in controls.

Total amino acid concentrations decreased significantly in patients with AH and no changes were observed in the control subjects. Branched amino acids in sera were not changed by MARS, but phenolic aromatic amino acids decreased markedly in patients with AH and increased in the control patients with pruritus. Therefore, the Fischer ratio increased in patients with severe AH (17%) but decreased in controls with resistant pruritus (3%). These changes were more prominent after correction by the baseline albumin levels. No relevant changes were observed in either the serum levels of tryptophan or ammonia. Patients with baseline hepatic encephalopathy and albumin concentration below 24 g/L, and those in whom albumin dialysis resulted in a decrease in total bilirubin greater than 20% with respect to pre-treatment levels, were those with major changes in amino acid levels and Fischer ratio. No significant changes in the amino



**Figure 3** Cumulated survivals of the ten patients with severe alcoholic hepatitis treated with 3 consecutive 7-h molecular adsorbent recirculating system sessions. Fifty percent of the patients were still alive 6 mo after treatment, and 40 percent survived 20 mo.

acid profile was induced by albumin dialysis in the control group.

Three patients died within less than 36 d after treatment. The median hospital stay of the ten patients was 16 d, and half of the patients were still alive 6 mo after treatment. No differences in the markers of severity of the disease and plasma renin activity were observed between patients surviving less or more than 6 mo. Overall, the three-, six- and twelve-month survival rate were 60%, 50% and 40%, respectively (Figure 3), results which parallel those observed in different trials using similar or other therapeutic approaches. Certainly, Jalan *et al*<sup>[36]</sup> also reported that 50% of the 8 patients with AH treated with MARS were still alive with good liver function 3 mo after treatment. More recently, in a series of 15 patients with severe AH it has been reported that MARS was safe and well tolerated. Moreover, MARS therapy improved the overall survival of patients who failed standard treatment and in 13% of the cases was useful as a bridge to liver transplantation<sup>[42]</sup>.

The largest randomized trial using an extracorporeal artificial device in patients with acute-on-chronic liver failure, indicate that MARS therapy improves some surrogate parameters of organ dysfunction. Accordingly, MARS was associated with a decrease in serum bilirubin and serum creatinine, and with a clear amelioration of hepatic encephalopathy in a high proportion of cases<sup>[43]</sup>. These features occurred particularly in patients treated by MARS plus standard treatment. Most of the patients were alcoholics but with a high rate of precipitating events such as severe infections and gastrointestinal bleeding, not resulting particularly from histologic demonstrated AH. Another relevant aspect highlighted in this trial was the difficulty of distinguishing acute-on-chronic liver failure from chronic decompensated liver disease, two entities that have different natural history and prognosis.

In another trial, extracorporeal liver support with FPSA did not increase the probability of survival as compared with standard medical therapy in patients with decompensated cirrhosis, although serum bilirubin de-

creased markedly in the FPSA group but not in the standard medical therapy group<sup>[44]</sup>. This trial included fewer alcoholic patients, and therefore the probability of an AH was subsequently lower.

## CONCLUSION

The results reported until now on the effects of extracorporeal liver support in patients with decompensated liver disease are somewhat confusing with respect to the patients' selection and the etiology and severity of the disease. Thus, it is very hard to allocate a unique group with severe AH with or without cirrhosis. The favorable effects of albumin dialysis in patients with severe AH suggest that the procedure used alone or in combination with pharmacological therapies may have a role in this clinical condition, but this should be proved in well designed controlled trials, particularly with respect to the improvement of short- and long-term survival. This will be particularly relevant to offer an alternative therapy in these patients, thus being a potential bridge to recovery or to be listed for liver transplantation<sup>[45]</sup>. In this concern, a randomized, controlled phase 3 trial to assess safety and efficacy of a bio-artificial liver therapy in patients with severe AH who have failed seven days of steroid therapy, is ongoing (ClinicalTrials.gov Identifier: NCT01829347).

## REFERENCES

- 1 **Lucey MR**, Mathurin P, Morgan TR. Alcoholic hepatitis. *N Engl J Med* 2009; **360**: 2758-2769 [PMID: 19553649 DOI: 10.1056/NEJMra0805786]
- 2 **MacSween RN**, Burt AD. Histologic spectrum of alcoholic liver disease. *Semin Liver Dis* 1986; **6**: 221-232 [PMID: 3022386 DOI: 10.1055/s-2008-1040605]
- 3 **European Association for the Study of Liver**. EASL clinical practical guidelines: management of alcoholic liver disease. *J Hepatol* 2012; **57**: 399-420 [PMID: 22633836 DOI: 10.1016/j.jhep.2012.04.004]
- 4 **O'Shea RS**, Dasarathy S, McCullough AJ. Alcoholic liver disease. *Hepatology* 2010; **51**: 307-328 [PMID: 20034030 DOI: 10.1002/hep.23258]
- 5 **Parés A**, Caballería J, Bruguera M, Torres M, Rodés J. Histological course of alcoholic hepatitis. Influence of abstinence, sex and extent of hepatic damage. *J Hepatol* 1986; **2**: 33-42 [PMID: 3950362 DOI: 10.1016/S0168-8278(86)80006-X]
- 6 **Bruguera M**, Bordas JM, Rodés J. Asymptomatic liver disease in alcoholics. *Arch Pathol Lab Med* 1977; **101**: 644-647 [PMID: 579305]
- 7 **Parés A**, Bosch J, Bruguera M, Rodes J. Características clínicas y criterios pronósticos en la hepatitis alcohólica. *Gastroenterol Hepatol* 1978; **1**: 118-123
- 8 **Mathurin P**, Lucey MR. Management of alcoholic hepatitis. *J Hepatol* 2012; **56** Suppl 1: S39-S45 [PMID: 22300464 DOI: 10.1016/S0168-8278(12)60005-1]
- 9 **Maddrey WC**, Boitnott JK, Bedine MS, Weber FL, Mezey E, White RI. Corticosteroid therapy of alcoholic hepatitis. *Gastroenterology* 1978; **75**: 193-199 [PMID: 352788]
- 10 **Forrest EH**, Evans CD, Stewart S, Phillips M, Oo YH, McAvoy NC, Fisher NC, Singhal S, Brind A, Haydon G, O'Grady J, Day CP, Hayes PC, Murray LS, Morris AJ. Analysis of factors predictive of mortality in alcoholic hepatitis and derivation and validation of the Glasgow alcoholic hepatitis score. *Gut* 2005; **54**: 1174-1179 [PMID: 16009691 DOI: 10.1136/gut.2004.050781]
- 11 **Dunn W**, Jamil LH, Brown LS, Wiesner RH, Kim WR, Me non KV, Malinchoc M, Kamath PS, Shah V. MELD accurately predicts mortality in patients with alcoholic hepatitis. *Hepatology* 2005; **41**: 353-358 [PMID: 15660383 DOI: 10.1002/hep.20503]
- 12 **Dominguez M**, Rincón D, Abalde JG, Miquel R, Colmenero J, Bellot P, García-Pagán JC, Fernández R, Moreno M, Bañares R, Arroyo V, Caballería J, Ginès P, Bataller R. A new scoring system for prognostic stratification of patients with alcoholic hepatitis. *Am J Gastroenterol* 2008; **103**: 2747-2756 [PMID: 18721242 DOI: 10.1111/j.1572-0241.2008.02104.x]
- 13 **Louvet A**, Naveau S, Abdelnour M, Ramond MJ, Diaz E, Fartoux L, Dharancy S, Texier F, Hollebecque A, Serfaty L, Boleslawski E, Deltenre P, Canva V, Pruvot FR, Mathurin P. The Lille model: a new tool for therapeutic strategy in patients with severe alcoholic hepatitis treated with steroids. *Hepatology* 2007; **45**: 1348-1354 [PMID: 17518367 DOI: 10.1002/hep.21607]
- 14 **Mathurin P**, O'Grady J, Carithers RL, Phillips M, Louvet A, Mendenhall CL, Ramond MJ, Naveau S, Maddrey WC, Morgan TR. Corticosteroids improve short-term survival in patients with severe alcoholic hepatitis: meta-analysis of individual patient data. *Gut* 2011; **60**: 255-260 [PMID: 20940288 DOI: 10.1136/gut.2010.224097]
- 15 **Carithers RL**, Herlong HF, Diehl AM, Shaw EW, Combes B, Fallon HJ, Maddrey WC. Methylprednisolone therapy in patients with severe alcoholic hepatitis. A randomized multicenter trial. *Ann Intern Med* 1989; **110**: 685-690 [PMID: 2648927 DOI: 10.7326/0003-4819-110-9-685]
- 16 **Mathurin P**, Mendenhall CL, Carithers RL, Ramond MJ, Maddrey WC, Garstide P, Rueff B, Naveau S, Chaput JC, Poynard T. Corticosteroids improve short-term survival in patients with severe alcoholic hepatitis (AH): individual data analysis of the last three randomized placebo controlled double blind trials of corticosteroids in severe AH. *J Hepatol* 2002; **36**: 480-487 [PMID: 11943418 DOI: 10.1016/S0168-8278(01)00289-6]
- 17 **Phillips M**, Curtis H, Portmann B, Donaldson N, Bomford A, O'Grady J. Antioxidants versus corticosteroids in the treatment of severe alcoholic hepatitis--a randomised clinical trial. *J Hepatol* 2006; **44**: 784-790 [PMID: 16469404 DOI: 10.1016/j.jhep.2005.11.039]
- 18 **Mezey E**, Caballería J, Mitchell MC, Parés A, Herlong HF, Rodés J. Effect of parenteral amino acid supplementation on short-term and long-term outcomes in severe alcoholic hepatitis: a randomized controlled trial. *Hepatology* 1991; **14**: 1090-1096 [PMID: 1959859 DOI: 10.1002/hep.1840140624]
- 19 **Cabré E**, Rodríguez-Iglesias P, Caballería J, Quer JC, Sánchez-Lombraña JL, Parés A, Papo M, Planas R, Gassull MA. Short- and long-term outcome of severe alcohol-induced hepatitis treated with steroids or enteral nutrition: a multicenter randomized trial. *Hepatology* 2000; **32**: 36-42 [PMID: 10869286 DOI: 10.1053/jhep.2000.8627]
- 20 **Akriviadis E**, Botla R, Briggs W, Han S, Reynolds T, Shakil O. Pentoxifylline improves short-term survival in severe acute alcoholic hepatitis: a double-blind, placebo-controlled trial. *Gastroenterology* 2000; **119**: 1637-1648 [PMID: 11113085 DOI: 10.1053/gast.2000.20189]
- 21 **Mathurin P**, Louvet A, Duhamel A, Nahon P, Carbonell N, Boursier J, Anty R, Diaz E, Thabut D, Moirand R, Lebrec D, Moreno C, Talbodec N, Paupard T, Naveau S, Rivain C, Pageaux GP, Sobesky R, Canva-Delcambre V, Dharancy S, Salleron J, Dao T. Prednisolone with vs without pentoxifylline and survival of patients with severe alcoholic hepatitis: a randomized clinical trial. *JAMA* 2013; **310**: 1033-1041 [PMID: 24026598 DOI: 10.1001/jama.2013.276300]
- 22 **Tilg H**, Jalan R, Kaser A, Davies NA, Offner FA, Hodges SJ, Ludwiczek O, Shawcross D, Zoller H, Alisa A, Mookerjee RP, Graziadei I, Datz C, Trauner M, Schuppan D, Obrist P, Vogel W, Williams R. Anti-tumor necrosis factor-alpha monoclonal antibody therapy in severe alcoholic hepatitis.

- J Hepatol* 2003; **38**: 419-425 [PMID: 12663232 DOI: 10.1016/S0168-8278(02)00442-7]
- 23 **Spahr L**, Rubbia-Brandt L, Frossard JL, Giostra E, Rougemont AL, Pugin J, Fischer M, Egger H, Hadengue A. Combination of steroids with infliximab or placebo in severe alcoholic hepatitis: a randomized controlled pilot study. *J Hepatol* 2002; **37**: 448-455 [PMID: 12217597 DOI: 10.1016/S0168-8278(02)00230-1]
  - 24 **Poynard T**, Thabut D, Chryssostalis A, Taieb J, Ratziu V. Anti-tumor necrosis factor-alpha therapy in severe alcoholic hepatitis: are large randomized trials still possible? *J Hepatol* 2003; **38**: 518-520 [PMID: 12663246 DOI: 10.1016/S0168-8278(03)00045-X]
  - 25 **Nguyen-Khac E**, Thevenot T, Piquet MA, Benferhat S, Gorla O, Chatelain D, Tramier B, Dewaele F, Ghrib S, Rudler M, Carbonell N, Tossou H, Bental A, Bernard-Chabert B, Dupas JL. Glucocorticoids plus N-acetylcysteine in severe alcoholic hepatitis. *N Engl J Med* 2011; **365**: 1781-1789 [PMID: 22070475 DOI: 10.1056/NEJMoa1101214]
  - 26 **Ostapowicz G**, Fontana RJ, Schiødt FV, Larson A, Davern TJ, Han SH, McCashland TM, Shakil AO, Hay JE, Hyman L, Crippin JS, Blei AT, Samuel G, Reisch J, Lee WM. Results of a prospective study of acute liver failure at 17 tertiary care centers in the United States. *Ann Intern Med* 2002; **137**: 947-954 [PMID: 12484709 DOI: 10.7326/0003-4819-137-12-200212170-00007]
  - 27 **Keeffe EB**. Liver transplantation: current status and novel approaches to liver replacement. *Gastroenterology* 2001; **120**: 749-762 [PMID: 11179248 DOI: 10.1053/gast.2001.22583]
  - 28 **Stockmann HB**, Hiemstra CA, Marquet RL, IJzermans JN. Extracorporeal perfusion for the treatment of acute liver failure. *Ann Surg* 2000; **231**: 460-470 [PMID: 10749605 DOI: 10.1097/00000658-200004000-00003]
  - 29 **Allen JW**, Hassanein T, Bhatia SN. Advances in bioartificial liver devices. *Hepatology* 2001; **34**: 447-455 [PMID: 11526528 DOI: 10.1053/jhep.2001.26753]
  - 30 **Demetriou AA**, Brown RS, Busuttill RW, Fair J, McGuire BM, Rosenthal P, Am Esch JS, Lerut J, Nyberg SL, Salizzoni M, Fagan EA, de Hempinne B, Broelsch CE, Muraca M, Salmeron JM, Rabkin JM, Metselaar HJ, Pratt D, De La Mata M, McChesney LP, Everson GT, Lavin PT, Stevens AC, Pitkin Z, Solomon BA. Prospective, randomized, multicenter, controlled trial of a bioartificial liver in treating acute liver failure. *Ann Surg* 2004; **239**: 660-667; discussion 667-670 [PMID: 15082970 DOI: 10.1097/01.sla.0000124298.74199.e5]
  - 31 **Podoll AS**, DeGolovine A, Finkel KW. Liver support systems—a review. *ASAIO J* 2012; **58**: 443-449 [PMID: 22820917 DOI: 10.1097/MAT.0b013e31825f3446]
  - 32 **Faybik P**, Krenn CG. Extracorporeal liver support. *Curr Opin Crit Care* 2013; **19**: 149-153 [PMID: 23385372 DOI: 10.1097/MCC.0b013e32835eb970]
  - 33 **van de Kerkhove MP**, Di Florio E, Scuderi V, Mancini A, Belli A, Bracco A, Dauri M, Tisone G, Di Nicuolo G, Amoruso P, Spadari A, Lombardi G, Hoekstra R, Calise F, Chamuleau RA. Phase I clinical trial with the AMC-bioartificial liver. *Int J Artif Organs* 2002; **25**: 950-959 [PMID: 12456036]
  - 34 **Stange J**, Mitzner SR, Klammt S, Freytag J, Peszynski P, Loock J, Hickstein H, Kortzen G, Schmidt R, Hentschel J, Schulz M, Löhr M, Liebe S, Schareck W, Hopt UT. Liver support by extracorporeal blood purification: a clinical observation. *Liver Transpl* 2000; **6**: 603-613 [PMID: 10980060 DOI: 10.1053/jlts.2000.7576]
  - 35 **Rifai K**, Ernst T, Kretschmer U, Bahr MJ, Schneider A, Hafer C, Haller H, Manns MP, Fliser D. Prometheus—a new extracorporeal system for the treatment of liver failure. *J Hepatol* 2003; **39**: 984-990 [PMID: 14642616 DOI: 10.1016/S0168-8278(03)00468-9]
  - 36 **Jalan R**, Sen S, Steiner C, Kapoor D, Alisa A, Williams R. Extracorporeal liver support with molecular adsorbents recirculating system in patients with severe acute alcoholic hepatitis. *J Hepatol* 2003; **38**: 24-31 [PMID: 12480556 DOI: 10.1016/S0168-8278(02)00334-3]
  - 37 **Sen S**, Mookerjee RP, Cheshire LM, Davies NA, Williams R, Jalan R. Albumin dialysis reduces portal pressure acutely in patients with severe alcoholic hepatitis. *J Hepatol* 2005; **43**: 142-148 [PMID: 15878216 DOI: 10.1016/j.jhep.2005.01.032]
  - 38 **Catalina MV**, Barrio J, Anaya F, Salcedo M, Rincón D, Clemente G, Bañares R. Hepatic and systemic haemodynamic changes after MARS in patients with acute on chronic liver failure. *Liver Int* 2003; **23** Suppl 3: 39-43 [PMID: 12950960 DOI: 10.1034/j.1478-3231.23.s.3.10.x]
  - 39 **Laleman W**, Wilmer A, Evenepoel P, Elst IV, Zeegers M, Zaman Z, Verslype C, Fevery J, Nevens F. Effect of the molecular adsorbent recirculating system and Prometheus devices on systemic haemodynamics and vasoactive agents in patients with acute-on-chronic alcoholic liver failure. *Crit Care* 2006; **10**: R108 [PMID: 16859530 DOI: 10.1186/cc4455]
  - 40 **Parés A**, Cisneros L, Salmerón JM, Más A, Torras A, Caballería J, Rodés J. The molecular adsorbent recirculating system (MARS) improves systemic hemodynamics and hepatic encephalopathy in patients with severe alcoholic hepatitis. *J Hepatol* 2002; **36** (suppl 1): 150 [DOI: 10.1016/S0168-8278(02)80541-4]
  - 41 **Parés A**, Deulofeu R, Cisneros L, Escorsell A, Salmerón JM, Caballería J, Mas A. Albumin dialysis improves hepatic encephalopathy and decreases circulating phenolic aromatic amino acids in patients with alcoholic hepatitis and severe liver failure. *Crit Care* 2009; **13**: R8 [PMID: 19175915 DOI: 10.1186/cc7697]
  - 42 **Hassanein T**, Tamsen MR, Petcharaporn L, Hassanemin R, Monson P, Baralak F. Extracorporeal Albumin Dialysis Improves Survival in Patients with Severe Alcoholic Hepatitis. *Hepatology* 2012; **56**: 974A
  - 43 **Bañares R**, Nevens F, Larsen FS, Jalan R, Albillos A, Dollinger M, Saliba F, Sauerbruch T, Klammt S, Ockenga J, Pares A, Wendon J, Brünner T, Kramer L, Mathurin P, de la Mata M, Gasbarrini A, Müllhaupt B, Wilmer A, Laleman W, Eefsen M, Sen S, Zipprich A, Tenorio T, Pavesi M, Schmidt HH, Mitzner S, Williams R, Arroyo V. Extracorporeal albumin dialysis with the molecular adsorbent recirculating system in acute-on-chronic liver failure: the RELIEF trial. *Hepatology* 2013; **57**: 1153-1162 [PMID: 23213075 DOI: 10.1002/hep.26185]
  - 44 **Kribben A**, Gerken G, Haag S, Herget-Rosenthal S, Treichel U, Betz C, Sarrazin C, Hoste E, Van Vlierberghe H, Escorsell A, Hafer C, Schreiner O, Galle PR, Mancini E, Caraceni P, Karvellas CJ, Salmhofer H, Knotek M, Ginès P, Kozik-Jaromin J, Rifai K. Effects of fractionated plasma separation and adsorption on survival in patients with acute-on-chronic liver failure. *Gastroenterology* 2012; **142**: 782-789.e3 [PMID: 22248661 DOI: 10.1053/j.gastro.2011.12.056]
  - 45 **Mathurin P**, Moreno C, Samuel D, Dumortier J, Salleron J, Durand F, Castel H, Duhamel A, Pageaux GP, Leroy V, Dharancy S, Louvet A, Boleslawski E, Lucidi V, Gustot T, Francoz C, Letoublon C, Castaing D, Belghiti J, Donckier V, Pruvot FR, Duclos-Vallée JC. Early liver transplantation for severe alcoholic hepatitis. *N Engl J Med* 2011; **365**: 1790-1800 [PMID: 22070476 DOI: 10.1056/NEJMoa1105703]

**P- Reviewers:** Buechler C, Beier JL, Duryee MJ, Sandahl TD, Uchiumi T

**S- Editor:** Qi Y **L- Editor:** A **E- Editor:** Wang CH





Published by **Baishideng Publishing Group Inc**

8226 Regency Drive, Pleasanton, CA 94588, USA

Telephone: +1-925-223-8242

Fax: +1-925-223-8243

E-mail: [bpgooffice@wjgnet.com](mailto:bpgooffice@wjgnet.com)

Help Desk: <http://www.wjgnet.com/esps/helpdesk.aspx>

<http://www.wjgnet.com>



ISSN 1007-9327

