

# Posttransplant Nephrocalcinosis Is Associated with Poor Renal Allograft Function: A Single-Center Experience

Abdul Moiz, MD, FACP, FASN,<sup>1,2</sup> Tariq Javed, MD,<sup>1</sup> Jorge Garces, MD,<sup>1</sup> Adriana Dornelles, ScD,<sup>3</sup>  
Catherine Staffeld-Coit, MD<sup>1</sup>

<sup>1</sup>Department of Nephrology, Ochsner Clinic Foundation, New Orleans, LA

<sup>2</sup>The University of Queensland School of Medicine, Ochsner Clinical School, New Orleans, LA

<sup>3</sup>Office of Biostatistical Support, Ochsner Clinic Foundation, New Orleans, LA

---

## ABSTRACT

**Background:** Nephrocalcinosis, characterized by intratubular and/or parenchymal deposition of calcium phosphate and calcium oxalate crystals, is frequently seen in renal allograft biopsies; however, the clinical consequence of this histologic finding remains unknown. Kidney transplant recipients with good allograft function usually demonstrate improvement in biochemical parameters; however, persistent hyperparathyroidism remains prevalent in this population of patients. We identified renal allografts with nephrocalcinosis and evaluated the effects on renal allograft function and survival.

**Methods:** We conducted a single-center, retrospective review of kidney allograft biopsies performed at our center from December 1, 2006 to November 30, 2012. Biopsies with nephrocalcinosis as the primary diagnosis were included in the final analysis. Biochemical parameters at the time of biopsy included serum creatinine, phosphate, calcium, intact parathyroid hormone (iPTH), 25-hydroxy vitamin D, and albumin. Serum creatinine was measured at 1, 3, 6, and 12 months after nephrocalcinosis was diagnosed. The use of calcimimetics, vitamin D analogs, active vitamin D, and bisphosphonates was also reviewed.

**Results:** We identified 12 patients with nephrocalcinosis as the primary diagnosis on renal biopsy. The average age of these patients was  $52.2 \pm 11.9$  years, and the average time since

transplantation was  $2.3 \pm 2.7$  years. The baseline serum creatinine was  $1.37 \pm 0.4$  mg/dL before the onset of acute kidney injury (AKI). Mean iPTH and 25-hydroxy vitamin D at the time of AKI were  $495.66 \pm 358.9$  pg/mL and  $19.9 \pm 13.3$  ng/mL, respectively. Renal function deteriorated in all patients, and mean serum creatinine at 12-month follow up was  $2.37 \pm 1.3$  mg/dL ( $P=0.028$ ). One patient progressed to end-stage renal disease at the end of the study period.

**Conclusion:** The histologic finding of nephrocalcinosis is associated with poor renal allograft function. Metabolic abnormalities including hyperparathyroidism persist in renal allograft recipients despite normal allograft function and may be associated with the development of nephrocalcinosis in renal transplant recipients.

---

## INTRODUCTION

Nephrocalcinosis refers to a generalized increase in the calcium content of the kidney and is characterized by intratubular or parenchymal deposition of crystals, primarily consisting of calcium phosphate and/or calcium oxalate. Intratubular crystal deposition is thought to occur as a result of supersaturation, mainly in the distal nephrons.<sup>1</sup> Tubular obstruction can acutely impair renal function by mechanical blockage of tubular fluid flow. In the long term, tubular obstruction can cause tubular atrophy, interstitial inflammation, and interstitial fibrosis, leading to chronic kidney disease (CKD).<sup>2,3</sup>

In patients with CKD, the calcium content of the kidney usually increases as renal function deteriorates.<sup>4</sup> In patients with CKD stage 5, calcium levels can be 8-fold greater than in normal kidneys.<sup>5</sup> Calcium oxalate crystals may be observed in the kidneys of patients with disorders that increase the production and excretion of oxalate. Calcium phosphate crystals are most commonly encountered in the kidneys of patients with hypercalciuria such as in patients with primary hyperparathyroidism.

---

Address correspondence to  
Abdul Moiz, MD, FACP, FASN  
Department of Nephrology  
Ochsner Clinic Foundation  
1514 Jefferson Hwy.  
New Orleans, LA 70121  
Tel: (504) 842-3930  
Email: [amoiz@ochsner.org](mailto:amoiz@ochsner.org)

**Keywords:** Hyperparathyroidism, kidney transplantation, nephrocalcinosis

The authors have no financial or proprietary interest in the subject matter of this article.

**Table 1. Baseline Characteristics of Patients (n=12)**

Variable	Mean ± SD / n (%)	Minimum-Maximum
Age, years	52.2 ± 11.9	34-75
Male	6 (50)	
African American	9 (75)	
White	3 (25)	
Time since transplantation, days	827.3 ± 963.7	8-2,604
Time since transplantation, years	2.3 ± 2.7	0.2-7.1
<b>Etiology of End-Stage Renal Disease</b>		
Diabetes	7 (58.3)	
Hypertension	3 (25.0)	
Hepatorenal syndrome	1 (8.3)	
Lupus	1 (8.3)	
Predialysis	0 (0)	
<b>Type of Transplant</b>		
Deceased donor kidney transplant	5 (41.7)	
Kidney-pancreas transplant	5 (41.7)	
Liver-kidney transplant	1 (8.3)	
Living donor kidney transplant	1 (8.3)	
<b>Induction Immunosuppression</b>		
Thymoglobulin (rabbit antithymocyte globulin)	6 (50.0)	
Alemtuzumab (Campath)	5 (41.7)	
Steroids	1 (8.3)	

Nephrocalcinosis is also frequently observed in renal allograft recipients. A high incidence of calcium oxalate deposits has been reported in kidney allografts with early dysfunction.<sup>6,7</sup> In one protocol biopsy study from Belgium, the prevalence of calcium phosphate crystals was 31.8% at 3 months posttransplantation.<sup>8</sup> Gwinner et al observed calcifications in renal allografts in 26.3% of patients within the first 6 months posttransplantation.<sup>9</sup>

Despite the frequent occurrence of nephrocalcinosis in kidney transplant recipients, its clinical significance remains unknown. Our study focused on renal transplant recipients with an isolated finding of nephrocalcinosis and attempted to identify the long-term implication of this histologic finding on renal allograft function and patient survival.

**METHODS**

We conducted a single-center, retrospective review of kidney allograft biopsies performed from

December 1, 2006 to November 30, 2012. Biopsy records were obtained by reviewing paper and electronic medical records. Protocol biopsies are not performed at our center, and the decision to perform a kidney biopsy is based on the clinical judgment of the physician. The most common indication for renal allograft biopsy is acute allograft dysfunction. We identified biopsies with only nephrocalcinosis as the primary diagnosis. Biopsies with additional diagnoses of acute rejection, acute tubular necrosis, and recurrent or de novo glomerulonephritis were excluded.

Renal transplant biopsies were performed using a biopsy gun with an 18-gauge needle, and at least 2 tissue cores were obtained. Tissue was preserved in paraformaldehyde and Michel’s fixative; slides were routinely stained with hematoxylin and eosin (H&E), periodic acid–Schiff (PAS), and a silver methenamine method. H&E-stained slides of fixed and frozen tissue, as well as the PAS and silver methenamine stain slides, were used to look for calcification. Crystal deposition was quantified by the number of tubules involved.

Biochemical analysis at the time of biopsy included review of serum creatinine, phosphate, calcium, intact parathyroid hormone (iPTH), 25-hydroxy vitamin D, and albumin. Serum creatinine was also obtained at 1, 3, 6, and 12 months post diagnosis of nephrocalcinosis. Use of calcimimetics, vitamin D analogs, active vitamin D, and bisphosphonates was also analyzed.

**Statistical Analysis**

Means, standard deviations, and medians were calculated for continuous variables. Frequencies and percentages were reported for categorical variables. Parametric paired (Student *t* test) and nonparametric paired (Wilcoxon signed rank test) comparisons were calculated to assess statistical significance from baseline to each follow-up. Spearman correlation coefficients were calculated to assess the degree of linear dependence between variables of interest. A *P* value <0.05 was considered statistically significant, and all statistical analyses were performed using Stata/IC (StataCorp LP, version 13).

**RESULTS**

We identified 12 patients with nephrocalcinosis as the primary diagnosis on the biopsy. Table 1 describes baseline demographics and clinical characteristics of the sample. The mean age was 52.2 ± 11.9 (SD) years, 50% were male, and 75% were African American. The most common cause for end-stage renal disease was diabetes (58.3%), followed by hypertension (25%). Thymoglobulin (rabbit anti-

**Table 2. Baseline Blood Chemistries**

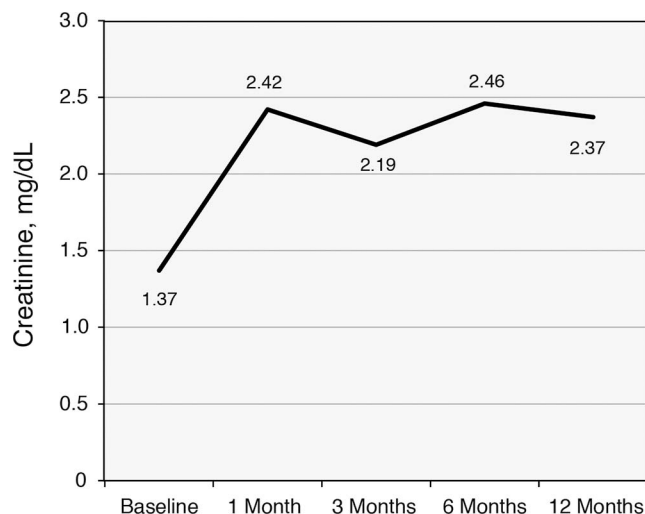
Variable	Mean $\pm$ SD	Minimum-Maximum
Creatinine, mg/dL	1.37 $\pm$ 0.4	
Phosphate, mg/dL	3.7 $\pm$ 1.2	2.2-6.5
Calcium, mg/dL	9.01 $\pm$ 0.6	8.2-10.4
Albumin, g/dL	3.21 $\pm$ 0.6	2.4-4.0
Intact parathyroid hormone at time of biopsy, pg/mL	495.66 $\pm$ 358.9	80-1,254
25-hydroxy vitamin D at time of biopsy, ng/mL	19.9 $\pm$ 13.3	6-43

thymocyte globulin) was the induction agent in 50% of cases, and Prograf (tacrolimus) was the calcineurin inhibitor of choice in 11 of 12 patients. All patients were on dialysis at the time of transplantation. The mean time since transplantation was  $2.3 \pm 2.7$  years.

The averages of baseline biochemical profiles are listed in Table 2. Baseline creatinine in this sample was  $1.37 \pm 0.4$  mg/dL before onset of acute kidney injury. The means of serum phosphate and calcium were  $3.7 \pm 1.2$  mg/dL and  $9.01 \pm 0.6$  mg/dL, respectively. Mean iPTH at the time of biopsy was  $495.66 \pm 358.9$  pg/mL and 25-hydroxy vitamin D was  $19.9 \pm 13.3$  ng/mL. None of the patients was taking a calcimimetic, and only 3 of 12 patients were on active vitamin D (calcitriol) at the time of acute kidney injury (data not shown). No use of phosphate supplements or phosphate-containing enemas was documented.

Figure 1 and Table 3 show the comparison of serum creatinine at baseline to each follow-up period (1, 3, 6, and 12 months). For this paired comparison, the sample size was reduced to 10 patients because 2 of the 12 patients were on hemodialysis at the time of biopsy. Serum creatinine levels showed an incremental increase at 12 months compared to baseline, 2.37 vs 1.37 mg/dL, respectively,  $P=0.028$ . Renal function was significantly worse in all the patients at 12-month follow-up; however, only one patient progressed to end-stage renal disease by the end of the study period.

When looking at the association between the calcium phosphate product ( $\text{Ca} \times \text{PO}_4$ ) and the number of tubules with crystal deposition, a moderate positive linear relationship was found,  $r=0.60$ ,  $P=0.037$ , (Figure 2), suggesting that an increase in  $\text{Ca} \times \text{PO}_4$  also increases the number of tubules with crystal foci. Additional associations were tested between  $\text{Ca} \times \text{PO}_4$  and peak creatinine, as well as  $\text{Ca} \times \text{PO}_4$  and parathyroid hormone, but did not show any significant results. The correlation between the number of tubules with crystal foci and creatinine at 12 months and the number of tubules with crystal foci

**Figure 1. Creatinine levels for the study period.**

and peak creatinine was also calculated but was not statistically significant (Table 4).

## DISCUSSION

The finding of nephrocalcinosis is prevalent in renal allograft biopsies although its long-term impact remains controversial. In one of the largest studies of kidney transplant recipients with nephrocalcinosis, no difference in renal function after a mean follow-up of 33 months was seen in patients with and without calcium-phosphate deposition ( $1.48 \pm 0.83$  mg/dL vs  $1.45 \pm 0.83$  mg/dL).<sup>8</sup> In a protocol biopsy study from Germany, nephrocalcinosis observed at 6 and 12 weeks after renal transplantation was associated with development of chronic allograft nephropathy ( $P=0.006$ ); however, no data on renal function or graft survival were reported.<sup>10</sup> In contrast, Pinheiro et al reported significantly lower 12-year renal allograft survival in patients with nephrocalcinosis compared to patients without this finding (49.7% vs 74.1%,  $P=0.013$ ).<sup>7</sup>

This histologic finding is seen more frequently in the first year after transplantation, suggesting a disordered mineral metabolism.<sup>8</sup> Some animal data suggest that alteration in mineral metabolism may contribute to crystal deposition and renal dysfunction.<sup>11</sup> Hypercalcemia, hypophosphatemia, and renal phosphate wasting are common early after kidney transplantation and are related to persistent hyperparathyroidism.<sup>12,13</sup> PTH levels show a biphasic decrease after successful transplantation, an approximate 50% decrease during the first 3-6 months followed by a more gradual decline.<sup>14</sup> Nevertheless, increased PTH levels persist in a substantial portion of renal transplant recipients, despite the presence of normal renal function.<sup>15</sup> This condition is often referred to as persistent (or tertiary) hyperparathyroidism. Long

**Table 3. Comparison of Creatinine Level at Follow-Up Periods**

Variable	Baseline	1 Month (P value)	3 Months (P value)	6 Months (P value)	12 Months (P value)
Creatinine, mg/dL	1.37 ± 0.40	2.42 ± 0.86 (0.012)	2.19 ± 0.58 (0.001)	2.46 ± 0.86 (0.002)	2.37 ± 1.30 (0.028)

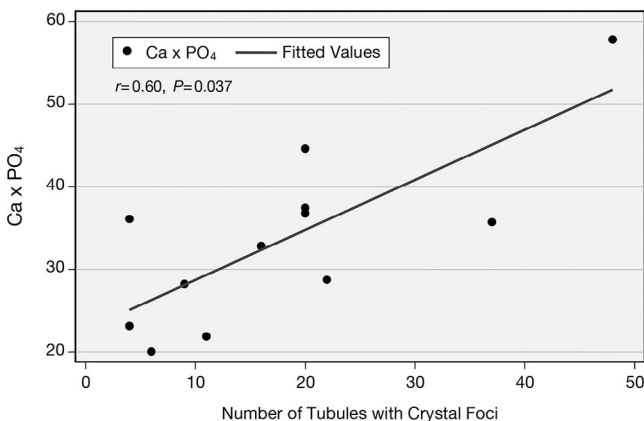
Note: In this parametric paired (Student *t* test) comparison, n was reduced to 10 because 2 patients who were on hemodialysis did not have recorded baseline creatinine levels. Values are reported as mean ± SD.

duration on dialysis, severe secondary hyperparathyroidism at the time of transplantation, or need for calcimimetic therapy confers an increased risk for persistent hyperparathyroidism.<sup>16</sup> After transplantation, suboptimal renal function, metabolic acidosis, and low vitamin D levels may also increase PTH secretion. Persistent hyperparathyroidism and hyperphosphatemia have been shown to contribute significantly to the occurrence of hypercalcemia and hypophosphatemia, most likely by inducing renal phosphate wasting (fibroblast growth factor 23 and PTH) and calcium release from the bones (PTH).<sup>12,13,17</sup>

Our study focused on patients who developed acute allograft dysfunction, and kidney biopsy revealed nephrocalcinosis as the main histologic finding. An overwhelming majority of the crystal deposits were calcium phosphate; however, calcium oxalate crystals were also observed in a few patients (data not shown). Interestingly, the percentage of interstitial fibrosis and tubular atrophy was mild in most of the biopsy samples (Table 5) indicating that renal parenchyma was well preserved in our study sample. Despite minimal histologic abnormalities, creatinine did not return to baseline in any of the 12 patients (1.37 ± 0.4 mg/dL vs 2.37 ± 1.3 mg/dL). One patient progressed to end-stage renal disease, requiring renal replacement therapy. In the absence of other abnormal findings in the renal biopsy (acute tubular necrosis, acute rejection, transplant glomerulopathy, or de novo or recurrent glomerulonephritis),

nephrocalcinosis is the likely cause for progressive renal impairment in our patients. Nephrocalcinosis in renal allografts may not be as benign a histologic finding as previously thought.

Although nephrocalcinosis is seen more commonly within the first year after transplantation, only 6 of our 12 patients were diagnosed within the first 12 months of transplantation, indicating that the metabolic abnormalities persisted long after transplantation despite patients regaining near-normal renal function. In one study, high PTH levels correlated with inferior graft survival (*P*<0.05) 1 year after transplantation in patients with calcifications.<sup>9</sup> Persistent or tertiary hyperparathyroidism was also prevalent in our patient sample; however, hypercalcemia and hypophosphatemia were not observed unlike in previous studies.<sup>12,13,17</sup> Hypercalcemia and hypophosphatemia have been independently associated with nephrocalcinosis in renal transplant recipients.<sup>13</sup> Our study also showed a moderately positive linear relationship between  $\text{Ca} \times \text{PO}_4$  and the number of tubules with crystal foci. The significance of this finding remains unknown because we know that in addition to urinary calcium and phosphate load, urinary pH and the concentration of inhibitors such as citrate, magnesium, pyrophosphate, and urinary proteins determine precipitation of microcrystals.<sup>18,19</sup> Unfortunately, urinary indices were only performed in



**Figure 2. Correlation between calcium phosphate product ( $\text{Ca} \times \text{PO}_4$ ) and the number of tubules with crystal foci.**

**Table 4. Calcium Phosphate Product ( $\text{Ca} \times \text{PO}_4$ ) and Correlations**

Variable	<i>r</i> <sup>a</sup>	<i>P</i> value
$\text{Ca} \times \text{PO}_4$ and number of tubules with crystal foci	0.603	0.037
$\text{Ca} \times \text{PO}_4$ and intact parathyroid hormone at time of acute kidney injury	0.419	0.174
$\text{Ca} \times \text{PO}_4$ and peak creatinine at acute kidney injury	0.490	0.149
Number of tubules with crystal foci and peak creatinine	0.184	0.609
Number of tubules with crystal foci and creatinine at 12 months	0.245	0.468

<sup>a</sup>Spearman correlation coefficient.

**Table 5. Biopsy Characteristics**

Variable	Mean $\pm$ SD	Minimum-Maximum
Number of tubules with crystal deposits	18.08 $\pm$ 13.4	4-48
Interstitial fibrosis and tubular atrophy, % of sample	22.91 $\pm$ 26.1	5-100

4 of 12 patients; hypocitraturia was seen in all 4 patients, but hypercalciuria was not observed.

Our study has several limitations. It is strictly an observational study with a small sample size, relatively short follow-up, and no control group for comparison. Also, follow-up biopsies to document resolution or progression of nephrocalcinosis were not performed in all patients.

## CONCLUSION

Our study points to the importance of identifying patients with persistent or tertiary hyperparathyroidism because these patients may be at risk for developing nephrocalcinosis. Aggressive treatment of hyperparathyroidism in the pretransplant period, whether by the use of calcimimetics or surgery, may be pivotal. Prospective studies are needed to further investigate this finding.

## REFERENCES

- Asplin JR, Parks JH, Coe FL. Dependence of upper limit of metastability on supersaturation in nephrolithiasis. *Kidney Int.* 1997 Dec;52(6):1602-1608.
- Chevalier RL. Pathogenesis of renal injury in obstructive uropathy. *Curr Opin Pediatr.* 2006 Apr;18(2):153-160.
- Bani-Hani AH, Campbell MT, Meldrum DR, Meldrum KK. Cytokines in epithelial-mesenchymal transition: a new insight into obstructive nephropathy. *J Urol.* 2008 Aug;180(2):461-468.
- Gimenez LF, Solez K, Walker WG. Relation between renal calcium content and renal impairment in 246 human renal biopsies. *Kidney Int.* 1987 Jan;31(1):93-99.
- Ibels LS, Alfrey AC, Huffer WE, Craswell PW, Weil R 3rd. Calcification in end-stage kidneys. *Am J Med.* 1981 Jul;71(1):33-37.
- Truong LD, Yakupoglu U, Feig D, et al. Calcium oxalate deposition in renal allografts: morphologic spectrum and clinical implications. *Am J Transplant.* 2004 Aug;4(8):1338-1344.
- Pinheiro HS, Câmara NO, Osaki KS, De Moura LA, Pacheco-Silva A. Early presence of calcium oxalate deposition in kidney graft biopsies is associated with poor long-term graft survival. *Am J Transplant.* 2005 Feb;5(2):323-329.
- Evenepoel P, Lerut E, Naesens M, et al. Localization, etiology and impact of calcium phosphate deposits in renal allografts. *Am J Transplant.* 2009 Nov;9(11):2470-2478.
- Gwinner W, Suppa S, Mengel M, et al. Early calcification of renal allografts detected by protocol biopsies: causes and clinical implications. *Am J Transplant.* 2005 Aug;5(8):1934-1941.
- Schwarz A, Mengel M, Gwinner W, et al. Risk factors for chronic allograft nephropathy after renal transplantation: a protocol biopsy study. *Kidney Int.* 2005 Jan;67(1):341-348.
- Lau K. Phosphate excess and progressive renal failure: the precipitation-calcification hypothesis. *Kidney Int.* 1989 Nov;36(5):918-937.
- Evenepoel P, Naesens M, Claes K, Kuypers D, Vanrenterghem Y. Tertiary 'hyperphosphatoninism' accentuates hypophosphatemia and suppresses calcitriol levels in renal transplant recipients. *Am J Transplant.* 2007 May;7(5):1193-1200.
- Evenepoel P, Van Den Bergh B, Naesens M, et al. Calcium metabolism in early posttransplantation period. *Clin J Am Soc Nephrol.* 2009 Mar;4(3):665-672.
- Bonarek H, Merville P, Bonarek M, et al. Reduced parathyroid functional mass after successful kidney transplantation. *Kidney Int.* 1999 Aug;56(2):642-649.
- Evenepoel P, Claes K, Kuypers D, Maes B, Bammens B, Vanrenterghem Y. Natural history of parathyroid function and calcium metabolism after kidney transplantation: a single-centre study. *Nephrol Dial Transplant.* 2004 May;19(5):1281-1287.
- Evenepoel P, Sprangers B, Lerut E, et al. Mineral metabolism in renal transplant recipients discontinuing cinacalcet at the time of transplantation: a prospective observational study. *Clin Transplant.* 2012 May-Jun;26(3):393-402.
- Evenepoel P, Meijers BK, de Jonge H, et al. Recovery of hyperphosphatoninism and renal phosphorus wasting one year after successful renal transplantation. *Clin J Am Soc Nephrol.* 2008 Nov;3(6):1829-1836.
- Moochhala SH, Sayer JA, Carr G, Simmons NL. Renal calcium stones: insights from the control of bone mineralization. *Exp Physiol.* 2008 Jan;93(1):43-49.
- Sayer JA, Carr G, Simmons NL. Nephrocalcinosis: molecular insights into calcium precipitation within the kidney. *Clin Sci (Lond).* 2004 Jun;106(6):549-561.

*This article meets the Accreditation Council for Graduate Medical Education and the American Board of Medical Specialties Maintenance of Certification competencies for Patient Care and Medical Knowledge.*