



## Endovascular

# Paclitaxel-eluting balloon and everolimus-eluting stent for provisional stenting of coronary bifurcations: 12-month results of the multicenter BIOLUX-I study ☆☆☆☆☆



Stephen Worthley<sup>a,\*</sup>, Randall Hendriks<sup>b</sup>, Matthew Worthley<sup>a</sup>, Alan Whelan<sup>b</sup>, Darren L. Walters<sup>c</sup>, Robert Whitbourn<sup>d</sup>, Ian Meredith<sup>e</sup>

<sup>a</sup> Cardiovascular Investigation Unit, Royal Adelaide Hospital and University of Adelaide, Adelaide, Australia

<sup>b</sup> Cardiology Research Centre, Fremantle Hospital, Fremantle, Australia

<sup>c</sup> Department of Cardiology, Prince Charles Hospital, Brisbane, Australia and University of Queensland, Brisbane Australia

<sup>d</sup> Department of Cardiology, St Vincent's Hospital, Melbourne, Fitzroy, Australia

<sup>e</sup> Cardiovascular Research Centre, Monash Medical Centre, Clayton, Australia

## ARTICLE INFO

## Article history:

Received 19 March 2015

Received in revised form 10 July 2015

Accepted 24 July 2015

## Keywords:

Bifurcation lesion  
Drug-eluting balloon  
Drug-coated balloon  
Provisional stenting

## ABSTRACT

**Background:** Several studies investigated the combination of bare metal stents in the main branch and drug-eluting balloons in the side branch in bifurcation lesions, but data on the combination of drug-eluting stents and drug-eluting balloons are scarce. We aim to assess the feasibility of provisional stenting with an everolimus-eluting stent in the main branch and a paclitaxel-eluting balloon in the side branch.

**Methods:** In this prospective, multi-center study conducted in 5 Australian sites, 35 patients with bifurcation lesions were enrolled. Angiographic and intravascular ultrasound assessments were conducted at 9 months; clinical follow-up was conducted until 12 months.

**Results:** The primary endpoint, late lumen loss in the side branch measured by quantitative coronary angiography, was  $0.10 \pm 0.43$  mm. No binary restenosis was observed. One patient died; 3 myocardial infarctions (one suspected and two in non-target vessels) and one target lesion revascularization occurred. No probable or definite stent thrombosis was observed.

**Conclusion:** The combination of an everolimus-eluting stent in the main branch and a paclitaxel-eluting balloon in the side branch appears to be a safe, effective and novel treatment option for bifurcation lesions.

© 2015 The Authors. Published by Elsevier Inc. This is an open access article under the CC BY-NC-ND license (<http://creativecommons.org/licenses/by-nc-nd/4.0/>).

**Abbreviations:** ARC, academic research consortium; BTHC, butyryltri-n-hexyl citrate.

☆ The study was funded by BIOTRONIK Australia Pty. Ltd., Pymble, Australia.

☆☆ Conflict of interest statement: Prof. Dr. Ian Meredith reports personal and proctor fees from Boston Scientific and personal fees from Guided Delivery Systems, both not related to the submitted work. Prof. Dr. Stephen Worthley reports personal and proctor fees from St Jude Medical and personal fees from Medtronic, both not related to the submitted work. Dr. Randall Hendriks, Prof. Dr. Matthew Worthley, Prof. Dr. Robert Withbourn, Dr. Alan Whelan and Prof. Dr. Darren Walters have no financial interest to declare.

★ Registered on [www.anzctr.org.au](http://www.anzctr.org.au), ID 335843

★★ Summary for annotated table of content: Several studies investigated the combination of bare metal stents in the main branch and drug-eluting balloons in the side branch in bifurcation lesions, but data on the combination of drug-eluting stents and drug-eluting balloons are scarce. BIOLUX-I is the first study to assess the combination of an everolimus-eluting stent with a paclitaxel-eluting balloon. Results were encouraging with late lumen loss in the side branch of  $0.10 \pm 0.43$  mm at 9 months, no binary restenosis and low complication rates.

\* Corresponding author at: Royal Adelaide Hospital, Cardiovascular Investigation Unit, Level 6, Theatre Block, North Terrace, Adelaide, SA500, Australia. Tel.: +61 8 8222 5608; fax: +61 8 8222 4525.

E-mail address: [stephen.worthley@adelaide.edu.au](mailto:stephen.worthley@adelaide.edu.au) (S. Worthley).

## 1. Introduction

Bifurcation lesions account for approximately 15% of contemporary percutaneous coronary interventions (PCIs) and are amongst the most technically challenging lesion subsets in PCIs [1–3]. In the past years, the introduction of drug-eluting stents (DESs) has significantly improved outcomes [3], and meanwhile, provisional stenting is considered to be the preferable approach for most of the bifurcation lesions [1–4]. Still, the dilemma of reducing side branch restenosis remains and further investigation into devices that may help to reduce restenosis in bifurcation lesions is warranted.

Drug-eluting balloons (DEBs), being successfully deployed in several indications in coronary and peripheral artery disease [5], could be a promising treatment modality to reduce side branch restenosis. The updated consensus group recommendations from Kleber et al. [1] as well as a publication of Mathey et al. [6] suggested that provisional stenting with DES in the main branch and DEB in the side branch might be a valuable treatment option which warrants scientific evaluation. We

therefore aim to assess the safety and efficacy of provisional stenting with an everolimus-eluting stent in the main branch and a paclitaxel-eluting balloon in the side branch. To the best of our knowledge, only one single center study investigating the combination of DES in the main branch and DEB in the side branch has been published to date [7]. In contrast to BIOLUX-I, this single-center study used the same drug –paclitaxel – for DEB and DES, whereas our study combines a paclitaxel-eluting DEB with a state of the art everolimus-eluting DES.

## 2. Methods

### 2.1. Study design and population

BIOLUX-I is a prospective, multi-center, single arm pilot study to assess the feasibility and safety of the Pantera Lux DEB (Biotronik AG, Buelach, Switzerland) for the treatment of symptomatic single de novo bifurcation lesions which are appropriate for provisional stenting technique. Patients were enrolled between January 2011 and August 2012. The trial is registered at [www.anzctr.org.au](http://www.anzctr.org.au), ID 335843, where the full set of general in- and exclusion criteria is available. Specific angiographic inclusion criteria were: Either a single target lesion or two lesions (target and non-target) located in separate coronary arteries. If a non-target lesion was treated, it had to be treated first. Further, the target lesion had to be a single de novo bifurcation lesion involving a coronary artery with a reference vessel diameter of 2.0 to 4.0 mm in the main branch and side branch with a main branch stenosis of  $\geq 50\%$  and  $< 100\%$ . Lastly, a target vessel thrombolysis in myocardial infarction (TIMI) flow  $\geq 2$  was required. Specific angiographic exclusion criteria were: Target lesion location in a vessel which has a bypass graft, significant stenosis ( $> 50\%$ ) proximal or distal to the target lesion that might require revascularization or impede runoff, excessively tortuous target vessel (two bends  $> 90^\circ$  to reach the target lesion), aorto-ostial or unprotected left main target lesion or target lesion within 5 mm of the origin of the left anterior descending, left circumflex, or right coronary artery, severely calcified target lesion, or evidence of a thrombus, further co-existence of unprotected left main disease (obstruction of  $> 50\%$ ).

Clinical assessments were scheduled at 1, 6, 9 and 12 months. At 9 months additionally angiography and intravascular ultrasound (IVUS) were performed. It was recommended to either use clopidogrel or prasugrel for 6 months and acetylsalicylic acid indefinitely post-procedure. Monitoring included 10% source document verification of key variables. Project and site management as well as data coordination and adjudication was organized by an independent Clinical Research Organization. The Safety Monitoring Committee was composed of physicians from the fields of interventional cardiology who were not directly involved in the conduct of the trial. Angiographic and IVUS assessments were done by an independent core laboratory. Ethics committee approval was obtained for all participating institutions and the clinical trial was conducted in accordance with Good Clinical Practice and ISO14155 as well as local regulations and applicable regulatory requirements. All patients provided written informed consent.

### 2.2. Procedure

The surface of the Pantera Lux DEB is homogenously coated with a delivery matrix of  $3 \mu\text{g}$  paclitaxel per  $\text{mm}^2$  using butyryltri-n-hexyl citrate (BTHC) as an excipient. BTHC incorporates paclitaxel into a microcrystalline structure to improve drug uptake into the vessel wall [8,9]. It degrades to citric acid and alcohol. Paclitaxel is a lipophilic anti-proliferative substance that allows a rapid drug absorption by the surrounding tissue. The DEB was available in lengths of 10 to 30 mm with diameters of 2.0 to 4.0 mm.

Pre-dilatation of the main branch with a standard balloon catheter was required. Then, the side branch was treated with Pantera Lux and the main branch with a DES (XienceV/Xience Prime, Abbott Vascular, Santa Clara, CA, USA). Post-dilatation in the main branch was allowed at the investigator's discretion in order to achieve optimal stent deployment (residual diameter stenosis  $< 10\%$ ). Thereafter, kissing balloon inflation with standard balloons had to be performed. Stenting of the side branch was deemed appropriate in the following cases: prolonged ischemia (attributable to a side branch complication), TIMI Grade flow 0 or 1, dissection in the side branch,  $> 70\%$  residual stenosis.

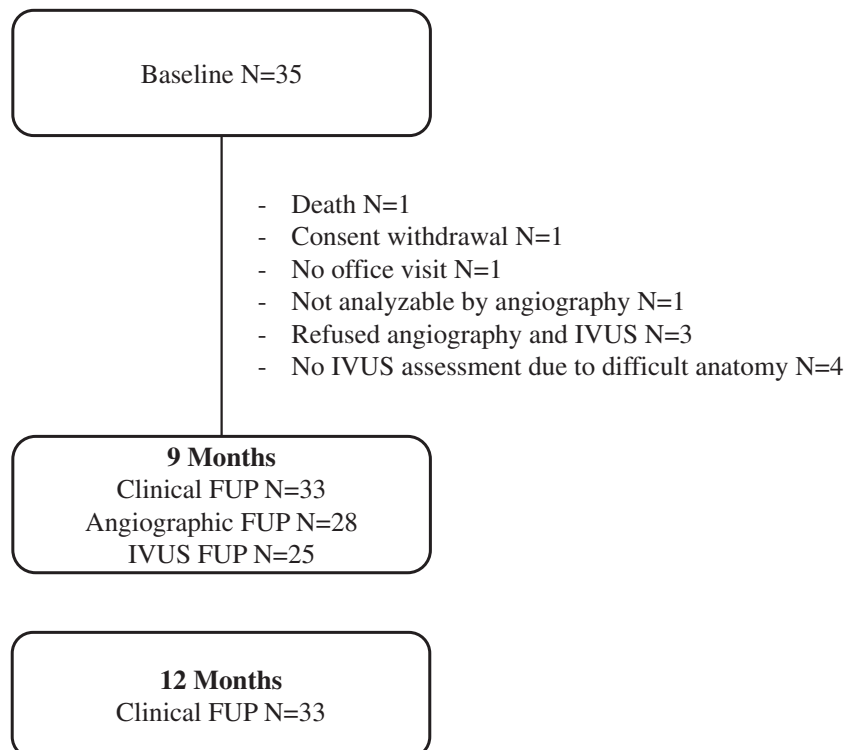


Fig. 1. Patient flow diagram. FUP, follow-up; IVUS, intravascular ultrasound.

### 2.3. Endpoints and definitions

Lesions were defined according the Medina classification [10]. The primary endpoint was late lumen loss (LLL) of the side branch at 9 months by quantitative coronary angiography (QCA), defined as the difference between the post-index procedure minimal lumen diameter (MLD) and the follow-up MLD. Secondary endpoints were device success, defined as final residual diameter stenosis of <30% by QCA in the side branch, using the assigned device only, procedural success, defined as final diameter stenosis <30% by QCA in the side branch and main branch, using the study device, without the occurrence of death, myocardial infarction or repeat target lesion revascularization (TLR) during the hospital stay, and lesion success, defined as final residual diameter stenosis of <30% by QCA in the side branch without the need for other lesion treatment (like cutting balloon, atherectomy) during the index procedure. Furthermore, a composite of cardiac death, target-vessel myocardial infarction and clinically driven target vessel revascularization (TVR) was assessed at 6, 9 and 12 months, clinically driven TLR at 6, 9 and 12 months and binary angiographic restenosis at 9 months, as measured by QCA. Definitions of cardiac death, myocardial infarction and TLR and stent thrombosis were according to the ARC-Academic Research Consortium guidelines [11].

### 2.4. Statistical analysis

The analysis was based on the principle of intention-to-treat (ITT). For this study, all subjects who met the study entry criteria, signed the written informed consent and were enrolled in the trial were counted in the intention-to-treat analysis. The primary analysis consists of descriptive statistics. These are presented as the mean and standard deviation for continuous variables and as frequencies and percentages for discrete variables.

## 3. Results

### 3.1. Baseline data

In BIOLUX-I, 35 patients were enrolled in 5 Australian centers. The patient flow is displayed in Fig. 1. Patients treated were predominantly male (82.8%), nearly one quarter had diabetes (22.9%) or previous percutaneous coronary interventions (PCIs) (22.9%). Lesions were mostly located in the left anterior descending artery (82.9%) (Table 1).

### 3.2. Procedural data

Per site assessment 26 patients (74.3%) had true bifurcation lesions with  $\geq 50\%$  stenosis in both branches, per visual core laboratory assessment 11 patients (31.4%) had true bifurcations Medina X,X,1 (Table 1), and per QCA 3 patients (8.6%). Concomitant non-target lesion treatment was performed in 5 patients (14.3%). In the main branch, 3 lesions were treated with 2 overlapping stents and one bailout stent was used to treat a small dissection. In one patient, the Pantera Lux DEB was unable to pass through the side branch. After pre-dilatation with an uncoated balloon, the DEB could be successfully deployed. Four additional stents were used in the side branch, all for treating vessel dissections (Table 2). Post-procedure side branch stenosis ranged from 3.34% to 49.96%, and 9 patients had a side branch stenosis  $\geq 30\%$ , resulting in a device success rate of 60.0% (21/35). Procedure and lesion success rates were 71.4% and 74.3% respectively.

### 3.3. Follow-up data

Angiographic and IVUS follow-up data are displayed in Table 3. LLL in the side branch was  $0.10 \pm 0.43$  mm per QCA and  $-0.03 \pm 0.22$  mm per IVUS assessment in the overall population (Table 3, Fig. 2) and  $0.06 \pm$

**Table 1**

Patient baseline and lesion data.

Patient baseline and lesion data	
Demographics	
Mean age $\pm$ SD (years)	65.9 $\pm$ 9.5
Min–Max	50–82
Male gender	82.8% (29/35)
Medical history	
History of smoking	74.3% (26/35)
Diabetes mellitus	22.9% (8/35)
History of hypertension	68.6% (24/35)
History of hyperlipidemia	82.8% (29/35)
Premature CAD in a first degree relative <sup>a</sup>	41.2% (14/34)
Previous CABG	2.9% (1/35)
Previous PCI	22.9% (8/35)
Stroke or TIA in Last 6 Months	2.9% (1/35)
Mean LVEF (%)	68 $\pm$ 10.4%
CCS Class	
Class I	28.6% (10/35)
Class II	42.9% (15/35)
Class III	8.6% (3/35)
Class IV	2.9% (1/35)
No angina	48.6% (6/35)
Medina classification <sup>b</sup>	
1,1,1	23.3% (7/30)
1,1,0	46.6% (14/30)
1,0,1	3.3% (1/30)
1,0,0	16.7% (5/30)
0,1,1	10.0% (3/30)
0,1,0	16.7% (5/30)
Bifurcation treated	
LAD	82.8% (29/35)
LCX	8.6% (3/35)
RCA	8.6% (3/35)
Previous stenting of MB or SB	0.0% (0/35)
Angulation between distal MB and SB < 70°	51.4% (18/35)

CABG, coronary artery bypass graft; CAD, coronary artery disease, Canadian Cardiovascular Society classification; LAD, left anterior descending; LCX, left circumflex; LVEF, left ventricular ejection fraction; MB, main branch; PCI, percutaneous coronary intervention; RCA, right coronary artery; SB, side branch; TIA, transient ischemic attack.

Values are mean  $\pm$  SD when appropriate.

<sup>a</sup> Unknown for 1 patient.

<sup>b</sup> By visual estimate.

0.41 mm in patients with true bifurcation per core laboratory analysis. No binary restenosis occurred.

At 12-month follow-up all patients were without symptoms of angina except one with CCS class I.

Clinical outcomes are displayed in Table 4. The composite endpoint of cardiac death, target-vessel myocardial infarction and clinically driven TVR was 5.9%. One patient with Medina class 1,1,0, non-target lesion treatment, post-dilatation and stenting of the side branch was found dead at home 4.5 months post-procedure. The general practitioner assessed the cause of death as suspected myocardial infarction secondary to ischemic heart disease. No autopsy was performed. Per ARC definition [11], the event was further classified as cardiac death and possible stent thrombosis. Two further non-target vessel myocardial infarctions occurred, one pre-procedure and one at 2.5 months. One clinically driven TLR was performed more than 9 months post-procedure in a patient who had Medina class 0,1,1 at baseline and a main branch bailout during procedure. This patient had a left main stenosis and aortic stenosis and received a coronary artery bypass graft and aortic valve replacement.

## 4. Discussion

To the best of our knowledge, this is the first multicentre study assessing the feasibility of provisional stenting with a combination of DES in the main branch and DEB in the side branch, using different drugs. Adjudicated endpoints and independent angiographic and IVUS core laboratories add to the strength of the study.

**Table 2**  
Procedural data.

Procedural data	
Main Branch	
Pre-dilatation	97.1% (34/35)
Xience Prime	97.1% (34/35)
Xience V	2.9% (1/35)
Post-procedure dilatation rates	
1 balloon	48.6% (17/35)
2 balloons	40.0% (14/35)
≥3 balloons	11.4% (4/35)
Main vessel bailout	2.9% (1/35)
Side branch	
Dilatation (uncoated balloon)	
1 balloon	17.1% (6/35)
≥2 balloons	20.0% (7/35)
Side branch bailout requiring stenting	11.4% (4/35)

The potential role of DEB in bifurcation lesions is to maintain the simplicity of provisional stenting with the advantage of reducing restenosis of the side branch. However, the combination of pre-dilatation with a DEB followed by main branch stenting with a bare metal stent appears to be inferior to DES plus uncoated balloon due to insufficient results in the main branch and similar results in the side branch [12,13]. Another treatment option is the combination of DES in the main branch and DEB in the side branch, which could potentially overcome the limitation of insufficient results of the DEB plus bare metal stent combination in the main branch. In a single-center study, Herrador et al. [7] compared patients treated with a paclitaxel-eluting balloon in the side branch and a paclitaxel-eluting stent in the main branch with a historical control of patients with uncoated balloon treatment in the side branch. Side branch stenosis and LLL at 9 months were significantly lower in the DEB group compared with the uncoated balloon group ( $25 \pm 16\%$  versus  $36 \pm 21\%$ ,  $p = 0.01$  and  $0.09 \pm 0.4$  mm versus  $0.40 \pm 0.5$  mm,  $p = 0.01$ ) and numerically less restenosis of the side branch occurred in the DEB group (7% versus 20%,  $p = 0.08$ ). Main branch LLL was  $0.49 \pm 0.6$  and  $0.62 \pm 0.7$  respectively.

We assessed the combination of a paclitaxel-eluting DEB in the side branch with an everolimus-eluting stent in the main branch and found – despite the very small baseline side branch diameter of only  $2.06 \pm 0.39$  – excellent angiographic follow-up data which are comparable to those previously reported for DES/ uncoated balloon combinations and DES/DEB combinations. Specifically, LLL of the side branch was  $0.10 \pm 0.43$  mm compared to  $-0.13$  mm to  $0.11$  mm for DES/uncoated balloon and DES/DEB combinations (and LLL of the main branch was  $0.28 \pm$

$0.59$  mm versus  $-0.06$  mm to  $0.49$  mm) [7,12–14]. Side branch diameter stenosis was  $22.6\% \pm 12.5\%$  versus  $25\%$  to  $33\%$  and binary restenosis was 0% compared to 7% to 20% for the side branch and 11% to 19% overall [7,12–14]. Notably, some patients had a negative LLL. With these small patient numbers, the underlying reason cannot be clarified. Eventually, it was caused by vessel-remodeling or by assessing different areas of the vessel as the treated lesion often cannot be accurately located when a stent is not implanted.

Overall, the angiographic parameters have to be interpreted taking into account the moderate pre-procedure stenosis of  $45.0\% \pm 15.2\%$  in the main branch and  $30.1\% \pm 16.4\%$  in the side branch, as assessed by QCA. Only 11 patients (31.4%) had true bifurcation lesions by visual estimate by the core laboratory. However, when assessing patients with true bifurcation lesions separately, LLL was  $0.06 \pm 0.41$ , suggesting that the DEB is equally effective in true bifurcation lesions. Notably, there was a prominent difference between the core laboratory and site assessment and even between visual estimation and QCA assessment of the core laboratory. Eventually, the very small vessel reference diameter of  $2.01 \pm 0.43$  hampered a consistent assessment. According to site data, 26 patients (74.3%) had a  $\geq 50\%$  side branch and main branch stenosis. This is especially interesting since a recent article compared the site assessment versus angiographic core laboratory assessment for 2013 records of the American College of Cardiology Cardiovascular Data Registry and found only modest agreement between angiographic readings in clinical practice and those of an independent core laboratory in regards to number of vessels affected (kappa from 0.39 to 0.59 depending on the affected vessel; an agreement in all vessels was only found in 60.9%). The authors concluded that further studies are needed to assess the implications on patient management [15]. Certainly, it is an indicator that for studies in bifurcation lesions, core laboratories should always be consulted.

Except in one case, in which the DEB originally could not pass the lesion, and the lesion had to be pre-dilated with an uncoated balloon first, no side branch pre-dilatation with an uncoated balloon was performed. According to the results of the Nordic-Baltic Bifurcation Study III [14], which showed that final kissing balloon inflation with uncoated balloons reduced angiographic side branch (re)stenosis, the protocol mandated final kissing balloon inflation for procedural homogeneity. However, a fair amount of discretion was allowed since there is no perfect way to treat bifurcations. In the end, only 37.2% (13/35) of the patients were treated with an uncoated balloon in the side branch in addition to the DEB treatment, reflecting the tendency to rather use the simpler approach without final-kissing balloon dilatation, which has been shown to reduce the use of contrast media and procedure

**Table 3**  
Angiographic and IVUS results.

Angiographic results	Main branch			Side branch		
	Pre-procedure	Post-procedure	9-month FUP	Pre-procedure	Post-procedure	9-month FUP
RVD (mm)	2.65 ± 0.57	3.03 ± 0.56	2.85 ± 0.41	2.01 ± 0.43	2.08 ± 0.59	2.01 ± 0.43
Lesion length (mm)	18.6 ± 6.0	–	–	5.51 ± 2.30	–	–
MLD (mm)	1.47 ± 0.45	2.76 ± 0.58	2.50 ± 0.45	1.45 ± 0.44	1.66 ± 0.47	1.52 ± 0.31
Diameter stenosis (%)	43.2 ± 16.8	9.1 ± 5.5	12.4 ± 9.2	26.8 ± 16.9	21.5 ± 13.1	22.6 ± 12.2
Binary restenosis	–	–	0.0% (0/28)	–	–	0.0% (0/28)
Late lumen loss (mm)	–	–	0.28 ± 0.59	–	–	0.10 ± 0.43
<b>IVUS results</b>	<b>Main branch</b>			<b>Side branch</b>		
MLD (mm)	–	2.95 ± 0.35	2.99 ± 0.35	–	2.23 ± 0.31	2.28 ± 0.28
MinLA (mm <sup>2</sup> )	–	6.23 ± 1.54	6.12 ± 1.54	–	3.47 ± 1.06	3.40 ± 0.78
LL diameter (mm)	–	–	0.01 ± 0.12	–	–	–0.03 ± 0.22
LL lumen area (mm <sup>2</sup> )	–	–	0.33 ± 0.65	–	–	0.14 ± 0.78
Stent eccentricity index <sup>a</sup>	–	0.85 ± 0.04	0.86 ± 0.03	–	–	–
ISA <sup>b</sup>	–	25.8% (8/31)	11.5% (3/26)	–	0.0% (0/2)	–

ISA, incomplete stent apposition; IVUS, intravascular ultrasound; LL, late loss; MinLA, minimal lumen area; MLD, minimal lumen diameter; RVD, reference vessel diameter.

Values are mean ± SD when appropriate.

<sup>a</sup> Minimal lumen diameter/maximal lumen diameter.

<sup>b</sup> Defined as a separation of at least one stent strut from the intimal surface of the arterial wall with evidence of blood speckling behind the stent struts without overlapping side branches.

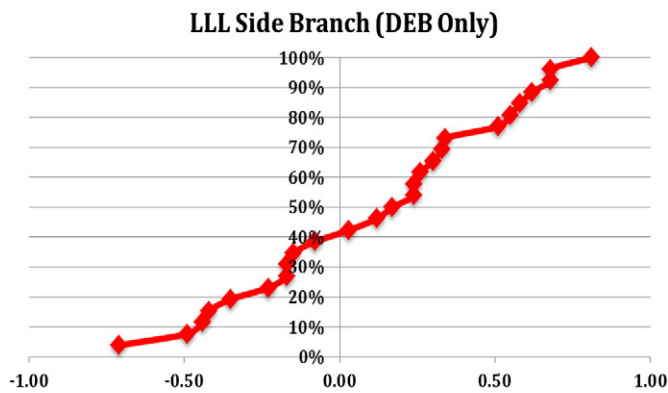


Fig. 2. Late lumen loss of the side branch at 9 months. LLL, late lumen loss. Patients with side branch stenting were excluded.

and fluoroscopy time [14]. Meanwhile, the 2014 consensus document states that kissing balloon inflation is not routinely required [3].

The acute success rates appear low. However, comparing them with other studies, it has to be considered that different definitions for acute success exist. BIOLUX-I applied the most rigorous definition using a threshold of side branch stenosis of <30%, whereas other studies [6,7,12] used a threshold of <50%. Notably, in BIOLUX-I, no patient had a post-procedure main branch stenosis  $\geq 30\%$  and only one patient had a post-procedure side branch stenosis of  $\geq 50\%$  (49.96%). It would be desirable that future ARC guidelines would include common definitions to report acute success rates to allow comparing acute success results across studies.

The complication rates were low with only one death, possibly due to myocardial infarction, two additional non-target vessel myocardial infarctions, one TLR, and no definite or probable stent thrombosis. While the patient numbers are low and absolute values have to be interpreted with caution, it is reasonable to conclude that the approach of combining a paclitaxel-eluting balloon with an everolimus-eluting stent is safe. Furthermore, aside from the angiographic and IVUS parameters the performance of this treatment modality is reflected in the reduction and maintenance of a low angina class at 12 months (Only one patient met the CCS class 1 criteria, all others were asymptomatic).

#### 4.1. Limitations

While per site assessment, 74.3% of the patients had side and main branch stenosis of  $\geq 50\%$  at baseline, only 11 patients were assessed as having a true bifurcation lesion by the core laboratory. Clinical follow-up rate was excellent with only one patient withdrawing consent. However, only 28 patients attended the angiographic follow-up. Most importantly, the BIOLUX-I study was a pilot study and inevitably the trial

Table 4

Clinical outcomes during 12 months.

Clinical outcomes	6-month FUP	9-month FUP	12-month FUP
Composite endpoint <sup>a</sup>	2.9% (1/35)	2.9% (1/35)	5.7% (2/35)
Cardiac death <sup>b</sup>	2.9% (1/35)	2.9% (1/35)	2.9% (1/35)
Target-vessel MI <sup>b</sup>	2.9% (1/35)	2.9% (1/35)	2.9% (1/35)
Non-target-vessel MI	5.7% (2/35)	5.7% (2/35)	5.7% (2/35)
TVR	0.0% (0/35)	0.0% (0/35)	2.9% (1/35)
TLR	0.0% (0/35)	0.0% (0/35)	2.9% (1/35)
Probable or definite stent thrombosis	0.0% (0/35)	0.0% (0/35)	0.0% (0/35)

FUP, follow-up; MI, myocardial infarction; TLR, clinically driven target lesion revascularization; TVR, clinically driven target vessel revascularization.

<sup>a</sup> Composite of cardiac death, target-vessel MI, and clinically driven TVR.

<sup>b</sup> One patient was found dead. Possible cause of death was determined as myocardial infarction.

is limited by a small sample size of 35 patients. Consequently, large scale randomized trials may be warranted to further investigate the use of this treatment modality. Thereby the combination of DES/DEB versus DES/uncoated balloon appears to be of special interest.

## 5. Conclusion

The combination treatment using the Xience V/ Xience Prime DES in the main branch and the Pantera Lux DEB in the side branch appears to be a safe, effective and novel treatment option for bifurcation lesions with low late lumen loss in the main and side branches.

## Acknowledgment

We thank Beatrix Doerr, Clinical Research Consulting, for her editorial assistance, the Clinical Research Organization PCRG-Pacific Clinical Research Group, North Sydney, Australia for the study conduct and analysis of the data, and CERC-Center of European Cardiovascular Research, Massy, France for the angiographic and IVUs core laboratory assessments.

### Funding

The study was sponsored by Biotronik Australia Pty. Ltd., Pymble, Australia.

## References

- [1] Kleber FX, Rittger H, Bonaventura K, Zeymer U, Wöhrle J, Jeger R, et al. Drug-coated balloons for treatment of coronary artery disease: updated recommendations from a consensus group. *Clin Res Cardiol* 2013;102:785–97.
- [2] Windecker S, Kolh P, Alfonso F, Collet JP, Cremer J, Falk V, et al. 2014 ESC/EACTS guidelines on myocardial revascularization: the Task Force on Myocardial Revascularization of the European Society of Cardiology (ESC) and the European Association for Cardio-Thoracic Surgery (EACTS). Developed with the special contribution of the European Association of Percutaneous Cardiovascular Interventions (EAPCI). *Eur Heart J* 2014;35:2541–619.
- [3] Lassen JF, Holm NR, Stankovic G, Lefèvre T, Chieffo A, Hildick-Smith D, et al. Percutaneous coronary intervention for coronary bifurcation disease: consensus from the first 10 years of the European Bifurcation Club meetings. *EuroIntervention* 2014;10:545–60.
- [4] Latib A, Colombo A. Bifurcation disease: what do we know, what should we do? *JACC Cardiovasc Interv* 2008;1:218–26.
- [5] Loh JP, Barbash IM, Waksman R. The current status of drug-coated balloons in percutaneous coronary and peripheral interventions. *EuroIntervention* 2013;9(8):979–88.
- [6] Mathey DG, Wendig I, Boxberger M, Bonaventura K, Kleber FX. Treatment of bifurcation lesions with a drug-eluting balloon: the PEPCAD V (Paclitaxel Eluting PTCA Balloon in Coronary Artery Disease). *EuroIntervention* 2011;7(Suppl. K):K61–5.
- [7] Herrador JA, Fernandez JC, Guzman M, Aragon V. Drug-eluting vs. conventional balloon for side branch dilation in coronary bifurcations treated by provisional T stenting. *J Interv Cardiol* 2013;26:454–62.
- [8] Joner M, Byrne RA, Lapointe JM, Radke PW, Bayer G, Steigerwald K, et al. Comparative assessment of drug-eluting balloons in an advanced porcine model of coronary restenosis. *Thromb Haemost* 2011;105:864–72.
- [9] Joner M, Radke PW, Byrne RA, Hartwig S, Steigerwald K, Leclerc G, et al. Preclinical evaluation of a novel drug-eluting balloon in an animal model of in-stent stenosis. *J Biomater Appl* 2013;27:717–26.
- [10] Medina A, Suárez de Lezo J, Pan M. A new classification of coronary bifurcation lesions. *Rev Esp Cardiol* 2006;59:183.
- [11] Cutlip DE, Windecker S, Mehran R, Boam A, Cohen DJ, van Es GA, et al. Clinical end points in coronary stent trials: a case for standardized definitions. *Circulation* 2007;115:2344–51.
- [12] Stella PR, Belkacemi A, Dubois C, Nathoe H, Dens J, Naber C, et al. A multicenter randomized comparison of drug-eluting balloon plus bare-metal stent versus bare-metal stent versus drug-eluting stent in bifurcation lesions treated with a single-stenting technique: six-month angiographic and 12-month clinical results of the drug-eluting balloon in bifurcations trial. *Catheter Cardiovasc Interv* 2012;80:1138–46.
- [13] López Mínguez JR, Nogales Asensio JM, Doncel Vecino LJ, Sandoval J, Romany S, Martínez Romero P, et al. A prospective randomised study of the paclitaxel-coated balloon catheter in bifurcated coronary lesions (BABILON trial): 24-month clinical and angiographic results. *EuroIntervention* 2014;10:50–7.
- [14] Niemelä M, Kervinen K, Erglis A, Holm NR, Maeng M, Christiansen EH, et al. Randomized comparison of final kissing balloon dilatation versus no final kissing balloon dilatation in patients with coronary bifurcation lesions treated with main vessel stenting: the Nordic-Baltic Bifurcation Study III. *Circulation* 2011;123:79–86.
- [15] Chakrabarti AK, Grau-Sepulveda MV, O'Brien S, Abueg C, Ponirakis A, Delong E, et al. Angiographic validation of the American College of Cardiology Foundation—the Society of Thoracic Surgeons Collaboration on the Comparative Effectiveness of Revascularization Strategies study. *Circ Cardiovasc Interv* 2014;7:11–8.