

Accepted Manuscript


Increasing feasibility and utility of ^{18}F -FDOPA PET for the management of glioma

Christopher Bell, Nicholas Dowson, Simon Puttick, Yaniv Gal, Paul Thomas, Mike Fay, Jye Smith, Stephen Rose

PII: S0969-8051(15)00093-1
DOI: doi: [10.1016/j.nucmedbio.2015.06.001](https://doi.org/10.1016/j.nucmedbio.2015.06.001)
Reference: NMB 7732

To appear in: *Nuclear Medicine and Biology*

Received date: 23 February 2015
Revised date: 27 May 2015
Accepted date: 3 June 2015



Please cite this article as: Bell Christopher, Dowson Nicholas, Puttick Simon, Gal Yaniv, Thomas Paul, Fay Mike, Smith Jye, Rose Stephen, Increasing feasibility and utility of ^{18}F -FDOPA PET for the management of glioma, *Nuclear Medicine and Biology* (2015), doi: [10.1016/j.nucmedbio.2015.06.001](https://doi.org/10.1016/j.nucmedbio.2015.06.001)

This is a PDF file of an unedited manuscript that has been accepted for publication. As a service to our customers we are providing this early version of the manuscript. The manuscript will undergo copyediting, typesetting, and review of the resulting proof before it is published in its final form. Please note that during the production process errors may be discovered which could affect the content, and all legal disclaimers that apply to the journal pertain.

Increasing feasibility and utility of ^{18}F -FDOPA PET for the management of glioma

Christopher Bell^{a,b}, Nicholas Dowson^a, Simon Puttick^c, Yaniv Gal^d, Paul Thomas^e, Mike Fay^{b,f,g}, Jye Smith^{b,g}, Stephen Rose^{a,*}

^a CSIRO Preventative Health Flagship, CSIRO Computational Informatics, The Australian e-Health Research Centre, Herston QLD 4029, Australia

^b The University of Queensland, School of Medicine, St Lucia, QLD 4072, Australia

^c Australian Institute for Bioengineering and Nanotechnology, The University of Queensland, St Lucia, QLD 4072, Australia

^d The University of Queensland, Centre for Medical Diagnostic Technologies in Queensland, St Lucia, QLD 4072, Australia

^e Department of Radiation Oncology, Royal Brisbane and Women's Hospital, Herston, QLD 4029, Australia

^f Genesis Cancer Care, Lake Macquarie Private Hospital, 36 Pacific Highway, Gateshead, NSW 2290, Australia

^g Specialised PET Services Queensland, Royal Brisbane and Women's Hospital, Herston, QLD 4029, Australia

Correspondence:

Assoc Prof Stephen Rose

CSIRO Computational Informatics

Royal Brisbane and Women's Hospital,

Brisbane 4029 Australia

Stephen.Rose@csiro.au

Telephone +61 7 32533620

Word count: ??? (Abstract), ??? (Text, Table and Figures) ???; 1 figures, 1
table

Keywords: Glioblastoma, infiltration, PET, ¹⁸F-FDOPA, glioma, dopamine

ACCEPTED MANUSCRIPT

Abstract

Introduction

Despite radical treatment therapies, glioma continues to carry with it a uniformly poor prognosis. Patients diagnosed with WHO grade IV glioma (glioblastomas; GBM) generally succumb within two years, even those with WHO Grade III anaplastic gliomas and WHO Grade II gliomas carry prognoses of 2-5 and 2 years, respectively. PET imaging with ^{18}F -FDOPA allows *in vivo* assessment of the metabolism of glioma relative to surrounding tissues. The high sensitivity of ^{18}F -DOPA imaging grants utility for a number of clinical applications.

Methods

A collection of published work about ^{18}F -FDOPA PET was made and a critical review was discussed and written.

Results

A number of research papers have been published demonstrating that in conjunction with MRI, ^{18}F -FDOPA PET provides greater sensitivity and specificity than these modalities in detection, grading, prognosis and validation of treatment success in both primary and recurrent gliomas. In further comparisons with ^{11}C -MET, ^{18}F -FLT, ^{18}F -FET and MRI, ^{18}F -FDOPA has shown similar or better efficacy. Recently synthesis cassettes have become available, making ^{18}F -FDOPA more accessible.

Conclusions

According to the available data, ^{18}F -FDOPA PET is a viable radiotracer for imaging and treatment planning of gliomas.

Advances in knowledge and implication for patient care

^{18}F -FDOPA PET appears to be a viable radiopharmaceutical for the diagnosis and treatment planning of gliomas cases, improving on that of MRI and ^{18}F -FDG PET.

ACCEPTED MANUSCRIPT

Introduction

The potential of L-3,4-Dihydroxy-6-[^{18}F]fluorophenylalanine (^{18}F -FDOPA) as a tool for managing glioma was first identified by Heiss et al. in 1996 [14], following a long history of use in Parkinson's Disease. In the light of recent improvements in tracer synthesis[1], and the likelihood of its increasingly widespread availability, a review of ^{18}F -FDOPA is necessary. This is also timely, as despite continuing advances in treatment regimes, the prognosis of glioblastoma multiforme (WHO Grade IV gliomas; GBM) remains poor [2]. While the median survival rate now exceeds 12 months, few patients live longer than two years [3-5].

While there is evidence that ^{18}F -FDOPA can provide additional information in detecting gliomas and planning treatment, it is not widely used in either the research or clinical setting.

One reason for this is the complex synthesis process involved. An automated electrophilic approach is available for radiotracer synthesis [6, 7], however difficulties with handling ^{18}F in gaseous form as well as a low radiotracer production yield [8, 9] means a two-step electrophilic approach remains the most common method for synthesis[10, 11]. While these limitations may lessen the interest in synthesizing this radiotracer, recent developments have seen the introduction of nucleophilic approaches [12, 13], which produce ^{18}F in liquid form. Given the complexity of electrophilic ^{18}F -FDOPA synthesis and the proven track record for ^{11}C -MET to provide sensitive and specific measurements of glioma volumes, research facilities may opt to investigate cases using ^{11}C -MET only. However the short half-life of ^{11}C means it generally needs to be produced on site. Despite this, the recent

availability of single-use synthesis cassettes for ^{18}F -FDOPA could make its use feasible in more centres.

Imaging is critical to the management of glioma for a number of reasons. Lower grade gliomas, while less aggressive, also have a poor prognosis with survival rates of between 2-5 years [14]. A significant factor in the management of low-grade tumours is the difficulty in predicting their transformation to a higher grade. A recent study showed that transformation of gliomas from low-grade to high-grade after recurrence can occur in 45-74% of cases, depending on the tumour subtype [15]. Recurrence is also of concern, as incidences subsequent to apparently complete regression can occur due to small colonies of residual cells that are capable of causing reemergence [16]. Recurrent lesions can result in extensive, ipsilateral or contralateral spread with severe symptoms and poor prognosis [17] and are often more aggressive than the initial primary lesion at the time of staging.

The biology of recurrent tumour can differ from de-novo glioma due to the selective effect that treatment imposes on the disease, resulting in a phenotypic shift to more aggressive infiltration [18]. Treatment also affects surrounding healthy tissue by ameliorating the some of the symptoms caused by bulk effects, but also by having an inflammatory and necrotic effect [19]. Combined with the differences in management, these factors alter the task of assessing the tumour whether for the purposes of characterising treatment response, planning or prognosis. For instance, in recurrent tumour, pseudo progression must be distinguished from active tumour [20], and assessing the response of the tumour can be problematic where regions of recurrence surround a large cavity [21]. In contrast for low grade gliomas the radiological findings form a minority of the score obtained during assessment [22],

or if planning the resection of high grade tumours using PET the margins of identifiably active tumour can be more critical than say overall dimension [23].

Positron emission tomography (PET) imaging utilizing metabolic radiotracers such as [^{11}C]methionine (^{11}C -MET), ^{18}F -Fluorodeoxyglucose (^{18}F -FDG) and ^{18}F -Fluoromisonidazole (^{18}F -FMISO) have been introduced into the pre-clinical, and to a lesser extent, the clinical setting. PET imaging has been shown to improve delineation of tumour volumes, as well as assist in grading of lesions and providing a prognosis, complementing information obtained through other modalities such as MRI [24-28]. An advantage of PET is that it directly examines an aspect of cellular metabolism that may be selected beforehand, while MRI is limited to identifying the physical effects of the tumour such as blood brain barrier breakdown or oedema. While such physical effects are useful they can be a less direct approach for inferring the location and progression of the tumour.

^{18}F -FDOPA is transported across the BBB by a number of amino acid transporters, which have been shown to be overexpressed in glioma [29] relative to background (healthy) tissue. In non-striatal tissue, ^{18}F -FDOPA is converted into either ^{18}F -Fluorodopamine by dopa carboxylase or the metabolite 3-O-methyl-6-fluoro-L-DOPA (3-OMFD) by catechol-O-methyl transferase. The kinetics of ^{18}F -FDOPA metabolism are similar to healthy tissue (see Fig. 4 in [30]), so it is likely the enhanced avidity of tumours arises primarily from the increase uptake (K_1) of the tracer.

The PET radiotracer, 6- ^{18}F fluoro-dihydroxy-l-phenylalanine (^{18}F -FDOPA) was first synthesised in the 1980's for the purpose of examining Parkinson's disease [31]. In 1996, a case study by Heiss *et al* [32] illustrated ^{18}F -FDOPA as a potential

diagnostic tool for glioma. Further multi-modal studies investigating the lesion were suggestive of a low-grade glioma, with high ^{11}C -MET uptake displayed within the same area. This unexpected, yet important finding was the first to describe the possibility that ^{18}F -FDOPA may provide complimentary information to other amino acid PET tracers, such as ^{11}C -MET and ^{18}F -tyrosine, in the assessment of gliomas.

The finding by Heiss *et al* sparked a great interest in ^{18}F -FDOPA. The literature suggests that this tracer may provide complimentary information to other diagnostic imaging. This paper provides an overview of the growing body of research focusing on the clinical applications of ^{18}F -FDOPA PET imaging for the management of glioma. In the light of recent improvements in tracer synthesis[1], the current literature supports the argument for the wider scale adoption of ^{18}F -FDOPA PET in clinical practice and for research purposes.

A comparison of ^{18}F -FDOPA PET with other modalities

Complimenting MRI with ^{18}F -FDOPA PET

Contrast Enhanced MRI is used extensively in the diagnosis and management of primary and recurrent glioma. The contrast enhancing regions of MRI reveal regions where the blood brain barrier (BBB) is disrupted. However, the regions of infiltrating tumour are known to extend well beyond the margins of BBB disruption [33]. Although oedema is visible on a number of MRI sequences by the variations in intensity that it induces, this does not directly identify regions of active tumour [33]. There is growing evidence that information gained from other modalities may compliment that obtainable from MRI. This is especially true in low-grade and non-enhancing glioma, where blood brain barrier (BBB) breakdown does not necessarily

occur. An advantage of amino acid radiotracers such as ^{18}F -FDOPA is that they do not require a perturbed BBB, as transport of the tracer across the BBB is facilitated by amino acid transporters. Moreover, PET tracers allow particular aspects of cellular activity to be imaged more directly, as opposed to relying on the physical changes tumour activity induces. There is also a concern in recurrent glioma, where MRI alone cannot always discriminate enhancing tumour from treatment-induced parenchymal injury, so called post-treatment radiation effect [34, 35]. Post-treatment radiation effects include pseudoprogression and radiation necrosis, believed to cause false declaration of treatment failure in up to 50% of cases [36-39]. Although the ability of MRI to distinguish between tumour and other tissue biology has been of significant interest [40-42], PET imaging may provide clinically relevant metabolic information that is not otherwise obtainable. For example, ^{18}F -FDOPA and MR images of a glioma patient are shown in Figure 1. Although the tumour volume corresponds closely to that of the MRI, the high ^{18}F -FDOPA uptake region extends beyond the contrast enhanced MRI region, potentially supplying a better estimate of the extent of tumour infiltration.

In a study into ^{18}F -FDOPA PET/MRI in primary and recurrent glioma, Ledezma *et al* [43] illustrated that the combination of ^{18}F -FDOPA PET and MRI was accurate at detecting lesions. An interesting finding in this study was that ^{18}F -FDOPA was unable to detect the glioma volume in four cases, whereas MRI was. The authors provide an explanation for one of these cases: following the scan the tumour shrank, possibly indicating that although tumour still remained, metabolic activity had been temporarily halted by treatment. Although MRI and ^{18}F -FDOPA PET information was complementary, ^{18}F -FDOPA proved to be a more sensitive modality by itself than

MRI, even with the false negative cases. A similar finding was made by Karunanithi *et al* [44] in a study comparing the diagnostic accuracy of contrast-enhanced MRI and ^{18}F -FDOPA in recurrent cases of glioma. ^{18}F -FDOPA PET detection was correct in 34 patients, with one false positive. MRI findings on the other hand, were only accurate in 28 patients, with false positives in five and false negatives in two. For the false positive case of ^{18}F -FDOPA, the authors suggest that tracer uptake could be due to the high levels of amino acid transport into microphages that are activated after surgery, or leakage of ^{18}F -FDOPA due to BBB breakdown caused by treatment. In a study by Kosztyla [45], locations of tumour recurrence were compared to the gross tumour volume (GTV) delineated on pre-treatment ^{18}F -FDOPA and MRI images. Firstly, this study showed that inter-observer agreement between ^{18}F -FDOPA PET and MRI delineations were not significantly different, although ^{18}F -FDOPA GTVs were larger than that of MRI. Secondly, sites of tumour recurrence existed outside both MRI and ^{18}F -FDOPA PET GTVs in all but one case. These results suggest that, although ^{18}F -FDOPA PET may provide additional anatomically focal information compared to MRI, it does not imply an improvement in treatment would occur if ^{18}F -FDOPA PET alone is used for radiation therapy planning, as sites of future recurrence may exist outside the dose map.

Hence, while MRI is currently implemented in the diagnosis and treatment of glioma, these studies support the potential of ^{18}F -FDOPA as a modality that is complementary to MRI. Specifically, ^{18}F -FDOPA could have utility where MRI findings are negative in primary/recurrent tumours or inconclusive in recurrent tumours.

The use of ^{18}F -FDOPA to complement MRI is made more feasible with the recent introduction of PET/MR imaging, where both PET and MR images are

acquired simultaneously, providing spatially and temporally registered images. PET/MRI has shown potential in both the clinical and pre-clinical setting for investigating areas of glioma treatment such as new drug development[46].

<<Location of Figure 1 >>

Comparison with the PET tracers ^{11}C -MET, ^{18}F -FDG and ^{18}F -FLT

Primary glioma

While the modality most widely used in treatment of gliomas is MRI, positron emission tomography (PET) is becoming more common, with the introduction of new radiotracers to compliment information gained from MRI. In the clinical environment, the most widely used radiotracer for imaging glioma is ^{18}F -Fluorodeoxyglucose (^{18}F -FDG) and its use in glioma cases was the first oncological application of PET [47-50]. However, some studies have highlighted the diagnostic limitations of this tracer [51, 52]. Specifically, the high metabolic rate of normal brain tissue results in a high background uptake of the tracer. This increase in background activity limits the contrast between normal brain tissue and lesions, making it difficult to distinguish between normal tissue and possible lesions. This is of special concern in low-grade gliomas, where glucose metabolism has been shown to be similar to that of normal tissue [53, 54]. In addition, inflammatory lesions such as those from infection also have an elevated glucose metabolism, leading to false positives and incorrect diagnosis [55]. To overcome these limitations, studies have been performed to investigate ^{18}F -FDOPA as a potential alternative to ^{18}F -FDG in primary and recurrent gliomas.

Chen *et al* [53] illustrated the potential for ^{18}F -FDOPA to effectively image primary gliomas as part of a wider study that also included clinically stable and recurrent patients. ^{18}F -FDOPA was significantly more specific and sensitive than ^{18}F -FDG in primary lesions, demonstrating the diagnostic utility of this tracer. In a similar study, Tripathi *et al* [54] investigated amino acid metabolism, glucose metabolism and proliferation using ^{18}F -FDOPA, ^{18}F -FDG and ^{18}F -FLT, respectively. Although this cohort contained only three patients with primary glioma, ^{18}F -FDOPA uptake was positive in all cases, whereas ^{18}F -FLT and ^{18}F -FDG uptake was only observed in one. Jora *et al* [56] and Jacob *et al* [57] both performed comparative investigations into the uptake of ^{18}F -FDOPA, ^{13}N -Ammonia, ^{18}F -FDG and MRI in low and high-grade primary and recurrent gliomas. Both studies reported that ^{18}F -FDOPA was significantly more reliable in the detection of primary gliomas than ^{13}N -Ammonia or ^{18}F -FDG.

The above studies demonstrate ^{18}F -FDOPA's utility to detect primary low and high-grade gliomas and as a potentially superior alternative to ^{18}F -FDG and ^{18}F -FLT.

In addition to ^{18}F -FDOPA, other amino acid radiotracers have been shown to detect glioma [58], including the ^{18}F -FDOPA metabolite, 3-O-methyl-6- ^{18}F -fluoro-L-dopa (OMFD) [59]. A frequently utilized tracer in this research field is ^{11}C -MET, which has been investigated extensively [5, 60] and is known to be more effective than ^{11}C -glucose [61] and CT [62, 63]. However, ^{11}C -MET has the drawback of a short half-life (20.4 minutes), limiting its availability to centers that are in close proximity to a cyclotron. The 110 minute half-life of ^{18}F radiotracers make them viable in a wider variety of scenarios. Becherer *et al* [64] investigated this potential in 20 patients, 18 of which were diagnosed with primary glioma. Results showed that the standard

uptake values (SUVs) of ^{18}F -FDOPA and ^{11}C -MET 20 minutes post injection showed a significant correlation ($P < 0.05$) and visual inspection revealed almost identical patterns of spatial uptake. Since both tracers are taken up via amino acid channels, this study suggests that there is a significant potential for ^{18}F -FDOPA imaging of gliomas where ^{11}C -MET may be difficult to obtain due to its short half-life.

Recurrent glioma

While ^{18}F -FDG is used extensively in the diagnosis and treatment of both primary and recurrent gliomas, it is also used in conjunction with MRI to detect recurrent disease, which is frequent in glioma. Detection of low-grade gliomas using ^{18}F -FDG has limitations due to both the low contrast ratio between tumour and normal tissues, and uptake in inflammatory lesions [53-55]. Not only is this an issue for low-grade recurrent gliomas [52], but studies suggest that this is also the case in high-grade recurrent gliomas [50, 65].

As with their findings for primary gliomas, Chen *et al* [53] and Tripathi *et al* [54] demonstrated that ^{18}F -FDOPA also outperforms ^{18}F -FDG in the detection of recurrence. In similar studies, Jacob *et al* [57] and Jora *et al* [56] showed that the performance of ^{18}F -FDOPA was superior compared to that of ^{13}N -Ammonia and ^{18}F -FDG.

Karunanithi *et al* [66] investigated using ^{18}F -FDOPA uptake to detect glioma recurrence. In a comparison to ^{18}F -FDG, ^{18}F -FDOPA gave better results. For 28 patients, 21 with recurrent disease, ^{18}F -FDOPA was able to detect all recurrences, with only one false positive occurrence, while ^{18}F -FDG was only able to detect 10 of the 21 recurrences, with no false positives. Notably, the only recurrences detectable

by ^{18}F -FDG were grade IV tumours (10 out of 11 recurrences), possibly due to the high glycolysis known to occur in this grade of glioma.

PET kinetic compartment modeling can be used to analyse the temporal behavior of tracers in the body, and has been investigated previously in radiotracers such as ^{18}F -FDOPA [30]. Kratochwil *et al* [67] also used a kinetic analysis to compare the uptake of ^{18}F -FDOPA and ^{18}F -FET in 16 high and low-grade recurrent gliomas. While results showed that ^{18}F -FDOPA was able to detect all 16 lesions, ^{18}F -FET only detected 15, failing to identify one grade II astrocytoma. This study suggests that both radiotracers used in conjunction with kinetic modeling have potential to assist in diagnosis of gliomas, though ^{18}F -FDOPA may be more effective in tumours distant from the striatum.

Comparison with SPECT imaging

In addition to MR and PET imaging, SPECT has been investigated for glioma grading [68-70], predicting survival [71] and identifying recurrence [72-74]. In a study by Karunanithi *et al* [75], tumour recurrence was assessed by both ^{18}F -FDOPA PET and $^{99\text{m}}\text{Tc}$ -GH SPECT/CT in 30 patients previously treated for histopathologically proven glioma. Of the 30 patients, 22 were positive for recurrence. ^{18}F -FDOPA was able to correctly identify recurrence in all cases, with only a single false positive. In contrast, only 19 of the 22 tumours were identifiable using SPECT imaging, with an additional 3 false positives cases occurring. While ^{18}F -FDOPA better detected glioma recurrence, the authors note that since SPECT imaging is a more economical modality, $^{99\text{m}}\text{Tc}$ -GH SPECT/CT could be a viable alternative for assessing glioma recurrences in cases where cost is of concern.

Applications of ^{18}F -FDOPA

Using ^{18}F -FDOPA to predict survival

In addition to ^{18}F -FDOPA's utility in detecting primary and recurrent tumours, the ability to predict survival would also be of substantial use. Currently, several factors, such as Karnovsky performance status (KPS), age, tumour size, extent of surgery and tumour grade and histology are used in predicting patient survival [76, 77]. Previous studies have shown that ^{18}F -FDG is also effective in predicting survival in primary and recurrent glioma patients [78, 79]. However, the low specificity of ^{18}F -FDG PET is a limitation. Karunanithi *et al* [80] investigated predictability of survival using ^{18}F -FDOPA in 33 patients with suspected recurrence. To accomplish this, positive ^{18}F -FDOPA uptake and ^{18}F -FDOPA indices of SUV_{max} , tumour to normal tissue ratio (T/N), tumour to striata (T/S), tumour to white matter (T/W) and tumour to cerebellum (T/C) were calculated from ^{18}F -FDOPA PET images. Tumour volume size was also calculated from MRI. Univariate analysis showed that several factors predict survival with significance, including: positive uptake ($P=0.007$), SUV_{max} ($P=0.001$), T/N ($P=0.001$), T/S ($P=0.005$), T/W ($P=0.0004$) and T/C ($P=0.003$). In multivariate analysis, only MRI tumour size ($P=0.002$) and T/N ($P=0.005$) were found to be independent predictors of survival. Receiver-operating characteristic ROC analysis was performed, with T/N greater than 1.51 and MRI tumour size greater than 2.5 cm indicative of a poorer predicted survival. This study suggests that ^{18}F -FDOPA is predictive of patient survival in cases of recurrent glioma. Dowson *et al* [81] further illustrated the prognostic capability of ^{18}F -FDOPA by showing that the uptake changes in the most

treatment resistant region of tumour post-treatment are predictive of patient survival.

Using ^{18}F -FDOPA to predict survival

In addition to ^{18}F -FDOPA's utility in detecting primary and recurrent tumours, the ability to predict survival would also be of substantial use. Currently, several factors, such as Karnovsky performance status (KPS), age, tumour size, extent of surgery and tumour grade and histology are used in predicting patient survival [76, 77]. Previous studies have shown that ^{18}F -FDG is also effective in predicting survival in primary and recurrent glioma patients [78, 79]. However, the low specificity of ^{18}F -FDG PET is a limitation. Karunanithi *et al* [80] investigated predictability of survival using ^{18}F -FDOPA in 33 patients with suspected recurrence. To accomplish this, positive ^{18}F -FDOPA uptake and ^{18}F -FDOPA indices of SUV_{max} , tumour to normal tissue ratio (T/N), tumour to striata (T/S), tumour to white matter (T/W) and tumour to cerebellum (T/C) were calculated from ^{18}F -FDOPA PET images. Tumour volume size was also calculated from MRI. Univariate analysis showed that several factors predict survival with significance, including: positive uptake ($P=0.007$), SUV_{max} ($P=0.001$), T/N ($P=0.001$), T/S ($P=0.005$), T/W ($P=0.0004$) and T/C ($P=0.003$). In multivariate analysis, only MRI tumour size ($P=0.002$) and T/N ($P=0.005$) were found to be independent predictors of survival. Receiver-operating characteristic ROC analysis was performed, with T/N greater than 1.51 and MRI tumour size greater than 2.5 cm indicative of a poorer predicted survival. This study suggests that ^{18}F -FDOPA is predictive of patient survival in cases of recurrent glioma. Dowson *et al* [81] further illustrated the prognostic capability of ^{18}F -FDOPA by showing that the uptake changes in the most

treatment resistant region of tumour post-treatment are predictive of patient survival.

Using ^{18}F -FDOPA to grade gliomas

Tumour grading using *in vivo* imaging such as ^{18}F -FDOPA PET is also of significant interest. The current accepted method for tumour grading involves either surgical biopsy or resection (if possible), after which tumour vascularity is assessed pathologically [82]. However, there are significant limitations to performing biopsies alone. Firstly, biopsies are not always possible due to the tumour location or patient condition. Secondly, there is a possibility that the tumour is underestimated or misrepresented by the small sample of tissue acquired, as more aggressive cells may exist in other areas of the tumour volume. [83]. Finally, additional neurological damage and morbidity can occur due to the invasiveness of the procedure [84]. Both ^{18}F -FMISO [24, 25, 85] and ^{18}F -FDG [65] have also been investigated for glioma grading.

As part of their study, Chen *et al* [53] found no ability for ^{18}F -FDOPA to be able to differentiate between high-grade and low-grade gliomas ($P=0.40$). Fueger *et al* [86] investigated the potential for ^{18}F -FDOPA to predict glioma grade in 59 patients with newly diagnosed glioma. ^{18}F -FDOPA SUV_{max} corresponded significantly with glioma grade, with correlation values $P=0.044$, $P=0.007$ and $P=0.010$ representing grade II vs. grade III, grade II vs. grade IV and grade III vs. grade IV, respectively. However, this correlation was significantly reduced in recurrent gliomas, with only grade II vs. grade III and grade II vs. grade IV reaching statistical significance. These results suggest that there is a potential for ^{18}F -FDOPA to be used

in grading newly diagnosed gliomas. However, when considering recurrent gliomas this may not be possible. In agreement with Fueger *et al*, Pafundi *et al* [87] also found that ^{18}F -FDOPA SUV_{max} strongly correlated with tumour grade in ten patients ($P=0.0005$), although they excluded oligodendrogliomas, due to an asymptomatic uptake observed within this tumour type. Nioche *et al* [88] also investigated ^{18}F -FDOPA for potential glioma grading using both static and dynamic PET acquisitions. Results from this study concurred with that of Fueger *et al*, with the authors able to discriminate between high and low grade primary gliomas using static ^{18}F -FDOPA PET imaging. However, the authors also found that high-grade and low-grade gliomas could also be discriminated in recurrent gliomas. Results improved, although not significantly, when kinetic factors, extracted from dynamic imaging, were used instead of static imaging.

Kratochwil *et al* [67] compared the uptake of ^{18}F -FDOPA and ^{18}F -FET in 16 high and low-grade recurrent gliomas. ^{18}F -FDOPA uptake peaked earlier than ^{18}F -FET in both high and low-grade and also provided a much higher tumour-to-blood (T/B) ratio. ^{18}F -FDOPA uptake peaked after 8 minutes in high grade and 10 minutes in low grade, while ^{18}F -FET uptake peaked at 9 minutes and 40 minutes. The additional time between uptake peaks of high and low grade glioma in ^{18}F -FET suggests that dynamic scanning may allow the discrimination between tumour grades. However, ^{18}F -FDOPA lacks a significant temporal gap between high and low tumour grades, potentially ruling out its use for this purpose.

From these studies, there appears to be some evidence that ^{18}F -FDOPA can assist in tumour grading, though further research is needed before conclusions can be made.

Using ^{18}F -FDOPA for neurosurgical and radiotherapy planning

For planning of both resection and radiation therapy, MRI is widely accepted as the gold standard, with T_1 -contrast-enhanced (T_1 -CE) MRI and T_2 /FLAIR imaging sequences utilized. However, ongoing research has shown that MRI has limitations, due to lack of contrast enhancement in tumoural regions [89], high contrast enhancement in benign tumours and lesions [89] and a lack of discriminability between malignant tissue and oedema on T_2 /FLAIR imaging [90, 91]. The inclusion of an additional imaging modality to compliment information available from MRI has the potential to assist in neurosurgery and radiation therapy planning, improving patient outcomes. Pafundi *et al* [87] investigated this potential in ten patients with diagnosed primary or recurrent glioma. ^{18}F -FDOPA and MR imaging was performed to identify areas of tracer uptake and contrast enhancement. Biopsies were performed for all patients in regions of both MRI and ^{18}F -FDOPA concordance and discordance, resulting in a total of 23 tissue samples. Pathological results found 22 of the 23 samples were positive for malignancies. 13 of 16 high-grade biopsy specimens were obtained from regions of high ^{18}F -FDOPA uptake, whereas only 6 of 16 of these regions showed enhancement of MRI. Three samples were obtained from areas where there was no high ^{18}F -FDOPA uptake or contrast enhancement. Three of the six low-grade specimens were taken from areas of high ^{18}F -FDOPA uptake, whereas contrast enhancement was negative in all six cases. These findings have two important implications. Firstly, ^{18}F -FDOPA has the potential to identify areas of tumour infiltration that is not necessarily evident on MRI, necessitating an additional modality to compliment MRI findings. Secondly, infiltrative tumour tissue can also exist outside regions of both ^{18}F -FDOPA uptake and MRI contrast enhancement.

For the treatment of high-grade gliomas with radiotherapy, the margin added to the gross tumour volume, defined on the contrast enhancing MRI, is 1-2cm to account both for occult infiltration and movement between fractions. In the study by Pafundi *et al* [76], two patients exhibited high tracer uptake outside the planned tumour volume, suggesting that a 1-2cm expansion does not fully account for infiltration in all cases.

Using ^{18}F -FDOPA to assess treatment response

PET imaging is also being investigated as a method for identifying tumour response to new treatments. It is well known that vascular endothelial growth factors (VEGF) play a crucial role in modulating angiogenesis and tumorigenesis, with hypoxia being able to stimulate VEGF secretion through activation of hypoxia-inducible transcription factors (HIFs) [92]. Since the prognosis of glioma is so poor, anti-angiogenic drugs that target VEGF have been suggested and introduced into the treatment regime [2, 93-100]. Bevacizumab is one such anti-angiogenic treatment, designed to inhibit vascular growth following radiotherapy. Although this treatment has already been introduced into the clinical environment, evaluation of its effectiveness is still of significance.

In a study by Harris *et al* [101], bevacizumab treatment was evaluated in 24 patients with recurrent gliomas using serially acquired ^{18}F -FDOPA PET, ^{18}F -FLT PET and MR imaging. Using voxel-wise changes between acquisitions, parametric response maps (PRMs) were generated for both ^{18}F -FDOPA and ^{18}F -FLT PET tracers as well as MRI. Scans were acquired before and twice after administration of bevacizumab treatment. Results from the study showed that an increase in tracer

uptake volume in PRMs was associated with a shortened progression free survival. However, only a weak correlation was found between PRM and overall survival, suggesting the need for further research.

¹⁸F-FDOPA imaging could influence treatment pathways

While it is important to assess the ability for new imaging techniques to assist in patient diagnosis and treatment, advances in research are futile if physicians do not adopt them. In a study by Walter *et al* [102], the frequency with which ¹⁸F-FDOPA altered the treatment regime was assessed. For 58 patients, pre-PET, early post-PET and late post-PET surveys were conducted. Survey statistics showed that a considerable percentage of treatment paths were altered when ¹⁸F-FDOPA imaging was considered. It was shown that after considering ¹⁸F-FDOPA PET imaging, clinical suspicion of tumour recurrence decreased in 17%, remained the same in 50% and increase in 33% of cases. In addition, survey results showed that ¹⁸F-FDOPA imaging altered the intended treatment path of 41% of patients, i.e., treatment approaches altered from “wait and see” to invasive treatments and *vice-versa*. Late post-PET surveys showed that these changes to the intended treatment path were carried out in 75% of cases. This illustrated that ¹⁸F-FDOPA has the potential to have a substantial effect on treatment course, with implementation within the clinical environment having the potential to assist in patient treatment regimes.

¹⁸F-FDOPA as a tool for cross-validation with new modalities

Recently, ¹⁸F-FDOPA PET imaging has been used to evaluate and validate new techniques and research. Numerous studies have investigated the potential for MR imaging indices, such as apparent diffusion coefficient (ADC), for pre-operative

tumour grading and treatment planning [103-107]. However, findings from these studies have been mixed. Rose *et al* [108] investigated the correlation between ^{18}F -FDOPA standard uptake value ratio (SUVR) and minimum ADC volumes to attempt to understand the relationship. Results from the study showed that there was little relationship between the two modalities, supporting the idea that areas of low ADC may in fact be related to compression from oedema or even ischemia.

Bell *et al* [109] used ^{18}F -FDOPA PET imaging to validate a method for generating a probability map and describing tumour cell infiltration, using MRI indices and whole brain tractography. They were able to show that identification of tumour boundaries was more accurate when delineations took into account progression of infiltrative tumour cells along white matter tracts.

^{18}F -FDOPA in detection of brain metastases

Additionally, two studies have been performed to investigate ^{18}F -FDOPA PET imaging for discrimination of brain metastasis from post-treatment effects. Using ^{18}F -FDOPA PET, Lizarraga *et al* [110] studied 32 patients suspected of metastatic progression to investigate whether ^{18}F -FDOPA PET could distinguish between metastases and radiation injury. Using visual interpretation, a sensitivity and specificity of 81.3% and 84.3% respectively was achieved across the cohort. Similarly, Cicone *et al* [111] investigated ^{18}F -FDOPA PET for differentiating radiation necrosis from tumour progression in 42 patients with suspected brain metastatic progression. A semi quantitative PET measure of maximum lesion to maximum background uptake ratio was found to be the best discriminator, with a ratio threshold of 1.59 yielding a sensitivity and specificity of 90% and 92.3% respectively.

These two studies suggest that ^{18}F -FDOPA may also be used to discriminate metastatic tumour progression from post-treatment injuries such as radiation necrosis in previously treated patients.

Limitations of ^{18}F -FDOPA

In addition to the limitations imposed by tracer synthesis, the effect of treatment procedures on ^{18}F -FDOPA uptake has also been investigated. As part of their study, Ledezma *et al* [43] highlighted mild ^{18}F -FDOPA activity along the tumour resection boundary in several cases studied. More recently, Chiaravalloti *et al* [112] found a relationship between ^{18}F -FDOPA uptake in patients with suspected tumour recurrence and the delay in PET imaging post radiotherapy. Results showed that uptake decreased with increasing delay over months, suggesting that a high uptake soon after radiotherapy may be treatment related, and as such, care should be taken when assessing patients with suspected tumour recurrence using ^{18}F -FDOPA PET.

Finally, ^{18}F -FDOPA is an amino acid tracer that targets dopamine receptors in the brain, resulting in high uptake within the striatum. As such, care should be taken when assessing tumours in near proximity to the striatum, as high uptake in this area may blur the understanding of the tumour boundary. Distinguishing tumour from healthy tissue in these areas probably entails performing a kinetic analysis of the data, and even then partial volume effects will result in some residual imprecision in the definition of the boundary.

Conclusion

The discovery that ^{18}F -FDOPA PET can localize gliomas instigated a number of recent research studies. The literature has demonstrated ^{18}F -FDOPA PET's efficacy for diagnosis, prognosis and treatment evaluation of patients with both primary and recurrent low and high-grade glioma, especially when complimenting MRI. As such, ^{18}F -FDOPA has shown its potential to alter treatment regimes in a large fraction of glioma cases. Despite its potential, ^{18}F -FDOPA is not widely used in either the research or clinical setting.

Currently, the complex production of ^{18}F -FDOPA by means of electrophilic synthesis requires significant equipment and knowledge. Recently, single-use cassettes for the nucleophilic synthesis ^{18}F -FDOPA have become available. The more practical synthesis of ^{18}F -FDOPA, could potentially enable its more widespread use, especially given the more limited utility of ^{18}F -FDG and the requirement of an onsite cyclotron for ^{11}C -MET.

Limitations of ^{18}F -FDOPA also include its high uptake by the basal ganglia. While this is a key feature in its use within the management of neuro-degenerate diseases, the diagnostic ability of the tracer is limited for tumours adjacent to this region. Hence it is likely to remain complimentary to MRI, the standard modality for imaging glioma patients.

Acknowledgements

The authors would like to acknowledge funding from the National Health and Medical Research Council of Australia (Project grants 631567 and APP1045984) and Cancer Council Queensland.

Conflict of interest

The authors declare no conflicts of interest.

ACCEPTED MANUSCRIPT

Bibliography

1. Pretze, M., C. Wangler, and B. Wangler, *6-[18F]fluoro-L-DOPA: a well-established neurotracer with expanding application spectrum and strongly improved radiosyntheses*. Biomed Res Int, 2014. **2014**: p. 674063.
2. Kim, B., et al., *Treatment of recurrent high grade gliomas with hypofractionated stereotactic image-guided helical tomotherapy*. Clin Neurol Neurosurg, 2011. **113**(6): p. 509-512.
3. Buckner, J.C., *Factors influencing survival in high-grade gliomas*. Semin Oncol, 2003. **30**(6 Suppl 19): p. 10-14.
4. Curran Jr, W.J., et al., *Recursive partitioning analysis of prognostic factors in three Radiation Therapy Oncology Group malignant glioma trials*. J Natl Cancer Inst, 1993. **85**(9): p. 704-710.
5. DeAngelis, L.M., *Brain tumors*. N Engl J Med, 2001. **344**(2): p. 114-123.
6. Kao, C.-H.K., et al., *GMP production of [18F]FDOPA and issues concerning its quality analyses as in USP "Fluorodopa F 18 Injection"*. Annals of nuclear medicine, 2011. **25**(5): p. 309-16.
7. Vries, E.F.J.D., et al., *Fully automated synthesis module for the high yield one-pot preparation of 6-[18F]-fluoro-L-DOPA*. 1999. **51**.
8. Behnam Azad, B., R. Chirakal, and G.J. Schrobilgen, *Trifluoromethanesulfonic acid, an alternative solvent medium for the direct electrophilic fluorination of DOPA: new syntheses of 6-[18F]fluoro-L-DOPA and 6-[18F]fluoro-D-DOPA*. Journal of Labelled Compounds and Radiopharmaceuticals, 2007. **50**(14): p. 1236-1242.
9. Forsback, S., et al., *Electrophilic synthesis of 6-[18F]fluoro-L-DOPA using post-target produced [18F]F₂*. Radiochimica Acta, 2008. **96**(12): p. 845-848.
10. Dolle, F. and S. Demphel, *6-[18F]Fluoro-L-DOPA by radiofluorodestannylation: a short and simple synthesis of a new labelling precursor*. Journal of Labelled Compounds, 1998.
11. Namavari, M., et al., *Regioselective radiofluorodestannylation with [18F]F₂ and [18F]CH₃COOF: a high yield synthesis of 6-[18F]Fluoro-L-dopa*. Int J Rad Appl Instrum A, 1992. **43**(8): p. 989-996.
12. Lemaire, C., et al., *Highly Enantioselective Synthesis of No-Carrier-Added 6-[18F]Fluoro-L-dopa by Chiral Phase-Transfer Alkylation*. European Journal of Organic Chemistry, 2004. **2004**(13): p. 2899-2904.
13. Wagner, F.M., J. Ermert, and H.H. Coenen, *Three-step, "one-pot" radiosynthesis of 6-fluoro-3,4-dihydroxy-L-phenylalanine by isotopic exchange*. Journal of nuclear medicine : official publication, Society of Nuclear Medicine, 2009. **50**(10): p. 1724-9.
14. Louis, D.N., et al., *The 2007 WHO classification of tumours of the central nervous system*. Acta Neuropathol, 2007. **114**(2): p. 97-109.
15. Jaeckle, K.A., et al., *Transformation of low grade glioma and correlation with outcome: an NCCTG database analysis*. Journal of neuro-oncology, 2011. **104**(1): p. 253-9.
16. Kaye, A.H. and E.R. Laws, Jr., *Brain Tumours: An Encyclopedic Approach*. 2001, Churchill Livingstone: Edinburgh, Scotland. p. 447-463.

17. Muller, W., D. Afra, and R. Schroder, *Supratentorial recurrences of gliomas. Morphological studies in relation to time intervals with astrocytomas*. Acta Neurochir (Wien), 1977. **37**(1-2): p. 75-91.
18. de Groot, J.F., et al., *Tumor invasion after treatment of glioblastoma with bevacizumab: radiographic and pathologic correlation in humans and mice*. Neuro Oncol, 2010. **12**(3): p. 233-42.
19. Kumar, A.J., et al., *Malignant gliomas: MR imaging spectrum of radiation therapy- and chemotherapy-induced necrosis of the brain after treatment*. Radiology, 2000. **217**(2): p. 377-84.
20. Brandsma, D., et al., *Clinical features, mechanisms, and management of pseudoprogression in malignant gliomas*. Lancet Oncol, 2008. **9**(5): p. 453-61.
21. Wen, P.Y., et al., *Updated response assessment criteria for high-grade gliomas: response assessment in neuro-oncology working group*. J Clin Oncol, 2010. **28**(11): p. 1963-72.
22. Pouratian, N. and D. Schiff, *Management of low-grade glioma*. Curr Neurol Neurosci Rep, 2010. **10**(3): p. 224-31.
23. Pirotte, B.J., et al., *Positron emission tomography-guided volumetric resection of supratentorial high-grade gliomas: a survival analysis in 66 consecutive patients*. Neurosurgery, 2009. **64**(3): p. 471-81; discussion 481.
24. Cher, L.M., et al., *Correlation of hypoxic cell fraction and angiogenesis with glucose metabolic rate in gliomas using 18F-fluoromisonidazole, 18F-FDG PET, and immunohistochemical studies*. J Nucl Med, 2006. **47**(3): p. 410-418.
25. Hirata, K., et al., *(1)(8)F-Fluoromisonidazole positron emission tomography may differentiate glioblastoma multiforme from less malignant gliomas*. Eur J Nucl Med Mol Imaging, 2012. **39**(5): p. 760-770.
26. Narita, T., et al., *Reoxygenation of glioblastoma multiforme treated with fractionated radiotherapy concomitant with temozolomide: changes defined by 18F-fluoromisonidazole positron emission tomography: two case reports*. Jpn J Clin Oncol, 2012. **42**(2): p. 120-123.
27. Spence, A.M., et al., *Regional hypoxia in glioblastoma multiforme quantified with [18F]fluoromisonidazole positron emission tomography before radiotherapy: correlation with time to progression and survival*. Clin Cancer Res, 2008. **14**(9): p. 2623-2630.
28. Valable, S., et al., *Complementary information from magnetic resonance imaging and (18)F-fluoromisonidazole positron emission tomography in the assessment of the response to an antiangiogenic treatment in a rat brain tumor model*. Nucl Med Biol, 2011. **38**(6): p. 781-793.
29. Youland, R.S., et al., *The role of LAT1 in (18)F-DOPA uptake in malignant gliomas*. J Neurooncol, 2013. **111**(1): p. 11-8.
30. Schiepers, C., et al., *18F-FDOPA kinetics in brain tumors*. J Nucl Med, 2007. **48**(10): p. 1651-1661.
31. Wahl, L. and C. Nahmias, *Modeling of fluorine-18-6-fluoro-L-Dopa in humans*. J Nucl Med, 1996. **37**(3): p. 432-437.
32. Heiss, W.D., et al., *F-Dopa as an amino acid tracer to detect brain tumors*. J Nucl Med, 1996. **37**(7): p. 1180-1182.

33. Chan, J.L., et al., *Survival and failure patterns of high-grade gliomas after three-dimensional conformal radiotherapy*. J Clin Oncol, 2002. **20**(6): p. 1635-1642.
34. Doooms, G.C., et al., *Brain radiation lesions: MR imaging*. Radiology, 1986. **158**(1): p. 149-155.
35. van Dellen, J.R. and A. Danziger, *Failure of computerized tomography to differentiate between radiation necrosis and cerebral tumour*. S Afr Med J, 1978. **53**(5): p. 171-172.
36. Brandes, A.A., et al., *MGMT promoter methylation status can predict the incidence and outcome of pseudoprogression after concomitant radiochemotherapy in newly diagnosed glioblastoma patients*. J Clin Oncol, 2008. **26**(13): p. 2192-2197.
37. Brandsma, D., et al., *Clinical features, mechanisms, and management of pseudoprogression in malignant gliomas*. Lancet Oncol, 2008. **9**(5): p. 453-461.
38. Brandsma, D. and M.J. van den Bent, *Pseudoprogression and pseudoresponse in the treatment of gliomas*. Curr Opin Neurol, 2009. **22**(6): p. 633-638.
39. Clarke, J.L. and S. Chang, *Pseudoprogression and pseudoresponse: challenges in brain tumor imaging*. Curr Neurol Neurosci Rep, 2009. **9**(3): p. 241-246.
40. Hu, L.S., et al., *Reevaluating the imaging definition of tumor progression: perfusion MRI quantifies recurrent glioblastoma tumor fraction, pseudoprogression, and radiation necrosis to predict survival*. Neuro Oncol, 2012. **14**(7): p. 919-930.
41. Mullins, M.E., et al., *Radiation necrosis versus glioma recurrence: conventional MR imaging clues to diagnosis*. AJNR Am J Neuroradiol, 2005. **26**(8): p. 1967-1972.
42. Reddy, K., D. Westerly, and C. Chen, *MRI patterns of T1 enhancing radiation necrosis versus tumour recurrence in high-grade gliomas*. J Med Imaging Radiat Oncol, 2013. **57**(3): p. 349-355.
43. Ledezma, C.J., et al., *18F-FDOPA PET/MRI fusion in patients with primary/recurrent gliomas: initial experience*. Eur J Radiol, 2009. **71**(2): p. 242-8.
44. Karunanithi, S., et al., *Comparative diagnostic accuracy of contrast-enhanced MRI and (18)F-FDOPA PET-CT in recurrent glioma*. Eur Radiol, 2013. **23**(9): p. 2628-2635.
45. Kosztyla, R., et al., *Patterns of Failure Obtained From Magnetic Resonance Imaging and 18 F-FDOPA Positron Emission Tomography Delineations From Multiple Observers*. J Journal of Radiation, 2013.
46. Puttick, S., et al., *PET, MRI, and simultaneous PET/MRI in the development of diagnostic and therapeutic strategies for glioma*. Drug Discov Today, 2015. **20**(3): p. 306-317.
47. Di Chiro, G., et al., *Cerebral necrosis after radiotherapy and/or intraarterial chemotherapy for brain tumors: PET and neuropathologic studies*. AJR Am J Roentgenol, 1988. **150**(1): p. 189-197.
48. Doyle, W.K., et al., *Differentiation of cerebral radiation necrosis from tumor recurrence by [18F]FDG and 82Rb positron emission tomography*. J Comput Assist Tomogr, 1987. **11**(4): p. 563-570.

49. Patronas, N.J., et al., *Work in progress: [18F] fluorodeoxyglucose and positron emission tomography in the evaluation of radiation necrosis of the brain*. Radiology, 1982. **144**(4): p. 885-889.
50. Wong, T.Z., G.J. van der Westhuizen, and R.E. Coleman, *Positron emission tomography imaging of brain tumors*. Neuroimaging Clin N Am, 2002. **12**(4): p. 615-626.
51. Olivero, W.C., S.C. Dulebohn, and J.R. Lister, *The use of PET in evaluating patients with primary brain tumours: is it useful?* J Neurol Neurosurg Psychiatry, 1995. **58**(2): p. 250-252.
52. Ricci, P.E., et al., *Differentiating recurrent tumor from radiation necrosis: time for re-evaluation of positron emission tomography?* AJNR Am J Neuroradiol, 1998. **19**(3): p. 407-413.
53. Chen, W., et al., *18F-FDOPA PET imaging of brain tumors: comparison study with 18F-FDG PET and evaluation of diagnostic accuracy*. J Nucl Med, 2006. **47**(6): p. 904-911.
54. Tripathi, M., et al., *Comparative evaluation of F-18 FDOPA, F-18 FDG, and F-18 FLT-PET/CT for metabolic imaging of low grade gliomas*. Clin Nucl Med, 2009. **34**(12): p. 878-883.
55. van Waarde, A., et al., *Selectivity of 18F-FLT and 18F-FDG for differentiating tumor from inflammation in a rodent model*. J Nucl Med, 2004. **45**(4): p. 695-700.
56. Jora, C., et al., *Comparative evaluation of 18F-FDOPA, 13N-AMMONIA, 18F-FDG PET/CT and MRI in primary brain tumors - A pilot study*. Indian J Nucl Med, 2011. **26**(2): p. 78-81.
57. Jacob, M.J., et al., *Comparative study of (18)F-DOPA, (13)N-Ammonia and F18-FDG PET/CT in primary brain tumors*. Indian J Nucl Med, 2011. **26**(3): p. 139-143.
58. Crippa, F., A. Alessi, and G.L. Serafini, *PET with radiolabeled aminoacid*. Q J Nucl Med Mol Imaging, 2012. **56**(2): p. 151-162.
59. Bergmann, R., et al., *3-O-Methyl-6-18F-Fluoro-L-Dopa, a New Tumor Imaging Agent: Investigation of Transport Mechanism In Vitro*. Journal of nuclear medicine : official publication, Society of Nuclear Medicine, 2004. **45**(12): p. 2116-2122.
60. Derlon, J.M., et al., *[11C]L-methionine uptake in gliomas*. Neurosurgery, 1989. **25**(5): p. 720-728.
61. Bergstrom, M., et al., *Discrepancies in brain tumor extent as shown by computed tomography and positron emission tomography using [68Ga]EDTA, [11C]glucose, and [11C]methionine*. J Comput Assist Tomogr, 1983. **7**(6): p. 1062-1066.
62. Lilja, A., et al., *Dynamic study of supratentorial gliomas with L-methyl-11C-methionine and positron emission tomography*. AJNR Am J Neuroradiol, 1985. **6**(4): p. 505-514.
63. Ogawa, T., et al., *Cerebral glioma: evaluation with methionine PET*. Radiology, 1993. **186**(1): p. 45-53.
64. Becherer, A., et al., *Brain tumour imaging with PET: a comparison between [18F]fluorodopa and [11C]methionine*. Eur J Nucl Med Mol Imaging, 2003. **30**(11): p. 1561-1567.
65. Padma, M.V., et al., *Prediction of pathology and survival by FDG PET in gliomas*. J Neurooncol, 2003. **64**(3): p. 227-237.

66. Karunanithi, S., et al., *18F-FDOPA PET/CT for detection of recurrence in patients with glioma: prospective comparison with 18F-FDG PET/CT*. Eur J Nucl Med Mol Imaging, 2013. **40**(7): p. 1025-1035.
67. Kratochwil, C., et al., *Intra-individual comparison of 18F-FET and 18F-DOPA in PET imaging of recurrent brain tumors*. Neuro-oncology, 2013(October): p. 1-7.
68. Katano, H., et al., *Comparison of thallium-201 uptake and retention indices for evaluation of brain lesions with SPECT*. Journal of Clinical Neuroscience, 2002. **9**(6): p. 653-658.
69. Sun, D., et al., *Clinical application of 201Tl SPECT imaging of brain tumors*. Journal of nuclear medicine : official publication, Society of Nuclear Medicine, 2000. **41**(1): p. 5-10.
70. Tomoyuki, K., et al., *Voxel-based analysis of 201Tl SPECT for grading and diagnostic accuracy of gliomas: comparison with ROI analysis*. Annals of nuclear medicine, 2013(27): p. 493-501.
71. Deltuva, V., et al., *Perioperative single photon emission computed tomography in predicting survival of malignant glioma patients*. Oncology letters, 2012. **4**(4): p. 739-744.
72. Gomez-Rio, M., et al., *(201)Tl-SPECT in low-grade gliomas: diagnostic accuracy in differential diagnosis between tumour recurrence and radionecrosis*. European journal of nuclear medicine and molecular imaging, 2004. **31**(9): p. 1237-43.
73. Lorberboym, M., et al., *The Role of Thallium-201 Uptake and Retention in Intracranial Tumors After Radiotherapy Experience of past decades has established that radiation*. 1996(November 1993): p. 223-226.
74. Tie, J., D.H. Gunawardana, and M.a. Rosenthal, *Differentiation of tumor recurrence from radiation necrosis in high-grade gliomas using 201Tl-SPECT*. Journal of clinical neuroscience : official journal of the Neurosurgical Society of Australasia, 2008. **15**(12): p. 1327-34.
75. Karunanithi, S., et al., *Prospective Comparison of 99mTc-GH SPECT/CT and 18F-FDOPA PET/CT for Detection of Recurrent Glioma: A Pilot Study*. Clin Nucl Med, 2013.
76. Jeremic, B., et al., *Multivariate analysis of clinical prognostic factors in patients with glioblastoma multiforme treated with a combined modality approach*. J Cancer Res Clin Oncol, 2003. **129**(8): p. 477-484.
77. Vos, M.J., et al., *Thallium-201 single-photon emission computed tomography as an early predictor of outcome in recurrent glioma*. J Clin Oncol, 2003. **21**(19): p. 3559-3565.
78. De Witte, O., et al., *Prognostic value positron emission tomography with [18F]fluoro-2-deoxy-D-glucose in the low-grade glioma*. Neurosurgery, 1996. **39**(3): p. 470-477.
79. Santra, A., et al., *F-18 FDG PET-CT for predicting survival in patients with recurrent glioma: a prospective study*. Neuroradiology, 2011. **53**(12): p. 1017-1024.
80. Karunanithi, S., et al., *Can F-FDOPA PET/CT predict survival in patients with suspected recurrent glioma? A prospective study*. Eur J Radiol, 2013.
81. Dowson, N., et al., *Early prediction of treatment response in advanced gliomas with (18)F-dopa positron-emission tomography*. Curr Oncol, 2014. **21**(1): p. e172-8.

82. Behin, A., et al., *Primary brain tumours in adults*. Lancet, 2003. **361**(9354): p. 323-331.
83. Ceyskens, S., et al., *[11C]methionine PET, histopathology, and survival in primary brain tumors and recurrence*. AJNR Am J Neuroradiol, 2006. **27**(7): p. 1432-1437.
84. Spetzler, R.F. and N.A. Martin, *A proposed grading system for arteriovenous malformations*. J Neurosurg, 1986. **65**(4): p. 476-483.
85. Yamamoto, Y., et al., *Hypoxia assessed by 18F-fluoromisonidazole positron emission tomography in newly diagnosed gliomas*. Nucl Med Commun, 2012. **33**(6): p. 621-625.
86. Fueger, B.J., et al., *Correlation of 6-18F-fluoro-L-dopa PET uptake with proliferation and tumor grade in newly diagnosed and recurrent gliomas*. J Nucl Med, 2010. **51**(10): p. 1532-1538.
87. Pafundi, D.H., et al., *Biopsy validation of 18F-DOPA PET and biodistribution in gliomas for neurosurgical planning and radiotherapy target delineation: results of a prospective pilot study*. Neuro Oncol, 2013. **15**(8): p. 1058-1067.
88. Nioche, C., et al., *Evaluation of quantitative criteria for glioma grading with static and dynamic 18F-FDopa PET/CT*. Clin Nucl Med, 2013. **38**(2): p. 81-87.
89. Mihara, F., et al., *Non-enhancing supratentorial malignant astrocytomas: MR features and possible mechanisms*. Radiation medicine, 2013. **13**(1): p. 11-7.
90. Grosu, A.-L., et al., *Implications of IMT-SPECT for postoperative radiotherapy planning in patients with gliomas*. International journal of radiation oncology, biology, physics, 2002. **54**(3): p. 842-54.
91. Schomas, D.A., et al., *Intracranial low-grade gliomas in adults: 30-year experience with long-term follow-up at Mayo Clinic*. Neuro-oncology, 2009. **11**(4): p. 437-45.
92. Mongiardi, M.P., *Angiogenesis and hypoxia in glioblastoma: a focus on cancer stem cells*. CNS Neurol Disord Drug Targets, 2012. **11**(7): p. 878-883.
93. de Bouard, S., et al., *Antiangiogenic and anti-invasive effects of sunitinib on experimental human glioblastoma*. Neuro Oncol, 2007. **9**(4): p. 412-423.
94. Goldbrunner, R.H., et al., *PTK787/ZK222584, an inhibitor of vascular endothelial growth factor receptor tyrosine kinases, decreases glioma growth and vascularization*. Neurosurgery, 2004. **55**(2): p. 426-32; discussion 432.
95. Kunkel, P., et al., *Inhibition of glioma angiogenesis and growth in vivo by systemic treatment with a monoclonal antibody against vascular endothelial growth factor receptor-2*. Cancer Res, 2001. **61**(18): p. 6624-6628.
96. Miletic, H., et al., *Anti-VEGF therapies for malignant glioma: treatment effects and escape mechanisms*. Expert Opin Ther Targets, 2009. **13**(4): p. 455-468.
97. Ran, S., et al., *Evaluation of novel antimouse VEGFR2 antibodies as potential antiangiogenic or vascular targeting agents for tumor therapy*. Neoplasia, 2003. **5**(4): p. 297-307.

98. Rubenstein, J.L., et al., *Anti-VEGF antibody treatment of glioblastoma prolongs survival but results in increased vascular cooption*. *Neoplasia*, 2000. **2**(4): p. 306-314.
99. Sandstrom, M., et al., *The tyrosine kinase inhibitor ZD6474 inhibits tumour growth in an intracerebral rat glioma model*. *Br J Cancer*, 2004. **91**(6): p. 1174-1180.
100. Verhoeff, J.J., et al., *Concerns about anti-angiogenic treatment in patients with glioblastoma multiforme*. *BMC Cancer*, 2009. **9**: p. 444-444.
101. Harris, R.J., et al., *18F-FDOPA and 18F-FLT positron emission tomography parametric response maps predict response in recurrent malignant gliomas treated with bevacizumab*. *Neuro Oncol*, 2012. **14**(8): p. 1079-1089.
102. Walter, F., et al., *Impact of 3,4-dihydroxy-6-18F-fluoro-L-phenylalanine PET/CT on managing patients with brain tumors: the referring physician's perspective*. *J Nucl Med*, 2012. **53**(3): p. 393-398.
103. Catalaa, I., et al., *Perfusion, diffusion and spectroscopy values in newly diagnosed cerebral gliomas*. *NMR Biomed*, 2006. **19**(4): p. 463-475.
104. Cha, S., et al., *Comparison of microvascular permeability measurements, $K(\text{trans})$, determined with conventional steady-state T1-weighted and first-pass T2*-weighted MR imaging methods in gliomas and meningiomas*. *AJNR*. American journal of neuroradiology, 2006. **27**(2): p. 409-17.
105. Kang, Y., et al., *Gliomas: Histogram analysis of apparent diffusion coefficient maps with standard- or high-b-value diffusion-weighted MR imaging--correlation with tumor grade*. *Radiology*, 2011. **261**(3): p. 882-890.
106. Murakami, R., et al., *Grading astrocytic tumors by using apparent diffusion coefficient parameters: superiority of a one- versus two-parameter pilot method*. *Radiology*, 2009. **251**(3): p. 838-845.
107. Zonari, P., P. Baraldi, and G. Crisi, *Multimodal MRI in the characterization of glial neoplasms: the combined role of single-voxel MR spectroscopy, diffusion imaging and echo-planar perfusion imaging*. *Neuroradiology*, 2007. **49**(10): p. 795-803.
108. Rose, S., et al., *Correlation of MRI-derived apparent diffusion coefficients in newly diagnosed gliomas with [18F]-fluoro-L-dopa PET: what are we really measuring with minimum ADC?* *AJNR Am J Neuroradiol*, 2013. **34**(4): p. 758-764.
109. Bell, C., et al., *Distance informed Track-Weighted Imaging (diTWI): A framework for sensitising streamline information to neuropathology*. *Neuroimage*, 2014. **86**: p. 60-6.
110. Lizarraga, K.J., et al., *(18)F-FDOPA PET for differentiating recurrent or progressive brain metastatic tumors from late or delayed radiation injury after radiation treatment*. *J Nucl Med*, 2014. **55**(1): p. 30-6.
111. Cicone, F., et al., *Accuracy of F-DOPA PET and perfusion-MRI for differentiating radionecrotic from progressive brain metastases after radiosurgery*. *Eur J Nucl Med Mol Imaging*, 2015. **42**(1): p. 103-11.
112. Chiaravalloti, A., et al., *Factors affecting (18)F FDOPA standardized uptake value in patients with primary brain tumors after treatment*. *Nucl Med Biol*, 2015. **42**(4): p. 355-9.

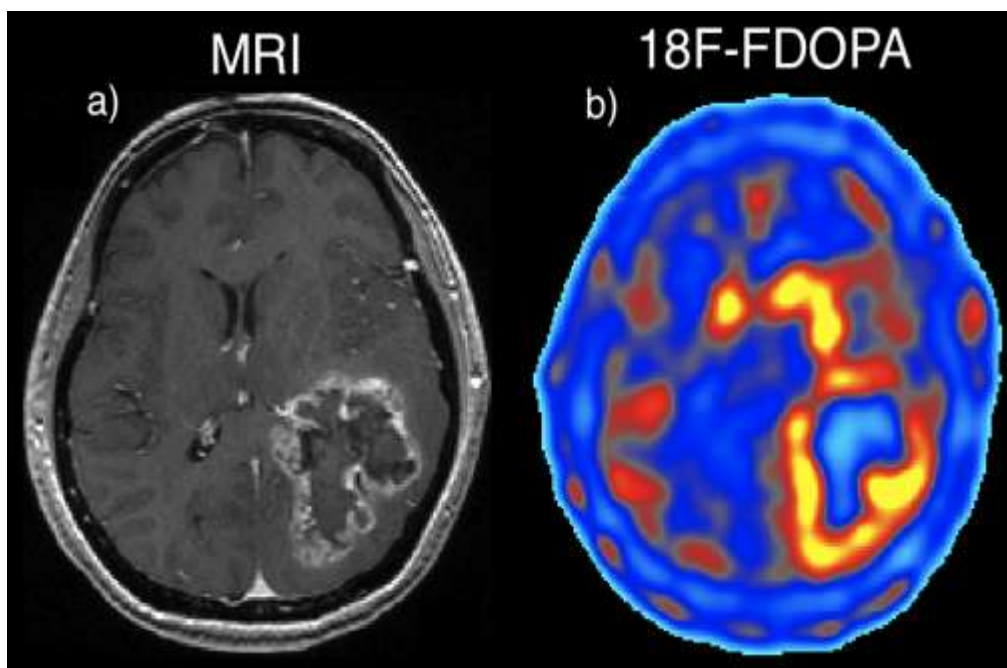


Figure 1 – a) Contrast enhanced MRI and b) ^{18}F -FDOPA imaging of a primary high-grade glioma (grade IV – GBM).

Table 1 - Summary of clinical ^{18}F -FDOPA PET studies. (HG – High grade; LG – Low grade; PBT – Primary brain tumour; DF – Disease free; NG – Non-glioma; PTC – Posttreatment changes; NA – Not applicable; PFS- Progression free survival; OS – Overall survival; TP – True Positive; FP – False Positive)

Reference	No. patients	tumours quantity and type	Study	Results
[22]	1	1 Low grade	Case study into possible neuro-degenerative disorder.	Unintentional discovery of low-grade glioma.
[53]	20	18 Primary 2 Disease free	Investigate the relationship between ^{11}C -MET and ^{18}F -FDOPA uptake.	Uptakes were very similar. ^{11}C -MET SUVR: 2.04 ± 0.53 ; ^{18}F -FDOPA SUVR: 2.05 ± 0.91 . Visual uptake was also very similar.
[42]	81	18 Grade II 13 Grade III 35 Grade IV 11 PTC 4 Remission	Compared ^{18}F -FDG and ^{18}F -FDOPA uptake in primary and recurrent gliomas.	^{18}F -FDOPA sensitivity: 96%; ^{18}F -FDOPA specificity: 43%; ^{18}F -FDG sensitivity: 61%; ^{18}F -FDG specificity: 43%. ^{18}F -FDOPA could not discriminate between low and high grade glioma.
[43]	15	3 Grade I 9 Grade II 3 In Remission	Compared ^{18}F -FLT, ^{18}F -FDG and ^{18}F -FDOPA in low-grade gliomas.	^{18}F -FDOPA – TP: 12 FP: 0 ^{18}F -FDG – TP: 7 FP: 0 ^{18}F -FDOPA – TP: 4 FP: 0
[45]	23	6 Primary 10 Recurrent 7 Disease free	Pilot study into the comparison of ^{18}F -FDOPA, ^{18}F -FDG, ^{13}N -Ammonia and MRI.	Sensitivity (%): ^{18}F -FDG - 44, ^{13}N -Ammonia - 25 ^{18}F -FDOPA - 100 MRI - 81 Specificity (%): ^{18}F -FDG - 86, ^{13}N -Ammonia - 86 ^{18}F -FDOPA - 71 MRI - 43
[33]	91	33 Grade II 24 Grade III 34 Grade IV	Investigated ^{18}F -FDOPA PET/MRI fusion for glioma detection. Group I – had histology to confirm Group II – Confirmation from serial MRI	^{18}F -FDOPA PET and MRI individually provided vital information for glioma detection. Group I – ^{18}F -FDOPA sensitivity: 95.2%, MRI: 90.5% Group II – MRI/PET concordance: 90.1%
[65]	30	22 Recurrent	Compared ^{18}F -FDOPA	^{18}F -FDOPA outperformed $^{99\text{m}}\text{Tc}$ -GH SPECT in

		8 Remission	and ^{99m}Tc -GH SPECT for recurrence of glioma.	detection of recurrent gliomas. ^{18}F -FDOPA – TP: 22 TN: 7 ^{99m}Tc -GH – TP: 19 TN: 5
[70]	33	25 Recurrent 8 Remission	Assessed potential for ^{18}F -FDOPA to predict survival in recurrent gliomas.	^{18}F -FDOPA tumour-to-normal (T/N) ration and MRI tumour size was significant in multivariate analysis of survival. T/N > 1.51 and MRI tumour size > 2.5 was indicative of poor prognosis.
[34]	35	26 Recurrent 9 Remission	Compared MRI and ^{18}F -FDOPA uptake in patients with suspected recurrent glioma.	^{18}F -FDOPA was more specific than MRI in tumour detection. ^{18}F -FDOPA sensitivity, specificity, accuracy: 100%, 89%, 97% MRI sensitivity, specificity, accuracy: 92%, 44%, 80%
[55]	28	21 Recurrent 7 Remission	Compared ^{18}F -FDG with ^{18}F -FDOPA in detection of recurrent gliomas.	^{18}F -FDOPA outperformed ^{18}F -FDG in detection and diagnosis of recurrent glioma. ^{18}F -FDOPA sensitivity, specificity, accuracy: 100%, 86%, 96% ^{18}F -FDG sensitivity, specificity, accuracy: 47%, 100%, 61%
[71]	9	9 Grade IV	Investigated ^{18}F -FDOPA uptake for predicting survival.	Treatment resistant clusters of cells were predictive of patient survival. A 1% reduction of uptake in the most intense cluster reduce the hazard to the patient by 10%.
[76]	59	13 Grade II 19 Grade III 27 Grade IV	Investigated potential of ^{18}F -FDOPA to grade gliomas.	Tumour grades could be discriminated in primary, but not recurrent gliomas using ^{18}F -FDOPA SUV_{max} Primary SUV_{max} : LG - 4.22 ± 1.30 , HG - 2.34 ± 1.35 , $P=0.005$ Recurrent SUV_{max} : LG - 3.36 ± 1.26 HG - 2.67 ± 1.18 , $P=0.22$

[78]	33	15 Grade II 10 Grade III 8 Grade IV	Investigated potential of ^{18}F -FDOPA to grade gliomas in static and dynamic scans.	Static scan: 5 minute scan 38 minutes post injection could discriminate HG and LG primary glioma with a sensitivity and specificity of 70% and 90%, respectively, with a threshold of $\text{SUV}_{\text{mean}} = 2.5$. Sensitivity and specificity of 100% and 80%, respectively for recurrent gliomas when threshold of 1.8 was used. Dynamic imaging did not significantly improve ability to discriminate between HG and LG tumours.
[91]	24	24 Recurrent	Evaluated potential for ^{18}F -FLT and ^{18}F -FDOPA serial PET, 1 pre- and 2 post-treatment, to predict response to treatment.	Decrease in ^{18}F -FDOPA uptake predicted longer PFS and OS. An increase in ^{18}F -FDOPA predicted shorter PFS and OS. Volume fraction of increased ^{18}F -FDOPA between the 2 post treatment time points predicted long and short term PFS and OS $P < 0.05$. ^{18}F -FLT uptake did not stratify OS.
[98]	15	Grade IV	Used ^{18}F -FDOPA to investigate the role of ADC in clinical evaluation of glioma.	^{18}F -FDOPA uptake and minimum ADC showed minimal overlap, suggesting minimum ADC could be due to oedema and ischemia, not tumour proliferation.
[99]	143	Grade IV	Used ^{18}F -FDOPA to validate a framework for identifying tumour infiltration in high-grade gliomas.	Incorporating white matter fiber tracks, delineation of tumour boundaries was improved in all cases.
[92]	58	NA	Investigated how ^{18}F -FDOPA influenced decisions on treatment in the clinical setting.	^{18}F -FDOPA was influential in the diagnosis of glioma, and altered treatment in a number of cases. Suspicion for recurrent increased in 33%, remain the same in 50% and decrease in

				17%. ^{18}F -FDOPA altered treatment plan in 41% and this change was followed through in 75%.
[57]	18	8 Low grade 8 High grade	Compared uptake and diagnostic value of ^{18}F -FDOPA and ^{18}F -FET.	Uptake of ^{18}F -FDOPA was higher than ^{18}F -FET in tumours. ^{18}F -FDOPA able to detect all recurrent lesions, whereas ^{18}F -FET detected all but one. ^{18}F -FET can provide information on tumour grade using dynamic scanning
[77]	10	8 High grade 2 Low grade	Histopathologically compared ^{18}F -FDOPA uptake and MRI to evaluate the use of ^{18}F -FDOPA for radiation therapy planning	Biopsy results showed that ^{18}F -FDOPA uptake in areas lacking MRI contrast enhancement corresponded to malignant tissue. ^{18}F -FDOPA was more sensitive than MRI for identifying tumour boundaries.
[56]	37	10 Grade IV 10 Grade III 13 Grade II 4 NG	Investigated kinetic modeling of tissue types in dynamic ^{18}F -FDOPA imaging of glioma.	A 2-compartment model was able to describe tumour and cerebellum tissues. A 3-compartment model, with specific corrections, was able to describe tumour and striata. High-grade gliomas had a significantly higher influx rate, equilibrium distribution volume and transport rate than lower-grade tumours.