

Case Report/Case Series

***BRAF*^{V600E} Mutation Status of Involuting and Stable Nevi in Dabrafenib Therapy With or Without Trametinib**

Phil McClenahan, BSc; Lynlee L. Lin, BSc; Jean-Marie Tan, MB, BCH, BAO (hons); Ross Flewell-Smith, BCom, BEng; Helmut Schaidler, MD; Kasturee Jagirdar, MSc; Victoria Atkinson, MBBS, FRACP; Duncan Lambie, BDS, MBBS, FRCPA; Tarl W. Prow, BS, MSc, PhD; Richard A. Sturm, PhD; H. Peter Soyer, MD, FACP

IMPORTANCE Recent advances in targeting *BRAF*^{V600E} mutations, which occur in roughly 50% of melanomas and 70% of benign nevi, have improved response rates and survival in patients with melanoma. With increased survival, the importance of other comorbidities increases and requires consideration in long-term management. This case report discusses dynamic dermoscopic nevus changes that occur during dabrafenib therapy and offers some conclusions regarding *BRAF* mutations and the changes.

OBSERVATIONS A man in his 30s had been monitored with whole-body dermoscopy at roughly 7-month intervals as part of a nevus surveillance study. Fourteen months after his initial visit, metastases were found, and the patient entered a clinical trial of dabrafenib with or without trametinib therapy. Continued dermoscopic monitoring for the next 12 months revealed that approximately 50% of the existing acquired melanocytic nevi involuted, while the remaining nevi did not change. Biopsy findings from 1 unchanged and 1 involuted nevus showed *BRAF* wild type in the unchanged nevus, *BRAF*^{V600E} mutation in the involuting nevus, and no malignant histopathologic characteristics in either one.

CONCLUSIONS AND RELEVANCE Our observations indicate that a previously suggested hypothesis regarding involuting nevi in *BRAF* inhibitor therapy is correct: Nevi that involute while a patient is undergoing *BRAF* V600E inhibitor therapy possess the *BRAF* V600E mutation, while others that grow or remain unchanged are wild type. However larger-scale trials are required to gather conclusive data and create a more complete clinical picture.

JAMA Dermatol. 2014;150(10):1079-1082. doi:10.1001/jamadermatol.2014.436
Published online April 2, 2014.

Author Affiliations: Dermatology Research Centre, The University of Queensland, School of Medicine, Translational Research Institute, Brisbane, Queensland, Australia (McClenahan, Lin, Tan, Flewell-Smith, Schaidler, Jagirdar, Prow, Sturm, Soyer); The University of Queensland, Institute for Molecular Biosciences, Brisbane, Queensland, Australia (Jagirdar, Sturm); Medical Oncology, Princess Alexandra Hospital, Woolloongabba, Queensland, Australia (Atkinson); The University of Queensland, Translational Research Institute, Brisbane, Queensland, Australia (Lambie); IQ Pathology, Brisbane, Queensland, Australia (Lambie).

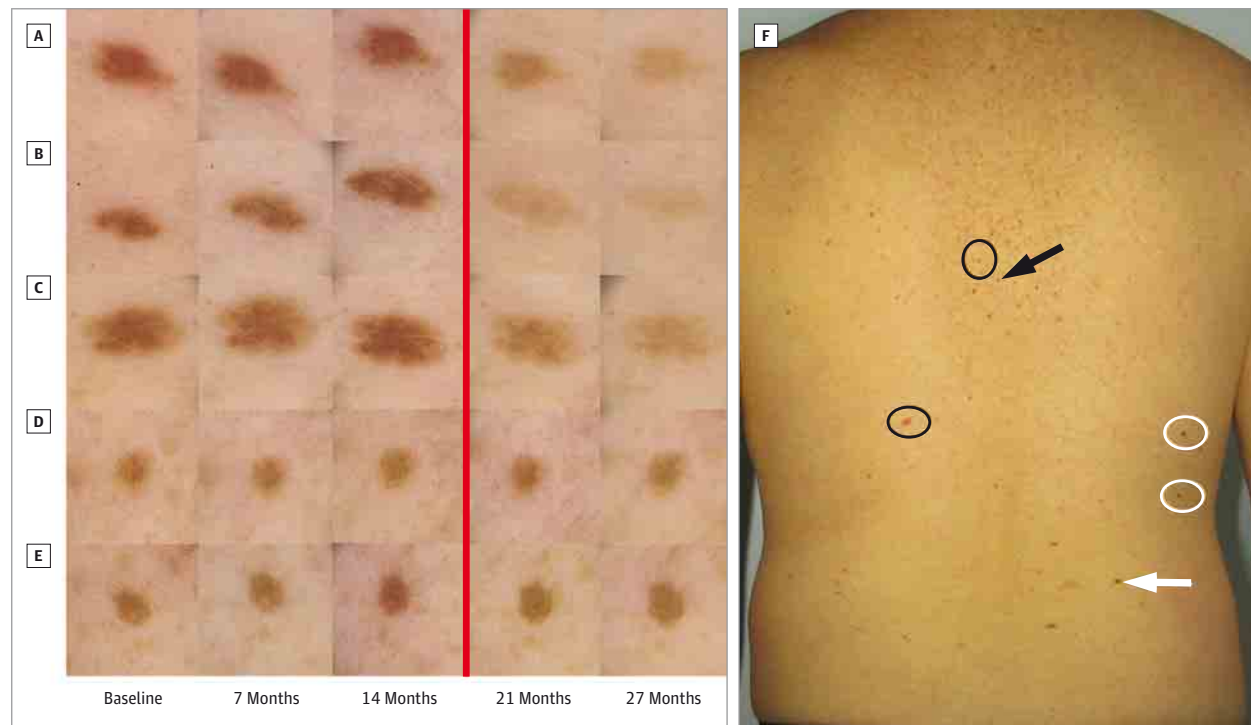
Corresponding Author: H. Peter Soyer, MD, FACP, Level 5, Translational Research Institute (TRI), 37 Kent St, Woolloongabba QLD 4102, Australia (p.soyer@uq.edu.au).

Melanocytes, like many other human cells, express the *BRAF* gene. However, mutation of *BRAF* in melanocytes occurs at high frequency in melanocytic proliferations such as nevi (70%-82%) and melanomas (50%-60%).^{1,2} Mutation of *BRAF* results in a defect of the mitogen-activated protein kinase (MAPK) pathway causing oncogenic proliferation and avoidance of apoptosis.³ Most frequently, *BRAF* mutations occur at the V600E position (74%-90%), and the next most common mutation occurs at V600K (16%-29%)⁴; together, these sites account for 95% of all *BRAF* mutations.

Initial breakthrough treatments were made with vemurafenib, a selective inhibitor of *BRAF*^{V600E}-mutated kinase. The inhibition of *BRAF*^{V600E} initially induces tumor growth arrest and partial or complete tumor regression in metastatic melanoma.⁵ Given the frequency of *BRAF*^{V600E} mutations in benign nevi,² it is also not surprising that changes have been observed in existing melanocytic nevi and that new nevi appear

during *BRAF*^{V600E} inhibitor therapy.^{6,7} Recently, a study of 42 patients treated with vemurafenib for a mean duration of 6.7 months described a high level of dermoscopic change in pre-existing lesions such as color changes, appearance and disappearance of globules, dermoscopic island pigmentation, and increases in size of nevi.⁸ New primary melanomas have also been reported during the early stages of vemurafenib treatment, arising from new erupting melanocytic proliferations or rapidly changing existing nevi.⁹ Zimmer et al,⁹ Dalle et al,⁷ and Perier-Muzet et al⁸ report that these new primary melanomas arising during vemurafenib therapy are *BRAF* wild type.

Herein we describe an example of nevus volatility and propose the molecular involvement in a patient undergoing *BRAF*^{V600E} inhibition therapy and who participated in a nevus surveillance study. All patients in the surveillance study provided written consent, and the study followed the Declaration of Helsinki protocols and was approved by the Princess Alexandra Hospital human research ethics committee.

Figure 1. Surveillance of Involuting Nevi During BRAF^{V600E} Inhibitor Therapy and Clinical Image of Back

A-C, Three nevi have undergone involution 7 months after initiation of BRAF^{V600E} inhibitor therapy. D and E, The other 2 nevi remain unchanged. Excisional shave biopsies and numerous ex vivo microbiopsies were performed on nevi C and E. Images to the left of the vertical red line were obtained before the patient commenced participation in the BRAF inhibitor trial; images to the

right of the line were obtained after he entered the trial. F, Clinical image of the back shows nevi locations: white arrow indicates biopsied involuting nevus; white circles indicate involuting nevi; black arrow indicates biopsied unchanged nevus; black circles indicate unchanged nevi.

Report of a Case

While participating in a nevus surveillance study, 1 of the patients, a man in his 30s who had been diagnosed 5 years earlier as having a superficial melanoma (Clark level 3, Breslow index 0.64 mm), developed metastases in the pancreas, liver, and mesenteric lymph nodes. Two months later, he was enrolled in a clinical trial of dabrafenib with or without trametinib therapy. Dabrafenib is a BRAF inhibitor similar to vemurafenib, and it was being tested with trametinib, a MEK (MAPK kinase) inhibitor that targets the same MAPK pathway. The trial was blinded and still ongoing at the time of the present report, and so it is unknown whether this patient's treatment regimen included trametinib.

The patient presented with Fitzpatrick skin type III, dark brown hair, and green eyes. He underwent imaging with a FotoFinder system (FotoFinder Systems GmbH) of all nevi larger than 2 mm on the back and larger than 5 mm on the rest of the body. No significant changes were observed dermoscopically throughout. Ten nevi larger than 5 mm were identified on the body, while 25 nevi larger than 2 mm were identified on the back, for a total of 31 nevi included in our analysis. There were 2 globular, 15 reticular, and 14 nonspecific/homogeneous nevi.

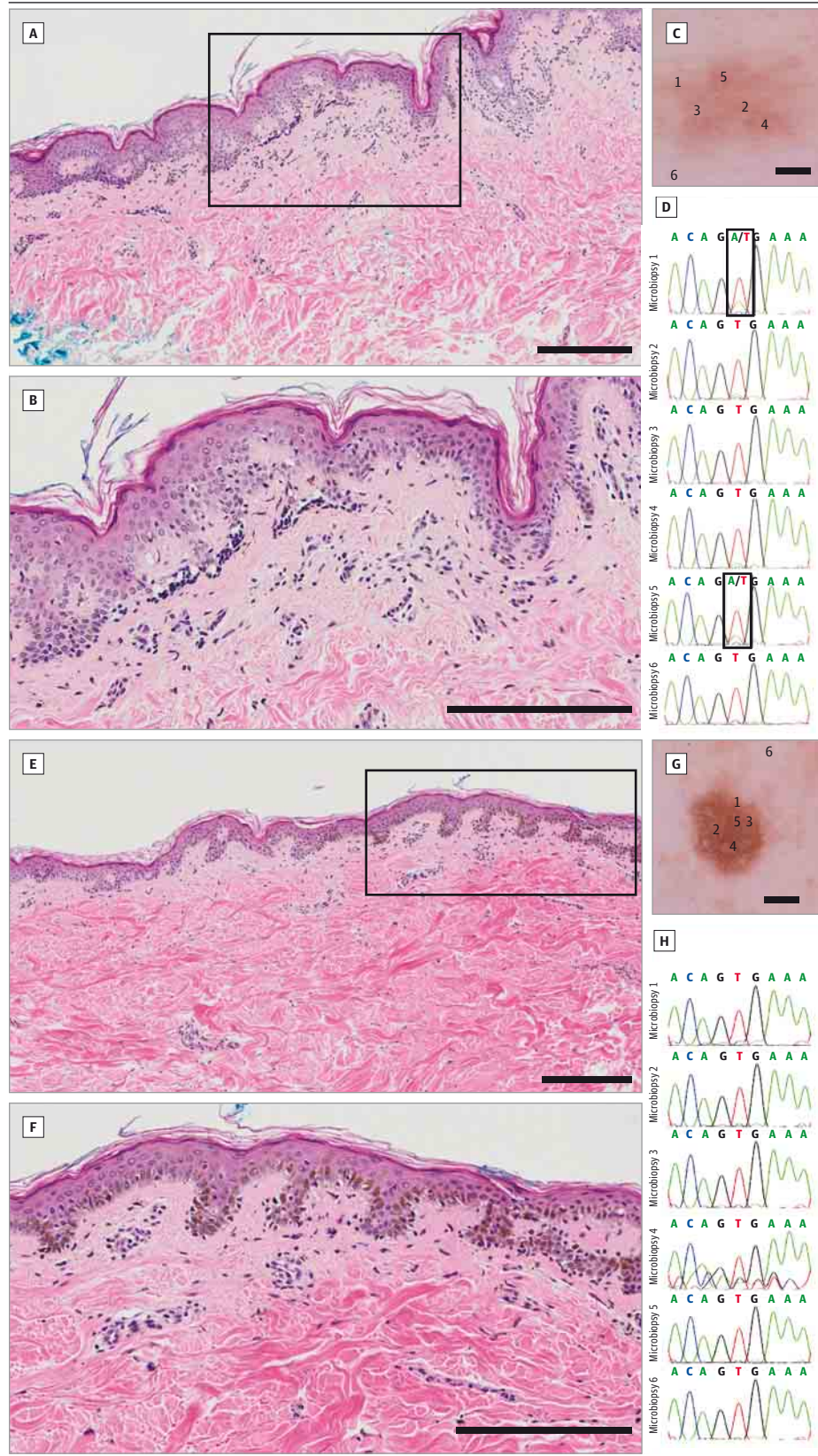
Full-body and dermoscopic imaging was conducted 5 times over the next 27 months at roughly 7-month intervals, and no

significant dermoscopic changes were identified by assessment of imaged nevi at the 7- or 14-month visits. However, at the 21-month visit, 6 months after he commenced participation in the BRAF inhibitor trial, assessment revealed significant dermoscopic changes 16 nevi (51% of total) (Figure 1). The nevi changes predominantly involved involution and a decrease in pigmentation and size. In addition, in concurrence with other reports,⁶ flattening of raised nevi was also observed. By dermoscopic pattern, 4 reticular, 10 homogeneous, and 2 globular nevi showed signs of involution. Therefore, 71% of the unspecific and 26% of the reticular nevi showed signs of involution, while both raised globular nevi decreased in pigmentation and flattened.

By the time of final imaging at 27 months' surveillance (12 months into the BRAF inhibitor trial), the nevi had generally not further changed, but 5 nevi had continued to involute: 3 reticular and 2 homogeneous nevi. Again, no increase in pigmentation was observed in any lesions, and no new nevi were observed. The patient had an otherwise excellent systemic response to the targeted therapy and an excellent partial response to the point of almost a complete response, with the exception of a small unchanged node near the pancreas that was seen on computed tomographic imaging.

There are a number of external and endogenous factors influencing changes and appearance of nevi over time. These

Figure 2. Histopathologic Images and Molecular Sequencing Charts for BRAF^{V600E} Status of 1 Involuting Nevus and 1 Noninvolving Nevus



A-D, Workup of an involuting nevus. E-H, Workup of a noninvolving nevus. C and G, Dermoscopic images show microbiopsy sites 1 through 5 (scale bar = 1 mm); site 6 in each panel is a control biopsy site adjacent to the nevus. D and H, Molecular analysis charts for microbiopsy sites shown in panels C and G, respectively. A and E, Histopathologic images of the nevi, neither of which shows any histopathological criteria for melanoma (scale bars = 200 μ m; boxes enclose areas shown at higher magnification in panels B and F). The involuted nevus in panel A is a benign, predominantly junctional nevus with few discrete nests of nonpigmented nevus cells at the dermal-epidermal junction; subtle lymphatic infiltration around suprapapillary vascular plexus; and no obvious signs of fibrosis or regression; sequencing (D) reveals that the nevus is heterogeneous for BRAF^{V600E} mutation at sites 1 and 5. The noninvolved nevus in panel E is a benign lentiginous melanocytic nevus with elongated pigmented rete ridges and slightly increased numbers of melanocytes at the dermal-epidermal junction; small junctional nests of melanocytes are also present; and sequencing (H) reveals no presence of BRAF^{V600E} mutation. B and F, Greater magnifications of the boxed areas of panels A and E, respectively (scale bars = 200 μ m).

include UV radiation exposure, hormonal changes associated with pregnancy,¹⁰ and targeted melanoma therapies such as selective BRAF^{V600E} inhibitors.⁶ As unchanged and changed nevi were at times adjacent at the same body site, UV exposure was not considered to be a major influencing factor, and pregnancy cannot be considered in our male patient. Therefore to sample molecular markers, specifically BRAF mutation status of changed and unchanged nevi, we used a newly described microbiopsy device.¹¹⁻¹³

Diagnostic shave excisions were performed on 1 involuted nevus and 1 unchanged nevus (Figure 1). The histopathologic diagnosis for the involuted lesion was a predominantly junctional compound nevus without significant inflammation or fibrosis, and the unchanged lesion was characterized as a junctional nevus with a lentiginous melanocytic pattern. Microbiopsy specimens were taken from 6 locations on both of the excised nevi (Figure 2). DNA samples extracted from microbiopsy specimens were subjected to polymerase chain reaction amplification using selected forward and reverse primers to flank the BRAF exon 15 and NRAS exon 2 mutation hotspots.¹⁴ Molecular sequencing of the samples for BRAF and NRAS mutations were performed after extraction of amplified products from the DNA gel. Sequencing revealed heterogeneous BRAF^{V600E} mutation in the involuting nevus and BRAF

wild type in the unchanged nevus, while both lesions were NRAS wild type.

Discussion

The involution of nevi in BRAF^{V600E} inhibitor therapy has been reported, but herein we report findings that support the hypothesis⁶ that these nevi are BRAF^{V600E} positive. This is related to decreased MAPK activity due to BRAF inhibition. In contrast to reports in vemurafenib-treated patients of increased size and pigmentation in some nevi and the appearance of new BRAF wild-type melanoma through paradoxical BRAF activation,¹⁵ we observed no increase in pigmentation of nevi or suspect changes in our patient. Because we could not know whether our dabrafenib-treated patient was also receiving trametinib, conclusions regarding the combination regimen cannot be drawn. However, our long-term monitoring prior to and during therapy combined with confirmation of involuting nevi possessing BRAF^{V600E} mutation adds another component to the dermoscopic changes in long-term therapy with BRAF^{V600E} inhibitors. Larger-scale and longer-term trials will give a broader and more accurate description of specific medication effects required for dermatologic follow-up.

ARTICLE INFORMATION

Accepted for Publication: February 26, 2014.

Published Online: April 2, 2014.

doi:10.1001/jamadermatol.2014.436.

Author Contributions: Mr McClenahan had full access to all of the data in the study and takes responsibility for the integrity of the data and the accuracy of the data analysis.

Study concept and design: McClenahan, Flewell-Smith, Soyer.

Acquisition of data: McClenahan, Lin, Tan, Jagirdar, Atkinson, Lambie, Prow, Sturm, Soyer.

Analysis and interpretation of data: McClenahan, Lin, Schaidler, Jagirdar, Prow, Sturm, Soyer.

Drafting of the manuscript: McClenahan, Lin, Flewell-Smith, Schaidler, Prow, Soyer.

Critical revision of the manuscript for important intellectual content: McClenahan, Tan, Jagirdar, Atkinson, Lambie, Sturm, Soyer.

Statistical analysis: McClenahan, Sturm, Soyer.

Obtained funding: Soyer.

Administrative, technical, or material support: Lin, Tan, Flewell-Smith, Jagirdar, Lambie, Prow, Sturm, Soyer.

Study supervision: Schaidler, Sturm, Soyer.

Conflict of Interest Disclosures: None reported.

Funding/Support: This study was supported in part by research grant APP1004999 from the National Health and Medical Research Council, Canberra, Australian Capital Territory, Australia.

Role of the Sponsor: The National Health and Medical Research Council had no role in the design and conduct of the study; collection, management, analysis, and interpretation of the data;

preparation, review, or approval of the manuscript; and decision to submit the manuscript for publication.

REFERENCES

- Davies H, Bignell GR, Cox C, et al. Mutations of the BRAF gene in human cancer. *Nature*. 2002;417(6892):949-954.
- Pollock PM, Harper UL, Hansen KS, et al. High frequency of BRAF mutations in nevi. *Nat Genet*. 2003;33(1):19-20.
- Wan PT, Garnett MJ, Roe SM, et al; Cancer Genome Project. Mechanism of activation of the RAF-ERK signaling pathway by oncogenic mutations of B-RAF. *Cell*. 2004;116(6):855-867.
- Thomas NE. BRAF somatic mutations in malignant melanoma and melanocytic naevi. *Melanoma Res*. 2006;16(2):97-103.
- Flaherty KT, Puzanov I, Kim KB, et al. Inhibition of mutated, activated BRAF in metastatic melanoma. *N Engl J Med*. 2010;363(9):809-819.
- Haenssle HA, Kraus SL, Brehmer F, et al. Dynamic changes in nevi of a patient with melanoma treated with vemurafenib: importance of sequential dermoscopy. *Arch Dermatol*. 2012;148(10):1183-1185.
- Dalle S, Poulalhon N, Thomas L. Vemurafenib in melanoma with BRAF V600E mutation. *N Engl J Med*. 2011;365(15):1448-1450.
- Perier-Muzet M, Thomas L, Poulalhon N, et al. Melanoma patients under vemurafenib: prospective follow-up of melanocytic lesions by digital dermoscopy [published online November 7, 2013]. *J Invest Dermatol*. doi:10.1038/jid.2013.462.
- Zimmer L, Hillen U, Livingstone E, et al. Atypical melanocytic proliferations and new primary melanomas in patients with advanced melanoma undergoing selective BRAF inhibition. *J Clin Oncol*. 2012;30(19):2375-2383.
- Hofmann-Wellenhof R, Wolf P, Smolle J, Reimann-Weber A, Soyer HP, Kerl H. Influence of UVB therapy on dermoscopic features of acquired melanocytic nevi. *J Am Acad Dermatol*. 1997;37(4):559-563.
- Soyer HP, Lin LL, Prow TW. A plea for biobanking of all equivocal melanocytic proliferations. *JAMA Dermatol*. 2013;149(9):1023-1024.
- Banan P, Lin LL, Lambie D, Prow T, Soyer HP. Effects of ex vivo skin microbiopsy on histopathologic diagnosis in melanocytic skin lesions. *JAMA Dermatol*. 2013;149(9):1107-1109.
- Lin LL, Prow TW, Raphael AP, et al. Microbiopsy engineered for minimally invasive and suture-free sub-millimetre skin sampling. *F1000 Res*. 2013;2:120. doi:10.12688/f1000research.2-120.v2. <http://f1000research.com/articles/2-120/v2>. Accessed February 26, 2013.
- Tschandl P, Berghoff AS, Preusser M, et al. NRAS and BRAF mutations in melanoma-associated nevi and uninvolved nevi. *PLoS One*. 2013;8(7):e69639.
- Hatzivassiliou G, Song K, Yen I, et al. RAF inhibitors prime wild-type RAF to activate the MAPK pathway and enhance growth. *Nature*. 2010;464(7287):431-435.