

Severe Hepatic Trauma: Nonoperative Management, Definitive Repair, or Damage Control Surgery?

Ari K. Leppäniemi · Panu J. Mentula ·
Mari H. Streng · Mika P. Koivikko ·
Lauri E. Handolin

Published online: 12 October 2011
© Société Internationale de Chirurgie 2011

Abstract

Background Management of severe liver injuries has evolved to include the options for nonoperative management and damage control surgery. The present study analyzes the criteria for choosing between nonoperative management and early surgery, and definitive repair versus damage control strategy during early surgery.

Methods In a retrospective analysis of 144 patients with severe (AAST grade III–V) liver injuries (94% blunt trauma), early laparotomy was performed in 50 patients. Initial management was nonoperative in 94 blunt trauma patients with 8 failures. Uni- and multivariate analyses were used to calculate predictor odds ratios (OR) with 95% confidence intervals (CI).

Results Factors associated with early laparotomy in blunt trauma included shock on admission, associated grade IV–V splenic injury, grade IV–V head injury, and grade V liver injury. Only shock was an independent predictor (OR, 26.1; 95% CI, 8.9–77.1; $P < 0.001$). The presence of a grade IV–V splenic injury predicted damage control

strategy (OR infinite; $P = 0.021$). Failed nonoperative management was associated with grade IV–V splenic injury (OR, 14.00; 95% CI, 1.67–117.55), and shock (OR, 6.82; 95% CI, 1.49–31.29). The hospital mortality rate was 15%; 8 of 21 deaths were liver-related. Shock (OR, 9.3; 95% CI, 2.4–35.8; $P = 0.001$) and severe head injury (OR, 9.25; 95% CI, 3.0–28.9; $P = 0.000$) were independent predictors for mortality.

Conclusions In patients with severe liver injury, associated severe splenic injury favors early laparotomy and damage control strategy. Patients who arrive in shock or have an associated severe splenic injury should not be managed nonoperatively. In addition to severe head injury, uncontrollable bleeding from the liver injury is still a major cause of early death.

Introduction

The improvement in the outcome of patients with major liver injuries seen during the past 10–15 years has been attributed to the increased use of nonoperative management in hemodynamically stable patients, and early use of perihepatic packing in severely bleeding patients, including those with juxtahepatic venous injuries [1]. Approximately 70–80% of patients with blunt liver injuries are currently managed nonoperatively, and even in the severe forms of hepatic injuries the nonoperative management rate is close to 50% [2–6]. The expectant approach has been successfully extended to patients with penetrating liver injuries [7].

Major surgical procedures, such as formal hepatic resection or the use of an atriocaval shunt, have been replaced with direct vessel repair of juxtahepatic venous injuries and/or early perihepatic packing in patients with severe physiological derangement resulting in improved

Abstract presented at the 10th European Congress of Trauma and Emergency Surgery, Antalya, Turkey, May 13–17, 2009.

A. K. Leppäniemi (✉) · P. J. Mentula · M. H. Streng
Department of Abdominal Surgery, Helsinki University
Hospital, Meilahti, Haartmaninkatu 4, PO Box 340, 00029 HUS,
Finland
e-mail: ari.leppaniemi@hus.fi

M. P. Koivikko
Department of Radiology, Helsinki University Hospital, HUS,
Finland

L. E. Handolin
Department of Orthopedics and Traumatology, Helsinki
University Hospital, HUS, Finland

outcome [8–10]. Furthermore, a multidisciplinary approach utilizing hepatic angiography performed after perihepatic packing is used in some centers [11–13].

There is little controversy that hemodynamically stable patients with minor liver injuries detected and graded with computed tomography (CT), and not having associated injuries requiring surgical repair, can safely be managed nonoperatively. Some patients require hepatic angioembolization to control bleeding from intrahepatic arterial injuries [14]. There is, however, significant variability in the management of severe or complex liver injuries (defined as American Association for the Surgery of Trauma Organ Injury Scale grade III–V liver injuries) [15]. Although some advocate a liberal use of surgical interventions, including liver resection, good results managing these injuries nonoperatively also have been reported [16–21].

The key clinical decision-making points include patient selection for initially nonoperative management, identification of patients who require delayed surgery after initial trial of nonoperative management, and intraoperative decision making between definitive repair of the liver injury and a damage control strategy. The purpose of this study was to identify factors associated with those three key decisions in patients with severe liver injuries.

Patients and methods

A retrospective analysis of patients with liver injuries treated at the Töölö and Meilahti hospitals of the University of Helsinki during a 10-year period (1997–2006) was conducted. Both hospitals are equivalent to level I trauma centers and have trauma teams led by senior surgical residents (hepatobiliary experience gained during common trunk training period and rotation through the liver surgery unit), with CT and angioembolization capabilities available around the clock. Both hospitals have standardized, algorithm-based evaluation (separate for blunt trauma, stab wounds, and gunshot wounds) and resuscitation and blood product use protocols.

The grade of the liver injury was determined from the CT scans reviewed by an independent radiologist (MK) or from operative notes. Only patients with severe (American Association for the Surgery of Trauma Organ Injury Scale grade III–V) liver injuries were included in the analysis [15].

A total of 144 patients with grade III–V liver injuries were identified. Their clinical characteristics are summarized in Table 1. Preoperative shock was defined as systolic blood pressure <90 mmHg on admission. Of the patients with associated injuries, there were 51 patients (35%) with an associated head injury (44 with grade III–V injuries),

Table 1 Clinical characteristics of 144 patients with severe liver injuries

Mean (range) age	33 (10–78) years
Female:male	57:87
Blunt trauma	135 (94%)
Transferred from another hospital	32 (22%)
Shock on admission	56 (39%)
Focused abdominal sonography for trauma	112 (78%)
Computed tomography	125 (87%)
Associated injuries	119 (83%)
Mean (SD) Injury Severity Score	31 (15) score points
Mean (SD) New Injury Severity Score	35 (16) score points

Unless stated otherwise, the number represents the number of patients (%)

45 (31%) with an associated renal injury (26 with grade III–V), and 35 (24%) with an associated splenic injury (15 grade III–V), respectively. The Injury Severity Score (ISS) [22] and the New Injury Severity Score (NISS) [23] were calculated from the hospital records. The mean (range) units of packed red blood cells, fresh frozen plasma, and platelets transfused within the first 24 h were 15 (range, 0–110), 6 (range, 0–55), and 8 (range, 0–64), respectively.

Early laparotomy was defined as selection of operative management as the initial option with a laparotomy performed within 12 h from admission. The 12-h cutoff point was chosen empirically based on clinically practical subgroup allocation. Failed nonoperative management was defined as laparotomy performed after initial selection of nonoperative management as the treatment option.

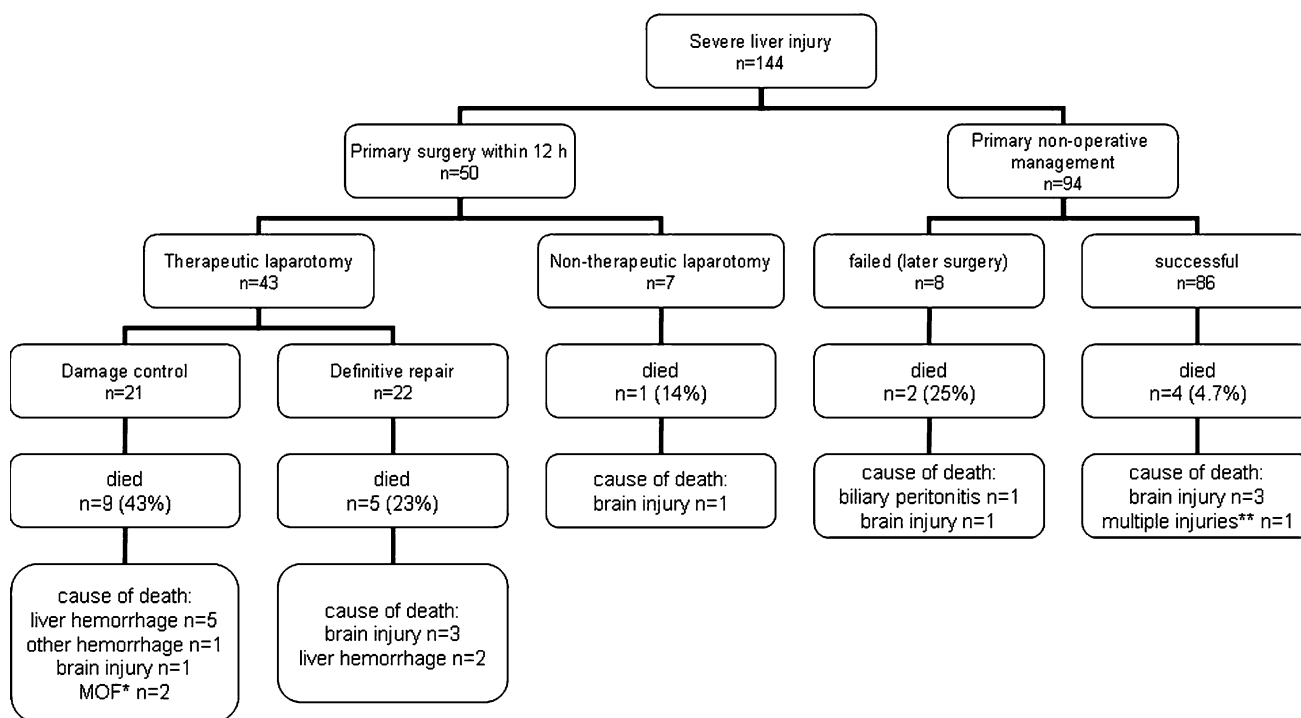
The statistical analysis was performed using statistical software (SPSS Statistics 17.0.; SPSS Inc., Chicago, IL). For univariate analysis, odds ratios with 95% confidence intervals were calculated for the predictors. Fisher's exact test was used in comparisons of proportions. Stepwise forward logistic regression was used for multivariate analysis to find independent predictors.

Results

There were 58 patients (40%) with grade III, 66 (46%) with grade IV, and 20 (14%) with grade V liver injuries. The management and outcome of patients is summarized in Fig. 1.

Early laparotomy

Fifty patients (35%) underwent early laparotomy with a median (interquartile range, IQR) delay from admission of 4 (2–7) h. Only two patients were operated on between 8 and 12 h after admission and none within 12–16 h.



* cause of MOF was not related to liver injury
 **brain injury and hemorrhage from pelvic fracture

Fig. 1 Management and outcome of 144 patients with severe liver injuries

Because of a standard management protocol of mandatory laparotomy for patients with penetrating injuries and demonstrated peritoneal violation, all nine patients with penetrating injuries (6 stab wounds, 2 gunshot wounds, 1 shotgun wound) underwent early laparotomy. Five of the 32 transferred patients underwent perihepatic packing in another hospital before transfer. Of the 135 patients with blunt trauma, early laparotomy was performed in 41 (30%) patients. The factors that predicted early laparotomy in blunt trauma patients for univariate analysis are presented in Table 2. For multivariate analysis, only shock on admission (odds ratio (OR), 26.1; 95% confidence interval (CI), 8.9–77.1; $P < 0.001$) was an independent predictor of early laparotomy.

Of the 43 patients subjected to early laparotomy and a therapeutic procedure to the liver (Fig. 1), 21 underwent a damage control procedure (perihepatic packing) and 22 underwent definitive repair. The principal procedures and their effectiveness to control hepatic hemorrhage are listed in Table 3. Of the 35 patients with splenic injuries, 12 underwent early laparotomy. Splenectomy was performed in ten patients and splenic salvage with partial splenectomy in two; one of them required subsequent splenectomy for continuous bleeding. One nonoperatively managed patient with splenic injury underwent successful angioembolization. In a univariate analysis, only the presence of an

Table 2 Predictive factors for early laparotomy in patients with Grade III–V liver injury (univariate analysis)

Factor	Odds ratio	95% Confidence interval
Shock on admission	30.72	11.00–85.8
Splenic injury grade IV–V	3.86	1.026–14.5
Head injury grade IV–V	3.54	1.46–8.59
Liver injury grade V	3.5	1.2–10.17
Multiple injury	3	0.83–10.82
Liver injury grade IV–V	0.92	0.43–1.93
Renal injury grade IV–V	0.82	0.24–2.73

associated grade IV–V splenic injury predicted damage control laparotomy. In fact all patients with grade IV–V splenic injuries underwent damage control laparotomy vs. 42% of those without ($P = 0.021$). Shock on admission, grade of the liver injury (IV–V or V only), multiple trauma, or massive blood transfusion was not predictive of damage control laparotomy.

Seven patients underwent early laparotomy but required no procedure to manage the liver injury (Fig. 1). The presence of a grade IV–V renal injury (OR, 24.8; 95% CI, 2.10–298.5) was the only predictor for no liver procedure at early laparotomy.

Table 3 Surgical procedures (only main procedure listed) and their effectiveness in controlling hepatic hemorrhage in 43 patients managed with early laparotomy for severe hepatic injury

Surgical procedure	No. of patients	Unsuccessful
Damage control	21	5
Perihepatic packing	20	5
Intrahepatic balloon tamponade	1	–
Definitive hepatic repair	22	2
Deep liver sutures	12	–
Topical hemostat	1	–
Ligation of right hepatic artery	2	–
Hepatotomy and hepatic vein repair	1	–
Nonanatomic sublobar resection	5	1
Nonanatomic lobectomy	2	1

Nonoperative management

The initial management strategy was nonoperative in 94 patients, all with blunt trauma. Fifteen patients arriving in shock responded to fluid resuscitation and underwent CT scan evaluation and nonoperative management. The nonoperative management rate was 69% for blunt grade III, 77% for grade IV, and 44% for grade V liver injuries. Hepatic angiography as an adjunct to nonoperative management was used in only one patient. Nonoperative management was considered a failure in 8 of 94 patients (9%; Fig. 1) who underwent a delayed laparotomy after a median delay from injury of 52 (IQR, 30–89) h. The reasons for failed nonoperative management were liver-related in three (continuous bleeding from the liver in 2; 1 of them had also a small-bowel perforation; biliary peritonitis in 1), bleeding from the spleen in two, duodenal perforation in one, hemoperitoneum without active bleeding in one, and a false suspicion of active bleeding in the CT scan in one patient, respectively. The predictive factors in univariate analysis for failed nonoperative management are presented in Table 4. Because of the small number of patients ($N = 8$), a multivariate analysis could not be performed. Overall, there were four patients with a grade IV–V splenic injury and 15 patients with shock on admission that underwent primary nonoperative management.

Outcome

The overall hospital mortality rate was 21 of 144 (15%). The principal cause of death was brain injury in nine, uncontrollable bleeding from the liver in seven, multiple organ failure in two, biliary peritonitis (hepatic injury initially managed nonoperatively, died of septic shock), multiple injuries, and multiple bleeding sources in one

Table 4 Predictive factors for failed nonoperative management in patients with grade III–V liver injury (univariate analysis)

Factor	Odds ratio	95% Confidence interval
Splenic injury grade IV–V	14	1.67–117.55
Shock on admission	6.82	1.49–31.29
Renal injury grade IV–V	2.85	0.5–16.3
Multiple injury	1.72	0.2–14.98
Head injury grade IV–V	0.97	0.11–8.69
Liver injury grade IV–V	0.62	0.15–2.66

Table 5 Predictive factors for hospital mortality in patients with grade III–V liver injury (univariate analysis)

Factor	Odds ratio	95% Confidence interval
Head injury grade IV–V	13.75	4.8–39.36
Shock on admission	13.42	3.73–48.3
Laparotomy	8.5	2.69–26.9
Nontransfer patient	6.74	0.87–52.31
Damage control laparotomy	6.35	2.25–17.92
Laparotomy within 12 h	6.29	2.26–17.51
Multiple injury	4.85	0.62–37.94
Liver injury grade V	3.11	1.04–9.34
Splenic injury grade IV–V	2.76	0.65–11.67
Penetrating injury	1.74	0.34–9.03
Renal injury grade IV–V	0.89	0.19–4.27
Liver injury grade IV–V	0.88	0.35–2.25

patient each (Fig. 1). Nine of the 21 damage control patients (43%) died; 5 of them were from uncontrollable hepatic parenchymal or juxtahepatic venous bleeding after attempted perihepatic packing. Among 22 patients who underwent an attempt of definitive hepatic repair, hepatic hemostasis could not be achieved in two patients managed with nonanatomic right lobectomy (shotgun wound) and nonanatomic resection of a part of the right lobe (blunt trauma), respectively (Table 3). Thus, the hepatic injury was a significant contributor to death in eight fatally injured patients (38%) with an overall hepatic mortality rate of 8 of 144 (6%).

The predictors for death in univariate analysis are presented in Table 5. In a forward conditional logistic regression analysis, the independent predictors for mortality were shock on admission (OR, 9.3; 95% CI, 2.4–35.8; $P = 0.001$) and the presence of a grade IV–V head injury (OR, 9.25; 95% CI, 3.0–28.9; $P = 0$).

The overall complication rate after initial operative management was 29 of 50 (58%), and it was 16 of 94 (17%) in patients who underwent initial nonoperative management. The most common abdominal complications were postoperative abscess ($n = 3$), postoperative

hemorrhage ($n = 3$), wound dehiscence ($n = 3$), and prolonged ileus ($n = 2$). Biliary peritonitis and necrosis of the gallbladder were observed in one patient each. A total of 23 patients—2 of them were among the failed nonoperative management group—underwent 37 reoperations. Liver resection at reoperation was performed in three patients, and one patient underwent a hepatic transplantation.

The median hospital length of stay in 50 patients who underwent early laparotomy was 16 (IQR, 5–29) days and 10 (IQR, 7–14) days in 94 nonoperatively managed patients ($P = 0.29$).

Discussion

In this series of 144 patients with severe liver injuries, 94 of 135 (70%) blunt trauma patients were initially managed nonoperatively with a failure rate of 9%. Currently, the nonoperative management rate in blunt hepatic trauma is more than 80% and is in most cases based on the evaluation of hemodynamic stability of the patient and early CT scan evaluation of the presence and severity of abdominal organ injuries [24–28]. Several studies have shown that nonoperative management is safe for hemodynamically stable patients with blunt liver injury regardless of the injury severity, and even complex liver injuries (grade III–V) can be successfully managed without surgery [2, 3, 6, 10, 19–21].

In this study, shock on admission was associated with the need of early laparotomy as well as failure of nonoperative management (Tables 2, 4). Overall, 15 patients who arrived in shock responded to fluid resuscitation and underwent CT scan evaluation and nonoperative management. The anatomical severity of the liver injury did not predict the need for early laparotomy or failure of nonoperative management, whereas the presence of an associated severe splenic injury (Tables 2, 4) was predictive for both.

In a study of 214 patients with a hepatic injury as the sole or principal injury and undergoing CT evaluation with a 86% nonoperative management rate, the independent predictors for the need of operative treatment included intraperitoneal contrast extravasation and hemoperitoneum in six compartments [16]. The anatomic grading system based on CT is less accurate in predicting the need for intervention [29]. In a prospective study of 112 patients managed nonoperatively, 12 patients (11%) required delayed surgery: 5 for liver-related and 7 for non-liver-related causes, respectively. Low systolic blood pressure on admission was associated with failed nonoperative management, whereas CT finding did not predict failure [2]. In another study with 55 patients managed nonoperatively, all 8 failures (15%) were unrelated to the liver injury [3]. Nonoperative management failed in eight patients in our series, but it is noteworthy that only three of them were liver-related.

It appears that clinical and radiological signs of active bleeding warrant early laparotomy, especially in the presence of an associated severe splenic trauma. Although angioembolization is frequently used in our hospitals in hemodynamically stable patients with splenic injury (and contrast blush on CT) and bleeding from pelvic fractures, the use of hepatic angioembolization is less common (only one patient in this series), probably due to our active surgical management policy and not using angiographic evaluation routinely after perihepatic packing.

The presence of an associated hollow viscus injury is difficult to diagnose but fortunately rare: 2 of 94 (2%) in this study. In a prospective study of 206 patients with blunt solid abdominal organ injuries, of which 72% were managed nonoperatively, intestinal injury was detected in only one patient initially managed nonoperatively [30].

Of the 50 patients who underwent early laparotomy in this series, 21 (42%) required a damage control approach with perihepatic packing as the main hepatic hemostatic procedure (Fig. 1). The presence of an associated severe splenic injury was a strong predictor for the need of a damage control approach, whereas shock on admission, severity of the liver injury, multiple trauma, or massive transfusion were not. Overall 9 of the 21 damage control patients (43%) died, 5 of them as a result of uncontrollable hepatic parenchymal or juxtahepatic venous bleeding.

Perihepatic packing is needed to control hepatic bleeding in patients with a compromised physiological stage in approximately 60% in patients with high-grade liver injuries [12]. In the past, atriocaval shunts were advocated for injuries of the retrohepatic part of the inferior vena cava, but because of the poor results, shunts have been replaced with perihepatic packing as a first-line treatment of juxtahepatic venous injuries. The survival rate using atriocaval shunt is approximately 9% compared with 62% after packing and 42% after direct repair [1].

The retrospective nature of this study limits the possibilities to pinpoint accurately the reasons for “failed” perihepatic packing in the five patients who died from uncontrollable bleeding from the liver. It is possible that some of the patients were already so coagulopathic, acidotic, and hypothermic that the condition could not be reversed by surgical intervention. However, the decision to select a damage control strategy in patients with combined severe hepatic and splenic injury seems justified.

Liver resection as a form of definitive repair was used in seven patients in this series. In most cases, definitive hemostasis can be achieved with simpler surgical techniques, such as suturing, topical hemostats, use of an omental flap or hepatotomy, and selective vascular ligation [1, 31]. In severe liver injuries, however, resection can sometimes be the best hemostatic method with the additional benefit of removing nonviable liver tissue.

Resectional debridement is used mostly in grade IV injuries to remove devitalized liver and achieve hemostasis [32, 33]. In a series of 216 patients with grade III–V liver injuries, 26% underwent liver resection with overall and liver-related mortality rates of 18 and 9% [17]. Compared with deep liver sutures, it is associated with lower mortality, smaller risk of recurrent bleeding, less blood transfusions, and fewer reoperations for hepatic complications [34].

The hospital mortality rate in this series was 15%, but only 8 of 21 deaths were liver-related. Shock on admission and the presence of an associated severe head injury were independent predictors of death (Table 5). In a series of 210 patients with grade III–V hepatic injuries, the overall and liver-related mortality rates were 46 and 30%, respectively [32]. The predictive factors for mortality in grade IV–V injuries are related to severe bleeding and include blood loss, number of packed red cell units transfused, hypothermia, acidosis, and dysrhythmia [12]. In a series of 183 patients with blunt liver injuries, the overall mortality rate was 17% and liver-related mortality rate was 5%. Nine of the 31 deaths were liver-related and caused by exsanguination in 8 and sepsis and multiple organ failure in 1 patient. Ten deaths were caused by exsanguination from associated abdominal vascular, solid organ, and thoracic injuries. Twelve deaths occurred in the late phase and were caused by severe cerebral edema in seven, fatal pulmonary embolism in four, and sepsis and multiple organ failure in one patient [5]. The importance of an associated severe head injury in the prognosis of these patients was confirmed in this study (Table 5).

Conclusions

In patients with severe liver injury, hemodynamic instability or signs of continuous bleeding warrant an early laparotomy. The presence of an associated severe splenic injury favors the use of damage control surgical strategy and predicts failure of nonoperative management. In stable patients without major associated injuries, liver resection should not be discarded as an option to manage complex liver injuries.

References

- Richardson JD, Franklin GA, Lukan JK et al (2000) Evolution in the management of hepatic trauma: a 25-year perspective. *Ann Surg* 232:324–330
- Croce MA, Fabian TC, Menke PG et al (1995) Nonoperative management of blunt hepatic trauma is the treatment of choice for hemodynamically stable patients. *Ann Surg* 221:744–753
- Velmahos GC, Toutouzas K, Radin R et al (2003) High success with nonoperative management of blunt hepatic trauma. *Arch Surg* 138:475–481
- Kozar RA, Moore JB, Niles SE et al (2005) Complications of nonoperative management of high-grade blunt hepatic injuries. *J Trauma* 59:1066–1071
- Schnuriger B, Inderbitzin D, Schafer M et al (2009) Concomitant injuries are an important determinant of outcome of high-grade blunt hepatic trauma. *Br J Surg* 96:104–110
- Duane TM, Como JJ, Bochicchio GV et al (2004) Reevaluating the management and outcomes of severe blunt liver injury. *J Trauma* 57:494–500
- Omoshoro-Jones JAO, Nicol AJ, Navsaria PH et al (2005) Selective non-operative management of liver gunshot injuries. *Br J Surg* 92:890–895
- Gao JM, Du DY, Zhao XJ et al (2003) Liver trauma: experience in 348 cases. *World J Surg* 27:703–708. doi:10.1007/s00268-003-6573-z
- Nicol AJ, Hommes M, Primrose R et al (2007) Packing for control of hemorrhage in major liver trauma. *World J Surg* 31:569–574. doi:10.1007/s00268-006-0070-0
- Ramkumar K, Perera MTPR, Marudanayagam R et al (2010) A reaudit of specialist-managed liver trauma after establishment of regional referral and management guidelines. *J Trauma* 68:84–89
- Mackenzie S, Kortbeek JB, Mulloy R et al (2004) Recent experiences with a multidisciplinary approach to complex hepatic trauma. *Injury* 35:869–877
- Asensio JA, Petrone P, Garcia-Nunez L et al (2007) Multidisciplinary approach for the management of complex hepatic injuries AAST-OIS Grades IV–V: a prospective study. *Scand J Surg* 96:214–220
- Johnson JW, Gracias VH, Gupta R et al (2002) Hepatic angiography in patients undergoing damage control laparotomy. *J Trauma* 52:1102–1106
- Misselbeck TS, Teicher EJ, Cipolle MD et al (2009) Hepatic angioembolization in trauma patients: indications and complications. *J Trauma* 67:769–773
- Moore EE, Cogbill TH, Jurkovich GJ et al (1995) Organ injury scaling: spleen and liver (1994 revision). *J Trauma* 38:323–324
- Fang JF, Wong YC, Lin BC et al (2006) The CT risk factors for the need of operative treatment in initially hemodynamically stable patients after blunt hepatic trauma. *J Trauma* 61:547–554
- Polanco P, Leon S, Pineda J et al (2008) Hepatic resection in the management of complex injury to the liver. *J Trauma* 65:1264–1270
- Asensio JA, Roldan G, Petrone P et al (2003) Operative management and outcomes in 103 AAST-OIS Grades IV and V complex hepatic injuries: trauma surgeons still need to operate, but angioembolization helps. *J Trauma* 54:647–654
- Pachter HL, Knudson MM, Esrig B et al (1996) Status of nonoperative management of blunt hepatic injuries in 1995: a multicenter experience with 404 patients. *J Trauma* 40:31–38
- Christmas AB, Wilson AK, Manning B et al (2005) Selective management of blunt hepatic injuries including nonoperative management is a safe and effective strategy. *Surgery* 138:606–611
- Srinivasan T, Wig JD, Gupta R et al (2008) Complex hepatic injuries: an audit from a tertiary center. *Eur J Trauma Emerg Surg* 34:287–293
- Baker SP, O'Neill B (1976) The Injury Severity Score: an update. *J Trauma* 16:882–885
- Osler T, Baker SP, Long W (1997) A modification of the Injury Severity Score that both improves accuracy and simplifies scoring. *J Trauma* 43:922–926

24. Meyer AA, Crass RA, Lim RC Jr et al (1985) Selective nonoperative management of blunt liver injury using computed tomography. *Arch Surg* 120:550–554
25. Farnell MB, Spencer MP, Thompson E et al (1998) Nonoperative management of blunt hepatic trauma in adults. *Surgery* 104:748–756
26. Hiatt JR, Harrier HD, Koenig BV et al (1990) Nonoperative management of major blunt liver injury with hemoperitoneum. *Arch Surg* 125:101–103
27. Federico JA, Horner WR, Clark DE et al (1990) Blunt hepatic trauma. Nonoperative management in adults. *Arch Surg* 125:908–909
28. Kozar RA, Moore FA, Moore EE et al (2009) Western Trauma Association critical decisions in trauma: nonoperative management of adult blunt hepatic trauma. *J Trauma* 67:1144–1149
29. Cohn SM, Arango JI, Myers JG et al (2009) Computed tomography grading systems poorly predict the need for intervention after spleen and liver injuries. *Am Surg* 75:133–139
30. Velmahos GC, Toutouzas K, Radin R et al (2003) Nonoperative treatment of blunt injury to solid abdominal organs. A prospective study. *Arch Surg* 138:844–851
31. Pachter HL, Spencer FC, Hofstetter SR et al (1983) Experience with the finger fracture technique to achieve intra-hepatic hemostasis in 75 patients with severe injuries of the liver. *Ann Surg* 197:771–778
32. Cogbill TH, Moore EE, Jurkovich GJ et al (1988) Severe hepatic trauma: a multi-center experience with 1,335 liver injuries. *J Trauma* 28:1433–1438
33. Hollands MJ, Little JM (1990) The role of hepatic resection in the management of blunt liver trauma. *World J Surg* 14:478–482. doi:[10.1007/BF01658671](https://doi.org/10.1007/BF01658671)
34. Leppäniemi A (1988) Blunt liver injuries. Resection vs. nonresection for primary hemostasis. *Acta Chir Scand* 154:371–374