

Loss of Chromosome Y in Prostatic Cancer Cells, but not in Stromal Tissue

Loss of the Y chromosome has been seen in a variety of human neoplasms [1]. Whether it has diagnostic or prognostic significance is at present not clear. The loss of this chromosome has been detected by means of metaphase techniques, for which culturing is needed, and by in situ hybridization (ISH) to interphase preparations [1], and, e.g., [2].

In a recent paper in this journal, loss of the Y chromosome was described in tissue cultures of gastric cancer cells by Castedo et al. [3]. This was compared with interphase ISH results in another study [2]. The suggestion was made that the Y-deficient cells were of stromal, and not of neoplastic origin. It was hypothesized that stromal cells without the Y chromosome could comply better with cancerous growth requirements. The authors pointed out that ISH to gastric tumor tissue sections could reveal significant data in this respect.

We have been using interphase ISH to routinely process tissue sections of solid tumors for the numerical analysis of specific chromosomes [4]. Recently, a prostatic adenocarcinoma was seen with loss of chromosome Y in neoplastic cells,

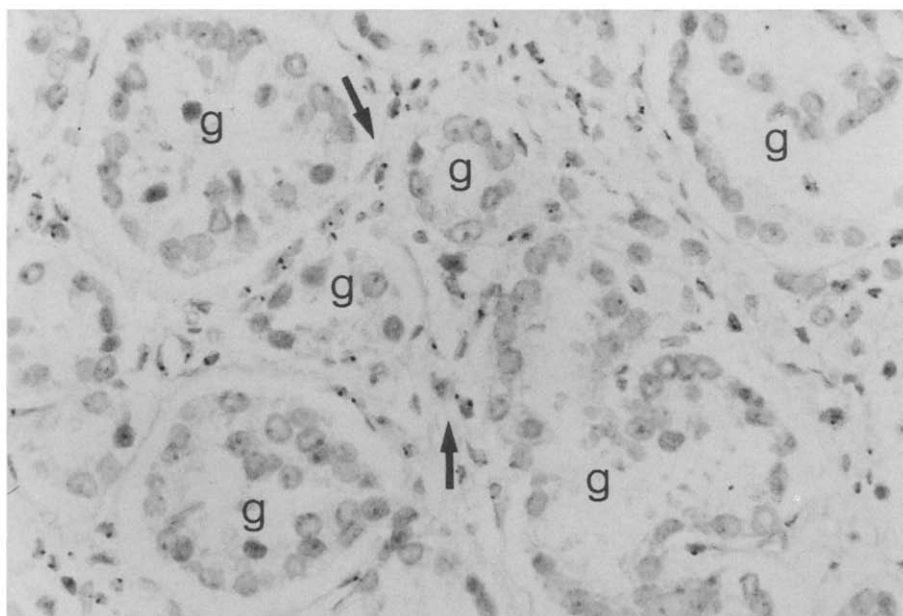
but not in the stromal cells (fibroblasts, endothelium, leukocytes, nerve cell nuclei, etc.). Also, hyperplastic and normal prostatic epithelium contained a chromosome Y-related ISH signal. In Figure 1, a part of this tumor is shown (Gleason Grade 2 area). The differences between the Y-bearing stromal cells and the Y-lacking cancer cell nuclei is obvious.

Our conclusion is that loss of chromosome Y in stromal tissue components was not required for these cells to proliferate with the neoplastic cells in this prostate tumor. Further, Y-loss was restricted to the cancer cells. This sheds some light on cytogenetic findings of cancer cell cultures and ISH results of tumor cell suspensions [2, 3]. It might be that the above-described phenomenon could vary in malignancies of different histologies. However, the investigation of issues of this (and other) nature can very well be addressed by interphase in situ hybridization of histologic sections.

HERMAN VAN DEKKEN
JANNEKE ALERS

Department of Pathology
Erasmus University Rotterdam
P.O. Box 1738
3000 DR Rotterdam
The Netherlands

Figure 1 In situ hybridization with the chromosome Y-specific alpha-satellite DNA probe to a 4- μ m section of a prostatic adenocarcinoma. The ISH spots were visualized with immunoperoxidase/DAB (black); hematoxylin was used as a counterstain (grey). Y chromosome-related signals can be seen in the stromal cell nuclei (some are arrowed), but not in the prostatic glands (marked G; 40 \times objective). Control hybridizations with autosomal aliphoid DNA probes revealed signals in stromal and prostatic tumor cell types.



REFERENCES

1. Sandberg AA (1990): *The Chromosomes in Human Cancer and Leukemia*, 2nd Ed. Elsevier, New York.
2. Van Dekken H, Pizzolo JG, Kelsen DP, Melamed MR (1990): Targeted cytogenetic analysis of gastric tumors by in situ hybridization with a set of chromosome specific DNA probes. *Cancer* 66:491-497.
3. Castedo S, Correia C, Gomes P, Seruca R, Soares P, Carneiro F, Sobrinho-Simoes M (1992): Loss of Y chromosome in gastric carcinoma. Fact or artifact? *Cancer Genet Cytogenet* 61:39-41.
4. Van Dekken H, Kerstens HMJ, Tersteeg TA, Vorhofstad AAJ, Vooijs GP (1992): Histological preservation after in situ hybridization to archival solid tumour sections allows discrimination of cells bearing numerical chromosome changes. *J Pathol*, in press.