



ELSEVIER

Netherlands Journal of Medicine 46 (1995) 25–29

The Netherlands
JOURNAL OF
MEDICINE

Brief report

Phagocytic plasma cells in a patient with multiple myeloma

P.M. Vanhagen^{a,b,*}, K. de Leeuw^c, A. Hagemeijer^d, B. Löwenberg^c^a Department of Immunology, Dijkzigt University Hospital, Dr. Molewaterplein 40,
3015 GD Rotterdam, Netherlands^b Department of Internal Medicine III, Dijkzigt University Hospital, Dijkzigt University Hospital, Dr. Molewaterplein 40,
3015 GD Rotterdam, Netherlands^c Department of Haematology, Dijkzigt University Hospital, Dr. Molewaterplein 40, 3015 GD Rotterdam, Netherlands^d Department of Cell Biology and Genetics, Dijkzigt University Hospital, Dr. Molewaterplein 40, 3015 GD Rotterdam, Netherlands

Received 19 November 1993; revision received 6 April 1994; accepted 7 April 1994

Abstract

Phagocytosis of blood cells by malignant plasma cells in multiple myeloma is an extremely rare condition. Here we present a 39-year-old woman with multiple myeloma. Bone marrow smear showed an extensive phagocytosis of erythrocytes and platelets by myeloma cells.

Keywords: Multiple myeloma; Phagocytic plasma cells

1. Introduction

Several reports have been published concerning the phenomenon of phagocytic plasma cells [1–11]. In the majority of cases the patients had myelomatosis or a “monoclonal gammopathy of undetermined significance”. Phagocytosis is morphologically very characteristic but remains a rare phenomenon.

Here, we describe a 39-year-old woman of Hindu origin, with Stage IIIA multiple myeloma and evident cytological signs of extensive phagocytosis of erythrocytes, platelets and occasionally polynuclear granulocytes and normoblasts by malignant plasma cells. We were able to characterize phagocytosis throughout the disease.

2. Case report

The patient consulted the Ear, Nose and Throat (ENT) department with pain in the throat. These symptoms resolved following treatment with antibiotics. In 1 month she had lost 5 kg body weight. Medical history and physical examination were otherwise unremarkable.

Laboratory results: erythrocyte sedimentation rate (ESR) 138 mm (after 1 h); haemoglobin 6.3 mmol/l; MCV 95 fl; platelets $139 \times 10^9/l$; white blood cell count $3.7 \times 10^9/l$; normal peripheral blood differential; bilirubin, liver enzymes, creatinine and urea normal; calcium 2.41 mmol/l; albumin 34 g/l and protein 108 g/l; serum immunoelectrophoresis revealed an IgG- λ paraprotein. Quantitative immunoglobulin determinations showed IgG 70.7 g/l, IgA 0.25 g/l, and IgM 0.29 g/l. Urinary electrophoresis demonstrated free

* Corresponding author.

λ -chains. Cytological examination of the bone marrow aspirate demonstrated 40% plasma cells, some with an atypical morphology. Considerable numbers of the plasma cells showed abundant vacuolization and phagocytosis of erythrocytes, platelets and occasionally polynuclear granulocytes and normoblasts (Figs. 1 and 2). Bone marrow biopsy showed numerous atypical plasma cells and fibrosis. Cytoplasmic immunofluorescence demonstrated that 99% of the plasma cells in the bone marrow were IgG- λ -positive. The phagocytic plasma cells showed non-fluorescent vacuoles confirming that these vacuoles did not contain immunoglobulins (Figs. 3 and 4).

There were no indications of haemolytic




Fig. 1. Erythrophagocytosis by a plasma cell with two nuclei.

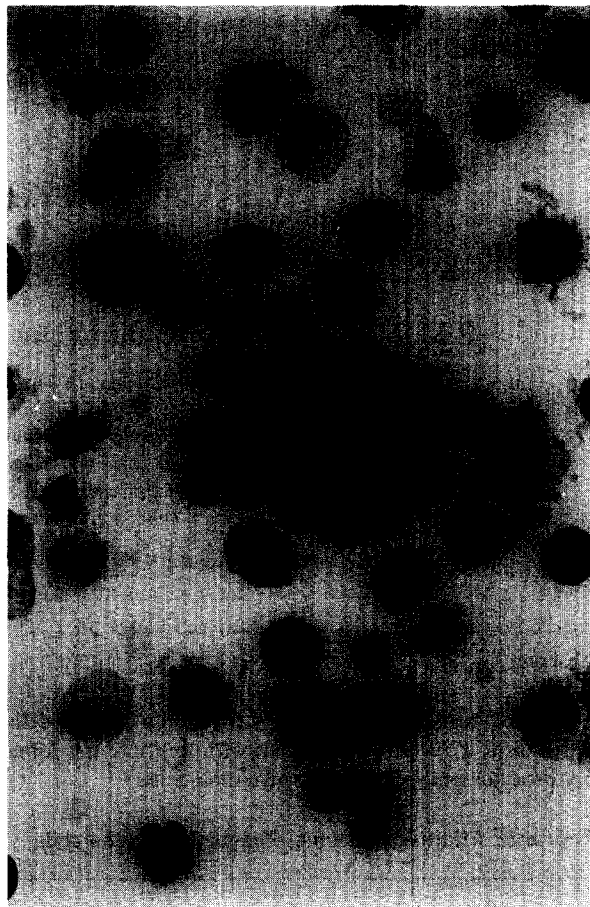


Fig. 2. Phagocytosis of a granular leukocyte, a normoblast and possibly a lymphocyte by a myeloma cell.


anaemia or diffuse intravascular coagulation as described in previous studies [10,11]. The phagocytic cells were negative for TdT. Cytochemical investigation showed neither esterase nor peroxidase activity. The IgG synthesis rate was 12.6 pg/plasma cell/24 h and was linear during this culture period. The immunoglobulin synthesis rate in myeloma cells in our laboratory varied between 5.0 and 50.0 pg/plasma cell/24 h. The DNA index was 3.0 (normal range 2.8–3.5).

X-ray skeletal survey revealed lytic spots in the left third rib and sternum, and radionuclide bone scan demonstrated high activity at these sites. The diagnosis multiple myeloma Stage IIIA [12]

was made based on clinical observations [12] as well as by measurement of the tumor mass (2.1×10^{12} myeloma cells) [13]. Therapy was started with prednisone and melphalan. The presence of phagocytizing plasma cells in the bone marrow was confirmed at subsequent occasions when the patient was followed up.

Cytogenetics: Bone marrow aspirate was obtained 3 months after the start of therapy and cultured for 1–4 days according to standard procedures: 63 metaphases were karyotyped using R- and Q-banding techniques. The metaphases obtained after 1, 2, and 3 days of culture were

mainly of myeloid origin, showing a normal karyotype ($n = 47$). The majority of cells karyotyped after 4 days in culture were abnormal pseudodiploid ($n = 12$) or hypotetraploid ($n = 4$) with a modal chromosome number of 85 and similar markers as in the pseudodiploid clone. The following aberrations were seen in all 16 abnormal cells: $du(1)(q12q44)$, -13 , $del(15)(q24 \text{ or } 25)$, $16q-$, $+21$. Additional structural changes were present in some cells: $del(1)(p21p32)(3 \times)$, $t(1q::3p)(5 \times)$, $del(13)(q14?) (3 \times)$, $14q+ (4 \times)$, $20q- (4 \times)$, $+22(3 \times)$ as well as incidental non-clonal breaks and re-arrangements.



Figs. 3 and 4. Phagosomes in IgG- and λ -positive plasma cells.

3. Discussion

Granulocytes, monocytes, macrophages and cells from the reticulo-endothelial system normally express the ability of phagocytosis. Plasma cells, the producers of the immunoglobulins, normally do not express phagocytic functions. However, a few reports have indicated that on rare occasions normal B-lymphocytes may possess the capacity to incorporate latex particles, red blood cells and micro-organisms [14–16]. Hairy cells have been reported to have selective phagocytic capability with respect to latex particles and zymosan [17,18]. In vitro phagocytosis has also, although highly infrequently, been described in leukaemic cells of B-chronic lymphocytic leukaemia and B-lymphocytic leukaemia [19,20]. Myeloma cells have been shown to internalize horseradish peroxidase (HRP), a marker of fluid-phase endocytosis, and cationized ferritin (CF), a tracer of absorptive endocytosis, after incubation in vitro [21]. HRP products were observed in the lysosomes and CF on the cell surface, rough endoplasmic reticulum and in the Golgi complex. These observations suggest that fluid phase endocytosis and membrane traffic may occur in myeloma cells [21]. Nevertheless, in vivo, phagocytic activity in human lymphoproliferative disorders has only been found in exceptional cases. Reports concerned with phagocytic plasma cells have nearly always been in association with multiple myeloma [1–11,21]. The age and sex distribution of patients with multiple myeloma that is characterized by phagocytic plasma cells appear to be comparable with multiple myeloma in general. The proportion of myeloma cells in peripheral blood slides exceeded 5% in 5 of 17 patients. The immunoglobulin class and type of M-component have no distinct characteristics [5]. Phagocytosis of erythrocytes, normoblasts, polynuclear granulocytes and even a few cases of phagocytosis of lymphocytes have been reported. Apparently, in most cases a high percentage of the plasma cells were vacuolated, suggesting the formation of phagosomes. The percentage of phagocytic cells in myeloma cells described in the literature has varied between 0.2 and 36% [5]. The pathogenesis of phagocytosis by myeloma

cells remains unresolved. Possible explanations, e.g. the relationship between the phagocytic phenomenon and the malignant transformation of these cells, still lack experimental evidence.

References

- [1] Abramson N, Kapff C, Ginsburg AD. The phagocytic plasma cells. *N Engl J Med* 1970;30:248–250.
- [2] Fitch JH, Lee S. Phagocytic myeloma cells. *Am Soc Clin Pathol* 1979;71:722–723.
- [3] Ben Lin Hom. Phagocytic plasma cells and Russel bodies in monoclonal gammopathy of undetermined significance. *Acta Haematol* 1986;75:178–180.
- [4] Ben Lin Hom, Olsen CL. Phagocytic plasma cells in patients with multiple myeloma. *Am J Clin Pathol* 1984; 81:689–690.
- [5] Kanoh T, Fujii H. Phagocytic myeloma cells. Report of a case and review of the literature. *Am J Clin Pathol* 1985; 84:121–124.
- [6] Kanoh T, Fujii H. The incidence of phagocytizing plasma cells in malignant plasma cell dyscrasias. *Scand J Haematol* 1985;36:480–483.
- [7] Kanoh T, Hishitani Y. Phagocytic myeloma cells. *Am J Clin Pathol* 1985;84:647.
- [8] Ludwig H, Pavelka M. Phagocytic plasma cells in a patient with multiple myeloma. *Blood* 1980;56(2):173–176.
- [9] Wirt PD, Grogan C, et al. Phagocytic, lambda chain, Plasma cell myeloma. *Am J Clin Pathol* 1983;80:1983.
- [10] Matsuzaki H, Hata H, Watanabe T, Takeya M, Takatsuki K. Phagocytic multiple myeloma with disseminated intravascular coagulation. *Acta Haematol* 1989;82:91–94.
- [11] Raman S, Frame B, et al. Diffuse nonsecretory osteosclerotic myeloma with extensive erythrophagocytosis. *Am J Clin Pathol* 1983;80:84–88.
- [12] Durie BGM, Salmon SE. A clinical staging system for multiple myeloma. *Cancer* 1975;36:842–854.
- [13] Salmon SE, Smith BA. Immunoglobulin synthesis and total body tumor cell number in IgG multiple myeloma. *J Clin Invest* 1970;49:1114–1121.
- [14] Hughes NR. Erythrocyte phagocytosis by human lymphocytes. *Nature* 1966;212:1575.
- [15] Fu SM, Winchester RJ, Rai UR, Kunkel HG. Hairy cell leukaemia: proliferation of a cell with phagocytic and B-lymphocyte properties. *Scand J Immunol* 1974;3:847.
- [16] Zucker-Franklin D, Davidson TL. The interaction of mycoplasmas with mammalian cells. Monocytes and lymphocytes. *J Exp Med* 1966;124:533.
- [17] Colomb, HM Leatherman E, Rosner MC. Hairy cell leukaemia; differences in phagocytic capacity of cells in vitro. *Virch Arch B: Cell Pathol* 1979;30:1–13.
- [18] Utsinger PD, Yount WJ, Fuller CR, et al. Hairy cell

- leukaemia; B-lymphocyte and phagocytic properties. *Blood* 1977;49:19.
- [19] Catowsky D, Sperandio P, O'Brien M, et al. Phagocytic potential of leukaemic B-lymphocytes. *Scand J Haematol* 1977;19:211.
- [20] Martelli MF, Falini B, et al. Prolymphocytic leukaemia with erythrophagocytic activity. *Br J Haematol* 1980; 46:141–142.
- [21] Ohtake K, Yano T, Kameda K, Ogawa T. In vitro endocytosis of benign and malignant human bone marrow plasma cells. *Am J Haematol* 1990;35:100–103.