

Effect of Balloon Angioplasty in Femoropopliteal Arteries Assessed by Intravascular Ultrasound

A. van der Lugt¹, E. J. Gussenhoven*¹, W. P. T. M. Mali², J. A. Reekers³, J. L. Seelen⁴,
A. V. Tielbeek⁵ and H. Pieterman¹

¹University Hospital Rotterdam-Dijkzigt, ²University Hospital Utrecht, ³Academic Medical Center Amsterdam, ⁴Maria Hospital Tilburg and ⁵Catharina Hospital Eindhoven, The Netherlands

Objective: To study the effects of balloon angioplasty (PTA) of the femoropopliteal artery with intravascular ultrasound (IVUS).

Materials and methods: Corresponding IVUS cross-sections ($n=1033$) obtained before and after PTA from 115 procedures were analysed. Vascular damage including plaque rupture, dissection and media rupture was assessed. Free lumen area (FLA), media-bounded area (MBA) and plaque area (PLA) were measured.

Results: After PTA vascular damage was seen at the target site in 83 (72%) arteries: plaque rupture in 30 (26%), dissection in 66 (57%) and media rupture in 20 (17%) arteries. The FLA increased from $5.4 \pm 3.4 \text{ mm}^2$ to $14.1 \pm 5.0 \text{ mm}^2$ ($p < 0.001$), MBA increased from $26.9 \pm 10.0 \text{ mm}^2$ to $32.9 \pm 10.7 \text{ mm}^2$ ($p < 0.001$) and PLA decreased from $21.6 \pm 8.5 \text{ mm}^2$ to $18.8 \pm 8.0 \text{ mm}^2$ ($p < 0.001$). The increase in MBA accounted for 68% of lumen gain. The frequency of vascular damage and the relative contribution of MBA increase and PLA decrease to luminal gain were not different in procedures with balloon diameter $\leq 5 \text{ mm}$ and $\geq 6 \text{ mm}$.

Conclusions: Vascular damage is common following PTA. Lumen gain is mainly due to vessel expansion and, to a lesser extent, to a decrease in plaque area.

Key Words: Intravascular ultrasound; Balloon angioplasty; Femoropopliteal artery.

Introduction

Interventional therapy could benefit from greater understanding of the mechanism of balloon angioplasty (PTA) and subsequent outcome. Since the clinical introduction of intravascular ultrasound (IVUS) in the 1980s, there are indications that this technique may reveal parameters related to the success and failure of intervention. Therefore, in September 1992 a multicentre study was started, named EPISODE (acronym for Evaluation Peripheral Intravascular Sonography On Dotter Effect).¹ One of the aims of this study was to address the effects of balloon angioplasty of the femoropopliteal artery.

This study describes the effects of balloon angioplasty as assessed by IVUS imaging. The effects seen at the target site were compared with those seen in the entire dilated segment. The influence of balloon diameter on these effects was investigated.

Material and Methods

Study group

The study group comprised 109 patients (69 men, 40 women; age range 36–92 (median 67) years) with femoropopliteal artery disease eligible for balloon angioplasty. These 109 patients were selected from the EPISODE study group ($n=142$) based on the availability of IVUS images before and after balloon angioplasty. Thirty-three procedures from the EPISODE study were not included in the present study: in 19 procedures IVUS images were not available for analysis due to the following reasons: no intervention was performed ($n=3$), machine failure ($n=6$), inability of the ultrasound catheter to pass the aortobifurcation in cases of contralateral entry of the artery ($n=4$), and inability to advance the guidewire and the ultrasound catheter along the diseased segment ($n=6$); in the remaining 14 procedures IVUS data were not available before intervention because the guidewire or the ultrasound catheter could not be advanced across the lesion (two stenoses and 12 occlusions). The investigation

* Please address all correspondence to: Elma J. Gussenhoven MD, Erasmus University Rotterdam (Ee 2312), Dr. Molewaterplein 50, 3015 GE Rotterdam, The Netherlands.

was approved by the local Committee on Human Research. Patients were included in the study after informed consent. The contribution of patients from each hospital was as follows: University Hospital Rotterdam-Dijkzigt 43 patients; University Hospital Utrecht 20 patients; Academic Medical Center (Amsterdam) 18 patients; Free Hospital (Amsterdam) 12 patients; Catharina Hospital (Eindhoven) eight patients; Maria Hospital (Tilburg) five patients; Groot Ziekenhuis Gasthuis (Den Bosch) three patients. The studies performed in the last four hospitals were guided by researchers from the first two hospitals.

Balloon angioplasty of both femoropopliteal arteries was performed in six patients, resulting in 115 procedures (88 stenotic and 27 occluded lesions). Patients were referred for intermittent claudication ($n=70$), rest and/or night pain ($n=18$), and ischaemic ulceration ($n=21$). The decision to perform an intervention was made in consultation between the vascular surgeon and interventional radiologist. Experienced interventional radiologists performed or directly supervised the intervention.

Balloon angioplasty

Standard balloon angioplasty was performed from the femoral artery approach. The intervention was preceded and followed by routine single plane angiography and IVUS study. The selection of balloon type, diameter, inflation time and inflation pressure were left to the discretion of the interventionalist, and were based on angiography only. Data collected on each procedure included the stenotic or occluded status of the artery, the length of the dilated segment and balloon diameter. The length of the dilated segment was recorded with the help of a radiopaque ruler.

Intravascular ultrasound

The IVUS studies were performed using mechanical systems based on a single ultrasound element (30 MHz). The circular image is produced by either a rotating element (DuMED, Rotterdam, The Netherlands) or by a rotating mirror (CVIS, Sunnyvale, CA, U.S.A.).² Both transducers are mounted on a guidewire tipped 4.3 F catheter (Du-MED 0.018" or 0.035"; CVIS 0.014").

The ultrasound catheter was introduced through an introducer sheath in an antegrade manner into the femoral artery. If the lesion was totally occluded,

attempts were made to advance the guidewire and subsequently the ultrasound catheter into and across the lesion. According to an established protocol, a series of IVUS images of the diseased segment were obtained with a 0.5 or 1 cm interval before and immediately after intervention by manual pull-back of the ultrasound catheter (Fig. 1). Under fluoroscopic control the location of the ultrasound catheter was systematically compared with the radiopaque ruler (calibration 0.5 cm); the catheter tip location was indicated manually on the video monitor.¹ The resulting images were displayed on the monitor via a video-scanned memory and stored on an S-VHS recorder. Care was taken to collect images before and after intervention on the same depth setting. During pull-back the gain setting was optimised and altered if necessary. When blood hampered detection of the luminal boundary, saline (5 cc) was injected via the sideport of the sheath in order to eliminate the echogenic blood (Fig. 2). Cross-sections obtained before and after intervention were matched using the location derived from the radiopaque ruler. Anatomic markers such as sidebranches and calcium were helpful in checking that the IVUS images corresponded. Corresponding cross-sections obtained within the dilated segment before and after balloon angioplasty (interval 0.5 or 1.0 cm) underwent a qualitative and quantitative off-line analysis.

Qualitative analysis

Cross-sections obtained after balloon angioplasty were evaluated for vascular damage including plaque rupture, dissection and media rupture (Figs. 1 and 3). Plaque rupture was defined as a radial tear in the intimal surface; dissection was defined as the presence of a tear in the intimal surface separating the lesion from the underlying arterial wall; and media rupture was defined as an interruption in the internal elastic lamina and media which exposes the hyperechoic adventitia to the arterial lumen.^{1,3} These morphological features could be present simultaneously in one cross-section. Vascular damage was defined as the presence of plaque rupture, dissection and/or media rupture. The extent of dissection, graded as an arc of the circumference (in steps of 30°), was categorised into four groups: absent (0°), minor (30–90°), moderate (120–180°) and severe (210–360°).

Quantitative analysis

Measurements were performed using a digital video analyser system.^{4,5} It was noticed that in still-frames

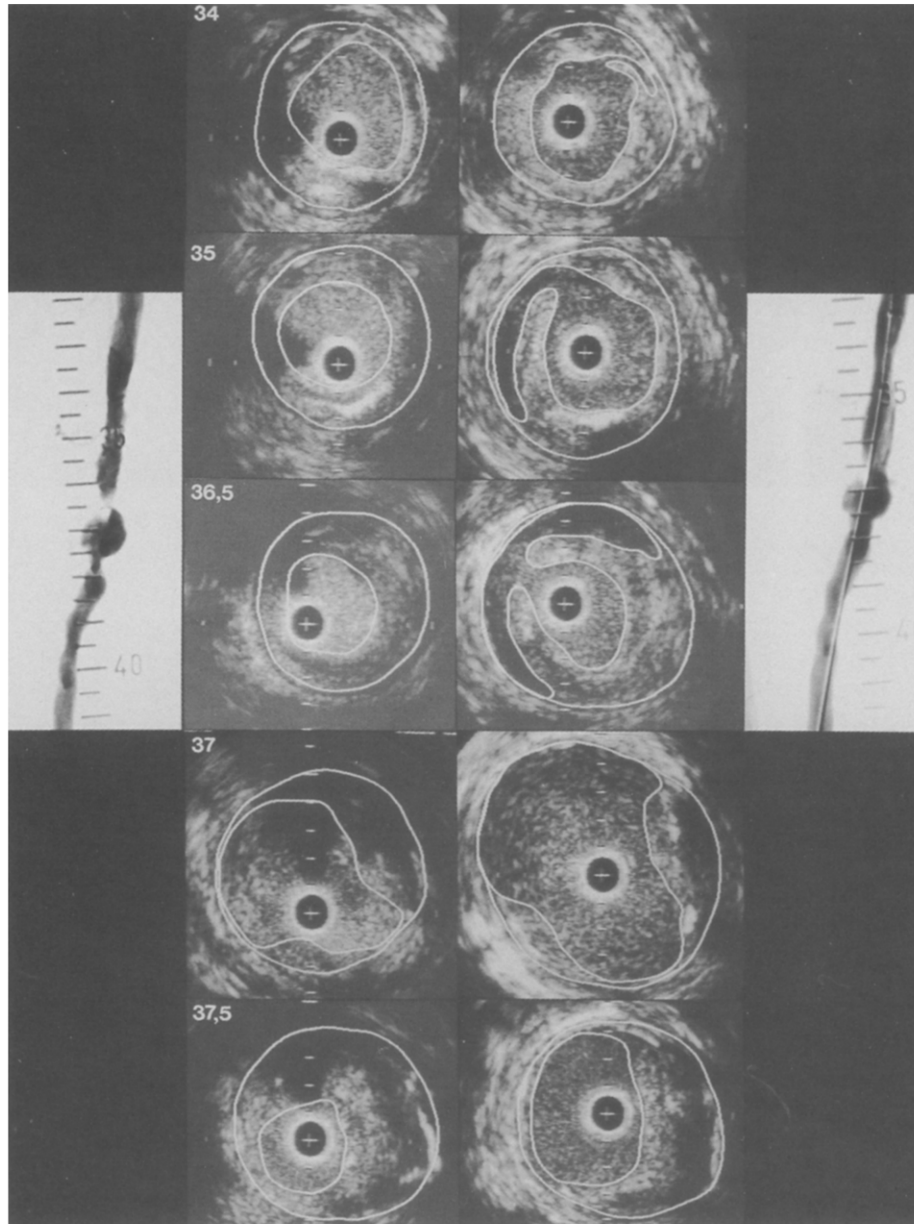


Fig. 1. Angiograms and corresponding intravascular ultrasound (IVUS) cross-sections obtained with a 0.5 or 1 cm interval from a patient before (left) and after (right) balloon angioplasty of the superficial femoral artery. The IVUS cross-sections are contour traced off-line facilitating the recognition of free lumen area (inner contour) and media-bounded area (outer contour). Note the variety in morphological features seen on IVUS before and after PTA. Dissections were seen at levels 34–36.5 cm. Catheter = +; calibration = 1 mm.

the intensity of bloodscatter may be similar in magnitude to vessel wall scattering, causing difficulty in discriminating the luminal boundary. To diminish this problem, echo images were replayed in real-time on an additional videomonitor to distinguish the luminal boundary. Analysis included free lumen area, defined as the area encompassed by the inner boundary of the intimal surface (characterised also by the presence of blood flow), and media-bounded area, defined as the native vessel area bounded by the hypochoic medial

layer (Figs. 1 and 3). The plaque area was calculated by subtracting free lumen area from media-bounded area. The percentage area stenosis was calculated as plaque area divided by media-bounded area. In the absence of a visible media on ultrasound, the adventitia was used as reference. When extensive dropout due to calcification was encountered the media-bounded area was not assessed, leading to missing data for the plaque area and percentage area stenosis. In arteries with occluded segments the free lumen area before

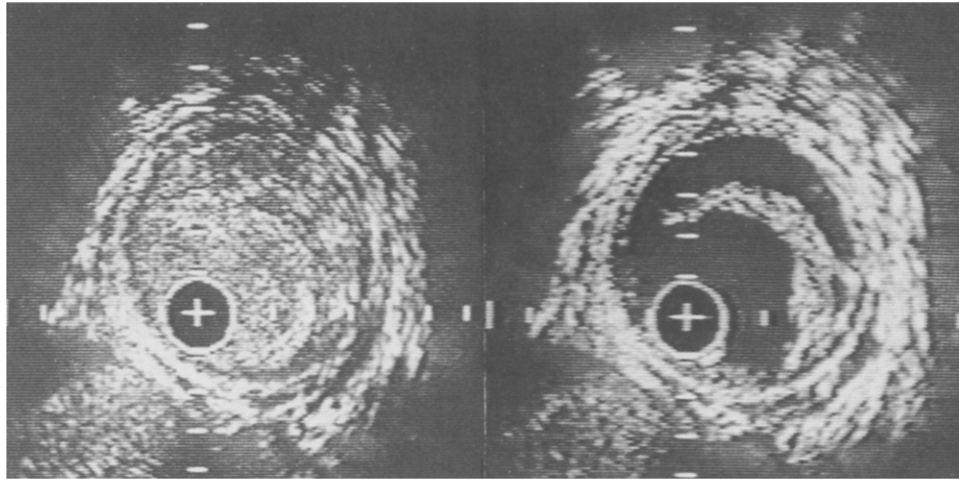


Fig. 2. Intravascular ultrasound cross-sections obtained at the same level after balloon angioplasty of the superficial femoral artery without (left) and with (right) flushing with saline. Saline is used to eliminate the echogenic blood to clearly visualise the dissection and the free lumen area. Catheter = +; calibration = 1 mm.

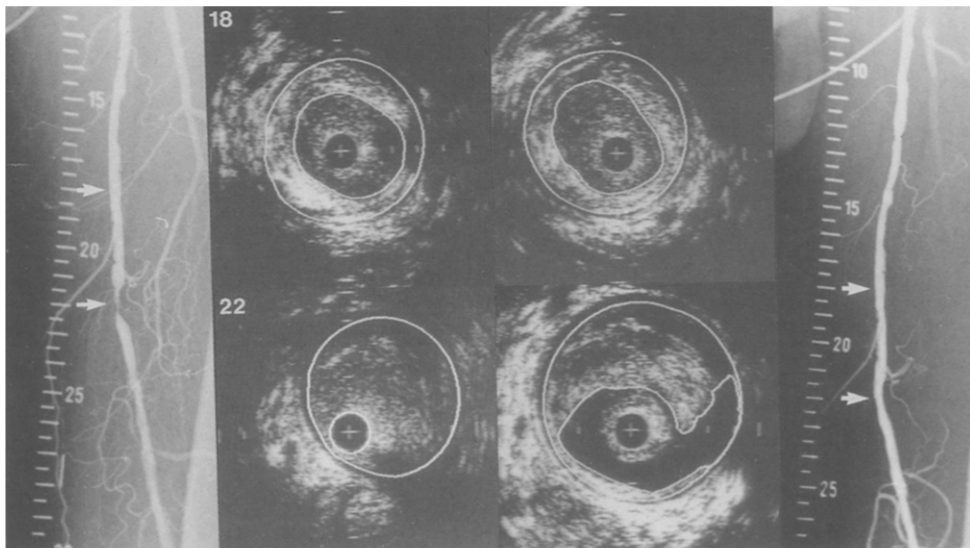


Fig. 3. Angiograms and corresponding intravascular ultrasound (IVUS) cross-sections of the superficial femoral artery obtained before (left) and after (right) balloon angioplasty (PTA, 19–23 cm). Before PTA both angiography and IVUS showed a significant stenosis at level 22. Following intervention the IVUS cross-section showed a dissection and media rupture at 4 o'clock. Note that the plaque area remained unaltered. Catheter = +; calibration = 1 mm.

intervention was the same as the area occupied by the ultrasound catheter.

Analysis of data

Qualitative and quantitative analyses of the IVUS images were basically performed by four researchers allocated to the participating university hospitals. The analyses were centrally reviewed by a second observer. Differences between the observers were resolved by consensus.

Interobserver and intraobserver variability has been studied and reported previously.^{6,7} Briefly, from 38 patients of the EPISODE study group, in cross-sections obtained before ($n=192$) and after balloon angioplasty ($n=212$), interobserver agreement was good for dissection and vascular damage (kappa values 0.69 and 0.66, respectively); fair for media rupture (kappa value 0.25); and poor for plaque rupture (kappa value 0.04). Interobserver differences for the extent of dissection was $18 \pm 48^\circ$ ($p=0.001$). Interobserver differences for free lumen area before and after intervention were

$0.22 \pm 2.07 \text{ mm}^2$ ($p=0.15$) and $0.03 \pm 1.94 \text{ mm}^2$ ($p=0.93$), respectively; and for media-bounded area $0.02 \pm 3.05 \text{ mm}^2$ ($p=0.85$) and $0.11 \pm 3.03 \text{ mm}^2$ ($p=0.62$), respectively.⁷ Intraobserver differences were slightly smaller than interobserver differences.⁶

A comparison was made between the frequency of vascular damage seen with IVUS at the target site (defined as the cross-section with the smallest lumen area before balloon angioplasty), in all cross-sections in the dilated segment, and per dilated segment. In addition, the extent of dissection at the target site, in all cross-sections, and the maximum extent of dissection seen in the dilated segment were compared.

Area measurements obtained at the target site were compared with the measurements in all cross-sections derived from the dilated segment. The relative contribution of media-bounded area increase to luminal gain (increase in free lumen area) was calculated by the ratio of media-bounded area increase to luminal gain. Similarly, the relative contribution of plaque area decrease was calculated by the ratio of plaque area decrease to luminal gain. Differences in effects at the target site in procedures with a balloon diameter $\leq 5 \text{ mm}$ and $\geq 6 \text{ mm}$ were compared.

Data are presented as mean \pm s.d. or as median and range if appropriate for continuous variables and as a percentage for categoric variables. Chi-squared analyses were used to assess differences in categoric variables. The Student's *t*-test and the Mann-Whitney test were used to assess differences in the area measurements and extent of dissections, respectively. A *p*-value <0.05 was considered statistically significant.

Results

After PTA, improvement in diameter stenosis was evident angiographically in 102 of the 115 procedures. In four procedures reocclusion (thrombus) was seen angiographically, while in nine other procedures no improvement was shown, which resulted in additional interventions (re-PTA three times, stent placement four times, bypass twice). No complications related to the IVUS study were encountered. The median length of the diseased segment subjected to dilation was 8 cm (range 4–32 cm). During pull-back of the ultrasound catheter it was evident that the lumen size changed markedly, as did the vascular damage after intervention. There were 1033 corresponding IVUS cross-sections before and after intervention available for analysis. The median number of cross-sections collected per dilated segment was 7 (range 3–26). Balloon diameter used was $\leq 5 \text{ mm}$ in 45 and $\geq 6 \text{ mm}$ in 70 procedures.

Table 1. The frequency of vascular damage seen with intravascular ultrasound after balloon angioplasty of the femoropopliteal artery at the target site ($n=115$), in all cross-sections ($n=1008$), and per dilated segment ($n=115$).

	Target site ($n=115$)	All cross-sections ($n=1008$)	Dilated segment ($n=115$)
Plaque rupture	30 26%	148 15%†	69 60%*
Dissection	66 57%	457 45%‡	101 88%*
Media rupture	20 17%	140 14%	47 41%*
Vascular damage	83 72%	560 56%†	105 91%*

† The differences between target site and all cross-sections, $p<0.01$,
‡ idem $p<0.05$.

* The differences between target site and dilated segment, $p<0.001$.

Qualitative analysis

In total 1008 (98%) IVUS cross-sections were qualitatively analysed. Poor image quality was encountered in 25 cross-sections. Data on the frequency of vascular damage including plaque rupture, dissection and media rupture at the target site, in all cross-sections, and per dilated segment are presented in Table 1. The frequency of vascular damage at the target site was 72%, in all cross-sections 56%, and per dilated segment 91%, respectively. Vascular damage not seen at the target site in 22 procedures was found with IVUS elsewhere in the dilated segment. Dissections seen at the target site were graded as minor (62%), moderate (26%) and severe (12%). A similar distribution was encountered in the dissections ($n=457$) seen in all cross-sections (67%, 24% and 9%, respectively). However, the distribution of the maximum extent of dissection in the dilated segment was different (39%, 42% and 19%, respectively). Neither the frequency of vascular damage nor the extent of dissection seen with IVUS at the target site were different in procedures with a balloon diameter $\leq 5 \text{ mm}$ and $\geq 6 \text{ mm}$ (Table 2).

Table 2. The frequency of vascular damage and extent of dissection seen with intravascular ultrasound at the target site in procedures with a balloon diameter $\leq 5 \text{ mm}$ ($n=45$) and $\geq 6 \text{ mm}$ ($n=70$).

	Balloon diameter $\leq 5 \text{ mm}$	Balloon diameter $\geq 6 \text{ mm}$
Plaque rupture	12 (27%)	18 (26%)*
Dissection	24 (53%)	42 (60%)*
Media rupture	7 (16%)	13 (19%)*
Vascular damage	32 (71%)	51 (73%)*
Dissection		
Absent	21 (47%)	28 (40%)*
Minor	17 (38%)	24 (34%)
Moderate	6 (13%)	11 (16%)
Severe	1 (2%)	7 (10%)

* The differences between procedures with a balloon diameter $\leq 5 \text{ mm}$ and $\geq 6 \text{ mm}$ were not significant.

Table 3. Area measurements before and after balloon angioplasty of the femoropopliteal artery assessed with intravascular ultrasound at the target site and in all cross-sections.

	Intravascular ultrasound		
	Before	After	% change
Free lumen area (mm ²)			
Target site (<i>n</i> =78)	5.4±3.4	14.1±5.0	+161%
All cross-sections (<i>n</i> =724)	11.8±7.1	17.0±6.5	+44%
Media-bounded area (mm ²)			
Target site (<i>n</i> =78)	26.9±10.0	32.9±10.7	+22%
All cross-sections (<i>n</i> =724)	27.4±9.8	31.9±10.0	+16%
Plaque area (mm ²)			
Target site (<i>n</i> =78)	21.6±8.5	18.8±8.0	-13%
All cross-sections (<i>n</i> =724)	15.7±7.4	14.9±6.7	-5%
Percentage area stenosis (%)			
Target site (<i>n</i> =78)	80.0±9.8	56.2±10.2	-30%
All cross-sections (<i>n</i> =724)	57.6±18.3	46.4±12.7	-19%

The differences between measurement before and after PTA are significant ($p<0.001$). *n*=number of cross-sections; + = increase; - = decrease.

Quantitative analysis

In 724 of 1033 (70%) corresponding IVUS cross-sections (including 78 of the 115 (68%) cross-sections at the target site) both free lumen area and media-bounded area could be calculated before and after intervention. Poor image quality and/or presence of calcification were the main reasons why quantitative analysis could not be performed in 309 cross-sections (range 0–21, median 2). As a result of balloon angioplasty, a significant increase in free lumen area and media-bounded area and a significant reduction in plaque area and percentage area stenosis was noted both at

the target site and in all cross-sections (Table 3; Fig. 4). Differences in area measurements before and after intervention were larger at the target site when compared with measurements obtained from all cross-sections. The relative contribution of vessel expansion (i.e. media-bounded area increase) and plaque area reduction was 68% and 32% at the target site, and 85% and 15% in all cross-sections, respectively.

At the target site the luminal gain was smaller in the procedures with a balloon diameter ≤ 5 mm than in the procedures with a balloon diameter ≥ 6 mm (6.9 ± 3.2 mm² and 10.0 ± 4.4 mm², respectively, $p=0.001$). However, no differences in relative contribution of media-bounded area increase were encountered (70% and 68%, respectively; $p=0.82$).

Discussion

Since the introduction of IVUS in clinical practice, investigators have acknowledged the ability of this technique to provide more insight into the effects of balloon angioplasty⁸⁻¹⁶ when compared to angiography. Studies dealing with IVUS both in coronary and peripheral arteries generally consider one arterial cross-section for analysis.⁸⁻¹⁶ In the present study, multiple adjacent corresponding ultrasound cross-sections obtained before and after balloon angioplasty of the femoropopliteal artery were analysed.

This study revealed that vascular damage seen with IVUS was a common feature encountered following balloon angioplasty. In 91% of the procedures vascular

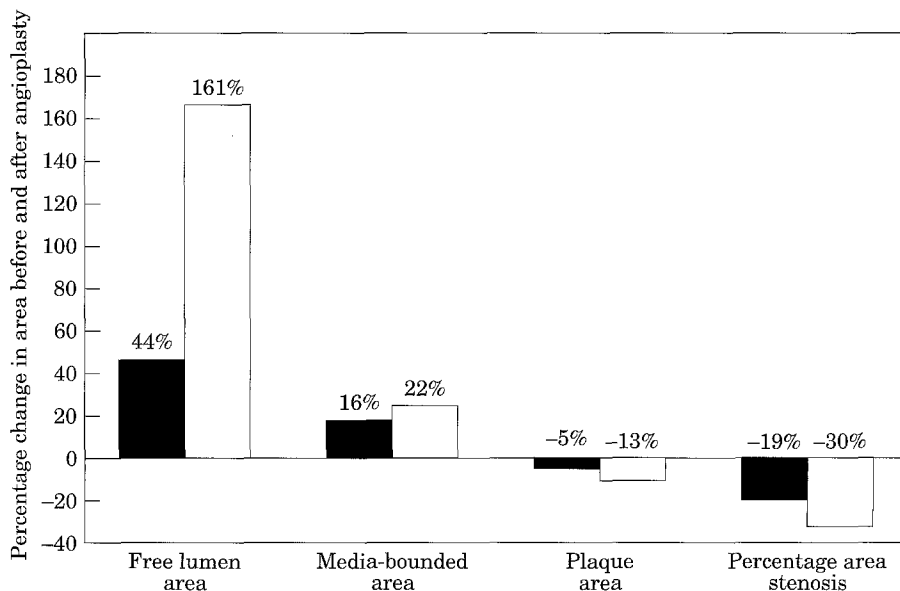


Fig. 4. Differences in area before and after balloon angioplasty of the femoropopliteal artery seen in all cross-sections and in those at the target site. (■) All cross-sections (*n*=724); (□) target site (*n*=78).

damage was seen, including plaque rupture (60%), dissection (88%) and media rupture (41%). Similarly, Losordo *et al.*¹⁶ reported vascular damage following balloon angioplasty of the iliac artery in all 40 patients studied with IVUS. The frequency of vascular damage seen with IVUS is higher than reported from angiographic studies.^{17,18} This reflects the advantage of this tomographic imaging technique to display more accurately the vascular anatomy compared to angiography.

Moreover, the present study revealed that the frequency of vascular damage at the target site seen with IVUS was lower compared to the frequency per dilated segment (72% vs. 91%). The lower frequency of vascular damage seen at the target site may be related to the inability of IVUS to detect vascular damage at the target site in all instances. Similar observations were found in an *in vitro* IVUS study on coronary arteries (63% vs. 95%).¹⁹ In this *in vitro* study dissections seen in histological sections were missed on ultrasound for the following reasons: the dissected lesion remained adherent to the vessel wall; dissection occurred without connection with the lumen, and calcium hindered visualisation of a dissection.¹⁹ Thus, in order to have insight in the presence of arterial damage, analysing the entire vascular specimen rather than one single cross-section is recommended.

The majority of dissections present were graded as minor (30°–90°) both at the target site (62%) and in all cross-sections (67%). However, on evaluating the entire dilated segment it was found that the maximum extent of dissection was >90° in 61% of the procedures. The importance of the presence and extent of vascular damage for outcome will be determined in an ongoing follow-up study.

Surprisingly, the balloon diameter used did not influence the presence nor the extent of vascular damage at the target site. Comparing quantitative data before intervention in the procedures performed with a ≤5 mm balloon with those treated with a ≥6 mm balloon, it was found that the free lumen area before intervention was not different ($5.3 \pm 3.0 \text{ mm}^2$ and $5.4 \pm 3.7 \text{ mm}^2$, respectively; $p=0.91$). Conversely, the media-bounded area was larger ($23.8 \pm 7.8 \text{ mm}^2$ and $29.0 \pm 10.8 \text{ mm}^2$, respectively; $p<0.001$). Thus, the fact that larger balloons were used in larger native vessels may explain the same amount and degree of vascular damage in procedures with a balloon diameter ≤5 mm and ≥6 mm.

The basic mechanism of balloon angioplasty has been under investigation since the introduction of this technique by Dotter and Judkins in 1964.²⁰ Initially, most of these studies were performed using cadaver

arteries.^{21,22} The introduction of IVUS has enabled the mechanism of balloon angioplasty *in vivo* to be studied more precisely. The present study reveals that the increase in free lumen area following balloon angioplasty was predominantly related to an increase in media-bounded area (i.e. vessel expansion) and, to a lesser extent, to a decrease in plaque area. As expected, the magnitude of increase in free lumen area seen at the target site was larger as compared with the mean increase measured in all cross-sections. This was accompanied by both a larger media-bounded area increase and plaque area decrease. Based on histological sections and angiographic records, Castaneda-Zuniga *et al.*²² proposed that the increase in lumen size was due to the fact that the media stretches, without significant compression or redistribution of plaque. The present IVUS study confirms the mechanism proposed by Castaneda-Zuniga: when all the cross-sections obtained from the dilated segment were taken into account the plaque area decreased slightly (5%). However, the relative contribution of plaque reduction was higher at the target sites, suggesting that the plaque at the target site may be crushed more extensively, leading to redistribution of plaque material.²³

Other IVUS studies revealed a similar mechanism of lumen enlargement in coronary arteries.^{12,15,19} However, Losordo *et al.*,¹⁶ using IVUS in iliac arteries, reported that: "plaque compression and plaque fracture were the principal factors for increased luminal patency; stretching of the arterial wall provided an additional but minor contribution". The reason for this contrary result remains speculative. Probably, the difference in native artery size and vessel structure may result in another mechanism of balloon angioplasty. Although a larger balloon diameter resulted in an increased luminal gain, the relative contribution of media-bounded area increase and plaque area decrease remained the same.

Limitations

In this study IVUS cross-sections were matched using a radiopaque ruler and anatomic markers such as calcification and sidebranches. It is realistic to argue that the accuracy of the matched data may not be 100%. Data on multiple cross-sections mask this potential mismatch. It should be acknowledged that 33 procedures were not included in this study, and that due to calcification and inadequate image quality, both the free lumen area and media-bounded area could be calculated in only 70% of the corresponding IVUS cross-sections. The latter may have influenced the

results, as severe calcification may show a different pattern of dilation. Finally, the assessment of IVUS parameters is subjective. However, the kappa value of dissection was good and the variability in measurements was minimal, with the exception of the variability in the extent of dissection.

Conclusions

Vascular damage is a common finding following PTA of the femoropopliteal artery. Lumen gain is mainly due to vessel expansion and, to a lesser extent, to plaque decrease. No relationship was observed between balloon diameter and (1) the incidence and extent of vascular damage, and (2) the relative contribution of media-bounded area increase and plaque area decrease to luminal gain.

Acknowledgments

This project was supported by grants from the Interuniversity Cardiology Institute of The Netherlands and The Netherlands Heart Foundation (900.572.002).

The authors thank the radiologists F.G. van den Berg, H. Spithoven and J. Teertstra for their support, David J. Posthuma for the data management and analysis and Theo Stijnen for the statistical analysis.

References

- GUSSENHOVEN EJ, LUGT VAN DER A, PASTERKAMP G *et al.* Intravascular ultrasound predictors of outcome after peripheral balloon angioplasty. *Eur J Vasc Endovasc Surg* 1995; **10**: 279–288.
- BOM N, TEN HOFF H, LANCÉE CT *et al.* Early and present examples of intraluminal ultrasonic echography. *SPIE* 1989; **1068**: 146–150.
- THE SHK, GUSSENHOVEN EJ, ZHONG Y *et al.* The effect of balloon angioplasty on the femoral artery evaluated with intravascular ultrasound imaging. *Circulation* 1992; **86**: 483–493.
- WENGUANG L, GUSSENHOVEN WJ, BOSCH JG, MASTIK F, REIBER JHC, BOM N. A computer-aided analysis system for the quantitative assessment of intravascular ultrasound images. *Proceedings of Computers in Cardiology* 1990: 333–336.
- WENGUANG L, BOSCH JG, ZHONG Y *et al.* Semiautomatic frame-to-frame tracking of the luminal border from intravascular ultrasound. *Proceedings of Computers in Cardiology* 1991: 353–356.
- WENGUANG L, GUSSENHOVEN WJ, ZHONG Y *et al.* Validation of quantitative analysis of intravascular ultrasound images. *Int J Card Imaging* 1991; **6**: 247–253.
- LUGT VAN DER A, GUSSENHOVEN EJ, PASTERKAMP G, BOM N, POSTHUMA DJ, STIJNEN T. Interobserver reproducibility of qualitative and quantitative analysis of intravascular ultrasound images before and after peripheral balloon angioplasty. *Ultrasound Med Biol* 1996; **22**: 399–404.
- FITZGERALD PJ, PORTS TA, YOCK PG. Contribution of localized calcium deposits to dissection after angioplasty: an observational study using intravascular ultrasound. *Circulation* 1992; **86**: 64–70.
- GERBER TC, ERBEL R, GÖRGE G, GE J, RUPPRECHT HJ, MEYER J. Classification of morphologic effects of percutaneous transluminal coronary angioplasty assessed by intravascular ultrasound. *Am J Cardiol* 1992; **70**: 1546–1554.
- HONYE J, MAHON DJ, JAIN A *et al.* Morphological effects of coronary balloon angioplasty in vivo assessed by intravascular ultrasound imaging. *Circulation* 1992; **85**: 1012–1025.
- TENAGLIA AN, BULLER CE, KISSLO K, PHILLIPS HR, STACK RS, DAVIDSON CJ. Intracoronary ultrasound predictors of adverse outcomes after coronary artery interventions. *J Am Coll Cardiol* 1992; **20**: 1385–1390.
- POTKIN BN, KEREN G, MINTZ GS *et al.* Arterial responses to balloon coronary angioplasty: an intravascular ultrasound study. *J Am Coll Cardiol* 1992; **20**: 942–951.
- KOVACH JA, MINTZ GS, PICHARD AD *et al.* Sequential intravascular ultrasound characterization of the mechanisms of rotational atherectomy and adjunct balloon angioplasty. *J Am Coll Cardiol* 1993; **22**: 1024–1032.
- SUNEJA R, NAIR RN, REDDY KG, RASHEED Q, SHEEHAN HM, HODGSON J. Mechanisms of angiographically successful directional coronary atherectomy: evaluation by intracoronary ultrasound and comparison with transluminal coronary angioplasty. *Am Heart J* 1993; **126**: 507–514.
- BRADEN GA, HERRINGTON DM, DOWNES TR, KUTCHER MA, LITTLE WC. Qualitative and quantitative contrasts in the mechanisms of lumen enlargement by coronary balloon angioplasty and directional coronary atherectomy. *J Am Coll Cardiol* 1994; **23**: 40–48.
- LOSORDO DW, ROSENFELD K, PIECZEK A, BAKER K, HARDING M, ISNER JM. How does angioplasty work? Serial analysis of human iliac arteries using intravascular ultrasound. *Circulation* 1992; **86**: 1845–1858.
- GERRITSEN GP, GUSSENHOVEN EJ, THE SHK *et al.* Intravascular ultrasonography before and after intervention: in vivo comparison with angiography. *J Vasc Surg* 1993; **18**: 31–40.
- LABROPOULOS N, GIANNOUKAS AD, VOLTEAS SK, AL KUTOUBI A. Complications of the balloon assisted percutaneous transluminal angioplasty. *J Cardiovasc Surg* 1994; **35**: 475–489.
- LUGT VAN DER A, GUSSENHOVEN EJ, STIJNEN T *et al.* Comparison of intravascular ultrasonic findings after coronary balloon angioplasty evaluated in vitro with histology. *Am J Cardiol* 1995; **76**: 661–666.
- DOTTER CT, JUDKINS MP. Transluminal treatment of arteriosclerotic obstruction. Description of a new technique and a preliminary report of its application. *Circulation* 1964; **30**: 654–670.
- CHIN AK, KINNEY TB, GREGORY MS, RURIK GW, SHOOR PM, FOGARTY TJ. A physical measurement of the mechanisms of transluminal angioplasty. *Surgery* 1984; **95**: 196–200.
- CASTANEDA-ZUNIGA WR, FORMANEK A, TADAVARTHY M *et al.* The mechanism of balloon angioplasty. *Radiology* 1980; **135**: 565–571.
- MINTZ GS, KOVACH JA, PARK KS *et al.* Conservation of plaque mass: a volumetric intravascular ultrasound analysis of patients before and after percutaneous transluminal coronary angioplasty. *J Am Coll Cardiol* 1993; **21**: 485 A (Abstr.).

Accepted 11 November 1996