

The American Journal of Dermatopathology
 Issue: Volume 18(1), February 1996, pp 30-34
 Copyright: © Lippincott-Raven Publishers
 Publication Type: [Articles]
 ISSN: 0193-1091
 Accession: 00000372-199602000-00005
 Keywords: Primary, Erythralgia, Histopathology, Skin

[Articles]

[◀ Previous Article](#) | [Table of Contents](#) | [Next Article ▶](#)

Cutaneous Pathology in Primary Erythralgia

Drenth, Joost P.H.; Vuzevski, Vojislav; Van Joost, Theo; Daele, M. Casteels-Van; Vermynen, J.; Michiels, Jan J.

Author Information

From the Department of Medicine (J.P.H.D.), Division of General Internal Medicine, University Hospital St. Radboud, Nijmegen; Departments of Pathology (V.V.), Dermatology (T.V.J.), Hematology (J.J.M.), University Hospital Dijkzigt, Erasmus University, Rotterdam, The Netherlands; Department of Pediatrics (M.C.-V.D.), and Center for Thrombosis and Vascular Research (J.V.), University of Leuven, Belgium.

Address correspondence and reprint requests to Dr. Jan J. Michiels at Internal Medicine, Hemostasis, Thrombosis, and Vascular Research, Department of Hematology, University Hospital Dijkzigt, Dr. Molenwaterplein 40, 3015 GD Rotterdam, The Netherlands.

Abstract











Primary or idiopathic erythralgia is characterized by recurrent, red, warm, and painful lower extremities. It arises at young age and persists throughout life because no treatment is available. We report the cutaneous pathology of affected skin lesions of three patients with primary erythralgia. Biopsy specimens showed a mild perivascular mononuclear infiltrate, thickened blood vessel basement membranes, abundant perivascular edema, and moderate endothelial swelling. The thickened basal membrane of the blood vessels showed a laminar structure, and abundant perivascular edema and moderate endothelial cell swelling were evident. These histopathologic findings in primary erythralgia appear to be nonspecific but allow diagnostic differentiation from erythromelalgia in which fibromuscular intimal proliferation and occlusive thrombi in the endarteriolar capillaries are apparent and from erythralgia secondary to vasculitis. Histopathologic examination of affected skin lesions in patients with red, congested, warm, and painful burning extremities is a valuable tool in the diagnostic process.

Erythromelalgia and erythralgia are defined as two independent and completely different disease entities (1-3). Clinically, there are three different types of recurrent red, warm, and burning pain in the extremities. Erythromelalgia is closely associated with thrombocytopenia ($>=350 \times 10^9/L$) in its primary form or is associated with various chronic myeloproliferative disorders (4,5). Symptoms are caused by platelet activation and aggregation in the end-arteriolar circulation, leading to ischemia and symptoms. The long-lasting relief of burning distress for 2-4 days afforded by a single low dose of aspirin is the valuable diagnostic test for erythromelalgia (6). The histopathology of erythromelalgia comprises arteriolar changes with narrowing of the lumen by (a) swelling of the endothelial cell lining, (b) proliferation of smooth muscle cells (SMC) with vacuolization and swelling of the cytoplasm, and (c) with or without thrombi (7-9).

Primary or idiopathic erythralgia is rare and arises at young age as a bilateral symmetric burning and redness of mainly the lower extremities in the absence of detectable disease (1-3). The diagnosis is made only according to a list of clinical criteria. Its pathogenesis remains elusive, and symptoms persist throughout life and are refractory to any treatment method. Secondary erythralgia usually occurs at adult age in association with various underlying disorders (1,10-14).

Diagnostic differentiation between primary erythralgia and erythromelalgia is very important since treatment and, consequently, prognosis differ.

Article Tools

-  [Complete Reference](#)
-  [Abstract Reference](#)
-
-  [Print Preview](#)
-  [Email Jumpstart](#)
-  [Email PDF Jumpstart](#)
-  [Email Article Text](#)
-  [Save Article Text](#)
-  [Add to My Projects](#)
-  [Export All Images to PowerPoint](#)
-  [+Annotate](#)

[Find Citing Articles](#)[Find Similar](#)[About this Journal](#)[Request Permissions](#)[360 Link](#)

Outline

- [Abstract](#)
- [PATIENTS AND METHODS](#)
- [RESULTS](#)
 - [Clinical Cases of Primary Erythralgia](#)
 - [Case 1](#)
 - [Case 2](#)
 - [Case 3](#)
- [HISTOPATHOLOGICAL FINDINGS](#)
- [DISCUSSION](#)
- [REFERENCES](#)
- [IMAGE GALLERY](#)

Histopathological examination of lesional skin may contribute to recognition of the separate types. Therefore, we performed a histopathological study to seek the underlying cutaneous pathology of primary erythralgia.

[Back to Top](#)

PATIENTS AND METHODS

The study group consisted of three patients with primary erythralgia. The diagnosis of primary erythralgia was made according to clinical criteria as described previously (2). Primary erythralgia is characterized by (a) attacks of bilateral or symmetric burning pain in the hands or feet; (b) attacks initiated or aggravated by standing, exercise, or exposure to heat; (c) relief obtained by elevation of the extremities and exposure to cold; (d) flushing and congestion of the affected parts with increased local heat during attacks; (e) unknown pathogenesis with no treatment available; (f) onset at early age (children and adolescents) and persistence throughout life; (g) relative sparing of the toes and absence of acrocyanotic ischemia and peripheral gangrene; and (h) an autosomal dominant hereditary trait in familial cases.

The pertinent clinical data are shown in Table 1. for histopathological studies, deep punch skin biopsy samples 0.3-0.6 cm in diameter were obtained from lesional skin on the dorsum of the feet. Subsequently, biopsies were fixed in 40% formaldehyde, dehydrated in alcohol, and embedded in Paraplast. Sections 2-4 µm thick were stained with hematoxylin azophloxine and with the van Gieson stain for light microscopy study. The results of histopathological examination are summarized in Table 2.

Case	Age	Sex	Onset	Duration	Location	Character	Relief	Aggravation	Family History
1	9	F	1980	6	Feet	Burning	Cold	Heat	None
2	53	F	Birth	53	Feet, ankles, lower legs	Burning	Cold	Heat	None
3	?	?	?	?	?	?	?	?	?

Table 2

[Back to Top](#)

RESULTS

[Back to Top](#)

Clinical Cases of Primary Erythralgia

[Back to Top](#)

Case 1

In 1980, a 9-year-old girl developed painful erythema of both legs below the knee and of both feet, associated with marked intolerance to heat. Physical exercise worsened the pain. With time, the sensation of burning increased gradually, with occasional paroxysmal pain. The patient attempted to reduce the pain by walking barefoot, by using a ventilator, and later by sitting with the legs in cold water. The pain markedly disturbed her sleeping pattern. Her father and younger brother have or had similar but far less intense symptoms. Since 1983, she had been frequently admitted to the University Hospital in Leuven. At clinical examination, the zones of erythema were consistently described as feeling very warm. The skin of the feet was fissured, and sometimes infected bullae were present, probably as a consequence of prolonged exposure to cold water. The backs of both hands also were erythematous but did not cause complaints. An extensive hematological and immunological investigation on several occasions was negative. Urinary catecholamine level and blood pressure (BP) were intermittently increased, and attributed to stress because extensive investigation, including isotope studies, failed to show a pheochromocytoma. Thermography confirmed the hyperthermia of both feet. Doppler registration of the ankle pulses showed low peripheral resistance, with increased diastolic blood flow. Dermatological treatment improved the skin lesions but not the pain. Between 1983 and 1986, she was treated with aspirin, cinnarizine, ketanserin, antihistaminics, the 5-lipoxygenase inhibitor nafazatrom, corticosteroids, nifedipine, prazosine, nitroprusside, percutaneous regional nerve stimulation, and psychotherapy. She even consulted an acupuncturist. None of these approaches had more than a transient effect. The diagnosis of primary erythralgia was made. In view of the excruciating pain and the lack of any therapeutic relief, the patient became more and more depressed and committed suicide in 1986.

[Back to Top](#)

Case 2

From birth, a 53-year-old woman had had persistent, bilateral, warm, and undulating burning pain of her feet, ankles, and the lower parts of her legs. Her hands caused no complaints. She could not tolerate any heat and declined wearing socks and/or shoes because this aggravated the burning distress. She always walked barefoot, even in winter. Nevertheless, she avoided walking, for this and any kind of exercise worsened the discomfort. The burning pain usually awakened her at night, and she sought relief by soaking her feet in ice-cold water. Physical examination disclosed red purplish symmetrical erythema and pitting edema on both feet, ankles, and the lower part of her legs (Fig. 1). Extensive laboratory investigations showed no abnormality; in particular, platelet counts were always



Fig. 1

within normal limits. The complaints increased with time, and various drugs, including [beta]-blockers, nonsteroidal antiinflammatory drugs (NSAIDs), and aspirin had no effect.

[Back to Top](#)

Case 3

Since adolescence, a 34-year-old woman had had slowly progressive burning erythema of the feet and lower legs. Warmth and physical exercise increased the sensation to burning pain and caused intensification of red purplish discoloration and swelling of the feet and lower legs. She walked barefoot even in winter. Multiple laboratory investigations showed no abnormality, and platelet counts were always within normal values. Various drugs, including aspirin, did not alleviate the discomfort. Of her three children, one daughter has similar but much less intense symptoms.

[Back to Top](#)

HISTOPATHOLOGICAL FINDINGS

Histopathological findings of skin punch biopsies from affected areas are shown in [Table 2](#). The results from examination of biopsy specimens from all three patients with primary erythralgia were comparable. Two (cases 1 and 3) had epidermal hyperkeratosis and some mild hyperplasia ([Fig. 2](#)). In all cases, the capillary blood vessels showed moderate to severe thickening of the wall ([Fig. 2](#)). It had a laminar appearance in two patients (cases 2 and 3) and a homogeneous structure in one (case 1). The endothelial lining of the vessel walls could be moderately swollen, with protrusion of the endothelial cells into the lumen. The striking histopathological appearance in one patient (case 3) was media proliferation of the arterioles in the absence of obvious vascular or inflammatory disease ([Fig. 3](#)). These changes were not due to other processes such as stasis because there were no hemosiderin-laden macrophages, as indicated by a negative finding on staining for iron. All biopsy specimens were characterized by minimal to moderate perivascular inflammatory infiltration, composed solely of mononuclear cells ([Fig. 4](#)). Mild to marked perivascular edema was a feature of all biopsy specimens from patients with primary erythralgia. The elastic fibers in all skin layers had a normal appearance (van Gieson stain). The subcutis was normal in all biopsy specimens. Fibromuscular intimal proliferation and occlusive thrombi in the arterioles, typical of erythromelalgia, were absent in all specimens of primary erythralgia ([7](#)).

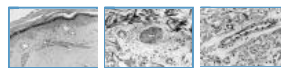


Fig. 2

Fig. 3

Fig. 4

[Back to Top](#)

DISCUSSION

We studied the histopathological features of skin punch biopsies from three patients with primary erythralgia. Primary erythralgia is a rare, incurable disorder of unknown etiology. The slight perivascular mononuclear infiltration apparently represents a response to an as yet unknown pathophysiological process. The poor prospects and the continuous agony of primary erythralgia may cause severe depression and even suicide, as in our case 1. The origin of the syndrome is not understood, but examination of biopsy specimens of affected skin may provide a clue to its pathogenesis. The histopathological findings from biopsy specimens in our cases with primary erythralgia show a clear but slight perivascular mononuclear inflammatory infiltrate. Moreover, the basal membrane of the capillaries is thickened with a laminar structure and the endothelial cells are swollen. In addition, there is abundant perivascular edema, which may cause the dermal vessels to have a manchettelike appearance. The histopathology of primary erythralgia was reported occasionally in four cases ([15-18](#)). Sections from two cases showed normal dermal vascular structures lined by flat endothelial cells ([15,16](#)). Biopsy specimens from a third case demonstrated dilated and proliferating capillaries and increased dermal collagen content ([17](#)). Skin punch biopsy specimen from the fourth patient showed a swollen endothelium of the dermal vessels and a slight lymphocytic perivascular infiltrate ([18](#)). In contrast, the pathological changes in erythromelalgia, which result from platelet-mediated processes in the endarteriolar circulation, are characterized by (a) endothelial cell swelling, (b) proliferation of SMC, and (c) deposition of intracellular platelet plugs ([7](#)). In longstanding cases of erythromelalgia, fibromuscular intimal proliferation develops; ultimately, the tissues become completely fibrosed. Administered in an early stage, aspirin reverses the vascular changes in erythromelalgia but does not alleviate symptoms in primary erythralgia ([19](#)).

Our findings in primary erythralgia do not provide a clue to its pathogenesis but are essentially different from the specific pathological findings in erythromelalgia and erythralgia secondary to cutaneous vasculitis, in association with systemic lupus erythematosus in particular ([10,11,13](#)). Primary erythralgia

is histopathologically featured by slight but clear moderate perivascular mononuclear cell invasion, endothelial cell swelling, perivascular edema, and slight to moderate thickening of the basal membrane of the capillaries. Histopathological examination of affected skin lesions in patients with red, warm, and painful burning extremities is a valuable tool in the diagnostic process for the differential diagnosis between erythromelgia and erythralgia.

[Back to Top](#)

REFERENCES

1. Drenth JPH, Michiels JJ. Three types of erythromelgia [Editorial]. *Br Med J* 1990;301:454-5. [\[Context Link\]](#)
2. Drenth JPH, Michiels JJ. Erythromelgia and erythralgia: diagnostic differentiation. *Int J Dermatol* 1994;33:393-7. [360 Link](#) | [Bibliographic Links](#) | [\[Context Link\]](#)
3. Michiels JJ, Van Joost Th. Primary and secondary erythralgia: a critical review. *Neth J Med* 1988;33:205-8. [360 Link](#) | [Bibliographic Links](#) | [\[Context Link\]](#)
4. Michiels JJ, Ten Kate FWJ. Erythromelgia in thrombocythaemia of various myeloproliferative disorders. *Am J Hematol* 1992;39:131-6. [360 Link](#) | [Bibliographic Links](#) | [\[Context Link\]](#)
5. Van Genderen PJJ, Michiels JJ. Erythromelgic, thrombotic and haemorrhagic manifestations of thrombocythaemia. *Presse Med* 1994;23:73-7. [\[Context Link\]](#)
6. Michiels JJ, Abels J, Steketee J, Van Vliet HHDM, Vuzevski VD. Erythromelgia caused by platelet-mediated arteriolar inflammation and thrombosis in thrombocytopenia. *Ann Intern Med* 1985;102:466-71. [\[Context Link\]](#)
7. Michiels JJ, Ten Kate FWJ, Vuzevski VD, Abels J. Histopathology of erythromelgia in thrombocythaemia. *Histopathology* 1984;8:669-78. [360 Link](#) | [Bibliographic Links](#) | [\[Context Link\]](#)
8. Croue A, Gardembas-Pain M, Verret JL, Boasson M, Rousselet MC, Saint Andre JP. Lésions histopathologiques de l'érythromélgie au cours d'une thrombocytémie essentielle. *Ann Pathol* 1993;13:128-30. [\[Context Link\]](#)
9. Michiels JJ, Van Joost Th. Erythromelgia and thrombocythaemia, a causal relation. *J Am Acad Dermatol* 1990;22:107-11. [\[Context Link\]](#)
10. Drenth JPH, Michiels JJ, Van Joost Th, Vuzevski VD. Secondary erythralgia in systemic lupus erythematosus. *J Rheumatol* 1993;20:144-6. [360 Link](#) | [Bibliographic Links](#) | [\[Context Link\]](#)
11. Drenth JPH, Michiels JJ, Van Joost Th, Vuzevski VD. Erythralgia secondary to vasculitis. *Am J Med* 1993;94:549-50. [360 Link](#) | [Full Text](#) | [Bibliographic Links](#) | [\[Context Link\]](#)
12. Drenth JPH, Michiels JJ, Van Joost Th, Vuzevski VD. Verapamil induced secondary erythralgia. *Br J Dermatol* 1992;127:292-4. [360 Link](#) | [Bibliographic Links](#) | [\[Context Link\]](#)
13. Ratz JL, Berfield WF, Steck WD. Erythralgia with vasculitis. *J Am Acad Dermatol* 1979;1:443-50. [360 Link](#) | [Full Text](#) | [Bibliographic Links](#) | [\[Context Link\]](#)
14. Alarcón-Segovia D, Diaz-Jouanen E. Erythralgia in systemic lupus erythematosus. *Am J Med Sci* 1973;266:149-51. [Ovid Full Text](#) | [360 Link](#) | [Bibliographic Links](#) | [\[Context Link\]](#)
15. Priollet P, Bruneval P, Lazareth I, Vayssairat M, Housset E, Barthelemy M. Erythromelgia without arteriolar changes [Letter]. *Ann Intern Med* 1985;103:639. [360 Link](#) | [Bibliographic Links](#) | [\[Context Link\]](#)
16. Uno H, Parker F. Autonomic innervation of the skin in primary erythralgia. *Arch Dermatol* 1983;119:65-71. [\[Context Link\]](#)
17. Kvernebo K, Seem E. Erythromelgia—pathophysiological and therapeutic aspects: a preliminary report. *J Oslo City Hosp* 1987;37:9-12. [\[Context Link\]](#)

18. Michiels JJ, Van Joost Th, Vuzevski VD. Idiopathic erythralgia. A congenital disorder. *J Am Coll Dermatol* 1989;21:1128-30. [\[Context Link\]](#)

19. Drenth JPH, Michiels JJ. Treatment options for primary erythralgia? [Letter]. *Am J Hematol* 1993;43:154. [360 Link](#) | [Bibliographic Links](#) | [\[Context Link\]](#)

Key Words: Primary; Erythralgia; Histopathology; Skin

IMAGE GALLERY

[Select All](#)

[Export Selected to PowerPoint](#)

Case#	Year	Age	Grade	Location	Treatment	Outcome
1811370	1989	15	Severe	Foot/lowers legs	Symptomatic	Poor
3143112	1993	15	Severe	Foot/lowers legs	Symptomatic	Poor
2193330	1993	15	Severe	Foot/lowers legs	Symptomatic	Poor

† Died at age 15.

Table 1

Histology		Dermis	
Case#	Year	Location	Grade
1811370	1989	Foot/lowers legs	Severe
3143112	1993	Foot/lowers legs	Severe
2193330	1993	Foot/lowers legs	Severe

Table 2

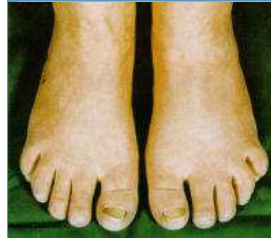

Fig. 1

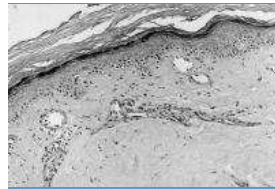


Fig. 2

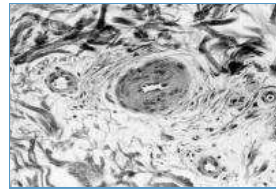


Fig. 3

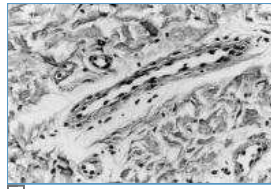


Fig. 4

[Back to Top](#)

[◀ Previous Article](#) | [Table of Contents](#) | [Next Article ▶](#)