
Acute Coronary Disease

Low-dose dobutamine echocardiography and rest-redistribution thallium-201 tomography in the assessment of spontaneous recovery of left ventricular function after recent myocardial infarction

Abdou Elhendy, MD, Giuseppe Trocino, MD, Alessandro Salustri, MD, PhD, Jan H. Cornel, MD, Jos R.T.C. Roelandt, MD, PhD, Eric Boersma, MSc, Ron T. van Domburg, MSc, Eric P. Krenning, MD, PhD, Galal M. El-Said, MD, and Paolo M. Fioretti, MD, PhD
Rotterdam, The Netherlands

Spontaneous improvement of contraction and perfusion occurs after acute myocardial infarction. The relative merit of low-dose dobutamine stress echocardiography (LDDE) and rest-redistribution thallium scintigraphy (RR TI) in this setting has not been evaluated. We studied 30 patients at 7 ± 3 days after acute myocardial infarction with LDDE (5 to 10 µg/kg/min) and RR TI single photon emission computed tomography. Viability was defined as improvement of wall thickening at LDDE in the presence of redistribution or a defect with uptake ≥50% of peak activity at RR TI. Baseline echocardiography and RR TI were repeated after 3 months. In 112 dyssynergic segments, viability was detected in 60 (54%) by RR TI and in 39 (35%) by LDDE ($p < 0.005$). Spontaneous improvement of function was detected in 35 (31%) segments. In the same regions, thallium uptake increased significantly. The sensitivity, specificity, and accuracy of LDDE for predicting late improvement of wall motion were 77%, 84%, and 82%, respectively. Those of RR TI were 77%, 57%, and 63%, respectively. Specificity and accuracy of LDDE were higher than RR TI ($p < 0.005$). We conclude that a myocardial viability pattern after acute myocardial infarction is more frequently detected by RR TI than by LDDE. Both techniques are equally sensitive, but LDDE is a more specific predictor of spontaneous recovery of regional left ventricular function. (Am Heart J 1996;131:1088-96.)

From the Thoraxcenter, Division of Cardiology, and Department of Nuclear Medicine, University Hospital Rotterdam-Dijkzigt and Erasmus University.

Supported in part by the Department of Cardiology, Cairo University Hospital, Cairo, Egypt. Dr Trocino is supported by the Department of Cardiology, San Gerardo Hospital, Monza, Italy.

Received for publication July 18, 1995; accepted Oct. 10, 1995.

Reprint requests: Paolo M. Fioretti, MD, University Hospital Rotterdam-Dijkzigt, Thoraxcenter Ba 300, Dr Molewaterplein 40, 3015 GD Rotterdam, The Netherlands.

Copyright © 1996 by Mosby-Year Book, Inc.
0002-8703/96/\$5.00 + 0 4/1/71354

Recent clinical studies have shown that after a recent myocardial infarction, late spontaneous recovery of regional left ventricular function and myocardial perfusion occurs in a substantial percentage of patients.¹⁻⁷ This finding is consistent with the concept of myocardial stunning^{8,9} and may have important clinical implications for an improved risk stratification^{10,11} and for a more proper selection of patients for coronary revascularization procedures.¹²⁻¹⁶ Therefore the prediction of late functional outcome of left ventricular function would be desirable if obtained with a noninvasive, simple, accurate, reproducible method. Low-dose dobutamine stress echocardiography (LDDE) and rest-redistribution thallium scintigraphy (RR TI) have the potential to fulfill most of these prerequisites.^{2-7, 10, 17, 18} However, the relative value of both techniques in detecting viable myocardium after a recent myocardial infarction has not been compared in the same patient population.

Accordingly, the aim of this study was threefold: (1) to study the agreement between LDDE and RR TI in diagnosing myocardial viability in patients with a recent myocardial infarction, (2) to describe the spontaneous changes of regional left ventricular function and perfusion 3 months after myocardial infarction, and (3) to assess the relative value of LDDE and RR TI to predict the late spontaneous improvement of regional left ventricular function.

METHODS

Study population. Thirty-two consecutive patients with a recent myocardial infarction and uncomplicated early

clinical course were included in the study. The mean age was 61 ± 11 years (range 37 to 78 years), and 21 (70%) were men. The diagnosis of myocardial infarction was made on the basis of the presence of at least two of the following criteria: (1) prolonged chest pain (>30 min), (2) deviation ≥ 1 mm in at least two leads on the standard electrocardiogram (ECG) and (3) significant increase (at least twice the upper normal limit) of serum creatine kinase.

The site of the infarction was inferior or inferoposterolateral in 20 patients and anterior or anteroseptal in 12. Intravenous thrombolysis was given in 17 patients; the delay in hospital admission or other clinical conditions were the contraindications in the others. A non-Q wave myocardial infarction was present in five patients. Fourteen patients underwent a diagnostic coronary angiography.

All patients underwent LDDE at a mean of 7 ± 3 days (range 5 to 14 days) after the infarction. The antianginal therapy was not discontinued before the test and included beta blockers in five patients. RR TI was performed in all patients at a mean of 1.2 days (range 1 to 2 days) from LDDE. All patients gave a written consent to participate in the study.

Dobutamine stress echocardiography. Dobutamine was infused with a volumetric pump at incremental doses (5 to 10 $\mu\text{g}/\text{kg}/\text{min}$) with steps of 3 minutes. A 12-lead electrocardiogram and arterial blood pressure were recorded at basal conditions and at the end of each stage. Patients were monitored with three electrocardiographic leads and two-dimensional echocardiography throughout the test. Echocardiograms (in standard multiple short- and long-axis views) were recorded on videotape at rest and during dobutamine infusion. The images were also digitized and stored on an optical disk (Vingmed CFM 800, Horton, Norway) for a display in quad-screen format. A 16-segment model of the left ventricle, according to the recommendations of the American Society of Echocardiography,¹⁹ was used to evaluate left ventricular wall motion. Both inward wall motion and systolic myocardial thickening were considered for the assessment. Each segment was graded on a 4-point scale (1, normal or hyperkinesis; 2, hypokinesis; 3, akinesis; 4, dyskinesis). Wall motion score index was calculated by dividing the sum of the scores by the number of the segments analyzed. Echocardiographic images were interpreted by two observers blinded to the patients' scintigraphic data. A third observer was asked in cases of disagreement, and a majority decision was reached. In our laboratory, the inter- and intraobserver concordance on the response of wall motion during LDDE was 92% (K 0.84) and 94% (K 0.86), respectively.²⁰ The test results were considered positive for the presence of viable myocardium if ≥ 1 dyssynergic segment had ≥ 1 decrease of wall motion score compared with resting echocardiogram during dobutamine infusion.

Rest-redistribution thallium SPECT. On fasting, 110 MBq of ²⁰¹-thallium was injected intravenously at rest, 5 minutes after sublingual administration of 1 mg of nitroglycerin. The acquisition of the single photon emission computed tomography (SPECT) images was started within

| | | | |
|------|---|-------|----|
| | | RR TI | |
| | | + | - |
| LDDE | + | 25 | 14 |
| | - | 35 | 38 |

Fig. 1. Agreement for detection of myocardial viability by LDDE and RR TI SPECT in 112 dyssynergic segments. Agreement = 56%; Kappa = 0.15.

10 minutes after the injection and repeated 4 hours later. A three-headed camera (Prism 3000, Picker, Cleveland, Ohio) equipped with low-energy, high-resolution parallel hole collimators was used. One hundred twenty projections were obtained over 360 degrees (3-degree stepwise increments), with an acquisition time of 45 seconds per head. The interpretation of the images reconstructed with 180-degree acquisition was made on the basis of six short-axis, three longitudinal, and three transverse long-axis slices. The analysis was visually performed with the assistance of quantitative measurements (circumferential profile analysis). Rest and redistribution images were displayed side by side for comparison. Analysis was performed by an experienced observer blinded to the results of LDDE. To obtain a matched regional assessment of wall motion and thallium uptake, the same 16-segment model used for interpretation of the echocardiogram was applied to interpret the SPECT images. The area falling >2 SD below mean normal values was calculated at each level, and the sum of the values was considered as the severity of global thallium uptake defect. Myocardial viability in dyssynergic segments was considered in the corresponding segment at RR TI in presence of normal perfusion, a reversible defect, or a fixed moderate defect with regional thallium uptake $\geq 50\%$ of maximal (100%) uptake.

Follow-up studies. A rest echocardiogram was performed in all patients at 3 months. The echocardiographic images were acquired in digital format and stored on the same optical disk used for the predischARGE study. The images of the baseline and follow-up echocardiogram were visualized side by side in a quad-screen format allowing a proper assessment of segmental changes. A regional improvement of left ventricular function was defined as a decrease of wall motion score ≥ 1 grade. An RR TI SPECT was performed in 18 of the 32 patients, and the analysis of the results was performed as previously described. The results were compared with those of the initial study to assess spontaneous changes of myocardial perfusion.

Statistics. Continuous data were expressed as

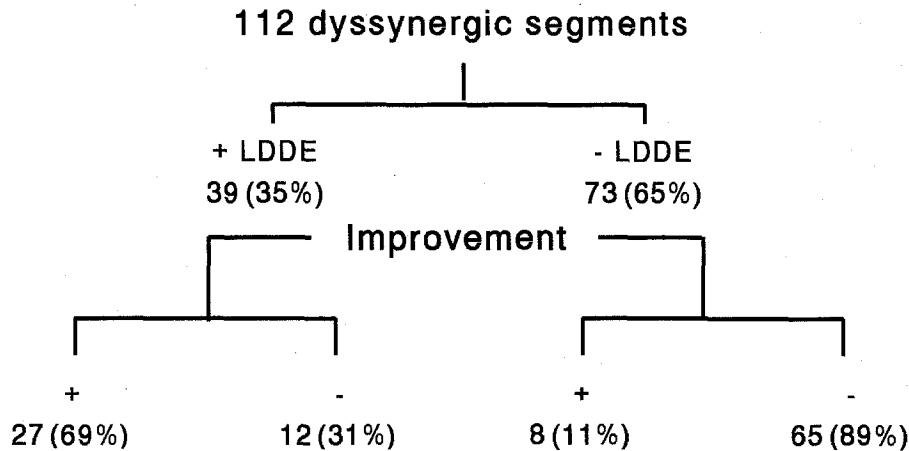


Fig. 2. Flow chart with results of LDDE for detection of myocardial viability in dyssynergic segments and improvement of contractility at follow-up.

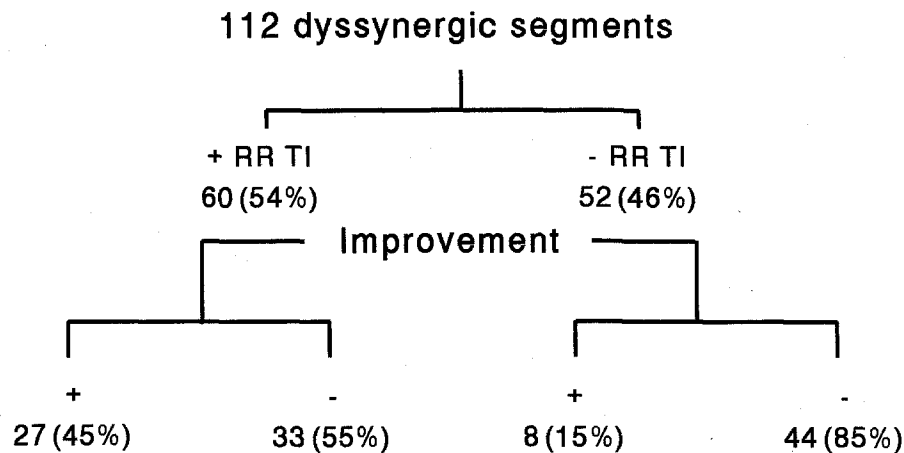


Fig. 3. Flow chart with results of RR TI SPECT for detection of myocardial viability in dyssynergic segments and improvement of contractility at follow-up.

mean \pm SD. Baseline and follow-up wall motion score index and thallium defect were compared by paired student's *t* test. Differences were considered significant when $p < 0.05$. The diagnostic accuracy of LDDE and RR TI was evaluated by calculating the sensitivity, specificity, positive and negative predictive value, and the corresponding 95% confidence interval. Agreement between the two methods was expressed by the K value. Values between 0.75 and 1 were considered indicative of good agreement, between 0.40 and 0.75 of moderate agreement, and between 0 and 0.40 of poor agreement.

RESULTS

No complications occurred during dobutamine infusion. Heart rate and systolic blood pressure at rest were 69 ± 14 beats/min and 120 ± 13 mm Hg, respectively, and did not change significantly during dobutamine infusion (73 ± 14 beats/min and $127 \pm$

18 mm Hg, respectively). During follow-up, two patients underwent coronary angioplasty for angina and were excluded from the analysis; the other 30 had an uncomplicated clinical course up to the repeated tests at 3 months after the infarction. Eighteen of these 30 remaining patients were studied at follow-up with RR TI.

Regional myocardial function and perfusion. Twenty segments were excluded from analysis because of poor quality. At baseline echocardiogram, 112 of the 460 segments analyzed were dyssynergic, and 35 (31%) had a late spontaneous improvement (14 patients). Viable myocardium was detected in 39 (35%) segments by LDDE and in 60 (54%) by RR TI (agreement 56%, K 0.15; Fig. 1). The prevalence of a viability pattern on RR TI was significantly higher compared with LDDE ($p < 0.005$).

Of the 39 dyssynergic segments with an improvement of wall motion during LDDE, 27 (69%) recovered at follow-up, whereas 8 (11%) of the 73 segments with a negative LDDE improved at follow-up (Fig. 2). A viability pattern on RR TI SPECT was present in 60 (54%) of the 112 dyssynergic segments. Wall motion at follow-up improved in 27 (45%) of these segments. Fifty two (46%) dyssynergic segments were not viable on RR TI; eight (15%) showed improvement of contractility at follow-up (Fig. 3).

Sensitivity, specificity, predictive values, and diagnostic accuracy of LDDE and RR TI SPECT in predicting late improvement of regional wall motion are reported in Table I. Sensitivity of both techniques was comparable; specificity and accuracy of LDDE were higher ($p < 0.0005$ and $p < 0.005$, respectively).

Sensitivity, specificity, predictive values, and accuracy of LDDE and RR TI for the overall prediction of functional recovery on patient basis are also shown in Table I. The number and distribution of dyssynergic segments with late functional improvement in relation to percentage perfusion defects at RR TI SPECT are shown in Fig. 4. This figure shows a trend to a lower prevalence of functional recovery in segments with more severe defects. Percentage of thallium defect in dyssynergic segments was significantly lower in segments with than without improvement at low-dose dobutamine ($34\% \pm 27\%$ vs $52\% \pm 22\%$, $p < 0.0005$) and in segments with than without late functional improvement ($38\% \pm 27\%$ vs $60\% \pm 14\%$, $p < 0.0001$).

Resting wall motion score index in the study group did not change significantly from baseline echocardiogram to follow-up (1.40 ± 0.29 vs 1.32 ± 0.28). The ECG of a woman with anterior infarction and late improvement of regional function is shown in Figs. 5 through 7 with baseline RR TI images and echocardiographic images at rest, low-dose dobutamine, and at follow-up.

Sequential changes of thallium uptake. In the 18 patients in whom RR TI SPECT at follow-up was performed, the mean value of the quantitative defect in the 66 dyssynergic regions analyzed decreased from $50\% \pm 19\%$ to $45\% \pm 18\%$ ($p < 0.001$). There was a trend toward a greater reduction of thallium defects in the regions with compared with those without a late recovery of contractility ($6.2\% \pm 14.2\%$ vs $4.9\% \pm 13.8\%$, $p =$ not significant). The index of severity of total thallium uptake defect decreased in the study group from 2137 ± 1321 to 1438 ± 947 ($p < 0.05$).

DISCUSSION

Several clinical observations have confirmed the experimental data on the frequent occurrence of a

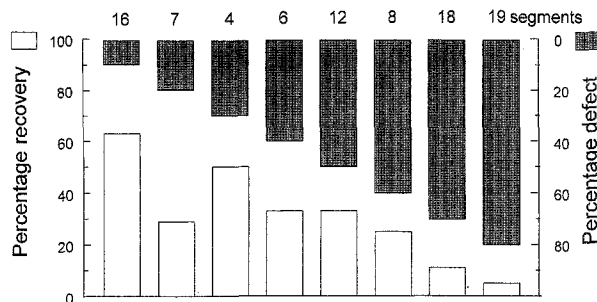


Fig. 4. Prevalence of functional recovery of dyssynergic segments according to percentage of perfusion defects (segments with reversible defects not included). Shows trend to lower probability of recovery with more severe defects.

spontaneous recovery of myocardial contractility during the first days after an acute myocardial infarction,^{21,22} consistent with the presence of a substantial amount of stunned myocardium. However, few clinical studies have been addressed to describe the late functional recovery of the infarcted area that occurs between 1 week and 3 months after the infarction,²⁻⁷ if such improvement is accompanied by a concomitant improvement of myocardial perfusion,²³ if improvement is predictable, and by which method it can be predicted.

In this study, LDDE and quantitative RR TI SPECT at a mean of 1 week after infarction were used to predict the late spontaneous recovery of regional left ventricular function after 3 months. The main findings of this study are (1) 31% of dyssynergic segments have a spontaneous improvement, (2) there is an improvement of thallium uptake in the dyssynergic regions of 10% (5% from 50% defect size) on average, (3) a contractile reserve of the dyssynergic regions detected by LDDE is a powerful predictor of late recovery of regional left ventricular function, and (4) a RR TI pattern of myocardial viability is equally sensitive but less specific for late spontaneous recovery of contractility.

Spontaneous improvement of left ventricular function and perfusion. Although this study had a small population, there is no previous clinical study with serial assessment of left ventricular function and thallium uptake from the first week up to 3 months after an acute myocardial infarction. The incidence of functional improvement of the dyssynergic segments of 31% was similar to that reported in other studies.^{7,8} Global left ventricular function assessed by wall motion score index showed a trend toward a slight improvement but did not reach statistical significance, possibly because of the small size of the study group. Myocardial regional thallium uptake in dyssyner-

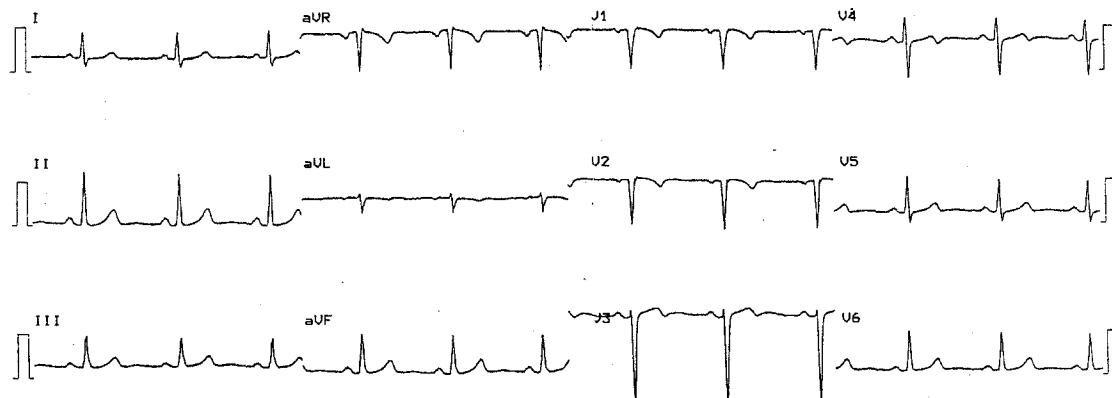


Fig. 5. Baseline electrocardiogram before dobutamine stress test of 45-year-old woman 7 days after uncomplicated Q-wave anterior myocardial infarction.

Table I. Diagnostic accuracy with 95% confidence intervals of LDDE and RR TI SPECT for predicting of spontaneous recovery of regional function

| | <i>SENS</i> | <i>SPEC</i> | <i>PPV</i> | <i>NPV</i> | <i>ACC</i> |
|---------------------------------------|-------------|-------------|------------|------------|------------|
| On segmental basis (n = 112 segments) | | | | | |
| LDDE | 77 | 84 | 69 | 89 | 82 |
| 95% CI | 69-85 | 78-91 | 61-78 | 83-95 | 75-89 |
| RR TI | 77 | 57 | 45 | 85 | 63 |
| 95% CI | 69-85 | 48-66 | 36-54 | 78-91 | 54-72 |
| On patient basis (n = 30 patients) | | | | | |
| LDDE | 79 | 75 | 73 | 80 | 77 |
| 95% CI | 64-93 | 60-90 | 58-89 | 66-94 | 62-92 |
| RR TI | 71 | 56 | 59 | 69 | 63 |
| 95% CI | 55-88 | 38-74 | 41-76 | 53-86 | 46-81 |

SENS, Sensitivity; *SPEC*, specificity; *PPV*, positive predictive value; *NPV*, negative predictive value; *ACC*, diagnostic accuracy; *CI*, confidence intervals.

gic regions improved significantly at follow-up. In our study, a state-of-the-art method was used to assess myocardial viability, including RR TI SPECT,^{10,24} multiple-head camera, quantitative assessment of regional uptake, and premedication with nitrates.²⁵ The data of our study are consistent with the results recently published by Galli et al.²³ with 99m Tc sestamibi. This finding is not surprising because recent data have demonstrated a great similarity between thallium and sestamibi in assessing myocardial viability.²⁶ Spontaneous improvement of perfusion may be attributed to a late resolution of myocardial and vascular stunning,²³ the creation of new macro- or microcollateral circuits, and spontaneous thrombolysis.⁹ A late resolution of thallium defects has been also described in clinical models of hibernating myocardium after successful coronary angioplasty.²⁷

Predictors of improvement of regional left ventricular function. LDDE was a strong predictor of spontaneous improvement of regional wall motion (Table I).

These data are aligned with those of previous reports.²⁻⁷ In contrast, the assessment of myocardial viability by thallium scintigraphy could only identify segments with low probability but not those with high probability of spontaneous improvement.

Explanations for these discordant results are difficult to find. Time course of improvement of myocardial perfusion and function might be different, unabling a proper prediction of one parameter from the other. The low specificity of thallium to predict improvement of wall motion can also be partially related to the presence of hibernating myocardium subtended by severely stenotic coronary lesions, which is amenable to improvement after revascularization. However, this assumption entails a limited sensitivity of LDDE in detecting myocardial viability in a hibernating myocardium because most of the nonrecovered segments with evidence of viability on RR TI were identified as nonviable by LDDE. Despite the advantage of thallium scintigraphy over echocardiography in terms of quantitative assessment of

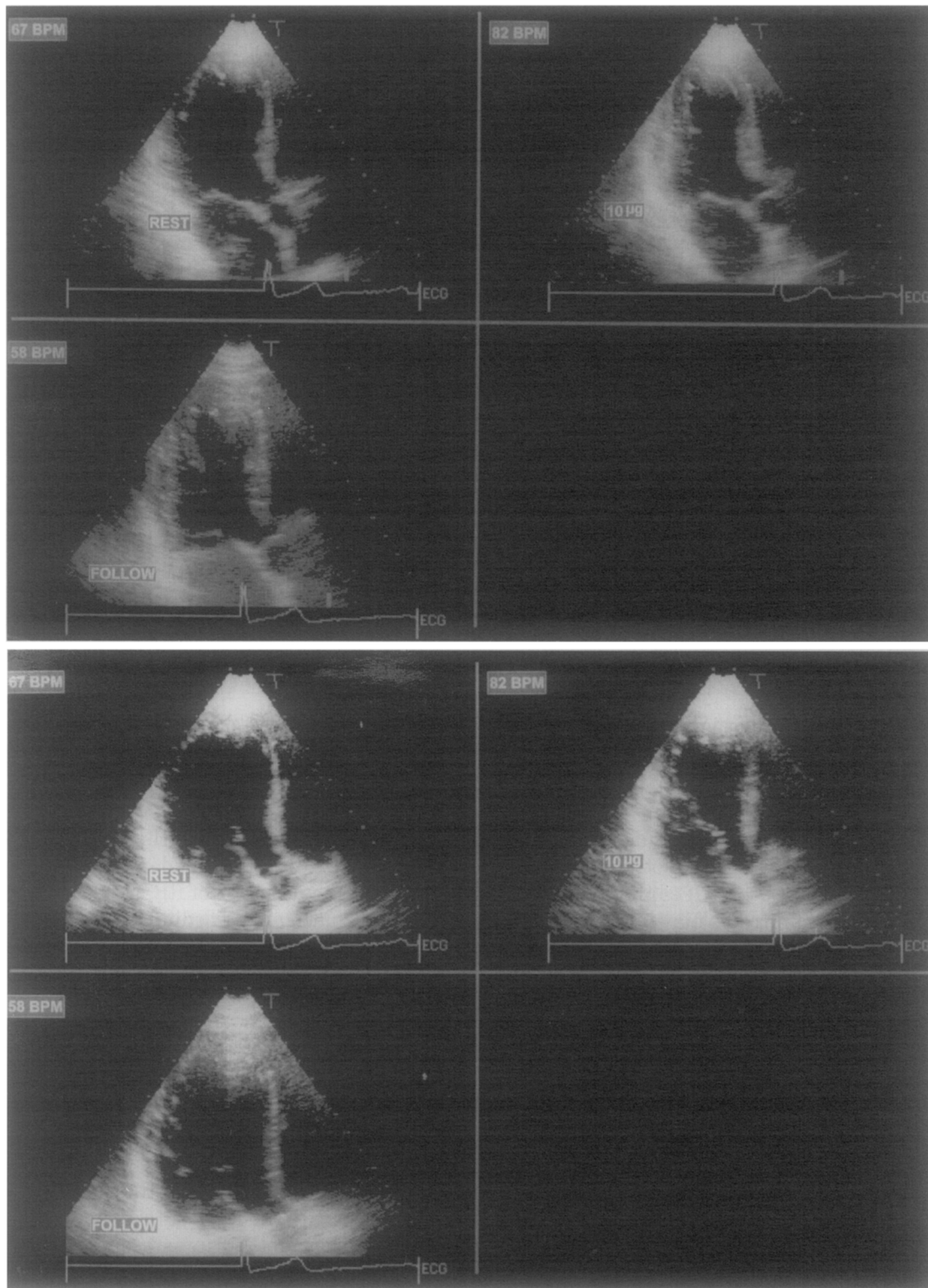


Fig. 6. Same patient as in Fig. 5. Systolic (*top*) and diastolic (*bottom*) echocardiographic frames in apical long-axis view of same patient at rest, low-dose dobutamine (10 µg/kg/min), and at follow-up shows hypokinesis of anterior septum at rest, with improvement of thickening at low-dose dobutamine. Follow-up resting echocardiogram performed after 3 months shows improvement of thickening of anterior septum.

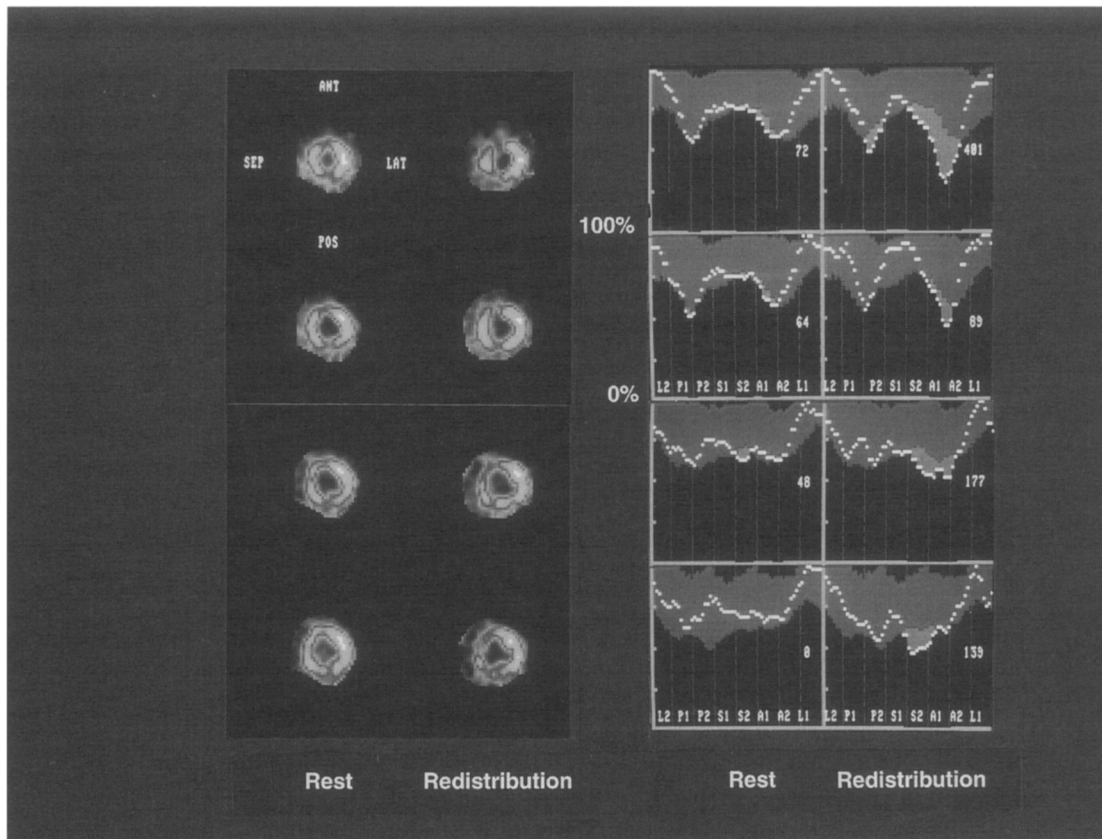


Fig. 7. Same patient as in Figs. 5 and 6. RR Tl SPECT images in short-axis slices from apex to mid septum (top to bottom) with corresponding circumferential profile analysis shows viability of septum evidenced by normal rest perfusion.

abnormalities, it has inherent technical limitations because it provides relative and not absolute information on myocardial uptake. It cannot be excluded that premedication of nitrates may improve the sensitivity of RR TI at the expense of specificity. Because of the potential for hypokinesis to occur in normal subjects,²⁸ some hypokinetic segments may not be related to the acute coronary events. Consequently, these segments may show evidence of viability without improvement at follow-up and compromise the accuracy of the two techniques.

Comparison with previous studies. Lomboy et al.²⁹ studied 31 patients 2 days after acute myocardial infarction with planar RR TI. Twenty-two patients underwent radionuclide angiography 3 days after infarction and at a variable follow-up period. The presence of viability pattern in the infarct zone was predictive of improvement of ejection fraction and regional function on follow-up radionuclide angiogram as opposed to patients without viability pattern who had worsening of ejection fraction and regional function. These different results compared with our study can be explained by the difference in patient

population and method. In the Lomboy et al. study, revascularization performed in 17 patients may have enhanced the accuracy of RR TI because of recovery of a hibernating myocardium. A limitation of that study is the lack of consistency in the time of obtaining follow-up studies of myocardial function by radionuclide angiography, which ranged from 6 to 270 days, with 64% of the studies performed before discharge (8 ± 2 days after infarction). It has been previously demonstrated that a substantial proportion of myocardial segments may recover spontaneously from 7 days to 2 to 3 months after acute myocardial infarction.^{6,7} These segments would be considered nonviable if the follow-up studies were performed earlier. Despite the fact that radionuclide angiography is a good method to assess global function, its value in assessing regional function may be limited by the inability to assess wall thickening. The latter fact is important in assessing myocardial viability because endocardial excursion alone may be passively altered by an adjacent segment. The echocardiographic technique is more useful in the tomographic evaluation of regional wall motion and thick-

ening and consequently provides tomographic abilities equivalent to those of RR TI SPECT imaging.

Agreement between thallium scintigraphy and low-dose dobutamine echocardiography on presence of myocardial viability. Two recent studies of patients with chronic left ventricular dysfunction and reduced ejection fraction have shown that a viability pattern is more frequently obtained with stress-reinjection thallium techniques than with LDDE, consistent with our findings on RR TI after acute infarction.^{20, 30} Arnese et al.²⁰ recently reported that in patients with chronic left ventricular dysfunction, LDDE and dobutamine stress-reinjection thallium scintigraphy have a comparable sensitivity for predicting regional myocardial recovery after surgical revascularization, whereas specificity of LDDE was significantly higher than thallium scintigraphy.

Panza et al.³⁰ reported that a positive inotropic response to dobutamine was directly related to the magnitude of thallium uptake. In our study, thallium uptake in dyssynergic segments was significantly higher in segments with than without improvement at LDDE and in segments with than without late functional improvement. It was suggested that the cellular mechanisms responsible for a positive inotropic response to adrenergic stimulation require a higher degree of myocyte functional integrity than those responsible for thallium uptake.³⁰ This possibility may explain the lower specificity of thallium scintigraphy in the study of Arnese et al. and in this study by the possibility that only myocytes with a high degree of functional integrity are capable of restoration of function spontaneously or after revascularization.

Study limitations. This study group was limited to patients with a relatively uncomplicated clinical course and mildly or moderately reduced left ventricular function. The extension of this information to a group of patients with more advanced left ventricular dysfunction would be desirable and clinically more relevant. Coronary arteriography was performed in a minority of patients, and therefore the association between angiographic anatomy and the functional outcome could not be performed. It cannot be excluded that some of the dyssynergic segments classified as viable by RR TI, which did not improve at follow-up, represent myocardial hibernation from the presence of significant stenosis of the related coronary artery.

Regional function was assessed at baseline and at follow-up studies rather than global function, which represents an important determinant of prognosis after acute myocardial infarction.³¹ However, the occurrence of compensatory hypertrophy after acute

infarction tends to preserve the global ejection fraction.⁸⁻³² This hypertrophy may resolve when improvement of regional function occurs, and thus ejection fraction may not change from baseline to follow-up despite regional improvement.⁸

Identification of myocardial segments of interest was made on the basis of echocardiographic analysis, which may seem to be in favor of a better accuracy of LDDE. Since echocardiography is an accurate method for assessing regional function, we believe that identification of dyssynergic myocardial segments by using a baseline echocardiogram is feasible for selecting myocardial regions of interest. A recent study by Panza et al.³⁰ used a similar approach.

Conclusions. The prevalence of a viability pattern on RR TI is higher than on LDDE in dyssynergic segments after acute myocardial infarction. About one third of these segments showed spontaneous improvement of wall motion from day 7 to 3 months; this improvement is paralleled by an improvement of thallium uptake. Our study also demonstrates that both LDDE and RR TI are equally sensitive but that LDDE is a more specific predictor of late spontaneous recovery of regional function.

We thank Ilonka Hoffmanns-van den Ancker for her invaluable help in the arrangement of follow-up studies.

REFERENCES

1. Picard MH, Wilkins GT, Ray PA, Weyman AE. Natural history of left ventricular size and function after acute myocardial infarction. Assessment and prediction by echocardiographic endocardial surface mapping. *Circulation* 1990;82:484-94.
2. Pierard LA, De Landsheere CM, Berthe C, Rigo P, Kulbertus HE. Identification of viable myocardium by echocardiography during dobutamine infusion in patients with myocardial infarction after thrombolytic therapy: comparison with positron emission tomography. *J Am Coll Cardiol* 1990;15:1021-31.
3. Smart SC, Sawada S, Ryan T, Segar D, Atherton L, Berkovitz K, Bourdillon PD, Feigenbaum H. Low-dose dobutamine echocardiography detects reversible dysfunction after thrombolytic therapy of acute myocardial infarction. *Circulation* 1993;88:405-15.
4. Previtali M, Poli A, Lanzarini L, Fetiveau R, Mussini A, Ferrario M. Dobutamine stress echocardiography for assessment of myocardial viability and ischemia in acute myocardial infarction treated with thrombolysis. *Am J Cardiol* 1993;72:124G-30G.
5. Salustri A, Elhendy A, Garyfallydis P, Ciavatti M, Cornel JH, Ten Cate FJ, Boersma E, Gemelli A, Roelandt JRTC, Fioretti PM. Prediction of recovery of ventricular dysfunction after first acute myocardial infarction using low-dose dobutamine echocardiography. *Am J Cardiol* 1994;74:853-66.
6. Watada H, Ito H, Oh H, Masuyama T, Aburaya M, Hori M, Iwakura M, Higashino Y, Fujii K, Minamino T. Dobutamine stress echocardiography predicts reversible dysfunction and quantitates the extent of irreversibly damaged myocardium after reperfusion of anterior myocardial infarction. *J Am Coll Cardiol* 1994;24:624-30.
7. Salustri A, Garyfallydis P, Elhendy A, Ciavatti M, Cornel JH, Gemelli A, Ten Cate FJ, Roelandt JRTC, Fioretti PM. T-wave normalization during dobutamine echocardiography for the diagnosis of viable myocardium. *Am J Cardiol* 1995;75:505-7.
8. Braunwald E, Kloner RA. The stunned myocardium: prolonged, post-ischemic ventricular dysfunction. *Circulation* 1982;66:1146-9.

9. Bolli R. Myocardial stunning in man. *Circulation* 1992;86:1671-91.
10. Ragosta M, Beller GA, Watson DD, Kaul S, Gimple LW. Quantitative planar rest-redistribution 201-Tl imaging in detection of myocardial viability and prediction of improvement in left ventricular function after coronary bypass surgery in patients with severely depressed left ventricular function. *Circulation* 1993;87:1630-41.
11. Yoshida K, Gould KL. Quantitative relation of myocardial infarct size and myocardial viability by positron emission tomography to left ventricular ejection fraction and 3-year mortality with and without revascularization. *J Am Coll Cardiol* 1993;22:984-97.
12. Barilla F, Gheorghide M, Alam M, Khaja F, Goldstein S. Low-dose dobutamine in patients with acute myocardial infarction identifies viable but not contractile myocardium and predicts the magnitude of improvement in wall motion abnormalities in response to coronary revascularization. *Am Heart J* 1991;122:1522-31.
13. Cigarroa CG, deFilippi CR, Brickner E, Alvarez LG, Wait MA, Grayburn PA. Dobutamine stress echocardiography identifies viable myocardium and predicts recovery of left ventricular function after coronary revascularization. *Circulation* 1993;88:430-6.
14. La Canna G, Alfieri O, Giubbini R, Gargano M, Ferrari R, Visioli O. Echocardiography during infusion of dobutamine for identification of reversible dysfunction in patients with chronic coronary artery disease. *J Am Coll Cardiol* 1994;23:617-23.
15. Marzullo P, Parodi O, Reisenhofer B, Sambucetti G, Picano E, Distanti A, Gimelli A, L'Abbate A. Value of thallium-201/technetium-99m sestamibi scans and dobutamine echocardiography for detecting myocardial viability. *Am J Cardiol* 1993;71:166-72.
16. Charney R, Schwinger ME, Chun J, Cohen MV, Nanna M, Menegus MA, Wexler J, Franco HS, Greenberg MA. Dobutamine echocardiography and resting-redistribution thallium-201 scintigraphy predicts recovery of hibernating myocardium after coronary revascularization. *Am Heart J* 1994;128:864-9.
17. Ellis SG, Wynne J, Braunwald E, Henschke CI, Sandor T, Kloner RA. Response of reperfusion-salvaged, stunned myocardium to inotropic stimulation. *Am Heart J* 1984;107:13-9.
18. Bolli R, Zhu W, Myers ML, Hartley CJ, Roberts R. Beta-adrenergic stimulation reverses postischemic myocardial dysfunction without producing subsequent functional deterioration. *Am J Cardiol* 1985;56:964-8.
19. Schiller NB, Shah PM, Crawford M, DeMaria A, Devereux R, Feigenbaum H, Gutgesell H, Reichek N, Sahn D, Schnittger I. Recommendations for quantitation of the left ventricle by two-dimensional echocardiography. *J Am Soc Echocardiogr* 1989;2:358-67.
20. Arnese M, Cornel JH, Salustri A, Maat APWM, Elhendy A, Reijs AEM, Ten Cate FJ, Keane D, Balk AHMM, Roelandt JRTC, Fioretti PM. Prediction of improvement of regional left ventricular function after surgical revascularization: a comparison of low-dose-dobutamine echocardiography with 201-Tl single-photon emission computed tomography. *Circulation* 1995;91:2748-52.
21. Ellis SG, Henschke CI, Sandor T, Wynne J, Braunwald E, Kloner RA. Time course of functional and biochemical recovery of myocardium salvaged by reperfusion. *J Am Coll Cardiol* 1983;1:1047-55.
22. Bolli R, Zhu W, Thornby JJ, O'Neill PG, Roberts R. Time course and determinants of function after reversible ischemia in conscious dogs. *Am J Physiol* 1988;254:H102-14.
23. Galli M, Marcassa C, Bolli R, Giannuzzi P, Temporelli PL, Imparato A, Silva Orrego PL, Giubbini R, Giordano A, Tavazzi L. Spontaneous delayed recovery of perfusion and contraction after the first 5 weeks after anterior infarction. Evidence for the presence of hibernating myocardium in the infarcted area. *Circulation* 1994;90:1386-97.
24. Dilsizian V, Bonow RO. Current diagnostic techniques of assessing myocardial viability in patients with hibernating and stunned myocardium. *Circulation* 1993;87:1-16.
25. He ZX, Darcourt J, Guigner A, Ferrari E, Bussiere F, Baudouy M, Mornad P. Nitrates improve detection of ischemic but viable myocardium by thallium-201 reinjection SPECT. *J Nucl Med* 1993;34:1472-7.
26. Dilsizian V, Arrighi J, Diodati JG, Quyyumi AA, Alavi K, Bacharach SL, Marin-Neto JA, Katsiyannis PT, Bonow RO. Myocardial viability in patients with chronic coronary artery disease. Comparison of 99mTc/sestamibi with thallium reinjection and [18F] fluorodeoxyglucose. *Circulation* 1994;89:578-87.
27. Manyari DE, Knudtson M, Kloiber R, Roth D. Sequential thallium-201 myocardial perfusion studies after successful percutaneous transluminal coronary artery angioplasty: delayed resolution of exercise-induced scintigraphic abnormalities. *Circulation* 1988;77:86-95.
28. Pandian NG, Skorton DJ, Collins SM, Falsetti HL, Burke ER, Kerber RE. Heterogeneity of left ventricular segmental wall thickening and excursion in 2-dimensional echocardiography of normal human subjects. *Am J Cardiol* 1983;51:1667-73.
29. Lomboy CT, Schulman DS, Grill HP, Flores AR, Orie JE, Grant JE. Rest-redistribution thallium-201 scintigraphy to determine myocardial viability early after myocardial infarction. *J Am Coll Cardiol* 1995;25:210-7.
30. Panza JA, Dilsizian V, Laurienzo JM, Curiel RV, Katsiyannis PT. Relation between thallium uptake and contractile response to dobutamine. Implication regarding myocardial viability in patients with chronic coronary artery disease and left ventricular dysfunction. *Circulation* 1995;91:990-8.
31. The Multicenter Postinfarction Research Group. Risk stratification and survival after myocardial infarction. *N Engl J Med* 1983;309:331-6.
32. Stack RS, Phillips HR III, Grierson DS, Behar VS, Kong Y, Peter RH, Swain JL, Greenfield JC. Functional improvement of jeopardized myocardium following intracoronary streptokinase infusion in acute myocardial infarction. *J Clin Invest* 1983;66:1421-6.