

Subfascial Endoscopic Ligation in the Treatment of Incompetent Perforating Veins

E. G. J. M. Pierik¹, C. H. A. Wittens¹ and H. van Urk²

¹Department of Surgery, Sint Franciscus Gasthuis, and ²Department of Surgery, Vascular Unit, University Hospital Rotterdam-Dijkzigt Rotterdam, The Netherlands

Objectives: To assess the technique of subfascial endoscopic ligation of incompetent perforatory veins by use of a mediastinoscope.

Design: Prospective open clinic study.

Setting: Two Departments of Surgery.

Materials and Methods: Thirty-eight consecutive patients (40 legs) with recurrent or protracted venous ulceration of the lower leg were treated. Through a short, transverse incision of the skin and fascia in the proximal $\frac{1}{3}$ of the lower leg a mediastinoscope (length 18 cm, diameter 12 mm) is inserted after which the perforating veins are ligated by haemoclips under direct vision.

Main Results: All legs showed signs of incompetent perforating veins by clinical examination, confirmed with continuous wave ultrasonography and in 31 legs there was associated deep vein incompetence. Sixteen patients had active ulceration at the moment of operation and 22 had a history of recent or recurrent ulceration. One patient developed an inflammatory reaction at the wound and in two legs a subfascial infection occurred, necessitating surgical drainage. No postoperative mortality was seen. All 16 ulcers healed within 2 months (mean: 34 days; range: 21-55 days). During a mean follow-up of 3.9 (range: 2-5) years only one out of 38 patients (2.5%) developed a recurrent ulcer.

Conclusions: Subfascial endoscopic ligation of incompetent perforating veins by use of a mediastinoscope is a relatively simple technique with a low postoperative complication rate and a low recurrent ulcer rate which makes it a valuable method for treating incompetent perforating veins.

Key Words: Venous ulceration; Subfascial endoscopy; Endoscopic ligation of perforating veins.

Introduction

Chronic leg ulceration affects about 1% of the European population at some point in their lives.^{1,2} Although the pathogenesis of venous ulceration is imperfectly understood, it is generally agreed that the transmission of high ambulatory pressures through incompetent perforating veins plays a major role.³⁻⁹

The treatment of these incompetent perforating calf veins consists of either direct surgical ligation as described by Linton¹⁰ or injection compression therapy popularised by Fergan.¹¹ Injection therapy guided by either clinical examination, ultrasound or ascending phlebography will miss approximately 40% of the incompetent perforating veins.¹² Since no single method predicts the site of all incompetent perfora-

tors, a full surgical exploration is essential to interrupt all incompetent perforating veins. These operations, as described by Linton,¹³ Cockett¹⁴ and Dodd,¹⁵ are simple and often successful, but necessitate long incisions through compromised skin and subcutaneous layers. Consequently, delayed wound healing, skin necrosis and wound infection frequently occur and complication rates of up to 58% have been reported.^{16,17}

As part of the trend towards minimally invasive surgery, endoscopic techniques have been developed which allow subfascial ligation and division of perforating veins under direct vision and with minor trauma.¹⁸⁻²⁰ New and often complex instruments have been devised for this procedure.

This study reports the first results of the endoscopic, subfascial ligation of incompetent perforating veins in patients with venous ulceration, by use of a simple, cheap and readily available instrument, namely the mediastinoscope.

Please address all correspondence to: C. H. A. Wittens, Sint Franciscus Gasthuis, Kleiweg 500, 3045 PM Rotterdam, The Netherlands

Patients and Methods

The study included 38 consecutive patients referred with recurrent (last ulceration less than 3 months ago) or protracted ulceration between March 1986 and April 1990. Twenty-eight women and 10 men, ranging in age from 38 to 73 years (mean age, 56.3 years) were treated. Two patients (both women) had bilateral ulcers. Thirteen patients had a history suggestive of deep vein thrombosis. Twenty patients had previously undergone unsuccessful surgery. All patients were studied by clinical examination (tourniquet-tests and palpation) and continuous wave ultrasonography. All showed symptoms and signs of incompetent perforating veins, four patients had incompetence of the long saphenous vein and in 31 patients associated deep vein incompetence was found.

Below-knee graduated elastic stockings (Class II) were fitted in all cases, with instructions to wear them pre- and postoperatively throughout the day. Sixteen patients still had active ulceration at the time of operation. All patients underwent endoscopic ligation of perforating veins, in four patients additional ligation and partial stripping of the long saphenous vein was performed.

All of the 38 patients returned for follow-up examination, for a period of 2 to 5 years postoperatively (mean follow-up: 3.9 years).

Technique

The operation is performed under spinal anaesthesia with the patient in supine position. After a short incision in the skin crease at the antero-medial side of the proximal third of the lower leg, the fascia is incised horizontally over 2 cm. Subsequently, the virtual subfascial space is opened by gentle finger dissection. A mediastinoscope is introduced in this space and pushed downward beneath the fascia to the level of the medial malleolus, separating the fascia from the underlying muscle.

A mediastinoscope with a length of 18 cm and a diameter of 12 mm, a light source and a long clipping instrument are used. This allows examination of the same subfascial area which is explored in the open subfascial operation (Fig. 1). Under direct vision all communicating veins (competent and incompetent) crossing this space are ligated with haemoclips and dissected (Fig. 2). After removal of the scope a fasciotomy of 10 cm was performed in the first 17 legs in order to prevent an anticipated muscle hernia. No

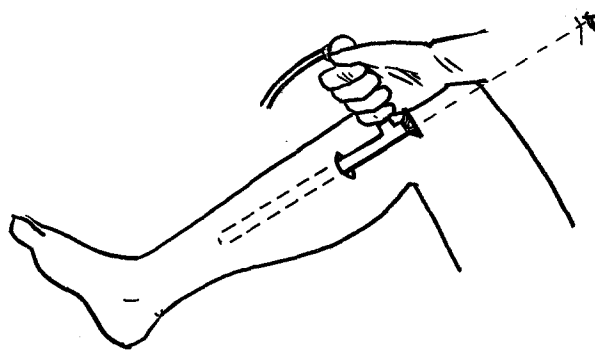


Fig. 1. Schematic drawing of a mediastinoscope introduced in the subfascial space.

drains are used and the skin is sutured in one running layer. Finally, the operated leg is covered with cotton wool and crêpe bandages. All patients are mobilized on the first postoperative day.

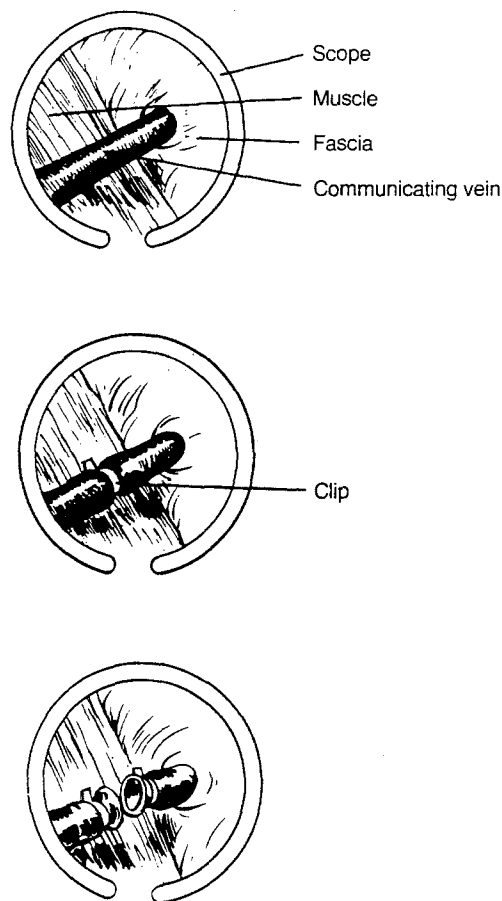


Fig. 2. Schematic drawing of the image of the subfascial space as seen through the mediastinoscope: (a) a communicating vein perforating the fascia, (b) a clipped perforating vein, (c) a clipped and divided perforating vein.

Results

Mean duration of the subfascial endoscopy was 21 minutes (range: 10–42). During operation between 1 and 5 perforating veins (mean: 2.4) were identified and ligated. In no patient did the endoscopic approach have to be converted into open exploration.

One patient developed an inflammatory reaction at the introduction site which was treated conservatively. One patient, operated on both legs, developed a subfascial infection on both sides necessitating surgical drainage, after which complete recovery occurred. In all other patients the wounds healed primarily. No patients, treated with or without fasciotomy, showed signs of muscle hernia. No subcutaneous haematoma formation nor signs of nerve damage were found.

All 16 ulcers still open at the time of operation healed within 2 months (mean: 34 days; range: 21–55 days). During a mean follow-up of 3.9 (range: 2–5) years only one out of 38 patients (2.5%) developed a recurrent ulcer, 2 years after operation.

Discussion

Adequate ambulatory compression therapy achieves healing of most venous ulcers, but recurrence is frequent and has been reported to affect up to 49% of patients at 3 months²¹ and 22–69% at 1 year after healing.^{21,22} Negus and Friedgood showed a recurrence rate of only 15% in a 6-year study of 109 ulcerated legs after ligation of incompetent perforating veins through a postero-medial approach.⁷ The present study showed a recurrence rate of only 2.5% after a mean follow-up of 3.9 years, 39 of 40 extremities of patients who had active ulceration or healed ulceration remained healed. The patient who developed a recurrent ulcer had an active ulcer at the time of operation which healed within 4 weeks. This was a patient with associated deep vein incompetence by ultrasonography.

Conventional operative approaches to ligate incompetent perforating veins require long incisions, often through highly atrophic and poorly nourished skin and subcutaneous tissues, and are frequently associated with delayed wound healing, skin necrosis and wound infection.^{7,14,23} To overcome these wound problems Edwards devised a phlebostome.²⁴ This instrument is introduced under the fascia some distance from the area of lipodermatosclerosis and shears off all perforating veins. The disadvantages of this technique are that it is a blind method and painful

subfascial haematomas occur. Subfascial endoscopy combines the advantage of Edwards introduction site and treatment under direct visual control. Our 7.5% wound complication rate is low and is comparable with the findings of Jugenheimer *et al.* who reported 3% delayed wound healing and 6% subcutaneous haematomas after endoscopic treatment of 72 patients with primary varicosis.²⁵ A mediastinoscope is present in most operating rooms and obviates the need to purchase special instruments.

In conclusion, subfascial ligation of incompetent perforating veins by use of a mediastinoscope is a fast and easy surgical procedure with a low complication rate which allows early ambulation and good cosmesis, with a low rate of recurrent venous ulceration.

References

- DALE JJ, CALLAM MJ, RUCKLEY CV, HARPER DR, BERRY PN. Chronic ulcers of the leg: a study of prevalence in a Scottish community. *Health Bull* 1983; **41**: 310–314.
- CALLAM MJ, RUCKLEY CV, HARPER DR, DALE JJ. Chronic ulceration of the leg: extent of the problem and provision of care. *BMJ* 1985; **290**: 1855–1856.
- COCKETT FB, JONES BE. The ankle blow-out syndrome: A new approach to the varicose ulcer problem. *Lancet* 1953; **i**: 17–23.
- DODD H, COCKETT FB. *The Pathology and Surgery of the Veins of the Lower Limb*. Edinburgh: E & S Livingstone, 1956.
- Venous ulcers (editorial). *Lancet* 1977; **i**: 522.
- BROWSE NL, BURNAND KG. The cause of venous ulceration. *Lancet* 1982; **ii**: 243–245.
- NEGUS D, FRIEDGOOD A. The effective management of venous ulceration. *Br J Surg* 1983; **70**: 623–627.
- WILKINSON GE, MACLAREN IF. Long term review of procedures for venous perforator insufficiency. *Surg Gyn Obstet* 1986; **163**: 117–120.
- NASH TP. Venous ulceration: factors influencing recurrence after standard surgical procedures. *Med J Aust* 1991; **154**: 48–50.
- LINTON RR. The communicating veins of the lower leg and the operative technic for their ligation. *Ann Surg* 1938; **107**: 582–593.
- FEGAN WG. Continuous compression technique of injecting varicose veins. *Lancet* 1963; **ii**: 109–112.
- O'DONNELL TF, BURNAND KG, CLEMENSON G, THOMAS ML, BROWSE NL. Doppler examination versus clinical and phlebographic detection of the location of incompetent perforating veins. *Arch Surg* 1977; **112**: 31–35.
- LINTON RR. The post-thrombotic ulceration of the lower extremity: its etiology and surgical treatment. *Ann Surg* 1953; **138**: 415–432.
- COCKETT FB. The pathology and treatment of venous ulcers of the leg. *Br J Surg* 1956; **43**: 260–278.
- DODD H. The diagnosis and ligation of incompetent perforating veins. *Ann R Coll Surg Engl* 1964; **34**: 186–196.
- FIELD P, VAN BOXEL P. The role of the Linton flap procedure in the management of stasis, dermatitis and ulceration in the lower limb. *Surgery* 1971; **70**: 920–926.
- PUTS JP, GRUWEZ JA. Surgical treatment of the post-thrombotic syndrome: improvement of the Linton operation by use of piracetam. *Br J Surg* 1993; **80** (Suppl): 115.
- HAUER G. Die endoscopische subfasciale diszision der perforansvenen-vorlaufige mitteilung. *VASA* 1985; **14**: 59.

- 19 FISCHER R. Surgical treatment of varicose veins; endoscopic treatment of incompetent Cockett veins. *Phlebologie* 1989; 1040-1041.
- 20 JUGENHEIMER M, NAGEL K, JUNGINGER TH. Ergebnisse der endoskopischen perforans-dissektion. *Chirurg* 1991; 62: 625-628.
- 21 MONK BE, SARKANY I. Outcome of treatment of venous stasis ulcers. *Clin Exp Dermatol* 1982; 7: 397-400.
- 22 BLAIR SD, WRIGHT DDI, BACKHOUSE CM, RIDDLE E, MCCOLLUM CN. Sustained compression and healing of chronic venous ulcers. *BMJ* 1988; 297: 159-161.
- 23 HAEGER K. Five-year results of radical surgery for superficial varices with or without coexistent perforator insufficiency. *Acta Chir Scand* 1966; 131: 38-49.
- 24 EDWARDS JM. Shearing operation for incompetent perforating veins. *Br J Surg* 1976; 63: 885-886.
- 25 JUGENHEIMER M, JUNGINGER TH. Endoscopic subfascial sectioning of incompetent perforating veins in treatment of primary varicosis. *World J Surg* 1992; 16: 971-975.

Accepted 11 April 1994