

## STRESS TESTING

**Dobutamine-Induced Hypoperfusion Without Transient Wall Motion Abnormalities: Less Severe Ischemia or Less Severe Stress?**

ABDOU ELHENDY, MD, PhD, MARCEL L. GELEIJNSE, MD, JOS R. T. C. ROELANDT, MD, FACC, RON T. VAN DOMBURG, MSc, FOLKERT J. TENCATE, MD, FACC, JAN H. CORNEL, MD, AMBROOS E. M. REIJS, MSc, GALAL M. EL-SAID, MD, FACC, PAOLO M. FIORETTI, MD, PhD  
Rotterdam, The Netherlands

**Objectives.** This study sought to compare the clinical characteristics, hemodynamic response and severity of ischemia in patients with coronary artery disease and reversible perfusion defects on dobutamine 2-methoxy isobutyl isonitrile (MIBI) single-photon emission computed tomography (SPECT) with or without transient wall motion abnormalities.

**Background.** The occurrence of reversible perfusion defects without concomitant wall motion abnormalities in patients with coronary artery disease was attributed to less severe ischemia. However, little data are available to support this observation.

**Methods.** Fifty-four consecutive patients with significant coronary artery disease and reversible perfusion defects on dobutamine (up to 40  $\mu\text{g}/\text{kg}$  body weight per min) MIBI SPECT were studied (mean  $\pm$  SD] age  $59 \pm 11$  years; 38 men, 16 women). All patients underwent simultaneous echocardiography. The myocardium was divided into six matched segments, and ischemic perfusion score was quantitatively derived in myocardial segments with reversible defects.

**Results.** New or worsening wall motion abnormalities occurred in 40 patients (74%) (group A) and were absent in 14 (26%)

(group B). There was no significant difference between the two groups with respect to age, previous myocardial infarction, number of abnormal coronary arteries ( $1.8 \pm 0.8$  vs.  $1.6 \pm 0.9$ ), number of reversible perfusion defects ( $1.6 \pm 0.9$  vs.  $1.8 \pm 0.7$ ) or ischemic perfusion score ( $412 \pm 750$  vs.  $526 \pm 553$ ). Patients in group A had a higher prevalence of male gender (80% vs. 43%,  $p < 0.01$ ), higher peak systolic blood pressure ( $147 \pm 30$  vs.  $127 \pm 31$  mm Hg;  $p < 0.05$ ), higher peak rate-pressure product ( $19,632 \pm 4,067$  vs.  $16,939 \pm 4,344$ ,  $p < 0.01$ ) and a higher prevalence of angina (53% vs. 14%) and ST segment depression (55% vs. 14%) than group B ( $p < 0.05$  for both).

**Conclusions.** In patients with coronary artery disease and ischemia on dobutamine MIBI SPECT, the absence of transient wall motion abnormalities is associated with a similar extent and severity of reversible perfusion defects, a lower stress rate-pressure product and a higher prevalence of female gender than patients with transient wall motion abnormalities. Mechanically silent ischemia should not be regarded as a marker of less severe ischemia on myocardial perfusion scintigraphy.

(*J Am Coll Cardiol* 1996;27:323-9)

The diagnosis of myocardial ischemia relies on the detection of different pathophysiologic sequelae of coronary artery disease. These include reversible hypoperfusion and wall motion abnormalities, ST segment depression and typical anginal pain (1-3). Reversible perfusion and wall motion abnormalities during exercise or pharmacologic stress testing are the most accurate markers of myocardial ischemia in patients referred for evaluation of coronary artery disease (1-14). It has been demonstrated that hypoperfusion precedes the occurrence of wall motion abnormalities in the ischemic cascade (15,16). The severity of myocardial ischemia assessed by thallium scintigraphy has been reported to determine the occurrence or absence

of concomitant transient wall motion abnormalities during a dobutamine stress test (17). If this is confirmed by other studies, a combination of reversible perfusion defects and transient wall motion abnormalities would identify patients with severe ischemia and provide additional data for the management and prognostic stratification of patients with coronary artery disease. The present study sought to compare the clinical, hemodynamic and scintigraphic variables in patients with coronary artery disease and reversible perfusion defects on dobutamine 2-methoxy isobutyl isonitrile (MIBI) single-photon emission computed tomography (SPECT), with and without transient wall motion abnormalities, on simultaneous echocardiography.

## Methods

**Patient selection.** The study included 54 consecutive patients with chest pain and inability to perform an adequate exercise test who were referred to our cardiac stress imaging laboratory for dobutamine stress echocardiography in conjunction with MIBI SPECT myocardial perfusion imaging. All

From the Thoraxcenter and Department of Nuclear Medicine, University Hospital Rotterdam-Dijkzigt and Erasmus University, Rotterdam, The Netherlands. This study was supported in part by the Department of Cardiology, Cairo University Hospital, Cairo, Egypt, and the Dutch Heart Foundation, Den Haag, The Netherlands, by Grant NHS 94.135.

Manuscript received June 13, 1995; revised manuscript received September 7, 1995; accepted September 15, 1995.

Address for correspondence: Dr. Paolo M. Fioretti, Thoraxcenter, Ba 300, 3015 GD Rotterdam, The Netherlands.

patients fulfilled the following criteria: the presence of reversible perfusion defects on MIBI SPECT in the vascular territory of one or more stenotic coronary arteries and adequate imaging quality (mean [ $\pm$ SD] age  $59 \pm 11$  years, range 32-80; 38 men, 16 women). Thirty-one patients (57%) were receiving antianginal medications, including beta-adrenergic blocking agents in 28 (52%). Thirty-seven patients (69%) had a previous myocardial infarction.

**Dobutamine stress test.** Dobutamine was infused through an antecubital vein starting at a dose of  $10 \mu\text{g}/\text{kg}$  body weight per min and increasing by  $10 \mu\text{g}/\text{kg}$  per min every 3 min to a maximum of  $40 \mu\text{g}/\text{kg}$  per min. Atropine (up to 1 mg) was given in patients not achieving 85% of their age- and gender-predicted maximal heart rate (18). The electrocardiogram was monitored continuously and recorded each minute. Blood pressure was measured every 3 min. The test was interrupted if severe chest pain, ST segment depression  $>2$  mm, significant tachyarrhythmias or a systolic blood pressure decrease  $>40$  mm Hg occurred during the test.

**Stress echocardiography.** Echocardiographic images were acquired at rest and during the test and recovery. The left ventricular wall was divided into 16 segments (19) and scored using a four-point scale: 1 = normal; 2 = hypokinesia; 3 = akinesia; 4 = dyskinesia (4,5). Both wall motion and thickening were considered for analysis. Wall motion score was obtained by summation of the individual scores of the 16 segments. The diagnosis of ischemia relied on the occurrence of wall motion abnormalities in one or more normal segments or the occurrence of akinesia or dyskinesia in one or more hypokinetic segments at rest. As we previously concluded (20), ischemia was not considered if akinetic segments became dyskinetic without improvement at low dose dobutamine. The echocardiograms were recorded on videotape and digitized on optical disk (Vingmed CFM 800). Images were compared side by side in quad-screen format. Image interpretation was performed by two experienced observers without knowledge of clinical, demographic or scintigraphic data. In case of disagreement, a majority decision was achieved by adding a third investigator. We previously reported an interobserver and intraobserver agreement for dobutamine stress echocardiographic assessment in our laboratory of 91% and 92%, respectively (21).

**SPECT imaging.** Approximately 1 min before the termination of the stress test, an intravenous dose of 370 MBq of MIBI was administered. Stress images were acquired 1 h after termination of dobutamine infusion. For rest studies, 370 MBq of MIBI was injected at least 24 h after the stress study (8). For each study, six oblique (short-axis) slices from the apex to the base and three sagittal (vertical long-axis) slices from the septum to the lateral wall were defined. Each of the six short-axis slices was divided into eight equal segments. The interpretation of the scan was semiquantitatively performed by visual analysis assisted by the circumferential profiles analysis. Stress and rest tomographic views were reviewed in side by side pairs by an experienced observer who was unaware of the patient's clinical or echocardiographic data. A *reversible perfusion defect* was defined as a perfusion defect on stress images

that partially or completely resolved at rest in two or more contiguous segments or slices. This was considered diagnostic of ischemia. A *fixed perfusion defect* was defined as a perfusion defect on stress images in two or more contiguous segments or slices that persisted on rest images. Echocardiographic and scintigraphic images were classified into six major segments: anterior, inferior, septal (subdivided into anterior and posterior), posterolateral and apical. To assess the severity of *hypoperfusion*, each of the six major left ventricular segments was scored on a four-grade scale: 0 = normal, and 3 = severely reduced or absent uptake. The *perfusion score* was derived by adding the scores of the six myocardial segments. The *visual ischemic score* was obtained by subtracting the rest score from the stress score. The *perfusion defect score* was quantitatively calculated by measuring the area between the lower limit of normal values ( $\pm 2$  SD) and the actual circumferential profile in six short-axis slices. The *ischemic score* was derived by subtracting the rest score from the stress score in segments with reversible defects.

**Coronary angiography.** Coronary angiography was performed, using the Judkins technique, within 3 months in all patients. Significant coronary artery disease was defined as a diameter stenosis  $\geq 50\%$  in one or more major epicardial arteries. Coronary arteries were assigned to particular myocardial segments as previously described (4).

**Statistical analysis.** Unless specified, data are presented as mean value  $\pm$  SD. The chi-square test and Fisher exact test were used to compare differences between proportions. The Student *t* test was used for analysis of continuous data;  $p < 0.05$  was considered statistically significant.

## Results

**Dobutamine stress test.** Heart rate increased from  $69 \pm 12$  beats/min at rest to  $131 \pm 18$  beats/min at peak stress ( $p < 0.0001$ ) and systolic blood pressure from  $129 \pm 20$  mm Hg at rest to  $141 \pm 30$  mm Hg at peak stress ( $p < 0.01$ ).

**MIBI SPECT results.** Reversible perfusion defects were detected in all patients (by inclusion criteria). A total of 97 reversible defects were identified. Those were completely reversible in 53 segments (55%, 34 patients) and partially reversible in 44 (45%, 32 patients). In 30 segments, a fixed perfusion defect was detected (21 patients). Among 97 segments with a reversible defect, 8 (8%) were not associated with a significant stenosis of the related artery (7 in inferior wall, 1 in anterior septum). These defects were not included in the calculation of ischemic perfusion defect score.

**Stress echocardiography.** Wall motion abnormalities were detected in 35 patients (65%) at rest. New or worsening wall motion abnormalities were detected in 40 (74%). These patients comprised group A. Group B comprised 14 patients (26%) without stress-induced wall motion abnormalities. Nine patients in group B had baseline wall motion abnormalities that were confined to the infarct region in all of them. Four of these patients showed improvement of contraction in the infarct region, whereas five patients had unchanged wall

**Table 1. Clinical Features and Hemodynamic Data in 54 Patients With Reversible Perfusion Defects on Dobutamine MIBI SPECT With and Without Transient Wall Motion Abnormalities**

	Transient WMA Present (n = 40)	Transient WMA Absent (n = 14)
Age (yr)	61 ± 10	57 ± 12
Female gender	8 (20%)	8 (57%)*
Previous infarction	26 (65%)	11 (79%)
Beta-blocker medication	23 (58%)	5 (36%)
Rest HR (beats/min)	70 ± 13	68 ± 11
Peak HR (beats/min)	134 ± 16	125 ± 18
Rest SBP (mm Hg)	130 ± 18	128 ± 23
Peak SBP (mm Hg)	147 ± 30	127 ± 31†
Rest rate-pressure product	9,160 ± 2,553	8,765 ± 2,535
Peak rate-pressure product	19,632 ± 4,081	16,939 ± 4,344*
85% of target HR achieved	22 (55%)	4 (29%)
Angina during test	21 (53%)	2 (14%)†
ST segment depression	17 (55%)‡	2 (14%)†

\*p < 0.01. †p < 0.05. ‡In patients with interpretable electrocardiographic results. Data presented are mean value ± SD or number (%) of patients. HR = heart rate; SBP = systolic blood pressure; WMA = wall motion abnormalities.

motion during dobutamine infusion. In group A, all patients had transient wall motion abnormalities in the vascular territories of one or more abnormal coronary arteries. A total of 83 ischemic segments were detected, 6 of them (7%) not in the vascular territory of an abnormal artery (3 inferior, 1 lateral, 2 anterior segments). In group B, a negative echocardiographic response was associated with a reversible perfusion defect confined to a dyssynergic segment in four patients (29%). The involved segments were hypokinetic in three patients and akinetic in one. Two of these patients had a lessening of thickening during dobutamine infusion.

**Clinical characteristics and hemodynamic response.** There was no significant difference between groups A and B with respect to age, previous myocardial infarction, risk factors or beta-blocker therapy. In patients with previous myocardial infarction, the infarct location was anterior in 13 (50%) in group A and 3 (27%) in group B. Patients in group B had a higher prevalence of female gender, a lower peak rate-pressure product, a lower peak systolic blood pressure, a lower incidence of angina and ST segment depression during the test (Table 1) and a trend to a lower peak dobutamine dose ( $37.9 \pm 5.8$  vs.  $39.8 \pm 1.6$   $\mu\text{g}/\text{kg}$  per min,  $p = 0.06$ ) than group A. Systolic blood pressure increased significantly from rest to peak stress in group A ( $p < 0.01$ ) but not in group B. Atropine was given to 20 patients in group A (59%) and 6 in group B (43%). A decrease or failure of increase of systolic blood pressure from rest to peak stress occurred in 12 patients (30%) in group A and 9 (64%) in group B ( $p < 0.05$ ). The test was interrupted in nine patients (23%) in group A (angina in six, ST segment depression in three) and in three (21%) (all with angina) in group B ( $p = \text{NS}$ ). Twenty-two patients in group A (55%) and four in group B (29%) achieved 85% of the maximal exercise heart rate predicted for age and gender ( $p = 0.09$ ).

**Table 2. Echocardiographic and Angiographic Data for 54 Patients With Reversible Perfusion Defects on Dobutamine MIBI SPECT With and Without Transient Wall Motion Abnormalities**

	Transient WMA Present (n = 40)	Transient WMA Absent (n = 14)
Rest WMA	26 (65%)	9 (64%)
Rest wall motion score	22 ± 6	20 ± 4
Stress wall motion score	26 ± 7	20 ± 4*
Multivessel disease	22 (55%)	5 (37%)
No. of stenotic arteries	1.8 ± 0.8	1.6 ± 0.9
LAD disease	27 (68%)	10 (71%)
LCx disease	18 (45%)	5 (36%)
RCA disease	25 (63%)	7 (50%)

\*p < 0.01. Data presented are mean value ± SD or number (%) of patients. LAD = left anterior descending coronary artery; LCx = left circumflex coronary artery; RCA = right coronary artery; WMA = wall motion abnormalities.

**Echocardiographic, angiographic and scintigraphic data.**

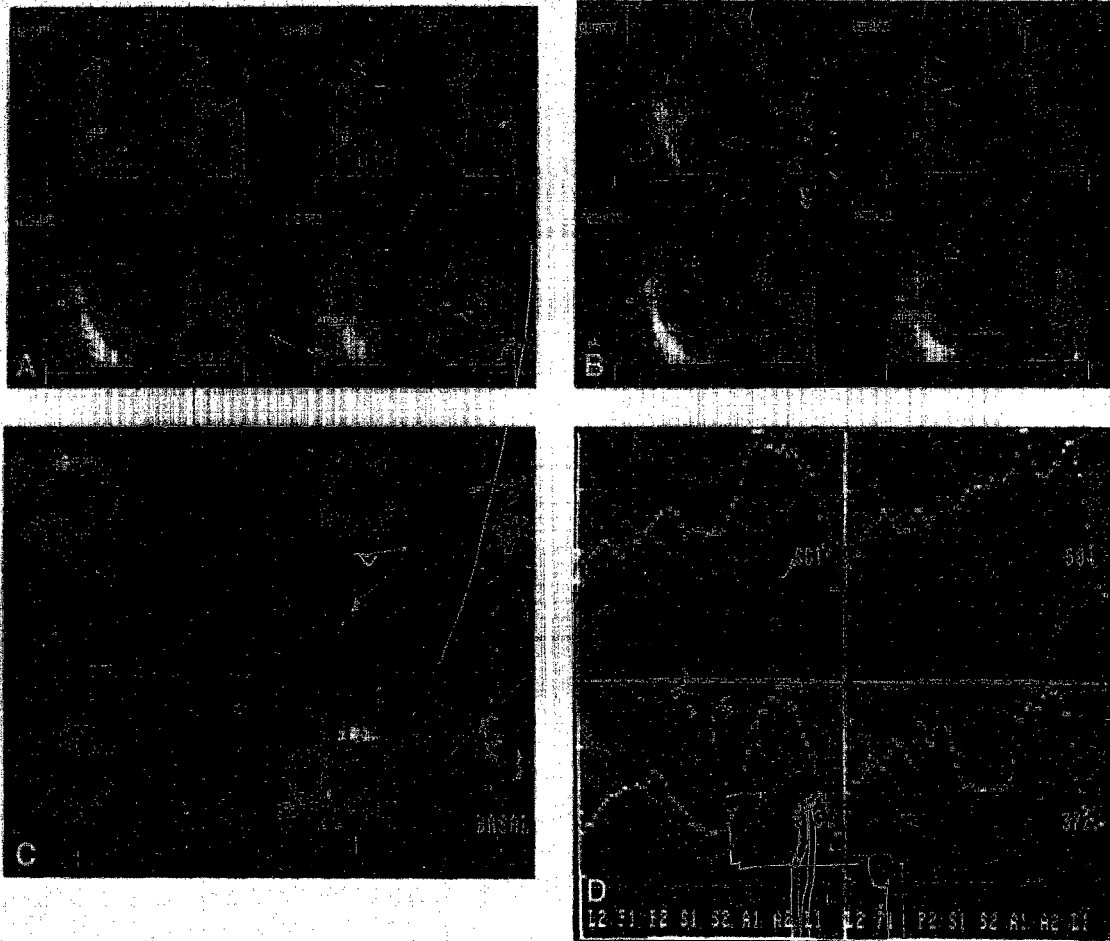
There was no significant difference between groups with respect to prevalence of multivessel disease, number and distribution of abnormal coronary arteries or rest wall motion score. Peak wall motion score was higher in group A. The number of reversible perfusion defects as well as stress, rest and ischemic perfusion scores was not different between groups (Table 2). The distribution of reversible defects in the six segments was similar (Table 3), except for a higher prevalence of anterior defects in group B ( $p < 0.01$ ). Inclusion in group A of the five patients of group B who had unchanged wall motion during dobutamine infusion did not change the comparable variables of reversible hypoperfusion in the two groups.

All patients with left bundle branch block ( $n = 6$ ) and left ventricular hypertrophy ( $n = 3$ ) had transient wall motion abnormalities. Scintigraphic and echocardiographic images of a patient in group A are shown in Figure 1.

**Table 3. Distribution of Reversible Perfusion Defects and Perfusion Defect Score in 54 Patients With and Without Transient Wall Motion Abnormalities**

	Transient WMA Present (n = 40)	Transient WMA Absent (n = 14)
Anterior	10 (25%)	9 (64%)
Inferior	18 (45%)	6 (36%)
Posterolateral	8 (20%)	1 (7%)
Anterior septum	8 (20%)	4 (29%)
Posterior septum	9 (23%)	3 (21%)
Apex	11 (28%)	3 (21%)
No. of reversible defects	1.6 ± 0.9	1.8 ± 0.7
Rest perfusion defect score	1,032 ± 1,286	600 ± 559
Stress perfusion defect score	1,362 ± 1,642	1,135 ± 988
Quantitative ischemic score	412 ± 750	526 ± 553
Visual ischemic score	3.5 ± 2	3.8 ± 1.2

\*p < 0.01. Data presented are mean value ± SD or number (%) of patients. WMA = wall motion abnormalities.



**Figure 1.** Diastolic (A) and systolic (B) echocardiographic frames from the apical long-axis view in a 56-year old man with left circumflex coronary artery disease, an old inferior myocardial infarction and exertional chest pain. At baseline, low dose dobutamine ( $10 \mu\text{g}/\text{kg}$  per min), high dose dobutamine ( $40 \mu\text{g}/\text{kg}$  per min) and atropine show hypokinesia of the posterior wall at rest deteriorating to akinesia at high dose and atropine images (arrows). Simultaneous perfusion scintigraphic image in the basal short-axis slice (C) and the corresponding circumferential profile (D) in the same patient show a defect in the posterolateral wall (arrows) at stress image (right) that was reversible at rest image (left). A = anterior; BPM = beats per minute; ECG = electrocardiogram; L = lateral; P = posterior; S = septal; 1 to 2 = clockwise division of segments in short-axis slices.

**Variables associated with female gender.** A negative response on the stress echocardiogram was obtained in 8 (50%) of 16 women and 6 (16%) of 38 men ( $p < 0.01$ ). The following variables were not different between women and men: age ( $62 \pm 13$  vs.  $58 \pm 9$  years), rest wall motion score ( $19.7 \pm 4.5$  vs.  $22.7 \pm 5.9$ ), peak systolic blood pressure ( $140 \pm 28$  vs.  $142 \pm 32$  mm Hg), rate-pressure product ( $17,403 \pm 4,385$  vs.  $19,210 \pm 4,384$ ,  $p = 0.2$ ), number of abnormal coronary

arteries ( $1.5 \pm 0.9$  vs.  $1.8 \pm 0.8$ ,  $p = 0.2$ ) and number of reversible defects ( $1.8 \pm 0.8$  vs.  $1.6 \pm 0.9$ ). Male gender was associated with a higher peak heart rate ( $135 \pm 15$  vs.  $124 \pm 16$  beats/min,  $p < 0.05$ ), peak wall motion score ( $25.6 \pm 7$  vs.  $21.2 \pm 0.5$ ,  $p < 0.05$ ), and prevalence of multivessel disease (61% vs. 25%,  $p < 0.05$ ); a trend to a higher prevalence of previous infarction (76% vs. 50%,  $p = 0.06$ ); and a higher stress perfusion score ( $1,609 \pm 1,590$  vs.  $598 \pm 937$ ,  $p < 0.05$ ), rest score ( $1,132 \pm 1,212$  vs.  $416 \pm 832$ ,  $p < 0.05$ ) and ischemic score ( $554 \pm 795$  vs.  $181 \pm 172$ ,  $p < 0.05$ ) than was female gender.

**Beta-blocker therapy.** There was no significant difference between patients with and those without beta-blocker therapy with regard to age, gender, extent of coronary artery disease, prevalence of ischemia on echocardiography or quantitative perfusion defect score. Patients taking beta-blockers had a lower peak heart rate ( $126 \pm 17$  vs.  $139 \pm 15$  beats/min,  $p < 0.01$ ), a lower peak rate-pressure product ( $17,869 \pm 4,250$  vs.  $20,116 \pm 3,706$ ,  $p < 0.05$ ) and a higher maximal dobutamine

dose ( $40 \pm 0$  vs.  $37 \pm 6 \mu\text{g/kg}$  per min,  $p < 0.05$ ) than those not taking beta-blockers. Among patients receiving beta-blockers, peak heart rate was higher in group A than in group B ( $130 \pm 18$  vs.  $108 \pm 16$  beats/min,  $p < 0.05$ ).

## Discussion

Identification of stress test variables associated with more severe ischemia is important in the management and prognostic stratification of patients with coronary artery disease, especially in the presence of equivocal indications for revascularization (22). The echocardiographic method of evaluation of wall motion during a stress test used in clinical practice depends on a semiquantitative visual evaluation with a limited scoring scale of different grades of dyssynergy (4-12). Conversely, the detection of a reversible perfusion defect with the relatively automated myocardial SPECT imaging is assisted by quantitative analysis of perfusion defect size. Theoretically, this can explain the lack of stress-induced wall motion abnormalities in patients with reversible hypoperfusion on the basis of less severe flow malperfusion and presumably less severe ischemia (14). Therefore, it is important to determine whether the absence of inducible wall motion abnormalities identifies a population with different clinical characteristics and extent and severity of ischemia, different hemodynamic response to dobutamine or extent of coronary artery disease.

The results of our study are derived from a symptomatic patient cohort with coronary artery disease and reversible defects on dobutamine perfusion scintigraphy. The data show that the presence or absence of transient wall motion abnormalities in conjunction with a reversible perfusion defect is not related to the severity of ischemia assessed by quantitative MIBI SPECT imaging. The absence of transient wall motion abnormalities correlated with a lower peak rate-pressure product, impaired systolic blood pressure response at peak stress and higher prevalence of female gender. The lower rate-pressure product in the group with a negative response on echocardiography can be explained by the occurrence of hypoperfusion earlier than wall motion abnormalities in the ischemic cascade (15,16). Consequently, diagnostic techniques dependent on the detection of wall motion abnormalities may be more vulnerable to a submaximal stress than with perfusion imaging techniques (12). The association between transient wall motion abnormalities and a higher prevalence of ST segment depression or angina, or both, during stress may be explained by the late occurrence of angina and ST segment depression after impairment of perfusion and function in the ischemic cascade (15,16,23). Because the latter stops before the occurrence of mechanical dysfunction in patients without transient wall motion abnormalities, these patients were more likely to have less angina and ST segment depression. There was a higher prevalence of reversible perfusion defects in the anterior wall in patients with than without transient wall motion abnormalities, which may result from the difficulties in delineation of the entire endocardium of the anterior wall in the apical two-chamber view. The apparent trend to a higher

rest wall motion and perfusion defect score in patients with transient wall motion abnormalities may be related to the relatively higher prevalence of anterior myocardial infarction in the former group. All patients with left bundle branch block or left ventricular hypertrophy had a positive echocardiographic study response. This is not surprising, because diagnostic problems in this cohort were described with scintigraphy (24,25) and not with echocardiography, which was reported to be more accurate in patients with than without left ventricular hypertrophy (11).

**Comparison with previous studies.** To our knowledge, this is the first study to evaluate severity of myocardial ischemia in patients with reversible perfusion defects in the presence or absence of simultaneous transient wall motion abnormalities during stress testing. Coma-Canella et al. (17) studied patients after recent myocardial infarction by dobutamine stress with radionuclide angiography and thallium-201 SPECT on two separate days. They concluded that mild to moderate ischemia on the basis of visual analysis of reversible thallium defects is compatible with improvement or no change of regional function, whereas severe ischemia results in worsening of function. Unlike radionuclide angiography, echocardiography allows tomographic evaluation of both endocardial excursion and wall thickening, improving the detection of mechanical dysfunction. The difference between the two studies may be explained by the tomographic assessment of wall motion and quantitative assessment of perfusion in our study.

**Accuracy of dobutamine stress testing in women.** Despite the finding that exercise perfusion scintigraphy is more accurate than electrocardiography in women (26), there are some inherent diagnostic problems of perfusion scintigraphy in women, including false positive test results caused by a shifting breast artifact. In our study, women had a higher incidence of negative responses on echocardiography, a lower peak heart rate, a lower peak wall motion score and a lower ischemic perfusion defect score. It cannot be precisely concluded whether these findings are related to the lower prevalence of multivessel disease, a lower peak heart rate or a difference in inducibility or detection of wall motion abnormalities in women. It has been reported (27) that exercise echocardiography is an accurate method for the diagnosis of coronary artery disease in women. Because the predicted maximal exercise heart rate is higher in men than women at a given age (28), a similar calculation of maximal heart rate during dobutamine stress testing may not be appropriate for women undergoing dobutamine stress echocardiography, where the detection of ischemia may be critically dependent on heart rate increment.

**Accuracy of dobutamine stress testing at various levels of stress.** Previous studies have shown that a submaximal dobutamine stress test response, defined as a test in patients receiving beta-blockers or unable to complete the standard protocol, is associated with reduced sensitivity of echocardiography, whereas the effect on sensitivity of perfusion scintigraphy is less prominent (11,12). Because the dobutamine stress test is an exercise-simulating stress modality, a significant

increase in rate-pressure product is required to yield a high accuracy, especially for the detection of abnormal wall motion. We previously showed (29) that in an unselected patient cohort with suspected myocardial ischemia who underwent dobutamine stress echocardiography with simultaneous MIBI SPECT, the addition of MIBI study results to echocardiographic study results that are negative for ischemia at submaximal testing was particularly useful for the prediction of cardiac events.

**Effect of beta-blockers.** In our study, the prevalence of ischemia detected at echocardiography was not different with or without beta-blocker therapy. This may be a result of the administration of atropine, which was reported to increase sensitivity, particularly in patients receiving beta-blockers (30), and of the higher dobutamine dose in patients receiving beta-blockers, which may compensate for the lower rate-pressure product by exerting a greater positive inotropic effect. Additionally, in patients receiving beta-blockers, peak heart rate was higher in patients with than without ischemia on echocardiography.

**Role of systolic blood pressure response.** High dose dobutamine infusion induces myocardial ischemia by increasing metabolic demand through an increase in heart rate and myocardial contractility (31-33). Coronary vasodilation and flow heterogeneity result from the increased myocardial demand and a weak vasodilator effect (33). The effect of dobutamine on systolic blood pressure is influenced by mechanisms related to contractility and systemic vascular resistance (34). Therefore, the importance of a systolic blood pressure response in the attainment of an adequate stress test level has not been proved. An interesting finding of our study is that patients with negative echocardiographic responses had an impaired systolic blood pressure response in contrast to those with positive responses. This difference is unlikely to be related to myocardial ischemia because in this situation, an impaired systolic blood pressure response is expected to occur in the group with rather than without mechanical dysfunction. Conversely, an impaired systolic blood pressure response is most likely the reason for a negative echocardiographic response and can be explained by a possible predominant peripheral vasodilator response in these particular patients. The role of a systolic blood pressure response is supported by the reported findings of a significant increase in systolic blood pressure with dobutamine, even comparable to that obtained with exercise in some studies (7,35). Echocardiography was reported to have good sensitivity, comparable to that of perfusion scintigraphy, when used with stress modalities associated with heart rate and systolic blood pressure increases, such as exercise (1,2) and dobutamine (8,9), whereas sensitivity is low compared with that for perfusion scintigraphy when applied with vasodilator stress testing with dipyridamole (36), in which there is a mild increase in heart rate during which systolic blood pressure either decreases or does not change. For echocardiographic imaging, the sensitivity of dobutamine and exercise was found to be higher than that of dipyridamole (37). It can be postulated that in particular patients, a modest but critical increment

in systolic blood pressure during dobutamine infusion is required to increase the left ventricular wall stress and result in subendocardial ischemia and deterioration of function that can be detected by visual assessment. This may not be as critical for reversible hypoperfusion that occurs at a lower stress level.

**Limitations of the study.** The number of patients with negative echocardiographic responses was small. The patient cohort was heterogeneous and included some patients with a previous myocardial infarction. However, only one patient had a negative echocardiographic study response and a reversible perfusion defect confined to an akinetic segment. Assessment of the severity of ischemia by perfusion scintigraphy may have some pitfalls because the latter detects flow malperfusion as well as true ischemia. Difference in perfusion may be attenuated in patients with multivessel disease (17). Finally, some patients were receiving medications, including beta-blockers. Nevertheless, we previously showed (30) that the addition of atropine increases the sensitivity of dobutamine echocardiography, especially in patients receiving beta-blockers.

**Clinical implications.** Because a lower peak rate-pressure product correlated with a negative dobutamine echocardiographic test response in patients with reversible perfusion defects, great attention should be given to achieving a higher product in patients undergoing dobutamine stress echocardiography alone. This may include stopping beta-blockers and implementing a stress protocol aimed at the attainment of a higher heart rate, including atropine administration (18,30) or the use of a longer dobutamine infusion time (38). The occurrence of mechanically silent ischemia manifested as reversible perfusion defects without transient wall motion abnormalities should be disregarded in the management of patients with coronary artery disease as a marker of less severe ischemia as assessed by myocardial perfusion scintigraphy.

We are grateful to René Frowyn, MSc and Joyce Postma-Tjona, MSc for their invaluable technical assistance.

## References

- Salustri A, Pozzoli MM, Hermans W, et al. Relationship between exercise echocardiography and perfusion single photon emission computed tomography in patients with single vessel coronary artery disease. *Am Heart J* 1992;124:75-83.
- Quinones MA, Verani MS, Haichin RM, Mahmarian JJ, Suarez J, Zoghbi WA. Exercise echocardiography versus Tl-201 single photon emission computed tomography in evaluation of coronary artery disease. Analysis of 292 patients. *Circulation* 1992;85:1026-31.
- Mahmarian JJ, Pratt CM, Cocaonugher MK, Verani MS. Altered myocardial perfusion in patients with angina pectoris or silent ischemia during exercise as assessed by quantitative thallium-201 single photon emission computed tomography. *Circulation* 1990;82:1305-15.
- Sawada SG, Segar DS, Ryan T, et al. Echocardiographic detection of coronary artery disease during dobutamine infusion. *Circulation* 1991;83:1605-11.
- Salustri A, Fioretti PM, Pozzoli MMA, McNeill AJ, Roelandt JRTC. Dobutamine stress echocardiography: its role in the diagnosis of coronary artery disease. *Eur Heart J* 1992;13:70-7.
- Segar DS, Brown SE, Sawada SG, Rayan T, Feigenbaum H. Dobutamine stress echocardiography: correlation with coronary lesion severity as determined by quantitative angiography. *J Am Coll Cardiol* 1992;19:1197-202.

7. Berthe C, Pierard LA, Hiernaux M, et al. Predicting the extent and location of coronary artery disease in acute myocardial infarction by echocardiography during dobutamine infusion. *Am J Cardiol* 1986;58:1167-72.
8. Forster T, McNeill AJ, Salustri A, et al. Simultaneous dobutamine stress echocardiography and technetium-99m isonitrite single-photon emission computed tomography in patients with suspected coronary artery disease. *J Am Coll Cardiol* 1993;21:1591-6.
9. Marwick T, Willemart B, D'Hondt AM. Selection of the optimal nonexercise stress for the evaluation of ischemic regional myocardial dysfunction and malperfusion: comparison of dobutamine and adenosine using echocardiography and Tc-99m MIBI single photon emission computed tomography. *Circulation* 1993;87:345-54.
10. Mairesse GH, Marwick TH, Vanoverschelde J-LJ, et al. How accurate is dobutamine stress electrocardiography for detection of coronary artery disease? Comparison with two-dimensional echocardiography and technetium-99m methoxy isobutyl isonitrite (MIBI) perfusion scintigraphy. *J Am Coll Cardiol* 1994;24:920-7.
11. Marwick TH, D'Hondt AM, Baudhuin T, et al. Optimal use of dobutamine stress for the detection and evaluation of coronary artery disease: combination with echocardiography, scintigraphy or both? *J Am Coll Cardiol* 1993;22:159-67.
12. Marwick TH, D'Hondt AM, Mairesse GH, et al. Comparative ability of dobutamine and exercise stress in inducing myocardial ischemia in active patients. *Br Heart J* 1994;72:31-8.
13. Hays JT, Mahmarian JJ, Cochran AJ, Verani MS. Dobutamine thallium-201 tomography for evaluating patients with suspected coronary artery disease unable to undergo exercise or vasodilator pharmacologic stress testing. *J Am Coll Cardiol* 1993;21:1583-90.
14. Marwick TH. *Stress Echocardiography: Its Role in the Diagnosis and Evaluation of Coronary Artery Disease*. Dordrecht, The Netherlands: Kluwer, 1994:167-9.
15. Nesto RW, Kowalchuck GJ. The ischemic cascade: temporal response of hemodynamic, electrocardiographic and symptomatic expression of ischemia. *Am J Cardiol* 1987;57:23C-7C.
16. Hauser AM, Vellappillil G, Ramos RG, et al. Sequence of mechanical, electrocardiographic and clinical effects of repeated coronary artery occlusion in human beings: echocardiographic observations during coronary angioplasty. *J Am Coll Cardiol* 1985;5:193-7.
17. Coma-Canella I, Gomes Martinez MV, Rodrigo F, Castro Beiras JM. The dobutamine stress test with thallium-201 single-photon emission computed tomography and radionuclide angiography: postinfarction study. *J Am Coll Cardiol* 1993;22:399-406.
18. McNeill AJ, Fioretti PM, El-Said EM, Salustri A, Forster T, Roelandt JRTC. Enhanced sensitivity for detection of coronary artery disease by addition of atropine to dobutamine stress echocardiography. *Am J Cardiol* 1992;70:41-6.
19. Schiller NB, Shah PM, Crawford M. Recommendations for quantitation of the left ventricle by two-dimensional echocardiography. *J Am Soc Echocardiogr* 1989;2:358-67.
20. Arnese M, Fioretti PM, Cornel JH, Postma-Tjoa J, Reijs AEM, Roelandt JRTC. Akinesis becoming dyskinesis during high-dose dobutamine stress echocardiography: a marker of myocardial ischemia or a mechanical phenomenon? *Am J Cardiol* 1994;73:896-8.
21. Bellotti P, Fioretti PM, Forster T, et al. Reproducibility of the dobutamine-atropine echocardiography stress test. *Echocardiography* 1993;10:93-7.
22. Machecourt J, Longere P, Fagret D, Vanzetto G, Wolf JE, Polidori C. Prognostic value of thallium-201 single-photon emission computed tomographic myocardial perfusion imaging according to extent of myocardial defect. Study in 1,926 patients with follow-up at 33 months. *J Am Coll Cardiol* 1994;23:1096-106.
23. Elhendy A, Geleijnse ML, Roelandt JRTC, Cornel JH, Domburg RT, Fioretti PM. Stress-induced left ventricular dysfunction in silent and symptomatic myocardial ischemia during dobutamine stress test. *Am J Cardiol* 1995;75:1112-5.
24. DePuey EG, Guertler-Krauczynska E, Robbins WL. Thallium 201 SPECT in coronary disease patients with left bundle branch block. *J Nucl Med* 1988;29:1479-85.
25. DePuey EG, Guertler-Krauczynska E, Perkins JV, Robbins WL, Whelchel JD, Clements SD. Alteration in myocardial thallium 201 distribution in patients with chronic systemic hypertension undergoing single photon emission computed tomography. *Am J Cardiol* 1988;62:234-8.
26. Melin JA, Wijns W, Vanbutsele RJ, et al. Alternative diagnostic strategies for coronary artery disease in woman: demonstration of the usefulness and efficiency of probability analysis. *Circulation* 1985;71:535-42.
27. Marwick TH, Anderson T, Williams J, et al. Exercise echocardiography is an accurate and cost-efficient technique for detection of coronary artery disease in women. *J Am Coll Cardiol* 1995;26:335-41.
28. Sheffield LT, Maloof JA, Sawyer JA, Roitman D. Maximal heart rate and treadmill performance of healthy woman in relation to age. *Circulation* 1978;57:79-84.
29. Geleijnse ML, Elhendy A, Domburg RT, et al. Optimal use of dobutamine stress test for risk stratification in patients with suspected myocardial ischemia: echocardiography, scintigraphy or both? [abstract] *Circulation* 1994;90 Suppl(Pt 2):1-454.
30. Fioretti PM, Poldermans D, Salustri A, et al. Atropine increases the accuracy of dobutamine stress echocardiography in patients taking beta-blockers. *Eur Heart J* 1994;15:355-60.
31. Ruffolo RR. The pharmacology of dobutamine. *Am J Med Sci* 1987;294:244-8.
32. Wartier DC, Zywloski M, Gross GJ, Hardman HF, Brooks HL. Redistribution of myocardial blood flow distal to a dynamic coronary arterial stenosis by sympathomimetic amines: comparison of dopamine, dobutamine and isoproterenol. *Am J Cardiol* 1981;48:269-79.
33. McGillem MJ, DeBoe SF, Friedman HZ, Mancini GBJ. The effects of dopamine and dobutamine on regional function in the presence of rigid coronary stenosis and subcritical impairments of reactive hyperemia. *Am Heart J* 1988;115:970-7.
34. Mazeika PK, Nadazin A, Oakley CM. Clinical significance of abrupt vasodepression during dobutamine stress echocardiography. *Am J Cardiol* 1992;69:1484-7.
35. Mazeika PK, Nadazin A, Oakley CM. Dobutamine stress echocardiography for detection and assessment of coronary artery disease. *J Am Coll Cardiol* 1992;19:1203-11.
36. Perin EC, Moore W, Blume M, Hernandez G, Dhekne R, DeCastro M. Comparison of dipyridamole echocardiography with dipyridamole thallium scintigraphy for the diagnosis of myocardial ischemia. *Clin Nucl Med* 1991;16:417-20.
37. Dagianti A, Penco M, Agati L, et al. Stress echocardiography: comparison of exercise, dipyridamole and dobutamine in detecting and predicting the extent of coronary artery disease. *J Am Coll Cardiol* 1995;62:18-25.
38. Weissman NJ, Nidorf SM, Guerrero JL, Weyman AE, Picard M. Optimal stage duration in dobutamine stress echocardiography. *J Am Coll Cardiol* 1995;25:605-9.