

# Chronic rejection of concordant aortic xenografts in the hamster-to-rat model

Marcel Scheringa<sup>a</sup>, Bas Buchner<sup>b</sup>, Ron WF de Bruin<sup>b</sup>, Rob A Geerling<sup>b</sup>, Marie-José Melief<sup>c</sup>, Andries H Mulder<sup>d</sup>, Edo O Schraa<sup>b</sup>, Jan NM Ijzermans<sup>b</sup> and Richard L Marquet<sup>b</sup>

<sup>a</sup>Department of Surgery, Leiden University Hospital, Leiden, <sup>b</sup>Laboratory for Experimental Surgery, <sup>c</sup>Department of Immunology and <sup>d</sup>Department of Pathology of the Erasmus University Rotterdam, Rotterdam

Received 30 November 1995; revised manuscript accepted 19 January 1996

**Abstract:** Several groups have demonstrated that it is possible to obtain long-term graft survival of concordant xenografts. One of the important questions that remains is whether xenografts are susceptible to chronic rejection. To answer this question we used the aorta transplantation model. One centimetre of hamster aorta was interposed in the abdominal aorta of Lewis rat recipients. The recipients were either untreated (group 1), or treated with 10 mg/kg cyclosporine (CsA), given intramuscularly three times a week (group 2). Rats were sacrificed at day 7, 14, 21, 28, 56 and 84 and the thickness of the intima, the media and the adventitia was measured. Furthermore, the cellularity of the media and the adventitia was assessed by counting the number of nuclei per 0.05 mm<sup>2</sup> and immunohistochemistry of the aortic grafts was performed. Graft arteriosclerosis developed in aortic xenografts of both group 1 and group 2. In group 1, intimal lesions were already present from day 21 onwards in all rats, whereas in group 2 they were present only in 33% (2/6) of the rats. At day 84 all the grafts in group 1 were totally occluded, while those in group 2 were still open. The thickness of the media was slightly increased in both groups during the whole observation period, mainly due to edema. Although a few infiltrating macrophages could be seen, the number of nuclei per 0.05 mm<sup>2</sup> of the media remained constant during the first 21 days, but declined sharply from day 21 onwards, as a consequence of disappearing myocytes. Thickness of the adventitia in both groups increased after transplantation due to infiltrating macrophages and T cells, reaching a peak at day 14. After day 14 the adventitial thickness in group 1 decreased rapidly to reach values comparable to group 2 from day 28 onwards.

In conclusion, graft arteriosclerosis, as a sign of chronic rejection, occurs in concordant aortic xenografts. The lesions in the xenografts develop extremely rapidly, and, compared to data from the literature, faster than in aortic allografts. The process of chronic rejection in aortic xenografts can be reduced by CsA.

## Introduction

In the past 10 years rapid progress has been made in understanding and controlling the rejection of concordant xenogeneic grafts. In 1987, Knechtle *et al.*<sup>1</sup> were the first to achieve survival of more than 100 days in the concordant hamster-to-rat heart transplantation model. Therapy consisted of total lymphoid irradiation combined with cyclosporine (CsA). Their

findings have been confirmed by other groups using various therapeutic protocols.<sup>2–4</sup> Later it was demonstrated in the cynomolgus monkey-to-baboon heart transplantation model that survival of more than 1 year could be achieved.<sup>5</sup> Due to these promising results, clinical xenotransplantation has been performed on a small scale.<sup>6</sup>

The question now arises whether xenografts will be susceptible to chronic rejection. Chronic rejection is becoming a major obstacle of long-term allograft survival. Although it has many histological and clinical appearances, depending on the type of graft, most investigators agree that the prime manifestation common to all is transplant arteriosclerosis associated

Address for correspondence: M Scheringa, Department of Surgery, Leiden University Hospital, Building 1, Room P1-Q, PO Box 9600, 2300 RC Leiden, The Netherlands.

with (and most likely due to) an ongoing immune response and inflammation in the graft.<sup>7,8</sup> Because the problem of chronic rejection has been perceived as secondary in importance to the control of powerful xenogeneic immune responses, it has received little experimental attention. Reemtsma *et al.* reported graft arteriosclerosis in renal arterioles in their 9-month surviving patient with a chimpanzee kidney.<sup>9</sup> They also found such lesions in heterotopically transplanted xenogeneic heart grafts in the cynomolgus monkey-to-baboon model. In this model intimal proliferation could already be demonstrated 6 days after transplantation, and was prominent 70–80 days after transplantation. Bailey *et al.* demonstrated signs of chronic rejection in lamb hearts transplanted orthotopically in newborn goats.<sup>10</sup> In all except one host they found histological abnormalities in the grafts, ranging from moderate chronic rejection to severe subacute and chronic rejection 24–165 days after transplantation.

Apart from these two reports, we know little about the susceptibility of xenogeneic grafts to chronic rejection. In an effort to extend our understanding of vascular lesions in (concordant) xenografts, we have adapted the aorta transplantation model, which is widely used to examine chronic rejection of allografts,<sup>11–13</sup> to study chronic rejection of xenografts. In this article we describe the development of graft arteriosclerosis in hamster aortas transplanted into non-immunosuppressed and CsA-treated rats.

## Materials and methods

### Experimental design

Recipient rats were divided into two groups after receiving an aortic xenograft. Rats in group 1 received no treatment (control group), whereas rats in group 2 received CsA three times a week, intramuscularly, in a dose of 10 mg/kg bodyweight. At day 7, 14, 21, 28, 56 and 84, four to eight rats from each group were sacrificed and the grafts were removed for histology or immunohistochemistry.

### Animals

Male Syrian hamsters (outbred) were used as donors and male Lewis rats (RT1<sup>1</sup>) as recipients of aortic grafts. All animals were obtained from Harlan CPB (Austerlitz, The Netherlands). Hamsters weighed between 75 and 115 g and rats between 250 and 350 g when used. The experimental protocols adhered to the rules laid down in the Dutch Animal Experimentation Act (1977) and the published Guidelines on the Protection of Experimental Animals by the Council of the EC (1986). The specific protocol was approved by the Committee on Animal Research of the Erasmus University Rotterdam, The Netherlands.

### Aorta transplantation

Aorta transplantation was performed as described by Menander *et al.*<sup>11</sup> Briefly, a segment of descending thoracic aorta of approximately 1 cm was removed from the hamster donor after animals were anticoagulated with 50 IU intravenous heparin (Organon Teknika, Boxtel, The Netherlands). The aorta segments were flushed with phosphate-buffered saline (PBS, 0.01 M, pH 7.4), placed in chilled PBS and later used as a transplant. Recipient rats were anaesthetized with ether whereafter a laparotomy was performed. The graft was transplanted into a heterotopic position below the renal arteries and above

the bifurcation. End-to-end anastomoses were performed with 9-0 monofilament nylon sutures (B. Braun-SSC, Neuhausen am Rheinfl, Switzerland). Total ischaemic time ranged from 30 to 45 min, 10–15 min of which was cold ischaemia. The grafts were removed at 7, 14, 21, 28, 56 and 84 days after transplantation and were processed for histology or for frozen-section immunohistochemistry.

### Histology

For evaluation of morphological changes, paraffin sections were stained with haematoxylin–eosin or elastin. Straight cross-sections of 5 µm were prepared from the centre of the graft to avoid the effects of the suture line. Slides were then examined by light microscopy for the following variables: the thickness of the different layers of the aorta (i.e. the adventitia, media, and intima, separated from each other by the external and internal elastic laminae, respectively) and the number of nuclei per 0.05 mm<sup>2</sup> of the media and adventitia. Thickness was measured with a calibrated ocular micrometer and was calculated by dividing the sum of the largest and smallest thickness by two. Furthermore, the grafts were scored blindly by a pathologist for various parameters such as normality of endothelial cells and presence of oedema.

### Immunohistochemistry

For immunohistochemistry, 5 µm thick frozen cross-sections were stained by the immunoperoxidase technique with the following monoclonal antibodies: ER-1 to CD5 (all T cells, concentration 1:4000); ER-2 to CD4 (T helper lymphocytes, macrophages and monocytes weakly, concentration 1:4000); OX8 to CD8 (T cytotoxic and suppressor lymphocytes, NK (natural killer) cells, concentration 1:8000); OX6 to Ia antigen (non-polymorphic, concentration 1:8000); ED-1 to monocytes, macrophages and dendritic cells, concentration 1:40) and HIS-14 to B lymphocytes (concentration 1:500). Staining without primary antibody (PBS) served as negative control. Furthermore, paraffin sections of 5 µm were stained with an anti-α-actin monoclonal antibody (Biogenex, Duiven, The Netherlands, concentration 1:100) that demonstrates smooth muscle cells. The thawed sections were fixed with acetone (Merck, Darmstadt, Germany). Directly after fixation for 10 min, the sections were washed for 10 min in PBS. Endogenous peroxidase was inhibited by incubation with 0.5% H<sub>2</sub>O<sub>2</sub> for 10 min. The sections were then washed for 10 min in PBS containing 0.2% bovine serum albumin (PBS/BSA). The mouse anti-rat monoclonal antibodies diluted in PBS/BSA were incubated for 1 h at room temperature. As second step antibody, peroxidase-conjugated rabbit immunoglobulin to mouse immunoglobulins (P161; Dakopatts, Denmark) was used in a 1:200 dilution in PBS/BSA with 1% normal rat serum to minimize background staining. After 45 min of incubation at room temperature, the substrate was added for 5 min at room temperature. As substrate, 3,3'-diaminobenzidine tetrahydrochloride (Sigma, St Louis, USA) 0.05% (w/v) dissolved in 0.1 M acetate buffer (pH 6.0) with imidazole (0.07% (w/v); Merck), NiSO<sub>4</sub>·6H<sub>2</sub>O and 0.01% H<sub>2</sub>O<sub>2</sub>, as described by Green *et al.*,<sup>14</sup> was used. Positive cells are stained black. Sections were evaluated and results were expressed as 0 (no positive cells) to 3 (maximum number of positive cells).

### Cyclosporine

CsA (Sandimmune; Sandoz, Basel, Switzerland) was dissolved in olive oil (OPG-Pharma, Utrecht, The Netherlands) to a con-

centration of 50 mg/ml and administered intramuscularly in a volume of 0.05–0.07 ml.

### Haemagglutination test

Sera of experimental animals were serially diluted with Haemacel (Behringwerke, Marburg, Germany) in a 96-well plate (Costar, Cambridge, UK) to an end volume of 50  $\mu$ l. Thereafter, 50  $\mu$ l of a 2% hamster erythrocyte suspension was added and the plates were incubated for 60 min at 37°C. The highest dilution at which agglutination could be observed was taken as antibody titre.

### Statistics

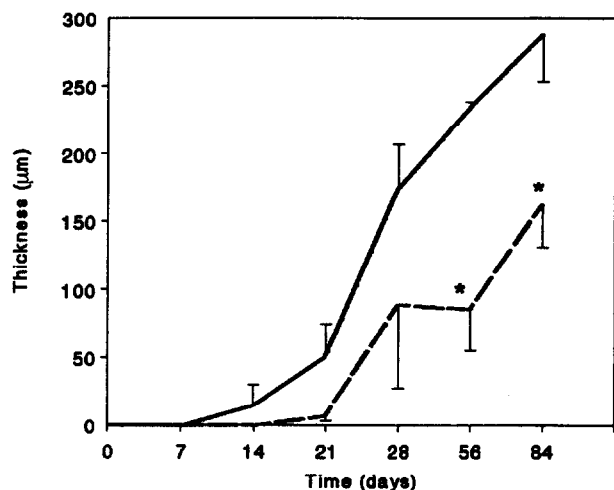
Data of thickness and the number of nuclei per 0.05 mm<sup>2</sup> are expressed as mean  $\pm$  SEM. Statistical comparisons between the control group and the CsA-treated group were performed using the Mann–Whitney *U*-test. For all data  $P < 0.05$  was considered significant.

## Results

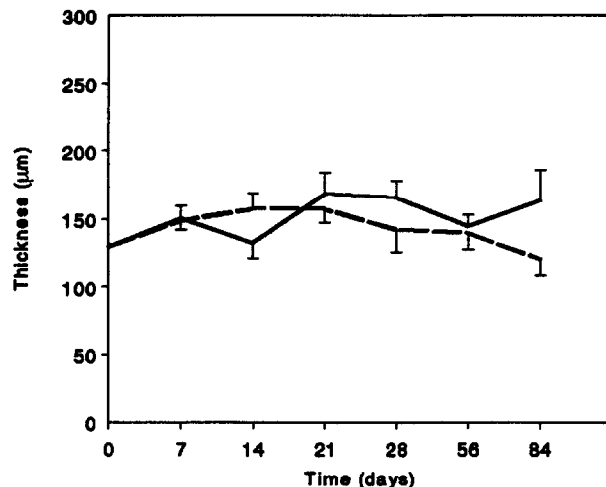
For evaluating the progress of vascular alterations in the two treatment groups, 70 transplants were performed successfully. The number of rats in group 1 on days 7, 14, 21, 28, 56 and 84 was, respectively, 6, 5, 5, 5, 4 and 6, and, in group 2, 6, 8, 6, 6, 7 and 6.

### Histology

Graft arteriosclerosis developed in aortic xenografts of both group 1 and group 2 (Figure 1). In group 1, intimal lesions could already be demonstrated at day 14 in 20% (1/5) of the rats and from day 21 onwards in all rats, whereas in group 2 they were present only in 33% (2/6) of the rats at day 21. From day 56 the difference in intimal thickness between both groups was statistically significant (day 56:  $P < 0.01$ ; day 84:  $P < 0.05$ ). At day 84 all the grafts in group 1 were totally occluded, while those in group 2 were still open. During the first 4 weeks, 25 of 27 grafts were extensively (more than 67% circumference) or totally denuded. In the weeks thereafter the



**Figure 1** Thickness of the intima (in  $\mu$ m  $\pm$  SEM) at various time points in group 1 (—) and group 2 (---). At day 56 and day 84 the differences in thicknesses between both groups were statistically significant (\* $P < 0.01$  and \* $P < 0.05$  respectively). All grafts in group 1 were totally occluded at day 84.



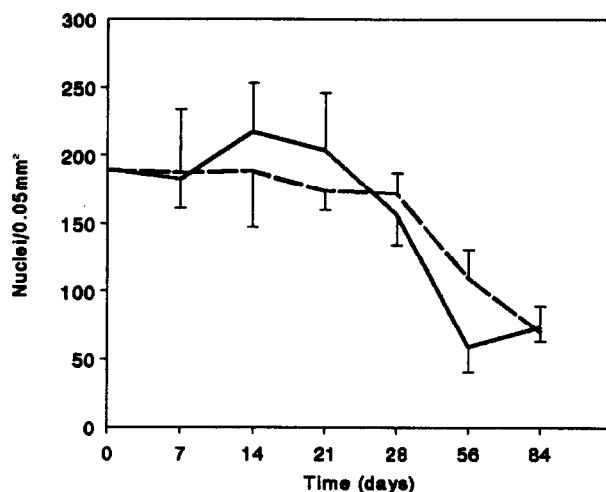
**Figure 2** Thickness of the media (in  $\mu$ m  $\pm$  SEM) at various time points in group 1 (—) and group 2 (---)

grafts were lined with high endothelium. Between days 28 and 84 new endothelium appeared. In group 1 all grafts (6/6) contained endothelial cells with enlarged nuclei until day 84, while in group 2 the endothelial nuclei were normal again at day 84 in 67% (4/6) of the grafts.

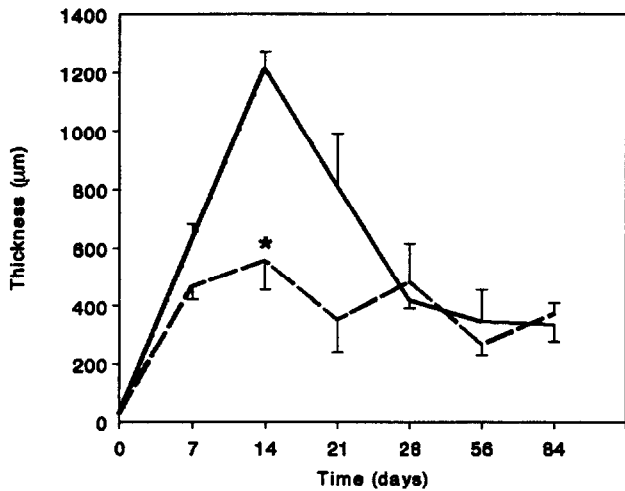
The thickness of the media was slightly increased in both groups, mainly due to oedema, associated with or caused by the inflammation (Figure 2). Thickness of the media in group 2 was normal again at day 84.

Although a few infiltrating macrophages could be seen, the number of nuclei per 0.05 mm<sup>2</sup> in the media remained constant during the first 21 days, but declined sharply from day 21 onwards as a consequence of migration or necrosis of myocytes (Figure 3). The decline in cell density coincided with the development of the intimal lesions. Destruction of the elastic laminae was predominantly found after day 28, especially in group 1. Group 2 showed only focal degeneration of the elastic laminae, whereas circumferential degeneration was seen in group 1.

Thickness of the adventitia in both groups increased after



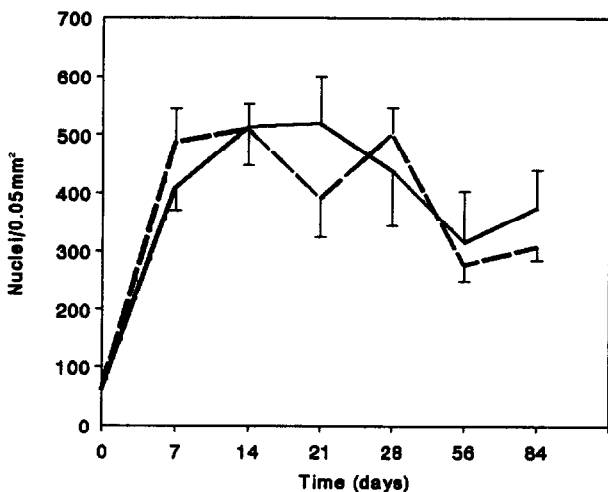
**Figure 3** The number of nuclei per 0.05 mm<sup>2</sup> ( $\pm$  SEM) of the media at various time points in group 1 (—) and group 2 (---)



**Figure 4** Thickness of the adventitia (in  $\mu\text{m} \pm \text{SEM}$ ) at various time points in group 1 (—) and group 2 (---). At day 14 the difference in thickness between both groups was statistically significant (\* $P < 0.01$ ).

transplantation, reaching a peak at day 14 (Figure 4). The thickness of the adventitia of a non-transplanted hamster aorta was  $35 \pm 15 \mu\text{m}$ . Peak value of the adventitial thickness in group 1 was  $1216 \pm 124 \mu\text{m}$  at day 14 while that in group 2 was  $560 \pm 296 \mu\text{m}$  ( $P < 0.01$ ). The increase in thickness of the adventitia was mostly due to a cellular infiltrate of inflammatory cells and to concomitantly occurring oedema. After day 14 the adventitial thickness in group 1 decreased rapidly to reach values comparable to group 2 from day 28 onwards. Adventitial thickness in both groups remained increased until the end of the experiment at day 84 (group 1:  $337 \pm 128 \mu\text{m}$ ; group 2:  $376 \pm 85 \mu\text{m}$ , not-significant).


The number of nuclei per  $0.05 \text{ mm}^2$  in the adventitia of both groups increased rapidly after transplantation (Figure 5). Maximal values in both groups were reached at day 14, whereafter they declined steadily until day 56. From day 56 the number of nuclei per  $0.05 \text{ mm}^2$  remained constant in both groups. There was no difference in cell density of the adventitia in both groups during the 84-day observation period, although



**Figure 5** The number of nuclei per  $0.05 \text{ mm}^2$  ( $\pm \text{SEM}$ ) of the adventitia at various time points in group 1 (—) and group 2 (---)

the total number of infiltrating cells was larger in group 1 (cell density  $\times$  area).

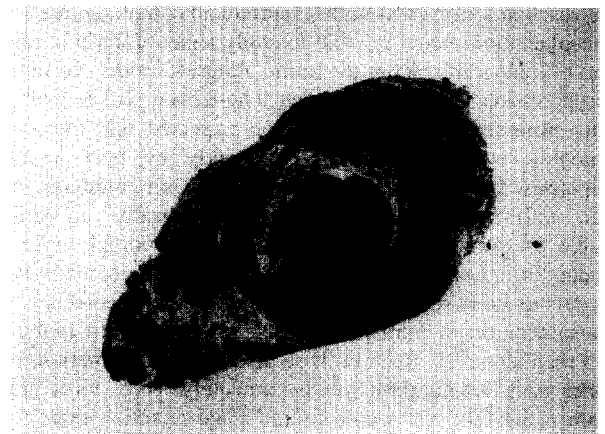Figure 6 shows how the process of cellular infiltration and intimal proliferation developed in aortic grafts in the control group.



(A)



(B)



(C)

**Figure 6** Development of intimal lesions in aortic grafts in the control group on day 28 (A), day 56 (B) and day 84 (C) after transplantation. Haematoxylin-eosin stain,  $\times 50$ . Open triangle: internal elastic lamina; closed triangle: external elastic lamina.

### Immunohistochemistry

The subclasses of infiltrating leucocytes in the grafts were examined by immunoperoxidase staining. The cells infiltrating the adventitia were mainly T cells and macrophages. Occasionally B-cells could be demonstrated. No consistent differences were seen between the number of CD4<sup>+</sup> and CD8<sup>+</sup> cells throughout the observation period. There was no difference between group 1 and group 2 concerning the type of infiltrating cells. However, the number of infiltrating cells was higher in group 1 at day 14 and declined thereafter to reach values comparable to group 2 from day 28 onwards. Cells infiltrating the media consisted mainly of macrophages. Occasionally, a few T cells could be seen, being either CD4<sup>+</sup> or CD8<sup>+</sup>. No B cells could be demonstrated. At the end of the observation period no infiltrating cells were seen in the media of group 2 while very few macrophages were present in the media of group 1.

The intima was infiltrated with macrophages and some T cells. In group 2 the number of infiltrating cells declined towards day 84; at that time hardly any infiltrating immune cells could be demonstrated. In group 1 the same tendency could be seen but especially the number of macrophages at day 84 was higher than in group 2, possibly associated with more necrosis being present at that time. It appeared that the intima consisted mainly of smooth muscle cells as shown by an antibody directed to smooth muscle cell actin. With this staining it could be demonstrated that cellular loss in the media was a consequence of disappearing smooth muscle cells.

### Antibody titre

In group 1 haemagglutinating antibodies were measurable from day 7 onwards. The highest titre was reached at day 14 (titre 1/8). From day 14 until day 56 the antibody titre in group 1 remained constant. At day 84 no antibodies could be demonstrated anymore. No antibodies could be found in group 2 during the whole observation period.

### Discussion

In this study we demonstrate the development of graft arteriosclerosis in concordant aortic xenografts. The development of the vascular lesions was highly reproducible, making this aorta transplantation model reliable to study signs of chronic rejection of xenografts. As in the aortic allograft model, no immunosuppression is needed to obtain long-term graft survival.<sup>11-13</sup> This surprised us, because we had expected that the aortic xenografts would be destroyed quickly by host immune responses. Instead, the grafts remained viable, although they were infiltrated heavily. That aortic xenografts can remain viable for some time has, however, been reported earlier in studies of 'classical' atherosclerosis. One of the recently used models to study recanalization of atherosclerotic vessels is the transplantation of human atherosclerotic aorta into rabbit or dog recipients.<sup>15-17</sup> Even in these discordant combinations, the aortic grafts are not destroyed hyperacutely. Thus, aortic grafts seem to be less susceptible to end-stage rejection than other vascularized grafts, possibly due to their size or to the high blood velocity within these grafts.

The way the intimal lesions developed in our hamster-to-rat model mimicked the situation in the allogeneic aorta transplantation model.<sup>11-13,18</sup> In both models the aortic graft becomes infiltrated with macrophages, T cells and occasion-

ally a few B cells. After this cellular infiltration of especially the adventitia, a progressive intimal thickening, made up primarily of smooth muscle cells, follows. Whether the intimal proliferation is caused by the infiltration cells, cannot be concluded from this experiment. In the allogeneic aorta transplantation model in the rat, a clear correlation exists between the degree of cellular infiltration and the severity of the arteriosclerotic lesions.<sup>19</sup> This has also been demonstrated in rat heart allografts. Cramer *et al.* concluded that, based upon the ability to modify the lesions by immunization and T cell specific immunosuppression, the arteriosclerotic changes in this heart allograft model were likely a chronic cell-mediated rejection response.<sup>20</sup> In the xenogeneic aorta model the same seems to be true, as shown in the CsA-treated recipients. In the immunosuppressed animals the intimal lesions were less pronounced. This coincided with fewer infiltrating cells being present. However, in this group the antibody titre was also lower than in the control group. Therefore, we cannot exclude that humoral responses might also be responsible for the intimal proliferation that we observed.

The pace of development of the arteriosclerotic lesions was higher in our aortic xenografts than in allografts. In various allogeneic combinations it has been reported that, up to 1 month after transplantation, the intimal lesions in aortic grafts were absent or only minor,<sup>11-13</sup> while in the xenogeneic model the intimal lesions were, by then, severe. This correlates with the findings of Reemtsma *et al.*, who found that, in the cynomolgus monkey-to-baboon heart transplantation model, the intimal lesion were already present after 6 days, while no intimal lesions could be found in the control allografts at that time.<sup>9</sup> Their data were, however, not conclusive because they could not exclude that atherosclerotic lesions might have been present in the cynomolgus heart graft before transplantation. The results taken together strongly suggest that xenogeneic grafts are more prone to chronic rejection than allografts. Further studies are needed to determine whether this may be a problem for clinical xenotransplantation.

Our results furthermore demonstrate that the development of arteriosclerotic lesions in xenografts can be inhibited by CsA. It is not clear what the effect of CsA is on this process in aortic allografts. The reported effects range from aggravation,<sup>21</sup> via no influence<sup>12</sup> to inhibition<sup>19</sup> of the process. The reported inhibition of chronic rejection in aortic allografts by CsA was partial at doses of 5 mg/kg given three times a week and complete at doses of 25 mg/kg given three times a week. This correlates with our findings in the xenogeneic model where a dose of 10 mg/kg given three times a week only inhibited the process. On the basis of this and on the basis of our histological and immunohistochemical data, we would like to suggest that chronic rejection in concordant xenografts and allografts only differs in quantity and speed of development, but not in quality.

In conclusion, arteriosclerosis, as a sign of chronic rejection, occurs in concordant aortic xenografts. The lesions in the xenografts develop extremely rapidly, and, compared to data from the literature, faster than in aortic allografts. The process of chronic rejection in xenografts can be reduced by CsA.

### Acknowledgement

This work was supported by a grant from the Fondation Bekales.

## References

- 1 Knechtle SJ, Halperin EC, Bollinger RR. Xenograft survival in two species combinations using total-lymphoid irradiation and cyclosporine. *Transplantation* 1987; **43**: 173–75.
- 2 Bogaerde vande J, Aspinall R, Wang M *et al.* Induction of long-term survival of hamster heart xenografts in rats. *Transplantation* 1991; **52**: 15–20.
- 3 Bouwman E, Bruin de RWF, Jeekel J, Marquet RL. Recipient pre-treatment permits long-term xenograft survival on a relatively low dose cyclosporine maintenance therapy. *Transplant Proc* 1992; **24**: 519–20.
- 4 Hasan RIR, Bogaerde vande J, Forty J, Wright L, Wallwork J, White DJG. Prolonged survival of hamster heart xenografts with cyclophosphamide therapy. *Transplant Proc* 1992; **24**: 517–18.
- 5 Roslin MS, Tranbaugh RE, Panza A *et al.* One-year monkey heart xenograft survival in cyclosporine-treated baboons. Suppression of the xenoantibody response with total-lymphoid irradiation. *Transplantation* 1992; **54**: 949–55.
- 6 Starzl TE, Fung J, Tzakis A *et al.* Baboon-to-human liver transplantation. *Lancet* 1993; **341**: 65–71.
- 7 Billingham RE. Graft coronary disease: the lesions and the patients. *Transplant Proc* 1989; **21**: 3665–71.
- 8 Foegh ML. Chronic rejection-graft arteriosclerosis. *Transplant Proc* 1990; **22**: 119–22.
- 9 Reemtsma K, Pierson III RN, Marboe CC *et al.* Will atherosclerosis limit clinical xenografting. *Transplant Proc* 1987; **19**: 108–18.
- 10 Bailey LL, Jang J, Johnson W, Jolley WB. Orthotopic cardiac xenografting in the newborn goat. *J Thorac Cardiovasc Surg* 1985; **89**: 242–47.
- 11 Mennander A, Tiisala S, Halttunen J, Yilmaz S, Paavonen T, Häyry P. Chronic rejection in rat aortic allografts; an experimental model for transplant arteriosclerosis. *Arterioscler Thromb* 1991; **11**: 671–80.
- 12 Steele DM, Hullet DA, Bechstein WO *et al.* Effects of immunosuppressive therapy on the rat aortic allograft model. *Transplant Proc* 1993; **25**: 754–55.
- 13 Isik FF, McDonald TO, Ferguson M, Yamanaka E, Gordon D. Transplant arteriosclerosis in a rat aortic model. *Am J Pathol* 1992; **141**: 1139–49.
- 14 Green M, Sviland L, Malcolm AJ, Pearson ADJ. Improved method for immunoperoxidase detection of membrane antigens in frozen sections. *J Clin Pathol* 1989; **42**: 875–80.
- 15 Oz MC, Lemole GM, Treat MR *et al.* Effects of a 2.15-micron laser on human atherosclerotic xenografts *in vivo*. *Angiology* 1990; **41**: 772–76.
- 16 Siegel RJ, DonMichael TA, Fishbein MC *et al.* *In vivo* ultrasound arterial recanalization of atherosclerotic total occlusions. *J Am Coll Cardiol* 1990; **15**: 345–51.
- 17 Weber H, Ruprecht L, Enders S. Human atherosclerotic coronary artery xenografts: a model for investigation of transluminal recanalization. *Angiology* 1991; **42**: 15–22.
- 18 Häyry P, Mennander A, Yilmaz S *et al.* Towards understanding the pathophysiology of chronic rejection. *Clin Invest* 1992; **70**: 780–90.
- 19 Geerling RA, de Bruin RWF, Scheringa M *et al.* Suppression of acute rejection prevents graft arteriosclerosis after allogeneic transplantation in the rat. *Transplantation* 1994; **58**: 1258–63.
- 20 Cramer DV, Chapman FA, Wu GD, Harnaha JB, Qian S, Makowka L. Cardiac transplantation in the rat: alteration of the severity of donor graft arteriosclerosis by modulation of the host immune response. *Transplantation* 1990; **50**: 554–58.
- 21 Mennander A, Tiisala S, Paavonen T, Halttunen J, Häyry P. Chronic rejection of rat aortic allografts. II. Administration of cyclosporin induces accelerated allograft arteriosclerosis. *Transplant Int* 1991; **4**: 173–79.