

# Acta Orthopaedica Scandinavica

ISSN: 0001-6470 (Print) (Online) Journal homepage: <http://www.tandfonline.com/loi/iort19>

## Bilateral locked facets in the thoracic spine

Mariette H. A. Willems, Reinder Braakman & Bert Van Linge

To cite this article: Mariette H. A. Willems, Reinder Braakman & Bert Van Linge (1984) Bilateral locked facets in the thoracic spine, Acta Orthopaedica Scandinavica, 55:3, 300-303

To link to this article: <http://dx.doi.org/10.3109/17453678408992361>



Published online: 08 Jul 2009.



Submit your article to this journal [↗](#)



Article views: 73



View related articles [↗](#)

Full Terms & Conditions of access and use can be found at  
<http://www.tandfonline.com/action/journalInformation?journalCode=iort19>

# Bilateral locked facets in the thoracic spine

Two cases of traumatic bilateral locked facets in the thoracic spine are reported. Both patients had only minor neurological signs. They both made a full neurological recovery after surgical reduction of the locked facets.

Bilateral locked facets are very uncommon in the thoracic spine. The diagnosis should be considered in any patient with a fracture-dislocation of the thoracic spine. In these cases additional lateral tomographs are required. Early open reduction of bilateral locked facets and internal fixation are mandatory.

**Mariette H. A. Willems,  
Reinder Braakman &  
Bert Van Linge<sup>1</sup>**

Departments of Neurosurgery and <sup>1</sup>Orthopaedic Surgery, University Hospital Rotterdam, Erasmus University, NL-3015 GD Rotterdam, The Netherlands

In the spine the interarticular facets are interlocked when the upper facets are displaced forward and lodge anterior to the lower facets. This can happen on one or both sides. The traumatic mechanism is supposed to be hyperflexion with or without rotation (Braakman & Penning 1976, Trickey 1976).

Bilateral interlocking of the articular processes is very rare in the thoracic spine, although it is well known in the cervical spine. Between 1972 and 1982, we saw two patients with bilateral locked facets in the thoracic spine following injury.

## Case reports

### Case I

A 47-year-old woman was thrown from her horse and complained immediately after the accident of an extremely painful back and a strange feeling in her left leg. The back pain increased with deep respiration.

There was a gibbus halfway along the thoracic spine, but no neurological deficit. Initial antero-posterior and lateral standard radiographs demonstrated wedge-like compression of T8 with a slice fracture of its upper border and forward dislocation of T7 in relation to T8 (Figure 1A). The patient was prescribed bed-rest and analgesics.

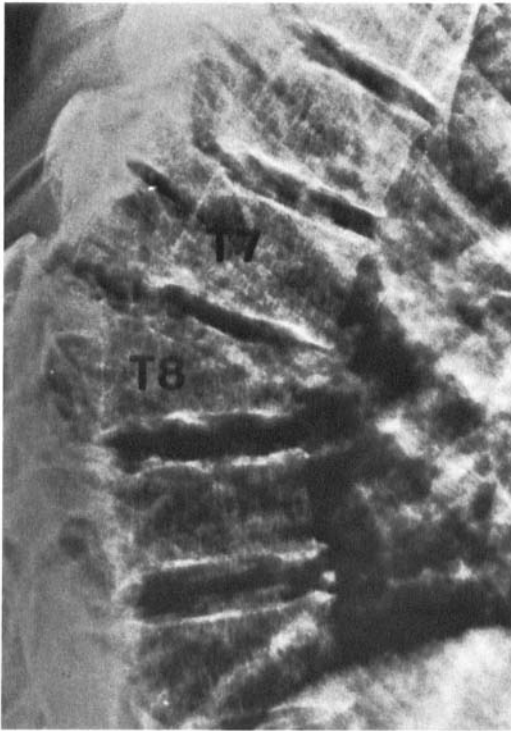
Two days after the accident, she still complained of

a strange feeling in her legs. Re-examination revealed normal motor and sensory function of the legs, but extensor plantar responses on both sides. Lateral tomograms clearly demonstrated bilateral interlocking between the inferior articular processes of T7 and the superior articular processes of T8 (Figure 1B). In addition, the spinous process of T7 was broken. There was a wedge fracture of T8 with avulsion of its upper border and a possible fracture of the right inferior articular facet of T7.

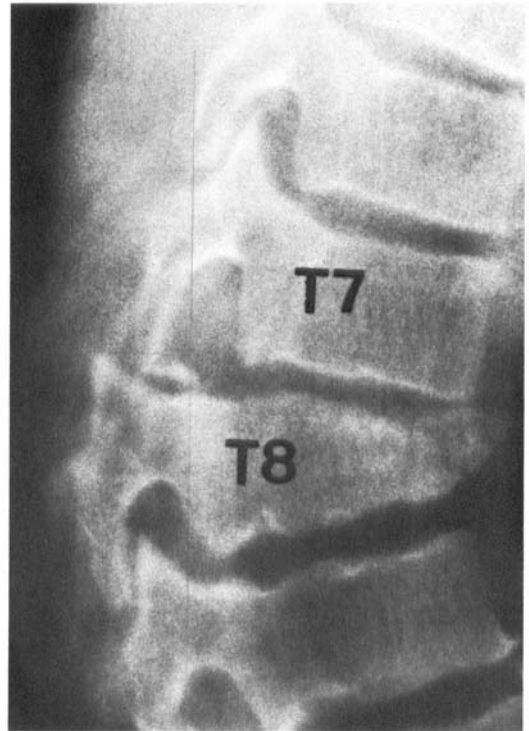
Surgery was carried out and the radiographic diagnosis was confirmed. Partial excision of the facets of T8 was required, before the upper facets could be levered back after the spine had been slightly deflected. A fusion across the decorticated arches of T6, 7 and 8 was performed with an iliac bone graft. The spine was immobilized by means of two plaster shells, which were replaced by a plaster jacket 2 weeks later. After 10 weeks, the patient was ambulated in a Jewett brace. This brace was removed after 3 months.

Radiographs made 1 week after surgery demonstrated a moderate kyphosis and a very slight anterior dislocation between T7 and T8. Six years after the accident, the patient had no complaints and was in no way restricted in her daily activities. Neurological examination was normal, but she had a mild angular deformity and limited range of extension of the thoracic spine.

Standard radiographs revealed an angular kyphosis of 30 degrees and disc space narrowing between T7 and T8. Flexion-extension studies showed no abnormal movement at the fracture site.



A



B

Figure 1 A. Lateral radiograph of the thoracic spine of patient I on admission. Severe fracture dislocation of T7 onto T8. B. Tomogram of the thoracic spine at the level of the fracture dislocation. The inferior articular process of T7 and the superior articular process of T8 is locked, on both sides. The photograph reveals the left side.

## Case II

A 14-year-old boy fell from a height of 4 meters. He complained immediately of intense pain in the back. Three days after the accident the patient was transferred to our hospital. He had mild loss of pain sensation in the left leg, and extensor plantar responses on both sides. Motor function of the legs was normal.

Antero-posterior and lateral radiographs revealed separation of the spinous processes of T11 and T12 and a fracture-dislocation with anterior shift of T11 compared to T12 (Figure 2A). Tomograms of the thoracic spine demonstrated bilateral locked facets between T11 and T12 (Figure 2B), a fracture of the arch of T12 and a slice fracture of the upper border of the same vertebra.

Operation on the sixth day after the accident revealed severe disruption of the posterior ligaments at the level of the dislocation. Apart from the fractured arch of T12, a fracture of the spinous process of T11 was found. There was bilateral interlocking between the inferior articular processes of T11 and the superior articular processes of T12. The dura was intact.

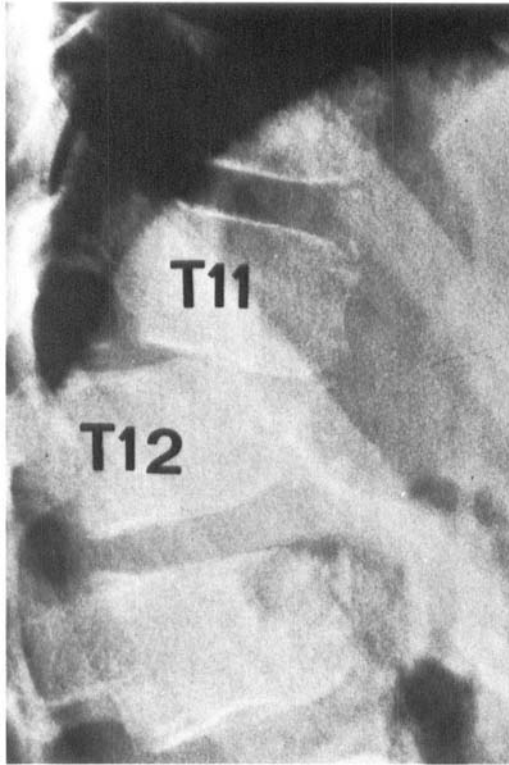
By careful manipulation, the articular processes could be disimpacted and levered into place. Internal

fixation was achieved by means of the insertion of a wire through the spinous processes of T10 and T12. Finally, an iliac bone graft was applied to the vertebral arches of T10, 11 and 12.

Postoperatively, the spine was immobilized in a plaster shell. Four weeks after surgery, the patient was ambulated in a plaster jacket. The plaster jacket was removed 3 months later. Nine months after the injury, the patient had no complaints and no neurological deficit was found. Standard radiographs, made 9 months after the accident, revealed a kyphosis of 15 degrees but no interlocking. There was loss of disc space between T11 and T12.

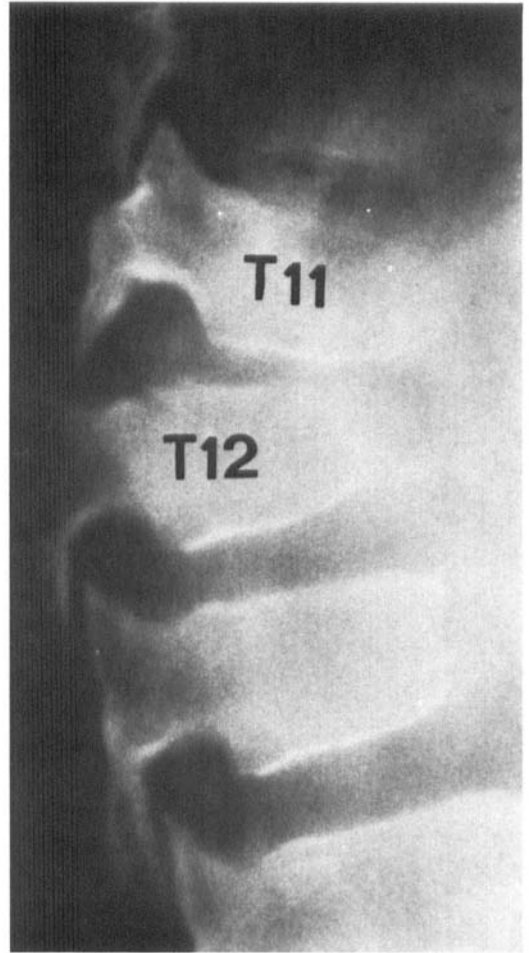
## Discussion

Bilateral interlocking is an unusual injury of the thoracic spine. We are unaware of previous similar case reports of bilateral facet interlocking in the thoracic region, with the exception of one case described by Böhler (1953). Howorth & Petrie (1964) mentioned "complete dislocations" of one or both lateral articulations in one



A

Figure 2 A. Lateral radiograph of the thoracic spine of Case II, showing a fracture dislocation of T11 onto T12.



B

B. Tomogram showing the left inferior articular facet of T11 to be lodged anterior to the superior articular facet of T12. The right facets were also locked.

of the joints of the thoracic or lumbar spine. Tulleken (1971) stated that uni- or bilateral locked facets were "an uncommon finding" in his series of 146 patients with injuries of the thoraco-lumbar spine and neurological signs. Trickey (1976) pointed out that a "pure dislocation" – when facets are locked – must be distinguished from a fracture-dislocation but he did not describe a patient with locked facets in the thoracic spine. Bedbrook (1979) reported that 11 per cent of his patients with thoraco-lumbar fracture-dislocations had locked facets, but he gave no specific example. Nicoll (1949) and Davies et al. (1980) discussed the therapeutic consequences of fracture-dislocations with locked facets.

The anatomical configuration of the thoracic vertebrae partly accounts for the low incidence

of bilateral locked facets in the thoracic spine.

Variations in the shape and position of the lateral articulations in the different regions of the spine contribute to different degrees of stability. Besides, the thoracic spine is more stable than the cervical spine, owing to the thoracic cage which articulates with the spine at the back and the sternum at the front (Stauffer 1977, Trickey 1976). A fracture-dislocation with bilateral locked facets is probably due to violent hyperflexion (Howorth & Petrie 1964) or to hyperflexion combined with rotational forces (Holdsworth 1970, Stauffer 1977).

In any case of a fracture-dislocation of the thoracic spine, additional lateral tomograms and/or computerized tomograms are required to display the postero-lateral joints of the injured vertebrae. Locked facets in the thoracic

spine will not, in general, unlock by postural means. Closed reduction by manipulation is probably dangerous, because the spinal cord or nerve roots might be damaged (Böhler 1953, Howorth & Petrie 1964, Nicoll 1949). Early open reduction and internal fixation are mandatory (Davies et al. 1980, Howorth & Petrie 1964, Trickey 1976).

In our first patient no internal fixation was performed to maintain operative reduction of the fracture-dislocation. Her postoperative moderate angular deformity increased by 10 degrees to 30 degrees during the 6 years following spinal injury. This case stresses the need for an adequate stabilization procedure following open reduction, i.e. bone grafting and internal fixation.

### Acknowledgements

The authors thank Dr. W. v.d. Slikke for permission to report his patients, Mrs. B. S. Vollers-King who language edited the text, and Miss B. A. A. Koehorst who typed the manuscript.

### References

- Bedbrook, G. M. (1979) Spinal injuries with tetraplegia and paraplegia. *J. Bone Joint Surg.* **61-B**, 267–284.
- Böhler, L. (1953) *Die Technik der Knochenbruchbehandlung*. Band I, pp. 422–426. Verlag Wilhelm Maudrich, Vienna.
- Braakman, R. & Penning, L. (1976) Injuries of the cervical spine. In: *Handbook of clinical neurology* (Eds. Vinken, P. J. & Bruyn, G. W.) Vol. 25, pp. 227–380. North Holland Publishing Company, Amsterdam.
- Davies, W. E., Morris, J. H. & Hill, V. (1980) An analysis of conservative (non-surgical) management of thoraco-lumbar fractures and fracture-dislocations with neural damage. *J. Bone Joint Surg.* **62-A**, 1324–1328.
- Holdsworth, F. (1970) Fractures, dislocations and fracture dislocation of the spine. *J. Bone Joint Surg.* **52-A**, 1534–1551.
- Howorth, M. B. & Petrie, J. G. (1964) *Injuries of the spine*, pp. 241–242. Williams & Wilkins, Baltimore.
- Nicoll, E. A. (1949) Fractures of the dorso-lumbar spine. *J. Bone Joint Surg.* **31-B**, 376–394.
- Stauffer, E. S. (1977) Treatment of fractures of the thoracolumbar spine. In: *Spinal disorders, diagnosis and treatment* (Eds. Ruge, E. & Wiltse, L. L.), pp. 380–381. Lea & Febiger, Philadelphia.
- Trickey, E. L. (1976) In: *R. Watson-Jones's fractures and joint injuries* (Ed. Wilson, J. N.), Vol. II, 5th ed. pp. 798–839. Churchill Livingstone, Edinburgh, London, New York.
- Tulleken, C. A. F. (1971) *Gesloten letsels van de laag thoracale en lumbale wervelkolom met neurologische stoornissen*. Thesis. Pasmans, J. H., Den Haag.