

Validation of Infarct Size and Location from the ECG by Inverse Body Surface Mapping

W Arnold Dijk¹, Peter M van Dam², Niek HJJ van der Putten³, Arie C Maan⁴, Mike JJ de Jongste¹

¹University Medical Center Groningen, Groningen, The Netherlands

²Radboud University Medical Center, Nijmegen, The Netherlands

³Erasmus University Medical Center, Rotterdam, The Netherlands

⁴Leiden University Medical Center, Leiden, The Netherlands

Abstract

This paper describes the incorporation of body surface mapping algorithms to detect the position and size of acute myocardial infarctions using standard 12 lead ECG recording. The results are compared with the results from cardiac MRI scan analysis. In case patient specific volume conductor models are used, the position of the infarction could be accurately determined. When generalized patient volume conductor models were examined, the estimation of the infarct position became significantly less accurate. The calculations of the size of the infarctions need further improvement.

1. Introduction

In patients with evolving myocardial infarction (AMI) rapid treatment through percutaneous coronary intervention (PCI) has been shown to be most effective when performed within 2 hours after the onset of the symptoms [1-2]. The electrocardiogram (ECG) is considered to be the pivotal test for diagnosing AMI, initially. Therefore, both correct and rapid execution of the interpretation of the ECG is mandatory in the process of optimal treatment of the AMI patient. Contemporary equipment are able to acquire and digitally transmit ECGs, allowing for on-line consulting of clinicians capable to perform a PCI. However, increasing workload necessitates the involvement of paramedics and diagnostic algorithms built into the ECG equipment. Many algorithms have been developed to identify ST-elevated myocardial infarction (STEMI) and predict the culprit artery from the ECG [3-5]. The algorithms vary from commercial available general purpose systems to systems especially designed for this purpose. However, the reliability of these algorithms has been shown to be moderate to poor, depending on the location of the culprit occlusion. The accuracy of the algorithms was even worse for ECG recordings of patients having a non-

STEMI myocardial infarction. Studies have shown that approximately 40% of the patients with a totally occluded coronary artery generate non-STEMI ECG recordings [5]. Also an algorithm [6] designed by our group, incorporating other parts of the ECG besides the ST-segment, is performing suboptimal. The meticulousness of each of these algorithms for a group of 525 STEMI patients is expressed by the Index of Merit (sensitivity + specificity – 100) for each of the major coronary arteries in table 1.

Table 1. Indexes of Merit for 4 different algorithms.

	RCA	LAD	LCX
Fiol[3]	72.3	76.3	16.1
Tierala[4]	71.9	82.3	29.9
Wang[5]	55.1	46.0	25.3
Maan[6]	70.4	82.2	46.4

Given the inaccuracies of the algorithms discussed above, we have explored in the present study the potentials of body surface mapping models. The state of the art systems like ECGSIM [7] are able to simulate effects of local physiological deviations due to the presence of myocardial ischemia on the ECG. During periods of ischemia electric activities of myocytes differ from electric activities in normal tissue. These differences are reflected in smaller transmembrane potential amplitude (TMP), shorter action potential duration (APD) and a decreased velocity of propagation. Using the inverse body surface mapping algorithms of the system, a recorded ECG can be matched by a generated model-ECG through a best fit algorithm by adjusting the size of the ischemic area, its TMP, APD and velocity of propagation. The incorporated fastest route algorithm enables for acceptable computation times. As a first step in evaluating this approach, we used a dataset of 41 well documented patients with a STEMI who underwent a PCI procedure and a cardiac MRI scan to determine the

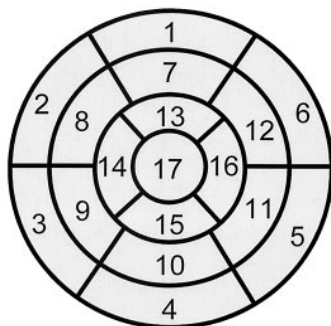
size and location of the myocardial infarction [8]. Twelve lead ECG recordings were taken, Creatine Kinase(CK), Creatine Kinase Myocardial Band(CK-MB), and Troponine T (cTnT) levels were analyzed at various moments.

2. Methods

MRI images of 5 patients (1 female, 4 males) were used to determine the geometry of the heart, in addition generalized geometries of lungs and torso were constructed from the MRI, to constitute the mandatory electric volume conductor. The average amplitude of the J+40 ms till J+60 ms interval of each selected beat of 12 lead surface ECG recordings were used to adapt the parameters of the model to the surface ECG. In the present study only location and size of the ischemic area and the TMP are adapted using a best fit algorithm [9]. The current algorithms are only be applied for the simulation of transmural infarctions. As of yet correlation with occluded coronary arteries was not assessed.

MRIs were performed at least 2 days after PCI. Patients were studied on a clinical 1.5 Tesla scanner. Electrocardiogram-gated images were acquired during repeated breath-holds of approximately 10 seconds. Infarct size analysis was performed by a blinded core laboratory. According to the 17-segment model as recommended by the American Heart Association, segment location was defined using cine images and late gadolinium enhancement (LGE) images (fig. 1) [10].

Left Ventricular Segmentation



- | | | |
|------------------------|-----------------------|---------------------|
| 1. basal anterior | 7. mid anterior | 13. apical anterior |
| 2. basal anteroseptal | 8. mid anteroseptal | 14. apical septal |
| 3. basal inferoseptal | 9. mid inferoseptal | 15. apical inferior |
| 4. basal inferior | 10. mid inferior | 16. apical lateral |
| 5. basal inferolateral | 11. mid inferolateral | 17. apex |
| 6. basal anterolateral | 12. mid anterolateral | |

Figure 1. Standardized myocardial segmentation and nomenclature for tomographic imaging of the heart.

Segmental wall thickening was calculated by subtracting end-diastolic from end-systolic wall thickness. Dysfunctional segments were defined as

segments with systolic wall thickening of less than 3 mm. The *superficial* extent of the myocardial infarction was calculated by summation of all slice volumes of hyperenhancement, using a standardized and predefined definition (signal intensity > 5 SD above the mean signal intensity of remote myocardium), and expressed as percentage of LV mass. The *transmural* extent of infarction was calculated by dividing the hyperenhanced area by the total area of the predefined segment [11]. Segments with more than 50% hyperenhancement were considered segments with transmural infarction. Segment 17 (apex) was excluded since segmental evaluation in the short axis orientation is considered unreliable.

To compare the results from ECGSIM with MRI-analyses, the ECGSIM data were also converted to standard 17-segment bull's-eye maps (fig.1). The optimization algorithm calculates from the ECG the ischemic / infarcted area through determination of the locations of the nodes where the Trans Membrane Potential amplitude has been decreased by more than 15%. The volume is derived through multiplication of the ischemic / infarcted area by the local wall thickness [9].

3. Results

In table 2 the baseline patient and angiographic characteristics are shown.

Table 2. Baseline characteristics of the dataset

Number of patients		41	
Male		32	Age 45 - 71
Female		9	Age 38 - 67
100% occluded arteries	RCA	10	
	LAD	24	
	LCX	7	

In 14 out of the 41 patients analysis of MRI-scans did not result in identifying a *transmural* ischemic / infarcted region, though in blood samples changes in levels of cardiac markers, such as Troponine, indicated tissue damage. This discrepancy could be caused by on time reperfusion through fast track PCI, inability of the MRI to analyze apical ischemic changes or sudden oxygen supply through recruited collaterals. The latter preventing massive myocardial areas from becoming necrotic. The data of the remaining 27 patients were used to validate the described inverse procedure.

Van Dam *et al.* [9] showed that optimal results were obtained when patient specific volume conductor models were used.

Figure 2 is an example of such a patient specific bull's-eye plot of a calculated infarcted region generated by ECGSIM. The different colors represent the amount of TMP amplitude decrement. A decrease in amplitude of >

15% indicates ischemia. The calculated location of the infarction corresponds with the MRI-reference[10].

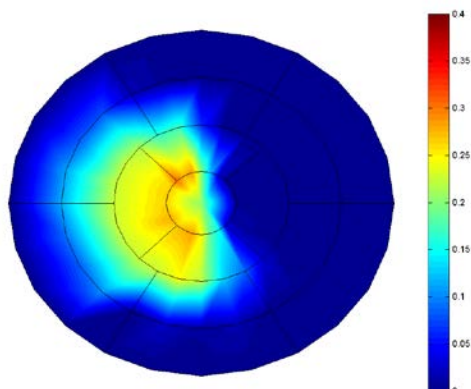


Figure 2. Bull's-eye presentation of Left Ventricle. Color shades represent ischemic tissue. The segmentation is in accordance with the standard.

Similar correlations are found for the other 4 patients using the specific volume conductor model. Since it is not feasible in acute situations to construct a patient specific volume conductor model we only used two gender-dependent models. These 2 models were derived from the 5 elaborated ones, the female model and an average male model.

In table 3 the calculated ischemic / infarcted segments are shown for both methods, using the female volume conductor model. The segments displayed between brackets had a hyperenhancement between 30% and 50% indicating non-transmural damage. In table 4 the results for male patients are displayed with the male volume conductor model that generated the best agreements with the MRI reference segments. In contrast to table 3 (females), we observed in about 85% of the male cases correspondence between ECG and MRI determined locations of the ischemic / infarcted regions.

Table 3. Left ventricular infarcted region location for female patients

patient	MRI segments	ECG segments
A	7,8,13(2)	11(4,5,10)
B	10,15(3,4,5,9,11)	9,10(14,15)
C	5,6,11,12,16(15)	5,11(4,6)
D	13	5(4,11)
E	4,5(10,11)	11(4,5,10)
F	2,7,8,9,13,14(16)	5,11(4,10)
G	1,2,6,7,8,12,13,14,16(9)	(4,5,10,11)
H	7,13	11(4,5,10)

Table 4. Left ventricular infarcted region location for 19 male patients

patient	MRI segments	ECG segments
A	7,8,13,14(1,9)	8,13,14,17(15)
B	7,8,13(14)	8,9,14(13,15)
C	7,13(14)	8,9,14(13,15)
D	8,9,13,14(2,15)	14(7,8,9,15)
E	5(3,10,11,15)	(2,3,6,12)
F	5,6,11,12,16(1,15)	(5,6,11,12)
G	4,10,15(5)	(9,10,14,15)
H	8,13,14	14(8,9,13,15,17)
I	11(5)	(8,9,10)
J	4,9(3,14)	(3,4,9,10)
K	8,13,14(2,7,9,15,16)	14(8,9,13,15,17)
L	1,2,6,7,8,12,13,14,16	14(8,9,13,15)
M	7,13(1)	8,9,14(13)
N	7,8,13,14(2,3)	14(8,9,13,15)
O	13(1,7)	14(8,9)
P	8,14(2,7,13)	8,14(9,13,15)
Q	5,11,15(3,10,16)	(9,14,15)
R	13	8,13(9,14,17)
S	4,5(10,11)	3,4(10,11)

In figure 3 the derived volume of the myocardial infarction is plotted against the derived volume from the MRI analysis. Both methods generate uncorrelated results.

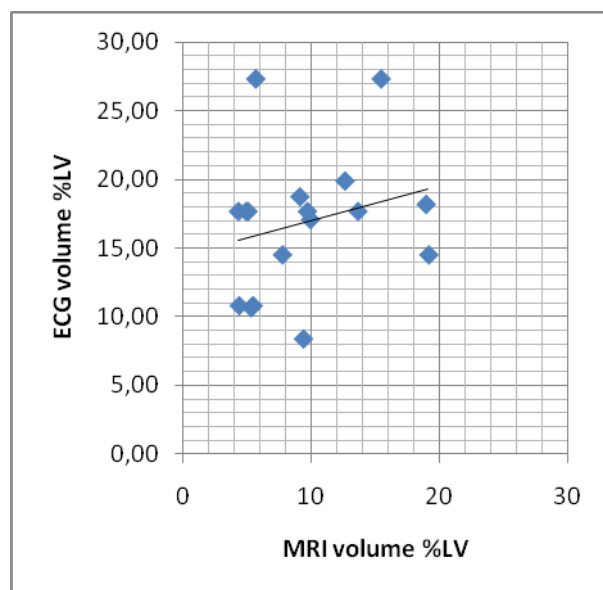


Figure 3. Relation between the infarct volume assessment by inverse ECG based method and MRI analysis.

4. Discussion

The position of the STEMI area on just the standard 12 lead ECG and an accurate patient specific volume conductor model can be accurately determined as is shown for a group of 5 patients. However, this accuracy decreases when no patient specific volume conductor model is available and therefore a generalized model has to be used, which is the case in daily practice. Even two, gender dependent, volume conductor models did not generate acceptable results, although the incorporation of a “male”-model did improve the outcome significantly. This stimulates the idea to develop more generalized models depending on gender, age, weight, etc.. Also different electrode positions should be considered since this has been shown to be beneficial for inferior myocardial infarction.

The derived volume if the ischemic / infarcted area disagrees significantly with the area calculated from MRI-scans. This might be partially explained by the fact that the ECG’s were recorded at the same day as the PCI procedure whereas the MRI-scans were performed 2 – 4 days later. Furthermore the translation from electrophysiological changes due to ischemia to a mathematical formulation has to be examined.

Once an accurate algorithm for the location and size of transmural infarction is realized, extension to analyzing non-STEMI infarction and locating the culprit occlusion will have to be taken before the system can be applied in daily practice.

References

- [1] Zijlstra F, de Boer MJ, Hoorntje JC, Reifers S, Reiber JH, Suryaoranata H. A comparison of immediate coronary angioplasty with intravenous streptokinase in acute myocardial infarction. *N Engl J Med* 1993 11;328(10):680-4.
- [2] Keeley EC, Boura JA, Grines CL. Primary angioplasty versus intravenous thrombolytic therapy for acute myocardial infarction: a quantitative review of 23 randomised trials. *Lancet* 2003 ;361(9351):13-20.
- [3] Fiol M, Cygankiewicz MD, Guindo J, Flotats A, Bayes Genis A, Carreras F, Zareba W, Bayes de Luna A. Evolving Myocardial Infarction With ST Elevation: Ups and Downs of ST in Different Leads Identifies the Culprit Artery and Location of the Occlusion. *Ann Noninvasive Electrocardiol* 2004; 9: 180-6.
- [4] Tierala I, Nikus KC, Sclarovsky S, Syvanne M, Eskola M. Predicting the culprit artery in acute ST-elevation myocardial infarction and introducing a new algorithm to predict infarct-related artery in inferior ST-elevation myocardial infarction: correlation with coronary anatomy in the HAAMU Trial. *Journal of Electrocardiology* 2009; 42: 120-7.
- [5] Wang SS, Paynter I, Kelly RV, Koch GG, Skains MS, Gettes LS. Electrocardiographic determination of culprit

lesion site in patients with acute coronary events. *J Electrocardiol.* 2009;42;46-51.

- [6] Maan AC, Dijk WA, van der Putten NHJJ, Man SC, Rahmatullah C, van Zwet E, Swenne CA, Schaliij MJ. A Vector Cardiographic Based Method To Determine the Culprit Artery in Acute Coronary Syndrome. *Computing in Cardiology* 2011;38:409–412.
- [7] van Dam PM, Oostendorp TF, van Oosterom A. Interactive Simulation of the Activation Sequence: replacing Effect by Cause. *Computing in Cardiology* 2011;38:657–660.
- [8] Nijveldt R, van der Vleuten PA, Hirsch A, Beek AM, Tio RA, Tijssen JGP, Umans VAWM, Algra PR, Piek JJ, van Rossum AC, Zijlstra F. Early assessment of ST-segment resolution, residual ST-segment elevation and Q waves in relation to left ventricular function, size and extent of infarction, and microvascular injury in acute myocardial infarction. *J. Am Cardiol Img* 2009;2(10):1187-94.
- [9] Van Dam PM, Dijk WA, van der Putten NHJJ, Maan AC, de Jongste MJJ. Estimating Infarct Severity from the ECG using a Realistic Heart Model. *Computing in Cardiology* 2012;39:
- [10] Cerqueira MD, Weissman NJ, Dilsizian V, Jacobs Alice K, Kaul S, Laskey WK, Penell DJ, Rumberger JA, Ryan T, Verani MS. Standardized Myocardial Segmentation and Nomenclature for Tomographic Imaging of the Heart: A Statement for Healthcare Professionals From the Cardiac Imaging Committee of the Council on Clinical Cardiology of the American Heart Association. *Circulation* 2002;105;539 – 542.
- [11] Bondarenko O, Beek AE, Hofman MBM, Kuhl HP, Twisk JWR, van Dockum WG, Visser CA, van Rossum AC. Standardizing the definition of hyperenhancement in the quantitative assessment of infarct size and myocardial viability using delayed contrast-enhanced CMR. *Journal of Cardiovascular Magnetic Resonance* 2005; 7: 481-5.

Address for correspondence.

Arnold Dijk
Thoraxcenter
University Medical Center Groningen
Hanzeplein 1
9713 EZ Groningen
The Netherlands
W.A.Dijk@umcg.nl.