

OPEN

Guideline for Care of Patients With the Diagnoses of Craniosynostosis: Working Group on Craniosynostosis

Irene M.J. Mathijssen, MD, PhD

(*J Craniofac Surg* 2015;26: 1735–1807)

Chaired by Irene M.J. Mathijssen, MD, PhD

Participants:

The Dutch National Cranial and Facial Deformities Patients and Parents Association (LAPOSA)

The Netherlands Society for Ophthalmology

The Netherlands Society for Anesthesiology

The Netherlands Society for Otorhinolaryngology

The Dutch Association for Pediatrics

The Netherlands Society for Oral Medicine and Oral and Maxillofacial Surgery

The Netherlands Society for Neurosurgery

The Netherlands Society for Plastic Surgery

The Society for Orthodontists

The Netherlands Society for Clinical Genetics

The Dutch Association of Psychologists

The Netherlands Society for Relationship Counseling and Family Therapy

Address correspondence and reprint requests to Irene M.J. Mathijssen, MD, PhD, Department of Plastic and Reconstructive Surgery, and Hand Surgery, Room Sk-1202, Erasmus Medical Center-Sophia, Wytewaweg 80, 3015CN Rotterdam, The Netherlands. E-mail: i.mathijssen@erasmusmc.nl

ABSTRACT

This guideline for care of children with craniosynostosis was developed by a national working group with representatives of 11 matrix societies of specialties and the national patients' society. All medical aspects of care for nonsyndromic and syndromic craniosynostosis are included, as well as the social and psychologic impact for the patient and their parents. Managerial aspects are incorporated as well, such as organizing a timely referral to the craniofacial center, requirements for a dedicated

craniofacial center, and centralization of this specialized care. The conclusions and recommendations within this document are founded on the available literature, with a grading of the level of evidence, thereby highlighting the areas of care that are in need of high-quality research. The development of this guideline was made possible by an educational grant of the Dutch Order of Medical Specialists.

The development of this guideline was supported by an educational grant of the Dutch Order of Medical Specialists.

Contents

Chapter 1. General introduction	1735
Chapter 2. Introduction to craniosynostosis	1736
Chapter 3. Referral and diagnostics	1737
Chapter 4. Perioperative care	1744
Chapter 5. Surgical treatment of nonsyndromic craniosynostosis	1747
Chapter 6. Surgical treatment of syndromic craniosynostosis—the cranial vault	1751
Chapter 7. Surgical treatment of syndromic craniosynostosis—the face	1753
Chapter 8. Increased intracranial pressure	1762
Chapter 9. Hydrocephalus	1768
Chapter 10. Chiari I malformation	1769
Chapter 11. Vision, refraction and motility abnormalities	1771
Chapter 12. Obstructive sleep apnea syndrome	1772
Chapter 13. Hearing impairments	1776
Chapter 14. Dentofacial deformities	1777
Chapter 15. Deformities of the extremities	1780
Chapter 16. Cognitive functioning and behavior	1783
Chapter 17. Patients' and parents' perspectives	1786
Chapter 18. Psychosocial functioning	1787
Chapter 19. Criteria for the craniofacial center and its team members	1790
Chapter 20. Summary	1794

1. GENERAL INTRODUCTION

Objective

This guideline provides recommendations for medical practice on suspicion of craniosynostosis and after confirmation of this diagnosis. It is based on the results of scientific research and subsequent forming of opinion by a multidisciplinary working group, composed of representatives of the medical specialties involved in the treatment of craniosynostosis, related professional disciplines, and other parties involved.

The wishes of parents and health professionals regarding the organization of health care for craniosynostosis were inventoried. The guideline document addresses the important issues for the support of parents with a child with a craniosynostosis.

Method Employed by the Working Group

The content of this guideline is based on evidence from published scientific research. Relevant articles were identified using systematic



What Is This Box?

A QR Code is a matrix barcode readable by QR scanners, mobile phones with cameras, and smartphones. **The QR Code links to the online version of the article.**

Received April 30, 2015.

Accepted for publication June 28, 2015.

The authors report no conflicts of interest.

This is an open access article distributed under the terms of the Creative Commons Attribution-NonCommercial-NoDerivatives 4.0 License, where it is permissible to download and share the work provided it is properly cited. The work cannot be changed in any way or used commercially.

Copyright © 2015 by Mutaz B. Habal, MD

ISSN: 1049-2275

DOI: 10.1097/SCS.0000000000002016

searches in Medline, Embase, and the Cochrane Library. Existing guidelines were specifically searched for in online accessible international and national guideline clearinghouses. Searches were limited to the Dutch, English, and French languages. In addition, articles were extracted from reference lists of relevant literature. This resulted in additional articles for several basic questions.

Care for children with craniosynostosis was introduced in the late 1960s and consequently the English literature from those years onwards was included. Searches were performed until December 1, 2009 and articles available as “Epub ahead of publication” at that date were included as well.

The following search terms were used: craniofacial, craniosynostosis combined with: genetics, hydrocephalus, Chiari, cerebral pressure, otitis, hearing, vision, psychology, anesthesia, complications, infection, development, growth, maxilla, mandible, distraction, osteotomy, Fort, midface, RED, halo, monobloc, facial bipartition, median faciotomy, and hypertelorism.

Relevant articles extracted from reference lists of retrieved literature and several relevant publications until November 1, 2009 were included as well. Under the headings Summary of the literature/Conclusions only published studies/guidelines are discussed. Case reports and letters were excluded, unless they reported a complication.

The selected articles were assessed on methodological quality graded by level of evidence according to the standard classification: see Table 1. After selection, those articles remained that are listed to underpin the various conclusions. The articles are assessed under the heading “Summary of the literature.” Next, the scientific evidence is briefly summarized in “Conclusions.” The main literature on which a conclusion is based is mentioned as well, including the level of evidence (see Table 2).

Other aspects than scientific evidence may be relevant to making a recommendation as well, such as patient preferences (derived from the results of the focus group sessions or relevant literature on the patient perspective), costs, availability, or organizational aspects. These kinds of aspects, provided they have not been subject of research, are mentioned under the heading “Considerations.” The experience and the opinion of the working group members have been key to the other considerations. The “Recommendation” results from the combination of the available evidence and the other considerations.

Patient Perspective

When developing this guideline, the working group particularly strived for incorporating the patient perspective. The working group therefore included representatives of the LAPOSA patient association. Besides, in collaboration with LAPOSA 2 focus group sessions were held: 1 with parents of a young child with a

craniosynostosis and 1 with young adults with craniosynostosis and parents of older children with a craniosynostosis. The working group incorporated outcomes of these sessions in the guideline. Finally, focus group participants were asked to comment on a draft version of the guideline.

Note

This guideline was drafted on the guidance of the *Appraisal of Guidelines for Research & Evaluation* (AGREE) instrument. This instrument was developed at a European level to enable assessment of the procedural quality of guidelines. By incorporating AGREE aspects in the introduction to the guideline it is made clear what quality requirements have been met.

2. INTRODUCTION TO CRANIOSYNOSTOSIS

Craniosynostosis is a congenital cranial malformation in which 1 or more cranial sutures have fused already in utero. The cranial sutures separate the skull bone plates and enable rapid growth of the skull in the first 2 years of life, in which growth is largely dictated by growth of the brain. Cranial sutures are essential to skull growth in the first 2 years (the period of rapid brain growth). Thereafter the process of appositional growth and internal resorption of the skull is the major process by which the skull increases in size.

Premature fusion of cranial sutures impedes normal growth of the skull, resulting in characteristic anatomic malformations of the skull.

Craniosynostosis occurs in 1 in 2100 to 1 in 2500 births and may be either nonsyndromic (also referred to as isolated) or syndromic. In syndromic craniosynostosis, other birth defects are present next to the craniosynostosis. In syndromic craniosynostosis, usually more than 1 cranial sutures have prematurely fused, typically involving both coronal sutures.

The distinction between nonsyndromic and syndromic is made on the guidance of dysmorphologic evaluation and genetic evaluation. Owing to advances in genetic diagnostics, nonsyndromic patients are increasingly recognized as syndromic patients. The discovery of the P250R mutation in the *FGFR3* gene in patients with a uni- or bilateral coronal suture synostosis clearly illustrates this phenomenon.

Approximately 60% of all craniosynostoses are of the nonsyndromic type and approximately 40% are of syndromic type. Within the group of nonsyndromic craniosynostoses the sagittal suture synostosis is the largest group, followed by metopic suture synostosis. Recently, the prevalence of metopic suture synostosis has clearly risen both in Europe and the United States, but this has not been explained. Synostosis of 1 or both lambdoidal sutures is very rare.

Of the syndromic types the Muenke syndrome is the most frequent, followed by Crouzon syndrome, and Pfeiffer syndrome.

TABLE 1. Classification of Methodological Quality of Individual Studies

	Intervention	Diagnostic Accuracy Assessment	Harm or Side Effects, Etiology, Prognosis*
A1	Systematic review of at least 2 mutually independent studies of A2-Level		
A2	Randomized double-blind comparative clinical study of good quality and sufficient size	Study comparing with a reference test (a “criterion standard”) with previously defined cut-off values and independent assessment of the results of study test and criterion standard, regarding a sufficiently large series of consecutive patients who all were administered the index- and the reference test	Prospective cohort study of sufficient size and follow-up, adequately controlled for confounding and with satisfactory exclusion of selective follow-up
B	Comparative study, but not possessing all qualities mentioned under A2 (this category also includes patient-checkup study, cohort study)	Study comparing with a reference test, but not possessing all qualities mentioned under A2	Prospective cohort study, but not possessing all qualities mentioned under A2, or retrospective cohort study or patient-checkup study
C	Noncomparative study		
D	Expert opinion		

* This classification only applies to situations in which controlled trials are not feasible for ethical or other reasons. If they should be feasible, the classification for interventions applies.

TABLE 2. Level of Evidence for the Conclusion

Conclusion based on	
1	Level A1 study or at least 2 mutually independent Level A2 studies
2	One Level A2 study or at least 2 mutually independent Level B studies
3	One Level B or C study
4	Expert opinion

The Apert syndrome has the lowest prevalence. The distinction between Crouzon syndrome and Pfeiffer syndrome was made on the basis of deformities of the big toe and thumb: if these were broad and short the syndrome was referred to as Pfeiffer syndrome. Because *FGFR2* mutations, however, were identified in both Crouzon and Pfeiffer syndrome, which can even be completely identical, the distinction between these 2 syndromes can be considered irrelevant. Before the discovery of *TWIST1* mutations and deletions in Saethre-Chotzen syndrome and the P250R *FGFR3* mutation in Muenke syndrome it was hard to distinguish between these patients. New mutations are expected to be found in the future, on account of which the group of nonsyndromic craniosynostoses will further decrease.

The following types of craniosynostosis are distinguished:
Nonsyndromic:

- Sagittal suture synostosis (scaphocephaly)
- Metopic suture synostosis (trigonocephaly)
- Coronal suture synostosis, unilateral (frontal plagiocephaly)
- Coronal suture synostosis, bilateral (frontal brachycephaly)
- Lambdoid suture synostosis (pachycephaly)

Syndromic:

- Apert syndrome (*FGFR2* mutation Ser252Trp and Pro253Arg, deletion exon IIIc, Alu insertion exon IIIc)
- Crouzon or Pfeiffer syndrome (*FGFR2* mutations exclusive of Apert mutations)
- Saethre-Chotzen syndrome (*TWIST1* mutations or deletions)
- Muenke syndrome (Pro250Arg *FGFR-3* mutation)
- Craniofrontonasal dysplasia (*EFNB1* mutations)
- Complex craniosynostosis (syndromic picture without known mutation, often 2 or more synostotic sutures)

Each type of craniosynostosis may vary in its severity of presentation. Notably, sagittal suture synostosis and metopic suture synostosis can show a very mild phenotype in which only a bone ridge at the afflicted suture is palpable and/or visible. The severe form of sagittal suture synostosis is characterized by considerable frontal bossing and punctiform occipital prominence in combination with saddle deformity in the midline of the skull. The severe form of metopic suture synostosis is characterized by a large wedge-shaped forehead with underdeveloped lateral parts of the supraorbital ridge, temporal depressions, and hypotelorism. Synostosis of 1 coronal suture causes orbital dystopia, in which the orbital cone at the afflicted side is placed higher than of the unaffected side, retrusion of the forehead at the afflicted side with compensatory bossing of the contralateral side, and asymmetry of the skull base and the face. Consequently, displacement of the ear and lateral deviation of the nose occur. Bilateral synostosis of the coronal sutures result in retrusion of the forehead and the supraorbital rim with a broad skull. Syndromic craniosynostosis is usually characterized by synostosis of both coronal sutures, but other types of craniosynostosis are seen as well.

Indications for surgical treatment of nonsyndromic craniosynostosis are the risk of increased intracranial pressure (ICP) and the abnormal skull shape. Since the first surgical intervention for craniosynostosis, a great many surgical techniques for the various

types of craniosynostosis have been described. A broad distinction is that between osteoclastic techniques and remodeling techniques, osteoclastic techniques involve resection of bone, thereby allowing the developing and expanding brain to change the shape of the skull, also because the adverse impulse to the growth direction of the skull is removed. The remodeling techniques, on the other hand, do not rely on the selfcorrecting capacity of the skull and the brain, but attempt to obtain the desired skull shape by a reconstruction.

The surgical treatment of patients with syndromic craniosynostosis was developed in Paris in the early 1970s. Treatment has a 2-fold aim: to enlarge the cranial volume so as to prevent sequelae of ICP (mental retardation and impaired vision), and to correct morphologic abnormalities of the cranium, the orbits, and the upper jaw. Multiple corrections of the skull and/or the face may be needed, although naturally it is strived for to restrict the number of interventions as much as possible.

The group of complex craniosynostoses is managed in the same way as the syndromic craniosynostoses, as these patients often experience similar problems of cognition and ICP.

Syndromic craniosynostosis, notably, the Apert and Crouzon/Pfeiffer syndromes, are associated with skeletal hypoplasia of the midface. The result may be narrowed airway causing obstructive sleep apnea syndrome (OSAS) in approximately 50%, exorbitism with risk of cornea injury, malocclusion, and esthetic/psychosocial problems.

Associated brain abnormalities in syndromic craniosynostosis include raised intracranial pressure (ICP), Chiari I malformation, ventriculomegaly, and hydrocephalus.

In all types of syndromic synostosis hearing loss is described. Vision, refraction and motility abnormalities in the nonsyndromic craniosynostoses are in fact only seen in unilateral coronal suture synostosis. In the syndromic group, abnormalities such as astigmatism and strabismus are very frequent.

Deformities of the extremities are notably restricted to the syndromic craniosynostoses, and in patients with Apert syndrome always present in a severe form. In the other syndromic types, deformities of the extremities are generally very mild.

Parents are often confronted with health professionals who do not recognize the craniosynostosis shortly after the birth of the child. This can be a source of stress for parents and lead to a delay in diagnosis and treatment. Nonsyndromic and syndromic craniosynostosis may co-occur with cognitive impairments and behavioral disorders. These may occur both intrinsic to the congenital defect and secondary to, for example, increased cranial pressure or abnormal physical appearance. Notably, families of a child with syndromic craniosynostosis may experience psychosocial problems, such as having to cope with negative reactions from others, a possible discrepancy between deviating physical appearance and cognition, and problems with school choice.

3. REFERRAL AND DIAGNOSTICS

Basic Questions

1. How to optimize recognition of craniosynostosis in the primary and secondary healthcare sectors?
2. How to organize referral?
3. What additional diagnostic procedures are applied in the tertiary healthcare sector?

Introduction

Craniosynostosis should be recognized timely for optimal treatment. It appears, however, that craniosynostosis patients often are

not referred at all or referred (too) late. A complicating factor in the recognition of craniosynostosis is the high incidence of positional head shape deformities. It may be expected that recognition, and thus referral of patients with craniosynostosis will happen earlier if health professionals in the primary and secondary healthcare sectors are facilitated to make this distinction.

Preceding the referral to a tertiary healthcare center, we often see overuse of diagnostic imaging, which is associated with further delay in referral, an extra burden and insecurity for patient and parents as well as unnecessary expenditure. This should be restricted to a minimum. There are many options to diagnose isolated craniosynostosis or any associated abnormalities. To restrict both underdiagnosis and overdiagnosis, basic question 3 concerns further diagnostic procedures in a tertiary healthcare center. Areas of attention are diagnostic imaging, genetic diagnostics, and the role of the pediatrician.

Inclusion of a clinical geneticist in a multidisciplinary craniofacial team provides the opportunity to address questions from parents and attending physicians.

Parents will first of all want to know if their child is healthy otherwise, what may have caused the deformity, how great the chance is of recurrence in a new pregnancy in the family and/or in the next generation, and what prenatal diagnostic methods are available. For the attending physician it is important to know if there are any associated anomalies (to be expected) next to the craniosynostosis that may be of influence to the treatment plan and the prognosis of the child.

Basic Question 1: How to Optimize Recognition of Craniosynostosis in the Primary and Secondary Health Care Sectors?

Summary of the Literature

The abnormal skull shape is recognized by parents themselves, midwife, obstetrician, general practitioner, infant health clinic (physician, nurse), (pediatric) physiotherapist, pediatrician, (pediatric) neurologist, and helmet maker. Occasionally, it is recognized later by other specialists and sometimes not until a craniofacial team is involved. Most of the children (50%–90%) were referred via the pediatrician, others via the infant health clinic, or parents themselves via the GP. These data are from the Birmingham craniofacial center and could therefore well compare with the situation in the Netherlands.^{1,2} For the situation in the Netherlands only the information from an article by Bredero-Boelhouwer is available,³ in which 18 children were identified by the referrers as having craniosynostosis and in 14 of whom this diagnosis was confirmed in the tertiary center. Of the 89 referrals with the initial diagnosis *nonsynostotic occipital plagiocephaly* (NSOP) made by the referrer, 10 patients appeared to have a craniosynostosis. Thus, professionals in the primary and secondary healthcare sectors wrongly diagnosed 14 of the total of 107 patients (13%).

Recognition of the condition is complicated by an increase in positional plagiocephaly (current prevalence 20% to 48%) since the early 1990s when supine sleep position was recommended to prevent cot death.^{2,4–6} The increase in positional head deformities carries the risk of missing the diagnosis of craniosynostosis in more patients.

A craniosynostosis or positional skull deformity is primarily recognized by physical examination, notably skull shape^{4,6} in combination with history taking,^{3,5} and an imaging study is rarely indicated.⁶ Both history taking and physical examination are well possible in the primary and secondary healthcare sectors. This deserves great attention because early recognition and surgical correction are essential to a satisfactory treatment outcome.⁶ Pediatrician and infant health clinic carry the main responsibility to recognize skull deformities. Ridgeway recommends a number of

diagnostic steps that should lead to early diagnosis, in which history taking and physical examination yield the most important information to distinguish between positional head shape deformities and craniosynostosis.⁵

Using this information in a flowchart at intake appears to be a safe method to make this distinction at the earliest. This will prevent delay in start of treatment as a possible consequence of the increase of patients of positional head shape deformities.³ This flowchart has been validated only in a tertiary center. There are no other publications on referral patterns in children with abnormal skull shape.

History Taking

History taking should address the distinction between positional head shape deformities and craniosynostosis on the one hand, and risk factors and associated anomalies on the other hand.

Craniosynostosis is present at birth, positional head shape deformities usually not.^{3–6} Improvement of abnormal head shape is seen in positional head shape deformities, but not in craniosynostosis. Presence or absence of a preferred sleep position is essential in the diagnostics of positional head shape deformities.^{3–6}

Analysis of a flowchart to differentiate positional head shape deformity versus craniosynostosis by means of a questionnaire (completed by telephone or e-mail) showed that the questionnaire recognized no more than 61.5% of the positional head shape deformities. Nurse practitioner contacts increased this percentage to 75%. A craniosynostosis was never missed (false-positive = 0%, which implies high sensitivity).³ In that study, the essential questions were:

- Is deformity present at birth?
- Is there a preferred sleep position?
- Is there improvement of the deformity?

The following risk factors for craniosynostosis are described: smoking habit, mother's antenatal stay at high altitude, paternal occupation,^{6–8} maternal alcohol use,^{7,8} maternal substance use,⁸ vitamin D deficiency or receptor insensitivity, chronic renal failure, hypophosphatemia, hyperthyroidism, mucopolysaccharidosis,^{5,9} and maternal drug use: phenytoin, retinoids, valproate, aminopterin/methotrexate, fluconazole, cyclophosphamide, folic acid nitrosates, thyroid gland medication, and vitamins.^{5,7,10,11} Also a high age of father and mother increases the risk of craniosynostosis.^{7,12}

Physical Examination of Skull and Face

More in detail the different craniosynostoses can be recognized as follows:

Sagittal synostosis:	frontal bossing, prominent occiput, bone ridge palpable on sagittal suture, decreased biparietal diameter, long and narrow head, tapering from parietal to sagittal suture, with usually a head circumference >2 SD. ^{1,5,6,8}
Metopic synostosis:	wedge-shaped forehead, including cranial part of the orbits, ridge on metopic suture, and hypotelorism. ^{5,12}
Unicoronal synostosis:	flattened forehead at afflicted side, including flattening of cranial part of the orbits, flattened cheek, nose deviation to unaffected side, orbital dystopia with higher position of the ipsilateral orbital rim, and bossing of contralateral side of forehead. ⁵
Lambdoid synostosis:	unilateral occipital flattening, depression of lambdoid suture ridge, low-positioned ipsilateral ear and back of the skull base. ⁵
Bicoronal synostosis:	broad head, flattened forehead and supraorbital rim. ⁵

Additional characteristics of skull and face are the following:

The anterior fontanel shows earlier fusion or is triangular shaped rather than diamond shaped in synostosis of 1 adjacent

suture.⁶ In Apert syndrome, there is even a large midline defect initially.¹³

Mid-face hypoplasia, proptosis, and hypertelorism are found particularly in the syndromic types of craniosynostosis.^{5,8,13} These and other syndrome-specific facial features are discussed in the genetics section of this chapter, including additional deformities of the extremities in particular.

The following characteristics may help to distinguish craniosynostosis from positional head shape deformities:

Positional plagiocephaly, such as a “parallelogram” seen from above, that is, ipsilateral occipital flattening, curved forehead, and ear more anterior ipsilateral.^{4,5} This in contrast with the “trapezium” shape in unilateral coronal suture synostosis, that is, ipsilateral flattening of the forehead and cranial part of orbit and occiput.^{5,6}

American Cleft Palate-Craniofacial Association (ACPA) recommends that craniofacial teams provide education to health professionals in obstetrics and neonatology as well as GPs and infant health clinic physicians so as to improve early recognition of children with craniofacial deformities.⁹

Grol emphasizes that effective implementation of guidelines requires behavioral changes in physicians.¹⁴ Interactive instruction methods via CD-rom and information-sites on Internet seem very effective. E-mail consultations improve the quality of decision-making, notably as they are easily accessible.¹⁵ Intensive instruction to small groups of physicians and peer review appeared little effective, however, in improving quality of care.¹⁶ Medical audits in the GP practice seems promising for quality of care improvement, but should be further developed.¹⁷ Availability of a good computer-aided medical information system is very important to recognize clinical pictures. Audit programs are most effective when integrated with other educational and research programs.¹⁸

Conclusions

- Level 3** Triage (with the use of a flow diagram) at intake of children with abnormal skull shape is likely to be effective to recognize craniosynostosis and to timely refer the children to the appropriate specialist.
B Bredero-Boelhouwer, 2009³
- Level 3** Craniosynostosis is often hardly recognized and recognition is even more complicated by the increase in positional skull deformities since supine sleep position was recommended to prevent cot death in the early 1990s.
C Komotar, 2006⁶
C Parameters ACPA, 2007⁹
C Ridgeway, 2004⁵
C White, 2010²
- Level 3** Craniosynostosis can be distinguished from NSOP on the basis of medical history and physical examination.
B Bredero-Boelhouwer, 2009³
C Komotar, 2006⁶
C Ridgeway, 2009⁵
- Level 3** Easily accessible (computer assisted) information in the primary and secondary health care sectors on history taking, physical examination, and use of decision tree improves quality of care.
C Grol, 2000¹⁴
C Smeele, 1999¹⁶
C Grol, 1995¹⁷
C van der Weijden, 1996¹⁵
C Grol, 1985¹⁸

Considerations

Often it takes long before parents and the child with craniosynostosis are referred to the tertiary center, which may lead to treatment delay and confusion, and consequently a great deal of parental stress.

The flow diagram to discriminate between positional skull deformities and craniosynostosis was validated in a tertiary care setting, where it was applied by secretaries who were not specifically trained in distinguishing between these 2 conditions. Consequently, we do not expect great differences in its reliability when applied in primary and secondary care settings. Ideally, validation for primary and secondary care settings finds place in these settings, but this does not seem to be practically feasible in view of the very low frequency of craniosynostosis compared with positional skull deformities.

Additional imaging studies to differentiate between positional skull deformities and craniosynostosis are rarely performed in tertiary centers. On clinical diagnosis of a positional skull deformity, skull x-ray or ultrasound are advised against to prevent unnecessary medical imaging (with associated costs, radiation exposure, burden for patient and parents, lack of added value, and required experience in interpretation). Consultation with a tertiary craniofacial center is indicated in suspected patients, for which submitting normal pictures (front view, lateral view, anterior view, and view from above) will usually suffice.

Recommendations

The following measures are essential to optimize recognition of craniosynostosis in the primary and secondary care sectors:

1. Ensure that easily accessible, reliable, and unambiguous information is available about skull deformities, either as appendix to this guideline, or via separate guidelines; preferably with many illustrations, clear terminology/definitions and addresses.
2. Ensure that the flow diagram (Appendix II) is used.³
3. Provide structured education and training instruction to infant health center physicians, GPs, midwives and obstetricians about over skull deformities via centers of expertise with an initiating role for the tertiary centers.
4. Provide feedback about the referral pattern on the basis of an analysis of national registry data (focus on patient's age at referral to tertiary center).

The craniosynostosis centers should develop a website with relevant information for the primary and secondary healthcare sectors, providing an e-mail address for online consultations. They should stimulate inclusion of the decision tree in the ICT-systems used by GPs and infant health center physicians, as well as in training programs for GPs, infant health center physicians, midwives, pediatricians and gynecologists. An interactive CD on history taking and physical examination in skull deformities is being prepared.

Collaboration with specialized centers for diagnostics and treatment of positional skull deformities will facilitate knowledge transfer.

Basic Question 2: How to Achieve Effective Referral?

With the exception of the study by Bredero-Boelhouwer there is no literature available about the referral pattern in the Netherlands.³ From the focus group sessions it became also clear that parents

highly appreciate quick referral to a specialized center (see chapter on focus groups).

Early recognition is important; delayed referral is associated with a risk of medical complications and less satisfactory operation results.¹ This article describes 47 referrals of scaphocephaly patients to the Birmingham craniofacial center during 3 years' time. The pediatrician was the first to recognize the condition in 64% of patients, the GP in 11%, and the parents in 25%. Timely referral to a specialized center is recommended to prevent use of inappropriate diagnostic procedures and resources.

Another study from the same center showed a shift in the years 2007 to 2008 as compared with 2003 to 2004: referrals from pediatricians dropped from 67% to 55%; referrals from GPs increased from 8% to 15%; referrals from specialists increased from 25% to 30%.² The deformity is recognized at birth in one-third of patients, at median age 0.5 months, mean 3.1 months, range 0 to 24 months, while the referral is at a later stage: pediatricians refer earlier (mean 8 months, median 3 months, range 0.25–78 months), the GPs and parents later (mean 24 months, median 16.5 months, range 2–36 months).¹ Delay is often because of the pediatrician's or GP's expectation that the condition will revert to normal.¹

Furthermore, diagnostics by pediatricians and GPs (eg, computerized tomographic (CT)-scan) delays referral, and it is recommended, therefore, to refer the child immediately without further diagnostics.¹ Pediatricians are expected to be able to recognize skull deformities and to diagnose them as either craniosynostosis or a positional skull deformity.⁵ A child with craniosynostosis should be referred to a craniofacial center,^{4,5} but this is not necessary for a child with a positional skull deformity.⁵

In the Netherlands, 9 specialized centers offer diagnostics for acquired skull deformities and helmet therapy, and they closely collaborate to achieve early recognition and referral of patients with craniosynostosis.⁴

The formal institution of craniofacial centers (4 centers to 56 million people in the United Kingdom) leads to concentration of craniofacial care.²

Conclusions

Level 3 Early recognition and referral of patients with craniosynostosis is important to prevent treatment delay and complications.

C Chatterjee, 2009¹

C Ridgeway, 2004⁵

C White, 2009²

Level 3 Additional diagnostic imaging by pediatrician or GP delays referral and is therefore advised against.

C Chatterjee, 2009¹

C White, 2009²

Considerations

The focus group has made clear that the period between first contact with a physician and the eventual referral to the craniofacial center is too long. This is in part because of delayed referral from the primary care setting to a pediatrician, but the workgroup is of the opinion that management by the pediatrician in the patient's own environment is of great value at this stage and in the subsequent stage. Still, rapid further referral should be guaranteed.

Consultation with a tertiary craniofacial center is indicated in suspected patients, for which submitting normal pictures (front view, lateral view, anterior view, and view from above) will usually suffice

Recommendations

When an abnormal skull shape is noted the primary care sector should refer the child to pediatrician, without additional

diagnostics. At suspicion of craniosynostosis, this is done without delay.

The pediatrician is the designated professional for initial management in the secondary health care sector and to further explore the options. The anamnestic flowchart of Bredero serves as a guideline to distinguish craniosynostosis from positional skull deformities. The pediatrician refers the child to a tertiary center.

Diagnostic imaging in the primary and secondary care sectors is advised against, unless performing skull x-rays has been approved by the craniofacial center and provided this does not lead to delay in referral. At suspicion of craniosynostosis this will be done at the shortest possible term.

Basic Question 3: What Additional Diagnostic Methods (Imaging and Genetic) Are Used in the Tertiary Center?

Diagnostic Imaging

X-ray of the skull (a-p, lateral, Towne of Tschell) is considered the first radiologic diagnostic test for craniosynostosis.^{1,2,4-6,9,19-21}

A CT of the skull is always performed on suspicion of craniosynostosis.^{1,6,7,11,13,22-24}

Magnetic resonance imaging (MRI) is performed on indication in syndromic craniosynostosis (see chapters on ICP, hydrocephalus, and Chiari I malformation).

A three-dimensional CT scan will reliably diagnose craniosynostosis.^{19-21,25} X-skull is reliable as well, but less reliable than three-dimensional CT scan.¹⁹⁻²¹ For both methods, experience in imaging and evaluation provides for greater reliability.²¹ From a cost-effective analysis, Medina concludes that radiologic screening for craniosynostosis in all children (low risk of craniosynostosis) is not justified. In children with skull deformities (moderate risk of craniosynostosis), an X-skull is indicated first, followed by a three-dimensional CT scan if the X-skull raises suspicion of craniosynostosis. On clear clinical suspicion of craniosynostosis (high-risk craniosynostosis), an immediate three-dimensional CT scan is indicated, without an X-skull.²¹ Cerovac concludes from a retrospective study involving 109 single-suture craniosynostoses, that an experienced clinician can make a clinical diagnosis with 100% certainty.²⁰ X-skull should confirm the diagnosis, even though this is less reliable (91%). Three-dimensional CT scanning should be reserved for suspected patients or for surgery planning.²⁰

It appeared that ultrasound could well visualize a craniosynostosis in 26 children with craniosynostosis aged from 2 to 7 months and in 23 of the 24 children with craniosynostosis aged from 1 to 11 months.^{26,27} Echography could therefore well serve as an alternative to imaging.

Conclusions

Level 3 X-skull is considered the first radiologic diagnostic test for craniosynostosis

C Komotar, 2006⁶

C Ridgeway, 2009⁵

C White, 2009²

C Parameters ACPA, 2007⁷

C Gellad, 1985¹⁹

C Cerovac, 2002²⁰

C Medina, 2002²¹

Level 3 (three-dimensional) CT is always performed on suspicion of craniosynostosis

C Chatterjee, 2009¹

C Cohen, 1993¹³
 C Komotar, 2006⁶
 C Bruce, 1996²²
 C Mathijssen, 2007²⁴
 C Parameters ACPA, 2007⁷
 C Strauss, 1998²³
 C Medina, 2002²¹
 C Regelsberger, 2006²⁶
 C Simanovski, 2009²⁷

Level 3

Ultrasound is an alternative to imaging as first diagnostic test for craniosynostosis

Considerations

The clinical diagnosis of craniosynostosis by means of physical examination forms the basis. Even though an X-skull is not always reliable, notably at very young age (several months old), as first further diagnostic test, it provides much information and can exclude craniosynostosis if all cranial sutures are clearly open. It is essential, however, that it is performed and evaluated by experienced clinicians. A three-dimensional CT scan images a craniosynostosis in a reliable way and is the most reliable objective diagnostic method. A standardly performed three-dimensional CT scan to objectivize the deformity is highly recommended for operative planning

Recommendations

X-skull (a-p, lateral, Towne for back of the head, Tschebul for forehead) is always performed in (suspected) craniosynostosis. If unclear, because of very young age of the patient, it is recommended to repeat X-skull after 1 or 2 months.

If X-skull confirms, or does not exclude, a synostosis, a CT-scan with three-dimensional-reconstruction is performed.

In case of very strong suspicion of craniosynostosis, the X-skull is skipped and a CT-scan with three-dimensional reconstruction is performed without delay.

Ultrasound of the cranial sutures can be performed as an alternative to X-skull.

Genetic Diagnostics

Etiologic diagnostics and genetic counseling is the task of the clinical geneticist. An etiologic or classifying diagnosis allows for making a prognosis (not so much regarding the craniosynostosis, but rather regarding the child's general and psychomotor development and possible associated anomalies). An etiologic diagnosis also provides for determining the risk of recurrence as well as the alternative choices in new pregnancies, such as prenatal diagnostics.

Craniosynostosis is a birth defect that can present both in isolated form and syndromic form. If next to the craniosynostosis congenital anomalies are present (either major anomalies or minor anomalies/dysmorphias), this is referred to as syndromic craniosynostosis. In line with the international literature, we distinguish between nonsyndromic and syndromic craniosynostosis.

Dysmorphologic examination may distinguish between nonsyndromic and syndromic patients on the basis of the presence of dysmorphic characteristics. In addition, several bodily measurements are made and compared with reference values. On indication, dysmorphologic examination (of the whole patient) is repeated. Possible indications are the development of new physical problems and newly observed delay in development in the course of time.

The January 2009 issue of the American Journal of Medical Genetics Part A is fully devoted to dysmorphologic examination of the face and extremities.

The adequate performance and interpreting of dysmorphologic examination is one of the specific medical competencies of a clinical geneticist.

Summary of the Literature

The craniofacial unit of Hôpital Necker des Enfants Malades is "the" referral center for craniosynostosis in France. Data of patients referred from 1985 through 1989 and of patients referred from 2003 through 2007 were compared on relative incidence of occurrence of the various types of craniosynostoses.²⁸ The first group included 472 patients, the second group 814 patients (in total 1286 patients) (Table 3).

The total number of patients increased 1.7-fold. The ratio nonsyndromic versus syndromic remained almost similar. In approximately 2 of every 15 children the craniosynostosis is of the syndromic type, in 1 in every 8 of them other than Apert, Crouzon or Saethre-Chotzen syndrome.

The article does not make clear how syndromic and nonsyndromic craniosynostosis were distinguished.

The associated anomalies in the syndromic types of craniosynostosis notably were anomalies of the face and of the extremities.^{29,30}

Table 4 shows the major features of the 7 most frequent syndromes.

The London Dysmorphology Database (version 1.0.12) includes 192 syndromes of which 1 of the characteristics is craniosynostosis. In a part of the syndromes, the craniosynostosis is a major characteristic, in another part the craniosynostosis is an "occasional abnormality."

More than half of the 192 syndromes follow a Mendelian inheritance pattern; some are the result of teratogens (including vitamin A and valproate). Chromosomal disorders are seen in a proportion of patients with a craniosynostosis (including 9p-, 11q-).

Frias and Carey reviewed 4 population studies that established relations between the occurrence of minor anomalies and the risk of a major anomaly.³¹ Although these 4 studies differed in their methods, they all demonstrate a clear relation between number of minor anomalies and the risk of a major anomaly. In the different studies, having 3 or more minor anomalies was associated with a 19.6%, 26%, 31%, 90% risk, respectively, of a major anomaly.

Scaphocephaly

From the same center in Paris, Lajeunie in 1996 published a series of 561 patients with a nonsyndromic scaphocephaly (of a total of 1408 craniosynostosis-patients admitted between 1976 and 1994).³² The man:woman ratio was 3.5:1. In 6% of the patients, a positive family history was documented.

This article does not provide the number of syndromic scaphocephaly patients.

Also the remaining literature does not provide information on the ratio between nonsyndromic versus syndromic scaphocephaly. Lajeunie³³ reports that most patients of scaphocephaly and trigonocephaly are nonsyndromic. A striking finding was 4.2% of the patients was one of the twins.

In 2002, Kan³⁴ described that in none of the 13 patients with scaphocephaly an *FGFR2* mutation was found in a comprehensive screening of the whole gene. Butzelaar³⁵ describes a pilot study in 30 consecutive patients with scaphocephaly, which retrospectively analyzed how many patients had consulted the Clinical Genetics department, what genetic tests were used, and what the test results were. In addition, the parents were sent a questionnaire on risk factors. Maternal alcohol use and smoking habit did not differ from

TABLE 3. Data of Patients Referred From 1985 Through 1989 and of Patients Referred From 2003 Through 2007 to the Craniofacial Unit of Hôpital Necker des Enfants Malades, Paris

Number of Patients	1985–1989		2002–2007		total	
	472	%	814	%	1286	%
Scaphocephaly	214		369		583	
Trigonocephaly	49		193		242	
Plagiocephaly	59		81		140	
Brachycephaly	20		31		51	
Oxycephaly	33		10		43	
other nonsyndromic	29		27		56	
Total nonsyndromic	404	85.6	711	87.3	1115	86.7
Apert	14		22		36	
Crouzon/Pfeiffer	30/7		28/20		58/27	
Saethre Chotzen	10		18		28	
Other syndromic	7		15		22	
Total syndromic	68	14.4	103	12.7	171	13.3

those in the general population. Prematurity was more often seen in the study group than in the general population.

None of the 30 included patients had craniofacial dysmorphias. In 4 of the 30 patients another anomaly was diagnosed (nevroid basal cell carcinoma syndrome, defects of the cardiovascular system and of the urinary tract. DNA testing was performed in 8 patients, in 1 of whom a *FGFR2* mutation was found.

Zeiger³⁶ investigated genetic and environmental factors associated with a higher risk of scaphocephaly in a group of 42 children from craniofacial clinics in the Baltimore-Washington area. In 24 of the 36 Caucasian children, DNA-testing was performed of specific exons of the *FGFR1*, 2, and 3 genes and of exon 1 of the *TWIST* gene. Pathogenic mutations were not found.

McGillivray³⁷ identified an *FGFR2*-mutation in a patient with familial scaphocephaly. Seto (2007)³⁸ identified a *TWIST* box mutation in a patient with a sagittal suture synostosis. The same

mutation occurred in the patient's nonaffected father. The significance of this mutation is not clear.

Trigonocephaly

Of a series of 1713 patients admitted between 1976 and 1996 in Paris, Lajeunie published an analysis of 237 patients with a trigonocephaly.³⁹ The nonsyndromic type occurred in 184 of the 237 patients (77.6%). Fifty-three (22.4%) of the patients had 1 or more other malformations next to the trigonocephaly. Thirteen of these 53 had a known syndrome; the diagnosis in the other 40 patients was unknown.

Also in the group of trigonocephaly patients the man:woman ratio was skewed, that is, 3.3: 1. The proportion of patients with a positive family history was 5.6%. The proportion of twins in this series was 3 times higher than in the general population, and was higher than in the group of patients with a scaphocephaly (6.8% versus 4.2%).³³

TABLE 4. The Major Features of the Most Common Craniosynostosis Syndromes

	Apert	Crouzon	Pfeiffer	Muenke	Saethre-Chotzen	Carpenter	Craniofrontonasal dysplasia
Synostosis coronal suture	+	+	+	+	+	+	+
Proptosis		+	+				
Ptosis			+		+		
Hypertelorism	+	+		+	+		+
Cleft palate	+						
Deformity of the auricles					Small auricles with prominent auricular crura		
Deformity of the hand	Complete syndactyly of dig 2–3–4, sometimes with 5 and or 1		Broad thumbs	Partial cutaneous syndactyly dig 2–3	Partial cutaneous syndactyly dig 2–3	Brachydactyly, clinodactyly, partial syndactyly, camptodactyly	Longitudinal grooves of the nails
Deformity of the foot	Complete syndactyly of all toes		Broad great toes; Partial cutaneous syndactyly dig 2–3–4		Broad great toe in hallux valgus; Mild brachydactyly; Partial cutaneous syndactyly dig 3–4	Duplicated great toe	Broad great toe; Longitudinal grooves of the nails
Malformations of the internal organs	10% congenital heart defect; 10% urogenital malformation					50% congenital heart defect, urogenital malformation (hypogenitalism)	

Azimi⁴⁰ investigated 25 patients with trigonocephaly (diagnosed between 1996 and 2001). In 16 patients it was an isolated anomaly, 2 patients in addition had a craniosynostosis of the sagittal suture without associated anomalies. The trigonocephaly was part of a syndrome in 7 patients (28%), in 2 of whom a chromosome abnormality was detected and Jacobsen syndrome could be diagnosed. Regarding the other 5 patients, in 1 the diagnosis of Say-Meyer trigonocephaly was made, in 1 I-cell disease and in another one Opitz-C syndrome. A diagnosis could not be made in 2 patients. In 2 of the syndromic patients *FGFR2* and *FGFR3* analysis was performed, which yielded no abnormalities.

In 1 of 9 patients with a seemingly nonsyndromic trigonocephaly a mutation in the *FGFR2* gene was found.⁴¹ This patient later developed features characteristic of the Crouzon-syndrome and the diagnosis was revised. Kress⁴² found a *FGFR1* mutation in 1 of 10 nonsyndromic trigonocephaly patients, who had or did not develop other dysmorphias. In 2002, Kan³⁴ reported that in none of 17 patients with trigonocephaly a *FGFR2* mutation was found in a comprehensive screening of the whole gene.³⁴ Jehee⁴³ analyzed the frequencies of occurrence of micro deletions of chromosome 9p and chromosome 11q in a cohort of 76 nonconsanguineous trigonocephaly patients (44 from Sao Paulo, 15 from Oxford, and 20 from Baltimore). The patients were classified into groups, a group of 40 patients with an isolated trigonocephaly and a group of 36 patients with associated abnormalities. A striking finding was that the condition was nonsyndromic in 71% of the English/American patients, but was syndromic in 63% of the Brazilian patients.

In the nonsyndromic group no 9p- or 11q-deletions were found.

In 7 of the 36 syndromic trigonocephaly patients a 9p- or 11q-deletion was found. Four of these deletions were not detectable with conventional cytogenetic analysis.

In a case-report, Van der Meulen (2006)⁴⁴ describes a trigonocephaly in a patient with Muenke syndrome.

Plagiocephaly, Brachycephaly, Oxycephaly

In these types of craniosynostosis the coronal suture is involved; unilaterally in plagiocephaly, bilaterally in brachycephaly and oxycephaly. In oxycephaly there is also a craniosynostosis of the sagittal suture.

Mulliken⁴⁵ performed molecular diagnostics in patients with a bilateral coronal suture synostosis, of whom 38 had been diagnosed with Apert, Crouzon, or Pfeiffer syndrome and 19 had no specific diagnosis. In all 38 syndromic patients, a mutation was identified in *FGFR2* (N = 33) or *FGFR3* (N = 5). In 14 of the other 19 patients a mutation was found, either in *FGFR2* (N = 4) or in *FGFR3* (N = 10).

In 2004, Mulliken⁴⁶ reported results of molecular genetic diagnostics in 47 patients with a unilateral coronal suture synostosis. This was a prospective study in children admitted between 1997 and 2000. Theman:woman ratio was 1:2. DNA testing of the *FGFR*-genes and the *TWIST* gene was performed in all 47 patients. In 8 patients a mutation was found in 1 of these genes (N = 3 in *FGFR3*, N = 2 in *FGFR2*, and N = 3 in *TWIST*). One patient was clinically diagnosed with craniofrontonasal dysplasia. The 47 patients were physically examined on inner canthal distance (ICD), among other things; ICD > 2SD was defined as hypertelorism. Also the parents of the children were examined. Of the 47 children, 13 showed hypertelorism or had a parent with characteristics of craniosynostosis. All above anomalies were found in these 13 children. In the children with a unilateral coronal suture synostosis in whom no hypertelorism was established, no mutation in *FGFR1*, 2, 3, or *TWIST* was found.

The known craniosynostosis syndromes, Apert syndrome, Crouzon syndrome, Pfeiffer syndrome, Muenke syndrome, Saethre-Chatzen syndrome, Carpenter syndrome, and craniofrontonasal

TABLE 5. Genes Involved in Syndromic Craniosynostosis

Clinical diagnosis	Genes to be Investigated
Apert	<i>FGFR2</i>
Crouzon	<i>FGFR2</i>
Crouzon with acanthosis nigricans	<i>FGFR3</i>
Pfeiffer	<i>FGFR2 (FGFR1)</i>
Carpenter	<i>RAB23</i>
Muenke	<i>FGFR3 (TWIST1)</i>
Saethre-Chatzen	<i>TWIST1 (FGFR3)</i>
Craniofrontonasal dysplasia	<i>EFNB1</i>

dysplasia (CFND), are characterized by craniosynostosis of one or both coronal sutures next to other birth defects. A proportion of patients with these syndromes show pathogenic mutations of known genes (Table 5).⁴⁷⁻⁵¹

In a comprehensive screening of the *FGFR2* gene in patients who were proven negative for a mutation in *FGFR1* or 3 or *TWIST*, the large majority of mutations were located on exon IIIa or IIIc. In addition, mutations were found in 7 new exons.³⁴

In patients with a syndromic craniosynostosis, genetic diagnostics is performed on the guidance of the syndrome diagnosis. Mutations are most frequent in *FGFR2*, followed by *FGFR3* and *TWIST*, and least frequent in *FGFR1* and *EFNB1*.^{52,53}

In Rotterdam, DNA testing of the *FGFR1*, 2, 3, and *TWIST* genes was performed during several years in all patients with a craniosynostosis, except those with an isolated scaphocephaly. *FGFR1* mutations were not identified.⁵⁴ Routine screening of the *FGFR1* gene does not seem to be useful, therefore, and should be performed only in patients with a specific phenotype.

Morriss-Kay⁵³ reported a prospective study in 214 patients born between 1993 and 2005. Analysis of *FGFR1*, *FGFR2*, *FGFR3*, *TWIST1* and *EFNB1* was performed as well as cytogenetic analysis. In 60 of the 214 patients a specific molecular diagnosis was made; in 4 patients this was a chromosomal abnormality, in 56 patients a mutation in *FGFR2*, *FGFR3*, *TWIST*, or *EFNB1*. The patients with the *FGFR2*, *FGFR3* and *TWIST1* mutations all had a craniosynostosis of 1 or both coronal sutures

Wilkie⁵² tested 217 patients in a diagnostic setting as from 2002. Submitting material of patients with a nonsyndromic scaphocephaly or trigonocephaly was strongly discouraged. In 59 of the 217 patients a pathogenic mutation was found, in 55 patients in *FGFR2*, *FGFR3*, or *TWIST*.

In 80% of the patients with a clinical diagnosis of Crouzon or Pfeiffer syndrome this diagnosis is confirmed by molecular testing.⁵⁴ Clinically diagnosed Apert syndrome is confirmed by molecular testing in almost all patients. Two specific mutations in *FGFR2* were found in approximately 98% of patients with Apert syndrome.⁵² In more than 80% of a group of patients with the phenotype of Saethre-Chatzen syndrome a mutation was found in the *FGFR3* or the *TWIST* gene.⁵⁵

If conventional molecular genetic diagnostics does not reveal mutations in one of the known craniosynostosis genes, additional diagnostics is warranted in patient of syndromic craniosynostosis. Genetics diagnostics was performed with different techniques in the screening of 45 patients with a syndromic craniosynostosis without known mutation.⁵⁶ New causal abnormalities were found in 19 patients.

Conclusions

Level 1 It has been demonstrated that the Apert, Crouzon, and Pfeiffer syndromes are caused by mutations in the *FGFR2* gen, except in Crouzon patients with acanthosis nigricans (*FGFR3* mutation)

- A2 Oldridge, 1997⁵⁷
A2 Meyers, 1995⁵⁸
- Level 1** It has been demonstrated that the Saethre-Chotzen syndrome is caused by mutations and deletions in the *TWIST1* gene
A2 Johnson, 1998⁵⁹
A2 Chun, 2002⁵⁵
- Level 1** It has been demonstrated that the Muenke syndrome is caused by the P250R mutation in *FGFR3*
A2 Muenke, 1997⁴⁹
A2 Chun, 2002⁵⁵
B Kress, 2006⁶⁰
B Mulliken, 1999⁴⁵
- Level 1** It has been demonstrated that craniofrontonasal dysplasia (CFND) is caused by mutations in het *EFNB1* gene
A2 Twigg, 2004⁵¹
A2 Wallis, 2008⁶¹
- Level 2** It is likely that almost no genetic abnormalities are found in nonsyndromic trigonocephaly and scaphocephaly. DNA testing is indicated in patients with other birth defects or dysmorphias next to the craniosynostosis of the sagittal suture or metopic suture or in case of a positive family history.
B Kan, 2002³⁴
B Wilkie, 2007⁵²
B Morriss-Kay, 2005⁵³
B Zeiger, 2002³⁶
C McGillivray, 2005³⁷
C Jehee, 2005⁴³
C Tartaglia, 1999⁴¹
C Kress, 2000⁴²
- Level 2** There are indications that *FGFR2*, *FGFR3* and *TWIST1* mutations are almost exclusively detected in patients with craniosynostosis of the coronal sutures.
B, Mulliken, 1999⁴⁵
B Morriss-Kay, 2005⁵³
B Wilkie, 2007⁵²
- Level 3** There are indications that in no more than 25% of patients with a craniosynostosis a specific molecular diagnosis could be made after analysis of the coding regions of *FGFR1*, *FGFR2*, *FGFR3*, *TWIST1*, and *EFNB1*
B Wilkie, 2007⁵²
B Morriss-Kay, 2005⁵³
- Level 3** There are indications that in familial scaphocephaly an *FGFR2* mutation can be found
C McGillivray, 2005³⁷
- Level 3** There are indications that in patients with syndromic trigonocephaly or complex nonclassifiable craniosynostosis additional diagnostics can lead to an etiologic diagnosis
C Shimojima, 2009⁶²
C Barbaro, 2009⁶³
C Jehee, 2005⁴³
- Level 3** There are indications that in a proportion of patients with unexplained syndromic craniosynostosis a cause can be established with the use of new molecular genetic techniques
C Jehee, 2008⁵⁶

Considerations

The Crouzon and Pfeiffer syndromes cannot be easily distinguished clinically and genetically, but such distinction is not relevant to choice of treatment. The first choice for the genetic diagnostics is analysis of the *FGFR2* gene.

Patients should be invited to contact the clinical geneticist again after reaching the age of 18 years to discuss the wish to have children and receive counseling if desired.

Recommendations

After referral of a child to a craniofacial team, the clinical geneticist of the team should be consulted. To distinguish between

nonsyndromic and syndromic craniosynostosis a clinical geneticist experienced in the fields of hereditary and congenital abnormalities/dysmorphias should perform a complete physical examination in each child. In addition, the family history regarding the occurrence of skull deformities and other birth defects should be documented.

If multiple dysmorphias/visible congenital abnormalities are observed, further diagnostics in the first weeks of life is indicated (including, among other things, cardiologic examination, renal ultrasound, and examination by pediatric neurologist).

Molecular genetic diagnostics is not offered in patients with nonsyndromic scaphocephaly and nonsyndromic trigonocephaly.

If these types of craniosynostosis occur in relatives, molecular genetic diagnostics is performed depending on the family history and preferably after consultation with a tertiary craniofacial center.

If a syndrome diagnosis has been made clinically, genetic diagnostics can be requested syndrome specifically:

Clinical diagnosis	Genes to be investigated
Apert	<i>FGFR2</i>
Crouzon	<i>FGFR2</i>
Crouzon with acanthosis nigricans	<i>FGFR3</i>
Pfeiffer	<i>FGFR2 (FGFR1)</i>
Carpenter	<i>RAB23</i>
Muenke	<i>FGFR3 (TWIST1)</i>
Saethre-Chotzen	<i>TWIST1 (FGFR3)</i>

More advanced diagnostics is indicated in the patient of a syndromic craniosynostosis without clinical diagnosis (= a non-classifiable craniosynostosis) or a clinical diagnosis that could not be confirmed genetically.

4. PERIOPERATIVE CARE

Basic Question

What organizational conditions should be minimally present for adequate and safe perioperative care for patients with a craniosynostosis?

Introduction

Correction of craniosynostosis in childhood can cause relatively much blood loss. The risk of blood loss is higher in older patients and in corrective surgery of syndromic craniosynostosis. Next to the surgical and anesthesiologic challenges, we should take into account that syndromic patients may be associated with comorbidity. This is why optimal organizational conditions should be in place, before, during, and after the intervention. This chapter deals with the specific risks involved in correction of nonsyndromic and syndromic craniosynostosis and recommendations are given to perform surgery as safely as possible.

Summary of the Literature

General

The “*Richtlijn Kwalificering Chirurgie bij Kinderen*” makes clear that the anesthesiologic goals in complex care such as craniofacial surgery can only be realized in specialized pediatric centers.⁶⁴

Preoperative Preparation

All members of the multidisciplinary team should be aware of possible comorbidity, that is, mostly in case of a syndromic craniosynostosis with compromised airway with or without OSAS. It is recommended to set the threshold for postponing the intervention low in case of a recent upper airway infection in

these patients (described in Apert syndrome by Elwood)⁶⁵ because airway infection is believed to be more strongly associated with complications.

One of the big problems (or complication) in the surgical correction of craniosynostosis is the occasional massive blood loss of 20% to 500% of the circulating volume, which may occur during the operation in a relatively short period and in patients with age-related circulating volume.⁶⁶

The following factors may predict large blood loss: syndromic craniosynostosis, pansynostosis, age <18 months, and duration of the procedure.⁶⁷

A number of methods have been proposed to reduce both the blood loss and the need of homologous (allogeneic) blood transfusion (in view of the risk of blood-transferable infection, immunologic reactions, coagulopathy, and transfusion-related acute lung injury (TRALI), but most studies are not randomized double blind and have a B-C Level. These methods can be classified into different categories and are applied pre-, per- or postoperatively. In the polyclinic (preoperative) period:

- Optimization of hematological conditions preoperatively, by administering erythropoietin (EPO) plus Fe supplement: A review concludes that multicenter studies are needed to determine the optimal dosing of EPO.⁶⁸ Different dosages have been described, that is, 600–200–100 U/kg once to thrice a week, but all during 3 weeks preceding the operation. Also the timing of administration, the optimal dosing of Fe, and cost-effectiveness must be determined. The use of EPO was also successfully combined with other methods in a number of B-C studies.^{69–73} A disadvantage of this method for the child is that blood must be drawn several times.
- Preoperative blood sampling for autologous transfusion during the operation: Opinions differ on this technique. It has been used as part of a “no allogeneic blood transfusion” protocol, but other authors think it is not indicated in these very young patients as only small volumes can be drawn. Furthermore, the procedure is not child friendly as the newborns and infants must be anesthetized.
- Preoperative selection of the extent of surgical procedure on the basis of age, accounting for the percentage of Hbf, which at 4 months has been decreased to 16% of total Hb.
- Preoperative surgical planning with the use of three-dimensional models seems to reduce operation time and thus also blood loss. Still, according to a C study, duration of the procedure is not decisive for the blood loss.⁷⁴
- Less invasive surgical procedures.^{75,76}

Immediately before surgery the presence of blood products and availability of a pediatric intensive care unit (PICU) bed for the postoperative period should be confirmed in case significant blood loss related to the child’s circulating capacity should occur. A clear plan must have been made anticipating problems with intubation. The use of pre- and postoperative checklists and the time-out procedure (TOP) before start of surgery importantly add to safety of the entire perioperative process.

Peroperative Management

Monitoring

Invasive monitoring is recommended in open procedures with expected severe blood loss. Invasive monitoring involves the use of a central venous line and an arterial line next to conventional monitoring (capnography, ECG, pulse oximeter, FiO₂, temperature, and urine output) and precordial Doppler. The major goals of invasive monitoring are timely recognition of serious problems that

may occur in open craniosynostosis surgery, such as hypohydration, hypotension, and electrolyte disturbances, as well as being able to check effectiveness of treatment of these problems.

Positioning

Venous cerebral congestion by hyperflexion of rotation of the head must be avoided.

Usually, the patient is placed in a moderate anti-Trendelenburg position to reduce blood loss (cave air embolism, see below under Complications). Notably, in children with exorbitism the eyes should be well protected with eye cream, and pressure on the eyes must be avoided (especially in prone position).

Single administration of an antibiotic, after the induction, before start of surgery is standard procedure.⁷⁶

Maintenance of Anesthesia

Most recommendations are aimed at a balanced technique that provides for cardiovascular stability with the use of opioids and volatile agents next to relaxants. The use of remifentanyl infusion (0.25–0.5 mcg/kg/min) is recommended as well.^{77–79} If remifentanyl is used for maintenance of anesthesia it is recommended to administer a bolus of morphine or piritramide before the end of the procedure so as to start postoperative pain management.

Measurement/Compensation Blood Loss Intraoperatively

An additional problem is that measurement of the lost volume intraoperatively is impeded by surgical technique and type of patient. Few studies have been performed to optimize blood loss measurement and findings are mostly not conclusive. Next to the above-mentioned preoperative approaches to reduce blood loss and/or to prevent allogeneic blood transfusion, several measures can be taken peroperatively:

- Infiltration of the skin with vasoconstrictors before the incision is much used but its effectiveness is disputed because of the greater degree of bleeding with treatment of the periostium and bone.
- Controlled hypotension is rarely used because it has no clear benefits and can be disadvantageous in case of ICP and also in the anti-Trendelenburg position.
- The acute normovolemic hemodilution (ANH) technique is used before the surgical intervention after the child is brought under anesthesia. It involves removal of whole blood via the arterial or central line which is replaced with colloids 1:1 or with crystalloids 1:3 according to precise calculations and formulas. Most healthy children tolerate a mild hemodilution (Htc 25%–30%). According to a B study, this technique in itself is not sufficient to reduce or avoid homologous blood transfusion in this type of surgery.⁸⁰
- Perioperative (intra- and postoperative) blood “recollection” is not routinely used in this type of surgery in view of the small collected volumes, the sometimes acute blood loss, and its cost-effectiveness. Fearon⁸¹ reported that 59 of 60 children needed a transfusion, of which only 30% received an allogeneic transfusion with the use of the cell-saver device. Duncan⁸² found no difference in allogeneic transfusion rate when a cell saver was used and when not. With the development of small reservoirs (50 ml) this method seems to be more promising and in C studies it has been associated with a considerable reduction of the homologous blood transfusion rate.
- Intraoperative antifibrinolytics.⁸³
- Aprotinin: is no longer used after serious complications in cardiac surgery. Tranexamic acid: its use in itself is controversial, but it has been applied in combination with other methods.

According to a comparative B study, none of these strategies to reduce bleeding and/or to prevent or reduce the use of homologous blood has shown sufficient effects.⁸⁰ A review by Di Rocco⁶⁸ confirms this conclusion. The transfusion strategies are usually based on intraoperative acceptance of Hb values approximately 7 g/dl (4 mmol/l) and Ht <30.⁸⁴

Guidelines for the application of blood products are in place in every hospital as established by the local transfusion committees, and in conformity with the *CBO Guideline Blood transfusion 2004*.⁸⁵ The latter guideline does not contain specific recommendations for very young children.

Complications

The best known complications are inherent to the surgical technique and/or a result of massive blood transfusion.

- Venous air embolism (VAE) and the subsequent cardiovascular collapse can be prevented by a precise technique and by rapid application of adequate monitoring (precordial Doppler, capnography, echocardiography, transcutaneous O₂-CO₂ monitoring, esophageal stethoscope, and venous central line). Although Faberowski⁸⁶ reports an incidence of 82.6% shown with Doppler in a small series of craniostomosis patients with a mean 90% blood loss, Tobias⁸⁷ describes an incidence of 8% with the use of Doppler in strip craniotomies. Meyer⁸⁸ reports a 2.6% incidence in children undergoing craniostomosis surgery who were monitored with end-tidal CO₂ only. The hemodynamic consequences of VAE are generally insubstantial, provided the patients are well monitored and measures are taken upon signs of VAE.
- As a result a massive blood loss the patient may develop relevant consumption coagulopathy and dilutional coagulopathy characterized, in principle, by depletion of soluble clotting factors.⁸³ As cryoprecipitate is not available everywhere and fresh frozen plasma (FFP) has limited effectiveness to compensate for fibrinogen deficiency, it is recommended at C level to timely use fibrinogen concentrate based on thromboelastography.⁸⁹ Temperature monitoring is crucial for the prevention and treatment of clotting disorders.
- Massive blood transfusion can result in development of TRALI.⁹⁰
- Airway management in syndromic children (Apert, Crouzon/Pfeiffer) is sometimes complicated by hypoplasia of the midface and exophthalmos that may impede hood ventilation, although direct laryngoscopy and intubation normally are possible. The situation changes when these children undergo a distraction osteotomy procedure and need to be intubated acutely in case of respiratory insufficiency, or when the distraction materials are being removed. Evidence from the C level studies is conflicting on this issue. One of the 2 studies recommends immediate fiberoptic intubation, whereas the other study claims that the distractors exert minimal effect in the anesthesiologic conditions when certain factors must be taken into account (the right screwdrivers and cutting pliers must always be available) and that removal of the vertical bar allows for direct laryngoscopy.⁹¹ Roche⁹² describes problems with intubation at the time when distractors are removed as a result of trismus that had not yet occurred when the distractors were placed.
- The possibility of cerebral salt wasting syndrome should be considered when a patient develops hyponatremia after craniostomosis surgery.⁹³ Then, a differential diagnosis with syndrome of inappropriate antidiuretic hormone secretion (SIADH) should be made right away as the treatment modalities for these 2 are quite different.

Criteria for extubation at the end of the procedure, before transport to the ICU, are the following: rapid recovery of spontaneous and stable breathing, hemodynamic stability, normothermia, short to medium operation time with relatively little blood loss, and no continuous large blood loss through the surgical drains.

Postoperative Management Pediatric Intensive Care Unit (PICU)

In principle all studies recommend ICU admission after open craniostomosis surgery to continue volume management there and, if necessary, start artificial respiration.

Bleeding may continue in the postoperative period via the drains, and the cardiovascular status next to Htc/Hb must be monitored carefully. Most studies on postoperative transfusion management report a tendency to overtransfusion.^{74,94}

Pain Treatment

There is scarce literature on postoperative pain treatment after craniostomosis surgery. In Rotterdam 2 double blind, placebo-controlled studies have investigated pain treatment in the first 24 hours after cranial correction for craniostomosis.^{95,96} Specific literature on pain treatment after facial surgery, such as Le Fort III or monobloc, is completely lacking.

Van der Marel⁹⁵ treated 20 children with oral paracetamol and 20 with rectal paracetamol. The pain scores in the oral group were higher, but this effect disappeared with exclusion of the patients who had vomited after oral administration. Despite the fact that 22.5% did not reach a 10 to 20 mg/L plasma level, the pain score exceeded 4 in fewer than 7.5%. Rectal administration of paracetamol was recommended.

Prins⁹⁶ describes 12 children who received intravenous paracetamol and 14 children who received rectal paracetamol. Effectiveness was assessed with the VAS score and COMFORT-B score. A statistically significant difference for the COMFORT-B score was found, to the effect that it was more often higher in the rectal paracetamol group. This is indicative of more discomfort, possibly caused by more pain, and intravenous administration was recommended.

In the European literature, the use of paracetamol and NSAIDs is recommended (if the blood loss is not significant) with or without codeine phosphate (British literature).

The American literature places a focus on treatment with morphine next to paracetamol and NSAIDs.

All textbooks emphasize, and this also appears from our own practice, is that the pain scores are surprisingly low.

In extubated patients oversedation must always be avoided.

In patients operated on for nonsyndromic craniostomosis, invasive monitoring can usually be discontinued the following day.

Conclusions

- | | |
|----------------|--|
| Level 1 | It has been demonstrated that postoperative pain in the first 24 hours can be adequately treated with administration of paracetamol.
<i>A2 Van der Marel, 2001⁹⁵</i>
<i>A2 Prins, 2008⁹⁶</i> |
| Level 2 | A number of preoperative measures (erythropoietin plus Fe, blood sampling for autologous transfusion) reduce both the blood loss and the need of blood transfusion.
<i>B Helfaer, 1998⁶⁹</i>
<i>A2 Fearon, 2002⁷²</i>
<i>B Meneghini, 2003⁷³</i> |
| Level 3 | It seems likely that craniofacial syndromes, pansynostosis, age <18 months and duration of the operation are predictors of massive blood loss.
<i>C Meyer, 1993⁹⁴</i>
<i>B White 2009⁶⁷</i> |

Level 3 None of the perioperative strategies (skin infiltration, anti-Trendelenburg position, hemodilution, and antifibrinolytics) to reduce bleeding and/or to avoid or diminish the use of homologous blood has shown satisfactory effects.

*B Hans, 2000*⁸⁰

*C Di Rocco, 2004*⁶⁸

Level 3 Overtransfusion in the postoperative course does regularly occur.

*C Kearney, 1989*⁷⁴

*C Meyer, 1993*⁹⁴

Considerations

Despite the proven effectiveness of erythropoietin and blood drawing for autologous transfusion, the use of these strategies is discouraged as they involve high costs and require repeated venipuncture, which is not child friendly.

Introduction of less invasive interventions is associated with less blood loss. As these, however, are very young children with a smaller circulating capacity, blood loss relatively is still significant. In selected cases admission to a medium care unit could be considered (defined as a monitored bed providing for artificial respiration).

Recommendations

The anesthesiologic goals in craniofacial surgery can only be realized in specialized pediatric centers, where multidisciplinary perioperative care is provided by a team composed of plastic surgeon, neurosurgeon, maxillofacial surgeon, pediatrician, pediatric anesthesiologist, pediatric intensivist, and specialized pediatric nurses with experience and means to manage and monitor this type of patients and where a sufficient number of children is operated on to keep the experience of the team at a high level.

Administration of EPO preceding the intervention, as well as collecting autologous blood for autotransfusion are advised against.

Postoperatively a bed in a PICU must be available. In less drastic interventions medium care may perhaps suffice, although 1 should be aware that these are mostly very young children with a smaller circulating capacity, in whom even slight postoperative blood loss must be monitored carefully.

Invasive monitoring is recommended in the case of open procedures with expected severe bleeding.

Overtransfusion in the postoperative phase should be prevented by adhering to the guideline on transfusion management.

Extubation at the end of the operation, before transport to the ICU, is possible in case of rapid recovery of spontaneous and stable breathing, hemodynamic stability, normothermia, short to medium operation time with relatively little blood loss, and no continuous large blood loss through the surgical drains.

The analgesic of choice for postoperative pain treatment is paracetamol. If this is not sufficient, an NSAID can be added even though this could increase the risk of postoperative bleeding.

5. SURGICAL TREATMENT OF NONSYNDROMIC CRANIOSYNOSTOSIS

Basic Questions

1. What are the indications for surgery in the different types of nonsyndromic craniosynostosis?
2. What treatment is most indicated for the different types of nonsyndromic craniosynostosis?
3. At what developmental stage is surgical treatment preferably performed?

Introduction

Nonsyndromic craniosynostosis can present in varying severity of the deformity of the skull. Surgical treatment seems indicated on the basis of:

1. the associated risk of ICP (see also chapter on ICP)
2. the prevention or restriction of associated neuropathology
3. the morphologic abnormality (with both esthetic and psychological consequences)

The variability in both the severity of the morphologic abnormality and in the occurrence of increased ICP may occasionally result in less strict operative indication on the basis of these parameters.

Many different surgical techniques have been described for the treatment of nonsyndromic craniosynostosis but the functional results of these techniques have not always been shown convincingly. In addition, the timing of surgery is debated.

For patients with a synostosis of multiple cranial sutures in whom a syndromic diagnosis cannot (yet) be made, the method of treatment of syndromic craniosynostosis is recommended. This chapter will place a focus on craniosynostosis of the sagittal suture (scaphocephaly), metopic suture (trigonocephaly), unilateral coronal suture (frontal plagiocephaly), and lambdoidal suture (pachycephaly).

Summary of the Literature

Indications for Surgery

The indications for treatment of craniosynostosis are the risk of ICP and the morphologic abnormality of the skull and face. As mentioned in chapter 8, the risk of increased ICP in scaphocephaly is 12%, in trigonocephaly 9%, and in plagiocephaly 10%. The estimated risk in bilateral coronal suture synostosis is 37%.

The chapter on cognition and behavior provides evidence of absence of a relation between cognitive functions in children with a nonsyndromic craniosynostosis and surgical treatment or not, severity of the deformity, or age at operation. The prevention or treatment of the associated neuropathology is therefore no indication for surgery.

The morphology can vary from very mild to an evidently abnormal skull shape.⁹⁷

In sagittal suture synostosis, compensatory growth of the other cranial sutures results in increasing deformity in the course of time, so that, for example, the frontal bossing in scaphocephaly can intensify after birth.^{98,99} Sagittal suture synostosis is characterized by highly variable expression, however, ranging from a ridge over the suture in combination with a slightly narrower skull to mid-parietal saddle-like bone formation with severe frontal bossing and a pointed and prominent back of the head.

Barritt¹⁰⁰ evaluated a series of 44 children with scaphocephaly, of whom 34 did not undergo surgery. This was common policy in this clinic at the time for children presenting with this condition at an age older than 6 months. In these 34 children, the deformity in any patient did not seem to improve in the first 10 years. In 14 children, the cranial index (CI) decreased ($69 > 65$), in 7 the CI increased ($64 > 68$) and in 7 it did not change.

The presentation of trigonocephaly also varies from very mild to severe. Its mildest form is characterized only by a bony ridge as a result of premature fusion of the metopic suture. In follow-up, cosmetic worsening is only rarely seen. The other end of the spectrum is characterized by a wedge-shaped forehead with hypotelorism and supraorbital retrusion on the basis of decreased growth of the forehead widthwise.¹⁰¹

Frontal plagiocephaly also shows some variation in phenotype, notably in facial asymmetry.¹⁰² In a study from Paris, 16% of the children who were operated on after the first year of life developed increased ICP (see chapter 8).¹⁰³

Unilateral synostosis of a lambdoidal suture causes increasing asymmetry of the back of the head and particularly also of the face. Increased ICP does not seem to be prominent in this type of synostosis, although reliable research on this issue is lacking (see chapter 8).

2. Surgical Treatment of Nonsyndromic Craniosynostosis

Since the first operative intervention for craniosynostosis, many surgical techniques for the various types of craniosynostosis have been described. A broad distinction is made between osteoclastic techniques and remodeling techniques. In the first group bone is removed, enabling the developing and expanding brain to change the shape of the skull, in part because the adverse impulse to the growth direction of the skull also is removed. From this technique evolved the remodeling techniques, because it was suspected that one cannot only rely on the self-correcting capability of the skull and the brain. These techniques are aimed at directly achieving the desired skull shape by a kind of reconstruction.

Randomized comparisons of the different surgical techniques have never been performed. For the different types of nonsyndromic craniosynostosis we will provide a review of the literature regarding the different techniques in these 2 groups, but also pay attention to the new developments in the past 10 years in a separate section.

2.1 Scaphocephaly

Strip Craniectomy

Ingraham¹⁰⁴ described a technique using bilateral parasagittal strip craniectomies, in which the fused suture was not resected. To prevent the problem of premature reossification of the skull bones he applied a layer of plastic to the bone rims. Successful treatment required early intervention, however, preferably in the first 2 months of life. The results of this technique were confirmed by other authors.^{105–107} Anderson and Geiger¹⁰⁵ attempted to prevent premature reossification with the use of chemical coagulation of the dura, but failed to demonstrate the advantages of this technique.

Albright¹⁰⁸ presented a sagittal strip craniectomy with biparietal wedge osteotomies. The same procedure was performed by Marucci¹⁰⁹ in 89 patients, but they noticed that 7 of the 89 patients later developed a cosmetically unsatisfactory vertex bulge, which they interpreted as a sign of possibly raised ICP or a new synostosis. Also Florisson¹¹⁰ reported that some patients with scaphocephaly again showed signs of raised ICP postoperatively.

A variant to this technique is wide resection of the sagittal suture (4 cm) in combination with a bone-strip resection along the coronal and lambdoid sutures, as described by Christophis.¹¹¹ The average CI improved from 66 to 76.

Amm¹¹² presented a technique, in which the usual 2.5 to 3 cm wide strip craniectomy of the sagittal suture, combined with lateral strip osteotomies, is expanded with weakening with a burr of the occipital bone, allowing the skull to hinge occipitally. They explicitly try to make use of gravital force by keeping the infant strictly in supine position during sleep for a period of 3 weeks. Using this technique an average improvement of the CI of 8.1 (4.8–16) points was achieved.

All in all, many of the described techniques represent only slight modifications of previously presented techniques and not real conceptual changes.

Postoperative infections are rare (0%).¹⁰⁸ Duration of hospitalization ranges from 1 to 6 days postoperatively.^{108,111,112} Here, too,

it appears that policy is guided by habituation in postoperative care rather than morbidity or impact of the operation.

Cranial Remodeling; the π Procedure Strips Are Resected

De π procedure is a technique in which strips are resected at either side of the synostotic sagittal suture bone, while in addition a bone strip is resected anteriorly to the coronal suture. The sagittal suture itself is not resected, and the temporoparietal bone is bent outwards. In this technique, the anteroposterior diameter of the skull is dynamically shortened by attaching the bone strip in the middle of the skull, which is shortened, to the frontal bone. Thus, it is in fact also a compression technique, which might be associated with an increase in ICP.

Gewalli¹¹³ with the use of a modified π procedure shortened the anteroposterior diameter in 26 children by a mean of 16 mm, and concluded from neuropsychologic assessment that this had not adversely affected mental development. Only a global development quotient, however, was tested in very young patients, without inclusion of a control group, which raises great doubt on the reliability of this finding.

In older children or in children with a more pronounced dysmorphism (notably frontal bossing), a more extensive calvarial reconstruction is needed, with resection and reconstruction of the frontobiparietal complex.¹¹⁴ Heller et al performed this intervention in 24 children with mean age 23 months (range 3 to 96 months) and thus achieved normal CI postoperatively in all children (mean 78 versus 68 preoperatively). The authors concluded that in this population this more extensive procedure had no adverse effect on postoperative growth rate of the skull or on intracranial volume.¹¹⁴

New Developments

Lauritzen¹¹⁵ reported in 2008 on the first 100 operations in which distraction was used to correct craniosynostosis. This method is eminently suitable for scaphocephaly in view of the unidirectional growth delay widthwise.

The results are not worse, but also not better than those of the current techniques and the small numbers preclude valid comparison. Also regarding the newer surgical techniques, randomized or comparative studies have not been published.

2.2 Trigenocephaly

Also in view of the complex three-dimensional dysmorphism seen in metopic synostosis, treatment by suturotomy solely is considered insufficient.^{116–120} In the past 30 years, therefore the emphasis was on reconstruction of the entire forehead, including the upper parts of the orbits.¹²¹ The question whether this should also include specific correction of the hypotelorism is subject of debate. Posnick¹²² analyzed the growth process on the basis of CT data in 10 patients and concluded that correction of the hypotelorism had remained insufficient. Selber¹²⁰ found that the use of interpositional bone grafts in a series of 68 metopic children led to a decrease in the development of temporal dents. In a population of 92 trigonocephaly children in which no bone graft was used, Van der Meulen,¹⁰¹ however, observed an automatic growth correction of the hypotelorism on x-ray, on account of which the use of an interpositional bone graft was judged to be unnecessary. From a photographic evaluation of 45 patients, Hilling¹²³ concluded that a satisfactory esthetic outcome on the long term was largely dependent on a good initial reconstruction.

2.3 Frontal Plagiocephaly

A distinction is made between unilateral and bilateral frontal advancement techniques. Some surgeons prefer the unilateral

advancement technique so as to be able use the unaffected side as a reference for the degree of advancement,¹²⁴ whereas others maintain that adequate advancement with good symmetry is only possible if the entire frontal bone and both orbital margins have been dissected.¹²¹

New Developments

Barone and Jimenez¹²⁵ report since the late 1990s on endoscopic strip craniectomy of the affected suture. The benefits mainly lie in low morbidity, short hospitalization, and little need of blood transfusions in comparison with the classic fronto-orbital advancement technique. The cosmetic outcome is reported as good, but it not adequately quantified.

Stelnicki¹²⁶ in the early years of this century started to use the strip craniectomy technique, but concluded that after endoscopic intervention often no full symmetry is reached and that the forehead unilaterally is still receding 3 or 4 mm. For this reason, the technique was adapted to an endoscopic unilateral fronto-orbital advancement technique. This was applied in 10 patients, who did not develop any complications, did not need blood transfusions, and could be discharged home after 2 days. The cosmetic outcome was assessed to be similar to that of fronto-orbital advancement.¹²⁶

2.4 Posterior Plagiocephaly

The number of publications on lambdoid suture synostosis is very limited, probably because of the very low prevalence. Unilateral lambdoid suture synostosis causes only relatively little volumetric restriction. The morphologic changes consist of an asymmetry of the face and an asymmetric basal occipital region.

New Techniques, Distraction

Kim¹²⁷ reports a study comparing distraction versus remodeling surgery. Among the patients were 3 children with brachycephaly treated with the distraction method and 4 with remodeling. The distraction method led to satisfactory calvarial expansion and an esthetically pleasing outcome. Advantages of distraction are the significantly shorter operation time, less bleeding, shorter stay at the neonatal intensive care unit (NICU), and better skull shape. A disadvantage of the distraction method is that children must have reached the age of 6 months.¹²⁸ Furthermore, a second operation is needed to remove the distraction materials, there is a risk of infection and dislocation of the material, and total hospitalization is relatively long. The authors are of the opinion that these downsides do not outweigh the benefits of distraction.

3. Evaluation of the Outcome of Surgery

Most children with a craniosynostosis are operated on in the first year of life. A direct evaluation of surgical outcomes is possible, but a final evaluation is not possible until the child has fully grown at adult age. As a surgeon's career spans perhaps 25 year, and at most 30 years, the surgeon can only at an advance career stage assess the result of his or her own work. Yet he or she will be able to see the definitive results of his/her predecessors. There may be a tendency to ascribe a poor result to a wrongly performed surgical technique, without questioning the technique itself. Furthermore, knowledge about the natural course of the condition with and without surgical intervention is usually lacking. This shortcoming undoubtedly is coresponsible for the fact that we see regular shifts in type of intervention in the course of decades and that paradigms change. One and the same research group may recommend a certain approach in the 1 decade and disassociate oneself from it in the next decade.¹²⁹

Only few solid objective results with such a long follow-up are available, whereas comparative studies of different surgical techniques (with or without randomization) have not at all been

performed. Moreover, notably the larger series yield mixed data, because all craniosynostoses, including the syndromic types, are pooled.

One way to assess the outcome of surgery is looking at the operative morbidity and mortality. Most series are too small, however, to yield significant data. Anyway, the mortality is very low for all procedures, from 0% to 1%.¹²⁹

Morbidity is reflected in the complications that may occur and length of hospitalization. Although the first is a relatively objective score, the second is certainly not. Length of hospitalization strongly depends on the treating physicians, but also on the healthcare system itself. To illustrate this, for similar procedures the average length of hospitalization in North America is significantly shorter than in Europe. The patients are simply discharged home earlier, which possibly is enabled by a better outpatient care system. Generally, hospitalization after minimally invasive interventions is 1 or 2 days; for more complex interventions 2 to 7 days.¹²⁹

As postoperative infections are very rare, only large series can yield significant data. In series of 248 patients who underwent surgery for unsutural craniosynostosis only 2 (0.4%) developed a postoperative infection.¹²⁹ In an older series of Whitaker the infection rate was 3.7% in 164 patients; however, a distinction between syndromic and nonsyndromic craniosynostosis was not made.¹³⁰ Still it seems that infections particularly occur in the syndromic patients.

Severe complications, such as brain lesions, also occur sporadically: 0% to 1%.¹²⁹ In a series of 107 patients, Sloan¹³¹ found a 3.7% complications rate, almost all of which were mild, and in a series of Whitaker the rate was 8%,¹³⁰ but this was largely on account of the syndromic craniosynostoses. In general, the complications rates in the nonsyndromic craniosynostoses are significantly lower than in the syndromic craniosynostoses, 3.5% and 39%, respectively, in the same series reported by Sloan.¹³¹ In nonsyndromic multisutural craniosynostoses the rate is higher than in monosutural craniosynostoses.¹³¹

The use of metal plates and screws has been customary in a certain period. Meanwhile, it has become evident that application of this material in young children may lead to intracranial translocation of the plates and screws, with the screw ends penetrating the dura.^{132–134} Risk factors for translocation seem to be longer plates, placement in the temporal region, young age, and syndromic craniosynostosis.¹³³ Hardly anything is known about the consequences of this complication. In the past few years, resorbable plates and screw devices have been applied for specific indications in craniosynostosis surgery. The reported rate of complications is low: infection 8/1883 patients¹³⁵ and 5/146 patients;¹³⁶ delayed foreign-body reaction in 12/1883 patients,¹³⁵ and postoperative resorbable device failure with loss of bony position in 5/1883 patients.¹³⁵

The outcome of surgery can also be expressed by need for secondary revision surgery. This is rarely needed. Fearon¹²⁹ reports 5 patients in 248 patients (2%) and Sloan¹³¹ reports a 7.2% rate of unscheduled reoperations in 250 patients.

Scaphocephaly

Amm¹¹² routinely uses three-dimensional surface analysis software to analyze CT-scans. Computerized tomography scanning, however, is a source of radiation exposure. Still it enables to assess the outcome in a relatively reliable and objective manner, and this yielded a mean 8.1 points improvement in CI.

Marucci¹⁰⁹ noticed a cosmetically unsatisfactory vertex bulge after minor surgery in 7 of 89 patients.

Trigonocephaly

At follow-up in the course of years after reconstruction of trigonocephaly, the lateral sides of the forehead often appear to

revert to a certain degree and temporal depressions may be seen, which however seldom are cosmetically unsatisfactory to the degree that revision surgery is justified.¹⁰¹

Hilling¹²³ evaluated the result of bifronto-orbital advancement in trigonocephaly from photographs of the patients pre- and post-operatively and after follow-up by a panel of independent assessors with the aid of a scoring form. They concluded that the cosmetic result generally was good to very good, but also that the severity of the deformity does not influence the eventual outcome. In addition, they established that the obtained result is stable during time and independent of the age at operation (6 to 15 months). Temporal depressions are ultimately the most frequent abnormalities at follow-up and cosmetically usually only little unfavorable.

Van der Meulen¹⁰¹ performed standard x-rays of the skull before and after operation and in the course of time and noted that although in fronto-orbital advancement, the hypotelorism had not been actively corrected, autocorrection still occurred during time.

Frontal Plagiocephaly

Assessment of the result of the various techniques applied in frontal plagiocephaly is highly subjective. Objective outcome measures are lacking and assessment therefore mainly consists of an evaluation of the achieved facial symmetry. In a series of 19 patients with longer follow-up, Anderson established that the result of identical procedures was highly variable, from moderate to very good, but that these results still were considered “acceptable”. Two of those patients underwent corrective ophthalmological surgery for strabismus as a result of a malformed orbit, whereas a third patient had rejected the same proposed intervention.¹²⁴ Although reasonably satisfied with the result, Anderson’s group still converted to bifrontal advancement in this abnormality.

The earlier mentioned panel assessment of photographs by Hilling¹²³ in trigonocephaly, was also applied by the same researchers in 59 patients with frontal plagiocephaly.¹⁰² The conclusions are more or less the same: the result is usually good, moreover stable during time, irrespective of the initial situation and irrespective of patient’s age at operation. Also in this deformity, the temporal depression is the most striking finding at follow-up.¹⁰² This raises the suspicion that occurrence of a temporal depression at the longer term after bifronto-orbital advancement is not so much a consequence of the primary condition but rather of the applied surgical technique. Direct evidence for this supposition, however, is lacking. For that matter, this research group also concludes that the frequency of temporal depressions decreases with increasing experience of the surgeon.

Sloan¹³¹ established that in almost 45% of the patients with a frontal plagiocephaly insufficient symmetry had been obtained after correction and thus an unsatisfactory outcome with the necessity of reoperation in 7% of patients.

Lo¹³⁷ specifically assessed the orbital morphology (both of bone and soft tissue) after surgical intervention and evaluated this by means of CT-scans. They noted that the orbital morphology had genuinely improved, but also that complete symmetry had not been obtained. Furthermore, outgrowth, however, was normalized.

3. Timing of Surgery

The timing of surgery differs worldwide and is dependent, among other things, on the surgical technique used.²⁴ An important factor is prevention of relapse. In patients with boat-shaped head, it was observed that the initially improved CI index had slightly decreased 1 year after correction, whereas in fronto-orbital advancements, the frontolateral skull will again slightly recede (a part reversal to the primary deformity). This in general does not cause cosmetic problems, the more so because some surgeons in

anticipation will apply overcorrection.¹²⁹ Some are inclined to wait until the age of 15 to 18 months for major, exclusively cosmetically correcting interventions, particularly because this delay is believed to lower the risk of relapse and thus the need of reoperation. Thompson¹³⁸ proposes that nonsyndromic craniosynostosis ideally is corrected within the first year of life, with scaphocephaly as a possible exception, corrected with early modified strip craniectomy.

The largest series is reported by Marchac,¹³⁹ nearly 1000 patients with all types of craniosynostoses were operated on in Paris. It is suggested to correct brachycephaly at the age of 2 to 4 months (often syndromic patients with raised ICP) and the other conditions at the age of 6 to 12 months. The reason why is not argued, however. Amm¹¹² prefers correction of scaphocephaly at the age of 6 to 12 months, without clear argumentation.

Fearon,¹⁴⁰ evaluating 16 children with trigonocephaly, established that the younger the child, the more spontaneous improvement of the hypotelorism after surgery, even though the hypotelorism itself was not surgically corrected. In 1996, they concluded that surgery at the age of 3 months would be ideal for good development of the orbits. Thirteen years later, however, the same research group concludes that the younger the child, the larger the growth inhibition of the skull after operative intervention. Their timing then is 4 months for the scaphocephalic child (to prevent progression of the frontal bossing) and 9 months for monosutural craniosynostoses requiring advancement (so that in any case the frontal band is strong enough, but the dural capacity of bone regeneration also is still sufficient to close all holes).¹²⁹

Also for frontal plagiocephaly, there is no consensus on the timing of surgery. Although minimal invasive surgical techniques need to be performed at young age, ages of 6 months to from 15 to 18 months are recommended for major reconstruction. Here, too, the most convincing argument for late surgery at the age of 18 months is a possibly lower chance of later relapse. Another approach to prevent relapse is “overcorrection” in the primary reconstruction, so that the final outcome after relapse still represents a “normal” situation into which the child has grown.¹²⁹ Several surgeons opt for early correction, however, for example before the age of 6 months, although this is not always motivated.^{124,140}

4.7. Conclusions

- | | |
|----------------|--|
| Level 2 | It seems likely that surgical intervention lowers the risk of increased ICP and improves cosmesis.
<i>B Arnaud, 1995¹⁴¹</i>
<i>B Mathijssen, 2006¹⁰³</i>
<i>B Renier, 1982¹⁴²</i>
<i>C Hilling, 2006a¹⁰²</i>
<i>C Hilling, 2006b¹²³</i> |
| Level 2 | It seems likely that there is increased risk of preoperatively raised ICP if surgery is performed after the first year of life
<i>B Arnaud, 1995¹⁴¹</i>
<i>B Mathijssen, 2006¹⁰³</i>
<i>B Renier, 1982¹⁴²</i> |
| Level 3 | It seems likely that in some mild types of craniosynostosis, such as palpable bone ridge during the metopic suture without bitemporal narrowing or partial synostosis of the sagittal suture, the natural course is favorable to the extent that operation is not indicated.
<i>C Barritt, 1981¹⁰⁰</i>
<i>C Van Veelen-Vincent, 2010⁹⁷</i> |
| Level 3 | It seems likely that the risk of relapse is somewhat larger after a limited early intervention than after a late complete skull remodeling.
<i>B Fearon, 2009¹²⁹</i> |

- Level 3** It seems likely that only resection of the synostotic suture (strip craniectomy) provides unsatisfactory result.
*C Anderson, 1981*¹¹⁶
*C Delashaw, 1986*¹¹⁷
*C Friede 1990*¹¹⁸
*C Aryan, 2005*¹¹⁹
*C Selber, 2007*¹²⁰
- Level 3** It seems likely that there is no difference between the different techniques (strip with helmet or springs, extended strip and complete skull remodeling) with regard to the morphologic result and CI. Probably there is a difference with regard to operation time and blood loss.
*C Amm, 2005*¹¹²
*C Barone, 1999*¹²⁵
*C Christophis, 2001*¹¹¹
*C Lauritzen, 2008*¹¹⁵
- Level 3** It seems likely that an extended strip craniectomy does not always create sufficient intracranial volume.
*C Florisson, 2010*¹¹⁰
*C Marucci, 2008*¹⁰⁹
- Level 3** It is probably the case that the orbital deformity does not normalize after resection of the synostotic suture only.
*C Aryan, 2005*¹¹⁹
*C Selber, 2007*¹²⁰
*C Stelnicki, 2009*¹²⁶
- Level 3** It is probably the case that the use of metal plates and screw devices in cranial remodeling in very young children leads to intracranial migration.
*C Fearon, 1995*¹³²
*C Goldberg 1995*¹³³
*C Persing, 1996*¹³⁴

Considerations

Although the risk of relapse seems to be somewhat increased after an early limited intervention, the risk is probably small. This should be weighed against the burden of a late complete cranial remodeling with longer operation time and more bleeding. This guideline therefore does not pronounce on a preference for early or late surgery. Still, in view of the results of Renier regarding the outcome of surgery after the first year of life, it is recommended to perform the intervention in the first year of life.

The novel techniques, such as the endoscopic strip craniectomy and the spring-assisted craniectomy, seem safe and effective. There is some concern in the field about the use of the remodeling helmet after endoscopic strip craniectomy. In patients with a NSOP this helmet exerts a restrictive influence on skull growth. This is notably an undesirable effect in craniosynostosis. It would be prudent, therefore, to systematically monitor patients treated in this way on restricted skull growth and signs of raised intracranial pressure. Considering the findings from the study of Marucci,¹⁰⁹ this holds true as much for patients treated with extended strip craniectomy.

Recommendations

Surgical correction is in principle not indicated for mild types of craniosynostosis, such as the metopic ridge and the partial synostosis of the sagittal suture, with few morphologic abnormalities. In all other types, operative correction of the deformity is indicated both on functional and cosmetic grounds.

Cranial remodeling in nonsyndromic craniosynostosis should take place in the first year of life.

Strip craniectomy for nonsyndromic craniosynostosis without additional measures is advised against.

The choice between the other techniques for scaphocephaly (ie, extended strip craniectomy, complete cranial remodeling, and strip

craniectomy combined with helmet or springs) is based on age of presentation and severity of the abnormality.

In case of orbital involvement, correction should include remodeling of the supraorbital margin (ie, trigonocephaly, frontal plagiocephaly, and brachycephaly).

The use of metal plates and screw devices in cranial remodeling in very young children is strongly discouraged.

6. SURGICAL TREATMENT OF SYNDROMIC CRANIOSYNOSTOSIS—THE CRANIAL VAULT

Basic Question

What type of cranial vault expansion is at what moment indicated as first treatment of the various types of syndromic craniosynostoses?

Introduction

Points of attention are the following:

1. In the different international centers either occipital expansion or fronto-orbital advancement is performed as first cranial vault expansion.
2. Timing of the first cranial vault expansion may differ; it is often performed by protocol when the child reaches a certain age, but in some centers not until when signs of increased ICP are noted. It is not clear whether this has any effect on functional results and/or number of operations performed.
3. The group of complex craniosynostoses (clinical suspicion of syndromic craniosynostosis without proven genetic abnormality, often with multiple sutural synostosis) is managed in the same way as the syndromic craniosynostoses, as these patients often experience similar problems regarding cognition and increased ICP.

Summary of the Literature

Cranial Vault Expansion: Frontal or Occipital?

In the mid-1990s, a number of articles were published reporting the experiences of various large centers, in which in particular the frontal cranial vault expansion was propagated.

- From Paris, it was reported that in syndromic patients with brachycephaly a fronto-orbital intervention was performed at the age of 2 to 4 months in which the forehead together with the supraorbital margin was dissected and only basically was reattached (“floating forehead”) to obtain a larger cranial volume. At later referral, a more extensive fronto-orbital advancement was performed (using tongue in groove).¹³⁹
- McCarthy et al described a comparable procedure in a group of 76 patients with a craniofacial syndrome. All underwent a primary fronto-orbital advancement within 18 months (mean 6.1).¹⁴³ In 28 patients a second procedure proved necessary (mean 28 months) and in 5 third procedure. The authors propose fronto-orbital advancement by protocol at the age of 6 to 9 months.

In a retrospective review of 167 patients with a syndromic craniosynostosis, De Jong⁵⁴ describes that a second intracranial intervention was needed in 14% with Apert syndrome, 22% with Crouzon/Pfeiffer, 5% with Muenke, and 15% with Saethre-Chotzen syndrome. In more than half of these patients the indication was increased ICP. In 1 patient a third cranial vault expansion was performed.

At the same time other large centers drew the attention to another option for patients with Apert or Crouzon/Pfeiffer syndrome: occipital cranial vault expansion. The benefits of a primary frontal expansion for a young child were considered too short lasting; it would have only a minimal effect on the remainder of the facial deformity and a next intervention for a facial correction (Le Fort III, monobloc or facial bipartition) would therefore be unnecessarily compromised.^{138,144}

As a result of a consensus meeting, Bruce²² proposed to postpone surgery of the midface in patients with the Apert and Crouzon/Pfeiffer syndromes as long as possible, with posterior decompression as first option.

From Birmingham a similar plea was made, also for patients with other diagnoses than Apert and Crouzon/Pfeiffer syndromes who develop no or only mild midface hypoplasia: on signs of increased ICP is increased, a posterior decompression should be performed first, allowing for an anterior intervention to be postponed (and sometimes declared to be even unnecessary eventually).¹⁴⁵ Furthermore, later timing of the frontal procedure would often remove the need of a frontal reoperation. Exception: severe exorbitism posing a threat to vision, for which fronto-orbital advancement should indeed be the first procedure.

In 2000 also Paris appears to have converted from frontal to occipital approach of faciocraniosynostosis (Apert and Crouzon/Pfeiffer syndromes). The classic management includes initial anterior skull remodeling and facial advancement as a second step. Since evolution of these complex faciocraniosynostoses results in turriccephalic aspect or recurrences more often than nonsyndromic craniosynostosis, *another approach can be used, consisting in an initial posterior vault expansion.*¹²¹ Fronto-orbital advancement is recommended, however, for the syndromic craniosynostosis in which retrusion of the orbital bar is the main feature (Saethre-Chotzen and Muenke syndromes).

Honnebier¹⁴⁶ reports that nearly half of the patients with Muenke syndrome required a second fronto-orbital correction to correct retrusion of the supraorbital margin following an initial fronto-orbital advancement at the age of 6 to 9 months. Virtually 100% will require an extracranial intervention to correct the temporal impressions. The authors do not provide a recommendation to adjust the timing of the initial intracranial intervention to this result.

The Rotterdam craniofacial team recommends occipital remodeling between 6 and 9 months for Apert and Crouzon/Pfeiffer syndromes except for patients with severe OSAS or severe exorbitism, in whom a monobloc with distraction is performed. Fronto-orbital advancement is recommended for the Muenke and Saethre-Chotzen syndromes, at 9 to 12 months for Muenke syndrome and at 6 to 12 months for Saethre-Chotzen syndrome. The difference in timing is based on the low risk of increased ICP in Muenke syndrome.⁵⁴

The team from Dallas provides arguments for parietal widening at very young age (8 to 16 weeks) in severe presentation of the Pfeiffer syndrome.¹⁴⁷ They renounce frontal correction because the bone is too soft for a fronto-orbital advancement. Occipital correction is not performed because they prefer to combine this with expansion of the foramen magnum in case of a symptomatic Chiari. For the milder types, they perform fronto-orbital advancement at the age of 9 to 15 months. As it is clear from the literature that a Chiari in Crouzon/Pfeiffer is often asymptomatic, solid underpinning of this reasoning seems to be lacking. Their strategy seems to be based on setting a low threshold for placement of a tracheostoma and not considering a monobloc procedure until the age of 3 or 4 years in such a situation.

In summary: now in 2009 posterior decompression is usually considered the first choice for children with Apert or Crouzon/Pfeiffer syndrome. Jeevan¹⁴⁸ in 2008 issued a warning relating to

this intervention: *cave* abnormal transosseous venous drainage! Fronto-orbital advancement is recommended for the syndromic types without midface hypoplasia.

In 2007,¹⁴⁴ Arnaud by means of a series of 36 children introduced “frontofacial monobloc with distraction” into the debate: this intervention may be essential in a very young child already demonstrating serious exorbitism and/or severe upper airway insufficiency, as it is associated with considerably lower morbidity and mortality than the “classic monobloc” as described by Marchac in 1996. Serious complications in 36 monoblocs with distraction were death by acute tonsillar herniation postoperatively in 1 patient and septic osteonecrosis of the frontal bone in 1 patient. Earlier operations preceding the monobloc increased the morbidity.¹⁴⁴

Kamoshima¹⁴⁹ describes the results of this intervention in 3 children as follows: “excellent functional and cosmetic outcome, with no remarkable complication.” Fitzgerald O’Conner described 10 syndromic craniosynostosis patients who underwent monobloc distraction.¹⁵⁰ The CT scans (pre- and postsurgery) demonstrated adequate advancement of the bony orbits, including forward advancement of the eyeball.

Timing: Standard or Not Until Signs of Increased ICP?

Parisian studies on mental development in syndromic craniosynostosis patients report higher IQ in patients operated on in the first year of life. This was found for patients with Apert syndrome,¹²¹ Crouzon syndrome,¹²¹ and Muenke syndrome with bicoronal synostosis,¹⁵¹ but not for patients with Muenke syndrome with a unilateral coronal suture synostosis (see chapter 16).¹⁰³ On the other hand, unilateral coronal suture synostosis (nonsyndromic and Muenke syndrome) was associated with higher risk of raised ICP in children operated on after the age of 12 months.

From analysis of the treatment protocols of the craniofacial centers participating in the International Society for Craniofacial Surgery it appeared there was consensus to perform the initial cranial vault expansion within the first year of life.²⁴

The London team is the only 1 with a different approach. They screened patients with Apert or Crouzon/Pfeiffer syndrome with the use of VEPs (visual evoked potentials) at ages 3, 6, 9, 12, and 18 months and next at ages 3, 4, 6, and 10 years. Cranial modeling is performed as soon as the VEPs show signs of delays in optic nerve conduction. Of the 24 apert patients treated according to this protocol, 20 developed increased ICP.¹⁵² The youngest patient showing increased ICP was 1 month old and the eldest 4 years and 5 months.

Metal plates and screw devices have been commonly used during a certain period. Later it became evident that application of this material in young children may lead to intracranial translocation of the plates and screws, with the screw ends penetrating the dura.^{132–134} Risk factors for translocation seem to be longer plates, placement in the temporal region, young age, and syndromic craniosynostosis.¹³³ Hardly anything is known about the consequences of this complication. In the past few years resorbable plates and screw devices have been applied for specific indications in craniosynostosis surgery. The reported rate of complications is low: infection 8/1883 patients¹³⁵ and 5/146 patients,¹³⁶ delayed foreign-body reaction in 12/1883 patients,¹³⁵ and postoperative resorbable device failure with loss of bony position in 5/1883 patients.¹³⁵

Conclusions

Level 3 It seems likely that posterior decompression is the first choice of cranial vault expansion in the Apert and Crouzon/Pfeiffer syndromes because this results in fewer risks associated with a monobloc or Le Fort III procedure carried out at a later stages.

In the Saethre-Chotzen and Muenke syndromes a fronto-orbital advancement is the first choice of cranial vault expansion because this will normalize the profile, upon which a monobloc or Le Fort III procedure is hardly ever indicated.

*C Thompson, 1994*¹³⁸

*C Bruce, 1996*²²

*C Sgouros, 1996*¹⁴⁵

*C Renier, 2000*¹²¹

*C Arnaud, 2007*¹⁴⁴

*C Honnebier, 2008*¹⁴⁶

*C De Jong, 2009*⁵⁴

Level 3 It seems likely that a monobloc-advancement is an adequate treatment of severe exorbitism and/or severe OSAS.

*C Arnaud, 2007*¹⁴⁴

*C Fitzgerald O'Connor, 2009*¹⁵⁰

Level 3 It seems likely that patients with a syndromic craniosynostosis in whom the cranial vault expansion is performed within the first year of life have better mental outcome.

*B Arnaud, 2002*¹⁵¹

*C Renier, 2000*¹²¹

*C Mathijssen, 2007*²⁴

Level 3 It is probably the case that the use of metal plates and screw devices in cranial remodeling in very young children leads to intracranial migration.

*C Fearon, 1995*¹³²

*C Goldberg 1995*¹³³

*C Persing, 1996*¹³⁴

Considerations

It is believed that occipital cranial vault expansion results in a larger intracranial volume than does a fronto-orbital advancement. Leaving the fronto-orbital region untouched in the first operation leads to lower risk of complications of a monobloc procedure performed at a later stage. Furthermore, by emphasizing the midface hypoplasia, a fronto-orbital advancement in Apert or Crouzon/Pfeiffer syndrome reinforces the facial dysbalance.

The question arises whether intensive ophthalmologic screening for increased ICP as well as the practice of performing cranial vault expansion not until results are abnormal should be protocolized. The high frequency of hospital visits and tests places a burden on patients, parents, and the members of the craniofacial team. In addition, there is a risk of false-negative VEP results, which does not seem to outweigh the lower number of patients who will not be operated on for the indication of increased ICP.

Recommendations

The initial cranial vault expansion in Apert or Crouzon/Pfeiffer syndrome is an occipital expansion; in Saethre-Chotzen or Muenke syndrome a fronto-orbital advancement.

If the patient also shows exorbitism with a threat to vision and/or severe OSAS, a monobloc-advancement with distraction should be considered as initial intervention (see chapters 7 and 12).

The initial cranial vault expansion in syndromic craniosynostosis is performed within the first year of life.

In patients with Apert, Crouzon/Pfeiffer, or Saethre-Chotzen syndrome it is recommended to perform the operation approximately at the age of 6 to 9 months, or earlier on evidence of increased ICP.

In patients with Muenke syndrome is recommended to perform the operation between the ages of 9 and 12 months.

The use of metal plates and screw devices in very young children is strongly discouraged.

7. SURGICAL TREATMENT OF SYNDROMIC CRANIOSYNOSTOSIS—THE FACE

Basic Questions

1. What treatment is most indicated for maxillary hypoplasia (sagittal, vertical and transversal), including exorbitism?
2. At what developmental stage is this treatment preferably performed?
3. At what moment and in which way should associated hypertelorism be treated?

The focus of this document is on maxillary hypoplasia in syndromic craniosynostosis patients; the exorbitism is a consequence of this hypoplasia and is therefore not separately investigated. Furthermore, (correction of) hypertelorism is evaluated as part of the monobloc operation.

Introduction

The Apert, Crouzon, and Pfeiffer syndromes are associated with hypoplasia of the maxilla, exorbitism, and hypertelorism. Indications for correction vary from acute vision impairment or respiratory problems to a relatively esthetic/psychologic problem. Various techniques are available to correct these deformities, and their timing greatly influences the eventual outcome.

Summary Literature

Syndromic craniosynostosis can be associated with skeletal hypoplasia of the midface, notably in the Apert and Crouzon/Pfeiffer syndromes. This benign hypoplasia can be present in 3 dimensions (sagittal, vertical, and transversal) and may result in restricted airway at the level of the nasopharynx (possible resulting in OSAS); exorbitism; malocclusion; and esthetic/psychosocial problems.

Although aspects of OSAS will be discussed in the "Aftercare" section of this guideline, the next section deals with the choice of surgical technique to correct the hypoplastic midface as well as the timing of surgery.

Corrections of the sagittal and vertical dimensions are discussed first, followed by those of the transversal dimensions.

Sagittal-Vertical

Timing of the Surgical Correction and (Postoperative) Growth

As investigated by Posnick in 1997, the face grows in 2 distinct periods. Craniofacial growth in the first 6 or 7 years is determined by growth of the brain, eyes, and the nasal cartilages.¹⁵³ The second period starts after the seventh year, in which growth consists of bony surface apposition and deposition, development of the processus alveolaris and enlargement of the nasal cavities and paranasal sinuses. Analysis of CT-scans of nonsyndromic healthy patients shows that growth of the orbits and the nasal bone is largest between the third and fourth years, so that at the age of 5 years already 93% of the eventual dimensions is reached. This observation is likely to be important for the timing of corrective surgery. Although some authors suggest that further growth could be restricted by surgery, others report (very) slow unchanged growth after surgery in syndromic craniosynostosis patients (see below).

Bachmayer (1986)¹⁵⁴ determined growth of the midface in 19 surgically treated syndromic craniosynostosis patients (Apert, Crouzon, and Pfeiffer syndrome) aged from 6 to 15 years. Postoperative growth of the maxilla in sagittal direction was less than

0.1 mm per year (negligibly small). In vertical direction, the growth was 1.3 mm per year and thus comparable with the growth in a healthy control group and schisis patients. Meazzini¹⁵⁵ concluded that the sagittal growth in untreated syndromic craniosynostosis patients was negligible, and if minimally present would not be adversely influenced by an operation. Kreiborg analyzed 8 patients with Crouzon or Apert syndrome on preoperative growth, stability of the Le Fort III osteotomy, and postoperative growth.¹⁵⁶ Some vertical growth was supposed to occur, irrespective of surgical intervention, and as a result of remodeling and appositional growth rather than sutural growth. During 10 years' follow-up (after Le Fort III osteotomy), no vertical or sagittal growth of the maxilla was observable.

Fearon¹⁵⁷ compared postoperative growth of the midface after conventional osteotomy (N = 10) with that after a distraction operation (N = 12). Neither group showed postoperative horizontal and vertical growth. Fearon states that the disturbed maxillary growth in the syndromic craniosynostosis patients is intrinsically associated with the syndrome, and that this would not so much be the effect of an operation.

Correction of the Hypoplastic Midface: the Le Fort III Osteotomy

In syndromic craniosynostosis patients, notably those with Crouzon/Pfeiffer syndrome or Apert syndrome, the hypoplasia of the midface consists of a hypoplasia of the maxilla, nasal bone, and zygomatic bone bilaterally including the bony orbits. The choice of treatment is primarily aimed at correction of these underdeveloped anatomic structures. The Le Fort III osteotomy, as originally described by Gillies and Harrison in 1950¹⁵⁸ but further developed by Tessier in 1967¹⁵⁹ (including the variations Tessier described for the lateral orbital margin) is designed to correct all these elements by a single forward advancement. Usually by means of an approach from cranial, the entire midface (including the maxilla, nose bone, and caudal part of the bony orbits bilaterally) is wholly detached from the skull base and moved forward. Hollier¹⁶⁰ described for the Le Fort III osteotomy a minimally invasive approach via local incisions (intraorally, upper, and lower eyelid).

Furthermore, a few publications are available on monobloc distractions (frontal bone including the Le Fort III part) in young patients, in whom osteotomy is not performed at all.^{161,162} After surgical placement of the bone-borne distraction device, distraction is started. Liu et al¹⁶³ described 4 patients (aged between 6 and 12 years) in whom a Le Fort III "sutural" distraction was performed (distraction without osteotomy), resulting in a mean 8 mm advancement. Pellerin et al reported on 4 syndromic craniosynostosis patients (all younger than 24 months) in whom midface advancement was obtained by means of a transfacial pin (K-wire) through both zygomatic bones connected percutaneously with an internal temporally fixed distractor bilaterally.¹⁶¹ All distractions are reported to have been successful.

Variants of the Le Fort III Osteotomy

In 1969, Obwegeser¹⁶⁴ presented several variants, including the combination of a Le Fort III and Le Fort I osteotomy in conjunction, and the "butterfly" (Le Fort III osteotomy without the nasal bone). In 2006, these osteotomic variants were again described by Kobus,¹⁶⁵ although with application of external frame distraction. Ueki et al (2005)¹⁶⁶ reported on a Crouzon patient (15 year of age) in whom distraction with external frame of the midface and surgically assisted rapid maxillary expansion (SARME) was performed in conjunction. The osteotomy of the midface can be performed according to the design of Kuffner, a "high" Le Fort I up to and including the infraorbital margin and up to the zygomatic arc bilaterally.

Le Fort III and (Mal-) Occlusion: Indication for Additional Orthognathic Surgery

The Le Fort III procedure is primarily aimed at correction of the hypoplasia of the nasal bone, orbits, and zygomatic bones. The occlusion is of secondary importance here. Also because open bite is frequently present, additional orthognathic surgery to correct the malocclusion is often required. This is naturally preceded by a thorough (cephalometric) analysis in consultation with the orthodontist (including orthodontic treatment) (see this section of the guideline). It is recommended to plan the surgical intervention aimed at correction of the malocclusion after age 18 years in all patients. If a Le Fort III osteotomy after age 18 years is indicated (and the distance to be bridged is limited), this can be combined with a Le Fort I osteotomy.

Additional Periorbital Surgery

Patients with syndromic craniosynostosis (notably those with Apert syndrome) often show down slanting of the palpebral fissures (in which the lateral portion of the eye slit is lower than the medial portion), which results in a characteristic syndromic appearance. Several operative techniques are available to move the position of the lateral canthus to cranial, thus normalizing the down slanting.¹⁶⁷ These procedures can be performed at the time of the distraction, at the time of possible orthognathic surgery, or separately. Occasionally, patients are satisfied with their facial appearance, or this surgical step is not at all indicated, and then further cosmetic interventions to the face are withheld.

The ventral movement of the midface, including the peri-orbital bony margin, is aimed at correction of the exorbitism, among other things. Nevertheless, after correction of the periorbital bony skeleton a soft tissue shortage of the lower eyelid may persist. Although all kinds of methods have been applied, such as local skin flaps, free skin transplants, and commercially available fillers, the Coleman lipofilling technique is increasingly used.^{168,169} After harvesting fat in places where this is abundantly available (such as abdomen, trochanter, and knee) the fat is centrifuged and next injected in the lower eyelid. It may be necessary to repeat this procedure several times to eventually obtain a good result.

Conventional Osteotomy or Distraction?

Application of distraction in the Le Fort III advancement is repeatedly underpinned with the argument that it allows for moving the hypoplastic midface over a larger distance to ventral (and possibly also to caudal) than with conventional osteotomy. This would lower the chance of needing a second intervention at later age after a first intervention during the child's growth phase. Furthermore, distraction could prevent a number of disadvantages of conventional osteotomy, such as intermaxillary fixation and the additional harvesting of autologous bone transplants with risk of comorbidity.

Tables 6 and 7 present data of the Le Fort III osteotomy and distraction, respectively, including numbers of patients, distance achieved, age at time of operation, and relapse (if mentioned in the publication).

Fearon¹⁵⁷ retrospectively analyzed 22 syndromic craniosynostosis patients who had undergone a Le Fort III advancement. Of these 22 patients (mean age 7.5 years), 10 had undergone conventional osteotomy and 12 distraction (2 with internal distractors and 10 with an external frame). The average advancement achieved in the osteotomy group for point A was 5.1 mm and for Nasion 7.7 mm; in the distraction group for point A 16.0 mm and for Nasion 7.0 mm. Asymmetry was observed with the use of internal distractors but not with the use of an external frame. The 2 groups did not differ with regard to operation time, need of transfusions,

TABLE 6. Conventional Le Fort III Osteotomy

	N	Advancement	Mean Age	Long Term
Ousterhout ¹⁹⁹	21	8.6	17 f/u 5	Stable
Kaban ¹⁹⁷	2	10	9.8	Stable
Bachmayer ¹⁹⁶	9	12.4	7.1	Relapse 9.4% horizontal 5.5% vertic.
Kreiborg ¹⁵⁶	8	10.9	10	Stable
David ¹⁸⁸	32	Horizontal 7.6 Vertical 8.0	16.6	Relapse?
McCarthy ¹⁹⁸	12	10	5.1	Stable
Fearon ¹⁵⁷	10	6		Stable
Meazzini ¹⁵⁵	17	6–14	7.3	Stable
Phillips ¹⁷¹	14	14.1	6.6	Stable

length of hospitalization (including ICU stay), and general complications. Fearon¹⁵⁷ recommends distraction as it allows for bridging a larger distance.

Iannetti et al¹⁷⁰ reported on 15 syndromic craniosynostosis patients, in 5 of whom Le Fort III osteotomy achieved an average 8.6 mm advancement and in 10 of whom Le Fort III distraction with internal distractors achieved a distance of 13.9 mm. Long-term results are not reported. Technical problems with the distractors are not mentioned. The authors recommend the conventional Le Fort III osteotomy if the distance to be bridged is less than 10 mm.

Meazzini et al¹⁵⁵ retrospectively analyzed the results of Le Fort III osteotomy in 17 syndromic craniosynostosis patients. Surgery was performed at a mean age of 7.3 years. Stability was assessed by means of cephalometry and judged as good with relapse to 3 mm after advancement of 6 to 14 mm (average advancement was not mentioned).

Phillips et al¹⁷¹ compared the results of their Le Fort III osteotomies in 14 syndromic craniosynostosis patients (mean age 6.6 years) with those in the literature for Le Fort III distraction techniques. Conventional Le Fort III osteotomy obtained a mean advancement of 14.1 mm at a mean 33 months' follow-up.

Le Fort III Distraction: Internal or External Distractors, or Combination?

Distraction of the detached midface (using Le Fort III osteotomy) can be performed with 2 types of distractors: internal and external distractors. A combination of internal (push) and external (pull) distractors has been reported as well.

TABLE 7. Le Fort III Distraction

	N	Advancement	Mean Age
Chin ¹⁷³	9	20	8.2
Satoh ¹⁷⁴	20	14–20	9.6
Meling ¹⁷⁵	7	23	11
Holems ¹⁷⁶	7	18	11
Gosain ¹⁷⁷	7	15	7
Kubler ¹⁷⁹	6	16	6
Cedars ¹⁷⁸	14	18	4–12
Fearon ¹⁸¹	41	18	8
Shetye ¹⁸²	15	16	5.9
Mu ¹⁸⁴	8	9	not mentioned
Malagon ¹⁸⁵	5	10	8
Lima ¹⁸⁶	11	10	9

1. *Internal distractors.* The internal distractors are placed subcutaneously in the temporal region with the “push section” at the site of the lateral orbital margin/zygoma part and at the site of the temporal cranial bone. The rod is either distracted transcuteaneously in dorsal direction above the ear or via the cheek in ventral direction. Among others, Molina has contributed to the development of these internal distractors.
2. *External distractors.* The external distractor consists of an externally placed external frame that is attached to with 6 to 8 pins to cranial vault bone. The detached midface is fastened to the frame with the use of a “tooth-borne” device and/or “bone-borne” microplates. Polley and Figueroa¹⁷² in 1997 introduced an external frame, the “rigid external distraction” (RED) device. Subsequently variations of the RED-frame have become available.
3. *Combination van internal and external distractors (push–pull).* This method is called the push–pull method and makes use of both types of distractors. After the Le Fort III osteotomy internal and external distractors are placed. An optimal vector is aimed for with the external distractor, and after having reached the intended position it can be removed. The internal distractor stabilizes the advanced midface and the external frame can be removed earlier after active distraction is stopped. This method would allow for more symmetrical advancement of the zygomatic arches, better advancement of the face on both occlusal and orbital level, and lastly for better advancement of the central part of the midface.

Re: Le Fort III Distraction With Internal Distractors

1. Chin and Toth¹⁷³ described 9 patients (mean age 8.2 years; 8 syndromic craniosynostosis and one with schisis) who underwent Le Fort III internal distraction. The internal distractors are distracted ventrally via the cheeks bilaterally. The mean midface advancement reached was 20 mm.
2. Satoh et al¹⁷⁴ described 20 syndromic craniosynostosis patients with mean age at surgery 9.6 years. A 14 to 20 mm distraction length was obtained. In 14 patients, a zygoma–zygoma internal distractor was used and in 6 patients zygoma–skull device. In the latter method (6 patients), the distractor is attached dorsally to the skull and the distraction rod is distracted percutaneously. In 3 of the 6 patients it was observed, however, that the convergent vector of the internal distractors exerted great strain on the zygomatico-maxillary suture, resulting in the Le Fort II portion being left behind. In these patients, conversion to

distraction with an external frame was necessary. Subsequently, the authors used a type of internal distractors that are distracted ventrally at the zygomatic arches and are placed in parallel with the use of a perioperatively applied reference rod. The authors prefer this type (zygoma-zygoma) of internal distractor. Slight asymmetry was noticed in 2/14 patients.

- Meling¹⁷⁵ described 7 patients with mean age 11 years in whom a mean distraction length of 23 mm was obtained, with in 1 case problems related to the internal distractor, and in 1 case deviation of the nose. All other cases were judged successfully. Data on stability and/or vector were not described.
- Holmes¹⁷⁶ described 7 consecutive syndromic craniosynostosis patients who underwent a Le Fort III osteotomy with internal distraction (mean linear distraction 18.1 mm, mean age 11 years). In 1 case a mechanical problem related to the internal distractor was observed. The authors report less advancement of the midface (Le Fort II complex) with the use of internal distractors. The bony zygomatico-maxillary junction in young patients is often too thin to transmit the vector 1 to 1. The authors have changed their policy; in the future they will apply he push-pull method.

Gosain¹⁷⁷ described 7 syndromic craniosynostosis patients (mean age 7 years, mean distraction 14.8 mm) in whom the Le Fort distraction with internal distractors was performed. In 5 cases a fracture occurred and/or weak zygomatico-maxillary junction and in 2 cases the internal distractors were replaced with an external frame.

Cedars¹⁷⁸ described 14 patients (13 syndromic craniosynostosis patients and one with schisis) who underwent Le Fort III distraction (internal). The mean distraction length obtained was 18 mm as determined by counting the number of rotations during the active distraction. In 1 patient the distraction caused asymmetry of the face; in 2 patients infection developed of the skin around the insertion site of the internal distractor, which resolved after removal of the internal distractor.

Re: Le Fort III Distraction With External Distractors (External Frame)

- Fearon¹⁵⁷ retrospectively analyzed 22 syndromic craniosynostosis patients who had undergone a Le Fort III advancement. Of these 22 patients (mean age 7.5 years), 10 had undergone conventional osteotomy and 12 distraction (2 with internal distractors and 10 with an external frame). The average advancement achieved in the osteotomy group for point A was 5.1 mm and for Nasion 7.7 mm; in the distraction group for point A 16.0 mm and for Nasion 7.0 mm. Asymmetry was observed with the use of internal distractors. This was not the case for the patients who underwent external distraction.
- Kubler¹⁷⁹ described in 6 patients (mean age: 6 years) fronto-orbital advancement by means of an osteotomy in combination with a Le Fort III distraction with external frame, with good results. The mean advancement of the Le Fort III portion was 15.8 mm.
- Mavili¹⁸⁰ described Le Fort III distraction with external frame in 4 syndromic craniosynostosis patients (age range: 5.2–12 years). The frame was fixed with an intraoral splint and with 2 infraorbital steel wires. In all patients the distraction was successful. There were no problems with the external frame. Information is lacking about the distance obtained as well as stability.
- Fearon¹⁸¹ analyzed Le Fort III advancement in 51 syndromic craniosynostosis patients (mean age 8 years), 41 of whom

underwent distraction with external frame. In the distraction group the mean obtained advancement was 18 mm. Cephalometric assessment after 1 year did not show any relapse. Furthermore, there was no growth of the maxilla after the Le Fort III operation. Problems with the external frame were not reported. The authors pose that the lack of growth is rather related to the syndrome and not so much a consequence of the operation.

- Shetye¹⁸² analyzed 15 syndromic craniosynostosis patients who underwent internal distraction with the Rigid External Distraction (RED) device. Fixation of the frame was by means of an occlusal splint and bone anchors at the site of the zygomatic arch and the maxilla. Point A had advanced 15.9 mm sagittally along the x-axis and moved downward 1.1 mm along the y-axis. These results were stable at cephalometric assessment after 1 year. Five patients developed a skin infection at the insertion site of the external pin, which in all patients could be managed successfully. In 2 patients there was traumatic dislocation of the frame. In 1 patient the external frame had to be repositioned under general anesthesia.
- Nout¹⁸³ analyzed 21 patients undergoing a Le Fort I and III external distraction. Most of the problems encountered were related to the external pin: loosening of the pin, infection of the skin around the pin, and in 3 patients there was traumatic dislocation of the frame, albeit without any effect on the final outcome.
- Mu¹⁸⁴ analyzed Le Fort III internal distraction (RED II device) in 8 syndromic craniosynostosis patients. In all patients the distraction, at mean 9 mm anteriorly and 1.5 mm caudally, was successful; in 1 patient a skin infection at the insertion site of the external pin was seen; in 1 patient a seroma. This publication is in the Chinese language, only the information in the English-language abstract is reported here. Malagon¹⁸⁵ described 5 syndromic craniosynostosis patients (mean age at operation 8 year) in whom a Le Fort III with halo frame was performed. The maxilla was advanced over 10 mm. Problems with the frame are not reported. In all patients the distraction was successful.
- Lima¹⁸⁶ described 11 syndromic craniosynostosis patients (mean age at operation 9 years) who underwent Le Fort III distraction with RED device. The mean obtained length was 10.3 mm horizontally and 2.4 mm vertically. Cephalometric assessment after 1 year showed less than 1 mm relapse in horizontal direction. Vertical face growth after 1 year was 2.9 mm.

Push-Pull Method

Schulzen¹⁸⁷ described 10 syndromic craniosynostosis patients (mean age 11 years), in whom the central midface using Le Fort III with push-pull distraction was advanced a mean of 12 mm. After the distraction period all devices were removed under anesthesia. It is not reported how the advanced segment was fixed during the consolidation phase. Push-pull distraction permits equal movement at both the upper and lower facial levels, advancement of the central midface, and symmetric movement. This method also provides a backup in case 1 device malfunctions.

Complications in Le Fort III Osteotomy/Distraction

Various complications have been reported in relation to the Le Fort III osteotomy and in relation to the application of internal and external distractors.

Complications of the Le Fort III Osteotomy. David¹⁸⁸ reported the following complications in 32 Le Fort III and monobloc osteotomies: blindness (1), frontal osteomyelitis (2),

cerebrospinal fluid (CSF) leakage (2), extradural abscess (1), periorbital abscess (1), wound infection (1), velopharyngeal insufficiency (4), diplopia (1), and facial nerve palsy (1).

Matsumoto¹⁸⁹ described a 9-year-old patient with Crouzon syndrome in whom a Le Fort III distraction is complicated by intracranial bleeding because of a skull base fracture. As a result, the patient died. Lanigan et al reported a skull base fracture in a nonsyndromic patient associated with the pterygomaxillary dysfunction (as part of the Le Fort osteotomy) resulting in unilateral blindness.¹⁹⁰

Nout¹⁹¹ described a lethal course in a 10-year-old patient with Apert syndrome in whom a Le Fort III osteotomy was performed immediately followed by placement of internal and external distractors. Anisocoria was noticed at the end of the intervention. Computed tomographic-angiography revealed a dissection of the internal carotid artery. Computed tomographic-angiography is therefore recommended in the preoperative planning of the Le Fort III distraction: in the first place to gain more insight into the thickness and configuration of the bone structures and intracranial structures in relation to the planning of the osteotomy lines and the placement of the distractors and secondly, to identify possible abnormalities of the arteries and veins.

Complications of Internal Distractors.

Mechanical problems in relation to internal distractors have been mentioned above.

Complications Van External Distractors.

The majority of the problems related to the external frame appear to be because of the percutaneous pins with which the frame is attached to the cranial vault. Skin infections and loosening pins are well-known problems reported in the orthopedic and neurosurgical literature. The data on incidences and recommendations on, for example, required torque, cannot be extrapolated one-to-one to syndromic craniosynostosis patients. These patients often have undergone earlier remodeling of the cranial vault. Thickness and strength of the cranial vault are not similar (less strength and lack of continuity in some places).

Nout¹⁸³ analyzed 21 patients (including 19 syndromic craniosynostosis patients) undergoing a Le Fort I and III external distraction. Most of the problems encountered were related to the external pin: loosening of the pin, infection of the skin around the pin, and in 3 patients there was traumatic dislocation of the frame, albeit without any effect on the final outcome.

1. A number of case reports describe intracranial migration of an internal pin.^{192–195} In all patients this had no permanent consequences with full recovery of the patient.

Timing of the Surgical Correction and (Postoperative) Growth

Although the number of cephalometric studies of maxillary growth in surgically treated and nonsurgically treated syndromic craniosynostosis patients is small, the results point at a clear picture. If there were to be any vertical and sagittal growth of the maxilla at all, it would be negligibly small or near-enough null: Bachmayer,¹⁹⁶ Meazzini,¹⁵⁵ Kreiborg,¹⁵⁶ Fearon,¹⁵⁷ and Fearon.¹⁸¹ The methodological quality of these findings can only be classified as Level 3 and 4.

Le Fort III Osteotomy or Distraction?

The publications on Le Fort III distraction consistently mention the following arguments, among other things, to prefer this

procedure during the conventional Le Fort III osteotomy: shorter operation with less blood loss, less pain, and shorter hospitalization, including ICU stay. But solid evidence is not provided in those studies. Yet the studies make clear that distraction permits to obtain a larger distance during which the detached portion can be advanced.

The publications on Le Fort III osteotomies demonstrate that the mean obtained midface advancement is approximately 9 to 10 mm (range 6–14 mm). The publications on Le Fort III distraction demonstrate that the mean obtained midface advancement is approximately 17 mm (range 9–23 mm). The methodological quality of these findings can only be classified as Level 3 and 4.

This would therefore also enable better functional and esthetic outcomes. Although in the Le Fort III distraction, in contrast to the conventional Le Fort III osteotomy, intermaxillary fixation and bone transplants are not needed, complications related to the internal and internal distractors may still occur. These are usually mild; in exceptional patients serious complications are described, often directly related to the pins of the external frame.

Lastly, it should be mentioned that a Le Fort III and a Le Fort I osteotomy technically can be combined in 1 operation, with which eventually the tooth-borne segment of the jaw can be moved over a larger distance.

Distraction With Internal of External Distractors?

The body of literature on the Le Fort III distraction includes more publications with more patients who have undergone a procedure with external frame than with internal distractors. At the same time, it is striking that recent publications tend to focus on the application of an external frame rather than the application of internal distractors.

It is not easy to summarize the results of the distractions with internal distractors. Individual publications report reasonable results, but at the same time in Satoh,¹⁷⁴ the internal distractors are eventually replaced with an external frame in 3/20 patients, whereas in Meling,¹⁷⁵ problems are reported in 2/7 patients. In Holmes,¹⁷⁶ we find a policy change on account of poor results with internal distractors in 7 patients in favor of the push–pull technique, in Cedars¹⁷⁸ the internal distractors were removed prematurely in 2/14 patients, and lastly in Gosain¹⁷⁷ the internal distractors were replaced with an external frame in 2/7 patients. Quite often this replacement is necessitated by a mechanical problem of the internal distractor.

The following publications on the Le Fort III distraction with external frame do not report any problems: Fearon¹⁵⁷ 22 patients; Mavili¹⁸⁰ 4 patients; Fearon¹⁸¹ 41 patients; Malagon¹⁸⁵ 5 patients; and Lima¹⁸⁶ 11 patients.

The following publications reported minor problems with the frame only:

Shetye¹⁸² pin-related skin infection in 5/15 patients and traumatic dislocation of the frame in 2/15; Nout¹⁸³ loosening of pins in 43% of the patients and traumatic dislocation of the in 3/21 patients, albeit without clinical consequences; and Mu¹⁸⁴ observed skin infection in 1/8 patients and seroma in 1/8.

The push–pull method is reported in only 1 publication, but Schulten is enthusiastic on the basis of outcomes in 10 patients.¹⁸⁷

Conclusions

Level 3 Maxillary growth in surgically and nonsurgically treated Apert, Crouzon, and Pfeiffer patients seems negligibly small.

B Fearon, 2001¹⁵⁷

B Fearon, 2005¹⁸¹

C Bachmayer, 1986¹⁵⁴

*C Meazzini, 2005*¹⁵⁵

*C Kreiborg, 1986*¹⁵⁶

Level 3 It seems likely that the mean advancement of the midface obtained with distraction is larger than that obtained with conventional osteotomy.

In Le Fort III distraction an external frame is preferred for its ease of placement and removal and optimum vector control. Any distractor (internal and external) related complications tend to be minor.

Le Fort III osteotomy:

*B Fearon, 2001*¹⁵⁷

*C Bachmayer, 1986*¹⁹⁶

*C David, 1990*¹⁸⁸

*C Kaban, 1986*¹⁹⁷

*C Kreiborg, 1986*¹⁵⁶

*C McCarthy, 1990*¹⁹⁸

*C Meazzini, 2005*¹⁵⁵

*C Ousterhout, 1986*¹⁹⁹

*C Phillips, 2006*¹⁷¹

Le Fort III distraction:

*B Fearon, 2005*¹⁸¹

*C Cedars, 1999*¹⁷⁸

*C Chin, 1997*¹⁷³

*C Gosain, 2002*¹⁷⁷

*C Holmes, 2002*¹⁷⁶

*C Kubler, 2004*¹⁷⁹

*C Lima, 2009*¹⁸⁶

*C Malagon, 2008*¹⁸⁵

*C Meling, 2006*¹⁷⁵

*C Mu, 2007*¹⁸⁴

*C Satoh, 2006*¹⁷⁴

*C Shetye, 2006*¹⁸²

*C Nout, 2010*¹⁹¹

Level 3 CT-angiography is recommended in the preoperative planning of the Le Fort III distraction. In the first place to gain more insight into the thickness and configuration of the bone structures and intracranial structures in relation to the planning of the osteotomy lines and the placement of the distractors. Secondly, to identify possible abnormalities of the arteries and veins.

*C Nout, 2010*¹⁹¹

Considerations:

Indications for midface advancement in OSAS and weighing up the pros and cons of a permanent or temporary tracheal cannula are dealt with in the chapter on OSAS.

One should be aware that there is no maxillary growth after a Le Fort III distraction at young age, so that a second Le Fort III (or mono-bloc) operation from the age of 18 years may be necessary. Additional orthognathic surgery (also from age 18 years) may be indicated to correct the malocclusion, including open bite (see chapter 14).

Operations that change the appearance considerably, such as a Le Fort III advancement in 12 to 17-year-old patients could give rise to psychosocial problems, which may already have been present because of the abnormal appearance.

Fronto-orbital advancement as the initial surgical intervention affects the facial profile and thus also influences the planning of the Le Fort III advancement (see chapter 6).

An external frame puts a considerable psychosocial burden on the patient and his/her family, those who activate the distractor. This may be a consideration to opt for an internal distractor instead. Furthermore, low mental development in syndromic craniosynostosis patients may be reason to opt for an internal distractor. The application of the internal distractor can be combined with a facial mask to optimize the vector of the Le Fort III distraction (see chapter 14).

Recommendations

The Le Fort III distraction in Apert and Crouzon/Pfeiffer patients to correct the maxillary hypoplasia (including exorbitism) is typically performed between the ages of 8 and 12 years, or from the age of 18 years. In case of severe OSAS and/or severe exorbitism posing a threat to vision it may be performed at younger age (see chapter on OSAS). In young children (≤ 6 years) a monobloc distraction is preferred, dependent on previous surgeries.

In view of the higher risk of psychosocial problems or unrealistic expectations in 12 to 18 year olds, the Le Fort III distraction is preferably not performed at these ages (see chapters 17 and 18).

After the Le Fort III, occlusion must be monitored. Orthognathic surgery is recommended in the patient of malocclusion (eg, Le Fort I, bilateral sagittal split osteotomy). This type of surgery is performed after age 18 years (see chapter 14).

Computed tomographic-angiography deserves to be considered in the preoperative planning of the Le Fort III distraction.

In Le Fort III distraction an external frame is recommended in view of its ease of placement and removal and the possibility of optimum vector control.

If internal distractors show mechanical problems they should be replaced with an external distractor.

Monobloc Osteotomy/Distraction and Hypertelorism

The monobloc frontofacial osteotomy is a combination of a transcranial advancement of the frontal bone and an extracranial Le Fort III advancement in 1 operation and in 1 piece. This surgical intervention is indicated in syndromic craniosynostosis patients to correct the hypoplastic midface with possibly associated functional problems and elevated ICP at a relatively too small cranial volume. It was described in 1978 by Ortiz-Monasterio et al.²⁰⁰

The body of good literature on the results of monobloc osteotomies is evidently much smaller than that regarding the Le Fort III advancement. Data on complications of the conventional monobloc operation were not available in Pubmed and for this reason we searched the publications of the first congresses of the International Society for Craniofacial Surgery. Only very few surgeons applied the conventional monobloc in the earlier days, and results including complications were presented at these meetings only. Exclusion of these publications would result in a bias with considerable underestimation of the complications of this procedure.

Hypertelorism in Syndromic Craniosynostosis Patients

Apart from midface hypoplasia, hypertelorism is a well-known phenomenon in syndromic craniosynostosis patients. Although it seldom leads to functional problems, the position of the bony orbits can esthetically be unappealing to such an extent that correction is indicated. In 1979, Van der Meulen described the "median faciotomy" for correction of the midline cleft with hypertelorism.²⁰¹ By vertical splitting of the monobloc segment in the midline and removing a wedge from the midline of the midface he was able to rotate the 2 halves of the midface toward each other, thus reducing the distance between the orbits. Tessier²⁰² later refined this technique and named it facial bipartition. This refined technique can be combined with forward advancement: "facial bipartition osteotomy with advancement", in which advancement can be performed with distraction as well.

Orbital hypertelorism may also be treated with orbital box osteotomy. This procedure cannot be performed until the teeth have erupted permanently, usually from approximately the age of 14 years. Orbital box osteotomy is well suited to be combined with

orthognathic surgery. Naturally, the positions of the medial and lateral canthus should be paid attention to in the orbital box osteotomy and the “facial bipartition”.^{167,203} Although some surgeons do not detach the canthi and prefer to leave these in situ at the bone, other surgeons purposefully detach the canthi to reattach them later to the bone. The latter method would permit better correction of the positions of the canthi.

Moreira Gonzalez reported good results after facial bipartition in 14 syndromic craniosynostosis patients, combined with advancement using osteotomy in 3 patients. Postoperative problems were the following: liquor leakage (2), infections (2).²⁰⁴ Problems with diplopia are not reported.

Urrego²⁰⁵ reported a surgical technique aimed at reducing the remaining telecanthus in this intervention. In 12 patients, a mean 39% reduction of interbrow distance was noted.

Posnick²⁰⁶ analyzed pre- and postoperative CT scans of 7 syndromic craniosynostosis patients undergoing facial bipartition osteotomy. Also after 1 year the results showed stable improvement but no complete normalization.

Risks and Complications of Monobloc/Facial Bipartition (With and Without Distraction)

The literature consistently points to the same risks, complications and problems around monobloc osteotomies: presence of a ventriculoperitoneal shunt, need of extensive bone grafts for the sake of stabilization, pressure on the soft tissues and cranial flap, and extradural retrofrontal dead space created by the advancement and which directly connects with the nasal cavity and the ethmoid. Occurrence of the latter complication could perhaps be reduced by closing the connection between this dead space and (para-) nasal cavity with galea frontalis flap or periosteal flap.

Aspects of relapse and revision of monobloc in relation to the indication of monobloc for OSAS are addressed in the relevant chapter.

Osteotomy

Posnick described 23 syndromic craniosynostosis patients, 10 undergoing monobloc advancement, 7 facial bipartition advancement, and 6 facial bipartition solely (all osteotomy, no distraction).²⁰⁷ All showed a retrofrontal dead space after the intervention, which in 10 patients had disappeared after 6 weeks and in all within 1 year. The presence of a ventriculoperitoneal shunt did not influence the risk of complications. One patient showed evidence of a late (after 3 months) CSF leakage via a skin fistula with necrosis of the frontal bone.

Timing of the Monobloc-Distraction in Relation to Orbital Growth

Bentley²⁰⁸ preoperatively analyzed the volumes of the bony orbits in 50 syndromic craniosynostosis patients and compared the outcomes with those of a normal group. Volumes in the syndromic craniosynostosis patients were smaller shortly after birth but tended to reach normal values at 6 to 8 months of age and had completely normalized at 13 months of age. This would imply that surgical intervention should be delayed until the age of 6 to 8 months, thus maximizing the effects of accelerated normal orbital growth.

Position of the Eye Globe After Monobloc Distraction

Fitzgerald O' Conner¹⁵⁰ analyzed in 10 syndromic craniosynostosis patients the position of the eyeball after monobloc distraction. At an osseous distraction distance of 12.9 mm (upper face) and 14.2 mm (lower face) the globe moved 5.3 mm (left eye) and

6.3 mm (right eye). Globe advancement was approximately 2/5 of the distraction distance, without evidence of optic nerve damage and impaired vision.

Distraction

As was done above for the Le Fort III distractions, the following section describes the application of internal and internal distractors in monobloc distractions.

Monobloc Distraction With External Distractors

1. Witherow²⁰⁹ reported 20 syndromic craniosynostosis patients undergoing monobloc distraction with halo external frame; mean advancement: 16.4 mm, mean age 7.8 years. Cerebrospinal fluid leakage was noted in 8 patients (the leakage stopped in 5 patients; 3 underwent a revision operation using a lumbar drain)
2. Witherow²¹⁰ evaluated relapse after monobloc distraction with external frame in 21 syndromic craniosynostosis patients (mean age 8.3 years, probably largely the same patients as mentioned under point 1). The midface was distracted to an average of 16.4 mm. Relapse was seen only in 3 of all patients during 14.8 months' follow-up period.
3. Ponniah²¹¹ studied the pre- and postoperative CT scans of 10 syndromic craniosynostosis patients undergoing monobloc distraction (7) and facial bipartition distraction, both using an external frame. In particular, the facial bipartition distraction differentially advanced the central part of the face more than the lateral areas.

Monobloc Distraction With Internal Distractors

1. Cohen²¹² described 5 syndromic craniosynostosis patients, in 3 of whom monobloc distraction was performed and in 2 a facial bipartition, in all patients using internal distractors (age between 9 months and 5 years). The distraction distance ranged from 22 to 30 mm. Device infection developed in 1 patient.
2. Arnaud²¹³ described 20 syndromic craniosynostosis patients who underwent monobloc distraction using internal distractors (mean age: 3.2 years). Cerebrospinal fluid leakage occurred in 3 patients. Device infection developed in 2 patients requiring removal of the distractor. Septic frontal necrosis occurred in 1 patient 2 months after completion of distraction, necessitating removal of the forehead flap.
3. Arnaud¹⁴⁴ studied 36 syndromic craniosynostosis patients undergoing monobloc distraction using internal distractors (mean age: 5.2 years). Distraction was uneventful in 28 patients; 7 required revision surgery because distractors stagnated. One patient died from acute brain tonsillar herniation before distraction was begun. Furthermore, loss of dead frontal bone in 1 patient.
4. Bradley²¹⁴ described 13 syndromic craniosynostosis patients (mean age 8.3 years) who underwent facial bipartition, including monobloc distraction using internal devices. Stable results were obtained and no complications were reported (no liquor leakage, meningitis, or frontal bone loss).
5. Fitzgerald O' Connor¹⁵⁰ described 10 syndromic craniosynostosis patients undergoing monobloc distraction (upper face distraction distance 12.9 mm and lower face 14.2 mm). From CT scans (pre- and post-) a mean forward movement of 5.3 mm

for the left globe and 6.3 mm for the right globe was established. Although there was no evidence of optic nerve stress with possible functional limitations, the long-term development should be closely monitored.

Complications in Monobloc Osteotomies/Distractions

David (1990)¹⁸⁸ reported the following complications in 32 Le Fort III and monobloc osteotomies: blindness (1), frontal osteomyelitis (2), CSF leakage (2), extradural abscess (1), periorbital abscess (1), wound infection (1), velopharyngeal insufficiency (4), diplopia (1), and facial nerve palsy (1).

Vyas²¹⁵ reported a left carotid-cavernous fistula as a complication in monobloc distraction in a patient with Apert syndrome. The fistula was successfully embolized. After 1 year there was still partial vision loss in the left eye, but there were no other sequelae.

Witherow described in 20 syndromic craniosynostosis patients the following complications after monobloc distraction: CSF leakage (8, in 5/8 it stopped spontaneously, 3/8 required lumbar drainage in combination with endoscopic repair of the tensor fascia latae muscle with Tissuecoll), hypernasality (5), loss of frontal dead/avital bone (1), temporary tracheotomy (2), fracture of the zygomatic bone (1), trismus which spontaneously had resolved after 6 months (5), and cornea ulceration (2).²⁰⁹

Complications in Monobloc Osteotomy/Distractor

The literature (case reports and no series larger than N=4) consistently points to the same risks, complications, and problems around the monobloc osteotomies (including the variants): presence of a ventriculoperitoneal shunt; need of extensive bone grafts; pressure on the soft tissues and cranial flap; and extradural retrofrontal dead space created by the advancement and, which directly connects with the nasal cavity and the ethmoid.

On the other hand, Posnick et al²⁰⁷ described monobloc osteotomy in 23 syndromic craniosynostosis patients, of whom 1 showed late CSF leakage via a skin fistula with necrosis of the frontal bone. In all patients, the retrofrontal dead space had disappeared after 1 year. The presence of a ventriculoperitoneal shunt did not influence the risk of complications.

This is the only series of appreciable size in which this was analyzed retrospectively.

Benham provide an overview of monobloc fronto-facial advancements performed in University of California, Los Angeles (UCLA) in the predistractor period from 1988 to 1996.²¹⁶ In total 26 patients were operated; mean operation time was more than 8 hours, mean blood loss 1700 cc. The following complications were noted: liquor leakage (27%), SIADH (15%), pneumonia (12%), epilepsy (8%), meningitis (4%), hypoxic injury (4%), pseudomeningocele (4%), oronasal fistula (4%), partial flap necrosis (4%), and abscesses (4%). This was already a considerable improvement compared with the results from the 1979 to 1988 period as a consequence of adaptations of the operative technique.

Wolfe reports the results of a classic monobloc in 44 patients.²¹⁷ The complications consisted of death (2%), liquor leakage (2%), violent infections (osteitis, temporal, and epidural abscesses, 9%) resulting in loss of the frontal bone in 7%. The created frontofacial dead space was mentioned as the major cause for these infections.

Marchac²¹⁸ reported their lethal complications after craniofacial surgery. Twenty of the 1397 patients undergoing intracranial operations died (1.4%). And even 6 of the 18 patients in whom a monobloc was performed died.

Timing

Regarding the timing of monobloc distraction in relation to growth of the orbits, Bentley et al (2002)²⁰⁸ concluded from CT-analysis in 50 syndromic craniosynostosis patients and control group that this should be delayed to minimally the age of 6 to 8 months to allow for optimal orbital growth.

Monobloc Distraction: Osteotomy or Distraction? Internal or Internal Distractors?

Regarding the choice of operation technique—distraction versus osteotomy—the literature unanimously makes clear that distraction allows for movement of the bone segment over a larger distance. Witherow²⁰⁹ described 20 syndromic craniosynostosis patients and Ponniah²¹¹ described 10 patients undergoing monobloc distraction with external frame. No major problems and complications were reported. Most of the publications, encompassing the large majority of patients, describe monobloc distraction with the use of internal distractors.

Position of the Eye Globe After Monobloc Distraction

Fitzgerald O'Connor¹⁵⁰ concluded from CT-analysis in 10 syndromic craniosynostosis patients undergoing monobloc distraction that globe advancement was approximately 2/5 of the distraction distance, without evidence of optic nerve damage and impaired vision. This is the only report on this issue.

Conclusions

Level 3 It is likely that monobloc distraction can be performed in a predictable way with either type of distractors (internal and external) with eventually fewer complications than with conventional monobloc osteotomy.

C Benham, 1997²¹⁶

C Marchac, 1995²¹⁸

C Wolff, 1995²¹⁷

C Witherow, 2008²⁰⁹

C Ponniah, 2007²¹¹

C Cohen, 1999²¹²

C Arnaud, 2007¹⁴⁴

C Bradley, 2008²¹⁴

C Fitzgerald O'Comer, 2009¹⁵⁰

Level 3 Regarding the timing of the monobloc operation there are indications that it is worth waiting until minimally the age of 6 to 8 months to allow for optimal growth of the orbits.

C Bentley, 2002²⁰⁸

Considerations

Regarding the indication for midface/monobloc advancement in OSAS and the considerations on the pros and cons of a permanent temporary tracheal cannula, please refer to the chapter on OSAS.

As there is no maxillary growth after an early monobloc, a second monobloc (or Le Fort III) operation after the age of 18 may be necessary.

Operations that change the appearance considerably, such as a monobloc in 12 to 17-year-old patients could give rise to psychosocial problems, which may already have been present because of the abnormal appearance (see chapter 17).

An external frame puts a considerable psychosocial burden on the patient and his/her family, those who activate the distractor. This may be a consideration to opt for an internal distractor instead. Furthermore, low mental development in these syndromic craniosynostosis patients may be reason to opt for an internal distractor.

As syndromic craniosynostosis patients, notably those with Apert or Pfeiffer/Crouzon syndrome, often show V-shape in the maxilla including the open bite, facial bipartition is preferred because this does not only correct the hypertelorism but also restores this V shape to a normal occlusal line. Regarding the timing of this intervention the same argument as in the midface/monobloc operations is proposed: at the age of 4 to 5 years by far the largest part of the osseous orbits has been fully developed.

Although orbital box osteotomy compromises vascularization of the margins that were detached with osteotomy (which could result in resorption and undesirable decrease in volume), this effect will be less with the facial bipartition. The orbital box osteotomy can be performed from approximately at the age of 14 years. After all, the caudal part of the osteotomy (under the infraorbital margin) requires sufficient space between the infraorbital nerve and the apical boundaries of the dentition. The orbital box osteotomy can be well combined with orthognatic surgery.

Recommendations

The monobloc distraction in syndromic craniosynostosis patients is indicated in severe exorbitism (ocular globe luxation and/or corneal injury) with

1. severe OSAS at the time of protocolized initial cranial vault expansion
2. severe OSAS in combination with elevated ICP.

In case of severe OSAS, age (and therefore timing) does not play a role. In very young children (<2 years) tracheal cannula placement may bridge the waiting time (see chapter on OSAS).

Monobloc distraction is preferred in view of the lower percentage of serious complications in comparison with the conventional monobloc osteotomy.

In view of the higher risk of psychosocial problems or unrealistic expectations in 12 to 18 year olds, a monobloc is preferably not performed at this age (see chapters 17 and 18).

Hypertelorism is preferably corrected from the age of 4 or 5 years by means of the facial bipartition technique. The orbital box osteotomy technique can be performed after the upper teeth have erupted permanently (from approximately the age of 14 years) and can be well combined with additional orthognatic surgery.

Computed tomographic-angiography is recommended in the preoperative planning of the monobloc distraction (with or without facial bipartition).

After the monobloc procedure, monitoring of occlusion is warranted. Orthognatic surgery is recommended if malocclusion should occur (eg, Le Fort I, bilateral sagittal split osteotomy). This surgery should be delayed until after the age of 18 years (see chapter 14).

Transversal Correction

The sagittal and vertical dimensions have already been addressed in the sections on the Le Fort III and monobloc osteotomy/distraction. The transversal correction is discussed below. The available literature on this topic is even more limited and mostly concerns small case series.

Transversal maxillary hypoplasia in adolescence and adulthood is seen in non-syndromic and syndromic patients, including schisis patients. This type of hypoplasia leads to transversal malocclusion.

In skeletally immature patients, the maxilla can be expanded orthodontically. In skeletally mature patients, however, a uni- or bilateral transversal hypoplasia can solely be corrected with the use of SARME. This procedure is a combination of surgical and

orthodontical techniques that offers room in the maxillary arch for orthodontically correct arrangement of the teeth. In addition, SARME substantially enlarges the maxillary apical (dentoalveolar) base and the palatal arch, which allows good movement of the tongue in swallowing. An additional favorable effect is a subjective improvement in nasal breathing as a result of the expansion of the narrowest passage in the nose (nasal valve) and of the nasal cavity volume.²¹⁹

The scientific background for the timing of this treatment is addressed below. In the absence of recent studies on this subject, however, we had to resort to literature from before 1980.

Growth at the sutures takes place by deposition of new bone at the suture borders by the adjacent cellular layer. By the end of fetal life this cellular layer will become thinner, which indicates slower growth rate and reduction of the number of fibers in the intermediary cellular layer, which separates the capsular layers. In a study of human sutures from birth to 18 years of age, Latham and Burston²²⁰ concluded that after some 2 to 3 years the sutures primarily are functioning as sites where the separate bone plates meet, but that remodeling is a continuous process. The cranial sutures will fuse before the complete eruption of the third molars. Shortly hereafter the facial sutures will fuse, and the sutures that connect the skull and the face are the last to fuse.²²¹ Regarding the facial sutures, Sicher²²² concluded from anatomic studies that fusion in humans on average starts by the middle of the fourth decade, at the posterior part of the median palatal suture, but that some facial sutures, including the frontozygomatic suture, remain open to later age.

A conflicting view is presented by Persson,²²³ who found evidence of osseous fusion of the median palatal suture at age 17 years. Latham and Burston,²²⁰ however, did not find evidence of synostosis in the same suture at age 18 years. An "overall view" is presented by Scott²²⁴ who believes that in spite of the fact that most of the facial sutures seem to be open on the surface, they show a certain degree of fusion somewhat deeper. The available literature clearly is not unambiguous and conclusive on this subject.

In clinical practice, however, transversal orthodontical expansion is successful until the age of approximately 14 to 15 years, depending on the patient's sex. After this age it is virtually impossible to achieve orthodontic expansion.²²⁵⁻²²⁷ In general it is believed that that the fusion of the midpalatal suture impedes expansion.²²⁵⁻²²⁷

The above applies to the nonsyndromic situation. The literature contains 2 studies dealing with maxillary sutures, maxillary transversal growth, and SARME in the syndromic situation.

Koudstaal et al²²⁸ describe the application of a bone-borne distractor device for the expansion of the maxilla in 8 syndromic and 5 non-syndromic patients. They conclude that this type of distractor is suitable for surgical expansion of the maxilla in both nonsyndromic and syndromic patients. Notably the small dimensions of the device make it suited for application in the extremely narrow upper jaws seen in syndromic craniosynostosis patients.

The literature does not contain publications on the effects of SARME on further growth of the maxilla, neither in nonsyndromic nor in syndromic patient groups.

Only very few publications are available on the indications, timing, and the effects of SARME in syndromic craniosynostosis patients. The information is based on literature data of nonsyndromic patients.

In summary, the patient's age determines the indicated therapy for transversal maxillary hypoplasia, either orthodontical expansion or SARME. As soon as the diagnosis of transversal maxillary hypoplasia is made and treatment can reasonably be started in view of the dental and mental situation, orthodontic expansion is indicated before the age of 14 to 15 years, SARME at older age.

Conclusions

Level 4 It seems likely that the SARME procedure can be performed from the age of 14 to 15 years.
C Koudstaal, 2006²²⁸

Considerations

The experts are of the opinion that in syndromic craniosynostosis patients the maxilla may be extremely narrow, in which situation a tooth-borne distractor in the SARME procedure technically is not feasible. In that case, the application of the bone-borne distractor is indicated. One should be aware that the palatal mucosa may be very thick in syndromic craniosynostosis patients. This may impede placement of some types of bone-borne distractors.

Recommendations

If a SARME procedure is performed in syndromic craniosynostosis patients, a tooth-borne distractor is preferred over a bone-borne distractor. But in case of an extremely narrow maxilla and insufficient space for a tooth-borne distractor (Hyrax), a bone-borne distractor is indicated. The thick palatal mucosa impedes the placement of a bone-borne distractor. A SARME procedure is performed from the age of 14 to 15 years.

8. INCREASED INTRACRANIAL PRESSURE

Basic Questions

1. What is the prevalence of ICP in the various types of nonsyndromic and syndromic craniosynostosis, before and after skull remodeling?
2. What screening (nature and frequency) is needed to timely identify increased ICP?
3. How can increased ICP be prevented or treated?

Introduction

The risk of increased ICP varies widely between the types of craniosynostosis, and the syndromic type carries a much higher risk than the nonsyndromic type. The risk in the nonsyndromic group, however, is much less recognized and therefore possibly under diagnosed. It is important to detect and treat increased ICP at an early stage. High ICP may lead to, for example, irreversible loss of vision.²²⁹ It is not clear what method is best suited to establish increased ICP, what thresholds should be set, and at what frequency it should be applied to identify problems at an early stage.

Summary of the Literature

Prevalence

I. Nonsyndromic Craniosynostosis. Until 1996, genetic diagnostics was not possible and therefore the distinction between syndromic and nonsyndromic was not always evidenced. In the older literature about ICP it is often unclear whether this really concerns nonsyndromic craniosynostosis. Especially, cases of unilateral or bilateral coronal suture synostosis may well be of a syndromic type. Most of the publications on ICP in craniosynostosis patients derive from 2 centers (Paris and London) and patient populations may overlap. Most studies only address increased ICP preceding a cranial vault expansion. Reliable data on the prevalence of increased ICP following cranial vault expansion are rare. There are no data at all on ICP in patients with a lambdoid

suture synostosis, most likely because of the very low prevalence of this type of synostosis.

The following publications are from the Parisian center, and patient populations may overlap:

Renier (1982) preoperatively performed invasive ICP measurements in 49 nonsyndromic patients, that is, 23 with scaphocephaly, 9 with plagiocephaly, 5 with trigonocephaly and 7 with brachycephaly. Increased ICP (>15 mm Hg) was measured in 3, 2, 0, and 3 patients, respectively; borderline ICP (11–15 mm Hg) in 4, 4, 1, and 2 patients, respectively and normal ICP (≤10 mmHg) in 16, 3, 4, and 2 patients, respectively.¹⁴² In 23 patients (both isolated and syndromic) the ICP measurement was repeated postoperatively: in all 23 the ICP had decreased over a number of weeks. Regarding the relation between ICP and age, ICP peaked at 6 years. In 17 patients, clinical suspicion of increased ICP years after the operation was confirmed with an invasive measurement. The diagnoses, however, are not mentioned.

Gault²³⁰ defined increased ICP as >15 mm Hg, irrespective of age, which widely ranged in the study population. Intracranial pressure was measured invasively preceding cranial vault expansion. Increased ICP was established in 1 of the 2 patients with brachycephaly, in none of the 4 patients with trigonocephaly, in none of the 3 patients with plagiocephaly, and in 2 of the 44 patients with scaphocephaly.

Arnaud¹⁴¹ preoperatively measured ICP invasively in 142 children with scaphocephaly. Intracranial pressure exceeded 15 mm Hg in 19 children, of whom 12 were older than 1 year, which was statistically significantly different.

Renier¹²¹ provides an overview of more than 2137 patients with craniosynostosis. Invasive preoperative ICP measurements revealed prevalences of 13.8% in scaphocephaly (246 measurements), 7.7% in trigonocephaly (39 measurements), 12.7% in plagiocephaly (63 measurements), and 31.3% in brachycephaly (32 measurements).

Mathijssen¹⁰³ reported invasive preoperative ICP measurements in plagiocephaly; ICP was >15 mm Hg in 8 of the 50 patients. These 8 children were all older than 1 year (statistically significant).

Also the craniofacial team in London published a considerable number of publications on this issue:

Thompson²³¹ performed invasive preoperative ICP measurements in 37 patients with plagiocephaly, 25 with scaphocephaly and 12 with trigonocephaly. Increased ICP (>15 mm Hg) was established in 3, 6, and 4 patients, respectively.

Thompson²³² preoperatively measured ICP invasively in 72 nonsyndromic patients: 18 children with scaphocephaly, 35 with plagiocephaly, 10 with brachycephaly and 9 with trigonocephaly. Intracranial pressure was increased (>15 mm Hg) in 13 children: 3 with scaphocephaly, 2 with plagiocephaly, 5 with brachycephaly, and 3 with trigonocephaly. Borderline ICP (10–15 mm Hg) was measured in 7, 13, 2, 5, and 3 patients, respectively. Here, too, it is not certain if the brachycephaly was really nonsyndromic. If increased ICP was defined on the basis of plateau waves rather than just mean ICP, the number of patients with increased ICP would have been somewhat higher.

Shipster²³³ reports increased ICP (>15 mm Hg), measured invasively, in 4 of 11 scaphocephaly patients. It is not clear why ICP was measured in these 11 patients and whether there may have been selection bias. Thompson²³⁴ is referred to, and probably the populations overlap. For this reason this publication is not included in Table 8.

The other studies are from Camperdown, Australia,²³⁵ Rome,^{236–237} and the United States, that is, Chicago,²³⁸ and Seattle.²³⁹

Whittle²³⁵ included 5 nonsyndromic craniosynostosis patients: 4 with scaphocephaly and 1 with plagiocephaly. Preoperative

invasive measurement revealed increased ICP in 2 of the 4 with scaphocephaly and in the 1 with plagiocephaly. The indications for ICP measurements were radiologic signs of mild hydrocephalus, loss of vision, headache or behavior change, and are therefore a source of bias. For this reason this publication is not included in Table 8.

Tamburrini²³⁶ reports invasive preoperative ICP measurements in 5 nonsyndromic craniosynostosis patients: 3 with scaphocephaly and 2 with brachycephaly. All 5 had normal ICP levels (≤ 15 mm Hg).

Tamburrini (2005)²³⁷ reports invasive preoperative ICP measurements in 7 nonsyndromic craniosynostosis patients: 3 with scaphocephaly and 4 with brachycephaly. Of the latter 4 patients, 2 had an anterior brachycephaly and 2 a posterior brachycephaly. The question is whether the 2 with posterior brachycephaly really showed synostosis. The 2 patients with a bicoronal synostosis had increased ICP. Possibly these were indeed cases of syndromic craniosynostosis. Probably these are the same patients as described in the 2004 publication. In view of the very small numbers and the dubious diagnoses this study is not included in Table 8.

Foster²³⁸ investigated the occurrence of resynostosis after primary skull remodeling in 13 patients with trigonocephaly, 30 with scaphocephaly, 22 with plagiocephaly, 1 with unilateral lambdoid suture synostosis and 9 with brachycephaly. The resynostosis rates were 7.7% (1), 3.3% (1), 0, 0, 0, respectively. In 1 patient with scaphocephaly increased ICP was established by means of lumbar puncture before second cranial vault expansion. As the occurrence of resynostosis was subjected to selection, these rates do not reflect the real prevalence in the total population of patients with a nonsyndromic craniosynostosis.

Scott describes 36 patients older than 2 years at the time of primary cranial vault expansion. A total of 17 patients showed preoperative symptoms consistent with increased ICP, and 10 had already earlier undergone cranial surgery elsewhere.²³⁹ The study group consisted of 5 patients with scaphocephaly, 2 with brachycephaly, 1 with trigonocephaly, 3 with multiple suture synostosis, 3 with Crouzon, 1 with Saethre-Chatzen, 1 with Muenke, and 1 with Shprintzen. In 10 patients, CT findings suggested increased ICP or papilledema. Symptoms resolved in most patients. This series is left out of consideration in view of the heterogeneity of the study population (syndromic/nonsyndromic; earlier operation or not) and the indistinct criteria for increased ICP.

Marucci¹⁰⁹ describes 81 patients with scaphocephaly who underwent limited cranial surgery before 6 months of age. Seven patients developed a progressive vertex bulge at the site of the

former anterior fontanel within an average of 8 months postoperatively. Five patients underwent invasive ICP measurement, and ICP was elevated in 4 of them. Five patients had progressive synostosis and 2 were positive for *FGFR2* mutations (of whom 1 was known with hypochondroplasia). Intracranial pressure was measured in 3 of the 5 eventually true nonsyndromic scaphocephaly patients, and was found to be raised in 1.

Florisson¹¹⁰ describes a retrospective study of 205 consecutive patients with a non-syndromic unsutural craniosynostosis, treated between January 2003 and June 2007, and in whom preoperatively 1 or 2 fundoscopies were performed by protocol. This revealed papilledema notably in the patients with scaphocephaly and to a lesser degree in those with trigonocephaly; the youngest patient was 3 months old.

A review from 2004 on the basis of 5 studies with a total of 503 patients with scaphocephaly, trigonocephaly, or plagiocephaly reports a 4% to 14% increased ICP range, with increased ICP defined as ICP >15 mm Hg.²⁴⁰

In summary, the risk of increased ICP seems to be 12% in scaphocephaly, 9% in trigonocephaly, and 10% in plagiocephaly. The range is larger for trigonocephaly (0%–33%) as a smaller number of patients was investigated. The estimated risk for the group of bilateral coronal suture synostosis patients is 37%. In the majority of the studies it is not clear, however, whether this really concerns nonsyndromic synostosis.

Risk of increased ICP following skull remodeling is explicitly mentioned only in a retrospective study from Rotterdam in 205 consecutive patients with a nonsyndromic craniosynostosis, treated between January 2003 and June 2007.¹¹⁰ Postoperative funduscopy was performed if increased ICP had been present preoperatively, or if clinical symptoms were noted, such as headache, behavioral change, worsening of vision, deviating cranial circumference curve, or copper beaten aspect on x-ray. Postoperative funduscopy had been performed in 46 patients (22% of initial population), of whom 3 patients with scaphocephaly (27, 39, and 46 months postoperatively) and 2 patients with trigonocephaly (1 persisting papilledema already present preoperatively, and 1 patient developed papilledema 34 months postoperatively) appeared to have papilledema.

II. Syndromic Craniosynostosis.

Note 1: diagnoses mentioned in older articles (<1996) are not genetically confirmed.

PM2: the distinction between the Crouzon and Pfeiffer syndromes later appeared to be irrelevant on account of overlapping genetic abnormalities in the FGFR2 syndrome.

Also regarding syndromic craniosynostosis, most of articles on ICP are from Paris:

Renier¹⁴² performed invasive ICP measurements preoperatively in syndromic patients, that is, 23 with oxycephaly, 6 with Apert, and 2 with Crouzon syndrome. Increased ICP (>15 mm Hg) was established in 10, 3, and 2 patients, respectively. Borderline ICP (11–15 mm Hg) was present in 9, 2, and 0 patients, respectively. Normal ICP (≤ 10 mm Hg) was found in 4, 1, and 0 children, respectively. In 23 patients (nonsyndromic and syndromic) the measurement was repeated postoperatively. Intracranial pressure decreased in all 23 patients during a number of weeks. Regarding the relation between ICP and age, ICP peaked at 6 years. Seventeen patients were measured years after the operation on clinical suspicion of increased ICP, which was confirmed with the measurement. The diagnosis, however, is not mentioned.

Gault²³⁰ reported increased ICP on the basis of preoperative invasive measurement in 4 of the 5 children with a complex craniosynostosis, that is in 3 of the 4 with an oxycephaly, 2 of the 3 with Crouzon syndrome, and in the only Apert patient.

TABLE 8. Prevalence of Increased Intracranial Pressure (ICP) in Nonsyndromic Craniosynostosis Before Skull Remodeling

Number of Patients With Increased ICP/ Number of Patients Measured (%)	Number of Patients				
	Scapho	Trigono	Plagio	Brachy	Lambdoid
Renier ¹⁴²	3/23 (13)	0/5 (0)	2/9 (22)	3/7 (43)	
Gault ²³⁰	2/44 (5)	0/4 (0)	0/3 (0)	1/2 (50)	
Arnaud ¹⁴¹	19/142 (13)				
Thompson ²³¹	6/25 (24)	4/12 (33)	3/37 (8)		
Thompson ²³²	3/18 (17)	3/9 (33)	2/35 (6)	5/10 (50)	
Renier ¹²¹	34/246 (14)	3/39 (8)	8/63 (13)	10/32 (31)	
Mathijssen ¹⁰³	8/50 (16)				
Florisson ¹¹⁰	7/103 (7)	3/71 (4)	0/28 (0)	0/3 (0)	
Total 74/601 (12)	13/140 (9)	23/225 (10)	19/51 (37)	0/3 (0)	

ICP, increased intracranial pressure.

Renier¹²¹ presented an overview of more than 2137 patients with craniosynostosis. Invasive preoperative ICP measurements resulted in prevalences of 60% in oxycephaly (95 measurements), 47.1% in multiple suture synostosis (17 measurements), 62.5% in Crouzon, 45% in Apert, and 29% in “other syndromes”.

The following publications are from the center in London:

Thompson preoperatively measured ICP invasively in 53 syndromic children, that is, 20 with Crouzon, 13 with Apert, 5 with Pfeiffer, 14 with Saethre-Chotzen syndrome, 1 with a cloverleaf skull, and 11 with multiple suture synostosis.²³² Increased ICP (>15 mm Hg) was found in 35 of them, that is, 13 Crouzon, 5 Apert, 3 Pfeiffer, 6 Saethre-Chotzen, 1 cloverleaf, and 7 multiple suture synostosis patients. Borderline ICP (10–15 mm Hg) was found in 7, 7, 1, 6, and 0 patients, respectively. On the basis of plateau waves rather than only mean ICP the number of patients with increased ICP was even slightly higher.

Hayward²⁴¹ described 24-hours ICP measurements in 11 symptom-free children (5 with Pfeiffer, 2 with Crouzon, 2 with Apert, 1 with Antley-Bixler syndrome and 1 with osteopetrosis). Plateaus of ICP were exclusively seen during active sleep with an increased mean ICP in all 11 children. During quiet sleep, the mean ICP was increased (>15 mm Hg) in 5 children, borderline (10–15 mm Hg) in 3, and normal in 3.

Marucci¹⁵² described 24 patients with Apert syndrome who were operated upon not until there were signs of increased ICP, which was the case in 83% at a mean age of 18 months (range 1 month to 4 years and 5 months). Of the patients who underwent operation, 35% experienced a second episode of increased ICP at a mean age of 3 years and 4 months (range 1 year and 11 months to 5 years and 9 months). The increased ICP was defined as presence of papilledema, an abnormal VEP scan, an ICP measurement >15 mm Hg, or more than 3 plateaus in 24 hours.

Other articles are from Camperdown Australia,²³⁵ Toronto,²⁴² Pittsburgh,²⁴³ Rome,^{236–237} Würzburg Germany,⁶⁰ Boston (Greene, 2008),²⁴⁴ Chicago,²³⁸ Rotterdam,²⁴⁵ and Oxford UK.²⁴⁶

Whittle²³⁵ included 8 patients with Crouzon syndrome, 1 with Apert syndrome, and 6 with complex craniosynostosis, of whom 10

(7 Crouzon, 1 Apert, 3 complex craniosynostosis, respectively) preoperatively showed increased ICP with invasive measurement. Indications for measurement were radiologic signs of mild hydrocephalus, worsening of vision, headache or behavioral change, and are thus subject to bias.

Siddiqi²⁴² evaluated 107 syndromic children with the following diagnoses: 52 Crouzon, 33 Apert, 8 Pfeiffer, 11 Saethre-Chotzen syndrome, and 4 cloverleaf skulls. Six (6%) developed symptoms of increased ICP after initial decompression (3 with Apert, 2 with Saethre-Chotzen, and 1 with Pfeiffer syndrome), defined as papilledema (N = 4), progressive macrocephaly (N = 1), and invasive ICP measurement (N = 1). One patient required a third operation on account of recurrent increased ICP. At follow-up 3 to 7 years later, none of the 6 patients showed signs of increased ICP. In this series routine screening of increased ICP was not performed, which is a cause of strong bias. For this reason this study is not included in Table 9.

Pollack²⁴³ described follow-up of 22 children with syndromic craniosynostosis, most of whom were operated upon between the ages of 6 to 18 months. Eight children developed recurrent increased ICP, defined as papilledema (N = 3), progressive proptosis (N = 1), or other clinical symptoms (N = 3). As most of the children did not show any symptoms, routine ophthalmologic examination is recommended.

Tamburrini²³⁶ described invasive ICP measurements in 16 syndromic children with the following diagnoses: 5 Apert, 4 Crouzon, 3 Pfeiffer syndrome, 2 turricephaly, and 2 osteopetrosis. Fourteen showed increased ICP (>15 mm Hg), that is, all except 1 child with Pfeiffer syndrome and 1 child with osteopetrosis.

Tamburrini²³⁷ described invasive ICP measurements in 12 syndromic craniosynostosis patients, of whom 5 with Apert, 4 with Crouzon, and 3 with Pfeiffer syndrome. Eleven of the 12 children had increased ICP. Most likely these are the same patients as described in the 2004 article.

Kress⁶⁰ reported a 35% prevalence (24/68 patients) of increased ICP in Saethre-Chotzen syndrome on the basis of papilledema or

TABLE 9. Prevalence of Increased Intracranial Pressure (ICP) in Syndromic Craniosynostosis

	Number of Patients With Increased ICP/Number of Patients Measured (%)				
Apert	Crouzon	Pfeiffer	Saethre-Chotzen	Muenke	Complex
Renier ¹⁴²	3/6 (50)	2/2 (100)			10/23 (43)
Gault ²³⁰	1/1 (100)	2/3 (67)			7/9 (78)
Thompson ²³²	5/13 (38)	13/20 (65)	3/5 (60)	6/14 (43)	8/12 (67)
Renier ¹²¹	? (45)	? (63)			65/112 (58)
Tamburrini ²³⁶	5/5 (100)	3/4 (75)	3/3 (100)		2/2 (100)
Hayward ²⁴¹	2/2 (100)	2/2 (100)	5/5 (100)		
Kress ⁶⁰				24/68 (35)	0/42 (0)
Greene ²⁴⁴					30/39 (77)
Marucci ¹⁵²					
Preop*	20/24 (83)				
Postop	7/20 (35)				
De Jong ⁵⁴					
Preop	2/22 (9)	24/45 (53) Cr/Pf	5/26 (19)	1/28 (4)	
Postop	11/31 (35)	8/40 (20) Cr/Pf	4/24 (17)	2/38 (5)	
Woods ²⁴⁶			9/26 (35)		
Postop 1 year			8/19 (42)		
Postop 5 years					

ICP, increased intracranial pressure. Many articles are from the same centers (Paris or London) and patient populations therefore could overlap. Most studies concern preoperative measurements: few data on postoperative prevalence.

* Operation not until increased ICP.

ICP >20 mm Hg. Forty-two Muenke patients did not show papilledema, whereas 2 had increased dural tension intraoperatively.

Greene²⁴⁴ selected 39 patients with complex craniosynostosis (excluding bilateral coronal suture synostosis and pansynostosis). In this group, the risk of increased ICP was 76.9%, defined as papilledema, a deflecting cranial curve or extensive endocortical erosion on CT scan.

Foster²³⁸ investigated the occurrence of resynostosis after primary skull remodeling in 31 patients with multiple suture synostosis, 2 with Apert, 4 with Crouzon, and 5 with Saethre-Chotzen syndrome. Percentages of resynostosis were 12.9% (N = 4), 0, 25% (N = 1), 0 (N = 0), and 20% (N = 1), respectively. In 1 patient with Saethre-Chotzen syndrome and 2 with multiple suture synostoses increased ICP was found with lumbar puncture before the second cranial vault expansion.

Bannink²⁴⁵ described the prevalence, treatment outcome, and risk factors for increased ICP in 33 Apert, 43 Crouzon, and 8 Pfeiffer syndrome patients. Papilledema was documented preoperatively in 25 of 66 (38%) patients and postoperatively in 30 of 70 patients (43%). Overall, 43 of the 84 (51%) patients (12 Apert, 31 Crouzon/Pfeiffer syndrome) showed papilledema at some moment. Impressions on skull x-ray or clinical symptoms such as headache or behavior changes were not correlated with the presence of papilledema and consequently proved unreliable screening methods. Complex craniosynostosis, the diagnosis Crouzon/Pfeiffer syndrome, exorbitism, and ventricular dilatation were found to be risk factors for papilledema.

Honnebier¹⁴⁶ did not find signs of increased ICP in any of 16 patients with Muenke syndrome, but does not report in which way and how frequently this was investigated.

Woods²⁴⁶ evaluated 34 Saethre-Chotzen patients with genetically confirmed diagnosis. Nine of the 26 patients (35%) with at least 1 year follow-up developed increased ICP, as well as 8 of the 19 patients (42%) with at least 5 years follow-up, for which reoperation was needed. Increased ICP was defined as a baseline of 20 mm Hg or higher, or 4 or more B-waves. The indications for ICP measurement were papilledema, a deflecting cranial curve, headache or aggressive behavior, impressions on skull x-ray, narrow ventricles, Chiari malformation, with effaced basal cisterns and sulci spaces.

De Jong⁵⁴ reported the prevalence of increased ICP, on the basis of papilledema, per syndrome, with the population of patients with Apert and Crouzon/Pfeiffer syndromes the same as the 1 described by Bannink in 2008.²⁴⁵

The 2004 review of Bristol et al reports a 53% to 89% range of increased ICP (>15 mm Hg), based on 98 patients with syndromic craniosynostosis.²⁴⁰

In summary, the prevalence of increased ICP in syndromic craniosynostosis is considerably higher than that in nonsyndromic craniosynostosis. Preoperatively the risk seems to be approximately 40% to 50% for Apert, 50% to 70% for Crouzon and Pfeiffer, 35% to 45% for Saethre-Chotzen, 0 for Muenke syndrome, and 50% to 80% for complex craniosynostosis. Increased ICP after a previous skull remodeling is a real danger and is estimated at 35% to 43% in Apert, Crouzon, Pfeiffer, and Saethre-Chotzen syndromes. This has not been investigated for complex synostosis. In Apert syndrome patients, the mean age during the second episode of increased ICP was 3 years and 4 months with a maximum of nearly 6 years.¹⁵² In Saethre-Chotzen the second operation on account of increased ICP was performed at a mean age of 3.4 years, with a maximum of 8.5 years.²⁴⁶

Screening

The different methods to determine the ICP consist of invasive measurements during 1 night and minimally 12 hours (such as epidural sensor or lumbar puncture), fundoscopy, VEP-scan, or

CT-scan (endocortical erosion). Increased ICP is almost routinely defined as a baseline above 15 mm Hg during slow wave sleep or more than 3 plateau waves. Eide²⁴⁷ compared the mean ICP with the number of peak ICPs above 20 mm Hg and is of the opinion that the mean ICP does not do justice to the full ICP measurement. The number of ICPs peaking above 20 mm Hg that should be considered abnormal cannot be ascertained. The definition of a plateau varies by author: The minimal level ranges from 20 to 35 mm Hg, the duration from 5 to 20 minutes.

I. Nonsyndromic Craniosynostosis.

Tuite²⁴⁸ compared in 74 children with nonsyndromic craniosynostosis the presence of signs of increased pressure on skull x-ray with invasive ICP measurement. Children with increased ICP more often showed diffuse impressions, diastasis of the sutures and erosion of the sella tursica. The sensitivity was very low, however, and therefore these are unreliable screening methods for increased ICP.

Tuite²⁴⁹ compared 58 patients with nonsyndromic synostosis and 55 patients with syndromic, 9 with multiple suture synostosis. Papilledema was established in 15 patients: 11 with syndromic synostosis, 2 with multisuture synostosis, 1 with trigonocephaly, and 1 with plagiocephaly. On the basis of an invasive measurement, 41 patients had increased ICP, 13 of whom showed papilledema. In children above the age of 8 years papilledema was specific and sensitive. Sensitivity at lower age was only 22%. Consequently, in this young group the absence of papilledema is no guarantee for normal ICP, but on the other hand the presence of papilledema is an evident sign of increased ICP.

Stavrou (1997)²²⁹ reported on 9 children, among whom 1 with plagiocephaly, 1 with trigonocephaly and 1 with scaphocephaly, age range 1 to 6 years, who showed lowering of vision as a consequence of an increased ICP.

Tamburrini²³⁷ concludes in a review of the literature that assessing the mean ICP during sleep in combination with plateau waves is the most reliable method indicating increased ICP.

Eide²⁵⁰ demonstrated in patients with shunt failure, hydrocephalus or craniosynostosis that there is no relation between ventricle size on CT scan and increased ICP. Also the change in ventricle size is no predictor of ICP changes.

Marucci¹⁰⁹ described that a progressive vertex bulge at the site of the former anterior fontanel in scaphocephaly patients after early and limited skull remodeling may be a sign of increased ICP.

In conclusion, it is not known how often a deflecting cranial circumference growth curve is related to an increased ICP and consequently it is hard to tell how useful it would be to include this parameter in the follow-up program. Radiologic findings such as impressions, ventricle size, or changes therein are unreliable as a screening method for increased ICP. Papilledema found with fundoscopy is highly probably a sign of increased ICP,²⁵¹ but its absence does not exclude an increased ICP. The reliability of fundoscopy seems to be age-related, although described in only one study. A VEP scan could show signs of increased ICP or onset of optical nerve injury at an early stage, before papilledema develops,²⁵² but this technique has not been proven with the use of invasive ICP measurements. In addition, a high percentage of abnormal VEP scans (24%) were reported in a population of predominantly nonsyndromic craniosynostosis patients, which is higher than the proportions reported in other studies using invasive ICP measurements.

Invasive ICP measurement remains the gold standard, but naturally has disadvantages such as the need of anesthesia, surgical intervention with risk of complications, and admission to an intensive or high care unit. Generally, the threshold is set at a baseline ICP exceeding 15 mm Hg or more than 3 plateau waves,

irrespective of the age of the patient. The scientific underpinning of this threshold is unclear, but it is adhered to by nearly all experts.

II. Syndromic Craniosynostosis.

Fok²⁵³ and Gault²⁵⁴ demonstrated in syndromic children that the intracranial volume is no reliable predictor for the ICP.

Gupta prospectively follows the optical nerve of 33 patients with nonsyndromic and syndromic craniosynostosis with the use of VEP, echographic thickness measurement and fluorescence angiography.²⁵⁵ Notably, multiple suture synostosis and exorbitism correlated with injury to the optical nerve as a result of papilledema. The VEP scans of all 5 patients with optic atrophy showed a prolonged latency period. Fluorescence angiography is useful to diagnose onset papilledema. Optical nerve thickness measurements are useful in the follow-up of papilledema. The added value of VEP scans with respect to funduscopy is not made clear.

Campbell²⁵⁶ presented a patient with Pfeiffer syndrome who underwent skull remodeling on account of papilledema, after which the papilledema resolved but vision gradually worsened. Invasive measurement still evidenced increased ICP in spite of the absence of papilledema. Unexplained lowering of vision may therefore be an indication for invasive ICP measurement, because absence of papilledema is no guarantee for normal ICP.

Tuite²⁴⁸ compared in 49 children with syndromic craniosynostosis the presence of signs of increased pressure on skull x-ray with invasive ICP measurement. Children with increased ICP more often showed diffuse impressions, diastasis of the sutures and erosion of the sella tursica. The sensitivity was very low, however, and therefore these are unreliable methods for screening on increased ICP.

Tuite²⁴⁹ compared 58 patients with non-syndromic synostosis and 55 patients with syndromic, 9 with multiple suture synostoses. Papilledema was established in 15 patients: 11 with syndromic synostosis, 2 with multisuture synostosis, 1 with trigonocephaly and 1 with plagiocephaly. On the basis of an invasive measurement 41 patients had increased ICP, 13 of whom showed papilledema. In children above the age of 8 years papilledema was specific and sensitive. Sensitivity at lower age was only 22%. Consequently, in this young group the absence of papilledema is no guarantee for normal ICP, but on the other hand the presence of papilledema is an evident sign of increased ICP.

Pollack²⁴³ described 22 syndromic children who routinely underwent ophthalmologic screening for increased ICP preoperatively and 6-month postoperatively. Papilledema was found preoperatively in 4 and postoperatively in 8 at a mean age of 16.5 months. Only 3 of these 8 showed clinical symptoms, which implies that this is an unreliable screening method.

Stavrou²²⁹ reported on 9 children, among whom 4 with Crouzon syndrome and 2 with complex craniosynostosis, age range 1 to 6 years, who showed lowering of vision as a consequence of increased ICP.

Connolly²⁵⁷ described selected patients with multiple suture synostosis and signs of increased ICP. Most of them had Crouzon syndrome (confirmed by *FGFR2* mutation) and generally showed a normal skull shape at birth with progressive synostosis. Increased ICP presented in these patients approximately at the age of 5 years. The authors recommended frequent screening using funduscopy but did not indicate frequency or age limit.

Hoefkens²⁵⁸ described 9 Crouzon syndrome children with postnatal synostosis, of whom 9 showed impressions on skull x-ray, 7 developed a bregma at the anterior fontanel, and 4 papilledema.

Tamburrini²³⁷ concludes in a review of the literature that assessing the mean ICP during sleep in combination with plateau waves is the most reliable method indicating increased ICP.

Liasis²⁵⁹ compares 3 ophthalmologic methods, viz. vision, funduscopy, and VEP scan in 8 syndromic children. All 8 showed a decrease in N80 to P100 amplitude preceding surgery and an increase postoperatively. Funduscopy showed no abnormalities in 3 patients, progressive bilateral swelling in 3, and unilateral swelling in 2 patients. Vision worsened in 1, improved in 4, and fluctuated in 2 patients, preoperatively. Invasive measurement demonstrated increased ICP in 3 of the 8 children, of whom 1 showed abnormal fundus, 1 unilateral papilledema, and 1 unnatural paleness of the papilla. The authors conclude that solely vision or funduscopy is insufficient and that VEP will timely detect vision abnormalities. This article, however, provides only little evidence for this!

Marucci¹⁵² described 24 patients with Apert syndrome who were operated upon not until there were signs of increased ICP, which was the case in 83% at a mean age of 18 months (range 1 month to 4 years and 5 months). Of the patients who underwent operation, 35% experienced a second episode of increased ICP at a mean age of 3 years and 4 months (range 1 year and 11 months to 5 years and 9 months). The increased ICP was defined as presence of papilledema, an abnormal VEP scan, an ICP measurement >15 mm Hg, or more than 3 plateaus in 24 hours.

Bannink²⁴⁵ demonstrated that the presence of papilledema is not associated with clinical symptoms such as vomiting, headache, vision, or behavior change.

Woods²⁴⁶ evaluated 34 Saethre-Chotzen patients with genetically confirmed diagnosis. The indications for ICP measurement were papilledema, a deflecting cranial curve, headache or aggressive behavior, impressions on skull x-ray, narrow ventricles, Chiari malformation, with effaced basal cisterns, and sulci spaces. Of the 9 patients with increased ICP, 3 showed papilledema, 6 delayed skull growth, 5 headache or aggressive behavior, and 8 signs of increased pressure on CT. The eldest patient with increased ICP was 9 years old.

In conclusion, clinical symptoms do not seem to be reliable screening methods for increased ICP. Also in syndromic craniosynostosis radiologic findings are an unreliable screening method for increased ICP. The finding of papilledema on funduscopy is highly probably a sign of increased ICP, but its absence does not exclude increased ICP. The reliability of a funduscopy seems to be age related, although this is addressed in only 1 study. Visual evoked potential as screening method is reported by only 1 center and its reliability is therefore hard to assess. An invasive ICP measurement remains the gold standard, but naturally has disadvantages, such as the need of anesthesia, surgical intervention with risk of complications, and admission to an intensive or high care unit. Generally, the threshold is set at a baseline ICP exceeding 15 mm Hg or more than 3 plateau waves, irrespective of the age of the patient. The scientific underpinning of this threshold is unclear, but it is adhered to by nearly all experts.

Prevention and/or Treatment

Generally a cranial vault expansion is performed within the first year of life. A number of studies have shown that the prevalence of increased ICP increases if the operation is performed after the first year of life. This has been demonstrated for scaphocephaly¹⁴¹ and plagiocephaly.¹⁰³

The London center pursues a policy by which a patient with Apert syndrome is operated upon not until there were signs of increased ICP.¹⁵² Of the 24 patients, 83% developed increased ICP at a mean age of 18 months (range 1 month to 4 years and 5 months). Of these patients, 35% experienced a second episode of increased ICP at a mean age of 3 years and 4 months.

The percentage of recurrent increased ICP is not essentially different from the percentages reported by teams performing a

protocolized cranial vault expansion.²⁴⁵ It therefore seems likely that an early cranial vault expansion is effective both preventively (for approximately 3 years) and therapeutically. The London center policy has the advantage that a small number of patients eventually does not undergo skull remodeling, but is it disadvantageous in that patients need to be screened for signs of increased ICP very frequently, for which there is no watertight method.

If increased ICP is established again at follow-up after an initial cranial vault expansion, treatment may consist either of a second cranial vault expansion or VP-drain insertion. The choice depends, among other things, on the presence of progressive ventriculomegaly (see chapter on hydrocephalus). As there is a relation between ICP and OSAS it is important to determine the presence and severity of OSAS in case of confirmed increased ICP, as treatment can be adjusted to this.^{260,261} Please refer to the chapter on OSAS.

Conclusions

Level 2 The prevalence of preoperatively increased ICP in nonsyndromic craniosynostosis is 12% (range 5%–24%) in scaphocephaly, 9% (range 0%–33%) in trigonocephaly, 10% (range 0%–22%) in plagiocephaly, and 37% (range 31%–50%) in bilateral coronal suture synostosis.

*B Renier, 1982*¹⁴²
*B Gault, 1992*²³⁰
*B Arnaud, 1995*¹⁴¹
*B Thompson, 1995*²³¹
*B Thompson, 1995*²³²
*B Mathijssen, 2006*¹⁰³
*C Florisson, 2010*¹¹⁰
*C Renier, 2000*¹²¹

Level 2 The prevalence of preoperatively increased ICP in syndromic craniosynostosis is 40%–50% in Apert, 50%–70% in Crouzon and Pfeiffer, 35%–45% in Saethre-Chotzen syndrome, 50%–80% in complex craniosynostosis, and zero in Muenke syndrome. Increased ICP after an earlier cranial vault expansion is estimated at 35%–43% in Apert, Crouzon, Pfeiffer, and Saethre-Chotzen syndromes.

*B Renier, 1982*¹⁴²
*B Gault, 1992*²³⁰
*B Thompson, 1995*²³²
*C Renier, 2000*¹²¹
*C Tamburrini, 2004*²³⁶
*C Hayward, 2005*²⁴¹
*C Kress, 2006*⁶⁰
*C Greene, 2008*²⁴⁴
*C Marucci, 2008*¹⁵²
*C Bannink, 2008*²⁴⁵
*C Woods, 2009*²⁴⁶

Level 2 Clinical symptoms and radiologic findings are unreliable screening methods for increased ICP. A progressive vertex bulge at the site of the former anterior fontanel may indicate increased ICP. Papilledema is an evident sign of increased ICP, but its absence does not exclude increased ICP.

*B Tuite, 1996*²⁴⁸
*B Tuite, 1996*²⁴⁹
*B Eide, 2002*²⁴⁷
*C Tamburrini, 2005*²³⁷
*C Pollack, 1996*²⁴³
*C Bannink, 2008*²⁴⁵
*C Marucci, 2008*¹⁵²
*C Woods, 2009*²⁴⁶

Level 3 An invasive ICP measurement remains the gold standard, but is associated with disadvantages and complications, and is not recommended as routine screening method. Increased ICP is defined as a baseline ICP >15 mm Hg (measured at least 12 hours during sleep) and/or minimally 3 plateau waves with ICP >35 mm Hg, during at least 20 minutes.

*C Tamburrini, 2005*²³⁷
*C Pollack, 1996*²⁴³
*C Marucci, 2008*¹⁵²
*C Woods, 2009*²⁴⁶

Level 3 Patients with a nonsyndromic craniosynostosis seem to have a small risk of developing increased ICP after initial cranial vault expansion, which may result in lowering of vision.

*C Florisson, 2010*¹¹⁰
*C Stavrou, 1997*²²⁹
*C Marucci, 2008*¹⁵²

Level 3 VEP scans may have added value in screening for increased ICP, next to fundoscopy.

*C Gupta, 2003*²⁵⁵
*C Liasis, 2006*²⁵⁹

Considerations

In spite of the fact that patients with a nonsyndromic craniosynostosis only have a relatively small risk of developing increased ICP with risk of loss of vision, this is a contributing reason to recommend operation, apart from the esthetic aspect. Also if operation is decided against it is of importance to frequently monitor the child for signs of increased ICP until the age of 6 years (at least once a year). The craniofacial team in Rotterdam has occasionally encountered papilledema in children with nonsyndromic craniosynostosis after cranial vault expansion until a maximum age of 6 years. At the time of this writing, there are no studies providing scientific underpinning for the maximum age until when increased ICP in nonsyndromic craniosynostosis should be monitored.

Muenke syndrome seems to distinguish itself from the other syndromic types of craniosynostosis by a slight risk of increased ICP. For this reason, I may consider to perform skull remodeling somewhat later than is common for syndromic craniosynostosis, which strategy seems to reduce the risk of recurrence of the deformity (see chapter 6).

Performing a cranial vault expansion by protocol in syndromic craniosynostosis, notably in Crouzon, Pfeiffer, Apert, and Saethre-Chotzen syndromes, seems justified in view of the high risk of increased ICP. A wait-and-see policy, implying surgical intervention only when increased ICP has been demonstrated, requires very intensive ophthalmologic monitoring, and does hardly reduce the indication for surgery. Moreover, there are no noninvasive screening methods that are 100% reliable.

Confirming papilledema by means of fundoscopy requires great experience. Reliability of the fundoscopy is better guaranteed when it is performed by an ophthalmologist with experience in this procedure in children.

Decision making on invasive ICP measurement should weigh the risks, burden for patient and parents, and deployment of resources (operation time, ICU-admission, anesthesia, and costs) against the added value of this measurement. Invasive ICP measurement is worth considering if the ICP level is decisive for performing an initial operation or reoperation, or in case of unexplained lowering of vision without papilledema. The project group is of the opinion that routine invasive ICP measurement is not indicated.

In view of the great risk of (recurrent) increased ICP, among other things, in syndromic craniosynostosis, treatment by a multidisciplinary team is recommended, in which one person is functioning as primary treating physician and is provided with all relevant information by the other team members, such as test results that are suggestive of increased ICP.

Recommendations

In nonsyndromic craniosynostosis, screening for increased ICP is recommended, by means of fundoscopy before the initial skull remodeling and in follow-up at the ages of 2 years and 4 years.

In syndromic craniosynostosis, screening for increased ICP is required, by means of fundoscopy before the initial skull remodeling and yearly until the age of 6 years. Muenke syndrome seems to be an exception to this requirement, but in view of the limited scientific underpinning the same recommendation is made.

Fundoscopy requires experience and is performed by an ophthalmologist, who will inform the primary treating physician of the results.

The finding of papilledema should be followed by a CT or MRI scan to assess changes in ventricle size (hydrocephalus). Other pathology that could contribute to an increased ICP, such as OSAS, is excluded. An invasive ICP measurement should be considered in case of unexplained lowering of vision, progressive vertex bulge without papilledema, or doubt about the degree of ICP increase in the decision making on reoperation.

The treatment of increased ICP is governed by the causal factors and should be geared to these.

9. HYDROCEPHALUS

Basic Questions

1. What are the prevalence, the causes, and the consequences of hydrocephalus in the different types of syndromic craniosynostosis?
2. What screening method (type and frequency) is indicated to timely detect hydrocephalus?
3. When is the treatment indicated and what is the appropriate treatment for hydrocephalus?

Introduction

Patients with a syndromic craniosynostosis may be at risk of developing hydrocephalus, which risk seems to be syndrome dependent. Specific screening methods are needed because craniosynostosis-related hydrocephalus develops gradually and the classic signs of hydrocephalus are often absent. Treatment of hydrocephalus is discussed in this chapter as well, as it should be specifically geared to this patient population.

Hydrocephalus occurs in more than one third of patients with syndromic craniosynostosis. It is very rare in nonsyndromic craniosynostosis, with an incidence not exceeding that in the general population.^{262–265}

The cause of expanded brain ventricles in craniosynostosis is not clear.

In clinical practice, it is hard to recognize hydrocephalus, as the classic signs of hydrocephalus or ICP may be fully absent.

Patients in whom expanded brain ventricles occur without increased pressure, as often seen in Apert syndrome, should be distinguished from cases in which expanded brain ventricles do occur with ICP, such as seen in the Crouzon and Pfeiffer syndromes. Shunt placement or cranial decompression is indicated in the latter patients to prevent papilledema and blindness.

Summary of the Literature

The current literature probably does not provide information on the real incidence. Because skull remodeling operations exert an

effect on ventricle width, only serial measurements are believed to be reliable. Serial measurements are reported in a few articles, but only in small groups of patients.^{264–266} Furthermore, the classic methods of measuring ventricle width are not useful if head shape and ventricle shape are abnormal.²⁶⁷ Volumetric measurements of the ventricular system or CSF/brain ratios, which would be more accurate in these patients, have not yet been described so far.

Taking these limitations into account, the literature does make clear that ventricle dilatation mainly occurs in syndromic craniosynostosis, that is, 30% to 70% in Crouzon and Pfeiffer syndromes^{262–264} and 40% to 90% in Apert syndrome.^{263–265,268} Hydrocephalus is occasionally reported in rare craniofacial syndromes such as Shprintzen-Goldberg syndrome.²⁶⁹ Hydrocephalus is incidentally found in isolated craniosynostosis, yet always on the basis of coincidental causes.^{262,263,270}

It remains unclear why hydrocephalus should develop in craniofacial malformations. Two mechanisms have been suggested: high liquid pressure owing to impaired venous drainage; and too small posterior cranial fossa with poor liquid drainage from the fourth ventricle. Hydrocephalus often co-occurs with Chiari I malformation. As Chiari I malformation develops earlier than the hydrocephalus, it is plausible that the small posterior cranial fossa should cause Chiari I malformation, which in turn may give rise to hydrocephalus.^{270–273} The progression rate of hydrocephalus also seems to be determined by the severity of the Chiari I malformation.²⁶³

Indications for aqueduct stenosis are not found.^{273,274}

Hydrocephalus also occurs, however, in the absence of Chiari I malformation, or may persist after decompression of the Chiari I malformation. In these patients, the hydrocephalus is perhaps the result of impairment of fluid resorption associated with impaired venous drainage.^{275,276} Angiography and CT-V can show the presence of extensive venous collaterals in syndromic craniosynostosis.¹⁴⁸ The presence of these collaterals is suggestive of impaired venous drainage. Cinalli²⁶² reported jugular vein stenosis.

Hydrocephalus is defined as a progressive increase of ventricle width, associated with signs of ICP. This should be distinguished from ventriculomegaly without ICP.^{262,264,267,270} The cause of ventriculomegaly is unknown as well. Brain maldevelopment has been suggested, or either atrophy or adaptation of the ventricular system to the abnormal head shape.^{264–267} The latter theory is also supported by the finding of a wider subarachnoid space at the level of the largest cranial deformation.

The clinical symptoms of hydrocephalus in craniosynostosis may cause confusion. Often the classic symptoms are absent and is only gradually developing papilledema seen.

The literature does not provide recommendations on the systematic screening for hydrocephalus. Collmann proposes a pragmatic approach in which routine MRI and MR venography are performed on the guidance of risk factors present, that is complex syndromic craniosynostosis, notably the Crouzon and Pfeiffer syndromes, lambdoid suture stenosis, crowded posterior fossa, and Chiari I malformation.²⁶³ Patients showing tonsillar herniation or increased ventricle width should be regularly monitored for signs of high pressure, notably papilledema. Frequency of monitoring is not mentioned.

Treatment is only indicated in case of increased ICP or progressively increasing ventricle width. Shunt placement produces an effect counter to the 1 intended in the treatment of craniosynostosis, that is, cranial expansion. Order and timing of treatment modalities have never been systematically investigated. Renier²⁷⁷ recommends performing cranial vault expansion first, and then to proceed to shunt placement—provided this is clinically feasible. Collmann draws the attention to the fact that ventricle width increases after each cranial vault expansion, a phenomenon which

should be distinguished from genuine hydrocephalus. Shunt placement is only indicated if increased ICP should persist and papilledema, in spite of adequate cranial vault expansion, should still be present after several weeks.^{263,270,278} In view of possible dislocation of bone fragments, Collmann²⁶³ recommends delaying shunt placement to at least 2 months after the cranial vault expansion.

The following alternative treatment methods for hydrocephalus are available: posterior cranial fossa decompression, Chiari I malformation decompression, and third ventriculocisternostomy. Still, posterior cranial fossa decompression does not always exert a favorable effect on hydrocephalus. Renier²⁷⁷ labels it as a challenging intervention which should be reserved for those patients when symptoms of tonsillar herniation are evident. Ventriculocisternostomy is not mentioned in the literature for this indication. Lumbo-peritoneal shunt presents a risk in case of tonsillar herniation.^{30,263}

There are no studies on the best way to organize follow-up of hydrocephalus. In view of the specific problems it would seem advisable to consult a neurosurgeon as soon as the MRI/MR-A shows indications for progressively increasing ventricle width and in the case of persisting papilledema. The same holds true if a shunt was placed indeed, as the diagnosis of anomalous drainage can be misleading.

Conclusions

- Level 3** The incidence of ventriculomegaly is probably 30% to 70% in Crouzon/Pfeiffer and 40% to 90% in Apert syndrome, but progressively increasing ventricle width with high ICP is more frequently seen in Crouzon/Pfeiffer syndrome than in Apert syndrome.
*C Cinalli, 1998*²⁶²
C Noetzel, 1985
*C Cohen, 1990*²⁶⁷
*C Renier, 1996*²⁷⁷
*C Hanieh, 1993*²⁶⁸
*C Collmann, 2005*²⁶³
- Level 3** Hydrocephalus is probably caused by impaired venous drainage and a too small posterior cranial fossa with Chiari I malformation and impairment of fluid resorption as a consequence.
*B Cinalli, 1998*²⁶²
*C Cinalli, 1995*²⁷¹
*C Sainte-rose, 1984*²⁷⁶
*C Thompson, 1997*²⁷³
*C Jeevan, 2008*¹⁴⁸
*C Francis, 1992*²⁷²
*C Taylor, 2001*²⁷⁵
*C Collmann, 2005*²⁶³
- Level 3** It is probably the case that MRI and MR-V screening for progressively increasing ventricle width is indicated in patients showing risk factors and/or papilledema.
*B Cinalli, 1998*²⁶²
*C Gosain, 1996*²⁷⁸
- Level 3** In principle, shunting is counterproductive to cranial vault expansion.
*C Collmann, 2005*²⁶³
*C Renier 2006*²⁷⁷

Considerations

Although there is no published evidence that shunting is counterproductive to cranial vault expansion, this is nevertheless highly likely. The consequence of this supposition is that cranial vault expansion is to be preferred during shunting in case of dilated brain ventricles with signs of increased pressure. Even if an initial cranial vault expansion has already been performed it is worth considering if a second cranial vault expansion is indicated or feasible: for example in case of skull growth retardation, persisting small cranial

volume, and insufficient or cosmetically less appealing initial correction. Shunt placement should be considered only if the cranial volume has proven to be sufficient.

Recommendations

Hydrocephalus should be differentiated from ventriculomegaly using serial imaging.

Magnetic resonance image-scanning before the first cranial correction is indicated for all patients with syndromic or complex craniosynostosis. Ventriculomegaly is to be monitored using MRI-scanning and sixth-monthly fundoscopy. Progressively increasing ventricle width or papilledema is managed according to a multidisciplinary treatment plan.

Shunting is counterproductive to cranial vault expansion. This is why in hydrocephalus, too, all efforts should be directed at treating increased ICP by means of cranial vault expansion. Placement of a shunt is indicated if high ICP should persist for a prolonged time (2 months) after adequate cranial vault expansion.

10. CHIARI I MALFORMATION

Basic Questions

1. What is the prevalence of Chiari I malformation in the different types of syndromic craniosynostosis?
2. What screening method (type and frequency) is indicated to timely detect Chiari I malformation?
3. How to prevent or treat this associated pathology?

Introduction

The risk of Chiari I malformation widely varies between the different types of syndromic craniosynostosis. The prevalence, causes, consequences, and need of preventive treatment are largely unclear—and even the definition is not unambiguous. Chiari I malformation is best demonstrated using MRI-scanning. The optimal frequency of scanning for the different types of craniosynostosis, however, is not known, and it is not clear what treatment is indicated—and when.

Summary of the Literature Prevalence

Cinalli²⁷¹ reported a 72.7% prevalence of chronic tonsillar herniation in 44 patients with Crouzon syndrome and a 1.9% prevalence in 51 patients with Apert syndrome, demonstrated on MRI scans. Ages varied from 3 months to 30 years. Tonsillar herniation was defined as absence of the cerebellomedullary cistern, asymmetry, and relocation of the brainstem or cerebellar tonsils herniating more than 2 mm under the line joining the basion to the opisthion. Premature synostosis of the lambdoid sutures (within the first 24 months of life) seems to be associated with tonsillar herniation.

Thompson²⁷³ shows in 10 patients a relation between extent of tonsillar herniation and level of intracranial pressure and volume of the posterior cranial fossa. This volume was determined with a two-dimensional method, however. All 4 patients with a hydrocephalus also showed tonsillar herniation.

A review article by Cinalli²⁷⁹ reports the following prevalence rates: 70% in Crouzon syndrome, 75% in oxycephaly, 50% in Pfeiffer syndrome, 100% in cloverleaf skull, and rare in Apert

syndrome. Although Chiari I malformation is present in 88% of the syndromic craniosynostosis patients with hydrocephalus, 53% of the children with a Chiari I malformation do not show hydrocephalus. Chiari I malformation develops earlier than hydrocephalus and therefore seems to be a prerequisite for the development of hydrocephalus. Nevertheless, another contributing factor is essential for the development of hydrocephalus.

Fearon¹⁴⁷ found a Chiari I malformation in 23 of 28 (82%) patients with Pfeiffer syndrome. Eleven patients of this group were genetically tested: 9 had a *FGFR2* mutation, 1 a *FGFR1* mutation, and 1 none. There is a reason; therefore, to question the diagnosis of Pfeiffer in this article, and it would certainly not seem useful to distinguish it from Crouzon syndrome.

Screening

The review article of Cinalli²⁷⁹ recommends MRI-scanning in the syndromic craniosynostosis group with a high risk of Chiari I malformation, but preferred ages or frequencies are not mentioned. Synostosis of the lambdoid sutures within the first 24 months of life seems to be a risk factor for Chiari I malformation.

In an earlier study by Cinalli²⁷¹ no more than 19% (6/44) of the Crouzon patients with tonsillar herniation were symptomatic. In the review article of Cinalli,²⁷⁹ more than one third of the patients had developed symptoms of Chiari I malformation or syringomyelia at later age. Symptoms included suboccipital pain, painful torticollis, syringomyelia syndrome, respiratory arrest, life-threatening brain-stem dysfunction, and axial hypotonia. Symptoms may develop rapidly, especially in very young children: breathing problems (central apneas), bilateral vocal cord paralysis, bulbar palsy, ventilatory control problems, persisting cyanosis, and breath-holding spells.

In a study by Fearon,¹⁴⁷ 10 of the 28 Pfeiffer patients underwent operative decompression in Chiari I malformation on account of swallowing and coordination problems, headache when coughing, syrinx formation, and central apneas. Protocolled screening with annual MRI until adulthood is recommended without further underpinning.

Prevention or Treatment

Cinalli²⁷⁴ describes an operative technique combining occipital expansion with suboccipital decompression in 4 patients with syndromic craniosynostosis and Chiari I malformation. In all 4 patients, however, the Chiari I malformation remained present. The authors who commented on the article (J. Venes, M. Choux, T.H. Milhorat, A.H. Menezes, and D.A. Bruce) mainly address the question whether surgical correction is actually indicated in asymptomatic Chiari I malformation. They suggest that occipital expansion as primary surgical intervention could possibly prevent the development of Chiari I malformation. No later studies have confirmed or rejected this supposition.

Fearon²⁸⁰ describes 5 syndromic children with Chiari I malformation who underwent frontal advancement. Radiologic characteristics on MRI improved in all 5, postoperatively. The presence of Chiari I malformation is considered a relative indication for decompression.

Cinalli²⁷⁹ prefers an occipital cranial vault expansion as primary surgical procedure in patients at risk of Chiari I malformation. In selected patients, occipital expansion to correct the occipital cranial deformity and repair of the Chiari I malformation by suboccipital decompression can be combined in 1 operation. If the Chiari I malformation develops later, venous drainage must be evaluated before occipital decompression is performed. The venous drainage system of the posterior fossa may be abnormal in the sense that venous drainage of the brains is dependent on collateral emissary veins.

Jeevan¹⁴⁸ reports this phenomenon in 9 of the 11 evaluated Crouzon/Pfeiffer patients, in 4 of whom this appeared to be the major drainage system for the brains. The authors recommend venographic studies as part of the preoperative evaluation of occipital decompression for Chiari I malformation. Al-Otibi²⁸¹ and Sandberg²⁸² describe that for this reason occipital decompression was withheld in 3 patients with Chiari I malformation (2 with Crouzon/Pfeiffer syndrome and 1 with osteogenesis imperfecta). Thompson presents a patient with a cloverleaf skull syndrome in whom division of occipital emissary veins during elevation of the skin flap led to an acute rise in ICP, resulting in death of the patient.²³⁴

Martinez²⁸³ describes a complication of occipital decompression in a Crouzon patient with Chiari I malformation, that is, an arteriovenous fistula over the mastoid region.

Conclusions

- Level 2** The prevalence rate of Chiari I malformation in Crouzon/Pfeiffer syndrome is 70% and is very low in Apert syndrome.
*B Cinalli, 1995*²⁷¹
*C Cinalli, 2005*²⁷⁹
- Level 3** Chiari I malformation in syndromic craniosynostosis mostly seems asymptomatic and can only be established using diagnostic radiology, preferably MRI.
*C Cinalli, 2005*²⁷⁹
*C Fearon, 2001*²⁸⁰
- Level 3** Patients with Crouzon/Pfeiffer syndrome often show abnormal intracranial-to-extracranial venous drainage on which the brains may be dependent.
*C Jeevan, 2008*¹⁴⁸
*C Al-Otibi, 2007*²⁸¹
*C Sandberg, 2007*²⁸²
*D Thompson, 1995*²³⁴
- Level 3** There are indications that surgical treatment of asymptomatic Chiari I malformation is not proven indicated or effective, but instead may be associated with risk of complications.
*C Cinalli, 1998*²⁷⁴
*D Martinez, 1996*²⁸³
*D Thompson, 1995*²³⁴

Considerations

Reliable information on the prevalence of Chiari I malformation in Saethre-Chotzen syndrome, Muenke syndrome or complex craniosynostosis is not available. The working group asserts that annual screening for symptoms and MRI-scanning at ages 0 and 4 years is indicated in these groups of patients, until a new recommendation is justified based on evidence from scientific publications.

The working group considers it appropriate that the responsible physician should request a baseline-MRI at the first referral of Crouzon/Pfeiffer patients, followed by a check-up MRI at the age of 4 years. As the literature describes a relation between premature fusion of the lambdoid sutures and the development of Chiari I malformation, and in view of the fact that this fusion typically takes place approximately the second year of life, MRI-scanning at the age of 2 years may be indicated. The consequences of Chiari I malformation in this group of patients are not yet clear, and routine scanning is therefore not yet recommended. From ongoing research it appears that 80% of the MRI-scans in children with syndromic craniosynostosis at the ages from 6 to 12 years show brain abnormalities. This is notably the case in Chiari I malformation in Crouzon patients.

Symptoms consistent with Chiari I malformation should be assessed during the annual follow-up visits, and further examination by the pediatric neurosurgeon is indicated upon suspicion of Chiari I

malformation. The pediatric neurosurgeon informs the responsible physician about the findings, which may be reason to adapt the follow-up program.

Recommendations

Screening for the presence of Chiari I malformation in patients with Crouzon/Pfeiffer syndrome by means of MRI-scanning is strongly recommended, that is, at the ages of 0 and 4 years and on clinical suspicion of asymptomatic Chiari I malformation.

Surgical treatment of Chiari I malformation is recommended only when the patient shows symptoms. Otherwise, active follow-up is indicated with annual evaluation by the pediatric neurosurgeon or pediatric neurologist of neurologic signs or symptoms, and, on indication, MRI-scanning and instructions to the parents.

If occipital decompression for Chiari I malformation is indicated, absence or presence of abnormal occipital venous drainage should be demonstrated preoperatively with CT-V or MR-V.

11. VISION, REFRACTION, AND MOTILITY ABNORMALITIES

Basic Questions

1. What is the prevalence of vision and motility abnormalities in the different types of nonsyndromic and syndromic craniosynostosis?
2. What screening method is indicated to timely detect vision and motility abnormalities?

Introduction

Impaired vision in craniosynostosis is caused by optic atrophy secondarily to papilledema in increased ICP, primary optic atrophy, corneal abnormalities in lagophthalmos, or amblyopia secondarily to strabismus or refractive errors. Early detection and management of these abnormalities is essential to retain vision.

Papilledema is discussed above in the chapter on intracranial pressure, and exorbitism and hypertelorism are discussed in the chapter on facial deformities. These aspects are left out of consideration in the current chapter.

Summary of the Literature

Nonsyndromic Craniosynostosis

Only 2 studies report on ocular abnormalities in the various types of nonsyndromic craniosynostosis and both concern small patient groups, as shown in Tables 10 and 11.^{255,284} The 29 patients reported by Vasco²⁸⁴ had no refractive errors and all 29 had normal vision 12 months postoperatively. The most frequent abnormality found 12 months postoperatively was strabismus in patients with unicoronal craniosynostosis.

Two other studies only report findings in patients with unicoronal craniosynostosis.

Tarczy-Hornoch describes 25 patients with unicoronal craniosynostosis, of whom 56% showed amblyogenic anisometropia, and

TABLE 10. Prevalence of Strabismus in NonSyndromic Craniosynostosis

	Coronal	Sagittal	Metopic
Gupta ²⁵⁵	2/7	1/30	0/8
Vasco ²⁸⁴	5/7	1/12	1/10

TABLE 11. Prevalence of Astigmatism in NonSyndromic Craniosynostosis (in Brackets; Numbers of Patients With Unilateral Versus Bilateral Astigmatism)

	Coronal	Sagittal	Metopic
Gupta ²⁵⁵	2/7 (1/1)	7/29 (2/5)	3/7 (0/3)

79% of whom had the largest refractive errors in the eye contralateral to the synostotic suture.²⁸⁵ The authors make a plea for evaluation of refraction anomalies, also in the absence of strabismus.

MacKinnon²⁸⁶ describes 37 patients with unicoronal craniosynostosis who all showed strabismus, of whom 20 mild, 10 moderate, and 7 severe.

Syndromic Craniosynostosis

Of all syndromic types of craniosynostosis, the most detailed and comprehensive ophthalmologic publications concern the Apert syndrome. The few studies addressing the other syndromes are of good quality and report few contradictory results.

Jadico²⁸⁷ compares ocular abnormalities in 18 patients with Apert syndrome, that is, 11 with S252W mutation and 7 with P253R mutation (Table 12). The S252W mutation is associated with more severe ocular abnormalities, with significant differences regarding strabismus, astigmatism, and blocked tear duct.

Khong²⁸⁸ makes a similar comparison between 20 S252W patients and 9 P253R patients (Table 13).

Khong²⁸⁹ reports ophthalmic findings in 61 patients with Apert syndrome.²⁹⁰ The most frequent cause of visual impairment was amblyopia (prevalence 35%), followed by corneal abnormalities (8%) and optic atrophy (5%).

Visual acuity <6/12 in best eye 19%; <6/12 in minimally 1 eye 54%.

Strabismus 63%

Ametropia 69% (hypermetropic 42%, myopic 27%)

Anisometropia (≥0.75 dioptry) 50%

Gray²⁹¹ found in 71 Crouzon patients that amblyopia was the most common cause of visual impairment (21%).

Visual impairment in minimally 1 eye 35%

Ametropia 77% (hyperopic ≥ 2 D 57%; myopic ≥ -0.5 D 20%)

Keratopathy 15% without consequences for vision

Jadico²⁹² compared 10 patients with a *TWIST* mutation (Saethre-Chotzen syndrome) with 11 patients with P250R *FGFR3* mutation (Muenke syndrome) (Table 14).

De Jong⁵⁴ reports the following proportions of refractive errors per syndrome in 132 patients: Apert 22/29 (76%), Crouzon/Pfeiffer

TABLE 12. Ocular Abnormalities in Apert Patients According to Type of *FGFR2* Mutation

	P253R (%)	S252W (%)
Strabismus	85	91
Ptosis	71	73
Amblyopia	43	73
Blocked tear duct	14	100
Myopia	14	36
Hypermetropia	14	9
Astigmatism	14	82

TABLE 13. Ocular Findings in Apert Patients According to Type of *FGFR2* Mutation

	P253R (%)	S252W (%)
Visual acuity <6/12 in best eye	20	12.5
Visual acuity <6/12 in minimally 1 eye	60	12.5
Visual acuity <6/12 (per eye)	40	12.5
Optic disc pallor	16	29
Amblyopia	56	20
Corneal abnormality and keratopathy (per eye)	25	21
Strabismus (per eye)	47	39

16/41 (39%), Muenke 17/35 (49%), and Saethre-Chotzen 14/27 (52%).

Khan²⁹³ reports findings in 141 patients with syndromic craniosynostosis, without distinguishing between the different types. In 52% of the 226 eyes, visual acuity is 6/12 or worse (46% of right eyes and 58.4% of left eyes). In 39.8% of 113 patients, visual acuity is 6/12 or worse in the best eye; and in 64.6% visual acuity is 6/12 or worse in minimally one eye.

A review by Lehman²⁹⁴ recommends frequent monitoring of refractive errors and motility abnormalities to prevent amblyopia and to preserve vision.

A number of case reports describe absence of ocular muscles in Apert syndrome, notably the superior rectus muscle, although other muscles may be absent as well. This abnormality has also been described for Pfeiffer syndrome.^{295–297}

Table 15 gives an overview on prevalence of strabismus and Table 16 on prevalence of astigmatism.

Conclusions

- Level 2** Vision, refraction and motility abnormalities occur very frequently in all types of syndromic craniosynostosis.
*B Jadico, 2006*²⁸⁷
*B Jadico, 2006*²⁹²
*B Khong, 2007*²⁸⁸
*C Gray, 2005*²⁹¹
*C De Jong, 2009*⁵⁴
*C Khan, 2003*²⁹³
*C Khong, 2006*²⁸⁹
*C Khong, 2006*²⁹⁰
*C Lehman, 2006*²⁹⁴
- Level 3** Strabismus and unilateral astigmatism in nonsyndromic craniosynostosis are seen almost only in unicoronal craniosynostosis.
*C Gupta, 2003*²⁵⁵

TABLE 14. Ocular Findings in Patients With Saethre-Chotzen Syndrome and Muenke Syndrome

	TWIST (%)	FGFR3 (%)
Ptosis	90	36
Amblyopia	70	18
Horizontal strabismus	70	55
Vertical strabismus	60	36
Blocked tear duct	60	0
Astigmatism	50	9
Inferior oblique overaction	40	45
Hyperopia	40	27
Myopia	30	18
Nystagmus	30	18
Optic nerve abnormalities	30	27

TABLE 15. Prevalence of Strabismus Presented as Percentage (Esotropia/Exotropia)

Apert	Crouzon	Pfeiffer	Saethre-Chotzen	Muenke	
Khan ²⁹³	82.9 (48.8/34.1)	66.7 (20.0/46.7)	94.7 (15.8/78.9)	53.4 (29.3/24.1)	–
Gray ²⁹¹		39			
Jadico ²⁹²				70 horizontal 60 vertical	55 36
Jadico ²⁸⁷	85 P253R 91 S252W				
Khong ²⁸⁹	65 (36/19)				
Lehman ²⁹⁴		39		63 horizontal	
De Jong ⁵⁴	93	63		37	39

*C Vasco, 2008*²⁸⁴
*C Tarczy-Hornoch, 2008*²⁸⁵
*C MacKinnon, 2009*²⁸⁶

Recommendations

In view of a high incidence of vision, refraction and motility abnormalities, orthoptic and ophthalmic evaluation is indicated for nonsyndromic unicoronal craniosynostosis and all syndromic types of craniosynostosis. Referral for evaluation is initiated at the first consultation in the tertiary center.

Follow-up is arranged dependent on the results.

12. OBSTRUCTIVE SLEEP APNEA SYNDROME

Basic Questions

1. What is the prevalence of OSAS in the different types of syndromic craniosynostosis?
2. What screening method (type and frequency) is indicated to timely detect OSAS?
3. How can OSAS be prevented or treated?

Introduction

The OSAS is characterized by episodes of partial and (or) complete upper airway obstruction during sleep state.^{298–300} These may lead to hypercapnia, hypoxemia, and abnormal sleep architecture. Dependent on the severity of the syndrome, vital dysfunctions to even fatal pulmonary heart disease may occur.

The clinical symptoms are diverse and are distinguished into those occurring in the night: troubled sleep, snoring, apneas, bedwetting and perspiration, and those occurring in the day: dry

TABLE 16. Prevalence of Astigmatism (>1D) Presented as Percentage (Right Eye/Left Eye)

	Apert	Crouzon	Pfeiffer	Saethre-Chotzen	Muenke
Khan ²⁹³	52.4 (54.8/50.0)	43.4 (40.0/46.7)	44.8 (47.4/42.1)	30.2 (28.6/31.7)	–
*Jadico ²⁹²				50	9
Jadico ²⁸⁷	14 P253R 82 S252W				
Khong ²⁸⁹	42				

* >1.5D.

mouth when waking up in the morning, fatigue, impaired cognitive functioning, poor school performance, and behavioral disorders. Disturbed growth may occur at the long term.

Children with craniosynostosis syndromes are among the risk groups for OSAS.

Early identification is of great importance in view of the severe consequences of OSAS, and considering that good treatment modalities are available.

Question 1: What Is the Prevalence of OSAS in the Different Types of Syndromic Craniosynostosis?

The most reliable method to determine the prevalence of OSAS is polysomnography (PSG). Not all studies on the prevalence of OSAS in craniosynostosis, however, use PSG; some apply another method, such as history taking, questionnaire, or desaturation-index.

Järund³⁰¹ retrospectively evaluated the clinical data of 73 patients with Apert, Crouzon or Pfeiffer syndrome and found that OSAS had been confirmed using PSG in 24%. Kakitsuba³⁰² performed PSG in 6 patients with a craniofacial synostosis and identified OSAS in 4 of them (67%). In another study, Järund³⁰³ established a 61% OSAS prevalence with the use of pulse oximetry in children with craniofacial malformations in whom OSAS was suspected. Pijpers³⁰⁴ retrospectively evaluated the occurrence of airway obstruction in 72 children with Apert (N = 28), Crouzon (N = 30), or Pfeiffer syndrome (N = 14). Children’s mean age was 9.3 years (0–17 years). Polysomnography had been performed in only 11 children. Symptoms of airway obstruction had been documented for 19 children (26%). Sirotnak³⁰⁵ conducted a review of 11 studies in children with Crouzon syndrome and established a 41% prevalence of airway obstruction. This review does not provide details on the methods used to detect breathing problems. Fearon¹⁴⁷ described a series of 28 patients with Pfeiffer syndrome. Tracheotomy was performed in 17 patients (61%) on account of respiratory problems, which were in part ascribed to abnormalities of the trachea (stenosis). De Jong⁵⁴ recently reported on the prevalence of OSAS in a group of 167 patients with syndromic craniosynostosis. Obstructive sleep apnea syndrome, diagnosed by means of an abnormal saturation profile, was seen in 31% of the patients with Apert syndrome, in 27% of patients with Crouzon/Pfeiffer syndrome, and in 5% of the patients with Muenke or Saethre-Chotzen syndrome (7).

Although OSAS was diagnosed with different methods, we may conclude that the prevalence of OSAS in syndromic craniosynostosis is high.

Question 2: What Screening Method Is Indicated to Timely Detect OSAS? General Diagnostics of OSAS History

Informing after symptoms related to OSAS is of essential value: Troubled sleep, snoring, apneas, skin discoloration, bedwetting, perspiration; and in the daytime: as an expression of hypoxemia, respectively, and a restless sleep pattern, with both periods of arousal and also periods of deep sleep: dry mouth when waking up in the morning, fatigue, impaired cognitive functioning, poor school performance and behavioral disorders.

Brouillette³⁰⁶ developed a scoring system based on the following nightly symptoms:

- a. Breathing problems? 0 = never, 1 = sometimes,
2 = often, 3 = always
- (having to work hard to breathe)
- b. Sleep apneas? 0 = no, 1 = yes
- (gasping for breath, pause in breathing,
or obstructed breathing such that the
chest moves up and down without inhaling air)

c. snoring?

0 = never, 1 = sometimes,
2 = often, 3 = always

The OSAS score is calculated with the following formula: $1.42 a + 1.41 b + 0.71 c - 3.83$

Obstructive sleep apnea syndrome is considered to be present at a score >3.5. At the time of this writing this is the only scoring system applied in children suspected of OSAS.

Parental observation of video images of the child’s breathing pattern during sleep could help making the diagnosis.

Bannink,³⁰⁷ in a study in a large group of children with syndromic craniosynostosis, showed that a negative answer to the question ‘breathing problems during sleep?’ may be sufficient to exclude moderate or severe OSAS.

Diagnostic Tests

Continuous saturation measurement during sleep in combination with blood gas analysis may provide insight into the severity of the OSAS.

Polysomnography is essential, however, to diagnose OSAS with certainty, and to accurately determine its severity. Polysomnography simultaneously registers oronasal airflow, thoracic movements, abdominal movements, transcutaneous saturation, and heart rate. Furthermore, the sleep stages can be monitored with neurophysiologic examination (EEG, EOG, and EMG).

Inspection of the upper airway by the ENT-physician, if necessary supplemented with endoscopy, is indicated in patients with severe obstructive symptoms. Obstruction may be present at multiple locations—in the nose, rhinopharynx, oropharynx, and hypopharynx—but also in the larynx or trachea. Diagnoses are: narrow nose, septum deviation, allergic or nonallergic rhinitis, choanal atresia, adenoid hypertrophy, midface hypoplasia, abnormal skull base, tonsillar hypertrophy, macroglossia, abnormal palate, retro- or micrognathia, laryngeal stenosis, fused tracheal rings. Once the obstruction has been localized, more targeted treatment can be started.

Imaging diagnostics (CT/MRI) of the obstructed area could provide further information.

To further map the consequences of severe OSAS, cardiologic examination is indicated to evaluate right ventricular hypertrophy or pulmonary hypertension.

Grading of Severity of OSAS

The use of an apnea-hypopnea index (AHI) and an oxygenation-desaturation index (ODI) is recommended to grade nocturnal respiratory problems.

Brouillette³⁰⁶ showed that an abnormal saturation measurement on the basis of the ODI only had a 97% positive predictive value for the diagnosis of OSAS in a group of healthy children >1 year with OSAS as a consequence of adenotonsillar hypertrophy. Saturation measurement is not reliable, however, to exclude OSAS (negative predictive value 47%). It is not known whether this holds true also for children with a syndromic craniosynostosis.

Polysomnography in addition permits to determine an arousal index, in which the total number of events is expressed as a respiratory disorder index. Traditionally, many studies in children applied criteria of OSAS applicable to adults. There, however, is growing evidence that mild nocturnal breathing problems and snoring may have neuropsychologic consequences. A major difference between children and adults with OSAS is that children may experience longer periods of partial airway obstruction during sleep, often without arousals or desaturations, but still with increased CO₂ concentration or increased breathing effort (which can be measured with an esophageal pressure measurement). Partial upper airway obstruction leading to “upper airway resistance

syndrome” may be underestimated if only the AHI is used to diagnose OSAS.

The morbidity from each separate respiratory parameter (ie, AHI, intermittent hypoxia, hypercapnia, or sleep fragmentation by arousals), however, is unknown.³⁰⁸

The various guidelines distinguish between mild, moderate, and severe OSAS. Guilleminault³⁰⁹ provided a much-used classification of OSAS based on the sum total of the number of apneas and hypopneas. Brietzke³¹⁰ in a systematic review reported the cutoff values used to classify OSAS. This review addressed the question whether history taking and physical examination would permit to adequately diagnose obstructive sleep apnea/hypopnea syndrome. In 4 studies, an AHI of >1 per hour was used as cutoff value,^{311–314} in 2 studies an AHI of >5/hr,^{315,316} and in 1 study an AHI >15/hr.³¹⁷ One other study established severe OSAS on the basis of an AHI >10/hr and/or desaturation <75%.

Next to cutoff values for the AHI, the following parameters should be determined to achieve comprehensive grading of OSAS distinguishing between mild, moderate, and severe: depth of desaturation, end tidal CO₂ peak level, total period of sleep in which the CO₂ value is >50 cm Hg, and number of arousals per hour. Table 17 presents an overview of the most-used definitions provided by different authors.

Basically, OSAS in children with syndromic craniosynostosis is diagnosed in the same way as in other children. The clinical history may raise suspicion of OSAS. Many children with syndromic craniosynostosis will be snoring, but this symptom is not discriminative for OSAS.

The golden standard is PSG, with level or number of channels dependent on the availability of equipment and the aim of the screening. The above-mentioned criteria for the diagnosis of OSAS are applicable, in principle, to all diagnostic groups.

Gonzalez²⁶⁰ investigated the occurrence of OSAS in 13 children with syndromic craniosynostosis with PSG using 5 channels: arterial oxygen saturation, heart rate, thoracic movements, abdominal movements, and ECG. Nasal flow was not measured. OSAS was classified as mild, moderate, or severe on the basis of the PSG profiles and clinical observation, that is, the degree of respiratory efforts, snoring, and inspiratory recessions. On the basis of these criteria, OSAS was diagnosed in 11 of the 13 children.

Hayward (2005)²⁴¹ investigated the relation between OSAS and increased ICP in 11 children with syndromic craniosynostosis. Obstructive sleep apnea syndrome was diagnosed using the same method as in the previous study by Gonzales,²⁶⁰ with in addition measurement of the oro-nasal flow. The presence of OSAS was established in all children.

Question 3: How Can OSAS Be Prevented or Treated?

Treatment of OSAS in General (See Also Guideline on Pediatric OSAS)

Type of treatment of OSAS in craniosynostosis is determined by severity of the symptoms and location of the obstruction, and is aimed at improving upper airway patency. Treatment may be pharmacological, for example, nasal corticosteroid spray or antibiotics; surgical, for example adenotonsillectomy; or nonsurgical, for example, nocturnal O₂ administration or continuous/bi-level positive airway pressure ((continuous positive airway pressure (CPAP) or bilevel positive airway pressure (BiPAP)).^{318–321}

Conservative measures are often successful in the milder types of OSAS, such as extensive nasal irrigation (saline lavage and air spraying), treatment of intercurrent infections, and assuring a specific sleep position.

Oxygen therapy may be indicated in nocturnal hypoxia, but only after having confirmed that the hypercapnia will not worsen as a result of reduced breathing activity after loss of the hypoxic drive in chronic hypercapnia.

Adenotonsillectomy

Adenotonsillectomy is almost always the treatment of first choice (also when adenoid and tonsils are not notably enlarged) from toddler-age in healthy children with more prominent OSAS. Little is known about the effect of adenotonsillectomy on OSAS symptoms in children with syndromic craniosynostosis. Amonoo-Kuofi³²² conducted a retrospective analysis on the effect of adenotonsillectomy in a group of 26 children with syndromic craniosynostosis and moderate or severe OSAS. The criteria for mild, moderate, or severe OSAS had been established by the researchers themselves from a combination of clinical observation and a sleep study. Adenotonsillectomy had been performed at a mean age of 4.5 years (range 1.6–13.9 years). Preoperatively, OSAS was severe in 7 children, moderate in 11, and mild in 7. Postoperatively, severe OSAS was still found in 3 children, moderate in 6, mild in 1, while 5 children had no longer symptoms of OSAS. The authors concluded that respiration had improved in 60% of the children. Therefore, adenotonsillectomy is the treatment of first choice in children with syndromic craniosynostosis and sleep-related respiratory problems. The authors propose that adenotonsillectomy may be beneficial also if the tonsils are small, and emphasize that multiple factors may underlie the respiratory problems and that supplementary therapy may be needed.

In craniofacial deformities, suturing of the tonsillar pillars may be considered, upon which scar retraction may further contribute to widening of the airways.

Nasopharyngeal Tube

Occasionally, placement of a nasopharyngeal tube (NTP) may be necessary before more definitive treatment is initiated. Ahmed³²³ evaluated the effect of initial NTP placement on moderate or severe OSAS in 27 children with a syndromic craniosynostosis. Mean age at nocturnal penile tumescence (NPT) placement was 12.3 months, range 0.5–48 months. Seventeen children had severe OSAS; 10 children moderate OSAS. After NPT placement, airway obstruction and saturation profile had improved in 26 of the 27 children (96%). The criteria for mild, moderate, or severe OSAS had been established by the researchers themselves from a combination of clinical observation and a sleep study. For 26 of the 27 children, treatment could be evaluated at the longer term. After 6 weeks, 24 children still had the NPT in place (1 child still underwent tracheotomy and 1 child died from a cause unrelated to the respiratory tract). Nocturnal penile tumescence remained the sole treatment in 23 of the 26 children, 6 months after placement and in 17 of the 26 children 12 months after placement. Having a NTP in place, however, may be very uncomfortable and even not be tolerated, may cause mucosal retention, and lead to comorbidity, such as fibrosis in the nasal cavity or chronic otitis media. In the study of Ahmed,³²³ however, there were few complications and tolerance was high.

Craniofacial Surgery

Mandibular distraction techniques and midface advancement have been widely applied in syndromic craniosynostosis for several years. Forward advancement of bony structures will increase the posterior–anterior diameter of the pharynx.³²⁴

Six recent studies looked into the effect of a Le Fort III correction or a monobloc advancement procedure. In 5 of the 6 studies, a retrospective analysis was performed.

Nelson³²⁵ retrospectively evaluated the effect of a Le Fort III distraction procedure in 25 children with syndromic craniosynostosis (age 10.4 ± 4.2 years), 18 children of whom preoperatively had respiratory problems. Six of these 18 children had a tracheostomy preoperatively, and decannulation was possible in 5 postoperatively. Preoperatively, 9 children received respiratory support with CPAP or BIPAP, which could be discontinued in 6 children after the operation. Polysomnography was performed both preoperatively and postoperatively in the 12 children without tracheostomy. In 10 children, the respiratory index improved from 33.4 to 12.6 ($P < 0.05$). In 2 children with a Chiari malformation associated with severe central apneas, the respiratory index did not improve. The authors concluded that a Le Fort III distraction has a clearly positive effect on the airway obstruction and that the improvement is dependent on the operative technique used. The authors point out that a number of children showed persisting respiratory problems postoperatively, as a consequence of insufficient widening, central apneas, or respiratory problems located below the level of the nasopharynx. The authors recommend assessing level of obstruction (endoscopy or dynamic MRI) before undertaking a Le Fort III procedure.

Fearon¹⁸¹ retrospectively evaluated the effect of a Le Fort III procedure with halo distraction in 51 children with syndromic craniosynostosis (mean age 8 years, range 3–16 years). Preoperative and postoperative PSG had been performed in 12 children. Postoperatively the respiratory index had improved from 24/hr. to 11/hr. ($P = 0.004$). Four children had a tracheostomy, which could be removed in three. The authors concluded that in 13 of the 16 children with respiratory tract problems the operation had led to improved respiration. They commented, however, that although maxillary hypoplasia plays a central role, multiple factors may underlie airway obstruction.

Arnaud¹⁴⁴ prospectively investigated in a group of 36 children with syndromic craniosynostosis (mean age 5.2 years) the effect of frontofacial monobloc advancement with the use of an internal distractor. Sixteen children showed upper airways problems, for which 6 needed a tracheostomy, while in the other 10 children saturation regularly decreased to $<95\%$. Postoperatively, 4 of 6 children could be decannulated and desaturations were no longer seen in 8 of the 10 children.

Witherow²⁰⁹ retrospectively analyzed long-term outcome (mean follow-up 24 months, range 6 months to 4 years) of monobloc advancement with distraction in 20 children (mean age 7.8 years, range 2–16 years). Seventeen children had an upper airway obstruction, but test results or PSG are not mentioned. Of the 7 children who needed a tracheostomy, 5 could be decannulated and CPAP could be stopped in 2 of the 5 children treated with CPAP.

Mathijssen compared the effect on respiration of a Le Fort III procedure ($n=24$, mean age 6 years, range 4 months to 18 years) with that of a frontofacial monobloc ($N=35$, mean age 4.5 years, range 7 months to 13 years).³²⁶ Respiratory problems were classified as mild in the case of snoring in combination with normal PSG, and as severe if saturation decreased to below 90% or if the child had a tracheostomy. Nine children who underwent a Le Fort III procedure showed respiratory problems preoperatively, 7 children had a tracheostomy. Postoperatively, 4 children could be decannulated and symptoms disappeared in 2 children with mild or severe respiratory problems. Respiratory symptoms recurred in 2 children. Twenty-five children who underwent a monobloc procedure showed respiratory problems preoperatively. Of the 6 children with a tracheostomy, 4 could be decannulated. Symptoms improved in 17 of the 19 children with mild or severe respiratory problems.

Flores³²⁷ retrospectively analyzed airway changes in 20 children with syndromic craniosynostosis after a Le Fort III distraction procedure. In children with respiratory problems, PSG was

standardly performed preoperatively. The degree of respiratory disturbances during sleep was classified on the guidance of a respiratory disturbance index (RDI): mild 2–5, moderate 5–10, and severe >10 . Disturbances were severe in 10 children, of whom 2 needed a tracheostomy. Postoperatively, 1 child could be decannulated; in the second child this was not feasible on account of a subglottic stenosis. Of the other 8 children with severe disturbances, 3 underwent PSG postoperatively, which showed lowering of the RDI. The remaining 5 children showed subjective improvement of the OSAS symptoms.

Bannink³²⁸ retrospectively evaluated the effect of a monobloc ($N=3$) or a Le Fort III procedure in 11 children with syndromic craniosynostosis who received respiratory support on account of airway problems. Respiratory support consisted of oxygen ($N=3$), CPAP ($N=3$), NTP ($N=1$) or tracheostomy ($N=4$). Polysomnography had been performed in 6 children preoperatively, using the following criteria: mild OSAS AHI 1–5, moderate OSAS AHI 6–25, and severe OSAS AHI >25 . On the basis of these criteria, 3 children had moderate OSAS, and 3 children had severe OSAS. At long-term follow-up, 4 of the 11 children still needed respiratory support (3 CPAP and 1 tracheostomy), whereas 1 child still showed severe OSAS symptoms (respiratory support had been discontinued).

The above studies made clear that follow-up studies are needed to demonstrate if mandibular distraction techniques have a lasting effect on OSAS. It is not fully known how long and to what extent improvement will be sustained, and what factors are involved. On the other hand, it is known that both the mandible and the maxilla will not grow in anterior direction postoperatively, which may perhaps necessitate reoperation at a later stage (Bachmayer, 1986).¹⁹⁶ Correction of the nasal septum may also be beneficial in the treatment of OSAS.

Tracheotomy

In the above-mentioned studies reporting on the results of craniofacial surgery, from 20% to 41% of children with respiratory problems had undergone tracheostomy placement. Age at tracheotomy is mentioned in only 1 study.³²⁸ In total, 42 tracheotomies (34%) were performed in 122 children with respiratory problems. After a Le Fort III or monobloc procedure, 29 of 42 children (69%) could be decannulated.

Continuous positive airway pressure or bilevel positive airway pressure

Respiratory support by means of noninvasive treatment with CPAP or BIPAP is an accepted treatment in children. A fitting nasofacial mask, however, may not be available for children with facial deformities. In addition, anatomic narrowing of the nasopharynx may complicate application of CPAP or BIPAP. Treatment of respiratory problems with the use of CPAP or BIPAP was described in 3 recent studies.^{209,325,328} It was applied in 17 of the 46 children with respiratory problems in total, and could be discontinued in 8 of these 17 children after a Le Fort III or monobloc procedure (47%).

Earlier, in 1996, Gonzalez et al³²⁹ reported on the effectiveness of CPAP in the treatment of OSAS in children with syndromic craniosynostosis.³²⁹ It was successful in 5 of the 8 children (age 2.2–15 years). Of the other 3 children, 1 did not tolerate the system, second withdrew from the study, and the third showed a complete obstruction of the upper airways by an enlarged adenoid.

Conclusions

Level 2 The diagnosis and severity of OSAS should be established with the use of PSG.

- B Brietzke, 2004*³¹⁰
- Level 3** In children with syndromic craniosynostosis, the prevalence of OSAS is high. The prevalence is highest in patients with Apert, Crouzon, or Pfeiffer syndrome (range 24%–67%).
*C De Jong, 2010*⁵⁴
*C Fearon, 2009*¹⁴⁷
*C Järund, 1996*³⁰¹
*C Järund, 1999*³⁰³
*C Kakitsuba, 1994*³⁰²
*C Pijpers, 2004*³⁰⁴
*C Sirotnak, 1995*³⁰⁵
- Level 3** The clinical diagnosis of moderate or severe OSAS can, in all likelihood, be excluded if the clinical history does not point at nocturnal breathing problems.
*C Bannink, 2010*³⁰⁷
- Level 3** Adenotonsillectomy is the surgical therapy of choice from toddler age if syndromic craniosynostosis is associated with OSAS.
*C Amonoo-Kuofi, 2009*³²²
- Level 3** Nasopharyngeal tube placement may serve as temporary treatment for upper airway obstruction.
*C Ahmed, 2008*³²³
- Level 3** Continuous positive airway pressure or bilevel positive airway pressure can be an effective treatment for OSAS.
*C Gonzalez, 1996*³²⁹
*C Nelson, 2008*³²⁵
*C Witherow, 2008*²⁰⁹
*C Bannink, 2010*³²⁸
- Level 3** Nasopharyngeal tube placement may serve as temporary treatment for upper airway obstruction.
*C Nelson, 2008*³²⁵
*C Witherow, 2008*²⁰⁹
*C Arnaud, 2007*¹⁴⁴
*C Mathijssen, 2006*³²⁶
*C Flores, 2009*³²⁷
*C Bannink, 2010*³²⁸
- Level 3** Tracheostomy may be indicated in children with a severe upper airway obstruction.
*C Ahmed, 2008*³²³
- Level 3** It is likely that a Le Fort III or a monobloc procedure improves upper airway problems.
*C Nelson, 2008*³²⁵
*C Witherow, 2008*²⁰⁹
*C Arnaud, 2007*¹⁴⁴
*C Mathijssen, 2006*³²⁶
*C Flores, 2009*³²⁷
*C Bannink, 2010*³²⁸

Considerations

Dependent on the severity of the symptoms in children with a craniosynostosis syndrome, it is recommended to first determine a nocturnal saturation profile. This is done by measuring the baseline saturation (normally $\geq 94\%$) and next the number of desaturations per hour (saturation $< 90\%$ or $\geq 4\%$ decreased compared with the baseline value during 10 seconds (ODI = oxygenation desaturation index)). Subsequently, additional PSG is indicated in children with an abnormal saturation profile or a strongly suspicious clinical history in combination with a normal saturation profile.

Many children with a syndromic craniosynostosis show an anatomic narrowing of the nose, with mouth breathing as a result. This complicates measurement of the nasal flow in a sleep study. Measuring the X-flow is the alternative in this case, although this has not yet been validated for this patient group.

There are indications that there is a relation between obstructive respiratory problems and an ICP. It is not clear, however, at what degree of OSAS the intracranial pressure could increase. Still, it is likely to occur both in prolonged mild OSAS and in short-lasting

severe OSAS. It is recommended, therefore, to perform comprehensivePSF, including CO₂ measurement, arousal detection and video monitoring, in children with syndromic craniosynostosis who show ICP.

Recommendations

In view of the high prevalence of OSAS in children with syndromic craniosynostosis it is mandatory to screen these children for OSAS.

If the clinical history documents nocturnal breathing problems, further evaluation for OSAS should take place.

If the medical history does not document nocturnal breathing problems, moderate and severe OSAS can be excluded, in all likelihood, and further evaluation is then, in principle, not indicated.

Symptoms of OSAS in combination with an abnormal saturation profile are strongly suspicious of OSAS. Additional PSG is indicated in this case, to be performed according to the guideline on pediatric obstructive sleep apnea syndrome (POSAS).

Polysomnography is indicated to determine OSAS severity.

Because multiple factors may underlie OSAS in children with a syndromic craniosynostosis, endoscopy of the upper airways is indicated to determine the level of obstruction.

Adenotonsillectomy is the surgical therapy of choice from toddler age if syndromic craniosynostosis is associated with OSAS.

Obstructive sleep apnea syndrome in children with syndromic craniosynostosis can be treated with the noninvasive ventilation strategies CPAP and BIPAP.

In young children with severe OSAS a nasopharyngeal tube can be used temporarily to ameliorate the symptoms.

A tracheotomy may be indicated in young children with severe OSAS.

A Le Fort III procedure or monobloc advancement should be considered in the management of respiratory problems in children with a syndromic craniosynostosis and severe OSAS requiring ventilator support.

The choice of treatment for OSAS is made on the basis of severity of the OSAS, age of the patient, causal factors, and possible other functional problems (such as ICP or exorbitism).

13. HEARING IMPAIRMENTS

Basic Questions

1. What are the prevalences, types, and causes of hearing impairment for the different types of syndromic craniosynostosis?
2. What kind of screening is necessary to timely discover hearing loss?

Introduction

There are several reasons for patients with syndromic craniosynostosis to have hearing impairments. Hearing loss can be an additional cause for developmental delay in children who already have an increased risk of such delay. This chapter gives an overview of the prevalences and types of hearing loss, and provides recommendations on screening enabling early initiation of treatment quickly. Treatment itself will not be discussed, as it is in accordance with otolaryngology guidelines.

Summary of the Literature

Since hearing loss hardly occurs in children with nonsyndromic craniosynostosis, this chapter is restricted to syndromic

craniosynostosis. The literature, consisting of only a few case reports and retrospective studies with usually a very low number of patients, provides no clarity about the prevalence and the cause of hearing loss in these patients.

Otitis media with effusion (OME) is reported in all types of syndromic synostosis. Reported prevalence rates range from that equal to that of healthy peers³³⁰ to 80% to 90% of the affected children.^{331–334}

The most recent article we found concerns a retrospective review of CT scans of the petrous parts of the temporal bone of 20 patients with Apert syndrome.³³⁵ All 20 had middle ear and inner ear deviations shown on CT. These patients were treated with tympanostomy tubes and/or hearing aids. The authors make a plea for CT scanning of the petrous part of the temporal bone of every patient with Apert syndrome, especially if the air-bone gap should persist after placing the tubes.³³⁴ For patients with Apert syndrome the presence of a cleft palate makes no difference.

One longitudinal study describes how, over time, persisting OME led to permanent sequelae such as atelectasis, perforation, and cholesteatoma in patients with Crouzon syndrome.³³⁶ In this study, ear and hearing impairment rates increased from 37% in infancy to 62% in older patients. In Pfeiffer syndrome, anatomic abnormalities of the external auditory canal and middle ear were reported in a case report on 9 patients. Four of those patients had OME as well.³³²

In Saethre-Chotzen syndrome, congenital middle ear abnormalities are reported in a case report on 4 patients.³³⁰

In Muenke syndrome, mild to moderate perceptible hearing loss in the lower and middle frequencies was found in from one third³³⁷ up to 95% of the reported patients.³³³ Honnebier¹⁴⁶ finds in 7 of 10 patients with Muenke syndrome in whom audiometry was performed an almost identical, mild (30 dB), symmetric perceptible hearing loss in the low and middle frequencies. For 2 patients a mild asymmetric and for 1 patient a mild bilateral mixed hearing loss was found. In a retrospective analysis of 167 syndromic patients, hearing loss is reported in 72% of the patients with Apert syndrome, 50% with Crouzon syndrome/Pfeiffer syndrome, 67% with Muenke syndrome, and 37% with Saethre-Chotzen.⁵⁴

Based on the auditory brainstem response (ABR) in syndromic craniosynostosis and event-related potentials (ERP) in children,³³⁵ including patients with frontal plagiocephaly,³³⁸ there are indications that these children have an increased risk of auditory processing disorders. The relevance and consequences of this finding are uncertain at this moment.

Conclusions

Level 3 In all children with syndromic craniosynostosis the possibility of OME should be considered.

C Corey, 1987³³⁶
C Doherty, 2007³³³
C Prager, 2008³³⁰
C Vallino-Napoli, 1996³³²
C Zhou, 2009³³⁴

Level 3 Congenital abnormalities of the inner ear, middle ear, and outer ear are regularly seen in children with syndromic craniosynostosis.

C Corey, 1987³³⁶
C Doherty, 2007³³³
C Prager, 2008³³⁰
C Vallino-Napoli, 1996³³²

Level 3 Mild to moderate perceptible hearing loss occurs especially in patients with Muenke syndrome, with a prevalence of 33% to 95%.

C Doherty, 2007³³³
C Honnebier, 2008¹⁴⁶
C De Jong, 2009⁵⁴

D Hollway, 1998³³⁷

Level 3 There are indications that auditory processing disorders occur in children with syndromic craniosynostosis. So far, it has not been documented whether this is the result of the synostosis or of the often associated OME. Furthermore, the relevance of this disorder and possible therapy are not clear.

C Corey, 1987³³⁶
C Church, 2007³³⁵
D Balan, 2002³³⁸

Considerations

As of 2006, all newborns in the Netherlands are screened for hearing problems through the neonatal hearing screening program (OAE/OAE/Algo through child and adolescent health care and Algo/Algo on NICUs). Screening is scheduled to be performed in the first 2 weeks of life, on NICUs sometimes, a bit later. The screening can reveal both conductive and perceptible losses. After an abnormal screening result for 1 or both ears, the children will be referred to a dedicated regional audiological center. In the audiological center, the child will be further tested until the nature of the loss and the therapeutic possibilities are clear. The goal is to start with an appropriate intervention (hearing aids) before the age of 6 months.

Any congenital losses (perceptible and conductive) are most likely identified in the neonatal hearing screening. One should be alert to problems that may occur later in life, especially OME. Persistent conductive losses after treatment of OME require attention, especially monitoring by imaging. An early CT scan of the petrous part of the temporal bone is useful to predict hearing problems and to decide whether treatment should consist of a hearing aid or a tympanostomy tube.

Recommendations

In the first 4 years of life an annual hearing test is indicated, with tympanometry and otoacoustic emissions, and, if possible, a pure-tone audiogram (from the age of 4 years, or somewhat earlier depending on the level of development and the capacity to follow instructions). After an unclear result, ABR and/or free field testing are performed, which can take place at the local audiological center.

The first skull-CT should include adequate sections of the petrous parts of the temporal bone, so that any structural abnormalities in the outer/middle and inner ear are identified at an early stage and appropriate therapy can be chosen without delay.

The therapy depends on the type of hearing loss (conform otolaryngology guidelines) and may consist of tympanostomy tubes, hearing aids (conventional, BAHA), or cochlear implant. Treatment is performed by the audiologist, either local or at the center. Reconstructive surgery for congenital middle ear abnormalities can take place at a later age.

Speech/language monitoring commences at the age of 2 years with standard speech and language assessment tests.

14. DENTOFACIAL DEFORMITIES

Basic Questions

1. What is the prevalence and nature of dentofacial deformities in syndromic craniosynostosis?
2. What orthodontic care is indicated in syndromic craniosynostosis?

Basic Question 1: What Is the Prevalence and Nature of Dentofacial Deformities in Syndromic Craniosynostosis?

The literature does not contain reports on the prevalence of dentofacial deformities in syndromic craniosynostosis. Below, we address only publications describing the nature of the deformities:

Dentofacial deformities occur in almost all syndromic types of craniosynostosis. It is not clear if patients with the syndrome of Saethre-Chotzen and patients with the syndrome of Muenke are affected as severely. Only one article on dental deformities is available, describing 8 patients with the syndrome by Muenke.¹⁴⁶ Dentofacial deformities are aggravated by the necessary surgical corrections. Twenty-one articles report on dentofacial growth and development in syndromic craniosynostosis.

The orthodontic and dental problems in syndromic craniosynostosis are related to abnormal growth of the maxilla both in vertical, transversal, and sagittal direction, on account of which the maxilla is too hypoplastic in all dimensions.^{155,339–341} Normal maxillary growth takes place by growth of the sutures around the maxillary sutures, including the median suture.^{342,343} This leads to forward and downward displacement of the maxilla (primary displacement). In addition, growth of the skull base proceeding from the synchondroses leads to forward and downward displacement of the maxilla (secondary displacement). Moreover, apposition and resorption processes take place at the bone surface of the maxilla.³⁴⁴ In normal development, growth at the level of the base of the orbits is largest until the age of 8 years.³⁴⁵

The underlying mechanisms are probably twofold, that is synostosis of the palatal suture and the sutures around the maxilla, as well as retarded growth from the cranial base. Reduced outgrowth of the maxilla and the associated restriction of the upper respiratory tract lead to mouth breathing and consequently to excessive open bites.^{346–348} The maxillary transversal hypoplasia in addition leads to a unilateral or bilateral cross bite.^{347,348}

The maxillary hypoplasia results in an anomalous sagittal relation between the upper and lower jaws. Furthermore, it nearly always leads to severely delayed eruption of the dentition, retention, and considerable 'crowding' in the upper dental arch.^{347–349} The delayed dental development is probably the cause of abnormal eruption patterns.³⁵⁰ Authors describe a narrow, high-arched palate with co-occurring large lateral gingival swellings. The palatal constriction and lateral swellings will intensify with age.^{347–348,351} Gingival thickness probably contributes to the delayed eruption of the dentition.^{347,352} Ectopic eruption of the first permanent molars occurs more frequently than in the normal population, that is, in 50% of patients with the Apert syndrome and in 40% of patients with the Crouzon syndrome.³⁵³

Hypodontia is another frequently reported condition.^{348,349} Shape and size of the teeth may be abnormal,^{347,349} but this was not found in the study by Letra.³⁴⁸ Good oral hygiene may be problematic in these patients, not only because of insufficient space, but also, for example, on account of the syndactyly in patients with the syndrome of Apert.^{354,355} In addition, many patients breathe through the mouth, so that inflammation of the gum tissue will be resolved less easily.^{356,357}

Compensatory changes in the lower dental arch are seen that are related to the disturbed maxillary growth.³⁵⁸

One article makes clear that in view of the large number of dental deformities orthodontic care is quite essential in patients with syndromic craniosynostosis.³⁴⁹ Dental development is delayed by at least 1 year, and this delay, next to other local factors, is responsible for delayed eruption of the dentition.³⁵⁰ A number of dentofacial characteristics, such as crowding, malocclusion, and gingival swellings worsen during growth, but orthodontic treatment

may reduce their severity and provide for better oral hygiene and fewer parodontal problems.³⁴⁸

Basic Question 2: What Orthodontic Care Is Indicated in Syndromic Craniosynostosis?

In view of the many dentofacial deformities (see above under question 1), extensive orthodontic care and guiding, including space management and eruption guidance, should start at a young age.

The general standard for current-day orthognathic treatment is both pre- and postoperative orthodontic treatment.³⁵⁹ The orthodontic-surgical intervention must be planned carefully, also on account of the skeletal malalignment of the jaws.^{359,360} It is not clear whether distraction osteogenesis to resolve airway problems, exophthalmia, or other objective problems could lead to further midface growth inhibition. The degree of mandibular growth is not clear.¹⁵⁴ As long as the face has not fully grown, it is not possible to reach the ultimate goal on occlusion level.^{155,157,197} Insufficient information is available on the stability of the Le Fort III distraction osteogenesis (see facial deformities).¹⁸¹ Orthognathic surgery after reaching the skeletal age of 18 years is usually indicated to obtain normal alignment of the jaws and occlusion.

The following factors should be taken into account when planning treatment: patient's emotional age, mental age, and the related degree of cooperation.³⁴⁴ There is no research available on the retention phase after orthodontic treatment in syndromic craniosynostosis patients. It is not likely that this would be different from that in patients without syndromic craniosynostosis. From a study, in nonsyndromic craniosynostosis patients it appeared that retention is necessary after orthodontic treatment.³⁶¹

Conclusions

- Level 3** It is plausible that the orthodontic and dental problems associated with syndromic craniosynostosis are related to the abnormal growth of the maxilla both in vertical, transversal, and sagittal direction, on account of which the maxilla is too hypoplastic in all dimensions.
B Kreiborg, 1981³⁴⁰
- Level 3** There are indications that dental development is delayed with at least 1 year, which results in delayed eruption and abnormal eruption patterns of the permanent teeth.
B Kaloust, 1997³⁵⁰
- Level 3** The maxillary hypoplasia leads to skeletal malalignment of the upper and lower jaws and to severely delayed eruption of the dentition, retention, and severe crowding of teeth in the upper dental arch.
C Dalben, 2006³⁴⁹
B Kaloust, 1997³⁵⁰
C Letra, 2007³⁴⁸
C Kreiborg, 1992³⁴⁷
- Level 3** There are indications that the eruption of the dentition is delayed by thickened gingival tissue.
C Kreiborg, 1992³⁴⁷
C Solomon, 1973³⁵²
- Level 3** Ectopic eruption of the first permanent molars occurs much more frequently than in the normal population.
C Cohen, 1996³⁵³
- Level 3** Reduced growth of the maxilla and the associated restriction of the upper airways lead to mouth breathing and consequently to excessive open bites.
C Letra, 2007³⁴⁸
C Kreiborg, 1992³⁴⁷
B Peterson-Falzone, 1981³⁴⁶
- Level 3** A number of dentofacial characteristics worsen during growth; orthodontic treatment could reduce the worsening.
C Letra, 2007³⁴⁸

Level 4 The experts agree that the teeth may be abnormally shaped and sized.
*C Dalben, 2006*³⁴⁹
*C Kreiborg, 1992*³⁴⁷

Considerations

Syndromic craniosynostosis is classified among the ‘rare diseases’ and from the above analysis of the available literature it appears that there is hardly any or no evidence at all. It is of great importance, therefore, that treatment centers both nationally and internationally apply a standard documentation schedule. This would allow for data pooling and gaining more knowledge on the clinical course of the syndromic craniosynostosis over time as well as the effects of interventions.

Especially for this group of patients it is more difficult to obtain an adequate level of oral hygiene with orthodontic treatment. This is in part because of developmental and behavioral problems (see Chapter 18) but also to physical problems such as hand deformities (see Chapter 15).

Regarding the deciduous teeth, the focus is on space management and eruption guidance. At this stage, surgery on orbital and dentofacial level is to be avoided, if possible, in view of further growth of the orbits and the location of the odontoblasts. Three-dimensional x-ray examination should be performed as soon as combined orthodontic-surgical treatment is scheduled (surgical aspects are dealt with in detail in Chapter 7).

During the first and second dentition transition phases various treatment strategies are feasible, such as dental or skeletal maxillary widening, eruption guidance and series extraction, or a combination of both. Any permanent teeth extractions should be done with future surgery in mind. Delayed dental development and abnormal eruption patterns are reasons to continue with regular orthodontic check-ups. Functional problems may necessitate coordinated orthodontic treatment and surgical intervention as integral parts of the comprehensive management of syndromic craniosynostosis. If hyper-telorism is present necessitating facial bipartition, orthodontic space between the central incisors must be provided.

Combined orthognathic treatment in sagittal direction is less obvious in patients aged between 12 and 18 years. The skeleton has not yet fully grown and puberty is starting.

Still, transversal corrections can take place in this period in preparation to the definitive sagittal corrections. In view of the three-dimensional complexity it would seem obvious to first perform the transversal and next the sagittal correction. Because in syndromic craniosynostosis patients the maxillary suture closes earlier, transversal distraction osteogenesis will mostly be indicated at this stage. The expansion device may be either tooth borne or bone borne.

The definitive sagittal correction is performed as soon as sufficient coordination of the dental arches has been reached at the age from 18 to 20 years.

Orthodontic-surgical management requires careful three-dimensional cephalometric planning in consultation with the surgeon. Presurgical orthodontic treatment is aimed at alignment of the dental arches and preparing for surgery. A rigid or semirigid dental anchoring construction is needed if surgery is performed in combination with distraction osteogenesis. In internal distraction osteogenesis, traction both at dental and skeletal level is needed to guarantee maximum stability, security, and optimal vector control during the active phase (± 1 month) and retention phase (± 3 months) of the distraction osteogenesis. Bone anchoring is a must, traction at dental level only is advised against in all cases. During the internal distraction osteogenesis, (extra) internal traction can be used such as a face mask. In all patients, postoperative stabilization should be achieved using intermaxillary elastic bands and/or a face mask. Orthognathic surgery is needed (also on account of the

characteristic open bite) to achieve the optimal end result, that is, normal alignment of the jaws and occlusion. On the other hand, psychosocial problems and (low) level of cognitive functioning may dictate compensating orthodontic management only.

Provided the oral hygiene allows for this, permanent retention is achieved by means of retention wires and in addition a retention device that stabilizes the dental arches in relation to each other. Regular monitoring is essential and evaluation should take place at least 2 years after treatment.

There is no solid evidence that orthodontic management and counseling of patients with syndromic craniosynostosis should be teamwork. Still, in view of the complex multidisciplinary nature of the problems this would seem obvious; the necessity of teamwork has been accepted worldwide for conditions such as cleft, to name one. From the perspectives of the patient and parents/care takers, however, the burden will be heavy as usually multiple stages of active orthodontic therapy are indicated, and treatment consequently will continue over several years. A patient and parents/care takers will have to visit the treatment center at least 10 times a year. Thus, a balance must be found between a limited number of centers for the orthodontic management of craniofacial deformities and good geographical distribution nationwide.

Recommendations

Oral hygiene must be monitored more intensively in comparison with the normal population.

Regular orthodontic monitoring is necessary in view of delayed dental development and abnormal eruption patterns (1 to 4 times a year).

In case of surgical intervention, coordinated orthodontic-surgical treatment is an integral part of the comprehensive management of syndromic craniosynostosis (surgical aspects are dealt with in detail in Chapter 7).

Immediately after surgery/distraction osteogenesis, orthodontic retention is indicated to stabilize the result and prevent relapse.

Provided the oral hygiene allows for this, permanent retention is achieved by means of retention wires and in addition a retention device that stabilizes the dental arches in relation to each other.

To ensure stability of the combined orthodontic-surgical interventions, orthodontic and facial orthopedic monitoring of the development into adulthood is indicated by means of standard protocol. Evaluation at least 2 years after treatment is required.

Instruction: Orthodontic Management. Monitoring in a Multidisciplinary Setting

To ensure stability of the combined orthodontic-surgical interventions, orthodontic and facial orthopedic monitoring of the development into adulthood is indicated, to be scheduled in relation to the characteristic developmental stages of the head and dentition. It is recommended to follow the schedule below (this is the recommended minimum set of records).

0 year	First consultation soon after birth: 360° stereo image or digital face and skull photographs (preoperatively).
0 to 2 yrs.	The craniofacial team proceeds along the lines of the care path for cranial (surgical) problems.
2 to 4 yrs.	First meeting with the craniofacial team: digital intra- and extraoral photographs, three-dimensional stereo image, global dentofacial assessment.
6 yrs.	Team and orthodontic check-up, documentation, if necessary treatment and monitoring (digital intra- and extraoral photographs, radiologic skull profile (RSP), orthopantomogram (OPT), three-dimensional stereo image, models).
9 yrs.	Team and orthodontic check-up, documentation, if necessary treatment and monitoring (digital intra- and extraoral photographs, RSP, OPT, three-dimensional stereo image, models).

±12 yrs. (preorthodontic treatment)	Team and orthodontic check-up, documentation (cone beam computed tomography (CBCT), or in second instance RSP, OPT), digital photographs, three-dimensional stereo image, models).
Postorthodontic treatment	Team and orthodontic check-up, documentation (CBCT, or in second instance RSP, OPT), digital photographs, three-dimensional stereo image, models).
End documentation (end of growth)	Team and orthodontic check-up, documentation (CBCT, or in second instance RSP, OPT), digital photographs, three-dimensional stereo image, models). If desired, definitive correction can be jointly planned. In principle this is the end of the team care path.

15. DEFORMITIES OF THE EXTREMITIES

Basic Questions

1. What are the nature and prevalence of the deformities of the upper and lower extremities for the different types of syndromic craniosynostosis?
2. What kind of screening is required to diagnose these deformities and how to proceed?

Introduction

As part of the phenotype of the craniosynostosis syndromes, deformities of the extremities are frequently seen, varying from very mild with hardly any functional consequences to very complex with very severe functional limitations. Deformities of the extremities that co-occur with a functional limitation need treatment, for which both timing and method are of relevance.

Summary of the Literature

Deformities of the hands and feet and, in less severe conditions, of the elbows, shoulders, knees, and hips, are reported for the syndromic types of craniosynostosis.

Deformities of the extremities are described for the following syndromes:

- 1) Apert
- 2) Crouzon/Pfeiffer
- 3) Saethre-Chotzen
- 4) Muenke

Apert Syndrome Hands

Complex (bony) syndactyly is practically symmetrically present in both hands, with involvement of at least the index finger, middle finger, and ring finger. Finger movement is only possible at the metacarpophalangeal (MCP) level and sometimes at the level of the proximal interphalangeal (PIP) joint in the little finger.³⁶² All other IP joints are either present or stiff. Stiffness is a constant symptom, even after the fused middle 3 fingers are separated at an early stage.³⁶³

Upton³⁶⁴ and Cohen³⁶⁵ both describe a classification system for severity of the syndactyly. The classification system of Upton is the one most commonly used:

Type 1) Complex syndactyly of the digits 2, 3, 4, while digits 1 and 5 are separated. There is a simple syndactyly of the digits 4 and 5. The thumb is short, broad, and deviates radially (in 45% of the Apert hands).

Type 2) Complex syndactyly of the digits 2, 3, 4 with simple syndactyly of digits 1 and 5. Synonychia of digits 2, 3, 4 and 5 is seen, although digit 5 may have its own nail. There is slight webbing of the soft tissue of the first web space. The thumb is short, broad, and deviates radially (in 39% of the Apert hands).

Type 3) Complex syndactyly of all fingers. All fingernails show synonychia, which often gives rise to ingrowth of nails and, consequently, to nail bed infections. Preaxial and postaxial polydactyly may occur. The thumb is often poorly developed (in 16% of the Apert hands).

Radiography: The thumb always has 2 phalanges: a better developed distal phalanx and a proximal deltalphalanx. This does not apply to type 3 hands. Over time, fusion of the proximal and distal phalanges of the thumb can be seen. The MCP joints are always visible as such. Depending on the hand type there can be fusion between the end phalanges of the digits 2 and 3; 2, 3, and 4; or between all. Sometimes there is fusion between the basis metacarpal (MC) 4 and MC 5 (never in type 1, 77% in the remaining types).³⁶⁶ Carpal fusion between the capitate bone and hamate bone may occur.

Additional anatomic deformities of the hands consist of a deviating vein pattern and nerve pattern, especially distal on the MC level,³⁶⁴ deformities of the flexor retinaculum, flexor tendons, extensor tendons, and intrinsic hand muscles. All these anatomic variations have implications for the surgical treatment.

Elbows

In the majority of the 10 Apert patients who were evaluated, the elbow functions were normal and less than half had radiologic deformities.³⁶⁴ Limited elbow functionality had a strong positive correlation with the severity of the hand and foot deformities. Progression toward synostosis will occur in patients with no elbow movement at birth. A proximal underarm synostosis between the radius and ulna was not reported.

Shoulders

Upton³⁶⁴ evaluated 19 Apert patients and found a prominent acromion, a broad major tuberositas, a small glenoid fossa of scapula, an indistinctly defined anatomic neck of the humerus, and an ovoidal shape of the humerus head. The glenoid dysplasia is most consistent. The range of motion in abduction, anteflexion and external rotation is limited and is further limited by growth.^{364,367} Murnaghan³⁶⁸ reports limited movement of the shoulder in the majority of Apert patients as well, especially by flexion and abduction. These are notably caused by the inclination of the inferior glenoid and rather not by soft tissue abnormalities or degenerative deformities.

Feet

The hands are always more severely affected than the feet. Children with Apert walk at a relatively late age (10–34 months). It is not reported why they are walking at a late age.³⁶⁹ The big toe may be bifid.

The classification of the foot deformities parallels that of the hand;

- Type 1) Digits 2, 3, and 4 are fused. The big toe is short, shortens progressively, and often deviates medially.
- Type 2) Digits 2, 3, 4, and 5 are fused.
- Type 3) All toes are fused (in most patients).

Progressive fusion of the tarsus and metatarsus is seen making the movement of foot and ankle increasingly difficult over time.³⁷⁰

TABLE 17. Grading of OSAS Severity

	Mild	Moderate	Severe
Guilleminault ³⁰⁹			
Apnea + hypopnea	1–5 events/hr	5–24 events/hr	>24 events/hr
Sheldon ⁴⁴⁸			
AHI	1–4	5–10	>10
Desaturation	86–91	76–85	≤75
Peak end tidal CO ₂	>53	>60	>65
End tidal CO ₂ %TST	10–24	25–49	≥50
Arousals per hour with EEG	>11	>11	>11
Galland ⁴⁴⁹			
Apnea index or	1–4 events/hr	5–9 events/hr	>10 events/hr
Desaturation in association with obstruction	Nadir of 87%–91%	Nadir of 76%–85%	Nadir of <75%
Hypoventilation	10%–24% total sleep time	25%–49% total sleep time	>50% total sleep time
Goroza ⁴⁵⁰			
AHI	5–15 events/hr	16–30 events/hr	>30 events/hr
Desaturations	81%–90%	71%–80%	<71%

AHI, apnea-hypopnea index; EEG, electroencephalogram; TST, total sleep time.

The first digit shortens with medial deviation from the big toe, secondary to growth deformities and a delta phalanx. In the toes with 2 phalanges, fusion occurs while retaining minimal movement in the metatarsophalangeal (MTP) joints. The midfoot and hindfoot characteristically fuse in a supination position. The fifth metatarsal is prominent with callus formation under the small head of the fifth and third metatarsal bones.³⁶⁴

Knees and Hips

Upton³⁶⁴ finds no functional deformities of the knee and hip in 19 patients.

Therapy

The aim of treatment is to create a deep, first web, to treat and prevent nail bed infections, to correct the position and length of the thumb and to divide the fingers to improve the pincer grip.³⁶⁴

Upton advises early treatment of macerations and nail bed infections, approximately at the age of 1 to 6 months. Experience has shown that this is an important problem for very young Apert patients, but specific numbers cannot be found in the literature.

Literature is conclusive about the necessity for an early initial web release in type 3 hands. Fereshetian³⁷¹ performs web release in between 3 and 6 months in type 3 hands, Zucker³⁷² and Fearon³⁷³ at 6 months, and Guero³⁷⁴ in between 6 and 9 months. Guero³⁷⁴ advocates a bilateral correction as well.

In general, it is advised to separate the remaining fingers between the ages of 6 and 18 months.^{366,371,372–374}

Corrective osteotomy of the thumbs is recommended at the age of 2 to 2.5 years by Chang,³⁷⁵ at 4 to 6 years by Fereshetian,³⁷¹ at 6 to 9 years by Fearon,³⁷³ and at 4 to 6 years by Upton.³⁷⁶

Corrective osteotomy of the fingers is recommended at between ages 4 and 7 years,³⁷¹ 6 and 9 years,³⁷³ and from 7 years.³⁷⁶

In Mathes’s textbook entitled Plastic Surgery, Upton³⁷⁶ provides a general overview of the treatment and timing of Apert hands (Table 18):

Regarding the outcome of the hand functions at a later age, Upton reports that in general the first web is shallow, the fingers short and stiff, but that the strength of the pincer grip is almost normal.³⁷⁶ Strength of the grip function is 30% of the normal value as a result of the lack of IP movement of the second, third, and fourth finger and distal IP movement of the fifth finger. For type 3 hands the release of the MC synostosis provides the most

important functional improvement by enabling the thumb-pink pincer grip.

Literature about the treatment of feet deformities in Apert syndrome is considerably rarer than that about hand deformities. Fearon sometimes recommends corrective osteotomy to the head of MC 2 when this is prominent at the plantar side of the foot.³⁷³ The aim is to have a smooth underside. Usually specially adapted footwear is sufficient for adequate function, without surgical treatment. In case of problems, a combination of specially adapted footwear and surgical correction of prominent MC heads and/or excessive callus formation is indicated to obtain maximum functionality.³⁷⁰

Saethre-Chotzen Syndrome

Anderson describes the radiologic hand deformities of 15 patients with Saethre-Chotzen syndrome (solely based on the phenotype).³⁷⁷ All patients in prepuberty showed delayed skeletal development. Most frequent finding (7/15) was an enlarged epiphysis of the distal phalanx of the thumb, followed by flattening of the distal epiphysis of the radius (4 patients), pseudoepiphyses in the metacarpals (3 patients), and individuals with camptodactyly, clinodactyly, hypoplasia of the middle phalanx, long metacarpals, and Kirner’s deformity of the distal phalanx of the little finger.

TABLE 18. General Overview of the Treatment and Timing of Apert Hands by Upton

Age	Procedure
1–6 months	Incision and drainage of macerations and nail bed infections First web release
6–18 months	Separating the fingers Release of joints
4–6 years	Release of clinodactylic thumb Excision of metacarpal synostosis Nail bed revision
7 yrs-adolescence	Osteotomy of the fingers Osteotomies Web revisions Metacarpal and carpometacarpal arthroplasty Soft tissue debulking

In an overview of hand deformities in craniofacial syndromes, Panthaki reports brachysyndactyly with cutaneous syndactyly of the second and third finger and clinodactyly as characteristic of Saethre-Chotzen syndrome.³⁷⁸

Two studies are most reliable, because they only describe patients with a genetically confirmed *TWIST1* mutation or deletion.^{60,379}

Trusen reports deformities found in a population with genetically proven Saethre-Chotzen syndrome.³⁷⁹ A double distal phalanx of the big toe was found in 12/35 patients and a triangle epiphysis of the distal phalanx of the big toe in 10/35 patients. These 2 deformities turn out to be pathognomonic for Saethre-Chotzen. Furthermore, additional hand and foot deformities were described in respectively 28 and 27 patients (Table 19).

Kress⁶⁰ found soft tissue syndactyly of the second and third fingers in 52 of the 71 Saethre-Chotzen patients (with proven *TWIST1* deletion of mutation) and bifid hallux in 44.

Muenke Syndrome

In 1997, Muenke described a large series of patients with the *FGFR3* P250R mutation and their phenotype.⁴⁹ Patients with this mutation are later diagnosed as having Muenke syndrome. The hand deformities described in this study consist of brachydactyly (13/44), clinodactyly (14/33), coned epiphyses (6/8), carpal fusion (2/16), thimble-like midphalanx (12/20), and an absent or fused midphalanx of the pink (2/19). The foot deformities are a broad hallux (6/23), brachydactyly (11/42), coned epiphyses (6/7), calcaneocuboid fusion (6/17), and a short and broad midphalanx (2/16).

Kress compares 71 Saethre-Chotzen patients (proven *TWIST1* mutation or deletion) with 42 Muenke patients (proven P250R *FGFR3* mutation).⁶⁰ Cutaneous syndactyly of the second and third finger or a bifid hallux was seen in none of the Muenke patients.

Trusen described hand and feet deformities of patients with Muenke and Saethre-Chotzen syndrome.³⁷⁹ Calcaneocuboid fusion is seen only in patients with Muenke syndrome.³⁷⁹ Additional hand deformities in 8 patients with Muenke are given in Table 20.

Crouzon/Pfeiffer Syndrome

Before the discovery of the *FGFR2* mutation that causes both Crouzon and Pfeiffer syndromes, the distinction between these 2 clinical diagnoses was based on the deformities of the extremities. In most patients of hand and foot deformities, the diagnosis was Pfeiffer syndrome. Because a number of identical *FGFR2*

mutations are reported in patients who were clinically diagnosed with either Crouzon or Pfeiffer syndrome, the distinction between these 2 syndromes seems to be of less relevance.

Cohen describes Pfeiffer syndrome, in which the deformities of the extremities consist of broad thumbs and halluces with radial or medial deformities, brachydactyly, and a varying degree of syndactyly.³⁸⁰ Progressive ankylosis of the elbows is possible.

Anderson describes mild radiologic deformities of the feet, such as deformities in shape, fusion or underdevelopment of the phalanges, metatarsalia, and tarsalia.³⁸¹ Only 3 of the 18 patients had no deformities.

The *FGFR1* P25R mutation shows characteristic hand and foot deformities with partial webbing of the fingers with broad thumbs and big toes, deviating toward medial, and characteristic syndactyly of the second web and sometimes of the third web.³⁸² The patients of the reported 3 families had, however, minimal or no craniosynostosis. Some patients had ankylosis of the elbow.

Therapy: surgical corrections of the hands are necessary in only very few patients.

Conclusions

- Level 1** It has been shown that Apert syndrome always co-occurs with severe deformities of the upper and lower extremities.
*A2 Wilkie, 1995*³⁸³
*A2 Bochukova, 2008*³⁸⁴
- Level 1** Crouzon/Pfeiffer, Saethre-Chotzen, and Muenke syndrome co-occur with mild deformities of the hands and feet.
*A2 Muenke, 1997*⁴⁹
*B Kress, 2006*⁶⁰
*B Trusen, 2003*³⁷⁹
- Level 3** It seems likely that type 3 hand deformity in Apert syndrome requires early correction (between 3 and 6 months).
*C Fereshetian, 1991*³⁷¹
*C Guero, 2005*³⁷⁴
*C Upton, 1991*³⁶⁴
*C Zucker, 1991*³⁷²
*D Upton, 2006*³⁷⁶

Considerations

Patients with (still) unoperated hands frequently show paronychia. Hardly anything about this condition, however, is reported in the medical literature. These infections cause a lot of discomfort for

TABLE 19. Additional Hand and Foot Deformities in Saethre-Chotzen Syndrome, According to Trusen

Hand	Brachyphalangy	21	
	Clinodactyly	17	
	Syndactyly—second web	15	
	Syndactyly—third web	2	
	Carpal fusion	8 (NN = 24)	
	Trapezium-trapezoid fusion	6	
	Cone-shaped epiphyses	9 (NN = 17)	
	Foot	Brachyphalangy	10 (NN = 26)
		Clinodactyly	12
		Partial syndactyly	14
Tarsal fusion		10 (NN = 25)	
Cone-shaped epiphyses		15 (NN = 17)	
Duplication distal phalanx hallux		12	
Triangular epiphysis distal phalanx hallux	0		

TABLE 20. Additional Hand Deformities in Muenke Syndrome, According to Trusen

Hand	Brachyphalangy	8	
	Clinodactyly	4	
	Syndactyly second web	1	
	Syndactyly third web	1	
	Carpal fusion	1	
	Trapezium-trapezoid fusion	1	
	Cone-shaped epiphyses	4 (NN = 7)	
	Foot	Brachyphalangy	5
		Clinodactyly	1
		Partial syndactyly	5
Tarsal fusion		2	
Cone-shaped epiphyses		6 (NN = 7)	
Duplication distal phalanx hallux		0	
Triangular epiphysis distal phalanx hallux	0		

the patient and require intensive care. Early treatment of the complex syndactyly improves this situation. Therefore, either prevention or treatment of paronychia is an additional reason to commence with early treatment of the hand deformity.

Recommendations

The functions of the upper and lower extremities of Apert patients need to be monitored during time with physical examinations and radiography. Treatment of the hands should commence at the earliest age possible, especially for type 3, and preferably performed simultaneously for both hands by a pediatric surgeon.

Monitoring of the lower extremities is performed by a pediatric orthopedic surgeon/pediatric rehabilitation physician/pediatric plastic surgeon.

16. COGNITIVE FUNCTIONING AND BEHAVIOR

Basic Questions

1. What is the prevalence of cognitive and/or behavioral problems for the different types of nonsyndromic and syndromic craniosynostosis?
2. What are the possible risk factors for cognitive and/or behavioral problems in patients with craniosynostosis?
3. What kind of screening (nature and frequency) is indicated for the detection and treatment/guidance of the problems?

NONSYNDROMIC CRANIOSYNOSTOSIS

Introduction

There is a large body of research on the cognitive functions and behavior of children with nonsyndromic craniosynostosis. The results of these studies, however, differ greatly; some researchers report hardly any cognitive and/or behavioral problems in children with nonsyndromic craniosynostosis,^{39,141,385-387} whereas others report very high percentages (up to 100%) of cognitive and/or behavioral problems. This discrepancy can often be explained by the methodological limitations that characterize many of these studies. A few of the most prevalent methodological limitations are

- insufficient description of how patients were recruited, so that it is not clear whether the patient group is representative, or whether there may be a selection bias;
- the studied groups are often small; moreover, the ages of the children vary greatly, necessitating the use of many different measurement instruments;
- often measurements instruments are applied that are not standardized, validated, or normalized;
- in studies on the prevalence of behavioral or learning problems, the results are often not corrected for IQ;
- the established prevalence of, for example, behavioral problems or a low IQ, is not compared with that of the general population.

In this chapter, only those studies with a reasonably reliable design (level B or C) are used to answer the above-mentioned basic questions. All articles that do not have minimally level C are disregarded.

Summary of the Literature

Question 1: What Is the Prevalence of Cognitive and/or Behavioral Problems for the Different Types of Nonsyndromic Craniosynostosis?

Intelligence

In 2 large studies (N = 167 and N = 86) on trigonocephaly, it was shown that children with nonsyndromic trigonocephaly (trigonocephaly without other birth defects) as a group have an average IQ-score that does not differ from that of the standard group.^{39,387} In the study by Lajeunie, the average IQ-score of this group was 103 (N = 127, SD = 12),³⁹ in the study by Van der Vlugt³⁸⁷ it was 104 (N = 60, SD = 20). These studies also showed that children with nonsyndromic trigonocephaly are not more likely to have an intellectual disability.

In a smaller study, (N = 24) Kapp-Simon³⁸⁸ found that very young children with trigonocephaly (average test age 7.3 months) had an average score (MDI-score = 94; SD = 6) on the mental scale of the Bayley Scales of Infant Development (BSID-II), but a low mean score (PDI-score = 84; SD = 11) on the motoric scale of the BSID-II. Speltz³⁸⁹ and Starr³⁹⁰ found in respectively 27 and 35 children with trigonocephaly scores comparable with those reported by Kapp-Simon³⁸⁸ on the mental scale of the BSID-II (Speltz: MDI = 95, SD = 7; Starr: MDI = 92) and on the motoric scale of the BSID-II (Speltz: MDI = 87, SD = 14; Starr: MDI = 84). The articles of Kapp-Simon³⁸⁸, Speltz,³⁸⁹ and Starr³⁹⁰ seem to deal with the same patient group, to which patients are added. It appears to be a prospective, multicenter study. The preoperative test data of the children are reported in Kapp-Simon³⁸⁸ and Speltz.³⁸⁹ The mean age of the children was 7.3 months in the study by Kapp-Simon and 6.5 months in the study by Speltz. Starr³⁹⁰ reports both the preoperative and the postoperative test data of the children. The latter study only analyzed data of those children for whom both preoperative and postoperative test data, however, were available. And, while the response rates in the studies by Kapp-Simon and Speltz are high (respectively 83% and 89%), the response rate drops to 55% when only the data are analyzed from the children for whom both preoperative and the postoperative test data are available. The average age of the children at postoperative testing was 18.4 months.

There are, therefore, some differences in the results of the studies between, on the 1 hand, the studies by Lajeunie³⁹ and Van der Vlugt³⁸⁷ and on the contrary, those from Kapp-Simon,³⁸⁸ Speltz,³⁸⁹ and Starr.³⁹⁰ Lajeunie and Van der Vlugt report that children with nonsyndromic trigonocephaly as a group have an average IQ-score and no increased risk of intellectual disability. The patient group from Kapp-Simon, Speltz, and Starr obtained as a group an average score on the mental scale of the BSID-II (MDI = 94, 95, and 92), but a lower mean or even a low mean score on the motoric scale of the BSID-II (PDI = 84, 87, and 84).

One possible explanation for these differences is that the data of the children with nonsyndromic and with syndromic trigonocephaly in the studies by Lajeunie and Van der Vlugt are represented in comparison. From these data, it appears that children with syndromic trigonocephaly have a strongly increased risk of intellectual disability (IQ < 70). The patient groups of Kapp-Simon, Speltz, and Starr consisted of both children with nonsyndromic and with syndromic trigonocephaly. Only data from the group as a whole, however, are presented. It is, therefore, possible that the lower scores they found might be on account of the lower scores of the children with syndromic trigonocephaly in particular.

The differences in outcome could also be explained by the difference in age: the children in the study by Kapp-Simon³⁸⁸ and Speltz³⁸⁹ were very young (mean 7.3 and 6.5 months, respectively); those in the studies by Lajeunie³⁹ and Van der Vlugt³⁸⁷ were older (mean 1.13 year and 7 years, respectively). Moreover, the standard scores of the BSID are considered insufficient by the COTAN (Dutch Committee on Testing Practices), especially for children younger than 12 months. Also, the MDI and PDI scores on the BSID at a very young age (4 months) are poor predictors for the IQ-score at a later age (4.5 years).³⁹¹ It is also remarkable that the control group, as reported in the article of Speltz,³⁸⁹ obtained significantly lower scores as well at the BSID-II in comparison with the standard group.

Mathijssen¹⁰³ found that more than 90% of 220 children with frontal plagiocephaly (with and without the P250R *FGFR3* mutation) had an IQ of >90. There was no significant difference in IQ between children with and without the P250R mutation. In studies from 1993 and 1998 in 17 and 35 patients with plagiocephaly, respectively, Kapp-Simon^{392,393} found that they as a group obtained average scores on the mental scale of the BSID-I (N = 17, MDI = 101, N = 35, MDI = 98).

The results of the multicenter study by Kapp-Simon,³⁸⁸ Speltz,³⁸⁹ and Starr,³⁹⁰ similar to the trigonocephaly group, deviate slightly from those of the above-mentioned studies. Kapp-Simon reports data of 18 patients with plagiocephaly. The mean score of these children on the mental scale of the BSID-II (MDI) was 93; that on the motoric scale 85. Speltz³⁹⁰ reports data of 28 children with plagiocephaly, the MDI was 90 and the PDI 83. In the study by Starr (response rate 55%) in 36 children, the MDI was 88 and the PDI 82.

A number of studies showed that the mean IQ of children with scaphocephaly does not deviate from that of the standard group and that children with scaphocephaly do not have an increased risk of intellectual disability.^{141,233,385,386,393}

In their most recent study, Kapp-Simon,³⁸⁸ Speltz,³⁸⁹ as well as Starr,³⁹⁰ however, report that children with scaphocephaly score significantly lower on the BSID-II than the standard group: Kapp-Simon: N = 49, MDI = 90, PDI = 85; Speltz: N = 62, MDI = 91, PDI = 84; and Starr: N = 86, MDI = 94, PDI = 84.

Summarizing, the results of most of these studies show that the children with nonsyndromic craniosynostosis as a group do not significantly deviate from the standard group with regard to intelligence and do not have an increased risk of intellectual disability. In the multicenter studies by Kapp-Simon, Speltz, and Starr children with craniosynostosis as a group, however, scored significantly lower than the standard group on both the mental and the motoric scale of the BSID-II. In the study by Kapp-Simon, the MDI scores distribution in the patient group, however, differed significantly from that of the standard group. Children with craniosynostosis had no increased risk of a score <85 on the mental scale of the BSID-II (more than 1 SD lower than the average of 100). Remarkably, none of the children in the patient group, however, had an MDI > 115. Total 48% of the studied children scored <85 on the motoric scale of the BSID-II (versus 16% in the standard group). Not a single child from the patient group also scored >115 on the motoric scale, whereas this was 16% in the standard group. Moreover, in the studies by Kapp-Simon, Speltz, and Starr, the study findings are not presented separately for children with nonsyndromic and with syndromic craniosynostosis, which may have led to lower test scores.

Language

Kapp-Simon³⁸⁸ used the Preschool Language Scale III (PLS-III) to evaluate the expressive and receptive language skills of 100 children with isolated craniosynostosis (mean age 7.3 months). The PLS-III has 2 scale indices: the respective (PLS-AC) and the

expressive language score (PLS-EC). For both scales, the norm score is 100 with a standard deviation of 15. The average score of the total patient group was 90 on the receptive and 96 on the expressive scale. And, even though both scores are within the standard range (85–115), these are significantly lower than the norm score.

The 24 children with trigonocephaly obtained an average score of 91 (SD = 13) on the receptive scale and an average score of 98 (SD = 13) on the expressive scale. For children with plagiocephaly (N = 18), the average score was 89 on the receptive scale and 97 on the expressive scale. And for the 49 children with scaphocephaly, the average score on the receptive scale was 91 and on the expressive scale was 95. A group of 9 children with lambdoid synostosis obtained an average score of 88 on the receptive and 94 on the expressive scale of the PLS-III. In the (same) study by Speltz³⁸⁹ in 125 children, the average scores on both the receptive and the expressive scale of the PLS-III of the craniosynostosis group did not significantly differ from those of the control group. But both the groups scored somewhat lower than the standard group on both scales (craniosynostosis group: PLS-III-AC = 92, PLS-III-EC = 97; control group: PLS-III-AC = 95 and PLS-III-EC = 97).

A study by Shipster²³³ in 76 children with scaphocephaly (mean age 4 years and 7 months) seems to show that these children have a significantly increased risk (37% versus ± 6% in the general population) of specific speech/language problems (= speech/language problems that are not the result of a low IQ), notably expressive language problems.

Other Cognitive Functions

Young children with nonsyndromic craniosynostosis obtained memory and response inhibition task scores that did not deviate significantly from the scores of a control group without craniosynostosis.³⁹⁴

Behavior

Children with trigonocephaly who have an IQ of 85 or higher, have no increased risk of behavioral problems.³⁸⁷ Children with trigonocephaly who have an IQ lower than 85, have a (strongly) increased risk of behavioral problems, similar to all other children (without craniosynostosis) who have an IQ of lower than 85.^{387,395}

Bolthausen³⁸⁶ studied the behavior of 24 children with scaphocephaly using the Child Behavior Checklist (CBCL). The average scores of the patient group (CBCL total score, CBCL internalizing score, and CBCL externalizing score: T = 52.9, T = 53.0, and T = 52.53, respectively) were within the normal range (40–60).

SYNDROMIC CRANIOSYNOSTOSIS

Introduction

There are only a few studies reporting on cognitive functions and behavior in children with syndromic craniosynostosis. Only very few of these studies are on B or C level; and are even lacking for some syndromes. In the latter patients, studies may not meet the C-level criteria and therefore may not be very reliable as well.

Summary of the Literature

Question 1: What Is the Prevalence of Cognitive and/or Behavioral Problems for the Different Types of Syndromic Craniosynostosis?

Intelligence

Children with syndromic trigonocephaly (=trigonocephaly together with other birth defects) have a significantly increased risk of intellectual disability. In the study by Lajeunie³⁹ more than 34% of the children had an IQ < 70. In the study by Van der

Vlugt,³⁸⁷ this percentage is 27%. The average IQ of these children was 83 (N = 32; SD = 22) in the study by Lajeunie and 89 (N = 26; SD = 20) in the study by Van der Vlugt.

Mathijssen¹⁰³ found that more than 90% of 220 children with frontal plagiocephaly (with and without the P250R *FGFR3* mutation) had an IQ of >90. There was no significant difference in IQ between children with and without the P250R mutation.

Children with Apert syndrome seem to have a strongly increased risk of intellectual disability.^{265,396,397} Patton³⁹⁷ reported that 52% of the 29 patients in his study had an IQ lower than 70. In the study by Renier,²⁶⁵ this percentage was 50%.

The average IQ of the patient group of Lefebvre³⁹⁶ was 74, that of Renier²⁶⁵ 62.

In a study by Shipster³⁹⁸ on cognitive functions, speech and language skills of children with Apert syndrome, the cognitive functions, however, were on an average level. The cognitive functions were studied using the Core Subscales of the British Ability Scales (BAS-II). These consist of 2 verbal tests and 2 tests on nonverbal functions. These 4 subtests provide a score for the general cognitive ability (GCA) and a nonverbal composite (NVC), based on the 2 nonverbal subtests. For both scales, the norm score is 100 with a standard deviation of 15. The children with Apert syndrome obtained an average score of 94 on the verbal scale (GCA) and an average score of 96 on the nonverbal scale (NVC).

True, this study was conducted in only 10 children, but seeing that only 12 children met the eligibility criteria (all children with Apert syndrome aged 4–6 years at the Craniofacial Unit of the Great Ormond Street Hospital), the response rate was 83%. One of the 2 eligible children who did not participate in the study had been previously tested and found to have an average intelligence. The second child functioned on a low average level at school.

So far, there is no reliable study on the cognitive functions and the behavior of children with Saethre-Chotzen syndrome. The few available studies have serious methodological limitations.^{59,60,399,400} These studies seem to suggest that children with Saethre-Chotzen syndrome have an increased risk of cognitive problems. This risk seems to be larger in the case of a deletion than in the case of a mutation.

Even though the studies by Kress,⁶⁰ Muenke,⁴⁹ and Flapper⁴⁰¹ on Muenke syndrome have serious methodological limitations, their studies suggest that patients with the *FGFR3* P250R mutation (=Muenke syndrome) possibly have an increased risk of intellectual disability.

Mathijssen¹⁰³, however, reported an average IQ in children with a mild form of Muenke syndrome and concluded that these children's IQ does not differ significantly from that of children with frontal plagiocephaly without *FGFR3* P250R mutation.

Even though the study by Flapper⁴⁰¹ (2009) has serious methodological limitations, this study seems to suggest that children with Crouzon syndrome and Pfeiffer syndrome have an increased risk of intellectual disability.

Language

Since different types of syndromic craniosynostosis (eg, Apert syndrome, Muenke syndrome) are associated with hearing loss, clinicians should remain alert about the speech/language development in children with these syndromes.³⁹⁸

In the study by Shipster³⁹⁸ on the cognitive functions, speech and language development of children with Apert syndrome, 8 of the 10 tested children had language difficulties. All 8 children had expressive language problems and 4 of them had problems with receptive language skills as well, despite the fact that the intellectual capacities of the group was of average level.

Behavior

Intellectual disability often coincides with behavioral problems. And since children with syndromic craniosynostosis seem to have an increased risk of intellectual disability, the likelihood of behavioral problems also appears to be higher for this group. Children with intellectual disability have a 50% to 60% chance to develop behavioral problems.³⁹⁵

In summary, children with syndromic craniosynostosis seem to have an increased risk of cognitive and/or behavioral problems. There, however, are large differences in outcome between the different syndromes. And even within a syndrome, outcomes may range widely; for example, Renier²⁶⁵ reports a 10 to 114 range in IQ score.

Basic Question 2: What Are the Possible Risk Factors for Cognitive and/or Behavioral Problems in Patients With Craniosynostosis?

In different studies, researchers have tried to uncover factors that could correlate with the (worse) cognitive functions of children with craniosynostosis. Factors studied are the following:

- whether or not to perform surgery;
- severity of the malformation;
- age at time of surgery;
- presence or absence of brain abnormalities;
- sex;
- socioeconomic status;
- maternal IQ.

So far, no significant relationship has been found between on the one hand the above-mentioned factors and on the contrary, cognitive functions of children with nonsyndromic craniosynostosis.^{141,233,385,388,390,392,393,402–409}

Basic Question 3: What Kind of Screening (Nature and Frequency) Is Indicated for the Detection and Treatment/Guidance of These Problems?

There are indications that children with (syndromic) craniosynostosis have an increased risk of behavioral problems. By mapping these problems at an early stage, child and parents can be timely referred to appropriate intervention (eg, speech-language therapy, physiotherapy, parent counseling, or parent management training) and adequate education for the child can be found.

Based on clinical experience, it appears useful to start psychodiagnostic testing of children who have an increased risk of cognitive and/or behavioral problems at the age of 2 years, testing for example, personal development, speech and language development, and behavior. The psychodiagnostic test should be preceded by testing for any auditory disorders.

It is important, too, to provide for testing of cognitive functions and behavior when it is time to choose the best type of elementary school. Screening for learning disabilities could take place later, between ages 7 and 9 years.

Conclusions

- Level 2** Children with nonsyndromic craniosynostosis have no increased risk of an intellectual disability (IQ < 70).
C Kapp-Simon, 1993³⁹²
C Arnaud, 1995¹⁴¹

- C Kapp-Simon, 1998*³⁹³
*C Speltz, 1997*³⁸⁵
*B Mathijssen, 2006*¹⁰³
*B Van der Vlugt, 2009*³⁸⁷
*B Shipster, 2003*²³³
*B Lajeunie, 1998*³⁹
*B Boltshauser, 2003*³⁸⁶
- Level 2** Children of 3 years and older with scaphocephaly have an increased risk (37% versus \pm 6% in the general population) of specific speech/language problems, especially of expressive language problems.
*B Shipster, 2003*²³³
- Level 2** Young children with nonsyndromic craniosynostosis obtain memory and response inhibition task scores that are comparable with those of the control group without craniosynostosis.
*B Toth, 2007*³⁹⁴
- Level 2** Children with scaphocephaly and children with nonsyndromic trigonocephaly who have an IQ > 85, have no increased risk of behavioral problems.
*B Boltshauser, 2003*³⁸⁶
*B Van der Vlugt, 2009*³⁸⁷
- Level 2** Children with an intellectual disability have an increased risk of behavioral problems.
*B Dekker, 2002*³⁹⁵
- Level 2** Children with syndromic trigonocephaly have an increased risk of intellectual disability (27–34% IQ < 70).
*B Lajeunie, 1998*³⁹
*B Van der Vlugt, 2009*³⁸⁷
- Level 2** No significant relationship has been found between on the one hand cognitive functions and on the other hand the following factors: whether or not to perform surgery, severity of the malformation, presence or absence of brain abnormalities, age at time of surgery, sex, socioeconomic status, and maternal IQ.
*B Shipster, 2003*²³³
*C Arnaud, 1995*¹⁴¹
*C Bellev, 2005*⁴⁰⁶
*C Kapp-Simon, 1993*³⁹²
*C Kapp-Simon, 1998*³⁹³
*C Kapp-Simon, 2005*³⁸⁸
*C Kapp-Simon, 2007*⁴⁰²
*C Magge 2002*⁴⁰⁴
*C Speltz 1997*³⁸⁵
*C Starr 2007*³⁹⁰
- Level 3** Children with Apert syndrome seem to have a strongly increased risk of being intellectually disabled.
*C Patton, 1988*³⁹⁷
*C Renier, 1996*²⁶⁵
*C Lefebvre, 1986*³⁹⁶
- Level 3** Children with Apert syndrome seem to have an increased risk of speech/language problems.
*C Shipster, 2002*³⁹⁸
- Level 3** Children with Crouzon syndrome, Muenke syndrome, or Saethre-Chotzen syndrome seem to have an increased risk of an intellectual disability.
*C Arnaud, 2002*¹⁵¹
*D Flapper, 2009*⁴⁰¹
*D Kress, 2006*⁶⁰
*D Muenke, 1997*⁴⁹

Considerations

Standard psychologic testing of all children with craniosynostosis (nonsyndromic and syndromic) places a large burden on the team, while it is often not necessary. It is advisable to apply testing as sensibly as possible. Routine screening on developmental and behavioral problems is indicated to identify patients who may

develop problems during time. This screening should take place at least at a young age, approximately, the time of entering primary school, and between ages 7 and 9 years to discover any learning disabilities. The team will have to make arrangements on who will perform this screening, and when indicated, fast referral to the psychologist is necessary.

Auditory processing disorders are regularly seen in children with syndromic craniosynostosis (see the chapter on hearing impairments), increasing the chance of speech/language problems for these children.

Recommendations

Children with scaphocephaly and Apert syndrome need to be tested for speech and language problems from the age of 2 years approximately.

Children with syndromic craniosynostosis need to be screened on a regular basis for cognitive and behavioral problems and, after referral, to be evaluated psychologically. These children are to be screened at least when they are 2 to 3 years old, at the moment of (primary) school choice, and between ages 7 and 9 years for any learning disabilities.

Psychologic testing on children with craniosynostosis is preferably conducted in the hospital where the child is under treatment for his or her craniosynostosis. If these tests are conducted elsewhere, it is important that the results of these tests are reported to the psychologist in the craniofacial team.

17. PATIENTS' AND PARENTS' PERSPECTIVES

Opinions of patients and of the parents of patients are important when it comes to creating guidelines. We (advisor of Department of Professional Quality of the Dutch Order of Medical Specialists, social worker, and nurse specialist) felt the need to enter into dialogue with parents and patients in a focus group addressing their experiences with the care and counseling of the child with craniosynostosis. Furthermore, we wished to make an inventory of the wishes and expectations about this counseling.

Via patient association LAPOSA, parents of children with craniosynostosis as well as older patients themselves were invited to participate in the focus group. Our aim was to provide for as much diversity as possible, that is, different treatment location; both nonsyndromic and syndromic craniosynostosis, different treatment techniques, and variety in ages. In the end, we held 2 evening sessions. In the first session, 9 parents of young children (1–6 years) attended. The second session was with parents of school-going children (6–18 years), and older patients (15+), and partners. The number of participants was 8 and we interviewed 2 externally.

The focus group discussions were mediated by Teus van Barneveld, advisor in the Department of Professional Quality of the Dutch Order of Medical Specialists and involved in the development of the guideline. Both social worker Francien Meerens and nurse practitioner Hansje Bredero-Boelhauer attended as well.

The topics addressed were the topics dealt with in the guideline: Intake/diagnosis; treatment; aftercare.

A summary of these sessions is presented below:

Intake

Even before intake, there was often considerable uncertainty about the condition, resulting in:

- many referrals (general practitioner >> pediatrician >> specialized center);
- late referrals;
- unnecessary or inaccurate or incorrect diagnostics;

- receiving incomplete or incorrect information.

All this is a source of great agitation/stress for the parents. It forces them to solve everything on their own.

Wishes/Needs

Education to child health clinics, obstetricians, general practitioners, and pediatricians. Short interval between suspicion of craniosynostosis to first contact. Clear information (written/internet) alongside the opportunity to ask questions and guidance when processing the information. Easy access to a member of the team. This contact must be able to handle coordination issues but also medical/psychosocially emotional issues.

Diagnosis and Treatment

Different treatment methods are available, but the how, what, and why of each method are unclear for the parents. This brings uncertainty and makes it difficult to make a well-balanced choice. Some parents indicated that the period between first contact and intervention was very long. They started to worry increasingly about the health of their child. Furthermore, the effect that the diagnosis can have on the family and the future raises concern. Even after the first treatment of children with syndromic craniosynostosis, the parents are still worried. Then, many questions arise, for example, on the child's development, auditory perceptions, and visual acuity. Parents notice that quite some things tend to go wrong or almost wrong, because of insufficient knowledge of other disciplines (eg, technicians). And, in general, they were not satisfied with the postoperative pain management as well.

Wishes/Needs

- Being able to choose the treatment. This means that they want to hear objectively from their treating physician which possible treatments are available, with all advantages and disadvantages.
- Once again, easy access to a member of the team. This contact should have an overview of all medical/psychosocial aspects. In addition, he or she should be able and allowed to independently undertake steps outlined in the treatment plan. To be able to coordinate multidisciplinary care is seen as important.
- Clear information from the physicians involved (which includes being able to talk to everybody), a personal approach.
- The need for social work. This is more important for parents with children with syndromic craniosynostosis. The team has to become actively involved here.
- Contact with a clinical geneticist should be offered whenever relevant.
- Contact with peers. This may be via the Internet (eg, Hyves, Facebook, blogs) or via patient associations.
- Educating disciplines involved in the treatment.
- Good postoperative pain management.

Aftercare

In this period, patients and parents are still confronted with the consequences of the condition. Questions and/or problems arise especially about choosing a school, dealing with practical issues,

accepting the abnormal appearance, resilience, and the physical/mental limitations. It is not always easy to smooth the contact between the care and educational sectors.

In the case of invasive procedures, active preparation and counseling by the team both in the home or home substituting situation and at school are highly appreciated.

When a child is being managed in multiple healthcare facilities, it is not easy to keep track. Sometimes, the parents and patient are even confused who should be doing what and when.

Regarding insurance: this usually gives the necessary problems. The Dutch Exceptional Medical Expenses Act (AWBZ) always is a source of problems. The basic health insurance package usually presents no problems. There appear to be many differences between the various health insurance packages.

The transition from child to adult care is a complex topic (eg, Who is the contact, which care can be left to the child itself?). The transfer to the adult hospital is certainly experienced as very suddenly.

In general, parents indicated that they managed to find their way in handling the situation. Support from the team in dealing with this process, however, can be valuable.

Wishes/Needs

- Also in the aftercare period, there is a need for a contact person to whom questions can be addressed, even if these do not seem to be directly related to craniosynostosis.
- Proactive involvement of the psychosocial team during the periods of treatment and the transition periods of the different developmental stages of the child.
- Guidance in choosing a school with behavioral/mental issues. Guidance may also be provided in a peripheral setting, but the team should give active attention to this issue.
- Communication between peripheral treatment providers and the team.
- Easy access to social work.
- Contact with a clinical geneticist when planning a new pregnancy.
- Preparation and guidance for the transition process.

18. PSYCHOSOCIAL FUNCTIONING

Basic Questions

What psychologic problems are the child, parents, and family faced with in the following phases:

- period of diagnosis up until the first treatment;
- follow-up treatment/follow-up, coinciding with the school-going age;
- aftercare, the period during adolescence and inventory of the last treatment.

What psychosocial care, for parents and patient, is indicated at what moment?

The questions mentioned above spring from the fact that not only the condition itself but also the medical treatment of craniofacial disorders influences psychosocial aspects. It can influence not only the child itself, but also his or her parents, brothers/sisters, (extended) family, friends, school, job of the parents. A whole system is involved in the treatment of a child with a craniofacial deformity. From a psychosocial perspective, it concerns the psychic (intrapyschic), relational (interpsychic), and social aspects of his or her life.

Craniofacial care clearly differs for patients with syndromic craniosynostosis and those with nonsyndromic craniosynostosis. In general, it appears that for syndromic craniosynostosis treatment lasts much longer, includes more surgical procedures and has a more sustaining influence on the life of the patient, possibly causing more psychosocial problems.

Summary of the Literature

Parents of children with a syndromic malady are confronted with long-term care paths, many different social workers and health professionals from different organizations. Many already receive support from different agencies (eg, MEE Foundation, Child protection, and Mental Health Care). Not all parents appreciate to receive support from the team. It is important to make an inventory of the psychosocial situation of the family on a regular basis.⁴¹⁰ In particular, the periods of interventions or transitions are important.

During the entire route, it is important to make it easy to contact a member of the team.⁴¹¹ Apart from medical knowledge about the diagnosis, this person should also have an overall (both medical and psychosocial) insight (holistic approach).

Period Up to and Including the First Treatment

During this period, psychosocial care of the parents will be central, because this period usually coincides with the baby and infant stage.

The following bottlenecks for the parents, or rather the family, can be identified: long-term uncertainty about the diagnosis, anxiety about a new pregnancy, uncertainty about the expected development, difficulty in choosing a school, coping of the patient and parents with the condition and the abnormal appearance, education, and having to deal with contrasting explanations in the hospital.^{412,413}

Diagnostics and Treatment

Parents indicate that there is a lack of knowledge at child health clinics and among general practitioners. Moreover, in the peripheral hospitals, they do not know what tests to perform and in what order. This results in a repetition of tests, very often leading to uncertainty and more stress for the parents.

In different studies and international guidelines, it is shown that during this first period a number of issues are important.^{412,413} Education/information about recommended treatments, options, risk factors, advantages, and costs to support them in

- making a well-balanced decision in the interest of the child (all advantages and disadvantages, locations, timing, procedures, experience, etc.).
- preparing the child and themselves for all recommended procedures.

To be alert to psychosocial problems/medical history⁴¹¹ in syndromic conditions, a focus/psychoeducation on emotional processes in parents/other family members during different phases of life.^{413,414}

Information must be easily understandable, tailored to the cognitive level, the social/emotional, and the medical situation.^{415,416} There is also a need for written information or web-based information.^{412,417}

Social Support

Brooke indicates that social support to the parents is an important protecting factor.⁴¹⁸

Processing, Acceptance, Parenthood, and Relationship

Supporting the parents to help them build self-confidence and to come to accept their situation, is considered to be one of the main tasks of the craniofacial team. In this case, the amount of time the team dedicates to the parents influences their perceived amount of support, and relatedly, the amount of stress. Both from clinical experience and the literature, it is clear that a too heavy burden increases parental stress. Even though the studies are small, similar results are found in multiple studies.^{412,413,417}

Clinical impression shows that parents with a child with a very visible deformity may be more inhibited in accepting this condition. Research by Sarimsky⁴¹⁴ confirms this for children with Apert syndrome.

Syndromic conditions are an additional stress factor to the relationship of the parents. In 60% of the divorced parents, the relationship between the parents, however, was already in jeopardy before the birth of the child. If the relationship is good, this stress factor is less prominent. Within the framework of “Early Intervention,” it is sensible to pay attention to this as well.⁴¹⁹

Follow-Up Treatment(s) and Follow-Up

Behavioral issues arise often if the child is already a bit older (this chapter deals with toddler, kindergarten, and high school age). Some behavioral issues are the result of a lower IQ (see chapter 16), some arise from the embarrassment of the parent to become involved in the upbringing, for example, as a result of the craniosynostosis (clinical experience), and some are because of reasons that are currently unclear.

During this period, psychosocial care initially is still strongly focused on the parents and the child is often counseled through the parents. As the child grows older, the focus will be more on the individual child.

School

At the time when the parents have to choose a school for the child, they may have questions about his or her cognitive functions. In particular, this is to be expected for children with syndromic craniosynostosis. There is no literature available about school choice. From clinical experience, we know that, if the parents have a problem, they will be looking for agencies that can support them and they regularly find answers on their own initiative. In the focus group, the parents mentioned that they appreciate backup support from the team.

Appearance/Resilience

If children are becoming more aware of their abnormal appearance, the parents will also question how they can support their child in this regard, for example, when it is bullied or when it is extremely shy. Literature describes that in this period, emotional and pedagogical support of the parents is of importance, because the amount of parental resilience influences the resilience of their child.⁴²⁰

Upbringing

Clinically, it is seen that a number of parents, because of the craniosynostosis (irrespective if it is syndromic or not) find it difficult to exert their educational tasks in such a way that they feel they have a grip on the child’s behavior. For various reasons related to the craniosynostosis, this may result in a mismatch between the required and provided upbringing. Information to the parents and screening for problems with the child’s behavior possibly followed by treatment from the craniofacial team are reported as important interventions to prevent problems.^{412,413}

Medical Treatment

Based on clinical experience, the following issues deserve attention.

For children and adolescents, a hospital admission, a medical test, or surgery can sometimes become a traumatic experience, causing posttraumatic stress syndrome (PTSS) symptoms (eg, problems with sleeping, separation anxiety, extreme fear for physicians, hospitals, etc.). Naturally, it is important to prevent this. Here, as well clinical experience shows that professional preparation of the child as well as the parents by a pedagogical worker is valuable and can prevent PTSS symptoms. Children with PTSS symptoms can receive treatment from a psychologist. There is no literature on this topic with reference to children with craniosynostosis.

Some medical treatments (such as wearing an external frame or other types of distractor devices) require a strong motivation and a high perseverance of the child and his or her family. It is important as well that the child is able to sustain such treatment.^{421,422} For families for whom the burden exceeds their coping ability, treatment success is an important risk factor. De Sousa⁴¹¹ and Lefebvre⁴²³ indicate that the timing of the treatment is important and that it preferably should take place when the family shows sufficient coping ability. In addition, Lefebvre⁴²³ indicates that expectations about the treatment should be realistic. Good information and an estimation of the child's coping ability but also that of the family are essential. The medical social workers should be able, if desirable, to adapt their language use to the level of the child.^{415,416}

Adolescence, Aftercare, Adulthood

Adolescence is the period when a child separates himself or herself from his or her parents.

The craniofacial team often encounters the following issues:

Appearance + Own Meaningfulness

Over one third of these adolescents experience stigmatization because of the abnormal appearance. Many adolescents are able to deal with this in a robust manner. It, however, is important to ensure psychologic support when problems arise. Counseling is aimed at the psychosocial adaptation and the self-understanding, social skills, and the self-image of these adolescents.^{424,425} Information itself is not enough especially for these "experienced" adolescents; it is important that they learn more about the procedures.⁴¹⁶ In this manner, they are involved in the decision-making, which in turn has a positive influence on their cooperation, satisfaction, and self-management.⁴¹⁵

Transition

Young persons are, according to the Dutch Medical Treatment Act, fully responsible for the decisions about their treatment from the age of 16. For those with a syndromic condition, for whom the parents have been making decisions for a long time, this can be a complicated transition. It may be desirable to offer support to the parents and/or adolescent in finding a new balance. In that case, it would seem important to develop the adolescent's autonomy and to find a way for the parents to continue with their parental duties. Finally, there should be continuity in the transition of care toward the adult care system.⁴²⁶ This whole process will be influenced if there is a developmental delay.

Posttraumatic Stress Disorder (PTSD)

Posttraumatic stress disorder occurs as a result of experiencing a traumatic event. A traumatic event is understood to be an event

characterized by the violation of the physical integrity and/or threat of death. From a young age, children with craniosynostosis experience stressful events and events that can cause their physical integrity to be violated; they are often handled by more than 1 adult at the same time to receive intravenous therapy against their will or to be x-rayed. Also pain, being away from their familiar environment, and separation from the parents are stress-increasing factors for the child.

The parents of these children may experience many stressful events as well. Parents often have to look on helplessly while their child suffers and can often do very little to help the child. For parents, the cranial surgery on their young child and the subsequent hospital admission is usually also a traumatic event. As a result of these stressful events, both parents and the child can develop acute stress responses. For most parents and children, these responses disappear during time, but they will be sustained in some parents and children, so that the events are not properly processed. This will cause PTSD.

A study by Bronner⁴²⁷ shows that 1 of every 10 children and parents develop PTSD after admission of the child to the intensive care unit. Stress responses of the parents (especially of the mother) are important indicators for PTSD in the child. The most important indicator of PTSD in the parents is their psychiatric vulnerability and the way parents deal with the admission to the intensive care unit. It is estimated that PTSD is present in approximately 8% of the general population.⁴²⁸ Posttraumatic stress disorder symptoms co-occur with symptoms of stress, and can manifest both as physical and mental problems. Posttraumatic stress disorder left untreated has a severe negative impact on the development and the psychosocial functions.⁴²⁹ Prevention of PTSD as well as early recognition and treatment of PTSD can improve the patient's quality of life.⁴³⁰

Conclusions

- Level 3** Posttraumatic stress disorder is present in $\pm 10\%$ of children admitted to an intensive care unit and in their parents.
C Bronner, 2008⁴²⁷
- Level 3** Stress reactions of parents (especially of the mother) are important predictors of PTSD in children.
C Bronner, 2008⁴²⁷
- Level 3** Parents with a limited coping ability and a psychiatrically burdening background are more prone to stress.
C Coulter, 1991⁴¹²
- Level 3** A too large burden for the parents leads to more stress.
C Campis, 1991⁴¹³
C Coulter, 1991⁴¹²
- Level 3** In treatment and intake for nonsyndromic craniosynostosis and syndromic craniosynostosis, the psychosocial situation of the family must have been mapped.
C Coulter, 1991⁴¹²
C Sarimsky, 1998⁴¹⁴
C St. John, 2003⁴¹⁹
- Level 3** Training/group work, aimed at social resilience (for parents and/or child) can strengthen the self-image.
C Robinson, 1996⁴²⁰
- Level 3** The timing of the interventions should be in accordance with the family's coping ability.
C Lefebvre, 1978⁴²³
C de Sousa, 2008⁴¹¹
- Level 3** In syndromic conditions, there is an increased risk of psychosocial problems.
C Sarimsky, 1998⁴¹⁴
C St. John, 2003⁴¹⁹
- Level 3** An easily accessible contact person is a great support for the parents.
C de Sousa, 2008⁴¹¹

- Level 3** Medical social workers should take into account the patients' level of development.
*C Chapados, 2000*⁴¹⁶
*C Lefebvre, 1982*⁴¹⁵
- Level 3** Besides oral information, adequate written (digital) information is also required.
*C Coulter, 1991*⁴¹²
*C Trulsson, 2003*⁴¹⁷
- Level 3** Social support is considered very important as well as contact with peers.
*C de Sousa, 2008*⁴¹¹
- Level 3** Adolescents do not always have realistic expectations of the treatments and this should be taken into account when preparing them for the treatments.
*C de Sousa, 2008*⁴¹¹
- Level 3** Adult craniostylosis patients have psychosocial problems on a regular basis.
*C Sousa, 2008*⁴¹¹

Considerations

There is some reluctance in the regular health care system to initiate treatment and counseling routes because sufficient knowledge of the condition in question is not always present. For patients and their systems, recognition is often an important tool to develop new coping strategies. The team should contain social workers who have obtained enough expertise about the craniofacial deformity allowing them to treat individual mental problems, system problems (parents/family) as well as to deal with practical questions and problems. In view of possible system problems, it is recommendable that the medical social worker should be familiar with these methods.

Pedagogical care is a valuable support when preparing the child and parents for interventions/procedures.

There is a clinical impression that it is valuable for a group of parents to discuss their reactions and emotions with a specialized psychosocial worker. Normalizing the reactions and helping to integrate ambivalent emotions aids the parents in exercising their parental duties in such a way that this will benefit the child in learning to develop himself or herself.

Recommendations

The craniofacial center needs to provide good information both orally (tailored to the level of the client system) and on a website/as flyer material.

Both in nonsyndromic and syndromic craniostylosis, a primary contact within the team (the care coordinator) is available who at initial screening can answer both medical and psychosocial questions and if necessary can refer to specialized social work.

Parents/patients have easy access to the care coordinator. The care coordinator has an overview of the treatment path.

It is highly recommended that the multidisciplinary team can offer psychosocial care during each phase of the treatment.

Throughout the years, easy access to a psychosocial worker is offered on a regular basis to map the transitory phases of the families and thereby prevent psychosocial problems as much as possible (prevention).

Individual child treatments are offered as well as family treatments and parent counseling, tailored to the level of the client system.

When the child is reaching school-going age, a specialized social worker will inquire after the choice of school and counseling will be provided for questions and problems arising here. This specialized social worker is expected to be familiar at least with the organization of the educational system, so that he or she can refer correctly if necessary.

Pedagogical care is standard for surgical procedures and available when necessary at the outpatient department to support children and their parents with the preparation/care.

During the entire medical treatment of the child, it is necessary to regularly inquire after symptoms of PTSD in child/parents (eg, by a nurse practitioner).

On suspicion of PTSD in the parents or child, her or she needs to be referred to the psychologist of the craniofacial team or to a psychologist in (the neighborhood of) the place of residence.

Adolescents who wish surgical treatment need to be offered at least 1 contact with a specialized social worker to check whether their expectations are realistic.

The craniofacial center needs to have an Early Intervention Program/peer supervision group in place to increase resilience.

During long sustained treatments that require a lot of motivation from the patient psychosocial screening and, if necessary, support, is desirable.

Patients and their parents are offered contact with peers/a patient association.

Knowledge transfer from the craniofacial team to the periphery (Child Health Clinic; general practitioner; pediatricians) should be well organized.

19. CRITERIA FOR THE CRANIOFACIAL CENTER AND ITS TEAM MEMBERS

Basic Questions

What are the criteria a craniofacial center and its team members should meet?

How is the care for patients with craniostylosis coordinated in the Netherlands?

How to manage quality control of the craniofacial center?

Question 1: What Are the Criteria a Craniofacial Center and Its Team Members Should Meet?

Introduction

The management of patients with nonsyndromic or syndromic craniostylosis requires a multidisciplinary approach, as the care is complex. Because craniostylosis is a rare condition, centralization of care is desirable resulting in a maximum of expertise, ensuring a high quality of care, and permitting scientific research aimed at improving care. Multidisciplinary care requires good coordination and communication within the team and with external health professionals and the patients and parents. Responsibilities and tasks of the various care providers within the team need to be clearly defined.

Comparative studies of the results of different craniofacial teams make benchmarking possible and can exert a positive effect on the quality of care. Benchmarking may take place both on a national and on an international level. Team and overall audits will provide an important contribution to the quality of care, but also to multi-center studies and innovation.

Summary of the Literature

There appear to be 2 types of team organizations worldwide: A team focused on craniofacial deformities only, or a craniofacial team that also treats cleft lip/palate. In the United States and Asia, we generally see a combination of the cleft lip and palate team and the craniofacial team, with an overwhelming majority of cleft lip and palate patients.^{8,9,23,431-437} In Europe,

Australia, and Canada, we usually see separate craniofacial teams.^{2,24,438,439} In Great Britain, there are 4 recognized craniofacial centers nationwide.² The separate craniofacial teams treat a larger concentration of patients with craniosynostosis and other craniofacial growth deformities (hemifacial microsomia, Treacher-Collins syndrome, craniofrontonasal dysplasia, clefts, and craniofacial tumors). Also, the team composition varies, as summarized in Table 21.

Apart from the specialties mentioned in Table 21, the following disciplines may also be part of the team: pediatric IC/neonatal IC,^{9,24,432-434,440} photographer,⁴³⁹ medical illustrator,^{433,438} and coordinator.^{23,437}

The following additional requirements are mentioned:

- Total 1 or 2 representatives of each specialty should be available—and preferably 2 especially for the core specialties—thereby benefiting flexibility, clinical support, collaboration, and quality.⁴³²
- The craniofacial team should always include a neurosurgeon.²⁴
- The presence of a specialized IC is strongly encouraged²⁴ or a requirement.⁹
- Team members should possess appropriate knowledge and skills.^{9,23,437,439}
- The noncore specialties do not have to be present at every consultation, but should be available for consultations.⁴³²
- The different team members come into action at the proper moment during the treatment path.⁴⁴⁰
- A team leader should be appointed.^{9,23,432,437}
- Teams should organize themselves and preferably certify themselves.^{2,432}
- Teams should exchange data on an international level (education, research).⁴³³
- A pediatrician should always be involved for a patient with Apert syndrome.¹
- Joint consultations should be held.^{9,23,431-435,437}
- The team should convene on a regular basis.^{9,23,433-435,437}
- Conduct a survey to evaluate patient satisfaction.⁹

In the literature, the roles of the different specialties are not always discussed. The ACPA does not even mention specialties, but it does mention the necessary specialist knowledge and skills.⁹

Roles of the specialists mentioned are the following:

- Plastic surgeon: operative correction of cranial/facial deformities, including outer ear/hands^{8,432-434,438,439}
- Neurosurgeon: trepanning with/without reconstruction; analysis and therapy of brain malformations^{8,433-434,438,439}
- Oral and maxillofacial surgeon, surgical correction of the maxilla and mandible: if necessary surgical correction of the face with plastic surgery⁸
- Otolaryngology/audiology/speech therapy, hearing: speech and breathing analysis and treatment^{8,9,432-435,438-439,441}
- Orthodontist: collecting data for monitoring craniofacial growth, assisting in the decision about the treatment modality, orthodontic treatment in accordance with surgical requirements, participation in perioperative care and retention, and evaluation of treatment results^{433,442}
- Dentist/prosthetist/dental hygienist: dental care (including position of the teeth) and shape of the jaw, possibly with occlusion images^{432-434,436}
- Pediatrician: analysis of general health, growth and development in children^{8,432-434}
- Ophthalmology, eye direction, and eye function (visual acuity, strabismus, funduscopy)^{8,433-434,438}
- Genetics, analysis of congenital defects and heredity: gene/chromosome analysis^{8,432,434,438,441}
- Anesthesiologist, perioperative monitoring of vital signs, anesthetics, and pain management^{8,433,438}
- Radiologist assesses the imaging tests and helps select the optimal treatment⁸
- Psychology/social work: psychometric/psychologic screening and treatment/guidance, social, and financial family counseling^{8,432-434,438,439}
- Nurse practitioner, care coordinator, guiding the patient and parents, dietary guidance, monitoring of growth and development^{8,433,434}

TABLE 21. Team Composition

lit	Ps	oms	ns	ot	od	De	pa	sw	ps	op	np	se	ge	au	slp	nu	di	an	Other/Remarks
431	4	x	x	x	x	X	X	x			x		x	x	x	x	x		pt
22	x	x	x	x	x			x	x									x	ps and/or oms; ap
432	x	x	x	x	x	X	x	x	x	x			x	x	x	x	x	x	pm, ra, pr
433	4		2	1	4		1	1	1	1	x	2			2				pr, ca, pr; 1 to 2 per spec
434	x		x		x		x	x	x	x			x	x	x	x			pr, rm
440	x	x	x	x	x		x		X	x				x	x	x		x	ra, pm
439	X	x	x	x	x			x	x	x					x			x	Pr
435	x	x		x	x	x	x	x	x		x		x	x	x		x		pr, mo
24	23	12	22	*	*	*	*	*	x	12-23	*	*	19	*	*	*	*	*	of the 23 teams
438	X		x		x	x		x	x	x			x		x			x	ra, ap
9	x	x	x	x	x	x	x	x	x	x		x	x	x	x	x		x	ra, ap,pr; special CF training
437	x	x	x	x	x	x	x	x	x	x			x	x	x				ps and/or oms; ra
23	x	x	x	x	x	x	x	66%	66%	x		x	x	x	x	x			ps and/or oms; pr, ra
8	X	x	x	x	x		x	x	x				x	x	x	x		x	Ra
5	x		x	x	x	x		x	x	x			x						
3	3	x	2	x	x		x	x	x	x	x	x	x	x	x			x	

AN, anesthesiologist; AP, anthropology; AU, audiology; CA, cardiology; DE, dentistry; DH, dental hygienist; DI, dietitian; GE, genetics; NP, nurse practitioner; NS, neurosurgery; NU, nursing; OMS, oral and maxillofacial surgery; OP, ophthalmology; OR, orthodontics; OT, otolaryngology; PA, pediatrics; PM, prenatal medicine; PR, prosthodontists; Ps, plastic surgery; ps, psychology/psychiatry; PT, physiotherapy; RA, radiology; RM, rehabilitation medicine; SE, secretary; SLP, speech therapy; SW, social work; X, team chairman.

*These specialties were not mentioned in this survey.

Aims of treatment within a multidisciplinary structure:

- Better (protocol based) care and coordination (eg, improvement of quality by concentration of care)^{3,8,9,431,433–439}
- Lesser burden for the patients/parents^{3,9,431,437}
- Higher satisfaction of the patients/parents^{3,431}
- More efficient utilization of resources^{3,9,434}
- Better information provision^{3,9,431,437}
- Conduct a survey to evaluate the patient’s satisfaction⁹

Furthermore, an important aim for the craniofacial team should be:

- To organize meetings for parents, patients, relatives, other health care professionals, and the community in a broader sense to enhance understanding of craniofacial deformities⁹
- To organize or support parents’ associations⁹

Conclusions

Level 3

It seems likely that multidisciplinary teams provide better care in the management of craniofacial deformities. The concentration of craniofacial care is higher in “pure” (ie, without cleft lip and palate) craniofacial teams.

*C Mathijssen, 2007*²⁴
*C Parameters ACPA, 2007*⁹
*C Standards USA, 2008*⁴³⁷
*C Strauss, 1998*²³
*C White, 2009*²
*D Anderson, 1985*⁴³¹
*D Capone, 2007*⁴³²
*D Chen, 1988*⁴³³
*D Chin, 1990*⁴³⁴
*D David, 1977*⁴³⁹
*D Holt, 1984*⁴³⁵
*D Munro, 1975*⁴³⁸
*D Pruzansky, 1980*⁴³⁶
*D Strohecker, 1993*⁸

Level 3

A craniofacial team includes at minimum: plastic surgery, neurosurgery, oral and maxillofacial surgery, otolaryngology (with audiology and speech therapy), orthodontics, pediatrics, social work, psychology/psychiatry, ophthalmology, genetics, and anesthesiology. Furthermore, it is highly recommendable to supplement the team with: nurse practitioner, secretary, nursing, radiology, and prenatal medicine. Availability of: physiotherapy, dietetics, dentist, prothetist, rehabilitation medicine, photographer, cardiology, and dental hygienist. A team leader needs to be appointed and plastic surgery is mentioned most frequently in the literature.

*C Mathijssen, 2007*²⁴
*C Parameters ACPA, 2007*⁹
*C Standards USA, 2008*⁴³⁷
*C Strauss, 1998*²³
*C White, 2009*²
*D Anderson, 1985*⁴³¹
*D Capone, 2007*⁴³²
*D Chen, 1988*⁴³³
*D Chin, 1990*⁴³⁴
*D David, 1977*⁴³⁹
*D Holt, 1984*⁴³⁵
*D Munro, 1975*⁴³⁸
*D Pruzansky, 1980*⁴³⁶
*D Strohecker, 1993*⁸

Level 3

Presence of a specialized ICU is either strongly encouraged or mandatory.

*C Mathijssen, 2007*²⁴
*C Parameters ACPA, 2007*⁹
*D Capone, 2007*⁴³²
*D Chen, 1988*⁴³³
*D Chin, 1990*⁴³⁴
*D Clifford, 1978*⁴⁴⁰

Level 3

Team members should possess the appropriate knowledge and skills and should come into action at the proper moments during the treatment path.

*C Parameters ACPA, 2007*⁹
*C Standards USA, 2008*⁴³⁷
*C Strauss, 1998*²³
*D Clifford, 1978*⁴⁴⁰
*D David, 1977*⁴³⁹

Level 3

Joint consultations must be provided and the team should meet regularly.

*C Parameters ACPA, 2007*⁹
*C Standards USA, 2008*⁴³⁷
*C Strauss, 1998*²³
*D Anderson, 1985*⁴³¹
*D Capone, 2007*⁴³²
*D Chen, 1988*⁴³³
*D Chin, 1990*⁴³⁴
*D Holt, 1984*⁴³⁵

Level 4

Total 1 or 2 representatives of each specialty should be available—and preferably 2 especially for the core specialties—thereby benefiting flexibility, clinical support, collaboration, and quality.

*D Capone, 2007*⁴³²

Level 4

The noncore specialties do not have to be present at every consultation, but should be available for consultations.

*D Capone, 2007*⁴³²

Considerations

Pedagogical care is a valuable tool to prepare the child and his or her parents for the surgical procedures/treatments (see chapter 18).

Recommendations

Craniofacial care needs to be provided within a multidisciplinary setting, in which cleft lip/palate is not treated by the craniofacial team (“pure” craniofacial). A treatment path needs to be established and the team members’ roles should be defined clearly. Joint consultations are held with the core specialties present and the other team members available for consultation.

A craniofacial center offers the following health care providers and facilities:

Health care provider/facility	Nonsyndromic	Syndromic
Pediatrician	x	x
Clinical geneticist	x	x
Pediatric anesthesiologist	x	x
Pediatric intensivist	x	x
Neurosurgeon	x	x
Ophthalmologist	x	x
Pediatric radiologist	x	x
Plastic surgeon	x	x
Oral and maxillofacial surgeon	x	x
Orthodontist		x
Otolaryngologist		x
Psychologist		x
Social worker	x	x

Health care provider/facility	Nonsyndromic	Syndromic
Speech therapist		x
Pedagogical worker	x	x
Team leader (1 of the core specialists)	x	x
Care coordinator (nurse practitioner)	x	x
(three-dimensional-)imaging, x-ray, CT	x	x
MRI		x
Pediatric-IC	x	x
Polysomnography		x

A back up of the core specialties (thus at least 2 specialists for neurosurgery, plastic surgery, and oral and maxillofacial surgery) is advised to guarantee continuity of health care.

The health care provided by the team is based on the protocols, which are yearly reviewed. Adjustment of the multidisciplinary care for each individual patient is regularly discussed in team meetings. Outcomes will be communicated to the patient and parents and to any other health care provider not belonging to the team.

One team member will act as team leader and will as such ensure that the team meets all its requirements. Besides, there will be a care coordinator, usually a nurse practitioner/nursing specialist, who assures the coordination of the care and who is the contact person for the patient and for other health care providers not belonging to the team. The coordinator of the craniofacial team will ensure that the different examinations (inside or outside the center) are conducted on the recommended moments and that the results are provided to the primary responsible health care provider.

It is the team's task to provide and optimize high-standard protocol-based craniofacial care. Good coordination, lesser burden of patient/parents, high satisfaction of patient/parents, efficient utilization of resources, better information provision, organization of meetings for parents, patients, relatives, other health care professionals and the community in a broader sense, and organization or support of parent associations are core duties. National and international profiling and certifications are essential.

Question 2. How Is the Care for Patients With Craniosynostosis Coordinated in the Netherlands?

Summary of the Literature

The (minimal) team size is discussed in few publications; the central idea is that quality of care will improve by concentrating this specific care.

- One team per 10 to 20M inhabitants⁴³⁹
- One team per 30 to 40M inhabitants⁴³⁸
- Four teams per 56M inhabitants (current situation in Great Britain)²
- Compared with kidney transplantation: when teams perform 25 surgical procedures yearly, the mortality rate higher than when teams perform more than 100 surgical procedures yearly⁴³⁸
- Benchmarking 23 teams by the ISCFs resulted in the following division of the number of intracranial surgical procedures: 0 to 11 surgeries in 9% of the teams; 12 to 23 in 9%; 24 to 35 in 30%; 36 to 51 in 17%; 52 or more in 35%²⁴
- American Cleft Palate-Craniofacial Association concludes that a sufficient number of patients needs to be treated for a craniofacial team to obtain and maintain expertise, maar does not specify any numbers⁹
- Establishing formally recognized craniofacial centers (4 for 56 million people) will lead to a concentration of craniofacial care²

Centralization and Coordination of Care in the Netherlands

With an incidence of 1 in every 2100 to 2500 births, craniosynostosis is a rare disease. The syndromic variant of craniosynostosis is even rarer. Each year, an estimated 100 children with craniosynostosis are born in the Netherlands. Care for these patients requires the support of multiple medical, dental, and paramedical specialties, whereby the coordination of care is essential, as indicated in the discussion of basic question 1 of this chapter. This is achieved by treating patients in a multidisciplinary team meeting a number of requirements:

1. Composition of the team (see the above-mentioned recommendations under basic question 1)
2. Experience with treatment of craniosynostosis
3. Having the necessary facilities
4. Good accessibility
5. Guaranteed continuity of the team as a whole and of its individual members
6. Systematic evaluation of the results
7. Innovation and scientific research

These requirements can only be met when the care of patients with craniosynostosis is centralized. A few studies demonstrate the value of centralization of craniosynostosis care. In the study of Haas,⁸⁹ it is shown that treating a low number of patients annually is associated with perioperative blood loss. Nine nonsyndromic patients are presented, who underwent surgery within a period of 10 months. The average duration of surgery was 6.4 hours, which is unusually long. Blood loss was proportionally high with an average value of 846 mL. In a comparable study, Kang⁴⁴³ presents 43 patients during a period of 10 years, and also reports exceptionally long duration of surgery (4 hours for correcting scaphocephaly). In 23.3% of the patients, respiratory problems that were not anticipated occurred directly after recovery from anesthesia: of these 10 patients, 6 had cerebral edema, 3 were inadequately weaned off mechanical ventilation, and 1 bled persistently; 1 patient died. Hilling concluded that with increasing experience of the surgeon, the prevalence of temporal depressions after plagiocephaly or trigonocephaly decreases.¹⁰²⁻¹²³ Considering the many developments in the management of craniosynostosis, as, for example, in the surgical treatment of scaphocephaly, centralization is the only way to arrive at proper evaluation of new methods of treatment and comparative studies.

Furthermore, the criteria on experience in surgical treatments are important in the discussion about centralization. Based on learning curve and maintaining a level of competence, the Dutch Health Care Inspectorate (IGZ) and a number of scientific societies have set a minimum number of 20 operations each year per surgeon for low-frequent and highly complex care.⁴⁴⁴⁻⁴⁴⁶ A report of the Dutch Cancer Society in 2010 also recommends concentration of health care on the basis of criteria concerning the infrastructure, volume, and the degree of specialization of the hospital and verifiable good results of the health care provided. The Cochrane⁴⁴⁷ review of the National Pediatric Oncology Centre (NKOC) provides the scientific foundation for the proposition that the higher number of patients and/or further specialization leads to a lower mortality rate in pediatric oncology. It would seem self-evident that the minimum of 20 patients each year per surgeon should also apply to the surgical treatment of craniosynostosis (nonsyndromic and syndromic craniosynostosis surgeries together).

Centralization of health care for nonsyndromic craniosynostosis in the Netherlands requires at most 2 centers. Considering the fact that in the Netherlands facial surgeries for syndromic craniosynostosis, as in Le Fort III, monobloc, and facial bipartition, are rare (estimated 10 annually) and are associated with a higher surgical risk in the case of skull expansion, it is essential that these procedures are performed in only 1 center. It is an explicit wish of the patients and their parents and of the patient society LAPOSA that this highly complex care is provided in a center located in the Netherlands. Centralization on a European level is considered undesirable because of the language barriers and the less easy access. Considering the complexity of the pathology and treatment of syndromic craniosynostosis and the very low incidence, centralization of this treatment in the Netherlands in 1 center is desirable.

Considerations

The literature is not conclusive about the minimal mass for a team: 1 team per 15 to 20 M inhabitants is the median (range 10–40 M, with minimally 35 essential procedures performed each year (range from several to over 100)). In anypatient, a sufficient number of patients must be treated to obtain and maintain expertise.⁹ Based on the number of patients in the Netherlands, 1 center could theoretically be enough. Having (a maximum of) 2 centers has the advantage of creating demographic spread within the Netherlands, providing innovations in health care by allowing for comparative studies between the 2 centers, being less dependent on 1 center, and providing the possibility of asking for a second opinion within the Netherlands. It seems advisable, in thispatient, to treat syndromic craniosynostosis within 1 center, considering the highly complex pathology involved in this matter. The working group considers it essential to analyze the results of these specific facial surgeries on a European/international level.

Recommendations

There is room for 1 craniofacial team for the management of patients with nonsyndromic and syndromic craniosynostosis and 1 craniofacial team for nonsyndromic craniosynostosis in the Netherlands. Both centers work together in the areas of education, research, patient careand quality-improving activities (such as a national audit).

The minimum number of intracranial surgeries for craniosynostosis is 20 each year per surgeon.

Question 3: How to Manage Quality Control of the Craniofacial Center?

The literature provides little information, except Grol¹⁷ who mentions that the use of medical audits in the general practitioner practice for improvement of quality is hopeful. In the United Kingdom, experience has been gained during a few years now with an annual audit of the formally recognized craniofacial centers. The participants consider these meetings as valuable and these have been an incentive to set up multicenter studies.

Recommendations

Every team publishes an annual report and at least once yearly there will be a team meeting addressing:

Item	Nonsyndromic	Syndromic
Number of surgeries per diagnosis	x	x
Number of surgeries per type of surgery	x	x
Number of patients treated according to protocol	x	x
Perioperative dura and brain damage	x	x

Item	Nonsyndromic	Syndromic
Excessive loss of blood	x	x
Duration of surgery	x	x
Infections	x	x
Unplanned surgical readmission	x	x
Problems with equipment (springs, distractors, helmet)	x	x
Quality of life		x
Appearance	x	x
Behavior		x
Neurocognitive behavior		x
OSAS		x
ICP	x	x
Hydrocephalus		x
Hearing		x
Speech/language skills	x ¹	x
Visual acuity	x ²	x

1 = only for scaphocephaly.
2 = only for plagiocephaly.

New patients with craniosynostosis are registered with the Dutch Association for Cleft Palate and Craniofacial Anomalies (NVSCA).

Quality of care could be further evaluated by conducting b-annual audits of the treatment centers in the Netherlands and abroad.

20. SUMMARY

A schematic overview is given in appendix I.

Management in the Primary Care Sector

Application of the flow diagram (appendix II) is essential to optimize recognition of craniosynostosis in the primary and secondary care sectors.³

Upon recognition of an abnormal skull shape, the primary care health professional refers to the pediatrician, without additional diagnostics. On suspicion of craniosynostosis, this is done at the shortest possible term.

Management in the Secondary Care Sector

The pediatrician further evaluates the child with suspected craniosynostosis by performing a general and a specific physical examination. Imaging studies in the secondary care sector are advised against, unless proper arrangements have been made with the craniofacial center on performing and interpreting cranial images—and this does not lead to delay in further referral. On suspicion of craniosynostosis, the pediatrician refers to the tertiary craniofacial center at the shortest possible term.

Management in the Craniofacial Center

After referral to a craniofacial center, the craniofacial team distinguishes between nonsyndromic and syndromic craniosynostosis on the basis of a comprehensive physical examination and the family history on the occurrence of abnormal skull shape and other congenital anomalies.

The craniofacial center is expected to

- provide good information, both oral and via website and brochures.
- appoint a care coordinator within the team who is qualified to screen for both medical and psychosocial problems and can refer to specialized health care if necessary.
- facilitate parents/patients to have easy access to the care coordinator, who has an overview of the treatment path.
- offer regular and low-threshold psychosocial care.

- standardly involve educational care when children undergo surgery or visit the outpatient clinic visits, so as to help children and their parents prepare for procedures.
- facilitate contacts with peers and patient associations.
- provide for good knowledge transfer to health professionals in peripheral institutions.

Nonsyndromic Craniosynostosis

In principle, mild presentations of craniosynostosis, such as a metopic ridge and partial synostosis of the sagittal suture with few morphologic abnormalities, are not indications for surgical correction. In all other types, operative correction of the deformity is indicated on both functional and cosmetic grounds.

Nonsyndromic Craniosynostosis

In principle, mild presentations of craniosynostosis, such as a metopic ridge and partial synostosis of the sagittal suture with few morphologic abnormalities, are not indications for surgical correction. In all other types, operative correction of the deformity is indicated on both functional and cosmetic grounds.

Intake

A skull x-ray or ultrasonogram and a three-dimensional skull CT are performed to confirm the diagnosis. Genetic diagnostics are offered whether one or both coronal sutures are involved or when there is a family history of craniosynostosis.

Screening for increased ICP using fundoscopy is indicated before the initial cranial remodeling is performed. Its need has not been demonstrated in the case of early surgery (before the age of 6 months), but fundoscopy is recommended then.

Orthoptic and ophthalmologic evaluations are required at the first referral for unilateral coronal suture synostosis. These can be performed by any ophthalmologist in collaboration with an orthoptist. Ophthalmologically complex cases (such as absence of ocular muscles or keratitis) should be referred to a specialized center.

Cranial Vault Expansion

Operative correction of nonsyndromic craniosynostosis is preferably performed within the first year of life. In case of orbital involvement, the orbit is also corrected in the same operation.

Performing strip craniectomy for nonsyndromic craniosynostosis without additional measures is advised against. The choice of other techniques for correction of scaphocephaly (ie, extended strip craniectomy, complete cranial remodeling, and strip craniectomy in combination with molding helmet or springs) is based on age at presentation and severity of the deformity.

The anesthesiologic goals in craniofacial surgery can only be achieved in specialized pediatric centers, as laid down in the guideline "Surgery in children" issued by the Netherlands Association of Anesthesiologists. Invasive monitoring is recommended in open procedures with expected massive blood loss.

Availability of a bed in a PICU postoperatively must be ensured. In less extensive interventions, medium care may suffice, although it should be realized that these patients mostly are very young children with a smaller circulating blood volume in whom even little postoperative blood loss must be well monitored.

Administration of paracetamol will be adequate to relieve postoperative pain (guideline on postoperative pain management).

Follow-Up

Screening for increased ICP using fundoscopy is performed at least at the ages of 2 and 4 years. This ophthalmologic evaluation can be performed by any ophthalmologist.

The care coordinator in the craniofacial team is responsible for having the fundoscopies performed at the recommended moments and for communicating the results to the most responsible physician.

If papilledema has been confirmed, a CT or MRI scan is made to assess changes in ventricle size (hydrocephalus). Other pathology that could contribute to increased ICP, such as OSAS, is excluded. Revision of the diagnosis of nonsyndromic craniosynostosis is reconsidered. An invasive ICP measurement is to be considered in case of unexplained worsening of vision, progressive vertex bulge without papilledema, or when decision-making on reoperation is complicated by doubt about the extent of ICP increase. The choice of treatment for increased ICP is dependent on the causal factors; a cranial vault expansion is preferred.

Children diagnosed with a scaphocephaly should be evaluated for speech- and language problems from the age of +2 years. Psychologic assessment of children with craniosynostosis can either be performed in the hospital where the child is being treated for the craniosynostosis, or regionally. If the assessment takes place elsewhere, it is important that the results are communicated to the psychologist in the craniofacial team. The psychologist in the team provides support in cases of nonsyndromic craniosynostosis when a child's behavioral problems are suspected to be related to the craniosynostosis.

Follow-up of patients with a nonsyndromic craniosynostosis is recommended up to the age of 18 years, at which age skull growth has been completed.

SYNDROMIC CRANIOSYNOSTOSIS

Intake

If multiple dysmorphias/visible congenital abnormalities are seen, additional diagnostic procedures are indicated as early as in the first weeks of life. Targeted DNA diagnostics can be requested if a clinical syndrome diagnosis has been made. More extensive evaluation is indicated in cases of syndromic craniosynostosis without clinical diagnosis (= a nonclassifiable, complex craniosynostosis) or a clinical diagnosis, which was genetically not confirmed.

Screening for increased ICP using fundoscopy is indicated in syndromic craniosynostosis preceding the initial cranial remodeling.

A skull x-ray or ultrasonogram and a three-dimensional skull CT (including sections of the petrous parts of the temporal bones) are made preoperatively as well as brain MRI to screen for Chiari malformation and to serve as baseline image of ventricle width. Patients with ventriculomegaly should be followed by means of MRI scanning and 6 monthly fundoscopy. A multidisciplinary treatment plan is drawn up if a patient shows progressively increasing ventricle width or papilledema.

Orthoptic and ophthalmologic evaluations are required in all syndromic types of craniosynostosis at the first referral. These can be performed by any ophthalmologist in collaboration with an orthoptist. Depending on the results, follow-up examination and treatment is arranged. Ophthalmologically, complex cases (such as absence of ocular muscles or keratitis) should be referred to a specialized center.

For all syndromic types of craniosynostosis, a hearing test is indicated in the first year of life with tympanometry and otoacoustic emissions. In case of an ambiguous result, brainstem evoked response audiometry and/or free-field audiometry is performed in the local audiology center. If the CT scan shows structural abnormalities of the outer-, middle- and/or inner ear, adequate therapy is chosen at an early stage. Standard

speech/language testing is initiated at age 2 years. The team coordinator is expected to see to it that hearing tests are performed (and that action is undertaken if necessary). The treating otorhinolaryngologist is expected to undertake the necessary action after an abnormal result of a hearing test.

Screening for OSAS is essential in view of the high prevalence of OSAS in children with a syndromic craniosynostosis. Furthermore, evaluation of OSAS is indicated only if the medical history points at nocturnal breathing problems. Parents should be instructed to recognize symptoms indicative of OSAS and to contact the team coordinator if symptoms occur. Clinical symptoms of OSAS in combination with an abnormal saturation profile are strongly suggestive of OSAS, in which patient (additional) polysomnography is performed to determine severity of the OSAS (in conformity with the guideline on pediatric OSAS).

As OSAS in children with a syndromic craniosynostosis is a multifactorial condition, endoscopy of the upper airways is indicated to determine the level of obstruction. Treatment for OSAS is selected based on the severity of OSAS, the patient's age, causal factors, and any other functional problems (such as increased ICP or exorbitism).

Treatment of the hand deformities in Apert patients is started as early as possible and is performed by a (pediatric) hand surgeon. In view of the complexity of the hand deformities in the Apert syndrome, it is strongly recommended to concentrate care in a specialized center for congenital hand deformities. The treatment and follow-up of any elbow-, shoulder-, foot- and hip problems is performed by a pediatric orthopedist, rehabilitation expert or plastic surgeon. The care coordinator maintains contacts with the health professionals outside the center that is responsible for the Apert patient's care.

Abnormalities of the lower extremities in the Crouzon/Pfeiffer, Saethre-Chotzen, and Muenke syndromes are usually so mild that surgical treatment is not needed. If functional problems are seen, the patient should be referred to a specialized team for congenital hand deformities.

Initial Cranial Vault Expansion

The initial cranial vault expansion in Apert or Crouzon/Pfeiffer syndrome is an occipital expansion; in Saethre-Chotzen of Muenke syndrome a fronto-orbital advancement. Monobloc advancement with distraction, however, should be considered as initial intervention if the patient shows vision-threatening exorbitism and/or severe OSAS. The initial cranial vault expansion in syndromic craniosynostosis is performed within the first year of life. In view of the great risk of increased ICP in the Apert and Crouzon/Pfeiffer syndromes and the somewhat limited risk in Saethre-Chotzen syndrome, we recommend performing it approximately the age of 6 to 9 months, or earlier in case of proven increased ICP. For patients with the Muenke syndrome, it may be advisable to perform the operation between 9 and 12 months, as they apparently have a lower risk of increased ICP and the esthetic results of surgery may fall short of expectations.

The anesthesiologic goals in craniofacial surgery can only be achieved in specialized pediatric centers, as laid down in the guideline "Surgery in children" issued by the Netherlands Association of Anesthesiologists. Availability of a bed in a PICU postoperatively must be ensured. Administration of paracetamol will be adequate to relieve postoperative pain after cranial remodeling (guideline on postoperative pain management).

Follow-Up After Initial Cranial Vault Expansion

In syndromic craniosynostosis, screening for increased ICP using fundoscopy should take place at least annually until the age of 6 years. Muenke syndrome seems to be an exception to this rule, but considering the limited scientific underpinning, the same recommendation applies. If papilledema is confirmed during the follow-up period, a CT or MRI scan is made to evaluate changes in ventricle width (hydrocephalus). Other pathology that could contribute to increased ICP, such as OSAS, is excluded. An invasive ICP measurement is to be considered in case of unexplained worsening of vision, progressive vertex bulge without papilledema, or when decision-making on reoperation is complicated by doubt about the extent of ICP increase. Treatment of increased ICP is determined by causal factors in the individual patient.

The care coordinator in the craniofacial team is expected to see to it that the fundoscopies are performed at the recommended moments and that the results are communicated to the most responsible physician.

Hydrocephalus should be distinguished from ventriculomegaly by means of serial imaging with repetition of MRI in any case at 4 years of age, and earlier if clinical symptoms occur. Patients diagnosed with ventriculomegaly should be followed using MRI and 6 monthly fundoscopy. A multidisciplinary treatment plan is drawn up if progressively increasing ventricle width or papilledema is seen.

Shunting is contraproductive to cranial vault expansion. Therefore, efforts should be directed at treating the increased ICP in hydrocephalus by means of cranial vault expansion whenever possible. Shunt placement is to be considered if increased ICP is sustained on the long term (2 months) after adequate cranial vault expansion.

Follow-up screening for the presence of Chiari malformations in patients with Crouzon/Pfeiffer syndrome by means of MRI scanning is strongly recommended at the age of 4 years and as well on clinical suspicion of Chiari I malformation. Surgical treatment of Chiari malformations is recommended only if the patient is symptomatic. Otherwise, the pediatric neurosurgeon initiates active follow-up with sixth monthly assessment of neurologic symptoms and the presence of papilledema, as well as an annual MRI of MRV. If occipital decompression (for Chiari) is indicated, abnormal occipital venous drainage must be excluded preoperatively.

Children diagnosed with the syndrome van Apert should be evaluated for speech- and language problems from the age of ± 2 years. Children with a syndromic craniosynostosis should undergo cognitive and behavioral testing at a young age and again around the age when type of (elementary) school is chosen. Repeat testing is recommended at age 8 or 9 to identify any learning disorders. Psychologic testing of children with a syndromic craniosynostosis is preferably done by the psychologist of the treating craniofacial team.

Psychosocial care for the family should be easily accessible during the entire treatment path, and counseling should be based on a system perspective.

Adolescents who wish surgical treatment need to be offered at least 1 contact with a specialized social worker to check whether their expectations are realistic. The craniofacial center should have an Early Intervention Program/peer supervision group in place to increase resilience. During long sustained treatments that require a lot of motivation from the patient psychosocial screening and, if necessary, support, is desirable.

For all syndromic types of craniosynostosis, a hearing test is indicated annually in the first 4 years of life, with tympanometry and otoacoustic emissions, and if possible with a pure tone audiogram from age 4 years. Therapy is selected based on the type of hearing loss (in conformity with guideline KNO) and may consist of tympanostomy tubes, conventional hearing aids or BAHA, cochlear implant, and reconstructive surgery for congenital middle ear abnormalities possibly at later age.

Oral hygiene must be monitored more intensively than in the general population. Regular orthodontic checkups are necessary on account of delayed dentition and abnormal eruption patterns (1 to 4 times yearly).

The Le Fort III distraction procedure for the correction of the maxillary hypoplasia (including exorbitism) in Apert and Crouzon/Pfeiffer patients is usually performed between ages 8 and 12 years, or from 18 years onwards. Vision-threatening severe OSAS and/or severe exorbitism may be reason to perform this intervention at a younger age (see chapter on OSAS). A monobloc distraction is preferred for young children (<6 years), depending on earlier interventions. As 12 to 18 year olds have a higher risk of psychosocial problem or may have unrealistic expectations, the Le Fort III procedure is preferably not performed at these ages (see chapters 17 and 18). The Le Fort III distraction with external frame is the method of choice in view of ease of placement and removal of the frame and the optimal vector control.

Monobloc distraction in syndromic craniosynostosis patients is indicated in case of severe exorbitism (globe luxation and/or corneal injury) with

1. severe OSAS at the time of the protocol-dictated initial cranial vault expansion
2. severe OSAS in combination with increased ICP

Monitoring of occlusion is indicated after the Le Fort III or monobloc procedure. Orthognathic surgery is recommended if malocclusion is found (eg, Le Fort I, bilateral sagittal split osteotomy). The operation is planned after age 18 years.

Hypertelorism is preferably corrected from the age of 4 or 5 years on using the facial bipartition technique (with or without midface advancement by means of distraction). The orbital box osteotomy technique can be applied after sufficient eruption of the maxillary dentition (from approximately the age of 14 years) and can be well combined with additional orthognathic surgery.

Immediately after surgery/distraction osteogenesis, orthodontic retention is indicated to stabilize the result and prevent relapse. Provided the oral hygiene allows for this, permanent retention is achieved by means of retention wires and in addition, a retention device that stabilizes the dental arches in relation to each other. To ensure stability of the combined orthodontic-surgical interventions, orthodontic and facial orthopedic monitoring of the development into adulthood is indicated by means of standard protocol. Evaluation at least 2 years after treatment is required.

If a SARME procedure is performed in syndromic craniosynostosis patients, a tooth-borne distractor is preferred during a bone-borne distractor. A bone-borne distractor, however, is indicated when the maxilla is extremely narrow and there is not enough space for a tooth-borne distractor (Hyrax). The thick palatal mucosa impedes the placement of a bone-borne distractor. A SARME procedure is performed from the age of 14 to 15 years.

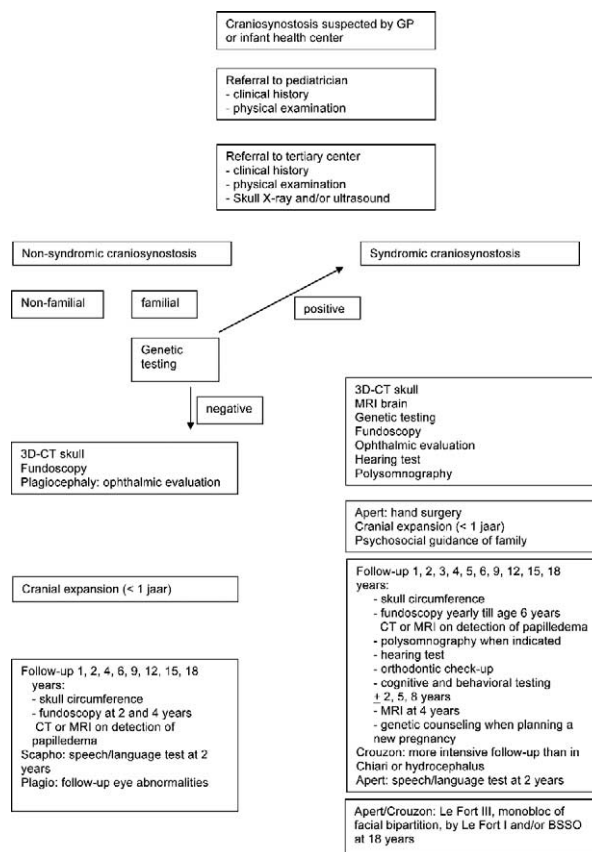
Follow-up of patients with a syndromic craniosynostosis is recommended until the age of 18 years, at completion of cranial and facial growth.

ACKNOWLEDGMENT

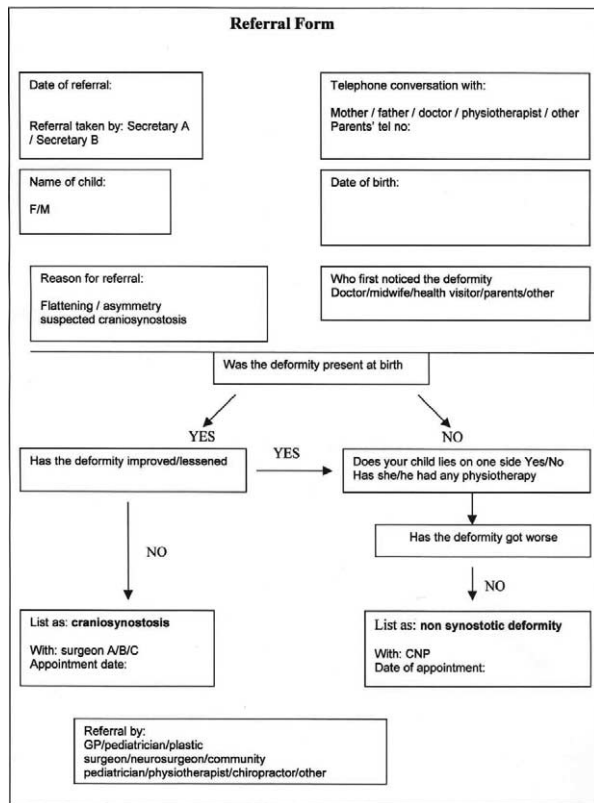
Participants of the working group: J. Beijer¹; A. Mus¹; N. Naus², MD, PhD; A. Gonzalez Candel³, MD; H. de Gier⁴, MD; L.J. Hoeve, MD, PhD⁴; G.C.B de Heus⁵, MD; K. Joosten, MD, PhD⁵; E.B. Wolvius, MD, DDS., PhD⁶; T.H.R. de Jong, MD⁷; E. ter Linde, MD PhD⁷; M.L.C. van Veelen, MD⁷; I.M.J. Mathijssen, MD, PhD⁸; L.N.A. van Adrichem, MD, PhD⁸; C.M. van der Horst, MD, PhD⁸; R. van der Hulst, MD, PhD⁸; J.J.N.M. van der Meulen, MD, PhD⁸; Kuijpers-Jagtman A., DDS, PhD⁹; E. Ongkosuwito, DDS, PhD⁹; A.J.M. Hoogeboom, MD¹⁰; J. Okkerse, PhD¹¹; F. Meertens¹².

- ¹ The Dutch National Cranial and Facial Deformities Patients and Parents Association (LAPOSA)
- ² The Netherlands Society for Ophthalmology
- ³ The Netherlands Society for Anesthesiology
- ⁴ The Netherlands Society for Otorhinolaryngology
- ⁵ The Dutch Association for Pediatrics
- ⁶ The Netherlands Society for Oral Medicine and Oral and Maxillofacial Surgery
- ⁷ The Netherlands Society for Neurosurgery
- ⁸ The Netherlands Society for Plastic Surgery
- ⁹ The Society for Orthodontists
- ¹⁰ The Netherlands Society for Clinical Genetics
- ¹¹ The Dutch Association of Psychologists
- ¹² The Netherlands Society for Relationship Counseling and Family Therapy

APPENDIX I.



APPENDIX II. FLOWDIAGRAM BREDERO-BOELHOUWER



REFERENCES

- Chatterjee JS, Mahmoud M, Karthikeyan S, et al. Referral pattern and surgical outcome of sagittal synostosis. *J Plast Reconstr Aesthet Surg* 2009;62:211–215
- White N, Warner RM, Noons P, et al. Changing referral patterns to a designated craniofacial centre over a four-year period. *J Plast Reconstr Aesthet Surg* 2010;63:921–925
- Bredero-Boelhouwer H, Treharne LJ, Mathijssen IMJ. A triage system for referrals of pediatric skull deformities. *J Craniofac Surg* 2009;20:242–245
- Feijen MMW, Habets Claessens EAWM, Leenders Dovens AJ, et al. Zuigelingen met een scheef hoofd [newborns with a moulded head]. *Ned Tijdschr Geneesk* 2009;153:A368
- Ridgeway EB, Weiner HL. Skull deformities. *Pediatr Clin North Am* 2004;51:359–387
- Komotar RJ, Zacharia BE, Ellis JA, et al. Pitfalls for the pediatrician: positional molding or craniosynostosis. *Pediatr Ann* 2006;35:365–375
- Rasmussen SA, Yazdy MM, Frias JL, et al. Conference report: priorities for public health research on craniosynostosis: summary and recommendations from a Centers for Disease Control and Prevention-sponsored meeting. *Am J Med Genet* 2008;146A:149–158
- Strohecker B. A team approach in the treatment of craniofacial deformities. *Plast Surg Nurs* 1993;13:9–16
- Parameters for Evaluation and Treatment of Patients With Cleft Lip/Palate or Other Craniofacial Anomalies. American Cleft Palate-Craniofacial Association. *Cleft Palate Craniofac J* 1993;30(Suppl 1):S1–S16.
- Lajeunie E, Barcik U, Thorne JA, et al. Craniosynostosis and fetal exposure to sodium valproate. *J Neurosurg* 2001;95:778–782
- Selber J, Reid RR, Chike-Obi CJ, et al. The changing epidemiologic spectrum of single-suture synostosis. *Plast Reconstr Surg* 2008;122:527–533
- Van der Meulen J, van der Hulst R, van Adrichem L, et al. The increase of metopic synostosis: a pan-European observation. *J Craniofac Surg* 2009;20:283–286
- Cohen MM, Kreiborg S, Odont D. An updated pediatric perspective on the Apert syndrome. *Am J Dis Child* 1993;147:989–993
- Grol R. Between evidence-based practice and total quality management: the implementation of cost-effective care. *Int J Qual Health Care* 2000;12:297–304
- Van der Weijden T, Dansen A, Schouten BJ, et al. Comparison of appropriateness of cholesterol testing in general practice with the recommendations of national guidelines: an audit of patient records in 20 general practices. *Qual Health Care* 1996;5:218–222
- Smeele IJM, Grol RPTM, van Schayck CP, et al. Can small group education and peer review improve care for patients with asthma/chronic obstructive pulmonary disease? *Qual Health Care* 1999;8:92–98
- Grol R, Wensing M. Implementation of quality assurance and medical audit: general practitioners' perceived obstacles and requirements. *Br J Gen Pract* 1995;45:548–552
- Grol R, van Eijk J, Mesker P, et al. Audit: a project on peer review in general practice. *Fam Pract* 1985;4:219–224
- Gellad FE, Haney PJ, Sun JCC, et al. Imaging modalities of craniosynostosis with surgical and pathological correlation. *Pediatr Radiol* 1985;15:285–290
- Cerovac S, Neil-Dwyer JG, Jones BM, et al. Are routine preoperative CT scans necessary in the management of single suture craniosynostosis? *Br J Neurosurg* 2002;16:348–354
- Medina LS, Richardson RR, Crone K. Children with suspected craniosynostosis: a cost-effectiveness analysis of diagnostic strategies. *AJR Am J Roentgenol* 2002;179:215–221
- Bruce DA. Consensus: craniofacial synostosis. Apert and Crouzon syndromes. *Childs Nerv Syst* 1996;12:734–736
- Strauss RP. Cleft palate and craniofacial teams in the United States and Canada: a national survey of team organization and standards of care. The American Cleft Palate-Craniofacial Association (ACPA) Team Standards Committee. *Cleft Palate Craniofac J* 1998;35:473–480
- Mathijssen IMJ, Arnaud E. Benchmarking for craniosynostosis. *J Craniofac Surg* 2007;18:436–442
- Parisi M, Mehsdizadeh HM, Hunter JC, et al. Evaluation of craniosynostosis with three-dimensional CT imaging. *J Comput Assist Tomogr* 1989;13:1006–1012
- Regelsberger J, Delling G, Helmke K, et al. Ultrasound in the diagnosis of craniosynostosis. *J Craniofac Surg* 2006;17:623–625; discussion 626–628
- Simanovsky N, Hiller N, Koplewitz B, et al. Effectiveness of ultrasonographic evaluation of the cranial sutures in children with suspected craniosynostosis. *Eur Radiol* 2009;19:687–692
- Di Rocco F, Arnaud E, Meyer P, et al. Focus session on the changing "epidemiology" of craniosynostosis (comparing two quinquennia: 1985–1989 and 2003–2007) and its impact on the daily clinical practice: a review from Necker Enfants Malades. *Childs Nerv Syst* 2009;25:807–811
- Boyardjiev SA. Genetic analysis of non-syndromic craniosynostosis. *Orthod Craniofac Res* 2007;10:129–137
- Chumas PD, Drake JM, Del Bigio MR. Death from chronic tonsillar herniation in a patient with lumboperitoneal shunt and Crouzon's disease. *Br J Neurosurg* 1992;6:595–599
- Frias JL, Carey JC. Mild errors of morphogenesis. *Adv Pediatr* 1996;43:27–75
- Lajeunie E, Le Merrer M, Bonaiti-Pellie C, et al. Genetic study of scaphocephaly. *Am J Med Genet* 1996;62:282–285
- Lajeunie E, Crimmins DW, Arnaud E, et al. Genetic considerations in nonsyndromic midline craniosynostoses: a study of twins and their families. *J Neurosurg* 2005;103:353–356
- Kan S, Elanko N, Johnson D, et al. Genomic screening of fibroblast growth-factor receptor 2 reveals a wide spectrum of mutations in patients with syndromic craniosynostosis. *Am J Hum Genet* 2002;70:472–486
- Butzelaar L, Breugem CC, Hanlo P, et al. Is isolated sagittal synostosis an isolated condition? *J Craniofac Surg* 2009;20:399–401

36. Zeiger JS, Beaty TH, Hetmanski JB, et al. Genetic and environmental risk factors for sagittal craniosynostosis. *J Craniofac Surg* 2002;13:602–606
37. McGillivray G, Savarirayan R, Cox TC, et al. Familial scaphocephaly syndrome caused by a novel mutation in the *FGFR2* tyrosine kinase domain. *J Med Genet* 2005;42:656–662
38. Seto ML, Hing AV, Chang J, et al. Isolated sagittal and coronal craniosynostosis associated with *TWIST* box mutations. *Am J Med Genet A* 2007;143:678–686
39. Lajeunie E, Le Merrer M, Marchac D, et al. Syndromic and nonsyndromic primary trigonocephaly: analysis of a series of 237 patients. *Am J Med Genet* 1998;75:211–215
40. Azimi C, Kennedy SJ, Chitayat D, et al. Clinical and genetic aspects of trigonocephaly: a study of 25 cases. *Am J Med Genet* 2003;117A:127–135
41. Tartaglia M, Bordoni V, Velardi F, et al. Fibroblast growth factor receptor mutational screening in newborns affected by metopic synostosis. *Childs Nerv Syst* 1999;15:389–393
42. Kress W, Petersen B, Collmann H, et al. An unusual *FGFR1* mutation (fibroblast growth factor receptor 1 mutation) in a girl with non-syndromic trigonocephaly. *Cytogenet Cell Genet* 2000;91:138–140
43. Jehee FS, Johnson D, Alonso LG, et al. Molecular screening for microdeletions at 9p22-p24 and 11q23-q24 in a large cohort of patients with trigonocephaly. *Clin Genet* 2005;67:503–510
44. Van der Meulen J, van den Ouweland A, Hoogeboom J. Trigonocephaly in Muenke syndrome. *Am J Med Genet A* 2006;140:2493–2494
45. Mulliken JB, Steinberger D, Kunze S, et al. Molecular diagnosis of bilateral coronal synostosis. *Plast Reconstr Surg* 1999;104:1603–1615
46. Mulliken JB, Gripp KW, Stolle CA, et al. Molecular analysis of patients with synostotic frontal plagiocephaly (unilateral coronal synostosis). *Plast Reconstr Surg* 2004;113:1899–1909
47. Wilkie AO. Abnormal spliceform expression associated with splice acceptor mutations in exon IIIc of *FGFR2*. *Am J Med Genet* 2002;111:105
48. El Ghouzzi V, Le Merrer M, Perrin-Schmitt F, et al. Mutations in the *TWIST* gene in Saethre-Chotzen syndrome. *NatGenet* 1997;15:42–46
49. Muenke M, Gripp KW, McDonald-McGinn DM, et al. A unique point mutation in the fibroblast growth factor receptor 3 gene (*FGFR3*) defines a new craniosynostosis syndrome. *Am J Hum Genet* 1997;60:555–564
50. Jenkins D, Seelow D, Jehee FS, et al. RAB23 mutations in Carpenter syndrome imply an unexpected role for hedgehog signaling in cranial-suture development and obesity. *Am J Hum Genet* 2007;80:1162–1170
51. Twigg SR, Kan R, Babbs C, et al. Mutations of ephrin-B1 (*EFNB1*), a marker of tissue boundary formation, cause craniofrontonasal syndrome. *Proc Natl Acad Sci U S A* 2004;101:8652–8657
52. Wilkie AO, Bochukova EG, Hansen RM, et al. Clinical dividends from the molecular genetic diagnosis of craniosynostosis. *Am J Med Genet A* 2007;143A:1941–1949
53. Morriss-Kay GM, Wilkie AO. Growth of the normal skull vault and its alteration in craniosynostosis: insights from human genetics and experimental studies. *J Anat* 2005;207:637–653
54. De Jong T, Bannink N, Bredero-Boelhouwer HH, et al. Long-term functional outcome in 167 patients with syndromic craniosynostosis: defining a syndrome-specific risk profile. *J Plast Reconstr Aesthet Surg* 2010;83:1635–1641
55. Chun K, Teebi AS, Jung JH, et al. Genetic analysis of patients with the Saethre-Chotzen phenotype. *Am J Med Genet* 2002;110:136–143
56. Jehee FS, Krepisch-Santos ACV, Rocha KM, et al. High frequency of submicroscopic chromosomal imbalances in patients with syndromic craniosynostosis detected by a combined approach of microsatellite segregation analysis, multiplex ligation-dependent probe amplification and arraybased comparative genome hybridization. *J Med Genet* 2008;45:447–450
57. Oldridge M, Lunt PW, Zackai EH, et al. Genotype-phenotype correlation for nucleotide substitutions in the IgII-IgIII linker of *FGFR2*. *Human Molec Genet* 1997;6:137–143
58. Meyers GA, Orlow SJ, Munro IR, et al. Fibroblast growth factor receptor 3 (*FGFR3*) transmembrane mutation in Crouzon syndrome with acanthosis nigricans. *NatGenet* 1995;11:462–464
59. Johnson D, Horsley SW, Moloney DM, et al. A comprehensive screen for *TWIST* mutations in patients with craniosynostosis identifies a new microdeletion syndrome of chromosome band 7p21.1. *Am J Hum Genet* 1998;63:1282–1293
60. Kress W, Schropp C, Lieb G, et al. Saethre-Chotzen syndrome caused by *TWIST1* gene mutations: functional differentiation from Muenke coronal synostosis syndrome. *Eur J Hum Genet* 2006;14:39–48
61. Wallis D, Lacbawan F, Jain M, et al. Additional *EFNB1* mutations in craniofrontonasal syndrome. *Am J Med Genet A* 2008;146A:2008–2012
62. Shimojima K, Yamamoto T. Investigation of the candidate region for trigonocephaly in a patient with monosomy 9p syndrome using array-CGH. *Am J Med Genet A* 2009;149A:1076–1080
63. Barbaro M, Balsamo A, Anderlid BM, et al. Characterization of deletions at 9p affecting the candidate regions for sex reversal and deletion 9p syndrome by MLPA. *Eur J Hum Genet* 2009;17:1439–1447
64. Netherlands Association of Anesthesiologists Dutch Guideline on Surgery in Children. Available at: <http://www.anesthesiologie.nl/>. Accessed July 13, 2015.
65. Elwood T, Sarathy PV, Geiduschek JM, et al. Respiratory complications during anaesthesia in Apert syndrome. *Paediatr Anaesth* 2001;11:701–703
66. Koh JL, Gries H. Perioperative management of pediatric patients with craniosynostosis. *Anesthesiol Clin* 2007;25:465–481
67. White N, Marcus R, Dover S, et al. Predictors of blood loss in fronto-orbital advancement and remodeling. *J Craniofac Surg* 2009;20:378–381
68. Di Rocco C, Tamburrini G, Pietrini D. Blood sparing in craniosynostosis surgery. *Semin Pediatr Neurol* 2004;11:278–287
69. Helfaer MA, Carson BS, James CS, et al. Increased hematocrit and decreased transfusion requirements in children given erythropoietin before undergoing craniofacial surgery. *J Neurosurg* 1998;88:704–708
70. Velardi F, Di Chirico A, Di Rocco C, et al. No allogenic blood transfusion protocol for the surgical correction of craniosynostoses I. Rationale. *Childs Nerv Syst* 1998;14:722–731
71. Velardi F, Di Chirico A, Di Rocco C, et al. No allogenic blood transfusion protocol for the surgical correction of craniosynostoses II. Clinical application. *Childs Nerv Syst* 1998;14:732–739
72. Fearon JA, Weinthal J. The use of recombinant erythropoietin in the reduction of blood transfusion rates in craniosynostosis repair in infants and children. *Plast Reconstr Surg* 2002;109:2190–2196
73. Meneghini L, Zadra N, Aneloni V, et al. Erythropoietin therapy and acute preoperative normovolaemic haemodilution in infants undergoing craniosynostosis surgery. *Paediatr Anaesth* 2003;13:392–396
74. Kearny RA, Rosales JK, Howes WJ. Craniosynostosis: an assessment of blood loss and transfusion practices. *Can J Anaesth* 1989;36:473–477
75. Teichgraber JF, Baumgartner JE, Waller AL, et al. Microscopic minimally invasive approach to nonsyndromic craniosynostosis. *J Craniofac Surg* 2009;20:1492–1500
76. Jimenez DF, Barone CM. Multiple-suture nonsyndromic craniosynostosis: early and effective management using endoscopic techniques. *J Neurosurg Pediatr* 2010;5:223–231
77. Chiaretti A, Pietrini D, Piastra M, et al. Safety and efficacy of remifentanyl in craniosynostosis repair in children less than 1 year old. *Pediatr Neurosurg* 2000;33:83–88
78. De Beer DAH, Mackersie A. Safety and efficacy of remifentanyl infusion in craniosynostosis repair in infants: letter to the editor. *Pediatr Neurosurg* 2001;34:327
79. Pietrini D, Ciano F, Forte E, et al. Sevoflurane-remifentanyl vs isoflurane-remifentanyl for the surgical correction of craniosynostosis in infants. *Pediatr Anesth* 2005;15:653–662
80. Hans P, Collins V, Bonhomme V, et al. Evaluation of acute normovolemic hemodilution for surgical repair of craniosynostosis. *J Neurosurg Anesthesiol* 2000;12:33–36
81. Fearon JA. Reducing allogenic blood transfusions during pediatric cranial vault surgical procedures: a prospective analysis of blood recycling. *Plast Reconstr Surg* 2004;113:1126–1130
82. Duncan C, Richardson D, Thiruchelvam J, et al. Reducing blood loss in synostosis surgery: the Liverpool experience. *J Craniofac Surg* 2008;19:1424–1430

83. Williams GD, Ellenbogen RG, Gruss JS. Abnormal coagulation during pediatric craniofacial surgery. *Pediatr Neurosurg* 2001;35:5–12
84. Cortellazzi P, Caldiroli D, Lamperti M, et al. Early transfusion and crystalloid infusion strategy in infants undergoing cranioplasty surgery. *Paediatr Anaesth* 2009;19:1251–1252
85. CBO Guideline Bloedtransfusie [Blood Transfusion]. ISBN: 90-8523-010-1 2004. Available at: <http://nvc.nl/sites/default/files/CBO%20Richtlijn%20Bloedtransfusie.pdf>. Accessed July 13, 2015.
86. Faberowski LW, Black S, Mickle JP. Incidence of venous air embolism during craniectomy for craniosynostosis repair. *Anesthesiology* 2000;92:20–23
87. Tobias JD, Johnson JO, Jimenez DF, et al. Venous air embolism during endoscopic strip craniectomy for repair of craniosynostosis in infants. *Anesthesiology* 2001;95:340–342
88. Meyer PG, Renier D, Orliaguet G, et al. Venous air embolism in craniosynostosis surgery: what do we want to detect? *Anesthesiology* 2000;93:1157–1158
89. Haas T, Fries D, Velik-Salchner C, et al. Fibrinogen in craniosynostosis surgery. *Anesth Analg* 2008;106:725–731
90. Ririe DG, Lantz PE, Glacier SS, et al. Transfusion-related acute lung injury in an infant during craniofacial surgery. *Anesth Analg* 2005;101:1003–1006
91. Wong GB, Nargozian C, Padwa BL. Anesthetic concern of external maxillary distraction osteogenesis. *J Craniofac Surg* 2004;15:78–81
92. Roche J, Frawley G, Heggie A. Difficult tracheal intubation by maxillary distraction devices in craniosynostosis syndromes. *Paediatr Anaesth* 2002;12:227–234
93. Byeon J-H, Yoo G. Cerebral salt wasting syndrome after calvarial remodeling in craniosynostosis. *J Korean Med Sci* 2005;20:866–869
94. Meyer P, Renier D, Arnaud E, et al. Blood loss during repair of craniosynostosis. *Br J Anaesth* 1993;71:854–857
95. Van der Marel CD, Van Lingen RA, Pluim MA, et al. Analgesic efficacy of rectal versus oral acetaminophen in children after major craniofacial surgery. *Clin Pharmacol Ther* 2001;70:82–90
96. Prins SA, Van Dijk M, Van Leeuwen P, et al. Pharmacokinetics and analgesic effects of intravenous propacetamol vs rectal paracetamol in children after major craniofacial surgery. *Paediatr Anaesth* 2008;18:582–592
97. Van Veelen-Vincent MLC, Mathijssen IMJ, Arnaud E. Non-syndromic craniosynostosis. In Lumenta CB, Di Rocco C, Haase J, Mooij B JJA, eds. Chapter 7.2.1 Neurosurgery. Berlin Heidelberg: Springer-Verlag; 2010:501–521. ISBN 978-3-540-79564-3.
98. Babler WJ. Role of cranial sutures in normal and abnormal skull development. *Neurosurg Clin North Am* 1991;2:539–549
99. Delashaw JB, Persing JA, Broaddus WC, et al. Cranial vault growth in craniosynostosis. *J Neurosurg* 1989;70:159–165
100. Barritt J, Brooksbank M, Simpson D. Scapocephaly: aesthetic and psychosocial considerations. *Dev Med Child Neurol* 1981;23:183–191
101. Van der Meulen JNNM, Nazir PRN, Mathijssen IMJ, et al. Bitemporal depressions after cranioplasty for trigonocephaly: a long-term evaluation of (supra) orbital growth in 92 patients. *J Craniofac Surg* 2008;19:72–79
102. Hilling DE, Mathijssen IMJ, Mulder PGH. Long-term aesthetic results of frontoorbital correction for frontal plagiocephaly. *J Neurosurg* 2006;105:21–25
103. Mathijssen I, Arnaud E, Lajeunie E, et al. Postoperative cognitive outcome for synostotic frontal plagiocephaly. *J Neurosurg* 2006;105:16–20
104. Ingraham FD, Alexandere E Jr, Matson DD. Clinical studies in craniosynostosis analysis of 50 cases and description of a method of surgical treatment. *Surgery* 1948;24:518–541
105. Anderson FM, Geiger L. Craniosynostosis: a survey of 204 cases. *J Neurosurg* 1965;22:229–240
106. Shilito J Jr, Matson DD. Craniosynostosis: a review of 519 surgical patients. *Pediatrics* 1968;41:829–853
107. Foltz EL, Loeser JD. Craniosynostosis. *J Neurosurg* 1975;43:48–57
108. Albright AL, Pollack IF, Adelson PD, et al. Outcome data and analysis in pediatric neurosurgery. *Neurosurgery* 1999;45:101–106
109. Marucci DD, Johnston CP, Anslow P, et al. Implications of a vertex bulge following modified strip craniectomy for sagittal synostosis. *Plast Reconstr Surg* 2008;122:217–224
110. Florisson JMG, Van Veelen MLC, Bannink N, et al. Papilledema in isolated single-suture craniosynostosis: prevalence and predictive factors. *J Craniofac Surg* 2010;21:20–24
111. Christophis P, Jünger TH, Howaldt HP. Surgical correction of scaphocephaly: experiences with a new procedure and follow-up investigations. *J Craniomaxillofac Surg* 2001;29:33–38
112. Amm CA, Denny AD. Correction of sagittal synostosis using foreshortening and lateral expansion of the cranium activated by gravity: surgical technique and postoperative evolution. *Plast Reconstr Surg* 2005;116:723–735
113. Gewalli F, Paulo da Silva Guimarães-Ferreira J, Sahlin P, et al. Mental development after modified pi procedure: dynamic cranioplasty for sagittal synostosis. *Ann Plast Surg* 2001;46:415–420
114. Heller JB, Heller MM, Knoll B, et al. Intracranial volume and cephalic index outcomes for total calvarial reconstruction among nonsyndromic sagittal synostosis patients. *Plast Reconstr Surg* 2008;121:187–195
115. Lauritzen CG, Davis C, Ivarsson A, et al. The evolving role of springs in craniofacial surgery: the first 100 clinical cases. *Plast Reconstr Surg* 2008;121:545–554
116. Anderson FM. Treatment of coronal and metopic synostosis. *Neurosurgery* 1981;8:143–149
117. Delashaw JB, Persing JA, Park TS, et al. Surgical approaches for the correction of metopic synostosis. *Neurosurgery* 1986;19:228–234
118. Friede H, Alberius P, Lilja L, et al. Trigocephaly: clinical and cephalometric assessment of craniofacial morphology in operated and nontreated patients. *Cleft Palate J* 1990;27:362–367
119. Aryan HE, Jandial R, Ozgur BM, et al. Surgical correction of metopic synostosis. *Childs Nerv Syst* 2005;21:392–398
120. Selber J, Reid RR, Gershman B, et al. Evolution of operative techniques for the treatment of single-suture metopic synostosis. *Ann Plast Surg* 2007;59:6–13
121. Renier D, Lajeunie E, Arnaud E, et al. Management of craniosynostoses. *Childs Nerv Syst* 2000;16:645–658
122. Posnick JC, Lin KY, Chen P, et al. Metopic synostosis: quantitative assessment of presenting deformity and surgical results based on CT scans. *Plast Reconstr Surg* 1994;93:16–24
123. Hilling DE, Mathijssen IMJ, Vaandrager JM. Aesthetic results of fronto-orbital correction in trigonocephaly. *J Craniofac Surg* 2006;17:1167–1174
124. Anderson PJ, David JD. Late Results after unicoronal craniosynostosis correction. *J Craniofac Surg* 2005;16:37–44
125. Barone CM, Jimenez DF. Endoscopic craniectomy for early correction of craniosynostosis. *Plast Reconstr Surg* 1999;104:1965–1973
126. Stelnicki E, Heger I, Brooks CJ, et al. Endoscopic release of unicoronal craniosynostosis. *J Craniofac Surg* 2009;20:93–97
127. Kim SW, Shim KW, Plesnila N, et al. Distraction vs remodeling surgery for craniosynostosis. *Childs Nerv Syst* 2007;23:201–206
128. Nonaka Y, Oi S, Miyawaki T, et al. Indication for and surgical outcomes of the distraction method in various types of craniosynostosis. Advantages, disadvantages, and current concepts for surgical strategy in the treatment of craniosynostosis. *Childs Nerv Syst* 2004;20:702–709
129. Fearon JA, Ruotolo RA, Kolar JC. Single sutural craniosynostoses: surgical outcomes and long-term growth. *Plast Reconstr Surg* 2009;123:635–642
130. Whitaker LA, Bartlett SP, Schut L, et al. Craniosynostosis: an analysis of the timing, treatment and complications in 164 consecutive patients. *Plast Reconstr Surg* 1987;80:195–212
131. Sloan GM, Wells KC, Raffel C, et al. Surgical treatment of craniosynostosis: outcome analysis of 250 consecutive patients. *Pediatrics* 1997;100:E2
132. Fearon JA, Munro IR, Bruce DA. Observation on the use of rigid fixation for craniofacial deformities in infants and young children. *Plast Reconstr Surg* 1995;95:634–637
133. Goldberg DS, Bartlett SP, Yu JC, et al. Critical review of microfixation in pediatric craniofacial surgery. *J Craniofac Surg* 1995;6:301–307
134. Persing JA, Posnick J, Magge S, et al. Cranial plate and screw fixation in infancy: an assessment of risk. *J Craniofacial Surg* 1996;4:267–270
135. Eppley BL, Morales L, Wood R, et al. Resorbable PLLA-PGA plate and screw fixation in pediatric craniofacial surgery: clinical experience in 1883 patients. *Plast Reconstr Surg* 2004;114:850–856

136. Ahmad N, Lyles J, Panchal J. Outcomes and complications based on experience with resorbable plates in pediatric craniosynostosis patients. *J Craniofacial Surg* 2008;19:855–869
137. Lo LJ, Marsh JL, Kane AA, et al. Orbital dysmorphology in unilateral coronal synostosis. *Cleft-Palate Craniofac J* 1996;33:190–197
138. Thompson D, Jones B, Hayward R, et al. Assessment and treatment of craniosynostosis. *Br J Hosp Med* 1994;52:17–24
139. Marchac D, Renier D, Broumand S. Timing of treatment for craniosynostosis and faciocraniosynostosis: a 20-year experience. *Br J Plast Surg* 1994;47:211–222
140. Fearon JA, Kolar JC, Munro IR. Trigonocephaly-associated hypotelorism: is treatment necessary? *Plast Reconstr Surg* 1996;97:503–509
141. Arnaud E, Renier D, Marchac D. Prognosis for mental function in scaphocephaly. *J Neurosurg* 1995;83:476–479
142. Renier D, Sainte-Rose C, Marchac D, et al. Intracranial pressure in craniosynostosis. *J Neurosurg* 1982;57:370–377
143. McCarthy JG, Glasberg SB, Cutting CB, et al. Twenty-year experience with early surgery for craniosynostosis: II. The craniofacial synostosis syndromes and pansynostosis—results and unsolved problems. *Plast Reconstr Surg* 1995;96:284–295
144. Arnaud E, Marchac D, Renier D. Reduction of morbidity of the frontofacial monobloc advancement in children by the use of internal distraction. *Plast Reconstr Surg* 2007;120:1009–1026
145. Sgouros S, Goldin JH, Hockley AD, et al. Posterior skull surgery in craniosynostosis. *Childs Nerv Syst* 1996;12:727–733
146. Honnebler MB, Cabiling DS, Hetlinger M, et al. The natural history of patients treated for *FGFR3*-associated (Muenke-type) craniosynostosis. *Plast Reconstr Surg* 2008;121:919–931
147. Fearon JA, Rhodes J. Pfeiffer syndrome: a treatment evaluation. *Plast Reconstr Surg* 2009;123:1560–1569
148. Jeevan DS, Anisow P, Jayamohan J. Abnormal venous drainage in syndromic craniosynostosis and the role of CT venography. *Childs Nerv Syst* 2008;24:1413–1420
149. Kamoshima Y, Sawamura Y, Yoshino M, et al. Frontofacial monobloc advancement using gradual bone distraction method. *J Pediatr Surg* 2008;43:1944–1948
150. Fitzgerald O'Connor EJ, Marucci DD, Jeelani NO, et al. Ocular advancement in monobloc distraction. *Plast Reconstr Surg* 2009;123:1570–1577
151. Arnaud E, Meneses P, Lajeunie E, et al. Postoperative mental and morphological outcome for nonsyndromic brachycephaly. *Plast Reconstr Surg* 2002;110:6–12
152. Marucci DD, Dunaway DJ, Jones BM, et al. Raised intracranial pressure in Apert syndrome. *Plast Reconstr Surg* 2008;122:1162–1168
153. Posnick JC. The craniofacial dysostosis syndromes. Staging of reconstruction and management of secondary deformities. *Clin Plast Surg* 1997;24:429–446
154. Bachmayer DI, Ross RB, Munro IR. Maxillary growth following Le Fort III advancement surgery in Crouzon, Apert, and Pfeiffer syndromes. *Am J Orthod Dentofacial Orthop* 1986;90:420–430
155. Meazzini MC, Mazzoleni F, Caronni E, et al. Le Fort III advancement osteotomy in the growing child affected by Crouzon's and Apert's syndromes: presurgical and postsurgical growth. *J Craniofacial Surg* 2005;16:369–377
156. Kreiborg S, Aduss H. Pre- and postsurgical facial growth in patients with Crouzon's and Apert's syndromes. *Cleft Palate J* 1986;23:78–90
157. Fearon JA. The Le Fort III osteotomy: to distract or not to distract? *Plast Reconstr Surg* 2001;107:1091–1103
158. Gillies H, Harrison SH. Operative correction by osteotomy of recessed malar maxillary compound in a case of oxycephaly. *Br J Plast Surg* 1950;3:123–127
159. Tessier P. Total facial osteotomy. Crouzon's syndrome, Apert's syndrome: oxycephaly, scaphocephaly, turriccephaly. *Ann Chir Plast* 1967;12:273–286
160. Hollier L, Kelly P, Babigumira E, et al. Minimally invasive Le Fort III distraction. *J Craniofac Surg* 2002;13:44–48
161. Pellerin P, Capon-Desgardin N, Martinot-Duquennoy V, et al. Midfacial distraction without osteotomy with a trans-facial pin. Report of 4 clinical cases. *Ann Chir Plast Esthet* 2001;46:277–284
162. Graewe FR, Morkel JA, Hartzenberg HB, et al. Midface distraction without osteotomies in an infant with upper respiratory obstruction. *J Craniofacial Surg* 2008;19:1603–1607
163. Liu C, Hou M, Liang L, et al. Sutural distraction osteogenesis (SDO) versus osteotomy distraction osteogenesis (ODO) for midfacial advancement: a new technique and primary clinical report. *J Craniofac Surg* 2005;16:537–548
164. Obwegeser HL. Surgical correction of small or retrodisplaced maxillae. The "dish-face" deformity. *Plast Reconstr Surg* 1969;43:351–365
165. Kobus KF. New osteotomies for midface advancement in patients with Crouzon syndrome. *J Craniofac Surg* 2006;17:957–961
166. Ueki K, Marukawa K, Nakagawa K, et al. Multidirectional distraction osteogenesis for Crouzon syndrome: technical note. *Int J Oral Maxillofac Surg* 2005;34:82–84
167. Rizvi M, Lypka M, Gaon M, et al. A simplified lateral canthopexy technique. *Plast Reconstr Surg* 2010;125:248e–249e
168. Coleman SR. Structural fat grafting: more than a permanent filler. *Plast Reconstr Surg* 2006;118:108S–120S
169. Barret JP, Sarobe N, Grande N, et al. Maximizing results for lipofilling in facial reconstruction. *Clin Plast Surg* 2009;36:487–492
170. Iannetti G, Fadda T, Agrillo A, et al. LeFort III advancement with and without osteogenesis distraction. *J Craniofac Surg* 2006;17:536–543
171. Phillips JH, George AK, Tompson B. Le Fort III osteotomy or distraction osteogenesis imperfecta: your choice. *Plast Reconstr Surg* 2006;117:1255–1260
172. Polley JW, Figueroa AA. Management of severe maxillary deficiency in childhood and adolescence through distraction osteogenesis with an external, adjustable, rigid distraction device. *J Craniofac Surg* 1997;8:181–185
173. Chin M, Toth BA. Le Fort III advancement with gradual distraction using internal devices. *Plast Reconstr Surg* 1997;100:819–830
174. Satoh K, Mitsukawa N, Tosa Y, et al. Le Fort III midfacial distraction using an internal distraction device for syndromic craniosynostosis: device selection, problems, indications, and a proposal for use of a parallel bar for device-setting. *J Craniofac Surg* 2006;17:1050–1058
175. Meling TR, Hans-Erik H, Per S, et al. Le Fort III distraction osteogenesis in syndromic craniosynostosis. *J Craniofac Surg* 2006;17:28–39
176. Holmes AD, Wright G, Meara JG, et al. Le Fort III internal distraction in syndromic craniosynostosis. *J Craniofac Surg* 2002;13:262–272
177. Gosain AK, Santoro TD, Havlik RJ, et al. Midface distraction following Le Fort III and monobloc osteotomies: problems and solutions. *Plast Reconstr Surg* 2002;109:1797–1808
178. Cedars MG, Linck DL, Chin M, et al. Advancement of the midface using distraction techniques. *Plast Reconstr Surg* 1999;103:429–441
179. Kubler AC, Speder B, Zoller JE. Fronto-orbital advancement with simultaneous LeFort III-distraction. *J Craniomaxillofac Surg* 2004;32:291–295
180. Mavili ME, Tuncbilek G, Vargel I. Rigid external distraction of the midface with direct wiring of the distraction unit in patients with craniofacial dysplasia. *J Craniofac Surg* 2003;14:783–785
181. Fearon JA. Halo distraction of the Le Fort III in syndromic craniosynostosis: a long-term assessment. *Plast Reconstr Surg* 2005;115:1524–1536
182. Shetye PR, Boutros S, Grayson BH, et al. Midterm follow-up of midface distraction for syndromic craniosynostosis: a clinical and cephalometric study. *Plast Reconstr Surg* 2007;120:1621–1632
183. Nout E, Wolvius EB, van Adrichem LN, et al. Complications in maxillary distraction using the RED II device: a retrospective analysis of 21 patients. *Int J Oral Maxillofac Surg* 2006;35:897–902
184. Mu XZ, Yu ZY, Wei M, et al. Surgical correction of craniofacial dysostosis with midface distraction osteogenesis. *Zhonghua Wai Ke Zhi* 2007;45:1055–1057
185. Malagon HH, Romo GW, Quintero Mosqueda FR, et al. Multivectorial, external halo-assisted midface distraction in patients with severe hypoplasia. *J Craniofac Surg* 2008;19:1663–1669
186. Lima DS, Alonso N, Câmara PR, et al. Evaluation of cephalometric points in midface bone lengthening with the use of a rigid external device in syndromic craniosynostosis patients. *Braz J Otorhinolaryngol* 2009;75:395–406

187. Schulten A, Lim AA, Bruun AA, et al. Combined push-pull distraction for correction of syndromic midfacial hypoplasia. *J Oral Maxillofac Surg* 2006;64:23–30
188. David DJ, Sheen R. Surgical correction of Crouzon syndrome. *Plast Reconstr Surg* 1990;85:344–354
189. Matsumoto K, Nakanishi H, Seike T, et al. Intracranial hemorrhage resulting from skull base fracture as a complication of Le Fort III osteotomy. *J Craniofac Surg* 2003;14:545–548
190. Lanigan DT, Romanchuk K, Olson CK. Ophthalmic complications associated with orthognathic surgery. *J Oral Maxillofac Surg* 1993;51:480–494
191. Nout E, Mathijssen IM, van der Meulen JJ, et al. Internal carotid dissection after Le Fort III distraction in Apert syndrome: a case report. *J Craniomaxillofac Surg* 2010;38:529–533
192. Le BT, Eyre JM, Wehby MC, et al. Intracranial migration of halo fixation pins: a complication of using an extraoral distraction device. *Cleft Palate Craniofac J* 2001;38:401–404
193. Rieger J, Jackson IT, Topf JS, et al. Traumatic cranial injury sustained from a fall on the rigid external distraction device. *J Craniofac Surg* 2001;12:237–241
194. Van der Meulen J, Wolvius E, van der Wal K, et al. Prevention of halo pin complications in post-cranioplasty patients. *J Craniomaxillofac Surg* 2005;33:145–149
195. Breugem CC, Bush K, Fitzpatrick DF. Le Fort III rigid external distraction complicated by intracranial movement of halo fixation pins. *Cleft Palate Craniofac J* 2008;45:33233–33236
196. Bachmayer DI, Ross RB. Stability of Le Fort III advancement surgery in children with Crouzon's, Apert's, and Pfeiffer's syndromes. *Cleft Palate J* 1986;23:69–74
197. Kaban LB, Conover M, Mulliken JB. Midface position after Le Fort III advancement: a long-term follow-up study. *Cleft Palate J* 1986;23:75–77
198. McCarthy JG, La Trenta GX, Breitbart AS, et al. The Le Fort III advancement osteotomy in the child under 7 years of age. *Plast Reconstr Surg* 1990;86:633–646
199. Ousterhout DK, Vargervik K, Clark S. Stability of the maxilla after Le Fort III advancement in craniostenosis syndromes. *Cleft Palate J* 1986;23:91–101
200. Ortiz-Monasterio F, Fuente del Campo A, Carrillo A. Advancement of the orbits and the midface in one piece, combined with frontal repositioning, for the correction of Crouzon's deformities. *Plast Reconstr Surg* 1978;61:507–516
201. Van der Meulen JC. Medial faciotomy. *Br J Plast Surg* 1979;32:339–342
202. Tessier PL. Apert's syndrome: acrocephalosyndactyly Type I. In Caronni EP, ed. *Craniofacial Surgery* Boston, MA: Little Brown; 1985:280–303.
203. Kelly CP, Cohen AJ, Yavuzer R, et al. Medial canthopexy: a proven technique. *Ophthal Plast Reconstr Surg* 2004;20:337–341
204. Moreira Gonzalez A, Elahi M, Barakat K, et al. Hypertelorism: the importance of three-dimensional imaging and trends in the surgical correction by facial bipartition. *Plast Reconstr Surg* 2005;115:1537–1546
205. Urrego AF, Garri JI, O'Hara CM, et al. The K stitch for hypertelorbitism: improved soft tissue correction with glabellar width reduction. *J Craniofac Surg* 2005;16:855–859
206. Posnick JC, Waitzman A, Armstrong D, et al. Monobloc and facial bipartition osteotomies: quantitative assessment of presenting deformity and surgical results based on computed tomography scans. *J Oral Maxillofac Surg* 1995;53:358–367
207. Posnick JC, al-Qattan MM, Armstrong D. Monobloc and facial bipartition osteotomies for reconstruction of craniofacial malformations: a study of extradural dead space and morbidity. *Plast Reconstr Surg* 1996;97:1118–1128
208. Bentley RP, Sgouros S, Natarajan K, et al. Changes in orbital volume during childhood in cases of craniostenosis. *J Neurosurg* 2002;96:747–754
209. Witherow H, Dunaway D, Evans R, et al. Functional outcomes in monobloc advancement by distraction using the rigid external distractor device. *Plast Reconstr Surg* 2008;121:1311–1322
210. Witherow H, Thiessen F, Evans R, et al. Relapse following frontofacial advancement using the rigid external distractor. *J Craniofac Surg* 2008;19:113–120
211. Ponniah AJ, Witherow H, Richards R, et al. Three-dimensional image analysis of facial skeletal changes after monobloc and bipartition distraction. *Plast Reconstr Surg* 2008;122:225–231
212. Cohen SR, Boydston W, Hudgins R, et al. Monobloc and facial bipartition distraction with internal devices. *J Craniofac Surg* 1999;10:244–251
213. Arnaud E, Marchac D, Renier D. Quadruple internal distraction with early frontal-facial advancement for faciocraniodyostosis. *Rev Stomatol Chir Maxillofac* 2004;105:13–18
214. Bradley JP, Levitt A, Nguyen J, et al. Roman arch, keystone fixation for facial bipartition with monobloc distraction. *Plast Reconstr Surg* 2008;122:1514–1523
215. Vyas RM, Keagle JN, Wexler A, et al. Unilateral vision impairment from a carotid-cavernous fistula after a monobloc osteotomy in a patient with Apert syndrome. *J Craniofac Surg* 2007;18:960–965
216. Benhaim P, Longaker MT, Kawamoto HK. In: Whitaker LA, ed. *Proceedings of the 7th International Congress of the International Society of Craniofacial Surgery. Proceedings of the 7th International Congress of the International Society of Craniofacial Surgery* Bologna, Italy: Monduzzi Editore; 1997:119–120
217. Wolfe A Marchac D Proceedings of the 6th International Congress of the International Society of Craniofacial Surgery Monduzzi Editore Bologna, Italy 1995 211- 213
218. Marchac D. *Proceedings of the 6th International Congress of the International Society of Craniofacial Surgery.* Bologna, Italy: Monduzzi Editore; 1995:225–228
219. Koudstaal MJ, Poort LJ, van der Wal KG, et al. Surgically assisted rapid maxillary expansion (SARME): a review of the literature. *Int J Oral Maxillofac Surg* 2005;34:709–714
220. Latham RA, Burston WR. The postnatal pattern of growth at sutures of the human skull. *Dent Pract* 1966;17:61–67
221. Krogman WM. Studies in growth changes in the skull and face of anthropoids: ectocranial and endocranial suture closure in anthropoids and old world apes. *Am J Phys Anthropol* 1930;46:315–353
222. Sicher H. *Oral Anatomy.* 4th ed. St. Louis, IL: The C.V. Mosby Company; 1965:71–75
223. Persson M. Structure and growth of facial sutures. *Odontol Rev* 1973;24:6
224. Scott JH. *Dentofacial Development and Growth.* Oxford, UK: Pergamon Press; 1967:89
225. Melsen B. Palatal growth studied on human autopsy material. *Am J Orthod* 1975;68:42–54
226. Öztürk M, Doruk C, Özeç I, et al. A. Pulpal bloodflow: effects of corticotomy and midline osteotomy in surgically assisted rapid palatal expansion. *J CranioMaxillofac Surg* 2003;31:97–100
227. Proffit WR. *Contemporary Orthodontics.* 3rd ed. St. Louis, IL: Penny Rudolph, Mosby Inc; 2000
228. Koudstaal MJ, van der Wal KG, Wolvius EB, et al. The Rotterdam Palatal Distractor: introduction of the new bone-borne device and report of the pilot study. *Int J Oral Maxillofac Surg* 2006;35:31–35
229. Stavrou P, Sgouros S, Willshaw HE, et al. Visual failure caused by raised intracranial pressure in craniostenosis. *Childs Nerv Syst* 1997;13:64–67
230. Gault DT, Renier D, Marchac D, et al. Intracranial pressure and intracranial volume in children with craniostenosis. *Plast Reconstr Surg* 1992;90:377–381
231. Thompson DNP, Malcolm GP, Jones BM, et al. Intracranial pressure in single-suture craniostenosis. *Pediatr Neurosurg* 1995;22:235–240
232. Thompson DNP, Harkness W, Jones B, et al. Subdural intracranial pressure monitoring in craniostenosis: its role in surgical management. *Childs Nerv Syst* 1995;11:269–275
233. Shipster C, Hearst D, Somerville A, et al. Speech, language, and cognitive development in children with isolated sagittal synostosis. *Dev Med Child Neurol* 2003;45:34–43
234. Thompson DN, Hayward RD, Harkness WJ, et al. Lessons from a case of kleeblattschädel. Case report. *J Neurosurg* 1995;82:1071–1074
235. Whittle IR, Johnston IH, Besser M. Intracranial pressure changes in craniostenosis. *Surg Neurol* 1984;21:367–372

236. Tamburrini G, Di Rocco C, Velardi F, et al. Prolonged intracranial pressure (ICP) monitoring in non-traumatic pediatric neurosurgical diseases. *Med Sci Monit* 2004;10:MT53–MT63
237. Tamburrini G, Caldarelli M, Massimi L, et al. Intracranial pressure monitoring in children with single suture and complex craniosynostosis: a review. *Childs Nerv Syst* 2005;21:913–921
238. Foster KA, Frim DM, McKinnon M. Recurrence of synostosis following surgical repair of craniosynostosis. *Plast Reconstr Surg* 2008;121:70e–76e
239. Scott JR, Isom CN, Gruss JS, et al. Symptom outcomes following cranial vault expansion for craniosynostosis in children older than 2 years. *Plast Reconstr Surg* 2009;123:289–297
240. Bristol RE, Lekovic GP, ReKate HL. The effects of craniosynostosis on the brain with respect to intracranial pressure. *Semin Pediatr Neurol* 2004;11:262–267
241. Hayward R, Gonzalez S. How low can you go? Intracranial pressure, cerebral perfusion pressure, and respiratory obstruction in children with complex craniosynostosis. *J Neurosurg* 2005;102:16–22
242. Siddiqi SN, Posnick JC, Buncic R, et al. The detection and management of intracranial hypertension after initial suture release and decompression for craniofacial dysostosis syndromes. *Neurosurgery* 1995;36:703–708
243. Pollack IF, Losken HW, Biglan AW. Incidence of increased intracranial pressure after early surgical treatment of syndromic craniosynostosis. *Pediatr Neurosurg* 1996;24:202–209
244. Greene AK, Mulliken JB, Proctor MR, et al. Phenotypically unusual combined craniosynostosis: presentation and management. *Plast Reconstr Surg* 2008;122:853–862
245. Bannink N, Joosten KF, van Veelen ML, et al. Papilledema in patients with Apert, Crouzon, and Pfeiffer syndrome: prevalence, efficacy of treatment, and risk factors. *J Craniofac Surg* 2008;19:121–127
246. Woods RH, Ul-Haq E, Wilkie AOM, et al. Reoperation for intracranial hypertension in *TWIST1*-confirmed Saethre-Chotzen syndrome: a 15-year review. *Plast Reconstr Surg* 2009;123:1801–1810
247. Eide PK, Bernt EH, Due-Tønnessen B, et al. Assessment of continuous intracranial pressure recordings in childhood craniosynostosis. *Pediatr Neurosurg* 2002;37:310–320
248. Tuite GF, Evanson J, Chong WK, et al. The beaten copper cranium: a correlation between intracranial pressure, cranial radiographs, and computed tomographic scans in children with craniosynostosis. *Neurosurgery* 1996;39:691–699
249. Tuite GF, Chong WK, Evanson J, et al. The effectiveness of papilledema as an indicator of raised intracranial pressure in children with craniosynostosis. *Neurosurgery* 1996;38:272–278
250. Eide PK. The relationship between intracranial pressure and size of cerebral ventricles assessed by computed tomography. *Acta Neurochir* 2003;145:171–179
251. Hayreh MS, Hayreh SS. Optic disc edema in raised intracranial pressure. I. Evolution and resolution. *Arch Ophthalmol* 1977;95:1237–1244
252. Mursch K, Brockmann K, Lang JK, et al. Visually evoked potentials in 52 children requiring operative repair of craniosynostosis. *Pediatr Neurosurg* 1998;29:320–323
253. Fok H, Jones BM, Gault DG, et al. Relationship between intracranial pressure and intracranial volume in craniosynostosis. *Br J Plast Surg* 1992;45:394–397
254. Gault D, Jones BM. Indirect intracranial volume measurement using CT scan. *Plast Reconstr Surg* 1992;90:1126–1127
255. Gupta PC, Foster J, Crowe S, et al. Ophthalmologic findings in patients with nonsyndromic plagiocephaly. *J Craniofac Surg* 2003;14:529–532
256. Campbell JW, Albright AL, Losken HW, et al. Intracranial hypertension after cranial vault decompression for craniosynostosis. *Pediatr Neurosurg* 1995;22:270–273
257. Connolly JP, Gruss J, Seto ML, et al. Progressive postnatal craniosynostosis and increased intracranial pressure. *Plast Reconstr Surg* 2004;113:1313–1323
258. Hoefkens MF, Vermeij-Keers C, Vaandrager JM. Crouzon syndrome: phenotypic signs and symptoms of the postnatally expressed subtype. *J Craniofac Surg* 2004;15:233–240
259. Liasis A, Nischal KK, Walters B, et al. Monitoring visual function in children with syndromic craniosynostosis: a comparison of 3 methods. *Arch Ophthalmol* 2006;124:1119–1126
260. Gonzalez S, Hayward R, Jones B, et al. Upper airway obstruction and raised intracranial pressure in children with craniosynostosis. *Eur Respir J* 1997;10:367–375
261. Hayward R. Venous hypertension and craniosynostosis. *Childs Nerv Syst* 2005;21:880–888
262. Cinalli G, Sainte-Rose C, Kollar EM, et al. Hydrocephalus and craniosynostosis. *J Neurosurg* 1998;88:209–214
263. Collmann H, Sorensen N, Krauss J. Hydrocephalus in craniosynostosis: a review. *Childs Nerv Syst* 2005;21:902–912
264. Noetzel MJ, Marsh JL, Palkes H, et al. Hydrocephalus and mental retardation in craniosynostosis. *J Pediatr* 1985;107:885–892
265. Renier D, Arnaud E, Cinalli G, et al. Prognosis for mental function in Apert's syndrome. *J Neurosurg* 1996;85:66–72
266. Proudman TW, Clark BE, Moore MH, et al. Central Nervous imaging in Crouzon's syndrome. *J Craniofac Surg* 1995;6:401–405
267. Cohen MM Jr, Kreiborg S. The central nervous system in the Apert syndrome. *Am J Med Genet* 1990;35:36–45
268. Hanieh A, David DJ. Apert's syndrome. *Childs Nerv Syst* 1993;9:289–291
269. Greally MT, Carey JC, Milewicz DM, et al. Shprintzen-Goldberg syndrome: a clinical analysis. *Am J Med Genet* 1998;76:202–212
270. Collmann H, Sorensen N, Krauss JJ, et al. Hydrocephalus in craniosynostosis. *Childs Nerv Syst* 1988;4:279–285
271. Cinalli G, Renier D, Sebag G, et al. Chronic tonsillar herniation in Crouzon's and Apert's syndromes: the role of premature synostosis of the lambdoid suture. *J Neurosurg* 1995;83:575–582
272. Francis PM, Beals S, ReKate HL, et al. J. Chronic tonsillar herniation and Crouzon's syndrome. *Pediatr Neurosurg* 1992;18:202–206
273. Thompson DNP, Harkness W, Jones BM, et al. Aetiology of herniation of the hindbrain in craniosynostosis. *Pediatr Neurosurg* 1997;26:288–295
274. Cinalli G, Chumas P, Arnaud E, et al. Occipital remodeling and suboccipital decompression in severe craniosynostosis associated with tonsillar herniation. *Neurosurgery* 1998;42:66–73
275. Taylor WJ, Hayward RD, Lasjaunias P, et al. J Enigma of raised intracranial pressure in patients with complex craniosynostosis: the role of abnormal intracranial venous drainage. *Neurosurgery* 2001;94:377–385
276. Sainte-Rose C, LaCombe J, Pierre-Kahn A, et al. Intracranial venous sinus hypertension: cause or consequence of hydrocephalus in infants? *J Neurosurg* 1984;60:727–736
277. Renier D, Arnaud E, Marchac D. [Craniosynostosis: functional and morphologic postoperative results]. *Neurochirurgie* 2006;52:302–310
278. Gosain AK, McCarthy JG, Wisoff JH. Morbidity associated with increased intracranial pressure in Apert and Pfeiffer syndromes: the need for long-term evaluation. *Plast Reconstr Surg* 1996;97:292–301
279. Cinalli G, Spennato P, Sainte-Rose C, et al. Chiari malformation in craniosynostosis. *Childs Nerv Syst* 2005;21:889–901
280. Fearon JA, Swift DM, Bruce DA. New methods for the evaluation and treatment of craniofacial dysostosis-associated cerebellar tonsillar herniation. *Plast Reconstr Surg* 2001;108:1855–1861
281. Al-Otibi M, Jea A, Kulkarni AV. Detection of important venous collaterals by computed tomography venogram in multisutural synostosis. *J Neurosurg* 2007;107:508–510
282. Sandberg DI, Navarro R, Blanch J, et al. Anomalous venous drainage preventing safe posterior fossa decompression in patients with Chiari malformation Type I and multisutural craniosynostosis. *J Neurosurg* 2007;106:490–494
283. Martinez-Perez D, Vander Woude DL, Barnes PD, et al. Jugular foraminal stenosis in Crouzon syndrome. *Pediatr Neurosurg* 1996;25:252–255
284. Vasco G, Baranello G, Ricci D, et al. Longitudinal assessment of visual development in non-syndromic craniosynostosis: a 1-year pre- and post-surgical study. *Arch Dis Child* 2008;93:932–935
285. Tarczy-Hornoch K, Smith B, Urata M. Amblyogenic anisometropia in the contralateral eye in unicoronal craniosynostosis. *J AAPOS* 2008;12:471–476
286. MacKinnon S, Roger GF, Gregas M, et al. Treatment of unilateral coronal synostosis by endoscopic strip craniectomy or fronto-orbital advancement: ophthalmologic findings. *J AAPOS* 2009;13:155–160

287. Jadico SK, Young DA, Huebner A, et al. Ocular abnormalities in Apert syndrome: Genotype/phenotype correlations with fibroblast growth factor receptor type 2 mutations. *J AAPOS* 2006;10:521–527
288. Khong JJ, Anderson P, Hammerton M, et al. Differential effects of *FGFR2* mutation in ophthalmic findings in Apert syndrome. *J Craniofac Surg* 2007;18:39–42
289. Khong JJ, Anderson P, Gray TL, et al. Ophthalmic findings in Apert's syndrome after craniofacial surgery. *Ophthalmology* 2006;113:347–352
290. Khong JJ, Anderson P, Gray TL, et al. Ophthalmic findings in Apert syndrome prior to craniofacial surgery. *Am J Ophthalmol* 2006;142:328–330
291. Gray TL, Casey T, Selva D, et al. Ophthalmic sequelae of Crouzon syndrome. *Ophthalmology* 2005;112:1129–1134
292. Jadico SK, Huenber A, McDonald-McGinn DM, et al. Ocular phenotype correlations in patients with *TWIST* versus *FGFR3* genetic mutations. *J AAPOS* 2006;10:435–444
293. Khan SH, Nischal KK, Dean F, et al. Visual outcomes and amblyogenic risk factors in craniosynostotic syndromes: a review of 141 cases. *Br J Ophthalmol* 2003;87:999–1003
294. Lehman S. Strabismus in craniosynostosis. *Curr Opin Ophthalmol* 2006;17:432–434
295. Weinstock FJ, Hardesty HH. Absence of superior rectus in craniofacial dysostosis. *Arch Ophthalmol* 1965;74:152–153
296. Cuttone JM, Brazis PT, Miller MT, et al. Absence of the superior rectus muscle in Apert's syndrome. *J Pediatr Ophthalmol Strabismus* 1979;16:349–354
297. Greenberg ME, Pollard ZE. Absence of multiple extraocular muscles in craniosynostosis. *J AAPOS* 1998;2:307–309
298. Joosten KFM, van den Berg S. Het obstructief slaapapnoesyndroom bij kinderen. *Ned Tijdschr Geneesk* 1998;142:2665–2669
299. Guillemainault C, van den Hoed J, Mitler M. Clinical overview of the sleep apnea syndromes. In: Guillemainault C, Dement W, eds. *Sleep Apnea Syndromes*. New York, NY: Alan R. Liss; 1978:1–12
300. Marcus CL, Loughlin GM. Obstructive sleep apnea in children. *Semin Pediatr Neurol* 1996;3:23–28
301. Järund M, Lauritzen C. Craniofacial dysostosis: airway obstruction and craniofacial surgery. *Scand J Plast Reconstr Hand Surg* 1996;30:275–279
302. Kakitsuba N, Sadaoka T, Motoyama S, et al. Sleep apnea and sleep related breathing disorders in patients with craniofacial synostosis. *Acta Otolaryngol* 1994;517:6–10
303. Järund M, Dellborg C, Carlson J, et al. Treatment of sleep apnea with continuous positive airway pressure in children with craniofacial malformations. *Scand J Plast Reconstr Hand Surg* 1999;33:67–71
304. Pijpers M, Poels PJ, Vaandrager JM, et al. Undiagnosed obstructive sleep apnea syndrome in children with syndromic craniofacial synostosis. *J Craniofac Surg* 2004;15:670–674
305. Sirotnak J, Brodsky L, Pizzuto M. Airway obstruction in the Crouzon syndrome: case report and review of the literature. *Int J Paediatr Otorhinolaryngol* 1995;31:235–246
306. Brouillette RT, Morielli A, Leimanis A, et al. Nocturnal pulse oximetry as an abbreviated testing modality for pediatric obstructive sleep apnea. *Pediatrics* 2000;105:405–412
307. Bannink N, Mathijssen IM, Joosten KF. Can parents predict obstructive sleep apnea in children with syndromic or complex craniosynostosis? *Int J Oral Maxillofac Surg* 2010;39:421–423
308. Halbower AC, Ishman SL, McGinley BM. Childhood obstructive sleep-disordered breathing: a clinical update and discussion of technological innovations and challenges. *Chest* 2007;132:2030–2041
309. Guillemainault C, Pelayo R, Clerk A, et al. Home nasal continuous positive airway pressure in infants with sleep-disordered breathing. *J Pediatr* 1995;127:905–912
310. Brietzke SE, Katz ES, Roberson DW. Can history and physical examination reliably diagnose pediatric obstructive sleep apnea/hypopnea syndrome? A systematic review of the literature. *Otolaryngol Head Neck Surg* 2004;131:827–832
311. Nieminen P, Tolonen U, Lopponen H, et al. Snoring children: factors predicting sleep apnea. *Acta Otolaryngol* 1997;529:190–194
312. Nieminen P, Tolonen U, Lopponen H. Snoring and obstructive sleep apnea in children: a 6-months follow-up study. *Arch Otolaryngol Head Neck Surg* 2000;126:481–486
313. Rosen CL. Clinical features of obstructive sleep apnea hypoventilation syndrome in otherwise healthy children. *Pediatr Pulmonol* 1999;27:403–409
314. Carroll JL, McColley SA, Marcus CL, et al. Inability of clinical history to distinguish primary snoring from obstructive sleep apnea syndrome in children. *Chest* 1995;108:610–618
315. Jain A, Sahni JK. Polysomnographic studies in children undergoing adenoidectomy and/or tonsillectomy. *J Laryngol Otol* 2002;116:711–715
316. Suen JS, Arnold JE, Brooks LJ. Adenotonsillectomy for treatment of obstructive sleep apnea in children. *Arch Otolaryngol Head Neck Surg* 1995;121:525–530
317. Goldstein NA, Sculerati N, Walsleben JA, et al. Clinical diagnosis of pediatric obstructive sleep apnea validated by polysomnography. *Otolaryngol Head Neck Surg* 1994;111:611–617
318. Waters KA, Everett FM, Bmderer JW, et al. Obstructive sleep apnea: the use of nasal CPAP in 80 children. *Am J Respir Crit Care Med* 1995;152:780–785
319. Hoeve HL, Joosten KF, van den Berg S. Management of obstructive sleep apnea syndrome in children with craniofacial malformation. *Int J Pediatr Otorhinolaryngol* 1999;49:S59–61
320. Clinical practice guideline: diagnosis and management of childhood obstructive sleep apnea syndrome. *Pediatrics* 2002;109:704–712
321. Goldstein NA, Fatima M, Campbell TF, et al. Child behavior and quality of life before and after tonsillectomy and adenoidectomy. *Arch Otolaryngol Head Neck Surg* 2002;128:770–775
322. Amonoo-Kuofi K, Phillips SP, Randhawa PS, et al. Adenotonsillectomy for sleep-disordered breathing in children with syndromic craniosynostosis. *J Craniofac Surg* 1980;20:1978–1980
323. Ahmed J, Marucci D, Cochrane I, et al. The role of the nasopharyngeal airway for obstructive sleep apnea in syndromic craniosynostosis. *J Craniofac Surg* 2008;19:659–663
324. Nout E, Cesteleyn LL, van der Wal KG, et al. Advancement of the midface, from conventional Le Fort III osteotomy to Le Fort III distraction: review of the literature. *Int J Oral Maxillofac Surg* 2008;37:781–789
325. Nelson TE, Mulliken JB, Padwa BL. Effect of midfacial distraction on the obstructed airway in patients with syndromic bilateral coronal synostosis. *J Oral Maxillofac Surg* 2008;66:2318–2321
326. Mathijssen I, Arnaud E, Marchac D, et al. Respiratory outcome of mid-face advancement with distraction: a comparison between Le Fort III and frontofacial monobloc. *J Craniofac Surg* 2006;17:880–882
327. Flores RL, Shetye PR, Zeitler D, et al. Airway changes following Le Fort III distraction osteogenesis for syndromic craniosynostosis: a clinical and cephalometric study. *Plast Reconstr Surg* 2009;124:590–601
328. Bannink N, Nout E, Wolvius EB, et al. Obstructive sleep apnea in children with syndromic craniosynostosis: long-term respiratory outcome of midface advancement. *Int J Oral Maxillofac Surg* 2010;39:115–121
329. Gonzalez S, Thompson D, Hayward R, et al. Treatment of obstructive sleep apnoea using nasal CPAP in children with craniofacial dysostoses. *Childs Nerv Syst* 1996;12:713–719
330. Prager JD, Wang EW, Molter DW. Hearing loss in patients with isolated nonsyndromic sagittal synostosis. *Int J Pediatr Otorhinolaryngol* 2008;72:223–227
331. Gould HJ, Caldarelli DD. Hearing and otopathology in Apert syndrome. *Arch Otolaryngol* 1982;108:347–349
332. Vallino-Napoli LD. Audiologic and otologic characteristics of Pfeiffer syndrome. *Cleft Palate Craniofac J* 1996;33:524–529
333. Doherty ES, Lachawan F, Hadley DW, et al. Muenke syndrome (FGFR3-related craniosynostosis): expansion of the phenotype and review of literature. *Am J Med Genet* 2007;Part A143A:3204–3215
334. Zhou G, Thomas Schwartz L, et al. Inner ear anomalies and conductive hearing loss in children with Apert syndrome: an overlooked otologic aspect. *Otol Neurotol* 2009;30:184–189
335. Church MW, Parent-Jenkins L, Rozelle AA, et al. Auditory brainstem response abnormalities and hearing loss in children with craniosynostosis. *Pediatrics* 2007;119:1351–1360
336. Corey JP, Caldarelli DD, Gould HJ. Otopathology in cranial facial dysostosis. *Am J Otolaryngol* 1987;8:14–17

337. Hollway GE, Suthers GK, Battese KM, et al. Deafness due to Pro250Arg mutation of *FGFR3*. *Lancet* 1998;351:877–878
338. Balan P, Kusherenko E, Sahlin P, et al. Auditory ERP's reveal brain dysfunction in infants with plagiocephaly. *J Craniofac Surg* 2002;13:520–525
339. Kreiborg S, Pruzansky S. Craniofacial growth in premature craniofacial synostosis. *Scand J Plast Reconstr Surg* 1981;15:171–186
340. Kreiborg S. *Crouzon Syndrome: A Clinical and Roentgencephalometric Study*. Copenhagen: Royal Dental College Copenhagen; 1981
341. Carinci F, Avantaggiato A, Curioni C. Crouzon syndrome: cephalometric analysis and evaluation of pathogenesis. *Cleft Palate Craniofac J* 1994;31:201–209
342. Bjork A, Skieller V. Growth in width of the maxilla studied by the implant method. *Scand J Plast Reconstr Surg* 1974;8:26–33
343. Bjork A, Skieller V. Growth of the maxilla in three dimensions as revealed radiographically by the implant method. *Br J Orthod* 1977;4:53–64
344. American Academy of Pediatric Dentistry. Guideline on management of the developing dentition and occlusion in pediatric dentistry. *Pediatr Dent* 2008;30:184–195
345. Farkas LG. Asymmetry of the head and face. In: Farkas LG, ed. *Anthropometry of the Head and Face*. 2nd ed. New York, NY: Raven Press; 1994:92–98
346. Peterson-Falzone SJ, Pruzansky S, Parris PJ, et al. Nasopharyngeal dysmorphism in the syndromes of Apert and Crouzon. *Cleft Palate J* 1981;18:237–250
347. Kreiborg S, Cohen MM Jr. The oral manifestations of Apert syndrome. *J Craniofac Genet Dev Biol* 1992;12:41–48
348. Letra A, the Almeida AL, Kaizer R, et al. Intraoral features of Apert's syndrome. *Oral Surg Oral Med Oral Pathol Oral Radiol Endod* 2007;103:e38–e41
349. Dalben GS, Neves LT, Gomide MR. Oral findings in patients with Apert Syndrome. *J Appl Oral Sci* 2006;14:465–469
350. Kaloust S, Ishii K, Vargervik K. Dental development in Apert syndrome. *Cleft Palate Craniofac J* 1997;34:117–121
351. Peterson SJ, Pruzansky S. Palatal anomalies in the syndromes of Apert and Crouzon. *Cleft Palate J* 1974;11:394–403
352. Solomon LM, Medenica M, Pruzansky S, et al. Apert syndrome and palatal mucopolysaccharides. *Teratology* 1973;8:287–291
353. Cohen MM Jr, Kreiborg S. A clinical study of the craniofacial features in Apert syndrome. *Int J Oral Maxillofac Surg* 1996;25:45–53
354. Mustafa D, Lucas VS, Junod P, et al. The dental health and caries-related microflora in children with craniosynostosis. *Cleft Palate Craniofac J* 2001;38:629–635
355. Nurko C, Quinones R. Dental and orthodontic management of patients with Apert and Crouzon syndromes. *Oral Maxillofac Surg Clin North Am* 2004;16:541–553
356. Ashley FP, Usiskin LA, Wilson RF, et al. The relationship between irregularity of the incisor teeth, plaque, and gingivitis: a study in a group of school children aged 11-14 years. *Eur J Orthod* 1988;20:65–72
357. Wagaiyu EG, Ashley FP. Mouthbreathing, lip seal and upper lip coverage and their relationship with gingival inflammation in 11-14 year-old school children. *J Clin Periodontol* 1991;18:698–702
358. Costaras-Volarich M, Pruzansky S. Is the mandible intrinsically different in Apert and Crouzon syndromes? *Am J Orthod* 1984;85:475–487
359. Proffit WR, White RP, Sarver DM. *Contemporary treatment of dentofacial deformity*. St Louis, IL: Mosby Inc; 2003
360. Grubb J, Evans C. Orthodontic management of dentofacial skeletal deformities. *Clin Plast Surg* 2007;34:403–415
361. Renkema AM, Sips ET, Bronkhorst E, et al. A survey on orthodontic retention procedures in The Netherlands. *Eur J Orthod* 2009;31:432–437
362. Al-Qattan MM. The use of split thickness skin grafts in the correction of Apert's syndactyly. *J Hand Surg Br* 2001;26:8–10
363. Upton J. Early surgical intervention in Apert's syndactyly. *Plast Reconstr Surg* 1986;77:286–287
364. Upton J. Classification and pathologic anatomy of limb anomalies. *Clin Plast Surg* 1991;18:321–355
365. Cohen MM Jr, Kreiborg S. Hands and feet in the Apert syndrome. *Am J Med Genet* 1995;57:82–96
366. Dao KD, Shin AY, Kelley S, et al. Synostosis of the ring-small finger metacarpal in Apert acrosyndactyly hands: incidence and treatment. *J Pediatr Orthop* 2001;21:502–507
367. Kasser J, Upton J. The shoulder, elbow, and forearm in Apert syndrome. *Clin Plast Surg* 1991;18:381–389
368. Murnaghan LM, Thurgur CH, Forster BB, et al. A clinicoradiologic study of the shoulder in Apert syndrome. *Pediatr Orthop* 2007;27:838–843
369. Anderson PJ, Hall CM, Evans RD, et al. The feet in Apert's syndrome. *J Pediatr Orthop* 1999;19:504–507
370. Mah J, Kasser J, Upton J. The foot in Apert syndrome. *Clin Plast Surg* 1991;18:391–397
371. Fereshetian S, Upton J. The anatomy and management of the thumb in Apert syndrome. *Clin Plast Surg* 1991;18:365–380
372. Zucker RM, Cleland HJ, Haswell T. Syndactyly correction of the hand in Apert syndrome. *Clin Plast Surg* 1991;18:357–364
373. Fearon JA. Treatment of the hands and feet in Apert syndrome: an evolution in management. *Plast Reconstr Surg* 2003;112:1–12
374. Guero SJ. Algorithm for treatment of Apert hand. *Tech Hand Up Extrem Surg* 2005;9:126–133
375. Chang J, Danton TK, Ladd AL, et al. Reconstruction of the hand in Apert syndrome: a simplified approach. *Plast Reconstr Surg* 2002;109:465–470
376. Upton J. The hand and upper limb. Chapter VIII. In: Mathes SJ, Hentz VR, eds. *Plastic Surgery: Part 2. Vol 8*. Philadelphia, PA: Saunders; 2006:170–175
377. Anderson PJ, Hall C, Evans RD, et al. The hands in Saethre-Chotzen syndrome. *J Craniofac Genet Dev Biol* 1996;16:228–233
378. Panthaki ZJ, Armstrong MB. Hand abnormalities associated with craniofacial syndromes. *J Craniofac Surg* 2003;14:709–712
379. Trusen A, Beissert M, Collmann H, et al. The pattern of skeletal anomalies in the cervical spine, hands and feet in patients with Saethre–Chotzen syndrome and Muenke-type mutation. *Pediatr Radiol* 2003;33:168–172
380. Cohen MM Jr. Pfeiffer syndrome update, clinical subtypes, and guidelines for differential diagnosis. *Am J Med Genet* 1993;45:300–307
381. Anderson PJ, Hall C, Evans RD, et al. The feet in Crouzon syndrome. *J Craniofac Genet Dev Biol* 1997;17:43–47
382. Rossi M, Jones RL, Norbury G, et al. The appearance of the feet in Pfeiffer syndrome caused by *FGFR1* P252R mutation. *Clin Dysmorphol* 2003;12:269–274
383. Wilkie AO, Slaney SF, Oldridge M, et al. Apert syndrome results from localized mutations of *FGFR2* and is allelic with Crouzon syndrome. *Nat Genet* 1995;9:165–172
384. Bochukova EG, Rosciolo T, Hedges DJ, et al. Rare mutations of *FGFR2* causing Apert syndrome: identification of the first partial gene deletion, and an Alu element insertion from a new subfamily. *Hum Mutat* 2009;30:204–211
385. Speltz ML, Endriga MC, Mouradian WE. Presurgical and postsurgical mental and psychomotor development of infants with sagittal synostosis. *Cleft Palate Craniofac J* 1997;34:374–379
386. Boltshauser E, Ludwig S, Dietrich F, et al. Sagittal craniosynostosis: cognitive development, behaviour, and quality of life in unoperated children. *Neuropediatr* 2003;34:293–300
387. Van der Vlugt JJ, Van der Meulen JJ, Creemers HE, et al. The risk of psychopathology in children with craniosynostosis. *Plast Reconstr Surg* 2009;124:2054–2060
388. Kapp-Simon KA, Leroux B, Cunningham M, et al. Multisite study of infants with single-suture craniosynostosis: preliminary report of presurgery development. *Cleft Palate Craniofac J* 2005;42:377–384
389. Speltz ML, Kapp-Simon K, Collett B, et al. Neurodevelopment of infants with single-suture craniosynostosis: presurgery comparisons with case-matched controls. *Plast Reconstr Surg* 2007;119:1874–1881
390. Starr JR, Kapp-Simon KA, Cloonan YK, et al. Presurgical and postsurgical assessment of the neurodevelopment of infants with single-suture craniosynostosis: comparison with controls. *J Neurosurg* 2007;107:103–110

391. Crowe TK, Deitz JC, Bennett FC. The relationship between the Bayley scales of infant development and preschool gross motor and cognitive performance. *Am J Occup Ther* 1987;41:374–378
392. Kapp-Simon KA, Figueroa A, Jocher CA, et al. Longitudinal assessment of mental development in infants with nonsyndromic craniosynostosis with and without cranial release and reconstruction. *Plast Reconstr Surg* 1993;92:831–839
393. Kapp-Simon KA. Mental development and learning disorders in children with single suture craniosynostosis. *Cleft Palate Craniofac J* 1998;35:197–203
394. Toth K, Collett B, Kapp-Simon KA, et al. Memory and response inhibition in young children with single-suture craniosynostosis. *Child Neuropsychol* 2007;26:1–14
395. Dekker MC, Koot HM, Van der Ende J, et al. Emotional and behavioral problems in children and adolescents with and without intellectual disability. *J Child Psychol Psychiatry* 2002;43:1087–1098
396. Lefebvre A, Travis F, Arndt EM, et al. A psychiatric profile before and after reconstructive surgery in children with Apert's syndrome. *Br J Plast Surg* 1986;39:510–513
397. Patton MA, Goodship J, Hayward R, et al. Intellectual development in Apert's syndrome: a long term follow up of 29 patients. *J Med Genet* 1988;25:164–167
398. Shipster C, Hearst D, Dockrell JE, et al. Speech and language skills and cognitive functioning in children with Apert syndrome: a pilot study. *Int J Lang Commun Disord* 2002;37:325–343
399. Cai J, Goodman BK, et al. Increased risk for developmental delay in Saethre-Chotzen syndrome is associated with *TWIST* deletions: an improved strategy for *TWIST* mutation screening. *Hum Genet* 2003;114:68–76
400. De Heer IM, De Klein A, van den Ouweland AM, et al. Clinical and genetic analysis of patients with Saethre-Chotzen syndrome. *Plast Reconstr Surg* 2005;115:1894–1902
401. Flapper WJ, Anderson PJ, Roberts RM, et al. Intellectual outcomes following protocol management in Crouzon, Pfeiffer, and Muenke syndromes. *J Craniofac Surg* 2009;20:1252–1255
402. Kapp-Simon, Speltz ML, Cunningham ML, et al. Neurodevelopment of children with single suture craniosynostosis: a review. *Childs Nerv Syst* 2007;23:269–281
403. Kelleher Mo, Murray DJ, McGillivray A, et al. Behavioral, developmental, and educational problems in children with nonsyndromic trigonocephaly. *J Neurosurg* 2006;105:382–384
404. Magge SN, Westerveld M, Pruzinsky T, et al. Long-term neuropsychological effects of sagittal craniosynostosis on child development. *J Craniofac Surg* 2002;13:99–104
405. Mendonca DA, White N, West E, et al. Is there a relationship between the severity of metopic synostosis and speech and language impairments? *J Craniofac Surg* 2009;20:85–88
406. Bellew M, Chumas P, Mueller R, et al. Pre- and postoperative developmental attainment in sagittal synostosis. *Arch Dis Child* 2005;90:346–350
407. Cohen SR, Cho DC, Nichols SL, et al. American society of maxillofacial surgeons outcome study: preoperative and postoperative neurodevelopmental findings in single-suture craniosynostosis. *Plast Reconstr Surg* 2004;114:841–847
408. Ruiz-Correa S, Starr JR, Lin HJ, et al. Severity of skull malformation is unrelated to presurgery neurobehavioral status of infants with sagittal synostosis. *Cleft Palate Craniofac J* 2007;44:548–554
409. Warschausky S, Angobaldo J, Kewman D, et al. Early development of infants with untreated metopic craniosynostosis. *Plast Reconstr Surg* 2005;115:1518–1523
410. Straus MA, Kaufman Kanter G. Definition and measurement of neglectful behavior: some principles and guidelines. *Child Abuse Negl* 2005;29:19–29
411. De Sousa A. Psychological issues in oral and maxillofacial reconstructive surgery. *Br J Oral Maxillofac Surg* 2008;46:661–664
412. Coulter ML, Sheuerle L, Laude M, et al. Psychosocial aspects of parents of children with craniofacial anomalies. *J Craniofac Surg* 1991;2:9–17
413. Campis LB. Children with Apert syndrome: developmental and psychologic considerations. *Clin Plast Surg* 1991;18:409–416
414. Sarimski K. Children with Apert syndrome: behavioural problems and family stress. *Develop Med Child Neurol* 1998;40:44–49
415. Lefebvre A, Barclay S. Psychosocial impact of craniofacial deformities before and after reconstructive surgery. *Can J Psych* 1982;27:579–584
416. Chapados C. Cleft lip and palate: the adolescent and his family. *Can Nurse* 2000;96:34–38
417. Trulsson U, Klingberg G. Living with a child with a severe orofacial handicap: experiences from the perspectives of parents. *Eur J Sci* 2003;111:19–25
418. Brook JS, Brook DW, Whiteman M. Older sibling correlates of younger sibling drug use in the context of parent-child relations. *Genet Soc Gen Psychol Monogr* 1999;125:451–468
419. St. John D, Pai L, Belfer M, et al. Effects of a child with a craniofacial anomaly on stability of the parental relationship. *J Craniofac Surg* 2003;14:704–708
420. Robinson E, Rumsey N, Partridge J. An evaluation of the impact of social interaction skills training for facially disfigured people. *Br J Plast Surg* 1996;49:281–289
421. Ayoub A, Duncan C, Moos F. Response of patients and families to lengthening of the facial bones by extraoral distraction osteogenesis: a review of 14 patients. *Br J Oral Maxillofac Surg* 2002;40:397–405
422. Primrose AC, Broadfoot E, Diner PA, et al. Patients' responses to distraction osteogenesis: a multi-centre study. *Int J Oral Maxillofac Surg* 2005;34:238–242
423. Lefebvre A, Munroe I. The role of psychiatry in a craniofacial team. *Br J Plast Surg* 1978;53:593–600
424. Kapp-Simon K, McGuire D, Long B, et al. Addressing quality of life issues in adolescents: social skills interventions. *Cleft Palate Craniofac J* 2005;42:45–50
425. Strauss RP, Ramsey BL, Edwards TC, et al. Stigma experiences in youth with facial differences: a multi-site study of adolescents and their mothers. *Orthod Craniofac Res* 2007;10:96–103
426. Jedeloo F S, Janssen F I, van Staa F AL. Doorbraak in transitiezorg. Actieprogramma op eigen benen vooruit! [Break through in transitional care. Action program moving forward on their own feet]. *Kwaliteit in zorg* 2009:10–13
427. Bronner MB, Knoester H, Bos AP, et al. Posttraumatic stress disorder (PTSD) in children after paediatric intensive care treatment compared to children who survived a major fire disaster. *Child Adolesc Psychiatry Ment Health* 2008;2:9
428. Olf M, Vries d. Prevalence of trauma and PTSD in the Netherlands. *Proc. 20th Annual Meeting of the Int. Soc. Traumatic Stress Studies 14-18 November*. New Orleans, LA 2004
429. Winston FK, Kassam-Adams N, Garcia-Espana F, et al. Screening for risk of persistent posttraumatic stress in injured children and their parents. *J Am Med Assoc* 2003;290:643–649
430. Guzelcan Y, Scholte WF, Olf M, et al. Posttraumatic stress disorder following physical illnesses or their treatment. *Tijdschr Psychiatr* 2004;46:611–617
431. Anderson BE, Wicks K. A team approach to the child with a craniofacial defect. *Plast Surg Nurs* 1985;5:32–36
432. Capone RB, Sykes JM. The cleft and craniofacial team: the whole is greater than the sum of its parts. *Facial Plast Surg* 2007;23:83–86
433. Chen YR, Chen SH, Noordhoff MS. Combined cleft and craniofacial team-multidisciplinary approach to cleft management. *Ann Ac Med* 1988;17:339–342
434. Chin RW, Falk RE. The instrumental role of a genetic counselor in a multidisciplinary setting: the craniofacial team as a model. *Birth Defects Orig Art Ser* 1990;26:185–190
435. Holt GR, Watson MJ. The otolaryngologist's role in the craniofacial anomalies team. *Otolaryngol Head Neck Surg* 1984;92:406–409
436. Pruzansky S. The dentist on a craniofacial team. *Birth Defects Orig Art Ser* 1980;16:115–124
437. American Cleft Palate-Craniofacial Association & Cleft Palate Foundation. *Standards for approval of cleft palate and craniofacial teams June 2008*. USA: American Cleft Palate-Craniofacial Association & Cleft Palate Foundation; 2008
438. Munro IR. Orbito-cranio-facial surgery: the team approach. *Plast Reconstr Surg* 1975;55:170–176
439. David DJ. Craniofacial surgery: the team approach. *Aust N Z J Surg* 1977;47:193–198

440. Clifford E. Tigers and elephants: an appreciation of craniofacial team nursing. *Cleft Palate J* 1978;15:301–305
441. Schaefer L, Sullivan MD. The speech-language pathologist's role on the craniofacial team. *Ear Nose Throat J* 1986;65:346–352
442. Prah-Andersen B. Controversies in the management of craniofacial malformations. *Sem Orthodon* 2005;11:67–75
443. Kang JK, Lee SW, Baik MW, et al. Perioperative specific management of blood volume loss in craniosynostosis surgery. *Childs Nerv Syst* 1998;14:297–301
444. Dutch guideline on Diagnosis and treatment of germ cell cancer. *Neth Assoc Urol* 2002
445. Dutch Guideline on Diagnosis and Treatment of Esophageal Cancer. 2005. ISBN 90-8523-092-6. Available at: <http://www.oncoline.nl/oesofaguscarcinoom>. Accessed July 13, 2015.
446. Dutch Guideline on Diagnosis and Treatment of an Aneurysm of the Abdominal Aorta. 2009. ISBN 978-90-9023962-0.
447. NKOC. De relatie tussen volume en kwaliteit van zorg in de (kinder) oncologie [The relation between volume and quality of care in (pediatric) oncology]. Cochrane Collab. 2009.
448. Sheldon SH. Sleep disorders in children. *Pediatr Ann* 2013;42:407–408
449. Galland BC, Dawes PJ, Tripp EG, et al. Changes in behavior and attentional capacity after adenotonsillectomy. *Pediatr Res* 2006;59:711–716
450. Goroza E, Sagy M, Sagy N, et al. Severity assessment of obstructive sleep apnea syndrome (OSAS) in pediatric patients. *Clin Pediatr* 2009;48:528–533