

Good Functional Recovery of Complex Elbow Dislocations Treated With Hinged External Fixation: A Multicenter Prospective Study

Gijs I. T. Iordens MD, Dennis Den Hartog PhD, Esther M. M. Van Lieshout PhD, Wim E. Tuinebreijer PhD, Jeroen de Haan PhD, Peter Patka PhD, Michael H. J. Verhofstad PhD, Niels W. L. Schep PhD; Dutch Elbow Collaborative

G. I. T. Iordens, D. D. Hartog, E. M. M. Van Lieshout, W. E. Tuinebreijer, P. Patka, M. H. J. Verhofstad
Trauma Research Unit, Department of Surgery, Erasmus MC, University Medical Center Rotterdam, Rotterdam, The Netherlands

J. de Haan
Department of Surgery, Westfriesgasthuis, Hoorn, The Netherlands

N. W. L. Schep
Trauma Unit, Department of Surgery, Academic Medical Center, Amsterdam, The Netherlands

The institution of one or more of the authors (GITI, DDH, EMMVL, PP, MHJV) has received, during the study period, funding from the Osteosynthesis and Trauma Care (OTC) Foundation (No. 2009-NSPP) and from Orthofix SRL (Bussolengo, Italy).

All ICMJE Conflict of Interest Forms for authors and *Clinical Orthopaedics and Related Research*® editors and board members are on file with the publication and can be viewed on request.

Each author certifies that his or her institution approved the human protocol for this investigation, that all investigations were conducted in conformity with ethical principles of research, and that informed consent for participation in the study was obtained.

Clinical Orthopaedics and Related Research® neither advocates nor endorses the use of any treatment, drug, or device. Readers are encouraged to always seek additional information, including FDA-approval status, of any drug or device prior to clinical use.

Dutch Elbow Collaborative: M. W. G. A. Bronkhorst (Bronovo Hospital, Den Haag, The Netherlands), M. R. De Vries (Reinier de Graaf Groep, Delft, The Netherlands), J. C. Goslings (AMC, Amsterdam, The Netherlands), S. J. Rhemrev (MC Haaglanden, Den Haag, The Netherlands), G. R. Roukema (Maasstad Ziekenhuis, Rotterdam, The Netherlands), H. G. W. M. Van der Meulen Haga Ziekenhuis, Den Haag, The Netherlands), E. J. M. M. Verleisdonk (Diakonessenhuis, Utrecht, The Netherlands), J. P. A. M. Vroemen (Amphia Ziekenhuis, Breda, The Netherlands), Ph. Wittich (St. Antonius Ziekenhuis, Nieuwegein, The Netherlands). All of these authors participated in patient inclusion, critically revised the manuscript, and read and approved the final version.

D. Den Hartog ✉

Trauma Research Unit

Department of Surgery

Erasmus MC

University Medical Center Rotterdam

PO Box 2040, 3000 CA

Rotterdam, The Netherlands

email: d.denhartog@erasmusmc.nl

Abstract

Background After a complex dislocation, some elbows remain unstable after closed reduction or fracture treatment. Function after treatment with a hinged external fixator theoretically allows collateral ligaments to heal without surgical reconstruction. There is, however, a lack of prospective studies that assess functional outcome, pain, and range of motion.

Questions/purposes (1) In complex elbow fracture-dislocations, does treatment with a hinged external fixator result in reduction of disability and pain, and in improvement in range of motion, function, and quality of life? (2) What are the complications seen after external fixator treatment?

Methods Over a two-year period, 11 centers recruited 27 patients aged 18 years or older were included and evaluated at 2 and 6 weeks and at 3, 6, and 12 months after surgery as part of this prospective case series. During the period of study, the participating centers agreed upon general indications for use of the hinged external fixator, which included persistent instability after closed reduction alone or closed reduction combined with surgical treatment of associated fracture(s), when indicated. . Functional outcome was evaluated using the Quick-Disabilities of the Arm, Shoulder and Hand (Quick-DASH; primary outcome) score, the Mayo Elbow Performance Index (MEPI), the Oxford Elbow Score (OES), and the level of pain (visual analog scale [VAS]). Range of motion, adverse events, secondary interventions, and radiographs were also evaluated. A total of 26 of the 27 patients (96%) were available for follow-up at 1 year.

Results All functional and pain scores improved. The median *Quick-Dash* score decreased from 30 (P₂₅-P₇₅ 23-40) at 6 weeks to 7 (2-12) at 1 year with a median difference of -25, p <0.001. The median MEPI score increased from 80 (64-85) at 6 weeks to 100 (85-100) at 1 year with a median difference of 15, p <0.001. The median OES increased from 60 (44-68) at 6 weeks to 90 (73-96) at 1 year with a median difference of 29, p <0.001. .. The median VAS decreased from 2.8 (1.0-5.0) at 2 weeks to 0.5 (0.0-1.9) at 1 year. Range of motion also improved. The median flexion-extension arc improved from to 50° (33°-80°) at 2 weeks to 118° (105°-138°) at 1 year. Similarly, the median pronation-supination arc improved from 90° (63°-124°) to 160° (138°-170°). At 1 year, the residual deficit compared to the uninjured side was 30° (5°-35°) for the flexion-extension arc , and 3° (0°-25°) for the pronation-supination arc. Ten patients (37%) experienced a fixator-related complication, and seven patients required secondary surgery (26%). One patient reported recurrent instability.

Conclusions A hinged external elbow fixator provides enough stability to start early mobilization

after an acute complex elbow dislocation and residual instability. This was reflected in good functional outcome scores and only slight disability despite a relatively high complication rate.

Level of Evidence: Level IV, therapeutic study. See Instructions for Authors for a complete description of levels of evidence.

Introduction

Background

Complex elbow dislocations, with injuries to osseous and ligamentous structures, is an important cause of instability of the elbow joint [18]. The goal in management of complex elbow dislocations is to reconstruct a stable joint that tolerates a functional after-treatment [18, 26, 31, 36]. Elbows with residual instability are frequently managed by primary ligament repair with or without a period of plaster immobilization. However, ligament repair has its disadvantages. Overtightening or malpositioning of the ligaments beyond the isometric point may contribute to stiffness and instability. Furthermore, ligament repair increases the risk of ulnar nerve injury and necessitates an extensive surgical approach [22, 24, 33]. Moreover, ligamentous repair may not be sufficient to stabilize the elbow in such a way that immediate active movement is tolerated [4, 26]. Plaster immobilization is unattractive, because earlier studies found that mobilization is essential during the healing of injured ligaments because the functional load on the collagen fibers prevents contracture and the risk of stiffness [1, 10, 16, 19, 25, 27, 35]. Another alternative is the hinged external fixator, which stabilizes the elbow and protects the elbow against valgus and varus stress and allows flexion and extension. Theoretically, this will allow the ligaments to heal without additional reconstruction and without compromising a functional after-treatment.

Rationale

Previous reports on ROM and patient-reported outcome scores after the use of a hinged external fixator in these types of injuries show promising but varying results [15, 17, 29, 30, 32, 36,37]. This is mostly the result of the fact that the majority of these studies were small retrospective case series. There is a lack of prospective studies on the use of a hinged external fixator in patients with instability after a complex elbow dislocation.

The aim of this study was to prospectively evaluate patients with acute complex elbow dislocations and residual instability, who were treated with a hinged external elbow fixator and early mobilization in terms of (1) functional outcome; and (2) fixator-related adverse events.

Study Questions

This study attempts to answer the following questions: (1) In complex elbow fracture-dislocations, can treatment with a hinged external fixator result in reduction of disability and pain, and in improvement in range of motion, function, and quality of life? (2) What are the complications seen after external fixator treatment?

Patients and Methods

Study Design and Setting

This study was a prospective multicenter case series. Surgeons representing 15 hospitals participated. All surgeons were selected based on their clinical case experience with this type of injury and the hinged elbow fixator. We assessed patients for eligibility for this study between December 15, 2009, and December 13, 2011.

Participants/Study Subjects

During the period of study, the participating centers agreed upon general indications for use of the hinged external fixator, which included (1) residual elbow instability after open reduction and internal fixation (ORIF) of all associated fractures and/or radial head replacement or (2) persisting post-reduction elbow instability of dislocations that were accompanied by fractures that did not require fracture treatment. Inclusion criteria for the study were patients aged 18 years or older with a complex elbow dislocation who were treated with a hinged elbow fixator (Orthofix[®] elbow fixator; Orthofix International, Bussolegno, Italy; FDA-approved since September 15, 1999) for instability after closed reduction alone or closed reduction combined with open treatment of associated fracture(s) when indicated. A complex elbow dislocation was defined as any type of elbow dislocation with fractures of the radial head, coronoid process, or proximal ulna (olecranon). Residual instability was defined as spontaneous re-dislocation of the joint, or as re-dislocation during flexion/extension or the pivot shift test. Valgus or varus laxity without (sub-)dislocation was not defined as residual instability and was not considered as an indication for fixator placement. These tests were performed in the operating room directly after operative treatment. In patients that were treated by closed reduction alone, spontaneous re-dislocation was used as an indication for fixator placement [23]. Exclusion criteria were pathological fractures, preexistent injuries of the affected arm, collateral ligament repair, a fracture of the ipsilateral distal humerus, and additional traumatic injuries to the affected arm (ie, ipsilateral distal radius fracture). Patients with insufficient understanding of the Dutch language or patients for whom problems in maintaining followup was to be expected were also excluded. All patients gave written informed consent to participate in this study, which was approved by the medical research ethics committees of all participating hospitals. The study protocol was published elsewhere [34].

During the study period, 42 patients experienced a complex elbow dislocation and were screened for eligibility. Fifteen patients were excluded: seven patients had a stable elbow after open reduction and internal fixation, four patients had additional injuries to the ipsilateral arm, two patients had a fracture of the proximal humerus, one patient only had a subluxation of the radial head, and one patient did not consent for participation (Fig. 1). Twenty-seven patients from 11 hospitals were included baseline characteristics of all patients are displayed in Table 1. The majority of the patients were female (52%) with a median age of 52 years (P₂₅-P₇₅ 38–59). All patients but one completed the followup period of 1 year. This patient died as a result of a nonsurgery-related accident and only completed the 6 weeks follow-up.

Fracture Characteristics

Characteristics on fractures, treatment, and outcome of all individual patients are displayed in Table 2. Nine patients (33%) presented with a terrible triad injury defined as an elbow dislocation accompanied by fractures of the radial head and coronoid process. Nine patients (33%) had an isolated fracture of the radial head. In six patients (22%), the dislocation was accompanied by an isolated fracture of the coronoid process. One patient (4%) had combined fractures of the coronoid process and olecranon, one patient (4%) had combined fractures of the radial head and olecranon, and one (4%) sustained fractures of radial head, coronoid process, and the olecranon. In 20 patients (74%) at least one of the fractures required open treatment, and seven patients only underwent closed reduction before hinged external fixation. Time to surgery was a median of 6 days (P₂₅-P₇₅ 1–10).

Surgical Procedure

If instability was present after fracture treatment, a hinged external fixator was mounted. With the elbow in 90° of flexion, the central axis of rotation was located by overlapping capitellum and trochlea in a lateral fluoroscopic image. Perfect overlap of these structures resulted in a circle with the center of this circle representing the axis of rotation. Along the axis of rotation, a 2-mm Kirschner wire was inserted. Its position was confirmed in both AP and lateral planes (Fig. 2). The central connecting unit of the external fixator was then applied over the Kirschner wire. The lateral aspect of the humerus was exposed by an approximately 4-cm incision just distal to the insertion of the deltoid muscle taking the radial nerve into account. The humeral screws were

inserted and the clamp cover was tightened. Subsequently, the ulnar screws were drilled laterally through a 4-cm incision. After tightening this clamp, the image intensifier was used to check reduction and congruency of the joint and the alignment of the fixator. Flexion and extension was required to go smoothly without compromising congruency during movement. A good indicator for perfect alignment was the Kirschner wire, which had to have no resistance in the center of the connecting unit during motion of the elbow. Furthermore, no widening of the joint space was accepted during flexion and extension in AP and lateral views. Finally, the link-locking screws were then tightened, the Kirschner wire removed, and the wounds on the upper arm and forearm approximated.

Aftercare

Protocolled supervised active and passive extension, flexion, and pro- and supination exercises were started immediately after surgery if tolerated (Fig. 3) [34]. After 6 weeks, the external fixator was removed in the outpatient department without any form of anesthesia. All patients received 50 mg indomethacin twice daily for 6 weeks as heterotopic ossification prophylaxis, unless nonsteroidal antiinflammatory drugs were contraindicated.

Outcome Assessment and Data Collection

Followup data were collected at 2 weeks, 6 weeks, 3 months, 6 months, and 12 months after surgery. Standard radiographs of the elbow were made at the time of admission, within 48 hours postsurgery, and at each followup visit.

Variables, Outcome Measures, Data Sources, and Bias

The primary outcome was the Quick-Disabilities of the Arm, Shoulder and Hand (QuickDASH) scores after 1 year, reflecting functional outcome and pain [2, 11]. Secondary outcome measures were level of pain measured with a visual analog scale (VAS), the Mayo Elbow Performance Index (MEPI) [20], the injury-related quality of life measured with the Oxford Elbow Score (OES) [3, 6], and health-related quality of life measured with the SF-36 [38]. Scores for the SF-36 physical and mental component summaries (PCS and MCS, respectively) were converted to a norm-based score and compared with the norms for the general population of the United States [38]. Permission for translation and the use of the OES for this study was obtained from Oxford and Isis Outcomes, part of Isis Innovation Limited (<http://www.isis-innovation.com/>). In

addition, ROM was measured using a goniometer. Complications and secondary interventions were recorded. Radiographs were evaluated by two observers independently (GITI, DDH) for type of dislocation, type of fractures, joint congruency, fracture consolidation, and the presence of heterotopic ossifications. Radial head fractures were classified using the Mason classification. Fractures of the coronoid process were classified according to the Regan and Morrey classification [13, 28, 34]. Fractures were considered healed if one of the following three criteria were met: (1) bridging of fracture by callus/bone trabeculae or osseous bone; (2) obliteration of fracture line/cortical continuity; or (3) bridging of fracture at three cortices. Heterotopic ossifications were classified as immature calcifications, small mature ossifications, large mature ossifications, or complete bone bridging/ankylosis [8].

Statistical Analysis

Data were analyzed using SPSS Version 20.0 (Chicago, IL, USA). Normality of continuous data was tested with the Shapiro-Wilk test and by inspecting frequency histograms (Q-Q plots). Descriptive analysis was performed to describe baseline characteristics (intrinsic, injury, and intervention-related variables) and outcome measures. Continuous data are reported as medians and percentiles (nonparametric data) or as means and SD (parametric data) and categorical data as numbers with percentages. A Wilcoxon Signed Rank test was used for comparing functional outcome scores at 1 year with those at their first followup measurement (*i.e.*, 2 weeks for ROM and 6 weeks for the *Quick-DASH*, OES, MEPI, and SF-36). A Mann-Whitney U-test was performed to assess statistical significance of difference in ROM between patients who received early treatment (ie, within 7 days after initial injury) and those who received delayed treatment (ie, 7 days or later after initial treatment). A p value < 0.05 was taken as the level of statistical significance.

Results

Patient-reported Pain, Functional Outcome, and Quality of Life

All outcome measures except for the SF-36 MCS improved after the initial assessment (Fig. 4). The median *Quick-DASH* score decreased from 30 (P₂₅-P₇₅ 23-40) at 6 weeks to 7 (2-12) at 1 year with a median difference of -25, p <0.001. The median level of pain (VAS) decreased from 2.8 (1.0-5.0) at 2 weeks to 0.5 (0.0-1.9) at 1 year. The median MEPI score increased from 80 (64-85) at 6 weeks to 100 (85-100) at 1 year with a median difference of 15, p <0.001. The median OES increased from 60 (44-68) at 6 weeks to 90 (73-96) at 1 year with a median difference of 29, p <0.001. The median SF-36 PCS increased from 40 (36-42) at 6 weeks to 52 (47-55) at 1 year, with a median difference of 14, p <0.001. The SF-36 MCS score, however, remained similar (6-week median 58 [46-61], 1-year median 56 [51-60], median difference -2, p = 0.784).

Range of Motion

ROM for both flexion-extension and pronation-supination arcs improved during the course of followup (Fig. 5). The median flexion-extension arc improved from 50° (33°-80°) at 2 weeks to 118° (105-138) at 1 year, with a median difference of 63°, p <0.001. Similarly, the pronation-supination arc improved from 90° (63°-124°) to 160° (138°-170°), with a median difference of 75°, p <0.001. At 1 year, the residual deficit compared to the uninjured side was 30° (5°-35°) for the flexion-extension arc and 3° (0°-25°) for the pronation-supination arc.

The study population could be divided into a group that was treated within 7 days after initial injury (early treatment N = 14) and a group that was treated 7 days or later after initial injury (delayed treatment, N = 13). There was a 15° difference in the arc of flexion and extension favoring the early treatment group after 1 year: 128° (P₂₅-P₇₅ 114-145) versus 113° (P₂₅-P₇₅ 80-119), respectively, (p = 0.02). This difference was mainly attributable to the greater extension deficit in the late treatment group: 8° (P₂₅-P₇₅ 0-25) for the early treatment group versus 25° (P₂₅-P₇₅ 13-30) for the late treatment group, (p = 0.03).

Fixator-related Complications

Ten patients (37%) experienced 12 fixator-related complications, requiring secondary intervention in seven patients (26%) (Table 2). Five patients (19%) had elbow incongruency

resulting from fixator malalignment. In these five patients, seven procedures of fixator replacement were required. One patient experienced a hardware defect, which required fixator replacement. Four patients (15%) had a pin-tract infection, of whom two patients were treated with oral antibiotics alone. The other two patients required débridement in the outpatient clinic combined with antibiotic treatment. One patient developed a pin-tract fracture of the ulna, which could be managed conservatively (leaving the fixator in situ) and one patient developed a pin-tract fracture of the humerus 5 months after removal of the fixator, requiring plate fixation. No redislocations occurred after removal of the fixator; however, one patient developed chronic elbow instability and required a lateral collateral ligament (LCL) reconstruction.

Discussion

Residual instability after a complex elbow dislocation is a serious condition with potentially life-changing sequelae and its treatment poses a challenge, even for experienced surgeons. The goal in management of complex elbow dislocations is to reconstruct a stable joint that tolerates functional aftertreatment [18, 26, 31, 36]. A hinged fixator may be used in order to achieve this. Previous studies reported promising but variable results regarding ROM and patient-reported outcome scores [15, 17, 29, 31, 35, 36]. The variability in reported results may have been a function of the shortcomings of retrospective analysis, since most of the studies on this topic have been small and retrospective; inconsistent surgical indications, loss to followup, and inconsistent approaches to measurement of outcomes make those studies difficult to evaluate. Therefore, we aimed to assess patients with complex elbow dislocations prospectively and in a consistent fashion were treated with a hinged external elbow fixator and early mobilization in terms of (1) functional outcome; (2) ROM; and (3) fixator-related adverse events.

This study had some limitations. First, the sample size was small in relation to the number of participating centers, but reasonable given that complex elbow dislocations with residual instability after fracture treatment is an uncommon problem. To the best of our knowledge, this is the first prospective study on complex elbow dislocations of this size with a highly structured followup design. The sample size did not allow analysis of a possible effect of fracture types on the patient-reported and clinical outcome measures. Second, because the inter- and intraobserver reliability of testing elbow stability is unknown, the decision to apply external hinged fixation was and will remain arbitrary. Likewise, some surgeons treated Mason II or III fractures with radial head prosthesis, whereas others used open reduction and internal fixation or even a nonoperative approach. With the medial collateral ligament disrupted after most elbow dislocations, the radial head acts as the primary buttress against valgus stress. One can imagine the importance of stable fracture fixation or radial head replacement on elbow stability in these patients. It is not unlikely that the heterogeneous approach to radial head fractures in current study could have contributed to a difference in outcome between patients.

Third, the 1 year of followup might not have been long enough to know the final patient-reported outcome measures and ROM, because the trends of the Quick-DASH, OES, MEPI, and ROM all suggested further improvement at 1 year. On the other hand, the role of osteoarthritis on the longterm outcome remains unknown.

Our series show very little disability after external fixator treatment of complex elbow fracture-dislocations. At 2 year, the median QuickDASH score of 7 is consistently lower than QuickDASH scores reported in previous papers on similar types of injuries treated with a hinged fixator (15-28 points) [7, 12, 30, 32] or treated with ligament repair (15–28 points) [5, 7, 9, 40]. The slight disability is paralleled by high scores on the additional patient-reported functional outcome measures. In the current study, most patients reported the maximum score (100 points) for the MEPI. MEPI scores in previous papers on patients with complex elbow injuries range between 75 and 93 [5, 12, 26, 30, 36, 39]. Most important differences in treatment between current and previous studies were the use of early active mobilization, the fact that no collateral ligaments were reconstructed, and the short interval between trauma and surgery. However it is likely that a combination of these factors played a role, their individual merit could not be extracted from current data.

Interestingly, the flexion-extension arc result was better than what is expected. The flexion-extension arc in the current study (118°) was in line with the arcs reported for patients treated with ligament repair (112°-117°) [5, 7, 9, 40], but consistently higher than previously reported for patients treated with a hinged external fixator (range, 93°-99°) [29, 30, 36, 39]. The latter could be explained by the fact that the mean time to fixator placement in the mentioned studies was between 26 days and 2 months versus 6 days in the current study. Although the current study was not designed to define the “window of opportunity” for surgery, it emphasizes the importance of early reestablishment of a concentric and stable joint, which allows early movement. This is in concordance with a study by Ruch et al [32] who found an arc of flexion-extension of 120° and 84° in patients who underwent early versus delayed treatment with a hinged external fixator, respectively.

The fixator-related complication rate was relatively high. The most frequent complication (five patients), which always resulted in fixator replacement, was joint incongruency. All other complications found in this study (pin tract infection, pin tract fractures, and re-dislocation) have been reported by others as well, at similar rates. All surgeons had previously applied hinged external elbow fixators and had attended a compulsory technique-oriented hands-on course before this study. Nevertheless, the most logical explanation for the high complication rate lies in underexposure of the surgeons to the procedure. This fuels the debate whether hinged elbow fixators should only be used by experienced surgeons. One patient reported moderate instability

when evaluating the MEPI (this is the same patient who was treated with a LCL repair). No true recurrent dislocation was encountered during the complete followup in any of the patients. This suggests that surgical repair of the collateral ligaments is not indicated as a standard procedure for adequate healing of the injured collateral ligaments. From experience with ligamentous injuries to the knee and ankle, it is known that ligaments have the ability to heal and to form a scar-like neoligament. Nevertheless, only little data are available supporting a nonoperative approach to ligamentous injuries of the elbow [7, 12, 14, 15].

This study confirmed that the hinged external elbow fixator provides enough stability to start early mobilization in patients with closed reduction or open treatment after an acute complex elbow dislocation with residual instability. This was reflected in good functional outcome scores and only slight disability despite a relatively high complication rate.

Acknowledgments

We thank the Oxford and Isis Outcomes, part of Isis Innovation Limited, for their kind support. We also thank Kiran C. Mahabier (research physician) and Harold Goei, Gerben De Reus, and Liza Van Loon (medical students) for their assistance in data collection.

References

1. Anakwe RE, Middleton SD, Jenkins PJ, McQueen MM, Court-Brown CM. Patient-reported outcomes after simple dislocation of the elbow. *J Bone Joint Surg Am*. 2011;93:1220-1226.
2. Beaton DE, Katz JN, Fossel AH, Wright JG, Tarasuk V, Bombardier C. Measuring the whole or the parts? Validity, reliability, and responsiveness of the Disabilities of the Arm, Shoulder and Hand outcome measure in different regions of the upper extremity. *J Hand Ther*. 2001;14:128-146.
3. Dawson J, Doll H, Boller I, Fitzpatrick R, Little C, Rees J, Jenkinson C, Carr AJ. The development and validation of a patient-reported questionnaire to assess outcomes of elbow surgery. *J Bone Joint Surg Br*. 2008;90:466-473.
4. Duckworth AD, Ring D, Kulijdian A, McKee MD. Unstable elbow dislocations. *J Shoulder Elbow Surg* 2008;17(2):281-6.
5. Egol KA, Immerman I, Paksima N, Tejwani N, Koval KJ. Fracture-dislocation of the elbow functional outcome following treatment with a standardized protocol. *Bull NYU Hosp Jt Dis* 2007;65(4):263-70.
6. Floor S, Overbeke AJ. [Questionnaires on the quality of life in other than the Dutch language used in the Nederlands Tijdschrift voor Geneeskunde (Dutch Journal of Medicine): the translation procedure and arguments for the choice of the questionnaire] Niet-Nederlandse vragenlijsten over levenskwaliteit gebruikt in het Nederlands Tijdschrift voor Geneeskunde: vertaalprocedure en argumenten voor de keuze van de vragenlijst. *Ned Tijdschr Geneeskd* 2006;150(31):1724-7.
7. Forthman C, Henket M, Ring DC. Elbow dislocation with intra-articular fracture: the results of operative treatment without repair of the medial collateral ligament. *J Hand Surg Am* 2007;32(8):1200-9.
8. Foruria AM, Augustin S, Morrey BF, Sanchez-Sotelo J. Heterotopic ossification after surgery for fractures and fracture-dislocations involving the proximal aspect of the radius or ulna. *J Bone Joint Surg Am* 2013;95(10):e66.
9. Garrigues GE, Wray WH, 3rd, Lindenhovius AL, Ring DC, Ruch DS. Fixation of the coronoid process in elbow fracture-dislocations. *J Bone Joint Surg Am*;93(20):1873-81.
10. Hefti F, Stoll TM. [Healing of ligaments and tendons]

- Heilung von Ligamenten und Sehnen. *Orthopade* 1995;24(3):237-45.
11. Hudak PL, Amadio PC, Bombardier C. Development of an upper extremity outcome measure: the DASH (disabilities of the arm, shoulder and hand) [corrected]. The Upper Extremity Collaborative Group (UECG). *Am J Ind Med* 1996;29(6):602-8.
 12. Ivo R, Mader K, Dargel J, Pennig D. Treatment of chronically unreduced complex dislocations of the elbow. *Strategies Trauma Limb Reconstr* 2009;4(2):49-55.
 13. Johnston GW. A follow-up of one hundred cases of fracture of the head of the radius with a review of the literature. *Ulster Med J* 1962;31:51-6.
 14. Josefsson PO, Gentz CF, Johnell O, Wendeborg B. Surgical versus non-surgical treatment of ligamentous injuries following dislocation of the elbow joint. A prospective randomized study. *J Bone Joint Surg Am* 1987;69(4):605-8.
 15. Jupiter JB, Ring D. Treatment of unreduced elbow dislocations with hinged external fixation. *J Bone Joint Surg Am* 2002;84-A(9):1630-5.
 16. Maripuri SN, Debnath UK, Rao P, Mohanty K. Simple elbow dislocation among adults: a comparative study of two different methods of treatment. *Injury* 2007;38(11):1254-8.
 17. McKee MD, Bowden SH, King GJ, Patterson SD, Jupiter JB, Bamberger HB, Paksima N. Management of recurrent, complex instability of the elbow with a hinged external fixator. *J Bone Joint Surg Br* 1998;80(6):1031-6.
 18. McKee MD, Pugh DM, Wild LM, Schemitsch EH, King GJ. Standard surgical protocol to treat elbow dislocations with radial head and coronoid fractures. Surgical technique. *J Bone Joint Surg Am* 2005;87 Suppl 1(Pt 1):22-32.
 19. Mehlhoff TL, Noble PC, Bennett JB, Tullos HS. Simple dislocation of the elbow in the adult. Results after closed treatment. *J Bone Joint Surg Am* 1988;70(2):244-9.
 20. Morrey BF. *The elbow and its disorders*. 2nd edition ed. Philadelphia: WB Saunders; 1993.
 21. Morrey BF, Askew LJ, Chao EY. A biomechanical study of normal functional elbow motion. *J Bone Joint Surg Am* 1981;63(6):872-7.
 22. Mughal M, Mathew P, Hastings H, 2nd. Iatrogenic injury to the ulnar nerve during primary repair of medial ulnar collateral ligament in complex elbow fracture dislocations. *J Hand Surg Eur Vol* 2013;38(6):686-7.

23. O'Driscoll SW, Bell DF, Morrey BF. Posterolateral rotatory instability of the elbow. *J Bone Joint Surg Am* 1991;73(3):440-6.
24. Pollock JW, Pichora J, Brownhill J, Ferreira LM, McDonald CP, Johnson JA, King GJ. The influence of type II coronoid fractures, collateral ligament injuries, and surgical repair on the kinematics and stability of the elbow: an in vitro biomechanical study. *J Shoulder Elbow Surg* 2009;18(3):408-17.
25. Protzman RR. Dislocation of the elbow joint. *J Bone Joint Surg Am* 1978;60(4):539-41.
26. Pugh DM, Wild LM, Schemitsch EH, King GJ, McKee MD. Standard surgical protocol to treat elbow dislocations with radial head and coronoid fractures. *J Bone Joint Surg Am* 2004;86-A(6):1122-30.
27. Rafai M, Largab A, Cohen D, Trafef M. [Pure posterior luxation of the elbow in adults: immobilization or early mobilization. A randomized prospective study of 50 cases] Luxation posterieure pure du coude chez l'adulte: immobilisation ou mobilisation precoce. *Etude prospective randomisee sur 50 cas. Chir Main* 1999;18(4):272-8.
28. Regan W, Morrey B. Fractures of the coronoid process of the ulna. *J Bone Joint Surg Am* 1989;71(9):1348-54.
29. Ring D, Bruinsma WE, Jupiter JB. Complications of Hinged External Fixation Compared With Cross-pinning of the Elbow for Acute and Subacute Instability. *Clin Orthop Relat Res* 2014.
30. Ring D, Hannouche D, Jupiter JB. Surgical treatment of persistent dislocation or subluxation of the ulnohumeral joint after fracture-dislocation of the elbow. *J Hand Surg Am* 2004;29(3):470-80.
31. Ring D, Jupiter JB, Zilberfarb J. Posterior dislocation of the elbow with fractures of the radial head and coronoid. *J Bone Joint Surg Am* 2002;84-A(4):547-51.
32. Ruch DS, Triepel CR. Hinged elbow fixation for recurrent instability following fracture dislocation. *Injury* 2001;32 Suppl 4:SD70-8.
33. Savoie FH, 3rd, Trenhaile SW, Roberts J, Field LD, Ramsey JR. Primary repair of ulnar collateral ligament injuries of the elbow in young athletes: a case series of injuries to the proximal and distal ends of the ligament. *Am J Sports Med* 2008;36(6):1066-72.
34. Schep NW, De Haan J, Iordens GI, Tuinebreijer WE, Bronkhorst MW, De Vries MR, Goslings JC, Ham SJ, Rhemrev S, Roukema GR, Schipper IB, Sintenie JB, Van der

- Meulen HG, Van Thiel TP, Van Vugt AB, Verleisdonk EJ, Vroemen JP, Wittich P, Patka P, Van Lieshout EM, Den Hartog D. A hinged external fixator for complex elbow dislocations: a multicenter prospective cohort study. *BMC Musculoskelet Disord* 2011;12:130.
35. Schippinger G, Seibert FJ, Steinbock J, Kucharczyk M. Management of simple elbow dislocations. Does the period of immobilization affect the eventual results? *Langenbecks Arch Surg* 1999;384(3):294-7.
 36. Sorensen AK, Sojbjerg JO. Treatment of persistent instability after posterior fracture-dislocation of the elbow: restoring stability and mobility by internal fixation and hinged external fixation. *J Shoulder Elbow Surg* 2011;20(8):1300-9.
 37. Stavlas P, Gliatis J, Polyzois V, Polyzois D. Unilateral hinged external fixator of the elbow in complex elbow injuries. *Injury* 2004;35(11):1158-66.
 38. Ware JE, Jr., Sherbourne CD. The MOS 36-item short-form health survey (SF-36). I. Conceptual framework and item selection. *Med Care* 1992;30(6):473-83.
 39. Yu JR, Throckmorton TW, Bauer RM, Watson JT, Weikert DR. Management of acute complex instability of the elbow with hinged external fixation. *J Shoulder Elbow Surg* 2007;16(1):60-7.
 40. Zeiders GJ, Patel MK. Management of unstable elbows following complex fracture-dislocations--the "terrible triad" injury. *J Bone Joint Surg Am* 2008;90 Suppl 4:75-84.

Tables

Table I Baseline characteristics

	N=27
Female †	14 (52%)
Age (year) ±	52 (38 – 59)
BMI (kg/m ²) ±	26 (23 – 28)
ASA-score †	
- ASA 1	19 (70%)
- ASA 2	7 (26%)
- ASA 3	1 (4%)
Tobacco use †	7 (26%)
Alcohol use †	19 (70%)
Injury to dominant arm †	13 (48%)
Type of dislocation †	
- Posterior	14 (52%)
- Postero-lateral	10 (37%)
- Lateral	1 (4%)
- Unknown*	2 (7%)
Associated Fractures †	
- Radial head	9 (33%)
- Radial head + Coronoid process	9 (33%)
- Coronoid process	6 (22%)
- Radial head + Coronoid process + Olecranon	1 (4%)
- Radial head + Olecranon	1 (4%)
- Coronoid process + Olecranon	1 (4%)
Radial head fractures †	20 (74%)
- Mason I	2 (10%)
- Mason II	5 (25%)
- Mason III	13 (65%)
Coronoid process fractures †	17 (63%)

- Regan & Morrey I	11 (65%)
- Regan & Morrey II	5 (29%)
- Regan & Morrey III	1 (6%)
Operative fracture management †	19 (70%)

Data are displayed as \pm median, with the first and third quartile given within brackets or as † patient numbers with the percentage given between brackets. BMI, body mass index; ASA, American Society of Anesthesiologists; LET, Low energy trauma; HET, High energy trauma. * Type of dislocation is unknown due to a prehospital reduction or due to the absence of pre-reduction radiographic images when reduction occurred in another hospital.

Table II Characteristics of the 27 individual patients in order of inclusion

Nr.	Gender	Age	Trauma mechanism	Fractures (Class.)	ORIF	Radial head Prostheses	Adverse Events	Secondary surgery	1-year <i>Quick-DASH</i>	1-year OES	1-year FE Arc	1-year PS Arc
1	M	39	LET	R(II)	R	-	Wound infection Limited ROM	- Arthrolysis	4.6	90	65	180
2	F	60	LET	R(III)	-	+	-	-	0.0	100	115	180
3	M	56	LET	C(II)	C	-	Ulnaropathy	Ulnar nerve release	6.8	92	115	180
4	F	50	HET	R(I), O	O	-	-	-	11.4	60	120	180
5	M	35	LET	R(III), C(I)	R	-	-	-	2.3	98	130	180
6	F	65	LET	R(II), C(II)	-	-	Incongruent joint	Replacement HEF	29.6	73	120	165
7	M	41	HET	R(II), C(I)	R	-	Pin-tract infection Joint crepitus	- ROH (radius)	2.3	96	135	160
8	M	54	LET	R(III), C(II), C,O O	C,O	+	Late infection	ROH (olecranon + radius)	9.1	88	115	160
9	F	53	LET	R(III), C(I)	R	-	Incongruent joint Pin-tract infection Limited ROM	Replacement HEF - Arthroplasty	22.7	67	80	160
10	F	64	LET	R(II)	-	+	-	-	0.0	98	150	170
11	M	30	HET	C(II)	-	-	HEF malfunction Persistent	Replacement HEF LCL reconstruction	20.5	58	115	170

							instability						
12	F	57	LET	R(III), C(I)	-	+	-	-		6.8	92	125	160
13	F	66	HET	R(III)	R	-	Incongruent joint	Replacement HEF	11.4	77	60	170	
							Pin-tract fracture	-					
							ulna						
14	F	54	LET	C(II), O	O	-	-	-		0.0	88	120	170
15	M	31	LET	R(I), C(I)	C	-	Septic arthritis	Debridement	11.4	81	105	155	
							Pin-tract fracture	Plate humerus					
							humerus						
16	M	43	LET	C(III)	-	-	Pin-tract infection	-	4.6	81	125	165	
17	F	64	LET	R(III), C(I)	R	-	-	-	n.a.	n.a.	n.a.	n.a.	
18	F	80	LET	R(II), C(I)	R	-	Incongruent joint	Replacement HEF	6.8	92	105	145	
19	M	57	LET	R(III)	R	-	-	-	13.6	90	145	170	
20	M	26	HET	R(III)	-	-	Incongruent joint	Replacement HEF	18.2	71	110	170	
							(3)	(3)					
21	F	47	HET	R(III)	R	-	-	-	2.3	96	110	170	
22	F	48	LET	R(III), C(I)	R	-	Pain	ROH (radius)	9.1	98	145	165	
23	F	29	LET	R(III)	R	-	-	-	0.0	94	145	160	
24	M	37	HET	C(I)	-	-	Pin-tract infection	-	6.8	69	80	160	
25	M	24	LET	R(III)	R	-	-	-	9.1	90	100	170	
26	F	52	LET	C(I)	-	-	-	-	15.9	73	150	155	
27	M	49	HET	C(I)	-	-	-	-	0.0	98	150	170	

ORIF, open reduction internal fixation; OES, Oxford Elbow Score; FE, Flexion-Extension; PS, Pronation-Supination; LET, low energy trauma; HET, high energy trauma; R, radial head; C, coronoid process; O, olecranon; ROH, removal of hardware; HEF, hinged external fixator; LCL, lateral collateral ligament; M, Male; F, Female. The fractures in patients 6, 11, 16, 20, 24, 26 and 27 were treated conservatively.

Figures

Fig. 1 Study flowchart. ORIF = open reduction and internal fixation.

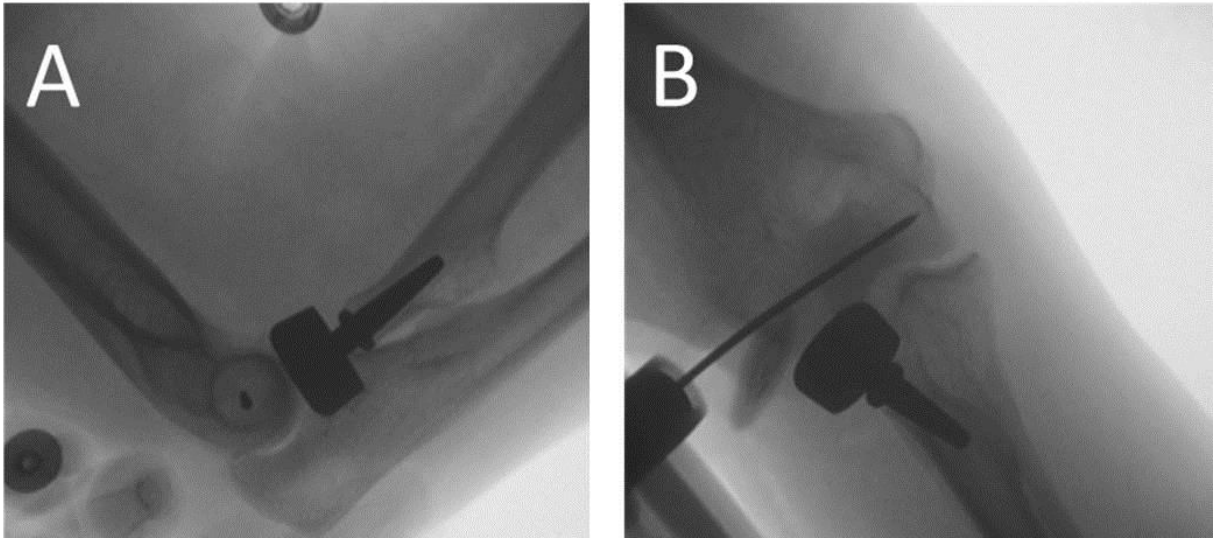


Fig. 2A-B Locating the center of rotation is done by overlapping the trochlea and capitellum of the humerus projecting them as a perfect circle. The center of this circle is considered the axis of rotation (A). The depth of the Kirschner wire is checked in AP view. Care should be taken not to drill too deep to avoid harming the ulnar nerve (B).

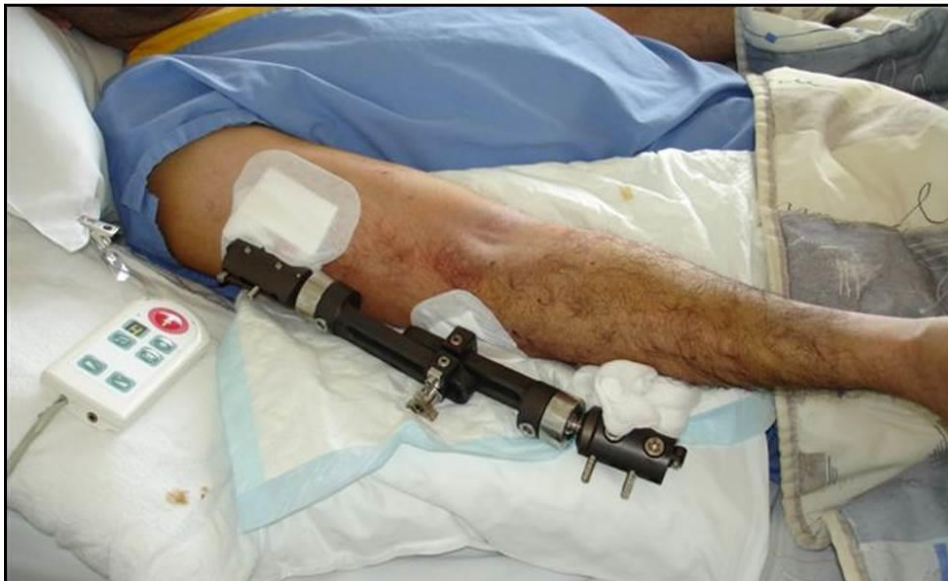
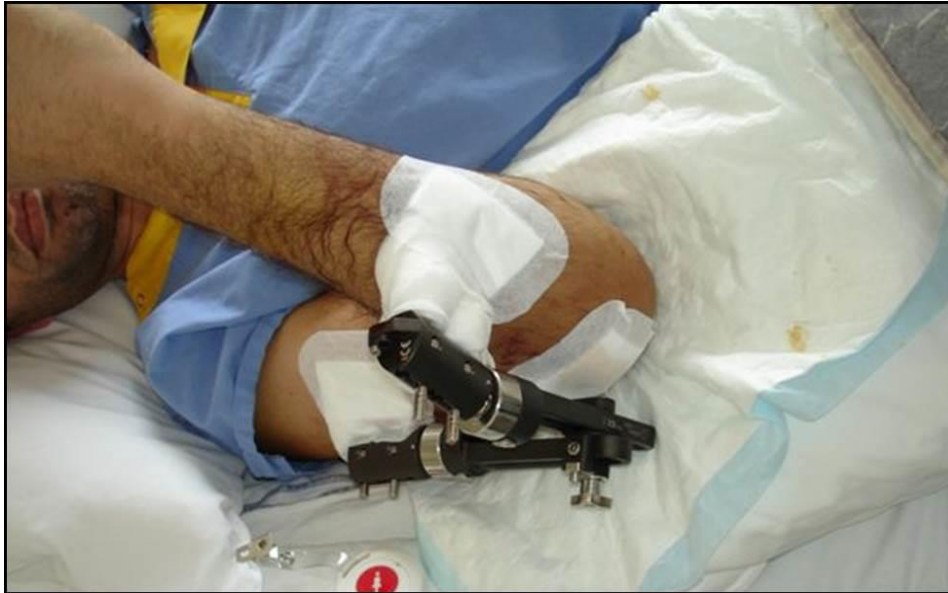
Fig. 3 Example of a study patient, demonstrating full flexion (upper panel) and extension (lower panel) immediately after surgery

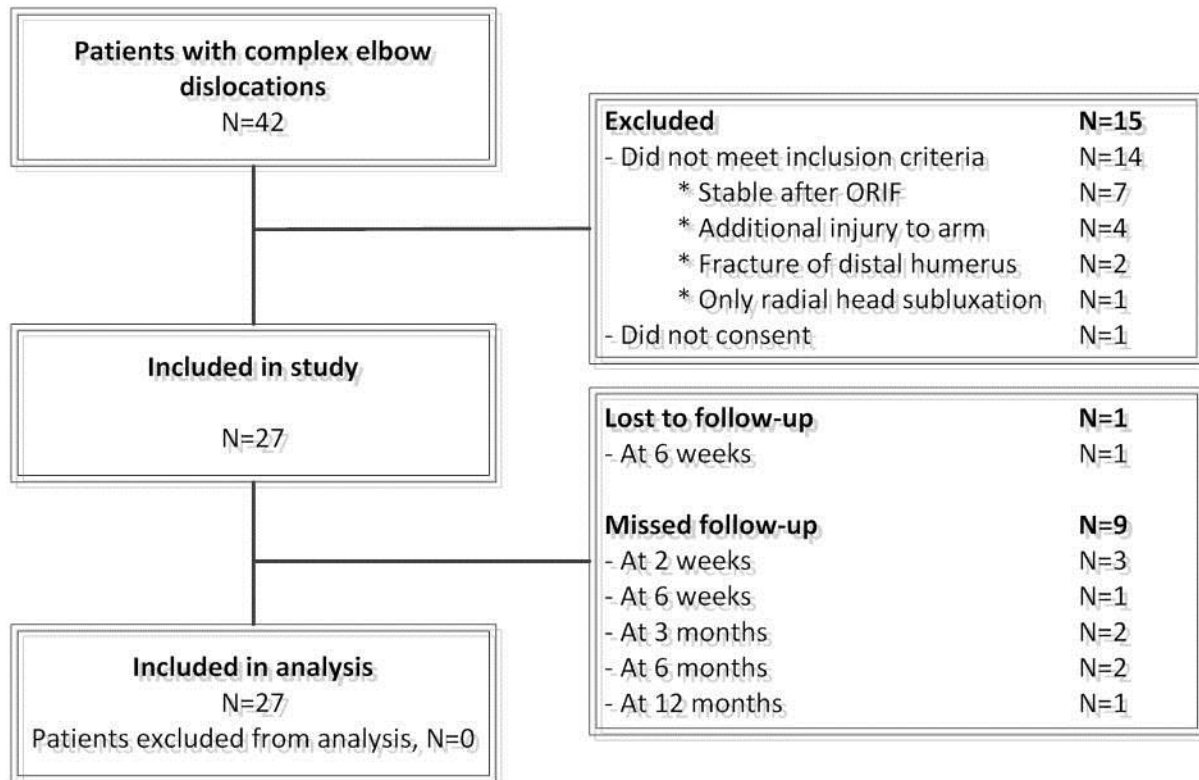


Fig. 4A-F Changes in Quick-DASH score (A), pain (B), MEPI (C), OES (D), SF-36 PCS score (E), and SF-36 MCS score (F) are displayed during followup. The dotted lines in the SF-36 PCS and MCS (E-F) represent the US population norm of 50 ± 10 (SD) points. All outcome scores except for the SF-36 MCS show improvement over time.

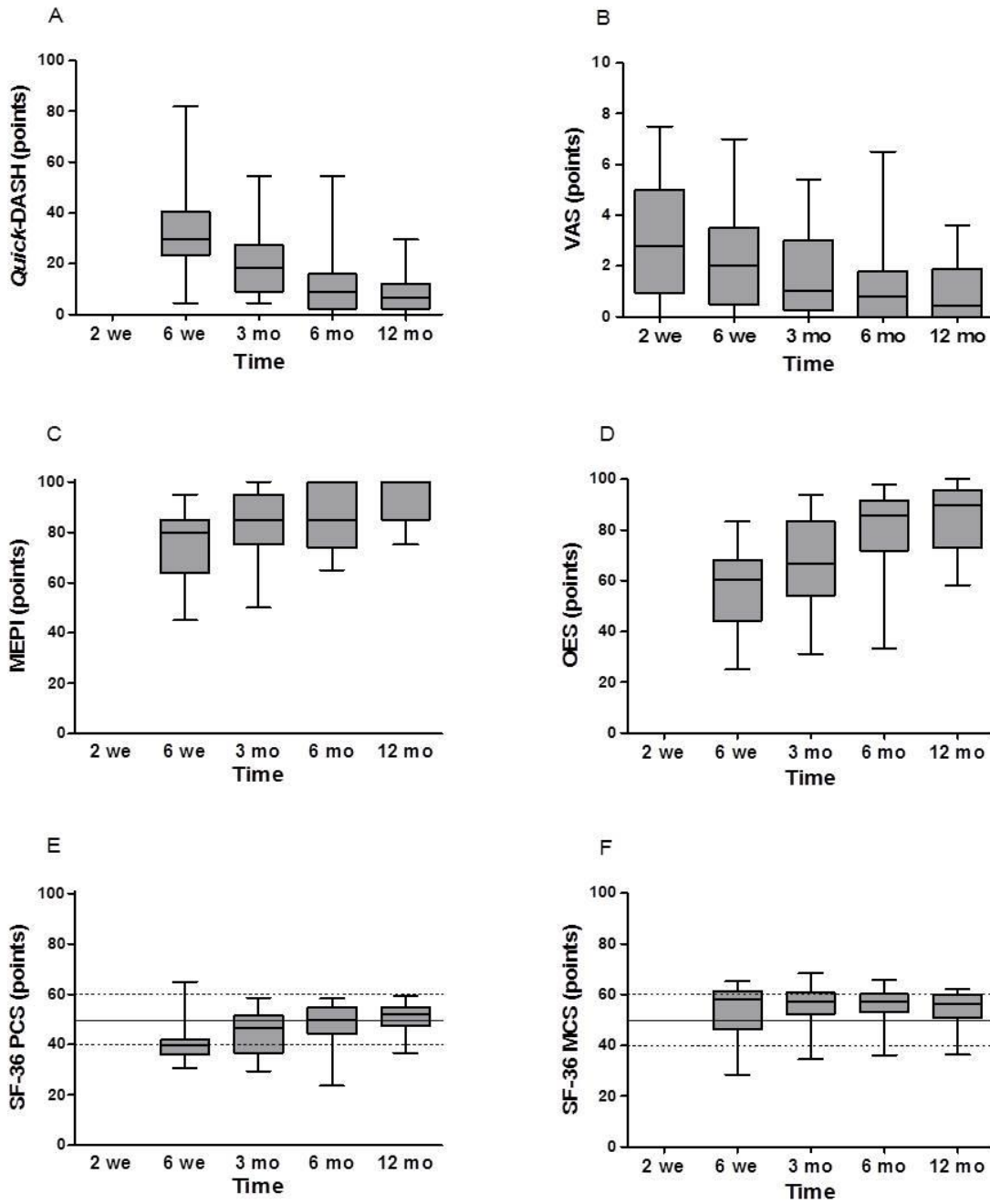


Fig. 5A-B Changes in arcs of flexion-extension (A) and pro- supination (B) are displayed during followup. The dotted lines represent the functional elbow ROM on positional and functional tasks as reported by Morrey et al [21]. ROM shows improvement over time.

