

CLINICAL STUDY

Regulation of steroidogenesis in a primary pigmented nodular adrenocortical disease-associated adenoma leading to virilization and subclinical Cushing's syndrome

Johannes Hofland¹, Wouter W de Herder¹, Lieke Derks¹, Leo J Hofland¹, Peter M van Koetsveld¹, Ronald R de Krijger², Francien H van Nederveen², Anelia Horvath³, Constantine A Stratakis³, Frank H de Jong¹ and Richard A Feelders¹

¹Section of Endocrinology, Department of Internal Medicine, Room Ee-532 and ²Department of Pathology, Erasmus Medical Center, PO Box 2040, 3000 CA Rotterdam, The Netherlands and ³Section on Endocrinology and Genetics, Program on Developmental Endocrinology and Genetics, Eunice Kennedy Shriver National Institute of Child Health and Human Development, National Institutes of Health, Bethesda, Maryland 20892, USA

(Correspondence should be addressed to J Hofland; Email: j.hofland@erasmusmc.nl)

Abstract

Context: Primary pigmented nodular adrenocortical disease (PPNAD) can lead to steroid hormone overproduction. Mutations in the cAMP protein kinase A regulatory subunit type 1A (*PRKAR1A*) are causative of PPNAD. Steroidogenesis in PPNAD can be modified through a local glucocorticoid feed-forward loop.

Objective: Investigation of regulation of steroidogenesis in a case of PPNAD with virilization.

Materials and methods: A 33-year-old woman presented with primary infertility due to hyperandrogenism. Elevated levels of testosterone and subclinical ACTH-independent Cushing's syndrome led to the discovery of an adrenal tumor, which was diagnosed as PPNAD. *In vivo* evaluation of aberrantly expressed hormone receptors showed no steroid response to known stimuli. Genetic analysis revealed a *PRKAR1A* protein-truncating Q28X mutation. After adrenalectomy, steroid levels normalized. Tumor cells were cultured and steroidogenic responses to ACTH and dexamethasone were measured and compared with those in normal adrenal and adrenocortical carcinoma cells. Expression levels of 17 β -hydroxysteroid dehydrogenase (17 β -HSD) types 3 and 5 and steroid receptors were quantified in PPNAD, normal adrenal, and adrenal adenoma tissues.

Results: Isolated PPNAD cells, analogous to normal adrenal cells, showed both increased steroidogenic enzyme expression and steroid secretion in response to ACTH. Dexamethasone did not affect steroid production in the investigated types of adrenal cells. 17 β -HSD type 5 was expressed at a higher level in the PPNAD-associated adenoma compared with control adrenal tissue.

Conclusion: PPNAD-associated adenomas can cause virilization and infertility by adrenal androgen overproduction. This may be due to steroidogenic control mechanisms that differ from those described for PPNAD without large adenomas.

European Journal of Endocrinology 168 67–74

Introduction

Primary pigmented nodular adrenocortical disease (PPNAD) constitutes a rare cause of adrenocortical hyperplasia and ACTH-independent Cushing's syndrome. PPNAD can occur sporadically or in conjunction with other tumors in Carney complex (1). Known genetic causes of PPNAD and Carney complex are mutations in components of the cAMP protein kinase A (PKA) pathway: *PRKAR1A* (2), *PDE11A* (3), and *PDE8B* (4). The net effect of these mutations is increased activity of the PKA catalytic subunits (2). Aberrant cAMP–PKA signaling in the adrenal cortex leads to hyperplasia, the formation of multiple pigmented nodules, and the sporadic formation of a large

tumor. The latter has been linked to mutations in *CTNNB1*, which lead to constitutive activation and nuclear translocation of its product β -catenin (5). Other manifestations of Carney complex include lentiginosis, myxomas, and pituitary, thyroid, and testicular tumors (6).

PPNAD is the most common endocrine manifestation of Carney complex (7) and can lead to ACTH-independent Cushing's syndrome (8). Testosterone hypersecretion from PPNAD has also been described in two female patients (9). In addition, the autonomous cortisol production by the adrenal nodules reacts paradoxically to dexamethasone administration in 69% of patients during the course of Liddle's test (8), due to increased glucocorticoid receptor (GR (NR3C1))

expression (10) and possibly specific interactions between the GR and the PKA catalytic subunits (11).

Macronodular adrenal hyperplasia and adrenocortical adenomas with autonomous cortisol production can be associated with aberrant expression of one of several eutopic and ectopic G-protein-coupled receptors (GPCRs) that are functionally coupled to steroidogenesis (12, 13). Eutopic or ectopic GPCR expression does not appear to play a major role in controlling steroidogenesis in PPNAD, unlike in macronodular hyperplasia or solitary adrenocortical adenomas (14), although clinical testing for aberrant responses has only been reported for two PPNAD patients (10).

Here, we describe a patient presenting with virilization and subclinical Cushing's syndrome due to PPNAD and a single adenoma that developed in her right adrenal. We performed several *in vivo* stimulation tests to screen for eutopic or ectopic stimuli that could possibly regulate the peculiar hypersecretion of cortisol and androgens. To obtain further insight in the regulation of steroidogenesis in this single tumor, *in vitro* studies were performed in which we examined the effects of ACTH and dexamethasone on steroidogenic enzyme expression and steroid production. In addition, expression levels of the testosterone-producing enzymes 17 β -hydroxysteroid dehydrogenase (17 β -HSD) types 3 and 5 and of the glucocorticoid and androgen receptors were measured in PPNAD as well as in other adrenal tissues.

Materials and methods

Clinical case

A 33-year-old Caucasian woman was referred to our department because of primary infertility and hyperandrogenism. The patient had been investigated for infertility for several years. Two years before referral, fertility screening showed no abnormalities in the

patient or her partner. Six intra-uterine insemination sessions and an IVF attempt did not result in pregnancy. The patient was then referred to the Department of Gynecology of our center for a second opinion; here, laboratory analysis showed an increased serum level of testosterone.

The patient had menarche at the age of 13 years. Soon thereafter, she started using oral contraceptives because of facial acne and hirsutism. Seven years before presentation, the patient stopped oral contraceptive use and regained regular menstrual cycles. She noticed increased and coarse hair on her face, abdomen, and upper legs with concomitant frontotemporal hair loss. During the past years, libido had increased and her clitoris grew larger. Her past medical history and family history were unremarkable nor did she take any medication or hormonal preparations.

Upon physical examination, the patient displayed a female phenotype with overt hirsutism and a male pattern baldness. Her extremities and torso were covered with multiple lentiginos; clitoromegaly was confirmed upon pelvic examination. Endocrinological evaluation showed increased levels of testosterone and 17-hydroxyprogesterone (17-OHP) and a suppressed ACTH level (Table 1). Morning and midnight cortisol levels were 263 and 246 nmol/l respectively. Cortisol and androgen levels were not adequately suppressed after the overnight 1 mg dexamethasone test. Abdominal CT scan subsequently showed a nodular enlargement in the right adrenal (19 \times 14 mm). Hounsfield units measured 45 at basal, rising to 135 after i.v. administration of contrast. Magnetic resonance imaging (MRI) confirmed the right adrenal nodule (Fig. 1A) with increased signal on the T2-weighted image, which enhanced after i.v. gadolinium administration. No signal loss was observed during the washout phase.

The patient was tested for ectopic hormone receptor expression by measuring cortisol, 17-OHP,

Table 1 Serum hormone levels.

	Reference values	Preoperative			Postoperative	
		At presentation	After 250 μ g synacthen	1 mg Dexamethasone overnight	1 week	27 months
Cortisol (nmol/l)	200–800	263	419	298	226	337
Testosterone (nmol/l)	0.5–3	9.7	10.1	7.5	<0.1	0.4
17-OHP (nmol/l)	0.5–10	30	31	25.9	3.1	2.2
Androstenedione (nmol/l)	2–15	14	17.4	14.5	1.14	<1.05
11-Deoxycortisol (nmol/l)	0–50	40	48		21	
DHEA (nmol/l)	1.4–25	7.2	12.5		4.1	5.3
DHEAS (μ mol/l)	0.8–10	1.00	1.01		<0.41	0.52
Estradiol (pmol/l)	100–1000	256			279	
ACTH (pmol/l)	0–11	<1.1			<1.1	11.7
LH (U/l)	2–8	4.4			1	
FSH (U/l)	1–8	9.2			1.4	
Urine cortisol (nmol/day)	0–850	455				

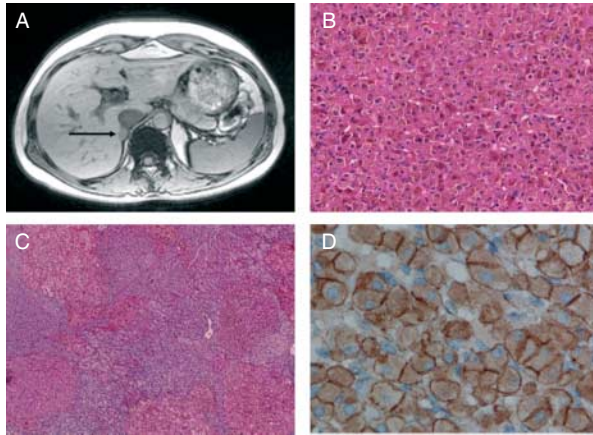


Figure 1 (A) Abdominal T1-weighted MRI revealed the presence of a hyperintense lesion in the right adrenal. Photomicrographs of the resected right adrenal: (B) large eosinophilic cells comprising the large black node. Several areas with increased intracellular pigmentation can be appreciated (magnification, 200 \times). (C) Several smaller nodules were found dispersed in the remaining adrenal cortex (magnification, 50 \times). (D) Immunohistochemical staining for β -catenin showed membrane and cytoplasmic staining of the adenoma (magnification, 800 \times).

androstenedione, and testosterone at several time points following LH-releasing hormone (100 μ g i.v.), thyrotropin-releasing hormone (200 μ g i.v.), glucagon (1 mg i.v.), metoclopramide (10 mg i.v.), and arginine-vasopressin (10 IU i.m.) administration; a standard mixed meal (116 g carbohydrates, 27 g proteins, and 14 g fat); and an upright posture test (15). The patient failed to show an increase in steroid levels of >50% after stimulation by the above-mentioned procedures.

The patient underwent an open right-sided adrenalectomy because of the suspicion of adrenocortical cancer. Postoperative testing showed nondetectable testosterone, DHEAS, and ACTH levels, whereas 17-OHP and androstenedione concentrations were markedly diminished (Table 1). Pathological examination of the right adrenal showed a 'black', round adenoma that measured \sim 2 cm in diameter. Microscopically, the tumor consisted of eosinophilic cells with extensive granular pigmentation (Fig. 1B). The tumor was embedded within an atrophic adrenal cortex peppered with multiple other pigmented nodules (Fig. 1C). The histopathological picture of the remaining cortex was consistent with that of PPNAD (1). Immunohistochemistry of β -catenin, using a mouse MAB (#610154, diluted 1:200, BD Biosciences, San Jose, CA, USA (16)), displayed a membranous and cytoplasmic staining in both the adenoma and the surrounding cortex (Fig. 1D).

Leukocyte DNA sequencing, performed as published elsewhere (17), revealed a previously reported PRKAR1A protein-truncating Q28X mutation (18), confirming the diagnosis of PPNAD. Separate sequencing of microdissected adenoma and PPNAD tissues, using methods (19) and primers (5) previously

reported, subsequently showed no mutations in exon 3 of *CTNNB1*.

Screening of the patient for pituitary tumors and for cardiac myxoma was negative, whereas the patient did suffer from several nonfunctional benign thyroid nodules and fibro-adenomas in both breasts. No family members showed signs of Carney complex-associated disease. Six months after the operation, the patient reported to be 7 weeks pregnant. At 39 weeks of pregnancy, she successfully gave birth to a healthy boy. Endocrinological evaluation 2 years after operation showed a normal HPA axis and normal levels of androgens (Table 1).

Control samples

Patient samples for *in vitro* examination were also obtained from one normal adrenal cortex obtained at radical nephrectomy due to renal cell carcinoma, from two patients with adrenocortical hyperplasia due to metastasized ACTH-producing neuroendocrine tumors and from four patients with adrenocortical carcinoma. Analysis of the normal and hyperplastic adrenal samples were combined in the group designated as 'controls'.

Three other patients with histologically proven PPNAD and clinical Cushing's syndrome were identified and adrenal samples were subsequently used for mRNA analysis. These included a 33-year-old female (PPNAD2), a 24-year-old female (PPNAD3), and a 24-year-old male (PPNAD4). PPNAD2 also showed no significant increases in cortisol production following *in vivo* testing for aberrantly expressed GPCRs. None of the PPNAD patients underwent the full Liddle's test, but PPNAD3 and PPNAD4 subjects did undergo a 7 mg i.v. dexamethasone test, which increased cortisol levels by 19 and 13% respectively. Other samples for mRNA analysis of the 17 β -HSD types 3 (*HSD17B3*) and 5 (*AKR1C3*) and steroid receptors included normal adrenals ($n=7$), ACTH-dependent hyperplasia ($n=10$), and clinically nonfunctional ($n=3$), cortisol- ($n=6$) and aldosterone-secreting ($n=6$) adrenocortical adenomas.

Informed consent was obtained from all patients before operation. The study was approved by the Medical Ethics Committee of the Erasmus MC and the DNA studies were completed under an approved Eunice Kennedy Shriver National Institute of Child Health and Human Development clinical protocol.

Tissue processing

Shortly after resection, adrenal tissue samples were snap-frozen and kept at -80°C for mRNA analysis or put in DMEM-F12 (Invitrogen) containing 5% FCS, penicillin, and streptomycin (Invitrogen) for purposes of primary culture. A monolayer culture was obtained by treating the tissue with collagenase (Sigma-Aldrich) as described previously (20). After allowing the cells to

attach overnight, the medium was changed to serum-free medium. The next day, cells were incubated with vehicle, 10 ng/ml ACTH₁₋₂₄ (Novartis) or 1 μ M dexamethasone (Sigma–Aldrich). After 48 h of incubation, the supernatants were removed and stored at -20°C ; cells were simultaneously snap-frozen and stored at -80°C . Hormone measurements were performed as previously reported (19).

mRNA and protein analysis

RNA was isolated from plated cells and homogenized frozen adrenal tissues with TRIzol reagent (Invitrogen). RNA measurement, reverse transcriptase reactions, and quantitative PCR (qPCR) were performed as described previously (21). The qPCR was performed in a 12.5 μ l volume for *HPRT1*, *STAR*, *CYP11A1*, *HSD3B2*, *CYP17A1*, *CYP21A2*, *CYP11B1* (21), *AKR1C3*, *HSD17B3*, and steroid receptors *GR* and *AR* (assay on demand, Hs00366267_m1, Hs00970002_m1, Hs00230818_m1, and Hs00907242_m1, Applied Biosystems). Expression levels were calculated relative to that of the housekeeping gene *HPRT1*, expression of which was stable between incubations and the different groups of tissues, using the δCt method.

Immunohistochemistry of HSD17B3 and AKR1C3 protein was performed with methods equal to that of β -catenin staining, using MABs purchased from Sigma–Aldrich (HPA015307, 1:30) and Abcam (ab49680, 1:3000) respectively.

Statistical analysis

All data on steroid hormone levels and mRNAs were analyzed using paired *t*-test or one-way ANOVA with *post hoc* Newman–Keuls multiple comparison test. Logarithmic conversion was applied to obtain normality if necessary. Statistical significance was assumed at $P < 0.05$.

Results

Primary cultures

Primary cultures were obtained from the patient's adrenal tissue, one normal adrenal, two hyperplastic adrenals, and four adrenocortical carcinomas. Forty-eight-hour incubation with ACTH of the patients' tumor cells led to significant increases in cortisol (5.3-fold), androstenedione (4.9-fold), and testosterone (3.6-fold) levels (Fig. 2A). The increase in cortisol secretion following ACTH stimulation in the control group was 6.8-fold and that of androstenedione 3.7-fold, whereas ACTH did not stimulate testosterone production by normal adrenal cells. Dexamethasone incubation did not alter steroid levels compared with vehicle. All steroidogenic enzymes studied were present in cells from the

PPNAD. Of the predominant human 17β -HSD isoforms that are known to be involved in testosterone production, *AKR1C3* mRNA expression in the cultured PPNAD cells was 68-fold higher than that of *HSD17B3*

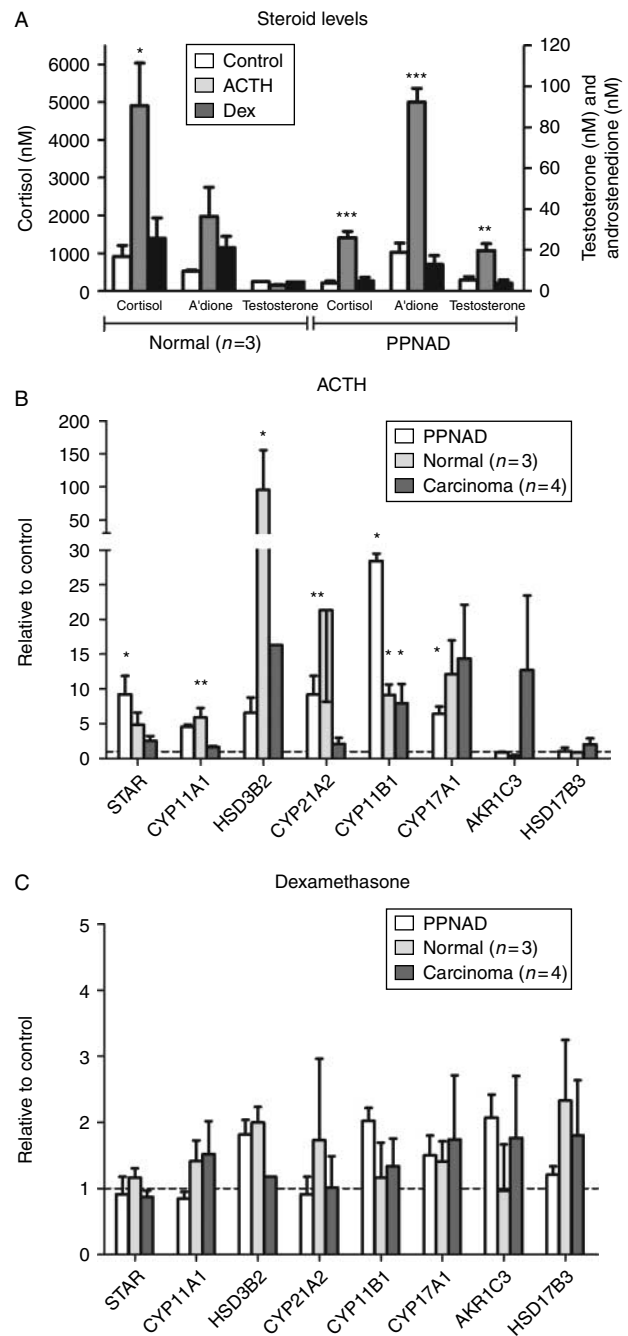


Figure 2 (A) Cortisol, androstenedione (A'dione), and testosterone levels in the supernatant of primary cultures following 48 h of ACTH or dexamethasone incubation. mRNA levels of steroidogenic enzymes in primary cultures of the PPNAD, normal and hyperplastic adrenals (control, $n=3$), and adrenocortical carcinomas ($n=4$) following 48 h of ACTH (B) or dexamethasone (C) incubation. * $P < 0.05$, ** $P < 0.01$, *** $P < 0.001$ compared with control. Data are expressed as mean \pm S.E.M.

mRNA. ACTH increased the expression of *STAR*, *CYP17A1*, *CYP21A2*, and *CYP11B1* in the PPNAD (Fig. 2B), whereas dexamethasone had no significant effect on steroidogenic enzyme mRNAs (Fig. 2C). Also, in control and carcinomatous adrenals, ACTH stimulated steroidogenic enzyme expression whereas dexamethasone did not affect these mRNAs.

17 β -HSDs and steroid receptors

The mRNA levels of *HSD17B3* and *AKR1C3* were measured in the fresh frozen tissue samples of the patient's tumor, three other PPNAD samples, normal adrenals, and adrenocortical adenomas. Overall, adrenal *AKR1C3* levels were higher than those of *HSD17B3*. Within the PPNAD group, our patient had the highest levels of *AKR1C3* and *HSD17B3* (Fig. 3, depicted as a filled square). Compared with all other adrenal samples, the virilizing PPNAD had the highest expression of *HSD17B3*. Of the different adrenal tissues, nonfunctional adenomas had higher levels of *AKR1C3* mRNA expression compared with cortisol-producing adenomas ($P < 0.05$, Fig. 3). Immunohistochemistry of both types of 17 β -HSD revealed specific, cytoplasmic staining in the control adrenals. *AKR1C3* was expressed in the zona reticularis and clustered to a lesser extent in the zona glomerulosa, whereas *HSD17B3* was expressed in the zona reticularis and adrenal medulla (Fig. 3). In the PPNAD tissue, both proteins showed a heterogeneous staining pattern among the large adenoma, the small nodules, and the remaining cortex. Staining of *AKR1C3* was more intense in the PPNAD-associated adenoma than in the surrounding cortex or normal adrenals and more prevalent than that of *HSD17B3* (Fig. 3).

Because of the paradoxical rise in cortisol after dexamethasone described in cases of PPNAD and the hyperandrogenism of the current PPNAD case, we also measured *GR* and *AR* mRNAs in these samples in order to investigate potential feed-forward loops of steroid receptor levels and glucocorticoid or androgen overproduction. The steroid receptor mRNAs were expressed in all samples, but there were no significant differences between *GR* or *AR* expression in any of the tissue types that were studied (Fig. 3).

Discussion

As the first description of Carney complex in 1985 (1), the genetic basis of the disease has been elucidated for the majority of the patients (22). However, the factors controlling the development of clinically significant PPNAD in individual patients remain largely unknown.

A patient presenting with PPNAD with primary infertility has not been described previously. The high serum levels of androgens and androgen precursors, combined with the absence of a cortisol diurnal rhythm and a suppressed ACTH, led to the discovery of an

adrenal tumor with atypical radiological features. As such high androgen levels have not been previously reported for PPNAD and the patient's left adrenal showed no abnormalities, an adrenocortical carcinoma was suspected and an open adrenalectomy was subsequently performed. Removal of the tumor led to normalization of serum androgen levels and a successful pregnancy within a few months. The steroid-secreting PPNAD-associated adenoma was the cause of the patient's primary infertility, as the serum steroid profile normalized after unilateral adrenalectomy despite the remaining left adrenal presumably also being affected by PPNAD. Unlike a previous report (23), this adenoma was not associated with *CTNNB1* mutations or constitutive β -catenin activation. This could reflect that only a subset of PPNAD-associated adenomas is

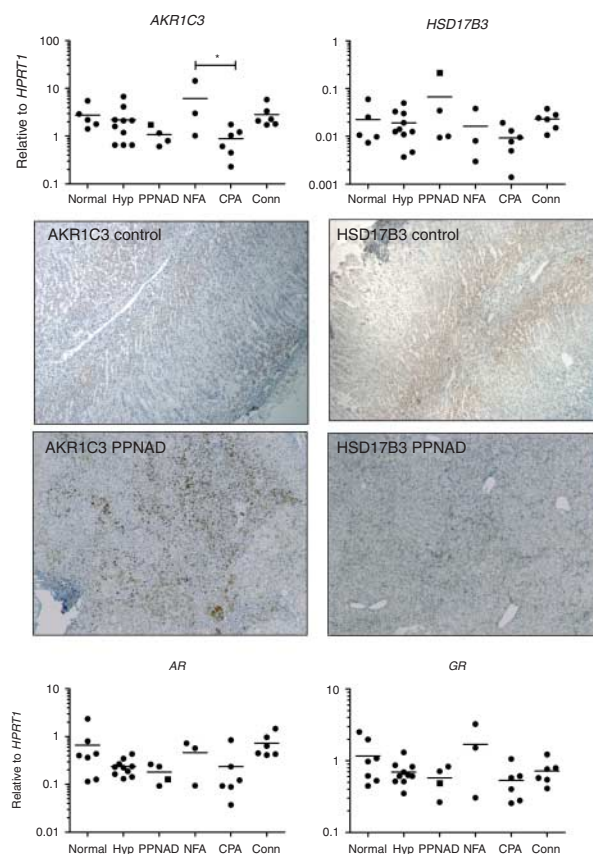


Figure 3 *AKR1C3*, *HSD17B3* (top panels), *GR*, and *AR* (bottom panels) mRNA expression in normal adrenal glands, adrenocortical hyperplasia (Hyp), PPNAD, and nonfunctional (NFA), cortisol-producing (CPA), and aldosterone-producing (Conn) adrenocortical adenomas. The virilizing PPNAD is depicted as a filled square. Expression is calculated relative to that of the housekeeping gene *HPRT1*. Bar denotes mean. * $P < 0.05$. In the centre: immunohistochemistry of *AKR1C3* and *HSD17B3* showed a cytoplasmic but heterogeneous staining pattern in the PPNAD-associated adenoma. The remaining cortex and smaller nodules showed a similar pattern, with *AKR1C3* as the predominant 17 β -HSD (magnification, 50 \times).

characterized by these mutations, as is the case in sporadic adrenocortical adenomas (24, 25).

Steroid overproduction in PPNAD usually results in a mild, ACTH-independent form of Cushing's syndrome (8). As is evident from our case, other steroids can also be produced in PPNAD, leading to a very different clinical presentation. The Q28X mutation (18) has been detected in two previous patients. These female relatives displayed lentiginos, breast myxomas, and PPNAD, but without hyperandrogenism. Recent studies in adrenal cortex-specific *Prkar1a* knockout mice showed that PKA R1 α loss is sufficient to drive PPNAD development and autonomous steroidogenesis. ACTH responsiveness remained intact in these mice (26). Human adrenal cells with mutated *PRKARIA* remain cAMP responsive and increase PKA activity even more compared with nonmutated cells as *PRKARIA* mutations lead to constitutive PKA activity (2, 9). *In vivo* and *in vitro* studies of our patient showed that the PPNAD cells still possessed the ability to respond to ACTH; production of cortisol, androstenedione, and testosterone increased after exposure to ACTH. The ACTH responsiveness in terms of cortisol and androstenedione was comparable between normal adrenocortical and the patient's PPNAD cells. However, results for testosterone differed: in the control cells, no increase of testosterone production was detected, whereas testosterone production by the PPNAD cells was significantly stimulated by ACTH. The ACTH effect as measured by steroidogenic enzyme mRNA expression levels showed an augmented and diminished response for *CYP11B1* and *HSD3B2* respectively making it possible that there was an aberrant regulation of steroidogenesis in the patient's PPNAD cells.

Testosterone is mainly formed from androstenedione by 17 β -HSD types 3 and 5, encoded by *HSD17B3* and *AKR1C3* respectively (27). Whereas *HSD17B3* is the predominant testosterone-forming enzyme in the testis, *AKR1C3* mainly ensures testosterone formation in nontesticular tissues, such as the adrenal cortex (28) and prostate gland (29). Our patient showed particularly high mRNA levels of *HSD17B3* compared with all other adrenal tissues, but this could not be confirmed by immunohistochemistry. *AKR1C3* mRNA expression in this PPNAD was augmented compared with the other PPNAD samples and staining of the enzyme revealed positive cell clusters in the large adenoma. Given the higher levels compared with *HSD17B3*, *AKR1C3* forms the principal candidate for the cause of hyperandrogenism in our patient, presumably due to mass effect in the dominant nodule. The origin of the augmented 17 β -HSD type 5 levels in this PPNAD-associated adenoma remains elusive as the factors that control adrenocortical *AKR1C3* expression are unknown.

In vivo studies in our original patient and PPNAD2 did not show evidence for ectopic expression of hormone receptors known to aberrantly control adrenal function in macronodular hyperplasia. This finding is consistent

with the two other cases described previously (10). It therefore appears unlikely that aberrant GPCR-signaling stimuli regulate increased adrenocortical steroidogenesis in human PPNAD cells.

The paradoxical rise in serum cortisol levels following Liddle's test implied that glucocorticoids can locally regulate adrenocortical steroidogenesis in the majority of PPNAD. Dexamethasone incubation in primary cells from our patient's PPNAD did not stimulate steroid secretion or steroidogenic enzyme mRNA levels, comparable to the effects in normal and malignant adrenal cells. This implies that overproduction of cortisol and androgens was present without stimulatory effects of the GR. Although the constitutively activated cAMP-PKA pathway could be sufficient cause for the hormonal syndrome in the patient, it could also be speculated that mechanisms different from glucocorticoid action are involved in steroidogenic control within PPNAD-associated adenomas. In addition, using qPCR, we could not show an increased expression of GR mRNA in PPNAD samples from four patients, two of whom showed slightly augmented cortisol levels after dexamethasone *in vivo*. This finding suggests that in at least some PPNAD tissues, aberrant coupling of the GR to the cAMP-PKA pathway (11) instead of GR overexpression (10) may be the culprit for the dexamethasone-induced rise in cortisol production. Other steroid receptors, such as the progesterone and estrogen receptors, have also been detected in PPNAD tissue (30). The finding that AR mRNA is present in PPNAD is novel, although the AR appears to be expressed similarly in the various adrenal tissues that were examined in this study.

In conclusion, we described a novel clinical presentation for PPNAD, a female with primary infertility due to a virilizing adenoma formed in the context of PPNAD. Successful pregnancy ensued upon adrenalectomy. This tumor also had a unique steroid secretion profile *in vitro*, suggesting that defects of the PKA pathway may also affect secretion of additional steroids, apart from glucocorticoids. The steroidogenic regulation in this PPNAD-associated adenoma may be different from that in PPNAD without adenomas.

Declaration of interest

The authors declare that there is no conflict of interest that could be perceived as prejudicing the impartiality of the research reported.

Funding

This work was in part supported by the Intramural Program of the Eunice Kennedy Shriver National Institute of Child Health and Human Development, National Institutes of Health, Bethesda, Maryland, USA.

Acknowledgements

The authors gratefully acknowledge Cobie Steenbergen for sequencing of *CTNNB1* and Lisette de Vogel for performing the immunohistochemistry.

References

- Carney JA, Gordon H, Carpenter PC, Shenoy BV & Go VL. The complex of myxomas, spotty pigmentation, and endocrine overactivity. *Medicine* 1985 **64** 270–283. (doi:10.1097/00005792-198507000-00007)
- Kirschner LS, Carney JA, Pack SD, Taymans SE, Giatzakis C, Cho YS, Cho-Chung YS & Stratakis CA. Mutations of the gene encoding the protein kinase A type I- α regulatory subunit in patients with the Carney complex. *Nature Genetics* 2000 **26** 89–92. (doi:10.1038/79238)
- Horvath A, Boikos S, Giatzakis C, Robinson-White A, Groussin L, Griffin KJ, Stein E, Levine E, Delimpasi G, Hsiao HP *et al.* A genome-wide scan identifies mutations in the gene encoding phosphodiesterase 11A4 (PDE11A) in individuals with adrenocortical hyperplasia. *Nature Genetics* 2006 **38** 794–800. (doi:10.1038/ng1809)
- Horvath A, Mericq V & Stratakis CA. Mutation in PDE8B, a cyclic AMP-specific phosphodiesterase in adrenal hyperplasia. *New England Journal of Medicine* 2008 **358** 750–752. (doi:10.1056/NEJMc0706182)
- Tadjine M, Lampron A, Ouadi L, Horvath A, Stratakis CA & Bourdeau I. Detection of somatic β -catenin mutations in primary pigmented nodular adrenocortical disease (PPNAD). *Clinical Endocrinology* 2008 **69** 367–373. (doi:10.1111/j.1365-2265.2008.03273.x)
- Bertherat J, Horvath A, Groussin L, Grabar S, Boikos S, Cazabat L, Libe R, Rene-Corail F, Stergiopoulos S, Bourdeau I *et al.* Mutations in regulatory subunit type 1A of cyclic adenosine 5'-monophosphate-dependent protein kinase (PRKAR1A): phenotype analysis in 353 patients and 80 different genotypes. *Journal of Clinical Endocrinology and Metabolism* 2009 **94** 2085–2091. (doi:10.1210/jc.2008-2333)
- Stratakis CA, Kirschner LS & Carney JA. Clinical and molecular features of the Carney complex: diagnostic criteria and recommendations for patient evaluation. *Journal of Clinical Endocrinology and Metabolism* 2001 **86** 4041–4046. (doi:10.1210/jc.86.9.4041)
- Stratakis CA, Sarlis N, Kirschner LS, Carney JA, Doppman JL, Nieman LK, Chrousos GP & Papanicolaou DA. Paradoxical response to dexamethasone in the diagnosis of primary pigmented nodular adrenocortical disease. *Annals of Internal Medicine* 1999 **131** 585–591.
- Groussin L, Jullian E, Perlemoine K, Louvel A, Leheup B, Luton JP, Bertagna X & Bertherat J. Mutations of the PRKAR1A gene in Cushing's syndrome due to sporadic primary pigmented nodular adrenocortical disease. *Journal of Clinical Endocrinology and Metabolism* 2002 **87** 4324–4329. (doi:10.1210/jc.2002-020592)
- Bourdeau I, Lacroix A, Schurch W, Caron P, Antakly T & Stratakis CA. Primary pigmented nodular adrenocortical disease: paradoxical responses of cortisol secretion to dexamethasone occur *in vitro* and are associated with increased expression of the glucocorticoid receptor. *Journal of Clinical Endocrinology and Metabolism* 2003 **88** 3931–3937. (doi:10.1210/jc.2002-022001)
- Louisset E, Stratakis CA, Perraudin V, Griffin KJ, Libe R, Cabrol S, Feve B, Young J, Groussin L, Bertherat J *et al.* The paradoxical increase in cortisol secretion induced by dexamethasone in primary pigmented nodular adrenocortical disease involves a glucocorticoid receptor-mediated effect of dexamethasone on protein kinase A catalytic subunits. *Journal of Clinical Endocrinology and Metabolism* 2009 **94** 2406–2413. (doi:10.1210/jc.2009-0031)
- Lacroix A. ACTH-independent macronodular adrenal hyperplasia. *Best Practice & Research. Clinical Endocrinology & Metabolism* 2009 **23** 245–259. (doi:10.1016/j.beem.2008.10.011)
- Mircescu H, Jilwan J, N'Diaye N, Bourdeau I, Tremblay J, Hamet P & Lacroix A. Are ectopic or abnormal membrane hormone receptors frequently present in adrenal Cushing's syndrome? *Journal of Clinical Endocrinology and Metabolism* 2000 **85** 3531–3536. (doi:10.1210/jc.85.10.3531)
- Hsiao HP, Kirschner LS, Bourdeau I, Keil MF, Boikos SA, Verma S, Robinson-White AJ, Nesterova M, Lacroix A & Stratakis CA. Clinical and genetic heterogeneity, overlap with other tumor syndromes, and atypical glucocorticoid hormone secretion in adrenocorticotropin-independent macronodular adrenal hyperplasia compared with other adrenocortical tumors. *Journal of Clinical Endocrinology and Metabolism* 2009 **94** 2930–2937. (doi:10.1210/jc.2009-0516)
- Lacroix A, Mircescu H & Hamet P. Clinical evaluation of the presence of abnormal hormone receptors in adrenal Cushing's syndrome. *Endocrinologist* 1999 **9** 9–15. (doi:10.1097/00019616-199901000-00004)
- Grotenhuis BA, Dinjens WN, Wijnhoven BP, Sonneveld P, Sacchetti A, Franken PE, van Dekken H, Tilanus HW, van Lanschot JJ & Fodde R. Barrett's oesophageal adenocarcinoma encompasses tumour-initiating cells that do not express common cancer stem cell markers. *Journal of Pathology* 2010 **221** 379–389. (doi:10.1002/path.2733)
- Bertherat J, Groussin L, Sandrini F, Matyakhina L, Bei T, Stergiopoulos S, Papageorgiou T, Bourdeau I, Kirschner LS, Vincent-Dejean C *et al.* Molecular and functional analysis of PRKAR1A and its locus (17q22–24) in sporadic adrenocortical tumors: 17q losses, somatic mutations, and protein kinase A expression and activity. *Cancer Research* 2003 **63** 5308–5319.
- Kirschner LS, Sandrini F, Monbo J, Lin JP, Carney JA & Stratakis CA. Genetic heterogeneity and spectrum of mutations of the PRKAR1A gene in patients with the Carney complex. *Human Molecular Genetics* 2000 **9** 3037–3046. (doi:10.1093/hmg/9.20.3037)
- Kok RC, Timmerman MA, Wolfenbittel KP, Drop SL & de Jong FH. Isolated 17,20-lyase deficiency due to the cytochrome b5 mutation W27X. *Journal of Clinical Endocrinology and Metabolism* 2010 **95** 994–999. (doi:10.1210/jc.2008-1745)
- Lamberts SW, Bons EG, Bruining HA & de Jong FH. Differential effects of the imidazole derivatives etomidate, ketoconazole and miconazole and of metyrapone on the secretion of cortisol and its precursors by human adrenocortical cells. *Journal of Pharmacology and Experimental Therapeutics* 1987 **240** 259–264.
- Chai W, Hofland J, Jansen PM, Garrelds IM, de Vries R, van den Bogaerd AJ, Feelders RA, de Jong FH & Danser AH. Steroidogenesis vs. steroid uptake in the heart: do corticosteroids mediate effects via cardiac mineralocorticoid receptors? *Journal of Hypertension* 2010 **28** 1044–1053. (doi:10.1097/HJH.0b013e328335c381)
- Stratakis CA. New genes and/or molecular pathways associated with adrenal hyperplasias and related adrenocortical tumors. *Molecular and Cellular Endocrinology* 2009 **300** 152–157. (doi:10.1016/j.mce.2008.11.010)
- Gaujoux S, Tissier F, Ragazzon B, Rebours V, Saloustros E, Perlemoine K, Vincent-Dejean C, Meurette G, Cassagnau E, Dousset B *et al.* Pancreatic ductal and acinar cell neoplasms in Carney complex: a possible new association. *Journal of Clinical Endocrinology and Metabolism* 2011 **96** E1888–E1895. (doi:10.1210/jc.2011-1433)
- Tissier F, Cavard C, Groussin L, Perlemoine K, Fumey G, Hagnere AM, Rene-Corail F, Jullian E, Gicquel C, Bertagna X *et al.* Mutations of β -catenin in adrenocortical tumors: activation of the Wnt signaling pathway is a frequent event in both benign and malignant adrenocortical tumors. *Cancer Research* 2005 **65** 7622–7627.
- Durand J, Lampron A, Mazzucco TL, Chapman A & Bourdeau I. Characterization of differential gene expression in adrenocortical tumors harboring β -catenin (CTNNB1) mutations. *Journal of Clinical Endocrinology and Metabolism* 2011 **96** E1206–E1211. (doi:10.1210/jc.2010-2143)
- Sahut-Barnola I, de Jossineau C, Val P, Lambert-Langlais S, Damon C, Lefrancois-Martinez AM, Pointud JC, Marceau G, Sapin V, Tissier F *et al.* Cushing's syndrome and fetal features

- resurgence in adrenal cortex-specific Prkar1a knockout mice. *PLoS Genetics* 2010 **6** e1000980. (doi:10.1371/journal.pgen.1000980)
- 27 Labrie F, Luu-The V, Lin SX, Simard J, Labrie C, El-Alfy M, Pelletier G & Belanger A. Intracrinology: role of the family of 17 β -hydroxysteroid dehydrogenases in human physiology and disease. *Journal of Molecular Endocrinology* 2000 **25** 1–16. (doi:10.1677/jme.0.0250001)
- 28 Hui XG, Akahira J, Suzuki T, Nio M, Nakamura Y, Suzuki H, Rainey WE & Sasano H. Development of the human adrenal zona reticularis: morphometric and immunohistochemical studies from birth to adolescence. *Journal of Endocrinology* 2009 **203** 241–252. (doi:10.1677/JOE-09-0127)
- 29 Hofland J, van Weerden WM, Dits NF, Steenbergen J, van Leenders GJ, Jenster G, Schroder FH & de Jong FH. Evidence of limited contributions for intratumoral steroidogenesis in prostate cancer. *Cancer Research* 2010 **70** 1256–1264. (doi:10.1158/0008-5472.CAN-09-2092)
- 30 de Cremoux P, Rosenberg D, Goussard J, Bremont-Weil C, Tissier F, Tran-Perennou C, Groussin L, Bertagna X, Bertherat J & Raffin-Sanson ML. Expression of progesterone and estradiol receptors in normal adrenal cortex, adrenocortical tumors, and primary pigmented nodular adrenocortical disease. *Endocrine-Related Cancer* 2008 **15** 465–474. (doi:10.1677/ERC-07-0081)

Received 11 July 2012

Revised version received 18 September 2012

Accepted 12 October 2012