

Neth Heart J (2013) 21:245–248
DOI 10.1007/s12471-013-0393-z

SPECIAL ARTICLE

Microsphere embolisation as an alternative for alcohol in percutaneous transluminal septal myocardial ablation

P. A. Vriesendorp · N. M. Van Mieghem · W. B. Vletter ·
F. J. Ten Cate · P. L. de Jong · A. F. L. Schinkel ·
M. Michels

Published online: 3 April 2013

© The Author(s) 2013. This article is published with open access at Springerlink.com

Abstract

Background Percutaneous transluminal septal myocardial ablation using microsphere embolisation is a new interventional technique to treat patients with hypertrophic obstructive cardiomyopathy.

Methods and results In two patients, considered at high risk for myectomy, targeted septal perforators were occluded with microsphere embolisation instead of alcohol ablation to reduce left ventricular outflow gradient. In both cases the left ventricular outflow tract gradient was immediately reduced. No adverse events occurred.

Conclusion This is the first clinical experience with Embozene® Microspheres in the Netherlands as an alternative for alcohol septal ablation. In both cases it resulted in immediate improvement in the haemodynamics, without any adverse events.

Keywords Hypertrophic cardiomyopathy · Percutaneous transluminal septal myocardial ablation · Microsphere embolisation

Introduction

Dynamic obstruction of the left ventricular outflow tract (LVOT) is an important component of the pathophysiology of hypertrophic cardiomyopathy (HCM) and is described in almost 70% of HCM patients [1]. Therapy in severely

symptomatic patients aims at reducing the extent of the LVOT obstruction, either medically using negative inotropic drugs or invasively by either myectomy or percutaneous transluminal septal myocardial ablation (PTSMA) using alcohol [2, 3]. PTSMA precludes general anaesthesia, sternotomy and cardiopulmonary bypass and thus results in an overall shorter in-hospital stay as compared with surgical myectomy. Conversely, PTSMA may be associated with a higher permanent pacemaker implantation rate for total atrioventricular block [4]. Furthermore, there is ongoing debate on the long-term impact of the resultant myocardial scar with arrhythmogenic potential [5]. In the current guidelines PTSMA is an alternative intervention for selected patients who are not optimal surgical candidates [2, 3].

Alcohol has been traditionally used for PTSMA. Its inherent cardiotoxicity and the risk of procedural alcohol spilling into the left anterior descending artery (LAD) have spurred interest in reliable and potentially safer embolic alternatives. There is vast experience with microspheres as an embolic agent to control bleeding or occlude the blood supply of certain tumours or arteriovenous malformations. Microspheres allow an easy, safe and targeted delivery [6, 7]. Recently, Embozene® Microspheres were demonstrated by Latsios et al. [8] as a potential alternative for alcohol in PTSMA. The aim of this report is to demonstrate the safety and efficacy of PTSMA using Embozene® Microspheres.

Material and methods

Microspheres

Embozene® Microspheres are specially designed spherical embolic agents, developed by CeloNova Biosciences Inc. (San Antonio, TX, USA). The microspheres are hydrogel cores with an anorganic polymer surface (Polyzene®-F), which is biocompatible and not absorbable. There are several

P. A. Vriesendorp · N. M. Van Mieghem · W. B. Vletter ·
F. J. Ten Cate · A. F. L. Schinkel · M. Michels (✉)
Department of Cardiology, Thoraxcenter, Erasmus MC,
's-Gravendijkwal 230, 3015 CE Rotterdam, the Netherlands
e-mail: m.michels@erasmusmc.nl

P. L. de Jong
Department of Cardiothoracic Surgery, Thoraxcenter, Erasmus MC,
's-Gravendijkwal 230, 3015 CE Rotterdam, the Netherlands

different sizes, which range from 40 μm to 900 μm in diameter, and each size has a different colour. For PTSMA the use of the 75 μm microspheres is recommended. A total of 0.6 ml of microspheres solution is diluted with 6 ml of contrast agent for optimal deliverability and visualisation.

Patients

Two HCM patients (age 64 and 77 years) with severe LVOT obstruction (>90 mmHg at rest) were selected for PTSMA because of invalidating symptoms (New York Heart Association (NYHA) functional class IV) despite optimal medical therapy. Based on multiple comorbidities, both patients were thought to be unsuitable for surgery by multidisciplinary heart team consensus and thus were considered for PTSMA. Both patients provided written informed consent for the procedure.

Intervention

The invasive PTSMA procedure evolves under transthoracic echocardiographic monitoring and conscious sedation. The right and left femoral artery and right femoral vein are cannulated using the standard Seldinger technique. A temporary pacemaker lead is placed in the apex of the right ventricle. Full anticoagulation is obtained with heparin aiming for an activated clotting time between 250 and 300 s. A 6F double lumen Langston™ pigtail catheter is advanced into the left ventricle allowing simultaneous pressure recordings in the left ventricle and the ascending aorta. The LVOT gradient is measured invasively and simultaneously with continuous wave Doppler throughout the procedure. The Brockenbrough-Braunwald-Morrow sign is assessed at baseline by artificially provoking ventricular ectopy

(Fig. 1). The left main coronary artery is selectively engaged with a 6F Judkins left guiding catheter. After visual assessment of the septal perforator branches of the LAD the first or second septal perforator is wired with a 0.014" hydrophilic coronary guidewire introduced into a 1.50 \times 15 mm over-the-wire (OTW) balloon (Trek™, Abbott Vascular). The OTW balloon is advanced into the septal perforator and inflated up to 6 atmospheres. After removal of the coronary guidewire, 2 ml of echo contrast (Sonovue, Bracco Diagnostics, Milan, Italy) is selectively injected into the septal perforator through the inner lumen of the OTW balloon to allow echocardiographic identification of the basal left ventricular septum as appropriate anatomical target for the microspheres (Fig. 2). Subsequently, with the balloon still inflated, 0.6 ml of Embozene Microspheres are injected. Filling of the septal perforator with eventual stasis of the injected solution is confirmed by fluoroscopy and continuous invasive haemodynamic monitoring demonstrates progressive reduction in LVOT gradient. The OTW balloon is deflated and removed. Figure 3 illustrates a favourable reduction in LVOT gradient from 65 mmHg to 5 mmHg and abolition of the 1st septal perforator.

Results

Safety

Both procedures were carried out uneventfully. No allergic reactions were reported after the use of microspheres. Transient per-procedural atrioventricular conduction disturbances were noted in one of the patients. The temporary pacemaker wire could be safely removed after 24 h. Neither patient required a permanent pacemaker implantation.

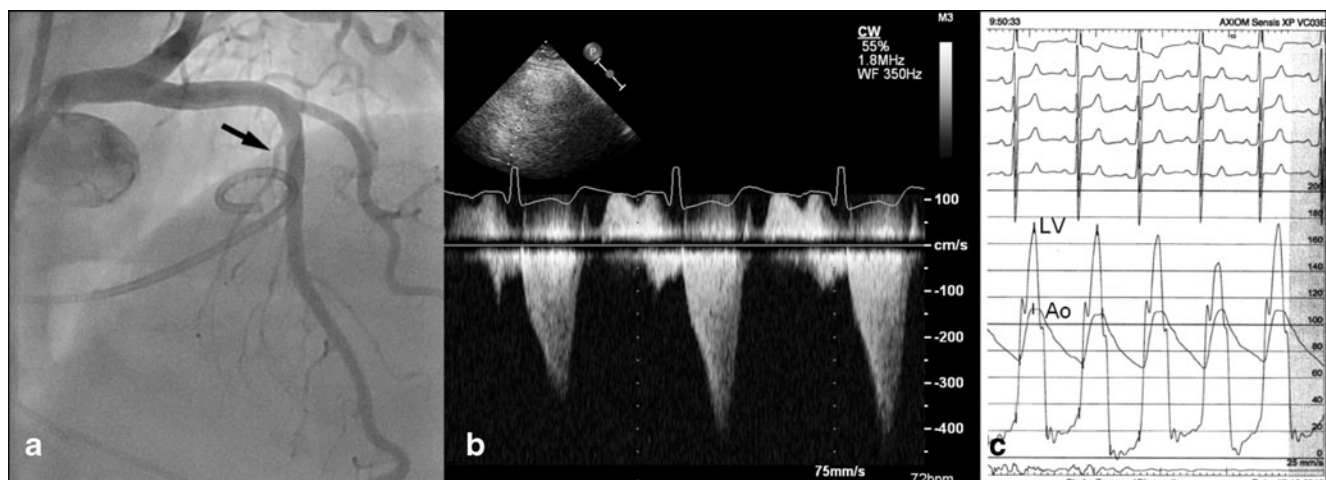


Fig. 1 Baseline coronary angiography (a) of the targeted septal artery (black arrow) and left ventricular outflow tract gradient measured with continuous wave Doppler (b) and invasively (c) direct before the procedure

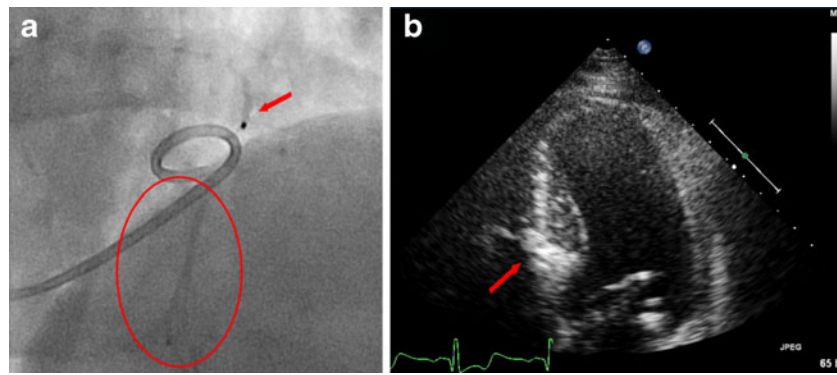


Fig. 2 Balloon inflation (a) in targeted septal artery (red arrow) and contrast agent downstream of the balloon (red circle). Opacification of the targeted septal area on 2D echocardiography (b)

Efficacy

Continuous recording of the LVOT gradient revealed an almost instant reduction of the LVOT pressure gradient (-50 mmHg and -60 mmHg) in both patients. Focal septal wall infarction was obtained as demonstrated by peak CK-MB levels (20 resp. 227 $\mu\text{g/L}$) and echocardiographic confirmation of hypokinesia and thinning of the basal septal wall.

Discussion

Alcohol injection in the septal artery is the most commonly used technique for PTSMA in patients with hypertrophic obstructive cardiomyopathy (HOCM). However, due to the direct toxicity of the alcohol on the myocardial tissue and the risk of leakage in the LAD with subsequent anterior wall infarction, this procedure is not without risks. Coil

embolisation has been proposed as an alternative for alcohol. Coils, like microspheres, may provide the opportunity to create a more controlled infarction. However, drawbacks of this technique are persistence or reoccurrence of LVOT obstruction during long-term follow-up and the risk of periprocedural migration of coils to the LAD with subsequent complications such as myocardial infarction and rarely a ventricular septal defect [9, 10].

For the first time in the Netherlands, we used Embozene[®] Microspheres as an alternative for alcohol to perform PTSMA in two patients and confirm its feasibility, corroborating the findings by the Siegburg group, where in one patient the LVOT obstruction was reduced from 70 to 10 mmHg without any complications [8]. The immediate improvement in haemodynamics and decrease of LVOT gradient is most likely caused by the focal infarction and subsequent akinesia of the septal wall. Long-term results need further research, but it is expected that due to thinning of the myocardium the LVOT gradient will further decrease.

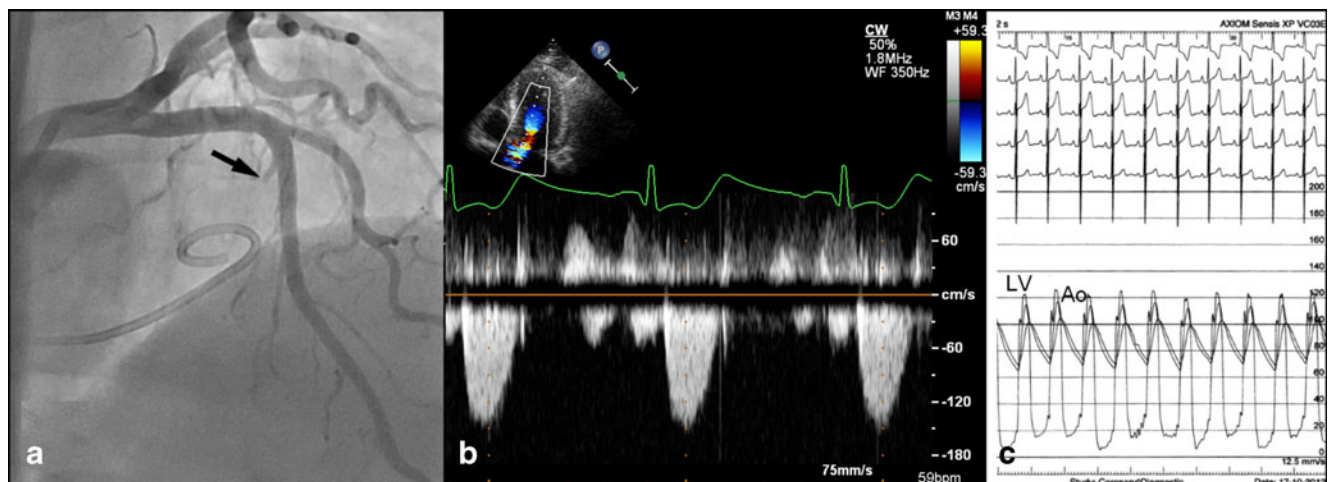


Fig. 3 Post-procedural situation with angiography (a) showing that targeted septal artery is no longer visible (black arrow) and decrease in left ventricular outflow tract gradient measured with continuous wave Doppler (b) and invasively (c) directly after the procedure

Microsphere embolisation in these two patients was safe and effective in inducing focal basal septal wall infarction. Its higher viscosity makes it safe to inject and reduces the risk of spilling into the LAD. Also the absence of intrinsic cardiotoxic effects (as seen with alcohol) may preclude untoward acute myocardial damage and create a more controlled infarction.

Conclusion

This is the first clinical experience with Embozene® Microspheres in the Netherlands as an alternative for the use of alcohol in PTSMA in severely symptomatic patients with HOCM. In both cases it resulted in immediate improvement in haemodynamics, without any adverse events.

Conflict of interests None declared.

Funding None.

Open Access This article is distributed under the terms of the Creative Commons Attribution License which permits any use, distribution, and reproduction in any medium, provided the original author(s) and the source are credited.

References

1. Maron MS, Olivotto I, Zenovich AG, et al. Hypertrophic cardiomyopathy is predominantly a disease of left ventricular outflow tract obstruction. *Circulation*. 2006;114:2232–9.
2. Gersh BJ, Maron BJ, Bonow RO, et al. 2011 ACCF/AHA guideline for the diagnosis and treatment of hypertrophic cardiomyopathy: executive summary: a report of the American College of Cardiology Foundation/American Heart Association Task Force on Practice Guidelines. *Circulation*. 2011;124:2761–96.
3. Maron BJ, McKenna WJ, Danielson GK, et al. American College of Cardiology/European Society of Cardiology Clinical Expert Consensus Document on Hypertrophic Cardiomyopathy. A report of the American College of Cardiology Foundation Task Force on Clinical Expert Consensus Documents and the European Society of Cardiology Committee for Practice Guidelines. *Eur Heart J*. 2003;24:1965–91.
4. Chen AA, Palacios IF, Mela T, et al. Acute predictors of subacute complete heart block after alcohol septal ablation for obstructive hypertrophic cardiomyopathy. *Am J Cardiol*. 2006;97:264–9.
5. ten Cate FJ, Soliman OI, Michels M, et al. Long-term outcome of alcohol septal ablation in patients with obstructive hypertrophic cardiomyopathy: a word of caution. *Circ Heart Fail*. 2010;3:362–9.
6. Stampfl U, Radeleff B, Sommer C, et al. Midterm results of uterine artery embolization using narrow-size calibrated embozene microspheres. *Cardiovasc Interv Radiol*. 2011;34:295–305.
7. Stampfl U, Stampfl S, Bellemann N, et al. Experimental liver embolization with four different spherical embolic materials: impact on inflammatory tissue and foreign body reaction. *Cardiovasc Interv Radiol*. 2009;32:303–12.
8. Latsios G, Gerckens U, Mueller R, et al. Substitution of ethanol with specially designed microspheres in a TASH procedure. *EuroIntervention*. 2011;6:889–92.
9. Carrel T, Schmidli J. Septal myectomy for hypertrophic obstructive cardiomyopathy: coil, boil and the role of rescue surgery. *Eur J Cardiothorac Surg*. 2009;36:210–1.
10. Durand E, Mousseaux E, Coste P, et al. Non-surgical septal myocardial reduction by coil embolization for hypertrophic obstructive cardiomyopathy: early and 6 months follow-up. *Eur Heart J*. 2008;29:348–55.