

Technical University of Denmark



## Detection of virus level in tissues of rainbow trout, *Oncorhynchus mykiss* in clinical stage of viral hemorrhagic septicemia

Ghiasi, Farzad; Olesen, Niels Jørgen

*Published in:*  
Brazilian Journal of Veterinary Pathology

*Publication date:*  
2014

*Document Version*  
Publisher's PDF, also known as Version of record

[Link back to DTU Orbit](#)

*Citation (APA):*  
Ghiasi, F., & Olesen, N. J. (2014). Detection of virus level in tissues of rainbow trout, *Oncorhynchus mykiss* in clinical stage of viral hemorrhagic septicemia. *Brazilian Journal of Veterinary Pathology*, 7(1), 3-6.

## DTU Library Technical Information Center of Denmark

---

### General rights

Copyright and moral rights for the publications made accessible in the public portal are retained by the authors and/or other copyright owners and it is a condition of accessing publications that users recognise and abide by the legal requirements associated with these rights.

- Users may download and print one copy of any publication from the public portal for the purpose of private study or research.
- You may not further distribute the material or use it for any profit-making activity or commercial gain
- You may freely distribute the URL identifying the publication in the public portal

If you believe that this document breaches copyright please contact us providing details, and we will remove access to the work immediately and investigate your claim.



Original Full Paper

# Detection of Virus Level in Tissues of Rainbow Trout, *Oncorhynchus mykiss* in Clinical Stage of Viral Hemorrhagic Septicemia

Farzad Ghiasi<sup>1\*</sup>, Niels Jorgen Olesen<sup>2</sup>

<sup>1</sup>Department of Fisheries Sciences, Faculty of Natural Resources, University of Kurdistan, Sanandaj, 416, Iran

<sup>2</sup>Section for Fish Diseases National Veterinary Institute, Technical University of Denmark, Aarhus Hangevej 2, DK-8200 N, Denmark

\* Corresponding Author: E-mail: [fghiasi@uok.ac.ir](mailto:fghiasi@uok.ac.ir)

Submitted September 09<sup>th</sup> 2013, Accepted February 20<sup>th</sup> 2014

## Abstract

In order to detecting VHS virus titer in various tissues in clinical stage of VHS disease, rainbow trout, *Oncorhynchus mykiss*, were exposed to virus by bath. The experiments were carried out with 140 fish obtained from rainbow trout farm. The fish were divided into two equal groups in 120 Liter tanks containing 70 fish. Group one was considered as control and group two infected by bath challenge with  $10^3$  TCID<sub>50</sub> ml<sup>-1</sup> of a VHS virus strain serologically similar to reference strain F<sub>1</sub> with high pathogenicity in rainbow trout. At days 12, 13 and 14 post infection the organs including kidney, spleen, heart, skin, liver, pyloric caeca and brain were sampled from dead fish with appropriate clinical signs of VHS separately. Each sample was placed in vials adding 1 ml transport medium to assess virus titer in various tissues. Results of the study, showed that significant difference between virus loads in various organs ( $p \leq 0.05$ ). The highest virus titer belongs to the heart while it is in minimum amount in the skin. According to the virus quantity the experimental tissues can be divided in three categories, respectively. Heart and kidney performed the highest amount of virus quantities while liver, gill, pyloric caeca and skin showed the lowest with brain and spleen lying in between. These results point out that the significant levels of VHS virus found in rainbow trout tissues are relevant for the biosecurity in VHS-free areas mainly when fish are displayed and retained as whole fish.

**Key Words:** VHS virus, tropism, rainbow trout.

## Introduction

Viral haemorrhagic septicaemia (VHS) is a serious viral disease affecting a range of fish species (5, 18). VHS virus belongs to the Novirhabdovirus genus of the family Rhabdoviridae. VHS virus isolates can be divided into four major genotypes and a number of subtypes with almost-distinct geographical distributions (4,17). European VHSV of freshwater origin causes disease primarily in rainbow trout (*Oncorhynchus mykiss*), with high mortality (9, 10). The organs affected during an infection with both VHS and IHN (Infectious Hematopoietic Necrosis) viruses are usually kidney and spleen, though most organs and tissues are affected in the later stages of the disease. Hematopoietic tissue in kidney and white pulp of the spleen are the most frequently affected tissues, but there are cases in which virus was

isolated from the brain only (22, 3, 18). Leukocytes and endothelial cells are anticipated to be important sites for virus replication (19, 20). It has been demonstrated that VHS virus effectively infects by waterborne challenge. Both gills and intestine are suggested as primary sites of infection (11, 21). Yamamoto et al., 1992 (19) showed that epithelial cells from skin and gills are capable of supporting early VHS virus and IHN virus replication. Kidney and spleen have the highest titers both in the acute and chronic phases. Brain should also be sampled in fish in the convalescent stage (12,18). Lovy et al., 2012 (7) reported, during the chronic phase, that viral persistence occurred in nervous tissues including meninges and brain parenchymal cells and in one case in peripheral nerves, while virus was mostly cleared from the other tissues of larva and Juvenile Pacific herring. A confirmed diagnosis

of VHS can be made only by isolating and serologically identifying the causative virus in an appropriate cell culture system (6). Most of the studies concluded that immunohistochemical techniques reveal fewer positive samples than virus cultivation. Cultivation is more sensitive than immunohistochemistry for detection of VHS virus (16). The main purpose of the present investigation was the comparison of VHS virus titer in different tissues in experimentally infected rainbow trout in order to find the best organ for virus isolation in end stage of the disease.

**Materials and methods**

**Fish**

140 apparently healthy fish average weight 75 g were collected from a local rainbow trout farm. The farm is approved VHS, IHN and IPN free. During the study the fish were fed once daily with commercial feed.

**Tanks**

The fish were divided in to two equal groups (I, II) in 120 Liter tanks supplied with unchlorinated tap water. The water temperature was 10±2oC. Tanks were aerated to maintain sufficient O2 concentration during infection.

**Virus**

A VHS virus isolate (DK-3592B) with two passages in BF-2 cells, serologically similar to the reference strain F1 and with proven high pathogenicity in rainbow trout was used (1).

**Cell line**

Isolation of VHS virus in culture of a number of fish cell lines is well documented somewhere else (8, 14). The fish cell lines BF-2 and RTG-2 are recommended. Alternatively, EPC or FHM cells may be used, but are in general less susceptible than BF-2 and RTG-2.

**Infection**

Group II, containing 70 fish were infected by bathing in concentration 10<sup>3</sup> TCID<sub>50</sub> VHSV ml<sup>-1</sup> of water. 0.5 ml virus suspension was mixed with 49.5 Eagle's

medium without fetal calf serum and added in tank without water renewal for two hours at 12°C to achieve desired virus concentration per ml in the tank water. Group I that considered as a control was exposed to an equal volume (50 ml) of virus - free medium and handled as the infected fish. Before the water goes out the facility got heat treatment in a pasteurization unit at 120°C during 2 minutes. Shoes and laboratory coat were changed before entering to the fish stable. Disposable gloves were worn during the work. Dead fish were removed daily from each tank. The number of dead fish and clinical signs of VHS were recorded every day.

**Sampling**

Providing organ samples for virus titration

One week after the mortality initiation, at days 12, 13 and 14 post infection, dead fish were collected. They were opened aseptically and 0.1g of each organ including brain, gill, heart, kidney, liver, pyloric caeca, spleen and skin from five fish were measured and placed in 8 Eppendorf tubes (8 pool), diluted to a ratio of 1:10 in a dilution medium. Samples were homogenized with the tissue mixer, treated with Gentamicin and stored in refrigerator 4°C over night. Half of the samples were used for virus titration and the remaining ones were stored in -20°C until used for virological examinations. During the sampling a piece of aluminum foil, new gloves and new sterile pair of scissors were used for every new sample to avoid contamination.

Virus titration

Samples were diluted in dilution plate from 10<sup>-1</sup> - 10<sup>-4</sup>. Subsequently, added to the 24-hour old monolayer BF- 2 cell line for isolation of VHS virus in cultures as documented by Olesen & Jørgensen 1992 (14), Lorenzen et al. ,1999 (8), The inoculated tissue culture plates were incubated at 15°C and monitored for viral cytopathic effect (CPE). When CPE is completed virus titers were calculated in different organs (Tab 1) (8).

**Table1.** *Oncorhynchus mykiss*. TCID<sub>50</sub>/ml in different organs about 2 weeks after challenge by bathing in concentration 10<sup>3</sup> TCID<sub>50</sub> VHSV ml<sup>-1</sup> of water.

Organs	Range of virus titers	Mean ± SD
Heart	2.8-4.4	3.5 ± 0.86
Kidney	2.9-4.6	3.47±.0.66
Brain	2.6-4.1	3.24±0.60
Spleen	2.4-3.9	3.17±1.07
Liver	1.4-3.1	2.54±0.67
Pyloric caeca	<1.3-2.9	2.33±0.73
Gill	1.3-2.8	2.27±1.01
Skin	<1.3-2.6	2.30±0.7

Titer expressed as log<sub>10</sub> TCID<sub>50</sub>/ml

Virological test

Tubes were placed in cold tap water and when thawed, 100µl from each tissue were collected in an Eppendorf tube and inoculated on BF-2 cell in 24-well plate as

described previously by Mortensen et al.,1999 (9). The 8 fold dilution from undiluted to 10<sup>-7</sup> were incubated at 15°C and inspected regularly with microscope for the occurrence of cytopathic effect (CPE). When CPE was

evident, supernatants were tested by ELISA to confirm the presence of VHS virus.

#### ELISA

ELISA used to detect VHS virus was performed according to general principles of direct ELISA described by Olesen & Jørgensen, 1991 (15). Virus is trapped by rabbit anti-VHSV antiserum which is coated onto the wells of an ELISA plate. The virus is identified by a monoclonal antibody against the VHSV N- protein (Mab IP5B11) coupled to the biotine / streptavidine - horseradish peroxidase system. Culture media from cells cultures showing evidence of CPE were analyzed with direct ELISA.

#### Statistical analyses

Significant difference between the data obtained from tissues were analyzed using Fisher's LSD and Duncan mean comparing test. The data were significant at  $p \leq 0.05$ .

#### Results and Discussion

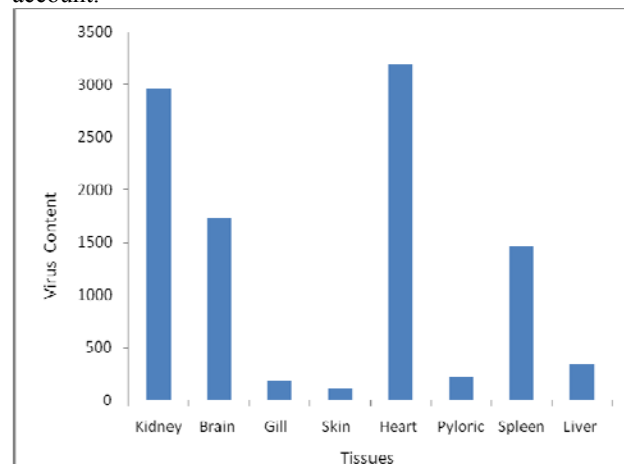
No mortality or presence of virus was observed in the control fish. Six days post challenge mortality was started in fish belonging to Group II. The amount of losses at beginning was high but decreasing in mortality was noticeable after five days. Few mortality cases were observed along days 11 to 21 with no death reported after that time. The Elisa test confirmed that VHS virus was the cause of death in infected fish. Clinical signs in dead fish were widespread dark discoloration, petechial haemorrhages in the base of the fin, peduncle, skeletal muscles, adipose tissues, anal, swim bladder, eyes and brain also hyperemia in kidney and pallor in liver and gills.

The present study revealed that there was significant difference between virus tropism in various organs ( $p \leq 5\%$ ). Heart and kidney produced the highest amount of virus while liver, gill, pyloric caeca and skin showed the lowest quantities and brain and spleen were in between (Fig1). The titration results for each organ are summarized in Table 1. In the end stage of disease (12, 13 and 14 d p.i.), virus was detectable in all samples but heart and kidney yielded the highest viral titers. These findings are in agreement with those reported by Brudeseth et al., 2002 (1) who found the highest load of VHS virus in kidney 5-7 day after infection in rainbow trout and Oidtmann et al. 2011(13) who reported the highest levels of virus in the internal organs of subclinical and clinically infected fish and brain tissue of survivors.

The present observation indicates that brain samples are valuable for VHS virus isolation either during disease or at the carrier stage almost as equally valuable as kidney and heart samples for virus detection (Fig1). In previous studies of VHS virus infection in rainbow trout (1, 11) it has been reported that virus could be detected *in situ* in brain tissue 5 days after infection which agrees with our findings in the present study. Previously brain has been suggested for virus detection in convalescence phase

of VHS disease (12, 18). In contrast with what we report for brain samples, Øystein et al., 1994 (16) found that virus is not detectable in brain at any stage of the disease. The reason for this discrepancy is not known, although antigenic variability among VHS virus strain/isolates could not be discarded. The interaction of a rhabdovirus with a cell depends on the presence of a receptor(s) molecule(s) on the cell and of a binding molecule (G) on the virion (2). The general opinion is that the gills are the prime portal of entry when virus is transmitted in water (18), although a report has focused on the epidermis and as a possible site for entry and early virus replication (19). It seems that virus elimination from skin and gills is faster than from another organs but this still needs better characterization of virus target cell in VHS virus infections and virus elimination during the disease and convalescence phase of viral haemorrhagic septicaemia.

In general virus titres/replication levels will reflect pathogenicity also for VHSV. It is possible that tropism play a role but virus strains are conserved across genotypes in receptor binding domains. Phylogenetic analysis of nucleo protein gene sequences confirm the existence of the four major genotype with sub-lineages previously identified based on N- and subsequent G- gene analyses (4, 17). Antibodies to G protein can also differentiate isolates into serotypes. It is known that antibody and complement will neutralize the virus *in vitro* and antibody also play an important role for protection. In addition our results demonstrate that significant levels of VHS virus can be found in tissues of rainbow trout which may have relevance for the biosecurity of VHS-free areas especially this fact may be important in fish displayed and retained as whole fish. The economic impact and risk management effects in fish farms might be taken into account.



**Figure 1.** *Oncorhynchus mykiss*, Comparison of VHSV titer in different organs about 2weeks after challenge by bathing in concentration 10<sup>3</sup> TCID<sub>50</sub> VHSV ml<sup>-1</sup> of water.

#### References

1. BRUDESETH BE., CASTRIC J., EVENSEN Q,2002. Studies on Pathogenesis Following Single and Double Infection with Viral

- Hemorrhagic Septicemia Virus and Infectious Hematopoietic Necrosis Virus in Rainbow Trout (*Oncorhynchus mykiss*). **Vet. Path.**, 39, 180-9. Doi:101354/vp.39-2180
2. COLL JM. The glycoprotein G of rhabdo viruses. **Arch virol.**, 1995, 140, 827-851.
  3. de KINKELIN P., de CHILMONCZYK S., DORSON M., le BERRE M., BAUDOYU, AM.,1979. Some pathogenic facets of rhabdoviral infection of salmonid fish. Symposium on Microbiology: Mechanisms of Viral Pathogenesis and Virulence ( Bachman PA,Ed.), pp. 357-75, **WHO** Collaborating Centre for Collection and Education of Data on Comparative Virology, Munich, Germany
  4. EINER-JENSEN, K., AHRENS, P. & LORENZEN, N. ,2005. Parallel phylogenetic analyses using the N, G or Nv gene from a fixed group of VHSV isolates reveal the same overall genetic typing. **Dis. Aquat. Org.** 67, 39–45.
  5. JENSEN MH. Research on the virus of Egtved disease. **Ann. N. Y. Acad. Sci.**, 1965, 126, 422-6.
  6. JORJENSEN, PEV. **A study on viral diseases in Danish rainbow trout, their diagnosis and control**, 1974. Ph.D. thesis, Royal Veterinary and Agricultural University, Copenhagen.
  7. LOVY J., LEWIS NL., HERSHBERGER PK., BERNNETT W., MEYERS TR., GARVER KA. Viral tropism and pathology associated with viral hemorrhagic septicemia in larval and juvenile Pacific herring. **Vet. Microbiol.**, 2012, 161, 66-77.
  8. LORENZEN E., CARESTENSEN B., OLESEN NJ. Inter-laboratory comparison of cell line for susceptibility to three virus : VHSV, IHNV and IPNV. **Dis. Aquat. Org.**, 1999, 37, 81-8
  9. MORTENSEN HF., HEUER O., LORENZEN N., OTTE L., OLESEN NJ. Isolation of viral haemorrhagic septicaemia virus (VHS) from wild marine fish in the Baltic Sea, Kattegat , Skaggrak and the North the North Sea. **Virus Res.**, 1999, 63, 95-106.
  10. MURANO AS. **Report on the first recorded outbreak of viral haemorrhagic septicaemia (VHS) in Great Britain and subsequent actions to contain, eradicate and investigate the origins of the infection Scottish aquaculture research report, n° 3.** Environment and Fisheries Department, Scottish Office of Agriculture, Aberdeen, United Kingdom, 1996.
  11. NEUKRICH M. Demonstration of Persistent Viral Haemorrhagic Septicaemia (VHS) Virus in Rainbow Trout after Experimental Waterborne Infection. **J. Vet. Med.** series B, 1986, 33, 471-6.
  12. NOGA, E.J., **Fish disease diagnostic and treatment.** Amsterdam: Iowa State University Press, 1996, 214-5.
  13. OIDTMANN B., JOINER C., STONE D., DODGE M., REESE RA., DIXON P. Viral load of various tissues of rainbow trout challenged with viral haemorrhagic septicaemia virus at various stages of disease **Dis. Aquat. Org.**, 2011, 93, 93-104.
  14. OLESEN NJ., JØRGENSEN PEV. Comparative susceptibility of three fish cell lines to Egtved virus, the virus of haemorrhagic septicaemia (VHS). **Dis. Aquat. Org.** 1992, 12, 235-7.
  15. OLESEN NJ., JØRGENSEN PEV. Rapid deection of viral haemorrhagic septicaemia virus in fish by ELISA. **J. Appl. Ichthyol.**, 1991, 7,185-6.
  16. OYSTEIN E., WILLY M., WAHLI T., OLESEN, NJ., JØRGENSEN PEV., HASTEIN T. Comparison of immunohistochemistry and virus cultivation for detection of viral haemorrhagic septicaemia virus in experimentally infected rainbow trout *Oncorhynchus mykiss*. **Dis. Aquat.Org.**, 1994:20,101-9
  17. SNOW, M., CUNNINGHAM, C. O., MELVIN, W. T. & KURATH, G. (1999). Analysis of the nucleoprotein gene identifies distinct lineages of viral haemorrhagic septicaemia virus within the European marine environment. **Virus Res.** 63, 35–44
  18. WOLF K.: Viral hemorrhagic septicemia. **Fish Viruses and Fish Viral Diseases.** Ithaca: Cornell University Press, 1988, 217-49.
  19. YAMAMOTO T., BATTIS WN., WINTON JR. In vitro infection of salmonid epidermal tissues by infectious hematopoietic necrosis virus and viral hemorrhagic septicemia virus. **J. Aquat. Animal Health**, 1992, 4, 231-9.
  20. YAMAMOTO, T.; CLERMONT, T.J., 1990: Multiplication of infectious hematopoietic necrosis virus in rainbow trout following immersion infection: organ assay and electron microscopy. **J. Aquat. Animal Health**, 2:261-70
  21. YAMAMOTO T., BATTIS WN., ARAKAWA CK., WINTON JR. Comparison of infectious hematopoietic necrosis in natural and experimental infections of spawning salmonids by infectivity and immunohistochemistry. AHNE W. KURSTAK. Ed. **Virus in Lower Vertebrates**, Heidelberg: Springer, 1989, 411-429.
  22. YASUTAKE WT., AMEND DF. Some aspects of pathogenesis of infectious hematopoietic necrosis (IHN). **J. Fish Biol.**, 1972, 4, 261-264 .