

Technical University of Denmark



## Mn-52 as a PET Neural Tract Tracer

**Napieczynska , Hanna; Calaminus , Carsten; Severin, Gregory; Fonslet, Jesper; Pichler, Bernd J.**

*Published in:*

Proceedings of European Molecular Imaging Meeting (EMIM) 2015

*Publication date:*

2015

[Link back to DTU Orbit](#)

*Citation (APA):*

Napieczynska , H., Calaminus , C., Severin, G. W., Fonslet, J., & Pichler, B. J. (2015). Mn-52 as a PET Neural Tract Tracer. In Proceedings of European Molecular Imaging Meeting (EMIM) 2015

## DTU Library

Technical Information Center of Denmark

---

### General rights

Copyright and moral rights for the publications made accessible in the public portal are retained by the authors and/or other copyright owners and it is a condition of accessing publications that users recognise and abide by the legal requirements associated with these rights.

- Users may download and print one copy of any publication from the public portal for the purpose of private study or research.
- You may not further distribute the material or use it for any profit-making activity or commercial gain
- You may freely distribute the URL identifying the publication in the public portal

If you believe that this document breaches copyright please contact us providing details, and we will remove access to the work immediately and investigate your claim.

## Mn-52 as a PET Neural Tract Tracer

**Napieczynska Hanna**<sup>1</sup>, Calaminus Carsten<sup>1</sup>, Severin Gregory W.<sup>2</sup>, Fonslet Jesper<sup>2</sup>, Pichler Bernd J.<sup>1</sup>

<sup>1</sup>Eberhard Karls University Tübingen, Werner Siemens Imaging Center, Department of Preclinical Imaging and Radiopharmacy - Tübingen, Germany

<sup>2</sup>Technical University of Denmark, The Hevesy Laboratory, Center for Nuclear Technologies - Roskilde, Denmark

### Introduction

Due to its unique properties of being an MR contrast agent and being transported by neurons in an activity-dependent manner, Mn has been widely used in different neurological applications [1]. However, its usage as neural tract tracer in longitudinal studies is limited by its toxicity [2]. Having found non-toxic doses of cold Mn being incapable of producing significant changes in the MRI signal, we investigated using no-carrier-added <sup>52g</sup>Mn [3] as a PET neural tract tracer.

### Methods

In the first experiment, 16 rats were stereotactically injected to the ventral tegmental area (VTA) with 0, 5, 50 or 200nmol of Mn<sup>2+</sup> in 0,5µl. T2W images and T1 maps (FLASH sequence) were acquired before and 24h after the injection on a 7T MR scanner. Average T1 values from 5 brain regions were tested with two-way ANOVA, followed by the Tukey HSD test (Bonferroni corrected). 4 weeks later, the toxicity effects were evaluated with the rotameter test and the tyrosine hydroxylase (TH) staining.

In the second study, <sup>52g</sup>Mn was produced on a small biomedical cyclotron, chemically isolated from proton irradiated Cr metal, and prepared for injection in saline. 8 rats were injected, with approx. 150 kBq, to the dorsolateral striatum (DLS) and 2 to the VTA via a guide cannula mounted on the skull 5-6 days earlier. They were scanned in a µPET scanner, and subsequently in the MR scanner, 7 or 12h later. Brains of 5 animals were used for autoradiography. PET images were reconstructed with the OSEM3D algorithm.

### Results

The dose of 200nmol produced a significant drop in the T1 value in 3 brain regions. However, 200 and 50nmol doses caused a lesion of the neurons in the injection location. The lesion did not occur after injecting 0 or 5nmol of Mn [Fig. 1]. The behavioral test did not reveal disturbances in the motor control system in any group.

<sup>52g</sup>Mn was obtained with > 99% radionuclidic purity and the specific activity of 7,5GBq/µmol. The non-radioactive Mn content was 7,0ng/MBq of <sup>52g</sup>Mn at 24h post-bombardment. Therefore, there was less than 0,07nmol of total Mn content injected in a 0,5µl volume which sufficed to produce strong signal in the PET images.

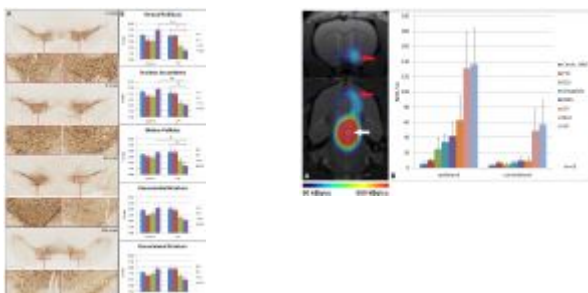
<sup>52g</sup>Mn transport to the ventral pallidum (VP) and nucleus accumbens (NAc) could be seen 12h after injection to the VTA [Fig. 2] and to the substantia nigra 7 or 12h after injection to the DLS. The autoradiograms confirmed the tracer location seen in the PET images.

### Conclusions

Our data shows that the dose required for Mn-enhanced MRI measurements produces long-term toxicity. Therefore, we propose <sup>52g</sup>Mn as a new PET tracer for neural tracts imaging. Mn concentration needed for PET is expected to be non-toxic. Further studies will evaluate the tracer's characteristics.

### References

1. Inoue T, Majid T, Pautler RG, Rev. Neurosci., 2011, 22(6): 675-694.
2. Ponzoni S, Gaziri LCJ, Britto LRG, Barreto WJ, Blum D, Neurosci. Letters, 2002, 328: 170-174.
3. Topping GJ, Schaffer P, Hoehr C, Ruth TJ, Sossi V, Med. Phys., 2013, 40(4): 0425021-0425028.



### Mn toxicity:

0, 5, 50 or 200nmol of Mn was injected to the right VTA. A. TH-staining shows a lesion caused by the 50 and 200nmol doses. B. A drop in T1 value could be detected in 3 ipsilateral brain regions 24h after injecting the highest dose. N=4 \* p<0,05 \*\* p<0,005

### Neural transport of Mn-52:

A. <sup>52g</sup>Mn (152 kBq) was injected to the right VTA (white arrow) and its transport to the NAc (red arrows) could be seen 12h later. B. PET signal quantification shows the highest content of the tracer in the ipsilateral NAc and VP (bars represent mean+SEM).

**Keywords:** Manganese, neural tract tracing, PET