



ESJ Natural/Life/Medical Sciences

Effect of an Aqueous Extract of *Alchornea Cordifolia* (Euphorbiaceae) Leaves on Sperm Parameters and Reproductive Function of Male Wistar Rats

Kone Allassane

Laboratory of Biology and Health, UFR Biosciences,
Félix Houphouët-Boigny University, Abidjan, Côte d'Ivoire

Gnahoué Goueh

Biochemical Microbiological Laboratory of SVT,
Higher Teacher School of Côte d'Ivoire

Diabate Daouda

Kouakou Koffi

Laboratory of Biology and Health, UFR Biosciences,
Félix Houphouët-Boigny University, Abidjan, Côte d'Ivoire

[Doi:10.19044/esj.2021.v17n17p236](https://doi.org/10.19044/esj.2021.v17n17p236)

Submitted: 12 January 2021

Accepted: 19 March 2021

Published: 31 May 2021

Copyright 2021 Author(s)

Under Creative Commons BY-NC-ND

4.0 OPEN ACCESS

Cite As:

Allassane K., Goueh G., Daouda D. & Koffi K. (2021). *Effect of an Aqueous Extract of Alchornea Cordifolia (Euphorbiaceae) Leaves on Sperm Parameters and Reproductive Function of Male Wistar Rats*. European Scientific Journal, ESJ, 17(17), 236.

<https://doi.org/10.19044/esj.2021.v17n17p236>

Abstract

Alchornea cordifolia (euphorbiaceae) is a tree whose leaves are used in traditional medicine to cure several health problems. Little information, however, exist on the effects of this herb on the male reproductive system. In order to assess the effect of *Alchornea cordifolia* on reproductive male parameters and testosterone production, twenty-four male wistar rats divided into four groups of six rats were used. The aqualus extract of *Alchornea cordifolia* was administered at a dose of 100 mg/kg of bw, 200 mg/kg of bw, and 400 mg/kg of bw per day, orally for 60 days. A significant increase in androgen-dependent organs, testosterone quantity, mobility, and sperm concentration was observed at doses of 200 mg/kg of bw and 400 mg/kg of bw. Only the unwinger sperm count significantly increased at the 100 mg/kg of bw dose. These results revealed that the aqualius extract of the leaves of

Alchornea cordifolia has the potential to improve sperm quality and have positive effects on the reproductive system.

Keywords: *Alchornea cordifolia*, spermatozoa, testosterone, androgenic, reproduction

Introduction

Reproduction is vital in the existence of all living things. The good functioning of the reproductive system ensures the perpetuation of the species and the demographic balance of the community. Thus, any related disfunction or disturbance results in damage at several levels, which begins from the couple to the social body (Tamboura, 2006). One of the reproductive anomalies is infertility, which is the inability to conceive naturally after a year of frequent unprotected mating (Schlosser *et al.*, 2007). From a responsibility perspective, in most cases, the female is systematically blamed (Akassa *et al.*, 2019). However, Lejeune (1999) has shown that a man and a woman equally share the responsibility for infertility. This contributed to the impetus for research on male reproduction which had long remained in its infancy and noticeably behind the study undertaken in females (Edouard Akono-Nantia *et al.*, 2007). Thus, many therapeutic advances have been made in recent years, particularly with the use of pharmaceutical specialities. Unfortunately, these drugs are expensive, and the use of herbal remedies remains necessary for a poor population.

Alchornea cordifolia is among the plants of traditional medicine which have strong therapeutic potentials, and it is primarily used for the treatment of various ailments such as respiratory, gastrointestinal, and genitourinary problem (Adewunmin *et al.*, 2001). *Alchornea cordifolia* leaves remain effective in the treatment of male fertility problems. Studies conducted by Ajibade and Olayemi (2015) and Ngaha-Njila *et al.* (2019) have shown that the methanoic extract of *Alchornea cordifolia* leaves improves male fertility and sperm quality, respectively. Nevertheless, few studies have been done with the aqueous extract. Therefore, the present study was initiated to evaluate the pharmacological effect of aqueous extract of *Alchornea cordifolia* on sperm parameters and on testosterone production in male wistar rats.

Material and Methods

Material

Plant Material

The fresh leaves of *Alchornea cordifolia* were harvested in October in the Agneby-Tiassa region (Côte d'Ivoire) precisely in Azaguié. A sample of this plant has been identified at the National Floristic Center (CNF) of Félix

Houphouet-Boigny University (Côte d'Ivoire). *Alchornea cordifolia* is registered under CNF herbarium number 322; 1248.

Animal Material

Male rats (*Rattus norvegicus*, Muridae) of the Wistar strain, aged 12-14 weeks, weighing between 150-180 g, from the animal house of the Normal Superior School, were used in the study of the fertility of the aqueous extract of *Alchornea cordifolia*.

Methods

Preparation of the Extract

The harvested leaves of *Alchornea Cordifolia* were dried in direct sunlight at room temperature. Thereafter, the dried leaves were grounded using an IKA A10 Labortechnik (Germany) brand mill to obtain a powder. Fifty (50) grams of the obtained powder was extracted by grinding. This was done three times in 1 L of distilled water in a mixer (Blender) for three minutes each. The homogenate obtained was drained three times on a square cloth. Subsequently, it was filtered successively four times through cotton wool and once using wattman paper (3 mm). The resulting filtrate was lyophilized to obtain the aqueous total extract of *Alchornea cordifolia* leaves.

Study of the Pharmacological Effects of *Alchornea Cordifolia* on Reproduction of Male Rats

The experiment was carried out on 24 rats. The animals were divided into 4 groups of 6 rats. Lot 1 received 1ml of distilled water. Lots 2, 3, and 4 received 1 mL of 100 mg/kg of bw, 200 mg/kg of bw, and 400 mg/kg of bw of total aqueous extract of *Alchornea cordifolia* for 60 days. Twenty-four (24) hours after the administration of the last dose, the animals were anesthetized with ether and then the sperm were collected. They were subsequently sacrificed by decapitation method, and the blood was collected in dry tubes for testosterone assay. Rats were dissected to remove and weigh the testes, elevator muscle, right epididymis, seminal vesicles, Cowper's gland, adrenal gland, glans, and prostate from each animal. The right testes and the right adrenal gland of the rats were preserved in 10% formalin for histopathological analysis.

Sperm Collection

The sperm collection was done according to the method described by Ngoula *et al.* (2007). The left caudal epididymis is removed by opening the scrotum. Thereafter, it is dilacerated in 10 ml of 9% NaCl before being incubated in a water bath at 36° C so that the spermatozoa will diffuse in the solution.

Spermatozoa Mobility

The mobility of the spermatozoa was assessed by direct examination of the previous solution. Thus, a fine drop of this solution was placed between slide and coverslip (previously maintained at 36 °R C.). The assessment was made under a light microscope (Olympus CX31RBSF, Philippine) at 100 × magnification. Mobile and still sperm were counted on 5 random fields and the percentage of motile forms was determined from the formula:

$$\% \text{ of motile spermatozoa} = \frac{\text{motile sperm count}}{\text{total number of sperm}} \times 100$$

Spermatozoa Density in the Epididymis

The spermatozoa density in the sperm was determined using the cell of Malassez of Kouam *et al.* (2016). A drop of the water bath was taken and placed on the Malassez cell, which was then covered with a coverslip. The sperm count was carried out under a light microscope (Olympus CX31RBSF, Philippine) at magnification 400. The number of spermatozoa per mm³ was estimated by the following formula:

$$N = \frac{X \times fd \times 10^{-6}}{4}$$

X = Number of spermatozoid counted in 4 grids of 20 small squares of the Malassez cell;

fd = Dilution factor (20);

N = Number of spermatozoid per mm³

Relative Weight of Organs Removed

The relative weight of the organs removed is obtained according to the following formula:

$$Pr(g) = \frac{Po(g)}{Pc(g)} \times 100(g)$$

With Pr: Relative weight, Pc: Body weight; Po: Body weight

Plasma Testosterone Assay

The amount of testosterone in the rat serum was analyzed using a testosterone kit (Syntron Bioresearch, Inc., Carlsbad, CA, USA). This comprised of a solid phase enzyme immunoenzimatic using the competitive binding principle.

Histopathological Examination

For histopathological examination, the right testis and the right adrenal gland of each animal were subjected to a series of dehydration in ethanol baths and embedding in paraffin. 5 μ m sections were made with a microtome. This was stained with Hematoxylin and Eosin (H&E) and observed under an optical microscope (Olympus CKX41, Germany).

Results

Effect of Aqueous Extract of *Alchornea Cordifolia* on the Body Weight of Rats

After 60 days of treatment, a slight increase in animal body weight was seen in rats treated with *Alchornea cordifolia* compared to control animals (Figure 1). However, this difference was not significant.

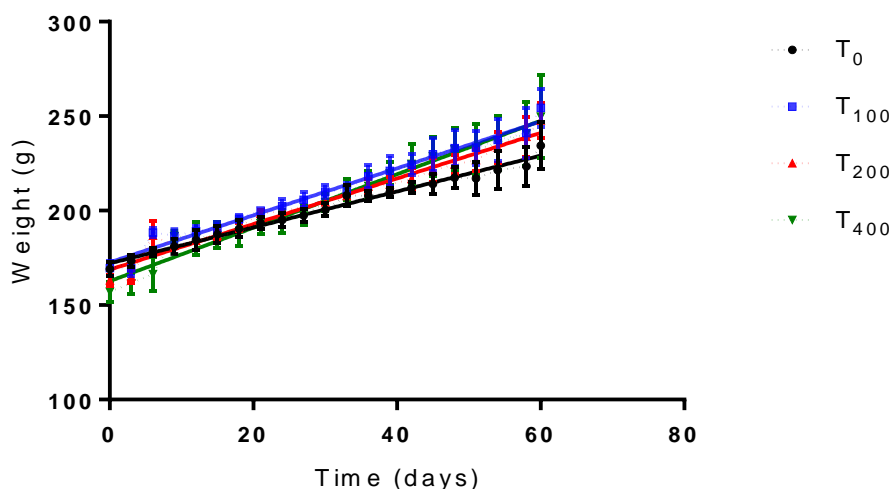


Figure 1. Evolution of the body weight of rats

T₀: distilled water; T₁₀₀: 100 mg/kg of bw from ETAAC; T₂₀₀: 200 mg/kg of bw from ETAAC; T₄₀₀: 400 mg/kg of bw from ETAAC.

Effect of ETAAC on the Weight of Male Reproductive Organs and Adrenal Gland

After 60 days of treatment, a significant increase was observed in the testes at a dose of 400 mg/kg of bw. Epididymis, seminal vesicle, prostate, and adrenal gland also increased at doses of 200 mg/kg of bw and 400 mg/kg of bw. As for Cowper's gland, glans gland, and elevator muscle, no significant difference was observed between the lots treated with ETAAC compared to the control lot. The results are reported in Table I.

Table I. Relative weights of reproductive organs and adrenal gland

Testes	Epididymis	Seminal Vesicle	Prostate	Cowper's Gland	Gland	elevator muscle	Adrenal Gland
T ₀	1,05±0,03	0,18±0,002	0,46±0,01	0,21±0,01	0,024±0,01	0,075±0,01	0,0174±0,001
T ₁₀₀	1,08±0,02	0,19±0,003	0,49±0,01	0,22±0,02	0,022±0,01	0,089±0,02	0,0183±0,001
T ₂₀₀	1,11±0,03	0,20±0,003*	0,53±0,01*	0,25±0,02*	0,024±0,01	0,087±0,03	0,0188±0,001*
T ₄₀₀	1,13±0,02*	0,21±0,007**	0,54±0,02*	0,25±0,01*	0,025±0,01	0,088±0,01	0,0193±0,001**

T₀: distilled water; T₁₀₀: 100 mg/kg of bw; T₂₀₀: 200 mg/kg of bw; T₄₀₀: 400 mg/kg of bw.

*: significant difference at P <0.05; **: significant difference at P <0.01

Effect of ETAAC on Testosterone Levels

After 60 days of treatment, a significant increase was observed in the level of serum testosterone at doses of 200 mg/kg of bw and 400 mg/kg of bw with a percentage of 34,15% and 39,14% respectively. This observation was seen in the treated rats compared to witnesses (Figure 2).

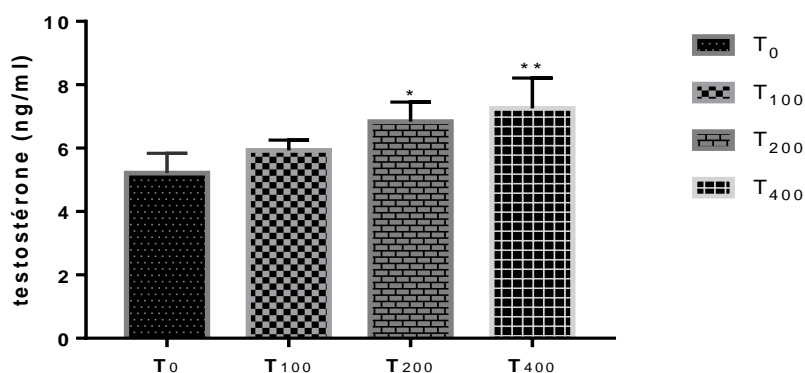


Figure 2. Effect of aqueous extract of *Alchornea cordifolia* on testosterone levels

T₀: distilled water; T₁₀₀: 100 mg/kg of bw; T₂₀₀: 200 mg/kg of bw; T₄₀₀: 400 mg/kg of bw.

Effect of ETAAC on Sperm Parameters

Sperm density significantly increased after treatment of rats with aqueous extract of *Alchornea cordifolia* at doses of 200 mg/kg of bw and 400 mg/kg of bw (Figure 3). The mobile sperm count also significantly increased in rats treated with ETAAC (Figure 4). Sperm morphology was not affected regardless of the dose of extract administered. Almost all sperm were normal in both control and treated rats.

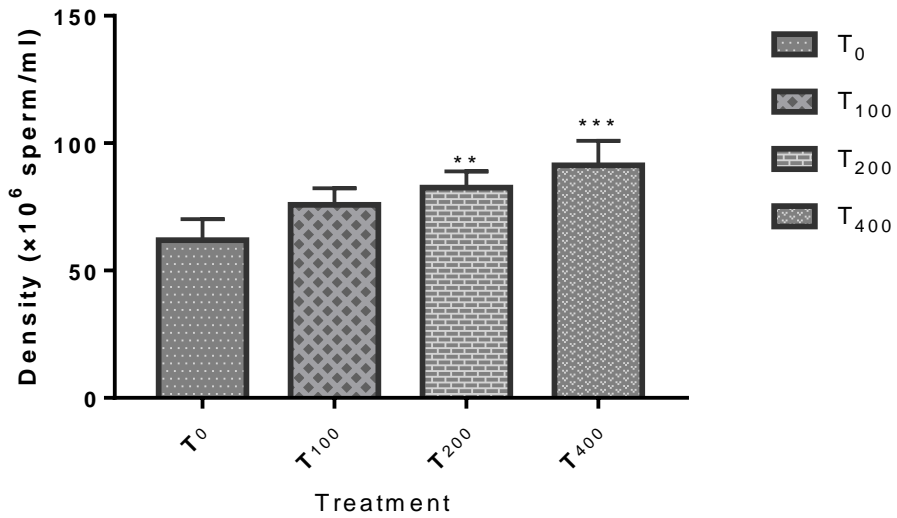


Figure 3. Effect of aqueous extract of *Alchornea cordifolia* on sperm density

T₀: distilled water; T₁₀₀: 100 mg/kg of bw; T₂₀₀: 200 mg/kg of bw; T₄₀₀: 400 mg/kg of bw.

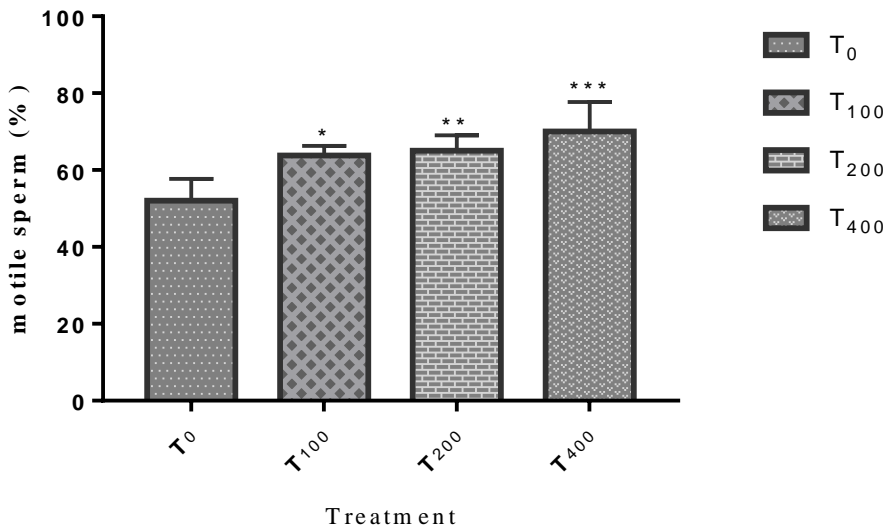


Figure 4. Effect of aqueous extract of *Alchornea cordifolia* on motile sperm count

T₀: distilled water; T₁₀₀: 100 mg/kg of bw; T₂₀₀: 200 mg/kg of bw; T₄₀₀: 400 mg/kg of bw.

Effect of Aqueous Extract of *Alchornea Cordifolia* on the Histological Structure of the Testis

Observation of histological sections of the testes of the rats showed an increase in the volume of the seminiferous tubules in the rats treated with the aqueous extract of *Alchornea cordifolia*. There was also concentration of sperm in the lumen of the seminiferous tubules.

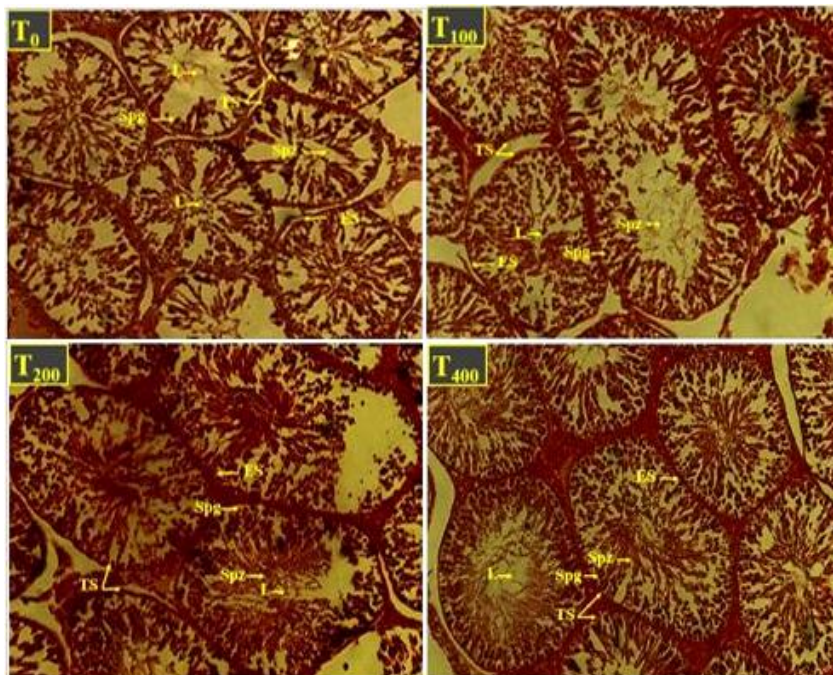


Figure 5. Cross section of testis of control rats and rats treated with different doses of ETAAC

L: Lumen; TS: Wall of the seminiferous tube; Spg: Spermatogonia; Spz: Spermatozoa; ES: Seminal epithelium; T₀: distilled water; T₁₀₀: 100 mg/kg of bw; T₂₀₀: 200 mg/kg of bw; T₄₀₀: 400 mg/kg of bw; Magnification: × 100
Stain: Hematoxylin eosin

Discussion

The general objective of the present study was to assess the pharmacological effect of ETAAC on sperm parameters and testosterone production in male rats. After 60 days of treatment, a slight increase in body weight of the treated rats was observed. This could be attributed to the normal growth of the animals during the period. However, the lack of significant difference shows that the aqueous extract of *Alchornea cordifolia* is believed to have no influence on weight growth. These results are identical to those of Ansah *et al.* (2011). The significant increase in the weight of certain androgen-

dependent organs, namely the epididymis, the seminal vesicle and the prostate at the doses of 200 mg/kg of bw to 400 mg/kg of bw and the testes at the dose of 400 mg/kg of bw, demonstrates the androgenic effect of ETAAC. This is because the weight, size, and secretory function of the testes, epididymis, seminal vesicles, and prostate are tightly regulated by androgens (Agarwal *et al.*, 1986). Regarding the epididymis, in addition to the secretions of fluids induced by androgens, the accumulation of sperm in this organ could be the cause of its increase in weight. This result is different from that of Ngaha-Njila *et al.* (2019) who did not observe a significant difference after 28 days of treatment with a methanolic extract of *Alchornea cordifolia*. The dose-dependent growth of the testes observed is due to steroidogenesis, which is the production of steroid hormones, mainly testosterone, provided by Leydig cells (Stocco, 2002). This testicular increase could be considered as a biological indicator of the effectiveness of the plant in stimulating hormone production (Thakur & Dixit, 2007). Besides steroidogenesis, the increase in testes could be attributed to stimulation of spermatogenesis, which is the process by which spermatogonia proliferate and turn into mobile sperm (Clermont, 1972). This result differs from that of Ansah *et al.* (2009) who obtained no significant difference after 14 days of treatment on mice. Nonetheless, the result is close to that of Ajibade and Olayemi (2015) who, after 30 days of treatment with a methanolic extract of *Alchornea cordifolia*, observed a significant increase in testes at a dose of 400 mg/kg of bw. The increase in the weight of the seminal vesicles and the prostate observed in this study is due to an intense stimulation of the secretion of the respective seminal and prostatic fluids. This abundance of fluid could be at the origin of the weight growth of these organs (Zougrou, 2017). In rats, any increase in serum testosterone is associated with an increase in the secretory activity of the seminal vesicles and an increase in their weight (Marzouk, 2017). The significant increase in the adrenal gland in rats treated at doses of 200 mg/kg of bw and 400 mg/kg of bw was impacted by the production of serum testosterone which increased significantly in this study. It is one of the essential hormones of male physiology. It is also responsible for the development of testicular function, which is the stimulation and maintenance of spermatogenesis (Weinbauer & Nieschlag, 1998). It is produced by the testes and secondarily by the adrenal glands (Bélanger, 1992). This significant increase in serum testosterone levels of 34,15% and 39,14% observed after 60 days of treatment respectively at doses of 200 mg/kg of bw to 400 mg/kg of bw, when compared to the controls, indicate that the extract of *Alchornea cordifolia* behaves as a testosterone agonist by binding to its receptors to mimic its biological activity. These results are also in the same direction as those of Ngaha-Njila *et al.* (2019) and Ajibade and Olayemi (2015). The increase in serum hormone levels after administration of the aqueous extract of *Alchornea cordifolia* could also justify the effects observed

on spermatic function. Therefore, the results obtained indicate that the aqueous extract of *Alchornea cordifolia* at doses of 200 mg/kg of bw and 400 mg/kg of bw causes a significant increase in the concentration in the epididymis and the rate of sperm mobility. In addition, the morphology of the sperm was not affected regardless of the dose of extract administered. Sperm are considered to be mobile cells that provide sensitive parameters to assess the impact of plant extracts on cell function (Gray *et al.*, 2016). Parameters such as sperm count, mobility, and sperm morphology are recognized as the fertility index in males (Woode *et al.*, 2011; Smith *et al.*, 1977). Thus, the extract from *Alchornea cordifolia*, which significantly increases the mobility of sperm, may have positive effects on male fertility. Improving the quality and quantity of spermatozoa is dependent on the quality of spermatogenesis and its transit to the caudal epididymis (Zougrou, 2017). Therefore, the increase in the sperm count in the caudal epididymis observed during this study could be explained by the ability of the extract to interfere with the spermatogenetic process in the seminiferous tubules and with the epididymal function. It may also interfere with the activity of testosterone on hypothalamic releasing factors and the anterior pituitary secretion of gonadotropins. These interferences may result in the improved spermatogenesis observed in rats treated with ETAAC. Hence, these results corroborate with those of Ajibade and Olayemi (2015). Also, some authors have reported that motility was considered to be an important factor in fertilization success and any negative impact of mobility would result in adverse effects on fertilization capacity (Dinithi *et al.*, 2015). In this study, a significant increase in sperm mobility in the treated batches shows the effectiveness of the extract on male fertility.

The morphometric and histological study carried out on the structure of the testis of the treated subjects revealed an increase in the volume of the seminiferous tubes as well as an abundance of sperm in their lumen. These results confirm the high sperm concentration observed in the caudal epididymis of the treated rats. They may also be linked to the increased serum testosterone levels induced by the extract.

Conclusion

In conclusion, the results show that the aqueous extract of *Alchornea cordifolia* could be used as a remedy for male fertility problems. This is justified by the ability to develop androgen-dependent organs, stimulate the production of testosterone, and increase the quality of sperm. This study also revealed the potential of the leaf extract of *Alchornea cordifolia*, which acted positively on the male reproductive system. The improvement in semen quality and observed reproductive performance justify its use in traditional medicine in the treatment of male infertility.

References:

1. Adewunmin, C.O., Agbedahunsi, J.M., Adebajo, C.A., Aladesanmi, A.J., Murphy, N. & Wando, J. (2001). Criblage des plantes médicinales nigériennes pour les propriétés trypanocidales. *J Ethnopharmacol* ; 77(1): 19-24.
2. Agarwal, S.S., Chauhan, S. & Mathur, R. (1986). Antifertility effects of embelin in male rats. *Andrologia*; 2125-131.
3. Ajibade, T.O. & Olayemi, F.O. (2015). Reproductive and toxic effects of methanol extract of *Alchornea cordifolia* leaf in male rats. *Andrologia*; 47(9): 1034–1040.
4. Akassa, H., Nkounkou, G.S.M., Badzi, C.N., Ossibi, A.W.E., H.H. T. & Abena, A. (2019).- Effets de l'extrait aqueux des écorces de tronc de *pausinystalia yohimbe* sur la qualité de la semence et les performances de reproduction chez le rat mâle wistar *Int. J. of Multidisciplinary and Current research*; 7(1): 732-740.
5. Ansah, C., Duwiejua, M., Oppong, E., & Woode, E. (2009). Toxicity study on *Alchornea cordifolia* leaf extract in mice. *Journal of science and technology*; 29(1): 8-16.
6. Ansah, C., Oppong, E., & Woode, E. (2011).- Subacute oral toxicity assessment of *Alchornea cordifolia* (Schumacher and Thonn) Mull Arg (Euphorbiaceae) extract in rats. *Tropical journal of pharmaceutical research*; 10(5): 587-594.
7. Bélanger, B. (1992). Adrenal steroidogenesis in the guinea pig: effects of androgens. *Steroids*; 57(2): 76-81.
8. Clermont, Y. (1972). The cycle of the seminiferous epithelium in man. *Americ. Journ. of Anat.*; 11235.
9. Dinithi, L., Peiris, C., Dhanushka, M.A.T., & Jayathilake, T.A.H.D.G. (2015). Evaluation of aqueous leaf extract of *Cardiospermum halicacabum* (L.) on fertility of male rats. *BioMed Research International*; 11–6.
10. Edouard Akono-Nantia, Paul F. Moundipa, Nathalie Sara E. Beboy, Thomas K. Monsees, & Carreau S. (2007). Etude de l'effet androgénique de l'extrait au méthanol de *Basella alba* L. (Basellaceae) sur la fonction de reproduction du rat mâle. *Andrologie*; 17(2): 129-133.
11. Gray, S.L., Lackey, B.R., & Boone, W.R. (2016). Effects of Panax ginseng, zearalenol, and estradiol on sperm function. *Journal of Ginseng Research*; 40, 251–259.
12. Lejeune, H. (1999). Panorama de l'infertilité masculine. *Andro.*; 99-27.
13. Marzouk, K. (2017). Les kystes de la vésicule séminale. 134.

14. Ngaha-Njila, M.I., Lembè, D.M., Koloko, B.L., Meng, G.Y., Ebrahimi, M., Awad, E.A., Baiee, F.H., Kenmogne, H., Hambe, M., & Mandenguè, S.H. (2019). Sperm parameters quality and reproductive effects of methanolic extract of *Alchornea cordifolia* leaves on senescent male rats. *Andrologia*; 110.
15. Ngoula, F., Watcho, P., Dongmo, M.C., Kenfack, A., Kamtchouing, P., & Chamboué, J. (2007). The Study of the Radiation Protection of Aged Garlic Extract to the Radiation Effects in Male Rat's Sperm *African Health Sces*; 3, 1680-1685.
16. Schlosser, J., Nakib, I., Carré-Pigeon, F., & Staerman, F. (2007). Infertilité masculine : définition et physiopathologie. *Encycl Med Chir*; 186.
17. Smith, K.D., Rodriguez-Rigau, I.J., & Steinberger, E. (1977). Relation between indices of semen analysis and pregnancy rate in infertile couples. *Fertil. Steril.*; 28(12): 1314-1319.
18. Stocco, D.M. (2002). Clinical disorders associated with abnormal cholesterol transport: mutations in the steroidogenic acute regulatory protein *Molecular Cells Endocrinology*; 19, 119-25.
19. Tamboura, H.H. (2006). Activité biologique des extraits aqueux de *Holarrhena floribunda* (G.Don) Durand & Schinz (Apocynaceae) : Etude des effets de type hormone mâle chez le rat Thèse de doctorat: 186.
20. Thakur, M. & Dixit, V.K. (2007). Aphrodisiac activity of *Dactylorhiza hatagirea* (D.Don) Soo in Male Albino Rats. *Evid. Based complement Med.*; 4(1): 29-31.
21. Weinbauer, G.F. & Nieschlag, E. (1998.). Andrology, Male Reproductive Health and Dysfunction. *Biomedicine & Pharmacotherapy*; 52(10): 11-59.
22. Woode, E., Alhassan, A., & Abaidoo, C.S. (2011). Effect of ethanolic fruit extract of *Xylopiya aethiopica* on reproductive function of male rats. *Int. J. Pharm. Biomed. Res.*; 2(3): 161–165.
23. Zougrou, N.E. (2017). Evaluation des effets toxicologiques et pharmacologiques d'un extrait aqueux de *cnestis ferruginea* vahl ex dc. (connaraceae) sur le systeme reproducteur des rats male et femelle. Thèse de Doctorat: 267.