

The time-dependent accumulation of protoporphyrin IX fluorescence in nodular basal cell carcinoma following application of methyl aminolevulinate with an oxygen pressure injection device

E. Blake^{a,*}, S. Campbell^b, J. Allen^a, J. Mathew^c, P. Helliwell^c and A. Curnow^a

^aClinical Photobiology, European Centre for Environment and Human Health, Peninsula Medical School, University of Exeter, Knowledge Spa, Royal Cornwall Hospital, Truro, Cornwall, TR1 3HD, UK.

^bDermatology Department, Royal Cornwall Hospital Treliske, Truro, Cornwall, TR1 3LJ, UK.

^cPathology Department, Royal Cornwall Hospital Treliske, Truro, Cornwall, TR1 3LJ, UK.

* Corresponding author: emma.blake@pms.ac.uk

Telephone: 00 44 (0)1872 256432

Fax: 00 44 (0)1872 256497

Sandra.campbell@rcht.cornwall.nhs.uk

James.allen@pms.ac.uk

Joe.mathew@rcht.cornwall.nhs.uk

Peter.helliwell@rcht.cornwall.nhs.uk

Alison.curnow@pms.ac.uk

Keywords. Photodynamic therapy (PDT), methyl aminolevulinate (MAL), protoporphyrin IX (IX), topical, non-melanoma skin cancer (NMSC)

Abstract

Topical protoporphyrin (PpIX)-induced photodynamic therapy (PDT) relies on the penetration of the prodrug into the skin lesion and subsequent accumulation of the photosensitiser. Methyl aminolevulinate (MAL)-PDT is an established treatment for thinner and superficial non-melanoma skin cancers (NMSC) but for the treatment of the thicker nodular basal cell carcinoma (nBCC) enhanced penetration of the prodrug is required. This study employed a new higher pressure, oxygen pressure injection (OPI) device, at the time of Metvix® application with a view to enhancing the penetration of MAL into the tumors. Each patient had Metvix® applied to a single nBCC followed by application of a higher pressure OPI device. Following different time intervals (0, 30, 60, 120 or 180 minutes) the tumors were excised. The maximum depth and area of MAL penetration achieved in each lesion was measured using PpIX fluorescence microscopy. As expected, an increase in the depth of MAL-induced PpIX accumulation and area of tumor sensitized was observed over time; when the Metvix® cream was applied for 0, 30, 60, 120 and 180 minutes the median depth of PpIX fluorescence was 0, 21, 26.5, 75.5 and 90%, respectively and the median area of tumor sensitized was 0, 4, 6, 19 and 60%, respectively. As the investigation presented here did not include a control arm, the relative depths of fluorescence observed in this study were statistically compared (using the non-parametric Mann Whitney U test) with the results of our previous study where patients had Metvix® cream applied either with or without the standard pressure OPI device. When the higher pressure OPI device was employed compared to without OPI this increase was observed to be greater following 30, 120 & 180 minutes although overall not significantly ($p=0.835$). In addition, no significant difference between the higher pressure OPI device employed here and the previously investigated standard pressure OPI device was observed ($p=0.403$). However, when the results for both OPI

devices were combined and compared to the standard treatment (no OPI employed) group, although the difference did not reach significance ($p=0.531$) a consistent and substantial increase in the depth of PpIX fluorescence was observed, therefore employment of an OPI device during topical MAL-PDT protocols warrants further investigation as a technique for enhancing MAL penetration.

1. Introduction

Basal cell carcinoma (BCC) is by far the most common form of cancer found in Caucasians worldwide [1]. In 2008, of the 98,800 people in the UK (a number which is thought to be underestimated) diagnosed with a non-melanoma skin cancer (NMSC), 45-50% of these were nodular BCC (nBCC) [2]. Although rarely life-threatening if left untreated nBCC can cause bleeding and local destruction resulting in disfiguration. In addition, a very small proportion of these tumors may metastasize into surrounding tissues and bones [2] so it is essential that all cases are treated.

Currently, the established treatments preferably undertaken for the treatment of nBCC are surgical excision and Moh's microscopic surgery. Although effective, these treatment modalities result in scarring. This is particularly undesirable for many nBCC patients with lesions on highly visible sites. In a population-based study it was found, for both genders, that the body-site distribution of nBCC was dominated by the face, followed by the neck [3]. Additionally, a single patient may have multiple nBCCs, and depending on their location some patients may require reconstructive surgery following excision.

Topical PDT offers a non-invasive alternative treatment modality with excellent cosmesis [4]. For the treatment of actinic keratosis (AK), Bowen's disease (BD) and superficial BCC (sBCC) PpIX-induced PDT with 5-aminolaevulinic acid (ALA) or methyl

aminolevulinic acid (ALA) has successful and sustained clearance rates [5]. For the treatment of nBCC however the topical use of ALA/MAL-PDT is limited by the depth of the therapeutic effect the current protocols can achieve as demonstrated by Martin *et al.* in a clinical trial of topical ALA-PDT of BCCs which revealed a highly variable ALA uptake into nodular and infiltrating BCC [6]. Past studies have found low cure rates ranging from 10% to 42% when ALA-PDT was investigated for the treatment of nBCC [9-12]. ALA is a small molecule which when applied topically can diffuse into cutaneous tissue but because it is hydrophilic it has limited capacity to cross tissue barriers such as the hydrophobic stratum corneum of the skin. Therefore the ester derivative, MAL, with greater lipophilicity (provided by the additional alkyl chain), can be utilised as it is expected to cross the stratum corneum more easily than ALA [13]. Past studies by Peng *et al.* have reported that in lesions of up to 2 mm thickness the application of MAL for 3 hours showed the highest ratio of PpIX fluorescence depth to tumor depth [7], in contrast to the more limited penetration with ALA [8]. A review of the use of MAL-PDT for the treatment of nBCC found clearance rates ranging from 75-82% at 3 months to 77% at 60 months [14]. Compared to standard surgical excision in a study of 101 patients with small nBCC lesions the clearance rate at 12 months were not dissimilar between the two treatment groups (surgery; 96% & PDT; 85%). However, follow up data after 5 years recorded recurrence rates to be significantly higher for the MAL-PDT treated lesions (14%) versus those surgically excised (4%). Longer follow-up data is needed to support the use of MAL-PDT for the treatment of nBCC versus surgical excision which has 5-year recurrence rates of less than 10% [15].

Successful PDT treatments require sufficient amounts of the photosensitiser, light of the correct activating wavelength and adequate tissue oxygen. Therefore the first consideration in topical PDT is the optimum depth of prodrug penetration and subsequent photosensitiser production. Methods of penetration enhancement for topical PpIX-PDT

prodrugs have included; the use of chemicals (e.g. DMSO [16] or glycolic acid [17]), iontophoresis [18], lesion surface preparation (e.g. gentle curettage [19] or tape-stripping [20]), elevating skin temperature [21], pressurized oxygen [22], micro-needle puncture [23], nanoemulsions [24] and needleless jet injection [25].

A previous study [22] conducted by our group with a (standard pressure) oxygen pressure injection (OPI) device recruited 6 patients into each of five study groups (0, 30, 60, 120 or 180 minutes Metvix® application) with half the nBCC lesions in each group receiving standard pressure OPI (a metered dosage of oxygen released at 2.0 bar). Results showed that over time, for all patients, an increase in PpIX fluorescence was observed. Notably, when the standard pressure OPI device was employed, PpIX fluorescence was enhanced relative to the standard treatment group which simply had the Metvix® cream applied as per normal practice without an OPI device [22]. Following Metvix® application with the standard pressure OPI device after 30, 60, 120 and 180 minutes the mean relative depth of PpIX fluorescence increased by 25%, 49%, 12% and 16%, respectively compared to the groups where the Metvix® cream was applied without OPI. The study presented here continues this investigation utilizing a newly available, higher pressure (2.2 bar) OPI device (Fig. 1) with a view to further increasing the penetration of MAL into nBCC lesions.

2. Materials and methods

The protocol and procedures conducted in this clinical trial were approved by the UK National Research Ethics Service (NRES). All patients were given verbal and written information regarding the study and all gave their agreement by written informed consent prior to the start of the study procedures. This study was an observer-blinded preliminary investigation of a single topical application of Metvix® cream (Galderma, France),

containing the photosensitizing prodrug MAL (160 mg/g), to nBCC with an OPI device. Fifteen Caucasian patients with a single nBCC lesion requiring treatment by surgical excision were recruited into the study. Three patients were allocated into each of the 5 study groups (0, 30, 60, 120 or 180 minutes Metvix® cream application).

Metvix® cream (1 mm thick) was applied to the nBCC lesion (including a 5 mm margin of surrounding normal skin) and lesions were then subjected to the OPI device. A metered dosage of oxygen was released at 2.2 bar through a hose system and a pressure-reducing valve which exits through a domed shaped nozzle. The latter was specifically designed so that when placed firmly over the lesion minimum oxygen could escape. This higher pressure OPI device (oxygen released at 2.2 bar) and the previously employed standard pressure OPI device (oxygen released at 2.0 bar) both work in exactly the same way except different oxygen pressures are exerted. The OPI machines work by concentrating oxygen from the air and purifying it through a series of filters. Using two molecular sieve chambers the oxygen molecules are separated, resulting in almost pure oxygen which is concentrated up to a maximum of 97% [26]. The amount of pressure exerted is not sufficient to damage skin and is not painful to the patient. The button was pressed six times over each lesion, with the treatment time for each metered application being 0.1 second. This arbitrary figure was chosen in our previous study [22] to try and ensure maximal effect and was therefore used consistently in each case. Once Metvix® cream is applied to the lesion the principle of the OPI device is simply to increase the penetration of the active ingredient MAL through the skin under the action of the pulsed pressure of concentrated oxygen.

2.1. Surgical excision and histology

All lesions were covered firstly with a sterile dressing (Tegaderm®, 3M) and then with a light occlusive dressing (Mepore®). After 0, 30, 60, 120 or 180 minutes Metvix®

application the lesion was removed by elliptical excision by a trained Dermatologist at the Royal Cornwall Hospital, Truro, UK. Tissue samples were immediately transported from the Dermatology Department to the Histopathology Department in black light-occluding bags at room temperature. Occluding the tumor from light was an important precaution to avoid possible photobleaching of any PpIX present. In a darkened room the excised tissue was measured and cut into sections by a trained Pathologist at the Royal Cornwall Hospital, Truro, UK. One section was taken for normal diagnostic histology and the remaining sections were mounted on an appropriate sized cork base with optimal cutting temperature (OCT) mounting fluid (Tissue-Tek®, Zoeterwoude, Netherlands) and snap frozen using chlorodifluoromethane (Cryospray 22, Bright Instruments Co. Ltd., UK). Frozen sections were placed in universal containers and stored in a -80°C freezer until analysis.

2.2. Fluorescence microscopy and image analysis

When all 15 tissue samples had been collected they were removed from storage, coded and prepared for cutting as follows. Each cork embedded tissue was mounted onto a cryostat chuck using OCT mounting fluid. Once equilibrated with the cryostat (OFT5000, Bright Instruments Co. Ltd., UK) operating temperature (~-35°C) 10 µm thick sections were cut from the tissue and put onto microscope slides using the Bright 5040 rotary microtome (housed in the cryostat). All microscope slides were kept in the dark during transport to the fluorescence microscope.

The fluorescence microscope (Olympus BX51, Olympus, UK) consisted of; a light source and excitation filter to excite the PpIX molecule, an emission filter and camera detector (Olympus DP70 CCD, Olympus, UK) to capture the resultant fluorescence and finally a computer with analySIS® imaging software to analyze the images. Appropriate filters were previously selected in preliminary *in vitro* studies, from the absorbance spectra of

0.2 mM pre-synthesized PpIX in DMSO solvent and from the emission spectrum of 10 mM pre-synthesized PpIX in DMSO [27]. The XF1008 (405DF40) excitation filter (Omega Optical Incorporated, Glen Spectra, UK) was used because it corresponds to the ~407 nm Soret absorption band of PpIX and allows the transmission of light between 385 and 425 nm. The XF3028 (630DF30) emission filter (Omega Optical Incorporated, Glen Spectra, UK) was used because it closely matches the excitation peak of PpIX at ~612 nm having a range of 615-645 nm. A dichroic mirror, XF2040 (435DRLP) (Omega Optical Incorporated, Glen Spectra, UK) was also used to direct and reflect the emission and excitation wavelengths of light [27]. The filters were housed in an Olympus filter holder and placed inside the fluorescence microscope.

Neutral density filters were used to reduce the intensity of the excitation light allowing more time to align the sample at a low intensity visible light, prior to capturing the fluorescence image which was achieved by choosing the PpIX filter on the microscope. During image capture all external light sources were removed and lighting levels were kept to a minimum to reduce the effects of photobleaching. Each tissue sample was analyzed at a magnification of x 20 with an exposure time of 10 seconds.

After the fluorescence images were captured, to demonstrate the architecture of the tissue sections each sample was stained using haematoxylin and eosin (H and E). The standard operating procedure to carry out the staining was provided by the Histology Department at the Royal Cornwall Hospital (Truro, UK). Samples were briefly rinsed in 100% alcohol, rinsed in xylene, taken back to alcohol and washed in distilled water. They were then stained in Mayer's haematoxylin (20 seconds), washed in distilled water, stained blue with Scott's tap water substitute, washed in distilled water, rinsed in 1% alcohol, rinsed in 100% alcohol, stained in alcoholic eosin, rinsed and dehydrated in 100% alcohol, cleared with xylene and finally, mounted using Mowiol mounting medium containing 2.5% 1,4-

diazobicyclo-[2.2.2]-octane (DABCO, Sigma-Aldrich, UK) and a glass coverslip. These samples were then imaged by using unfiltered visible light and the automatic settings of the analysis® software control panel (exposure time <1 second).

2.3. Data analysis

All the images were exported and analyzed in NIH ImageJ software (<http://rsb.info.nih.gov/ij/>). For each fluorescence image a precise distance of the maximal depth of fluorescence, perpendicular from the surface epithelium was measured. The corresponding H and E slides were all shown independently to a single histological expert (blinded to the treatment group) at Royal Cornwall Hospital, Truro, UK to advise on the tissue architecture for each section and to confirm the maximal tumor depth. Precise distances of the maximal tumor depth for each tissue sample were then measured. The maximal depth of fluorescence and corresponding maximal tumor depth measurements were used to calculate a percentage of depth of PpIX penetration. In addition, for each fluorescence image a measurement of the area of fluorescence was recorded and the area of tumor present, as observed from the corresponding H and E slide, was also recorded, thus allowing a percentage of PpIX accumulation in relation to the tumor size to be calculated for each tissue sample.

Due to the small sample size (n=3) at each intervention these data are presented as medians. Least squares linear regression analysis was utilized to analyze the data obtained from the depth and area of fluorescence measurements (which were all background subtracted). To compare the relative depth of fluorescence between groups; the higher pressure OPI device, the standard pressure OPI device [22], the standard treatment group (where no OPI device employed to apply the Metvix® cream) [22] and the combined OPI measurements, these data were analyzed using the non-parametric Mann Whitney U test.

Combined OPI measurements were subsequently employed to increase the numbers of data points for statistical comparison.

3. Results

3.1. Fluorescence microscopy

All 15 tissue samples were analyzed and their data are included as a whole in Table 1, however for brevity, not all samples are illustrated in Figure 2. Fig. 2a-e therefore presents typical fluorescence micrographs (and the corresponding H and E images) of nBCC tissue sections excised at 0, 30, 60, 120 or 180 minutes respectively after the application of Metvix® and the OPI device. For each fluorescence image the arrow indicates the depth of maximum fluorescence observed from the surface of the tumor and for each H and E stained image the arrow indicates the maximal tumor depth from its surface.

Fig. 2a shows a typical nBCC lesion without Metvix® application (control) and demonstrates no visible PpIX fluorescence. This can be attributed to the fact that without exogenous administration of MAL, no detectable levels of endogenous PpIX accumulated within cells of either the tumor or the surrounding normal tissue. Fig. 2b-e show the distribution of MAL-induced PpIX fluorescence in nBCC lesions 30, 60, 120 or 180 minutes respectively after application of Metvix® with the OPI device. In each case, fluorescence can be observed in the epidermis overlying the tumor as well as in at least some of the tumor cells. Notable fluorescence was observed 180 minutes following Metvix® application with OPI (Fig. 2e), which is the length of the standard drug-light interval employed in dermatological MAL-PDT [28]. However at this time point the fluorescence observed still failed to achieve full thickness penetration of the tumors to be treated, highlighting the

difficulties experienced clinically when trying to treat these thicker NMSC with the current topical PDT regime.

3.2. Depth and area of PpIX distribution

For each tissue sample, without knowing the treatment group the maximum depth of fluorescence observed was measured as well as the corresponding maximum tumor depth of the H and E section. Table 1 shows the maximum depth of each nBCC analyzed and a median value for each time group. The range of depth of the lesions investigated varied greatly (470.3 to 2011.8 μm) demonstrating a high interpatient variability. The range of depth of PpIX penetration varied from 0 to 1150.8 μm and the median values for each group increased over time; when the Metvix® cream was applied for 0, 30, 60, 120 and 180 minutes the median depth of PpIX fluorescence was 0, 150.5, 303.8, 741.8 and 1016.7 μm , respectively. One example of the variation between patients occurred most markedly in patient 12 (Metvix® for 2 hours), in which the depth of PpIX fluorescence exceeded that of the nBCC depth measured. This only occurred in patient 12 and was due to the detection of PpIX fluorescence within a sebaceous gland which can act as a route of PpIX penetration.

A percentage of depth of PpIX penetration was then calculated (Fig. 3) to try and minimize the effect of the heterogeneous nature of nBCC tumors. In addition, the total area of fluorescence and the total area of tumor were measured and a percentage of PpIX accumulation in relation to the tumor size calculated (Fig. 4). Fig. 3 demonstrates that as expected there is a strong correlation between relative depth of fluorescence observed in the tumors and Metvix® application time ($R^2 = 0.962$). The same trend was observed when the relative area of fluorescence was examined (Fig. 4), with a strong correlation between relative area of fluorescence observed in the tumors and Metvix® application time was also being detected ($R^2 = 0.824$). In this study fluorescence of the full tumor thickness and

fluorescence of the full tumor area of these nBCC lesions was not always reached suggesting more than one treatment cycle would be required to effectively treat these thicker tumours.

Comparison of the results presented here with those published previously [20] revealed the same trends (Fig. 5), however the differences observed between the new higher pressure OPI device and the previously published standard treatment (no OPI) data [20] were not as large as those previously observed with the standard OPI device. No statistically significant difference was observed between the findings observed with the two devices employed ($p=0.403$). However, combining all the OPI results together (Fig. 5.) did reveal a consistent and substantial increase in the depth of PpIX fluorescence observed, although the difference between the combined OPI results and the standard treatment (no OPI employed) group did not reach significance ($p=0.531$) in this small sample size.

4. Discussion

Topical PDT for nBCC is yet to become an established treatment modality. Ongoing research continues to investigate whether modifications to the standard PpIX-induced PDT protocol can be made to increase efficacy. For example, the use of ALA esters with lower lipophilicity such as MAL and HAL, employment of penetration enhancers such as DMSO [29], iron chelation [30], micro-needle arrays [23], an oxygen pressure injection (OPI) device [22], altering light dosimetry parameters [31], modifying oxygen levels [32] and ablative fractional laser resurfacing (AFXL) [33].

Previous work has reported the use of a standard pressure oxygen pressure injection (OPI) (*Oxy-jet*®) device in an observer-blinded pilot study of a single application of Metvix® to nBCC, with or without the use of OPI. At different time intervals (0-180 minutes) the tumors were excised and depth of penetration of MAL was measured using fluorescence

microscopy to detect the production of PpIX. The results suggested two things, firstly using the OPI device may reduce the time required between cream application and light treatment and secondly by using OPI the prodrug MAL may penetrate deeper into thicker tumors [22]. In this study, employing a more powerful higher pressure machine, increasing the penetration of MAL was the ultimate goal. Once again a definite trend of increased relative depth of MAL-induced PpIX with increased application time was observed, and this appeared to be slightly enhanced compared to the relative depths of MAL-induced PpIX recorded in the previous study when no OPI device was employed. However, when comparing the two different OPI devices, no significant difference in MAL-induced PpIX penetration was observed ($p=0.403$), with the small sample size employed. This suggests either device could be incorporated into MAL-PDT protocols to deliver the same beneficial effects of increased MAL penetration. However at the licensed MAL-PDT protocol drug-light interval of 180 minutes full tumor thickness fluorescence was not observed in all cases. This indicates that it is likely that, if maximal efficacy is desired, the drug-light interval cannot be reduced and more than one treatment cycle is required to treat these nodular tumors. The application of OPI after Metvix® application however is a simple and fast treatment modification, with the disposable and autoclavable nozzle dome being large enough to treat the majority of single nBCC lesions recruited for PpIX-induced PDT whilst still remaining small enough to be easy to position over the majority of lesions.

Noteworthy as a limitation of this study was that despite being blinded to the study group identifications during the analysis, only a single user analysed the tissue slices. Furthermore, thirteen patients are represented in each scatter diagram (Fig. 3 and Fig. 4) not 15, as originally recruited into each group, as the tissue section available for analysis from patient 8 was folded on the slide and difficult to interpret and the tissue section from patient 11 was accidentally photobleached prior to analysis. Finally, as this study investigated a

small number of patients in each group, minimal statistical analysis was conducted. To get a better understanding of the results and to inform the development of a future clinical trial more data is needed by sampling a greater number of patients.

In another recent study investigating PpIX fluorescence enhancement [34] the skin of 14 healthy volunteers was pre-treated with micro-needles prior to the application of 2%, 8% and 16% MAL for 4 hours. The results from this study are promising – following incubation the use of micro-needles increased PpIX fluorescence with 2% and 8% MAL but not with 16%.

The results presented here and the previous study with the OPI device [22], although limited, are encouraging. The simple technique of employing pressurized oxygen may be a useful modification to the standard topical MAL-PDT protocol. No discomfort was felt by any patient upon application of the OPI device and no adverse affects from the trial were reported. Future studies should consider the efficacy of treatment of nBCC with the use of an OPI device at time of Metvix® application followed by the standard PDT procedure (a three hour time lapse prior to light activation with visible red light (635 nm)) with clinical outcome assessments made at follow-up appointments of at least 3, 6, 12 and 24 months. Furthermore, the licensed MAL-PDT treatment for superficial BCC and Bowen's disease requires two treatment cycles. These lesion types may therefore also benefit from the use of an OPI device to enhance penetration of MAL if a single treatment cycle would be preferable and so future OPI studies could also consider the best protocol for these lesion types.

5. References

[1] A. Arits, M.H.J. Schlangen, P.J. Nelemans, N.W.J. Kelleners-Smeets, Trends in the incidence of basal cell carcinoma by histopathological subtype, *JEADV*, 25 (2011) 565-569.

- [2] Cancer Research UK website, Non-melanoma skin cancer, <http://info.cancerresearchuk.org/cancerstats/types/skin/incidence/#Non-melanoma>, accessed 6th June (2011).
- [3] B.A. Raasch, P.G. Buettner, C. Garbe, Basal cell carcinoma: histological classification and body-site distribution, *Brit J Dermatol*, 155 (2006) 401-407.
- [4] L.E. Rhodes, M. de Rie, Y. Enstrom, R. Groves, T. Morken, V. Goulden, G.A. Wong, J.J. Grob, S. Varma, P. Wolf, Photodynamic therapy using topical methyl aminolevulinate vs surgery for nodular basal cell carcinoma: results of a multicenter randomized prospective trial, *Arch Dermatol Res*, 140 (2004) 17-23.
- [5] C.A. Morton, Topical photodynamic therapy in dermatology, *S Afr Med J*, 91 (2001) 634-637.
- [6] A. Martin, W.D. Tope, J.M. Grevelink, J.C. Starr, J.L. Fewkes, T.J. Flotte, T.F. Deutsch, R.R. Anderson, Lack of selectivity of protoporphyrin IX fluorescence for basal cell carcinoma after topical application of 5-aminolevulinic acid: implications for photodynamic treatment, *Arch Dermatol Res*, 287 (1995) 665-674.
- [7] Q. Peng, A.M. Soler, T. Warloe, J.M. Nesland, K.E. Giercksky, Selective distribution of porphyrins in skin thick basal cell carcinoma after topical application of methyl 5-aminolevulinate, *J Photochem Photobiol B*, 62 (2001) 140-145.
- [8] Q. Peng, T. Warloe, J. Moan, H. Heyerdahl, H.B. Steen, J.M. Nesland, K.E. Giercksky, Distribution of 5-aminolevulinic acid-induced porphyrins in noduloulcerative basal cell carcinoma, *Photochem Photobiol*, 62 (1995) 906-913.
- [9] P. Wolf, E. Rieger, H. Kerl, Topical photodynamic therapy with endogenous porphyrins after application of 5-aminolevulinic acid. An alternative treatment modality for solar keratoses, superficial squamous cell carcinomas, and basal cell carcinomas?, *J Am Acad Dermatol*, 28 (1993) 17-21.

- [10] S. Fijan, H. Honigsmann, B. Ortel, Photodynamic therapy of epithelial skin tumors using delta-aminolaevulinic acid and desferrioxamine, *Brit J Dermatol*, 133 (1995) 282-288.
- [11] A.M. Wennberg, L.E. Lindholm, M. Alpsten, O. Larko, Treatment of superficial basal cell carcinomas using topically applied delta-aminolaevulinic acid and a filtered xenon lamp, *Arch Dermatol Res*, 288 (1996) 561-564.
- [12] I. Wang, B. Bauer, S. Andersson-Engels, S. Svanberg, K. Svanberg, Photodynamic therapy utilising topical delta-aminolevulinic acid in non-melanoma skin malignancies of the eyelid and the periocular skin, *Acta ophthalmologica Scandinavica*, 77 (1999) 182-188.
- [13] F.S. De Rosa, A.C. Tedesco, R.F. Lopez, M.B. Pierre, N. Lange, J.M. Marchetti, J.C. Rotta, M.V. Bentley, In vitro skin permeation and retention of 5-aminolevulinic acid ester derivatives for photodynamic therapy, *J Control Release*, 89 (2003) 261-269.
- [14] P. Lehmann, Methyl aminolaevulinate-photodynamic therapy: a review of clinical trials in the treatment of actinic keratoses and nonmelanoma skin cancer, *Brit J Dermatol*, 156 (2007) 793-801.
- [15] R.I. Ceilley, J.Q. Del Rosso, Current modalities and new advances in the treatment of basal cell carcinoma, *Int J Dermatol*, 45 (2006) 489-498.
- [16] A.M. Soler, T. Warloe, J. Tausjo, A. Berner, Photodynamic therapy by topical aminolevulinic acid, dimethylsulphoxide and curettage in nodular basal cell carcinoma: a one-year follow-up study, *Acta Derm Venereol*, 79 (1999) 204-206.
- [17] P. Ziolkowski, B.J. Osiecka, G. Oremek, M. Siewinski, K. Symonowicz, Y. Saleh, A. Bronowicz, Enhancement of photodynamic therapy by use of aminolevulinic acid/glycolic acid drug mixture, *J Exp Ther Oncol*, 4 (2004) 121-129.
- [18] L.E. Rhodes, M.M. Tsoukas, R.R. Anderson, N. Kollias, Iontophoretic delivery of ALA provides a quantitative model for ALA pharmacokinetics and PpIX phototoxicity in human skin, *J Invest Dermatol*, 108 (1997) 87-91.

- [19] A.M. Soler, T. Warloe, A. Berner, K.E. Giercksky, A follow-up study of recurrence and cosmesis in completely responding superficial and nodular basal cell carcinomas treated with methyl 5-aminolaevulinate-based photodynamic therapy alone and with prior curettage, *Brit J Dermatol*, 145 (2001) 467-471.
- [20] B.A. Goff, R. Bachor, N. Kollias, T. Hasan, Effects of photodynamic therapy with topical application of 5-aminolevulinic acid on normal skin of hairless guinea pigs, *J Photochem Photobiol B*, 15 (1992) 239-251.
- [21] J.T. van den Akker, K. Boot, D.I. Vernon, S.B. Brown, L. Groenendijk, G.C. van Rhoon, H.J. Sterenborg, Effect of elevating the skin temperature during topical ALA application on in vitro ALA penetration through mouse skin and in vivo PpIX production in human skin, *Photochem Photobiol Sci*, 3 (2004) 263-267.
- [22] S.M. Campbell, A. Pye, S. Horton, J. Matthew, P. Helliwell, A. Curnow, A clinical investigation to determine the effect of pressure injection on the penetration of topical methyl aminolevulinate into nodular basal cell carcinoma of the skin, *J Environ Pathol Toxicol Oncol*, 26 (2007) 295-303.
- [23] R.F. Donnelly, D.I. Morrow, P.A. McCarron, A.D. Woolfson, A. Morrissey, P. Juzenas, A. Juzeniene, V. Iani, H.O. McCarthy, J. Moan, Microneedle-mediated intradermal delivery of 5-aminolevulinic acid: potential for enhanced topical photodynamic therapy, *J Control Release*, 129 (2008) 154-162.
- [24] L.W. Zhang, S.A. Al-Suwayeh, C.F. Hung, C.C. Chen, J.Y. Fang, Oil components modulate the skin delivery of 5-aminolevulinic acid and its ester prodrug from oil-in-water and water-in-oil nanoemulsions, *Int J Nanomedicine*, 6 (2011) 693-704.
- [25] D. Barolet, A. Boucher, No-needle jet intradermal aminolevulinic Acid photodynamic therapy for recurrent nodular Basal cell carcinoma of the nose: a case report, *J Skin Cancer*, (2011) 1-5.

- [26] OXYjet, OXYjet Leo machine technology, <http://www.oxyjetuk.co.uk/>, accessed 29th May (2011).
- [27] A.J. Pye, Enhancement of protoporphyrin IX induced photodynamic therapy using iron chelation, in: *Clinical Photobiology*, Peninsula Medical School, 2006, pp. 278-309.
- [28] P. Juzenas, S. Sharfaei, J. Moan, R. Bissonnette, Protoporphyrin IX fluorescence kinetics in UV-induced tumors and normal skin of hairless mice after topical application of 5-aminolevulinic acid methyl ester, *J Photochem Photobiol B*, 67 (2002) 11-17.
- [29] E. Christensen, E. Skogvoll, T. Viset, T. Warloe and S. Sundstrom, Photodynamic therapy with 5-aminolaevulinic acid, dimethylsulfoxide and curettage in basal cell carcinoma: a 6-year clinical and histological follow-up. *J Eur Acad Dermatol Venereol*, 2008.
- [30] O. Bech, D. Phillips, J. Moan and A. J. MacRobert, A hydroxypyridinone (CP94) enhances protoporphyrin IX formation in 5-aminolaevulinic acid treated cells. *J Photochem Photobiol B*, 41 (1997) 136-144.
- [31] D. J. Robinson, H. S. de Bruijn, N. van der Veen, M. R. Stringer, S. B. Brown and W. M. Star, Fluorescence photobleaching of ALA-induced protoporphyrin IX during photodynamic therapy of normal hairless mouse skin: the effect of light dose and irradiance and the resulting biological effect. *Photochem Photobiol*, 67 (1998) 140-149.
- [32] A. Curnow, J.C. Haller, S.G. Bown, Oxygen monitoring during 5-aminolaevulinic acid induced photodynamic therapy in normal rat colon. Comparison of continuous and fractionated light regimes, *J Photochem Photobiol B*, 58 (2000) 149-55.
- [33] K. Togsverd-Bo, C.S. Haak, D. Thaysen-Petersen, H.C. Wulf, R.R. Anderson, M. Haedesdal, Intensified photodynamic therapy of actinic keratoses with fractional CO₂ laser: a randomized clinical trial, *Brit J Dermatol*, 166 (2012) 1262-1269.
- [34] P. Mikolajewska, R.F. Donnelly, M.J. Garland, D.I. Morrow, T.R. Singh, V. Iani, J. Moan, A. Juzeniene, Microneedle pre-treatment of human skin improves 5-aminolevulinic

acid (ALA)- and 5-aminolevulinic acid methyl ester (MAL)-induced PpIX production for topical photodynamic therapy without increase in pain or erythema, *Pharm Res*, 27 (2010) 2213-2220.

Table 1. Maximum depth of each nBCC tumor investigated including the median depths following Metvix® application with the higher pressure OPI device after 0, 30, 60, 120 and 180 minutes.

Fig.1. Photograph of (a) the OPI device (OXY-jet LEO, Nora Bode, Germany) and (b) the OXY-jet applicator with the detachable domed nozzle on the end.

Fig.2. Images of representative nBCC lesions and corresponding haematoxylin and eosin sections excised after (a) 0 minutes, (b) 30 minutes, (c) 60 minutes, (d) 120 minutes and (e) 180 minutes of Metvix® applied with the higher pressure OPI device.

Fig.3. Scatter graph representing the median maximum depth of fluorescence over time for each nBCC tumor analyzed (up to 3 hours) (n=13).

Fig.4. Scatter graph representing the median relative area of fluorescence over time for each nBCC tumor analyzed (up to 3 hours) (n=13).

Fig.5. Bar chart representing the median relative depth of fluorescence over time (up to 3 hours) for Metvix® applied; without an OPI device (standard treatment group), with the standard pressure OPI device, with the higher pressure OPI device and the combined results observed with Metvix® applied with either the standard or higher pressure OPI device.

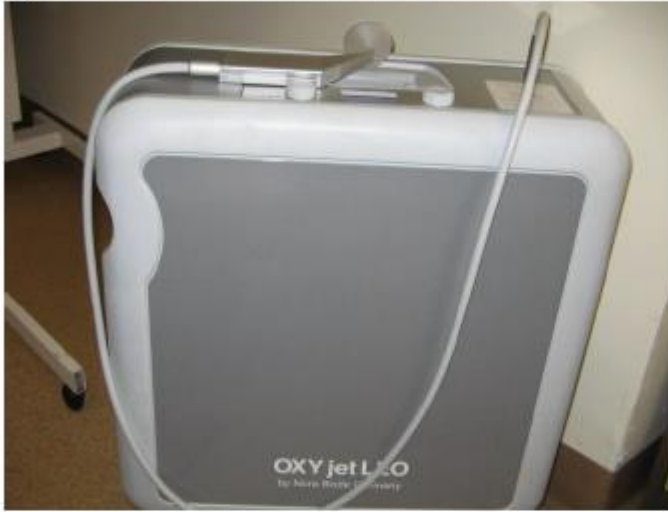MAL application time (minutes)	Maximum depth of each nBCC (μm)			Group median (μm)
0	595.8	202.3	1204.0	595.8
30	507.0	470.3	1000.5	507.0
60	1144.1	*	1235.0	1189.5
120	2011.8	^	857.1	1434.4
180	1127.8	1129.2	855.8	1127.8

* tissue section on slide was folded and difficult to interpret

^ slide was accidentally photobleached prior to analysis

Table 1.

(a)



(b)



Fig.1.

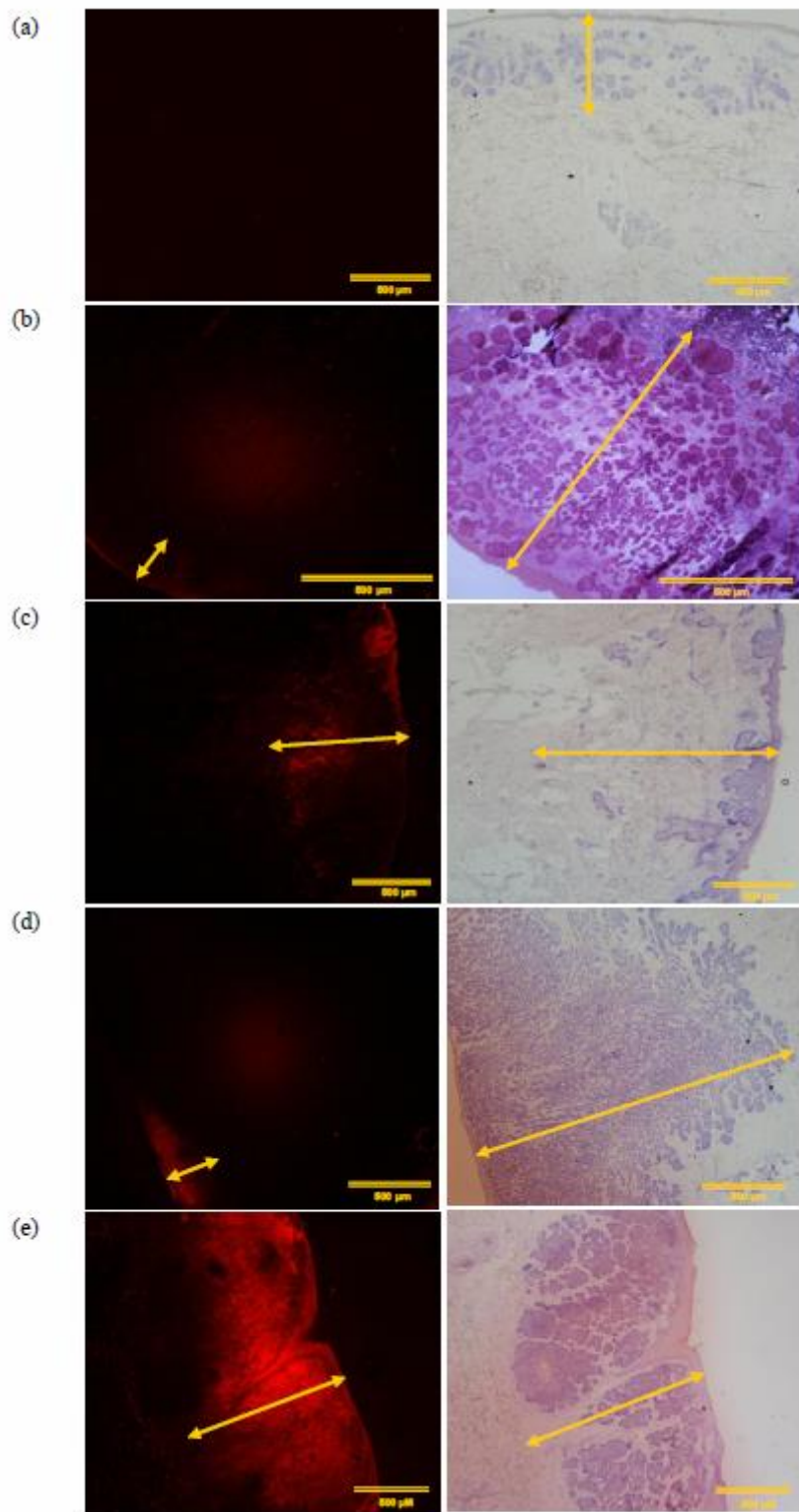


Fig.2.

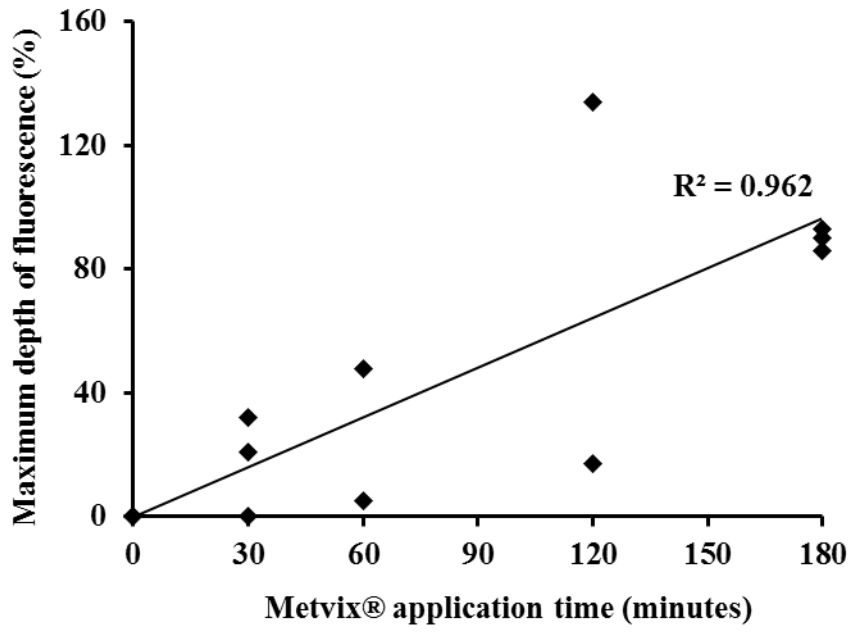


Fig.3.

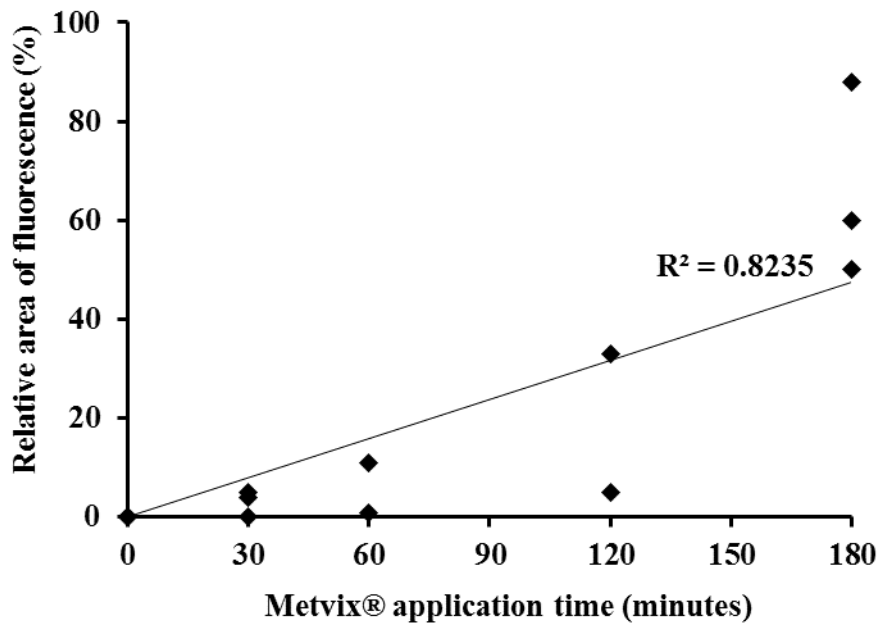


Fig.4.

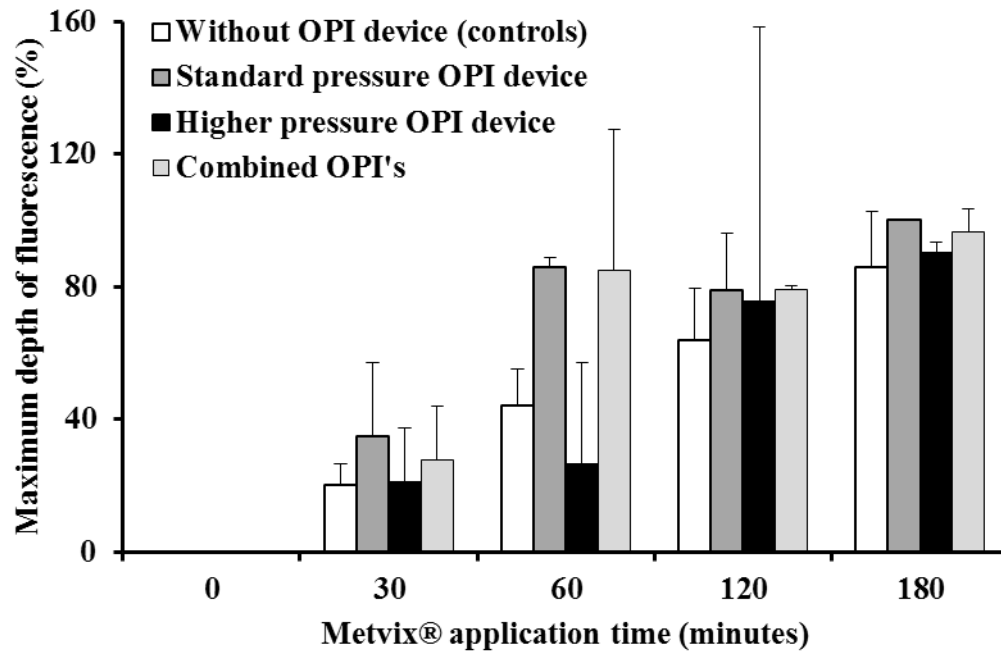


Fig.5.