

Marquette University

e-Publications@Marquette

Library Faculty Research and Publications

Library (Raynor Memorial Libraries)

12-2020

Quantitative Assessment of Root Development after Regenerative Endodontic Therapy: A Systematic Review and Meta-Analysis

Teng Kai Ong
Marquette University

Ghee Seong Lim
University of Malaya

Maharaj Singh
Marquette University, maharaj.singh@marquette.edu

Alissa Fial
Marquette University, alissa.fial@marquette.edu

Follow this and additional works at: https://epublications.marquette.edu/lib_fac

Recommended Citation

Ong, Teng Kai; Lim, Ghee Seong; Singh, Maharaj; and Fial, Alissa, "Quantitative Assessment of Root Development after Regenerative Endodontic Therapy: A Systematic Review and Meta-Analysis" (2020). *Library Faculty Research and Publications*. 112.
https://epublications.marquette.edu/lib_fac/112

Marquette University

e-Publications@Marquette

Raynor Memorial Libraries Faculty Research and Publications/Raynor Memorial Libraries

This paper is NOT THE PUBLISHED VERSION.

Access the published version via the link in the citation below.

Journal of Endodontics, Vol. 46, No. 12 (December 2020): 1856-1866.e2. [DOI](#). This article is © Elsevier and permission has been granted for this version to appear in [e-Publications@Marquette](#). Elsevier does not grant permission for this article to be further copied/distributed or hosted elsewhere without the express permission from Elsevier.

Quantitative Assessment of Root Development after Regenerative Endodontic Therapy: A Systematic Review and Meta-Analysis

Teng Kai Ong

Department of Surgical Sciences, Division of Endodontics, Marquette University School of Dentistry, Milwaukee, Wisconsin

Ghee Seong Lim

Department of Restorative Dentistry, Faculty of Dentistry, University of Malaya, Kuala Lumpur, Malaysia

Maharaj Singh

Biostatistics–Research and Graduate Studies, Marquette University School of Dentistry, Milwaukee, Wisconsin

Alissa V. Fial

Marquette University Raynor Memorial Libraries, Milwaukee, Wisconsin

Abstract

Introduction

The purposes of this review were to appraise the level of evidence of the existing regenerative endodontic therapy (RET) publications, perform a meta-analysis on the survival and healing rates of necrotic immature permanent teeth treated with RET, and run a meta-analysis on the quantitative assessment of the root development of those teeth.

Methods

Electronic searches were performed in Web of Science, PubMed, CINAHL (Cumulative Index to Nursing and Allied Health Literature), and Cochrane Library databases. Two authors independently screened the titles and abstracts for eligibility. The analyses were performed on the clinical outcomes (ie, survival, healing, and root development) of the procedure.

Results

Eleven articles were included in the qualitative and quantitative syntheses. Three studies were randomized controlled trials, 6 were prospective cohort studies, and 2 were retrospective cohort studies. The pooled survival and healing rates were 97.3% and 93.0%, respectively. The pooled rates of root lengthening, root thickening, and apical closure were 77.3%, 90.6%, and 79.1%, respectively. However, if 20% radiographic changes were used as a cutoff point, there were only 16.1% root lengthening and 39.8% root thickening.

Conclusions

Within the limitations of the present study, it can be concluded that RET yielded high survival and healing rates with a good root development rate. However, clinical meaningful root development after RET was unpredictable.

Key Words

Meta-analysis, pulp revascularization, regenerative endodontic therapy, root development, systematic review

Significance

Regenerative endodontic therapy on necrotic immature permanent teeth was shown to have high survival and healing rates with a good root development rate. However, the existing literature failed to show predictable clinical meaningful root development after regenerative endodontic therapy.

In the health care field, it is crucial for clinicians to set an achievable treatment goal or goals when a treatment plan is proposed to patients. For instance, the goals of endodontic treatment are to treat and to prevent apical periodontitis¹. Therefore, in the event of healing or absence of apical periodontitis, the treatment is considered successful^{2,3}.

However, the management of necrotic mature and immature teeth could be different. The immature tooth often exhibits a wide open apex with no apical stop and thus complicates the root filling. Also, the immature tooth could present with a short root with a compromised crown-to-root ratio at times.

On top of that, the root dentin of an immature tooth could be rather thin; this is especially concerning at the cervical region because this region is predisposed to catastrophic horizontal root fracture⁴. Apexification using mineral trioxide aggregate as an apical plug (MAP) is 1 of the treatment options in treating necrotic immature teeth that showed high survival and success rates⁵. Nonetheless, MAP in an immature tooth would not encourage the thickening and lengthening of the root, and, certainly, the tooth would remain nonvital. With the advent of regenerative endodontic therapy (RET), this treatment approach could potentially address the drawbacks that is presented in MAP. The American Association of Endodontists described root development as a desirable but nonessential secondary goal of RET⁶. Therefore, it would be interesting to know the predictability of this desirable goal after RET.

In the past decade, RET in necrotic immature teeth has received much attention, and many articles related to RET have been published⁷. However, there is a lack of standardization of the treatment protocol between studies; therefore, it is hard to make a direct comparison of the treatment outcome from those studies⁸. Additionally, many studies adopted different outcome assessments, with distinct parameters for the success of RET. These problems could easily translate into a false presentation of the data on RET, thus confusing clinicians.

Three previously published systematic reviews assessed the outcome of RET^{5,9,10}. These systematic reviews included both qualitative and quantitative measurements of continued root development after RET^{5,9,10}. However, there could be an interpretation bias if qualitative or visual assessment is used to determine root development. Tong et al¹⁰ included only the quantitative measurement of root development after RET in a meta-analysis. However, they only performed the meta-analysis on the studies comparing the outcome with similar exposure and thus omitted many other studies with valuable findings. Therefore, the purposes of this review were as follows:

1. Critically appraise the quality of evidence of the existing RET publications
2. Perform a meta-analysis of the survival and healing rates of necrotic immature permanent teeth treated with RET
3. Run a meta-analysis on the quantitative assessment of the root development of necrotic immature permanent teeth treated with RET

Methods

Inclusion Criteria

In the present study, any procedure that attempted to revascularize or regenerate a necrotic immature permanent human tooth with the intention to induce root development was included as RET regardless of the methods of disinfection and the types of scaffolds used. Root development including root lengthening, root thickening, and/or apical closure was discussed separately and measured quantitatively.

Exclusion Criteria

The criteria for excluding studies were as follows:

1. Nonhuman studies
2. Abstract and title do not meet the inclusion criteria

3. Review articles
4. Descriptive case report or case series
5. Non-English studies
6. Study included primary teeth or mature permanent teeth
7. Full article not found

The clinical exclusion criteria were the following:

1. Pulpal diagnosis other than pulp necrosis
2. Follow-up less than 12 months
3. An orifice barrier other than calcium silicate–based material was used
4. Visual comparison or assessment on root development
5. Root development for each sample was not mentioned or not quantifiable
6. Root lengthening, thickening, and apical closure were discussed or measured as a whole in root development

Search Strategy and Outcome Measures

With the assistance of a medical librarian, literature searches were conducted in the following electronic databases: PubMed/MEDLINE, CINAHL (Cumulative Index to Nursing and Allied Health Literature), Cochrane Clinical Trials, and Web of Science. The parameters included an initial focus on regenerative endodontics in teeth, both immature and permanent, and pulp necrosis. Special attention was focused on determining the terminology that concentrated on procedures and therapies for regenerative endodontics. Additionally, terminology specific to necrosis, apical abscess, and pathology were included. The initial search was conducted in December 2019. For a complete list of the literature search strategies, see Appendix 1.

The results were limited to the English language only. The publication date range was selected as 1990–2019. There was no limit on the type of publication. The search strategy was first established in PubMed/MEDLINE using a combination of Medical Subject Headings (MeSH) (database controlled vocabulary) and key words. The MeSH headings were searched along with the key words. Specific MeSH terminology included regenerative endodontics, periapical abscess, periapical periodontitis, and dental pulp necrosis. From there, the other database search strategies were developed, and searches were conducted. With each database search, the database's controlled vocabulary was searched in combination with key words. The search yielded 3088 publications, with 2608 reviewed after duplicates were removed. Eleven publications were included in this meta-analysis. The Preferred Reporting Items for Systematic Reviews and Meta-Analyses flowchart summarizing the systematic review process is provided in Figure 1.

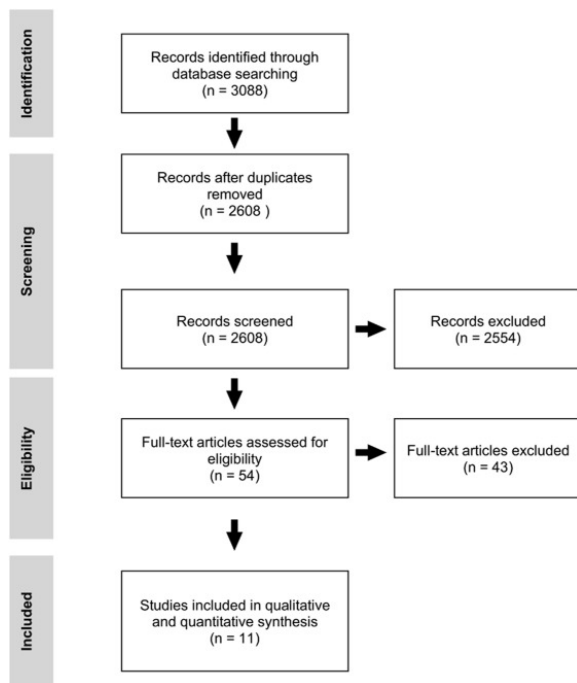


Figure 1. The Preferred Reporting Items for Systematic Reviews and Meta-Analyses flow diagram.

Quality Analysis and Level of Evidence

All of the articles were assessed by 2 reviewers (T.K.O. and G.S.L.) independently. The Newcastle-Ottawa Scale was used to assess the quality of the observational studies (cohort studies), and the Cochrane risk of bias tool was used to assess the quality of randomized controlled trial and uncontrolled prospective trial studies. The Scottish Intercollegiate Guidelines Network Grading System was used to grade the level of evidence (LOE) for the articles included in this study. In the event of a disagreement, consensus was reached by discussion.

Clinical Outcomes

Survival was defined as the tooth being retained after the treatment at follow-up. Healing was defined as the absence of clinical symptoms with resolution of the periapical radiolucency. Root lengthening was defined as the increment of the root length. Root thickening was defined as the increment of root thickness. Apical narrowing/closure was defined as narrowing of the apical diameter of the root. The radiographic root area (RRA) was defined as the changes on the total root area. The 20% percent cutoff point on radiographic changes was defined when the measurement of root changes (root lengthening, root thickening, apical narrowing/closure, and RRA) showed more than a 20% positive value. Intracanal calcification was defined as any form of calcification detected in the root canal including calcific barrier formation, partial pulpal obliteration, and total pulpal obliteration.

Statistical Analysis

All percentages were converted into proportions, and statistical analysis was performed using proportions and the total sample in the studies. The effect size of the proportions for all the studies that had complete data was computed. Heterogeneity among studies was computed as I^2 . For all computations, an alpha level of 0.05 was used. In the present study, both the fixed and random effects were computed, but only the random effect was adopted for the interpretation of results. The

statistical analyses and computations were performed using Comprehensive Meta-Analysis Version 3.3.070 (Biostat, Englewood, NJ).

Results

Study Design

In all, 11 studies were included in this study^{11, 12, 13, 14, 15, 16, 17, 18, 19, 20, 21} (Table 1). Of these 11 studies, 3 were randomized controlled trials^{12,15,20}, and the rest were observational studies with 6 prospective cohort studies^{11,13,14,18,19,21} and 2 retrospective cohort studies^{16,17}.

Table 1. The Studies Included in the Systematic Review and Meta-analysis

First author	Year	Sample size	Study design	Age (y)	Male:female ratio	Tooth	Follow-up (mo)	Etiology	NaOCl % (concentration)	Medication	EDTA	Scaffold	Barrier	Permanent restoration
Kahler ¹¹	2014	9	Prospective cohort study	8–12	2:7	A/P	18–36	Trauma, anomalies, unknown	1	Metronidazole, ciprofloxacin, amoxicillin	No	Blood clot	MTA	Glass ionomer restoration
Bezgin ¹²	2015	20	RCT	7–12	11:9	A/P	18	Trauma, caries	2.5	Metronidazole, ciprofloxacin, cefaclor	Yes	PRP/blood clot	MTA	Composite restoration
Chan ¹³	2017	28	Prospective cohort study	9.23 ± 2.36	12:10	A/P/M	30	Trauma, anomalies, caries	5.25	Metronidazole, ciprofloxacin, cefaclor	No	Blood clot (collaplug)	MTA	Composite restoration
Li ¹⁴	2017	20	Prospective cohort study	10.6 ± 0.995	9:11	P	12	Anomalies	2.5	Calcium hydroxide	No	Blood clot	MTA	Composite restoration
Lin ¹⁵	2017	69	RCT	8–16	NS	A/P	12	Trauma, anomalies	1.5	Metronidazole, ciprofloxacin, clindamycin	Yes	Blood clot	MTA	Composite restoration
Peng ¹⁶	2017	28	Retrospective cohort study	10.7 ± 2.2	15:13	A/P	13-63	Trauma, anomalies, caries	5.25	Ciprofloxacin, metronidazole, minocycline	No	Blood clot	MTA	Composite restoration
Silujjai ¹⁷	2017	17	Retrospective cohort study	8–46	7:10	A/P/M	12-93	Trauma, anomalies, caries	1.5–2.5	Ciprofloxacin, metronidazole, minocycline	Yes	Blood clot	MTA	Composite restoration
Nazzal ¹⁸	2018	12	Prospective cohort study	7–10	10:2	A	18–27	Trauma	0.5	Metronidazole, ciprofloxacin	Yes	Blood clot	Portland cement	Composite restoration
EzEldeen ¹⁹	2015	5	Prospective cohort study	8–15	0:5	A/P	19.4 ± 5.4	Trauma, anomalies, autotransplantation	2.5	Metronidazole, ciprofloxacin	Yes	Blood clot	MTA	Composite restoration
Shivashankar ²⁰	2017	54	RCT	6–28	32:28 (6 dropped out)	A	12	Trauma, caries	5.25	Ciprofloxacin, metronidazole, minocycline	No	Blood clot/PRP/PRF	MTA	Not mentioned
Saoud ²¹	2014	20	Prospective cohort study	11.3 ± 1.9	14:6	A	12	Trauma	2.5	Ciprofloxacin, metronidazole, minocycline	No	Blood clot	MTA	Composite restoration

A, anterior; M, molar; MTA, mineral trioxide aggregate; NaOCl, sodium hypochlorite; P, premolar; PRF, protein-rich fibrin; PRP, protein-rich plasma; RCT, randomized controlled trial.

Quality Assessment of Risk of Bias

A high level of bias was evident in 2 randomized controlled trials (LOE = -1), and a low level of bias was evident in 1 randomized controlled trial (LOE = 1). Also, a high level of bias was found in all uncontrolled prospective trials (LOE = 3). Both cohort studies scored 8 of 9 (LOE = 2++) and therefore were considered of high quality. Tables 2 and 3 show the quality assessment of the articles and the risk of bias summary, respectively.

Table 2. The Newcastle-Ottawa Scale for Retrospective Cohort Studies

Study	Peng et al, 2017 ¹⁶	Silujai and Linsuwanont, 2017 ¹⁷
1. Selection		
A. Representativeness of the exposed cohort	+	+
B. Selection of the nonexposed cohort		
C. Ascertainment of exposure	+	+
D. Demonstration that outcome of interest was not present at start of study	+	+
2. Comparability		
A. Comparability of cases and controls/cohorts on the basis of the design or analysis	++	++
3. Outcome		
A. Assessment of outcome	+	+
B. Was follow-up long enough for outcomes to occur	+	+
C. Adequacy of follow-up of cohorts	+	+
Total	8/9	8/9
Sign LOE	2++	2++

+, yes; LOE, level of evidence.

Table 3. The Risk of Bias Summary and Classification of Level of Evidence Outcomes

First author, year	Random sequence generation	Allocation concealment	Blinding of participants and personnel	Blinding of outcome assessment	Incomplete outcome data	Selective reporting	Other potential threats to validity	Other sources of bias	Sign grading
Kahler, 2014 ¹¹	NA	NA	NA	-	+	+	-	-	3
Bezgin, 2015 ¹²	-	-	-	+	+	+	+	-	-1
Chan, 2017 ¹³	NA	NA	NA	-	+	+	+	+	3
Li, 2017 ¹⁴	NA	NA	NA	-	+	+	+	+	3
Lin, 2017 ¹⁵	+	+	-	-	+	+	+	?	-1
Nazzal, 2018 ¹⁸	NA	NA	NA	-	+	+	+	?	3

EzEldeen, 2015 ¹⁹	NA	NA	NA	-	+	+	+	-	3
Shivashankar, 2017 ²⁰	+	+	+	+	+	+	+	?	1
Saoud, 2014 ²¹	NA	NA	NA	?	+	+	+	?	3

-, high risk; ?, unclear risk; +, low risk; NA, not applicable.

Analysis of Outcome Measures

Table 4 summarizes the outcome of the analytic studies, whereas Table 5 summarizes the outcome of the included studies differentiated by their etiologies.

Table 4. The Outcome of Analytic Studies

First author, year	Sample size	Survival	Healing	Root lengthening	Root thickening	Apical narrowing	RRA	Root lengthening (>20%)	Root thickening (>20%)	Apical narrowing (>20%)	RRA (>20%)	Calcific barrier or intracanal calcification
Kahler, 2014 ^{11*}	9	—	—	44.4	88.9	—	—	11.1	55.6	—	—	—
Kahler, 2014 ¹¹	16	100	90.3	—	—	66.6	—	—	—	—	—	—
Bezgin, 2015 ¹²	20	100	95	—	—	65	90	—	—	—	20	40
Chan, 2017 ¹³	28	96.4	92.9	91.7	—	92.9	81.8	0	0	82	0	—
Li, 2017 ¹⁴	20	100	100	100	—	100	100	55	—	100	100	—
Lin, 2017 ¹⁵	69	100	100	81.2	82.6	65.2	—	—	—	—	—	37.7
Peng, 2017 ¹⁶	28	96.4	92.9	—	—	—	—	—	—	—	—	29
Peng, 2017 ^{16*}	24	—	—	79.2	91.7	—	—	29.2	58.3	—	—	—
Silujjai, 2017 ¹⁷	17	100	76.5	58.8	70.6	—	—	11.8	29.4	—	—	23.5
Nazzal, 2018 ¹⁸	12	100	100	58.3	50	75	—	—	—	—	—	—
EzEldeen, 2015 ¹⁹	5	100	100	100	100	100	—	—	—	100	—	100
Shivashankar, 2017 ²⁰	54	100	96.3	74.1	81.5	—	—	—	—	—	—	5.6
Saoud, 2014 ²¹	20	100	100	95	90	100	—	0	45	100	—	25

—, no data available; RRA, radiographic root area.

*Only part of the samples was analyzed as incomplete data provided in the study; - indicates no data available.

Table 5. The Outcomes of Studies Differentiated by Etiologies

Etiology	First author, year	n	Survival	Healing	Root lengthening	Root thickening	Apical narrowing	RRA	Root lengthening (>20%)	Root thickening (>20%)	Apical narrowing (>20%)	RRA (>20%)	Calcific barrier or intracanal calcification
Trauma	Kahler, 2014 ¹¹	5	100	—	60	80	—	—	20	20	—	—	—
	Bezgin, 2015 ¹²	14	100	92.9	—	—	65	85	—	—	—	14.3	—
	Lin, 2017 ¹⁵	21	100	100	42.9	—	61.9	—	—	—	—	—	—
	Silujjai, 2017 ¹⁷	5	100	80	40	60	—	—	0	0	—	—	0
	Nazzal, 2018 ¹⁸	12	100	100	58.3	50	75	—	—	—	—	—	—
	EzEldeen, 2015 ¹⁹	1	100	100	100	100	100	—	—	—	—	100	—
Dental anomalies	Saoud, 2014 ²¹	20	100	100	95	90	100	—	0	45	100	—	25
	Kahler, 2014 ¹¹	2	100	—	50	100	—	—	0	100	—	—	—
	Li, 2017 ¹⁴	20	100	100	100	—	100	100	55	—	100	100	—
	Lin, 2017 ¹⁵	48	100	100	97.9	—	91.7	—	—	—	—	—	—
	Silujjai, 2017 ¹⁷	10	100	70	60	80	—	—	20	40	—	—	30
	EzEldeen, 2015 ¹⁹	3	100	100	100	100	100	—	—	100	—	—	100
Caries	Bezgin, 2015 ¹²	6	100	100	—	—	100	100	—	—	—	33.3	—
	Silujjai, 2017 ¹⁷	2	100	100	100	50	—	—	0	50	—	—	50

—, no data available; RRA, radiographic root area.

Follow-up Period

There was a wide variability in the follow-up period among the studies. The follow-up period ranged from 12–93 months (Table 1).

Survival Rate

The total sample for 11 studies was 289. The point estimate for the rate of tooth survival was 97.32% (95% confidence interval [CI], 94.34%–98.75%; $P < .01$; $I^2 = 0$) (Fig. 2A).

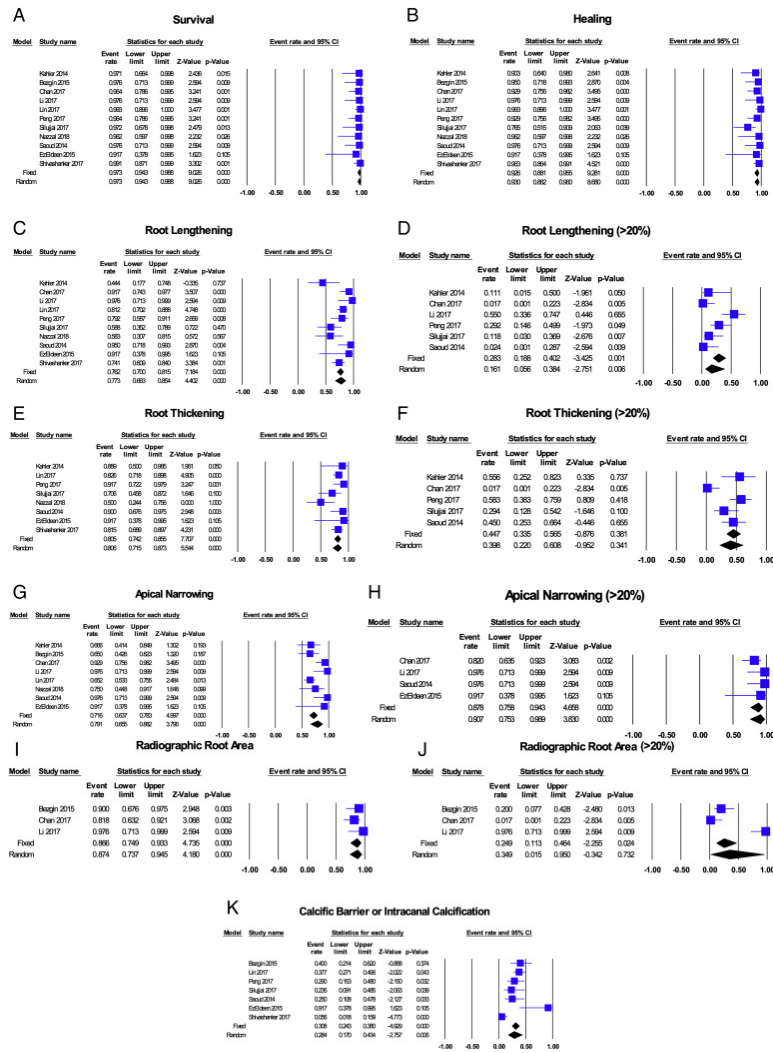


Figure 2. A forest plot for (A) survival rates, (B) healing rates, (C) root lengthening, (D) root lengthening >20%, (E) root thickening, (F) root thickening >20%, (G) apical narrowing, (H) apical narrowing >20%, (I) RRA, (J) RRA >20%, and (K) a calcific barrier or intracanal calcification.

Healing Rate

The healing rate was reported in all of the articles and was evaluated through clinical and radiographic means. The total sample was 289 with a healing rate of 93.0% (95% CI, 88.16%–96.00%; $P < .01$; $I^2 = 0$) (Fig. 2B).

Root Development

Root Lengthening

Root lengthening was reported in 10 of 11 studies, with a total sample of 258; 77.3% (95% CI, 66.34%–85.41%; $P < .01$; $I^2 = 55.72$) (Fig. 2C) of these samples showed root lengthening. Of these 10 studies, 6 studies (with a total sample of 118) showed the data availability on the 20% cutoff point of root lengthening. Only 16.1% (95% CI, 5.59%–38.35%; $P < .01$; $I^2 = 72.42$) (Fig. 2D) of these samples showed more than 20% of root lengthening at follow-up.

Root Thickening

Root thickening was reported in 8 studies, with a total sample of 210; 80.6% (95% CI, 71.53%–87.31%; $P < .01$; $I^2 = 36.30$) (Fig. 2E) of these samples showed root thickening. Of these 8 studies, 5 studies (with a total sample of 98) showed the data availability on the 20% cutoff point of root thickening; 39.8% (95% CI, 21.98%–60.79%; $P = .34$; $I^2 = 63.43$) (Fig. 2F) of these samples showed more than 20% of root thickening at follow-up.

Apical Narrowing or Apical Closure

Apical narrowing was reported in 8 studies, with a total sample of 190; 79.1% (95% CI, 65.53%–88.22%; $P < .01$; $I^2 = 55.31$) (Fig. 2G) of these samples showed apical narrowing. Of these 8 studies, 4 studies (with a total sample of 73) showed the data availability of the 20% cutoff point of apical narrowing; 90.7% (95% CI, 75.26%–96.91%; $P < .01$; $I^2 = 23.12$) (Fig. 2H) of these samples showed more than 20% of apical narrowing at follow-up.

RRA

RRA was only reported in 3 studies, with a total sample of 68; 87.4% (95% CI, 73.71%–94.53%; $P < .01$; $I^2 = 17.13$) (Fig. 2I) of these samples showed the increment of RRA. However, only 34.9% (95% CI, 1.49%–95.02%; $P = .73$; $I^2 = 87.36$) (Fig. 2J) of the samples showed the RRA increment when 20% was used as a cutoff point.

Other Radiographic Findings

Intracanal calcification was reported in 7 of 11 studies, with a total sample of 213. Only 28.4% (95% CI, 17.03%–43.35%; $P < .01$; $I^2 = 69.07$) (Fig. 2K) of these samples showed intracanal calcification.

Discussion

RET has been shown to present with high survival and success rates in a meta-analysis study⁵. However, the pure healing of apical periodontitis according to how it is defined in the aforementioned study does not necessarily mean the true “success” of RET²². Therefore, in the present study, pure resolution of apical periodontitis would be termed *healing* of RET. The present meta-analysis study showed that the survival and healing rates of RET were 97.3% and 93%, respectively. This outcome is similar to the aforementioned meta-analysis study, which exhibited a 97.5% survival rate and a 93.7% success rate in RET⁵.

Root development was frequently interpreted as the presence of root thickening, root lengthening, and apical closure^{5,12,23}. Nevertheless, apical closure or narrowing is a physiological process of root maturation, and it could even be observed in apexification^{15,24, 25, 26, 27}. Its occurrence relies on the

viability of the epithelial root sheath and the presence of vital cells (fibroblast and cementoblast) at the apical region²⁸. Therefore, its sole presentation without evidence of root thickening and lengthening should not be considered as root development nor seen as a “success” of RET. Even in the event of failed RET, continued apical closure could be demonstrated²⁹. Therefore, in the present study, the authors only included studies in which the degrees of root lengthening, root thickening, and apical narrowing after RET were evaluated separately. Apical closure and apical narrowing are the terminologies often used interchangeably even though there are some fundamental differences between the 2. However, the authors were not able to distinguish apical narrowing from apical closure in most of the studies included in this meta-analysis evaluation because the 2 terminologies were used haphazardly. Taking both into consideration, the apical closure or apical narrowing found in this meta-analysis was 79.1%, and this finding is comparable to the meta-analysis study by Tong et al¹⁰.

Many published RET studies used qualitative or visual assessment to determine the presence of root development in the past^{30, 31, 32, 33, 34}, which may engender interpretation bias. Therefore, in this meta-analysis, only the studies with quantitative measurement of root development performed were included. Besides, the different angulation in positioning of the X-ray beam could lead to radiographic image distortions, giving rise to the wrong interpretation of the result. A few studies showed some negative values in root development after RET, and this indicated the inconsistency in radiographic positioning^{11,12,16,21}. Likewise, it is arguable that some positive values in root development after RET could be caused by an error in radiographic positioning. Therefore, it is vital to acknowledge that without standardization in assessing and evaluating root development, bias in the studies cannot be repudiated. However, it is understandable that standardization of radiography is sometimes difficult, especially with young patients. The use of quantitative assessment of root lengthening and thickening should eliminate evaluation bias as much as possible. The present meta-analysis showed more than 75% of root lengthening (77.3%) and root thickening (80.6%) after RET. Nevertheless, there is a drawback of using quantitative assessment of root length or root thickness; any trivial increment of the root length or the root thickness will be reported as positive root development. Even though this has not been scientifically proven, it would be consequential to recognize the practicability of minute radiographic changes and their clinical significance. With this presumption, it would be ambivalent if RET should be advocated or would be beneficial to patients, especially when the other available treatment option such as apexification could provide a similar clinical outcome⁵. Therefore, the root development after RET presented in the published studies without considering the degree of increment could overestimate the outcome and the “benefits” of RET.

Alobaid et al³⁴ suggested that 20% of the radiographic increment of root length and root width is of clinical significance. This 20% threshold is an arbitrary figure, and it has not been tested scientifically. However, the assumption of a 20% threshold of clinical significance could be used to avoid overestimation of the “benefits” of RET, either due to trivial root maturation and/or false interpretation because of the error in radiographic positioning. With this cutoff point, the present meta-analysis showed there were 16.1%, 39.8%, and 90.7% of root lengthening, root thickening, and apical closure/narrowing after RET, respectively. This showed that clinically significant root development (root lengthening or thickening) was not predictable. Studies have shown that age, apical diameter, stage of root development, and follow-up time could influence the degree of root development after RET^{13,14,21,35}. Also, clinical execution of RET would affect the extent of root

development as well. For instance, if the coronal barrier placed over the blood clot is pushed deep into the canal, the amount of root development would be restricted by the canal space availability for regeneration. Thus, all the aforementioned factors should be taken into consideration in RET to demonstrate predictable and clinically significant root development.

RRA was suggested by Flake et al³⁶ to assess the overall root development. Even though there were only 3 studies using this assessment, RRA assessment was included in this meta-analysis because a study showed that the RRA method has high agreement regarding reliability compared with other quantitative measurements of root development after RET³⁷. The present meta-analysis showed that 87.4% of the samples exhibited the increment of RRA, and this figure was found higher than the rate of root lengthening and thickening. Nevertheless, if a 20% radiographic change was used as a cutoff point, only 34.9% of the samples showed an increment of RRA.

Nosrat et al³⁸ published a case report showing root canal treatment performed on 2 teeth that received RET 6 years ago because of restorative and esthetic reasons. However, the canal of both teeth were found empty during the procedure with no vital tissue or bleeding identified even though there was radiographic evidence of apical closure³⁸. It would be interesting to contemplate if the scaffold induced during RET survived in the first place. Previous histologic and radiographic studies showed the formation of a calcific barrier under a mineral trioxide aggregate barrier after vital pulp therapy^{39, 40, 41, 42, 43, 44, 45, 46}. It was used as a sign of success of vital pulp therapy. Therefore, the same should be applied on RET; a calcific barrier or any form of calcification should be noted after RET to signify the presence of vital tissue in the canal. Total or partial pulpal obliteration was reported in a few studies^{12, 15, 16, 17, 20, 21, 47}. Despite being undesirable, total or partial pulpal obliteration were considered as favorable complications. Even though the presence of intracanal calcification was not the main finding or objective in this review, 7 studies mentioned that in their results. Therefore, this presentation was included in this meta-analysis because many were acknowledging its presence and significance in recent years^{29, 47, 48, 49}. Taking all types of calcification formed in the canal into account, this meta-analysis showed 28.4% of intracanal calcification after RET. This figure was much lower than a retrospective study by Song et al⁴⁷ that exhibited 62.1% of RET-associated intracanal calcification. One possible explanation for the lower incidence of intracanal calcification found in this meta-analysis is that the periapical radiograph used in most of the included studies might not have the right resolution to display intracanal calcification. Further studies could consider the use of cone-beam computed tomographic imaging to identify if the resolution of the periapical radiograph is unable to display intracanal calcification.

In most of the RETs of necrotic immature permanent teeth, the etiology of pulpal necrosis was dental trauma, dental anomalies, or caries. With the limited data and studies included in the present study that differentiated the outcome of RET from different etiologies, we showed that clinically significant (>20% positive value of radiographic changes) root lengthening and thickening were more predictable in dental anomalies compared with dental trauma (Table 5). According to Nagata et al³¹, dental trauma could disrupt the apical papilla cells, and the physical compression or stretch of Hertwig epithelial root sheath cells resulting from the trauma probably compromised the repair. Therefore, their study showed a lower increment of root length and thickness after RET on teeth with a history of trauma. However, further studies with a larger sample size and a longer follow-up are needed to draw a more

conclusive relationship between the etiologies of necrotic immature permanent teeth and the root development outcome after RET.

Even though many articles on RET have been published, it is still difficult to make a direct comparison of their results or data on root development. This is because the case selection, clinical procedure, and case assessment for RET in those studies were widely varied. There is a need for clinicians and researchers to build a consensus to standardize all of these variables so a more compelling and meaningful conclusion can be made.

Conclusions

Within the limitations of the present review, it can be concluded that RET yielded high survival (97.3%) and healing rates (93.0%) with good root development (77.3% root lengthening and 80.6% root thickening). However, clinical meaningful root development after RET remained unpredictable (16.1% root lengthening and 39.8% root thickening).

Acknowledgments

The authors deny any conflicts of interest related to this study.

Appendix 1 Literature search strategies

PubMed/Medline

("Regenerative Endodontics"[Mesh] OR "Regenerative endodontics" OR "regenerative endodontic" OR "Endodontic regeneration" OR ("Endodontics"[Mesh] AND "Regeneration"[Mesh] AND "Therapeutics"[Mesh]) OR "regenerative endodontic therapy" OR "regenerative endodontic therapies" OR (Endodontolog* AND regenerat*) OR (endodontic* AND regenerat*) OR "Pulp Revascularization" OR "Pulp revitalization" OR ("Dental Pulp"[Mesh] AND revascular*) OR ("Dental Pulp"[Mesh] AND revitaliz*) OR ("Tissue Engineering"[Mesh] AND "Endodontics"[Mesh]) OR ("tissue engineering" AND endodontic*) OR "dental pulp stem cell" OR "dental pulp stem cells" OR "pulp regeneration" OR "Regeneration"[Mesh] OR Regenerat* OR Revascularization OR Revitalization OR "regenerative endodontic treatment" OR "regenerative endodontic procedures" OR "regenerative endodontic procedure" OR "regenerative treatment") AND ("Open apex" OR "open apices" OR "Dentition, Permanent"[Mesh] OR "permanent dentition" OR "secondary dentition" OR "adult dentition" OR "Permanent teeth" OR "permanent tooth" OR "Tooth"[Mesh] OR Tooth OR Teeth OR "Immature teeth" OR "immature permanent teeth" OR "immature tooth" OR "immature permanent tooth" OR "immature apex" OR "immature apices" OR "non-vital immature teeth" OR "non vital immature teeth" OR "nonvital immature teeth" OR "necrotic immature teeth" OR immature) AND ("Apical abscess" OR "Periapical Abscess"[Mesh] OR "periapical abscess" OR "Suppurative Periapical Periodontitis" OR "Periapical Abscesses" OR "Apical periodontitis" OR "Periapical Periodontitis"[Mesh] OR "Periapical Periodontitis" OR "Dental Pulp Necrosis"[Mesh] OR "dental pulp necrosis" OR "Pulp Necrosis" OR ("Dental Pulp"[Mesh] AND "Necrosis"[Mesh]) OR ("dental pulp" AND necrosis) OR ("dental pulps" AND necrosis) OR ("dental pulp" AND necroses) OR ("dental pulps" AND necroses) OR "pulp necrosis" OR "pulpal necrosis" OR "traumatized pulp" OR "Tooth, Nonvital"[Mesh] OR "Nonvital Tooth" OR "Devitalized Tooth" OR "Pulpless Tooth" OR "Pulpless Teeth" OR "Devitalized Teeth" OR "periapical lesion" OR "apical lesion" OR "apical radiolucency" OR "periapical radiolucency" OR "necrotic pulp" OR

“chronic apical abscess” OR “chronic periapical abscess” OR “apical pathology” OR “infected pulp” OR “necrotic teeth” OR “necrotic tooth” OR “Nonvital Teeth” OR "Treatment Outcome"[Mesh] OR “treatment outcome” OR “non-vital tooth” OR “non-vital teeth”)

Filters: Publication date from 1990/01/01 to 2019/12/31, English

CINAHL (Cumulative Index to Nursing and Allied Health Literature)

(“Regenerative endodontic*” OR “Endodontic regeneration” OR ((MH "Endodontics+") AND (MH "Regeneration+") AND (MH "Therapeutics+"))) OR “regenerative endodontic therap*” OR (Endodontolog* AND regenerat*) OR (endodontic* AND regenerat*) OR “Pulp Revascularization” OR “Pulp revitalization” OR ((MH "Dental Pulp") AND (MH "Revascularization+")) OR (“Dental pulp*” AND revascular*) OR ((MH "Dental Pulp") AND revitaliz*) OR (“dental pulp*” AND revitaliz*) OR ((MH "Tissue Engineering") AND (MH "Endodontics+"))) OR (“tissue engineering” AND endodontic*) OR (“tissue generation” AND endodontic*) OR “dental pulp stem cell*” OR “pulp regenerat*” OR (MH "Regeneration+") OR Regenerat* OR (MH "Revascularization+") OR Revascularization OR Revitalization OR “regenerative endodontic treatment*” OR “regenerative endodontic procedure*” OR “regenerative treatment*”) AND (“Open apex” OR “open apices” OR (MH "Dentition, Secondary") OR “permanent dentition” OR “secondary dentition” OR “secondary dentition” OR “adult dentition” OR “Permanent teeth” OR “permanent tooth” OR “Immature teeth” OR (MH "Tooth+") OR Tooth OR Teeth OR “Immature teeth” OR “immature permanent teeth” OR “immature tooth” OR “immature permanent tooth” OR “immature apex” OR “immature apices” OR “non-vital immature teeth” OR “non vital immature teeth” OR “nonvital immature teeth” OR “necrotic immature teeth” OR immature) AND (“Apical abscess*” OR “periapical abscess*” OR “Suppurative Periapical Periodontitis” OR “Apical periodontitis” OR "Periapical Periodontitis" OR ((MH "Dental Pulp") AND (MH "Necrosis+"))) OR (“dental pulp*” AND necrosis) OR (“dental pulp*” AND necroses) OR “pulp necrosis” OR “pulpal necrosis” OR “traumatized pulp” OR “Nonvital Tooth” OR “Devitalized Tooth” OR “Pulpless Tooth” OR “Pulpless Teeth” OR “Devitalized Teeth” OR “periapical lesion” OR “apical lesion” OR “apical radiolucency” OR “periapical radiolucency” OR “necrotic pulp” OR “chronic apical abscess” OR “chronic periapical abscess” OR “apical pathology” OR “infected pulp” OR “necrotic teeth” OR “necrotic tooth” OR “Nonvital Teeth” OR (MH "Treatment Outcomes+") OR “treatment outcome*” OR “Outcome* of Treatment*” OR “Treatment Effectiveness” OR “non-vital tooth” OR “non-vital teeth”)

Limiters - English Language; Published Date: 19900101-20191231

Cochrane (clinical trials)

“Regenerative endodontic*” OR “Endodontic regenerat*” OR “regenerative endodontic therap*” OR (Endodontolog* AND regenerat*) OR (endodontic* AND regenerat*) OR “Pulp Revascularization” OR “Pulp revitalization” OR (“tissue engineering” AND endodontic*) OR “dental pulp stem cell*” OR “pulp regeneration” in Title Abstract Keyword AND “Open apex” OR “open apices” OR “permanent dentition” OR “secondary dentition” OR “adult dentition” OR “Permanent teeth” OR “permanent tooth” OR “Immature teeth” OR Tooth OR Teeth OR “immature permanent teeth” OR “immature tooth” OR “immature permanent tooth” OR “immature apex” OR “immature apices” OR “non-vital immature tooth” OR “non vital immature tooth” OR “nonvital immature tooth” OR “non-vital immature teeth” OR “non vital immature teeth” OR “nonvital immature teeth” OR “necrotic immature teeth” OR

immature in Title Abstract Keyword AND "Apical abscess" OR "periapical abscess" OR "Suppurative Periapical Periodontitis" OR "Periapical Abscesses" OR "Apical periodontitis" OR "Periapical Periodontitis" OR "dental pulp necrosis" OR "Pulp Necrosis" OR ("dental pulp*" AND necrosis) OR ("dental pulp*" AND necroses) OR "pulp necrosis" OR "pulpal necrosis" OR "traumatized pulp" OR "Nonvital Tooth" OR "Devitalized Tooth" OR "Pulpless Tooth" OR "Pulpless Teeth" OR "Devitalized Teeth" OR "periapical lesion" OR "apical lesion" OR "apical radiolucency" OR "periapical radiolucency" OR "necrotic pulp" OR "chronic apical abscess" OR "chronic periapical abscess" OR "apical pathology" OR "infected pulp" OR "necrotic teeth" OR "necrotic tooth" OR "Nonvital Teeth" OR "treatment outcome*" OR "non-vital tooth" OR "nonvital tooth" OR "non vital tooth" OR "non-vital teeth" OR "non vital teeth" OR "nonvital teeth" in Title Abstract Keyword - (Word variations have been searched)

Web of Science

TOPIC: ("Regenerative endodontic*" OR "Endodontic regenerat*" OR "regenerative endodontic therap*" OR (Endodontolog* AND regenerat*) OR (endodontic* AND regenerat*) OR "Pulp Revascularization" OR "Pulp revitalization" OR ("tissue engineering" AND endodontic*) OR "dental pulp stem cell*" OR "pulp regeneration") AND **TOPIC:** ("Open apex" OR "open apices" OR "permanent dentition" OR "secondary dentition" OR "adult dentition" OR "Permanent teeth" OR "permanent tooth" OR "Immature teeth" OR Tooth OR Teeth OR "immature permanent teeth" OR "immature tooth" OR "immature permanent tooth" OR "immature apex" OR "immature apices" OR "non-vital immature tooth" OR "non vital immature tooth" OR "nonvital immature tooth" OR "non-vital immature teeth" OR "non vital immature teeth" OR "nonvital immature teeth" OR "necrotic immature teeth" OR immature) AND **TOPIC:** ("Apical abscess" OR "periapical abscess" OR "Suppurative Periapical Periodontitis" OR "Periapical Abscesses" OR "Apical periodontitis" OR "Periapical Periodontitis" OR "dental pulp necrosis" OR "Pulp Necrosis" OR ("dental pulp*" AND necrosis) OR ("dental pulp*" AND necroses) OR "pulp necrosis" OR "pulpal necrosis" OR "traumatized pulp" OR "Nonvital Tooth" OR "Devitalized Tooth" OR "Pulpless Tooth" OR "Pulpless Teeth" OR "Devitalized Teeth" OR "periapical lesion" OR "apical lesion" OR "apical radiolucency" OR "periapical radiolucency" OR "necrotic pulp" OR "chronic apical abscess" OR "chronic periapical abscess" OR "apical pathology" OR "infected pulp" OR "necrotic teeth" OR "necrotic tooth" OR "Nonvital Teeth" OR "treatment outcome*" OR "non-vital tooth" OR "nonvital tooth" OR "non vital tooth" OR "non-vital teeth" OR "non vital teeth" OR "nonvital teeth")

References

- 1 J. Siqueira, I. Rôças, D. Ricucci, M. Hülsmann. **Causes and management of post-treatment apical periodontitis.** *Br Dent J*, 216 (2014), pp. 305-312
- 2 I. Bender, S. Seltzer, W. Soltanoff. **Endodontic success--a reappraisal of criteria. 1.** *Oral Surg Oral Med Oral Pathol*, 22 (1966), pp. 780-789
- 3 L. Strindberg. **The dependence of the results of pulp therapy on certain factors-an analytical study based on radiographic and clinical follow-up examination.** *Acta Odontol Scand*, 14 (1956), pp. 1-175
- 4 M. Cvek, G. Tsilingaridis, J.O. Andreasen. **Survival of 534 incisors after intra-alveolar root fracture in patients aged 7-17 years.** *Dent Traumatol*, 24 (2008), pp. 379-387

- 5 M. Torabinejad, A. Nosrat, P. Verma, O. Udochukwu. **Regenerative endodontic treatment or mineral trioxide aggregate apical plug in teeth with necrotic pulps and open apices: a systematic review and meta-analysis.** *J Endod*, 43 (2017), pp. 1806-1820
- 6 *AAE clinical considerations for a regenerative procedure*, American Association of Endodontists, Chicago, IL (2018), pp. 1-7
- 7 A.J. Smith, P.R. Cooper. **Regenerative endodontics: burning questions.** *J Endod*, 43 (2017), pp. S1-S6
- 8 A. Diogenes, M. Henry, F. Teixeira, K. Hargreaves. **An update on clinical regenerative endodontics.** *Endod Topics*, 28 (2013), pp. 2-23
- 9 G. Nicoloso, G. Goldenfum, T. Pizzol, *et al.* **Pulp revascularization or apexification for the treatment of immature necrotic permanent teeth: systematic review and meta-analysis.** *J Clin Pediatr Dent*, 43 (2019), pp. 305-313
- 10 H. Tong, S. Rajan, N. Bhujel, *et al.* **Regenerative endodontic therapy in the management of nonvital immature permanent teeth: a systematic review-outcome evaluation and meta-analysis.** *J Endod*, 43 (2017), pp. 1453-1464
- 11 B. Kahler, S. Mistry, A. Moule, *et al.* **Revascularization outcomes: a prospective analysis of 16 consecutive cases.** *J Endod*, 40 (2014), pp. 333-338
- 12 T. Bezgin, A. Yilmaz, B. Celik, *et al.* **Efficacy of platelet-rich plasma as a scaffold in regenerative endodontic treatment.** *J Endod*, 41 (2015), pp. 36-44
- 13 E. Chan, M. Desmeules, M. Cielecki, *et al.* **Longitudinal cohort study of regenerative endodontic treatment for immature necrotic permanent teeth.** *J Endod*, 43 (2017), pp. 395-400
- 14 L. Li, Y. Pan, L. Mei, J. Li. **Clinical and radiographic outcomes in immature permanent necrotic evaginated teeth treated with regenerative endodontic procedures.** *J Endod*, 43 (2017), pp. 246-251
- 15 J. Lin, Q. Zeng, X. Wei, *et al.* **Regenerative endodontics versus apexification in immature permanent teeth with apical periodontitis: a prospective randomized controlled study.** *J Endod*, 43 (2017), pp. 1821-1827
- 16 C. Peng, Y. Yang, Y. Zhao, *et al.* **Long-term treatment outcomes in immature permanent teeth by revascularisation using MTA and GIC as canal-sealing materials: a retrospective study.** *Int J Paediatr Dent*, 27 (2017), pp. 454-462
- 17 J. Silujjai, P. Linsuwanont. **Treatment outcomes of apexification or revascularization in nonvital immature permanent teeth: a retrospective study.** *J Endod*, 43 (2017), pp. 238-245
- 18 H. Nazzal, K. Kenny, A. Altimimi, *et al.* **A prospective clinical study of regenerative endodontic treatment of traumatized immature teeth with necrotic pulps using bi-antibiotic paste.** *Int Endod J*, 51 (2018), pp. 1946-1952
- 19 M. EzEldeen, G. Van Gorp, J. Van Dessel, *et al.* **3-dimensional analysis of regenerative endodontic treatment outcome.** *J Endod*, 41 (2015), pp. 317-324
- 20 V. Shivashankar, D. Johns, R. Maroli, *et al.* **Comparison of the effect of PRP, PRF and induced bleeding in the revascularization of teeth with necrotic pulp and open apex: a triple blind randomized clinical trial.** *J Clin Diagn Res*, 11 (2017), pp. ZC34-ZC39
- 21 T. Saoud, A. Zaazou, A. Nabil, *et al.* **Clinical and radiographic outcomes of traumatized immature permanent necrotic teeth after revascularization/revitalization therapy.** *J Endod*, 40 (2014), pp. 1946-1952

- 22 S. Bukhari, M. Kohli, F. Setzer, B. Karabucak. **Outcome of revascularization procedure: a retrospective case series.** *J Endod*, 42 (2016), pp. 1752-1759
- 23 A. Alagl, S. Bedi, K. Hassan, J. AlHumaid. **Use of platelet-rich plasma for regeneration in non-vital immature permanent teeth: clinical and cone-beam computed tomography evaluation.** *J Int Med Res*, 45 (2017), pp. 583-593
- 24 S. Shabahang. **Treatment options: apexogenesis and apexification.** *Pediatr Dent*, 35 (2013), pp. 125-128
- 25 E. Sheehy, G. Roberts. **Use of calcium hydroxide for apical barrier formation and healing in non-vital immature permanent teeth: a review.** *Br Dent J*, 183 (1997), pp. 241-246
- 26 T. Jeeruphan, J. Jantararat, K. Yanpiset, *et al.* **Mahidol study 1: comparison of radiographic and survival outcomes of immature teeth treated with either regenerative endodontic or apexification methods: a retrospective study.** *J Endod*, 38 (2012), pp. 1330-1336
- 27 F. Masmoudi, I. Bourmeche, A. Sebai, *et al.* **Root lengthening with apical closure in two maxillary immature permanent central incisors after placement of mineral trioxide aggregate (MTA) as an apical plug.** *Eur Arch Pediatr Dent*, 19 (2018), pp. 65-71
- 28 J. Tenca, A. Tsamtsouris. **Continued root end development: apexogenesis and apexification.** *J Pedod*, 2 (1978), pp. 144-157
- 29 L. Lin, S. Kim, G. Martin, B. Kahler. **Continued root maturation despite persistent apical periodontitis of immature permanent teeth after failed regenerative endodontic therapy.** *Aust Endod J*, 44 (2018), pp. 292-299
- 30 G. Jadhav, N. Shah, A. Logani. **Revascularization with and without platelet-rich plasma in nonvital, immature, anterior teeth: a pilot clinical study.** *J Endod*, 38 (2012), pp. 1581-1587
- 31 J. Nagata, B. Gomes, T. Rocha Lima, *et al.* **Traumatized immature teeth treated with 2 protocols of pulp revascularization.** *J Endod*, 40 (2014), pp. 606-612
- 32 M. Nagy, H. Tawfik, A. Hashem, A. Abu-Seida. **Regenerative potential of immature permanent teeth with necrotic pulps after different regenerative protocols.** *J Endod*, 40 (2014), pp. 192-198
- 33 I. Narang, N. Mittal, N. Mishra. **A comparative evaluation of the blood clot, platelet-rich plasma, and platelet-rich fibrin in regeneration of necrotic immature permanent teeth: a clinical study.** *Contemp Clin Dent*, 6 (2015), pp. 63-68
- 34 A. Alobaid, L. Cortes, J. Lo, *et al.* **Radiographic and clinical outcomes of the treatment of immature permanent teeth by revascularization or apexification: a pilot retrospective cohort study.** *J Endod*, 40 (2014), pp. 1063-1070
- 35 B. Estefan, K. El Batouty, M. Nagy, A. Diogenes. **Influence of age and apical diameter on the success of endodontic regeneration procedures.** *J Endod*, 42 (2016), pp. 1620-1625
- 36 N. Flake, J. Gibbs, A. Diogenes, *et al.* **A standardized novel method to measure radiographic root changes after endodontic therapy in immature teeth.** *J Endod*, 40 (2014), pp. 46-50
- 37 N. Sutarn, J. Jantararat, L. Ongchavalit, *et al.* **A comparison of 3 quantitative radiographic measurement methods for root development measurement in regenerative endodontic procedures.** *J Endod*, 44 (2018), pp. 1665-1670
- 38 A. Nosrat, N. Homayounfar, K. Oloomi. **Drawbacks and unfavorable outcomes of regenerative endodontic treatments of necrotic immature teeth: a literature review and report of a case.** *J Endod*, 38 (2012), pp. 1428-1434

- 39 A. Eskandarizadeh, M. Shahpasandzadeh, M. Shahpasandzadeh, *et al.* **A comparative study on dental pulp response to calcium hydroxide, white and grey mineral trioxide aggregate as pulp capping agents.** *J Conserv Dent*, 14 (2011), pp. 251-255
- 40 Z. Li, L. Cao, M. Fan, Q. Xu. **Direct pulp capping with calcium hydroxide or mineral trioxide aggregate: a meta-analysis.** *J Endod*, 41 (2015), pp. 1412-1417
- 41 A. Nosrat, A. Peimani, S. Asgary. **A preliminary report on histological outcome of pulpotomy with endodontic biomaterials vs calcium hydroxide.** *Restor Dent Endod*, 38 (2013), pp. 227-233
- 42 M. Caliskan. **Clinical reliability of the dentine bridge formed after pulpotomy: a case report.** *Int Endod J*, 27 (1994), pp. 52-55
- 43 K. Barrieshi-Nusair, M. Qudeimat. **A prospective clinical study of mineral trioxide aggregate for partial pulpotomy in cariously exposed permanent teeth.** *J Endod*, 32 (2006), pp. 731-735
- 44 M. Eghbal, S. Asgary, R. Baglue, *et al.* **MTA pulpotomy of human permanent molars with irreversible pulpitis.** *Aust Endod J*, 35 (2009), pp. 4-8
- 45 M. Qudeimat, A. Alyahya, A. Hasan. **Mineral trioxide aggregate pulpotomy for permanent molars with clinical signs indicative of irreversible pulpitis: a preliminary study.** *Int Endod J*, 50 (2017), pp. 126-134
- 46 L. Chueh, C. Chiang. **Histology of irreversible pulpitis premolars treated with mineral trioxide aggregate pulpotomy.** *J Endod*, 35 (2010), pp. 370-374
- 47 M. Song, Y. Cao, S. Shin, *et al.* **Revascularization-associated intracanal calcification: assessment of prevalence and contributing factors.** *J Endod*, 43 (2017), pp. 2025-2033
- 48 B. Kahler, S.L. Kahler, L. Lin. **Revascularization-associated intracanal calcification: a case report with an 8-year review.** *J Endod*, 44 (2018), pp. 1792-1795
- 49 M. Chen, K. Chen, C. Chen, *et al.* **Responses of immature permanent teeth with infected necrotic pulp tissue and apical periodontitis/abscess to revascularization procedures.** *Int Endod J*, 45 (2012), pp. 294-305