

# Automatic Detection and Calculation of Drusen Areas in Retinal Fundus Fluorescein Angiography Images

## Retinal Fundus Anjiyografi Görüntülerinde Drusen Alanlarının Otomatik Tespiti ve Hesaplanması

Önder DEMİR<sup>1</sup>, Buket DOĞAN<sup>1</sup>, Esra ÇALIK BAYEZİT<sup>2</sup>, Kazım YILDIZ<sup>1</sup>

<sup>1</sup> Computer Engineering Department, Technology Faculty, Marmara University 34722, Kadıköy / İSTANBUL

<sup>2</sup> Vocational School, Fatih Sultan Mehmet Vakif University, ISTANBUL, TURKEY

### Abstract

Computer aided detection (CAD) systems are widely used in the analysis of biomedical images. In this paper, we present a novel CAD system to detect age-related macular degeneration (ARMD) on retinal fundus fluorescein angiography (FFA) images, and we provide an areal size calculation of pathogenic drusen regions. The purpose of this study is to enable identification and areal size calculation of ARMD-affected regions with the developed CAD system; hence, we aim to discover the condition of the disease as well as facilitate long-term patient follow-up treatment. With the aid of this system, assessing the marked regions will take less time for ophthalmologists and observing the progress of the treatment will be a simpler process. The CAD system consists of four stages, a) preprocessing, b) segmentation, c) region of interest detection and d) feature extraction and drusen area detection. Detection through CAD and calculation of drusen regions were performed with a dataset composed of 75 images. The results obtained from the developed CAD system were examined by a specialist ophthalmologist, and the performance criteria of the CAD system are reported as conclusions. As a result, with 66 correct detections and 9 incorrect detections, the developed CAD system achieved an accuracy rate of 88%.

**Keywords:** Computer Aided Detection, Age Related Macular Degeneration, Morphologic Image Processing, Retinal Fundus Fluorescein Angiography

### Öz

Bilgisayar destekli tespit (BDT) sistemleri biyomedikal görüntülerin analizinde geniş bir kullanım alanına sahiptir. Bu çalışmada retinal fundus anjiyografi görüntüleri üzerinde yaşa bağlı makula dejenerasyonu (YBMD) hastalığının tespiti için bir BDT sistemi gerçekleştirilmiş ve patojenik drusen alanlarının büyüklüğünün hesaplanması sağlanmıştır. Çalışmanın amacı YBMD hastalığının görüldüğü alanların tespitinin ve büyüklüğünü hesaplamının yanında hastalığa karşı uygulanan tedavinin sonucunun takibini de sağlamaktır. Geliştirilen sistemin yardımıyla optalmoloji uzmanları işaretlenen alanları kısa sürede tespit edebilecek ve hastalığın tedaviye verdiği cevabı basit bir şekilde gözlemleyebileceklerdir. Geliştirilen BDT sistemi 4 aşamadan oluşmaktadır, a) ön işleme aşaması, b) bölütleme aşaması, c) ilgi alanı tespiti ve d) öz nitelik çıkarma ve tespit aşaması. Geliştirilen BDT sistemi 75 görüntüden oluşan bir veri setiyle test edilmiştir. BST sisteminin elde ettiği sonuçlar bir optalmoloji uzmanıyla karşılaştırılarak sonuç bölümünde sunulmuştur. Geliştirilen BDT sistemi 66 doğru, 9 hatalı tespit yaparak %88 doğruluk oranı sağlamıştır.

**Anahtar Kelimeler:** Bilgisayar Destekli Tespit, Yaşa Bağlı Makula Dejenerasyonu, Morfolojik Görüntü İşleme, Retinal Fundus Anjiyografi

## I. INTRODUCTION

Eye problems brought about by advanced age can have a serious impact, including loss of vision if untreated at an early stage. Macula (yellow spot) is a region in the retina layer where optic cells are most concentrated [1]. ARMD is an eye condition commonly known as “yellow spots” caused by deformation of the macula region of the eye.

According to the World Health Organization (WHO), ARMD ranks third in vision disorders that result in loss of sight with 8.7% prevalence[2]. The disease affects the macula in such a way that the eye gradually loses its ability to see. The early findings of ARMD-related loss of vision may include seeing shadowy areas in central vision and mostly blurred or distorted vision. The main risk factor in developing macular degeneration is advancing age. In developed countries, the most significant reason for blindness in people over 50 years of age is macula disease [3,4].

Macular degeneration develops as a result of the aging of the macula region. FFA has been a standard tool in the investigation and management of retinal diseases since 1961 [5,6].

In order to detect ARMD in retinal images, structures like optic discs, blood vessels, and macula should be identified within the image. In the literature, relevant studies concentrating on detection of structures like optic discs, blood vessels, and macula in retina use various methods, such as phase congruency [7], morphological image processing [8,9], Gabor filter [10], wavelet transform [11], region growing, Gaussian filter [12], and multilevel image processing [13]. In light of the previous studies, detecting ARMD by using features like the position of optic disc in retina, the convergence of blood vessels on the optic disc, the distance of the macula region to the optic disc, pixel intensity values of the optic disc, blood vessels, and drusen is found to provide successful outcomes in diagnosis of the disease.

Güven[14] uses Hough transform to determine optic disc localization, the thresholding method is used to obtain the brightest pixel region, and Canny’s method is used for edge detection. Contrast-limited adaptive histogram equalization is used for the segmentation and detection of ARMD. The ARMD segmentations created through the proposed method were then compared by an ophthalmologist through the process of manual segmenting. The positive predictive value of the proposed method was calculated as 95.68%. The study does not contain sensitivity information of the system.

Köse and Yavuz use the retinal blood vessels as reagents to identify the positions of significant structures, such as the optic disc in the retina and macula in addition to the diagnosis of the disease. For this purpose, in the aforementioned

study, the green band of the colored fundus image was filtered through a Gabor filter to clarify the vessels. In order to bring the vessels to the forefront, top hat conversion and highest percentage thresholding (p-tile) were used. The study was tested on 20 images selected from STARE database and reported to achieve 86.31% sensitivity and 92.9% accuracy[15]. Joseph employs a gradient-based segmentation algorithm to detect drusens that isolate drusens and provide basic drusen characterization for the modeling stage. The detected drusens are then fitted by using Modified Gaussian functions, producing a model of the image that is used to evaluate the affected area[16].

Brandon and Hoover use a multilevel analysis in the detection of drusens in retinal images. Their study was composed of a multilayered structure that contains a pixel layer, a region layer, an area layer, and an image layer. In area-layered classification, regions marked as false positive were eliminated with filtering and each area was separated into sub-regions that contain no drusens, fewer drusens, or many drusens. In image-layered classification used in the final stage, the regions marked by areal layer are counted and classified by checking their average area. The study consisted of 38 healthy images, 68 unhealthy images with drusens, and 19 abnormal drusen images without drusens. They reported a success rate of 87% [13].

In our previous work, a CAD system was developed using morphological image processing technique to detect regions of interest affected by ARMD disease on data set composed of 87 images. Following the segmentation phase, region of interests were labeled by analyzing the most important morphological features that would identify ARMD. The accuracy of CAD system is tested by ophthalmologist and the accuracy of the system is %85.05 [9].

Upon analysis of the studies in the literature, it can be concluded that even if the results show a high accuracy rate for some of the images, these could not provide a long-term tool in monitoring the whole treatment course of patients with ARMD, and how the patients respond to treatment. This study, on the other hand, differs from other studies in that it allows physicians to calculate the area of the diseased region during the whole course of the treatment, and monitor the growth and reduction in this area.

With contemporary treatments, it is possible not only to prevent loss of vision due to ARMD, but also to increase sight [17,18]. ARMD is a chronic disease that requires regular treatment. Therefore, it is extremely important to observe follow-up and treatment plans recommended by the physician. The physician should examine and monitor the patient frequently [3,18]. When the increasing number of patients

and the cost of healthcare are considered, this study provides advantages by reducing the duration of the detection process, increasing accuracy, and lowering costs.

This study develops a CAD system that can be used to diagnose deformations caused by ARMD in the macula region and track their course in time. Thus, the study aims to achieve a higher assessment rate with fewer images in less time by decreasing the number of images an ophthalmologist should examine, and providing preliminary information during the follow-up phase of the disease.

## II. MATERIALS AND METHODS

This study, which was conducted with the permission and approval of TR Ministry of Health and the Turkish Institute of Public Hospitals, used a dataset composed of 75 images, 16 of which were healthy images and 39 unhealthy images obtained from the Beyoglu Eye Training and Research Hospital. In addition, the dataset was extended with the addition of 20 unhealthy images from STARE dataset [19] downloaded from the website “<http://www.parl.clemson.edu/stare>”. The retinal images were composed of structures of blood vessels, optic discs, and the macula region. In order to identify the macula region where drusens develop, blood vessels and optic discs should be removed from the images. Despite having different shapes, the similarities in the colors and tissues of these structures can cause the elimination of the region of interest (ROI), such as the macula region, from the images during the segmentation stage [15]. For this reason, an algorithm was used that allowed pixel neighborhood-dependent optic disc elimination by using feature extraction for blood vessel segmentation from the images, elimination of the optic discs, and identification of the region of interest.

### 2.1 The Stages of the Developed CAD System

The block diagram of CAD system is presented in Figure 1. The developed CAD system consists of 4 stages. In the initial stage of preprocessing, the vessels are eliminated from the image. In the second stage, thresholding and edge detection are performed for segmentation. In the third stage, regions of interest are identified and features are extracted. In the final stage, decisions are made by evaluating the data obtained.

### 2.2 Preprocessing Stage

FFA images are RGB colored images. During the preprocessing stage, FFA images are initially separated into the green color band. The image in the green color band is then diluted and subjected to thresholding in order to eliminate the vessels in the image.

By running the colored image of the fundus in the retinal images through the green color band, better results were achieved for optic discs and ARMD detection. By using morphological image processing and various operators, a number of operations were performed on the images, such as identification and extraction of structures like borders and skeletons in the image, and the removal of noises and segmentation [20]. Dilation is one of the main operators of mathematical morphology [20]. Dilation is the process of enlarging the object in the digital image to the size of the segments it intersects with structuring elements (SE). Dilation is performed by moving each pixel in the digital image to the center point of SE. SE adds pixels to the empty areas by moving onto each pixel value and hence provides a clearer image. In the initial stage of the developed CAD system, a dilation operator is

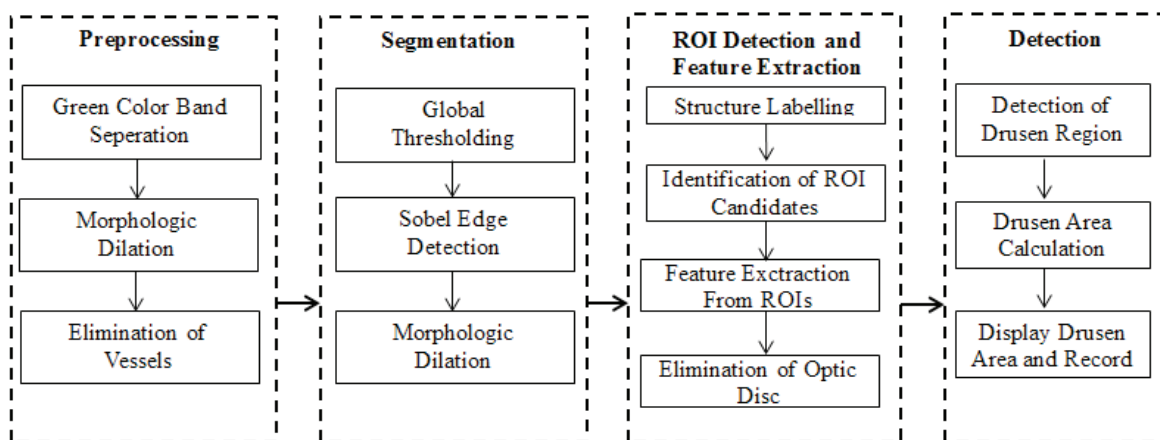
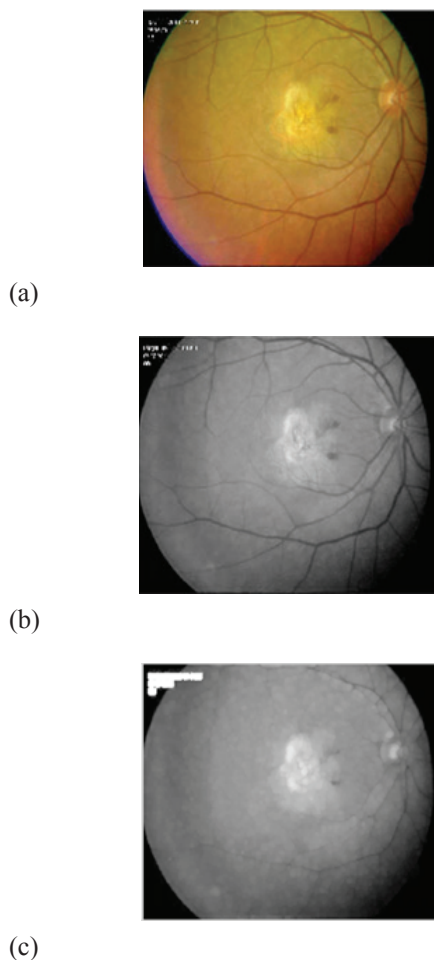


Figure 1. The block diagram of CAD system

used to eliminate vessels as one of the morphological image processing operators. To be able to perform dilation, an appropriate structuring element should be selected. Since selecting the structuring element based on the shape sought in the image will provide better detection results, the structuring element selected for this system developed a disc shape to detect drusens caused by ARMD. By using this selected structuring element, the dilation process was performed. After the dilation operator is applied to attenuate the clarification of the vessels, the vessels with reduced visibility are eliminated by thresholding.

Figure 2 (a) shows the original image and Figure 2 (b) shows the separated image into the green color band. In the image where the dilation operator is applied, the vessels are substantially eliminated and their visibility reduced. After the dilation operator is applied, the elimination of the vessels with reduced visibility is achieved as seen in Figure 2 (c).



**Figure 2.** (a) Original image (b), image separated into green, (c) and image obtained after the application of green color band of the dilation operator

### 2.3 Segmentation Stage

Thresholding is the process of equalizing pixel values that form the image matrix from a larger or smaller value to another value. Usually, for an image with 256 gray level intensity, this value is equalized to 0 (black) or 255 (white). Hence, regions with undesired intensity are removed from the image. Following the process of thresholding, the image is converted into a binary image to obtain a matrix composed of 0 and 1.

In this study, global thresholding method is used. The thresholding value (T) is determined by a value obtained through the histogram graphic of the image. The appropriate T value is obtained by calculating the threshold value of the pixel values of the diseased regions at minimum level through the histogram graphic analysis of the images in the data used. In line with the established T value, the threshold value is determined as well as the averages of the smaller and larger pixels. The average of these two values is used as the threshold value. After the application of thresholding value, Sobel edge detection algorithm is used to identify the structural borders in the data image as well as to clarify vertical and horizontal edges. Applying Sobel edge detection algorithm on the image might cause some of the border lines to break. To remove these breaks, the dilation operator is re-applied. For this process, a disc-shaped structuring element of one unit is used. As a result, areal values are retained by minimally dilating the borders of regions of interest.

Figure 3 (a) shows the binary image converted after thresholding a sample FFA image. Figure 3 (b), on the other hand, shows the image after Sobel edge detection algorithm is applied. Figure 3 (c) shows the Sobel edge detection algorithm applied the image of relevant pixels coupled with the dilation operator by using the disc-shaped structural element of one unit.



**Figure 3.** (a) Image after thresholding, (b) image after Sobel algorithm, and (c) image after dilation

### 2.4 Identification of ROI and Feature Extraction Stage

In the case of images where edges are clarified by using the dilation operator, possible ROIs are identified. All structures located in these regions are separated from the background image and labeled by identifying their borders.



These labels aid in extracting neighboring information of the objects through analysis of the number of objects in the image together with data about the borders. Information about the number of objects in the image as well as the neighborhood of the identified objects is obtained by a matrix that contains information about the borders. Pixels in close proximity are combined within this neighborhood. This process facilitates monitoring the changes in the potential ROIs during the course of treatment. As can be seen in Figure 5 (b), potential ROIs are marked and its borders are indicated with different colors.


In the present study, after identification of the regions that could potentially be ROIs, the area, border, shape, and perimeter features of these ROIs are extracted. By using these features, ROIs are encircled in a specified region through the algorithm developed.

Since the aim of the present study is to detect ARMD developed in the macula region, the optic disc should be eliminated from the images. The optic disc has a diameter of around 1.5 mm. The blood vessels in the retina merge in the optic disc. Because of these characteristics of the optic disc, it is considered to be a region with fixed features in the retinal images. In the study conducted, a rule-based detection of the optic disc is performed. Then, the perimeter, area, and shape features of the detected ROI's are identified according to the criteria and marked in the images.

The optic disc is usually located as the largest area in the spherical structure. The rule that detects and eliminates the optic disc in the images can be seen in Figure 4. Figure 5 shows the camera image of fundus when the optic disc is eliminated.

## 2.5 Detection Stage

In the final stage, ARMD in the macula region of the retina is detected and marked. Figure 5 (a) shows the calculated value of the drusen region in a sample FFA image. In Figure 5 (b), the region where ARMD has developed is marked and indicated with a perimeter in the original image. At this stage, the area of the detected macula region is computed and recorded. This information aids ophthalmologists in assessing the progress of the disease and response to the treatment.



**Figure 5.** (a) Image with clarified borders (b) image obtained through optic disc elimination

## III. RESULTS AND DISCUSSION

To be able to measure the success rate of the method employed in ARMD detection, the developed CAD system was tested by an ophthalmologist and the success rate of the applied method was determined. For accurate detection of ROI in the images obtained through the implementation of the CAD

```

E: Label Number of ROI (Initialize Value of E = 1)
MaxArea= Area of Largest Circular ROI (Initialize Value of MaxArea = 0)
M: Label Number of ROI has Maximum Area
If (E is Circular)
{
    If (Area of E > MaxArea)
    {
        M = E
        E++
    }
    Else E++
}
Else E++
Remove M From Image

```

**Figure 4.** Elimination rule of optic disc

system, certain criteria were defined. As seen in Table 1, the values calculated by using four basic values, True Positive (TP), False Positive (FP), False Negative (FN), True Negative (TN), were used as the performance criteria to assess the results of all tests implemented on the medical images [21].

**Table 1.** CAD System Results and Performance Criteria

CAD System Results				Performance Criteria		
TP	TN	FP	FN	Sensitivity (%)	Specificity (%)	Accuracy (%)
51	15	1	8	86.44%	93.75%	88%

The developed CAD system was used on 75 retinal images, 16 of which were healthy and 59 of which exhibited ARMD. Then, the elimination of the optic disc from the image and accurate marking of the macula region that developed ARMD were tested. Of the 75 images, 66 of them (TP and TN) were detected accurately while 9 (FP and FN) were false detections. The assessment results were expressed as performance criteria. Table 1 shows the performance criteria obtained by application of the CAD system. Based on the calculations, the sensitivity value was found to be 86.44% and the specificity was 93.75%. Through the computer-aided detection of ARMD developed in the retina, the test conducted on 75 FFA images achieved an accuracy rate of 88%. Furthermore, the area of each region marked as diseased on FFA images was calculated, and individual sizes of each region as well as the total size of the diseased region were determined.

In addition to increasing the accuracy of our previous work [9], the areas of interests of the ARMD disease in the images were calculated in this study. The database has similar feature with in [15]. Our results show sensitive of the algorithm is higher but accuracy is not as good as [15]. But our algorithm has capability to find area and can make a comparison with time. In [15] authors only work with selected 20 images. In this work, the algorithm was tested on more images so the accuracy could be rule out.

#### IV. CONCLUSIONS

In this study, a computer-aided detection system for ARMD was performed on healthy and diseased FFA images. For the detection of ARMD, by utilizing the shape differences of the blood vessels, their visibility was reduced from the images. Following the segmentation stage, the characteristic structural features that could differentiate ARMD were analyzed, ROIs were labeled, and the optic disc was eliminated by using its specific features on the retina to separate the optic disc from the macula region, where ARMD had developed. On the image, the regions labeled as drusen were

marked over the original image to be detected, and their areal sizes were calculated and then displayed. In this way, ophthalmologists can now compare FFA images of patients taken in different times, and monitor the changes in drusen regions that occur over time.

The developed method contributes to the literature with morphological image processing stages and the designed approach. In the designed CAD system, the aim is to develop a method that could be used in the diagnosis and monitoring of a number of eye diseases, such as retinopathy of prematurity, diabetic retinopathy, and retinal detachment, to facilitate the work processes of ophthalmologists.

In the literature, studies conducted on retinas are performed on two-dimensional images. In the future, the target is to develop three-dimensional retinal images to assist in the diagnosis of retinal diseases.

#### References

- [1] Edwards, M., Bressler, N., & Raja, S. (1999). Macular disorders-Age-related macular degeneration. *Ophthalmology, 1st ed. London, UK: Mosby International, 8.*
- [2] Kılınç, D., Borandağ, E., Yücalar, F., Tunalı, V., Şimsek, M., & Özçift, A. (2016). KNN algoritması ve r dili ile metin madenciliği kullanılarak bilimsel makale tasnifi.
- [3] Coleman, H. R., Chan, C.-C., Ferris, F. L., & Chew, E. Y. (2008). Age-related macular degeneration. *The Lancet, 372(9652), 1835-1845.*
- [4] Ding, X., Patel, M., & Chan, C.-C. (2009). Molecular pathology of age-related macular degeneration. *Progress in retinal and eye research, 28(1), 1-18.*
- [5] Novotny, H. R., & Alvis, D. L. (1961). A method of photographing fluorescence in circulating blood in the human retina. *Circulation, 24(1), 82-86.*
- [6] Kwan, A. S., Barry, C., McAllister, I. L., & Constable, I. (2006). Fluorescein angiography and adverse drug reactions revisited: the Lions Eye experience. *Clinical & experimental ophthalmology, 34(1), 33-38.*
- [7] Geng, L., Shao, Y.-T., Xiao, Z.-T., Zhang, F., Wu, J., Li, M., & Shan, C.-Y. (2014). Fundus optic disc localization and segmentation method based on phase congruency. *Bio-medical materials and engineering, 24(6), 3223-3229.*
- [8] Pourreza, R., Pourreza, H., & Banaee, T. (2010). *Segmentation of blood vessels in fundus color images by Radon transform and morphological reconstruction.* Paper presented at the Advanced Computational Intelligence (IWACI), 2010 Third International Workshop on.
- [9] Calik, E., Dogan, B., & Ucan, O. N. (2015). *Computer Aided Detection of age related macular degeneration in retinal images.* Paper presented at the Signal Processing and Communications Applications Conference (SIU), 2015 23th.

- [10] Soares, J. V., Leandro, J. J., Cesar, R. M., Jelinek, H. F., & Cree, M. J. (2006). Retinal vessel segmentation using the 2-D Gabor wavelet and supervised classification. *Medical Imaging, IEEE Transactions on*, 25(9), 1214-1222.
- [11] Freund, D. E., Bressler, N., & Burlina, P. (2009). *Automated detection of drusen in the macula*. Paper presented at the Biomedical Imaging: From Nano to Macro, 2009. ISBI'09. IEEE International Symposium on.
- [12] Abramoff, M. D., & Niemeijer, M. (2006). *The automatic detection of the optic disc location in retinal images using optic disc location regression*. Paper presented at the Engineering in Medicine and Biology Society, 2006. EMBS'06. 28th Annual International Conference of the IEEE.
- [13] Brandon, L., & Hoover, A. (2003). Drusen detection in a retinal image using multi-level analysis *Medical Image Computing and Computer-Assisted Intervention-MICCAI 2003* (pp. 618-625): Springer.
- [14] Güven, A. (2013). Automatic detection of age-related macular degeneration pathologies in retinal fundus images. *Computer methods in biomechanics and biomedical engineering*, 16(4), 425-434.
- [15] Yavuz, Z., & Köse, C. (2011). *Retinal blood vessel segmentation using Gabor filter and top-hat transform*. Paper presented at the Signal Processing and Communications Applications (SIU), 2011 IEEE 19th Conference on.
- [16] Joseph, M. S. G. (2015). Automated Drusen Detection and Quantification for Early Identification of Age Related Macular Degeneration in Retinal Images Using Analytical Modeling Algorithms.
- [17] Vingerling, J. R., Dielemans, I., Hofman, A., Grobbee, D. E., Hijmering, M., Kramer, C. F., & de Jong, P. T. (1995). The prevalence of age-related maculopathy in the Rotterdam Study. *Ophthalmology*, 102(2), 205-210.
- [18] Jonasson, F., Arnarsson, A., Sverrisson, T., Stefánsson, E., Sigurdsson, H., Gislason, I., . . . Bird, A. (2003). 5-year incidence of age-related maculopathy-Reykjavik Eye study. *Investigative Ophthalmology & Visual Science*, 44(13), 3083-3083.
- [19] McCormick, B., & Goldbaum, M. (1975). *STARE= Structured Analysis of the Retina: Image processing of TV fundus image*. Paper presented at the Jet Propulsion Laboratory, Pasadena, CA: USA-Japan Workshop on Image Processing.
- [20] Dougherty, G. (2009). *Digital image processing for medical applications*: Cambridge University Press.
- [21] Dhawan, A. P. (2011). *Medical image analysis* (Vol. 31): John Wiley & Sons.