

ULTRASONOGRAPHIC IMAGING ON THE PROGRESS OF WOUND HEALING AFTER ABDOMINAL SURGERY IN DOGS

A.B.Z. Zuki¹ and J.S. Boyd²

¹*Faculty of Veterinary Medicine, Universiti Putra Malaysia, 43400 UPM Serdang, Selangor, Malaysia*

²*Division of Veterinary Anatomy, Department of Veterinary Preclinical Studies, University of Glasgow Veterinary School, Bearsden Road, Glasgow G61 1QH, Scotland, United Kingdom.*

SUMMARY

The present study has been carried out with the aim of evaluating the progress of abdominal wound healing after abdominal surgery and to detect any changes that might occur during the reparative phase using B-mode ultrasound. Five dogs of different breeds, sex and age were used in this study. The dogs had undergone ventral abdominal surgery for various reasons. A real-time B-mode ultrasound machine (Capasee TOSHIBA) connected with a 7.5 MHz linear array transducer was used in this study. The ultrasonographic examination was done transversely across the ventral abdominal midline (wound) from cranial to caudal and longitudinal scan was done along the wound (incision site) from cranial to caudal. Initial scanning was carried out on day one (approximately 24 hours) post-operation. Subsequent scans were carried out on the basis of one day apart while the animal was still in the hospital. The ultrasonographic appearance of wound (surgical site) at the early stage was ill-defined hypoechoic with acoustic shadowing artefact. With time the wound appeared hypoechoic with some degree of an echogenic center and casting acoustic shadowing artefact. By day 11 post-operation, the wound was found to have a disorganised echogenic structure with acoustic shadowing artefact. By day 13 post-operation, the wound appeared as disorganised hyperechoic with acoustic shadowing artefact due to the presence of fibrous tissue formation. Results from this study also demonstrate that the wound could be evaluated in both transverse and longitudinal scans. However, the transverse scan seems to be easier than the longitudinal scan in evaluation of the surgical wound.

Keywords: ultrasonographic imaging, wound healing, abdominal surgery, dogs

INTRODUCTION

Ultrasonography can be used to detect subtle differences in acoustic impedance of soft tissues and, therefore, is a sensitive technique for locating and characterising fluid collections and masses (Christensen *et al.*, 1988). The development of hematoma and fibrous scars can be followed up by ultrasonography. In a study of post-operative incision site complications, Trout *et al.* (1994) reported that ultrasonography is a sensitive technique that could be used to detect and localise fluid accumulations at the surgical site. However, many ultrasonographic features of surgical sites were not specific for dogs with early post-operative incision site complications. In human beings, ultrasonography has been used successfully for the diagnosis of hematomas, seromas, and inflammatory processes such as abscesses (Jain *et al.*, 1992; Berstein and Hansen, 1991; Howard and Einhorum, 1991). Ultrasonography has also been shown to be highly effective in early recognition of post-operative hematoma formation after hip or femoral shaft surgery, including total hip displacement (Glaser *et al.*, 1988; Parrini *et al.*, 1988). Ultrasonography has also been used to monitor healing of ventral abdominal midline incisions after exploratory laparotomy in 21 ponies (Wilson *et al.*, 1989). In an experimental study on the healing of ruptured

gastrocnemius muscle in rats, Lehto and Alanen (1987) have pointed out the accuracy of ultrasonography in the examination of muscle trauma, especially during the early phase of healing. Ultrasonography has also been shown to be useful in defining mass location, lesion tissue characteristics, invasion into nearby blood vessels and esophagus, and the optimal location for directing needle aspiration or tissue biopsy (Fornage *et al.*, 1983).

The present study has been carried out with the aim of evaluating the progress of abdominal wound healing after abdominal surgery and to detect any changes that might occur during the reparative phase using B-mode ultrasound.

MATERIALS AND METHODS

Animal and preparation technique

Five dogs of different breeds, sex and age referred to the Glasgow University Small animal Clinics (GUSAC) were used in this study. The dogs had undergone ventral abdominal surgery for various reasons. The surgery was carried out on the ventral abdominal midline (VAM). The ventral abdominal area had been prepared earlier for abdominal surgery. The hair had already been removed. Thus, it was only necessary to apply ultrasound gel prior to ultrasonographic examination.

Ultrasonographic examination

A real-time B-mode ultrasound machine (Capasee TOSHIBA) connected with a 7.5 MHz linear array transducer was used in this study. A video recorder (Panasonic) was connected to the scanner to record the scanned images. The animal was laid on the table on lateral recumbency during scanning. The ultrasonographic examination was done transversely across the ventral abdominal midline (wound) from cranial to caudal and longitudinal scan was done along the wound (incision site) from cranial to caudal. Initial scanning was carried out on day one (approximately 24 hours) post-operation. Subsequent scans were carried out on the basis of one day apart while the animal was still in the hospital. An ultrasonographic examination was then carried out when the animals returned for wound assessment and removal of suture material. The scanned images for each of the cases were recorded during scanning on a super VHS videotape for revision at a later date. The best images were printed during review and labeled accordingly.

RESULTS

Day one post-operation

Ultrasonographic examination of the ventral abdominal wound scanned transversely on day one (approximately 24 hours) post-operation demonstrated a wound which appeared as an ill-defined hypoechoic area with acoustic shadowing artefact (Fig. 1). The rectus abdominis muscle on both sides of the wound appeared well defined and almost isoechoic relative to the subcutaneous tissue. The edges of the wound appeared to have been well apposed. A small fluid accumulation within the subcutaneous tissue at the surgical site of the skin appeared anechoic with ill-defined margins. The wound was found to be exactly on the linear alba, but at a certain point was found on the muscle just lateral to the linear alba. The suture material within the subcutaneous tissue appeared hyperechoic with acoustic shadowing artefact.

Longitudinal scan along the wound demonstrated a disorganised pattern of muscle with intermittent acoustic shadowing originating from the skin surface which was due to suture material in the skin (Fig. 2). Areas of haemorrhage and small fluid accumulations within the subcutaneous tissue appeared anechoic to hypoechoic with acoustic shadowing artefacts.

Day two post-operation

Transverse scan on ventral abdominal wound demonstrated an ill-defined hypoechoic area with acoustic shadowing artefact (Fig. 3). The supposed haemorrhagic area within the subcutaneous tissue superficial to the rectus abdominis muscle was still visible and appeared as an ill-defined hypoechoic area with acoustic shadowing artefact. The area of muscle damage appeared disorganised and hypoechoic. Areas of supposed haemorrhage and small fluid accumulation within the subcutaneous tissue were still present and appeared anechoic to hypoechoic with acoustic shadowing artefact on the longitudinal scan.

Day eleven post-operation

The scanning was done a day after removal of suture material. Transverse scan of the ventral abdominal wound demonstrated a disorganised hypoechoic area with an echogenic center, casting an acoustic shadowing artefact (Fig. 4). The echogenic area of the wound was suggestive of the presence of fibrous tissue formation which was essential for the wound healing process. The area surrounding the surgical site appeared disorganised and hypoechoic suggestive of soft tissue damage.

Longitudinal scan of the ventral abdominal wound demonstrated that the wound appeared as a disorganised area of mixed echogenicity indicating an area of muscle damage with intermittent acoustic shadowing artefacts emanating from the ill-defined hypoechoic areas within the muscle (Fig. 5). These ill-defined hypoechoic areas were actually the original sites of the suture material which had been infiltrated by serum and cellular debris.

Day 13 post-operation

Ultrasonographic examination of the ventral abdominal wound demonstrated a disorganised echogenic area with acoustic shadowing artefact (Fig. 6). The area surrounding the surgical site appeared more organised than on the previous scan. The large fluid accumulation with acoustic enhancement artefact separating the subcutaneous tissue and rectus abdominis muscle was still present. A small portion of fibrous tissue formation was seen protruding into the fluid space at the surgical site.

Longitudinal scan of the wound demonstrated a disorganised echogenic structure representing the area of muscle damage with the presence of fibrous tissue formation (Fig. 7). The small hypoechoic areas which were casting intermittent acoustic shadowing artefact were still visible but appeared smaller than on day 11 examination. These hypoechoic areas represented the original sites of the reabsorbing suture material. There was some echogenic material present within the fluid area suggesting that this was consolidating.

Day 15 post-operation

Ultrasonographic examination of ventral abdominal wound demonstrated a disorganised hyperechoic structure with acoustic shadowing artefact (Fig. 8). The fibrous tissue appeared more hyperechoic compared to the image on the day 13 post-operation. The large fluid accumulation between the subcutaneous tissue and the rectus abdominis muscle was still present. The presence of echogenic material indicated that there was consolidation taking place.

Longitudinal scan demonstrated a disorganised hyperechoic structure with the presence of some hypoechoic areas producing acoustic shadowing artefact (Fig. 9). These small hypoechoic areas within the muscle represented the original sites of suture material and were still visible on ultrasound. The disorganised hyperechoic structure was due to the presence of fibrous tissue formation.

Day 17 post-operation

Transverse scan of the ventral abdominal wound demonstrated a disorganised hyperechoic area with acoustic shadowing artefact (Fig. 10). The overall dimensions of the wound appeared to be smaller than on day 15 examination. The large fluid accumulation was still present and appeared as in the previous scan.

Longitudinal scan of the surgical site demonstrated a disorganised hyperechoic area representing the area of muscle damage and the presence of fibrous tissue formation (Fig. 11). The small hypoechoic areas with acoustic shadowing artefacts could still be seen.

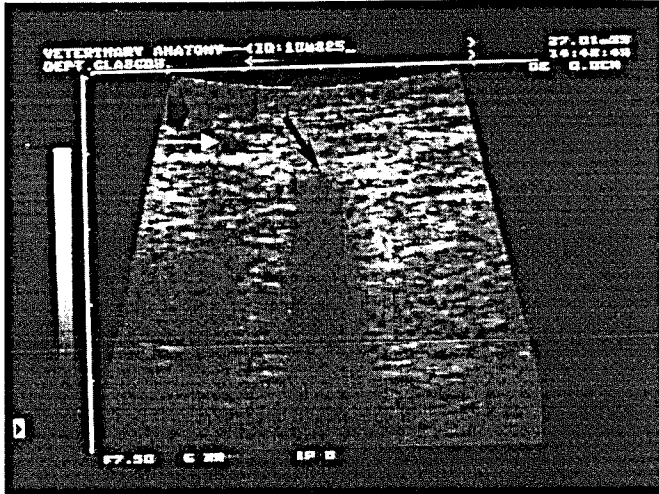


Fig. 1. Transverse scan of the ventral abdominal wound approximately 24 hours post-operation demonstrated an ill-defined hypoechoic area with acoustic shadowing artefact (arrow). The rectus abdominis muscle on both sides of the wound appears well defined and almost isoechoic relative to the subcutaneous tissue. The edges of the wound appear to have well apposed. The wound on the skin and subcutaneous tissue appears hypoechoic with acoustic shadowing artefact (arrow head) and is not parallel with the wound in muscle. A small fluid accumulation within the subcutaneous tissue (small arrow) appears anechoic.

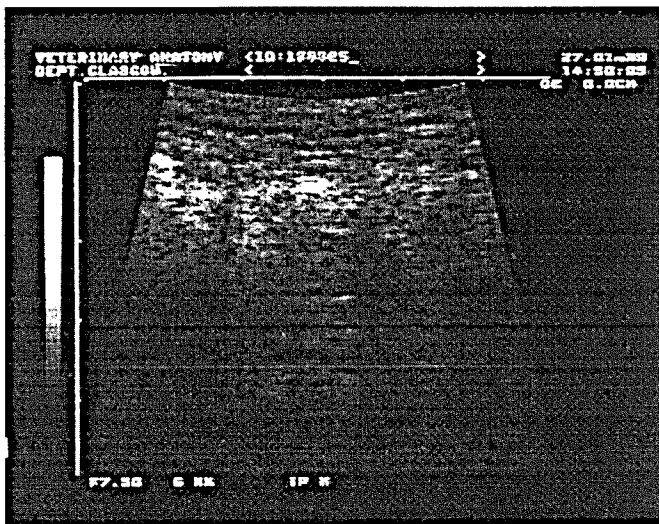


Fig. 2. Longitudinal scan along the ventral abdominal wound approximately 24 hours post-operation demonstrates a disorganised pattern of muscle with intermittent acoustic shadowing which is due to suture material in the skin.

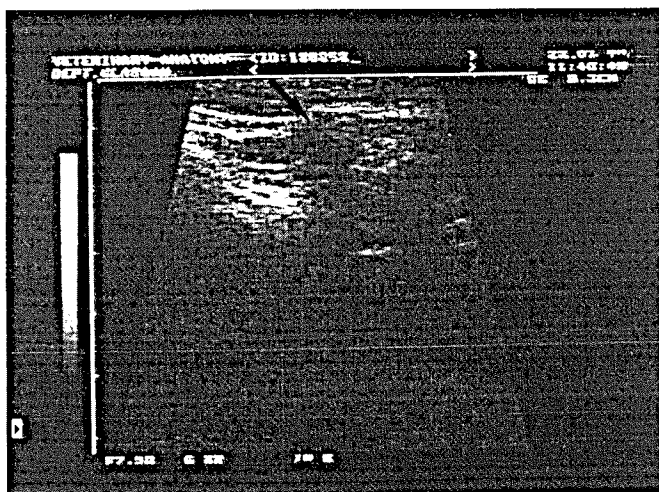


Fig. 3. Transverse scan of the ventral abdominal wound on day two post-operation demonstrates an ill-defined hypoechoic area (arrow) with acoustic shadowing artefact.

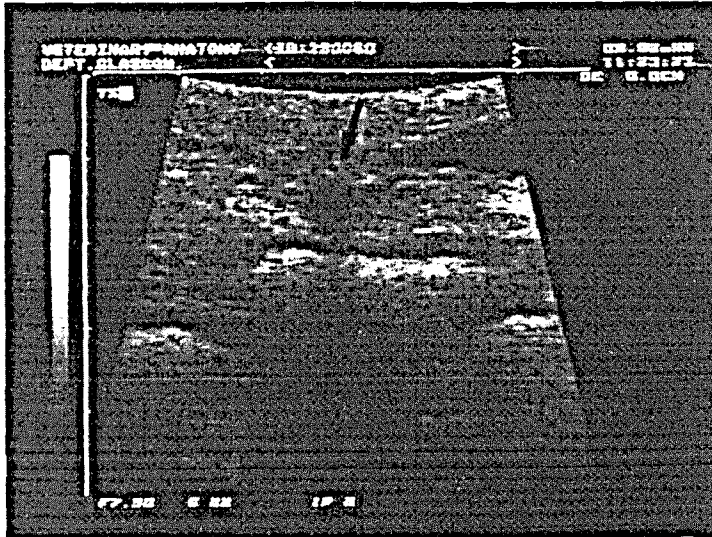


Fig. 4 Transverse scan of the wound on day 11 post-operation demonstrates a disorganised hypoechoic area (arrow) with an echogenic centre and casting acoustic shadowing artefact. The echogenic area of the wound is suggestive of the presence of fibrous tissue formation which is essential for the wound healing process. Note also the area surrounding the surgical site appears disorganised suggestive of soft tissue damage.

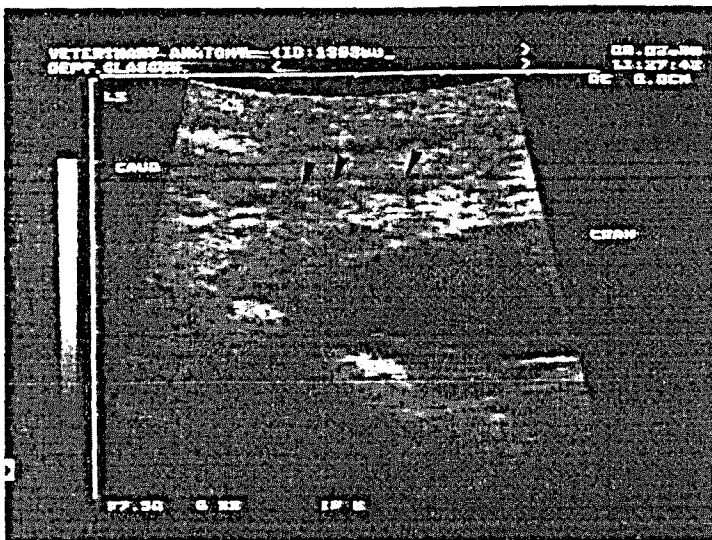


Fig. 5 Longitudinal scan of the ventral abdominal wound on day 11 post-operation demonstrates a disorganised hypoechoic to echogenic structure representing the area of muscle damage with intermittent acoustic shadowing artefacts emanating from the ill-defined hypoechoic areas (arrow heads). These hypoechoic areas are actually the original site of the suture material and have been filled by serum and cellular debris.

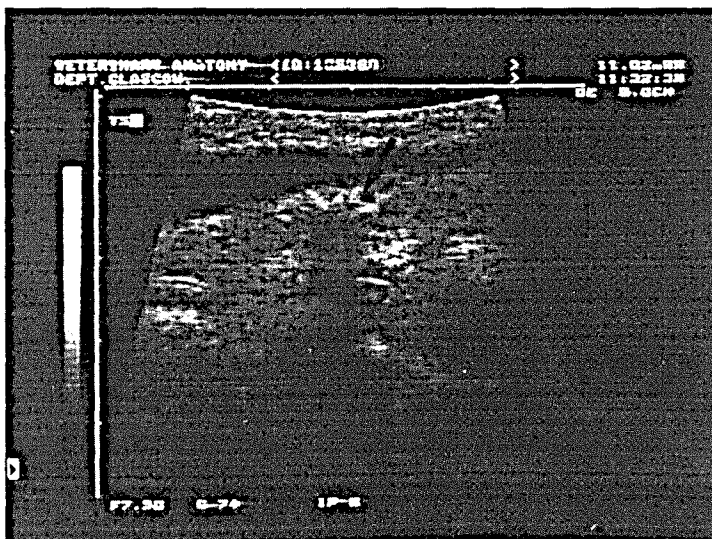


Fig. 6. Transverse scan of the ventral abdominal wound on day 11 post-operation demonstrates a disorganised echogenic area (arrow) casting an acoustic shadowing artefact. The area surrounding the surgical site appears more organised than on the previous scan. Note also the fluid filled area is still present.

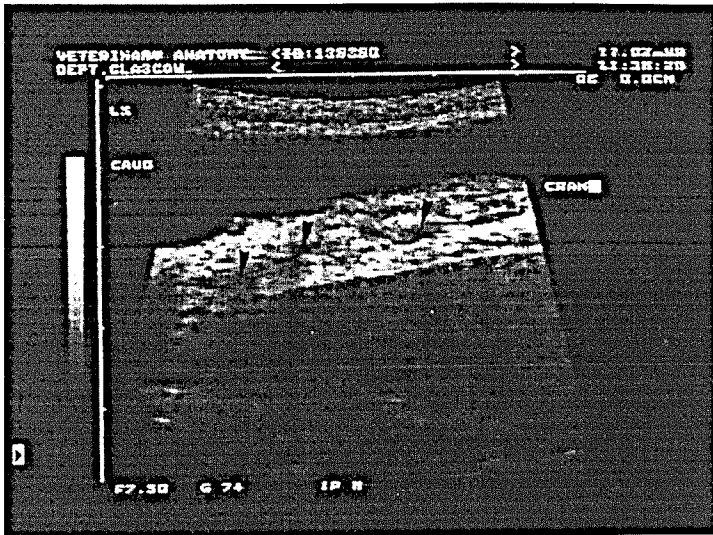


Fig. 7. Longitudinal scan of the ventral abdominal wound on day 13 post-operation demonstrates a disorganised echogenic area representing the muscle damage with the presence of fibrous tissue formation. Small hypoechoic areas (arrow heads), which are casting intermittent acoustic shadowing artefacts are still visible but appear smaller than on the day 11 examination. These hypoechoic areas represent the site of suture material undergoing reabsorption. The overall increase in echogenicity is due to acoustic enhancement artefact caused by fluid accumulation.

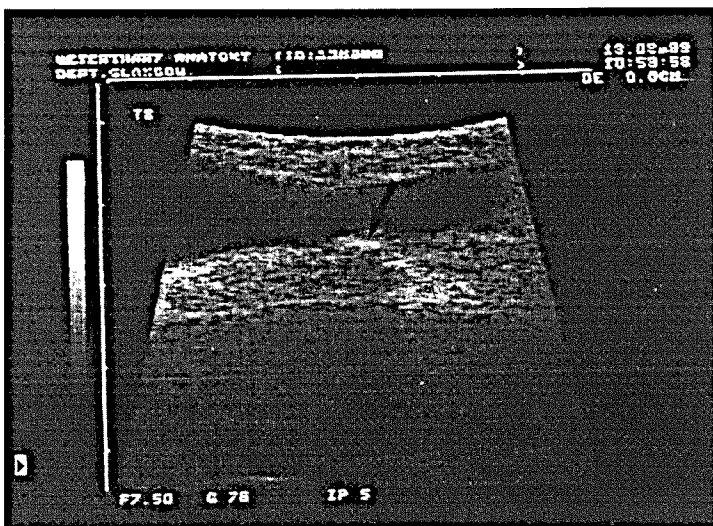

Fig. 8. Transverse scan of the ventral abdominal wound on day 15 post-operation demonstrates a disorganised hyperechoic area (arrow) with acoustic shadowing artefact. Fibrous tissue appears to have an hyperechoic appearance compared to the image on the day 13 post-operation. The large fluid accumulation between the subcutaneous tissue and rectus abdominis muscle is still present.

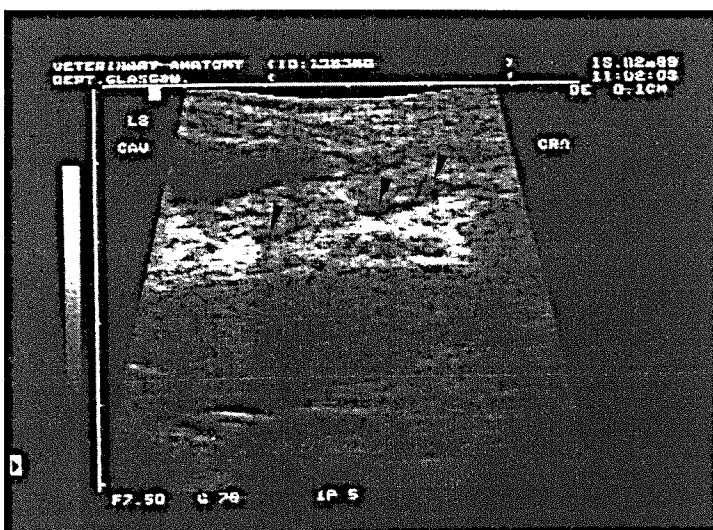


Fig. 9. Longitudinal scan of the ventral abdominal wound on day 15 post-operation demonstrates a disorganised hyperechoic structure with the presence of some hypoechoic areas producing acoustic shadowing artefacts (arrow heads). These small hypoechoic areas within the muscle are actually the site of suture material being reabsorbed and are visible on ultrasound. The disorganised hyperechoic structure is due to the presence of fibrous tissue formation.

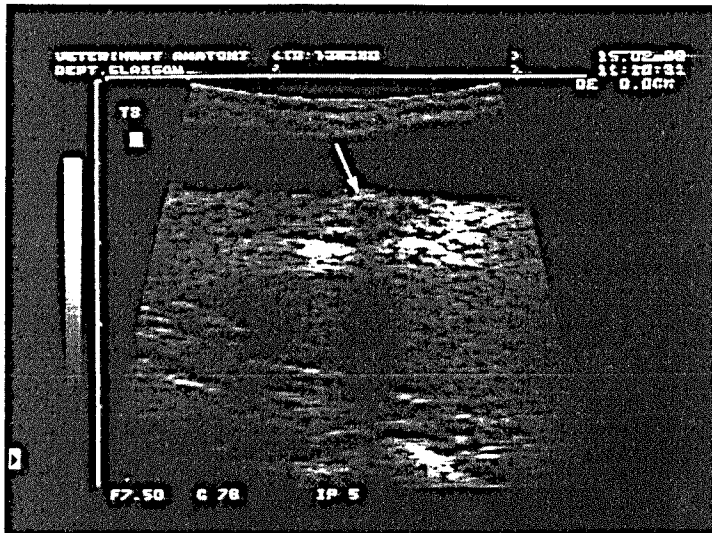


Fig. 10. Transverse scan of the ventral abdominal wound on day 17 post-operation demonstrates a disorganised hyperechoic area (arrow) with acoustic shadowing artefact. The wound appears somewhat smaller than on day 15 examination. The large fluid accumulation is still present and appears as in the previous scan.

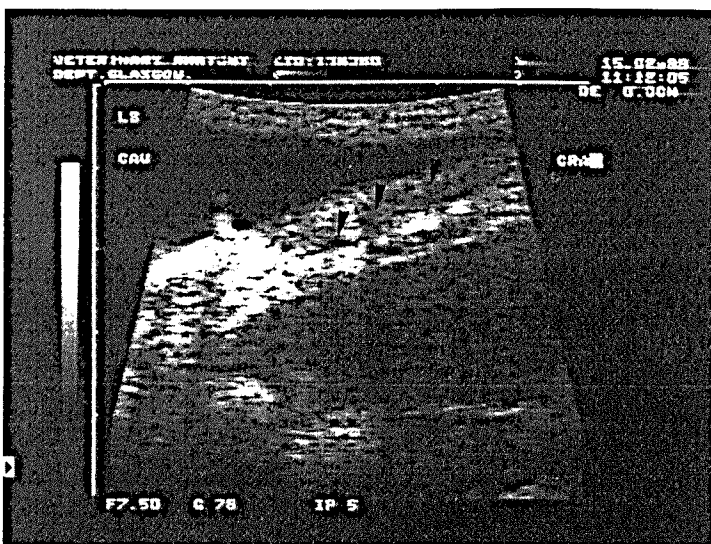


Fig. 11. Longitudinal scan of the ventral abdominal wound on day 17 post-operation demonstrates a disorganised hyperechoic area representing the area of muscle damage and the presence of fibrous tissue formation. Note also the hypoechoic areas (arrow heads) with acoustic shadowing artefacts still visible.

DISCUSSION

The ultrasonographic appearance of wound (surgical site) at the early stage was ill-defined hypoechoic with acoustic shadowing artefact. With time the wound appeared hypoechoic with some degree of an echogenic centre and casting acoustic shadowing artefact. This is consistent with the finding by Wilson *et al.*, (1989). By day 11 post-operation the wound was found to have a disorganised echogenic structure with acoustic shadowing artefact. By day 13 post-operation, the wound appeared as disorganised hyperechoic with acoustic shadowing artefact due to the presence of fibrous tissue formation. It has been reported that the most common finding of fibrosis in muscle was disorganised hyperechoic structure (Laine *et al.*, 1985; Fornage *et al.*, 1983). Thus, it is in accord with the finding in this study. The disorganised hyperechoic structure was suggestive of fibrous tissue formation which is essential for the healing process in soft tissue injury. In a recent study, Kramer *et al.* (1997) reported that muscle healing can be ultrasonographically evaluated. The fibrous tissue

formation in the muscle appeared hyperechoic with or without acoustic shadowing artefact. In addition, development of scar tissue depends on the extent of ruptured muscle fibres.

Ultrasonographic appearance of the suture material in the linea alba has been reported to have a focal hyperechoic appearance with acoustic shadowing artefact (Wilson *et al.*, 1989). Similarly, in this study the suture material used to close the linea alba appeared hyperechoic with acoustic shadowing artefact. In addition, the suture material in the skin produced intermittent acoustic shadowing artefact. The hypoechoic to anechoic areas surrounding the suture material have been observed and described as a suture sinus (Wilson *et al.*, 1989). However, in this study the small areas of hypoechoic to anechoic with acoustic shadowing artefacts in the muscle were observed on day 11 post-operation. They were actually the original sites of suture material in the muscle. It is believed that these hypoechoic to anechoic areas that produce acoustic artefacts are due to serum and blood contained cellular debris. These areas decrease in size with time.

Fluid accumulation at the surgical site not only results from sequestration of inflammatory by-products, but also may be caused by the surgical procedure itself. Dissection performed during surgical approach, soft tissue damage associated with iatrogenic injury, and incomplete haemostasis during surgery may contribute to the accumulation of small amounts of blood or serous fluid during the early post-operative period. The ultrasonographic appearance of fluid collection within the body is well known. Fluid accumulation or oedema may appear relatively anechoic and become echogenic as they are organised (Fornage *et al.*, 1983). Small or thin fluid collections may not show acoustic enhancement artefact (Fornage *et al.*, 1983). In the present study, large fluid accumulation developed in between the subcutaneous tissue and the rectus abdominis muscle at the surgical site and appeared anechoic with acoustic enhancement artefact. The presence of large fluid accumulation at the surgical site increased the overall echogenicity of the ventral abdominal muscle due to acoustic enhancement artefact. With time echogenic material was present within the fluid filled area suggesting that consolidation was taking place.

Results from this study also demonstrate that the wound could be evaluated in both transverse and longitudinal scans. However, the transverse scan seems to be easier than the longitudinal scan in evaluation of the surgical wound. The wound is easily evaluated by comparing with the normal adjacent tissues in transverse scan. In longitudinal scan, the wound required to be scanned more carefully because the wound was mobile when applying pressure. Furthermore, the wound area was thin and at certain points the wound on the skin was not parallel with the wound on the muscle or linea alba.

ACKNOWLEDGEMENTS

The study was conducted at the Glasgow University Veterinary School, Scotland, U.K. under the supervision of Professor J.S. Boyd, Head of Division of Veterinary Anatomy.

REFERENCES

- Berstein, I.T. and Hansen, B.J. (1991). Iatrogenic psoas abscess. *Scandinavian Journal of Urology and Nephrology* **25**: 85-86
- Christensen, R.A., Sonnenberg, E.V., Casola, G. and Wittish, G.R. (1988). Interventional ultrasound in the musculoskeletal system. *Radiology Clinics North America* **26**: 145-156
- Fornage, B.D., Touche, D.H., Segal, P. and Rifkin, M.D. (1983). Ultrasonography in the evaluation of muscular trauma. *Journal of Ultrasound in Medicine* **2**: 549-554
- Glaser, F., Knopp, W. and Muhr, G. (1988). Early recognition of post-operative hematoma formation. *Arch Orthopaedic Trauma Surgery* **107**: 253-255
- Howard, C.B. and Einhorum, M.S. (1991). Ultrasound in the detection of subperiosteal abscess. *Journal of Bone and Joint Surgery [Br]* **73**: 175-176
- Jain, A.K., Kumar, S., Shiv, V., Singh, H. and Tuli, S.M. (1992). Retrofascial pyogenic iliac fossa abscess 20 cases studied by ultrasonography. *Acta Orthopaedic Scandinavica* **63**: 53-56
- Kramer, M., Gerwing, M., Hach, V. and Schimke, E. (1997). Sonography of the musculoskeletal system in dogs and cats. *Veterinary Radiology & Ultrasound* **38**: 139-149
- Lehto, M. and Alanen, A. (1987). Healing of a muscle trauma: correlation of sonographical and histological findings in an experimental study in rats. *Journal of Ultrasound Medicine* **6**: 425-429
- Laine, H., Harjula, A., and Peltokallio, P. (1985). Experience with real time sonography in muscle injuries. *Scandinavian Journal of Sports Science* **7**: 45-49
- Parrini, L., Baratelli, M. and Parrini M. (1988). Ultrasound examination of hematomas after total hip replacement. *International Orthopaedics* **12**: 79-82
- Trout, N.J., Penninck, D.G., Boudrieau, R.J. and Kudisch, M. (1994). Early postoperative ultrasonographic evaluation of incisional sites in dogs: 15 cases (1990-1992). *Journal of American Veterinary Medical Association* **205**: 1565-1568
- Wilson, D.A., Badertscher, R.R., Boero, M.J., Baker, G.J. and Foreman, J.H. (1989). Ultrasonographic evaluation of the healing of ventral midline abdominal incisions in the horse. *Equine Veterinary Journal Suppl* **7**: 107-110

RINGKASAN

ULTRASONOGRAFI IMEJAN KEATAS KEMAJUAN PENYEMBUHAN LUKA SELEPAS PEMBEDAHAN ABDOMEN PADA ANJING

Kajian ini telah dilakukan dengan tujuan untuk menilai kemajuan penyembuhan luka abdomen selepas pembedahan dan mengesan sebarang perubahan yang mungkin berlaku semasa proses pemaikpulihan dengan menggunakan mesin ultrabunyi mod-B. Lima ekor anjing yang berlainan baka, jantina dan umur digunakan dalam kajian ini. Pembedahan pada ventral abdomen anjing-anjing ini dilakukan diatas sebab-sebab yang tertentu. Mesin ultrabunyi masa-sebenar mod-B (Capasee TOSHIBA) disambungkan kepada pengarah berfrekuensi 7.5 MHz telah digunakan. Pemeriksaan ultrasonografi telah dilakukan secara melintang pada garisan tengah abdomen dari kranium ke kauda, dan secara memanjang disepanjang luka dari kranium ke kauda. Imbasan awal dilakukan pada hari pertama selepas pembedahan. Imbasan berikutnya dilakukan selang sehari selagi anjing masih berada dalam hospital. Gambar ultrasonografi luka (tempat pembedahan) pada mulanya kelihatan hypoechoic dan menghasilkan artifak teduhan akaustik. Kemudian luka menjadi hypoechoic bercampur dengan bahan echogenik dan menghasilkan artifak teduhan akaustik. Pada hari ke 11 selepas pembedahan, luka kelihatan menjadi struktur echogenik tak teratur. Pada hari ke 13 selepas pembedahan, luka kelihatan seperti hyperechoic tak teratur dan menghasilkan artifak teduhan akaustik disebabkan kehadiran tisu fibrus. Hasil dari kajian ini juga menunjukkan yang luka boleh dinilai secara imbasan melintang dan juga memanjang pada luka. Walaubagaimanapun, imbasan melintang adalah lebih senang dari imbasan memanjang bagi menilai luka pembedahan.