

Case Study

Sarcoma of the Heart: a Rare Intracardiac Tumor and Review of Literature

¹MR Norhafizah, ²MD Noraini, ³AM Sakr, ¹MS Shiran & ¹MA Razana

¹Department of Pathology, Universiti Putra Malaysia

43400 UPM Serdang, Selangor, Malaysia

²Department of Pathology, Hospital Kuala Lumpur, Jalan Pahang

50586 Kuala Lumpur

³Hospital Umum Sarawak, Jalan Tun Ahmad Zaidi Aduce, 93586 Kuching, Sarawak

ABSTRACT

Primary sarcomas of the heart are exceptionally rare and are aggressive tumours. We report a 38-year-old Chinese lady who had an intermediate grade sarcoma with myofibroblastic differentiation. The tumour was found in the right atrium. Literature reviews of rare intracardiac sarcomas are discussed.

Keywords: Cardiac tumours, myofibroblastic sarcoma, right atrium

INTRODUCTION

Primary tumors of the heart are rare, accounting for only 0.001-0.28% of autopsy cases in the general population with 75% of the cases reported as benign.^[1] The most common benign tumors are myxomas, which constitute approximately 50% of primary cardiac tumours. Primary cardiac sarcomas are the most common among malignant primaries; accounting for 25% of all primary cardiac tumors.^[2] We report a rare case of cardiac sarcoma in the right atrium. The tumour was composed of spindle shaped mesenchymal cells with increased mitoses and focal necrosis that corresponded to Grade 2 of the French Federation Nationale des Centres de Lutte Contre le Cancer (FNCLCC) grading system.

THE CASE

A 38-year-old Chinese lady was apparently well until she presented with history of shortness of breath and palpitation for one-month duration. There were no other associated symptoms. There was no significant past medical or surgical history. On examination, there was severe mitral stenosis and moderate mitral regurgitation. Echocardiography was done and showed a large mass in the left atrium measuring 60 x 20 mm, obstructing the mitral inlet. An urgent surgical excision of the mitral mass and atrial septum closure with Dacron patch was performed. The specimen was sent for histopathological evaluation.

The gross examination revealed a whitish lobulated and smooth surfaced tumour measuring 60 x 20mm in greatest diameter. Histologically, the tumour was composed of cellular fascicles of spindle cells with fairly uniform size (Figure 1). The nuclei were spindle-shaped. Mitotic activity was 13/10 high power fields. Zonal areas of necrosis were identified (10% tumour necrosis). There was no significant pleomorphism, atypia or lymphoplasmacytic infiltrate. Focal 'staghorn' vascular pattern and cystic areas were also identified. There was infiltration of the tumour cells into adjacent muscle and nerve bundles. Immunohistochemically, the tumour cells were positive for vimentin and smooth muscle actin but negative for factor VIII related antigen, CD34, desmin, bcl-2, CD99, S-100 protein and cytokeratin (Figures 2 and 3). Histological grading of this tumour was evaluated by using the FNCLCC grading system (modified from Trojani *et al.*). The tumour showed score-2 for tumor differentiation, score-1 for necrosis and score-2 for mitotic figures. Based on the histopathological features and immunohistochemistry findings, a diagnosis of intermediate grade sarcoma, Trojani Grade 2 with myofibroblastic differentiation was made.

Post-operatively, the patient developed partial right limb tonic clonic seizures a few hours after the operation. The seizures were settled after administration of intravenous phenytoin. Computed tomography of brain showed right middle cerebral artery infarct with midline shift and increased intracranial pressure. There was no evidence of metastases in the brain. An emergency decompression craniotomy was performed. Following this her condition improved although recovery was slow. Three weeks later she was discharged from the hospital with a Glasgow Outcome Scale of 2/5 and was put on stroke rehabilitation team follow-up. She was also referred to a psychiatrist for depression. She was readmitted for cranioplasty and there was no complication. Her left sided limb power improved to 3/5

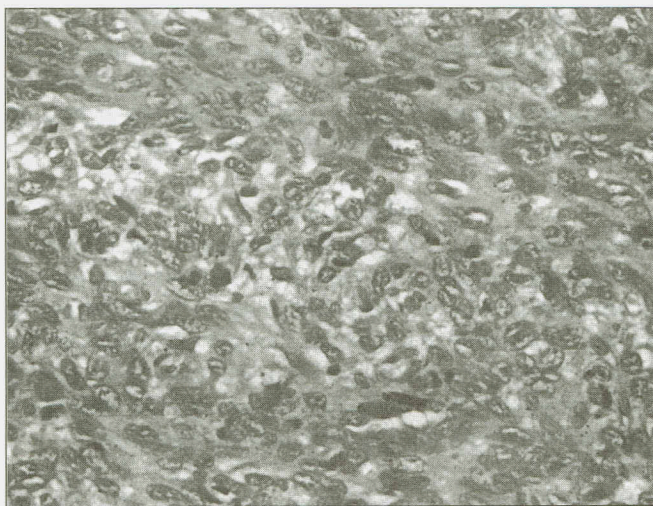


Figure 1. Photomicrograph shows hypercellular tumor with spindle shaped cells of fairly uniform size (Hematoxylin and eosin stain, x400)

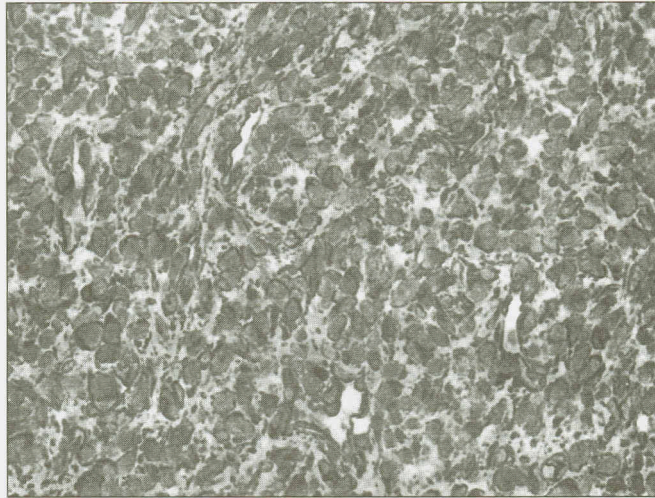


Figure 2. Tumour cells show strong immunopositivity to vimentin (Immunohistochemical stain, x400)

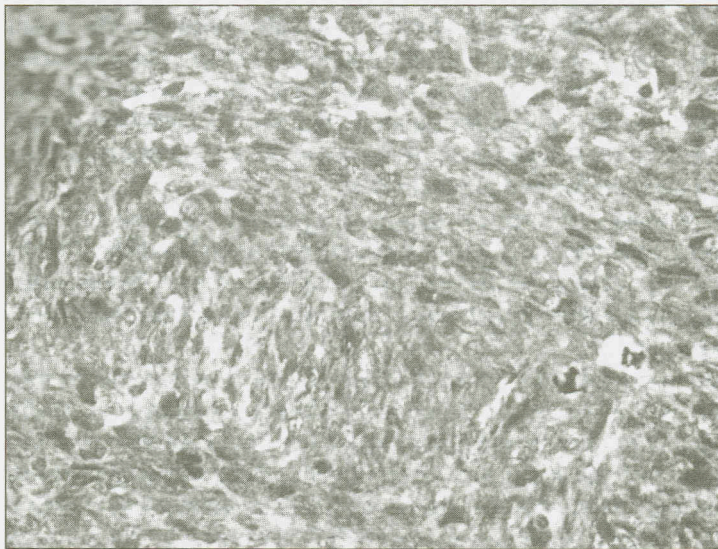


Figure 3. Tumour cells show strong immunopositivity to smooth muscle actin (Immunohistochemical stain, x400)

and she was alert and conscious. During the last follow-up there was no evidence of metastases. There was no adjuvant chemotherapy or radiotherapy administered to the patient.

DISCUSSION

Sarcomas of the heart are exceptionally rare. The largest post-mortem study reported by the American Medical Association showed the prevalence of primary cardiac tumours to be only 0.0017%. In primary cardiac tumours of the adults, one quarter of cases are malignant; most are sarcomas. Mean age at presentation of patients with primary cardiac sarcoma is 41 years (range 1-80 years).^[3] Cardiac sarcomas occur in adults without any sex predilection. Although it may arise in any area of the heart, Burke *et al* reported that malignant tumours were more frequently found in the right side of the heart and that benign neoplasms were more common on the left side with an equal distribution of cardiac sarcoma between the right and left sides of the heart. Right heart sarcomas infiltrate widely and metastasize early.^[4] Left heart sarcomas, although larger, are less infiltrative and metastasize later than right heart sarcoma.^[5] Cardiac sarcomas may involve the outer surface of the heart or they may be intracavitary or within the muscle wall.

The symptoms of primary cardiac sarcoma vary and depend on its location. The tumours usually remain asymptomatic, as seen in our patient, until they produce a mass effect by obstructing cardiac output, invade or embolise. Patients may present with intractable congestive heart failure, arrhythmias or signs of superior vena cava obstruction. It may also result in myocardial infarction, syncope and/or sudden death. In rare cases, a metastatic lesion is the first manifestation of the disease.^[1, 2, 3, 6]

Chest X-ray is of little value for detection of cardiac sarcomas. The most widely used diagnostic procedure is echocardiography. The tumour shape, size and surface are better delineated by magnetic resonance imaging (MRI). A combination of echocardiography and MRI also helps to detect and evaluate tumour extension. Computed tomography (CT) scan is also very useful for the diagnosis of cardiac masses in complementing echocardiography as it is more widely available compared to MRI.^[7]

Tissue sampling is the only method for a definitive diagnosis of cardiac sarcoma. Grossly, most of the tumors are polypoid or filiform with smooth surface. The most frequently encountered histologic subtypes are angiosarcoma, leiomyosarcoma and rhabdomyosarcoma. Others include myxosarcoma, osteosarcoma, synovial sarcoma and neurofibrosarcoma.^[1, 2, 6]

The histological type of sarcomas does not always provide sufficient information for predicting the clinical course and therefore for planning of therapy. A grading system is used to evaluate the degree of malignancy and mainly the probability of distant metastasis and overall survival. As in our case, sarcomas are graded by using Modified Trojani or FNCLCC grading system, which is based on tumour differentiation, tumour necrosis and mitotic count. Coindre *et al* reported that the FNCLCC grading system was the most important predictive factor for metastases of pleomorphic sarcoma, unclassified sarcoma and synovial sarcoma, and the second and third independent factor for leiomyosarcoma.^[7] In the past it was difficult to confidently identify the differentiation of cardiac sarcomas. Precise

identification of potential differentiation is made possible with the use of monoclonal antibodies. A useful panel of antibodies includes vimentin, cytokeratin, epithelial membrane antigen (EMA), desmin, smooth muscle actin, sarcomeric actin, specific muscle actin, CD 31, CD 34, CD 68, S100 protein and Factor VIII related antigen.^[3] In our case, the tumor cells showed myofibroblastic differentiation as demonstrated by immunopositive smooth muscle actin staining. However, the exact subtype could not be determined as further immunohistochemical staining was not supportive.

Electron microscopy is usually helpful to ascertain tumour differentiation in difficult cases. For example, demonstration of microfilaments, dense bodies and discontinuous external lamina are compatible with myofibroblastic differentiation. However, some of the cardiac sarcomas are unclassifiable even with the help of ultra structural and immunohistochemical techniques. These were consistent with a series of 10 endocardial-based spindle cell tumors with myofibroblastic proliferation of uncertain classification reported at the Armed Forces Institute of Pathology between the years of 1993 and 2006.^[8]

Surgery is the principle modality of treatment in cardiac sarcoma. However, it is often difficult if the tumour is too large, as complete resection cannot be achieved. The role of post adjuvant radiation and chemotherapy remains controversial and has not been proven to be consistently beneficial. A study by Donsbeck *et al.* showed that adjuvant chemotherapy and/or radiotherapy does not prevent local recurrence or visceral metastases. However adjuvant chemotherapy or radiotherapy can be beneficial in improving the quality of life. For treatment of sarcomas, many authors agree that the value of systemic chemotherapy depends on the specific histological subset of the sarcoma.^[5,7,9]

Prognosis for patients with cardiac sarcoma is dismal irrespective of treatment. Mean survival was reported as 16.5 months after diagnosis. By multivariate analysis, a low level of mitotic activity and any type of therapy were the only significant factors affecting the survival rate.^[4,6,9] Favourable prognosis factors include left sided tumours, absence of necrosis, low mitotic count and absence of metastasis at diagnosis. Age, gender, presence of differentiation and histologic type do not affect prognosis. However, histologic grading is useful in predicting the outcome, as has also been shown for soft tissue sarcomas of other sites. Local recurrence occurs in 50% of cases, even in cases of complete resection. The more common sites of metastases include lungs, long bones, adrenal, brain and pleura.^[7,9]

CONCLUSION

Cardiac sarcomas are a rare entity. Because of the rarity of such cases, a careful histological evaluation and a panel of antibodies are required for the diagnosis. The other important issue is the treatment of choice for cardiac sarcomas. There is still in doubt as to what is the best guideline for management of such cases.

REFERENCES

- [1] Reynen K. Frequency of primary tumors of the heart. *American Journal of Cardiology* 1996; 77:107.
- [2] Burke AP, Cowan D, Virmani R. Primary sarcomas of the heart. *Cancer* 1992; 69:387-395.

- [3] Gandy KL, Burtelow MA, Reddy VM *et al.* Myofibroblastic tumor of the heart: a rare intracardiac tumor. *Journal of Thoracic & Cardiovascular Surgery* 2005; 130:888-889.
- [4] Reardon, Micheal J, Walkes, Jon-Cecil, Benjamin, Robert. Therapy insight: malignant primary cardiac tumours. *Nature Clinical Practice Cardiovascular Medicine* 2006; 3(10): 548-553.
- [5] World Health Organization Classification of Tumours, Tumours of Soft Tissue and Bone, Lyon: IARC Press, 2002.
- [6] World Health Organization Classification of Tumours, Tumours of the Lung, Pleura, Thymus and Heart, Lyon: IARC Press, 2004.
- [7] Donsbeck AV, Ranchere D, Coindre JM, Le Gall FS, Cordier JF, Loire R. Primary cardiac sarcoma: an immunohistochemical and grading study with long-term follow-up of 24 cases. *Histopathology* 1999; 34(4): 295-304.
- [8] Burke AP, Li L, Kling E, Kutys R, Virmani R, Miettinen M. Cardiac inflammatory myofibroblastic tumor: a benign neoplasm that may result in syncope, myocardial infarction, and sudden death. *American Journal of Surgical Pathology* 2007; 31(7): 1115-1122.
- [9] Sarjeant, Jeniffer M, Butany, Jagdish *et al.* Cancer of the heart, epidemiology and management of primary tumor and metastasis. *American Journal of Cardiovascular Drugs* 2003; 3(6): 407-421.