

# We are IntechOpen, the world's leading publisher of Open Access books Built by scientists, for scientists

5,500

Open access books available

136,000

International authors and editors

170M

Downloads

Our authors are among the

154

Countries delivered to

TOP 1%

most cited scientists

12.2%

Contributors from top 500 universities



WEB OF SCIENCE™

Selection of our books indexed in the Book Citation Index  
in Web of Science™ Core Collection (BKCI)

Interested in publishing with us?  
Contact [book.department@intechopen.com](mailto:book.department@intechopen.com)

Numbers displayed above are based on latest data collected.  
For more information visit [www.intechopen.com](http://www.intechopen.com)



# Non-Invasive Diagnostics in Acute Compartment Syndrome

*Richard Martin Sellei, Philipp Kobbe and Frank Hildebrand*

## Abstract

Diagnosis of acute compartment syndrome (ACS) of the extremities is based on clinical signs with or without complementary measurement of muscle compartmental pressure. However, in cases of imminent compartment syndrome, unconscious patients or children the appropriate diagnose remains challenging. Despite all efforts to improve technical devices to objectify the signs by measurements of numerous parameters, needle compartment pressure measurement is to date accepted as the gold standard to facilitate decision making. But its invasiveness, the controversy about pressure thresholds and its potentially limited validity due to a single measurement support the need for further developments to diagnose ACS. Numerous technical improvements have been published and revealed promising new applications for non-invasive diagnostics. Since the pathology of an ACS is well characterized two approaches of measurements are described: to detect either increasing compartmental pressure or decreasing perfusion pressure. In the following, currently known investigations are reviewed and related to their pathophysiological principals, modes of clinical application, value and reliability.

**Keywords:** diagnostics, non-invasive, acute compartment syndrome, technical approaches

## 1. Introduction

Acute compartment syndrome (ACS) is characterized by an increasing intra-compartmental pressure (ICP) provoked by intrinsic or extrinsic reasons [1, 2]. The consecutive muscle swelling due to a decreased perfusion pressure results in an impaired microcirculation and an additional increase of ICP [3]. The rise in venous pressure and cellular hypoxia causes further tissue oedema and swelling within the compartment finally concluding in the vicious circle of ACS [1, 4]. Numerous cases of different causes and heterogenous clinical appearances of ACS are presented in the literature. Differences in the velocity and severity of ACS development lead to a substantial heterogeneity of clinical findings. The initial clinical suspicion and awareness about a possible ACS by the physician itself is one of the most important issues not to miss the diagnose. The history and clinical findings of the affected patient alone resulted in a low positive predictive value. However, the negative predictive value to exclude an ACS by the clinician is as high as 98% [5]. The prompt diagnosis of the ACS is crucial to obviate the potential devastating clinical results after an overlooked or delayed recognition of an ACS. Hence, there is a reasonable need for complementary technical applications to facilitate and to objectify the presented condition of the muscle

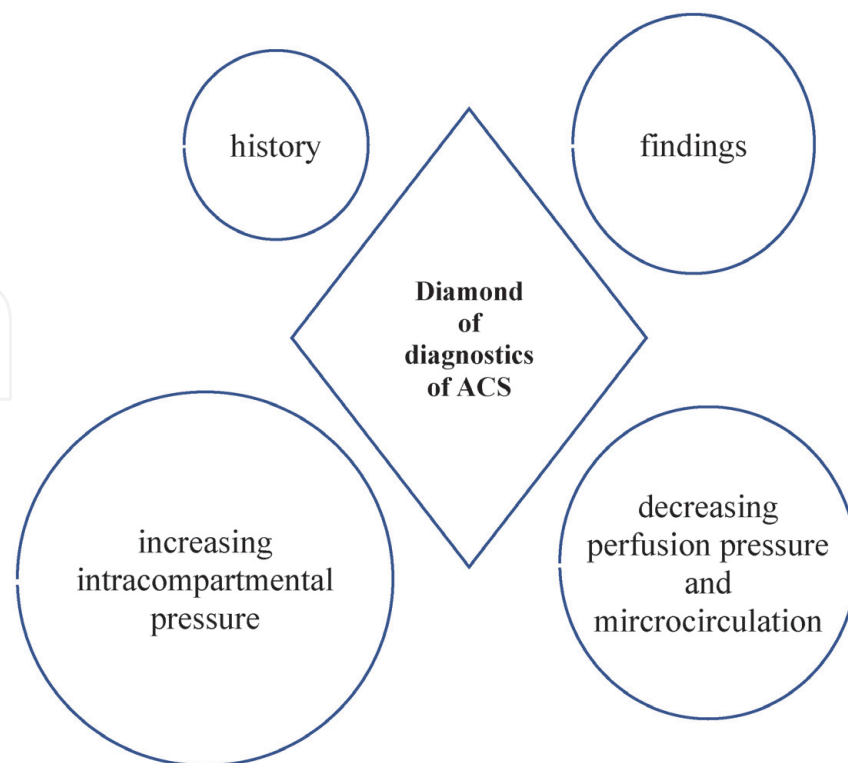
compartment. This uncertainty in diagnostics finally results in a high probability of over diagnose ACS following unnecessary fasciotomies.

## 2. Diagnostics and clinical investigations in ACS

By reason of continued controversy regarding the value and interpretation of compartmental pressure monitoring numerous scientific approaches have published over the last three decades. To date, none of the innovative techniques persuaded the clinician to replace invasive compartmental pressure monitoring by a new instrument or application. This certainty allows to conclude, that further developments of basic investigations are needed to assess either the increasing pressure or the decreasing perfusion pressure. The desired innovation of an additional technical investigation should provide specific requirements:

- Non-invasiveness
- Simplicity and possible repetitive/continuous application
- Clear threshold for the need of surgical intervention
- High inter- and intra-observer reliability
- Low cost and easily available application

Regarding the mentioned requirements different approaches are conceivable to achieve the improvements in clinical investigations (**Figure 1**).



**Figure 1.**

*The suspicion of an ACS allows to pursue the assumed diagnosis. The history of injury, the clinical findings and objectified diagnostics lead to the diagnosis or disclosure of an ACS. Decreased perfusion pressure provokes a disturbed microcirculation and results in increasing intra-compartmental pressure by a proceeding oedema. These four pathophysiological columns create the basic principles of diagnostics: The diamond of diagnostics of ACS.*

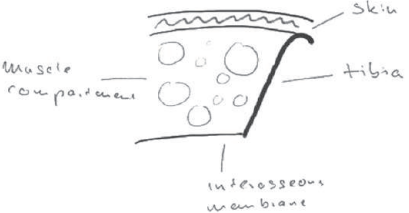







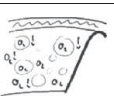
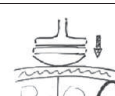
### 3. Non-invasive diagnostics in acute compartment syndrome

#### 3.1 Clinical findings

The clinical findings of the clinician are caused by one of the two fundamental pathophysiological mechanisms such as decreasing perfusion pressure with compromised microcirculation and/or increased intra-compartmental pressure. These two major mechanisms aggravate each other and lead to the clinical red flag signs summarized by the seven P's (pressure, pain out of proportion, pain with passive stretching, paresthesia, paresis, pink skin color, pulses present) [6]. As a result of a major uncertainty to indicate fasciotomy by clinical assessment only, the technical efforts in innovations concentrate on changes of the above mentioned parameters.

#### 3.2 How can we objectify our findings non-invasively?

Many excellent approaches have been published over the last decades to objectify the parameters in order to exclude ACS or to substantiate imminent such as acute compartment syndrome. All of them can be categorized by terms of the pathology and parameter which is measured. The non-invasive approaches to diagnose ACS can be discriminated by the detection of a decreased perfusion pressure and reduced microcirculation or the increased pressure within the muscle compartment (**Table 1**).

Non-invasive diagnostics and measurements of ACS pathophysiology	
Decreasing perfusion pressure	Increasing compartmental pressure
 Infrared imaging	 Imaging
 Pulse oximetry	 Tissue hardness measurement
 Laser doppler flowmetry (LDF)	 Pulsed phase locked loop ultrasound (PPLL)
 Contrast enhanced ultrasound (CEUS)	 Shear wave elastography (SWE)
 Near-infrared spectroscopy (NIRS)	 Pressure related ultrasound (PRUS)

**Table 1.** Non-invasive approaches of diagnostics to identify and to objectify an acute compartment syndrome.

## **4. Noninvasive measurement of surrogates of decreased perfusion pressure**

### **4.1 Infrared imaging**

Infrared imaging to measure the surface temperature was used to detect ACS of the affected lower leg by comparison with the uninjured limb. The aim of this application was to use a portable and non-invasive technology, for detecting ACS in patients with multiple trauma [7]. The hypothesized reduction in surface temperature has been proven in a clinical study. The authors used an index of temperature measurements of the proximal vs. distal limb (thigh-foot-index) and showed a significant difference in patients developing ACS in 167 cases. They concluded that infrared imaging may support early detection of ACS in trauma patients based on correlation between a decreasing perfusion pressure and an increased difference of the temperature index. However, thresholds of the index are difficult to define, especially in trauma patients.

### **4.2 Pulse oximetry**

Pulse oximetry was examined to detect the decreasing perfusion pressure in case of ACS as it has been advocated as a simple non-invasive investigation of vascular compromise nearly thirty years ago [8]. Whilst a significant decrease of oxygen saturation was detected, the sensitivity of 40% was low. Therefore, this application was conceded [9].

### **4.3 Pulsed doppler ultrasound**

Mc Loughlin et al. hypothesized that a diastolic retrograde arterial flow (DRAF) may represent an early sign of ACS. They therefore mimicked a compartment syndrome by using a cuff inducing external compression of the forearm with increasing pressure in two patients. The authors showed a strong correlation of DRAF (%) with the degree of external pressure applied and concluded that this technique may represent a useful tool in detection and evaluation of ACS [9]. To our knowledge no further work was published pursuing this application.

### **4.4 Laser doppler flowmetry**

Abraham et al. investigated the direct measurement of muscle blood flow with laser doppler flowmetry (LDF) compared with the intracompartmental pressure measurement in patients with chronic compartment syndrome (CCS) [10]. In the CCS group a delayed hyperaemic peak in muscle blood flow was detected. They concluded that LDF should be investigated further as a technique for diagnosis of CCS. In the literature, no evaluation of LDF in ACS was found.

### **4.5 Contrast enhanced ultrasound (CEUS)**

Geis et al. used contrast enhancement in ultrasound to detect the compromised perfusion pressure and to monitor changes of microcirculation in ACS. In a clinical study, eight patients with ACS underwent a B-mode ultrasound examination using a multifrequency probe. An intravenous bolus injection of a contrast agent resulted in a colored visualization of microperfusion. A time-intensity-curve was analyzed retrospectively and quantified by a software. Parameters as time-to arrival (TTA), peak of signal intensity (%), time-to peak (TTP), the regional blood volume (RBV), the

regional blood flow (RBF), and the mean-transit-time (MTT) were calculated and resulted in significant differences in case of ACS [11]. The authors concluded that CEUS may be capable of differing between ACS and an imminent compartment syndrome. These results were supported by a volunteer study with a simulated decrease of perfusion pressure by tourniquet of the thigh [12]. However, the bolus application of a contrast agent and its possible undesirable effects, particularly in patients with pre-existing cardio-vascular illness, refuses further clinical application of this technology.

#### **4.6 Near-infrared spectroscopy (NIRS)**

The invasive measurement of the oxygen partial pressure has been examined in animal models [13] and in clinical studies [14]. These investigations demonstrated a correlation of decreasing local muscle tissue oxygenation and increasing pressure due to ACS. The sensitivity and specificity of the partial pressure oxygenation of less than 30 mmHg as a threshold in an animal model showed excellent results [15] and have been confirmed in a non-invasive technique of oxygen saturation measurement by near-infrared spectroscopy (NIRS) [16]. This approach assessed the level of oxygenated muscle hemoglobin and muscle myoglobin. With the decreased blood flow after trauma-induced ACS, a reduction in local oxygen saturation as well as oxygen tension was detected [17]. In animal models, NIRS showed a clear correlation between decreased tissue oxygenation and reduced muscle perfusion pressure [18]. In further clinical studies using NIRS, the strength of non-invasive techniques for monitoring of affected limbs was emphasized [19, 20].

However, the reliability of NIRS measurements as a single parameter in monitoring ACS showed poor values [21]. The main limitations in this approach are constrained depth of penetration (30-40 mm), variables affecting penetration and reflection of radiated infrared light signal (e.g. melanin), the lack of appropriate threshold for ACS indicating fasciotomy and the effect of hypotension and hypoxia in trauma patients on the measurement. However, with further technical developments NIRS has the potential to be used in monitoring trauma patients with imminent compartment syndrome or even be able to indicate the need for surgical intervention.

#### **4.7 Dynamic phosphorous-31 magnetic resonance spectroscopy**

Recently Otha et al. utilized dynamic phosphorous-31 magnetic resonance spectroscopy ( $^{31}\text{P}$ -MRS) for visualization of metabolic changes as surrogate of muscle ischemia in an animal model [22].  $^{31}\text{P}$ -MRS is able to dynamically monitor the rate of inorganic phosphate (Pi) depletion and synthesis, phosphocreatine (PCr), intracellular pH and mitochondrial oxidative capacity. They demonstrated a significant decrease of the PCr/(Pi+PCr) ratio after inducing ischemia in an ACS model with rats. The intracellular and arterial pH index also decreased over time significantly. The authors concluded, that this noninvasive imaging approach rapidly detects metabolic changes in the muscle compartment and may represent a non-invasive method for determining early damage in ACS in the future.

#### **4.8 Phonomyography**

Martinez et al. used acoustic myography (Phonomyography) to measure the degree of muscle ischemia in an animal model [23]. After 30 minutes of simulated ischemia, the signal from the calf musculature provoked by stimulation of the sciatic nerve in the thigh, decreased significantly at 55%. At 120 minutes of ischemia, the signal dropped at 68%. In conclusion, the

authors recognized phonomyography as a non-invasive method for continuous monitoring of patients with ACS.

## **5. Noninvasive measurement of surrogates of increased intra-compartmental pressure**

### **5.1 Imaging**

The imaging of muscle compartments developing an ACS was insufficient to detect early morphological changes. B-mode ultrasound imaging [24] as well as MRI imaging [25] was described as potential methods to detect severe pathologies (e.g. muscle swelling or necrosis). However, imaging alone does not reliably detect pathological changes in an early stage of an ACS. In a clinical study, Gershuni et al. identified a correlation between enhanced pressure and increasing volume of the tibial anterior compartment after exercise by B-mode ultrasound in the cross-section view [26]. Rajasekaran et al. presented a significant increase in muscle compartment thickness in patients with chronic exertional compartment syndrome compared with control subjects after exertion using ultrasound [27]. Wang et al. measured the thickness of the anterior compartment in twenty acute trauma cases. The thickness and the ICP were significantly increased compared to the uninjured lower limb, but the increase in ICP did not show a significant correlation with the change in thickness of the injured lower leg [28].

Beside the thickness of the compartment in a feasibility study, the ultrasound-guided angle measurement as a surrogate of increased pressure was investigated in a human cadaver model of ACS. The authors measured the tibia-fascia angle (TFA) between the anterolateral cortex of the tibia and the tangent to the curving anterior compartment fascia with its origin at the tibial attachment. Measurements in forty specimens resulted in a mean TFA of  $61.0^\circ (\pm 12^\circ)$  at 10 mmHg. Each increase in pressure by 3.9 mmHg was associated with an increase of TFA by one degree. The inter-observer reliability was good (ICC 0.77). The authors concluded that the increasing ICP of the anterior tibial compartment can be estimated well by ultrasound-based TFA measurement post mortem. However, the authors also stated that the findings are too preliminary to be used in clinical practice [29].

### **5.2 Tissue hardness measurement**

Over the last three decades non-invasive diagnostic principles have been introduced and enhanced. Several authors showed promising results when investigating the soft-tissue elasticity. In a study of 75 cases of suspected ACS, a noninvasive hardness measuring device was included. Upper and lower extremities were tested. ICP pressure values and hardness ratios were compared to one another as continuous variables. Due to the low specificity of the noninvasive measurement of hardness compared to the invasive pressure measurement, the authors concluded that the use of the hardness monitor has no potential to determine the diagnosis of compartment syndrome [30]. In a feasibility study of healthy volunteers and patients with chronic myofascial neck pain syndrome a soft tissue stiffness meter was evaluated to measure the soft tissue stiffness (STS) in the form of the instantaneous force (N) by which the tissue resists the constant deformation produced by a cylindrical indenter. The resulting data of a hand-held computerized soft tissue stiffness meter (STSM) in index muscles (e.g. m. trapezius and m. levator scapulae muscle) resulted in a linear, positive relationship between the indenter force (N) and the dynamic compressive modulus (MPa) of elastomer stiffness. The authors

concluded that STSM assessment can evaluate the tissue stiffness quantitatively and yield reproducible data [31]. Steinberg et al. first introduced in 1994 a hardness meter to determine the quantitative muscle compartment hardness in six dogs and three anatomical specimen limbs simulation ACS by plasma injection into the index compartment. In six patients with suspected ACS the quantitative muscle hardness also was measured and compared with the uninjured limb. The authors showed a close correlation between the direct measurement of ICP with the wick catheter and quantitative hardness in compartment syndrome models in dog and anatomic specimen limbs, and in patients suspected of having compartment syndromes. They concluded, that the determination of surface hardness of limb muscle compartments, which appears accurate and reproducible, offers the advantages of being noninvasive and well suited for longer-term assessments of ICP [32]. Further development of this device showed promising results in a study of eighteen volunteers simulating an increased ICP in a tourniquet model. The results showed a statistically significant strong linear relationship between the ICP and the quantitative hardness measurement. Again, the authors concluded that quantitative hardness measurements may accurately predict ICP for most patients. This technique may greatly enhance the medical community's ability to diagnose compartment syndrome with a noninvasive means [33].

The use of quantitative muscle compartment hardness measurement finally was examined in a large cohort of 205 patients with ACS by two independent observers resulting in a strong overall correlation of hardness measurement and ICP. The authors concluded that the quantitative hardness is potentially useful for the monitoring of IMP elevation in compartment syndrome [34]. These studies confirm that the presented approach of objectifying the clinical findings by the observer may have the potential for the future to monitor, predict and determine the need for fasciotomy in better modes than today. However, there is still a need for a reliable tool assessing the soft-tissue swelling to objectify the clinical findings by further developments.

### **5.3 Pulsed phase locked loop (PPLL) ultrasound**

A further approach to determine a parameter correlated with the decreased ICP is the portable technique of ultrasonic pulsed phase locked loop (PPLL) technology. With this method the myofascial displacement is detected after stimulation with an ultrasonic impulse. The difference in frequency of the transmitted ultrasonic impulse and the detected reflection is measured. Linear displacements of the myofascial layer that result from the arterial pulse can be detected. Lynch et al. transferred this technology to determine decreasing myofascial displacements in ACS with increasing ICP [35]. In several studies they showed a strong non-linear correlation between the PPLL measurements and the direct ICP determination in ex-vivo and animal models [35, 36]. This correlation with increasing ICP also was proven in a study with healthy volunteers [37] and patients with ACS [38]. The demonstrated results showed remarkable sensitivity of 75% and specificity of 75%. Because of the non-linear correlation with the ICP and the arterial pulse amplitude interpretation concerns were raised regarding the PPLL technology especially in trauma patients with hypotension. Further studies may deliver more data that support this technique in noninvasive monitoring of ACS.

### **5.4 Elastography**

Ultrasound elastography was introduced in the early 1990s [39, 40]. It allows to differentiate the mechanical properties of tissue by qualitative visual or quantitative



measurements [41]. Over the last three decades, this technique evolved into a tool for real-time imaging of the distribution of tissue strain in relation to its elastic modulus. The most common technique of stress application is the strain (compression, real-time) ultrasound elastography [42]. Low-frequency compression on the soft tissue (e.g. breast, abdominal organs, muscle) is usually applied manually with a hand-held B-mode transducer. The resulting axial tissue displacement or strain provokes different echo sets before and after compression, which are visualized by different colors. Thus, ultrasound elastography provides information on relative tissue stiffness compared with the adjacent and surrounding tissue within the image section. There is limited data available on the use of real-time elastography for skeletal muscle [43, 44]. Niitsu et al. described in a feasibility study in healthy volunteers the potential measurement of muscle hardness calculating the “strain ratio” by the relative elasticity of the biceps muscle compared to that of the reference before and after exercise [43]. These results were supported by a study in seven volunteers after muscle exercise [45]. Toyoshima et al. recently demonstrated the feasibility of soft tissue elasticity measurement based on ultrasound shear wave elastography (SWE). The elastic modulus of tissue was estimated from shear wave speed (SWS; m/sec) induced by acoustic radiation force of a focused ultrasound beam. In an ex-vivo animal model with turkey hind limbs increasing ICP was simulated in the anterior-lateral and anterior-deep compartment. A strong correlation was observed between the increasing ICP and increasing SWS measurements. The authors concluded, that the ICP can be accurately measured by using ultrasound shear wave elastography [46]. However, further clinical studies are needed to prove the concept of SWE in patients with ACS.

### **5.5 Pressure related ultrasound (PRUS)**

The use of B-mode ultrasound combined with a pressure sensor can be used to determine the muscle hardness. Muraki et al. investigated whether a combination of the thickness and hardness of muscles without muscle tension is feasible to estimate muscle strength of the anterior thigh during knee extension in adult volunteers. A compression ratio (%) of the muscle thickness before and after compression (10 N) using an internal coiled spring resulted in a significant positive correlation with the strength [47].

The probe pressure-related use of B-mode ultrasound to estimate compartment pressure was first described in a basic in-vitro model [48]. In this context, the ratio (%) between the compartment depth in a condition without compression compared to a state with a defined pressure by the ultrasound probe (100 mmHg) was calculated. The authors demonstrated a strong non-linear correlation between a decreasing compression depth and an increasing ICP with a Pearson correlation coefficient of  $r^2 = 0.960$ . The results in this feasibility study were confirmed in a cadaver study. The authors concluded that pressure-related ultrasound (PRUS) could be a reliable tool to determine the correlation between the measured compartmental displacement and the increasing ICP [49]. Bloch et al. tested this experimental setup of compression sonography in an animal model in six domestic pig legs. Increasing ICP in the anterior tibial compartment was simulated in 5 mmHg steps. The elasticity ratio (%) significantly differed from the baseline measurement compared with the simulated pressure of 30 and 40 mmHg. A compression ratio less than 12.9% had a sensitivity of 94.4% and a specificity of 89% to properly diagnose ACS. The authors concluded, that compression sonography might offer a non-invasive technique help in cases of uncertain ACS [50]. In a prospective study in six patients with verified ACS the muscle compartment elasticity of the injured lower limb was compared with the uninjured limb. This comparison resulted in a

significant difference of the compression ratio (%) using PRUS [51]. The uninjured anterior tibial compartment resulted in a ratio of 17.95% (SD  $\pm$  5), whereas the injured limbs showed ratios of 5,14% ( $\pm$  2) and thereby was significantly different. A ratio less than 10.5% had a sensitivity of 95.8% and a specificity of 87.5% to properly diagnose ACS. Therewith the results of the previously described animal model were confirmed. Marmor et al. used PRUS to determine the pressure at the condition of flattening the concave myofascial layer. In this cadaver study significant differences for the compartment fascia flattening pressure (CFFP) between the control and the simulated ACS group were demonstrated. The authors suggested that there is a potential for the clinical use of this modality in the future [52]. These results recently have been confirmed in a prospective clinical study in fifty-two patients with tibial fractures. The CFFP in the injured limbs resulted in a significant difference compared with the uninjured lower leg with good to excellent inter- and intra-observer agreements [53]. The inter- and intra-observer reliability of PRUS was recently investigated in a blinded in-vitro model in twelve volunteers [54]. This study confirmed a very high reproducibility of measurements ( $ICC_{inter}$  of 0,986 and  $ICC_{intra}$  of 0,985). Further technical improvements and clinical studies are required to implement this application in clinical scenario.

## 6. Conclusion

To date, the diagnosis of ACS is based on the suspicion in history of the patient, the clinical findings and in cases of uncertainty supported by invasive ICP measurements. There is an unambiguous need for further technical approaches to objectify either the decreasing perfusion pressure and microcirculation or the increasing intra-compartmental pressure within the myofascial layer to measure the condition of suspected ACS. In the literature, numerous publications demonstrate the difficulty of a clear and precise determination of the condition within the suspected muscle compartment. Subsequently, sometimes unnecessary or delayed fasciotomies are inevitably provoked. Thus, the requirements of an ideal approach to objectify a suspected ACS is easy to determine. A non-invasive, reliable, low-cost and easy monitoring with defined threshold to determine fasciotomy is needed.

The above described technical innovations and applications aspire to fulfill these requirements. The measurement of the decreasing perfusion pressure seems to be more sensitive to detect early changes in the diamond concept of ACS diagnostics. In respect of the complex and dynamic changes of the muscle compartment condition the combination of different approaches may solve the mentioned requirements in the future.

At this point in time, none of these modalities have come into widespread use and the gold standard currently remains clinical examination and compartment pressure monitoring and if in doubt, it would be better to decompress an ACS to save the limb. Further developments and refinements are needed in the present non-invasive methods to make them more robust in contributing to the diagnosis of ACS.

IntechOpen

### **Author details**

Richard Martin Sellei<sup>1,2\*</sup>, Philipp Kobbe<sup>2</sup> and Frank Hildebrand<sup>2</sup>

1 Department of Orthopaedic Trauma, Sana Klinikum Offenbach, Offenbach am Main, Germany

2 Department of Orthopaedic Trauma and Reconstructive Surgery, University of Aachen Medical Center, Aachen, Germany

\*Address all correspondence to: richard.sellei@sana.de

### **IntechOpen**

---

© 2021 The Author(s). Licensee IntechOpen. This chapter is distributed under the terms of the Creative Commons Attribution License (<http://creativecommons.org/licenses/by/3.0>), which permits unrestricted use, distribution, and reproduction in any medium, provided the original work is properly cited. 

## References

- [1] Schmid AH. Acute compartment syndrome. *Injury*. 2017; 48:S22-S25.
- [2] Garner MR, Taylor SA, Gausden E, Lyden JP. Compartment syndrome: Diagnosis, management, and unique concerns in the twenty-first century. *HSS J*. 2014; 10:143-152.
- [3] Hansen EN, Manzano G, Kandemir U, Mok JM. Comparison of tissue oxygenation and compartment pressure following tibia fracture. *Injury*. 2013; 44:1076-1080.
- [4] Rorabeck CH, Clarke KM. The pathophysiology of anterior tibial compartment syndrome: An experimental investigation. *J Trauma*. 1978; 18:299-304.
- [5] Ulmer T. The clinical diagnosis of compartment syndrome of the lower leg: Are clinical findings predictive of the disorder? *J Orthop Trauma*. 2002; 16: 572-577.
- [6] Von Keudell AG, Weaver MJ, Appleton PT, Bae DS, Dyer GSM, Heng M, Jupiter JB, Vrahas MS. Diagnosis and treatment of acute extremity compartment syndrome. *Lancet*. 2015; 386:1299-1310
- [7] Katz LM, Nauriyal V, Nagaraj S, Finsch A, Pearlstein K, Szymanowski A, Sproule C, Rich PB, Guenther BD, Pearlstein RD. Infrared imaging of trauma patients for detection of acute compartment syndrome of the leg. *Crit Care Med*. 2008; 36:1756-1761
- [8] Mars M, Hadley GP. Failure of pulse oximetry in the assessment of raised limb intracompartmental pressure. *Injury*. 1994; 25:379-381
- [9] Mac Loughlin S, Ma Loughlin MJ, Mateu F. Pulsed Doppler in simulated compartment syndrome: A pilot study to record hemodynamic compromise. *Ochsner J*. 2013; 13:500-506
- [10] Abraham P, Leftheriotis G, Saumet JL. Laser Doppler Flowmetry in diagnosis of chronic compartment syndrome. *J Bone Joint Surg*. 1998; 80-B: 365-369
- [11] Geis S, Gehnert S, Lamby P, Zellner J, Pfeifer C, Prantl L, Jung EM. Contrast enhanced ultrasound (CEUS) and time intensity curve (TIC) analysis in compartment syndrome: First results. *Clin Hemorheol Microcirc*. 2012; 50:1-11
- [12] Sellei RM, Waehling A, Weber CD, Jeromin S, Zimmermann F, McCann PA, Hildebrand F, Pape HC. Contrast enhanced ultrasound (CEUS) reliably detects critical perfusion changes in compartmental muscle: A model in healthy volunteers. *Eur J Trauma Emerg Surg*. 2014; 40:535-539
- [13] Weick JW, Kang H, Lee L, Kuether J, Liu X, Hansen EN, Kandemir U, Rollins, Mok JM. Direct measurement of tissue oxygenation as a method of diagnosis of acute compartment syndrome. *J Orthop Trauma*. 2016; 30: 585-591
- [14] Hansen EN, Manzano G, Kandemir U, Mok JM. Comparison of tissue oxygenation and compartment pressure following tibia fracture. *Injury*. 2013; 44: 1076-1080
- [15] Doro CJ, Sitzman TJ, O'Toole RV. Can intramuscular glucose levels diagnose compartment syndrome? *J Trauma Acute Care Surg*. 2014; 76: 474-478
- [16] Reisman WM, Shuler MS, Roskosky M, Kinsey TL, Freedman BA. Use of near-infrared spectroscopy to detect sustained hyperaemia following lower extremity trauma. *Mil Med*. 2016; 181:111-115
- [17] Lee SH, Padilla M, Lynch JE, Hargens AR. Noninvasive measurement

of pressure of detecting compartment syndromes. *J Orthop Rheumatol*. 2013; 1:5

[18] Budberg SC, Shuler MS, Hansen M, Uhl E, Freedman BA. Comparison of NIRS, serum biomarkers, and muscle damage in a porcine balloon compression model of acute compartment syndrome. *J Trauma Acute Care Surg*. 2016; 81:876-881

[19] Shuler MS, Roskosky M, Kinsey T, Glaser D, Reisman W, Ogburn C, Yeoman C, Wanderman NR, Freedman B. Continual near-infrared spectroscopy monitoring in the injured lower limb and acute compartment syndrome. *B Joint J*. 2018; 100-B:181-797

[20] Tobias JD, Hoernschemeyer DG. Near-infrared spectroscopy identifies compartment syndrome in an infant. *J Paediatric Orthop*. 2007; 27:311-313

[21] Schmidt A, Bossee M, O'Toole R, Obremsky W, Zipunnikov V, Dunrui D, Rey K, MacKenzie E. Continuous near-infrared spectroscopy monitoring in the injured lower limb and compartment syndrome. *Bone Joint J*. 2018; 100-B: 787-797

[22] Ohta H, Van Vo NM, Hata J, Terawaki K, Shirakawa T, Okano HJ. Utilizing dynamic phosphorous-31 magnetic resonance spectroscopy for early detection of acute compartment syndrome: A pilot study on rats. *Diagnostics*. 2021; 11:586-601

[23] Martinez AP, Moser TP, Saran N, Paquet M, Hemmerling T, Berry GK. Phonomyography as a non-invasive continuous monitoring technique for muscle ischemia in an experimental model of acute compartment syndrome. *Injury*. 2017; 48: 2411-2416

[24] Jerosch J, Geske B, Sons HU, Winkelmann W. The value of sonography in assessing intracompartmental pressure in the

anterior tibial compartment. *Ultraschall Med*. 1989; 10:206-210

[25] Correa DG, Costa FM, Mendonca S, Severo A, Canella C. Magnetic Resonance Imaging Alterations in Acute Compartment Syndrome. *J Foot Ankle Surg*. 2021; ahead of print; doi: 10.1053/j.jfas.2019.10.006

[26] Gershuni DH, Gosink BB, Hargens AR, Gould RN, Forsythe JR, Mubarak SJ. Ultrasound evaluation of the anterior musculofascial compartment of the leg following exercise. *Clin Orthop Rel Res*. 1982; 167: 185-190

[27] Rajasekaran S, Beavis C, Aly AR, Leswick D. The utility of ultrasound in detecting anterior compartment thickness changes in chronic exertional compartment syndrome: A pilot study. *Clin J Sport Med*. 2013; 23:305-311

[28] Wang SH, Lin KY, Yang JJ, Chang JH, Huang GS, Lin LC. The thickness of the anterior compartment does not indicate compartment syndrome in acutely traumatized legs? *Injury*. 2014; 45:578-582

[29] Muehlbacher J, Pauzenberger R, Asenbaum U, Gauster T, Kapral S, Herkner H, Duma A. Feasibility of ultrasound measurement in a human model of acute compartment syndrome. *World J Emerg Surg*. 2019; 14:4; doi: 10.1186/s13017-019-0222-9

[30] Dickson KF, Sullivan MJ, Steinberg B. Noninvasive measurement of compartment syndrome. *Orthopedics*. 2003; 26:1215-1218

[31] Arokoski JPA, Surakka J, Ojala T, Arokoski JP, Surakka J, Ojala T, et al. Feasibility of the use of a novel soft tissue stiffness meter. *Physiol Meas*. 2005; 26:215-228

[32] Steinberg BD, Gelberman RH. Evaluation of limb compartment with suspected increased interstitial pressure.

A noninvasive method for determining quantitative hardness. *Clin Orthop Relat Res.* 1994; 300:248-53

[33] Steinberg BD. Evaluation of limb compartments with increased interstitial pressure. An improved noninvasive method for determining quantitative hardness. *J Biomech.* 2005; 38:1629–1635

[34] Steinberg B, Riel R, Armitage M, Berrey H. Quantitative muscle hardness as a noninvasive means for detecting patients at risk of compartment syndrome. *Physiol Meas.* 2011 Apr;32(4):433-44. doi: 10.1088/0967-3334/32/4/005. Epub 2011 Mar 8. PMID: 21383493

[35] Lynch JE, Heyman JS, Hargens AR. Ultrasonic device for the noninvasive diagnosis of compartment syndrome. *Physiol Meas.* 2004; 25:N1-N9

[36] Lynch JE, Lynch JK, Cole SL, Carter JA, Hargens AR. Noninvasive monitoring of elevated intramuscular pressure in a model compartment syndrome via quantitative fascial motion. *J Orthop Res.* 2009; 27:489-494

[37] Lee SH, Padilla M, Lynch JE, Hargens AR. Noninvasive measurement of pressure for detecting compartment syndrome. *J Orthop Rheumatol.* 2013; 1:5

[38] Wiemann JM, Ueno T, Leek BT, Yost WT, Schwartz AK, Hargens AR. Noninvasive measurements of intramuscular pressure using pulsed phase-locked loop ultrasound for detecting compartment syndromes: A preliminary report. *J Orthop Trauma.* 2006; 20:458-463

[39] Ophir J, Cespedes I, Ponnekanti H, Yazdi Y, Li X. Elastography: A quantitative method for imaging the elasticity of biological tissues. *Ultrasound Imaging.* 1991; 13:111–134.

[40] Lerner RM, Huang SR, Parker KJ. “Sonoelasticity” images derives from ultrasound signals in mechanically

vibrated tissues. *Ultrasound Med Biol.* 1990; 16:231–239

[41] Garra BS. Imaging and estimation of tissue elasticity by ultrasound. *Ultrasound.* 2007; 23:255–268

[42] Park GY, Kwon DR. Application of real-time sonoelastography in musculoskeletal diseases related to physical medicine and rehabilitation. *Am J Phys Med Rehabil.* 2011; 90:875–886

[43] Niitsu M, Michizaki A, Endo A. Muscle hardness measurement by using ultrasound elastography: A feasibility study. *Acta Radiol.* 2011; 52:99–105

[44] Ariji Y, Katsumata A, Hiraiwa Y, Izumi M, Iida Y, Goto M, et al. Use of sonographic elastography of the masseter muscle for optimizing massage pressure: A preliminary study. *J Oral Rehab.* 2009; 36:627–635

[45] Yanagisawa O, Sakuma J, Kawakami Y, Suzuki K, Fukubayashi T. Effect of exercise-induced muscle damage on muscle hardness evaluated by ultrasound real-time tissue elastography. *SpringerPlus.* 2015; 2:308

[46] Toyoshima Y, Webb J, Gregory A, Fatemi M, Alizad A, Zhao C. Ultrasound shear wave elastography for measuring intracompartmental pressure of compartment syndrome using a Turkey hind limb model. *J Biomech.* 2020; 98: 109427

[47] Muraki S, Fukumoto K, Fukuda O. Prediction of the muscle strength by the muscle thickness and hardness using ultrasound muscle hardness meter. *SpringerPlus.* 2013; 2:457-464

[48] Sellei RM, Hingmann SJ, Kobbe P, Weber CD, Grice JE, Zimmermann F, Jeromin S, Hildebrand F, Pape HC. Compartment elasticity measured by pressure-related ultrasound to determine patients “at risk” for compartment syndrome: An

experimental in vitro study. *Patient Saf Surgery*. 2015; 9:4-10

[49] Sellei RM, Hingmann SJ, Weber CD, Jeromin S, Zimmermann F, Turner J, Hildebrand F, Pape HC. Assessment of elevated compartment pressures by pressure-related ultrasound: A cadaveric model. *Eur J Trauma Emerg Surg*. 2015; 41:639-645

[50] Bloch A, Tomaschett C, Jakob SM, Schwinghammer A, Schmid T. Compression sonography for non-invasive measurement of lower leg compartment pressure in an animal model. *Injury*. 2018; 49:532-537

[51] Sellei RM, Wollnitz J, Reinhardt N, de la Fuente M, Radermacher K, Weber CD, Kobbe P, Hildebrand F. Non-invasive measurement of muscle compartment elasticity in lower limbs to determine acute compartment syndrome: Clinical results with pressure related ultrasound. *Injury*. 2020; 51: 301-306

[52] Marmor MT, Charlu J, Knox R, Curtis W, Hoogervorst P, Herfat S. Use of standard musculoskeletal ultrasound to determine the need for fasciotomy in an elevated muscle compartment pressure cadaver leg model. *Injury*. 2019; 50: 627-632

[53] Marmor MT, Barker JP, Matz J, Donohoe E, Herring MJ. A dual-sensor ultrasound based method for detecting elevated muscle compartment pressure: A prospective clinical pilot study. *Injury*. 2021; doi: 10.1016/j.injury.2021.02.054. Online ahead of print

[54] Sellei RM, Warkotsch U, Kobbe P, Weber CD, Reinhard N, de la Fuente M, Radermacher K, Hildebrand F. Non-invasive and reliable assessment of compartment elasticity by pressure related ultrasound: An in-vitro study. *Injury*. 2020; doi: 10.1016/j.injury.2020.10.069. Online ahead of print