

## Effects of Feeding Oxalic Acid to Pregnant Rats<sup>1</sup>

A. R. SHEIKH-OMAR and H.B. SCHIEFER<sup>2</sup>

Department of Veterinary Pathology and Microbiology, Faculty of Veterinary Medicine and Animal Science, Universiti Pertanian Malaysia, Serdang, Selangor, Malaysia

**Key words:** Pregnant rats; oxalic acid; tubulonephrosis; renal oxalosis.

### RINGKASAN

Dua kajian telah dijalankan. Tujuan kajian rintis adalah untuk mencari sukatan asid oksalik yang sesuai dipergunakan dalam kajian utama. Tiga puluh ekor tikus Wister bunting telah digunakan dalam kajian utama dibahagikan kepada 3 kumpulan 10 ekor. Haiwan-haiwan dalam 2 kumpulan menerima asid oksalik pada sukatan 0.035 g dan 0.045 g seekor setiap hari sampai ke hari bersalin. Haiwan-haiwan dalam kumpulan ketiga menerima larutan garam normal. Tidak ada keguguran, kecacatan gros atau 'renal oxalosis' telah kelihatan dalam anak-anak tikus yang baru lahir. Tetapi perubahan-perubahan menyerupai 'tubulonephrosis' telah dilihat dalam anak-anak tikus yang baru lahir dalam kumpulan menerima 0.03 g sehari dalam kajian rintis. Ada bukti dalam kajian utama bahawa dosis oksalik yang diberi mempengaruhi kejadian 'renal oxalosis' dalam ibu-ibu tikus dan juga perbezaan saiz litter. Sebab-sebab kejadian ini diperbincangkan.

### SUMMARY

Two studies were carried out. The aim of the pilot study was to find a suitable dose of oxalic acid to be used in the principal study. Thirty pregnant Wister rats were used in the principal study divided into three groups of 10 animals each. The animals in two groups received oxalic acid at 0.035 g and 0.045 g per day per animal until parturition. The animals in the third group received normal saline. No abortions, gross malformations or renal oxalosis were observed in the foetuses and newborn in both studies. However changes comparable to tubulonephrosis were observed in the newborn in the group receiving 0.03 g/day in the pilot study. A correlation was observed in the principal study between the dose of oxalic acid and renal oxalosis in the dams as well as differences in litter size. Possible reasons for these observations were discussed.

### INTRODUCTION

Renal oxalosis has been observed in aborted bovine foetuses, postnatal calves, postpartum lambs and in feline foetuses. In the bovine cases, the observation was made in 53.3% of those in which the cause of abortion was not established, and in 66.7% of those with congenital malformations (Schiefer and Moffatt, 1974). The relationship of renal oxalosis and the congenital malformations and abortions has not, however, been established. Schiefer *et al.* (1976) failed to produce congenital malformation or abortion in pregnant ewes fed with oxalic acid even though

some of the lambs did have renal oxalosis *post-partum*. Nevertheless this observation and that of renal oxalosis in a foetus from a pregnant cat that had died of ethylene glycol toxicosis (Moffat, 1977) provided evidence that oxalic acid can cross the placental barrier in certain species and appear as calcium oxalate in foetal kidneys. Hence, the calcium oxalate crystals observed in the aborted bovine foetuses could be exogenous in origin, the exact source of which remains to be determined.

In order to utilize laboratory animals as an experimental model for cattle, preliminary inves-

<sup>1</sup> Based on a project submitted by A.R. Sheikh-Omar as partial requirement for the M.V.Sc. degree at the University of Saskatchewan.

<sup>2</sup> Department of Veterinary Pathology, Western College of Veterinary Medicine, University of Saskatchewan, Canada.

tigations in this area were indicated. The objective of this study was therefore to determine whether oxalic acid fed to pregnant rats would cross the placental barrier and perhaps cause damage to the developing foetus leading to malformation and foetal death and/or abortion. A pilot study was carried out to determine suitable oral dose levels of oxalic acid which could be given to pregnant rats in the principal study for longer duration without killing them.

## MATERIAL AND METHODS

### *Pilot Study*

Twenty adult female Wister rats mated 10 days previously and each weighing approximately 220 g were divided randomly into four groups of five animals. The animals in three groups were dosed with 0.5 ml solution of oxalic acid<sup>1</sup> via stomach tube at 0.06 g, 0.05 g and 0.03 g per head per day respectively while each animal in the fourth group was similarly dosed with 0.5 ml normal saline per day until the day of parturition. Dosing was done under ether<sup>2</sup> anaesthesia once daily around 1.00 pm.

Each animal was kept in a separate cage, fed commercial rat ration, with water available *ad libitum* throughout the course of the experiment. The weight of the animals was determined once daily at time of dosing. The physical condition of each animal was assessed each day. All dams and their young were killed by inhalation of chloroform<sup>3</sup> at the end of the experiment. These animals and those that died during the course of the experiment, any aborted foetus and all newborn were necropsied. Each foetus and newborn was carefully examined for gross anomalies. Selected tissues were fixed in 10% neutral buffered formalin, embedded in paraffin, sectioned at 6 $\mu$  and stained with hematoxylin-eosin (H & E). Where indicated additional sections were treated with Pizzolato's Peroxide Silvers method (Pizzolato, 1964) and with Roscher's Ca-naphthalhydroxamate method (Roscher, 1971) for demonstration of calcium oxalate. All sections were examined under conventional and polarized light conditions.

### *Principal Study*

Thirty adult female Wister rats bred seven days previously and weighing approximately 200 g were used. They were divided in three groups of ten animals with those in the first two

groups receiving 0.5 ml solution of oxalic acid at 0.045 g and 0.035 g per head per day respectively. Each animal in the third group was dosed with 0.5 ml of normal saline.

The procedure carried out in the pilot study was repeated in this study.

## RESULTS

### *Pilot Study*

All ten animals in the two groups receiving the high and medium dose rates of oxalic acid (0.06 g and 0.05 g) died within seven days. Each animal developed anorexia, depression, rapid breathing and loss in body weight before death. At necropsy, the only remarkable gross findings in all animals were severe hemorrhagic gastritis and ballooned, mostly empty small intestine. A few animals had small amounts of blood in the small intestine. Histologically, there were oxalate crystals in the gastric mucosa (Fig.1) and in the renal tubules, accompanied by tubulonephrosis (Fig. 2).

The animals in the group receiving the lowest dose of oxalic acid (0.03 g) and in the control group, gained weight and did not show any signs of reluctance to eat. Three died of an overdose of ether on day 10 of the experiment, two from the treated group and one from the control. No gross or histological lesions were noted in all animals in these two groups. However, all the kidneys of the newborn in the treated group showed marked vacuolation of the cells of the proximal tubules and pyknotic as well as karyorrhectic nuclei (Fig. 3). No oxalate crystals were demonstrated in these lesions, which were classified as tubulonephrosis.

The findings are summarized in Table 1.

### *Principal Study*

Three animals died during the study. From the treated groups, one each died with severe hemorrhagic gastritis and marked renal oxalosis on post-mortem examination. Two of the three were depressed, anorexic and breathing heavily before death. The third animal died of an overdose of ether.

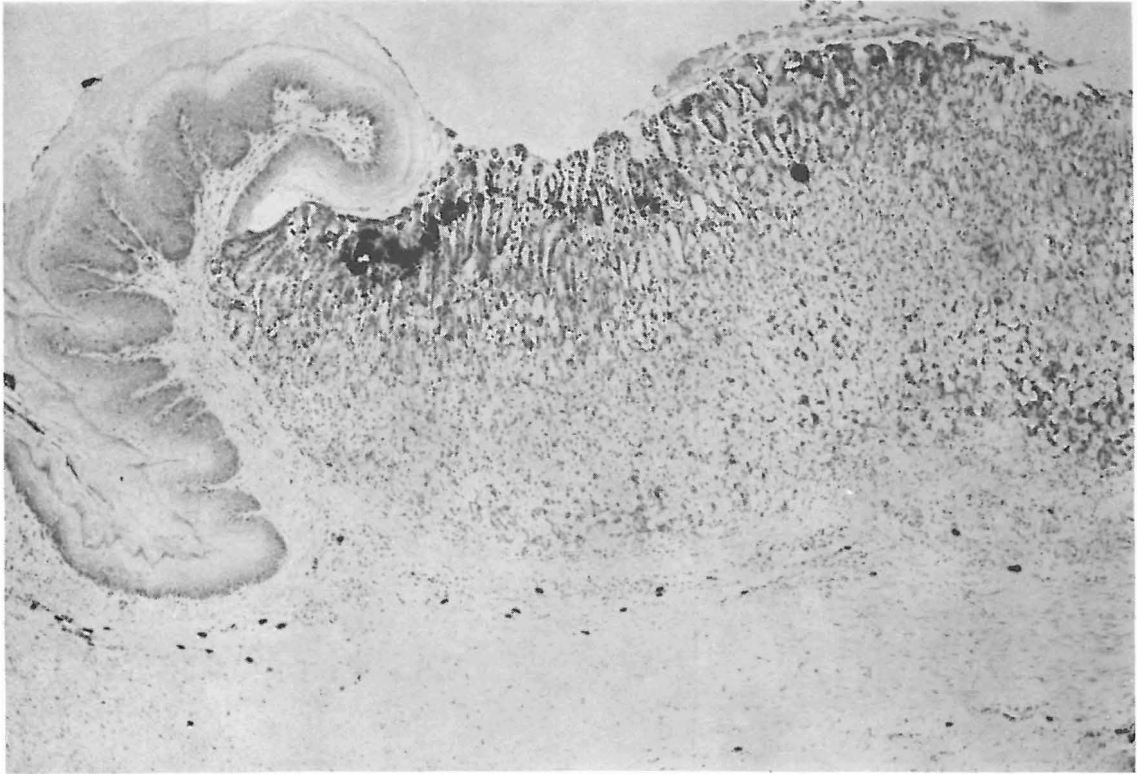
Twelve animals were found to be not pregnant. Three belonged to the group receiving the high dose of oxalic acid, four to the low dose group and five to the control group.

<sup>1</sup> BDH Chemicals Ltd., Poole, England.

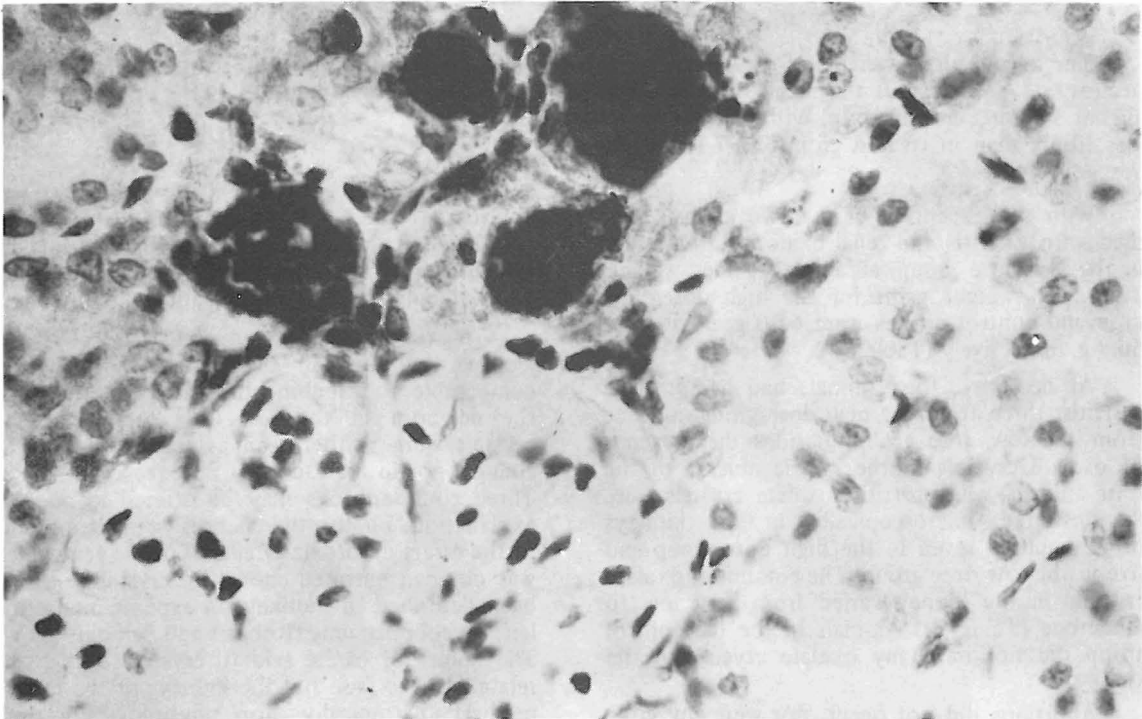
<sup>2</sup> Mallinkrodt, St. Louis, No. 63149.

<sup>3</sup> Hauer-Lockhart, Mississauga, Ontario.

EFFECTS OF FEEDING OXALIC ACID TO PREGNANT RATS



*Fig. 1 Oxalate (black) in the glandular gastric mucosa of a pregnant rat. Pizzolato stain. x 50*



*Fig. 2 Oxalate (black) in the renal tubules of a pregnant rat. Pizzolato stain. x 500*

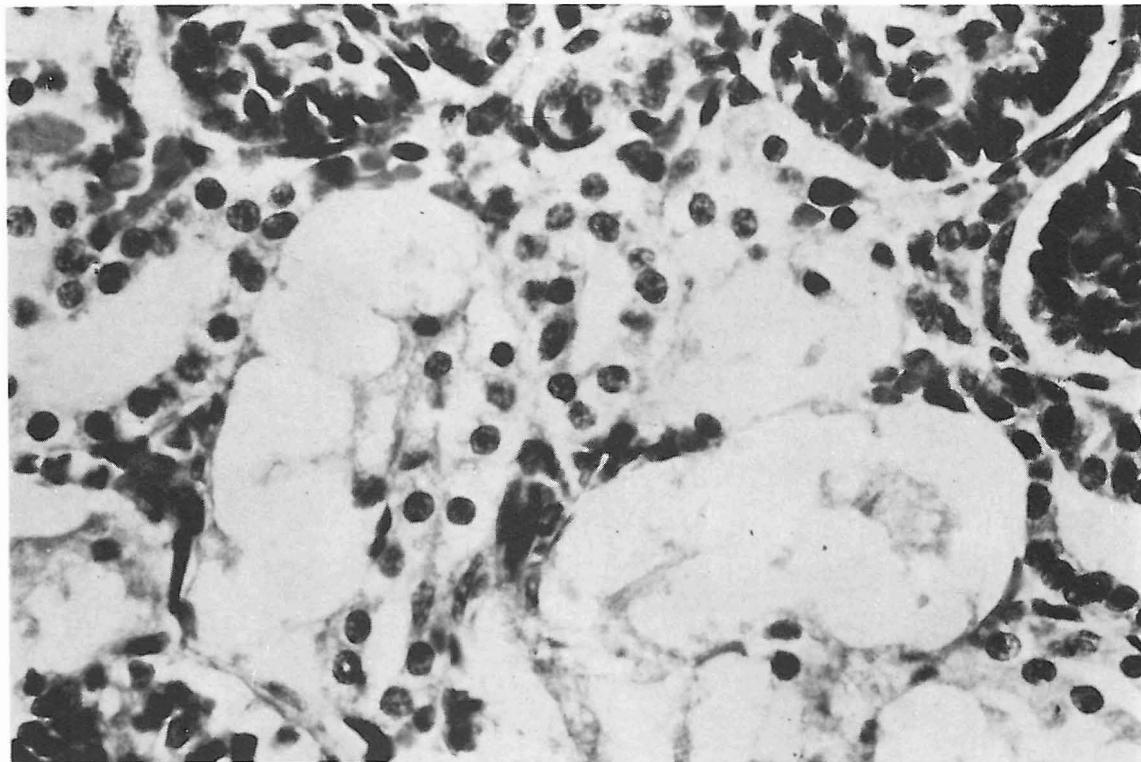


Fig. 3 Marked vacuolation of the cells of the proximal renal tubules of a murine newborn. H & E. x 500

The mean birth weight of newborn in all groups was uniform but the mean litter size was higher in the control group, with 12.2 newborn per litter, than in treated groups at 7.1 and 8.8 respectively.

With the exception of the two animals that died with gastritis and renal oxalosis and another in the low dose group, all animals gained weight. The mean weight gains for the high dose, low dose and control groups were 65.0 g, 51.5 g and 66.7 g, respectively (Table 2).

At necropsy, four animals had hemorrhagic gastritis, three from the high dose group and one from the low dose group. Besides the presence of oxalate crystals in the gastric mucosa of the four animals with gastritis, oxalate crystals were demonstrated microscopically in the kidneys of 12 animals, seven in the high dose group and five in the low dose group. The amount of oxalate crystals in the kidney varied from very few to numerous (Table 3). Animals in the the control group did not have any oxalate crystals in the kidney.

Abortions did not occur, nor were any gross malformations observed in the fetuses and new-

born. Neither tubulonephrosis nor oxalate crystals were observed histologically in the offspring.

#### DISCUSSION

A dose level between 0.03 g and 0.05 g was considered suitable for the principle study since the dams receiving 0.03 g in the pilot study did not show any renal oxalosis or associated illness while all dams receiving 0.05 g and higher died.

The results of the study fell short of its objective. Although in the pilot study, changes comparable to tubulonephrosis were observed in the newborn in the low dose group, oxalate crystals were neither seen associated with these changes nor in the kidneys of the respective dams. Three considerations may be offered as possible explanation. Firstly, the changes were attributable to the direct cytotoxic effects of oxalic acid which was not concentrated enough to crystallise as has been described in monkeys in experimental ethylene glycol poisoning (Roberts and Seibold, 1969). The failure of oxalic acid to crystallise might be related to the fact that the kidneys of the rat are neither anatomically nor physiologically well developed at birth (Pugh, 1967) and acquire the

EFFECTS OF FEEDING OXALIC ACID TO PREGNANT RATS

TABLE 1  
Pilot Study : Summary of Findings

Group	Dam				Foetuses (F) or Newborn (N)			
	Number Pregnant/ Total Number	Number Died	Number Killed	Number with Renal Oxalosis	Number	Renal Oxalosis	Tubulo-nephrosis	Mean Litter Size
High Dose (0.06 g/day Oxalic acid)	5/5	5 <sup>a</sup>	0	5	46F	—	—	9.2
Medium Dose (0.05 g/day Oxalic acid)	2/5	5	0	5	19F	—	—	9.5
Low Dose (0.03 g/day Oxalic acid)	3/5	2 <sup>c</sup>	3	0	30N <sup>d</sup>	0/27	27/27	10.0
Control	2/5	1 <sup>c</sup>	4	0	18N	0/18	0/18	9.0

a = Death occurred at the following days: 3, 4, 4, 4, 7

b = Death occurred at the following days: 3, 3, 4, 6, 6

c = Each did not recover from ether

d = Three newborn were eviscerated and kidneys not available for examination

— = Kidneys were too small or missed on histological sectioning

TABLE 2  
Principal Study : Summary of Findings

Group	Dam				Foetuses (F) or Newborn (N)			
	Number Pregnant/ Total Number	Number Died	Number Killed	Mean Wt. Gain (g)	Number with Renal Oxalosis	Total Number	Mean Birth Wt. (g)	Mean Litter Size
High dose (0.045 g/day Oxalic acid)	7/10	1 <sup>a</sup>	9	65.0	7	40N 10F	5.5 <sup>c</sup>	7.1
Low dose (0.035 g/day Oxalic acid)	6/10	2 <sup>b</sup>	8	51.5	5	53N	5.8	8.8
Control	5/10	0	10	66.7	0	61N	5.5	12.2

a = Died on day 13 with severe hemorrhagic gastritis and marked renal oxalosis

b = One died on day 6 with severe hemorrhagic gastritis and marked renal oxalosis; the other died on day 10 due to overdose of ether

c = Excluding the 10 foetuses which were not weighed

TABLE 3  
Principal Study : Number of dams With Gastritis and Degrees of Renal Oxalosis In Dams

Group	Gastritis	Renal Oxalosis <sup>a</sup>				Total
		+	2+	3+	4+	
High dose	3/10	1	2	1	3	7/10
Low dose	1/10	2	—	2	1	5/10
Control	0/10	—	—	—	—	0/10

a = Refers to 4 different levels in the amount of calcium oxalate crystals present in the kidney; — = none; + = very few; 2+ = several; 3+ = many; 4+ = numerous.

ability to concentrate urine not earlier than between the age of 11 and 23 days (Boss *et al.* 1963). Secondly, there might have been oxalate crystals temporarily associated with the changes but disappeared due to a flushing effect as suggested by others (Schiefer *et al.* 1976). An important assumption in both considerations is that some unknown enhancing factor present in the pilot study, may have been absent in the principal study. This will explain why the tubular changes were not reproducible in the principal study despite the use of higher dose levels of oxalic acid. The third consideration is that the changes were due to some unknown causes unrelated to oxalic acid treatment.

Apparently almost any drug or foreign compound has the ability to cross the placental barrier even though the rate of passage of certain substances may be very low (Beck, 1973; Jucham, 1973). This may also be true with oxalic acid in rats. Possibly the hemochorial placentation in the rat is an even easier barrier for oxalic acid to pass than the epitheliochorial placentation of ruminants.

The response to oxalic acid in the rats in the principal study appeared to be dose dependent with renal oxalosis present in seven and five in the high and low dose groups respectively. A positive relationship is also apparent between the presence of hemorrhagic gastritis and the severity of renal oxalosis as is the case in the halogeton poisoning in cattle (James, 1972). Further, a dose relationship may be postulated as an explanation of the difference in litter size. The high dose group had a mean litter size of 7.1, the low dose group a litter size of 8.8, as compared to the control group with 12.2. One can speculate that the oxalic acid interfered with nidation, causing early resorption of embryos, with no traces left at time of birth.

One may conclude from this study that rats do not appear to be suitable models for the study of foetal toxic damage due to oxalic acid. It is also tempting to conclude that the feeding of oxalic acid does not have any effect at all in pregnant rats but such a conclusion appears to be premature in view of the fact that considerable difference of litter size, correlated with dose of oxalic acid, was observed.

#### ACKNOWLEDGEMENTS

Facilities for the project were generously provided by the Department of Veterinary Pathology, Western College of Veterinary Medicine, University of Saskatchewan. The project was financed by Canada Department of Agriculture and Dr. Sheikh-Omar was supported by the Canadian International Development Agency.

#### REFERENCES

- BECK, C. C. (1973): How impervious is the placental barrier? *Vet. Med. Small Anim. Clin.* **68**: 468-480.
- BOSS, J. M., D'LOUHE, N. M., KRAUS, M., and KRECEK, J. (1963): The structure of kidney in relation to age and diet in white rats during the weaning period. *J. Physiol.* **168**: 196-204.
- JAMES, L. F. (1972): Oxalate toxicosis. *Clin. Toxicol.* **5**: 231-243.
- JUCHAM, M. R. (1973): Placental metabolism in relation to toxicology CRC Critic. *Reviews in Toxicol.* **2**: 125-158.
- MOFFATT, R. E. (1977): Renal Oxalosis in the Cat. *Can. Vet. J.* **18**: 351.
- PIZZOLATO, P. (1964): Histochemical recognition of calcium oxalate. *J. Histochem. Cytochem.* **12**: 333-336.
- PUGH, D. (1967): The droplets of immature rat kidney. *J. Anat.* **101**: 93-97.

## EFFECTS OF FEEDING OXALIC ACID TO PREGNANT RATS

ROBERTS, J. A. and SEIBOLD, H. R. (1969): Ethylene glycol toxicity in the monkey. *Toxicol. Appl. Pharmacol.* **15**: 624-631.

ROSCHER, A. A. (1971): A new histochemical method for the demonstration of calcium oxalate in tissues following ethylene glycol poisoning. *Am. J. Clin. Path.* **55**: 99-104.

SCHIEFER, B. and MOFFATT, R. E. (1974): Bovine abortion associated with renal oxalosis in the fetus. *Can. Vet. J.* **15**: 57-65.

SCHIEFER, B., HEWITT, M. P. and MILLIGAN, J. D. (1976): Fetal renal oxalosis due to feeding oxalic acid to pregnant ewes. *Zbl. Vet. Med. A.* **23**: 226-233.

(Received 12 November 1979)