

61576

A Clinical study of the THERAPEUTIC
advantages which can be obtained
by the use of
F I B R O L Y S I N .

----oOo----

A THESIS presented for the
degree of M.D.

EDINBURGH UNIVERSITY

by

FRANK EDGAR WALL.

M.B. Ch.B.

April 1908.



I N T R O D U C T I O N .

In this Thesis which I present for the degree of M.D. of Edinburgh University. I hope to bring forward some illustrations of the advantages that may be obtained in certain chronic fibroid conditions by treatment with Fibrolysin.

The work has been carried out in Mr Hodsdon's Wards in the Royal Infirmary, Edinburgh, and to him I am particularly indebted for clinical material and facilities of research. I also desire to thank Dr James, Dr G.A. Gibson, Dr G. Thyne, Mr Cotterill and Mr Støuart for permission to study the effects of treatment in certain of their cases.

E. Merck of Darmstadt was kind enough to supply me with extensive data relating to the chemistry and the literature of the drug.

The subject of this thesis "Fibrolysin" is a double compound of thiosinamin and sodium salicylate. It was introduced by Mendel of Essen to replace the alcoholic solutions of thiosinamin which had gained the reputation of causing pain on injection, whilst aqueous solutions of that drug possess the disadvantage that at low temperatures part of the thiosinamin precipitates as a white crystalline powder.

Fibrolysin overcame these shortcomings.

It is a white crystalline powder, freely soluble in water and contains one molecule of thiosinamin and half a molecule of sodium salicylate. The aqueous solution of Fibrolysin does not keep if exposed to the action of light and air and is used in the form of a sterilised solution in ampullae of 2.3 CC (m 37) capacity.

It corresponds to 0.2 grm (gr 3) of thiosinamin.

This solution does not give rise to pain when injected and according to E. Mendel¹ possesses the same efficiency as thiosinamin. According to the communications of E. Mendel¹ W. Doevenspeck² L. Hirschland³ and Kalberlah⁴ Fibrolysin may be used subcutaneously, intra-muscularly or intravenously in doses of 2.3 CC's at intervals of 1 to 3 days. The subcutaneous injections are made under suitable aseptic precautions *at* -

at the seat of affection but I have found sloughing follows this method. On the other hand no bad effects have been seen to follow the injections into the gluteal muscles or deep muscles of the back nor have any untoward symptoms followed on the intravenous injections which surpass both the above methods by its prompt and reliable action.

Fibrolysin is indicated in all cases where it becomes necessary to soften scar tissue and its therapeutic efficacy in stenosis, strictures, ankylosis and contractions has been acknowledged. It is also indicated in scleroderma, pock marks, adhesions, agglutinations and coalescences of internal organs and serous surfaces, and as a means of reducing and removing glandular tumours, fibrous tumours, fibrous cords and Keloids, in pleuritic callosities, cordlike coalescences of the pleura and in "scarry" lesions of the heart.

In otology it is recommended for the treatment of hard hearing and deafness arising from fibrous changes within the middle ear, of coalescence and induration of the tympanum as well as in fixity and ankylosis of the auditory ossicles.

S. McCullagh⁵ reports favourably on the action of

this drug, whether it is given subcutaneously or internally in ear conditions associated with the formation of new connective tissue. The earlier the patient is placed under the treatment the sooner the cure and better the prognosis. If calcareous changes be present already the prognosis is unfavourable. In tinnitus aurium, most of all in chronic catarrh of the middle ear, but also where there is residual discharge after suppuration, McCullagh obtained satisfactory results. He, however, directs particular attention to the fact that the administration of Fibrolysin requires to be assisted by mechanical measures, for the preparation has not the power to cure by itself, but merely renders the soil favourable for the action of mechanical remedies.

In the treatment of Uterine Fibromyomata Dr. Sidney H. Gardiner obtained such satisfactory results by gluteal injections of Fibrolysin as to encourage him to believe that the use of this remedy would do much to save such cases from radical operation.

A résumé of the cases successfully treated by Dr Gardiner will best illustrate the results.

Case 1.

A woman aged 38 married: one child. She suffered from profuse menstruation, occurring every 3 weeks for the past 3 or 4 years, accompanied by leucorrhoeal discharges of a mucoid character. On examination a nodulated mass was revealed on the left side of the cervix, softer posteriorly and extending into the cul-de-sac. It was evidently a case of prolapsed and cystic left ovary, with either an inflammatory mass or fibroid growth on the side of the cervix or immediately in front of, and adherent to the ovary. Local treatment had no influence upon the tumour, and the treatment of Fibromyomata with Ergot etc., showed no noticeable results. After 11 months the first injection was made. Upon the 4th injection the tumour was found to be much reduced in size, almost painless when touched. After the 14th injection no trace of the tumour could be found. Bi-manual examination deep into the pelvis behind the uterus, and rectal examination showed nothing left but the left ovary, still in the cul-de-sac, but not so painful. With the disappearance of the tumour came a marked improvement in the general condition, and after a period of 9 months had elap-

sed there had been no return of the tumour and the patient had regained her health.

Case 11.

The patient was suffering from vomiting during pregnancy, and was unable to retain her food. When seen by Dr Gardiner he found a basin containing a pint and a half of mucous saliva beside her. On examination the presence of a tumour on the right lower uterine segment and one higher up was found. Four years before this tumour was mistaken for a pregnancy by her physician. Fibrolysin injections were made every 2nd or 3rd day until the end of the 2nd week of treatment, when the patient had recovered sufficiently to come to Dr Gardiner's surgery for treatment. Twenty one injections were given in all, and in due time she was delivered of a healthy child.

In this case it is interesting to note the effect of the drug, in allaying the irritation in the uterus that had caused the reflex symptoms viz. vomiting and salivation.

Case 111.

This was one of fibromyomata embedded into the right side of the uterus and being subperitoneal there was no haemorrhage. The patient had been

under Dr Gardiner's observation for nearly 18 months and his diagnosis was confirmed by 3 other physicians. With the exception of the disappearance of a pain in the right iliac and hypogastric region, there was little effect noticeable at first from the treatment with Fibrolysin - However after the 55th injection the tumour had almost completely disappeared and a recent examination showed no return.

Case 1V.

This patient was delivered 9 years previously of her last child, and had since had an abortion without any apparent cause. During the past few years she had developed palpitation of the heart with an impaired digestion. Her mental state became clouded and she failed to think and act in an orderly manner. Upon examination a uterine tumour was found reaching up to the umbilicus, and measuring from side to side over 6½ inches either involving the whole uterus or surmounting the fundus and spreading laterally. Eight injections of Fibrolysin were administered monthly, and at the time of writing the patient had been given 48 in all. - Although still under treatment the following improvements had taken place:-

Menstruation, which was formerly profuse and lasting from 7 to 8 days, is now regular, lasting 3 to 4 days and never profuse. The tumour was reduced in size laterally from $6\frac{1}{2}$ to 4 or $4\frac{1}{2}$ inches, while its length from cervix to fundus was also proportionately reduced, the uterus being freely movable. The waist line had decreased by 4 inches, and the bust measurement had slightly increased. Her general health she considered fully restored, she worked better, tired less easily, and her mental fears and emotions had disappeared.

Dr Aldo Castellani⁷ (Director of the Clinic for Tropical Diseases) Colombo, Ceylon, in a paper read before the Ceylon Branch of the British Medical Association on June 29th 1907 gives some striking results in the treatment of Elephantiasis.

The method of treatment began by making the patient enjoy a complete rest in bed for a week, the affected parts being bandaged with flannel and indiarubber bandages, and massaged regularly twice daily. Thereupon began the injecting of Fibrolysin - A sterile pad of gauze was attached to the place of the injection and the part tightly bandaged, an antitoxin syringe with a strong needle

being used and 2-3CC of Fibrolysin injected every day or other day for almost a month. The injections were now stopped for a week, during which time the use of flannel & indiarubber bandages was resumed. In cases of Verrucose Elephantiasis it was found that the use of rubber bandages rendered the skin much smoother besides causing the hard verrucose to disappear or become smaller. Should however the skin of the affected parts be smooth, the use of rubber bandages is not advocated. Now followed a second course of 30 injections, then a weeks rest and bandaging and more injections if necessary. The affected parts became much smaller in size, the skin became softer and more elastic and could be pinched up in folds. After the treatment the wearing of puttees or of an elastic stocking is most strongly advised, as otherwise, swelling will again set in. This however is due to an oedematous infiltration, as a day of rest is quite sufficient to cause its subsidence.

For this reason Dr Castellani suggests removing the superfluous skin, when the disease affects the legs, by the removal of long elliptical strips of skin, stitching up the margins of the wound together.

This is impracticable before the treatment, the skin being enormously thickened and inelastic would not permit a coaptation of the opposing surfaces.

The following cases will illustrate the results obtained.

Case 1.

On the admittance of a Gíngalese lad aged 18. to the Clinic, who had been suffering for 12 years from Elephantiasis of the right leg, the measurements of the limb were:-

Round the ankle - $23\frac{1}{2}$ inches

Round the calf - $25\frac{1}{2}$ inches

He underwent the above course of treatment receiving altogether 62 injections, at the end of the course the circumference of the ankle had been reduced to 9 inches, that of the calf to 12 inches, the skin was of almost normal elasticity and the patient was able to walk easily. For 2 weeks he omitted to bandage the leg which thereupon began to swell, but 24 hours complete rest in bed and rubber bandaging reduced the limb to its previous measurements.

Case 2.

In a case of Elephantiasis verrucosa of the right leg and foot the patient had been a sufferer for 20 years - He underwent a treatment of 90 Fibrolysin

injections, the comparative measurements being:-

	Ankle	Calf	Thigh
Before Treatment	24½	27	25 inches
After Treatment	14½	16	21 inches

Case 111.

A Cingalese woman aged 56, after suffering for 15 years from Elephantiasis of the left leg and foot, was treated with only 22 injections of Fibrolysin, which succeeded in reducing the circumference of the ankle from 19 to 11½ inches.

Dr Castellani is of the opinion that his above described palliative method for the treatment of Elephantiasis will prove to be fraught with beneficial results as long as the case does not show any complications such as ulcers, and this must be regarded as an advance in the treatment of this malady.

J. Plesch⁸ agrees with S. McCullagh⁵ and is of opinion that Fibrolysin requires to be assisted by mechanical remedies - he obtained the same results with Fibrolysin injections and massage in Dupuytren's contraction as are obtained by operation - he gave 2.3 CCs every second day and never saw any evil consequence, either at the seat of the injection or

on the patient's general condition, an opinion fully endorsed by Jellinek⁹,

K. Pollack¹⁰ reports the cure of an old standing stricture of the oesophagus due to a burn by a caustic, the stricture was of 8 years standing. It had progressed so far, in spite of suitable treatment for the last 2 years that the patient was not able to swallow even a morsel. Pollack injected doses of 0.5 CC in 8 of a 10% solution of thiosinamin and obtained an appreciable improvement within the first 5 days. After the treatment had been continued for 6 weeks the patient was able to take all sorts of food, after 24 injections the patient was cured.

Weisselberg¹¹ in a case of oesophageal stricture due to the drinking of caustic soda obtained excellent results by the use of Fibrolysin. Weisselberg began by attempting to soften the stricture by injections of thiosinamin(9.0 : 70.0) but no success was obtained until he had given Fibrolysin 2.3 CC every 2nd or 3rd day when the two upper strictures of the oesophagus began to yield and after 39 injections a rapid improvement was produced. From the results obtained by Pollack and Weisselberg in the treatment of oesophageal stricture it would

appear that Fibrolysin is more rapid and more certain in its action than Thiosinamin.

Combe¹² further reports on the use of the drug and states that it has given good results in Pyloric stenosis and in adhesions by bands.

In a case of a child of 3 who had a stenosed larynx after tracheotomy and was subject to attacks of dyspnoea, he obtained complete success by means of 10 Injections. He also obtained marked improvement in the case of a child of 10 suffering from cardiac stenosis cirrhosis and ascites, and lastly he found it useful in a number of cases of cerebral sclerosis.

A. V. Planta¹³ reports a case in a child of 5 who had a severe external burn from fuming nitric acid. An extensive scar was formed which was as hard as a board and "colloidal" especially at its edges. Intramuscular injections of fibrolysin were given every other day into the gluteal region with the result that the scar tissue became softer, and a thoroughly satisfactory result was obtained after 25 injections without any secondary action.

The fibrous bands were no longer to be seen, and the scar itself was flaccid, and differed but little from the normal skin.

L. Waelsch¹⁴ reports a case of cure, by intramuscular injections of Fibrolysin, of plastic induration of the penis.

O. Woltke¹⁵ reports a case of cure in a case of chronic synovitis of the knee joint with restricted movement.

K. Boseck¹⁶ in a case of progressive myositis ossificans found thiosinamin useful. In this case the influence of the preparation would seem to have been executed on the process of ossification.

In ophthalmological practice the results reported by K. H. Grunert¹⁷ of the use of thiosinamin are of interest. He found thiosinamin of great use in lupoid scars of the skin and in post-neuritic atrophy.

In the former case the author used a solution of 4 grm (gr 60) of thiosinamin in 8 grm (gr 120) of glycerine and 40 grm ($1\frac{1}{3}$ oz) of water, in the latter case, the same solution with the addition of 0.2 gr (gr 3) of strychnine nitrate, of this 1 CC (m 16) is

injected into the gluteal muscles, at first daily, then at gradually increasing intervals. The remedy acts by softening and diminishing ~~of~~ post-neuritic connective tissue formations in the optic nerves. The addition of strychnine is only needed at the beginning of the treatment, for once the condition has come to a standstill, the improved condition may be obtained by this ~~sinamin~~ alone. Grunert maintains that the condition invariably grows worse if the treatment be left off too soon and this observation is of some clinical importance.

Bruno¹⁸ found that Fibrolysin acted beneficially in softening scar tissue in leucoma of the sort often seen after the subsidence of Keratitis with hypopyon. Even well marked leucomata, which seriously interfere with vision may be reduced to slight nebulae by injections of Fibrolysin into the glutei or back. These injections are found to be equally efficacious in cicatrical spots resulting from syphilitic iritis and exudative choroiditis. In many cases they are useful in softening and loosening the scar tissue, and thus facilitating the further treatment by antiseptics ~~mydriatics~~ or ~~myotics~~.

B. Salfeld¹⁹ thinks the value of Fibrolysin should

not be underestimated in chronic polyarthrititis and arthritis deformans. By the simultaneous use of baths, and other physical methods of treatment it rapidly produces the absorption of fluid or of swelling, diminishes crepitus, lessens pain and above all increases the mobility of the affected joints. The method advocated by Salfeld for the application of the drug is by intramuscular injection.

Herschell²⁰ recommends Fibrolysin strongly in the treatment of Gastric adhesions following on inflammatory affections such as gastric ulcer and cholecystitis. He, however, suggests that the drug is incapable of acting per se and must be assisted by mechanical measures in order to effect a cure.

Baumstock²¹ has also pointed out that this point is of great importance in connection with the treatment of benign stenosis of the pylorus and is of opinion that the cure of the obstruction must be effected by the stomach itself forcing food through the pylorus, by its muscular contractions after the stricture has been softened by Fibrolysin.

From this fact follows the important deduction

that unless the musculature of the stomach is fairly vigorous it is waste of time to treat the case with Fibrolysin, and an operation should be no longer delayed. The most favourable cases will be those of slight pyloric stenosis which are yet in the stage in which we find visible peristaltic movements and tonic contraction of the stomach,

Pope²² reports favourably of the use of Fibrolysin in the treatment of Locomotor Ataxy. An account of one of his cases is of particular interest.

J.B. aged 32, was admitted to the Leicester Infirmary on December 20th 1906, complaining of shooting pains in the legs and numbness of the feet. He had noticed the symptoms for the past two years: and had had great difficulty in walking in the dark: For the previous four weeks he had been confined to bed unable to walk at all.

Past History:-

He had an "abscess on the chest" fourteen years ago, urethral discharge ten years ago; no clear history of syphilis.

Condition on admission:-

His nutrition was fairly good, general health fair, sleeps poorly: complains of legs

feeling cold. Ill-marked areas of paraesthesia in both legs: tactile sense impaired; thermal sensation impaired but not lost: no complete analgesia: tactile conduction retarded. He is very ataxic. Romberg's symptom marked. Inco-ordination of both upper and lower extremities marked - was quite unable to stand or walk. Argyll-Robertson pupil phenomena marked; no nystagmus. Left pupil smaller than right. Knee jerks absent. Plantar reflex flexor. Has slight difficulty in micturition, none in defaecation. Facial muscles of right side slightly atrophied. No morbid changes to be detected in other organs.

Treatment:-

This was begun by keeping him under observation for nearly a fortnight without treatment and his condition underwent no change.

On January 2nd 1907, treatment by intramuscular injections of Fibrolysin was commenced. He received 2.3 CCs every alternate day.

February 12th he has had nineteen injections. He could stand better, and walk a little with assistance. Still much inco-ordination.

February 20th has had 21 injections. Knee jerks present on both sides.

March 6th. Had in all twenty-four injections
No injurious local effects. Immediate effects of each injection were a feeling of warmth and diaphoresis. Was able to walk with assistance.

May 1st:- Walked to hospital with the aid of sticks
The knee jerks are still present. Has no shooting pains. Pupil reaction unchanged. Achilles reflex faint but perceptible. In this case advanced ataxia had retrogressed so that the patient could get about. The knee jerks had returned. Ormerod, in Allchin's System of Medicine, says "we think that when ataxia has developed steadily, and become thoroughly established, it is likely to be permanent". This case seems to indicate that Fibrolysin might be beneficially employed in some cases of Locomotor Ataxia.

The following are the cases on which I have based my considerations on the value of this drug.

Case 1.

A successful case of Dupuytren's contraction of the palmar fascia treated by local injections of Fibrolysin. The history of the case is as follows:-

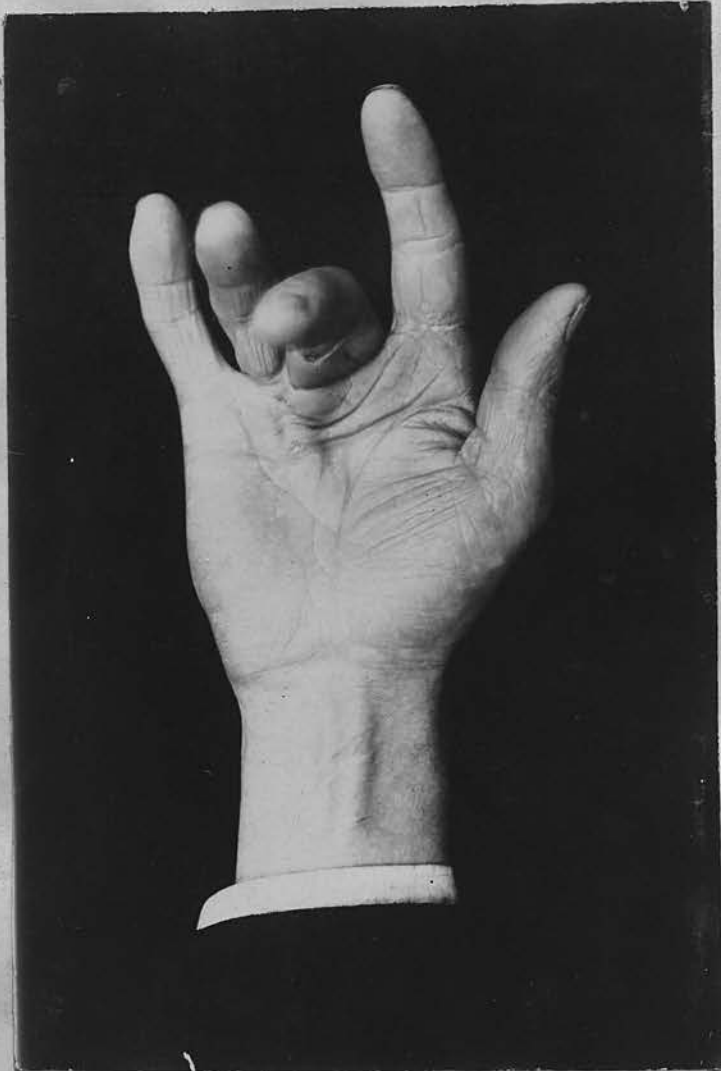J. H.

Aged 40.

Occupation - Tinsmith.

He came under my notice on October 2nd 1907 in the surgical wards of the Royal Infirmary, EDINBURGH. which are under the care of Mr Hodsdon. He diagnosed his own condition which he said had been present for over 20 years. There was no history of gout, rheumatism, or osteo-arthritis in any member of the patient's family or in the patient himself. His previous health has been excellent. When examined, the condition was found to be assymetrical. The skin of the palm was hard and horny and its centre was occupied by a thickened and puckered swelling which had been present for over 20 years and was the first abnormality to be noticed by the patient. The skin was bound down to the palmar fascia and the palm presented dense thickenings especially marked along the lines of the affected fingers.

Two years after he noticed the swelling in the palm, his middle finger began to show signs of flexion and it was not till 4 years later that the ring finger began to take part in this retrograde process.



The middle finger was flexed at the first metacarpophalangeal joint and there was also flexion at the 1st and 2nd interphalangeal joints the phalanges

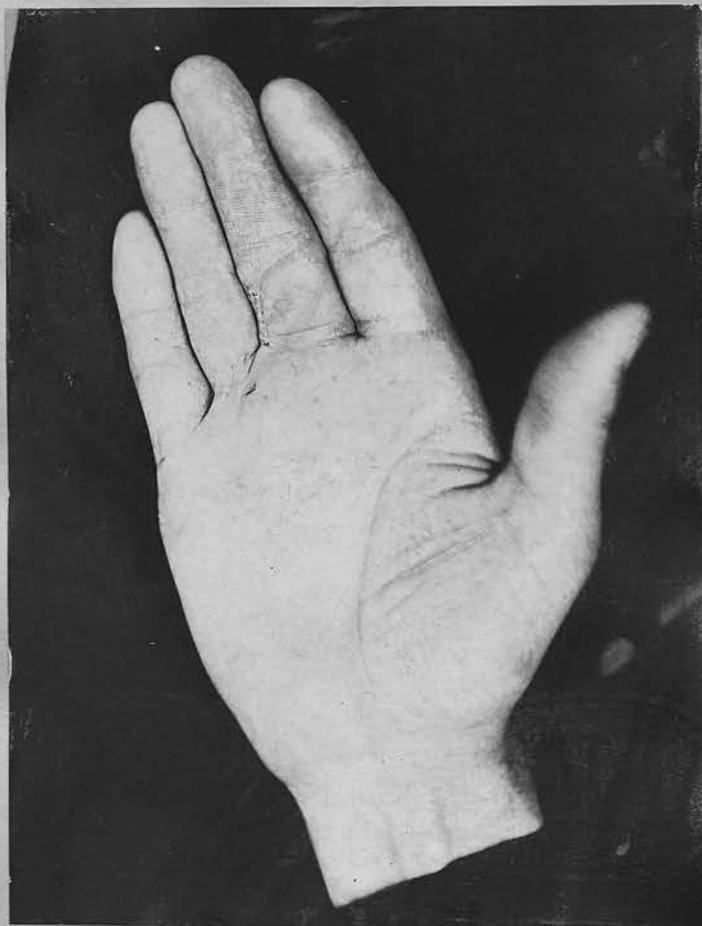being almost in the same straight line and the finger forming a right angle with the palm of the hand. The ring finger was not affected to the same extent. There was flexion of the metacarpophalangeal joint and of the 1st and 2nd interphalangeal joints. Both fingers were fixed. Extension and flexion were impossible.

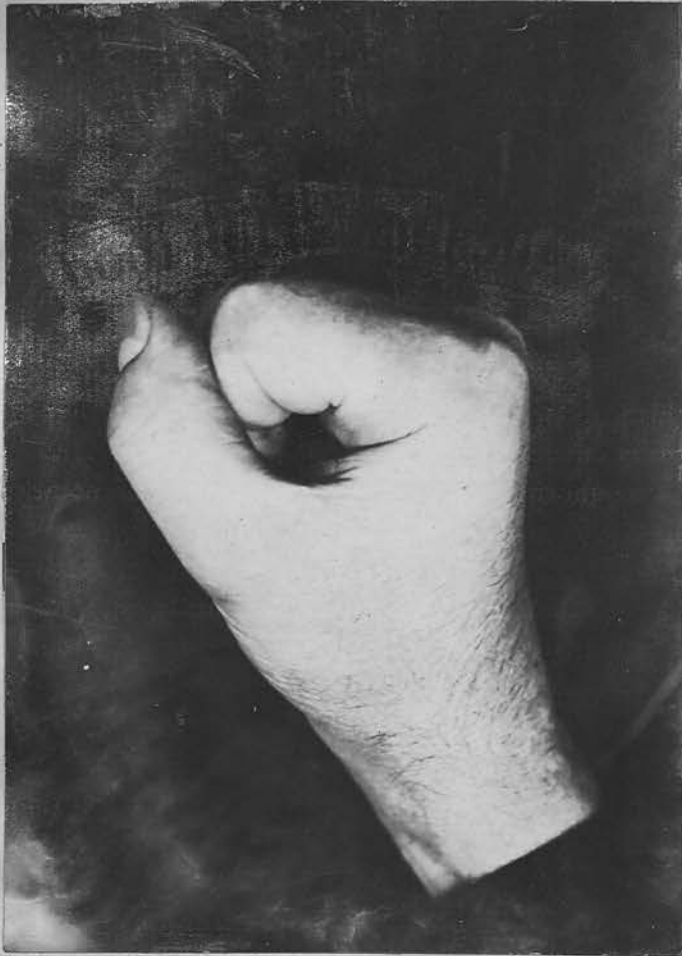Treatment.

He had been treated formerly by various medical men and at a sister Institution in Glasgow where he was advised to undergo an operation. He declined to submit to any operation and was advised to try systematic use of massage and emollients combined with the application of a back splint at bed time. He says he persisted in this treatment for 10 years but without any beneficial results and sought admittance to the R.I.E. with the object of having something done without undergoing an operation.

With the usual aseptic precautions hypodermic injections of Fibrolysin were given every 4th day combined with massage and the application of a back splint at bed time. The amount of the drug used at each injection was 2-3 CCs i.e. m 37 which corresponds to

0.2 grammes (grains 3) of thiosinamine. The injections were all given directly into the palm and well under the palmar fascia. This method is to be preferred, or injections into the deep muscles of the glutei or back to prevent sloughing of the skin which I have found to follow the too superficial injection of this drug. In all 20 injections were given with the result that the inserted photographs show:-





The fingers became straightened out and once more occupied their normal position. Both flexion and extension were complete, and the hand which was useless before treatment became as serviceable as it was before the condition commenced. This case is of particular interest in that the result obtained was better than the results that usually follow operation. That the effect was due to the selective influence of the drug on pathological fibrous tissue seems to follow from the fact that he had tried massage and

emollients for over 10 years without any benefit.

The result compares favourably with the case recorded
by J. Plesch⁸ of Dupuytren's contraction.

Case 2..

J. B.

Aged 36.

Occupation - Soldier

Complaint - Stenosis of Rectum.

Faminy History:-

Nothing to note.

History of Previous Illnesses:-

and

History of Present Complaint:- Patient had the

usual children's complaints but until the beginning

of the present condition he was particularly

healthy. Has had both syphilis and gonorrhoea.

While at Secunderabad, 4 years ago he had dysentery

and was confined to hospital for over 3 months.

He says that at the height of the attack the stools

were mixed with blood and mucus, and that the passage

of anything from the bowel was accompanied by great

pain and tenesmus. After the acute symptoms

subsided he suffered considerably from burning and

weight about the rectum. The treatment as far as

can be ascertained consisted in absolute rest, the

bowels kept open and morphia suppositories administ-

ered. Hot fomentations were applied to the

perinaeum and the rectum was irrigated 3 or 4 times daily with solutions of Condy's Fluid. The condition after this treatment cleared up for some time and then the signs of stenosing proctitis began to become marked. He suffered from alternate attacks of constipation and diarrhoea and the motions became flattened and increased difficulty in passing them was becoming manifest.

When seen by me at West Marshall Street Dispensary he was beginning to show signs of toxic absorption and was thin and emaciated. He complained of griping pains in the abdomen and frequent desire to evacuate the bowels and the amount passed at each motion consisted of a small faecal mass and a large quantity of blood and mucus.

On examination of the Rectum there was present a very markedly contracted condition of the bowel, the stricture was fibrous and elastic and was very irregular and extensive and was almost impassable on digital examination; The length of time the condition had been present and the history of Syphilis and Dysentery led to the diagnosis of stenosing proctitis.

Treatment.

Having been formerly treated by irrigation with warm antiseptics, simple laxatives, and anti-syphilitic remedies the condition became gradually worse and some measure had to be adopted that would overcome the increasing stenosis of the bowel and the frequent difficulty of evacuating the accumulated faeces. Fibrolysin 2.3 CCs was injected every 2nd day and after 35 injections the fibrous thickening of the rectal wall became less, and the index finger could with ease be passed high up into the bowel. The pain and tenesmus became less marked, the motions became normal, and the pipe stem character became less and less noticeable. The motions were also unaccompanied by the passage of blood and mucus. The patient continued having the injections for the next few weeks when 45 in all were given with the following results:-

The pain and tenesmus were entirely absent. There was no passage of blood or mucus and the motions were normal in every respect. On digital examination the walls of the rectum presented no marked induration or thickening, and the extreme sensitiveness which was

a marked feature at the beginning of the treatment was entirely absent. The advantages of using Fibrolysin in such a condition as this are obvious:- There is no danger of setting up a breach of surface, as may happen in passing bougies, and giving rise to a periproctitis which may end fatally, or, if the patient survive, in abscess or fistula high up in the the bowel which is very difficult to treat and which may require free division of the sphincters. In this case an internal or external proctotomy would be unable to meet the conditions of the case. Excision of the stricture, although the ideal method, was I think impracticable, as the stricture was so long that reunion would be impossible. The operation would also have been accompanied by great danger of septic infection and subsequent inflammation in the pelvic cellular tissue, reproducing the contraction, and in all probability the patient would have derived little benefit from any attempt at a radical operation.

Case 3.

J. D.

Aged 38.

Occupation:- Coachman.

Complaint:- Pain in limbs stiffness and swelling around joints.

Family History:- Nothing to note.

History:-

Patient was admitted to Ward 31 R. I. E. on October 6th 1905. He first noticed that his ankles were stiff and swollen and his shoulder and elbow joints became stiff and painful shortly afterwards. This condition followed exposure and occurred 4 months previous to his admission. He had, however, an attack of rheumatism 9 years ago and was unable to work for five months. Both ankles and knees were affected during this attack but no other joints involved. Had gonorrhoea 18 years ago. When a patient in Ward 31 his condition was as follows:- Both ankles were very stiff and their movements limited. Any attempt at flexion or extension was accompanied by pain, which on the left side radiated up to the groin and on the right side upwards to a little above the knee.

Knee Joints:-

Right knee could be flexed to about half a right angle but to do so caused pain in the inner side of the popliteal space. Extension was free.

Left knee at times could not be flexed at all. If he succeeded in doing so he had to forcibly press the knee to straighten the limb again. Any movement of this joint caused pain below the patella and in the popliteal space.

Hip Joints:-

Were not affected.

Metacarpo - phalangeal joints:-

Right hand:- Flexion was limited and caused pain. With difficulty he could bring the fingers within $\frac{1}{2}$ inch of the palm of the hand.

Marked localised pain over the right thenar eminence.

The inter-phalangeal joints were not affected.

Left Hand:-

There was no localised pain and he could touch the palm of his hand with the tips of his fingers but the effort caused great pain.

Wrist joints:-

About $\frac{1}{3}$ of the normal range of movement was permitted, but less than this when the fingers

were flexed. Movement caused pain.

Shoulder joints:-

Were stiff on waking in the morning but this soon passed off. There was pain over the acromion process. He could raise the arm to a horizontal position and on forward flexion about half way to the level of the shoulders. Backward flexion was normal

Elbow Joints:-

Flexion and extension limited, and movement caused pain.

Treatment:-

While in Ward 31 his treatment was as follows:- electricity, baths, phenacetin, asperin and salicin. Shortly after his discharge from the R.I.E his condition became worse and he was treated by Dr Thyne with similar remedies with little success.

He came under my care on February 20th 1908, and his condition was as follows:-

He could not walk without the aid of sticks and the assistance of a friend. He complained of pain, stiffness and swelling in his joints.

His ankles were swollen and oedematous, and no movement whatever could be elicited. They appeared to be

completely ankylosed, and any attempt at walking or movement caused shooting pains up the legs.

Knee Joints:-

Were both stiff and movement greatly limited. Creaking was elicited in both joints. The left knee used to give way under him and unless a support were near he fell over. Movement caused pain

Hip Joints:-

Left hip was stiff and the movement greatly restricted.

Right hip was painful, but the movements were little affected.

Metacarpo - phalangeal joints:-

Flexion greatly limited, and he was unable to bring the tips of the fingers nearer the palm than $\frac{3}{4}$ inch. Was unable to hold anything in the hands.

Wrist Joints:-

Movement caused pain and was greatly restricted.

Elbow Joints:-

Were painful. Flexion and extension were limited. About $\frac{1}{3}$ of normal movement retained

Shoulder Joints:-

Were swollen and stiff. On attempting movement pain and creaking elicited in both joints. Could not raise the arm to a horizontal position, and both forward and backward flexion were greatly restricted. Painful on pressure equally over both sides and best marked over the area corresponding to the acromion and coracoid processes.

His neck was stiff, and any attempt at movement caused great pain. His range of movement at the occipito-atlantoid joint was less than half the normal.

Respiratory System:-

In march 1905 he had some polypi removed from his nose. These gradually returned and when he was first seen by me were protruding from both nostrils. The left nostril was completely obstructed.

Circulatory System:-

Slight accentuation of the Aortic 2nd sound. There was nothing else abnormal to note in any other system.

Treatment:-

Fibrolysin injections (dose 2 3 CCs) were given every 3rd day. He had 24 injections given directly into the muscles of the gluteal region. From

the commencement the improvement in this case was most rapid. After 5 injections the movements in all the affected joints, with the exception of the ankles, became noticeable. After 12 injections the polypi disappeared and there was no further obstruction in the nasal passages. He could walk a mile or more with the aid of a stick, and complained only of tiredness in the ankles and left knee. The swelling in the joints had disappeared. There was no pain. The full range of movement was regained in the knees; hips, shoulders, elbows, wrists, and metacarpophalangeal joints. Full movement was also regained in the occipito,-atlantoid joint. The ankles, although much improved, were still stiff and only about $\frac{1}{3}$ of their normal range of movement returned. The joints still creaked but not to the same extent as before the treatment commenced. This case bears out the contention of Salfeld that the use of Fibrolysin should not be underestimated in cases of arthritis deformans. Its use in this case caused a rapid absorption of fluid, diminished crepitus, lessened pain, and above all increased the mobility of the affected joints.

Case 4.

Male, aged 30.

Complaint:- Stiffness of left knee.

Family History:-

Father Rheumatic.

Nothing further to note.

History of Present Condition:-

When a boy he had a bad synovitis of the left knee accompanied by a copious effusion into the joint. Two years ago the condition became worse and he suffered from severe pain behind the ligamentum patellae. The pain was so severe that the knee constantly gave way under him and soreness persisted, after an attack of this kind, for days. He knows of no special causal movement. No effusion or locking follows. There was no history of any accident to give rise to the condition. Has had to give up tennis and hockey.

There is very slight creaking in the joint on making attempts at movement. X ray showed a slight diffuse shadow due probably to thickened synovial membranes, behind the ligamentum patellae.

Diagnosis:-

Some rheumatic thickening of the synovial membranes with fringes or pedunculated bodies giving rise to the sudden symptoms.

On February 28th 1907 he was operated on by Mr W. J. Sturt. The joint was opened by Kocker's external J. incision and the patella was dislocated as for excision. The synovial membrane was generally thickened, but no fringe or tag was discovered. The thickening affected especially the ligamentum mucosum, intercondyloid notch and the femur above the cartilage in front. A considerable amount of thickened membrane was removed and the joint was closed. Healing was by first intention.

Patient would not permit the joint to be moved to any great extent, and stiffness resulted due probably to adhesions between raw surfaces in the joint.

Throughout the treatment the progress or otherwise was noted by tracings, of the angle of flexion of knee taken with flexible lead tubing and recorded.

Active and passive movements were tried, but flexion and extension of the limb became greatly impaired and all improvement ceased. An apparatus was devised in the form of an elastic band which was fastened round

the boot and attached to a belt, so as to exert continuous traction. This was used by the patient while at his office and also in his own house.

Massage active and passive movements were continued all through. Electricity was tried - high frequency and static and by April 1907 the angle of flexion, when the leg was forced back causing great pain, = 80° . There was still a distinct limp and he was unable to fully extend the limb. During the next three months there was very little improvement.

Fibrolysin was now used. The first injection was given on July 11th 1907, and a subsequent injection every alternate day. In this case the injections were given directly into the muscles surrounding the joint. Generally the patient complained of some soreness at night and the following day and at times a feeling of headache and lassitude.

The administration of Fibrolysin was marked by a steady improvement and he was able to cycle and play tennis during the last week of August. By the end of October there was practically no limp and the improvement has been steady and continuous. He is able voluntarily to flex the limb past a right angle

without any difficulty and extension is practically complete.

This case had in spite of massage active and passive movements resisted all treatment and it was not till Fibrolysin had been administered that improvement recommenced. The number of injections given were only 10 and were all applied locally and aided by active and passive movement combined with massage. It seems from this case that when Fibrolysin is assisted by mechanical measures and injected locally its action is more certain and rapid and it takes less time to effect a cure.

Case 5.

Female,

Aged 38.

History:-

Thirteen years ago she had an attack of appendicitis. An incision was made in the line of the fibres of the external oblique, over the usual situation of the appendix; the external oblique and its aponeurosis were divided in the same line and the edges were drawn aside; the internal oblique and transversalis were divided in the line of their fibres; the transversalis fascia and peritoneum were divided in the line of the external oblique.

The appendix was found, divided, and ligatured. The stump was invaginated by means of a purse - string suture. The patient made an uneventful recovery. Within a few weeks after the operation she began to experience pain behind the middle of the scar. This pain came on at irregular intervals, lasted for some hours and occasionally for a day or two.. There was no discoverable cause. It was uninfluenced by menstruation or exertion.

Two years ago she had an attack of what was called pelvic peritonitis.

On palpitation the scar was found to be slightly tender and a small nodule could be felt under its centre. She was examined by Dr W. D. Fordyce and her pelvic organs found to be normal. There was no marked constipation and no menstrual irregularity.

Diagnosis

Gastric adhesions between the caecum and abdominal wall.

Treatment:-

Fibrolysin injections 2-3 CCs were given every alternate day. In all 13 injections were given and up to the time of writing the patient has had no recurrence of the above symptoms and the pain has entirely disappeared.

Case. 6.

A.A.

Aged 49.

Occupation:- Iron-moulder.

Diagnosis:- Pain, the result of fibrous tissue involving branches of the lingual nerve.

History:-

Was operated on in Leith Hospital for carcinoma of the tongue. The operation was performed in two stages - viz.:- The right half of the tongue was removed and three weeks later the affected glands in the neck. The operation was completely successful so far as the malignant condition was concerned. He, however, almost immediately after the operation, complained of pain in the stump of the tongue. The pain was described as dull and aching and at times ^{more} severe and yet was never absent. The pain was sufficiently severe to keep the patient awake night after night. Three months after the operation and after the failure of all other remedies Fibrolysin was used.

The injections in this case were given into the muscles of the shoulder every 4th day. The amount of the

drug used was 4 CC's. After 4 injections the patient stated that he had never had so little pain since the operation was performed and that he had slept better than he had done for months. In fact he was so well that he requested to be discharged from hospital although further treatment was advised.

Case.7.

Mrs R.

Aged 60.

Occupation:- Housewife.

Diagnosis:- Gastric adhesions.

History:-

Was operated on by Mr Cotterill for gall stones, a cholecystectomy being performed. Her recovery was uneventful. After leaving hospital she complained of pain in the right side below the costal margin. These pains were of a dragging character and were accompanied by abdominal swelling, nausea, and vomiting. The condition was temporarily relieved by vomiting but invariably returned.

Drugs, dieting etc., were persisted with for some months but without any amelioration of the symptoms. After a careful examination no organic disease was discoverable and her condition was diagnosed by Mr Cotterill as gastric adhesions secondary to the operation.

Fibrolysin(4 CC) was injected every 4th day into the gluteal muscles. After 3 injections the dragging pain completely disappeared. On the 20th day after the treatment was commenced the patient had an

attack of epigastric pain accompanied by abdominal distension. The hepatic flexure was chiefly involved. There was, however, no vomiting and the attack was much less severe than its predecessors. Ten injections in all were given in this case with the result that the patient was sufficiently well to return to her ordinary duties and was entirely relieved of pain.

Case. 8.

Name. T.G.

Aged. 67

Occupation:- Furnaceman

Complaint:- Retention of Urine.

History:-

Was admitted to Ward VI. R.I.E on Jan. 4th 1908 suffering from retention of urine. He gave a history of having had gonorrhoea 40 years ago and was treated at that time by the army surgeon. The attack was not severe and he was treated by complete rest, diet, drugs etc., and remained in hospital for a month. There is no history to be obtained of syphilis. He first experienced difficulty in the act of micturition 31 years ago when he noticed the stream forked and the time taken in the passage of urine much prolonged. He never had complete retention till he was admitted to the R.I.E. On rectal examination his Prostate was found to be enlarged and tender.

TREATMENT

A hot bath and a morphia suppository was tried but failed to relieve the condition. Various instruments

were used without relieving the condition. Aspiration above the symphysis pubis, however, immediately relieved him. Fibrolysin 2.3 CC were given and on the following day the stricture allowed the passage of a filiform bougie.

He was given 3 more injections, one every 2 day. and after 8 days the stricture admitted a 9-12 Listers' bougie with ease.

In this case the Fibrolysin paved the way for the easy passage of the instruments and when discharged there was no difficulty in micturition. Further dilatation in this case will be employed and no more Fibrolysin given as the mechanical process is sufficient to dilate the softened tissue in the urethra after it has once been acted on by Fibrolysin.

Case 9.

G.M.

Aged 25 - single.

Occupation:- Plumber.

He was admitted to Ward XXIX. on Jan., 22nd 1908, and complained of numbness and weakness of the hands and left leg.

Family History:-

Father died aged 55, cause biliary colic.

Mother died aged 53, cause heart disease.

3 Brothers and 3 Sisters active and healthy.

1 Brother died in infancy.

No history of venereal disease.

No previous illnesses or accidents.

History of Present Illness:-

Patient had no trouble till 7 weeks previous to admission to the R.I.E. His complaint started by a sudden feeling of giddiness and weakness of the left leg, and he says he reeled about like a drunken man. This condition continued for about three days and he then became confined to bed where he remained for seven weeks previous to his admission. Five weeks after the onset of the present condition he complained of weakness and numbness in both hands. His general health has not

suffered. He shows no other obvious morbid appearances.

Condition on admission:-

His general health and nutrition are good. He complains of a feeling of numbness and tingling in both hands, and in the left lower limb below the knee. There is also a feeling of coldness down the back of the left leg. Sensibility to touch is much impaired over both palmar and dorsal surfaces of the left hand, with the exception of a small area in the palm where touch is fairly well perceived. There is impairment of sensibility to touch to a less marked degree over the extensor surface of the left arm, and over the lower limb below the knee. Sensibility to pain is dulled to a slight degree over both hands, and left ankle and foot, being most marked, however, over the left hand. Sight is good and has never shown any impairment and the discs and fundi are healthy. The pupils are moderately dilated equal and regular and react both to light and accommodation. Hearing, taste, and smell unimpaired.

Motor:-

Organic reflexes normal. Plantar reflexes

give extension. Abdominal, cremasteric, epigastric scapular, and cilio-spinal reflexes present, but not exaggerated. Achilles jerk much exaggerated especially on the left side. Knee jerks greatly increased and ankle and knee clonus marked, all of these being best seen on the left side. Adductor jerks lively. Wrist, supinator, biceps and triceps jerks all slightly exaggerated, equally on both sides. Muscles show no wasting, but they show a considerable weakness especially on the left side.

There is marked inco-ordination of all 4 limbs, finger to nose, heel to toe tests etc., being very imperfectly performed. Rombergism present to a marked degree. There is no tremor, intention or otherwise. Muscular sense impaired.

Speech shows no departure from the normal.

His gait is reeling. There is spasticity of left lower limb and it is inclined to drag and his walk is reminiscent of the alcoholic.

There is nothing abnormal to note in any of the other systems.

Treatment:-

He attended the electrical department

every 2nd day and seemed at first to gain some temporary benefit but in the beginning of March he suddenly lost all power of both legs and lay listless and unable to move. He complained of diplopia and his face muscles became weak and he developed right sided facial paralysis.

At this stage the treatment by Hypodermic injections of Fibrolysin was commenced. The ocular symptoms began to disappear and movement of the limbs was once more regained. The right sided facial paralysis was almost entirely absent and the strabismus was no longer present. He can move his leg in all directions and he has no difficulty in walking 100 yards with the assistance of a stick. Ankle and knee clonus although still present is much less marked than it was during the previous week and the condition leaves little to be desired. The dose of Fibrolysin employed in this case was m. XXX. administered every 2nd day. Although still under treatment his progress is sufficiently rapid and marked to suggest that Fibrolysin can act on pathological fibrous tissue irrespective of its cause or situation.

C O M M E N T A R Y.

The published records of cases treated by Fibrolysin are definitely encouraging, and the results obtained are sufficiently numerous to claim for it a high place in therapeutics. It has constituted a real advance in the treatment of scar tissue and it is superior to radio-therapy both in the matter of results and its ease of application.

Thiosinamin, which is the most potent constituent of Fibrolysin, belongs according to Pohl" to the little known substances which in the lower animals is called "Alkylsynthese" and it is this which appears to give the drug its important therapeutic value. Pohl also states that these are the only alkyl combinations which have no poisonous effects"

"If given to the lower animals either by the mouth subcutaneously, intramuscularly, or intravenously

Thiosinamin causes a gradual prolongation of expiration.

The character of the exhalation shows the presence of alkyl sulphides. In 24 hours the animal breathed out 24 milligrammes of sulphide but this is much less than the total amount of thiosinamin taken. The rest of the thiosinamin is passed in the urine unchanged.

The presence of Fibrolysin can after injection be detected by the mawkish odour of the patients breath. The patient is also conscious of a peculiar taste in the mouth. This is said to occur after intravenous injection and the effect was produced in all my cases whether the subcutaneous or intramuscular injection was employed. Mendel claims that this is a proof that Fibrolysin is immediately broken up into its component parts Thiosinamin and Sodium Salicylate, and as the decomposition takes place more rapidly after intravenous injection he advocates this method of treatment as being the most rapid and efficacious. The intramuscular injections have their advantages over the intravenous and subcutaneous injections. After subcutaneous injection of Fibrolysin the patient complains of some transient pain which passes off in a few minutes and leaves a reddened area which sloughs and destroys the whole thickness of the skin. My experience of the intravenous method of using Fibrolysin is limited to 2 cases and was attempted once in each case. Both patients complained of headache, lassitude and vomiting and the symptoms were sufficiently severe to prevent this method being employed again.

Mendel, however, states that Fibrolysin given intravenously causes no clotting of blood and has no harmful influence on the blood corpuscles thus excluding all danger of embolism. He advocates the injection into the large veins and states that no injury follows to the endothelial lining of the vein and that repeated injections may be employed in the same situation without causing thrombosis. In the smaller veins small thrombi are liable to form. The one advantage of this method is its rapidity and intensity of action and it is therefore useful in conditions where it is necessary to relieve pain after one injection.

The intramuscular method:-

Is the simplest and the method that should be generally adopted. It is painless and I was unable to find any instances where any untoward symptoms have followed its use. Discoloration of the skin around the seat of injection which has the appearance of a bruise may occur and last for a few days. I have also noticed a small nodule about the size of a pea follow this method but it disappears and leaves no bad effects.

General disturbances following the use of the drug are said to be very rare and the statement made by Lewandowsky that Fibrolysin should not be used in acute inflammatory conditions is refuted by Mendel.

Hirschland, Mendel, and Salfeld have each given over 300 injections without reporting any bad results.

Blood changes:-

After injecting Fibrolysin changes are noticed in the blood. Generally after an injection there is an appreciable diminution in the number of red blood corpuscles accompanied by a leucopenia. This condition lasts for about 1 hour when a blood count shows that the red blood cells have reached their normal number again and there is a marked leucocytosis. The number of leucocytes present in all my cases was over 20,000 and averaged 25,000

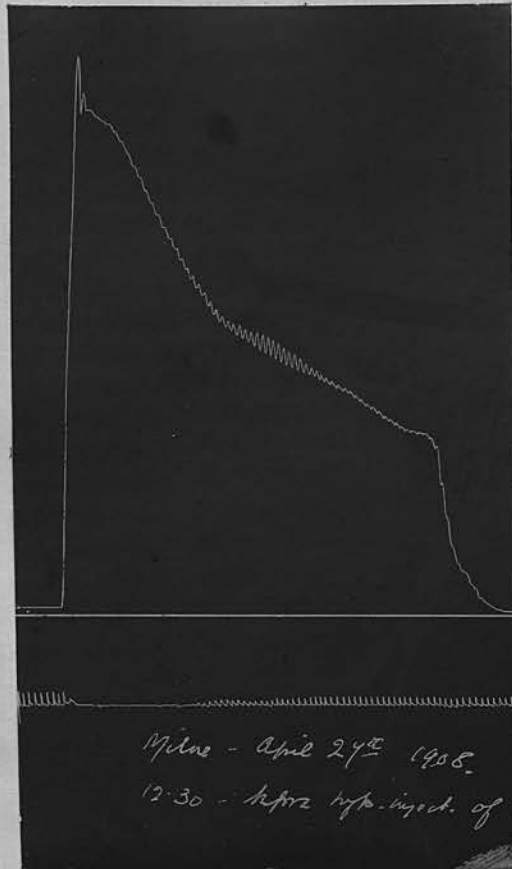
The maximum leucocytosis is gained in 8 hours and in 48 hours the number of leucocytes is again normal.

The effect on the blood pressure after an injection of Fibrolysin is interesting.

The following tracings were taken with Dr G.A. Gibson's Sphygmomanometer from Case 9 who was suffering from Disseminated Sclerosis. The tracings were taken

from the same arm and under similar conditions at intervals of one, two and a half, five, eleven, and twenty-five hours after injection.

Tracing I.



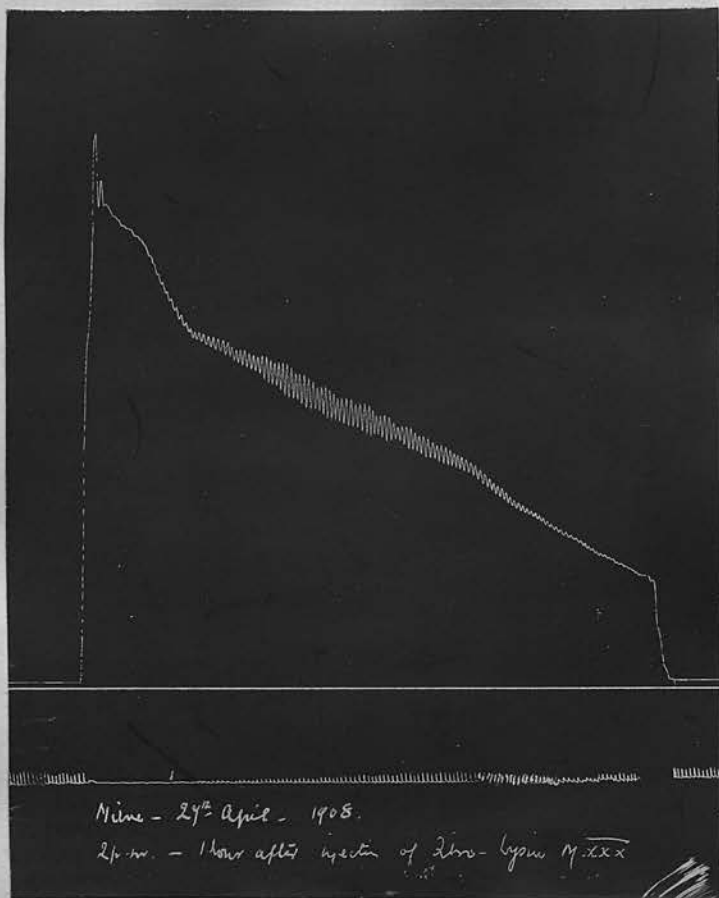
abscissa.

Radial Pulse

Maximum Systolic Pressure = 92 m. m Hg.
 " Diastolic " = 70 m m Hg.

Injection given at 12:30 am before hypodermic
of Fibrolysin (M. XXX).

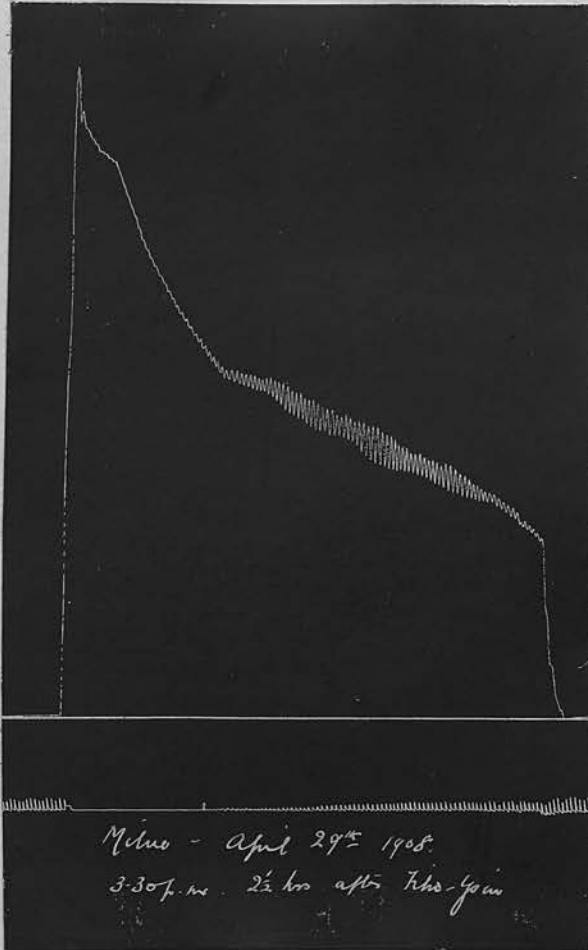
Tracing 2.



Maximum Systolic Pressure = 106 mm.Hg
 " Diastolic Pressure = 83 mm.Hg

2 p.m. 1 hour after injection

Tracing 3.




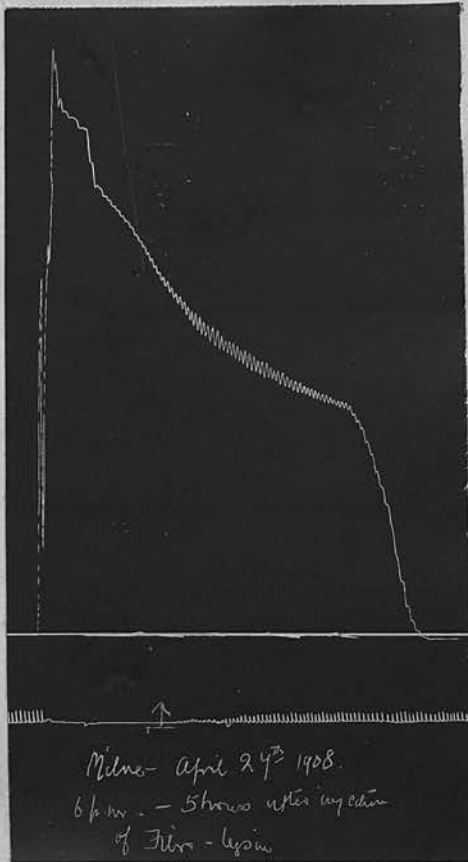
Maximum Systolic Pressure = 104 mm Hg
 " Diastolic " = 76 mm Hg

3:30 p.m. 2 1/2 hours after injection.

Tracing 4

58.


Tracing 5



M.S.P = 90 M M Hg
M.D.P = 72 M M Hg
6 p.m. - 5 hours after injection.

M.S.P. = 94 M M Hg
12 am. 11 hours after injection

Tracing 6.



M.S.P = 96 M M. Hg

2 p.m. 25 hours after injection.

At first there was a marked increase in both the systolic and diastolic pressures. The tracing which showed the greatest increase being the one taken 1 hour after injection. Thereafter the pressure, both systolic and diastolic fell, till at 5 ^{hours} ~~o'clock~~ it had become lower than it was before injection. Later it gradually rose to the normal.

From these tracings and from the estimation of the blood pressure by Riva Rocci's sphygmomanometer, Fibrolysin causes an initial rise followed by a negative phase and then a return to normal.

Its effect upon a cheloid or the scar of a burn has been recorded by many observers and I have on this subject only verified their statements.

In the scar tissue which remains after a burn the changes can easily be demonstrated. Almost immediately, after an injection is given in the region of the scar tissue, the colour of the scar becomes paler and the tissues appear to be infiltrated. The movements in the region of the scar become much easier and its elasticity becomes greatly improved. A serous infiltration can be demonstrated and is similar to the infiltration caused by Bier's congestion and is the active

process in softening the scar tissue and facilitating absorption. On examination of the scar tissue microscopically the outlines of the connective tissue become indistinct and the strands of fibrous tissue swollen and the connective tissue nuclei separated (Mendel)

Lange has demonstrated in frogs that Fibrolysin causes in toxic doses not only absorption of pathological fibrous tissue but also an anasarca in the physiological tissues.

It still remains a difficult question to decide as to whether the drug acts in its action on the tissues, unaided or assisted by some mechanical agency or to the local or general inflammatory action induced.

The difficulty in deciding this question is not rendered any easier by the apparent therapeutic value of administration which has been obtained by administration in cases of internal fibroid overgrowth (Disseminated Sclerosis, gastric adhesions) etc.,. As already mentioned Mendel considers the improvement to be due to the direct action of the drug causing an inflammatory process viz:- "serous infiltration". Yet one must also consider the

leucocytosis, which I have noticed in my cases, as a very possible reaction which may be responsible for the dissolution of the scar tissue.

Now has the drug any specific action on fibrous tissue? Has it any other action than that of an ordinary irritant inducing inflammatory reaction in the tissue or has it a specific action?

Certainly its action is greatly enhanced the nearer the *site* of the diseased tissue the injection is carried out and this is still further assisted by the combined use of systematic local massage.

S U M M A R Y.

That the administration of Fibrolysin in certain conditions of overgrowth of pathological fibrous tissue is of value I feel convinced.

From the cases I have had opportunity of studying the best results were obtained where local injections were employed. The nearer the injection to the *site* of the disease and especially if assisted by local massage the more rapid and more effective the result. It causes a transient leucocytosis and a coincident variation in the blood pressure of the nature of a rapid rise and a subsequent fall.

Where a more general action is required for the treatment of internal conditions the gluteal intramuscular method was the most useful.

In direct local action such as the scar tissue following a burn it acts almost immediately, the scar becoming paler in colour and more transparent the tissue becoming relaxed and the range of movement becomes considerably improved. This however, is only transient and must be repeatedly carried out to effect a permanent cure.

Injections should be given every 2nd day in doses of 2.5 CCs largely depending on the case but as an average in the cases which do improve requiring 20-50 injections. The solution of necessity must be sterile and should not be exposed to light or air as a precipitation of white crystals of Thiosinamin is apt to occur. If injected in this precipitated form the risk of abscess formation is considerable. Also in cases where there has been a formation of fibrous tissue in the internal organs such as gastric adhesions, intra thoracic adhesions and various nervous lesions there is in many cases undoubted good, which can be achieved by the administration of Fibrolysin.

L I T E R A T U R E.

1. E. Mendel. Therapeutische Monatshefte 1905, No 2 & 4.
E. Mendel. Therapie der Gegenwart 1905, No 8 p. 378
2. W. Doevenspeck Therapie der Gegenwart 1905, 6 & 10.
3. Hirschland. Archiv für Ohrenheilkunde 1905, No 2 & 3.
4. Kalberlah. Münchener Medizinische Wochenschrift
1905. No 44.
5. S. McCullagh. Medical News 1905, 30 December.
Internationales Zentralblatt für Ohrenheilkunde
1906 No 9 page 415. Zentralblatt für die gesamte
Therapie 1906 No 6.
6. Dr Sydney Gardiner.
7. Dr Aldo Castellani. Proceedings of British
Medical Association, Ceylon Branch. June 29th 1907.
8. J. Plesch. Wiener Klinisch Therapeutische
Wochenschrift. 1906 No 16 page 365.
9. Jellinek. Wiener Klinische Wochenschrift 1906,
No 23 page 369.
10. K. Pollack. Therapie der Gegenwart 1906 No 3,
page 97. Semaine Médicale 1906, No 24 page 280.
11. Weisselberg. Münchener Medizinische Wochenschrift
1906, No 33 page 1623.
12. Combe. Revue Médicale de la Suisse Romande 1906
No 2.

13. A. V. Planta. Korrespondenzblatt für Schweizer Aerzte 1906, No 18.
14. Waelsch. Munchener Medizinische Wochenschrift 1906, No 48 page 2350.
15. O. Woltke. Medizinische Oboerrhenie 1906, No 10.
Bulletin Medical 1906, No 51.
Revue de Therapeutique 1906, No 15 page 523.
16. K. Boseck. Munchener Medizinische Wochenschrift 1906, No 48 page 2350.
17. Grunert, ibidem 1906, No 37 page 1831.
18. Bruno. Rivista Internazionale di Clinica e terapie 1906, No 2. Wochenschrift für Therapie und Hygiene des Auges 1906, No 9.
19. B. Salfeld. Therapeutische Monatshefte 1906, No 12.
20. Herschell. Folia Therapeutica, July 1905
21. Baumstock. Berlin Med. Wochenschrift: 1904, No 24.