

D. S. Middleton  
—

COMMENTARY

ON

1921

INTESTINAL TUBERCULOSIS.



## INTESTINAL TUBERCULOSIS.

Abdominal Tuberculosis may be divided into three great types:-

1. Intestinal.
2. Glandular.
3. Peritoneal.

The three cases just described introduce the Intestinal type of the disease, and this type alone can therefore be dealt with here.

Intestinal Tuberculosis is usually described as belonging to two classes.

1. Hypertrophic or Ileo- Caecal type.
2. The Entero-peritoneal type.

It must be pointed out at once that these two types are in no way different diseases except in their prognosis.

Their Etiology is the same, but the chronic form occurs in the healthy more or less resistant individual while the acute form is seen in the person who puts up no resistance to the Tubercle Bacillus. This question of resistance is also probably responsible for the different portions of the alimentary canal attacked in the two forms.

The/

The terms would therefore describe the two extremes of the disease, but many cases are seen which are intermediate between the two and can hardly be allocated definitely either to the one or the other type.

Intestinal Tuberculosis usually occurs in persons suffering from a Tuberculosis<sup>us</sup> Lung lesion as a result of swallowing of infected sputum. Infection by milk is believed to be rare in the adult and in the child it tends to produce glandular Tuberculosis rather than Intestinal.

The end result is however that we have Tubercle Bacilli, derived from some source, travelling along the intestine with the food contents. Now these food contents pass very rapidly along the small intestine especially the jejunal portion, but are delayed for a considerable length of time in the Caecum for the purpose of the absorption of water.

The Tubercle Bacilli will travel along with the food contents, and will also be hurried along the small Intestine and delayed in the Caecum.

It is here that the individuals resistance to Tubercular infection comes into play. The healthy individual can deal with the few bacilli gaining entrance to the Peyer's patches of/  
of/

of the small intestine during their hurried transit, and as a result his small intestine will take no damage. It is, however, a different matter when a large number of bacilli are allowed to lie in contact with the mucosa of his Caecum for a considerable length of time. Here, unless resistance be very strong indeed, the mucosa will be eroded by the Bacilli, ulcers will form and the bacilli will gradually invade the wall of the intestine. The tissues of the individual being capable of strong reaction throw down the usual barrier of fibrous tissue to limit the advance of the bacilli, which however progress slowly in spite of the formation of more and yet more fibrous tissue.

This struggle runs a very slow chronic course extending over months or years, with the formation of a palpable Ileo-caecal tumour, and gradually increasing stenosis of the gut, eventually if untreated, terminating in acute obstruction.

This then is the one extreme of the disease seen in the resistant individual. In the individual whose powers of resistance are small or non-existent, such as, for instance, the advanced case of Phthisis, the Bacilli pursue a very different course.

Passing down the small intestine they enter many of the Peyer's patches and solitary follicles, poliferate and cause extensive ulceration of the mucosa. No resistance being  
forth-/

forthcoming, the ulceration extends deeper and deeper till the Peritoneal coat becomes diseased, and the ulcer perforates, into the Peritoneal cavity or into an adjacent coil of intestine. This ulcerative process may take only a matter of a few days between its onset and the death of the patient from Peritonitis.

This then is the very acute Entero-Peritoneal type of the disease. Between this style and the hypertrophic type lie all degrees of chronicity or acuteness, depending on the resistance of the individual affected.

Diagnosis in the very acute type as in Case<sup>2</sup>~~1~~, seen as a terminal complication of an advanced case of Phthisis presents no difficulty.

(AS IN CASE III) **The** very chronic uncomplicated form affecting the Ileo-caecal region causes typically long-continued discomfort in the Ileo-caecal region with colicky pains relieved by borborygmi and eventually a persistant sausage shaped tumour becomes palpable. By the time this occurs, the history has usually covered a period of 2 - 3 years and this forms the main point of differential diagnosis from malignant disease.

Cases of Ileo-Caecal tuberculosis are frequently mistaken for a chronic form of appendicitis and in the later stages, when the obstructive factor commences to come into play, symptoms/

symptoms not unlike attacks of acute appendicitis may show themselves, without any actual disease of the appendix being present. Many cases are recorded of laparotomy having been performed on a diagnosis of acute ~~appendix~~<sup>a</sup>, a normal appendix and a Tuberculous Caecum having been found.

Actual acute appendicitis, tends however, to occur comparatively frequently in two ways:-

(1) Stenosis of the base of the appendix by contraction of the fibrous tissue laid down in a tuberculous Caecum.

(2) Actual Tuberculosis of the Appendix.

Tubercles develop in the mucosa of the ~~appendix~~<sup>a</sup> and before they have become macroscopic produce obstruction of the Lumen and resulting acute symptoms. These tubercles, microscopic as they usually are, are very apt to be missed during the pathological examination, and if tuberculosis elsewhere around the Ileo-caecal region has not been noted at the operation, the case is put down as an ordinary acute Catarrhal appendicitis, the deeper tuberculous origin of the condition being missed.

Obviously under such conditions, tuberculosis of the appendix will be considered a rarer condition than it really is.

Osler/

Osler puts down tuberculosis of the appendix as occurring in 1 per cent of all Intestinal Tuberculosis.

Intermediate Cases of tuberculous disease of the intestine  
(as in Case I) mainly affecting the Peyer's patches with ulceration and a good deal of reactionary fibrotic thickening, present the most difficult type in which to arrive at a diagnosis. The Lungs are, of course, almost invariably diseased, but slight degrees of Pulmonary tuberculosis, quiescent, it may be, are difficult to diagnose.

Colicky pains accompanied by irregular attacks of diarrhoea alternating with constipation are the usual text-book description of the disease, but many cases present a history entirely of constipation or even of no disturbance of the bowels.

Tubercle may in some cases be isolated from the stools, and if found are almost pathognomonic of Tuberculosis of the intestinal tract, when abdominal symptoms are present.

The condition must be kept in mind where vague abdominal pain and discomfort are complained of, and especially if an area of superficial hyperaesthesia be present around the Umbilicus, this area being ~~that~~ described by Mackenzie and Head, as being that connected with referred pain from the small intestine.

In practice, however, it is found that many cases of this disease are not diagnosed except on the operating table.

Treatment /

## Treatment

- (1) The very acute terminal type of the disease is invariably fatal and no treatment is<sup>s</sup> of any avail.
- (2) The most<sup>11E</sup> chronic cases affecting the Peyer's patches may, if localised to a comparatively small segment of the bowel, be treated by complete excision. Before this is thought of, however, the whole alimentary canal must be carefully examined and found free of disease.

Failing excision, if the disease is confined to a loop of small intestine, it can be isolated and put at rest, by a lateral anastomosis between the bowel above and that below the disease. Rest, of this sort, which is practically complete, is found to be quite as successful as it is in other tuberculous affections, such as tuberculosis of joints.

If the disease is too widespread for either of the above methods, recourse must be had to the general hygienic treatment of tuberculosis.

- (3) The Ileo-Caecal. This condition is only too often seen by the surgeon when on the verge of obstruction and when the peri-caecal areolar tissue<sup>15</sup> is infiltrated. It must be emphasized that the condition is readily diagnosable before this stage, and in all probability would be diagnosed easily enough if/



if the existence of the condition were only borne in mind by the medical attendant. Comparitively early operation holds out an excellent chance of complete cure.

The procedure followed is usually to effect at a first operation a communication between the Ileum above the disease and the transverse colon just below the hepatic flexure. This is unusually done by cutting the Ileum across, closing the lower end and implanting the upper ~~stemp~~ by end-to-side anastomosis into the colon.

This operation in itself holds out a fair chance of natural cure ~~and~~ by the rest it gives to the Caecum. It is better and more certain, however, to open the abdomen a second time and excise the whole Caecum and ascending colon completely, along with any infected lymph glands.

*S. Middleton*

THREE CASES

OF

INTESTINAL TUBERCULOSIS.

CASE I.

George Macleod. Aet 61.

Melwick,

Thurso,

Sutherlandshire.

Recommended by

Complaint.

Previous Illnesses.

History.

Dr Baird, Armadale, Sutherlandshire.

Pain in Abdomen of 14 days duration.

The Patient has at intervals during the past 20 years had attacks of Sciatica in his Right Leg. He had Bronchitis more than a year ago. He has never had previous trouble with his stomach.

Although his present illness has only lasted for 14 days, the patient has been "off colour" for the last few years, with slight headaches, malaise, and a little nausea after his food. For about two months he has had a slightly yellowish colour, and for the last month has had a sensation of fulness in the abdomen, but he has never had any vomiting.

About a fortnight ago he began to have pain after food in the/

the region of the umbilicus. The pain was of a dull boring type, and was intermittent in character, coming on about an hour after food and lasting for from two to four hours.

The taking of food has never relieved the pain or made it worse. He has had no vomiting and has never noticed any obvious Melaena. He is thinner than he used to be and thinks he has lost some weight. His bowels have always been pretty regular, never having any diarrhoea, but occasionally being constipated.

Examination.

Abdomen. is somewhat Scaphoid. Liver dulness normal: Kidneys and Spleen impalpable. Some rigidity of the Recti and some splashing in the Stomach. Well-marked tenderness on pressure in the immediate vicinity of the Umbilicus, and definite hyperaesthesia can be elicited just around the Umbilicus.

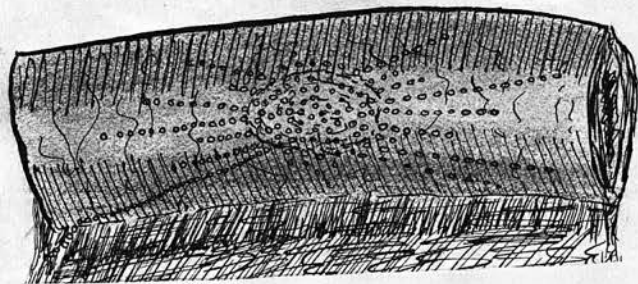
Per Rectum. No abnormality was made out.

Bismuth Meal. Was normal except for some slight delay in the stomach.

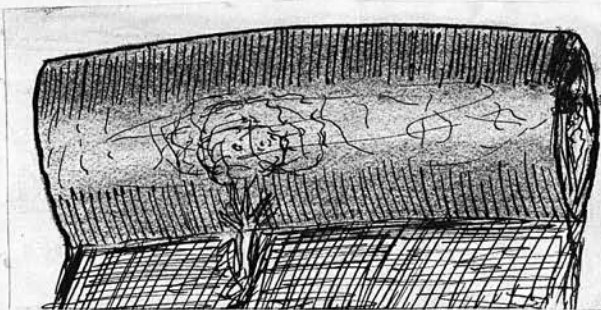
Test Meal. Total acidity 120. Free HCl 60.

Other Systems normal. (Note: ~~number of~~ <sup>No</sup> lesions found in Lungs).


No very definite diagnosis was arrived at, but an exploratory laparotomy was decided on.



PERITONEAL SURFACE OF ULCER  
WITH RADIATING SUB-PERITONEAL  
LYMPHATIC TUBERCLES.



SHOWING APPARENT SPREAD FROM  
AN ULCER BY WAY OF LACTEALS.



SHOWING THE WAVY  
WHITE CALCIFIED LINE  
REFERRED TO IN THE  
TEXT.

PROBABLY AN INFECTED  
AND CALCIFIED SUB-PERITONEAL  
LYMPHATIC VESSEL.

OPERATION.

(Mr Wilkie.)

An exploratory mid-line incision was made and the abdomen thoroughly examined. Omental adhesions to the Gall-bladder were divided. On palpation a few calcereous glands were felt in the Mesentery of the lower Ileum. The Stomach and Duodenum, Ileo-caecal area and Colon were apparently normal.

The small intestine was then examined systematically, and eighteen tuberculous ulcers were found. The highest ulcer was 2 feet from the Duodeno-Jejunal flexure, and the lowest about 4 feet above the Ileo-caecal valve. The ulcers were oval in shape lying in the long axis of the intestine and were clearly showed up on the peritoneal surface by a crop of minute subperitoneal tubercles which covered the ulcer area and radiated from it in lines following the directions of the subperitoneal lymphatics even in some cases to the Mesentery. In another type the Lacteals leading from the ulcerated area were found to be yellow in colour, enlarged, and hard. Many of the ulcers were considerably fibrosed. At one point about the middle of the small intestine, a white wavy line was seen under peritoneum, intensely hard and apparently calcareous (see diagrams of Ulcers found)

SEE DIAGRAMS.

The/

The abdomen was then closed and the patient returned to bed.

Progress. The patient had some diarrhoea for a week after the operation but this then ceased. He ran a slight temperature for a few days but declared he felt much better. He was discharged in about 17 days with the wound entirely healed.

---

CASE II.

Margaret Mackie. Aet 45.

Poorhouse Hospital,

Linlithgow.

Recommended by.

Dr Hunter, Linlithgow.

Admitted.

27.12.20 to Ward 8.

The Patient was admitted on the evening of waiting-day in a moribund condition with a note from the Doctor to say that she had had acute abdominal pain for some days and he suspected Peritonitis. The patient was too collapsed to give much history. She had had acute abdominal pain for some days accompanied by frequent vomiting, which during the past 48 hours had been almost faecal in character. Her bowels had not opened for 4 days. She never had been troubled with diarrhoea.

The Patient had suffered for over a year from advanced Phthisis and had been treated for this in an institution.

Examination.

The Patient was very weak, extremely emaciated and in great pain. The abdomen was <sup>t</sup>humid and failed to move with respiration./



respiration. Great tenderness was elicited below the level of the Umbilicus.

A diagnosis was made of "obstruction" probably due to Tuberculous disease of the Intestine, and instant operation decided on.

#### OPERATION.

Mr Wilkie operated, making a midline incision below the umbilicus under local anaesthesia and performed a rapid Ileostomy on the first distended coil of small intestine that presented. The abdomen was then quickly closed, but the patient succumbed shortly afterwards.

#### Post-Mortem Report.

Abdomen. Generalised acute Peritonitis with faecal matter in the cavity. About 3 feet below the duodeno-jejunal flexure, small shallow ulcers became visible. These increased in number and size as the intestine was traced down, reaching their maximum intensity in the Ileo-caecal region.

The Jejunum showed three fair-sized perforations, the highest about five feet below the duodenum, and the Ileum became riddled with holes as the adjacent coils which were matted together by recent lymph were separated. The lowest perforation was a large one about the/

the size of a shilling, just a few inches from the Ileo-caecal valve.

The Large Intestine showed ulcers as far down as the middle of the Transverse Colon. None of these were, however, perforated.

No caseation of Mesenteric Glands.

Liver. Well-marked Chronic Venous Congestion and fatty change. Numerous Military Tubercles throughout.

Kidneys. Toxic changes marked. One small tubercle seen in the medulla of the left Kidney.

Ureters, Bladder and Suprarenals healthy.

Pleural Cavities both obliterated entirely by dense adhesions.

Lungs. Both lungs show extensive cavitation in their upper parts. The cavities are mainly recent and acute, though a few show signs of some fibrotic reaction. The Lower lobes contain small acute cavities and also a few grape-like clusters of peribronchial tubercles.

The Root Glands are not involved.

Heart. Right side slightly dilated. Fatty infiltration at apex of Right ventricle. Left side healthy.

Early atheroma of the Aorta.

CASE III.

Patrick McBride. Aet 16.

47 Engine Street,  
Bathgate.

Admitted to Ward 7, R.I.E., on August 16th, 1920, with a history of having been taken suddenly ill while in his usual health. He had been eating green pears 24 hours prior to admission. He complained of colicky pains in the abdomen at first general, later settling down to the Right Iliac Fossa. He had no vomiting. No previous attacks had been experienced. When taken ill, castor oil produced a good motion of the bowels.

On examination his Temperature was 100° F. and his Pulse 116.

There was well-marked superficial and cutaneous hyperaesthesia over the appendix area. There was also well-marked deep tenderness and a good deal of rigidity of the abdominal muscles, especially in the Right Lower Quadrant. Some discomfort on micturition was complained of.

A diagnosis of Appendicitis was made and Mr Wilkie operated soon after admission.

The abdomen was opened by the gridiron method in the usual/

usual fashion and a mass of inflamed omentum was found wrapped around the lower end of the Caecum and the Appendix which was lying between the lateral wall of the Caecum and the Peritoneum of the Right Iliac Fossa in a little abscess cavity containing about 43ss of thick odourless yellow pus. The Caecum did not come to the surface easily and it was torn at one point in attempting to bring it out of the wound. This tear was closed and the caecum was finally mobilised and the appendix removed in the usual manner, the stump being invaginated.

The perforation was found to have occurred in a small patch of gangrene near the base of the appendix.

The abdomen was closed with drainage.

The progress of the case was good and the patient was discharged on 6.9.20 with the wound practically completely healed.

On the 29.11.20 the patient was re-admitted with pus still discharging from the lower end of the appendix wound.

On giving an enema, fluid discharged from the abdominal wound.

Examination of the lungs showed dullness over the left upper lobe and retraction below the clavicle. Vocal Resonance was/

was increased and abundant crepitations of all tones could be heard over the left upper lobe.

On 4.12.20. Mr Wilkie operated under general anaesthesia.

A probe was passed in between the two sinuses found to be present and the skin was found to be undermined. An incision was accordingly made down to the muscle and the wound enlarged. One sinus was now found to extend upwards, backwards and inwards towards the Caecum and the other one almost directly backwards and downwards.

The muscle was next incised together with a good deal of scar tissue underlying it, and a fistula was found to extend down to the Caecum, opening into its upper end. The Caecum was contracted and hard, being non-existent below the level of the Ileo-caecal valve, which could be palpated through the wound. Specimens of granulation tissue which appeared to be Tuberculous in nature, were removed from the sinuses.

The whole wound was now prolonged upwards so as to expose the Caecum and Ileo-caecal valve more freely and a dressing was/

was applied.

The patient recovered from the operation well and fluid faeces discharged from the wound freely.

No Tubercle Bacilli were found in the granulation tissue removed.

On the 21.12.20 17 days after his operation, the boy developed acute abdominal pain, vomiting and a definite ladder pattern, and although the patient was in a very weak state, operation was imperative, and was undertaken by Mr Wilkie on the 22nd under local anaesthesia.

A small left parmesial incision was made below the Umbilicus splitting the left Rectus. The Peritoneum was opened and omentum studded with miliary tubercles presented. This was torn through and a dilated knuckle of jejunum presented which was carefully pulled out and found to be devoid of any lesion. This knuckle of bowel was rapidly opened and a rubber tube was inserted into lumen and securely stitched in position. The bowel was stitched to the parietal peritoneum and the wound quickly/

quickly sutured with Iodine Tannic Acid Cargut, and Silk-worm Gut Sutures.

Subcutaneous saline was administered to the extent of two pints.

The patient however grew weaker and died the next morning.

Note on Line of treatment which was to have been carried out in this case after the Caecostomy.

It was proposed when the Caecostomy was acting well and the boy was fit for operation, (which he unfortunately never became) to immunise him with B. Coli Vaccine and injections of Sodium Nucleinate to raise his leucocytosis, 24 hours before operation.

This operation would have taken the form of an anastomosis between the lower end of the Ileum and the beginning of the transverse colon, the diseased portion being thus isolated and drained of its contents by the faecal fistula present.

At yet another operation, the offending and isolated intestine would have been completely excised.

Post-Mortem Report.

Peritoneum. General Peritonitis. Acute tuberculosis with a superadded Pyogenic condition. The Obstruction was due to kinking caused by adhesions low down in the Ileum, the lower coils of which were matted together. These adhesions appeared to be a week or two in age. In the region of the Caecum the adhesions were of longer standing.

The Jejunum was distended and it was obvious by inspection of the Peritoneal surface of the intestines that there were numerous ulcers present on the mucous surface of the Jejunum and Ileum. In many of these ulcers, the floor was very thin and several appeared to be on the point of perforation. This condition would allow of the passage of organisms from the bowel to the Peritoneal cavity with ease. The Lower Ileum and the large Gut were collapsed.

On opening the intestines numerous ulcers, mostly small in size, were seen. These were all recent and had little reaction around them. They extended from about a foot below the duodeno-jejunal flexure to the ascending colon. The Caecum was shrunken and exhibited/



exhibited numerous small ulcers and raised, reddened, unulcerated Patches. The Ileostomy had been performed in the Ileum above the site of obstruction, and in a coil of intestine free of ulcers.

Mesenteric Glands. Several infected evidently recently.

Liver shows little fatty change.

Kidneys. Toxic change. One or two miliary tubercles.

Pleural Cavities.. Pleurisy in both cavities of some standing.

Dense adhesions over the apex of the left lung.

Left Lung. The upper lobe is grossly diseased, showing ramifying cavities and large caseous areas. One of the cavities shows well-marked fibrous reaction in its neighbourhood and is of some considerable standing. The remainder of the process is acute. The Root Glands are caseated. No gross lesion in lower lobe.

Right Lung. No evidence of T.B.

Heart Healthy.

Tonsils and Cervical Glands. No evidence of T.B.

*D. S. Middleton*

CASE OF PANCREATIC CYST.

Mrs Morris. Aet 46. Married.

68 Hall Street,  
Lochgelly.

Housewife.

Recommended by

Dr Dickson.

Admitted

29.11.20 to Ward 8.

Complaint.

Tenderness in Abdomen.

Lump in Epigastrium.

Previous Illnesses.

Puerperal Fever 13 years ago at birth of second child, associated with "white legs, congestion of right lung and congestion of the Kidneys".

History.

Patient had an attack of jaundice 3 years ago, coming on suddenly and lasting 5-6 weeks. It was associated with vomiting without nausea, pain in lower part of abdomen and emaciation. Nearly a year later she had/

had another exactly similar attack. She was then well for a few months but 18 months ago she had a severe illness which kept her in bed for 5 months. This illness started with sudden jaundice which lasted for one month. She was severely ill, vomiting for 3 days, had fluid in her abdomen, and Dr Sturroch of Dunfermline diagnosed the case as one of cancer and gave her 6 weeks to live. The pain during the jaundiced period was severe, of a colicky nature, and referred at first below umbilicus, finally settling in the Epigastrium.

The patient since pulling through this illness has not enjoyed good health, and has been forced to go to bed every week or so for a few days. She also vomited, on an average, about twice a week. On one occasion she thinks she vomited a little blood.

About 9 months ago the patient noticed a lump in the upper part of the abdomen which gradually got larger, forcing her to loosen her corsets. The lump was tender on pressure over it, and later gave rise to a feeling of tightness in the abdomen. Three weeks ago she took a turn for the worse and started to vomit whenever she took any food, even milk. The swelling still remained but varied with the vomiting a little. She had no jaundice. The vomiting stopped two days/

days before admission, but the swelling has enlarged considerably lately and she has noticed some pain in the middle of her back.

She has in the last fortnight noticed some enlargement of the veins over her abdomen and is troubled a good deal with borborygmi and occasionally with palpitations.

She has never been constipated but she has noticed for some time that the motions were, as a rule, pale in colour, at intervals, however, they became dark, almost black, for a few days.

For the last 2 - 3 months she has had several attacks of bleeding from the nose, always from the left nostril. She had got very thin since her illness. 5 - 6 weeks ago, an ulcer developed above each ankle.

Her periods stopped suddenly two years ago.

Social History.

Husband fruit-merchant. As far as can be made out from the doctor's letters, the patient is a chronic alcoholic.

Family History.

Father and Mother dead: cause unknown.

Two brothers alive and well. Two dead: cause unknown.

She has had six children, 3 boys and 3 girls who are all well.

No miscarriages.

Examination.

On admission

Pulse	)	
Temperature	)	normal.
Respirations	)	

General. The patient is markedly emaciated and has a slightly flushed face. She has a very poor memory for past events and gives a very disjointed and contradictory History. There is no marked visible jaundice but there is a slight yellow tinge in the mucous membranes.

The Abdomen. There is <sup>a</sup> marked prominence filling up the Epigastrium, extending downwards to about  $1\frac{1}{2}$  inches above the umbilicus and laterally a little way into each hypochondrium.

The abdomen presents a marbled appearance owing to numerous somewhat dilated veins under the skin.

Sometimes a sausage-like swelling can be observed in the Right lumbar region, running transversely across it to just above the umbilicus/

umbilicus and superficial to the lower part of the tumour.

A constriction may then be seen to appear at this end of the swelling and shortly after a wave of peristalsis is seen to pass from this constriction over the swelling from left to right. This was sometimes accompanied by borborygmi, and occurred at somewhat irregular intervals of from 10 - 30 seconds.

On palpation, this sausage-shaped swelling is found to contain gas and this gas can be pressed across the tumour with a gurgling sound.

The main tumour on palpation is found to be smooth, fluctuating and tensely cystic in character. It is absolutely spherical, and feels about the size of a small cocoon, and projects beneath each costal margin. It is tender to the touch. The tumour does not move with the fingers and only about  $\frac{1}{2}$  - 1 inch on deep respiration. It does not move with the position of the patient.

Between the tumour and the abdominal wall is a cord-like structure about the thickness of one's little finger. It runs almost vertically upwards over the tumour from the neighbourhood of the/

the umbilicus. It does not pulsate but can be emptied and fills again fairly quickly either from above or below.

On Percussion. The tumour is dull and this dullness is separated from that of the Liver by a band of resonance usually.

This band is often absent, when the dullness is continuous, or may at times be almost two inches in breadth. On the left side of the tumour no resonant stomach note can be obtained, the dullness continuing till lung is reached. The spleen as far as can be made out from percussion is slightly enlarged, reaching well into the mid axillary line.

Elsewhere there is a tympanitic note on percussion.

The Liver appears to be normal in size but opposite the tumour the lower edge is pushed upwards and to the right a little.

Alimentary System. Faeces. Bulky, pale in colour and very offensive.

No visible excess of fat but on microscopic examination an unusually large number of fat globules are seen. No excess of undigested muscle fibres were seen as the patient has eaten no meat for some days.



Genito-urinary system. Urine. on admission.

S.G. 1022. Acid. Bile + .

No albumin or sugar.

Yellowish-brown in colour.

Tests for Internal Pancreatic insufficiency.

1. Aschness Oculo-Cardiac Test.

On pressing on the ball of the eye with the finger  
the pulse was retarded in the normal fashion.

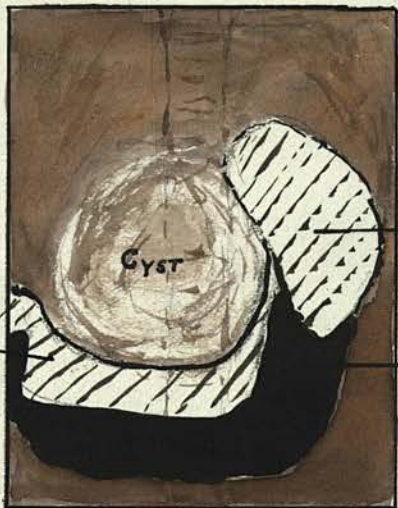2. Adrenalin Test. (Loewe).

3 drops of 1-1000 adrenalin repeated in 5 minutes  
did not produce any dilatation of the pupil.

3. No Exophthalmos or von Graefe's sign.

The Back. At the point where the patient complained of pain  
(2nd and 3rd Lumbar spines) some tenderness on pressure  
was felt, and this tenderness extended over an area about  
the size of the palm of one's hand on each side of these vertebrae.  
There was also some hyperaesthesia over this area.

# BISMUTH MEAL. AND ENEMA.



AFTER MEAL.



1 HOUR.



3 HOURS.



ENEMA.

The Legs. Show no varicose veins, but an ulcer in the lower third of each leg associated with some crusting and considerable pigmentation.

Wassermann Reaction negative.

X-rays. Dr Hope Fowler took a series of photographs after a Bismuth Meal. (SEE DIAGRAM)

Directly after the meal. Shows a shadow thrown by the cyst with the more definite shadow of the Bismuth in the stomach below the cyst. The Spleen throws a good shadow and is somewhat enlarged. The Transverse Colon appears as a dark area and contains gas.


1 hour - Much the same appearances are seen, little Bismuth having passed out of the stomach.

3 hours. - The stomach is not to be seen, but the caecum, ascending and transverse colon contain Bismuth. Gas is seen in the small intestine.

Enema. Shows gas in the stomach,

Bismuth in Transverse Colon (from meal)

and " " Pelvic Colon (from Enema).



RECTUS. MUSCLE.

DILATED VEINS IN FALCIFORM LIG.

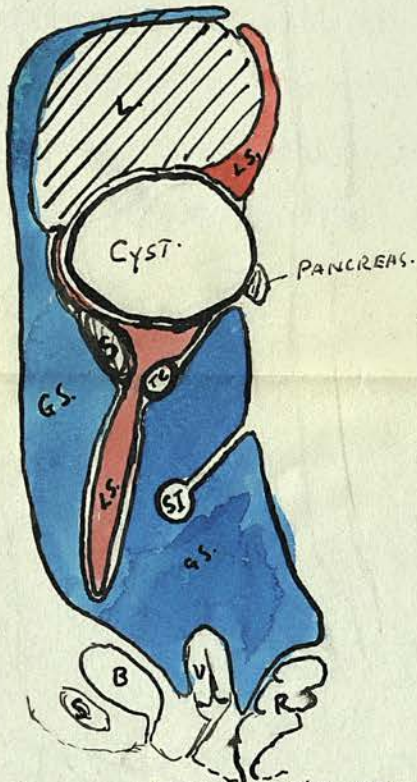VEINS IN LESSER OMENTUM.

OPENING IN LESSER OMENTUM WITH CYST WALL PROTRUDING.

STOMACH (PYLORUS)

PYLORIC VEIN.

VIEW OF WOUND.



PANCREAS.

GS.

LS.

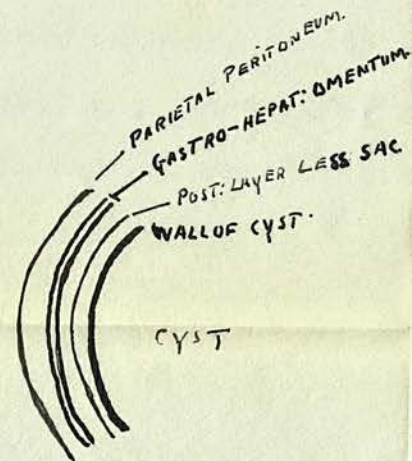
ST.

B.

U.

R.

TO SHOW THE DIRECTION OF PRESENTATION OF CYST.



TO SHOW THE PERITONEAL COVERINGS OF CYST.

OPERATION.

8.12.20. Sir Harold Stiles. Preliminary injection  $\frac{1}{100}$ th gr.  
Atropine .

A Right paramedian incision was made above the umbilicus, about  $3\frac{1}{2}$  inches long and  $\frac{1}{2}$  inch from mid-line. This was carried down to the muscle and the Right Rectus was split in the direction of its fibres. The past wall of Rectus sheath and the fascia Transversalis and Peritoneum were incised in the direction of the skin wound. The first thing preventing was the gastro-hepatic omentum with largely dilated veins coursing through it. The stomach showed next with a pyloric vein the thickness of one's little finger. The greater omentum was normal and showed no dilation of veins. The falciform Ligament prevented the picture of a cord-like mass of huge veins, and appeared to be the cord-like structure felt on palpating the Cyst. All these structures were carefully packed out of harm's way with strips of gauze, leaving the gastro-hepatic omentum exposed. An opening was made into the lesser sac, through this, avoiding all the veins carefully and the wall of the cyst presented at the opening. The cyst was now aspirated with a trocar and/

and cannula and about  $1\frac{1}{2}$  Kidney-dishes were filled with the brownish fluid which escaped. Some of this fluid was collected in sterile flasks for examination. This fluid was under considerable pressure. When the cyst was mostly emptied, its wall was picked up with tissue forceps, and the puncture made by the trocar was enlarged as an incision about  $\frac{1}{2}$  inch long.

On pushing the finger through this incision the cyst was found to be single, with a smooth wall and a tiny collapsed pocket could be felt by the tip of the finger on the posterior wall. This felt like a tiny diverticulum running into the Pancreas.

As excision of this large cyst was out of the question a length of rubber tubing was pushed through the incision in the cyst, and stitched in position with catgut interrupted sutures. It was further secured by invagination by means of a purse-string suture of thin Tannic acid-Iodine catgut.

The Gall-bladder was a little distended and the Liver a little cirrhotic.

The Sac was stitched to the abdominal wall all round by numerous points of Tannic acid Iodine catgut, these stitches grasping the post. Sheath of the Rectus and part of the muscle to get a good anchorage.

The abdominal wound was next closed all round the rubber tube in three layers.

1. Peritoneum, fascia Transversalis, past-sheath of Rectus and Rectus muscle (Doyens handled needle and catgut).
2. Anterior layer sheath of Rectus (Catgut).
3. Skin (silkworm gut).

A stitch was then put through the skin and the tube, and a dry gauze dressing applied, the long tube sticking out through the dressing.

Anaesthesia Induced by Chloroform.

Maintained by Ether.

The patient was returned to bed with a good pulse and appeared to have stood operation very well. The End of the long tube was placed in a jar in order to collect the fluid drained off from the cyst.

The patient did not vomit at all on recovering from the anaesthetic, but had a good deal of pain. At 10.15 p.m. on the night of operation she was given  $\frac{1}{12}$ th gr. of Heroin hypodermically as she/

she was suffering a good deal of pain.

The temperature rose after operation to 101.4° F., the pulse was 92 and the Respirations 28.

9.12.20. Patient still complaining of some pain. Otherwise is well.

The temperature dropping.

10.12.20. Pain now very little and the patient is quite well.

Temperature now normal, as are pulse and Respirations.

11.12.20. Very dark-brown fluid has been drained well from the cyst.

Food given (light) for first time since operation.

Bowels moved by Castor Oil and Enema for first time.

13.12.20. Wound dressed. Quite clean and healing well.

Temperature tending to swing a little. Fluid still draining.

16.12.20. Wound dressed. Tube has come out.

Temperature settling down again.

A red rubber catheter was placed in the cyst instead of the tube and drainage continued.

Some mild Sepsis occurred round the wound in the next few days but soon cleared up, the wound healing firmly except for the fistulous opening into the cyst. There was no digestion of the surrounding skin whatever.



14.1.20. Patient discharged with cyst still draining by soft rubber catheter. Instructions were sent to the Doctor to keep the fistula patent.

REPORT ON FLUID FROM CYST.

- I. Faintly alkaline and contains small quantities of blood.
- II. Contains Trypsin or Trypsinogen, as shown by the following test:-

1 cc. of the fluid was incubated with 10 cc. of a 1% alkaline solution of Casein and 4 cc of Ringers solution at 38° C.

Digestion was incomplete after 1½ hrs. but after 17 hours the Casein had been completely hydrolysed to bodies not precipitable by 1% Acetic acid, one of which was shown to be Tryptophane. This test is diagnostic for Trypsin as against other proteolytic enzymes.

III./

III. The fluid contains considerable quantities of Amylase. At a dilution of 1 - 1200 it digested .1% starch solution to bodies giving no colour with Iodine, in 30 minutes at 38°C. At a dilution of 1 - 3000 the starch had been completely hydrolysed to Erythro-dextrin.

The fluid therefore contains a considerable quantity of two of the Pancreatic ferments.

---

*D. S. Middleton*

COMMENTARY

ON

PANCREATIC CYSTS.

## PANCREATIC CYSTS.

The point of most interest, and causing most difficulty in this case, was that of Diagnosis. Given a cystic swelling of large size in the Epigastrium there are several possibilities to be considered. The following are the most likely causes of such a swelling.

1. True or false Pancreatic Cyst.
2. Hydatid of Liver or cystic Gall-bladder.
3. Kidney cyst or Tumour.
4. Mesenteric Cyst.
5. Splenic Tumours.
6. Ovarian Cyst or fibroid uteri.

Now the fact that the cyst at intervals could be shown to be entirely separate from the Liver by percussion was in itself sufficient to rule out a Hydatid cyst of the Liver or a cystic Gall-bladder while a Kidney Cyst or Tumour would be crossed from above downwards probably by the descending Colon. A Mesenteric Cyst is nearly always near the free border of the Mesentery and hence freely movable. It would probably have a coil of intestine crossing its surface at some point.

The last two tumours and also an Ovarian Cyst or Fibroid uteri/

uteri were rendered almost impossible by the discovery of gastric peristalsis below the tumour, showing that the cyst was projecting above the stomach. This finding was later confirmed by means of the X-rays, which also showed a spleen which was only slightly enlarged, thus confirming the results of percussion and ruling out a Splenic tumour.

Thus by a process of mere exclusion a conclusion was reached pointing to the Pancreas as the seat of origin of the Cyst.

Now Pancreatic Lesions may produce symptoms in three ways.-

1. By interference with the digestive secretions.
2. By interference with the internal secretion of the Islets of Langerhans.
3. Pressure effects if a tumour is present.

#### Examination of the external or digestive secretions.

1. Presence of undigested fat in the stools or steatorrhoea, showing a lack of fat-splitting ferment.
2. Presence of large amount of undigested muscle fibre in the stools or Creatorrhea, showing insufficient protein digestion.
3. The Sajodin Test. This test depends on the fact that the drug Sajodin, which is a combination of Iodine with/

with various organic bodies undergoes decomposition in the intestine under the influence of the Pancreatic juices with the formation of Iodides which are absorbed and excreted in the urine in a few hours. This test was introduced by Winternitz.  $\frac{1}{2}$  a gram of Sajodin is administered and the urine tested for Iodides at intervals afterwards. If none appears, the Pancreatic juices are deficient.

4. Sahli's Capsule Test is on much the same basis, but a drug which is excreted in an easily recognisable form in the urine, is given in a gelatin capsule. The gelatin is not digested if Pancreatic juices are lacking, and no traces of the drug appear in the urine.

5. Wohlgemuth's Diastase Test. Wohlgemuth showed that where the Pancreatic Ducts were totally obstructed an abnormal amount of Diastase was excreted in the urine. He called this condition one of "colourless Pancreatic Jaundice".

6. Oskar Grass tests the presence of Pancreatic juice in the faeces by taking an alkaline extract of the faeces and testing its capability of digesting Casein.

7. An Oil Breakfast may be given with the idea of supplying fat in such quantity as will be very easily recognisable if it is not split by pancreatic juices.

8. Einhorns Duodenal Sound allows of small quantities of Duodenal content being withdrawn. This sample can then

be tested for Pancreatic ferments.

In the present case, as there was no Creatorrhoea and very little undigested fat in the stools, it could be accepted that there was no interference with the digestive secretions of the Pancreas.

#### Examination of the Internal Secretions.

1. Glycosuria. The Internal Secretions of the Islets of Langerhans are known to play some part in the Glycogenic metabolism of the body and in some cases of cörrhotic Pancreas resulting from a chronic Pancreatitis, Glycosuria has resulted.

2. The Sympathetic System is influenced by the Pancreatic internal secretions as it is by the Thyroid secretions and several tests are based on this.

- a. Eye symptoms as in hyperthyroidism  
e.g. Exophthalmos, von Graefes sign, etc.
- b. Aschners Oculo-Cardiac Test.

Normally if the finger is pressed on the eyeball, the pulse becomes slowed by some 10 beats or so per minute. If this slowing does not take place, the Pancreatic internal secretions are not normal.

c./

c. Loewes Adrenalin Test. 2 - 3 drops of 1 - 1000 freshly prepared adrenalin are instilled into the eye and repeated in 5 minutes. Normally no dilatation of the Pupil ensues. If dilatation takes place the Pancreatic internal secretion is said to be at fault.

The last two tests are directed entirely at the sympathetic system which is said to be controlled to a large extent by the secretions of the Islets of Langerhans. They are not however tests directly of the Pancreatic internal secretions and it is very probable that the Pancreas shares the control of the stability of the sympathetic system with other endocrine organs.

In the present case no indications were obtained of any abnormality of the Internal Secretions of the Pancreas.

Symptoms due to Pressure of Cyst.

1. On Vena Cava with enlargement of veins on sides of abdominal wall.
2. On Portal vein with enlargement of intraabdominal veins, veins around umbilicus, at the cardiac orifice of the stomach and in the Anal canal, the last three being points where communications between the Portal and Systemic Venous circulations exist.



3. On the Stomach with indigestion and vomiting.
4. On the Diaphragm with breathlessness.
5. On the Heart with Palpitation.
6. On the Colon with disturbance of the Bowels.
7. On the Common Bile-Duct with jaundice and pale offensive stools.

In the case under consideration the cyst was of such large size that pressure effects were marked.

Thus:- there was evidently some pressure on the Vena cava, though not a great deal, as there was some enlargement of superficial Epigastric and axillary systems of veins at the lateral parts of the abdominal wall.

There was pressure on the Portal vein as there were some enlarged veins around the umbilicus though these did not amount to the typical "medusa-head". There is an indefinite history of the vomiting of blood, which suggests under the circumstances the presence of dilated veins at the lower end of the oesophagus. The veins within the abdomen proved at the operation to be enormously dilated. The slight but very definite enlargement of the spleen was probably also due to this cause.

The bile-duct evidently was subject to pressure as slight jaundice and pale offensive stools denote. The pressure was/

was evidently intermittent as the patient gives a history of the stools becoming dark again at intervals for a few days, though this darkening may very possibly have been due to the presence of blood in the stools from the swallowing of blood leaking from the oesophageal veins.

The Patient complained considerably of vomiting and Palpitations evidencing pressure on the Stomach and Heart.

### Etiology.

Pancreatic Cyst may be divided into two classes.-  
True or False.

The False Cyst is merely an exudation or extravasation, usually blood stained, into the lesser sac of the Peritoneum, the Foramen of Winslow becoming closed and the lesser sac distended with fluid. It usually follows on a history of trauma, and forms a much less well-defined Epigastric swelling than the True Cyst.

The True Cysts are of 4 types.-

#### I. True Retention Cysts as seen in the breast.

These cysts result from the blockage of small ducts by Pancreatic calculi as a rule. They do not tend to grow to a large size unless a larger duct<sup>is</sup> occluded.

#### II./

II. Multiple Cysts resulting from chronic Pancreatitis. They occur much as in the breast, but are rarer in the Pancreas, which is supplied with little in the way of fibrous stroma to cause occlusion of ducts. One of these cysts may grow to a very large size. The chronic pancreatitis gives rise to no very definite symptoms but glycosuria is very often present, supposedly resulting from the fibrosis that occur in the Islets of Langerhans.

III. A Cystic Adenoma just as it occurs in the breast is seen in the Pancreas, but is very rare. It forms one or more cysts with papillomatous intracystic outgrowths and has a tendency to become malignant, either carcinomatous when the Epithelium undergoes malignant changes, or Sarcomatous when the connective tissue is the seat of the change.

IV. Cysts may form as the result of an acute Pancreatitis which has been recovered from. This type of cyst is very rare, as recovery from an acute Pancreatitis is by no means common. When an acute Pancreatitis occurs, haemorrhagic in type, with fat necrosis, and recovery takes place, a considerable amount of fibrosis must of necessity occur in the substance of the gland during the process of absorption of the blood-clot, etc.: and fibrosis may easily lead to cyst formation from blockage of ducts.

It/

It is to this type that the present case in all probability belongs. The patient gives a history, albeit a somewhat confused one, of three attacks of jaundice inside 3 years. The first two of these appear to have been milder altogether than the third and were probably merely attacks of catarrhal jaundice. These attacks imply a pre-existing duodenal catarrh, and duodenal catarrh forms the starting ground for infection of the Pancreas and possible acute Pancreatitis. When the patient therefore gives a history of a third attack accompanied by jaundice, and of a very severe character, during which she evidently nearly died and on recovering was confined to bed for five months, we look for another explanation than catarrhal jaundice, and find the diagnosis of Acute Pancreatitis ready to hand. The history, though vague, corresponds with the history of the ordinary case of acute Pancreatitis in the three main particulars of sudden vomiting, epigastric pain of severe character, and collapse.

The Patient's doctor evidently felt a mass in the Epigastrium, saw the Catarrhal jaundice which accompanied the Pancreatitis, and very naturally came to the conclusion that the patient had Cancer of probably the head of the Pancreas implicating the common bile-duct.

This severe illness left the patient a legacy of chronic ill/

ill-health culminating in the development of an obvious tumour in the Epigastrium about 9 months ago.

#### Treatment.

Small cysts in the tail of the Pancreas may be shelled out of the gland substance and removed, but in the case of large cysts such as the one under discussion, removal is, of course, out of the question. All that can be done is to incise the cyst, drain it, and by keeping the wound open, establish a fistula leading to the cyst. No limit can be placed on the length of time such a fistula will take to close, but it is, as a rule, a matter of a year or so.

Examination of the fluid showed that it contained Pancreatic ferments and was therefore a True Cyst.

*L. S. Middleton*

COMMENTARY

ON

ACROMEGALY.

## ACROMEGALY.

A disease first described by Pierre Marie and attributed by him to an alteration occurring in the Pars Anterior of the Pituitary gland.

The pituitary gland consists of two parts distinct from each other in structure and development.

- (1) The Pars Anterior or Ant: Lobe, and the Pars Intermedia of the post: Lobe, developed from Rathke's Pouch in the Primitive Stomodeum.
- (2) The Pars Posterior of the Post: Lobe developed from the cerebral vesicle.

In the disease known as Acromegaly, a definite lesion is found in the Pars Anterior and it is this part therefore with which we have to deal mainly.

The Ant: Lobe is essential to life, as shown by the fatal results of experimental removal and of fractures of the base of the skull causing widespread damage to this lobe.

Hypersecretion of the Ant: Lobe is

(1)/

(1) Physiological in pregnancy, when it may even cause temporary acromegalic symptoms along with bitemporal hemianopia, both passing off during the Puerperium.

This organ therefore has a cyclic function such as is seen in many other organs such as the Mammae etc. Now all cyclic organs show a tendency to get, so to speak, out of hand, during the rise or fall of their activities and hence to pass into the pathological. In this connection it is interesting to note that a practitioner has described six cases of hypo-pituitarism all occurring in his practice in women after the birth of their first child. This connection between the onset of hypo-pituitarism and the decline of the gland activity after pregnancy appears to be more than a mere coincidence.

(2) Hyperplasia with consequent hypersecretion of the gland is said to occur in all general and local infections, and Blair Bell holds that the secretion of the anterior lobe exerts a neutralising or anti-toxic effect in these cases. This presumably forms the basis for the theory that Acromegaly is caused by a chronic intestinal toxæmia.

(3) Pathological Hypersecretion with Acromegaly occurs not, as was previously thought, in all tumours of the ant: lobe, but only when the lobe is the seat of a simple hyperplasia or adenoma. Destructive tumours, such as carcinoma, /



carcinoma, gumma etc., do not produce any known general effects, unless the carcinoma is the result of a previous simple adenoma.

When this adenoma occurs before growth has ceased, gigantism results, if afterwards Acromegaly results.

The secretion of the Ant: lobe therefore appears to govern growth. This is borne out by a series of cases described by Hastings Gilford of a rare disease called Anteileiosis which is the result of non-development or arrested development of this lobe occurring at any time from foetal viability to puberty, and which is characterised by the complete arrest of physical growth. That is to say the child retains for the rest of its days the physical development present when the arrest of development took place.

The Post: lobe is composed partly of nervous and partly of stomodaeal elements. The mode of pouring out of the secretion of this gland is still under discussion, Herring believing that the cells of the Pars Intermedia become colloid and pass through the Pars Nervosa into the C.S.F. while Blair Bell considers the secretion is poured directly into the blood stream in the ordinary way.

Hypersecretion of the Post: Lobe gives rise to a decreased sugar tolerance with a tendency to glycosuria /

glycosuria while

Hyposecretion gives rise to an increased sugar tolerance.

This is associated with a train of symptoms known as "Dystrophia Adiposo-genitalis" or "Fröhlich's Syndrome" which is characterised by an increased deposit of fat and sexual retrogression.

In practice one finds that a disease of one lobe affects the other one and vice versa, so that symptoms may be jumbled up and are often difficult to allocate accurately to any one part of the gland. For instance: an adenoma of the anterior lobe will cause Acromegaly. As a result of its being enclosed in a box with the posterior lobe, however, the posterior lobe will be thrown out of gear, first in the direction of a transient hypersecretion due to irritation resulting later in a hypersecretion due to pressure atrophy. Add to this the fact that, owing to the very close relationship between the endocrine organs, symptoms may be produced from other glands merely by the upsetting of the normal balance, and one finds a vast mass of symptoms, difficult to sort out.

Diagnosis is based on general and local symptoms.

#### General Symptoms.

- (a) Due to hypersecretion of the ant: lobe, we get the classical changes of Acromegaly accompanied by gigantism if growth has/

has not ceased. The enlargement of the bones, the broadening the face with the typical sullen expression (see cases) caused by the coarseness of the skin and the thickness of the lips.

(b) Pressure symptoms on the Posterior lobe.

At first a pressure irritation is produced with glycosuria and decreased sugar tolerance.

Later a pressure atrophy takes place with Polyuria, increased Sugar Tolerance, and the development of Fröhlich's Syndrome.

(11) Local Symptoms are referable to the pressure effects of the enlarging tumour.

1. Headache at first due to erosion of the walls of the Sella Turcica and usually localised to one temple, and later due to increased intracranial tension when the tumour has extended upwards. The headache is then of an occipito-frontal type often associated with Neuralgic pains over the face and also sometimes with optic Neuritis.
2. Vomiting becomes marked on the onset of increased intracranial tension.

3. Optic Changes.

(a) Optic Neuritis as mentioned above, or

(b) Bitemporal Hemianopsia due to

pressure of the tumour on the chiasma interrupting the fibres crossing in the middle line and going to the nasal halves of each retina, and causing blindness in the two temporal fields.

4. Pressure on Oculo-Motor Nerves.

With pupillar changes and ptosis of upper eyelids.

Other cranial nerves are less commonly implicated.

Rarer ~~case~~<sup>ARE</sup> is Pressure on the 3rd Ventricle causing sleepiness and Polyuria.

6. "Uncinate Fits" from pressure on the uncinatè gyrus.

7. Mental Dulness in a marked degree from pressure on the Frontal lobes.

Differential Diagnosis is as a rule easy, though in the early stages the disease has often been mistaken for My~~se~~<sup>x</sup>coedema and treated accordingly. It is interesting to note that the patient in Case 11. was treated with Thyroid in the early stages with somewhat serious results.

Etiology/

Etiology. The primary cause of Acromegaly is still hidden in obscurity. What actually causes the hyperplasia responsible for the disease? Some authorities have as mentioned before, at once made an attempt to correlate it with the old standbys of oral sepsis and intestinal intoxication, but more benefit can probably be got from studying the connection between the gland and the Reproductive endocrine glands.

The ant: lobe of the Pituitary has a very intimate connection with the reproductive organs as the facts already mentioned in regard to the Pituitary's response to pregnancy show. Castration in either male or female animals is also followed by some hyperplasia of the ant: lobe of Pituitary.

We know for certain that with a Pituitary enlargement we have an atrophy of the Reproductive glands, which has ~~was~~ usually been attributed to the atrophy of the post: lobe, as a part of "Fröhlichs Syndrome". We also know that changes<sup>s</sup> in the Reproductive glands, and in particular atrophy or removal of these glands causes a hyperplasia of the ant: lobe.

This leaves us with the knowledge that these glands hold a position towards each other fairly represented by the phrase "United we stand, divided we fall".

One very interesting fact, however, pointing towards the Reproductive glands as the seat of the trouble, is that Acromegaly/

Acromegaly is by far most commonly met with in women from 20 - 40 years of age, that is during the most fertile years of women, whose reproductive glands are admittedly more active and more regularly cyclic than those of the male sex.

Treatment Medical treatment has hitherto been unavailing.

Extracts of Pituitary gland etc., produce no improvement and the cases usually run on during the course of years with gradually increasing headache, finally accompanied by vomiting and blindness, till the patient is in a state of unspeakable misery and is often tempted to commit suicide. There are isolated cases where for no apparent reason the symptoms show no change, being of a permanent character (Case 1.) This is in all probability due to fibrosis occurring in the tumour with consequent shrinkage and diminution of the pressure and symptoms, REFERABLE TO PRESSURE.

Thyroid extract is said to have done wonders in a few cases, but in all probability the so-called cases of Acromegaly which responded to this treatment were more of a myxoedematous type with a facies which resembled that of Acromegaly.

Surgical Treatment is still more or less in its infancy. The operation is not permanently curative but has for its object merely the relief of urgent pressure symptoms, which must be severe for such a drastic/

drastic operation to be permissible. The indications therefore may be said to be intense headache, vomiting and blindness. Under these conditions patients will undertake the most drastic operations in order to gain relief.

Having regard to the difficult situation of the Pituitary gland, it is but natural that many routes should have been suggested by which to reach it. All are open to some objection.

(1) The Oral or Nasal Routes. ~~and~~ traversing the Basisphenoid and opening into and traversing the sphenoidal sinus.

The great objection to this route is that a septic area is traversed no matter how carefully the nasopharynx has been cleansed previous to the operation. This causes at once a mortality from 20 - 30% from basal meningitis. Again the surgeon must work in a very confined space by the aid of a forehead lamp and he must traverse the sphenoidal sinus, the position of which it is difficult to determine very accurately even with the best of X-Ray plates.

(11) The Bitemporal route used by Cushing ~~has been~~ mainly on animals. It consists of making extensive openings on both sides of the skull, and is of most value for decompression.

(111) The Fronto-orbital Route was used first by Krauze and McArthur and was perfected by Frazier. The difficulty in/

in this approach is to get free access, otherwise, <sup>WITH</sup> the exception of the fact that the eyeball may be displaced and oedematous for some time afterwards this operation offers the best results.

With the idea of improving the access, the suggestions of several surgeons were combined in Case 11. as mentioned below with the result that access was extremely good.

1. An extensive flap. (Sargent)
2. Retention in the flap of the supra-orbital margin, (Elsberg)
3. Inclusion of Part of the temporal fossa (Adson)

The actual technique of the operation is described in Case 11.

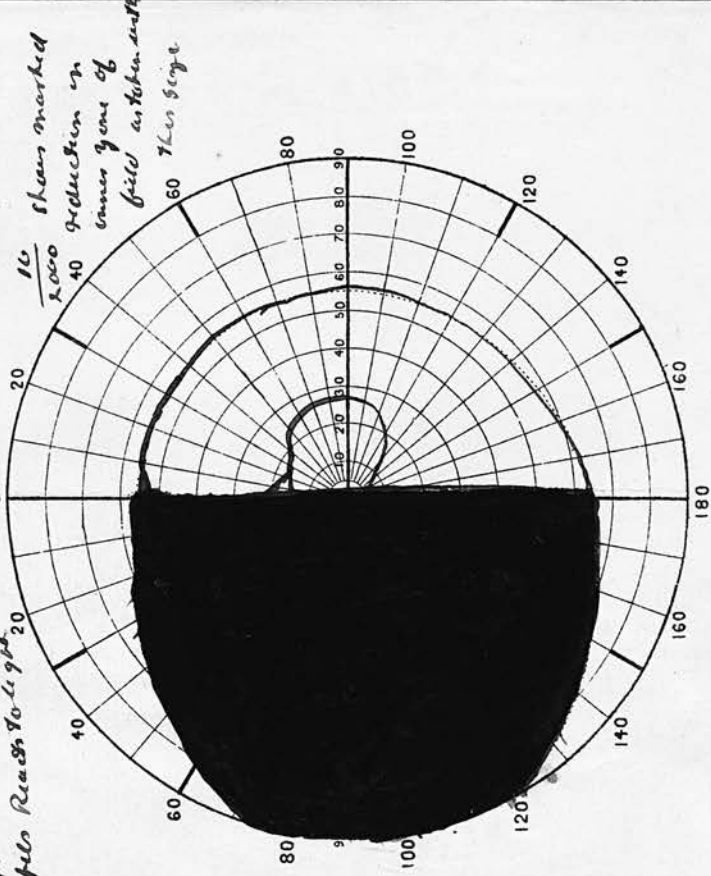


TWO CASES

OF

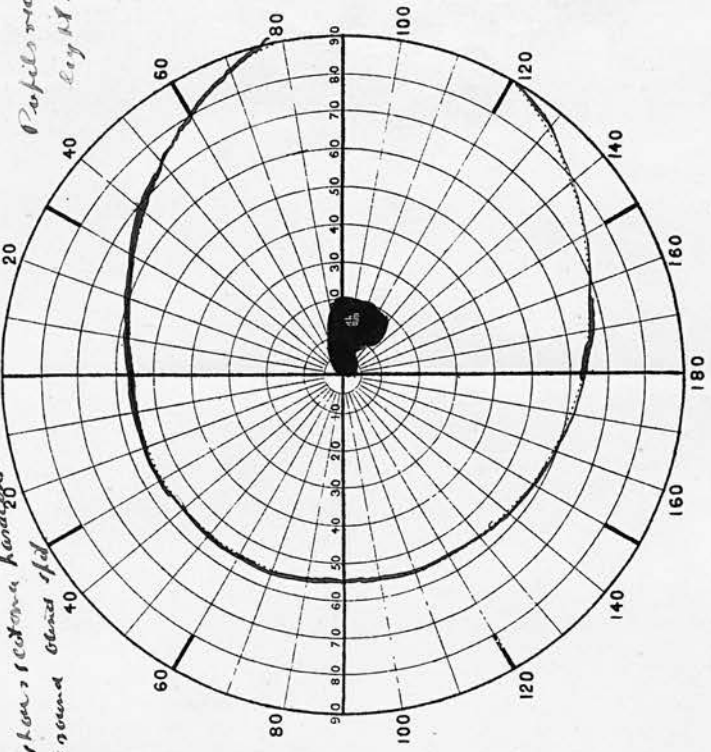
ACROMEGALY.

A  
 V 24. without glasses LEFT EYE.  
 Pupils React to light  
 15/300 Good field  
 normal field  
 1 cent of peripheral portion



16/2000  
 40  
 Shear marked  
 reduction in  
 inner zone of  
 field at bottom with  
 this stage

B  
 V 18 without glasses.  
 20/300 Good full field  
 Shear reduced inner zone  
 4/2000  
 1 Shear 1 cent of peripheral portion  
 2000 around blind spot



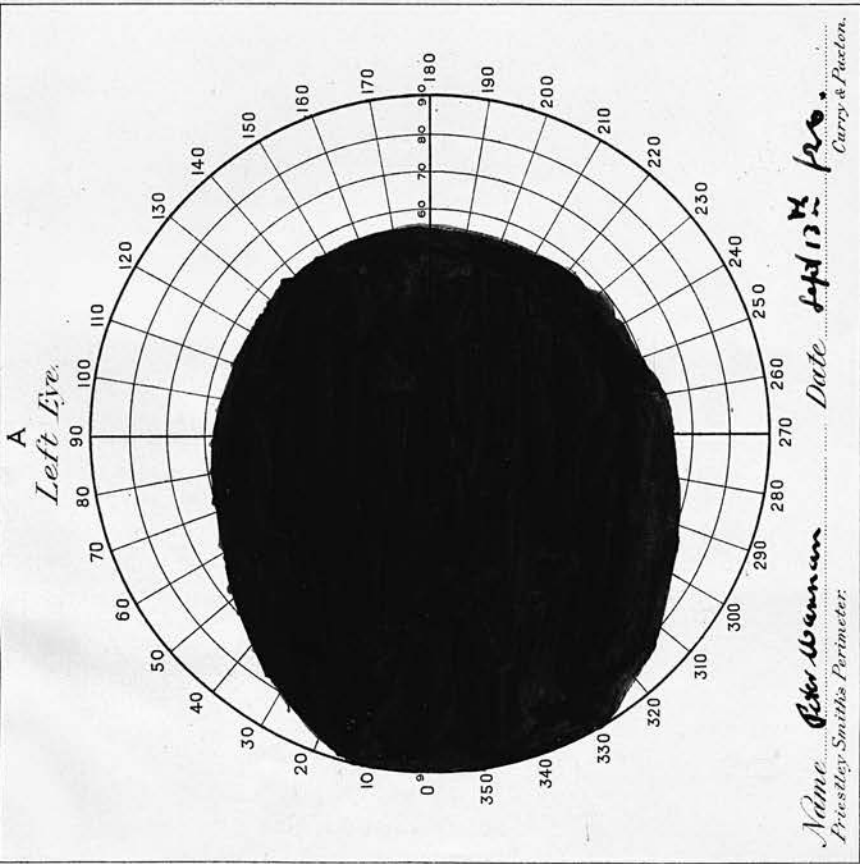
Pupils react to  
 light.

**PRIESTLEY SMITH PERIMETER CHARTS.**

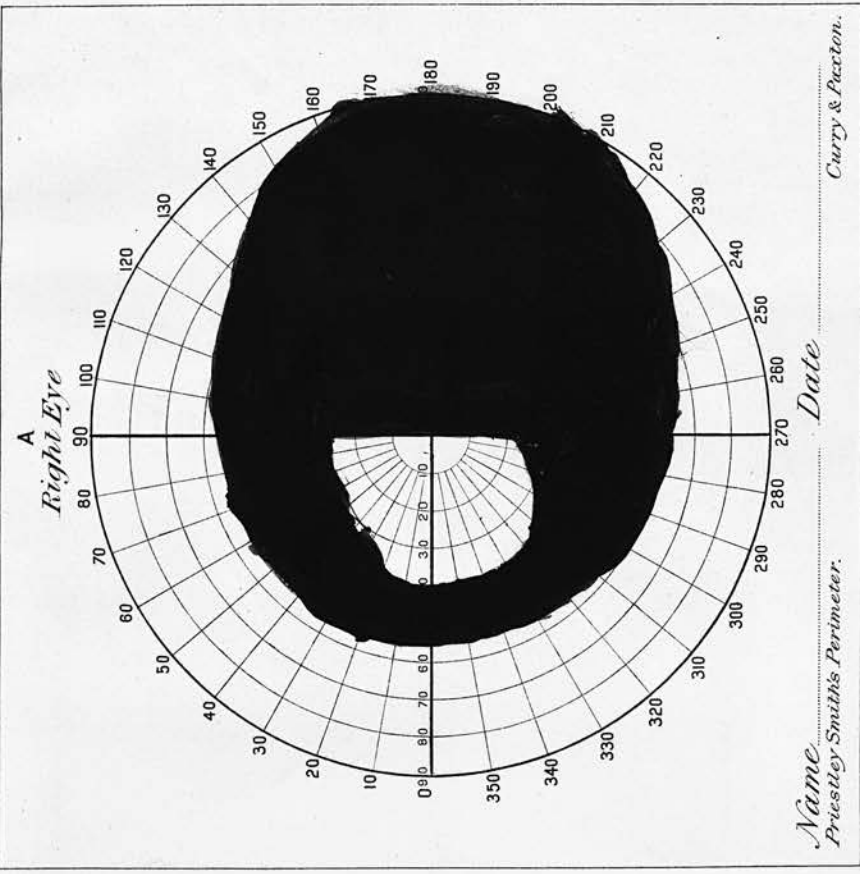
Name *Peter Worman*

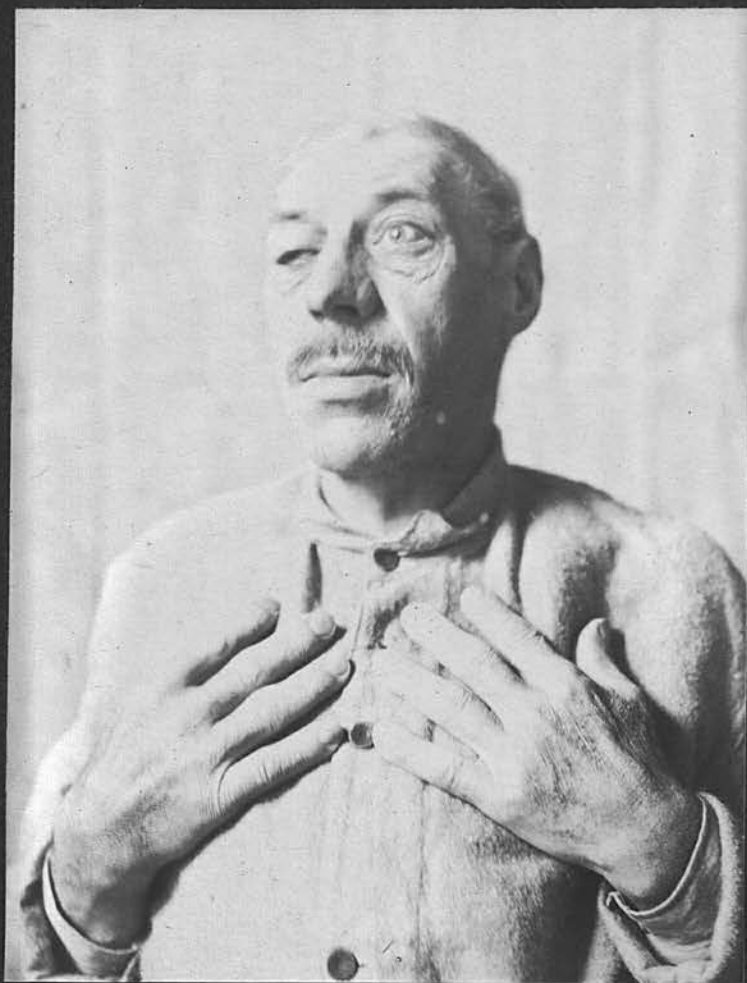
Date Oct 30 1926.

The eccentric dotted line indicates the average normal Field of Indirect Vision ; the small shaded circle the position of the blind spot. *copy*



*offici. Copy.*





PETER WAINMAN  
ALBOMENIST

CASE I.

Peter Wannan.            Aet 52.            Married.

Boiler-fireman in a Coal-mine.

10 Black Braes, Falkirk.

Dr Garrand.

21st October, 1920, to Ward 7.

Diagnosis.    Acromegaly.    (stage of hypo pituitarism).

1. Pains in head	)	<u>Duration</u> =    5 months.
2. Loss of vision	)	

Occupation.

Address.

Recommended by

Admitted.

Complaint.

History.

About 5 months ago, the patient, after having felt rather out of sorts for a few days, developed a slight headache which got worse until it became extremely severe, passing over the Vertex from the frontal region to the occipital region, being worst in the Forehead. The pain was severe, unintermittent, and of a boring rather than shooting or throbbing character. The pain kept the patient from sleeping and made him very restless.

On/

examined his eyes and told him no glasses would be of help.

On the 1st of July his eyesight fairly suddenly got much worse, and he developed diplopia for a short time. He noticed that his feet were swollen in the mornings but this disappeared during the course of the day. His headache continued in the same place and could no longer be relieved by blistering. He began to feel weak and easily tired. He also noticed that the skin on the backs of his hands was getting roughened and he had little sensation left in it. He does not, however, admit to any change in the size of his hands or feet, or in the shape of his face.

His condition got steadily worse till on the 4th of September Dr Garrand sent him to see Professor Gulland and he was admitted to Ward 31. On admission his headache and vomiting were extremely severe and he appeared to be almost blind. While here, his eyes were tested by Dr Sinclair who reported on them as follows.-

"Sept. 13th, 1920.

Vision  $\frac{6}{36}$  .

Right Eye.

Pupil reacts to light. Optic disc pale. The temporal field is lost and the nasal field considerably contracted.

The pupils react to light. Right Field is now full with a paracentral Scotoma passing up close to the fixation point. Left temporal field completely lost. Functional activity in both fields reduced. Optic discs show atrophic pallor.

Progress.

On admission Temp. was 97° F.

Pulse " 84.

Resp. were 30.

The temperature has since remained persistently subnormal, being always just above or below 97° F. The pulse and Respirations have dropped to normal.

The patient's symptoms since admission have improved steadily and he says his headache is very slight and his eyes are improving daily.

November 8th, 1920. The patient was transferred to Ward 26 under Professor Meakins with the purpose of testing his sugar tolerance.

By this time the patient's headaches have disappeared entirely. His eyes, except for his left temporal field and paralysed left Rectus are well, and the slight Ptosis and Proptosis noticeable on admission have disappeared.

He says he has shaken off his lethargy and has regained a considerable amount of his former energy.

The patient has never noticed any Polyuria and does not admit venereal disease or sexual disturbances.

Previous Health.

Always good health, but always inclined to be stout.

Social History.

His social surroundings are average, and he appears to have led a fairly regular life. He smokes and describes himself as a moderate drinker but admits that he often had "Saturday night" bouts in his younger days. Since his illness started he has lost all desire for spirits.

Family History.

Father and Mother died in old age, cause unknown. His Father, the patient says, had very large hands and feet and was very stout. He has four brothers and one sister, all alive and well, but all his brothers are, like him, stout and have large hands and feet. In fact, one brother has larger hands than the patient.

He has six of a family, the eldest being 18. All are in good health and are of ordinary stature.



## Examination.

### General.

Height 5 ft. 7 ins.    Weight 11 stone 10 $\frac{1}{2}$  lbs.

The patient is of the typical broad, thickset, working man type with a somewhat barrel-shaped chest. His intelligence is average but his cerebation is rather slow. He sweats profusely on the least exertion and is easily tired.

### Facies.

The face is heavy and coarse-looking. It gives the impression of great length with a good deal of broadness at the lower part. There is slight maxillary and mandibular prognathism and his Lower Jaw is heavy and massive. The prominences of the skull are well-marked, especially the external occipital protuberance and nuchal lines. The Nose is long and broad out of proportion to rest of face. The Lips are full and thick and the lower one is typically pendulous. The Skin of the face is rather inclined to be coarse. The left eye shows a very slight degree of proptosis and a tendency towards Ptoxis of the upper lid. The Teeth are all very carious, there is marked Pyorrhoea Alveolaris and there is a slight tendency towards separation of the individual teeth. The tongue is very large, broad, flabby, and slightly furred.

## Integument.

The skin of the body generally does not show any particular change except that described in connection with the face and also a tendency to scaliness of the skin over bony points. On the lower third of the left leg there is a band of brownish pigmentation of the varicose type. There has never been any ulceration here. No pigmentation in flexures. No warty growths.

## Subcutaneous Tissues.

The body generally shows a comparatively normal covering of fat except on the abdomen which is very protuberant owing to great subcutaneous deposition of fat. There is some eversion of the umbilicus.

On the upper part of the anterior surface of the Right Thigh there is a subcutaneous swelling about the size of a large saucer with dimpling of skin over it and a lobulated feel. It appears to be lipomatous in character. There is a similar smaller lipoma on the lateral surface of the left Thigh just below the Trochanter, and measuring about 2 by 1 ins. The Lipoma on the Right Thigh the patient has had since he can remember. That on the Left Thigh he has never noticed.

There is distinct oedema around both ankles even after the patient has been in bed for some days.

### Muscular System.

The muscles of the body are all very flabby and out of condition. There is not, however, very advanced atrophy.

There is limitation of extension of the Right Elbow, the tendon of Biceps becoming taut before full extension has taken place. This, the patient states, has been present for many years and he thinks is caused by the great deal of shovelling he used to do when at work, this form of exercise entailing continued contraction of his Right biceps with the elbow in a semi-flexed position.

### Bony Skeleton.

The skeleton in general is built on a decidedly generous scale. The bones show enlargement at their epiphyses and the ribs are thickened. The enlargement of the medial condyles of the Femur and tibia on each side is marked. The crests of the Iliac are thickened. There is Kyphosis in the upper Dorsal region.

### Respiratory and Digestive Systems.

Show nothing of note.

### Circulatory System.

The heart and vessels show nothing of note.

### Nervous System.

The Blood-pressure, (systolic) ranges from 110 - 132. Knee and ankle-jerks are brisk. The Plantar reflex is normal. All other reflexes normal.

III Cranial Nerve.

Pupil reaction to light and accommodation slightly sluggish. Slight Ptosis of left upper eyelid.

VI Nerve. -

On right side normal. On left side it is totally paralysed, there being complete loss of lateral movements of the eyeball.

Slight Proptosis of left eyeball.

Thyroid gland palpable. No signs of persistent thymus. Slight testicular atrophy.

Sympathetic System.

Ductless Glands.

Genito-Urinary System.

The Testicles.

The left Testicle is small, soft, and appears to be somewhat atrophied. The Epididymis is normal.

The Right Testicle is slightly harder and larger than the left. The Epididymis is markedly thickened. There is a soft cystic swelling above the Right testicle. This is about the size of a hens egg, does not enter the inguinal canal and has no impulse on coughing. It has been present as long as the patient can remember and has never given rise to trouble. It appears to be a hydrocoele of the cord.

There/

There is some loss of testicular sensation.

The patient has never had any trouble with micturition.

Urine. Oct. 28th, 1921.

Acid. S.G. 1024. Amber coloured. No sugar, no albumen.

No polyuria.

X-Ray.




DIAGRAM OF X-RAY APPEARANCES  
OF SELLA TURCICA

(NOTE. PIECE OF BONE APPARENTLY SUSPENDED  
IN THE CENTRE OF THE SELLA)

2nd Eye Report.

The patient's eyes were again examined on October 30th by Dr Sinclair who reported as follows:-

"Right Eye. Vision improved from  $\frac{6}{36}$  on Sept. 12th to  $\frac{6}{18}$  on October 30th; and Left Eye from mere Perception of Light on Sept. 12th up to  $\frac{6}{24}$  on Oct. 30th.

The/

The condition of the field is characteristic of the later stages of pituitary tumour pressing on the chiasma.

Left Eye. Pupil does not react to light. No remaining area of field. Disc atrophic on temporal side."

(See chart).

On the 8th of September the patient was transferred to the side-ward of Ward 8. He was photographed (attached), and by this photograph he appears to have exhibited fairly marked Proptosis of the left eyeball and also some Ptosis of the upper lids. On transfer to this Ward, the headache was severe and vomiting almost continuous, but he soon improved a little, his headache getting less severe and his vomiting disappearing. He thinks the sight of his Right Eye also began to return at this time.

He was discharged on the 27th to await operation. Since his discharge he has improved gradually but steadily. He can now see fairly well and his headache is now more of the nature of discomfort than actual pain. His skin has got smoother and the sensation has returned to it. He has had no vomiting since leaving the R.I.E.

He/

November 19th, 1920. The patient's sugar-tolerance has proved to be markedly increased.

His Wassermann reaction (blood) was negative.

Operation was decided against, in view of the patient's improvement, and he was discharged from Hospital.

ANNIE KENNEDY.

Aet. 61.

Single.

OCCUPATION.

None. Lives with married sister.

ADDRESS.

6 Livingstone Place, Edinburgh.

RECOMMENDED BY

Dr Matheson.

ADMITTED.

10.11.20. to Ward 8.

DIAGNOSIS.

Acromegaly.

COMPLAINT

1. Pain and feeling of swelling in head.
2. Tenderness of skin over head, face, and neck.
3. Enlargement of hands, feet, face and tongue.
4. Soreness at Back of Right Eye.

DURATION.

8 years.

HISTORY.

About 8 years ago the patient had a sore throat and afterwards developed occasional headaches, localized to the Right temporal region and the top of the head. The sore throat cleared up fairly quickly with gargling, and for some years she took pills from her Doctor without any effect on her headaches, which continued till about 4 years ago, when they got worse, and became continuous in the Right temporal region at a point about  $1\frac{1}{2}$  ins. behind and 1 inch above the lateral angle of the orbit. From here the pain gradually spread over the Right side

of/



of her head, and during the last two years has involved the left side of her head also. The skin over her scalp, face, and neck, also became tender to the touch, and this pain sometimes reached down to her Right Shoulder. The pain throughout was not of a throbbing nature but was of a persistent boring nature. During the last two years her headache has been the same, is continuous, keeps her awake, and in the patient's own words, "makes her life a misery to her".

When her headache is at its worst, she complains that her head feels "swollen up and hard", and the tenderness in her skin then also gets very severe, such things as the pressure of the pillow, movement of her hair or stroking of the skin with cotton-wool making her almost cry out with pain. Owing to this headache she has been confined to bed for close on a year.

The patient had to start wearing glasses shortly after this illness started, and now cannot read but has good sight for distances. At the beginning of her illness she noticed that she avoided bright light as it irritated her eyes, and preferred to sit in a darkened room, although previous to this she had always favoured a bright cheery room. Lately she has often noticed a sharp burning pain at the back of her right eye.

About 5 or 6 years ago, she began to notice an increase in size/

size of her hands and feet, as she had to take larger gloves and a complete size larger in boots. She also noticed some roughening of the skin over her body generally, and some thinning of her hair. Small warty "pimples" appeared on the skin and some moles which she had had all her life got rather larger in size. Her lips got thick, her tongue large, her few remaining teeth got wider apart, her eyes began to water a lot, her voice got altered in tone, becoming harsher, and deeper, and she got stouter and heavier.

Shortly after these symptoms appeared, her Doctor put her on Thyroid Extract, evidently under the impression that she was a case of Myxoedema. She took the extract for a few days while going about as usual and then became suddenly ill, went to bed and became unconscious. This unconsciousness lasted more than a week, and her sister afterwards told her that she was often delirious and had to be held in bed. After she recovered consciousness again she speedily recovered, but her Doctor stopped the Thyroid extract.

About one year ago she came to Edinburgh from Milnathort, Fifeshire, to stay with her married sister, and Dr Matheson, seeing her in April sent her to Ward 24. Here Sir Harold Stiles was asked to see her and she was discharged pending operation.

The/

The patient's periods ceased normally at 45. Her bowels have always been somewhat costive. She feels the cold a great deal and thinks her head is usually worse on a cold day. She has had no vomiting at all since the start of the illness. When in Ward 24, she was given first 50 gms. and then 100 gms. of Glucose without the appearance of any sugar in the Urine.

PREVIOUS HEALTH.

1. "Sore Spine" at 18 years of age, which confined her to bed for about 2 months.
2. Gastric Ulcer with haematemesis at 25 years of age. This was cured by medical treatment, though she had attacks of indigestion at intervals for some years afterwards.

SOCIAL HISTORY.

is very good in all respects.

FAMILY HISTORY.

Father died from a shock and Mother from Heart failure.

She has four sisters. One died from Cancer of the Uterus.

The other three are alive and well. Her married sister with whom she is living is her twin sister and they used to be so alike that even their parents could scarcely tell them apart. The patient's appearance is now so altered that no one would suppose they were related in any way. One of her other sisters is pretty stout.

EXAMINATION.

Height 5 ft. 7 $\frac{1}{2}$  inches.      Weight 11 stone 11 $\frac{1}{2}$  lbs.

A.K.  
ACROMEGALY.



*Macintyre*

DUNFERMLINE.



THE PATIENT AT PRESENT DAY (AET 61)

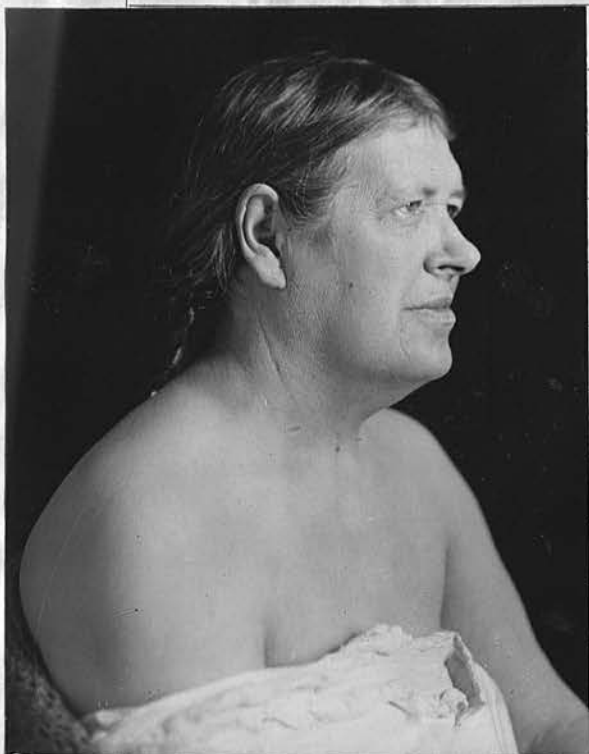NOTE THE CHANGE IN THE SHAPE OF THE  
LOWER PART OF THE FACE, JAWS, MOUTH  
NOSE, EYES AND EARS.

THE PATIENT. AGED 30.

ALSO NOTE THE ENLARGEMENT OF THE

A.R.

ACROMEGALY.



NOTE EAR CHANGES, AND SLIGHT  
MANDIBULAR PROGNATHISM.



NOTE FAT AROUND NECK ESPECIALLY  
AND THE STRAINED APPEARANCE OF A  
SUFFERER FROM CONSTANT HEADACHE.

The Face. is somewhat heavy and coarse, with typical broadening of the lower part. The lips are thick, the lower is pendulous. The nose is a little thickened across the base, and the ears are large about the lobes.

The Hands are large and the fingers thick and square.

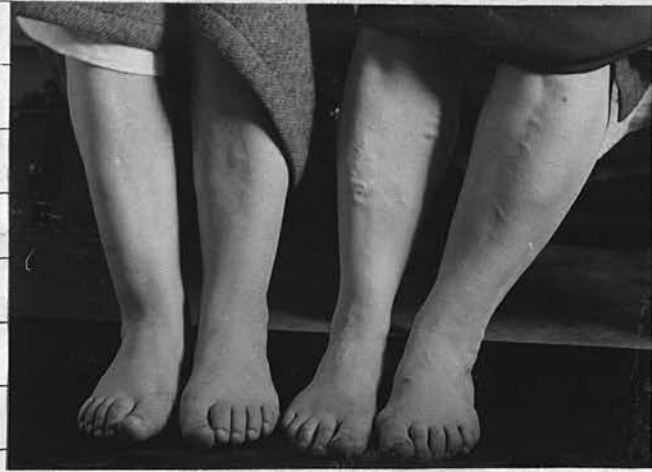The Feet are large and massive.

The Tongue is very large, flabby and somewhat furred, but quite moist.

The Teeth. Most of her teeth were removed about the beginning of her illness as they were very bad. There remain the incisors and canines of the lower jaw only. They show considerable separation and marked Pyorrhoea Alveolaris.

The Skin. All over the body inclines to be coarse. Several fairly large moles of the common variety. Numerous rough little warty spots all over the body, but much more numerous on the abdomen. There is considerable pigmentation in the flexures, especially the axillae and in the pit of the umbilicus. There is a considerable degree of hyperaesthesia of the skin over head, face and neck for some two inches or so below the mandible in front and somewhat lower behind.

Subcutaneous tissues all over body are well impregnated with fat, but this is most apparent in 4 spots.



LEFT. PATIENTS FEET WITH THICK MASSIVE ANKLES.

RIGHT. NORMAL FEET



LEFT. PATIENTS FOOT TO SHOW PAD OF FAT.  
BEHIND MALLEOLUS.

RIGHT NORMAL FOOT.

(1) around neck and below chin.

(2) on the abdomen.

(3) a small pad above each patella.

(4) small pads behind both malleoli on both ankles.

Muscular System. There is considerable weakness and atrophy of all the skeletal muscles. This is attributable to the fact that she has been confined to bed practically for a year.

The Bony Skeleton is thickened and massive, and bony prominences are all unduly well-marked.

Nervous System. Knee-jerks and ankle-jerks brisker than normal.

Plantar Reflex normal. There is a tendency to <sup>PATELLAR</sup> ~~clonus~~ and ankle-clonus, but no true continued clonus can be elicited.

Respiratory System. Nothing abnormal to note.

Circulatory System. The chest is so fat that the heart sounds somewhat faint and distant. Sounds are all closed and rhythm is normal. Percussion is also rendered difficult by the amount of fat, but no enlargement can be made out.

Alimentary System. Nothing to note except tendency to constipation.

Eyes. Pupils react normally: no abnormality can be made out on superficial examination.

Report/



A.K

ACROMEGALY.



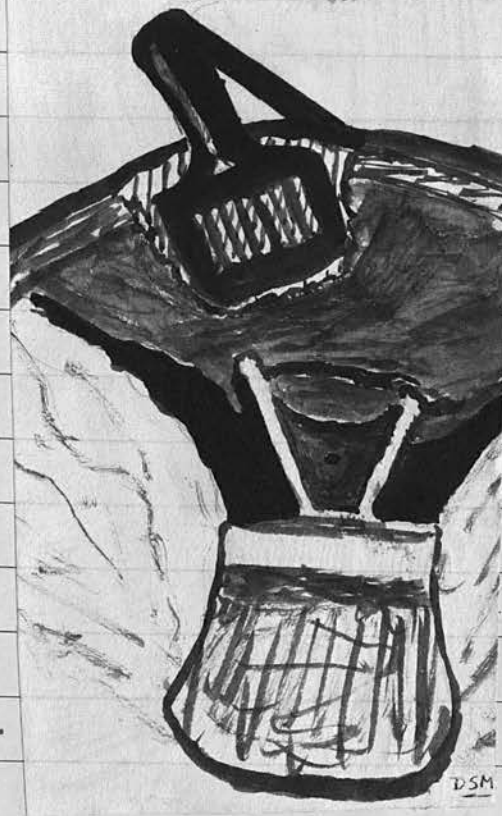SHOWS CERTAIN AMOUNT OF  
DORSAL KYPHOSIS.



THIS PHOTOGRAPH ~~IS~~ SHOWS THE PATIENT  
IN THE POSITION SHE ASSUMED WHEN  
AT REST.

ANNIE KENNEDY

PITUITARY TUMOUR.



ABOVE IS SEEN THE APERTURE WHICH WAS NIBBLED OUT OF THE ROOF OF THE ORBIT, WITH THE ORBITAL CONTENTS RETRACTED WITH A TONGUE DEPRESSOR.

BELOW IS THE SUBSTANCE OF THE FRONTAL LOBE RETRACTED BY A GLASS RETRACTOR.

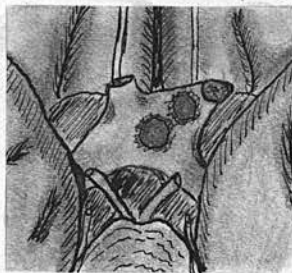
IN FRONT OF THE RETRACTOR IS A SMALL PORTION OF THE CHIASMA WITH THE TWO OPTIC NERVES DIVERGING FROM IT AND RUNNING TO ENTER THE OPTIC FORAMINA. BETWEEN THESE NERVES LIES THE PERFORATED DIAPHRAGM.

the Optic Chiasma which was considerably distorted as shown in the diagram.

The Sella Turcica was considerable, measuring:-

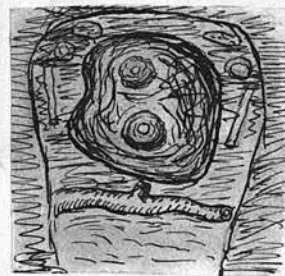Length (Ant. part.) 16 mm. the normal being 12 mm.

Depth 15 mm. " " " 8 mm.



THE OPTIC CHIASSMA AS SEEN.  
FROM BELOW.

NOTE THE DEFORMATION  
AND THE DEPRESSIONS CAUSED  
BY THE NIPPLE-LIKE PROCESSES  
OF THE TUMOUR.



THE SELLA TURCICA SEEN  
FROM ABOVE WITH THE  
PITUITARY GLAND IN SITU.

NOTE :- THE ENLARGEMENT  
OF THE GLAND AND THE TWO  
NIPPLE-LIKE PROCESSES ON THE  
SURFACE.

Report on eye condition by Dr Sinclair.

"Vision Right Eye =  $\frac{6}{6}$  . Left Eye =  $\frac{6}{12}$  .

Pupils react to light. Fundus Oculi normal.

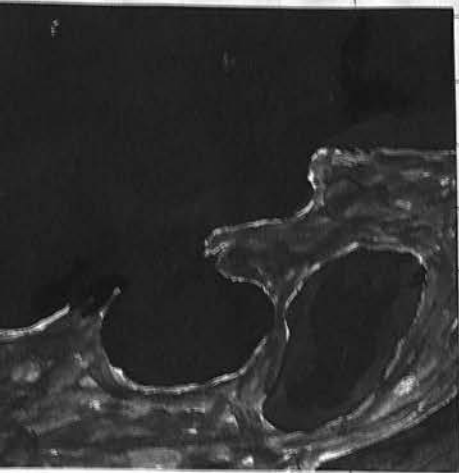
Fields Normal limits with  $\frac{5}{250}$  white (ordinary)

Screen Test shows little change. In Right Eye a slight relative defect of colour vision in lower temporal quadrant close up to fixation point. In the left eye no failure of vision is found in testing region of fixation point.

So far as the functional condition of vision is concerned there is at present only a suggestion of Quadrantal failure in the central portion of the field in Right Eye."

X-Ray Examination. Shows considerable enlargement of Sella Tursica in vertical and antero-posterior directions. Erosion of the bone is not a marked feature and the opening of the Sella Tursica is quite narrow. The posterior clinoid processes, however, are considerably thinned and tend to be tilted upwards. No encroachment on the sphenoidal sinus. The skull is thickened. Frontal Sinuses do not appear to be very large.

Sugar Tolerance. Increased. 100 gms. Glucose produced no glycos<sup>u</sup>emia whatever. (17.11.20).



On admission. Temperature was 98.2° F.

Pulse was 92.

Respirations were 20.

Since admission patient has remained in much the same condition, having a great deal of pain in her head. The temperature has been persistently subnormal since admission.

In view of the severity of the symptoms and the patient's wishes, operation was decided upon and the date fixed for the 19th November.

Sir Harold Stiles operated on the 19th November 1920.

Preparation. The ordinary routine preparation for operation was carried out, the whole scalp being shaved and prepared.

Anaesthesia was induced by chloroform. An intratracheal tube was inserted through larynx and ether administered by electric motor apparatus. Previous injection of  $\frac{1}{120}$ th gr. Atropine hypodermically

The Operation. was planned to combine the advantages of operations described by various other surgeons, thus the osteoplastic flap was partly frontal and partly temporal. Other points were:-

1. Extensive flap - Sargent.
2. Retention of supra orbital margins in flap - Elsberger.

3. Inclusion of part of Temporal fossa in opening - Adsen.

Elsberger turned his flap inwards, but this flap was turned outwards as by this means the superficial temporal artery was retained in the flap, thus insuring a good blood supply.

It was decided to approach the Sella Turcica from the left side.

Sterile towels were placed below the head and round the neck, etc.: and one was clipped to the skin of the left cheek and scalp by means of Michels clips, in such a way that it screened the nose and mouth off from the area of operation. The ear was plugged with sterile wool and the eyelids clipped together by two Michels clips. The patient was placed in the supine position, with the shoulders raised about 30 degrees, and with the head hanging well back over a sandbag.

An incision was made from a point on the superciliary ridge just above the inner angle of the orbit, along the superciliary ridge and straight back for about 1 inch beyond the lateral angle of the orbit. Another incision was carried directly upwards for about  $1\frac{1}{2}$  inches from the medial end of the first incision. Both incisions were carried down to the bone, the supra orbital nerve being divided at its exit from the supra orbital notch and the supra orbital vessels caught and divided. The periosteum along the supra orbital ridge was incised and/

and was elevated upwards and downwards off the supra orbital margin.

It was also carefully cleared from the roof of the orbit for about  $\frac{3}{4}$  of an inch.

The angular flap at the junction of the two incisions was now reflected so as to expose a portion of the frontal bone, and an opening was made in the skull  $\frac{1}{2}$  an inch above the supra orbital margin, and close on 1 inch lateral to the medial end of the incision, so that the frontal sinus would not be opened. A Harrison's drill was used to open the skull, starting with a small burr and changing twice to larger sizes. The skull was a full  $\frac{1}{2}$  inch in thickness. As there was a good deal of oozing from the diploe the opening was at first packed with gauze and later the bleeding was stopped with Horsleys wax.

The anterior and upper part of the temporal muscle was now incised in the direction of its fibres, the periosteum below was divided and separated and the muscle and periosteum were retracted downwards by means of a Kochers double hook. Here another opening was drilled in the skull about 1 inch behind the lateral angle of the orbit, so as to be clear of the middle meningeal artery. The skull here again was about  $\frac{1}{2}$  an inch in thickness.

The eyeball was now retracted downwards with a spatula and the periosteum/

periosteum further separated from the roof of the orbit. The supra-orbital margin was then sawn through just medial to the External angular process with a small Heys saw. The division was completed with a fine chisel and a hammer, and the division here was connected to the Temporal burr opening with the chisel.

The roof of the orbit, just where it joins the supra-orbital margin, was then chiselled through right along the orbit about as far as the supra-orbital notch. The supra-orbital margin was then sawn through in such a fashion as to unite a point just lateral to the supra-orbital notch with the supra-orbital burr opening. This connection was completed with an ordinary Osteotome in a bevelled fashion, so that the division in the ~~bone~~<sup>bone</sup> sloped from without, inwards and laterally. This was done in order to prevent compression of the brain by the bony flap when it was replaced.

The small vertical incision already made above the medial orbital angle was now prolonged upwards as a paramedian incision about 1 inch from the medial <sup>n</sup> line, and diverging from the midline till at the top it was about  $1\frac{1}{2}$  inches from the midline. This incision was carried on to a point almost vertically above the external auditory meatus. It was about 4 inches long, and was carried down to the

~~bone~~  
bone, /



ANNIE KENNEDY.

PITUITARY TUMOUR.

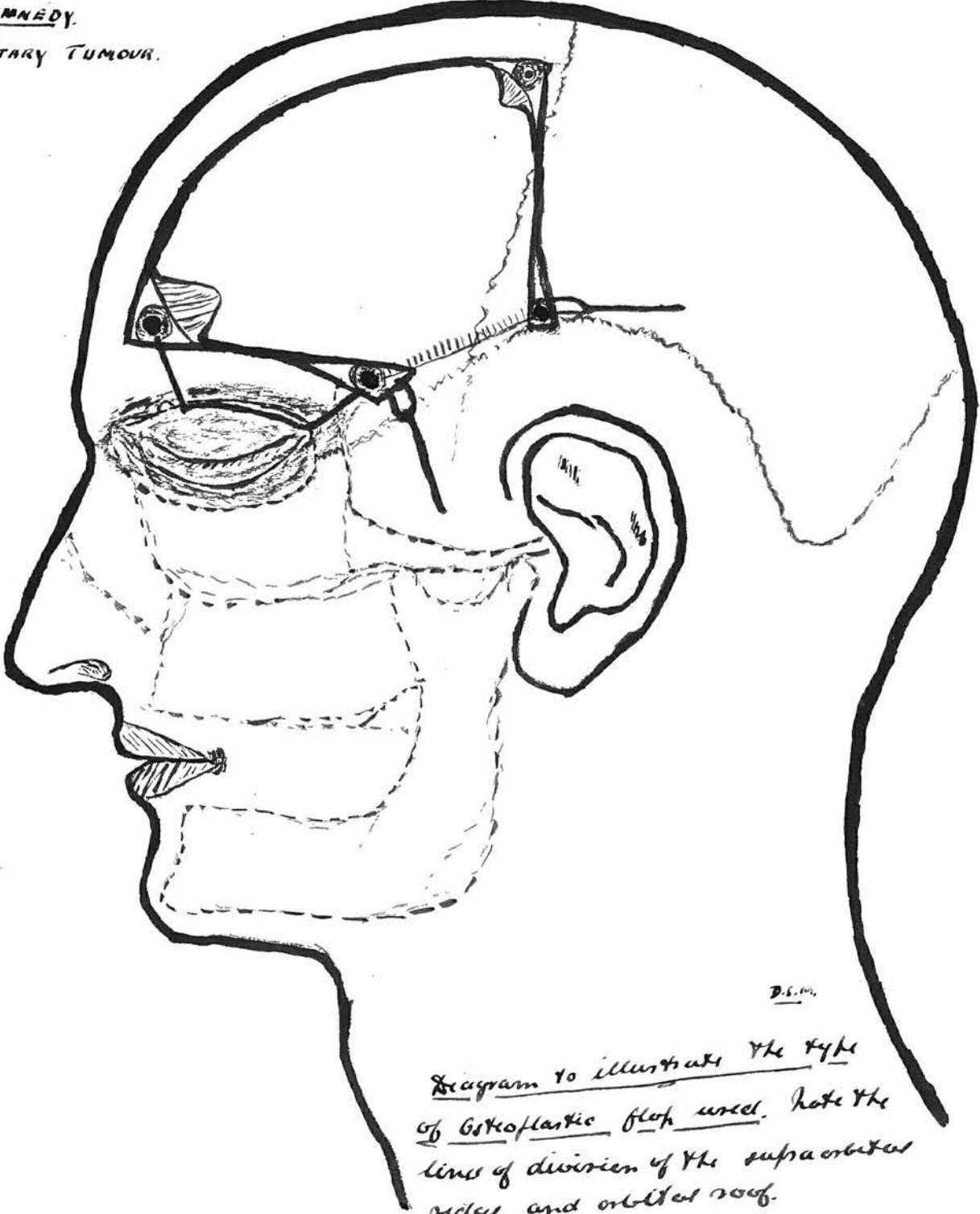


Diagram to illustrate the type  
of osteoplastic flap used. Note the  
lines of division of the supra-orbital  
ridges and orbital roof.

~~base~~<sup>bone</sup>, the bleeding from the edges of the scalp being stopped by means of scalp haemostatic clamps.

The perioranium at the top of this incision was separated from the bone, and a burr opening was drilled through the skull about  $3\frac{1}{2}$  inches above the supra-orbital opening. The skull here was extremely thick; so much so, in fact, that after the biggest burr was buried to its greatest circumference, the smallest burr had again to be resorted to in case of the heavier one crashing through the skull and injuring the Dura Mater. By means of gentle use of the small burr, the skull was safely opened.

Another incision was now carried from the upper end of this vertical incision directly downwards to a point about  $1\frac{1}{2}$  inches directly above the External Auditory Meatus. The bleeding was as before stopped by clamps and the periosteum in the lower part of the incision was elevated.

A fourth burr opening was now drilled through the skull just on the temporal ~~surface~~<sup>suture</sup> about 2 inches directly above the External Auditory Meatus. Here again the skull was very thick.

The opening at the Vertex and the supra orbital opening were now connected with a Horsley's Laminectomy saw and the bone  
sawn/

sawn about half-way through in a bevelled fashion. The opening at the Vertex and the posterior of the two Temporal openings were connected in like fashion. The connections between these three openings were completely severed with a Doyen's Osteotome. There was considerable bleeding from the Diploe. It was now attempted by means of a chisel to prise up the osteoplastic flap so as to fracture the bony base of the flap. Unfortunately, at the first attempt a fairly large portion of the outer table split partially away from the inner table along the medial incision. A second attempt was more successful, the base of the flap fracturing and the osteoplastic flap was turned down exposing the Dura Mater covering the frontal lobe on the left side. The deeper part of the supra-orbital ridge, which should have accompanied the flap was left in situ and was removed piecemeal with <sup>bone</sup>~~base~~ forceps.

The bleeding from the diploe was now stopped with Horsley's wax. The <sup>bone</sup>~~base~~ and soft parts of the osteoplastic flap were secured together by means of Krause's forceps.

The Frontal lobe covered by the Dura Mater were now seen to be bulging out of the opening under considerable tension.

The Frontal lobe and Dura were now separated from the orbital roof/

roof and retracted by means of a spatula, while the orbital roof was removed with nibbling forceps.

The temporal ~~base~~<sup>bone</sup> was now nibbled away in a downward direction with some difficulty owing to the thickness of the bone, which however got thinner further down. This exposed the anterior part of the temporo-sphenoidal lobe in the lower and posterior part of the opening. The middle meningeal artery was exposed, crossing the lower and anterior angle of the opening in the skull, but was not injured.

Gauze was now packed in between the skull and the Dura, all round the bony opening, so as to protect the soft parts from the sharp edges of the bone.

A head lamp was used to illuminate the field of operation from this point onwards.

Some more of the orbital roof was removed with nibbling forceps, after further separation of the Dura Mater from the bone. The orbital contents were retracted by means of a tongue depressor with a broad flat end which just fitted the opening in the orbital roof.

Two Sargent's glass retractors were used to pull the Frontal lobe away from the floor of the anterior Fossa of the skull. The field was douched with hot saline (117° F.) to clear the view and stop oozing. The excess saline was mopped out with little pledglets of gauze.

It was here discovered that the Dura Mater had been accidentally perforated with escape of a good deal of cerebrospinal fluid. This made the retraction of the Frontal lobe much easier and increased the view enormously.

It was now decided to open the Dura and this was done as follows:-

The Dura was picked up off the surface of the brain fairly far forwards, by means of a small sharp hook, and this elevated piece of Dura was carefully opened at one point with a small tenotomy knife.

An angled director (MacEwen's) was introduced and slid down between the Dura Mater and the brain towards the sellar region. The Dura was then opened along this director by slipping a knife along it.

A flap of Dura was dissected outwards, exposing the inferior surface of the Frontal lobe. The field was again douched with hot saline.

The frontal lobe was again retracted with the glass spatulae and the Falx Cerebri was recognised, when a sudden gush of blood took place from the deepest part of the field. The patient as a result lost a

good deal of blood. The area was packed with gauze for close on a minute and when this was removed and the field irrigated with hot saline, the bleeding was seen to have practically stopped. The

haemorrhage was supposed to be due to either

1. Opening of Cavernous Sinus

2. Cutting of an arachnoidal vein on the surface of the brain.

In view of the fact that the haemorrhage stopped so soon, the arachnoidal vein was probably to blame. This supposition was borne out when the edges of the glass retractors were found to be somewhat sharper than they ought to have been, and it was thought that this had caused laceration of the vein.

Corrugated rubber dam was now inserted between the retractors and the brain, and the frontal lobe once more retracted.

The Right Optic Nerve was now seen, and almost immediately after the left optic nerve, connected to right by a small piece of the chiasma and having part of the Diaphragma Sellae between it and the Right. (see diagram). The Diaphragm was thin and there was a small hole in it which was attributed to a cyst which had been accidentally ruptured during previous manipulations.

A blunt probe was passed in at the perforation and passed easily down to the bottom of the Sella Turcica. A small scoop was next inserted and a little pituitary tissue scooped out. This was followed by a little bleeding from the fossa.

The field was now irrigated once more with hot saline and all retractors/

retractors were removed. The Dura was restitched over the Frontal lobe with interrupted catgut sutures.

Part of the split-off inner table of base in the flap was removed and the Osteoplastic flap replaced in position. The scalp clamps were removed and the scalp sutured with interrupted silk-worm gut sutures, after a few vessels had been ligatured. A plain gauze dressing was applied after painting with Iodine.

The operation lasted for 2 hours 15 minutes, the patient being under the anaesthetic altogether for  $2\frac{1}{2}$  hours, but had pure air only for the last half hour of this.

The patient stood the operation well, but lost a lot of blood. Her face was pale and her pulse was irregular in time and force at the wrist, sometimes being barely perceptible for some seconds together.

The left pupil was pin-point while the Right was considerably dilated.

The patient was returned to bed and Rectal Salines administered. The operation finished at 2.30 p.m. and the patient showed no signs of returning consciousness and about 5.30 p.m. her Respirations became weaker, more irregular and finally ceased, the circulation ceasing shortly afterwards.

Pathological Report.

General. Nothing abnormal was noted in the body save the general appearances of Acromegaly, the abundant fat, a Right Ovarian cyst of small dimensions, a ~~large~~<sup>LANES</sup> kink at the lower part of the Ileum, accompanied by a prolapsed and mobile Caecum with an appendix fixed for part of its length. There was a slight insufficiency of the Aortic valves, with a generally dilated heart.

The Lungs showed some Emphysema with some congestion and oedema and also some Bronchitis.

The following glands were removed and found to be normal:-  
Left Ovary: Pancreas: Spleen: Suprarenals: Thyroid and Parathyroids and Thymus.

The Pituitary was very large, the size of a walnut or more and weighed  $4\frac{1}{8}$  grms. as against the normal .730 gr. of a woman.

The enlargement was mainly in an upward direction and two nipple-like processes protruded upwards, their tips being embedded in the/  
the/