

CHRONIC NON-SPECIFIC THYROIDITIS

A SURVEY AND INVESTIGATION OF ITS COMPONENT
DISEASE PROCESSES, WITH PARTICULAR REFERENCE
TO THEIR CLINICAL AND PATHOLOGICAL MANIFESTATIONS

THESIS SUBMITTED FOR THE DEGREE OF

Ch.M.

by

JAMES ALEXANDER LAMB CLARK

M.B., Ch.B., F.R.C.S.E.



APRIL, 1958

CONTENTS

	<u>Page</u>
<u>INTRODUCTION</u>	1.
 <u>PART I - THE EVOLUTION OF THE CONCEPT OF THYROIDITIS</u>	
Historical Survey	3.
Summary	62.
 <u>PART II - THE CLINICAL AND PATHOLOGICAL ASPECTS</u> <u>OF HASHIMOTO'S DISEASE, STRUMA</u> <u>LYMPHOMATOSA OR LYMPHADENOID GOITRE</u>	
Introduction	64.
Histo-pathology	66.
1. The Thyroid Parenchyma	67.
2. The Round Cell Infiltration	74.
3. The Connective Tissue	79.
General Commentary on Histo-pathology	85.
Pathological Anatomy and Operative Findings	89.
The Clinical Aspects	93.
1. Age and Sex Incidence	93.
2. Duration of Goitre	94.
3. Other Symptoms	95.
4. Clinical Assessment of Thyroid Function	99.
(a) Hyperfunction	99.
(b) Hypofunction	104.
5. Clinical Assessment of Ovarian Function	105.
6. Rôle of Iodine	106.
7. Physical Examination	106.
(a) The Thyroid	106.
(b) Other Findings	107.
8. Radiology	109.
9. Laryngoscopy	109.
10. The Clinical Diagnosis of Struma Lymphomatosa	110.
11. Laboratory Aids to the Diagnosis of Struma Lymphomatosa	112.
(i) Serum Protein Abnormalities and Serum Flocculation Reactions	113.
(ii) Serological Diagnosis	114.
(iii) Radioactive Iodine (¹³¹ I) Studies	115.
12. Rôle of Thyroid Biopsy	120.
The Treatment of Struma Lymphomatosa	122.
1. Resection	122.
2. Radiotherapy	124.
3. Treatment by Thyroid Substitution	128.
4. Cortisone	129.

	<u>Page</u>
Follow-up of Cases	129.
1. Incidence of Hypothyroidism or Myxoedema	130.
2. Recurrent Thyroid Enlargement	136.
3. Survival: Association with Other Diseases	138.
4. Alteration in Laboratory Tests	139.
Summary	140.

PART III - SOME FURTHER OBSERVATIONS
ON STRUMA LYMPHOMATOSA

Variations in the Pathological and Clinical Picture	142.
Introduction	142.
Group 1 Cases	145.
Histo-pathology	145.
Commentary on Histo-pathology of Cases in Group 1	154.
Pathological Anatomy and Operative Findings	159.
The Clinical Aspects	159.
Treatment and Follow-up	162.
Commentary on Clinical Aspects of Cases in Group 1	165.
The Nature of the Group 1 Cases	166.
Group 2 Cases	167.
Histo-pathology	167.
Pathological Anatomy and Operative Findings	172.
The Clinical Aspects	172.
General Commentary on Cases in Group 2	174.
Relationship of Struma Lymphomatosa to Other Forms of Thyroid Disease	176.
A. Other Forms of Thyroiditis	176.
B. Malignant Disease of the Thyroid	177.
C. Simple and Toxic Goitre	177.
1. The Significance of the Askanazy Change	178.
2. The Clinical and Pathological Aspects	184.
3. Conclusion	189.
Aetiology of Struma Lymphomatosa	190.
1. A Thyroiditis	190.
2. A Phase of Thyrotoxicosis	191.
3. A Primary and Unrelated Thyroid Disorder	191.
4. An Auto-Immunisation	194.
5. Geographical Factors: Incidence: Age and Sex Distribution	196.
Summary	198.

PART IV - SUBACUTE THYROIDITIS

Introduction	199.
Synonyms	199.
Geographical Distribution	200.
Incidence	202.
The Clinical Aspects	203.
Laboratory Investigations	205.
Diagnosis	208.
Clinical Course	209.
Aetiology	210.
Pathology	211.
Treatment	217.
Prognosis	220.
Relationship to other Thyroid Diseases	221.
Case Report	222.

PART V - RIEDEL'S THYROIDITIS

Introduction	228.
Historical Summary	229.
Struma Lymphomatosa and Riedel's Thyroiditis	234.
Subacute Thyroiditis and Riedel's Thyroiditis	248.
Other Conditions and Riedel's Thyroiditis	252.
Riedel's Thyroiditis	253.
Criticism of the Concept of Riedel's Thyroiditis	262.
Summary	266.

PART VI - THYROIDITIS AND MALIGNANT DISEASE

Introduction	268.
Case Reports	269.
Resumé of Cases	293.
Discussion	296.

<u>MAJOR CONCLUSIONS</u>	300.
------------------------------------	------

<u>REFERENCES</u>	310.
-----------------------------	------

ACKNOWLEDGEMENTS

My thanks are due:-

To Mr K. Paterson Brown who first suggested a review of the subject of Chronic Thyroiditis. Work carried out on patients in his charge at the Royal Infirmary of Edinburgh constitutes the body of this thesis. His personal interest in and enthusiasm for the investigation have been of the greatest value and a constant stimulus throughout.

To Professor Emeritus Sir James Learmonth, K.C.V.O., C.B.E., for much helpful advice in the earlier stages of the work and for making possible the radioactive iodine studies in the follow-up investigation of the incidence of hypothyroidism in Struma Lymphomatosa.

To Dr A.G. Macgregor of the Department of Therapeutics for much advice and help with the radioactive iodine tests and for his sustained interest throughout; also to the technical staff of that Department and Sister M. Thorburn, Ward 15 of the Royal Infirmary, for their assistance in carrying out these tests.

To Professor R. McWhirter for permission to make use of much valuable information in the records of the Department of Radiotherapy of the Royal Infirmary.

To Dr A.E. Stuart of the Department of Pathology for assistance in the pathological interpretation of certain of the cases, for the material with which to illustrate

/ the

the pathology of Subacute Thyroiditis and for much help in other ways.

To Mr I.S.R. Sinclair of the Department of Clinical Surgery for permission to make use of the case included in Part V, p. 238.

To the publishers of the British Journal of Surgery for permission to reproduce Figs. 3, 4, 98 and 99; and to the publishers of the Journal of Clinical Endocrinology and Metabolism for permission to reproduce Fig. 106.

To Mr T.C. Dodds and the staff of the Photomicrography Unit, Department of Pathology, for their hard work and close collaboration in the preparation of the colour photomicrographs.

To Mr D.B. Smith of the Department of Clinical Surgery for the production of the clinical illustrations.

To the House Surgeons in Wards 15/16 of the Royal Infirmary during the period 1955-58 for much help with the clinical work.

To Miss E.M.S. Barbour and Miss E.A. Donaldson for much valuable secretarial assistance.

Introduction

The term Thyroiditis, denoting basically an inflammatory condition of the thyroid gland, has in fact been applied to a fairly wide range of disease processes, not all of which would appear to satisfy the aetiological, clinical and pathological requirements of an inflammatory response. Acute (bacterial) inflammations of the thyroid, phlegmonous and suppurative, and the commoner granulomatous lesions, tuberculous, syphilitic and actinomycotic, have an immediately obvious and acceptable claim to such a title. There exist, however, certain other thyroid disorders, which, by long usage, have come to be known by the term - Chronic, or Chronic Non-Specific, Thyroiditis - although possessed of few of the features of inflammation in the more usual sense. It is at present customary to consider this group of Chronic Non-Specific Thyroiditis as consisting of at least three, though possibly more, separate diseases, namely Struma Lymphomatosa, Hashimoto's Disease or Lymphadenoid Goitre, Subacute or de Quervain's Thyroiditis and Riedel's Thyroiditis and it is to an investigation of these conditions that this work is devoted. While the term Chronic Non-Specific Thyroiditis can in no sense be regarded as a suitable connotation for these various disorders, it has been retained here for the reasons that, in the present state of our knowledge concerning them and having regard to their differing nature, it is difficult to find an alternative and more suitable generic title

/ by

by which they might be designated. Thus, where reference is made throughout the thesis to Thyroiditis it is to be interpreted as denoting, unless otherwise stated, Chronic Non-Specific Thyroiditis.

The work has been largely carried out in the Surgical Unit of Mr. K. Paterson Brown in the Royal Infirmary of Edinburgh and the cases which constitute the body of the thesis have been taken from the thyroid material investigated and treated there between 1943 and 1957.

PART I

THE EVOLUTION OF THE CONCEPT OF THYROIDITIS

Historical Survey

The first part of this study is devoted to an attempt to trace the manner in which the concept of Thyroiditis has evolved throughout the sixty years which separate the descriptions of the first recorded cases from the present day. Such an attempt necessitates a review not only of the original works of Riedel, Hashimoto and de Quervain, but also of those subsequent publications and statements of opinion which, for better or worse, have undoubtedly influenced general surgical thought. These may be regarded as the milestones measuring what progress has been made in our understanding of the disease processes in question and as such they are presented, in the first instance, without criticism.

In 1869, Semple recorded the case of a woman of fifty years of age who, although apparently dying finally of advanced pulmonary tuberculosis, had been under observation for two years because of an excessively hard, diffuse thyroid enlargement with marked respiratory difficulty. At autopsy a considerable, diffuse, firm, tough and indurated thyroid enlargement was found, surrounding, firmly united to and somewhat constricting the trachea. The gland itself consisted principally of dense fibrous tissue, although in some parts where the change was less advanced, thyroid structure was still visible. Referring to the process as "Fibroid enlargement of the thyroid body", Semple considered the disease to consist simply in an increase of the interstitial tissue of the thyroid and consequent atrophy of
/ its

its gland structure. This may represent the first recorded example of a case of Thyroiditis.

In 1884, Bowlby reported a remarkable case in a woman of forty-two years of age. When first seen, three years before her death, she exhibited a slight, firm, painless enlargement of the thyroid, without pressure symptoms. Gradually the gland enlarged and became excessively hard, associated with serious difficulty in breathing and later swallowing. Her death followed tracheotomy for the attempted relief of the urgent dyspnoea. Autopsy revealed an extremely hard, diffuse thyroid enlargement, extending down to the bifurcation of the trachea. Moreover, the juxta-thyroid structures, both in the neck and in the thorax - muscles, vessels and nerves - were infiltrated by and included in the tumour, while both trachea and oesophagus were infiltrated and showed marked compression and narrowing. Microscopically the structure was entirely fibrous. Bowlby recorded the case as an "Infiltrating Fibroid Tumour of the Thyroid", but in retrospect it seems possible that Thyroiditis, and not neoplasia, was responsible for the clinical and pathological findings.

While these case reports by British authors are of some chronological interest, it is to Riedel that we owe the first suggestion of a hitherto unrecognised disease of the thyroid gland. Riedel published his observations in three original contributions appearing in 1896, 1897 and 1910, and these form the basis of what has since become

/ known

known as Riedel's Thyroiditis. It is of fundamental importance to be thoroughly familiar with these original publications and no further apology seems necessary for their reproduction here, in full, as translated from the German.

First Publication - 1896

"Chronic Inflammation leading to the
formation of Iron-Hard Tumour of the Thyroid"

At the beginning of this year I drew attention in the Berlin Clinical Weekly to a rather striking kind of chronic inflammation of the pancreas. The pancreas degenerates into a tumour as big as a fist and the bile duct is finally displaced; if one gives operative help by connecting the gall bladder to the intestines, the whole tumour regresses. These cases are now two years old; the patients operated upon have continued to remain healthy. I now know for certain that they were not carcinomas but chronic inflammations which had led to the formation of enormous tumours. Now I have something similar to report about the thyroid gland. It has indeed many strange aspects - think of goitre metastases. I am starting a discussion on a new unusual feature of the thyroid. I begin with the case referred to on which I operated in 1883. A forty-two year old man, who for six months had noticed that his thyroid gland was increasing in size with accompanying pretty acute dyspnoea, came under my care. I found an immovable bilateral swelling which was not very big but was extraordinarily hard. I assumed that it was a question of a malignant struma, tried to operate on 30.11.83, exposed the tumour, saw immediately that it was extraordinarily firmly adherent on both sides to the carotid artery and the internal jugular vein. I resected a part of the internal jugular vein and then, after I had removed a piece as big as a walnut from the goitre I discontinued the operation, because I was forced to consider the case inoperable. The post-operative progress was uncomplicated; on 17.12.83 the patient was discharged with his wound healed. The patient reported back from time to time, and each time he was better pleased with his condition. Dyspnoea had ceased. After six months the man declared himself to be completely healthy and fit for work. In the meantime we had examined the preparation and found that there was no trace of new growth present. It

/ was

was an inflammatory process; infiltration with round cells was demonstrable; carcinoma and sarcoma were excluded, and there was likewise no evidence of syphilis or of tuberculosis in the patient. According to the axiom, "One swallow does not make a summer", I have waited twelve years before publishing the case. I found the matter too puzzling. Then last winter fate willed that, after I had operated on perhaps three hundred goitres in the meantime and seen nothing more of the kind, I once again had a patient to treat with a similar condition. Her mother has goitre which causes her no trouble. The patient has noticed for the space of a year that her neck was becoming thicker. For eight to ten weeks the goitre grew fairly quickly and became strikingly firm and solid. The patient could carry out her domestic duties, but, whenever she had to make any more strenuous effort, she developed dyspnoea with slight palpitation of the heart and finally dysphagia too. Present State: A very hard goitre as big as a hen's egg on the right and on the left as big as a small apple, but it could be fairly easily moved with the trachea. The pharynx was in the midline: the vocal cords function normally. She had a decided "goitre voice" and slight bronchitis in both lower lobes of the lungs. Pulse 90. The operation on 8.1.96 had to be discontinued on account of the extensive coalescence of the tumour with the blood vessels and the recurrent laryngeal nerve. One could not think of removing the swelling. The further course was the same in this case too; the patient's state of health improves and at first she feels well. Examination of the preparation brings out the existence of inflammatory tissue here too. I have called this "iron-hard". That may perhaps be a little exaggerated, but, as you can now see and judge for yourselves, it is a solid, hard tissue so that this expression is perhaps justified after all.

Now the outcome of the cases. I, of course, now enquired what had happened to the first patient. After many difficulties and exertions I succeeded in finding out that the patient had felt completely well for about nine months, that he had never again had dyspnoea, but that he had then developed nephritis and died one year and three months after the operation (7.3.85). His son wrote to me that the operation had, from the first, turned out extraordinarily well. The result had been very favourable. "My father developed nephritis and then had repeated strokes, succumbing to the fourth one." There was no post-mortem. The second patient felt just as well and her breathing improved with every day. Her fate, however, fulfilled itself more swiftly. One day she went out

of the house in to the courtyard and on coming back suddenly declared, "I feel ill" - and dropped down dead. There was no autopsy done here either. One gets the impression in every way that she probably died of an embolism. Thus we have to do with chronic inflammations in both cases. If you look at the microscopic preparations you will find collections of round cells interspersed among normal thyroid tissue, whereby the latter has been more or less destroyed. By just looking at the preparation, one has no idea of how hard the tumour is; one expects solid fibrous tissue to constitute the tumour but, as has already been said, one sees only embedded round cells.

Before the operation the tumour appears even harder; this is explained by the numerous firm adhesions of the tumour to the surrounding soft parts, particularly to the blood vessels, nerves and trachea.

All these adhesions have something tough and leather-like about them; they bleed extremely profusely; one cannot make any headway with the resecting of the tumour. The large blood vessels (carotid artery and jugular vein) appear as if walled in; one can quite well cut through them above and below the tumour, but one cannot separate them from it; the recurrent laryngeal nerve is hardly to be found, embedded as it is in callous tissue. The trachea is softened and one fancies it is already perforated. Even the most malignant tumour can be more easily separated than this tumour which is attributable exclusively to chronic inflammation.

I regret that I have no sections; the microscopic examination of the preparations and the clinical course of the cases, however, provide sufficient proof that new growth in the narrower sense of the word is not present.

All the same, both my patients may have had metastases from inflammatory goitre tumours in their internal organs and may have died from them. In Case 1, the four strokes give one food for thought considering the age of the patient. Locally neither of the patients experienced any re-enlargement of the tumours, which again is very striking; at most, a fifth of the tumour disappeared. It is scarcely possible to give an explanation of the favourable effect of the operation; only the fact that the growth of the tumour ceased post-operatively remains quite certain.

The knowledge of this fact is important for the treatment of similar cases; one should operate but

one should desist at the right time. By continuing the operation I would have caused severe damage to both patients by injuring vessels and nerves and they would eventually have died. Only after working for two hours on the first patient did I give up after ligating the internal jugular vein; in the second case the situation became clear to me more quickly and I discontinued the operation before the large vessels were injured. I had, however, tugged the nerve about so much that the patient developed partial paralysis of the corresponding vocal cord after the operation; this, too, could have been avoided. Whether still other means exist of improving or of eliminating the complaint other than partial excisions of the tumour is open to doubt. Case 2 was treated with iod-alkali internally and externally with iodine ointments, both without any success, and it was the same with treatment with thyroid extract in tablet form; thus it seems as if only partial excision of the tumour has, for the time being, any influence on the inflammatory process.

Second Publication - 1897

"Presentation of a patient with
Chronic Strumitis"

Last year I demonstrated here a preparation of a struma which had degenerated to a peculiarly hard tumour. The microscopic examination of the preparation and the clinical progress of the case proved that it was not a question of neoplasm in a narrower sense, but of a chronic inflammation of the thyroid gland. Directly after my lecture my friend Cordua from Hamburg informed me that he had operated on a similar case; a thirteen year old girl who had a hard struma just as hard as my twenty-three year old female patient's; Cordua had to give up the operation just as I had had to give it up; in spite of this, however, the child did get well. In the summer of 1896, Dr. E. Tailhefer, Head of the Surgical Clinic of the Faculty of Medicine in Toulouse, informed me by letter that he had observed a similar case.

Chance has ordained that I am today in the position of being able to present to you a patient with iron-hard struma; this struma is very probably also of an inflammatory nature and not neoplasm in the restricted sense.

The twenty-nine year old patient was completely healthy until the beginning of May, 1896; he knew

/ nothing

nothing of the existence of his thyroid gland. At that time he noticed a small, hard swelling up on the right at the level of the larynx; in the course of four weeks this enlarged in such a way that, first the right side of the neck grew hard, then the hard swelling crossed over the midline towards the left side to develop there to the same extent as on the right. About six weeks after the onset of the trouble, the tumour reached the size that it still is today.

Soon the patient developed severe dyspnoea; Iodine calc. was used without success; in the middle of July the patient was admitted to the clinic.

On the twenty-first of July an attempt was made to remove the goitre; it did not succeed because the goitre was inseparably merged with the surrounding muscles, vessels and nerves. I removed a piece about as big as a walnut from the greyish-white tumour which was mostly hard but also somewhat softer in places, and I then broke off the operation, especially as it became ever clearer during the operation that chronic strumitis, not neoplasm, was present.

The examination of the excised tumour proved that it consisted of spindle and round cells; it remained doubtful whether inflammatory tissue or neoplasm (fibrosarcoma) was present; only further observation of the clinical progress could decide; it decided in favour of chronic inflammation.

The wound healed quickly, so that the patient could be discharged as early as August 8th; he took Fowler's solution continuously; the dyspnoea remained.

Towards Christmas such violent attacks of dyspnoea occurred at nights that the patient was once again sent to the clinic. He now looked very cyanotic and coughed a great deal; when masses of mucus gathered at nights behind the stricture, choking fits occurred to which the patient threatened to succumb.

Therefore, on the 11th January, 1897, another attempt was made to provide an airway; a wedge extending to the trachea was cut out of the isthmus which was approximately two to three centimetres thick; we succeeded in clearing the trachea by forming a narrow channel.

The patient now recovered slowly; the dyspnoea remained, it is true, but the nocturnal choking fits ceased. At present the patient can go for longer

/ walks

walks, although slowly; the vocal cords are completely intact, although his speech is rough and hoarse. As I have already said, the swelling has not grown any more since June last year - it has even become smaller, because two pieces, each as big as a walnut, have been removed from it. The scars are correspondingly deeply indrawn and are firmly adherent to the goitre.

The case has not yet run its course so that one cannot yet pass any definite judgment on it. If, however, it were primary and what is more, corresponding to the rapidity with which it arose, very malignant new growth, then it would be highly surprising that the swelling should not have grown larger in the course of nine months; surely a malignant tumour usually grows considerably in the space of nine months.

In this case, just as in the two cases discussed earlier, the tumour reached its maximum size within a very short time and then remained that size permanently. This fact undoubtedly tells mostly in favour of inflammation. In publishing his cases of "Scirrhus of the Thyroid Gland" (Wein. Med. Wschr. 1888. No.20) Billroth has also discussed the question as to whether it is new growth or chronic inflammation. The clinical course of Billroth's cases argues throughout in favour of new growth (a slow uninterrupted growth, secondary glandular swelling in Case 1). A parallel exists between Billroth's cases and mine only in so far as the tumours in his cases were also very hard; for the rest they differ completely from one another.

Third Publication - 1910

"Concerning the Course and Outcome of Chronic Strumitis"

Recently Silatschek has added a new case, observed in Innsbruck, to the seven cases of "iron-hard" struma already known. In discussing this case he remarks as follows: "I should not like to omit to mention here that von Eiselsberg, specially referring to the case of Tailhefer, despite the lack of epithelial elements, does not entirely exclude the possibility of a scirrhus (carcinoma) of the thyroid gland. He cites as a comparison scirrhus (carcinoma) of the stomach, where, in the majority of sections one may also come across fibrous tissue only, and yet there is a scirrhus (carcinoma) present; only further clinical progress can then determine the diagnosis. One cannot dismiss the fact that the

/ possibility

possibility of a scirrhous (carcinoma) perhaps exists in isolated cases of chronic strumitis so far observed, this being all the more probable as, in fact, there has been no follow-up of a case over a period of years. Yet in the majority of cases of which we are so far informed, there is no cause to doubt that, in fact, a purely chronic inflammatory process has been before us and not a malignant neoplasm."

These remarks are in every way to the point; it is all the more gratifying that at least one case exists which, observed for fifteen years, proves conclusively that this chronic inflammation which leads to the formation of extremely hard tumours has been rightly described by me as a characteristic disease picture.

The very first patient upon whom I operated provides nearly conclusive evidence, because, microscopic examination of the partly excised tumour having taken place, the patient was still living one and a quarter years after the operation. The goitre had receded further; then the man, who was almost cured, died of nephritis. Still more reliable, however, is the observation of the patient whom I introduced to the Surgical Congress of 1897; he presented himself here on 14.8.1910 as an almost entirely healthy man. The history of his sufferings is so interesting that I shall render it again in rather more detail:

A.M., 29 years old, admitted 10.7.1896, was completely healthy until the beginning of May, 1896; he did not know that a thyroid gland existed. At that time he noticed a small, hard swelling up on the right at the level of the larynx; in the course of four weeks this swelling grew larger in such a way that first the right side of the neck hardened, then the hard swelling spread over the midline towards the left side to develop there to the same extent as on the right. After about six weeks the swelling was as big as a man's fist. The patient developed violent dyspnoea and, at night especially, attacks of choking.

On the 21st July I tried to remove the extraordinarily hard tumour which had grown firmly into its surroundings, but directly discontinued the operation, because the large vessels and nerves were merged with the tumour; only a piece as big as a walnut was cut out of the greyish-white mass which was mostly hard but also softer in places, particularly as it became

ever clearer that Strumitis chronica, not new growth, was present.

The wound healed quickly but dyspnoea persisted. The patient was sent home with Fowler's solution. Towards Christmas he came back; he now appeared cyanotic and coughed a good deal; when, at nights, masses of mucus gathered behind the obviously narrowed upper part of the trachea, choking fits occurred to which the patient threatened to succumb.

Therefore, on 11.1.1897, a wedge was cut out of the isthmus which was approximately two to three centimetres thick. We succeeded in clearing the trachea by forming a narrow channel. The patient now recovered slowly; dyspnoea remained, but the nocturnal choking fits ceased. His speech was rough and hoarse, but the vocal cords which we could only now examine were intact. Nine months later the tumour had become smaller, the cicatrices were deeply indrawn and coalesced with the skin. Fits of dyspnoea remained and the patient was unfit for work. In the middle of 1901 the complaints ceased. The man's old capacity for work returned, so that he could be actively employed in a furniture removal business.

At the beginning of January, 1905, he felt ill for four days and then a copious gastric haemorrhage occurred once during which he lost more than a litre of blood; the patient was given an ice pack to the epigastrium for a fortnight and had to swallow lumps of ice; he was confined to bed for three months. The old attacks of dyspnoea returned; they lasted for four years, occurring again particularly at nights, so that he could not sleep in bed. This condition improved at the beginning of 1909, so that he could work again as a woodcutter; he now splits about one and a half cubic metres a day, but must avoid bending, because when he does he becomes giddy. At the moment there is outwardly not a trace of goitre to be found in the neck: the patient is lean but strong. The examination of the larynx and of the trachea respectively gave the following result: 17 cms. beyond the teeth a considerable but not very extensive stenosis of the subglottic space and of the trachea. The right wall bulges evenly into the lumen; on the left there is a projection which is rather sharp-edged and cord shaped. The vocal cords move normally.

Typical case: young person, subacute swelling and hardening of the thyroid gland, directly severe dyspnoea, no fever, so that infection is out of the

/ question.

question. The microscopic state bears this out: there is an accumulation of spindle and round cells among the normal elements of the goitre, displacing the latter more and more: slight endarteritis as in many chronic inflammatory processes.

The rapid development of young connective tissue is striking, yet we have indeed something analogous in the formation of common scars. Another striking point is that until now the affliction has been so rarely observed. I have seen only three patients - the last was the one described above, operated on fifteen years ago; I have had hard goitres before me often enough since then; they were either calcified or malignantly degenerated. As against 1,064 benign goitres which have been operated on here, there are only three with chronic inflammation. But, as a matter of fact, this number is still high when one reflects that out of the whole of Germany only one more case (Cordua) has been published; what happened to that case cannot be confirmed, because the author has died.

Silatschek's patient got better spontaneously; perhaps this spontaneous healing holds the key to the "rarity of cases". It is surely conceivable that in many affected persons the affliction develops to a certain degree only and then recedes spontaneously; they have therefore no cause to appear in a surgical clinic. It is possible that general practitioners occasionally see such cases. If the inflammation progresses, if it involves the entire thyroid gland, if severe dyspnoea arises, then the sick person will always seek operative help; this help is to be confined to the excision of a wedge extending to the trachea; bleeding is severe but the operation is at least practicable, because the vessels have a small calibre. A hemithyroidectomy is quite impossible, because the carotid artery, internal jugular vein and the vagus nerve are inseparably merged with the tumour. If the isthmus of the thyroid gland is rather larger in volume, then tracheotomy is also impossible; the superior does not succeed, because one cannot separate the goitre from the trachea; for the inferior tracheotomy there is not sufficient space below the isthmus over the jugular fossa.

Where there is serious dyspnoea the excision of a wedge from the isthmus will always be the most rational thing to do; it seems to have had a life-saving effect on my patient. Subsequently the connective tissue in the goitre has obviously withered

/ more

more and more, the resulting pull of the scar on all sides has compressed the man's trachea, but it has, however, remained in toto fairly wide.

The whole disease is a puzzling one; we do not know why the connective tissue in the thyroid gland develops, increases more and more and then shrivels again, so that with or without surgical aid a relative healing comes about by means of cicatrization. Many an afflicted person may, however, already have gone miserably to destruction under the diagnosis "inoperable cancer", so that the attention of wider medical circles must be drawn to the disease.

Thus, with the publication of his clinico-pathological observations, extending over a period of fourteen years, Riedel firmly established for the first time the existence of a form of thyroid disease which had previously gone unrecognised and which certainly defied inclusion among the commoner, established and better understood affections of the gland, known at that time.

In 1912, two years after the publication of Riedel's third and last contribution, the canvas was further broadened by the work of Hashimoto. Under the title, "Contribution to the Knowledge of Lymphoid Changes in the Thyroid Gland (Struma Lymphomatosa)", Hashimoto recorded what he considered to be a new thyroid disease entity, previously undescribed. His original article is too lengthy for reproduction in full here and, indeed, no useful purpose would be served by so doing. Again, however, as with Riedel, an intimate acquaintance with Hashimoto's clinical and pathological descriptions and his major conclusions is of such fundamental importance and relevance, that these are reproduced in the following passages as translated from the original.

Hashimoto's Publication - 1912"Contribution to the Knowledge of Lymphoid
Changes in the Thyroid Gland
(Struma Lymphomatosa)"

By the new expression which I have invented, "lymphomatous change in the thyroid gland", I mean a proliferation of lymphatic elements with the formation of lymphoid follicles as well as a certain change in the parenchyma and interstitial tissue which one can see in the excised struma tissue. Such findings aroused my whole interest and caused me to work on the subject mentioned above.

In the course of six years, I observed in our clinic four struma cases of this kind which I should like to term "Struma Lymphomatosa", and as this disease has not, as far as I know, been described in the literature, may I be permitted to describe it in greater detail.

The histories of our cases are briefly as follows:

CASE 1. Admitted on 21.11.1907. J.U. A female aged 61 years. Her father died of apoplexy, but otherwise there are no hereditary factors. The patient has been healthy from childhood on and never been through any illness worth mentioning. She denies venereal infection. Only seven months before, the patient noticed a swelling in the median part of the neck which has not, she alleges, grown any larger since then. Until now she has not suffered from sleeplessness, palpitation of the heart or disturbance in general health.

Present State. She is of medium height, moderately stoutly built and moderately well nourished. Her inner organs are intact. There is no sign of Basedow's disease. The tumour, which is situated in the median part of the neck, is horseshoe-shaped, as a whole bigger than a hen's egg, and rises during swallowing. It is not tender to the touch, rather solid, fixed to the trachea firmly but moves freely against the skin and surroundings. Glandular and skeletal systems show nothing abnormal.

Diagnosis. Struma Parenchymatosa.

Operation on 22.11.07 under chloroform anaesthesia. Collar incision according to Kocher. Subcapsular resection of both lobes. The dissection of the superficial tissues of the goitre took place without special difficulty; there was little bleeding. The extirpated struma tissue was somewhat solid.

Progress. A slight rise in temperature to 38° C. occurred. The patient feels very weak. After a week the drainage tube and ligature were removed. The scar healed by first intention. Very slight post-operative hoarseness exists. According to information by letter on 7.3.11 the patient is quite well and the part operated on has not so far swollen again.

CASE 2. Admitted on 30.5.09. Y.N. A 40 year old peasant woman of healthy family. She had had smallpox at the age of two. For twenty years she has suffered from leucorrhoea. Forty days ago the patient noticed a painless tumour near the cricoid cartilage which has not increased noticeably in size since then. For one month past the patient perceived that her voice was husky. Moreover, slight headaches occurred at times and her appetite was upset.

Present State. She is of medium height, gracefully built, moderately well nourished, rather anaemic. All her internal organs are intact. In the median part of the neck there is a horseshoe-shaped tumour, consisting of two lobes and a connecting part; the right lobe 7 x 3.5 cm., the left lobe 5.5 x 4.5 cm., at the base 6.5 cm. broad. The tumour is not sensitive to pressure. It is outstandingly solid and finely nodular; it rises when the patient swallows. It is hardly moveable on the underlying structures - otherwise there is no other adhesion. There is nothing abnormal in the rest of the body, particularly the glandular and skeletal system.

Diagnosis. Suspected malignant struma.

Operation on 2.7.09 under chloroform narcosis. Kocher's collar incision. The entire thyroid gland tissue was enlarged like a tumour and everywhere uniformly very solid to the touch. In dissecting the superficial tissues of the goitre there was pretty severe bleeding. Excision was carried out from both lobes, that is to say a piece measuring 6 x 3.5 x 2.5 cm. from the right and from the left a piece 5 x 3.2 x 2 cm. The surface of the excised struma tissue is finely granular and divided lobularly.

Progress. Smooth progress, free from complications. The wound healed by first intention, and the patient was discharged as cured on 19.7.09. Condition at that time: her facial colour was still anaemic. Her appetite was good. A fragment of tumour still

/ remained

remained in the part operated on. She was readmitted for further investigation on 27.1.11. For about nine months after she was discharged, the patient felt physically very weak and was unfit for work. From the beginning of 1910 she gradually regained her physical strength and the patient was able to work. Her condition at that time was as follows: facial colour anaemic, moderately well nourished. All her internal organs were intact. The remainder of the tumour which had been palpable when she was discharged had disappeared without trace. Her faeces contained numerous eggs of ankylostoma. These were cleared by internal administration of thymol and naphthalene. The Wasserman reaction and tuberculin injection gave negative results.

CASE 3. Admitted on 19.6.05. S.T. A female, 55 years old, who had once had a premature child-birth, but was otherwise in good health. She denies syphilis. Thirty days previously the patient chanced to discover a swelling in the front part of her neck which until now has not shown any marked increase in size. She complains of a feeling of tenseness in the shoulders and of slight headaches which occur from time to time.

Present State. She is small in stature, moderately well nourished and somewhat anaemic. Her internal organs are intact. In the front part of her neck there is a tumour which corresponds exactly with the thyroid gland; the right lobe is as big as a hen's egg, the left as big as a pigeon's egg and the whole is horseshoe-shaped. The tumour is not sensitive on pressure and is in general very solid, fixed to the trachea and moves freely against the skin and the surrounding tissue. The glandular and skeletal systems, as well as the rest of the body, present nothing abnormal.

Diagnosis. Struma Fibrosa.

Operation on 20.6.05 under chloroform anaesthesia. A Kocher's incision was used. The right lobe of the thyroid gland was as big as a hen's egg; it was very solid and swollen like a tumour; the left lobe was as big as a pigeon's egg and was constructed like the afore-mentioned, i.e., very solid and swollen. Resection of both lobes was carried out. The excised tumour tissue was constructed exactly as in Case 2.

Progress. Her voice was husky and she complained of slight pain on swallowing. There was a feeling of tension in the neck. Her general state of health was upset. When the sutures came out the wound healed by first intention. The patient feels well. She

was discharged healed on 7.7.05. In the part of the neck operated on one can still feel a solid tumour residue which had been intentionally left behind when the operation was performed. Slight anaemia and huskiness still persist. On 20.3.11, that is, five and three-quarter years after the operation, the patient was given a full clinical examination. After she was discharged she continued for a while to feel generally weak and had a poor appetite. In the winter the patient felt the cold to a striking degree and became weakly.

In 1906 oedema appeared over the body all year long, of course with certain periods of remission and exacerbation. From the beginning of 1907 onwards her condition had gradually improved. The oedema in the body improved considerably after the internal administration of thyroid preparations.

Present State: The patient is moderately well nourished and not anaemic. The urine is free of albumin. Despite careful palpation there is nothing abnormal to be found in the region of the thyroid gland.

CASE 4. Admitted on 19.9.07. S.K. a 45 year old widow, who has never undergone any illness worth mentioning. She denies venereal disease. Three days previously the patient noticed a tumour in the anterior median aspect of the neck which up to now has not caused any trouble and has not specially increased in size.

Present State. She is tall, stoutly built and slightly anaemic. Her internal organs are intact. In the anterior part of the neck below the cricoid cartilage there is a tumour as big as a hen's egg, shaped like a horseshoe, rising when the patient swallows and not tender to the touch. It is firmly fixed at the base and moves on the surrounding tissues. The cervical glands were not enlarged anywhere. The skeletal system and the remaining parts of the body show nothing abnormal.

Diagnosis. Struma Fibrosa.

Operation on 20.10.07 under chloroform anaesthesia. A collar incision was made. One sees uniformly swollen thyroid tissue of very solid consistency. When the superficial tissues of the goitre were dissected there was copious bleeding. Resection of both lobes and of the isthmus was carried out. The portion of tissue excised appears similar to that in Case 2.

/ Progress

Progress. Slight attacks of coughing with sputum occurred - otherwise a smooth course without complications. The wound healed by first intention. She was discharged on 31.10.07 in the following state: facial colour pale, appetite good, the piece of goitre left behind still palpable. She was given a full clinical examination on 10.3.11, that is three and a half years after the operation. After she was discharged she felt generally very weak for some considerable time. In addition, slight oedema appeared from time to time in her face. She alleges that, in the summer of 1910, a swelling without symptoms again appeared in the thyroid region, but it regressed spontaneously.

Present State: Moderately well nourished, but slightly anaemic. Her inner organs are intact and her voice only slightly husky. In the anterior region of the neck one can feel that both lobes of the thyroid are strumously enlarged. The lobes are not tender to the touch, but are solid.

Clinical Summary

If we summarise the foregoing clinical observations, then it is a question of a total of four patients who were all of female sex and over forty years old. They came from healthy families and did not live in any "goitre region". No one among their relatives was troubled with goitre. The patients' way of life offered nothing striking. The patients had never previously been seriously ill, above all had never suffered any serious infectious disease with which diseases of the thyroid gland are frequently associated. Venereal disease and tuberculosis were clinically excluded. In every case the increase in size of the thyroid gland was discovered by chance. No discomfort worth mentioning arose in connection with this. With patients in a good general condition and with normal body temperatures we found no particularly rapid increase in size of the thyroid. Always both lobes were affected. The size of the tumour varied. Severe symptoms of compression like dyspnoea or aphonia were never present. Only in one case was there any history of slight hoarseness before the operation, and in this case incomplete closure of both vocal cords could be confirmed, which was attributable to the faulty functioning of the inter-arytenoid muscle. One could not point to any trace of inflammation in the distended thyroid gland. The tumour could be pretty freely displaced. But the consistency was mostly so solid that one could suspect a malignant tumour or Riedel's strumitis. Regional

/ lymph

lymph glands were not to be palpated anywhere in the body. We could find nothing abnormal in the internal organs.

The results of the operations showed no particularly strong adhesions to the surrounding tissues as in Riedel's struma, a fact which is expressly stressed by the author in question. Post-operative hoarseness remained more or less in all cases, although it was always a question of a very slight degree.

In the further progress after the operation oedema allegedly appeared throughout the whole body which usually disappeared when thyroid preparation was administered by mouth. It is specially to be stressed that, whereas in the other cases of benign struma observed in our clinic the post-operative progress turned out to be quite uneventful, in the above-mentioned cases the patients always needed a prolonged convalescence before they were restored to their complete state of health. In one case (Case 4) a recurrence of the struma is said to have reappeared for a time, but that soon shrank again to a minimum.

Histological Findings

All our four cases show a uniform anatomico-pathological condition. The second and third cases in particular stand out by reason of specially instructive variations. As far as the infiltration of the tissue by round cells and the parenchymatous degeneration are concerned, Case 4 is most seriously attacked. The lymphoid follicles are strikingly well developed in Cases 2 and 3. As Cases 2 and 3 in general present a well developed picture of the disease, I should like to occupy myself chiefly with these two cases in what is to follow. Case 4 offers a picture which differs somewhat from the three others, yet it is to be interpreted as nothing other than an advanced change.

Under the microscope we see various noteworthy states, above all, however, the striking abundance of lymphoid follicles, diffuse change of the gland follicles and, connected with this, new growth of connective tissue.

The lymphoid follicles are specially abundant at the periphery of the excised gland tissue. They are situated inside the lobules as well as in the interstitial tissue, scattered or closely crowded together. The shape and size of the lymphoid follicles is extremely variable; mostly polygonal, spindle-shaped, roundish or irregular. They mostly

possess inside them a germinal centre, in which we find a characteristic cell form, generally provided with a faintly coloured vacuolated nuclear particle. In the germinal centre there are always large and small lymphocytes and to be sure, the large ones out-number the small. Here and there we see capillaries provided with endothelial cells and reticular cells. We also find very isolated plasma cells, the nuclei of which are eccentrically situated and supplied with a network of chromatin arranged in typical fashion. In addition to that we note that mitotic nuclear division figures are to be seen in great abundance in the germinal centre.

The marginal zone of the lymphoid follicle consists of reticular connective tissue and contains in its meshes closely packed lymphocytes. The lymphocytes near the germinal centre are arranged in parallel rows and enclose reticular cells in their midst. Elastic fibres are hard to discover in the lymphoid follicle.

The size of the vesicles varies considerably according to the case. In Case 1 the vesicles are generally large, but in Case 4, small. The size of the individual vesicles varies in transverse section from 30 to 360. As far as the form of the small to medium-sized vesicles is concerned, this shows mostly roundish or oval transverse section - on the other hand, at the place where the vesicles appear large, we see an irregularly shaped form. The numerical proportion of the vesicles of varying size to one another is, in general, hard to determine. It is related first and foremost to the condition of the interstitial tissue and the infiltration of round cells. Where the connective tissue of the interstitial tissue had developed intensively or the round cell infiltration was present to a striking degree, the smaller vesicles were to be seen in superior numbers. Especially in Case 4, the smaller vesicles predominate. Here there are also such areas that consist almost entirely of very small vesicles of about 30 diameter, indeed often even epithelial cells lying side by side haphazardly in heaps. Thus one can no longer recognise any indication of vesicle structure. These last mentioned vesicles also occur in Cases 1, 2 and 3 and are accompanied by proliferated interstitial connective tissue. In the hyperplastic connective tissue there are mostly some epithelial cells lying together in a group, or scattered singly. These cells by their size and form, as well as behaviour of the nucleus, make it easy to recognise that they derive from atrophied vesicles.

As to the form of the cells of the vesicles we find a flattened form if the vesicles are in a well-filled condition, a cubical if they are not so fully filled and a cylindrical where they contain only a small amount of colloid substance or, instead of that, any abnormal content. Whereas in Case 1 only the vesicles which were filled with colloid were disseminated almost throughout the entire tissue, we found in the other cases diffusely distributed characteristic vesicles distinguished by a shape varying from cubical to columnar.

The epithelium of the lining of the follicle is for the most part arranged in one layer. The protoplasm of these cells is brightly stained by eosin in particular places, or dingily stained in others.

The colloid in the vesicles is very varied in our cases. As far as the staining capacity of the colloid is concerned, this varies according to the position. In well preserved vesicles the colloid is mostly well stained, but in others in which the epithelium of the follicle is very much changed, one meets with a weak staining capacity of the colloid. Generally speaking, one can say that the colloid substance is greatly reduced, indeed in altered follicles even to the point of almost disappearing completely.

In addition we see in the vesicles still other different elements of which those poor in colloid are especially abundantly represented. These elements consist of epithelial cells, leucocytes or derivatives of these as well as a fragmented mass.

The behaviour of the connective tissue is very important in our cases. There is marked proliferation everywhere which offers a beautiful picture with van Gieson's stain. This was diffuse and was especially strongly marked in Case 4, so that one could no longer recognise the lobular arrangement of the vesicles. The connection between the proliferation of the connective tissue and the change of the vesicles was also interesting. The vesicles in the proliferated connective tissue were scarce and were conspicuous by reason of their small form. In individual places one sees a circumscribed very greatly developed mass of connective tissue which enclosed a number of very small vesicles in its interior. Further, it seemed very striking that the connective tissue was diffusely infiltrated by mononuclear leucocytes. The infiltration of round cells which consisted mainly of small lymphocytes

displayed the same strikingly characteristic condition in all our cases. Between these round cells we still saw a moderate number of plasma cells whose protoplasm and nuclei were quite typically stained. The infiltration of round cells mainly affected the surroundings of some big vessels. The giant cell-like formations with numerous peripheral nuclei and red coloured protoplasm were dispersed in Case 4 by the proliferated connective tissue.

As far as the vessels are concerned, in all our cases these did not appear to have altered noticeably.

Moreover, I had not neglected to try to seek out bacteria in numerous paraffin sections (with carbol fuchsin, methylene blue, Gram stain, etc.). Although I searched diligently, I did not find micro-organisms anywhere.

Summary of the Histological Changes

It transpires from the histological findings just quoted that the main changes in all our cases consist of:-

1. Numerous formations of lymphoid follicles.
2. A striking change of the epithelium of the vesicles, as well as of their contents.
3. Extensive new formations of connective tissue.
4. Diffuse round cell infiltration.

If we look through the anatomico-pathological findings of our four cases, we can immediately discover corresponding changes, even if such changes show differences of degree. In Case 1, the change in the vesicles is very slight, as one comes across them well filled with colloid, provided with almost normal follicles and with well preserved epithelial cells. Here, however, the vesicles are not as big as we are accustomed to see them in a marked colloid struma. In Cases 2 and 3 the vesicles are changed in typical fashion. They show epithelial cells which are inclining to depopulation, atrophied vesicle remains and abnormal content. In Case 4 the vesicles are generally small, atrophic, with little colloid substance and abnormal content.

The round cell infiltration is only slight in Case 1, moderate in Cases 2 and 3, but in Case 4, strikingly pronounced. These round cells consist of

/ mononuclear

mononuclear lymphocytes as well as plasma cells. The lymphoid follicles are present in moderate abundance in Case 1, in Cases 2 and 3 they are very plentiful. The proliferation of connective tissue is barely to be demonstrated at all in Case 1, whereas in Cases 2 and 3 it has developed pretty intensively, and in Case 4, very vigorously. The change of the parenchyma is only slight in Case 1, moderate in Cases 2 and 3, and in Case 4 very advanced.

Comparative Discussion

..... At the Fifteenth Congress of Surgeons (1896) Riedel reported on a peculiar kind of chronic inflammation of the thyroid and drew people's attention to the fact that a striking tumour formation appeared with this, similar to what occurs in chronic inflammation of the pancreas. Since then other authors have given information about cases similar to this and by so doing aroused lively interest in our circles.

Now I should like to occupy myself with the difference between our struma cases and Riedel's.

All our patients and Riedel's as well were otherwise healthy and had previously suffered no illness worth mentioning - above all, no severe infectious diseases. The strumas of Riedel favoured the third decade and occurred much more frequently in men than in women. All our cases concerned persons over forty years old and of the female sex. The consistency of the tumour in our cases was mostly strikingly solid. But one cannot term them "iron-hard".

In the cases of Riedel's struma which came to be operated upon, the extirpation did not succeed, because the tumour was firmly adhered to big vessels and nerves, and always a small piece of it only was cut out. On the other hand in our cases, despite rather difficult dissection of the capsule, we could nevertheless carry out the resection as in a case of benign struma.

In the histological picture we see in our cases as well as in Riedel's strumas, round cell infiltration, proliferation of the connective tissue and regression of the epithelium of vesicles.

We have no knowledge of the formation of lymphoid follicles in cases of Riedel's struma. The further progress was almost the same in both cases. The

/ palpable

palpable remains of the tumour gradually dwindled.
.....

The remainder of Hashimoto's paper is devoted to the differentiation of his Struma Lymphomatosa from other and better known thyroid disorders and to his preoccupation with the similarity between his material and cases of Mikulicz's disease. Although allowing that his material probably was in the nature of a chronic inflammatory process, he left no doubt that he considered his findings indicative of a disease quite distinct from that described by Riedel.

The next statement of opinion, which was to influence surgical thought profoundly in the ensuing years, emanated from Ewing in 1922. The following excerpt is from his work "Neoplastic Diseases", appearing in that year, and under the title "Benign Granuloma of the Thyroid. Riedel's Struma":-

..... I have studied four cases which illustrate both the above conditions, and in two of them a very extensive and peculiar sclerosis had overtaken and largely replaced the lymphoid tissue. It appears, therefore, that Hashimoto and Riedel have described the early and the late stages of the same pathological process.

These cases occurred in adults, and produced tumours of considerable size involving the whole gland. The growth was rather active for a few months, after which the process became slower or stationary. The regional nodes were unaffected. There were no symptoms of hypothyroidism. One very large tumour produced severe dyspnoea from pressure, but receded rapidly under radium. The form of the gland was retained.

In the early stages the gland is thickly beset with very numerous lymph-follicles with active germ centres, the reticulum cells of which became so numerous as to suggest lymphosarcoma. In one

/ instance

instance the condition had been diagnosed as carcinoma. The persisting reticulum cells incarcerated between the hyaline strands of fibrous tissue yield a picture resembling small-cell alveolar carcinoma. All stages of atrophy of the alveolar epithelium can be traced. Fibrosis and hyaline transformation begin early and eventually, as in Riedel's cases, the enlarged gland becomes very firm and dense.

Thus, Ewing was responsible for what may be termed the "unitarian concept", as opposed to the idea of two separate disease entities and in this way a division of opinion arose, each view subsequently claiming its own adherents.

In passing, it is worthy of note that Ewing's remarks regarding the subsidence of the tumour in one case "under radium", is probably the earliest reference, at any rate in the Anglo-American literature, to the effect of radiotherapy upon this process.

Bohan, in 1924, published a case under the title "A Case of Ligneous Thyroiditis Associated with High-Grade Dental Infection" which he considered analogous with the malady described by Riedel. His patient was a woman aged thirty-eight with marked pressure symptoms, but what particularly attracted his attention was the concomitant marked oral sepsis. Films of the teeth showed 11 with apical infection and all teeth showed pyorrhoea in varying degrees. Cultures taken from the abscessed teeth showed colonies of streptococcus viridans and staphylococcus. When such were injected into rabbits, autopsy revealed extensive haemorrhages in the thyroid gland and marked oedema, with small haemorrhages in the thymus, no other

/ lesions

lesions being found. Bohan concluded that a direct relationship existed between the oral sepsis and the thyroid condition and his observations are of interest as an attempt to associate focal infection with the aetiology of Thyroiditis.

In 1925, Meeker gave a clinico-pathological description of one case under the title "Riedel's Struma associated with Remnants of the Post-Branchial Body", and reviewed the literature up to that time. Meeker accepted Ewing's hypothesis and in fact the microscopic specimens were submitted to the latter. The particular interest of her publication is her description of certain peculiar groups of epithelial cells occurring as cell nests, sometimes with lumina. These she interpreted as remnants of the post- or ultimo-branchial body, and she took the view that extension of inflammation from the pharynx or trachea along the ultimo-branchial duct system into the thyroid gland might account for the pathology and incidence of the disease.

Also in 1925, a further publication appeared which was of some importance and which was certainly destined to have considerable influence on subsequent terminology. This was the work of Williamson and Pearse in which they coined, for the first time, the term Lymphadenoid Goitre. In a subsequent article in 1929, they further elaborated their views, the following excerpt being taken from the latter publication.

When working on the histology of the thyroid in 1925 we found that there were two activities carried on by the normal gland. The two functions we refer to are: (1) The production of secretion proper; or what for greater precision may be called "lymphogenic" secretion. This secretion contains no thyroxin. (2) The accumulation of colloid - that is, iodo-colloid, which contains the thyroxin moiety of the thyroid products.

One of the features of the normal secretory process is the conspicuous activity of the reticulo-endothelial cells with the production of lymphocytes in the interfollicular lymph spaces of the thyroid gland units. It is this latter feature of the secretory process which calls for the specific designation "lymphogenic" secretion.

To the pathologist the knowledge of a specific process in the normal physiology of a gland must lead to search for the corresponding pathological condition in which undue strain falls upon that specific process. This, then, led us to look for a class of thyroid disorder in which the functional imbalance would lie in the over-production of lymphocytes during the secretory process of an otherwise normal thyroid gland. In the course of a review of about 4,000 goitres we were able to separate some glands answering to this description. These, when ranged in sequence, betrayed their own pathological sequelae - fibrosis and atrophy. Thus a pathological condition which had been obscure could now be discerned as a specific progressive disorder often associated with goitre. To this class of enlarged thyroid gland we gave the name "lymphadenoid goitre".

Goitres which essentially belong to the group of lymphadenoid goitres have been called by earlier observers "chronic inflammatory thyroiditis", "granulomatous thyroiditis", "endothelioma", "sarcoma", and also "Riedel's disease" or "woody thyroid", etc. Although these various designations fail to convey the true pathogenesis of this condition they do indicate its most striking features: (1) the lymphocytic activity which is typical of the early or progressive stages of the process, and (2) the fibrosis and atrophy which accompany its later stages.

The term Lymphadenoid Goitre, formulated in this way by Williamson and Pearse, has, with the passage of time, taken its place in the nomenclature of Thyroiditis and has come to be used synonymously with Struma Lymphomatosa or

Hashimoto's disease.

In 1927 and again in 1929, McCarrison, working on the experimental production of goitre, succeeded in producing a type of goitrous enlargement in young rats, which was unrelated in its origin to iodine deficiency, the basal factor in its causation being a diet containing more than 60 per cent of white-flour or of vitamin-poor carbohydrate, 20 per cent or less of protein, with fats and inorganic salts (including iodine) in adequate amounts but no green vegetables nor fruit. Approximately 25 per cent of the rats so fed exhibited goitres of various sizes at post-mortem examination. McCarrison considered the pathological findings in his rat goitres to be identical with the appearances described by Williamson and Pearse as characteristic of the progressive stage of Lymphadenoid Goitre in the human subject. He considered vitamin deficiency to be the aetiological factor in the experimental animal, although failing to incriminate one particular vitamin, and drew attention to the possibility of a similar causal factor in man.

McCarrison was the first, and has subsequently proved to be one of the few workers, to apply an experimental, as opposed to a purely clinico-pathological approach, to the problem of Thyroiditis.

It had long been recognised that lymphoid tissue may occur in the thyroid gland normally and in simple goitre, but particularly well marked in thyrotoxic states, in

/ other

other words, in affections of the gland apart from the "pure" forms of Thyroiditis. Indeed, Hashimoto, in his original contribution, drew attention to this fact, but at the same time carefully excluded any signs of Basedow's disease in his patients.

As time passed and subsequent investigators became increasingly familiar with the concept of Thyroiditis and cognisant of the rather more universal distribution of such lymphoid tissue, attempts were made to find a relationship between the more familiar and better understood thyroid disorders (in particular thyrotoxicosis) and Thyroiditis, rather than regard the latter as an entirely separate and mystifying entity.

The work of Williamson and Pearse represents such an attempt, but the possibility of such a relationship was more forcibly expressed in two publications appearing around about this time.

The first of these was by Warthin in 1926. Impressed by and critical of the widespread use of iodine as a popular panacea in all forms of goitrous disease at that time, he wrote as follows:-

In the case of the adenomatous goitre treated by Lugol's the one striking thing has been the marked hyperplasia of the lymphoid tissue, and in some instances this has reached an extraordinary degree, the entire goitre being transformed into a mass of lymph nodes with large exhausted germ-centres. In a number of our cases the clinical history has been that of a gradual or more rapidly developing induration of the goitre, an "iron-hard" or "wooden" consistency, leading to the suspicion of malignancy.

In some of these cases the histological picture has been identical with that of Riedel's struma.

Warthin thus implied not only an association between simple goitre and Thyroiditis but hinted at the aetiological significance of iodine in the genesis of the latter, a view which was to be subsequently reiterated by other workers in this field.

The second publication in this connection was that of Eason in 1928 who remarked:-

The cause, course, pathology and result of primary Graves' disease vary. We recognise, however, that many (those of mild and even average severity) run a course of several years, during approximately the first two or three of which the direct evidences of hyperthyroidism are most severe. In the subsequent years, in a considerable number of the cases, hyperthyroidism becomes less severe, while other possibly more disabling symptoms, begin to show themselves. It is therefore interesting to recall this sequence of events and to reconsider, in the light of gradually accumulating data, the relationship which these events may have to clinical hypothyroidism, myxoedema and chronic thyroiditis (Riedel's struma). In this class of case important omissions in the patient's history are by no means infrequent in the medical wards. The special reasons are the rapid condition of the patient's mentality, and possibly also the unincited mental attitude of the doctor who is gratified that his diagnosis of myxoedema or Riedel's struma is correct and that further, even meticulous, inquiry into the history of such cases does not promise the reward that fresh light on the aetiology will emerge. For such and other reasons there is a ring fence cutting off from our knowledge the later histories of many cases of exophthalmic goitre, and the earlier histories of many cases of myxoedema together with which in this connection Riedel's struma may be considered.

Eason made no attempt to distinguish between the work of Hashimoto and Riedel, but his observations are of interest in that they are among the earliest to draw

/ attention

attention to the theory, which has subsequently been repeated and elaborated by later writers, that Thyroiditis may represent what can be called the "burned-out" phase of an earlier thyrototoxic state.

Following Ewing's pronouncement in 1922 regarding the supposed identity of the Riedel and Hashimoto forms of Thyroiditis, the controversy remained in abeyance until the appearance in 1931 of the now classic paper of Graham. The latter forcibly expressed his views as follows:-

The writer, likewise, is of the opinion, based on a study of Hashimoto's four cases, four reported by Graham and McCullagh, and cases which I now believe can be identified in the literature, that Riedel's struma is not necessarily preceded by struma lymphomatosa; that struma lymphomatosa does not necessarily progress to Riedel's struma; and that it is highly improbable that there is any necessary relationship between these two conditions.

The basis of Graham's hypothesis, diametrically opposed to that of Ewing, was the collection and analysis of 104 reported cases of Thyroiditis from 82 original publications in the world literature up to that time. Of these he accepted 41 as examples of Riedel's and 24 as examples of Hashimoto's struma, the remainder forming a heterogeneous group in which he considered the material to have been improperly reported as instances of Thyroiditis or where there was insufficient data for positive opinion.

Graham then proceeded to analyse the Riedel and Hashimoto groups thus defined and his results are reproduced in Fig. 1. His findings, particularly in

/ respect

	Hashimoto (24)	Riedel (41)
Sex		
Male	4.2%	41.5%
Female	95.8%	58.5%
Average Age	52.4 Yrs.	36.2 Yrs.
Thyroid Involvement		
Unilateral	-	50%
Bilateral	100%	50%
Diffuse Cervical Cellulitis	-	78%
Post-operative Hypothyroidism	58%	19%

Fig. 1

Analysis of 65 reported cases of Thyroiditis
(After Graham).

respect of age and sex distribution and the degree of thyroid involvement, led Graham to conclude that the Hashimoto form could not possibly be the forerunner of the condition described by Riedel, as Ewing had earlier postulated.

Graham, unlike Ewing, paid little or no attention to histo-pathologic criteria in his assessment of the problem, believing that too great reliance upon the microscopical findings had resulted in more confusion than clarity.

He concluded:-

The group of cases generally classified as Riedel's disease, may be looked upon as having a local inflammatory process in the thyroid In these cases the general body economy is affected only secondarily by reason of destruction of the thyroid, interference with respiration and deglutition, and injuries to important blood vessels and nerves. Such a process has its counterpart in other organs and tissues, and may be expected to behave in a similar manner, except for the fact that the thyroid gland is so situated that complications can occur readily.

The changes which occur in the thyroid in the presence of the Hashimoto type of lesion may be considered primarily to be local manifestations of a constitutional disorder, the nature of which is as yet not understood.

Thus Graham, in his important contribution, laid the foundation of the argument, later to be elaborated by McClintock and Wright, and Joll, for regarding these two forms of Thyroiditis as separate, distinct and unrelated entities.

Between 1934 and 1942, three much-quoted publications appeared all purporting to define a relationship between thyrotoxicosis and Thyroiditis:-

(a) In 1934, Polowe reported the case of a woman, aged 26 years, whose presenting complaints were of profuse perspiration, constipation and inability to gain weight. Examination revealed slight enlargement of the right thyroid lobe, persistent tachycardia with elevation of the systolic and diastolic blood pressures, and a high basal metabolism. The diagnosis was "hyperthyroidism with hypertension". Subtotal thyroidectomy was carried out. The microscopy of the resected tissue showed "hypertrophic (toxic) struma", but the outstanding feature was the enormous lymphoid infiltration, including numerous lymph follicles with germinal centres. After operation the patient felt improved, gained weight and ceased to perspire profusely; there was, however, no improvement in basal metabolic rate, pulse rate or blood pressure readings.

Polowe concluded:-

As far as I can discover, this is the first case to be reported of struma lymphomatosa associated with hyperthyroidism. As such it furnishes an interesting link, perhaps the first stage in the pathogenesis of the obscure thyroid disease known as the struma lymphomatosa of Hasimoto or the lymphadenoid goitre of Williamson and Pearse. Thus, evidence is now at hand to show that clinically the reconstructed sequence of events may be: first, a phase of hyperthyroidism; second, a phase of apparently normal thyroid activity, and, third, a hypothyroid or myxoedematous phase

(b) In 1938, Vaux made a study of 38 cases of Lymphadenoid Goitre, dividing them on a histological basis, into three groups - early, intermediate and late. In 35 of these in which clinical details were available

the incidence of thyrotoxicosis appeared to decrease and that of hypothyroidism to increase, parallel with the transition from the early to the late stages.

Vaux concluded that the most reasonable interpretation of the condition was an involution of the thyroid following mild thyrotoxicosis.

(a) In 1942, Eden and Trotter reported a case which they considered to provide - "undeniable evidence of the association of lymphadenoid goitre with the full clinical picture of Graves' disease". This was a woman of 56 years of age whose complaint was of a swelling in the neck and general ill health for three months. The general appearance was characteristic of Graves' disease in an elderly subject with generalised muscular wasting, moderate enlargement of the thyroid, bilateral lid retraction and auricular fibrillation. In addition there was an early degree of pre-tibial myxoedema and a persistently elevated basal metabolic rate. Following thyroidectomy, a rapid recovery was observed, which included disappearance of the lid retraction and fibrillation, while the patient felt steadier and more composed. Four months after operation a degree of myxoedema became apparent.

Naked-eye examination of the gland revealed an opaque, white, fibrous structure with coarse lobulation and little islets of pink hyperplastic gland tissue bound up in the fibrosis. Microscopically there was well-marked lymphatic infiltration, both follicular and diffuse,

marked fibrosis, inter- and intralobular, and, wherever there was intact glandular tissue, well-marked epithelial hyperplasia.

On the basis of these findings, they made the following observations:-

It is clear that such a typical case of Graves' disease cannot be dismissed as a slight toxic reaction to the thyroiditis It is equally evident that the pathological picture cannot be classed as that of the common lymphatic type of toxic diffuse goitre, for the lymphatic infiltration, fibrosis, and destruction of thyroid tissue are fully as great as in classical examples of Hashimoto's thyroiditis.

The observations and conclusions of these authors (Polowe, Vaux, Eden and Trotter) may thus be regarded as a continuation and elaboration of the views originally expressed by Eason in 1928.

As had Warthin in 1926, so did Boyden, Collier and Bugher in 1935 and Dunhill in 1937 suggest the possible aetiological significance of iodine medication in the genesis of Thyroiditis. Boyden et al., in particular, reporting nine cases under the title Riedel's Struma, found the incidence of iodine ingestion quite striking in their material, and while prepared to admit that iodine might not be the sole aetiological factor, found themselves in agreement with Warthin when they remarked that

..... the peculiar pathological changes found in cases of Riedel's struma are largely the result of prolonged iodine ingestion in individuals of the Graves' constitution type.

In 1936, Professor de Quervain of Bern, in association with Giordanengo, published a paper which, like those of

/ Riedel

Riedel and Hashimoto, marked the recognition and description of a new form of Thyroiditis and which was subsequently to become associated with the name of de Quervain. As such this contribution is deserving of the closest study. de Quervain had in fact written upon this subject as early as 1904, so that its inclusion at this juncture is perhaps rather out of context, but it was only with the latter paper that the concept of a new disease entity was established and this would seem sufficient reason for the anachronism of its present description.

The basis of this work was a clinico-pathologic report of eight cases, of which two are reported here in detail as being representative of the group as a whole.

de Quervain and Giordanengo's
Publication - 1936

"Acute and Subacute Non-suppurative Thyroiditis"

Second Case. Mrs. R., Marguerite, born in 1891 in Biel where she is a housewife. She had never suffered from struma. At the end of December, 1935, she fell ill with an influenza-like illness with fever and catarrh of the upper respiratory passages. In addition to that severe pains developed in the anterior region of the neck which radiated towards the left ear and led to sleeplessness. At the same time a tender swelling which also extended somewhat to the left appeared directly over the sternum. The doctor was called in on the 22nd January, 1936, and found that the patient had a temperature of 37.3. He made the diagnosis of a suppurative strumitis and directed the patient to the Surgical Clinic in Bern as an emergency case. There she was observed from 23rd to 27th January, 1936. The evening temperatures fluctuated between 37.2 and 37.4, the morning temperatures between 36.4 and 37.3, and the pulse between 80 and 108. The sedimentation rate was 110/120 mm. Wassermann was negative. The urine was normal. Haemoglobin 85 per cent and white blood cells 10,320. In the jugular fossa, directly above the border of the sternum and rising above it by

4 cm. there was a solid swelling pertaining to the isthmus which rose when the patient swallowed and which could be followed up into the left lobe of the thyroid gland which was about 5.5 cm. high and firmly thickened. The right lobe of the thyroid was likewise more solid than is normal, 5 cm. high and scarcely tender on pressure. Nothing to report about the heart and lungs, nor about the abdomen and the rest of the body status. She is fragilely built and rather pale. The pupillary reaction was normal. There were no manifestations of sympathetic involvement. - Diagnosis: Subacute non-suppurative Thyroiditis. As the condition had dragged on for four weeks, the patient was very anxious to have operative treatment.

Operation was performed on 28th January, 1936 (de Quervain): the isthmus measured 3 cm. from top to bottom and had changed with the lower horn of the left lobe of the thyroid into a firm whitish mass measuring 4 cm. which could be freed without difficulty. The 6 cm. high left lobe which was 2.5 cm. broad at isthmus level showed the same change. The firmness of the thyroid gland reminds one of Riedel's struma. It was confined exclusively to the thyroid tissue from which the muscles could be separated without any special difficulty. The right lobe was not obviously changed, was normal in size and did not show nodular formations anywhere. A wedge of tissue 4 cm. in length and 7 mm. at the base was cut out of the isthmus and the left lobe without ligation of the larger vessels and the muscles were closed over this. The volume of the tissue excised for biopsy was approximately 2.5- 3 c.cm. A small strip of gauze was used for drainage. This was removed after 24 hours. The wound healed by first intention. The patient left on 5th February, 1936.

The histological examination of the preparation by Professor Wegelin yielded the following findings:

The piece of tissue consisted of granular tissue with epithelioid cells, lymphocytes, isolated plasma cells and many foreign-body giant cells, here and there containing colloid. Glandular lobules were for the most part destroyed. Here and there, some still preserved polymorphous vesicles, varying in size from small to medium, with flat epithelium and with sparse to moderately dense eosinophil colloid, now and then with basophilic accumulations. The connective tissue was partly rich in cells, partly poor in cells.

Diagnosis: Chronic thyroiditis with foreign-body giant cells.

/ During

During the operation material was taken for bacteriological examination. The cultures remained sterile. Animal inoculations: negative result.

Further progress: the follow up examination on 11th May, 1936, showed an operation scar free from complications, a thyroid gland which was just palpable and of normal consistency. The very solid part of the left lobe and of the isthmus which was not removed at the operation has once more taken on normal consistency and normal dimensions. The right lobe, too, which was not touched at the operation feels normal. The patient did not feel troublesome complaints in the neck region any longer, but on the other hand she complained of general depression and of pains in the lower extremities which were not rooted in any objective finding.

Blood findings: Haemoglobin 100 per cent; R.B.C. 3,760,000; W.B.C. 8,000; Polynuclear neutrophils 57 per cent; Lymphocytes 40 per cent; Large mononuclears 3 per cent; E.S.R. 35/58; Calcium 11.6 mgm. per cent.

The urine was normal. Basal metabolic rate -5 per cent, on 2nd June -12 per cent, on 4th July -15 per cent despite administration of $\frac{1}{2}$ -2 tablets of thyroxin a day and on 4th August it was still -5 per cent. The patient still had complaints of a nervous nature. There were no objective signs of hypothyroidism.

Fourth Case. A. Fritz, 39 years old, was placed at our disposal by Dr. A. Lüthi, hospital surgeon in Thun.

Family history: his mother and brothers and sisters had struma. His mother died of tuberculosis and two siblings aged 10 died of meningitis. In 1926 the patient was under treatment for two months because of suspected tuberculosis of the lungs (there was no examination of the sputum).

At the end of December, 1935, the patient developed pains in the neck and the ears, and headaches, a feeling of giddiness and perspiring at night. In the neck in the neighbourhood of the thyroid gland was a swelling which was increasing in size. Struma maligna was suspected.

The patient was admitted to hospital on 20th January, 1936, with a temperature of 37.1 and a pulse rate of 96-112. E.S.R. was 46/103 mm. In the neck were two very firm nodes in the thyroid

/ gland

gland which were not outwardly visible and which rose up when the patient swallowed. He alleged that they were sensitive to pressure. The right node: 5.5 x 3.5 x 3.5 cm., the left: 3.5 x 3 cm. was located somewhat deeper. There were no disturbances of the sympathetic. The vocal cords moved well.

Lung condition: prolonged expiration over the apices and on the right some ronchi.

On 21st January, 1936, the very solid, thickened tissue was removed which according to personal information from Dr. Mithi already showed itself on macroscopic section not as a node, but as inflammatorily altered thyroid tissue. On the left, resection of the upper pole was carried out. The wound was closed.

There was a rise in temperature to 39.2 on the fifth day and then a normal falling off in temperature with a pulse rate which remained rather high. The patient was discharged on 4th February, 1936.

Histological Report (Professor Wegelin): there were lobules of the thyroid gland mostly reduced in size which consisted of large, medium-sized and small vesicles. The epithelium varied from cubical to flat. Colloid was moderately abundant, eosinophilic or basophilic. The interlobular septa were mostly greatly thickened - connective tissue with extensive infiltration by lymphocytes, plasma cells, epithelioid cells and leucocytes, forming in places granulation tissue which penetrated into the lobules and destroyed the follicles, often forming foreign-body giant cells around about the colloid accumulations. Here and there, especially in the large vesicles there was very great desquamation of epithelium and fatty degeneration of the desquamated cells, and in places, of the rest of the epithelial cells also. In places the proliferation of connective tissue in the interstitial septa was so great that the lobules were pushed wide apart. In isolated atrophic lobules there were only sparse small vesicles and very greatly increased connective tissue. Arteries appeared to some extent with thickened walls and calcification of the elastic lamina. There was, besides, some nodular tissue with a preponderance of medium-sized vesicles surrounded by a thick capsule with infiltrates similar to those found in the interlobular septa. Here, too, the granulation tissue infiltrated between the follicles.

Diagnosis: thyroiditis chronica (Riedel's iron-hard struma).

/ Description

Description of Pathological Changes - In the group as a whole the following pathological picture emerged:-

Upon macroscopic examination,, the inflammatory tissue is conspicuous by its solidity. This can, as for example in three of our cases, go almost as solid as cartilage, and leads on then to the idea of the 'iron-hard struma of Riedel'.

In examining the sections only a part of the thyroid is seen to be affected by the inflammation and we see that even in greatly changed areas, isolated lobules or groups of vesicles are still preserved and even display a normal picture. One can in a single field of vision often survey all stages of inflammation, from simple proliferation and desquamation of the epithelial cells to complete replacement of the contents of the vesicles by inflammatory granulation tissue and to a connective tissue organisation of the inflammatory focus.

In summarising we said, that the parenchymatous inflammation was characterised by:

- (a) increase, shedding and degeneration of the epithelial cells;
- (b) change in and disappearance of the colloid;
- (c) penetration of multinuclear leucocytes, small round cells and larger cellular elements (wandering connective tissue cells?) into the vesicles and formation of foreign-body giant cells around colloid accumulations which have not been reabsorbed;
- (d) appearance of a connective tissue organisation.

The increase of cells in the interstitial tissue is based in part on lymphocytic infiltration which, by way of exception, takes on the appearance of a lymph follicle. Rarely do neutrophilic or basophilic leucocytes predominate. The connective tissue itself shows an increase in nuclei - partly young, oval nuclei, partly older, elongated nuclei. In parts it is very rich in nuclei like young connective tissue, in parts oedematously loosened and in other places already markedly scarred, relatively poor in cells and at times appearing hyaline. In the vesicles which are least changed, one sees in

a circumscribed place an incipient proliferation of the epithelium of the thyroid gland, associated with the formation of vacuoles in the colloid. The epithelium frequently shows fatty degeneration and the nuclei show symptoms of degeneration. In vesicles that are rather more severely changed appear cells of the lymph cell type, less numerous polymorphonuclear leucocytes and in addition connective tissue cells In many vesicles appear peripheral giant cells At times the nuclei are distributed more or less irregularly over the cell or are accumulated in the interior of it. More frequently they lie at the periphery of the cell in the form of a wreath In spite of this wreath-shaped arrangement of the nuclei, one does not get the impression, on looking more closely, that these are tubercle giant cells before one, and Langhans himself, the father of the tubercle giant cells, would not accept such an interpretation in our first case (1904) and, like us, interpreted the giant cells as foreign-body giant cells. Often a proper wreath of giant cells encloses a colloid accumulation or a single cell embraces such an accumulation with its processes. At times colloid accumulations are also found settled in an isolated giant cell. They then distinguish themselves clearly from the finely grained protoplasm of the giant cell by their homogeneous appearance.

In the more greatly changed vesicles the epithelial lining has disappeared, and the vesicle is entirely filled up with a cellular material of varied origin, which is to be described as inflammatory granulation tissue. Finally the boundaries of the vesicles disappear and the vesicle becomes merged in the general inflammatory change of the interstitial tissue.

The differences between the individual cases are essentially related to the more or less high degree of connective tissue change, the frequency of the giant cells and the number of polymuclear leucocytes. Suppurative liquation could not be demonstrated in any of the cases.

The following additional excerpts from this lengthy, complicated but nevertheless fundamental paper, help to crystallise the concept of what has since become known as Subacute, de Quervain's, Giant-cell or Pseudo-Tuberculous Thyroiditis.

/ Thus

Thus:

And so there is, in fact, an inflammation of the thyroid gland and what is more, this inflammation already shows anatomico-pathologically a certain gradation of changes ranging from those of an acute character to those of a chronic process which with the predominance of taut connective tissue reminds one of Riedel's struma.

We gain a rough conception of the relative frequency of the individual forms of inflammation, only on the strength of clinical statistics and even these are partly misleading, because they contain only the more severe cases. This is particularly true of pure thyroiditis which in its mild form remains in the hands of the family doctor and does not come to be closely observed clinically.

The possibility, which has been known for a long time now, indeed the frequency of spontaneous healing, is borne out in full measure by the observations made known since 1904. We can even say that spontaneous healing is the rule

Numerically the most important cause is provided by the inflammatory illnesses of the upper respiratory passages. The patient in such cases mentions influenza or grip, sore throat or acute pharyngitis.

Important, although not decisive for the diagnosis, is that an acute infectious illness, even if it is at times a very slight attack, appears first. The thyroiditis does appear exceptionally even in the course of this, but mostly only after some days or even weeks, at times almost without any fever, in other cases with high fever and even rigors. At the same time there appears in the neighbourhood of the lobe of the thyroid gland a solid swelling, sensitive to pressure, which may be accompanied by an inflammatory infiltration of the adjacent area.

As subjective symptoms are found, above all, pains radiating out towards the ear, the temples, the occiput, the shoulder and even away towards the arm.

..... As a rule, all these manifestations die away in the course of a few days or weeks under the influence of a mild temporizing, pain-deadening treatment, and the gland returns to its normal state,

/ even

even after a circumscribed, solid, horny infiltrate could be felt in it perhaps for several weeks further. In other cases this solid inflammatory connective tissue becomes so solid that a transition to Riedel's thyroiditis can be considered.

Characteristic of thyroiditis are subsequent outbreaks of inflammation in the same lobe and the transition of this, after some days or even weeks, to the other lobe or to the processus pyramidalis. We (de Quervain) have seen the illness shift to another portion of the thyroid gland three times out of seven cases which we personally observed.

The differential diagnosis must take syphilis and tuberculosis into account and also consider a haemorrhage in a goitrous node which so far had not been diagnosed. The differential diagnosis is most difficult in the face of struma maligna. In the acute, feverish onset of thyroiditis the question does not arise, but it certainly does when the illness, after an initial stage which passed off mildly, has proceeded to a chronic phase. The acute initial manifestations have perhaps been ascribed then to an incidental influenzal illness, and the doctor has before him only the solid swelling of the thyroid gland which is not very mobile and with the pains radiating out towards the ear, the nape of the neck and the shoulder, that are so characteristic of cancer.

.... Only by way of exception do we find particulars about the white blood cell picture. They are too few and too ambiguous to allow any conclusions. Until now there is almost no information about the erythrocyte sedimentation rate. In our Case 2 it was unusually high (110/120), while the number of white blood cells amounted only to 10,320.

The treatment will be an aetiological one, if one can infer the nature of the stimulant of inflammation from the primary illness. In the remaining cases, no matter whether their aetiology is known or not, one will alleviate the pains by antipyretics or antineuralgics External applications can be of use and pleasant for the patients; cold compresses in the initial stage, warm in the advanced stage, anti-phlogistine, short-wave diathermy, etc.,

The favourable practical results which are obtained in the treatment of inflammatory processes with small X-ray doses, seem to encourage us to try this treatment in thyroiditis also.

/ Operative

Operative intervention will not generally be indicated. In our statistics it was undertaken either because the reabsorption of the thyroid infiltrate proceeds slowly, in which case a malignant tumour cannot be positively excluded, or because of the sometimes persistent subjective complaints in protracted cases. One will surely deal gently with the thyroid tissue on the strength of the knowledge now gained

If one operates on account of complaints it will probably be sufficient to cut out a thin wedge out of the affected part of the thyroid gland. There is a chance that such a relieving operation will have a favourable influence on the pains and the healing process will be speeded up.

What speaks for fibrous thyroiditis and against struma maligna even at an exploratory operation, is the striking hardness of the whitish thyroid tissue which positively crunches under the knife. The hardness of the tissue is much more striking than we have ever found in the most solid scirrhous.

Prognosis - In our collective statistics myxoedema is mentioned only twice.

de Quervain enters into a lengthy discussion concerning the relationships between the Subacute Thyroiditis which he describes and Hashimoto's and Riedel's forms of Thyroiditis. The following pertinent remarks have been extracted from his analysis of the problem:-

Important for prognosis and therapy is the evidence that thyroiditis lymphomatosa represents clinically, histologically and prognostically an illness entirely different from ordinary thyroiditis.

More difficult to pronounce judgment upon are the relations between subacute thyroiditis, as we have described it in this work, to 'Riedel'.

A. Reist who discussed this question in great detail in 1922 on the strength of Wegelin's material and the observations available up to that time comes to the correct conclusion that probably very varying processes have been described under the designation

/ 'Riedel's

'Riedel's disease' and that the clinical picture alone ought not to be the determining factor.

This group of cases (Subacute Thyroiditis) is held together by a histological picture of the same kind in which the formation of foreign-body giant cells in the vesicles presents the most striking factor.

The observations at the operation show that at times the afflicted tissue is as firm as in Riedel's illness and that it crunches under the knife as in Riedel's illness.

The adhesion of the affected lobe with the surrounding tissue is, to be sure, as we have observed ourselves, a comparatively pronounced one, but the gland is not adhered into a solid mass with the neighbouring tissues to the same degree as is depicted in most descriptions of 'Riedel'.

The present state of our knowledge can be summarised roughly in the following way:

If one wants to designate every occurrence in the thyroid gland of a taut connective tissue which is as solid as cartilage as Riedel's illness, then one can say that individual cases of simple subacute or chronic thyroiditis with giant cells lead to 'Riedel'. If one takes into account the whole clinical picture of both illnesses together with their histological characteristics, one will then interpret thyroiditis connected with formation of foreign-body giant cells, for the present, as a disease picture on its own.

Thyroiditis associated with the formation of giant cells can lead in the subacute and chronic phase to a solid growth of connective tissue which reminds one of Riedel's thyroiditis. The clinical course of both illnesses is, however, a different one in typical cases. It will be a question for the future to ascertain whether a particular histological type corresponds to the clinical notion of Riedel's illness, or whether this conception is to be used simply as a collective term for the solid, fibrous degeneration in illnesses of the thyroid family varying in origin and histological character.

Reference has already been made to the important contribution by Graham in 1931, in which, on clinical grounds and by analysing reported cases up to that time,

he clearly distinguished as separate, unrelated entities the Riedel and Hashimoto strumas. In 1937, two further authors, McClintock and Wright, in a continuation study of the same nature, reached similar conclusions to those of Graham. They reviewed the literature from 1930 and added the cases thus collected and analysed to Graham's figures. In this way they were able to base their conclusions on a study of 60 cases of Riedel's and 50 cases of Hashimoto's, disease. (Fig. 2).

Furthermore they drew attention to what they considered to be significant differential features in the pathology of the two conditions. Thus:-

Grossly the gland in Riedel's struma is very firm, usually stony hard, with extreme diffuse fibrosis. There is loss of lobulations and the incised surfaces of the gland show little evidence of the typical colloid-containing acini which characterize the normal structure.

In the case of struma lymphomatosa, on the other hand, the tissues are firm but not hard, smoothly lobulated, and are not markedly fibrosed. The normal lobular character of the gland is still present although on section there is found definite diminution or almost complete absence of colloid material.

Histologically, too, the glands of the two diseases differ from each other. Riedel's struma is characterized by marked diffuse sclerosis of the affected portions of the gland, with varying numbers of persisting acini. The cells of these persistent glands are not remarkable. In general they resemble those which form the normal acini. Accumulations of lymphocytes, and occasionally of other leukocytes, are often found, but these accumulations are focal in distribution and appear to be definitely of inflammatory nature. Lymph nodules are not often found.

In contrast, struma lymphomatosa, while it shows some evidence of fibrosis, is characterized chiefly

	Hashimoto (50)	Riedel (60)
Sex		
Male	1.4%	18.2%
Female	98.6%	81.8%
Average Age	49.2 Yrs.	40.3 Yrs.
Thyroid Involvement		
Unilateral	-	30.5%
Bilateral	100%	69.5%
Post-operative Hypothyroidism	78.8%	27%

Fig. 2

Analysis of 110 reported cases of Thyroiditis
(After McClintock and Wright).

by marked, often extreme, lymphoid infiltration of the gland. This infiltration is often associated with a peculiar, but quite typical atrophy of the neighbouring acini The cells which form many of these atrophic acini are large, parenchymatous, acidophilic, with more cytoplasm than normal and small hyperchromatic nuclei. They appear degenerated rather than normal. Colloid is diminished in amount and is often absent. Large hyperplastic lymph nodules are commonly present.

McClintock and Wright invoked yet a further argument in support of their views. Although not the first to do so, they reported a case of Hashimoto's struma operated upon at two different periods, the second time after an interval of two years. In this case, the clinical features and histologic changes at the second admission were practically identical with those found originally. They remarked:-

If struma lymphomatosa were the precursor of Riedel's struma, sufficient time had certainly elapsed in this case for the changes to have become evident

Thus their observations, clinical and pathological, were in line with those of Graham and lent added conviction to the hypothesis originally expressed by the latter concerning the lack of relationship between these two forms of Thyroiditis.

In 1938, Renton, Charteris and Heggie published the first paper to focus attention on the value of radiotherapy in the treatment of Thyroiditis. Under the title of Riedel's Thyroiditis and subscribing to the views of Ewing concerning the unitarian concept of Riedel's and Hashimoto's strumas, they described the treatment of five / cases

cases employing a radium collar and giving skin dosages varying between 1,800 and 4,000 r. In all they observed disappearance of the thyroid enlargement and symptomatic improvement. There was no tendency to recurrence, the cases having been followed for from two to five years, and no case showed signs of thyroid deficiency following such treatment.

Impressed by such results they regarded the use of radium as safe, simple and preferable to surgical treatment.

The year 1939 saw the appearance of Joll's classical paper. Of all writers on the subject, Joll waxed most vehement in support of the argument for regarding Hashimoto's and Riedel's diseases as distinct and separate entities, basing his conclusions on a clinico-pathologic study of 81 cases of the former and five cases of the latter condition. Pursuing and elaborating this hypothesis, which had originally been formulated by Graham (1931) and subsequently expanded by McClintock and Wright (1937), Joll summarised the differential diagnosis between the two conditions as shown in Figs. 3 and 4.

In addition to so differentiating between the two conditions, Joll gave a full clinico-pathological description of Struma Lymphomatosa and discussed its diagnosis, treatment and prognosis, and it is probably true to say that his work finally convinced the majority of surgical opinion that the Hashimoto and Riedel forms

		HASHIMOTO'S STRUMA (81 CASES)	RIEDEL'S STRUMA (5 CASES)
SEX	MALE FEMALE	3.7% 96.3%	20% 80%
AVERAGE AGE		57.6 YRS.	44.4 YRS.
AVERAGE DURATION OF SYMPTOMS		1.7 YRS.	6.1 MTHS.
AVERAGE DURATION OF GOITRE		4.2 YRS.	1.9 YRS.
THYROID INVOLVEMENT	UNILATERAL BILATERAL	100% -	80% 20%
PRE-OPERATIVE FUNCTION	THYROTOXIC HYPOTHYROID	- 35.2%	- -
OPERATIVE FINDINGS	DIFFUSE EXTRA- THYROID INVOLVE- MENT	-	100%
POST-OPERATIVE FUNCTION	HYPOTHYROID	64.8%	20%

FIG. 3

SUMMARY OF DATA RELATING TO HASHIMOTO'S DISEASE AND RIEDEL'S STRUMA. (AFTER JOLL).

	HASHIMOTO'S STRUMA	RIEDEL'S DISEASE
1.	PREPONDERRATES IN WOMEN FROM 45 TO 60 YEARS OF AGE.	OCCURS IN YOUNGER MEN AND WOMEN THAN DOES STRUMA LYMPHOMATOSA.
2.	THERE IS A TENDENCY TO MYXOEDEMA.	THERE IS LITTLE TENDENCY TO MYXOEDEMA EXCEPT AFTER RADICAL OPERATIONS.
3.	ALL PARTS OF THE THYROID GLAND ARE INVOLVED, BUT NOTHING OUTSIDE IT. THE GOITRE IS SOMETIMES LARGE BUT NEVER WOODY HARD.	THE DISEASE IS USUALLY UNILATERAL WITH EXTENSION TO EXTRATHYROID STRUCTURES. THE GOITRE IS SMALL, INTENSELY HARD AND SMOOTH.
4.	PRESSURE EFFECTS ARE SELDOM SEVERE.	GRAVE PRESSURE EFFECTS ARE THE RULE.
5.	THE HISTOLOGICAL STRUCTURE, WHICH VARIES WITH THE STAGE OF THE DISEASE, IS CHARACTERISTIC.	THE MASS IS FORMED OF DENSE SCAR TISSUE.

FIG. 4

DIFFERENTIAL DIAGNOSIS BETWEEN HASHIMOTO'S STRUMA AND RIEDEL'S DISEASE. (AFTER JOLL).

of Thyroiditis should be regarded as separate and unrelated diseases. At the same time, Jell was one of the first writers to recognise and acknowledge the existence of the giant cell type of Thyroiditis as described by de Quervain and Giordanengo.

In 1943, De Courcy advanced the theory that Riedel's Thyroiditis was the result of a previous perithyroiditis which caused a partial constriction of the vessels entering the thyroid gland. In his own words:-

My own observations on a series of cases, including the one here reported in detail, have convinced me of the aetiologic relationship between perithyroiditis and woody thyroiditis. I believe that, as a result of the perithyroiditis, the fibrous growth characteristic of the disease begins outside rather than within the thyroid gland. Histologic evidence indicates that, as a sequel to perithyroiditis and its complications, there results partial occlusion of the blood vessels entering the gland with subsequent formation of the fibrous tissue characteristic of Riedel's struma. In other words, because of the perithyroiditis it appears to me that Riedel's struma is a vascular rather than a glandular disease.

Schilling, in 1945, regarded Chronic Non-specific Thyroiditis as embracing Struma Lymphomatosa (Hashimoto), Struma Fibrosa (Riedel), and the pseudogiant cell type or Struma Granulomatosa (de Quervain). He further envisaged Struma Lymphomatosa as a clinico-pathologic entity. The pseudogiant cell type of de Quervain, he regarded as a variant of Riedel's Thyroiditis and looked upon both as different manifestations of the thyroid's response to inflammation.

Schilling's conclusions were as follows:-

/Struma

Struma lymphomatosa is considered a distinct clinico-pathologic entity. Its aetiology is unknown, though it is considered a degenerative disease in contradistinction to a neoplastic or inflammatory disease. The excessive demands on the thyroid during the sexual life of the female are considered fundamental in the aetiology of this disease. These excessive demands may be mediated through the hypophysis.

Struma fibrosa and its giant cell variant are considered two late manifestations of the thyroid from an acute to chronic inflammatory process. The fibrosis of the gland is considered first a replacement phenomenon of damaged glandular tissue.

The pseudogiant cells are merely evidence of the more acute nature of the inflammatory process which may regress or more rarely progress to a diffuse infiltrating fibrosis.

Emphasis is placed on the protean manifestations of the thyroid gland to inflammations resulting from bacteria, systemic disease, and poisons. The role of a virus as an inflammatory agent is yet undetermined.

Treatment of struma lymphomatosa by radiotherapy is the method of choice after a preliminary biopsy.

Surgery of struma fibrosa should be as conservative as possible. Radiotherapy may be effective in the earlier, more acute, giant cell variant of struma fibrosa.

In 1945, King and Rosellini reported the treatment of seven cases of acute thyroiditis and three cases of migratory thyroiditis using thiouracil. Although they used such a nomenclature, there can be little doubt that the disease they described was identical with de Quervain's or Subacute Thyroiditis and their reference to its treatment by an anti-thyroid drug is the earliest in the literature. A satisfactory response, as judged by relief of symptoms and disappearance of the glandular enlargement, was observed in eight of the cases and they

/ regarded



regarded thiouracil as a specific treatment for the disease.

Since the first description of Struma Lymphomatosa by Hashimoto in 1912, practically all the subsequent writings on the pathology of the condition emphasised, as the principal histo-pathological feature, the lymphoid accumulations within the gland and relatively little attention was paid to the alterations in the thyroid epithelium, other than to suggest varying degrees of a non-specific and secondary degeneration of the latter.

In 1946, however, Parnley and Hellwig found:-

..... alterations of the thyroid epithelium which have not been correctly interpreted in recent studies, and we believe that these epithelial changes, rather than the more conspicuous accumulations of lymphoid tissue, are the most important characteristics of this disease.

In our opinion, the accumulation of lymphoid tissue is a secondary phenomenon and represents a response of lymphocytes to an abnormal function and proliferation of thyroid epithelium.

..... More striking was another type of thyroid epithelium, which was present in every case of our series, namely pale large polygonal cells which resembled hepatic or adrenal cells much more than thyroid epithelium. These unusual cells were arranged either in acini with small lumens or in solid cell strands surrounded with lymphoid tissue. The size of these pale cells varied between 20 to 30 microns, their vacuolated cytoplasm took an intense stain with eosin and the nuclei were of varying size; often eccentric, they had a fine chromatin network and occasionally one or two small nucleoli.

The pale eosinophilic cells with abundant cytoplasm, so characteristic of lymphadenoid goitre, are without doubt identical with the "protoplasm rich" cells of Hürthle.

..... the Hürthle cell is a physiologic-pathologic variant of the thyroid cell and arises

/ from

from normal thyroid epithelium because of metabolic or nutritional disturbances.

The hyperplastic pale cells found in every lymphadenoid goitre of our series represent an attempt to compensate for the exhaustion of thyroid hormone.

These observations of Parnley and Hellwig were among the first to focus attention specifically upon the distinctive nature of the thyroid epithelial change in this condition and to suggest that this and not the more conspicuous lymphoid accumulation, might represent the primary and fundamental alteration.

Two years later, in 1948, Lennox described a similar cell type as being predominant in six cases of Hashimoto's disease which he examined. He preferred the term "Askanazy cells" to identifying them, as Parnley and Hellwig had done, with the Hürthle cell, remarking:-

Askanazy was the first to note them in toxic thyroids On the one hand Hürthle merely redescribed the parafollicular cells of puppy thyroids which, as he himself acknowledges, had already been demonstrated to the Royal Society by Baber in 1876 and more fully in 1881, and on the other hand the relation of the parafollicular cells to those now under discussion is very doubtful. Nonidez and Zechel and Raymond have made detailed studies of these cells in dogs, cats and rabbits, but a survey of recent descriptions of the human thyroid, orthodox and unorthodox, shows little evidence of support among histologists for the occurrence of any similar structure in the normal human gland. It seems most significant that parafollicular cells are frequent, in those animals in which they occur, only in the first few weeks of life, whereas the cells with which we are here concerned occur chiefly at the opposite end of life.

In addition to his description of such Askanazy cells as a feature of Hashimoto's disease, Lennox drew attention

to their occurrence in the normal thyroid and in a variety of other thyroid conditions such as Graves' disease, toxic adenoma, non-toxic goitre, etc. He failed to demonstrate their presence in four cases of Riedel's struma. For the most part he observed a close association between such Askanazy change and significant lymphocytic infiltration and lymphoid hyperplasia in the adjacent tissue.

Regarding the physiological significance of the Askanazy-cell change, he concluded that it must represent a regressive phenomenon affecting the thyroid epithelium.

Although these authors, (Parnley and Hellwig; Lennox), preferred a different nomenclature (Hirshle; Askanazy) for the cell type they described, the importance of their work lies in the fact that, for the first time, attention was focused in Hashimoto's disease upon the epithelial rather than the lymphoid changes.

Despite the searching investigations and dogmatic opinions of Graham (1931), McClintock and Wright (1937) and Joll (1939) - all of which had favoured the view that the Hashimoto and Riedel forms of Thyroiditis should be regarded as separate and unrelated entities - there were, even as late as 1948, certain authors who did not subscribe to these views. As examples may be quoted two cases recorded in that year by Means and one by Merrington, all three of which purported to demonstrate features of both these types of Thyroiditis. The latter author expressed himself thus:-

/ from

..... from a study of recorded cases it is clear that there is a single broad clinical picture common to both, and attempts to draw a line between them have not been convincing. Even when the diagnosis is supported by pathological findings, it seems likely that there are a considerable number of cases of an intermediate type. These considerations, together with the findings in the case presented here indicate that the two forms of chronic thyroiditis are related. It would seem reasonable, therefore, to describe both types simply as 'chronic thyroiditis', and to qualify only extreme cases by the terms fibrous or lymphoid.

Of all writers on the subject of Thyroiditis in the past decade none has been more prolific than George Crile, Jr., of the Cleveland Clinic. A series of publications appearing between 1948 and 1952 reflects his observations and conclusions concerning the triad of Subacute Thyroiditis, Struma Lymphomatosa and Riedel's Struma, all of which he regards as separate and unrelated entities. The following excerpts from his works summarise Crile's views:-

Subacute thyroiditis is a relatively common clinico-pathologic entity distinct from struma lymphomatosa and Riedel's struma. Although it produces characteristic local and systemic symptoms, the diagnosis is often missed by those not familiar with the disease.

The disease may manifest itself in an acute form with fever, malaise and severe local pain and tenderness or may exist in a chronic form in which the local and systemic symptoms are minimal and the diagnosis is not clear.

The acute form may be confused with pharyngitis, otitis, dental infection, influenza or fever of unknown origin. The chronic form may simulate globus hystericus, adenoma of the thyroid, carcinoma of the thyroid, hyperthyroidism or chronic nervous exhaustion.

The diagnosis depends on the observation of a firm, usually symmetric enlargement of the thyroid

/ which

which is frequently tender and is associated with a high sedimentation rate and low uptake of radioactive iodine. In doubtful cases satisfactory biopsy specimens of the thyroid can be obtained in the office by use of the Vim-Silverman liver-biopsy needle.

The response of 38 patients treated by roentgen therapy in average doses of 600 to 800 r was dramatically prompt and complete. Thyroidectomy is not necessary.

Concerning Struma Lymphomatosa, Grile advocated a conservative management employing either large doses of desiccated thyroid or X-ray therapy to both of which he found the condition responsive. He further described a condition of "Lymphoid Thyroiditis" regarding which he remarked as follows:-

Lymphoid thyroiditis may be an early phase of struma lymphomatosa or it may be an entirely different entity. It shows the same lymphocytic infiltration and the presence of germinal follicles as does struma lymphomatosa, but fibrosis is minimal or absent and the oxyphilic epithelium is not seen. These patients, like those with struma lymphomatosa, tend to have low basal metabolic rates and clinical evidence of mild hypothyroidism. The disease occurs predominantly in females, is common in the age group from 20 to 40, and frequently develops following childbirth. The only symptom is a progressive diffuse enlargement of the thyroid, which may become three or four times its normal size, may cause mild pressure symptoms or feelings of discomfort, and may become quite conspicuous.

Lymphoid thyroiditis responds promptly and dramatically to treatment with large doses of desiccated thyroid. The cause of lymphoid thyroiditis and struma lymphomatosa is unknown, but since they are benefited so strikingly by the administration of large doses of desiccated thyroid it is possible that they represent an exhaustion response of the thyroid, and that the changes are reversible by putting the thyroid entirely at rest. This treatment is much more physiologic than thyroidectomy, and many needless operations can be saved.

As in Subacute Thyroiditis, so in Struma Lymphomatosa,

/ Grile

Crile recommended that the diagnosis be confirmed by biopsy with the Silverman needle.

Concerning Riedel's struma, Crile made one important observation. In seven of his eleven cases, he found adenomas or remnants of degenerating adenomas in the centre of the proliferating fibrous tissue. He goes on to suggest:-

On the other hand, if one remembers the fact that in most cases, at the centre of the fibrosed lobe, there is a degenerating adenoma and that around this adenoma the fibrous tissue is deposited in concentric laminations which afford natural cleavage planes, it is often possible, without jeopardizing the vital structures adherent to the capsule of the thyroid, to split the lobe open and emucleate this central core. The results following this simple procedure have been excellent in the three cases in which I have found it practicable. Pressure symptoms have been relieved, the bulk of the tumour has been strikingly diminished, and the progress of the inflammatory and productive process appears to be arrested.

He further suggested the possibility of some change in the adenoma setting off a fibrous reaction resembling that seen in a keloid.

In illustration of the increasingly large series of cases of Thyroiditis reported in recent times, particularly from America and especially in respect of Subacute Thyroiditis, may be quoted the figures from the following two publications in 1949 and 1954 respectively. Thus:-

In 1949, Osmond and Portmann reported on 143 examples of Thyroiditis, taken from a total of 7,045 cases of thyroid disease seen at the Cleveland Clinic between 1936 and 1947. Of these, no less than 93 were regarded as

/ Subacute

Subacute Thyroiditis, while there were 16 examples of Struma Lymphomatosa and eleven of Riedel's Thyroiditis.

In 1954, Lindsay and Dailey reviewing 7,263 thyroidectomies at the University of California Hospital performed between 1920 and 1952, found 23 patients with Subacute Thyroiditis, 220 patients with Hashimoto's disease and two with Riedel's Thyroiditis.

In 1953 a number of papers appeared reporting on the beneficial effects of cortisone in the treatment of Subacute Thyroiditis, of which that of Glark, Nelsen and Raiman may be taken as illustrative. These authors treated three cases of the disease with a single daily dose of 25 mgm. for a total of 12 to 14 days. They observed marked relief of local and systemic symptoms in the first 24 hours, complete disappearance of pain and tenderness in from four to seven days and decrease in size with softening of the gland within the first week. In all three the gland had returned to normal size and consistency within two months. They noted no recurrences.

No summary of the historical evolution of Thyroiditis would be complete without reference to the views enunciated by Levitt and presented in his book - "The Thyroid" - published in 1954. Levitt expressed himself thus:-

I shall seek to substantiate the hypothesis that abnormalities of the thyroid gland are not isolated diseases, but are phases in an evolving continuum. For practical purposes I shall cite six distinct stages, which I have named according to their histological characteristics.

Commenting on the status of Lymphadenoid Goitre,
Hashimoto's and Riedel's Diseases:-

We are left with these final facts. Riedel described three patients showing two different conditions: first, that of Riedel's fibrosis which is, I believe, the terminal phase of a degenerating toxic epithelial hyperplasia, and the second and third, that of Riedel's chronic thyroiditis, which appears related to the condition of subacute thyroiditis.

Hashimoto similarly described four patients, the second and third of whom demonstrated the typical fibro-lymphoid hyperplasia of Hashimoto. The first was suffering from a phase preceding fibro-lymphoid hyperplasia, that is, diffuse lymphoid hyperplasia. The fourth patient showed, in fact, a condition of Riedel's fibrosis, a more advanced stage of the fibro-lymphoid hyperplasia of Hashimoto.

I would therefore suggest that the terms Hashimoto's and Riedel's diseases be dispensed with altogether. Both eponymous terms, hallowed though they be by the passage of time, are nondescript. The designation of "lymphadenoid goitre" is likewise ambiguous.

In their stead, I would suggest "diffuse lymphoid hyperplasia", "fibro-lymphoid hyperplasia" and "fibrosis", which, while fulfilling the microscopical and macroscopical desiderata, complete the clinical picture. They fit into the jig-saw puzzle of thyroid disease as the three terminal phases of the six stages of the degenerating toxic thyroid gland:-

- (1) Epithelial hyperplasia.
- (2) Lympho-epithelial hyperplasia.
- (3) Focal lymphoid hyperplasia.
- (4) Diffuse lymphoid hyperplasia.
- (5) Fibro-lymphoid hyperplasia.
- (6) Fibrosis.

Levitt may thus be regarded as the modern champion of the hypothesis originally formulated by Eason in 1928 and to which reference has already been made - the desire to integrate "Thyroiditis" into the clinico-pathological life

/ history

history of the thyrotoxic state rather than regard it as a separate, unrelated disease or group of diseases.

In conclusion, certain recent and highly significant contributions to the enigma of Struma Lymphomatosa bring this historical summary up to the present time.

Cooke and Wilder (1954), Cooke and Luxton (1955) and Luxton and Cooke (1956) drew attention to the occurrence of abnormal liver-function tests and abnormalities in the electrophoretic pattern of the plasma proteins in a significant proportion of cases of Struma Lymphomatosa and urged the diagnostic value of these investigations in such cases. They found the liver-function tests most consistently abnormal to be the colloidal gold and thymol turbidity reactions and the plasma protein abnormality to consist of an increase in the gamma-globulin fraction. They further observed a return of these findings to normal values, in a certain proportion of patients, under the influence of treatment by thyroid extract. Their results have since been largely confirmed by other workers notably Skirpan et al., in 1955 and Skillern et al., in 1956.

As a development of this work, Roitt et al., in a preliminary report appearing in 1956, suggested that an immune response might be involved. These workers obtained precipitin reactions between the serum of Hashimoto patients and saline extracts of normal thyroid glands.

/ They

They found the antibodies organ-specific for the thyroid and suggested that the antigen in the thyroid extract might be thyroglobulin. They envisaged the Hashimoto patient as being immunised against human thyroglobulin and suggested that the destruction of the thyroid in this disease might result from a progressive interaction of thyroglobulin with the auto-antibody in the patient's serum. They further indicated that such a precipitin reaction might prove a more specific diagnostic test for Struma Lymphomatosa than serum protein alterations or liver-function tests.

Finally in a recent and exhaustive investigation of a series of Struma Lymphomatosa patients made in 1956 by Skillern, et al., the following major conclusions emerged:-

The results of these observations indicate that struma lymphomatosa is probably primary thyroid failure with compensatory thyroid enlargement and is not chronic thyroiditis. the basic defect is probably a failure of the thyroid cells, resulting in a deficiency of thyroxine. The histopathologic evidence for this failure of the thyroid cells is usually, but not always, shown by varying degrees of oxyphilia in the cytoplasm of the cells. The deficiency of thyroxine results in increased production of thyrotropic hormone in an attempt to stimulate the cells to increase their output of thyroxine. Histopathologically, this may induce hyperplasia and often hypertrophy of the thyroid cells, causing most of the thyroid enlargement. Lymphocytic infiltration and fibrosis in these goitres are probably secondary to the failure of the thyroid cells, Due to the compensatory hyperplasia of the thyroid cells, the patient may exist in a clinically euthyroid state (compensated thyroid failure) for months to years before a clinically hypothyroid state (decompensated thyroid failure) occurs. Treatment with desiccated thyroid decreases

the size of the goitre by depressing TSH production, and corrects both symptomatic and asymptomatic thyroxine deficiency.

Since the goitre of struma lymphomatosa is a failing gland with compensatory enlargement, there seems little reason for surgical treatment, particularly since the patient usually has to take desiccated thyroid postoperatively anyway. Moreover, the diagnosis can now be made preoperatively.

The cause of the failure of the thyroid cells is unknown. The only precipitating factor that could be elicited in a few of the patients in this series was the stress of pregnancy

Another possible precipitating factor, not observed in the patients in this series, appears to be overactivity of the thyroid cells in certain patients with Graves' disease, resulting in focal areas of thyroid-cell exhaustion characterized by oxyphilia, lymphocytic infiltration and fibrosis.

Summary

Many of the observations and opinions reproduced in the foregoing pages have, with the passage of time, proved incorrect and reference to their inaccuracy will be made elsewhere in this work. Nevertheless in such a highly controversial subject as that of Chronic Non-Specific Thyroiditis where there is even yet ignorance and disagreement not only concerning the nature but even the identity of its component disease processes, intelligent discussion can only proceed against a background of previous argument and hypothesis regardless of the veracity of the latter. It is for this reason that the historical aspect has been dealt with in such detail. Broadly speaking, three main impressions emerge from the above survey:-

- (a) A failure of agreement concerning the identity, unity or inter-relationships of those disease processes presently regarded as comprising the group of Chronic Non-Specific Thyroiditis.
- (b) An ignorance of their fundamental nature and causation, and
- (c) A lack of knowledge regarding the relationship of the subject as a whole to other forms of thyroid disease.

It is with these problems that the remainder of this work is concerned.

PART II

THE CLINICAL AND PATHOLOGICAL ASPECTS
OF HASHIMOTO'S DISEASE, STRUMA LYMPHOMATOSA
OR LYMPHADENOID GOITRE

Introduction

The term Lymphadenoid Goitre, originally coined by Williamson and Pearse, has, with the passage of time, become synonymous with Hashimoto's Disease or Struma Lymphomatosa and so it is regarded here.

The material which forms the basis of this section and from which conclusions are drawn, consists of 42 cases of Struma Lymphomatosa investigated and treated in the charge of Mr K. Paterson Brown in the Royal Infirmary of Edinburgh between 1st October, 1943 and 31st March, 1957. Reference will also be made to a small additional amount of material investigated and treated after the latter date.

The clinical details of these cases have been abstracted from the available case records, medical, surgical and radiotherapeutic. The histo-pathology of each case has been carefully reviewed. In this way it is felt that a comprehensive picture of the disease, from both clinical and pathological viewpoints, is obtained by one person and that, as a surgeon, what is lost in the finer interpretation of pathological detail, might be compensated by such a breadth of study. Undoubtedly this is an important consideration. One has only to consult a small fraction of the literature to agree that much of the confusion which surrounds not only Struma Lymphomatosa but also the more general subject of Chronic Non-Specific Thyroiditis, has stemmed from reports by surgeon or

/ pathologist ...

pathologist, each isolated in his own speciality and passively accepting the other's opinion, while ignorant of his findings. The surgeon is well placed to correlate the clinical, operative and gross pathological findings and if he add to these a knowledge of the histo-pathology of the resected tissue, may obtain a comprehensive view of the subject as a whole.

In selecting these 42 cases as true examples of Struma Lymphomatosa, the diagnosis was made solely on the basis of the histo-pathological findings in the resected thyroid or portion thereof and without reference to their clinical features. The latter are frequently incomplete, confusing and equivocal as recorded in and abstracted from past case records: the microscopical findings in the resected tissue constitute a permanent, unchanging record and must represent the final court of diagnostic appeal.

Wherever possible, multiple sections from each gland were examined. A most important point in assessing all forms of thyroid pathology, this is particularly the case in attempting to embrace and demonstrate the varied histo-pathological picture of Struma Lymphomatosa and, as will be shown later, in attempting to solve the Hashimoto-Riedel controversy. Failure to make a searching and extensive microscopical enquiry has undoubtedly led to much confusion in the past.

Histo-pathology

Until the publication of the observations of Parnley and Hellwig (1946) and Lennox (1948), scant mention had been made of the changes in the thyroid parenchyma other than to suggest a rather non-specific degeneration of the latter, resulting from its replacement and compression by the perhaps rather more striking microscopical feature, namely the lymphoid infiltration. These authors, however, first focused attention on a specific or distinctive type of epithelial appearance in Struma Lymphomatosa, and although preferring a different nomenclature to describe this appearance - Hirthle cell (Parnley and Hellwig), Askanazy cell (Lennox) - suggested that the parenchymal and not the lymphoid changes might represent the primary and fundamental histo-pathological alteration. All 42 cases in the present group, showed this type of epithelial change and, what is considered more important, did so essentially uniformly. While it is not intended to enter here into a discussion concerning the relative merits of the alternative nomenclature referred to above, the term Askanazy cell has been preferred and will be employed hereinafter for descriptive purposes. Frequently, as will be illustrated later, severe and extensive destruction of the thyroid parenchyma may take place, so that little recognisable epithelial structure may remain and may necessitate widespread search for its detection, but, where such has been the case, any residual epithelial

/ tissue

tissue has been found to show the Askanazy appearance. Other forms and variants of degenerative epithelial change do of course occur and will be described later, but, for the present purpose, the recognition of Askanazy epithelium has been made the sheet-anchor of the diagnosis of the cases of Struma Lymphomatosa included in this group. To employ and impose such an apparently restricted diagnostic criterion may, at first sight, seem injudicious, but, for reasons which will appear later, is a necessity, particularly in considering the relationships of this disorder and other forms of Thyroiditis to one another and to simple, toxic and neoplastic thyroid disease.

1. The Thyroid Parenchyma

(a) Askanazy Epithelium

The changes in the thyroid parenchyma are best described as they affect vesicular structure as a whole. Fig. 5 illustrates what is the early and basic appearance.

Thus, the size of the thyroid vesicles is uniformly reduced, while they possess a regularly round or ovoid outline. Likewise colloid is overall much diminished in amount; it is entirely lacking in considerable numbers of vesicles; elsewhere it is represented by a small amount of well-stained, dense, homogeneous, non-vacuolated material. The vesicles are lined by a single row of typical Askanazy epithelial cells. Frequently vesicles, devoid of or poor in colloid, are occupied by plugs

of desquamated epithelial cells.

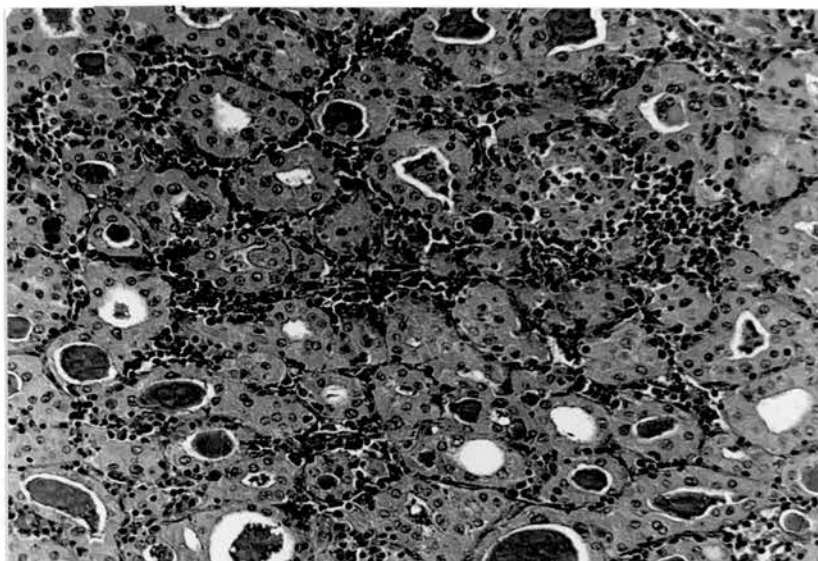


Fig. 5

Vesicular size is uniformly small, with a regularly round or ovoid outline. Overall colloid is much reduced in amount and where present is dense, well-stained and homogeneous. The vesicles are lined by a single row of typical Askanazy epithelium. Haematoxylin and eosin X 150.

Fig. 6 shows this highly characteristic appearance of the thyroid parenchyma in Struma Lymphomatosa at greater magnification.

The Askanazy epithelium lining the thyroid vesicles is a single row of plump, swollen cuboidal cells, with large, round vesicular nuclei and abundant, eosinophilic, finely granular cytoplasm. The cytoplasmic eosinophilia is a striking and regularly observed feature of this type of epithelium. Frequently vesicular outline and colloid content are no longer discernible and epithelium possessing the above characteristics is present more or less as a syncytium. (Figs. 5 and 6).

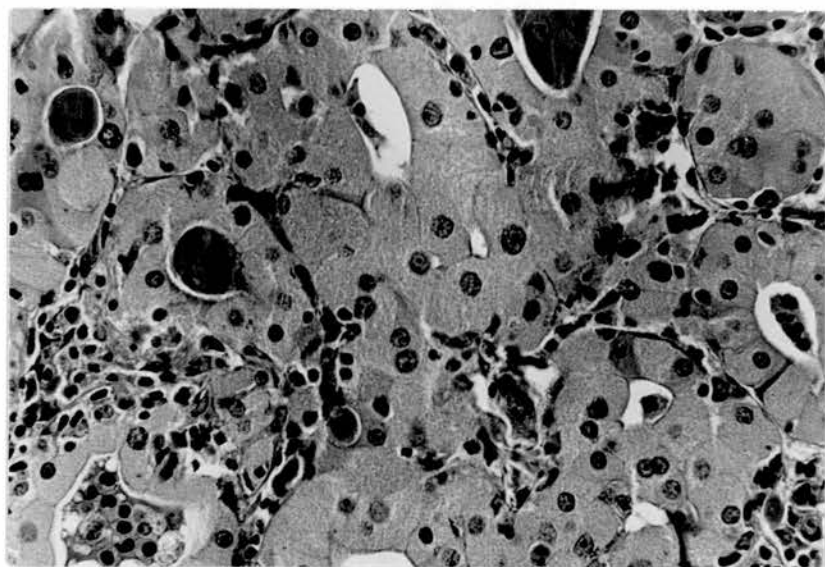


Fig. 6

Higher magnification of parenchymal structure in Struma Lymphomatosa, to show particularly characters of Askanazy epithelium. H. & E. X 300.

The overall effect of this peculiar change in the thyroid epithelium is to impart a highly characteristic, immediately recognisable and what might be described as an almost "hepatic" appearance to the parenchymal structure, when any sufficiently extensive field of tissue is examined.

(b) Loss of Parenchymal Structure

Not all areas of the gland show the well-retained, or what might be called florid, Askanazy appearance depicted in the foregoing microphotographs. Frequently the thyroid parenchyma shows evidence of marked degeneration or disorganisation. In such areas (Fig. 7), vesicular architecture is virtually lost and colloid non-existent.

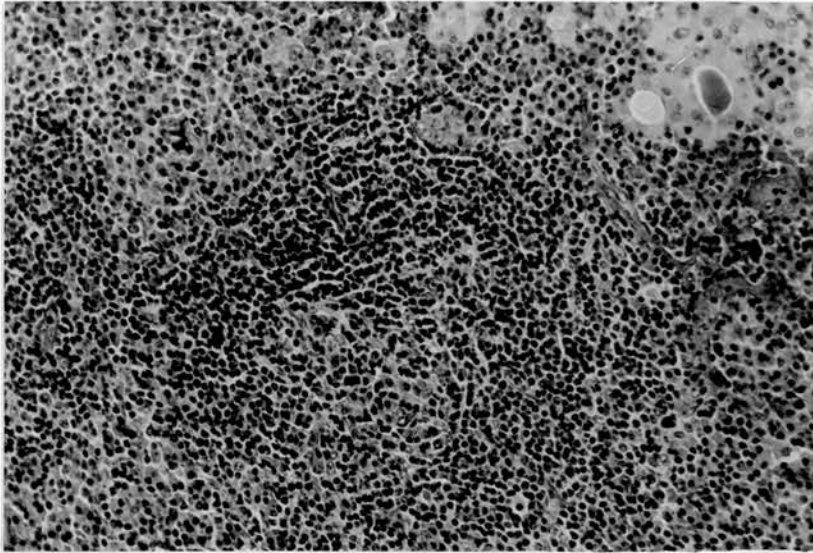


Fig. 7

The thyroid parenchyma is scarcely recognisable as such, vesicular structure is disorganised and colloid virtually non-existent. One focus of Askanazy change is, however, included.
H. & E. X 175.

Under higher magnification (Fig. 8), there is revealed a disorderly arrangement of round cells interspersed with which are the thyroid epithelial cells, the latter exhibiting no vesicular arrangement or at most forming an ill-defined vesicle occasionally embracing a tiny droplet of colloid. Even so, however, it is usually possible to recognise, in these disorganised elements of the original vesicles, the distinctive Askanazy epithelial characteristics already described.

These changes, resulting in loss of the thyroid parenchymal structure, are to be regarded as a further and more degenerate phase, in the history of the earlier, florid Askanazy epithelial appearance.

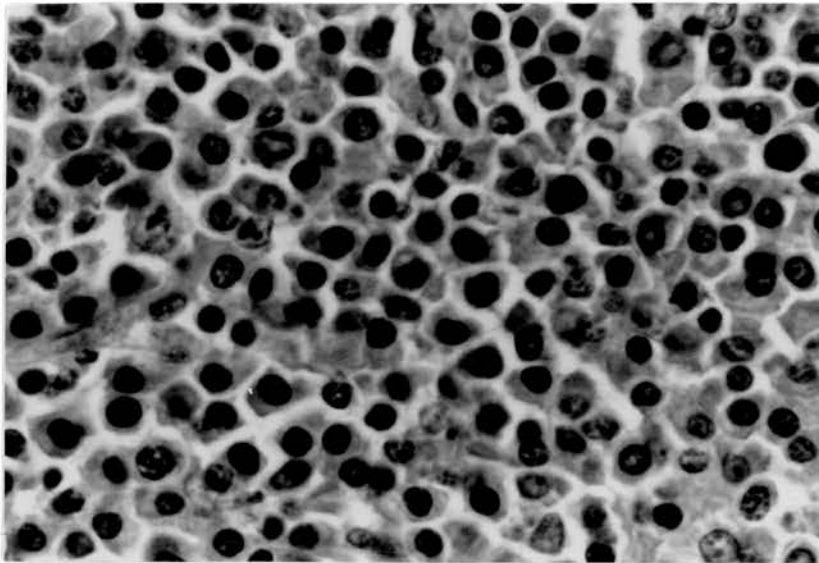


Fig. 8

Higher magnification to show disorganisation of parenchymal structure. H. & E. X 650.

(c) Giant Cells

Relatively few authors have drawn attention to the occurrence of giant cells as part of the histo-pathological picture of Struma Lymphomatosa. They do nevertheless occur, sometimes in large numbers, in a significant proportion of cases. (Figs. 9 and 10).

Whether reference to this feature should be included with the parenchymal changes or more correctly in the description of the mesoblastic changes in Struma Lymphomatosa, is a controversial point, arising from a division of competent pathological opinion concerning the true nature of these multi-nucleated aggregates. Whether they are, in fact, true foreign-body giant cells possessed of phagocytic properties, directed presumably towards

/ colloid

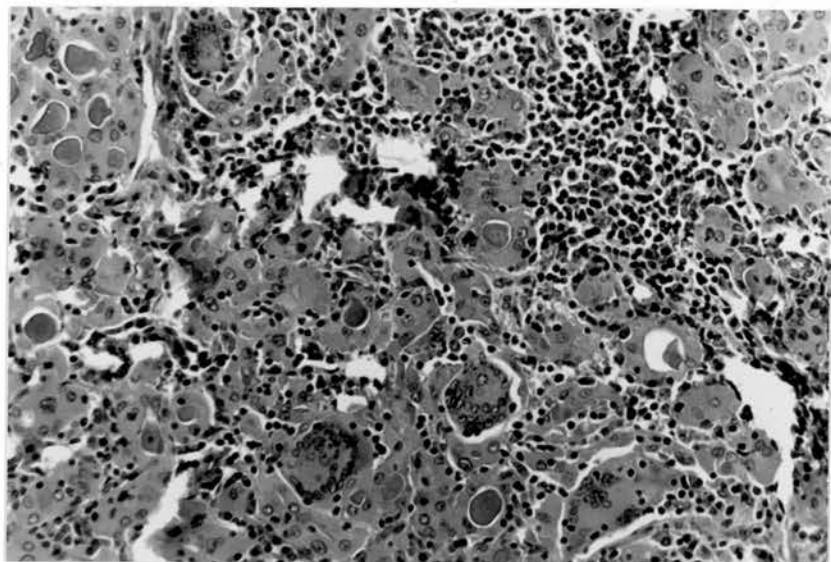


Fig. 9

Giant Cells - note also uniform Askanazy epithelial structure and round cell infiltration.
H. & E. X 185.

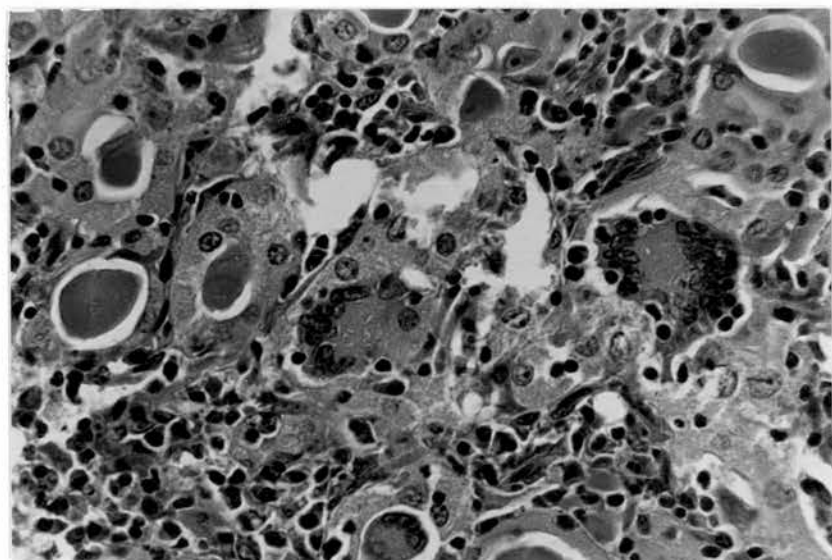


Fig. 10

Giant Cells - higher magnification. H. & E. X 400.

colloid, or merely fused masses of desquamated epithelial cells - pseudo-giant cells - and without phagocytic activity, remains unsolved. Joll favoured the former view, regarding them as true foreign-body giant cells, engaged in the elimination of colloid which could not be otherwise absorbed and quoted an incidence of 10 per cent in his material. Vaux, on the other hand, regarded them as derived from the vesicular epithelium as a result of compression by the lymphocytic infiltration and fibrosis.

Whatever the origin and functional significance or otherwise of these cells may be, there are three points of importance in relationship to them:-

- (i) Their occurrence in a significant proportion of cases of Struma Lymphomatosa must be recognised.
- (ii) They cannot be regarded as in any way pathognomonic of the condition since they (or similar structures) may be met with in other forms of Chronic Non-Specific Thyroiditis.
- (iii) There can be little doubt that frequently in the past their presence has resulted in an erroneous diagnosis of some form of Specific Thyroiditis, most commonly tuberculous.

(d) Squamous Metaplasia

As a minor feature of the parenchymal change, in a small number of cases, is to be seen a metaplasia of the vesicular epithelium to a squamous type. (Fig. 11).

This type of change was not, however, prominent in this group of cases. Further reference will be made to it at a later stage.

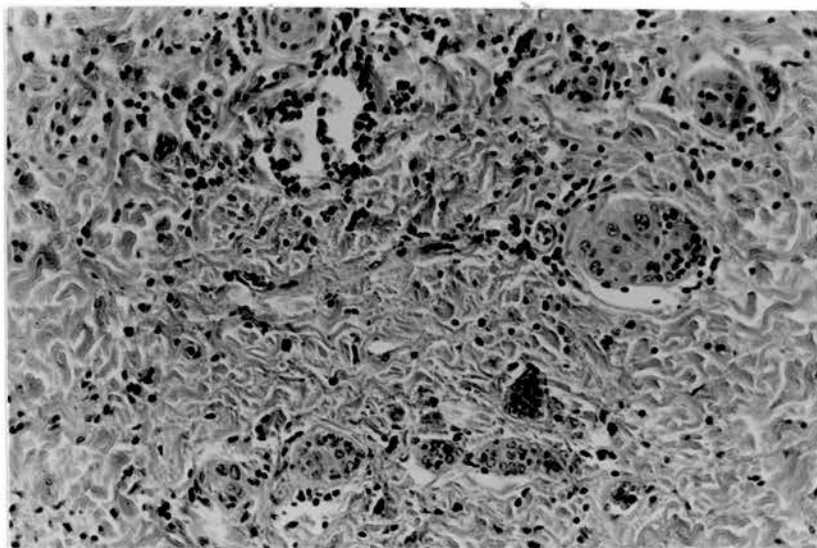


Fig. 11

Squamous metaplasia in Struma Lymphomatosa.
H. & E. X 170.

2. The Round Cell Infiltration

(a) The Lymphoid Follicles

The feature of the histo-pathological picture of Struma Lymphomatosa which, in the past, has been regarded as the most characteristic is the presence of the lymphoid follicles. In certain cases these may be very numerous and closely packed, constituting a most conspicuous element of the tissue, with the thyroid parenchyma apparently compressed in islands between them (Fig. 12).

The lymphoid follicles vary in size and shape, although usually rounded or ovoid. Their structure is by now well recognised, since attention and description have for long been concentrated upon them. (Figs. 13 and 14).

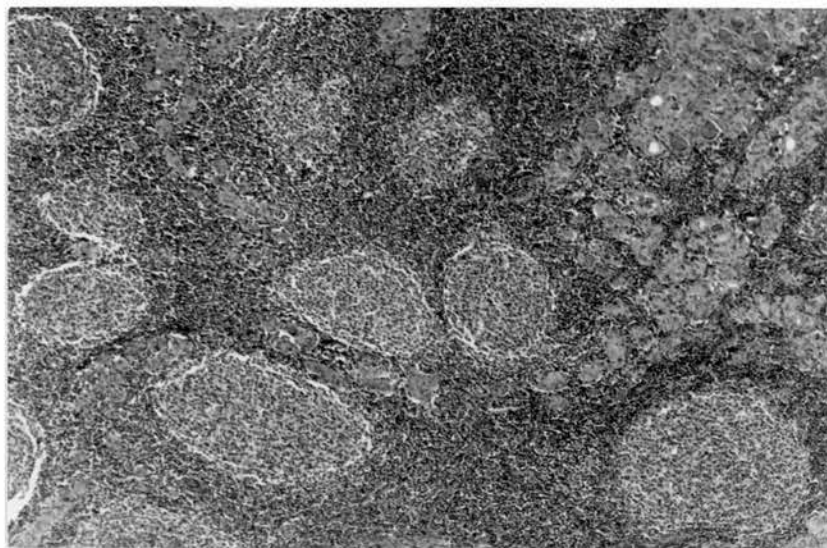


Fig. 12

Numerous, closely packed lymphoid follicles.
Note also the uniform structure of the thyroid
parenchyma - reduced vesicular size, Askanazy
epithelium and overall marked diminution in
colloid content. H. & E. X 60.

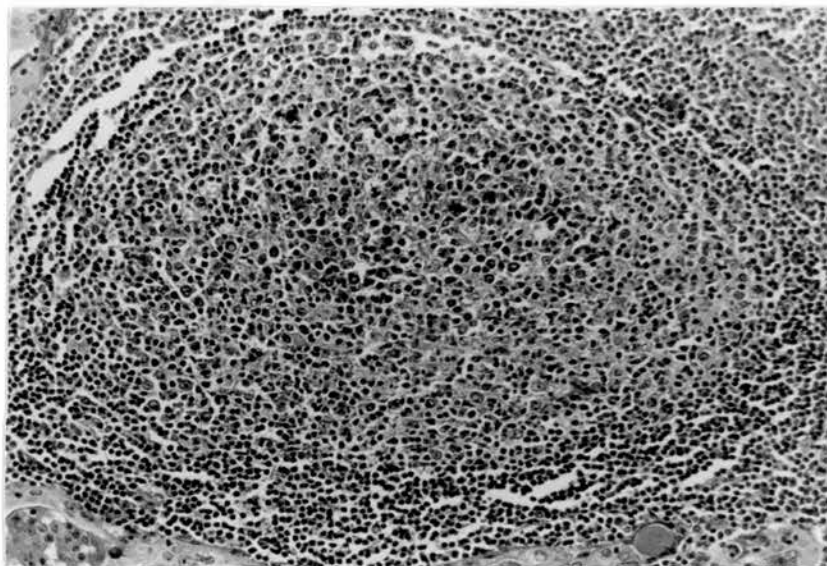


Fig. 13

Lymphoid follicle - higher magnification.
H. & E. X 150.

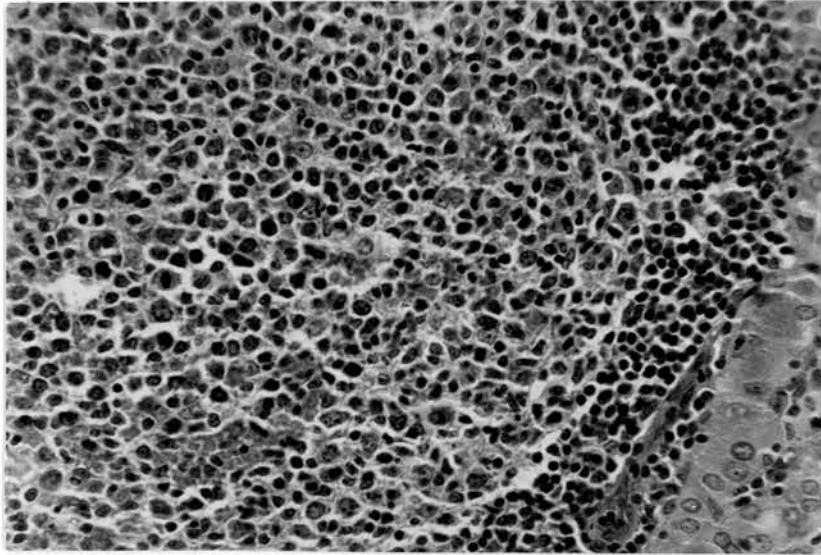


Fig. 14

Lymphoid follicle - germinal centre, zone of lymphocytes and thyroid parenchyma.
H. & E. X 300.

They possess a germinal centre, a central, paler-staining, less compact zone, which, on detailed examination, consists of the reticulum or stem cells, frequently observed in mitosis, a number of intermediate cell types and occasional lymphocytes and plasma cells. Surrounding the germinal centre and well demarcated from it is a peripheral, darker-staining, more compact zone, consisting of orderly concentric rows of mature lymphocytes with occasional interspersed plasma cells.

While these lymphoid follicles undoubtedly constitute a conspicuous feature of many of the cases, it is equally important to recognise that, on occasion, they may be relatively few in number and more widely disseminated

/ throughout

throughout the tissue, while there is evidence that in the later stages and particularly in areas showing considerable fibrosis, they may become hyalinised and effete. (Fig. 15).

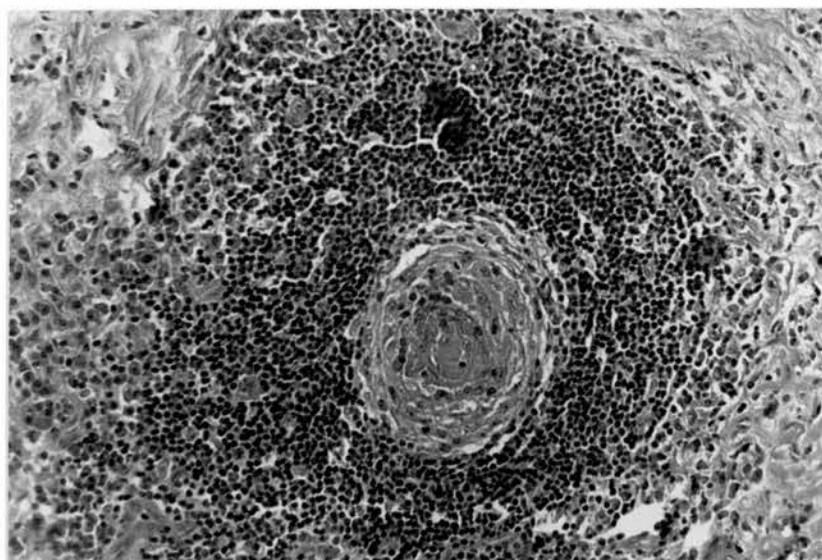


Fig. 15

Lymphoid follicle - hyalinisation. Note also loss of parenchymal structure and surrounding fibrosis. H. & E. X 150.

Certainly the histo-pathological diagnosis of Struma Lymphomatosa must not rest solely upon the abundant presence of these structures and cases must not be rejected because of their relative scarcity.

(b) The Intervesicular Round Cell Infiltration

In addition to the lymphoid follicular element, there is constantly present a diffuse inter-vesicular round cell infiltration of varying intensity. This may be relatively light, taking the form of "streams" of round cells interspersed between the thyroid vesicles (Fig. 16).

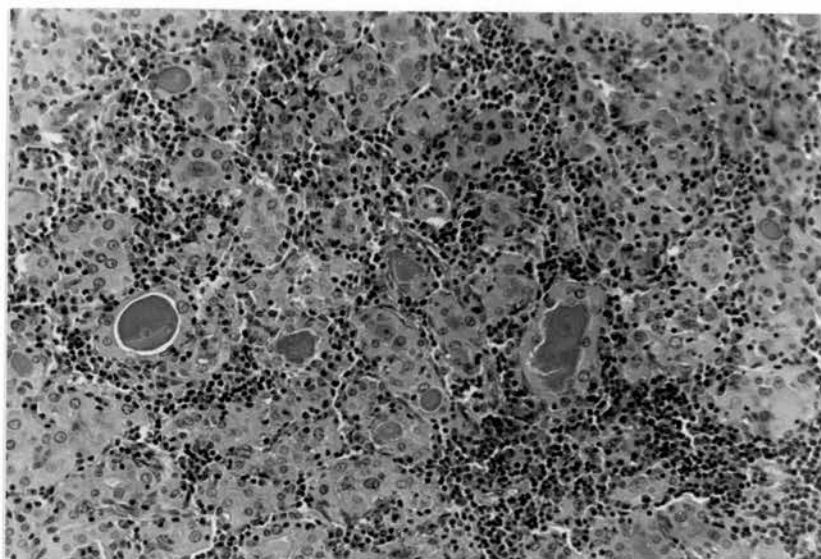


Fig. 16

Inter-vesicular round cell infiltration. Typical parenchymal appearance. H. & E. X 160.

In other situations, however, the round cell infiltration may be heavy and obliterative so that parenchymal structure is scarcely recognisable. (Figs. 17 and 18).

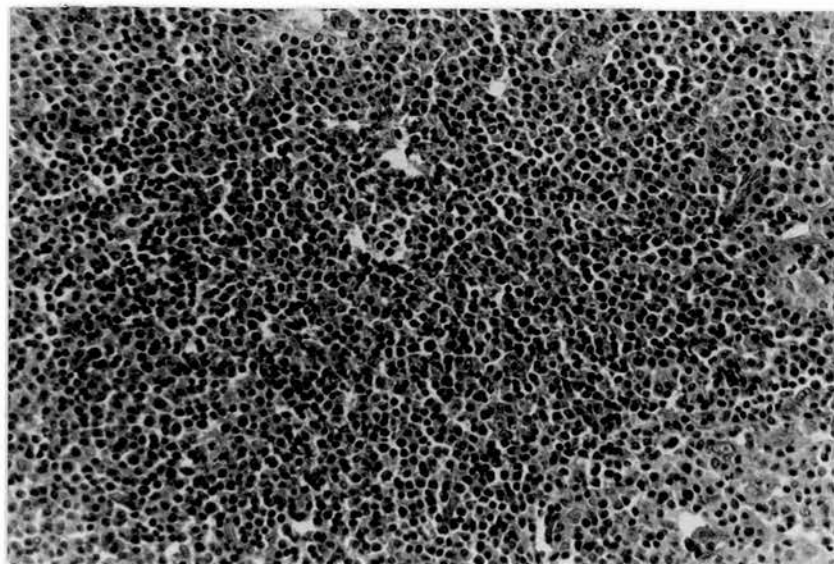


Fig. 17

Round cell infiltration. Loss of parenchymal structure. H. & E. X 175.

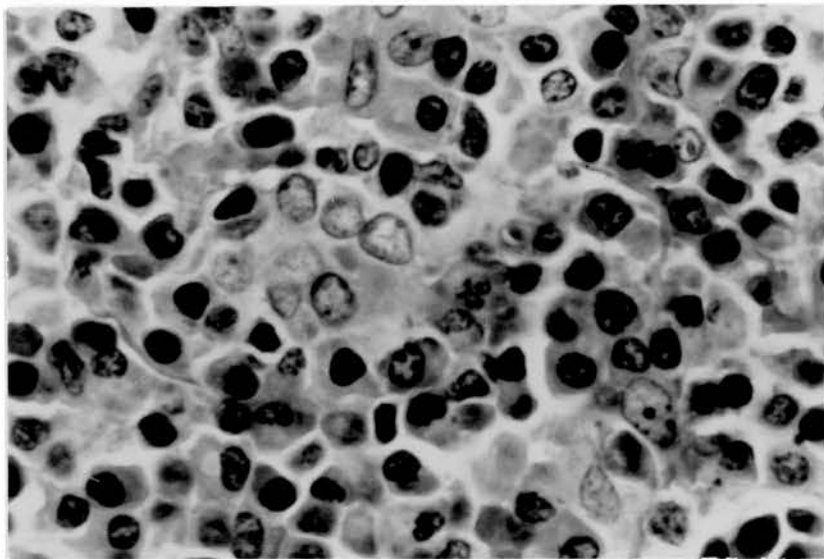


Fig. 18

Higher magnification of Fig. 17. H. & E. X 750.

It has always been customary to regard the lymphocyte as the predominant cytological component of the cellular infiltrate in Struma Lymphomatosa, and undoubtedly large numbers of these are present. Nevertheless in areas of heavy infiltration particularly and to a lesser extent throughout the tissue generally, there may be equal or greater numbers of plasma cells, as shown in this material. (Fig. 19).

3. The Connective Tissue

Perhaps the most important single point concerning the connective tissue changes in Struma Lymphomatosa is the realisation that marked fibrosis may be and frequently is a distinctive feature of the histo-pathological picture. The connective tissue increase appears to follow three different patterns:-

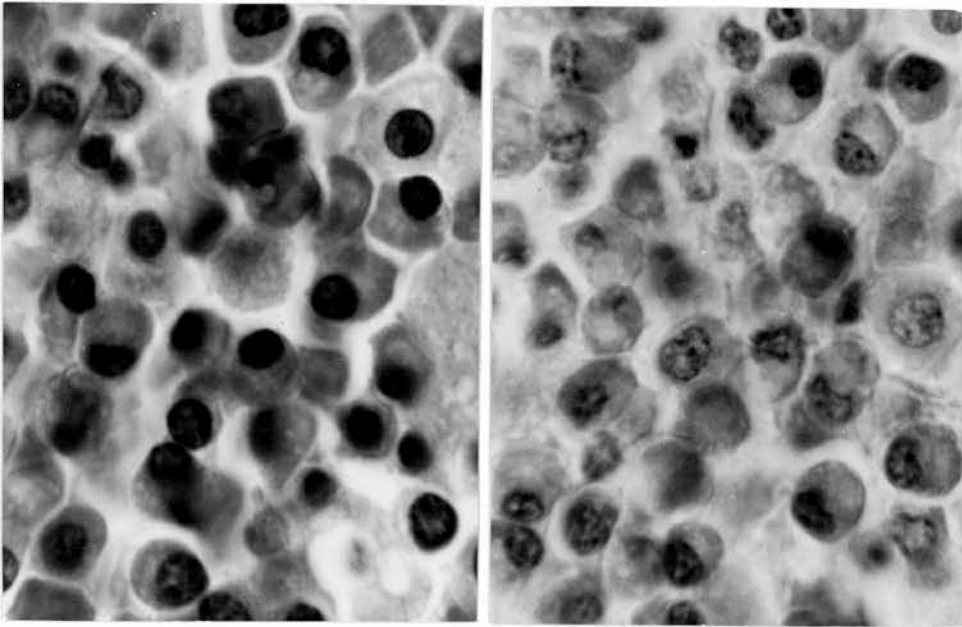


Fig. 19

Showing plasma cell content of round cell infiltration. H. & E.: Unna-Pappenheim X 1150.

- (a) Increase and broadening of the normally present interlobular connective tissue stroma. These well marked septa of fibrous tissue divide the parenchyma into islands and enhance the lobulated architecture of the gland. (Fig. 20).

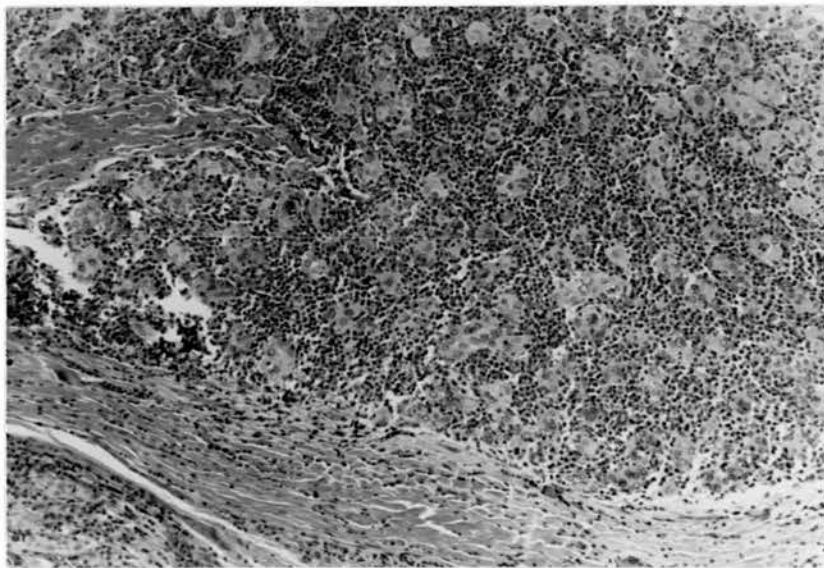


Fig. 20

The Connective Tissue - exaggeration of interlobular septa. H. & E. X 100.

- (b) Coarse strands of fibrous tissue may extend from these thickened and broadened interlobular septa into the parenchymal lobules pervading and ramifying between the thyroid vesicles, uniting with one another and with further interlobular septa. (Figs. 21 and 22).

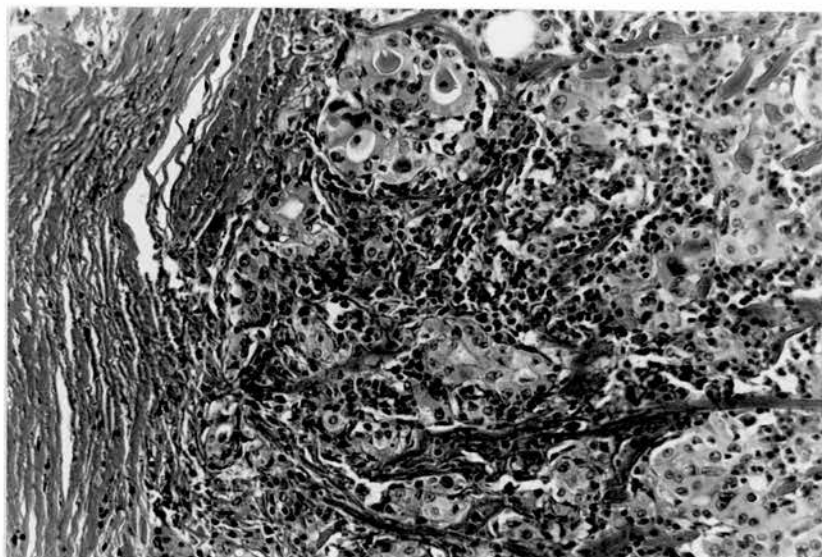


Fig. 21

The Connective Tissue - coarse intervesicular fibrosis. Note well retained parenchymal structure. H. & E. X 150.

- (c) Finally, in areas where parenchymal structure is essentially lost, usually associated with a heavy round cell infiltration, there may be evidence of a finer, more diffuse type of fibrosis. (Fig. 23). This, however, is less commonly observed than the coarse inter- and intra-lobular fibrosis described above.

In the markedly fibrotic and presumably most advanced cases of the disease, this increase of the connective tissue elements is very striking. The usual appearance is of small islands of parenchyma isolated in and surrounded by

a sea of fibrous tissue. (Fig. 24). The residual thyroid structure in such areas, if preserved and recognisable, shows the typical Askanazy appearance already described. (Fig. 25).

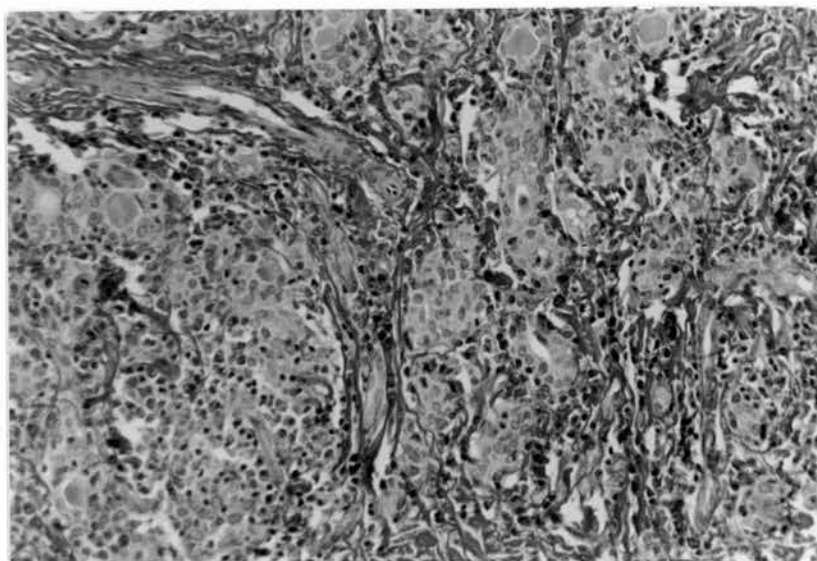


Fig. 22

The Connective Tissue - similar view to Fig. 21.
van Gieson X 175.

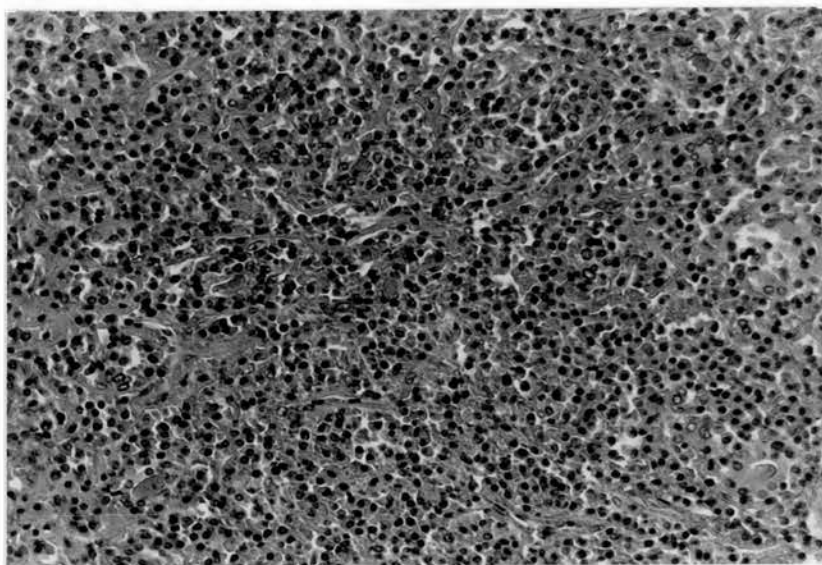


Fig. 23

The Connective Tissue - fine fibrosis. Loss of
parenchymal structure. H. & E. X 175.

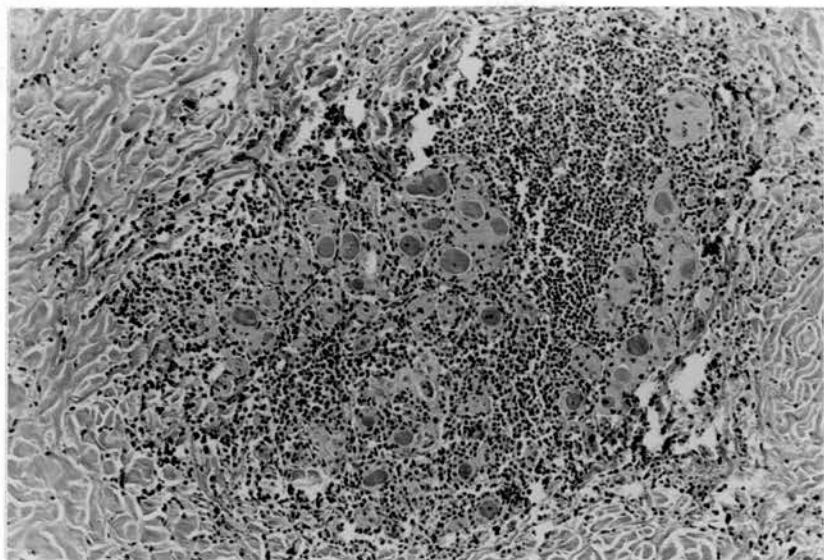


Fig. 24

The Connective Tissue - predominant fibrosis.
H. & E. X 80.

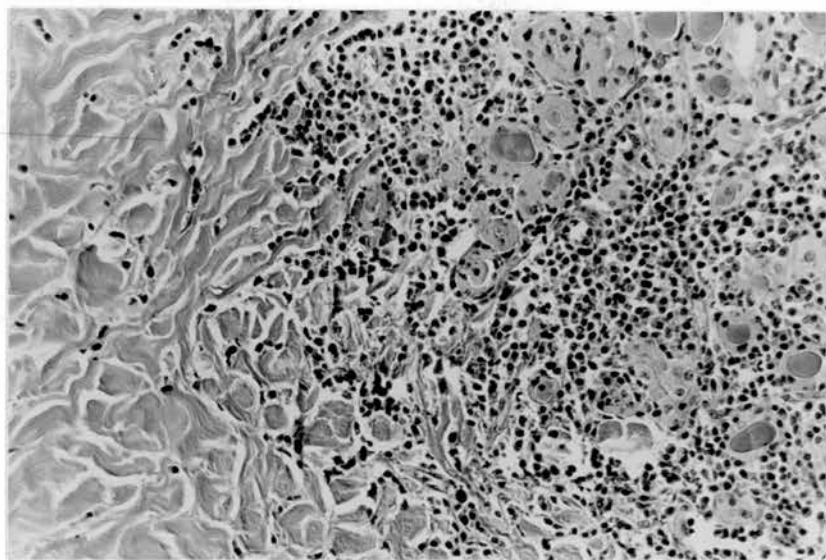


Fig. 25

The Connective Tissue - higher magnification.
Note Askanazy structure of residual
parenchyma. H. & E. X 170.

The final expression of this connective tissue increase is the occurrence, throughout widespread areas, of an unrelieved fibrosis with minimal round cell infiltration and sometimes hyalinised. (Figs. 26 and 27).

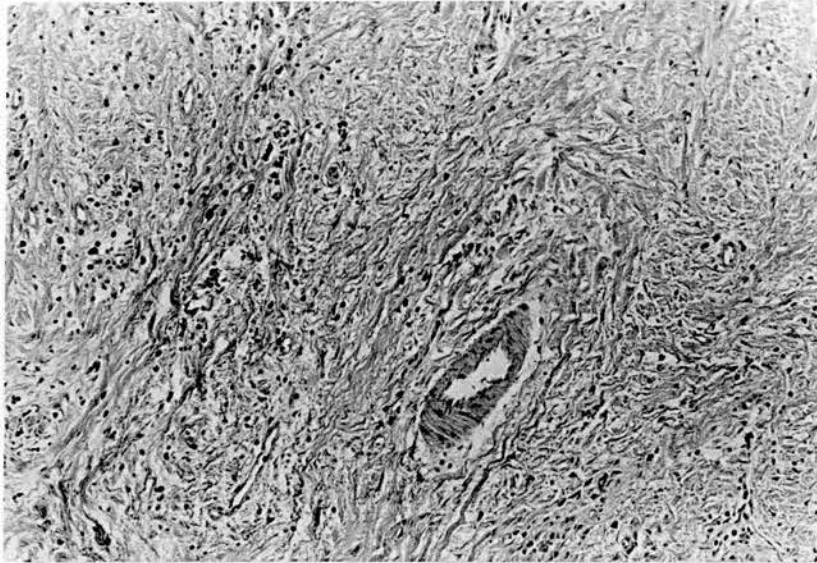


Fig. 26

Fibrosis. H. & E. X 100.

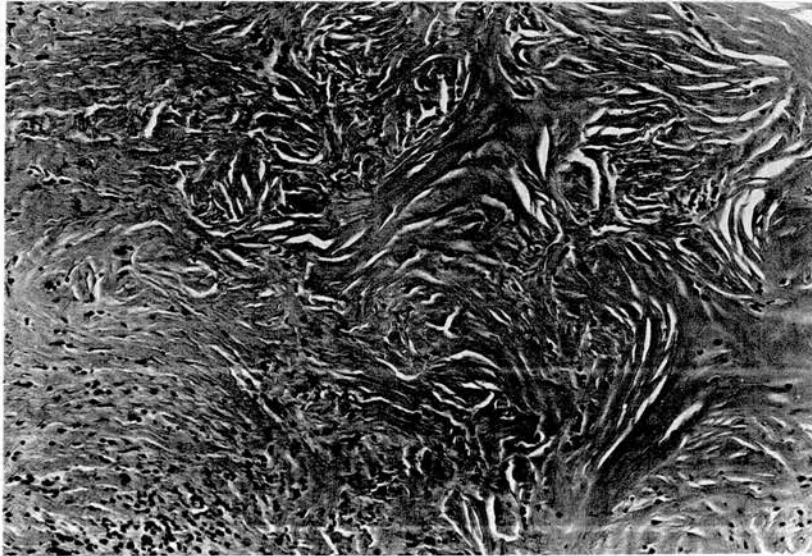


Fig. 27

Fibrosis. H. & E. X 100.

General Commentary on Histo-pathology
of Cases in Present Group

As stressed in the preface to this section on histo-pathology, the diagnosis of Struma Lymphomatosa in this group of 42 cases was made solely and absolutely on the microscopical findings. Furthermore the sheet-anchor of such diagnosis was the uniform presence and recognition, where parenchymal structure was sufficiently well retained to render this possible, of the distinctive Askanazy type of epithelial change. In other words, examination of this material revealed no evidence of normal thyroid epithelial structure or of the epithelial changes commonly associated with and seen in the various forms of simple, toxic or neoplastic goitrous enlargement. It was further suggested that the imposition of such an apparently restricted diagnostic criterion might prove injudicious and in fact this point will be elaborated and discussed at a later and more appropriate stage in this work. For the present, however, the employment of this criterion, quite apart from constituting an important, constant and striking feature of the histo-pathological picture, serves to delimit a uniform group of cases.

In the preceding pages the individual components of the microscopical picture of Struma Lymphomatosa have been illustrated and described. It is of equal importance, however, to obtain a more comprehensive view of the disease process as a whole. Within the limits defined in the previous paragraph, the histo-pathological picture - comprising as it does the distinctive Askanazy

/epithelial

epithelial and vesicular changes, loss of parenchymal structure, giant cells, squamous metaplasia, lymphoid follicular proliferation, round cell infiltration and fibrosis - is remarkably pleomorphic, so that in the majority of cases all combinations and permutations of these individual microscopic appearances may be observed in different sections or in different and frequently closely adjacent fields of the same section. In partial illustration of this pleomorphism, Figs. 27, 28 and 29, are taken from closely related areas of the same gland and by no means constitute an isolated example.

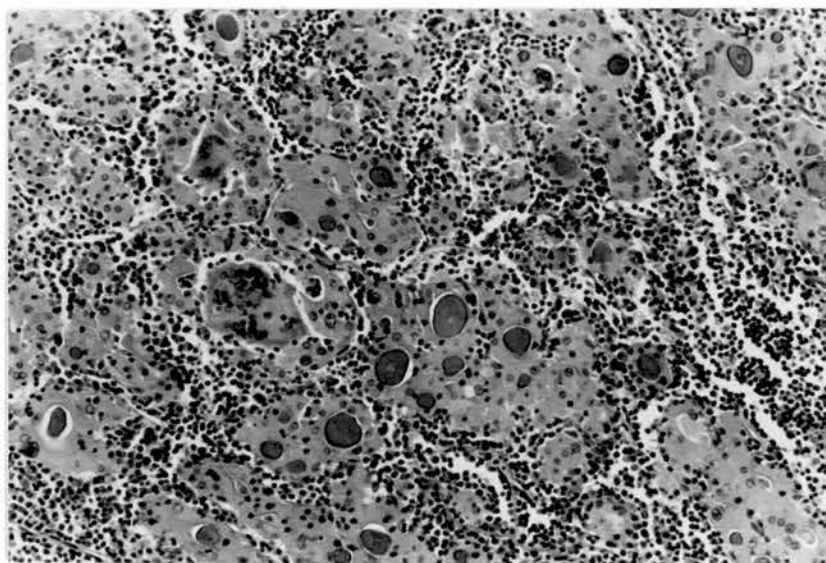


Fig. 28

Askanazy parenchymal structure and round cell infiltration. H. & E. X 100.

Such pleomorphism is and has been responsible for much of the difficulty and confusion encountered in the interpretation of the histo-pathological picture of Struma Lymphomatosa. Particularly does it confirm the necessity,

as has been previously stressed, for an extensive microscopical enquiry. Moreover it makes for considerable difficulty in staging or assessing a particular case in terms of the degree of progression of the pathological process, and in attempting to correlate such staging with the duration of the condition as determined on clinical grounds.

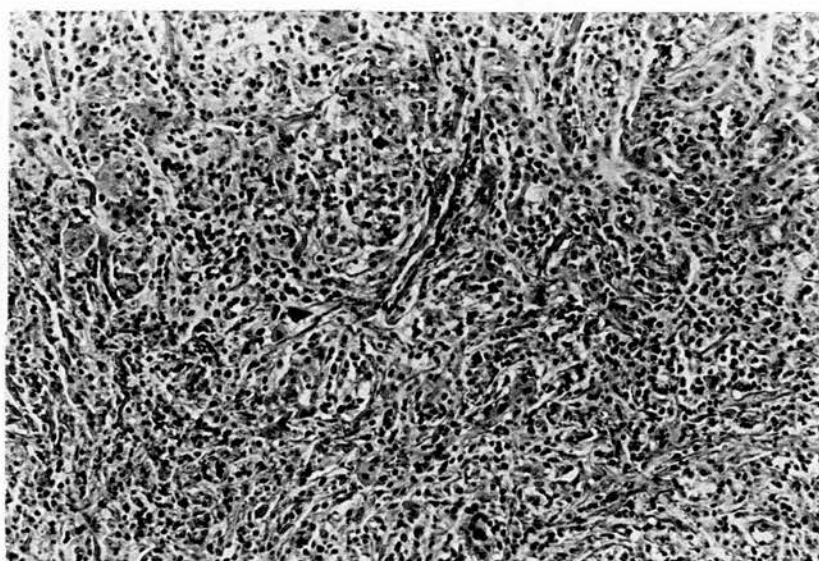


Fig. 29

Loss of parenchymal structure, absence of colloid,
round cell infiltration and fibrosis.
H. & E. X 100.

Little or nothing is known concerning the natural life history of untreated Struma Lymphomatosa, and this applies equally to its pathological and clinical course. The beginning and end points, with the intervening sequence of pathological events, are wrapped in mystery, and form one of the principal subjects for discussion at a later stage.

/ For

For the present, however, the histo-pathological examination of this material allows of the following conclusions:-

- (a) Whether or not the change in thyroid epithelial structure to the Askanazy type represents the histo-pathological expression of the underlying, primary and fundamental disordered physiological mechanism of Struma Lymphomatosa, it is almost certainly an early established feature. It is invariably accompanied by varying degrees of lymphoid follicular activity and round cell infiltration.
- (b) Whichever is the primary event - the epithelial change or the cellular infiltration and it may well be the former - the older concept of an intense lymphoid follicular and round cell activity replacing, compressing and causing a final pressure atrophy and disappearance of the parenchyma is not supported by the microscopical findings.
- (c) The final pathological state of the thyroid in untreated Struma Lymphomatosa is almost certainly one of uniform fibrosis.
- (d) If these criteria be accepted, then a minority of cases can be classified as early or late.

Between these, however, the pathological process is uneven and the description of sequential stages would be erroneous. While the overall process

/ is

is undoubtedly an evolving continuum of increasing degeneration, this does not occur in an orderly and uniform fashion.

In this section, much attention has been paid to the occurrence of fibrosis as part of the histo-pathological picture of Struma Lymphomatosa, while it has been suggested above that its uniform presence probably represents the final event in the untreated case. This point will be elaborated later in a discussion of the Hashimoto-Riedel controversy. It is of some interest at this stage, however, to note that in no less than six of these cases the original microscopy reports formulated by a variety of pathologists gave a diagnosis of Riedel's Thyroiditis.

Pathological Anatomy and Operative Findings

In discussing the pathological anatomy of Struma Lymphomatosa it is not only convenient but important to include and compare the operative findings as determined by the surgeon.

1. Size and Weight

The gland of Struma Lymphomatosa is almost invariably considerably enlarged. Thus Marshall et al. (1948), in 78 glands, recorded an average weight for the two lobes of approximately 100 gm. Statland et al. (1951), in 32 subtotal thyroidectomies, recorded an overall average weight of 66.8 gm., the largest specimen weighing 225 gm. Lindsay et al. (1952), in 168 cases, observed weights between 10-211 gm., with a mean of 39.3 gm. In the present

group of 42 cases the weight of resected thyroid tissue was recorded in only eight, in all of which subtotal thyroidectomy had been carried out. This varied from 65-163 gm., with a mean of 121 gm.

2. Extent of Involvement

Almost invariably the enlargement affects both lobes, isthmus and pyramidal lobe diffusely, although, in the case of the lobes, perhaps asymmetrically. Indeed it is not uncommon to find one lobe larger than the other. The uniform, diffuse involvement of the thyroid in Struma Lymphomatosa is a feature which has been much emphasised and used as a strong line of argument by those who prefer to regard the Hashimoto and Riedel forms of Thyroiditis as distinct and unrelated entities. 39 of the 42 glands in this group showed this uniform, diffuse involvement at operation. In the remaining two, however, - undisputed cases of Struma Lymphomatosa from histo-pathological examination - the enlargement was confined to one lobe, there being a confident operative note regarding the normality of the remainder of the gland.

Very commonly the enlarged lobes pass posteriorly as a retro-tracheal or even retro-oesophageal extension and may indeed meet or overlap as a "circular goitre". While this feature is not exclusive to Struma Lymphomatosa it occurs sufficiently frequently to be of considerable importance and further reference will be made to it when the clinical aspects are discussed.

Only two of the glands showed evidence of some

/ retrosternal

retrosternal prolongation. Sholl and Black (1954) have reported a case of Struma Lymphomatosa with substernal extension, producing a superior vena caval syndrome. This was dramatically relieved by subtotal thyroidectomy, the weight of resected tissue being 262 gm.

3. Gross Appearance

The naked eye characteristics of the gland have been often described and illustrated. Typically the surface is smooth but distinctly lobulated. It is not nodular. There is a thin fibrous capsule beneath which may be seen coursing the blood vessels. In general, vascularity is diminished but the vessels show no special tendency to be abnormal. Classically the gland has a uniformly firm or rubbery, solid consistence. On cross section, the tissue has a homogeneous, succulent, pinkish-grey or pinkish-yellow appearance and shows a division into lobules of varying size by the connective tissue framework. There is no evidence of normal colloid-containing tissue and the vesicles are beyond the range of naked-eye vision. Haemorrhage, necrosis, calcification, abscess formation, nodules and cysts are conspicuous by their absence. The impression given by the mass of fresh tissue has frequently been likened to a "giant" hyperplastic lymph node.

Variations from the classical appearance described above may, however, occur and were noted in the present group. Of the 42 cases, 35 had sufficient tissue removed to render accurate assessment of the gross appearance

/ possible

possible (the remaining seven had biopsy only). Of these 35, 25 coincided exactly with the foregoing description. The variations in the remainder were distributed as follows:-

- (a) Isolated, small colloid cyst..... 2
- (b) Occasional, small, colloid-filled spaces..... 2
- (c) Minimal nodule formation..... 1
- (d) Minimal foci of haemorrhage..... 1
- (e) Isolated area of calcification..... 1

It must be emphasised that these variations were minimal, were superimposed upon the basic, classical appearance as described and in essence did not detract from it. They are not important, form an inconspicuous part of the disease and as Joll has suggested doubtless antedate it.

- (f) Predominant fibrosis..... 3

This last variation is, however, of considerable importance. In the section on histo-pathology, strong emphasis was laid on the occurrence of fibrosis, frequently widespread, as a microscopical finding and it is perhaps disappointing to find only three cases exhibiting macroscopic fibrosis sufficient to impart a definite gross appearance of such and quite unlike that classically seen in Struma Lymphomatosa. Nevertheless it is almost certain that, in general, the gross appearance and consistency of the thyroid in this disease must be influenced by its fibrous tissue content and this point will be elaborated at a later stage.

4. Extra-thyroid Extension

In the differentiation of the Hashimoto and Riedel forms of Thyroiditis much emphasis is and has been placed on the fact that, in the former, the disease process is confined within the capsule of the gland without evidence of extra-thyroid extension, whereas, in the latter, the capsule is transgressed with extension into the tissue planes of the neck in the form of a diffuse infiltrating fibrosis.

In none of these cases of Struma Lymphomatosa was there any evidence at operation of extra-capsular extension, adhesion to adjacent cervical structures or spreading fibrosis in the neck and this was so even in the most fibrotic glands. It is well known that thyroid resection in Struma Lymphomatosa is classically a simple technical procedure, rendered so by the peculiar solidity of the gland, the ease with which it may be mobilised and its generally diminished vascularity - all features frequently commented upon in the present series.

The Clinical Aspects

1. Age and Sex Incidence

In this group of cases the age at time of treatment varied from 36 to 74 years.

Regarding the sex incidence, 37 of the cases were females and five were males.

Explanatory Note

The figures just quoted for age and sex incidence apply only to the 42 cases presently under discussion.

Pathological considerations have necessitated the review of two additional and separate groups of cases at a later stage in this work and thus the final corrected figures for age and sex incidence must appear subsequently and are to be found on pages 197 and 198.

2. Duration of Goitre

Of the cases in this group, all but one had a complaint of thyroid enlargement as part of the symptomatology. The duration of such enlargement was distributed as follows:-

Less than 1 year.....	22 cases
1-2 years.....	10 cases
2-5 years.....	6 cases
More than 5 years.....	3 cases (8, 10 and 30 years)

The shortest duration was three weeks, the longest 30 years and the average, 28 months. In nine of the cases the duration of the thyroid enlargement was over two years. Joll (1939) quoted an average duration of 4.2 years, with extremes of three weeks and 30 years. Statland et al., (1951) had six cases with a duration of goitre of more than five years, out of their series of 51 patients, while Lindsay et al. (1952) had a range of one month to 30 years, with 40 per cent one year or less.

The thyroid swelling may be steadily and slowly progressive or there may have been little alteration in size since the time of its first appearance: in other instances, an episode of more recent and acute enlargement

/ occurs

occurs before the patient presents for treatment.

Attention has already been drawn to the difficulty in correlating the histo-pathological picture in any particular case with the duration of the condition as determined clinically. This is certainly true in respect of the duration of the thyroid enlargement. Thus, Figs. 7, 8, 17-19 and 23 show the virtually uniform histo-pathological appearance in a case with goitrous enlargement of one year's duration; Fig. 6 is equally representative of the microscopic findings in the case in which the duration of thyroid enlargement was thirty years; this illustration by no means constitutes an isolated example in the present series.

3. Other Symptoms

At best the complaints of patients with struma lymphomatosa are vague with the one exception that they have a goitre and a fullness of their throat. (Schilling, 1945).

The great majority of authors are in agreement with this statement and, in particular, the absence of severe pressure symptoms has been used as a point of distinction from Riedel's Thyroiditis in which such symptoms have been held to constitute a prominent, if not the principal, feature of the clinical picture.

In this group, those symptoms which might perhaps be regarded as immediately referable to or produced by the enlarged gland were as follows:-

/ Hoarseness

Hoarseness and voice change.....	16 cases
Sensations of pressure and choking...	13 cases
Difficulty in swallowing.....	9 cases
Thyroid discomfort and pain.....	8 cases

(a) Hoarseness and voice change

No less than 16 patients complained of some change in the voice. This might vary from a mild, intermittent but definite huskiness to a frank, persistent and disabling hoarseness. Few authors appear to have found a similar frequency of this symptom and little importance has been attached to it. Yet the suggestion is offered that in no other group of thyroid enlargements, of different aetiology, with the exception of neoplasm, is voice change so frequent or emphatic a complaint as in the Struma Lymphomatosa group. Its importance is obvious as one factor, amongst others, which may induce the clinician to consider a diagnosis of malignancy and in this connection further reference will be made to it later.

Regarding the cause of this symptom there is less certainty. It is not a result of interference with recurrent laryngeal nerve function, at any rate as determined by gross inspection of cord movement. In these 16 patients complaining of voice change, laryngoscopy was carried out in 14 and found normal in 13; in the remaining case there was early paresis of one cord.

Joll (1939), remarking that some hoarseness and dysphonia of an intermittent character is often observed, favoured the view that it was due to the mechanical effect of the

very solid goitre and its well marked tendency, which has already been stressed, to retro-tracheal extension. It was not found possible in this group, because of insufficient data, to establish any correlation between the symptom under discussion and the occurrence and extent of retro-tracheal or retro-laryngeal extension, but it is possible to be certain that an individual patient with this complaint may exhibit little or nothing in the way of laryngo-tracheal compression or displacement or posterior extension, while the converse may also be observed.

(b) Sensations of pressure and choking

These are the mild pressure symptoms of Struma Lymphomatosa and include a feeling of tightness or pressure about the neck, mild choking attacks, constant awareness of "something in the throat" and desire to clear it etc. Thirteen patients in the present group made such complaints. While surgically unimportant and by no means pathognomonic, being observed in any large goitre, they may nevertheless be a source of considerable anxiety to the patient.

(c) Difficulty in swallowing

This symptom, exhibited by nine of the cases, might equally well be included with the immediately preceding group, rather than deserve special mention. In no case was it severe. Most authors mention dysphagia as a slight and occasional feature of the symptomatology of Struma Lymphomatosa; it is almost certainly a simple pressure effect upon the oesophagus and without intrinsic

/ involvement

involvement of the latter.

(d) Thyroid discomfort and pain

Most authors are in agreement with Taylor (1955) when he remarks - "Pain or tenderness practically never occurs", and most series quote only a very low incidence of this particular symptom, e.g. Marshall et al. (1948) 10 out of 78 cases, Statland et al. (1951) 5 out of 51 cases and Lindsay et al. (1952) 15 per cent in 170 cases. Pain was a feature in only 8 cases of the present group. This varied from a mild feeling of soreness in the neck to a definite complaint of unilateral or bilateral pain, sometimes radiating up to ear or jaw.

The striking absence of pain in Struma Lymphomatosa is in sharp contrast to its almost uniform occurrence - not infrequently indeed as the presenting symptom - in Subacute Thyroiditis. Any case in which pain constitutes a prominent feature must be carefully assessed before its inclusion in the Hashimoto group.

Recently, Doniach and Hudson (1957), commenting upon the occurrence of pain in four of their cases of Struma Lymphomatosa, suggested that it may be connected with a rapid hypertrophy of glandular elements and lymphoid invasion with resulting intracapsular tension and further drew an analogy to the aching and tenderness which may occur in the thyroid after injections of thyrotrophic hormone and in thyrotoxic patients overtreated with anti-thyroid drugs.

4. Clinical Assessment of Thyroid Function

(a) Hyperfunction

In Part 1, extensive reference was made to the works of various authors who have repeatedly attempted to draw attention to a possible relationship between thyrotoxicosis and Struma Lymphomatosa, e.g. Eason, Polowe, Vaux, Eden and Trotter, Levitt. Others have been equally vociferous in denying the possibility of such a relationship. In any group of cases, therefore, it is obviously of the greatest importance to search for evidence of remote or recent hyperfunction.

Such a search, when relying purely on symptomatology and conducted as a review of past material, is fraught with danger, particularly so when accurate records of basal metabolic rate estimations are not available and in an era before radioactive iodine investigation was possible, both of which are of assistance in confirming or refuting clinical impressions. This largely applies to the present group of cases.

A number of patients may complain of such symptoms as nervousness, fatigue, palpitation, etc., but these are obviously not necessarily attributable to thyroid hyperfunction and might equally well be manifestations of an anxiety or menopausal state, particularly so in a disease showing the age distribution of Struma Lymphomatosa, while similar symptoms may arise simply from the concern of a large goitre producing pressure. At the same time, however, it is necessary to keep in mind the view expressed

by Joll. The latter, while essentially denying the possibility of an aetiological relationship between thyrotoxicosis and Struma Lymphomatosa, remarked as follows:-

It cannot be denied that certain toxic features may also occur in exceptional cases, exemplified by loss of weight, nervousness, and a moderate elevation of the basal metabolic rate, but these are explicable in relation to the degree of dyspnoea which exists and to the hypertrophic changes in the thyroid epithelium, which, however, are comparatively short-lived. In other words, toxic features do not precede the disease, though they may be associated with its onset, in which event they have no tendency to become aggravated or to lead to the complete picture of thyrotoxicosis, primary or secondary.

The problem is obviously a difficult one; its only solution would be by means of a strictly contemporary clinical and laboratory study in a significant series of cases and over a suitably comprehensive time period - an unattainable ideal, since by the time the patient presents for investigation and treatment, manifestations of prior toxicity, if in fact such exists, may be no longer recordable.

This aspect of the subject will be discussed again at a later stage; for the moment the following generalisations may be made from the analysis of a group of cases such as the present:-

- (i) In 30 of the 42 cases, there was nothing in the symptomatology to suggest remote or recent toxicity; physical examination at the time of presentation for surgical treatment failed to reveal any signs of thyroid hyperfunction; the

/ clinical

clinical diagnosis rested between simple goitre, Thyroiditis or malignant disease, but never thyrotoxicosis.

- (ii) Of the remaining 12 cases, 11 reported symptoms possibly suggestive of recent and one of remote toxicity; in none of these did physical examination, at the time of presentation for surgical treatment, reveal convincing signs of thyroid hyperfunction; in ten, the clinical diagnosis rested between simple goitre, Thyroiditis or malignant disease and in only two was the possibility of thyrotoxicosis considered.

In order to illustrate more clearly the type of case comprising this latter group, one of the more flagrant examples has been selected for reproduction here, in full, of the case history.

Mrs. J.B. Age 44 years. Housewife.
Admitted R.I.E. - 29.3.1955.

History of Present Illness. At the beginning of 1954 a hysterectomy was performed for menorrhagia. Since then she had become progressively unwell, "very nervy and making mountains out of molehills". She was irritable, often felt tense and her family bore the brunt of her temper. Shortly after the hysterectomy she first noticed an enlargement of her thyroid gland which thereafter steadily increased in size. She was conscious of its presence, but had no dysphagia or difficulty in breathing. There was no pain. She was mildly breathless on exertion, her energy had decreased and she had become rather listless. During the six months prior to hospitalisation she had observed a fluctuating weakness in her voice, unassociated with sore throats. She perspired a great deal and had occasional flushes. She was not tremulous. She had observed a decided preference for the colder weather since her illness began. She slept poorly.

Her appetite was poor, she never felt hungry and

/ had

had little inclination to eat. In July 1954 she weighed 9 st. 4 lb. (59.1 kg.); on admission to hospital in March 1955 her weight was 8 st. 6 lb. (53.6 kg.). Bowel action normal. No urinary symptoms. Her only other complaints were of occasional mild headaches and a slight cough which she attributed to smoking.

Past History. Pneumonia on two occasions; appendicectomy; hysterectomy.

Family History. One adopted child.
Three siblings alive and well, apart from one sister with a duodenal ulcer.
Both parents dead - mother of Bright's disease; father from a probable carcinoma of pancreas.

Clinical Examination showed a rather thin, co-operative woman who gave an impression of mild toxicity.

Weight 8 st. 6 lb. (53.6 kg.).
Temperature 97°F; Pulse rate, 60 per minute;
Respiratory rate, 20 per minute.
Blood pressure - 134/78 m.m. of mercury.

There was a marked bilateral and uneven enlargement of the thyroid. Some parts of the gland were very firm indeed but there was no restriction of mobility. The thyroid was not tender and there was no bruit in relation to it.

The eyes were rather staring, but there was no true exophthalmos. Eye movements were full with no diplopia or other eye signs. The skin of the hands was hot and perspiring and they displayed a slight fine tremor when outstretched. The voice was a little "croaky" but not definitely husky.

The remainder of the examination was negative.

An X-ray of the neck showed considerable thyroid enlargement extending retro-tracheally and tending to narrow the trachea in its antero-posterior diameter and displace it slightly to the left. (Figs. 30 and 31).

Laryngoscopy revealed slight inter-arytenoid thickening, but both cords moved equally and freely.

Two physicians examined this patient independently and both considered that she exhibited, symptomatically

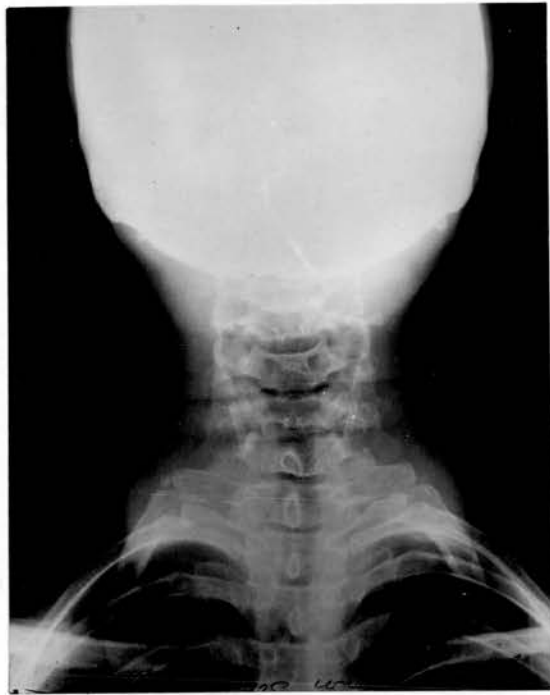

Fig. 30

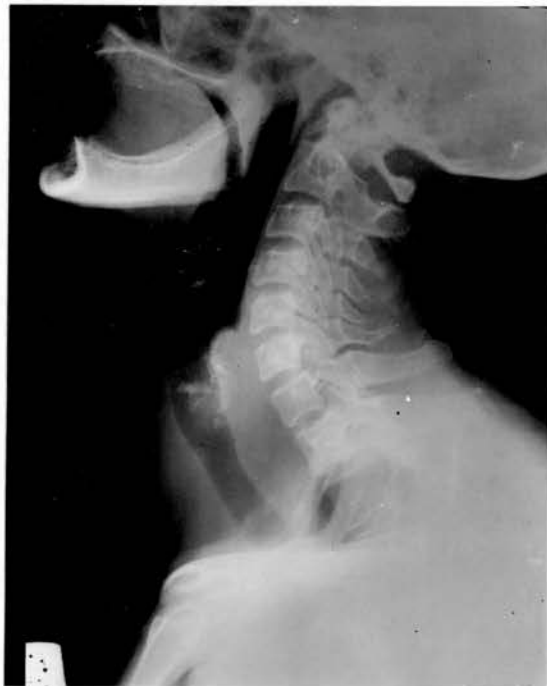

Fig. 31

Mrs. J. B. Antero-posterior and lateral views of neck. Note slight increase in retro-tracheal shadow and antero-posterior narrowing of trachea.

and clinically, many of the features of hyperthyroidism, although remarking on certain anomalies, particularly the persistently low pulse rate. A diagnostic radioactive iodine test was finally carried out, all the indices being within the limits of normal thyroid function:

0-8 hour excretion.....	29.5%
8-24 hour excretion.....	13.5%
24-48 hour excretion.....	5.6%
0-48 hour excretion.....	48.6%
T. index.....	4.5%

The 48 hour gland uptake was 37% of the dose. The 48 hour plasma protein-bound ¹³¹I was 0.2% of the dose per litre.

The patient underwent subtotal thyroidectomy on the 11th April, 1955, from which she made an uneventful recovery, apart from a small serous collection in the wound which resolved spontaneously. The pathological diagnosis was Struma Lymphomatosa and the microscopy is depicted in Figs. 7, 8, 17-19 and 23.

She subsequently exhibited the features of hypothyroidism which were controlled by 2 gr. of dried thyroid extract daily.

Comment. In retrospect it appears extremely unlikely that this patient was, at any time throughout her illness, thyrotoxic. There was no history of any remote toxic episode. Her symptomatology and clinical findings are frequently anomalous and might equally well be referable to an anxiety state induced by the antecedent hysterectomy. A radioactive iodine test at the time of hospitalisation indicated normal thyroid function. Nevertheless two competent physicians had separately considered the possibility of mild thyrotoxicosis and the case illustrates well the difficulties involved.

The final conclusion from a review of this group must be that there is no direct aetiological relationship

/ between

between thyrotoxicosis and Struma Lymphomatosa. To insist, as does Levitt, that the condition invariably represents a phase in the evolution of the degenerating toxic gland is certainly erroneous. To postulate, as did Eason, that the vapid condition of the patient's mentality (when hypothyroid) might preclude a history of remote antecedent thyrotoxicosis is fallacious and inapplicable to the majority of cases. To prove, as Joll suggested, that toxic features might be associated with the onset of the disease is, as has been shown, very difficult and even if so, only relates to a small minority.

(b) Hypofunction

In contrast to the foregoing controversy, there is little or no argument concerning the well-defined relationship between Struma Lymphomatosa and hypofunction of the thyroid. A proportion of patients suffering from this disorder are hypothyroid when they present for treatment, although accurate statistics on this point are relatively few and variable. Thus Joll (1939) had an incidence of pre-treatment hypothyroidism of 35.2%, Marshall et al. (1948) had 11% moderately hypothyroid and 7% markedly so, Statland et al. (1951) considered that only four of their 51 cases showed possible early myxoedema pre-operatively while Lindsay et al. (1952) quoted a figure of 2% in their series of 170 cases. For reasons similar to those encountered when attempting to assess hyperfunction, namely insufficient data, it was impossible in the present

group to define exactly the pre-treatment metabolic state of these patients as it concerns hypofunction, although complaints of hypothyroid symptoms such as lassitude, weight gain, cold sensitivity, etc., were frequently noted. The metabolic end-point of Struma Lymphomatosa, treated or untreated, is hypothyroidism or frank myxoedema and this aspect will be discussed at greater length when dealing with the follow-up of this group of cases.

5. Clinical Assessment of Ovarian Function

Various authors, impressed by the frequency of this disorder in women near or during the menopause, have sought to establish an aetiological relationship between it and loss of ovarian function. Thus Parmley and Hellwig (1946) considered loss of ovarian function the primary factor in the genesis of Struma Lymphomatosa, the effect being mediated through the hypophysis. Schilling (1945) also felt that the excessive demands on the thyroid during the sexual life of the female should be considered fundamental in the aetiology of this disease. Lindsay et al. (1952), on the other hand, compiled data concerning number of pregnancies and history of menstrual irregularities in their large series and contrasted their findings with those from a comparable group of control patients of the same ages and social status, observed over the same period. There were no significant differences. Of the 37 female patients in the present group, 18 were

/ menopausal

menopausal at the time of treatment, 12 were still menstruating, 5 with dysfunction of one kind or another, while in the remaining 7 cases there was no record.

6. Role of Iodine

Reference has already been made to those authors - Warthin; Boyden et al. and Dunkhill - who, in the past, have laid emphasis on the possible influence of iodine medication in the development of Thyroiditis. In only four of the patients in the present group was there a history of iodine administration and in each of these the drug had been given for only a short period pre-operatively as a form of preparation, although one of them had, in addition, been treated with iodine many years previously. The hypothesis that iodine ingestion may have an aetiological significance in Struma Lymphomatosa cannot be seriously entertained.

7. Physical Examination

(a) The Thyroid

Fig. 32 presents the clinical characteristics of the thyroid enlargement in tabular form, as recorded in the present group.

Clinically the gland reflects the gross pathological characteristics already described. Thus it is usually considerably and diffusely, though perhaps asymmetrically, enlarged. On the whole the thyroid shape of the goitre is well preserved in Struma Lymphomatosa and on occasion, the gland as it enlarges, retains and presents the exact

/ anatomical

Extent of involvement	Diffuse (1) Unilateral No record	41) 1)42 0)
Consistence	Soft Firm Hard Variable (2) No record	2) 28) 6)42 4) 2)
Surface	Smooth Lobulated Nodular No record	10) 0) 10)42 22)
Mobility	Free Restricted Fixed No record	33) 3) 2)42 4)
Tenderness	+ - No record (3)	3) 4)42 35)

Fig. 32

Clinical characteristics of the goitre in 42 cases of Struma Lymphomatosa.

- (1) One case recorded clinically as diffuse involvement, was shown at operation to be unilateral.
- (2) i.e. firm with harder areas.
- (3) may be presumed absent.

anatomical form of the thyroid which is immediately obvious on inspection of the neck. This appears to be a feature peculiar to the Hashimoto gland and when present, is virtually pathognomonic.

The surface is smoothly lobulated, although frequently and mistakenly interpreted by the clinician as being nodular. Classically the consistence is uniformly firm or rubbery, although it may be distinctly and unquestionably hard; also the consistence may vary in different parts of the same gland. Mobility is essentially free, although in certain of the larger examples there may be slight apparent restriction of movement. No case in this group exhibited clinical evidence of diffuse extra-thyroid extension of the disease process. Tenderness is an exceptional finding.

Figs. 33 and 34 illustrate one of the patients in the group.

(b) Other findings

Apart from the physical signs in the neck, the remainder of the examination in cases of Struma Lymphomatosa is singularly unrewarding.

The patient may be euthyroid or present an appearance and other findings indicative of varying degrees of hypothyroidism. (Figs. 33 and 34). As previously mentioned, there was never, in this series, convincing physical proof of hyperthyroidism.

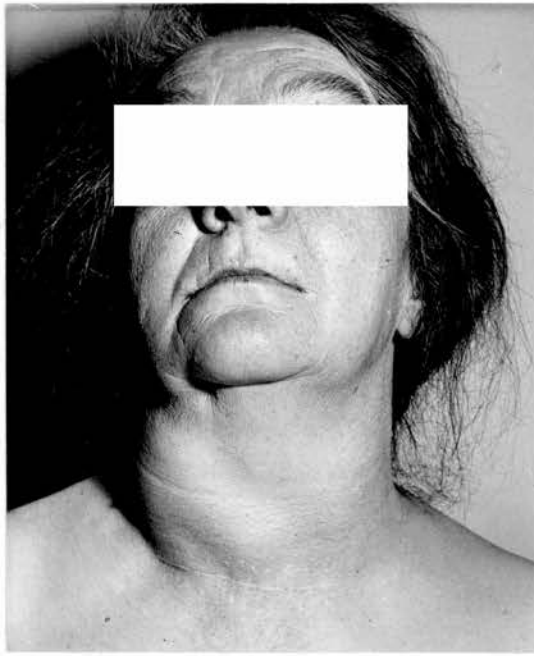

Fig. 33

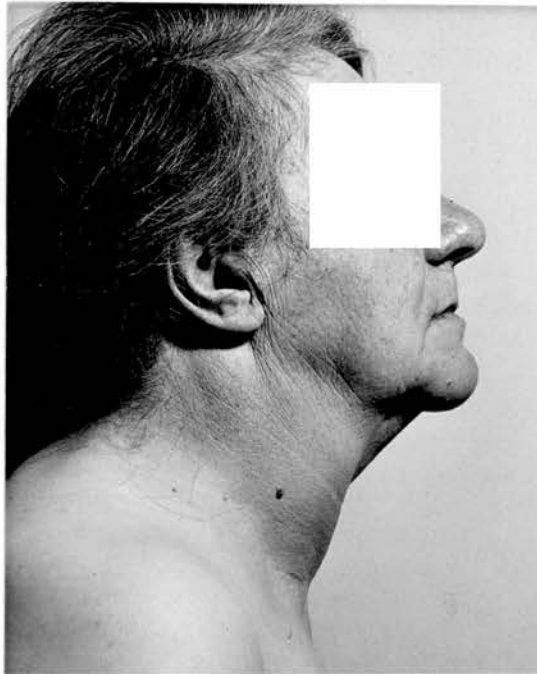

Fig. 34

Mrs. I. P. Age 59 years. Struma Lymphomatosa. Goitre of 2 years duration.
Note hypothyroid facies.

Luxton and Cooke (1956) observed hepatomegaly in one of their patients with Struma Lymphomatosa. The spleen became palpable six years later and clinical evidence of progressing hepatic cirrhosis was confirmed at laparotomy two years after that. Further, persistent splenomegaly sufficient to make the spleen clinically palpable was observed by one of them in six of 24 patients with this disease, confirmed histologically in five of the six cases. They suggest that in this condition the abdomen should always be most carefully examined and that in a doubtful case a palpable spleen would support the diagnosis.

In the present group of 42 cases, a record of abdominal examination was available in only 23 and in 22 of these no abnormality was observed. In the remaining case the liver was palpable one finger-breadth below the costal margin. In no case in which the abdomen was examined was there evidence of splenic enlargement.

Luxton (1957) appeared to find an association, which he considered statistically significant, between Struma Lymphomatosa and Paget's disease of bone. In 35 patients with Struma Lymphomatosa, clinical Paget's disease (confirmed radiologically) was present in three and Paget's disease was discovered radiologically in four others. Luxton was unable to advance any reason for such an association.

These relationships between Struma Lymphomatosa, hepato-splenomegaly and Paget's disease are ill-defined and to date have received no confirmation from other sources.

8. Radiology

In 28 of the 42 cases, antero-posterior and lateral X-ray examination of the neck was carried out. Varying degrees and combinations of tracheal compression and deviation are observed, but the most significant finding, present in 16 of the 28, is the radiological evidence of retro-tracheal extension of the enlarged thyroid. This results in a well defined increase in the pre-vertebral soft tissue shadow and may be associated with distinct forward displacement of the larynx and trachea. Fig. 31 shows a mild degree of this phenomenon, while Fig. 35 illustrates the most extreme example in the group.

This well marked tendency to posterior enlargement of the thyroid in Struma Lymphomatosa is usually insufficiently stressed in writings on the subject. It is, however, not exclusive to this disorder and may be seen in other forms of thyroid enlargement such as malignant disease and thyrotoxic glands showing marked increase of size as the result of prolonged anti-thyroid drug therapy (Fig. 36). As was suggested previously it may play some part in the production of the dysphonia from which a significant proportion of patients with Struma Lymphomatosa suffer.

9. Laryngoscopy

Laryngoscopy was carried out in 25 of the 42 cases. In 22 of these cord movement was normal. In two cases there was early limitation of movement of one cord and in

/ only

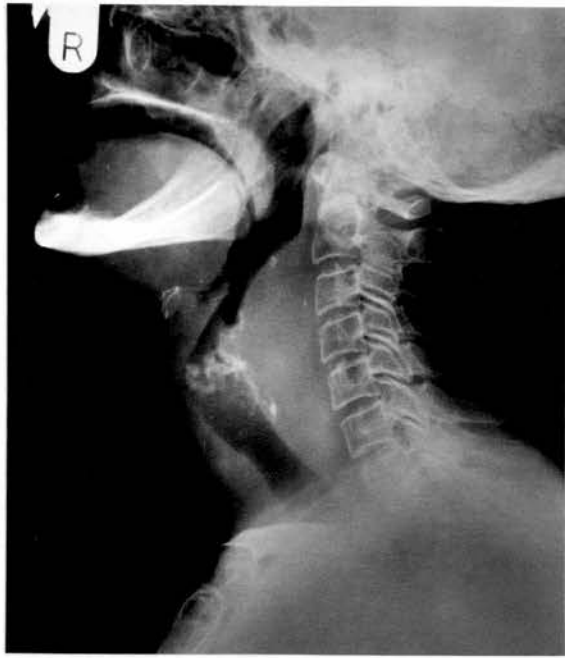

Fig. 35

Lateral X-ray of neck showing marked increase in the pre-vertebral soft tissue shadow and striking forward displacement of the trachea. Same case as Figs. 33 and 34.

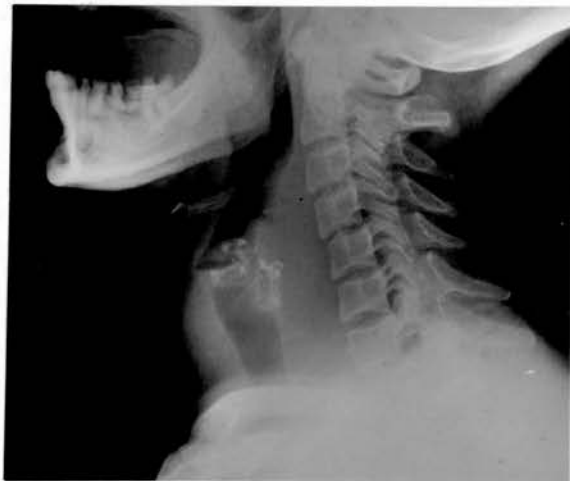

Fig. 36

Lateral X-ray of neck. Thyrotoxicosis. Posterior enlargement resulting from prolonged anti-thyroid drug therapy.

only one case was there established unilateral paresis. These findings reflect the confinement of the pathological process within the capsule of the gland: Joll (1939) had no instance of laryngeal paralysis in his series of cases.

10. The Clinical Diagnosis of Struma Lymphomatosa

A firm goitre which appears in a middle-aged patient, usually a woman, reaches its maximum in a few months, and involves every part of the gland, causes only a moderate degree of dyspnoea, but produces neither serious pressure effects, thyrotoxic symptoms, pain, tenderness, pyrexia nor other inflammatory phenomena, is almost certainly a struma lymphomatosa. If to these features be added the absence of any evidence of involvement of extra thyroid tissues and the presence of some degree of hypothyroidism, the diagnosis is placed beyond a peradventure. (Joll).

While these remarks are essentially true, nevertheless the purely clinical diagnosis of Struma Lymphomatosa is, or rather has in the past, been a matter of no small difficulty. Consultation of recorded series and experience in the present, lend confirmation to this statement. Thus Marshall et al. (1948) had only a correct pre-operative diagnosis of 17% and the figure of 21% given by Lindsay et al. (1952) shows little improvement. Such experience has, in the past, been almost universal. The various clinical diagnoses in the present group of 42 cases are shown in Fig. 37.

While the details given in Fig. 37 undoubtedly do some injustice to the clinical acumen of the surgeon concerned, inasmuch as "possibilities" may have become "certainties" with further clinical observation and the

/ necessary

Clinical Diagnosis	No. of Cases
Struma Lymphomatosa	7
? Struma Lymphomatosa: ? Carcinoma	5
Simple goitre	12
Carcinoma	8
? Simple goitre: ? Carcinoma	3
? Riedel's Thyroiditis: ? Carcinoma	1
Thyrotoxicosis	2
No record	4
TOTAL	42

Fig. 37

Clinical Diagnoses in 42 Cases of Struma Lymphomatosa.

necessary correction not been made in the case record, nevertheless they do illustrate the difficulty involved.

The reasons for such difficulty appear to be twofold. First, the full clinical picture of Struma Lymphomatosa, as described in the foregoing pages, is by no means always present and second, the various symptoms and signs can in no way be regarded as pathognomonic and may be individually or collectively present in other forms of thyroid disease. The two conditions with which Struma Lymphomatosa is most likely to be confused are simple diffuse nodular goitre and malignant disease. From the former of these it is to be differentiated chiefly by the consistence of the enlarged thyroid. Its resemblance to the latter may on occasion be very close, especially in those cases where the goitre is very hard in consistence and where, in addition, pressure effects may be more marked than is usual and perhaps associated with such a suspicious symptom as hoarseness. It must further be recalled that not all cases of malignant disease of the thyroid are associated with such obvious signs of malignancy as extreme fixation and local extra-thyroid extension, severe pressure effects and glandular or more extensive spread. Thus it comes about that in a certain proportion of cases of Struma Lymphomatosa the clinical diagnosis must remain a suspicion rather than an established fact. This will apply particularly to the surgeon or physician who deals only occasionally with thyroid disease.

It is necessary to add that the foregoing remarks apply particularly to an era in which the subject of Thyroiditis as a whole formed an intriguing but nevertheless minor part of the spectrum of thyroid disease. At the present time the spotlight of medical and surgical attention is sharply focused on this problem and there is an increased clinical awareness of the occurrence of these conditions. It is probable that in the future, the clinical diagnosis of Struma Lymphomatosa, mirroring this increased interest and familiarity, will be more frequently and more accurately made than it has in the past. Certainly Thyroiditis is no longer a pathological curiosity and the clinician must ever be mindful of its occurrence.

The differential diagnosis of Struma Lymphomatosa from the other forms of Thyroiditis is one of the major themes of this work and will become increasingly apparent as it progresses.

11. Laboratory Aids to the Diagnosis of Struma Lymphomatosa

Until very recently there were no laboratory aids to the diagnosis of Struma Lymphomatosa, if one excludes estimations of serum cholesterol and determinations of basal metabolic rate, the results of which merely give information concerning the level of thyroid function. Since 1953, however, an ever increasing amount of diagnostic assistance has proceeded from the laboratory so that at present there are a number of such tests which help to confirm or refute

a clinical suspicion of the disease. As has already been pointed out, the present group of cases were investigated and treated between the years 1943 and 1957, that is in a period before the application of these tests became at all general. In consequence of this, personal experience with and results from such investigations are extremely limited in the present group, and of the nine cases whose results are shown in Fig. 38 only the first three are included in it. The remaining six cases, which, however, fulfill the same histo-pathological diagnostic criteria and are therefore suitable for inclusion here, were investigated at a later date. Moreover this would appear an opportune moment to summarise the present position concerning the laboratory diagnosis of Struma Lymphomatosa.

(i) Serum protein abnormalities and serum flocculation reactions

It was Fromm et al. (1953) who first reported the occurrence of raised gamma globulins in Struma Lymphomatosa, when they carried out differential protein estimations in four cases of this disease. Reference has already been made to the work of Cooke and Wilder (1954), Cooke and Luxton (1955) and Luxton and Cooke (1956) whereby they found similar serum protein abnormalities and in addition reported the occurrence of abnormal flocculation tests of liver function in a significant proportion of patients with this disease. Further papers by Skirpan et al. (1955), Skillern et al. (1956) and Doniach and Hudson (1957) all appear to have confirmed the diagnostic value of these tests.

Fig. 38 shows the pre-treatment serum protein findings in nine patients with Struma Lymphomatosa in whom electrophoretic studies were carried out. As will be seen, the principal abnormality in serum protein is an elevation of the gamma globulin level - the average for nine cases being 1.6 g. per 100 ml. (24.7% of total protein); the average for albumin was 3.1 g. per 100 ml. (44.8% of total protein). Doniach and Hudson (1957) found in eleven cases, an average gamma globulin figure of 2.13 g. per 100 ml. (29.3% of total protein) and an average albumin of 2.01 g. per 100 ml. (4.2% of total protein). Skillern et al. (1956) in 20 patients had a gamma globulin range from 0.65 to 2.62 g. per 100 ml. and an albumin range from 2.66 to 4.30 g. per 100 ml.

Tests of liver function dependent on relative concentrations of globulins and albumin have been found abnormal and of diagnostic significance by the aforementioned workers. The colloidal gold and thymol turbidity reactions appear to be most significant in this respect. Thus of nine patients, the colloidal gold reaction was abnormal (1-5) in eight tested, while figures for thymol turbidity ranged from the upper limit of normal in all (4-11 units). (Fig. 38).

(ii) Serological Diagnosis

Reference has already been made to the work of Roitt et al. (1956) whereby, in a preliminary report, they detailed their experience with a serological test for the

/ diagnosis

PATIENT	SERUM CHOLESTEROL MG. PER 100 ML.	SERUM PROTEINS											LIVER FUNCTION TESTS		SEROLOGY			¹³¹ I STUDIES						
		TOTAL PROTEIN G. PER 100 ML.	ALBUMIN		GLOBULINS								COLLOIDAL GOLD	THYMOL TURBIDITY (UNITS)	PRECIPITIN	TANNED CELL	COMPLEMENT- FIXATION	48-HOUR UPTAKE %	48-HOUR EXCRETION	T. INDEX	48-HOUR P.B. ¹³¹ I % OF DOSE PER LITRE	P.B.I. MICRO- GRAMS %	PERCH- LORATE TEST	T.S.H. TEST
			G. PER 100 ML.	%	ALPHA 1		ALPHA 2		BETA		GAMMA													
					G. PER 100 ML.	%	G. PER 100 ML.	%	G. PER 100 ML.	%	G. PER 100 ML.	%												
1. I.P.	210	6.2	2.1	34	0.4	6	0.7	11	0.9	14	2.2	35	5	7	+	+ (1/10 ⁶)	+++	51	49.4	6.0	0.6	3.8	N.R.	N.R.
2. A.B.	257	6.9	3.6	53	0.5	8	0.7	10	0.6	9	1.5	21	1	4	N.R. (1)	N.R.	N.R.	N.R.	N.R.	N.R.	N.R.	N.R.	N.R.	N.R.
3. I.M.	382	6.7	3.5	53	0.4	5	0.4	6	1.0	15	1.4	21	5	7	N.R.	N.R.	N.R.	N.R.	N.R.	N.R.	N.R.	N.R.	N.R.	N.R.
4. I.T.	204	5.8	2.3	39	0.4	7	0.4	6	0.9	16	1.4	24	4	7	+	+ (1/80)	+++	23.6	70.4	3.6	0.6	3.6	N.R.	+
5. I.D.	208	7.3	3.3	46	0.5	7	0.8	11	1.0	14	1.7	23	5	9	+	+ (1/10 ⁴)	+++	43.7	39.6	13	0.8	2.7	N.R.	+
6. B.G.	185	8.1	3.4	42	0.4	5	0.9	12	1.1	14	1.2	27	3	5	+	+ (>1/10 ³)	N.R.	N.R.	N.R.	N.R.	N.R.	3.7	+	N.R.
7. J.F.	284	7.7	3.5	45	0.5	7	0.9	11	1.1	14	1.7	23	2	9	+	+ (1/10)	ANTI- COMPLE- MENTARY	17.8	64.9	3.1	0.3	5.9	N.R.	N.R.
8. A.N.	258	6.2	3.2	52	0.4	6	0.4	7	0.7	11	1.5	25	3	4	+	N.R.	+	31	47.4	3	0.1	4.3	N.R.	N.R.
9. V.L.	214	8.0	3.1	39	0.7	9	1.1	14	1.2	16	1.9	23	N.R.	11	+	+ (>1/10 ³)	ANTI- COMPLE- MENTARY	56.9	32.3	3.2	0.2	N.R.	+	N.R.

(1) NO RECORD

FIG. 38

SERUM PROTEIN ESTIMATIONS, LIVER FUNCTION TESTS, SEROLOGICAL FINDINGS AND ¹³¹I STUDIES IN NINE UNTREATED CASES OF STRUMA LYMPHOMATOSA.

diagnosis of Struma Lymphomatosa, obtaining a specific precipitation reaction between the serum of Hashimoto patients and saline extracts of normal thyroid gland. They suggested that such a precipitation reaction might prove a more specific diagnostic test for Struma Lymphomatosa than serum protein alterations or tests of liver function. Fig. 38 illustrates the application of such serological diagnosis in seven patients using precipitin, tanned cell and complement-fixation reactions, with almost uniformly positive results.

(iii) Radioactive Iodine (^{131}I) Studies

There has, to date, been relatively little experience with radioactive iodine investigation of untreated cases of Struma Lymphomatosa, compared with the now voluminous literature reporting its metabolic behaviour in other forms of thyroid disease. Consequently published reports of its use are conflicting and its value as a diagnostic aid awaits fuller evaluation.

Werner et al. (1949), using direct counting of thyroid uptake, found nothing of diagnostic significance in seven cases of Chronic Thyroiditis and remarked that lack of correlation between ^{131}I uptake and basal metabolism may be found.

Dempsey et al. (1949), using the autoradiographic technique, found no radioactivity in the zones of oxyphilic epithelium in a case of Struma Lymphomatosa. Taylor (1955) found autoradiographic evidence of a discrete and spotty distribution, there being no uptake over the lymphoid areas.

Statland et al. (1951) computed ^{131}I uptake by the thyroid in seven of their cases and found the results to be within the normal range in all but one. In three patients in whom protein-bound iodine (PBI) studies were carried out, the values in two were indicative of hypothyroidism while the third was in the definite myxoedema range. Commenting on autoradiographic findings in three cases, they drew attention to the difficulty encountered in attempting to correlate thyroid histological changes with areas of ^{131}I uptake. Zones composed primarily of degenerating follicles sometimes showed a small amount of darkening of the autoradiograph film where, from the histological appearance alone, it might be supposed that the degree of atrophy would preclude any functional activity. They further suggested that this observation might help to explain the relatively low incidence of frank myxoedema in patients with Struma Lymphomatosa in whom the histological picture alone would indicate a profound diminution in gland function and depression in hormone output.

McConahey and Keating (1951) carried out ^{131}I studies on 13 patients with Struma Lymphomatosa. They found the values normal in most of these, including five who were considered to be clinically myxoedematous at the time of the investigation. They suggested that thyroidal accumulation of ^{131}I in this condition is not a measure of the secretion of thyroid hormone, in view of the failure of the gland to manufacture a normal amount of the latter

/ while

while iodide collection is adequate.

Gribetz et al. (1954) found the total serum protein-bound iodine concentration (PBI) abnormally elevated in three of five cases of Struma Lymphomatosa occurring in adolescent girls. In two of the three, the butanol-extractable, thyroxine-like iodine (BEI) was also measured and found normal. In the light of these findings they suggested that the total serum PBI in such cases is made up to an abnormally large extent of nonbutanol-extractable, calorigenically inactive substances, the result of disordered thyroid hormone synthesis and release.

Skillern et al. (1956) carried out determinations of total serum protein-bound iodine (PBI) in 12 patients with Struma Lymphomatosa. Results were in the low-normal range in nine and in the high-normal range in three. In all, values for butanol-extractable protein-bound iodine (BEI) were low or low-normal. They pointed out that the presence of normal PBI values indicates that this test alone is of little value in assessing the degree of thyroid failure in this condition. BEI determination, which is regarded as a more accurate measure of thyroxine levels than the PBI value, has similar limitations and they remarked that the even greater difficulty in performing the BEI determination further diminishes its value as a routine clinical test at present. Calculating the disparity between PBI and BEI values in their cases, they were less dogmatic than Gribetz et al., and concluded that, while this disparity could be due to the presence of a

/ metabolically

metabolically inactive iodinated protein, they were not prepared to rule out the normal limitation of error of both of these procedures as a factor.

Concerning the thyroidal accumulation of ^{131}I , their results indicated that this is not a satisfactory measure of deficiency of thyroxine production.

Finally they showed that the administration of thyroid-stimulating hormone (TSH) to patients with Struma Lymphomatosa fails to induce a significant increase in the uptake of a second tracer dose of ^{131}I , indicating that the failure is at thyroid and not pituitary level.

Owen and McCahey (1956) investigated 38 patients with Struma Lymphomatosa after the administration of tracer doses of ^{131}I . They found evidence of an unusual iodinated protein of the serum, resembling thyroglobulin and non-butanol-extractable; this iodinated serum protein, not normally present, they failed to identify, but drew attention to similar butanol-insoluble compounds of iodine which have been reported after prolonged administration of Lugol's solution or after the use of ^{131}I for thyroid carcinoma.

In 1957, Morgans and Trotter introduced the perchlorate test as a diagnostic aid in cases of Struma Lymphomatosa. This test indicates defective organic binding of iodine by the thyroid in this condition, which is shown by a progressive fall in the values for thyroid radioactivity (expressed as a percentage of initial radioactivity) at given intervals after a dose of potassium perchlorate has

/ been

been administered. That is, after perchlorate there is a considerable loss of ^{131}I from the gland - evidence of defective organic binding, and this is not seen in other thyroid disorders.

Doniach and Hudson (1957) largely confirmed the experience of the other workers already quoted. In particular they observed a normal or high thyroid uptake of ^{131}I even in the presence of clinical myxoedema and a low basal metabolism. An autoradiographic study of one case showed a uniform distribution of the isotope and they suggested that this explains why topographical surveys in vivo produce isocount pictures which follow the outline of the palpable goitre in Struma Lymphomatosa, whereas in non-toxic nodular and malignant goitres the ^{131}I distribution is uneven and the isocount picture rarely portrays the shape and extent of the gland.

Of the nine patients whose results are shown in Fig.38 ^{131}I studies were performed in seven. 48-hour uptake varied between 17.8% and 56.9%, 48-hour excretion between 32.3% and 70.4% and T index between 3 and 13, in six of the cases. 48-hour plasma protein-bound ^{131}I was estimated in six patients and varied from 0.1% to 0.8% of the dose per litre, showing, in general, a high 48-hour plasma activity. This finding coincides with the results obtained by Doniach and Hudson in four patients and would appear to confirm their suggestion that, in Struma Lymphomatosa, there is a small thyroidal iodine pool with a high activity and rapid turnover. Chemical protein-bound iodine (PBI) was / measured

measured in six of the cases, results being in the low or low-normal range in four and normal in two. The perchlorate test was carried out in only two of the cases and in both gave a positive result, showing a 20% reduction in gland uptake after 400 mg. of potassium perchlorate. Finally the administration of thyrotrophic hormone (TSH) to two patients induced no significant increase in gland uptake of a second dose of ^{131}I .

(iv) Conclusion

Considerable laboratory assistance is now available in the diagnosis of Struma Lymphomatosa. Greatest value attaches to differential serum protein estimations, tests of liver function, serological reactions and ^{131}I studies, all of which should be carried out in combination as individual tests may, on occasion, give misleading results.

12. Role of Thyroid Biopsy

The value and place of thyroid biopsy is difficult to assess in the present state of Struma Lymphomatosa. Certainly, prior to the introduction of the foregoing laboratory aids to diagnosis, it was true to say that the final court of diagnostic appeal was biopsy of the gland and demonstration of the appropriate histo-pathological changes, or alternatively, confirmation by the gross appearance at thyroidectomy and pathological examination of the resected specimen. At present, however, increased familiarity with the clinical picture, additional aids to diagnosis and the conservative management of Struma Lymphomatosa, all militate against operation and there is

/ undoubtedly

undoubtedly a current trend to dispense with biopsy when the diagnosis is clear.

Grile (1951) has advocated the technique of needle biopsy, whereby, using a needle of the Vim-Silverman type, it is possible to core out one or more cylinders of thyroid tissue and so avoid the necessity of a formal biopsy. The method is particularly applicable to the gland of Struma Lymphomatosa, in virtue of its characteristically firm and solid consistence and it is certainly possible to obtain histo-pathological confirmation of the diagnosis in this way. Added attractions are that the method is devoid of technical risk and is carried out under local anaesthesia, so that it is suitable for out-patient investigation. Further, it produces no operative reaction in the neck and does not interfere, as does formal biopsy, with subsequent assessment of the gland's response to conservative therapy.

Against this, however, there are two serious disadvantages. Grile himself has emphasised that the method should not be employed in cases of operable carcinoma because of the danger of implantation of malignancy in the skin and subcutaneous tissues. In the present state of increasing diagnostic accuracy by methods other than biopsy, the cases in which the latter is required are the doubtful ones where there may be a distinct possibility of malignancy, that is the cases in which the technique is to be avoided. Secondly there must be an inherent distrust in placing absolute reliance

on what is, of necessity, a very limited sample particularly in a gland so notoriously pleomorphic in its pathological manifestations as is the thyroid. The relationships between Thyroiditis and malignant disease are not accurately defined and Crile and Fisher (1953) have reported a case illustrating the simultaneous occurrence of Thyroiditis and papillary carcinoma, in which needle biopsy failed to detect the latter. This aspect will be dealt with more fully when the relationship between Thyroiditis and malignancy is discussed at a later stage. For these reasons formal biopsy is to be preferred in the doubtful case.

It seems highly probable that pathological confirmation of the diagnosis in Struma Lymphomatosa will become less essential as laboratory methods become more firmly established.

The Treatment of Struma Lymphomatosa

1. Resection

Hashimoto treated his four cases by subtotal thyroidectomy and until very recently, it is probably true to say that resection has constituted the most popular form of treatment. Thus of the 42 cases in the present group, 35 were submitted to resection in one form or another. Fig. 39 gives the statistics of these cases.

(i) Surgical Details

The gross appearance at operation has already been described when discussing the pathological anatomy of this condition. Of the three cases treated by resection of one

Extent of Resection	No. of Cases	Diagnosis at Operation				Major Complications	
		Struma Lymphomatosa	? Struma Lymphomatosa	Other			
Total	2	0	0	2	? Carcinoma	1	Died
Subtotal	29	16	7	6	No comment	1	Tertiary
Unilateral	3	0	2	1	Toxic	-	-
"Wedge"	1	0	0	1	Riedel	-	-
-	35	16	9	10	-	2	-

Fig. 32

Summary of 35 Cases of Struma Lymphomatosa treated by Resection.

lobe only, two were truly unilateral, while in the third, resection was confined to the larger lobe of a diffusely involved gland. In no case was there evidence of extra-capsular extension of the disease process and this was so even in the most fibrotic gland, diagnosed as Riedel's Thyroiditis and treated by "wedge" resection of portions of both lobes and the isthmus of the thyroid, such a policy being dictated, in the case in question, by the finding of a densely fibrosed gland and the pre-operative knowledge of early paresis of one recurrent nerve. On the contrary, the thyroid resection usually proved an essentially simple technical procedure.

(ii) Diagnosis at Operation

The gross appearance at operation is generally sufficiently characteristic to render possible a confident or suspected diagnosis in a majority of cases - 71.4% in this group. Herein, however, lies the major hazard in the surgical treatment of Struma Lymphomatosa. Occasionally, even by the experienced surgeon, the appearances at operation may be misinterpreted as neoplastic and induce him to perform total thyroidectomy, with the attendant risks of post-operative tetany, recurrent nerve damage and perhaps even, as in one case here, the death of the patient. Such complications are particularly regrettable following a procedure which is neither necessary nor desirable, yet such has been the experience of more than one surgeon in the past.

(iii) Undesirability of Surgical Treatment

While conservative subtotal thyroidectomy has long been the classical method of treatment of this condition, it is not physiologically a desirable therapeutic measure: Joll remarked:- "It is a matter of considerable doubt as to whether surgical treatment is necessary in Hashimoto's disease, assuming that pressure symptoms are slight." The increasing diagnostic accuracy afforded by laboratory methods renders surgical confirmation less necessary and it is no longer true to say that the diagnosis of Struma Lymphomatosa is first made by the pathologist after thyroidectomy. Resection hastens the onset of hypothyroidism, although such a state is the natural metabolic end-point of the disease. Surgery carries a small but definite risk. Finally, the introduction of an effective form of conservative therapy, by the administration of thyroid extract, seems likely to render surgical treatment increasingly unnecessary in the future, although it is as yet too early to claim that surgery has no further part to play in the management of this disorder (*vide infra*).

2. Radiotherapy

The place of radiotherapy in the treatment of Struma Lymphomatosa has never been well documented, opinion as to its efficacy has been controversial and no large series of cases, so treated, exists upon which to draw conclusions.

It will be recalled that Ewing (1922) first remarked upon the subsidence of the thyroid enlargement "under

/ radium"

radium" in one case of this disease. In 1938, Renton et al. first focused attention on the value of radiotherapy in the treatment of Thyroiditis, recording their experience with radium in five cases of what they entitled Riedel's Thyroiditis, but which, as will be shown later, were in fact, clear-cut examples of Hashimoto's disorder or Struma Lymphomatosa. With skin dosage between 1,800 and 4,000 r they observed disappearance of the thyroid enlargement and symptomatic improvement, without tendency to recurrence, in all their cases. Impressed by their results they regarded radium as safe, simple and preferable to surgical treatment. Schilling (1945) stated that Struma Lymphomatosa shows an excellent response to X-ray therapy. Marshall et al. (1948) had not employed irradiation in any of their cases and, while admitting some reports of good results in the literature, were not enthusiastic concerning its use, fearing additional fibrosis and destruction of secreting thyroid tissue. Means (1948), though possessed of little experience, advocated its use, suggesting that the lymphoid nature of the lesion would lead one to expect that irradiation would be effective. Grile (1948) stated that the frequency with which Struma Lymphomatosa will respond to irradiation had not been established. Information concerning the rapidity of response to irradiation has been equally confusing.

(i) Experience with X-ray Therapy

Of the 42 cases in the present group, six were treated by X-ray therapy to the thyroid, following biopsy

/ confirmation

confirmation of the diagnosis. The details of these cases are shown in Fig. 40.

In cases 1 to 5, employing a minimum tumour dose between 2,500 and 4,400 r., no trace of thyroid swelling could be detected clinically at intervals of from $8\frac{1}{2}$ years to $1\frac{1}{2}$ years after treatment. From the data available it proved impossible to determine the exact time at which the goitre disappeared after such treatment, although in all five cases the response was slow, as judged by the fact that in each case complete dispersal of the swelling had not been achieved at the end of treatment and some degree of persistent thyroid enlargement was noted in all at intervals of from one month to two years after therapy. Moreover, the finding of complete disappearance of the goitre in a long term follow-up ($1\frac{1}{2}$ - $8\frac{1}{2}$ years) is of no significance, as each of these patients subsequently exhibited the features of hypothyroidism and was given thyroid extract, which, in the light of present knowledge, may well have contributed to the final and complete resolution of the thyroid enlargement.

The slow response or lack of response of Struma Lymphomatosa to X-ray therapy is well illustrated by Case 6. Figs. 33 and 34 are pre-treatment clinical photographs of this patient, at which time the neck measurement was 41 cms. Figs. 41 and 42 show the appearance four months after a minimum tumour dose of 2,300 r., there having been no response to treatment and the neck measurement remaining unchanged. The patient had received no thyroid extract.

	Patient	Minimum Tumour Dose	Response
1	G.H.	4,400r.	Thyroid impalpable at 8½ years
2	C.P.	3,000r.	Thyroid impalpable at 7½ years
3	W.D.	3,500r.	Thyroid impalpable at 7 years
4	E.W.	3,080r.	Thyroid impalpable at 7 years
5	I.N.	2,500r.	Thyroid impalpable at 1½ years
6	I.P.	2,300r.	Thyroid unchanged at 4 months

Fig. 40

Summary of 6 Cases of Struma
Lymphomatosa treated by
X-ray therapy.

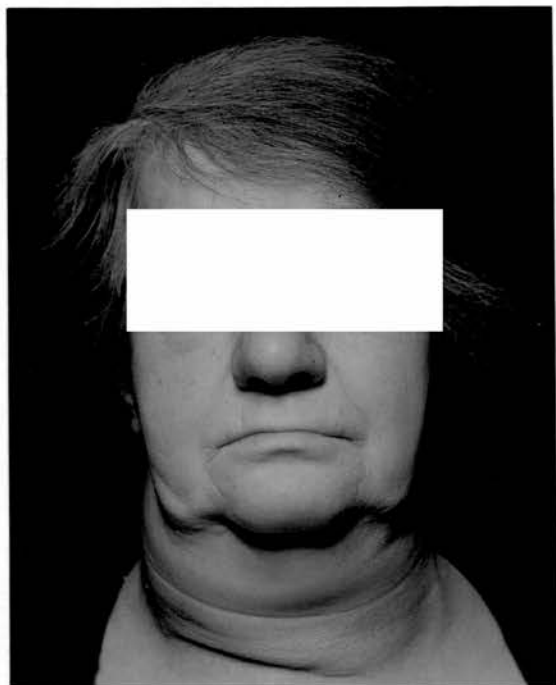


Fig. 41

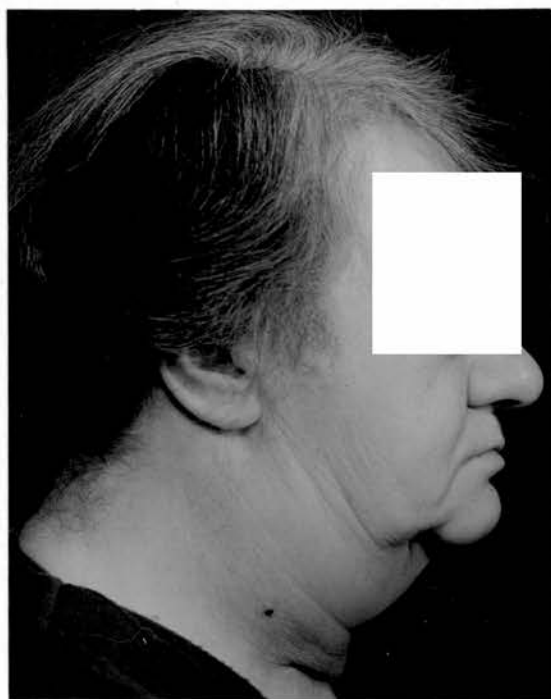

Fig. 42

Mrs. I. P. Age 59 years. Struma Lymphomatosa. Same patient as shown in Figs. 33 and 34, 4 months after 2,300 r. of X-ray therapy to thyroid.

For some reason, the gland of this patient began to shrink thereafter although all treatment was still withheld and when seen seven months after irradiation, there was a very appreciable diminution in the size of the goitre. This regression, starting somewhere between the 4th and 7th months after the therapy and in the absence of any other form of treatment, is difficult to explain.

(ii) Conclusion

By and large it would appear that the goitre of Struma Lymphomatosa is responsive to X-ray therapy, but it is important to realise that the response is slow and in certain cases may be altogether lacking. Attention will be drawn at a later stage to this point, when comparing the response of thyroid carcinoma to radiotherapy. It would seem that the somewhat variable nature of the response in Struma Lymphomatosa may reflect the histopathological composition of the gland in question, those possessing a large proportion of lymphoid tissue presumably exhibiting a better and quicker response than the more fibrotic examples. There is nothing to confirm the experience of Renton et al. (1938) and the suggestion of McSwain and Moore (1943) that irradiation is superior to surgery in the avoidance of subsequent hypothyroidism. As with surgery, irradiation is likely to play an increasingly smaller part in the future management of this disorder, since the introduction of conservative treatment.

3. Treatment by Thyroid Substitution

Statland et al. (1951) first drew attention to the possibility of a conservative management of Struma Lymphomatosa by the exhibition of thyroid extract. They were impressed by the frequency of regrowth of thyroid tissue following surgical ablation in patients not receiving adequate post-operative thyroid substitution therapy. In such patients, the administration of adequate doses of thyroid extract stopped this regrowth of tissue and caused a marked diminution in or clinical disappearance of the gland. They envisaged the primary event in Struma Lymphomatosa as a failure at thyroid cell level which, by resulting in a decreased output of thyroid hormone, induces a secondary pituitary stimulation with resultant increase in gland size. Appropriate thyroid substitution therapy, by raising the level of thyroid hormone, would then, by reciprocal action, depress pituitary activity and thus bring about a regression in the size of the goitre.

Since then Grile and his associates - Grile (1952), Grile and Schneider (1952), Skillern et al. (1956) - have enthusiastically advocated the use of thyroid extract in the treatment of this disorder to the exclusion of surgery and radiotherapy. In most instances, a significant reduction in goitre size was observed although the gland was usually not returned to normal size by this treatment. Most of the reduction occurred within two months and the optimal dosage of desiccated thyroid proved to be 3 gr. daily.

/ Although

Although sufficient time has not yet elapsed to permit of an accurate assessment of the universal efficacy of such treatment in Struma Lymphomatosa, it would appear to represent a more rational therapeutic approach and will, in the future, no doubt be preferred to older and less desirable methods. Nevertheless, it would seem premature at this stage to claim that surgery has no further part to play in the management of this disorder. It is hard to believe, in the light of histo-pathological findings, that the more fibrotic and degenerate examples of the disease can be altogether favourably influenced by such conservative measures and for these surgical ablation may still prove necessary.

Of the present group of cases only one has been submitted to this form of management and insufficient time has yet elapsed to assess the response.

4. Cortisone

As an isolated observation, Crile (1952) has recorded a striking decrease in gland size in one case of Struma Lymphomatosa under cortisone therapy, but there was rapid recurrence when treatment was discontinued.

Follow-up of Cases

Introduction

In the follow-up of any group of cases of Struma Lymphomatosa, the under-mentioned points require investigation.

1. Incidence of hypothyroidism or myxoedema.
2. Recurrent thyroid enlargement.
3. Survival: association with other diseases.
4. Alteration in laboratory tests.

1. Incidence of hypothyroidism or myxoedema

There is a well known association between Struma Lymphomatosa and hypothyroidism or frank myxoedema (Figs. 43 and 44). In the untreated disease, hypothyroid features may exist when the patient first presents and, although information is lacking concerning the natural clinical history of the disorder, it seems highly probable that a hypothyroid state would be the inevitable metabolic end-point if all treatment were withheld. Surgical ablation and possibly radiotherapy, by further removal or destruction of secreting tissue, would appear to hasten the onset of this already inevitable subthyroid state. To aim at a conservative type of operation as has been usually advocated in the past, in the hope of avoiding the "complication" of hypothyroidism, seems to have no intrinsic merit. It would appear that the patient with Struma Lymphomatosa is, in fact, so committed irrespective of the amount of tissue removed, since the pathological process, once established, progresses inevitably through increasing degrees of degeneration to eventual non-function.

Nevertheless, reported figures for the incidence of hypothyroidism following surgical treatment have shown considerable variation: McClintock and Wright (1937), Joll (1939) and Marshall et al. (1948) reported respectively 78.8, 64.8 and 79 per cent. of hypothyroidism following surgery, while Allen and Reeves (1951) quoted the astonishingly low figure of 25 per cent. after subtotal

/ thyroidectomy

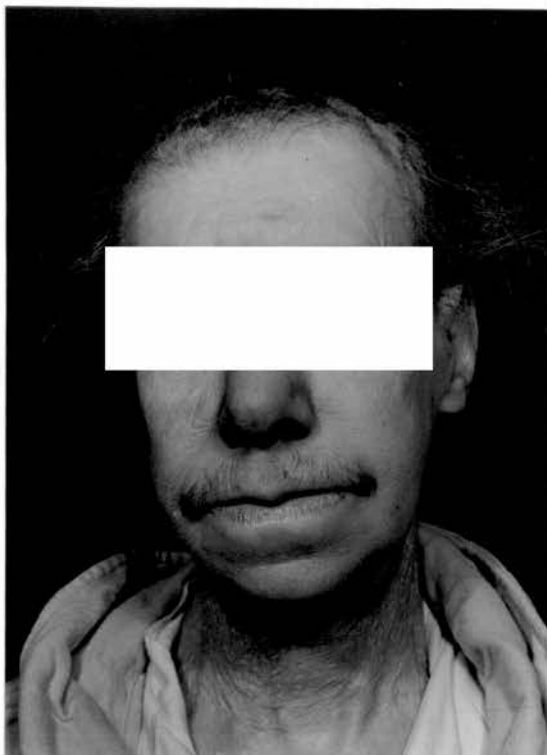

Fig. 43

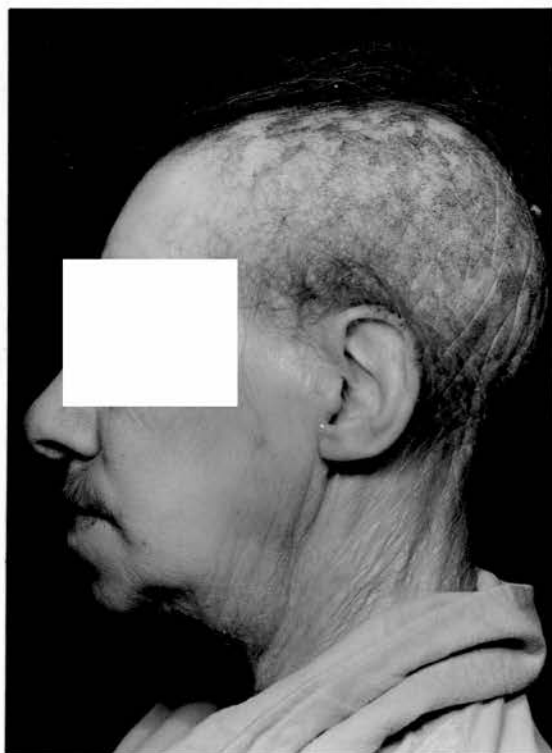


Fig. 44.

Miss M. K. Subtotal thyroidectomy for Struma Lymphomatosa in October 1949. Condition in March 1957. The patient had, at some intervening point, discontinued her thyroid extract.

thyroidectomy for this condition, although a result such as this may well indicate the inclusion of cases which are not true examples of the disease. As has already been suggested, there is nothing to confirm that irradiation is in any way superior to surgery in the avoidance of subsequent hypothyroidism, although accurate statistical evidence for this is lacking.

In the follow-up of the present group of cases, close attention has been paid to the occurrence and incidence of hypothyroid phenomena and where possible a ^{131}I study was carried out.

Method of Follow-up ^{131}I Study

Thyroid medication, if being given and this was usually the case, was withdrawn three to four weeks beforehand, to obviate the effect which such substitution therapy is known to have upon the metabolism of iodine by the thyroid. During the 24 hours immediately preceding the ^{131}I test, thyrotrophic hormone (TSH) was given in order to induce maximal stimulation of any residual thyroid epithelium capable of response and to offset any inhibitory effect of the previous exogenous thyroid extract. The TSH preparation used was Thytropar (Armour) - the highly purified, lyophilized thyrotrophic principle of bovine anterior pituitary gland. This was administered in a total dosage of 10 USP units. (25 mg.) dissolved in 3 ml., 1 ml. of the solution being given hypodermically in 3 eight hourly injections.

^{131}I in doses of 5-10 microcuries was then given and

/ the

the 48 hour urine excretion pattern was determined according to the techniques of Fraser et al. (1953). Divided collections of the 0-8 hour, the 8-24 hour and the 24-48 hour fractions were made and the index T calculated according to the formula -

$$T = \frac{(0-8 \text{ hour excretion as \% of dose}) \times 100}{(8-24 \text{ hour \%}) \times (0-48 \text{ hour \%})}$$

Using such methods, patients with normal thyroid function have an excretion over 48 hours of between approximately 35% and 70% of the administered dose, and the T index usually lies between 2.7 and 10.0.

Hypothyroidism, or definitely subnormal thyroid function, is usually associated with higher total 48 hour excretion figures, the range being about 55% to 95%, but the more characteristic feature is an alteration in the pattern of excretion such that the 8-24 hour fraction exceeds 20% of the dose, and the T index is below 2.5.

The results obtained were as follows:-

- (1) After subtotal resection (29 cases; effective follow-up possible in 24).

Fig. 45 shows the follow-up details of the 29 cases treated by subtotal resection, the effective follow-up period, excluding Case 29, ranging from 1 to 11 years. No details were available in three of the cases while a fourth died one year after treatment: reference to this case is made later. Of the remaining 24 cases, 21 showed unmistakable clinical evidence of hypothyroidism at varying intervals after surgery, there being no positive available record of its development in the other three, although

/ these

NO.	PATIENT	POST-OPERATIVE CLINICAL HYPOTHYROIDISM	THYROID SUBSTITUTION THERAPY		ASSESSMENT AT	THYROID GLAND	SERUM CHOLESTEROL MG. PER 100 ML.	151I FOLLOW-UP		T INDEX		
			STARTED AT	PRESENT DOSE GR. PER DAY				0-8 HR. FRACTION % DOSE	8-24 HR. FRACTION % DOSE		2 1/2-48 HR. FRACTION % DOSE	0-48 HR. FRACTION % DOSE
1.	J.P.	NO DETAILS	NO DETAILS	3	11 YRS. POST-OP.	IMPALPABLE	228	33.6	33.9	20.8	88.3	1.1
2.	G.H.	+	6 MTHS. POST-OP.	1 1/2	" " " "	"	310	17.1	28.2	17.0	62.3	1.0
3.	C.R.	+	" " " "	NO DETAILS	" " " "	"	220	36.0	28.4	13.8	76.2	1.6
4.	E.C.	+	2 " " "	2	" " " "	"	279	32.7	31.3	15.7	79.7	1.3
5.	H.G.	+	3 " " "	NO DETAILS	" " " "	"	302; 426	13.6	33.4	21.2	68.2	0.6
6.	J.P.	+	2 YRS. " " "	1	" " " "	"	297	35.7	18.4	15.3	69.4	2.8
7.	J.S.	+	2 MTHS. " " "	1	" " " "	"	176	46.0	25.5	25.1	96.6	1.9
8.	H.F.	+	1 " " "	1 1/2	" " " "	"	243	39.2	32.4	15.0	86.6	1.4
9.	C.S.	+	2 " " "	1 1/2	" " " "	"	NOT DONE	31.1	34.6	15.7	81.4	1.1
10.	H.R.	+	1 MTH. POST-OP.	NO DETAILS	NO FOLLOW-UP POSSIBLE							
11.	H.B.	+	4 " " "	NO DETAILS	5 1/2 YRS. POST-OP.	NO DETAILS	NOT DONE	NOT DONE	NOT DONE	NOT DONE	NOT DONE	
12.	R.J.	+	NO DETAILS	1 1/2	" " " "	IMPALPABLE	NOT DONE	51.9	30.3	10.7	92.9	1.8
13.	J.S.	+	NO DETAILS	1 1/2	" " " "	"						
14.	R.P.	+	5 MTHS. POST-OP.	DISCONTINUED	" " " "	"	NOT DONE	35.5	24.2	16.4	76.1	1.9
15.	A.D.	+	3 MTHS. POST-OP.	1	NO FOLLOW-UP POSSIBLE							
16.	A.H.	+	3 " " "	1	1 1/2 YRS. POST-OP.	IMPALPABLE	279	28.2	34.1	20.5	82.8	1.0
17.	E.O'N.	+	3 " " "	2	1 1/2 " " "	"	472	31.8	33.9	16.0	81.7	1.2
18.	R.M.C.	+	NO DETAILS	NO DETAILS	NO FOLLOW-UP POSSIBLE - DIED 1 YR. POST-OP.							
19.	I.D.	+	3 MTHS. POST-OP.	1	3 1/2 YRS. POST-OP.	IMPALPABLE						
20.	H.M.C.	+	2 " " "	2	" " " "	"	250	36.4	33.8	5.4	75.6	1.4
21.	A.S.	+	3 " " "	2	2 1/2 " " "	"						
22.	J.R.	+	3 " " "	2	2 1/2 " " "	"	346					
23.	J.B.	+	5 " " "	1	2 1/2 " " "	"	NOT DONE	32.8	24.9	14.2	71.9	1.8
24.	A.L.	+	NO DETAILS	NO DETAILS	NO FOLLOW-UP POSSIBLE							
25.	A.B.	+	1 MTH. POST-OP.	NO DETAILS	2 YRS POST-OP.	IMPALPABLE	199	36.5	30.5	16.0	85.0	1.5
26.	G.D.	+	1 " " "	1	2 " " "	"	368	14.6	24.5	9.8	48.9	1.2
27.	J.B.	+	NO DETAILS	NO DETAILS	1 " " "	"	217	32.9	11.1	39.0	83.0	3.6(1)
28.	G.B.	+	1 MTH. POST-OP.	1 1/2	1 " " "	"						
29.	I.M.	+	9 DAYS " " "	1	2 MTHS. POST-OP.	"	294					

FIG. 45

DETAILS OF FOLLOW-UP OF 29 CASES OF STRUMA LYMPHATOSA TREATED BY SUBTOTAL THYROIDECTOMY.

(1) 131I test suspect - see text.

these latter had taken thyroid extract continuously thereafter and were found to be hypothyroid at the time of final assessment.

In three cases there was no accurate record of the interval elapsing between resection and the institution of thyroid extract: in the remaining 21 cases the time varied from one month to two years, with an average of four months.

Of the 24 cases, all but one were receiving thyroid extract at the time of final assessment and had taken it continuously in the intervening period: the one exception, Case 14, had shown clinical evidence of hypothyroidism and been started on thyroid extract five months after operation, but had thereafter discontinued the drug: a ¹³¹I study in this patient, five years after operation, gave figures indicative of subnormal thyroid function.

In 17 of the cases, the daily dose of thyroid extract being taken at the time of final assessment varied between $\frac{1}{2}$ and 3 gr., an accurate knowledge of dosage was lacking in six cases, while the remaining case had, as has been mentioned, discontinued the drug.

Of the 15 patients in whom serum cholesterol estimations were performed, thyroid extract having been withdrawn three to four weeks beforehand, values ranged from 176 to 472 mg. per 100 ml. and were mostly in the myxoedema range.

¹³¹I follow-up studies were obtained, according to the

/ method

method described above, in 18 of the cases. The 8-24 hour fraction ranged from 11.1% to 34.6% and in all but two cases exceeded 20% of the dose. The total 48 hour excretion figures ranged from 48.9% to 98.6%, while the T index lay between 0.6 and 3.6, being below 2.5 in all but two cases.

(The ^{131}I test in Case 27 must be regarded as suspect. The curve is not a smooth one. The 8-24 hour fraction is unduly low, presumably due to mixing of urines, and the T index correspondingly high: thyroid extract had been discontinued four weeks before the test and in the interval this patient had developed gross clinical evidence of hypothyroidism.) In the six cases in which a ^{131}I follow-up study was not obtained, all had shown clinical evidence of hypothyroidism after operation and had taken thyroid extract continuously thereafter.

Thus in 21 of the 24 cases in which effective follow-up was possible, there was clinical and/or ^{131}I evidence of hypothyroidism following subtotal thyroidectomy (87.5%). In two cases - Nos. 6 and 14 - the clinical and ^{131}I findings showed a discrepancy. In one case - No. 27 - there was a similar discrepancy, but the ^{131}I test must be regarded as suspect and the patient as being, in fact, hypothyroid.

(ii) After other forms of surgery (6 cases: relevant or effective follow-up in 4).

Fig. 46 shows the follow-up details of the six cases treated by other forms of surgery. Two of those were treated by total thyroidectomy and do not merit consideration in the present connection.

NO.	PATIENT	POST-OPERATIVE CLINICAL HYPOTHYROIDISM	THYROID SUBSTITUTION THERAPY		ASSESSMENT AT	THYROID GLAND	SERUM CHOLESTEROL MG. PER 100 ML.	131I FOLLOW-UP				T INDEX
			STARTED AT	PRESENT DOSE GR. PER DAY				0-8 HR. FRACTION % DOSE	8-24 HR. FRACTION % DOSE	24-48 HR. FRACTION % DOSE	0-48 HR. FRACTION % DOSE	
1.	N.B.(1)	NO DETAILS	NEVER TAKEN	THYROID	9 YRS. POST-OP.	"NO FURTHER TROUBLE"		NOT DONE				
2.	W.F.(2)	" "	1 YR. POST-OP.	1/2	" "	IMPALPABLE	257	25.7	11.0	68.8	1.8	
3.	C.B.(1)	" "	NEVER TAKEN	THYROID	4 1/2 " "	" "	NOT DONE	11.0	6.1	72.6	6.9	
4.	M.O.C.	" "	3 MTHS. POST-OP.	2	3 YRS. POST-OP.	IMPALPABLE	243	35.3	17.0	65.8	0.6	
5.	J.M.	" "			NO FOLLOW-UP POSSIBLE	DIED 3 YRS. POST-OP.						
6.	J.R.	" "			NO FOLLOW-UP POSSIBLE	OPERATIVE DEATH						

FIG. 46

DETAILS OF FOLLOW-UP OF 6 CASES OF STRUMA LITHIPHANOSA TREATED BY "WEDGE", UNILATERAL AND TOTAL RESECTION

- (1) Unilateral glandular involvement.
- (2) Diffuse glandular involvement.

CASES 1-3 - UNILATERAL RESECTION
CASE 4 - "WEDGE" RESECTION
CASES 5 and 6 - TOTAL RESECTION

One case - No. 4 - with a diffusely involved, fibrotic gland and treated by "wedge" resection of portions of both lobes and the isthmus, gave subsequent clinical and ^{131}I evidence of hypothyroidism.

One case - No. 2 - with a diffusely involved gland but treated by resection of the more enlarged lobe only, likewise gave subsequent clinical and ^{131}I evidence of hypothyroidism.

Two cases - Nos. 1 and 3 - noted at operation to have involvement of one lobe only, the other being normal to naked-eye inspection and treated by resection of the affected lobe, have apparently remained euthyroid, there being ^{131}I evidence to support this in one of them $4\frac{1}{2}$ years after operation. It would appear that in these cases, the residual thyroid tissue has remained free from disease and continued to subserve normal metabolic requirements.

(iii) After radiotherapy (6 cases: effective follow-up possible in 4).

Fig. 47 shows the follow-up details of the six cases treated by irradiation. Case 6 is excluded as affording insufficient time for effective follow-up.

In one case - No. 2 - thyroid extract was started before treatment, no subsequent ^{131}I follow-up was obtained and thus no proper conclusion can be drawn.

The remaining four cases gave subsequent clinical and/or ^{131}I evidence of hypothyroidism following irradiation treatment.

NO.	PATIENT	POST-IRRADIATION CLINICAL HYPOTHYROIDISM	THYROID SUBSTITUTION THERAPY		ASSESSMENT AT	THYROID GLAND	SERUM CHOLESTEROL MG. PER 100 ML.	131I FOLLOW-UP				T INDEX	
			STARTED AT	PRESENT DOSE GB. PER DAY				0-8 HR. FRACTION % DOSE	8-24 HR. FRACTION % DOSE	2 1/2-48 HR. FRACTION % DOSE	0-48 HR. FRACTION % DOSE		
1.	G.H.	+	3 YRS. POST-IRRAD.	1 1/2	8 1/2 YRS. POST-IRRAD.	IMPALPABLE							
2.	C.P.	—	BEFORE TREATMENT	3	" "	"			NOT DONE				
3.	M.D.	+	4 MTHS. POST-IRRAD.	1	" "	"	169	31.7	31.4	16.9	80.0	1.3	
4.	E.W.	NO DETAILS	6 " " "	NO DETAILS	7 " " "	"	287	26.9	34.0	20.1	83.0	1.0	
5.	I.N.	+	10 " " "	" "	1 1/2 " " "	"			NOT DONE				
6.	I.P.	-	-	-	1 1/2 MTHS. " "	UNCHANGED	210	33.0	10.9	5.5	49.4	6.0	

FIG. 47

DETAILS OF FOLLOW-UP OF 6 CASES OF STRUMA LYMPHOMATOSA TREATED BY IRRADIATION

(iv) Conclusion

From Figs. 45, 46 and 47 comprising 39 cases of Struma Lymphomatosa in which the thyroid gland was diffusely involved and treated by surgery or irradiation, effective follow-up was possible in 30. Of these 30 cases, 27 or 90% subsequently exhibited subnormal thyroid function as determined by clinical evidence and/or ^{131}I studies. Such figures would appear to confirm the statements made in the opening paragraphs of this section.

Two cases (Fig. 46) with apparent unilateral disease and treated by resection of the affected lobe only, remained euthyroid.

2. Recurrent thyroid enlargement

Joll (1939) considered recurrence after operation most unusual and stated that when it occurs it is due usually to the bilateral nature of the goitre not having been recognised, resulting in a unilateral resection and necessitating a further intervention on the contralateral side. He further advanced in explanation that in an asymmetrical goitre (based on congenital asymmetry of the thyroid gland) one large lateral lobe may so overshadow the other smaller lobe that the latter is allowed to remain undisturbed, and the fact that it is equally affected pathologically is not recognised.

While such an explanation undoubtedly accounts for a number of the cases in which second operations have been necessary, nevertheless there are well-defined instances in the literature - Hellwig (1938) and Statland et al. (1951) -

in which, despite adequate subtotal resection of the gland, regrowth occurred and necessitated further intervention.

Statland et al. had seven instances of regrowth of thyroid tissue following surgery for Struma Lymphomatosa - an unusually high figure. As has already been mentioned it was this finding which led these authors to infer that recurrence might be due to failure of adequate post-operative thyroid substitution therapy and so to their suggestion of a primarily conservative management of the disease by the exhibition of thyroid extract. Nevertheless examples may be found in the literature where regrowth occurred following adequate surgery and while the patient was receiving thyroid.

In the present series no instance of recurrent thyroid enlargement was noted following subtotal resection, other forms of surgery and irradiation treatment over a follow-up period ranging from 1 to 11 years. Indeed in all cases the gland was impalpable at the time of final assessment. (Figs. 45, 46 and 47). This includes one case (No. 2, Fig. 46) with diffuse involvement of the gland, but treated by resection of the larger lobe only. All of these patients had taken thyroid extract continuously and in adequate dosage following treatment and in the light of present knowledge this may well have proved a factor in the prevention of recurrence. The same is true, however, of the two unilateral cases (Nos. 1 and 3, Fig. 46) who had never taken thyroid and of the one case (No. 14, Fig. 45) with diffuse involvement who had only taken the drug for

a short period and thereafter discontinued it.

3. Survival: association with other diseases

There were three deaths in the present group of cases. The first of these (No. 6, Fig. 46) was an operative death in an elderly male patient and occurred 48 hours following total thyroidectomy which was carried out in the mistaken belief that the thyroid enlargement was malignant, death resulting from a combination of pulmonary insufficiency and cardiac failure in a poor risk subject. Reference has already been made to the danger of mistaking Struma Lymphomatosa for malignancy at operation and to the occasional regrettable sequelae of the ensuing total resection, of which this case is an example.

The second death was also in a male patient who had likewise undergone total thyroidectomy (No. 5, Fig 46). In this case, however, death resulted from a severe pneumonia three years later and was quite unrelated to the original disease or its treatment.

The third of these patients (No. 18, Fig. 45) is of greater interest and merits closer consideration: discussion of this case is, however, deferred for the present and appears in Part VI, p. 289.

Reference has already been made to the observations of Luxton and Cooke (1956) and Luxton (1957) who have drawn attention to a possible association of Struma Lymphomatosa with both hepato-splenomegaly and Paget's disease of bone. Neither of these points were, however, investigated in the follow-up of the present group of cases.

4. Alteration in laboratory tests

(i) Following treatment with thyroid extract

The exhibition of thyroid extract in optimal dosage not only produces a regression in size of the goitre of Struma Lymphomatosa, but causes a reversal to normal of the disordered serum proteins and serum flocculation reactions - Luxton and Cooke (1956) and Skillern et al. (1956). The time taken to achieve such a result, however, apparently varies widely and may occupy many months - in one case reported by Luxton and Cooke, tests were grossly abnormal when first recorded 61 months after the start of thyroid and remained so for at least 35 more months, while in a number of other cases reversal to normal was not observed until periods of two years or more had elapsed from the start of treatment.

(ii) Following surgery

Luxton and Cooke (1956) investigated six patients previously treated by partial thyroidectomy and before thyroid extract was started. Flocculation reactions were grossly abnormal in three, at intervals of 13 and 16 months and nine years after operation. In one case these reactions were very slightly abnormal 11 days after operation, while in the remaining two they were negative at $3\frac{1}{2}$ and 5 year intervals respectively.

Doniach and Hudson (1957), in their post-operative survey, found the serum proteins normal in most cases of Struma Lymphomatosa after removal of the goitre and in two cases had actual proof of the change from high pre-operative

gamma globulins to normal values after operation.

Although they preferred to regard the abnormal gamma globulins as being closely associated with the presence of the goitre, they likewise found a lag before reversal took place and, believing an immune reaction to be involved, suggested that, while the source of antigen may be removed at thyroidectomy, there might be some delay in the cessation of antibody production by the reticulo-endothelial system.

(iii) Fig. 48 shows the follow-up serum protein estimations and liver function tests in six cases of Struma Lymphomatosa. Four of these are currently under treatment with thyroid extract in what is considered optimal dosage, while the remaining two have had subtotal thyroidectomy as the primary treatment. While the number of cases is small and the duration of follow-up short, the general trend among the conservatively treated cases is towards a reversal of the initially abnormal findings. In Case 9, however, gamma globulin levels, colloidal gold and thymol turbidity tests are still grossly abnormal nine months after the start of thyroid extract. Of the two cases treated by subtotal thyroidectomy, Case 5 is of interest in showing an apparently rapid reversal of the previously abnormal tests.

Summary

In Part II, the clinical and pathological aspects of a homogeneous group of 42 cases of Struma Lymphomatosa have been reviewed. Much emphasis has been laid on the histopathological picture of the established disease and in

/ particular

PATIENT	SERUM CHOLESTEROL		SERUM PROTEINS										LIVER FUNCTION TESTS	
	MG. PER 100 ML.	G. PER 100 ML.	ALBUMIN		GLOBULINS						COLLOIDAL GOLD	THYROID TURBIDITY (UNITS)		
			G. PER 100 ML.	%	ALPHA 1		ALPHA 2		BETA				GAMMA	
					G. PER 100 ML.	%	G. PER 100 ML.	%	G. PER 100 ML.	%			G. PER 100 ML.	%
2.A.B. 1 mth. 2 mths. 6 mths. 11 mths.	257 302 202 207 223	6.9 7.3 7.3 6.0 6.1	3.6 4.2 4.2 2.9 4.3	53 57 58 49 70	0.5 0.4 0.3 0.4 0.2	8 5 4 7 3	0.7 0.5 0.4 0.6 0.2	10 7 6 10 3	0.6 0.7 0.6 0.7 0.5	9 9 9 11 8	1.5 1.5 1.7 1.4 0.9	21 21 23 23 15	1 4 N.R.(2) 0 0	4 7 2 3 3
3.I.M. 1 mth. 1½ mths.(1)	382 294	6.7 6.9	3.5 2.9	53 42	0.4 0.6	5 8	0.4 0.6	6 9	1.0 0.8	15 11	1.4 2.1	21 30	5 N.R.	7 3
4.I.T. 1 mth. 2 mths.	204 260 254	5.8 7.1 6.3	2.3 3.4 3.3	39 49 53	0.4 0.5 0.4	7 7 6	0.4 1.2 0.5	6 14 7	0.9 1.1 0.8	16 16 13	1.4 1.1 1.3	24 15 21	4 0 1	7 7 9
5.I.D. 1 mth. (1) 1 mth. 2 mths.(1)	208 268 230	7.3 6.1 5.3	3.3 3.1 3.6	46 52 69	0.5 0.5 0.2	7 8 3	0.8 0.6 0.2	11 10 4	1.0 0.9 0.5	14 15 10	1.7 1.0 0.8	23 16 15	5 0 1	9 5 3
6.B.G. 3 mths.	185 230	8.1 6.0	3.4 2.8	42 47	0.4 0.4	5 7	0.9 0.6	12 9	1.1 0.9	14 15	1.2 1.3	27 22	3 0	5 9
9.V.L. 1 mth. 4 mths. 9 mths.	214 169 N.R. 245	8.0 7.6 8.2 7.6	3.1 2.8 3.3 2.8	39 37 40 37	0.7 0.4 0.4 0.4	9 6 4 5	1.1 0.8 0.7 0.6	14 11 9 8	1.2 0.9 1.0 1.0	16 12 12 13	1.9 2.6 2.9 2.8	23 35 35 37	N.R. N.R. 5 5	11 N.R. 8 15

Fig. 48

Follow-up Serum Protein Estimations and Liver Function Tests in 6 Cases of Struma Lymphomatosa. (See also Fig. 38)

(1) months after subtotal thyroidectomy.

(2) no record.

particular on the prevalence of the distinctive Askanazy epithelial structure, the pleomorphic nature of the changes and the frequent occurrence of widespread fibrosis - all features which would appear to have received insufficient attention in previous writings upon the subject. From the clinical viewpoint, the disease is presently passing through a phase of transition and it will be some time before the full significance of such aspects as the recently discovered laboratory aids to diagnosis and the conservative approach to treatment can be evaluated. Indeed there is already some evidence that positive serological reactions, similar to those encountered in Struma Lymphomatosa, may also be obtained in a rather wider spectrum of thyroid disease, notably cases of thyrotoxicosis. Moreover the foregoing review cannot be regarded as in any sense complete, as certain clinico-pathological variations from the classical picture of Struma Lymphomatosa would appear to exist and these must now be discussed.

PART III

SOME FURTHER OBSERVATIONS ON STRUMA LYMPHOMATOSA

Variations in the Pathological and
Clinical Picture

Introduction

In the introduction to Part II it was explained how the 42 cases in that group were assembled and diagnosed as examples of Struma Lymphomatosa solely on the basis of the histo-pathological findings in the resected thyroid or portion thereof and without reference to their clinical features. For this purpose, multiple sections from each gland were examined. Furthermore, great stress was laid, as a diagnostic feature, on the presence in these glands of what has been termed and repeatedly referred to as the Askanazy change affecting the thyroid epithelial structure. In that group of cases, this change was found to be universally present whenever thyroid vesicular structure was well retained, while in those examples displaying more advanced degeneration and disintegration, often with fibrosis, it could be demonstrated in the residual areas of parenchymal preservation. In the group as a whole, therefore, although there was encountered an undoubted and important intrinsic pleomorphism in the histo-pathological picture based on varying degrees of degeneration and fibrotic replacement, the universal epithelial change was of the Askanazy type and this to the complete exclusion of any other normal or pathological thyroid parenchymal appearance. At the same time, however, it was suggested that to employ and impose such an apparently restricted diagnostic criterion - to say in effect, "No universal Askanazy change, no Struma Lymphomatosa" - might be injudicious and the

/ purpose

purpose of the present section is to attempt to throw some further light on the pathology of this condition by reference to the findings in a further group of 18 cases investigated and treated, as were those in Part II, in the charge of Mr. K. Paterson Brown in the Royal Infirmary of Edinburgh between 1st October, 1943 and 31st March, 1957.

Even today, the histo-pathological changes of Struma Lymphomatosa are ill understood and described. As early as 1912, Hashimoto, in his original publication, observed a variation in the histo-pathological findings in his four cases and it would seem pertinent at this point to reproduce again some extracts from his observations:-

All our four cases show a uniform anatomico-pathological condition. The second and third cases in particular stand out by reason of specially instructive variations. As far as the infiltration of the tissue by round cells and the parenchymatous degeneration are concerned, Case 4 is most seriously attacked. The lymphoid follicles are strikingly well developed in Cases 2 and 3. As Cases 2 and 3 in general present a well developed picture of the disease, I should like to occupy myself chiefly with these two cases in what is to follow. Case 4 offers a picture which differs somewhat from the three others, yet it is to be interpreted as nothing other than an advanced change.

If we look through the anatomico-pathological findings of our four cases, we can immediately discover corresponding changes, even if such changes show differences of degree. In Case 1, the change in the vesicles is very slight, as one comes across them well filled with colloid, provided with almost normal follicles and with well preserved epithelial cells. Here, however, the vesicles are not as big as we are accustomed to see them in a marked colloid struma. In Cases 2 and 3 the vesicles are changed in typical fashion. They show epithelial cells which are inclining to depopulation, atrophied vesicle remains and abnormal content. In Case 4 the vesicles are generally small, atrophic, with little colloid substance and abnormal content.

The round cell infiltration is only slight in

Case 1, moderate in Cases 2 and 3, but in Case 4, strikingly pronounced. These round cells consist of mononuclear lymphocytes as well as plasma cells. The lymphoid follicles are present in moderate abundance in Case 1, in Cases 2 and 3 they are very plentiful. The proliferation of connective tissue is barely to be demonstrated at all in Case 1, whereas in Cases 2 and 3 it has developed pretty intensively and in Case 4, very vigorously. The change of the parenchyma is only slight in Case 1, moderate in Cases 2 and 3, and in Case 4 very advanced.

Interpreting these observations, Cases 2, 3 and 4 would appear to confirm the intrinsic pleomorphism of the histo-pathological picture of Struma Lymphomatosa to which reference has already been made and which has been amply illustrated in Part II. In Case 1, however, Hashimoto has described a gland in which the change in the vesicles was very slight, where they were well filled with colloid although not of a size such as is seen in a colloid struma, where the round cell infiltration was only slight and the proliferation of connective tissue barely demonstrable. In the light of what is to follow it seems probable that this case may be analogous to some of those about to be described in this section.

More recently, Crile and Hazard (1951), Crile (1952) and Crile and Schneider (1952) have described a condition of Lymphoid Thyroiditis which they have regarded as either an early phase of Struma Lymphomatosa or an entirely different entity. It is reputed to show the same lymphocytic infiltration and the presence of germinal follicles as does Struma Lymphomatosa, but fibrosis is minimal or absent and the oxyphilic epithelium, i.e. Askanazy change, is not seen. It has been found predominantly in

/ females

females, in the age group from 20-40. These authors have not, however, given any detailed account of the histopathological changes in the glands of these patients and it is by no means certain that it is correct to split off a separate group in this way.

Skillern et al. (1956) refer to a division of their cases of Struma Lymphomatosa into those with and those without oxyphilia of the epithelium, but fail to elaborate upon the histopathological minutiae of the latter group. The same is true of the findings of Harland and Frantz (1956), who, in 116 cases of this disease, found 70 with diffuse oxyphilia and 46 with little or no oxyphilia.

These findings would seem to indicate that, from the histopathological point of view, Struma Lymphomatosa is divisible into two groups, the first and larger of the two characterised by diffuse Askanazy epithelial change and with reasonably well understood microscopical appearances and a second and smaller group with little or no Askanazy change and with, to date, no minute description of the alternative parenchymal appearances. Beyond these observations, however, no serious attempt has been made in the last few years to add to our knowledge of the histopathology of Struma Lymphomatosa, regarding which much confusion still exists.

The 18 cases which provide the material for the present study are divided into two groups.

Group 1 - 14 Cases

Histo-pathology

The 14 cases in this group present a somewhat variable
/ histo-pathological

histo-pathological picture but all have one common and constantly present feature, namely the occurrence of areas of tissue in which the microscopical findings are indistinguishable from those observed and described in Part II. That is to say, all cases in this group display evidence of the Askanazy epithelial change, round cell infiltration - both lymphoid follicular and diffuse inter-vesicular - and varying degrees of connective tissue replacement. The extent of tissue so involved varies, however, in the individual cases, so that if one seeks to make a diagnosis of Struma Lymphomatosa on purely histopathological grounds and using the presence of Askanazy change as the criterion, considerable difficulty is experienced in certain of the cases. At one extreme is the case in which the Askanazy change is virtually, although not absolutely, universal and alternative parenchymal appearances correspondingly minimal: the resemblance of such a case to those reviewed in Part II is very close and, even on histopathological grounds alone, the diagnosis could not be other than Struma Lymphomatosa. At the other extreme, however, is the case in which the Askanazy change and alternative parenchymal appearances are more indiscriminately and equally mixed and where, in consequence, any diagnosis on microscopical findings alone is a matter of great difficulty, if not impossible. Between the two all combinations are seen, the only reservation being that in all of the cases a considerable amount of Askanazy change can be detected. Attempts to / subdivide

subdivide the group fail, simply because no clear cut line of separation exists.

That these cases constitute an interesting and important group and one worthy of close consideration is shown by this very fact that in none of them is the parenchymal change diffusely and universally of the Askanazy type, as was the case with the group described in Part II. Instead, although the Askanazy type of change is present in considerable amounts in all, with its reduced vesicular size, diminished colloid content and single row of eosinophilic, granular, cuboidal epithelium, alternative parenchymal appearances of varying extent are manifest in every case and it is this variable histo-pathological picture which requires fuller consideration.

(a) As has been stressed, all the glands in this group contain areas of tissue the features of which are indistinguishable from those already described for Struma Lymphomatosa. (Figs. 49 and 50).

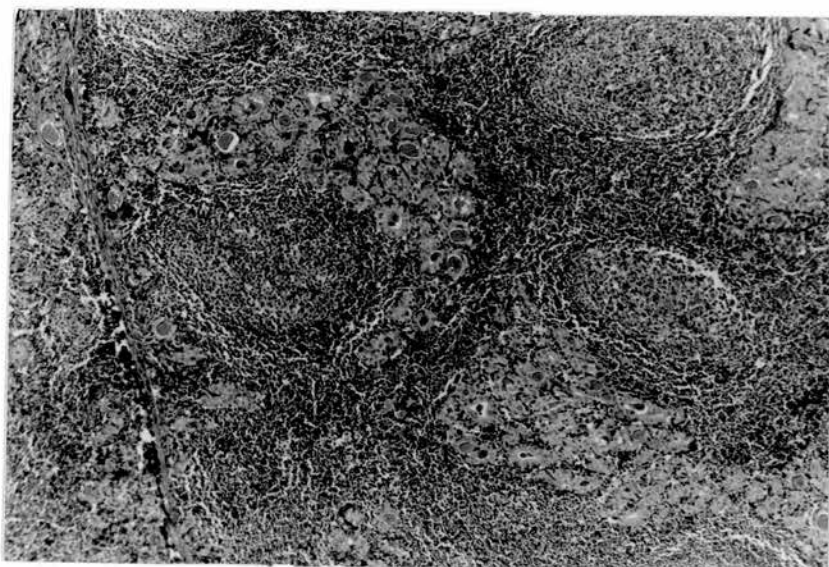


Fig. 49

Note numerous lymphoid follicles, interspersed between which are islands of thyroid parenchyma displaying uniform Askanazy epithelium with reduced vesicular size and diminished colloid content - an appearance identical with that seen in the cases described in Part II. H. & E. X 60.

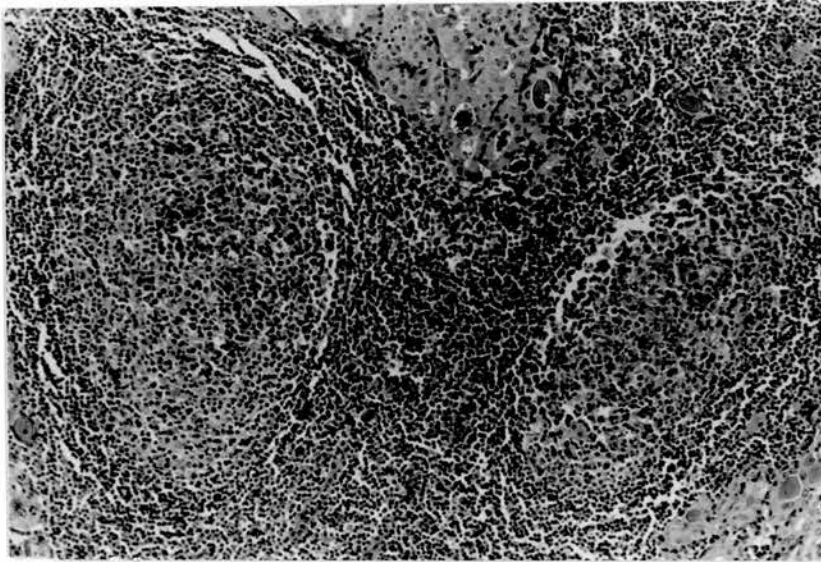


Fig. 50

Higher magnification of Fig. 49. H. & E. X 100.

(b) Interspersed with the Askanazy type of change, may be found in certain instances, areas of variable size showing the histo-pathological features of hyperplasia. (Figs. 51, 52 and 53).

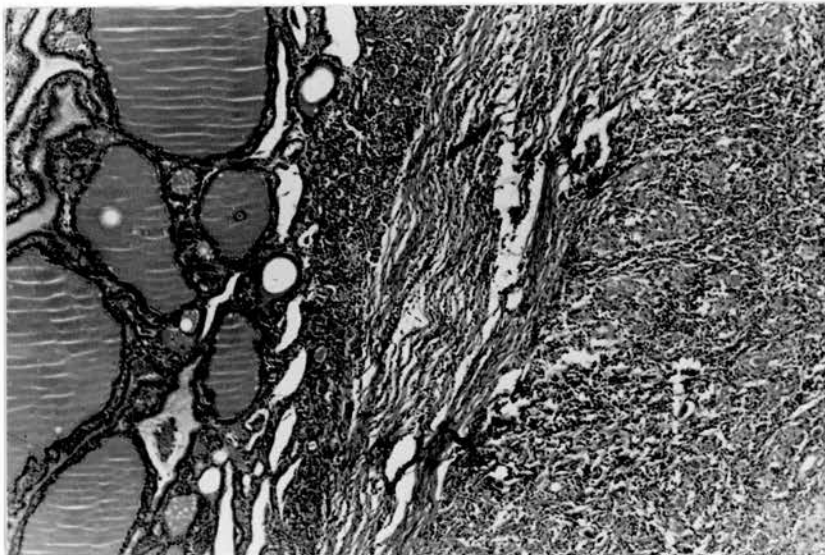


Fig. 51

Showing the junctional area between, on the left, a 1 cm. lobule of macrofollicular hyperplasia and on the right, adjacent to and surrounding it, an area displaying well marked Askanazy change. H. & E. X 65.

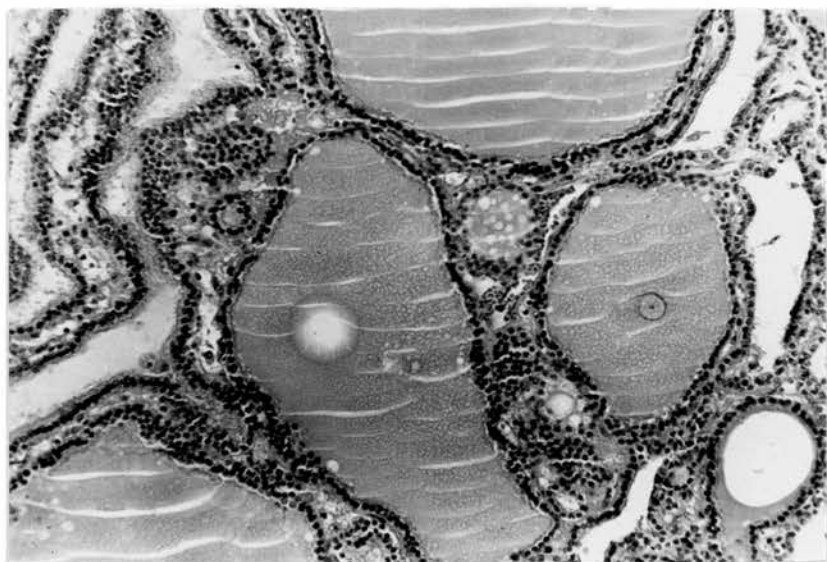


Fig. 52

Higher magnification of left half of Fig. 51.
Note absence of round cell infiltration.
H. & E. X 125.

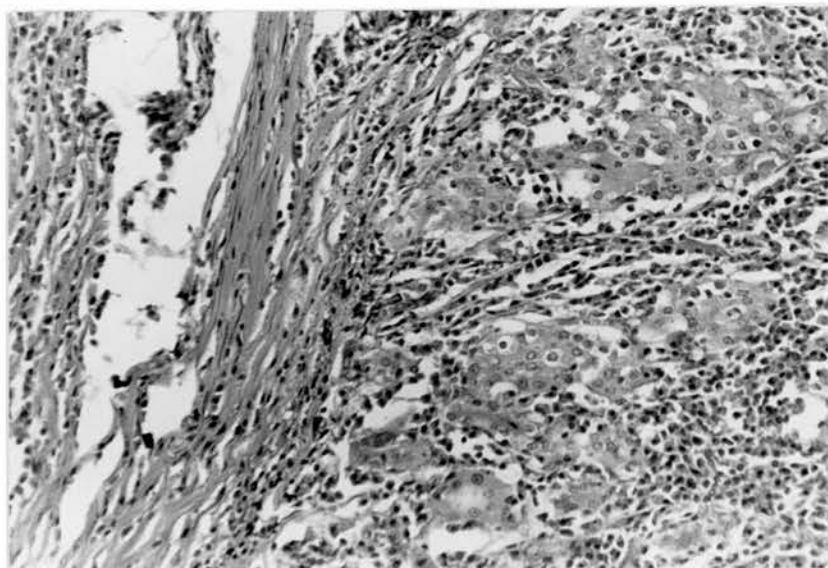


Fig. 53

Higher magnification of right half of Fig. 51.
Typical Askanazy appearance. H. & E. X 170.

And again, Figs. 54, 55 and 56.

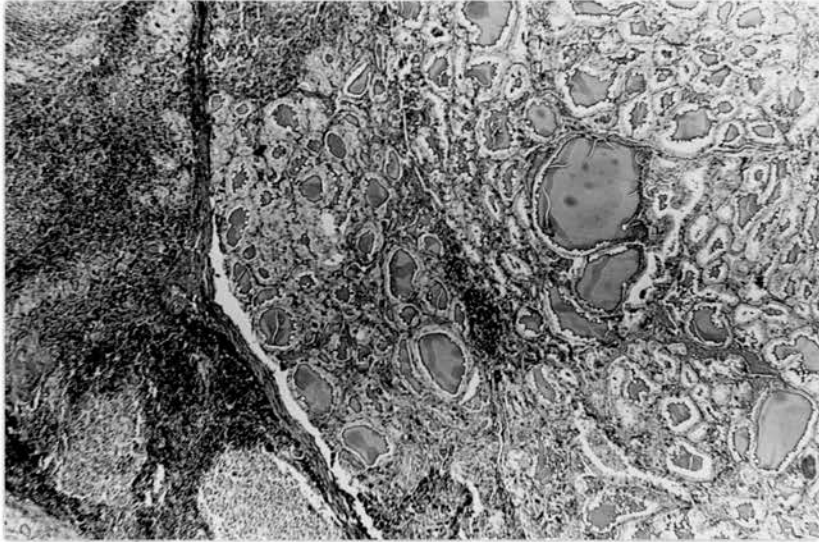


Fig. 54

On the left, typical Askanazy appearance; on the right, an area of microfollicular hyperplasia.
H. & E. X 55.

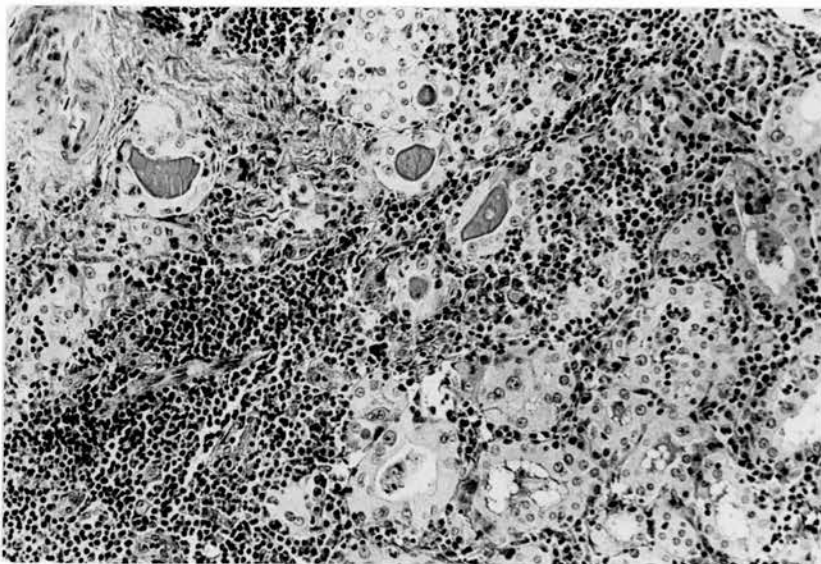


Fig. 55

Higher magnification of left half of Fig. 54.
H. & E. X 160.

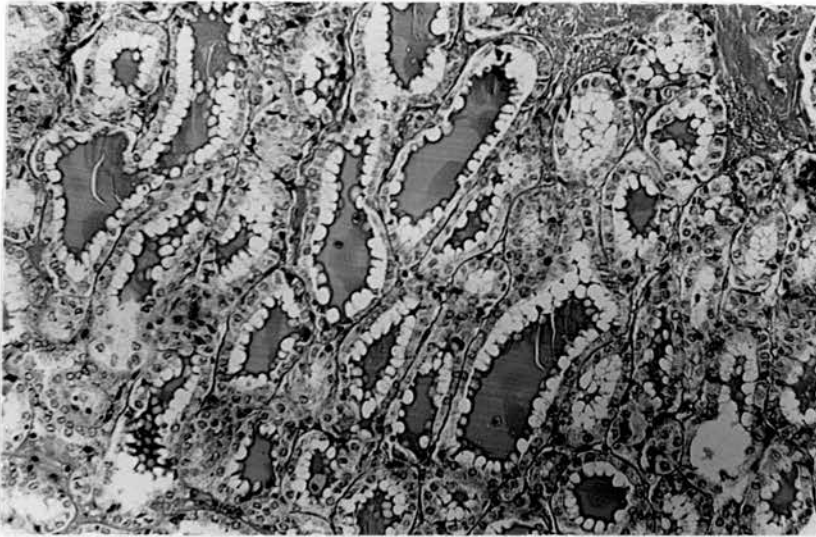

Fig. 56

Higher magnification of right half of Fig. 54.
H. & E. X 160.

(c) Certain areas of these glands present, what, for lack of a better general descriptive term, may be called a "colloid" appearance.

(1) In some instances, groups of thyroid vesicles are present which do in fact present an appearance of true colloid involution, being considerably enlarged, well filled with abundant, deeply stained, homogeneous colloid and lined by a single layer of low inactive epithelium. (Fig. 57).

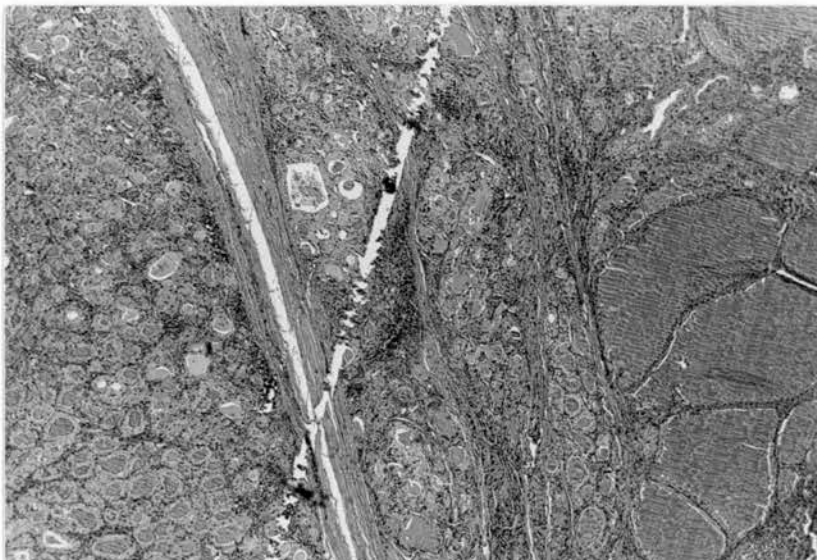


Fig. 57

An area of colloid involution surrounded by Askanazy change. H. & E. X 40.

(ii) Much more common, however, are areas, sometimes quite extensive, in which the thyroid vesicles are around normal size, regularly round or ovoid in outline, filled with well stained homogeneous colloid and lined by a single layer of flattened epithelium. (Figs. 58 and 59).

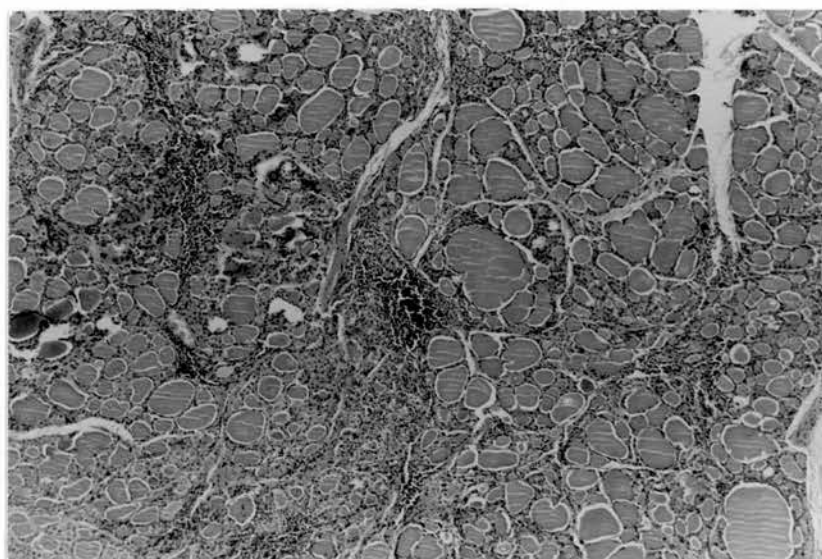


Fig. 58

Uniform "colloid" appearance. H. & E. X 40.

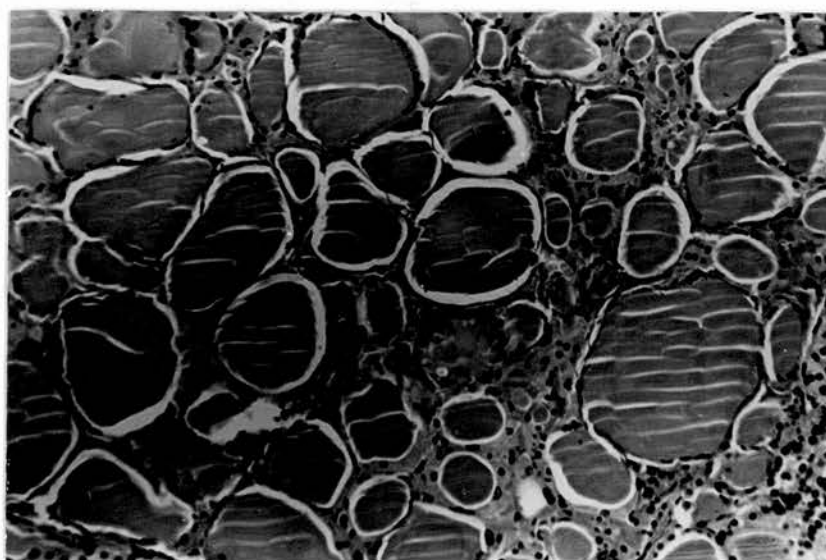


Fig. 59

Higher magnification of Fig. 58. H. & E. X 160.

(iii) Equally common are areas in which the vesicular structure is similar to the foregoing, but the epithelial lining is of low cuboidal type, showing an approximation to, but not having the identity of, Askanazy epithelium. (Figs. 60 and 61).

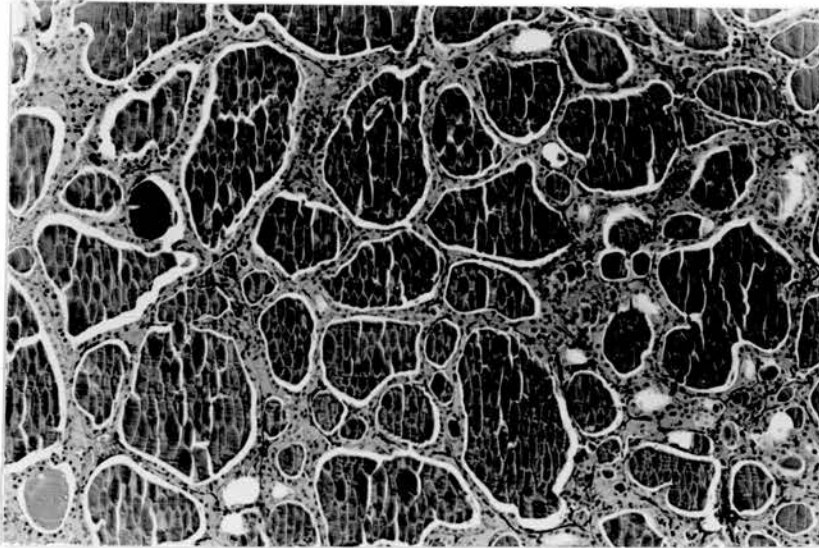


Fig. 60

"Colloid" area, in which although colloid is plentiful, epithelial characteristics approximate to the Askanazy type. H. & E. X 85.

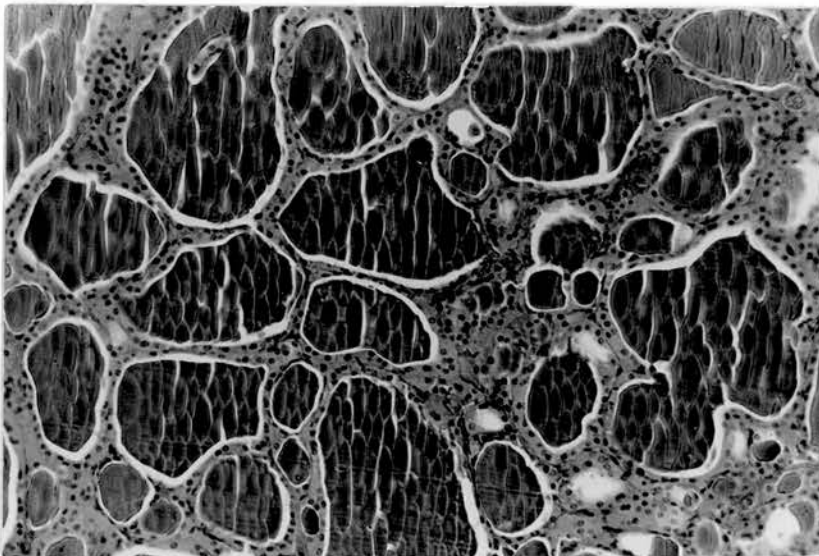


Fig. 61

Higher magnification of Fig. 60. H. & E. X 160.

It is possible that this latter appearance is the precursor of the true Askanazy change and it is interesting to note in connection with it the description given by Hashimoto himself of the vesicular changes in his first case, where, it will be recalled:- "..... the change in the vesicles is very slight, as one comes across them well filled with colloid, provided with almost normal follicles and with well preserved epithelial cells. Here, however, the vesicles are not as big as we are accustomed to see them in a marked colloid struma."

The absence of round cell infiltration in all these various "colloid" areas is a striking and noteworthy feature.

(d) Finally, areas are encountered in which none of the foregoing histo-pathological features - Askanazy, hyperplastic or involutinal - are found and which in consequence present a somewhat "non-specific" appearance. (Fig. 62).

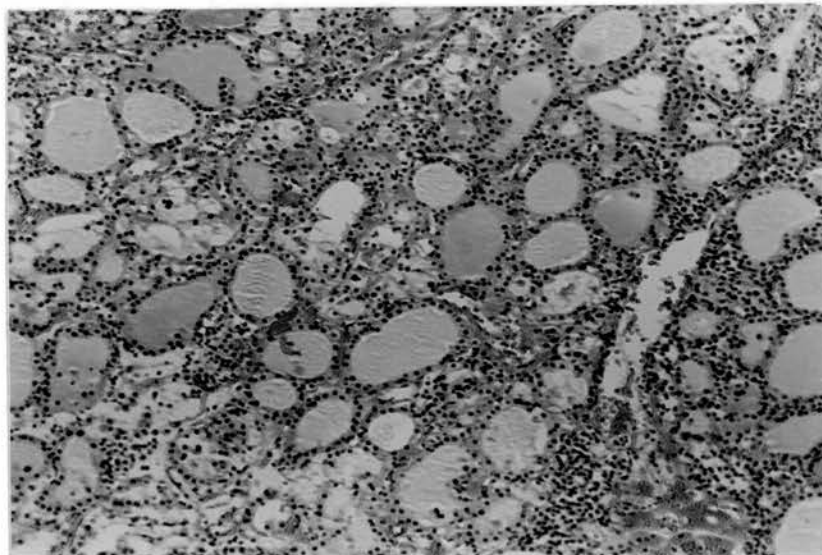


Fig. 62

"Non-specific" appearance. H. & E. X 75.

Commentary on Histo-pathology of Cases in Group 1.

As previously stressed and illustrated in the foregoing
/ microphotographs,

microphotographs, the 14 cases in this group all display evidence of Askanazy change, although variable in its extent. In some the volume of tissue thus involved is so great and alternative parenchymal appearances so restricted that, as has already been suggested, a diagnosis of Struma Lymphomatosa is at once apparent on histo-pathological grounds alone. Such cases show a close resemblance to and provide an interesting commentary on those reviewed in Part II. The minute structure of the thyroid can never be said to be absolutely uniform - indeed its pleomorphism and the difficulty of its histo-pathological interpretation are well known - and while a certain number of cases of this disorder may show the gland diffusely and uniformly affected by the Askanazy change, nevertheless it is probable that if a sufficiency of tissue be examined, many others, similarly affected, will show in restricted areas changes such as have been described in the present group. It is conceivable that small, restricted areas of hyperplasia may be compensatory for the overall diminution of gland function, while, as already suggested, the particular type of "colloid" appearance shown in Figs. 60 and 61, may represent the stage immediately preceding the establishment of true Askanazy change. Cases of this kind, then, present no particular diagnostic difficulty.

At the other end of the group, however, are these cases in which the histo-pathological appearances are much more varied. Figs. 63, 64 and 65 illustrate three different appearances, each of considerable extent, found

in one such gland of the present group.

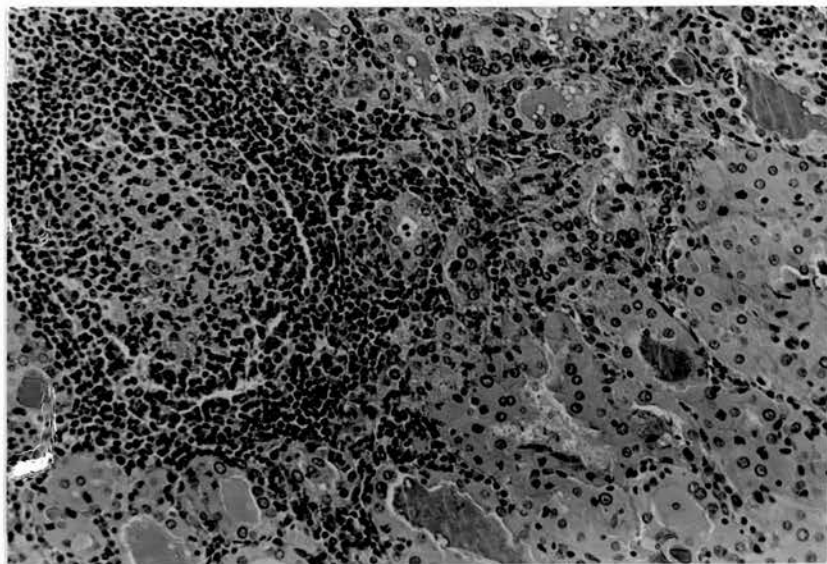


Fig. 63 H. & E. X 175.

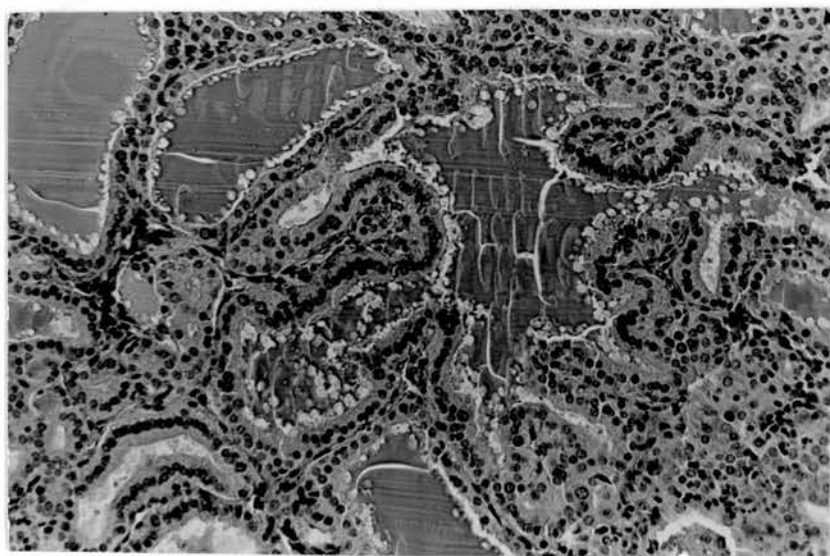


Fig. 64 H. & E. X 175.

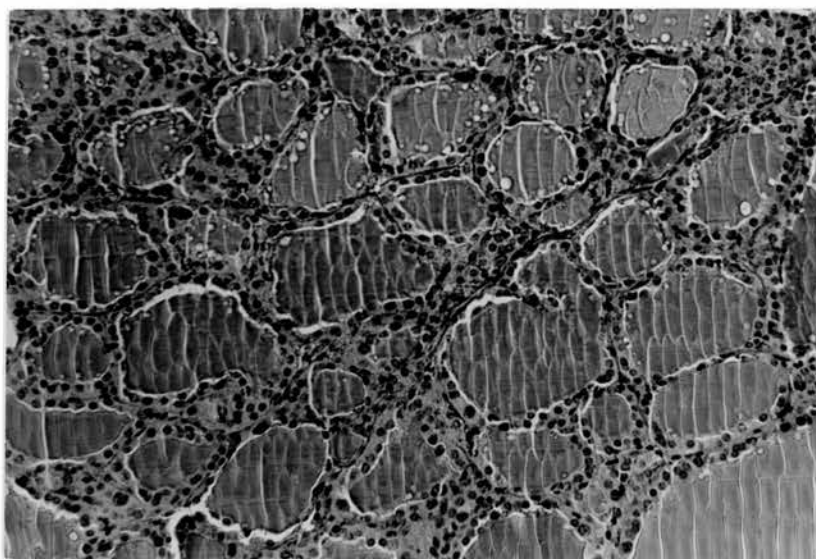


Fig. 65 H. & E. X 175.

Figs. 63, 64, and 65. Illustrating variable appearances found in certain Group 1 cases.

When such is the case the histo-pathological diagnosis becomes a matter of considerable difficulty and this is frequently reflected in such conclusions by the pathologist as - early or mild Struma Lymphomatosa, regressive change in a simple or hyperplastic gland, etc. (Fig. 66). This difficulty is, of course, not a new one and has been encountered frequently by other investigators of this subject. It concerns the whole relationship of Struma Lymphomatosa to simple and toxic thyroid disease, which will be discussed separately at a later stage. Askanazy change may occur in toxic and non-toxic goitre, as Lennox (1948) has shown, although to what extent is not exactly known. When, as in certain cases of the present / group,

Struma Lymphomatosa	7
Early or Mild Struma Lymphomatosa	3
Early Riedel's Thyroiditis	1
Diffuse hyperplastic goitre	1
Hyperplastic goitre with degenerative changes	1
Nodular colloid goitre with marked regressive change	1
Total	14

Fig. 66

Diagnoses of Pathologists originally reporting Group 1 Cases.

group, the histo-pathological picture shows an approximately equal admixture of Askanazy and other parenchymal changes, the question arises as to whether such glands are, in fact, examples of Struma Lymphomatosa or rather toxic or non-toxic goitres displaying Askanazy change. If it be the former, then obviously the histo-pathological spectrum of Struma Lymphomatosa must be considerably widened, while, if the latter explanation be accepted, it must be equally obvious that very considerable areas of the toxic or non-toxic gland may be affected by this type of change.

The question is probably insoluble on histo-pathological grounds alone and help must be sought from the clinical records of such cases. Before passing to a consideration of these, however, the following remarks seem pertinent. There is a present-day tendency, resulting from improved methods of diagnosis, either to dispense altogether with histo-pathological confirmation when dealing with Struma Lymphomatosa or alternatively to rely on the information given by a restricted needle biopsy. The former course would seem regrettable and means an end to any further advance in the histo-pathological field, while, if the evidence of the foregoing pages be accepted, the futility of attempting to solve the problem by needle biopsy is at once apparent. What is in fact required, is a searching pathological enquiry allied and correlated with, clinical and all the other ancillary methods of diagnosis presently available.

Pathological Anatomy and Operative Findings

The thyroids of the 14 cases in this group showed gross pathological features similar to those already described for the gland of Struma Lymphomatosa. All were considerably enlarged and diffusely involved, although one case presented successive involvement of first the right and then the left lobe, at an interval of $2\frac{1}{2}$ years, while in another, the gland was found to consist at operation of one lobe only. Of the eight cases in which a record of the operative diagnosis is available, Struma Lymphomatosa was diagnosed or suspected from the naked-eye appearance in six, while the remaining two were suspected of being malignant. In no case was diffuse extra-thyroid extension of the pathological process found, such as is regarded as being typical of Riedel's Thyroiditis. In two cases, however, the strap muscles were adherent to the surface of the gland, while in a third, where a total thyroidectomy was performed because of a suspicion of malignancy, the gland was found to be densely adherent to the trachea in the midline requiring sharp scalpel dissection at this point and leaving, indeed, some thyroid tissue on the anterior surface of the latter structure. These findings are of some importance and reference will be made to them again at a later stage.

The Clinical Aspects

1. Age and Sex Incidence

All 14 cases were female: the age at time of treatment varied from 40 to 68 years.

2. Duration of Goitre

The shortest duration was one month, the longest 29 years. The duration of thyroid enlargement was distributed as follows:-

Less than 1 year.....	3 cases
1-2 years.....	2 cases
2-5 years.....	1 case
More than 5 years.....	8 cases

3. Other Symptoms

Of symptoms immediately referable to the enlarged gland, mild pressure sensations were noted in seven of the patients, hoarseness in five; two patients complained of slight difficulty in swallowing; in no case was thyroid discomfort or pain observed.

4. Clinical Assessment of Thyroid Function

In nine of the 14 patients there was no symptomatic evidence of remote, recent or current hyperfunction and likewise physical examination at the time of presentation for treatment revealed no signs of toxicity. Two of these nine patients had had short spells of iodine treatment, one eight years prior to presenting for treatment and the other for two short periods, 6 and 2½ years previously.

Three patients reported symptoms possibly suggestive of antecedent toxicity, but in none of them did physical examination at the time of treatment reveal evidence of thyroid hyperfunction. One of these had had intermittent iodine medication over a number of years and the drug was also used for pre-operative preparation.

The remaining two patients had been considered actively thyrotoxic elsewhere, seven and three years respectively prior to presenting for surgical treatment. Both had been treated with thiouracil, but the drug had been discontinued 18 and 5 months beforehand. In the former of these, physical examination at the time of surgical treatment showed no evidence of thyroid overactivity, but the latter was considered to demonstrate signs of toxicity and was prepared for operation with a course of iodine.

None of the group gave symptomatic or clinical evidence of thyroid hypofunction prior to treatment.

5. Physical Examination

(a) The Thyroid

The clinical characteristics of the goitres in this group of patients are shown in Fig. 67.

(b) Other Findings

Physical assessment of thyroid function has already been detailed above. No enlargement of liver or spleen was detected in the nine patients in whom such a search was made.

6. Radiology and Laryngoscopy

Of the seven patients in whom antero-posterior and lateral X-ray examination of the neck was carried out, four showed radiological evidence of retro-tracheal extension of the enlarged thyroid. The other findings were minor degrees of tracheal compression and deviation.

Of the 14 patients, seven had laryngoscopy. Of these, six showed normal cord movement. The seventh patient had

Extent of Involvement	Diffuse ⁽¹⁾ Unilateral ⁽²⁾	11) 3)	14
Consistence	Soft Firm Hard No record	2) 9) 1) 2)	14
Surface	Smooth Nodular No record	6) 2) 6)	14
Mobility	Free No record	9) 5)	14
Tenderness	+ - No record ⁽³⁾	0) 1) 13)	14

Fig. 67

Clinical characteristics of the goitre in
Group 1 Cases.

- (1) One case, included here as diffuse, was operated on twice, showing first enlargement of the right and later the left lobe.
- (2) Two cases subsequently shown to be diffuse at operation.
One case subsequently shown to consist anatomically of one lobe only.
- (3) May be presumed absent.

an apparently normal larynx two weeks prior to operation, but at intubation the right cord was noted to be paralysed; this patient went on to develop a bilateral paralysis following total thyroidectomy.

7. The Clinical Diagnosis

The recorded clinical diagnoses in this group are shown in Fig. 68. In no case was a clinical diagnosis of Struma Lymphomatosa made. Carcinoma was diagnosed or suspected in four of the cases.

8. Laboratory Aids to Diagnosis

Special aids to diagnosis - serum protein abnormalities and tests of liver function, serological tests and ^{131}I studies - were not employed in the present group of cases, which were dealt with at a time when such aids were not generally available. In one case, however, electrophoretic determination of plasma proteins and tests of liver function were carried out four months after subtotal thyroidectomy and one month after starting thyroid extract in a dose of one grain daily for well established hypothyroidism. The findings were within normal limits, apart from a serum cholesterol figure of 588 mg. per 100 ml.

Treatment and Follow-up

Of the 14 cases in this group, ten were treated by subtotal thyroidectomy and as already noted, one of these had first the right and $2\frac{1}{2}$ years later, the left lobe subtotally resected. Nine had no post-operative complications, but the tenth patient died on the second day after operation. This patient was a poor surgical risk with hypertension and

Clinical Diagnosis	No. of Cases
Simple goitre	5
Simple goitre: ? Carcinoma	2
? Carcinoma	1
Carcinoma	1
Primary Thyrotoxicosis	1
? Secondary Thyrotoxicosis	1
No record	3
Total	14

Fig. 68

Clinical Diagnoses in Group 1
Cases.

evidence of cardiac and renal impairment. Considerable difficulty was experienced at operation in mobilising the gland, both lobes of which had enlarged retro-tracheally and were firmly wedged in that position. Stridor and respiratory difficulty, without evidence of haemorrhage, were noted on the evening of operation and an endotracheal tube was passed with considerable relief - unfortunately the state of the vocal cords was not observed at this intubation. On the second post-operative day the patient suffered a sudden cardio-vascular collapse and died, although possessed of an adequate airway at the time of death. Autopsy confirmed the clinically suspected cardiac and renal damage and showed partial collapse of both lower lobes and intense pulmonary congestion. No abnormality could be detected at the thyroidectomy site and both recurrent nerves were anatomically intact, although the distinct possibility of a traction injury could not be excluded.

One patient underwent subtotal resection of the right lobe only, there being no sign at operation of the existence of a left lobe. She subsequently developed a mild tetany.

Two cases were treated by total thyroidectomy, because of a suspicion of malignancy at operation. Of those, one had no post-operative complications, while the other developed both a bilateral nerve paralysis and tetany, this being the patient in whom one cord was observed to

be paralysed before operation.

The final case was treated by biopsy confirmation of a diagnosis of Struma Lymphomatosa followed by a course of X-ray therapy of 3,000 r to the thyroid, there being no appreciable clinical change in the gland at the conclusion of treatment.

Of the ten cases treated by subtotal thyroidectomy, one died post-operatively and in another the duration of follow-up was only three months. Of the remaining eight cases, four subsequently showed clinical evidence of hypothyroidism at intervals of 3, 3, 4 and 13 months after operation and were thereafter constantly maintained on thyroid extract. In three of these, hypothyroidism was confirmed by a ^{131}I investigation carried out according to the technique previously described. The remaining four cases treated by subtotal resection and with adequate follow-up, did not exhibit clinical hypothyroidism and never required substitution therapy, the ^{131}I findings being in agreement with the clinical impression in two of these and at variance in two. (Fig. 69).

The one patient treated by subtotal resection of the single right lobe subsequently showed clinical evidence of hypothyroidism and was started on thyroid extract three months after operation, maintained continuously thereafter. When assessed six years later, a serum cholesterol value of 287 mg. per 100 ml. was obtained and a ^{131}I investigation gave an 8-24 hour fraction of 18.8% of the dose and a T index of 2.3.

NO.	PATIENT	POST-OPERATIVE CLINICAL HYPOTHYROIDISM	THYROID SUBSTITUTION THERAPY		ASSESSMENT AT	THYROID GLAND	SERUM CHOLESTEROL MG. PER 100 ML.	131I FOLLOW-UP	
			STARTED AT	PRESENT DOSE GR. PER DAY				8-24 HR. FRACTION	T. INDEX
1.	E.G.	-	NEVER TAKEN THYROID	---	11½ YRS. POST-OP.	PALPABLE	267	8.9	8.4
2.	H.D.	-	NEVER TAKEN THYROID	---	6 " " "	IMPALPABLE	376	13.9	4.1
3.	A.G.	+	3 MTHS. POST-OP.	1	4 " " "	"	236	31.2	1.5
4.	G.S.	-	NEVER TAKEN THYROID	---	3½ " " "	"	NOT DONE	27.7	1.6
5.	H.C.	+	4 MTHS. POST-OP.	1	3 " " "	"	145	24.0	2.2
6.	R.L.	-	NEVER TAKEN THYROID	---	2½ " " "	"	250	26.2	1.7
7.	J.S.	+	13 MTHS. POST-OP.	1½	2 " " "	"	558	30.0	1.3
8.	M.S.	+	3 " " "	1½	5 MTHS. " " "	"	588	---	NOT DONE
9.	A.W.	-	NO THYROID TO DATE	---	3 " " "	"	NOT DONE	---	NOT DONE
10.	J.R.	---	---	---	POST-OPERATIVE DEATH	---	---	---	---

FIG. 69

DETAILS OF FOLLOW-UP OF 10 CASES IN GROUP 1
TREATED BY SUBTOTAL RESECTION

No follow-up was possible in the patient treated by irradiation.

Commentary on Clinical
Aspects of Cases in Group 1

When the clinical aspects of this group of cases are viewed as a whole, they present a close resemblance to the material reviewed in Part II and are generally compatible with the findings in Struma Lymphomatosa. This may be explained by the fact that several undoubted cases of this disease are included in the group, while the remainder, even if not true examples of the disorder, present considerable amounts of thyroid tissue microscopically indistinguishable from that seen in Struma Lymphomatosa and might therefore be expected to assume at least the physical characteristics of that disease. The one case presenting successive involvement of the two lobes of the gland and operated upon twice at an interval of $2\frac{1}{2}$ years with similar histo-pathological findings on each occasion, may be added to the several examples of such a sequence which have already been reported in the literature of Struma Lymphomatosa. Taken as a whole, the present group, as compared with that discussed in Part II, demonstrates two points of difference to which attention might be drawn - a higher proportion of cases with a long duration of goitre (more than five years) - 8 out of 14, as contrasted with 3 out of 41, and a lower incidence of post-operative hypothyroidism - which, in a general way, illustrate the more pleomorphic composition of the group and the greater

/ proportion

proportion of relatively uninvolved thyroid tissue. This apart, however, it is no more easy a matter to effect the internal subdivision of the group on clinical, than it is on histo-pathological, grounds.

The Nature of the Group 1 Cases

It has frequently been remarked that the diagnosis of Struma Lymphomatosa must not rest on histo-pathological criteria alone, but that all aspects of the individual case, clinical as well as pathological, must be taken into account. When this is done with the present group of cases, the balance of evidence weighs in favour of their acceptance as examples of Struma Lymphomatosa and this despite the admixture of pathological appearances previously observed and illustrated. It must be remembered, however, that the clinical features of Struma Lymphomatosa are characteristically non-specific, that the condition is frequently mistaken for other forms of thyroid disease notably simple goitre and neoplasm and that "toxic" features may confuse the picture, with the result that, in the final analysis, there has until now existed a certain residuum of cases in which clinical findings may offer little assistance to the diagnostic difficulty of the pathologist faced with a histo-pathologically pleomorphic appearance.

It is to this particular residuum, illustrated by the present group of cases, that laboratory aids to diagnosis, not generally available during the period covered, would

seem especially applicable in helping to solve the diagnostic category into which such cases should be placed and in attempting to define with greater accuracy the clinical and pathological limits of Struma Lymphomatosa which for the present remain somewhat nebulous.

Group 2 - 4 Cases

Histo-pathology

The four cases now to be considered constitute a homogeneous group and pose a rather different aspect of this same problem, namely the difficulty of accurately defining the clinico-pathological limits of Struma Lymphomatosa. The reasons for their separate consideration are essentially histo-pathological and three-fold:-

- (a) Gross parenchymal destruction and absence of Askanazy change.
 - (b) Extensive connective tissue replacement.
 - (c) Occurrence of squamous metaplasia.
- (a) Gross parenchymal destruction and absence of Askanazy change

In these four cases the amount of surviving thyroid parenchyma upon which to base observations and conclusions is minimal in each. In areas of such survival, however, the epithelial and vesicular appearances are not those of the already familiar Askanazy change. Figs.70-73 illustrate the appearances observed in parts of two of these glands, while elsewhere parenchymal disintegration was so complete as to prohibit description.

While none of these glands showed evidence of frank Askanazy change in the surviving parenchyma, all

/ demonstrated

demonstrated well marked round cell infiltration with both a lymphoid follicular and diffuse distribution.

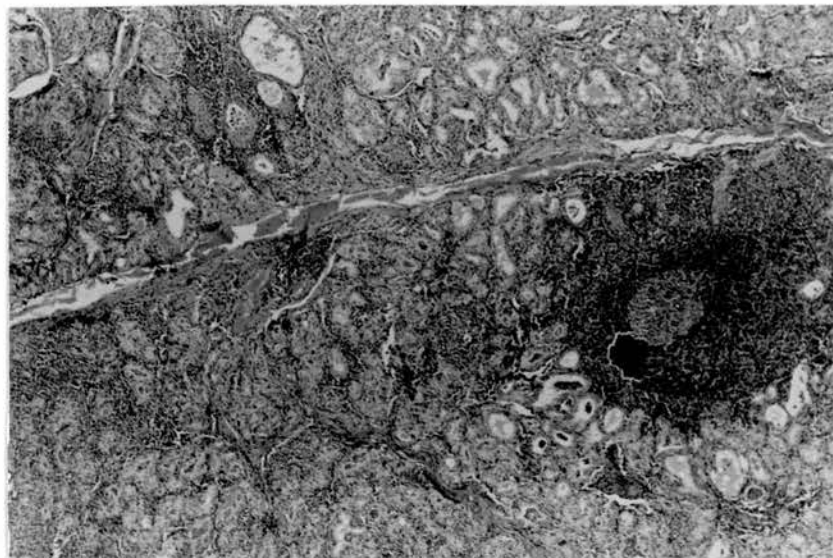


Fig. 70

General view of parenchymal structure. The thyroid vesicles are irregular in size and shape, although mostly small and containing little colloid. Nowhere is there evidence of frank Askanazy change. H. & E. X 40.

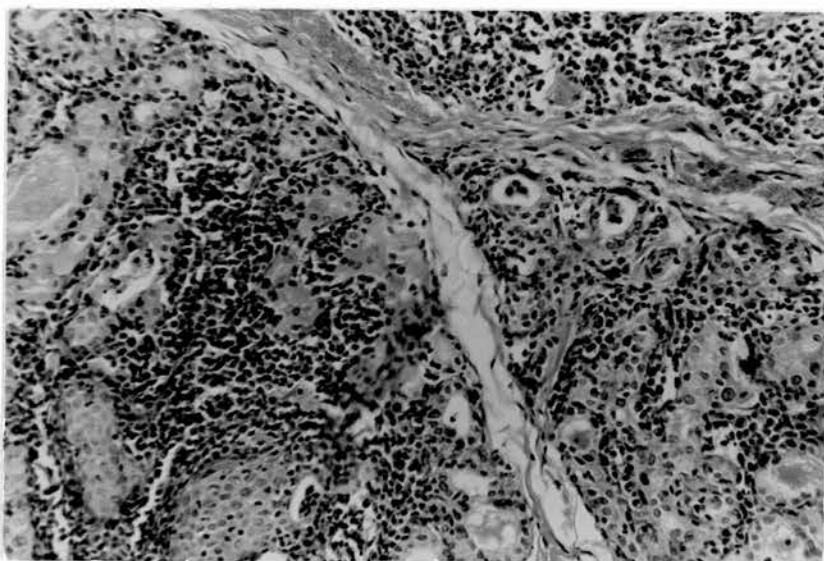


Fig. 71

Higher magnification. Note squamous metaplasia. H. & E. X 145.

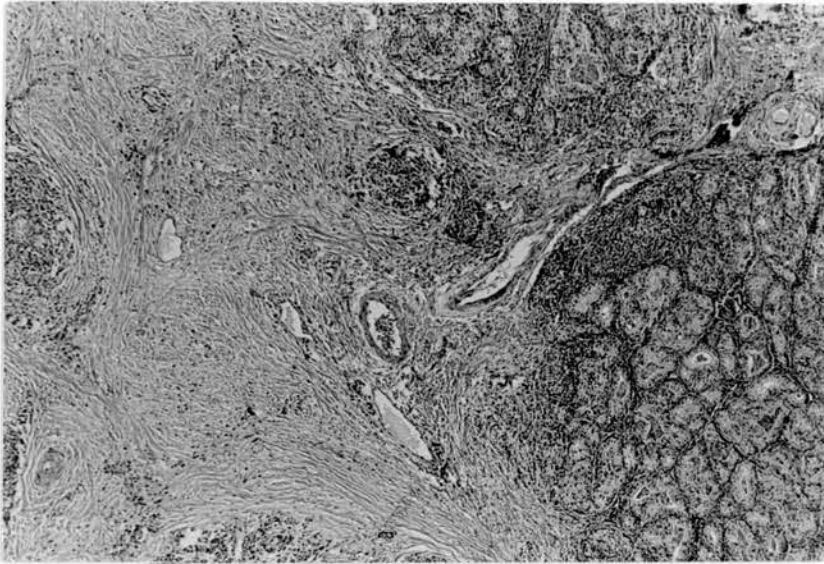


Fig. 72

Showing, at one margin, a lobule of hyperplastic appearance with small vesicles lined by columnar epithelium and containing scanty colloid. H. & E. X 40.

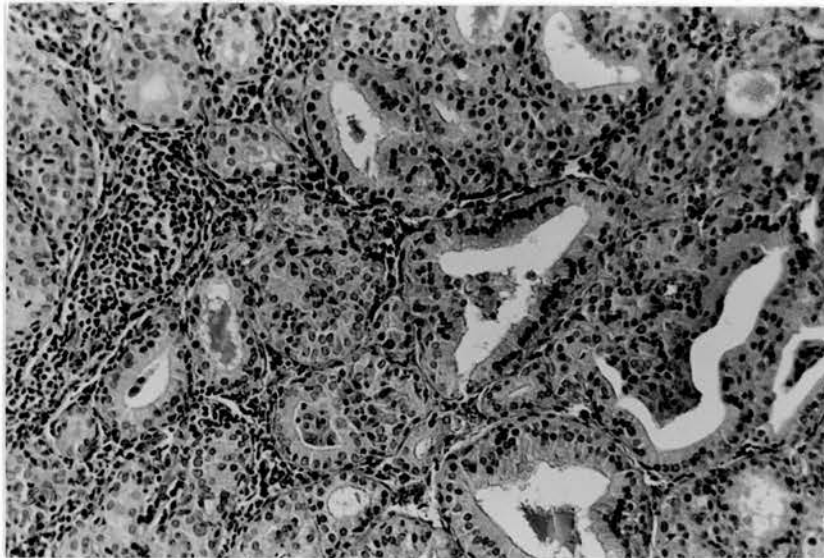


Fig. 73

Higher magnification of same area. H. & E. X 145.

(b) Extensive connective
tissue replacement

Coinciding with the advanced parenchymal disintegration and destruction, these glands showed extensive connective tissue replacement of large areas of the tissue, the fibrosis being of dense, collagenous, avascular type with minimal accompanying round cell infiltration.

(Figs. 74 and 75).

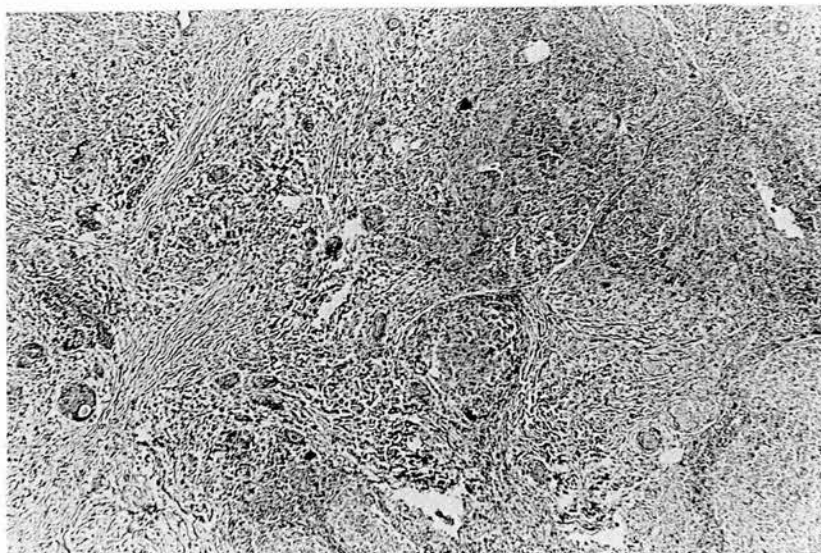


Fig. 74

Connective tissue replacement. Note foci of squamous metaplasia. H. & E. X 40.

/ (c)

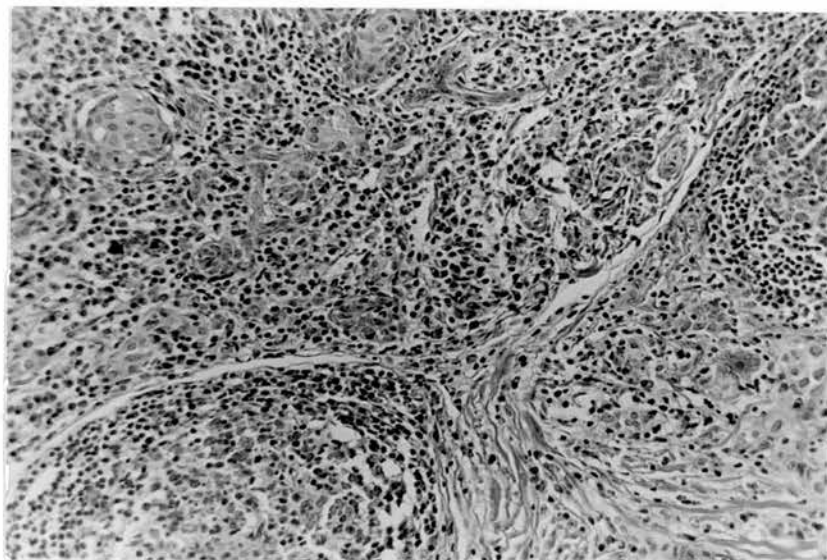


Fig. 75

Higher magnification from same field. H. & E. X 145.

(c) Occurrence of squamous metaplasia

In the material reviewed in Part II this change was observed, although infrequently, whereas in three of the present cases it was found in numerous small foci throughout the tissue examined and sufficiently obtrusive to constitute a noteworthy feature of the microscopical findings. (Figs. 71, 74 and 76).

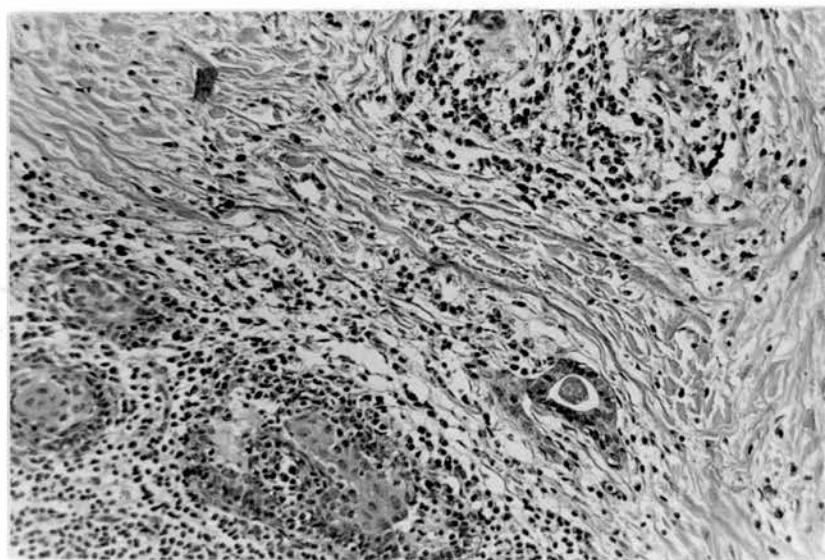


Fig. 76

Squamous metaplasia. H. & E. X 145.

Pathological Anatomy and Operative Findings

These four cases had formal biopsy of the thyroid gland so that opportunity presented for inspection of its gross appearance. In each, the gland was diffusely although only slightly enlarged. In two the overlying strap muscles were lightly but quite definitely adherent over the surface of the lobes. In all the gland felt extremely and indeed stony hard, while the outer surface had a whitish colour. The cut surface had a similar appearance and was obviously densely fibrotic.

The Clinical Aspects

1. Age and Sex

Three of the cases were female and one male: the ages at time of treatment were 42, 46, 47 and 60 years.

2. Duration of Goitre

The duration of thyroid enlargement was 2, 2 and 3 months and 3 years 8 months respectively.

3. Other Symptoms

These patients had no complaints immediately referable to the goitre. There were no pressure symptoms, voice change or pain.

4. Assessment of Thyroid Function

In no patient was there symptomatic evidence of remote, recent or current hyperfunction. Two of the patients gave a recent history suggestive of mild hypothyroidism, but in none were signs of frank hypofunction elicited at physical examination. The pre-treatment findings for

/ basal

basal metabolic rate, serum cholesterol and ^{131}I investigation are shown in Fig. 77 and are, for the most part, consistent with a diagnosis of hypofunction.

5. Physical Examination

(a) The Thyroid

Clinical examination revealed a diffusely, although not greatly, enlarged thyroid in three of the four cases and in one of these the thyroid shape of the goitre was well preserved producing an "anatomical" enlargement immediately obvious on inspection of the neck. In the remaining case, the only palpable abnormality in the neck, even at repeated examination over an interval of $2\frac{1}{2}$ years, was a small, apparently localised swelling in the lower pole of the right lobe, there being no discernible generalised enlargement of the gland. Only at operation was diffuse involvement confirmed.

In all three patients with clinically obvious diffuse enlargement the gland was extremely hard in consistence, mobile and painless.

(b) Other findings

No case demonstrated enlargement of liver or spleen.

6. Radiology, Laryngoscopy and Clinical Diagnosis

X-ray examination of the neck showed no significant abnormality apart from slight enlargement of the soft tissue thyroid shadow.

Laryngoscopy revealed no abnormal findings.

131I Investigation										
No.	Patient	B.M.R.	Serum Cholesterol mg. per 100 ml.	48-hour Uptake %	48-hour P.B. 131I % of dose per litre	Excretion Pattern				T Index
						0-8 hr. fraction %	8-24 hr. fraction %	24-48 hr. fraction %	0-48 hr. fraction %	
1.	J.H.	-	257	11.7	0.6	35.8	21.0	9.6	66.4	2.6
2.	C.G.	-25%	280	10.0	1.1	40.5	22.3	10.9	73.7	2.5
3.	C.M.	+7%	294	13.6	-	38.4	22.0	7.6	68.0	2.6
4.	C.L.	-4%	287	10.2	0.2	25.0	16.4	8.7	50.1	3.

Fig. 77

Pre-treatment findings for B.M.R., Serum Cholesterol and 131I Investigation in Group 2 Cases.

In three of the cases, a clinical diagnosis of Struma Lymphomatosa was made - those with diffuse thyroid enlargement. In the fourth case, the diagnosis was of a simple thyroid nodule.

7. Laboratory Aids to Diagnosis

The ^{131}I results illustrated in Fig. 77 show in general a low 48 hour gland uptake and high 48 hour P.B. ^{131}I .

In addition, two of the patients were submitted to a perchlorate test. Only one of these, however, gave a positive result, 400 mg. of potassium perchlorate producing a fall in thyroid uptake from 100% to 80.9% in 50 minutes.

Electrophoretic determination of plasma proteins and tests of liver function were carried out in all four cases before starting treatment and the results are shown in Fig. 78.

Serological tests were not carried out.

Treatment and Follow-up

All four cases have been treated conservatively by the exhibition of thyroid extract in optimal dosage, but the period of follow-up to date is insufficient to permit of conclusions concerning shrinkage of the gland and alteration in laboratory findings.

General Commentary on Cases in Group 2

Having regard to clinical, pathological and laboratory findings, it would appear that the four cases in this small group must be accepted as examples of Struma Lymphomatosa.

/ Their

NO.	PATIENT	SERUM CHOLESTEROL MG. PER 100 ML.	SERUM PROTEINS										LIVER FUNCTION TESTS			
			TOTAL PROTEIN G. PER 100 ML.	ALBUMIN		GLOBULINS						COLLOIDAL GOLD	THYMOL TURBIDITY (UNITS)			
				G. PER 100 ML.	%	ALPHA 1		ALPHA 2	BETA		GAMMA					
						G. PER 100 ML.	%		G. PER 100 ML.	%				G. PER 100 ML.	%	
1.	J.H.	257	6.3	3.5	56	0.3	5	0.6	9	9	0.6	9	1.3	21	0	1
		272	6.8	2.7	39	0.8	12	1.1	16	13	0.9	13	1.4	20	0	2
2.	C.G.	280	8.1	4.4	55	0.3	4	0.9	11	11	0.9	11	1.5	19	1	3
		340	6.9	3.3	48	0.5	7	0.7	11	13	0.9	13	1.5	22	0	5
3.	C.M.	294	6.6	3.7	56	0.3	4	0.5	8	9	0.6	9	1.5	23	3	4
		287	7.2	3.7	52	0.5	7	0.8	11	12	0.8	12	1.4	19	-	3

Fig. 78

Serum Protein Estimations and Liver Function Tests in Group 2 Cases.

Their consideration as a separate group would seem justified, however, by the fact that they illustrate certain histo-pathological and clinical variations from what may be regarded as the classical picture of the disease.

Microscopically Askanazy change could not be demonstrated in the residual parenchyma, but the total volume of such was so restricted that this may mean little, since it is in such cases, where gland destruction is so advanced and connective tissue replacement so complete, that the impossibility arises of knowing the exact nature of the preceding parenchymal changes. Alternatively, it may be that these cases correspond to a type of Struma Lymphomatosa, as certain other authors seem to have found - Skillern et al. (1956) and Harland and Frantz (1956) - in which Askanazy change would not appear to occur. They again emphasise, however, the occurrence of widespread fibrosis and to a lesser extent squamous metaplasia as definite, though hitherto little recognised, features of the kaleidoscopic histo-pathological picture of Struma Lymphomatosa.

The intense fibrosis in these glands found its clinical and gross pathological expression in their stony hard consistence and white, fibrotic appearance as contrasted with the firm, pinkish-grey gland of the classical case. Nor did they exhibit the degree of enlargement customarily found in this disease, the clinical

/ picture

picture being that of a small, diffusely involved, densely hard, mobile, painless goitre.

The laboratory findings were generally in keeping with a diagnosis of Struma Lymphomatosa, although the electrophoretic pattern and flocculation tests were less strikingly abnormal than is usually the case.

In the present state of our knowledge, the only alternative diagnoses which might be entertained for these cases are Subacute Thyroiditis or Riedel's Thyroiditis. The former of these may be excluded by the lack of any systemic upset in the clinical picture and in particular the absence of any complaint of pain in the neck, the failure to demonstrate tenderness in the gland or to confirm the characteristic histo-pathological picture of this disease and finally the altogether different pattern of ^{131}I metabolism. The diffuse extra-thyroid fibrosis and severe pressure effects classically assigned to Riedel's Thyroiditis were quite lacking.

Relationship of Struma Lymphomatosa to
other forms of Thyroid Disease

A. Other forms of Thyroiditis

1. Subacute Thyroiditis

There is no recognisable aetiological, pathological or clinical relationship between Struma Lymphomatosa and Subacute Thyroiditis.

2. Riedel's Thyroiditis

The question of a possible relationship between Struma Lymphomatosa and Riedel's Thyroiditis is at once so

/ involved

involved and has in the past been the subject of so much controversy that separate consideration is given to it in Part V.

B. Malignant Disease of the Thyroid

The relationship of Struma Lymphomatosa to malignant disease of the thyroid likewise forms the subject of a separate discussion in Part VI.

C. Simple and Toxic Goitre

Numerous attempts have been made in the past to define a relationship between Struma Lymphomatosa on the one hand and simple and more particularly, toxic goitre on the other, and so to integrate the former condition into the clinico-pathological life history of thyroid disease in general and of the thyrotoxic state in particular, rather than regard it as an entirely separate and mystifying entity. That such attempts should have been inevitable followed from the long established observation that round cell infiltration, both follicular and diffuse - a universal feature of the histo-pathological picture of Struma Lymphomatosa - may also be encountered in the apparently normal thyroid gland, in simple goitre and most conspicuously in the gland of thyrotoxicosis.

Such an apparent, if somewhat unilateral, histo-pathological identity invited clinician and pathologist alike to establish an aetiological relationship between thyrotoxicosis and Struma Lymphomatosa and through the succeeding years various authors - Warthin (1926), Eason / (1928)

(1928), Polowe (1934), Boyden, Celler and Bugher (1935), Dunhill (1937), Vaux (1938), Elen and Trotter (1942) and Levitt (1954) - have either suggested or claimed such a relationship. Others have been equally vociferous in denying this possibility and the controversy still flares into activity from time to time. The following pages make no pretence at its solution but rather attempt to comment upon certain aspects of the problem which appear to have received insufficient attention in the past.

1. The Significance of the Askanazy Change

It is only in recent years that the histo-pathological picture of Struma Lymphomatosa has gained a fuller recognition and in particular the fact has emerged that, if not in all cases then in a very substantial majority, there appear to be two basic and constantly associated elements of that picture - round cell infiltration and a change in the thyroid epithelium to the Askanazy type. It is this latter finding which has been so repeatedly missed or disregarded in the past and yet it would appear that any attempt to define a morphological and consequently aetiological relationship between Struma Lymphomatosa and simple and toxic forms of thyroid disease must bear this dual nature of the change in mind, since it is obvious that the Askanazy nature of the parenchyma must have a certain, if presently obscure, significance.

Numerous authors have variously estimated the occurrence of "lymphoid tissue" in the normal thyroid and

in the glands of simple and toxic goitre with results depending upon whether account was taken solely of lymphoid follicles with germinal centres or whether all such tissue, embracing lymphoid aggregations without germinal centres and diffuse round cell infiltrations, were included.

Only one author, however, - Lennox (1948) - appears to have made a systematic study of the occurrence of Askanazy tissue in the various forms of thyroid pathology, and his results are of some interest. Working with material, consisting of 250 surgically resected thyroids and 150 normal thyroids obtained postmortem, he recorded the following findings. Askanazy tissue was encountered in 12% of 150 normal thyroids, 16.3% of 123 cases of diffuse toxic goitre, 50% of 12 cases of toxic adenoma and 5% of 74 cases representing a mixed group of colloid goitres, nodular goitres and simple adenomas.

In Struma Lymphomatosa there is a near constant association between Askanazy epithelium and round cell infiltration, both lymphoid follicular and diffuse. The morphological identity of certain areas of simple and toxic goitres with Struma Lymphomatosa would be enhanced by the finding in such areas of this association of changes. It is, however, immediately apparent that this is not always so. In his material, consisting of normal glands, simple and toxic goitres, Lennox was generally impressed by the close association between Askanazy epithelium and round cell infiltration, but alludes also to the

/ apparently

apparently dissociated occurrence of the two changes. No statistical study of this point has been made in the present work, but Figs. 79 to 86 illustrate the findings in a small, unselected group of simple and toxic glands, examined with this problem in mind.

Simple Goitre

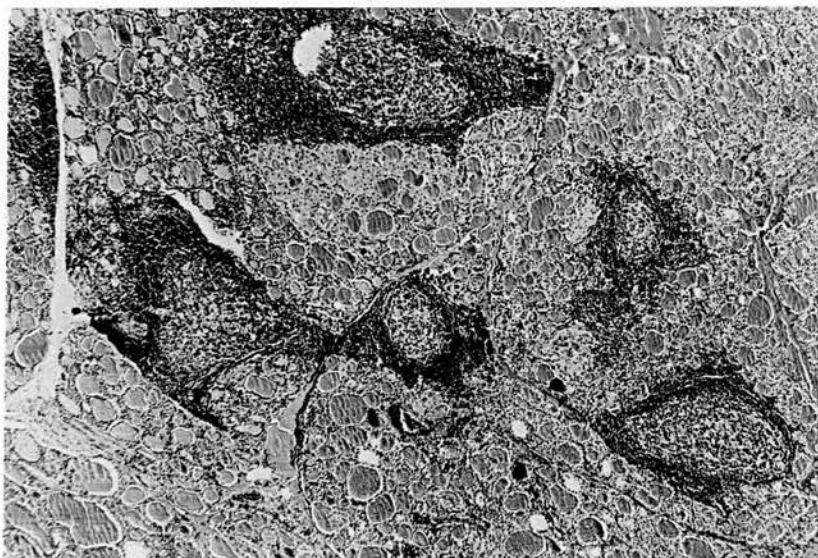

Fig. 79

Simple goitre showing well marked formation of lymphoid follicles with germinal centres.
H. & E. X 50.

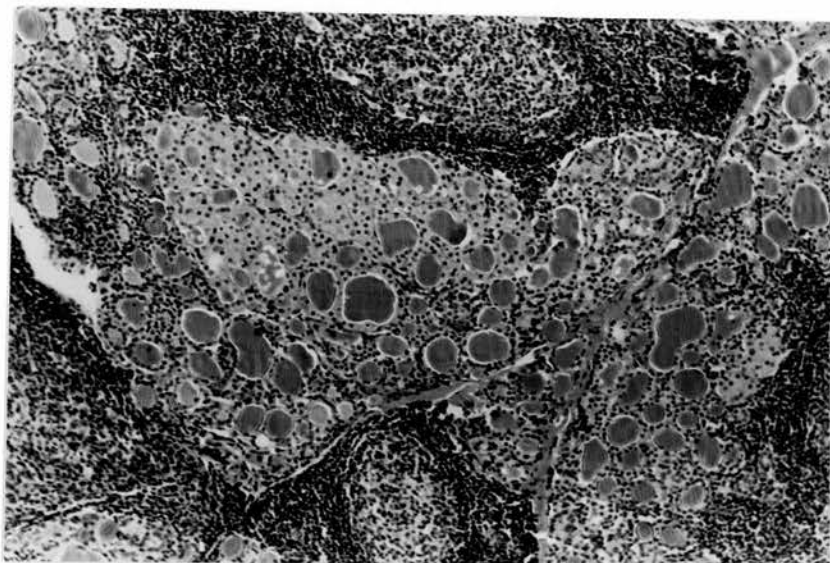


Fig. 80

Same view - higher magnification. In the centre of the field is an island of well developed Askanazy change, while, related to the lymphoid follicle on the right are two vesicles represented by a syncytium of Askanazy epithelium. H. & E. X 85.

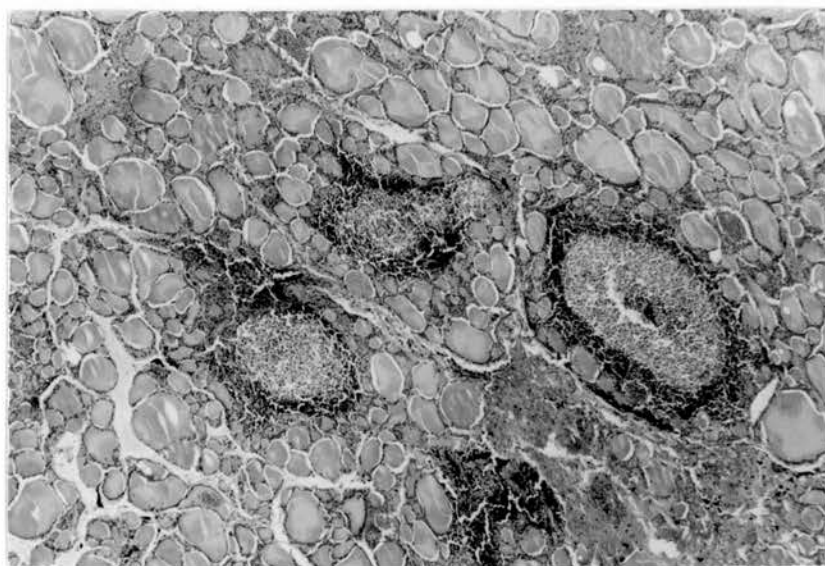

Fig. 81

Simple goitre showing collection of lymphoid follicles with germinal centres. H. & E. X 50.

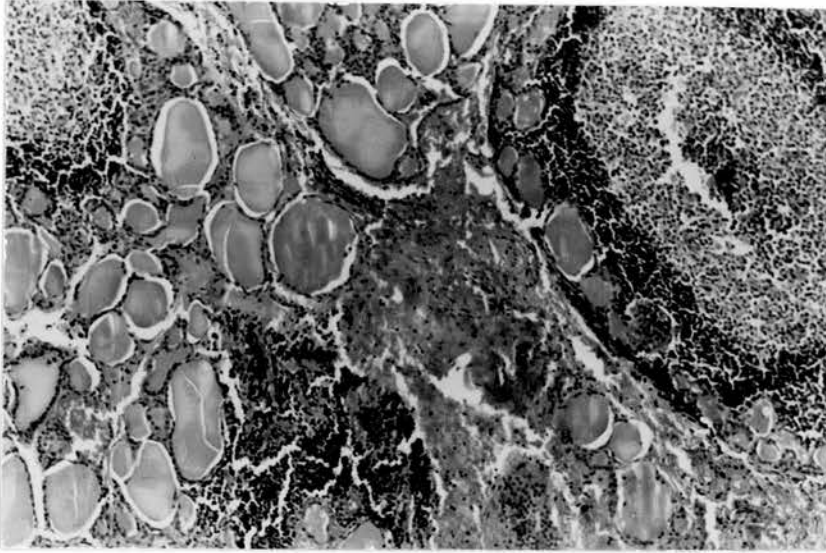


Fig. 82

Same view - higher magnification. Askanazy change is not in evidence. H. & E. X 85.

Toxic Goitre

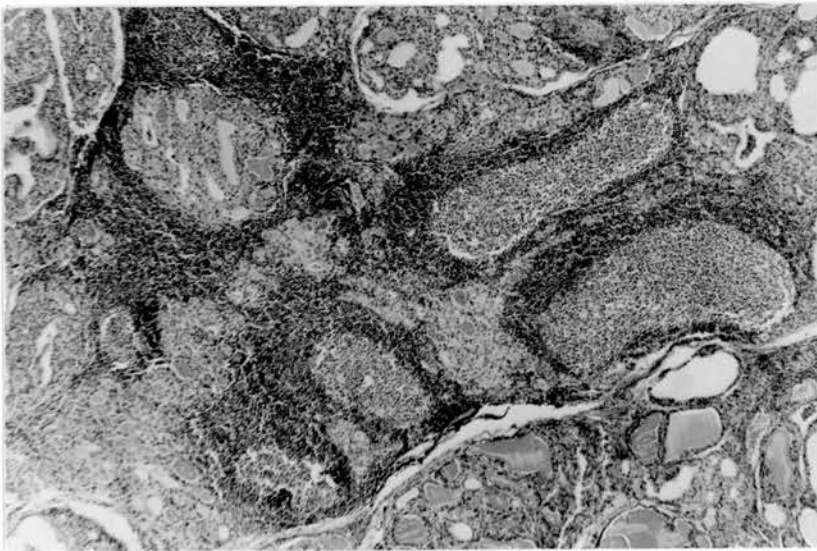


Fig. 83

Thyrotoxicosis showing area of lymphoid follicle formation. H. & E. X 50.

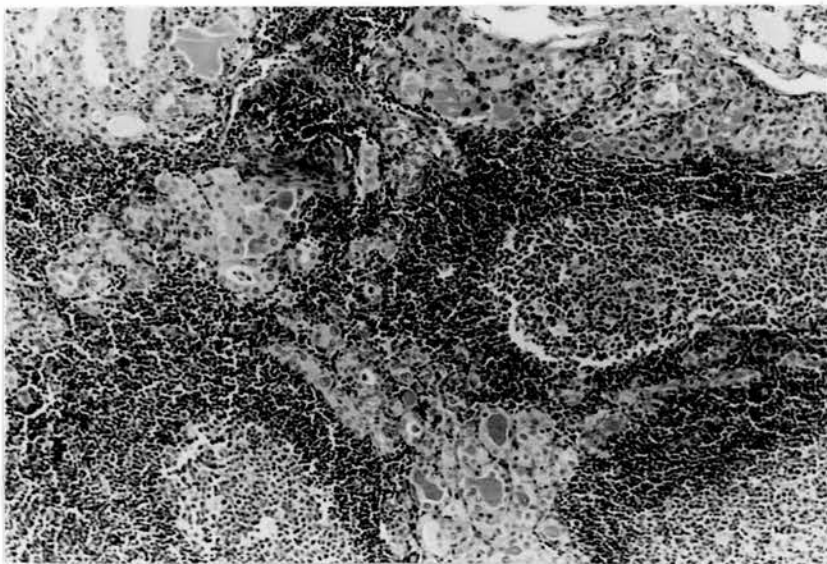


Fig. 84

Same view - higher magnification. Note well developed Askanazy appearance of related parenchyma. H. & E. X 85.

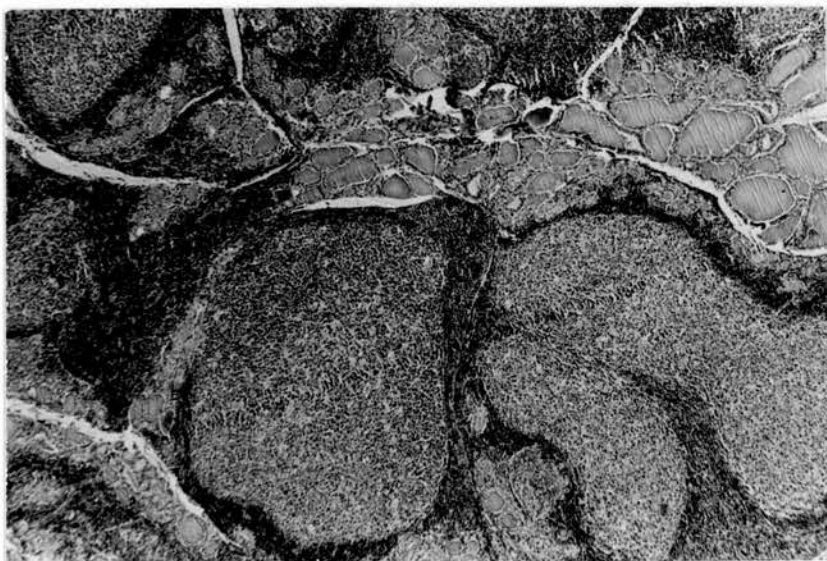


Fig. 85

Thyrototoxicosis showing marked lymphoid hyperplasia. H. & E. X 50.

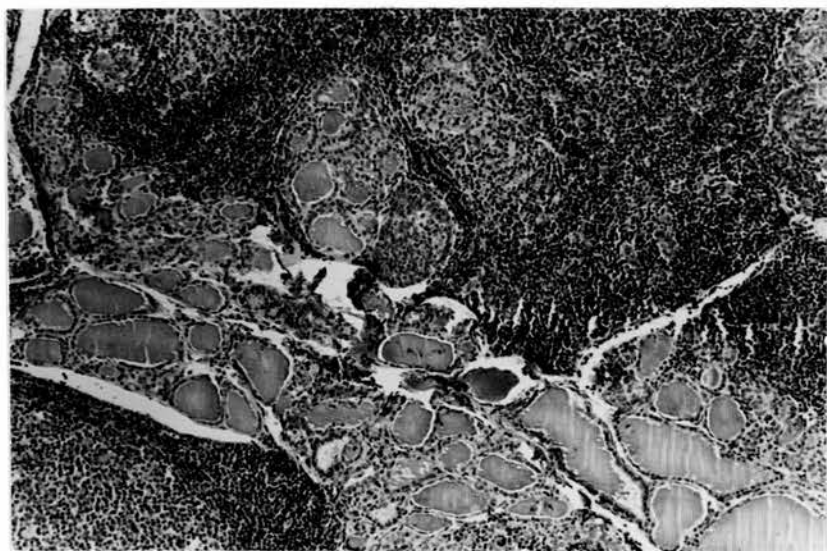


Fig. 86

Same view - higher magnification. The related parenchyma is compressed but there is no evidence of Askanazy change. H. & E. X 85.

It will be apparent from the foregoing illustrations that, in both simple and toxic goitre, lymphoid follicle formation (and round cell infiltration generally) may or may not be associated with Askanazy parenchymal change and while there is no obvious explanation for their association in some instances and dissociation in others, perhaps, in seeking a truer morphological relationship between these conditions and Struma Lymphomatosa, equal attention should be given to the parenchymal as to the mesenchymal changes.

2. The Clinical and Pathological Aspects

In dealing with the clinical assessment of thyroid function of the group of cases reviewed in Part II (pp. 99-104) the argument was expressed for the final

/ conclusion

conclusion that, having regard to purely clinical criteria, there is no direct aetiological relationship between thyrotoxicosis and Struma Lymphomatosa. Certainly in the vast majority of cases of the latter condition there is nothing in the anamnesis or physical examination to suggest remote, recent or present toxicity.

Polowe (1934), Eden and Trotter (1942) and Gtirkan (1945) have each reported single cases in which the full clinical picture of thyrotoxicosis was found, after removal of the gland, to be associated with the gross and microscopical appearance of Struma Lymphomatosa and the claim has been made that such cases provide, as it were, the "missing link" in the association between the two conditions. (Fuller clinical and pathological details of Polowe's and Eden and Trotter's cases were given on pp. 34 & 35). None of these authors appear to have been aware of the specific parenchymal (Askanazy) change in Struma Lymphomatosa and further, none of their illustrations would appear to confirm it in the material they present under such a diagnosis. As far as may be said without personal examination of the original histo-pathological preparations, the appearances in their microphotographs are not those of Struma Lymphomatosa and the cases in question might more properly be regarded as examples of Graves' disease exhibiting lymphoid hyperplasia.

The constant high incidence of hypothyroidism or myxoedema in Struma Lymphomatosa is well known. The finding of focal areas of lymphoid infiltration in certain simple and toxic goitres has led investigators to seek a

/ similar

similar relationship between the degree of replacement of such a gland by this infiltration and the subsequent liability of the patient to subnormal thyroid function. Thus Bothe (1931) suggested that cases demonstrating such areas of round cell infiltration were more prone to develop myxoedema following thyroidectomy. Whitesell and Black (1949) made a detailed study of this relationship. Eighty-six cases of exophthalmic goitre with associated "thyroiditis" were examined and the mean grade and the standard deviation of the grade of parenchymal replacement by "thyroiditic" tissue were calculated after perusal of multiple sections from each gland. They stressed the important point that the estimated degree of replacement may be fallacious unless many sections from several regions in the thyroid are examined. They gave attention to replacement by lymphocytes alone or by both fibrous tissue and lymphocytes, but did not comment upon any related parenchymal change. They found that patients with the mixed fibrolymphocytic type were somewhat older than patients with the lymphocytic type. Female patients showed greater replacement than male patients in each decade. With greater degrees of replacement the basal metabolic rates were lower and the incidence of auricular fibrillation was less. The incidence of exophthalmos increased progressively with increasing degrees of replacement. The incidence of post-operative myxoedema rose progressively with the degree of parenchymal replacement,

/ until,

until, in cases showing 40% to 50% replacement the incidence of post-operative myxoedema approached 70%.

Greene (1950) had similar findings in respect of the incidence of post-operative myxoedema. He followed the post-operative condition of 161 thyrotoxic patients after subtotal thyroidectomy and related the occurrence of hypothyroidism to the presence in the glands of lymphadenoid tissue. Thus, of his 161 cases, two were found to be suffering from Hashimoto's disease and the thyroids of a further 42 contained lymphadenoid nodules (lymphoid follicles with germinal centres) indistinguishable from those found in Hashimoto's disease. Like Whitesell and Black, he made no reference to parenchymal change. Of the 44 patients whose glands showed the characteristic change, 20 developed severe hypothyroidism and a further seven were under suspicion. Of the 117 patients whose glands did not show the characteristic change, none developed hypothyroidism. Greene advanced the hypothesis that those patients with toxic goitres which are found to contain lymphadenoid nodules are suffering from early Hashimoto's disease.

Thus Whitesell and Black, and Greene focused attention on the possibility that the occurrence of post-operative hypothyroidism in a particular patient might depend more on the degree of lymphoid replacement of the gland remnant and less on the exquisite judgment of the surgeon concerned in ensuring that the correct amount of thyroid tissue is left behind. The suggestion was also made that in thyrotoxic

cases, showing a significant degree of lymphoid replacement, spontaneous recovery from the thyrotoxicosis might be expected and operation so avoided. With this in mind, Greene (1953) attempted to define clinical criteria for the pre-operative diagnosis of such replacement, but failed, remarking:- "Except by palpation, by which it is possible to detect only the most severe changes, there is no means of making a pre-operative diagnosis of lymphadenoid replacement of normal thyroid tissue."

Before giving whole-hearted support to the foregoing hypothesis, it should be recalled that lymphoid hyperplasia may be extremely well developed without interfering significantly with the secretory powers of the gland and that a number of the severest thyrotoxicos, having demanded surgery for their control consequent upon the failure of medical management, are precisely those who show in the resected gland a significant degree of such replacement. In this connection also, the case cited by Dunhill (1937) is of interest. A patient with all the signs and symptoms of toxic goitre, established fibrillation and commencing congestive heart failure was submitted to thyroidectomy. The gross and microscopic findings were those of advanced lymphadenoid change. Myxoedema was confidently predicted. The patient remained well, however, for four or five years until, under the physical and emotional strain of her husband's illness and death, there was recurrent thyroid enlargement with return of fibrillation. A second operation was performed and the histo-pathology was the

usual one of toxic goitre without evidence of lymphoid infiltration.

In seeking further points of identification between thyrotoxicosis and Struma Lymphomatosa a recent publication by Anderson et al. (1957) is of some interest. In an investigation still in progress and using a complement-fixation reaction, these workers have obtained positive results, similar to those encountered in Struma Lymphomatosa, in 50 per cent of cases of thyrotoxicosis. They make no mention of histo-pathological findings in these thyrotoxic cases, the sera of which they have found to contain complement-fixing antibodies reacting with extracts of thyroid gland, but it will obviously be an important line of future investigation to correlate such serological reactions with the histo-pathology of the toxic gland and in particular with the degree of lymphoid replacement.

3. Conclusion

In the present state of our knowledge, it cannot be accepted as proved that a direct aetiological relationship exists between thyrotoxicosis and Struma Lymphomatosa. In this work attention has been devoted principally to Hashimoto's disease as it appears in its final and established form. That an earlier stage must exist cannot be denied and it may be tempting to infer that such a stage might, in fact, be one of "lymphoid thyrotoxicosis". Nevertheless the fact remains, that in those cases exhibiting what may be called the classical pathological

/ picture

picture of Struma Lymphomatosa, clinical evidence of toxicity is sought in vain and conversely, when flagrant thyrotoxicosis is clinically manifest, complete identity of pathological appearance is lacking. Until such time as a more convincing clinico-pathological transition is established or new facts come to light, the two conditions must be regarded as essentially distinct.

Aetiology of Struma Lymphomatosa

After nearly half a century of description and discussion the aetiology of Struma Lymphomatosa still remains unsolved. From time to time various theories of causation have been advanced but always these have lacked definite clinical or scientific confirmation. The purpose of this section is to provide a comprehensive review of past and present concepts regarding the aetiology and nature of this disorder and this would seem best accomplished under five headings.

1. Struma Lymphomatosa - a Thyroiditis

The earlier authors, Hashimoto (1912), Shaw and Smith (1925)⁽¹⁾ and Meeker (1925)⁽¹⁾, naturally regarded the histo-pathological findings in the thyroid as being indicative of a chronic inflammatory or granulomatous process and thus looked upon the condition as a true
/ Thyroiditis.

(1) These authors, although writing under the title of Riedel's Struma, were in fact describing Struma Lymphomatosa - see Part V.

Thyroiditis. Meeker described certain appearances in the thyroid which she interpreted as remnants of the ultimo-branchial body and postulated a possible extension of inflammation from the pharynx along the ultimo-branchial duct system - a hypothesis which has never received subsequent confirmation and would not appear to merit serious consideration. Indeed, with the passage of time, the whole tendency has been to discredit the belief that the condition has an inflammatory basis and most modern authorities do not, in fact, subscribe to the inclusion of Struma Lymphomatosa as a true Thyroiditis.

2. Struma Lymphomatosa - a Phase of Thyrotoxicosis

This theory of aetiology has already been discussed at different points in this work and in the immediately preceding section.

Here also may be mentioned the views of Warthin (1926), Boyden, Collier and Bugher (1935) and Dunhill (1937), all of whom laid emphasis on the possible influence of iodine medication in the genesis of Struma Lymphomatosa, a hypothesis which has, however, failed to receive confirmation in clinical experience.

3. Struma Lymphomatosa - a Primary and Unrelated Thyroid Disorder

Under this heading are considered a miscellaneous collection of hypotheses, the dominant theme being, however, the concept of either a constitutional disturbance or alternatively of a primary thyroid disorder unrelated in

/ nature

nature to the mechanism of other thyroid disease processes.

Reference has already been made to the experimental work of McCarrison (1927, 1929) and his claim for vitamin deficiency as an aetiological factor in Struma Lymphomatosa. McCarrison's work has never received subsequent confirmation or denial, but clinical experience is such as to suggest that dietary imbalance alone is a most improbable causal agent.

Graham and McCullagh (1931) were among the first to consider the pathological changes in Struma Lymphomatosa as being suggestive of the end result of some unknown constitutional disturbance. The process impressed them as a sclerosis and they drew an analogy to cirrhosis of the liver and nephrosclerosis.

Schilling (1945) considered Struma Lymphomatosa a distinct clinico-pathological entity, of degenerative rather than neoplastic or inflammatory nature. He further suggested that the excessive demands on the thyroid during the sexual life of the female might be fundamental in the aetiology of this disorder, such demands possibly being mediated through the pituitary.

Parmley and Hellwig (1946) regarded the disease as the result of a disturbance of the normal cycle of colloid secretion and release. They considered a decline of ovarian function as removing the antagonistic effect on pituitary activity with resultant increase of thyrotrophic hormone secretion. This, in turn, produced in the thyroid

loss of colloid and hyperplasia, but with deficient thyroid function as colloid synthesis was impaired. They drew an analogy to the disturbance of cyclical activity in the thyroid vesicle which occurs in thiouracil goitre, initiated, however, in the case of Struma Lymphomatosa, not by a chemical agent but by loss of ovarian function.

Chesky, Dreese and Hellwig (1951), employing supravital studies of fresh surgical material, suggested, that by change in the composition of colloid, macrophages are attracted into the lumen of vesicles, ingest colloid and return to the intervesicular stroma. There they disintegrate and the liberated colloid incites round cell aggregation. As a cause of the altered colloid composition they inferred an excess secretion of thyrotrophic hormone.

Statland, Wasserman and Vickery (1951) envisaged the primary event in Struma Lymphomatosa as a failure at thyroid cell level whereby the capacity to produce thyroid hormone is diminished although not completely or immediately abolished. They suggested, that although the cause of this primary alteration in thyroid cell status was unknown, it resulted in a secondary pituitary stimulation with increased production of thyrotrophic hormone and consequent thyroid enlargement. These observations first provided the basis for the treatment of the condition by thyroid substitution therapy. Skillern et al. (1956) elaborated this theory and postulated phases of compensated and decompensated thyroid failure.

Sommers and Meissner (1954), using histochemical techniques, demonstrated severe diffuse degenerative changes and discontinuities in the thyroid basement membranes in "chronic thyroiditis". They regarded this as suggestive morphological evidence that a major factor in pathogenesis might be the failure to maintain an effective structural continuity of the thyroid basement membrane, and noted comparable situations in thymic embryology and in Mikulicz's disease of salivary glands.

4. Struma Lymphomatosa - an Auto-Immunisation

The most recent and exciting hypothesis concerning the aetiology of Struma Lymphomatosa is the concept of an auto-immunisation and has stemmed from the work of Witebsky and Rose (1956). These workers found that crude saline extracts of rabbit thyroids proved antigenic for rabbits, the antibodies being demonstrable by complement-fixation, precipitation and other techniques. Such antibodies they found to be tissue-specific and produced in thyroidectomized, or partially thyroidectomized, rabbits injected with extracts of their own thyroid glands. They were also able to induce severe changes in the thyroid glands of rabbits immunized with thyroid extract, consisting of parenchymal replacement by a lymphocytic and eosinophilic round cell infiltration.

The clinical application of this work was suggested by Roitt et al. (1956), who obtained precipitin reactions between the serum of Hashimoto patients and saline extracts

of normal thyroid glands. They suggested that the antigen might be thyroglobulin and envisaged a progressive interaction between the latter and the auto-antibody in the patient's serum, resulting in the thyroid destruction of Struma Lymphomatosa.

Similar results have been published by Anderson et al. (1957) who have, in addition, applied these tests to cases of thyrotoxicosis and obtained positive findings in 50 per cent of such material. Many authors - Shaw and Smith (1925)⁽¹⁾, Brenner (1928), Saphir and Binswanger (1930), Wells (1930), Weller (1936) and Rushton, Cragg and Stalker (1940) - have described Hashimoto-like changes in the thyroid glands of patients dying from non-tuberculous Addison's disease. In such cases, the adrenals themselves show atrophy and round cell infiltration. Anderson et al., have now demonstrated, in certain cases of Addison's disease, the presence of an anti-adrenal antibody giving a complement-fixation reaction with extracts of adrenal gland and by analogy, have inferred a similar process of auto-immunisation as being responsible for the progressive destruction of the adrenal cortex in idiopathic forms of this disease. In two cases of Addison's disease, one with Hashimoto changes in the thyroid, they have found both anti-adrenal and anti-thyroid antibodies and they have

/ suggested

(1) see footnote, p. 190.

suggested that certain cases of Addison's disease may in fact produce both auto-antibodies.

The foregoing experimental and clinical work awaits urgent extension and confirmation before its true significance can be evaluated, but it seems possible that it may open up an altogether new and far-reaching concept of the aetiology and pathogenesis, not only of Struma Lymphomatosa, but of other endocrine disease processes.

5. Struma Lymphomatosa - Geographical Factors:
Incidence; Age and Sex Distribution

Struma Lymphomatosa appears to be significantly commoner in Great Britain and America than in other geographical locations. It is of interest to note, for example, that de Quervain of Berne writing in 1936, reveals little personal contact with the disorder and reproduces microphotographs lent by a Dr. Rast of London. In a recent personal Continental visit (1956), embracing such centres as Lyons, Strasbourg, Zurich, Berne, Utrecht and Copenhagen, one striking feature was the great rarity of and lack of knowledge concerning this thyroid disease, which contrasts sharply with the considerable numbers of cases reported from British and American centres.

As is obvious from Fig. 87 the incidence of Struma Lymphomatosa has varied widely according to different authors - 0.2% Osmond and Portmann (1949) to 7.2% Chesky et al. (1951). In the present series the incidence was 5.9%, if the 18 cases reviewed in Groups 1 and 2, Part III, be included. Such divergent findings are no doubt partly

/ explained

AUTHOR	LOCATION	PERIOD	TOTAL THYROIDECTOMIES OR CASES OF THYROID DISEASE	TOTAL CASES OF THYROIDITIS		STROMA LYMPHOMATOSA		SUBACUTE THYROIDITIS		RIEDEL'S THYROIDITIS	
				NO.	PER CENT.	NO.	PER CENT.	NO.	PER CENT.	NO.	PER CENT.
GRAHAM	EDINBURGH	-	670	-	-	6	0.9	-	-	-	-
RENTON, CHARTERIS AND HEGGIE (1)	GLASGOW (1938)	-	418	-	-	7	1.7	-	-	-	-
KETNES	LONDON	TO JAN. 1939	1,600	-	-	25	1.6	-	-	-	-
JOLL	LONDON	TO JAN. 1939	5,650	-	-	51	0.9	-	-	-	-
MARSHALL, MEISSNER AND SMITH	BOSTON, U.S.A.	1928 - 1946	25,000	187	0.7	78	0.3	-	-	-	-
CRILE	CLEVELAND, OHIO, U.S.A. (1948)	-	900	25	2.8	3	0.33	17	1.9	5	0.5
OSHOND AND PORTMANN	CLEVELAND, OHIO, U.S.A.	1936 - 1947	7,045	143	2.0	16	0.2	93	1.3	11	0.1
ALLEN AND REEVES	NORTH CAROLINA, U.S.A.	1930 - 1949	2,685	63	2.3	12	0.4	36	1.3	15	0.5
CHESKY, DREESE AND HELLNIG	KANSAS, U.S.A.	1941 - 1951	2,031	169	8.3	14/6	7.2	9	0.4	8	0.4
LINDSAY, DAILEY, FRIEDLANDER, WEE AND SOLEY	CALIFORNIA, U.S.A.	1920 - 1950	6,571	195	3.0	170	2.6	23	0.3	2	0.03
PRESENT SERIES	EDINBURGH	1943 - 1957	1,008	60(2)	5.9	60	5.9	0	0	0	0

(1) PUBLISHED AS RIEDEL'S STROMA

(2) 18 CASES IN GROUPS 1 AND 2, PART III, INCLUDED.

FIG. 37

THE INCIDENCE OF CHRONIC NON-SPECIFIC THYROIDITIS (VARIOUS AUTHORS).

explained by differing diagnostic criteria in different centres and there seems little doubt that most modern authors have found a decidedly higher incidence of the disease than did the earlier investigators. This is probably due to its better and more frequent recognition resulting from greater clinical and pathological familiarity with the disorder, rather than an actual increased incidence.

In this series of cases the age at time of treatment varied from 36 to 74 years, the mean being 50.9 years. The incidence by decades is shown in Fig. 88.

These figures coincide with the findings of most other authors. Thus Marshall et al. (1948) had an average age of 50 years in 78 cases and Joll (1939) an average of 57.6 years in 81 cases, the youngest in his series being a girl aged 10 years. Certain investigators, however, in substantially large series of Struma Lymphomatosa have found a rather younger age distribution of their cases. Schilling (1945) puts the maximum age incidence in the fourth and fifth decades: Lasser and Grayzel (1949), average age 38 years: Statland et al. (1951), 42.3 years: Lindsay et al. (1952), 31.7 years: Taylor (1955) remarks that the disease most frequently presents between the ages of 30 and 40 years. A number of cases have now been reported in children and adolescents, but the youngest on record appears to be a girl aged six years at the onset of the condition, presenting for treatment at the age of $7\frac{1}{2}$ years, and

/ reported

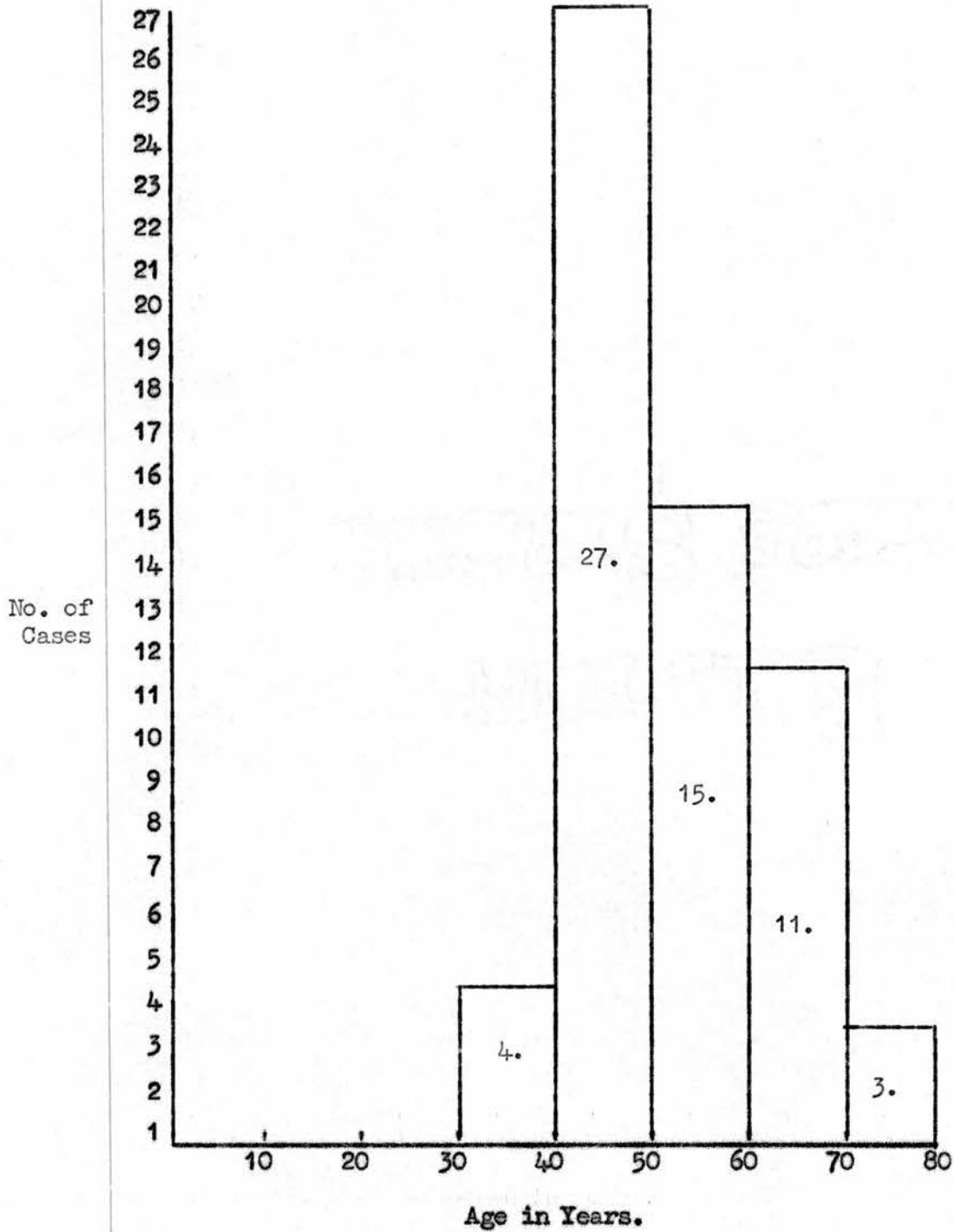


Fig. 88

Age Distribution of 60 Cases of Struma Lymphomatosa.
 (18 Cases in Groups 1 and 2, Part III, included).

reported by Lasser and Grayzel (1949). Gribetz et al. (1954) present a remarkable series of six girls all of whom were between the ages of 9 and 13 years when first seen, the goitres having developed when they were between 6 and 10 years old.

One note of warning seems necessary concerning the inclusion of such cases under the diagnosis of Struma Lymphomatosa. The possibility must be kept in mind of an adolescent simple goitre exhibiting focal lymphoid hyperplasia, and this must lead one to examine very carefully the diagnosis of Struma Lymphomatosa in any very young patient.

Regarding the sex incidence, 54 of the cases in the present series were females and six were males (10%). These figures may be compared with those for sex distribution taken from a number of major series. (Fig. 89).

Summary

In Part III, certain clinico-pathological variations from what must be accepted as the classical picture of Struma Lymphomatosa have been illustrated by reference to a further 18 cases divided into two groups and this material has been added to that reviewed in Part II, making a collective series of 60 cases of this disorder.

The relationship of Struma Lymphomatosa to certain other forms of thyroid disease, notably thyrotoxicosis, has been considered and the various hypotheses concerning its aetiology reviewed.

Author	Date	No. of Cases	Female	Male
Joll	1939	81	96.3%	3.7%
Marshall et al.	1948	78	98.7%	1.3%
Statland et al.	1951	51	100%	-
Lindsay et al.	1952	170	99%	1%
Taylor	1955	33	93.9%	6.1%
Present Series (1)	1957	42	90%	10%

Fig. 82

Sex Distribution of Struma Lymphomatosa.

(1) 18 cases in Groups 1 and 2, Part III, included.

PART IV

SUBACUTE THYROIDITIS

Introduction

On pp. 37-46 are set forth extracts from the work of de Quervain of Berne who first drew attention to this disorder in 1904. In a second paper (with Giordanengo) in 1936, there came into being the concept of a hitherto unrecognised form of thyroid disease, which de Quervain called Subacute Thyroiditis. Schilling (1945) recognised the existence of the disease and reported cases, but preferred to regard it as a variant of Struma Fibrosa (Riedel) rather than as a clinico-pathological entity in its own right. Also in 1945, King and Rosellini recorded the first attempt at definitive treatment of the condition employing thiouracil. Nevertheless, the disease remained virtually unknown and unrecognised until the last decade, during which, however, much attention has been focused upon it and increasingly frequent case reports and series of cases have appeared, especially from American sources. Thus, although first described half a century ago and at a time comparable with the first descriptions of the other major forms of Thyroiditis, the disease is only now achieving its due recognition and appearing for the first time in standard medical, surgical and pathological works. As a now established part of the spectrum of Thyroiditis it merits consideration in the present study.

Synonyms

Subacute or de Quervain's Thyroiditis has come to be known by a miscellany of other titles, the principal of

/ which

which are pseudotuberculous thyroiditis, giant cell thyroiditis and granulomatous thyroiditis or struma granulomatosa, all terms descriptive of the histo-pathological features of the disease.

Geographical Distribution

The disease would appear to show a peculiar geographical distribution, which cannot be wholly or satisfactorily explained by differing degrees of clinical and pathological acumen in its recognition in different parts of the world. Thus it appears to be of common occurrence in America and Scandinavia, but decidedly rare in this country and on the Continent of Europe. Crile (1948), from the Cleveland Clinic, Ohio, was able to report 27 cases of Subacute Thyroiditis, as against 14 cases of Struma Lymphomatosa and 11 cases of Riedel's Thyroiditis. Osmond and Portmann (1949), (Fig. 87), from the same centre, reviewed 7,045 cases of thyroid disease between the years 1936-1947 and found 143 cases of Thyroiditis, of which no less than 93 were examples of Subacute Thyroiditis, there being only 16 cases of Struma Lymphomatosa and 11 cases of Riedel's Thyroiditis. Allen and Reeves (1951), from North Carolina, reviewed 2,685 cases of thyroid disease occurring between 1930 and 1949. They had 65 cases of Thyroiditis, of which 36 were classified as Subacute Thyroiditis, 12 as Struma Lymphomatosa and 15 as Riedel's Thyroiditis. Other American authors, however, have not found the same high incidence of this disease. Thus Chesky et al. (1951), from

/ the

the Hertzler Clinic, Kansas, reviewed 2,031 patients requiring thyroidectomy in the previous ten years and found 169 cases of Thyroiditis, of which only nine were interpreted as Subacute Thyroiditis, there being 146 cases of Struma Lymphomatosa and eight cases of the Riedel type. The figures of Lindsay et al. (1952), from California, are similar - of 6,571 thyroidectomies carried out from 1920 to 1950, there were 195 cases of Thyroiditis, distributed thus - Struma Lymphomatosa 170, Subacute Thyroiditis 23, Riedel's Thyroiditis 2. These series of cases are, of course, not strictly comparable as regards manner of selection, treatment and probably diagnostic criteria, yet they do emphasise the not infrequent occurrence of Subacute Thyroiditis in America and are supported by numerous other reports of isolated and smaller groups of cases.

In striking contrast to this there are, to date, only two references to the disease in the British literature. Fraser and Harrison (1952) reported three cases of Subacute Thyroiditis and Taylor (1955) claimed to have seen six examples of the disorder in the previous three years. In the surgical charge of Mr. K. Paterson Brown in the Royal Infirmary of Edinburgh, 1,008 thyroid operations were carried out between 1st October, 1943 and 31st March, 1957, and on no occasion was a clinical or pathological diagnosis of Subacute Thyroiditis made. Earlier cases may, of course, have been missed because of unfamiliarity with the clinical and pathological picture, but during the last two years of

/ this

this period, despite constant awareness of and search for the occurrence of the disease, no example has been detected among the thyroid material presenting for surgical treatment. There is good reason to believe that physicians in this centre, who might conceivably have been responsible for filtering off a type of thyroid disorder not requiring surgical management, have in fact an equally negative experience of Subacute Thyroiditis. Since 31st March, 1957, however, the opportunity has been afforded for the study of one case which merits consideration in the present context and this is reported and discussed separately after the classical picture of the disease has been reviewed.

Incidence

The incidence of Subacute Thyroiditis is thus difficult to compute in the light of these variable geographical findings. It is difficult to know whether the increased frequency of the past decade represents an overall increase in incidence of the disease or is due to better recognition. Crile and Rumsey (1950) reported that in the three year period 1946 through 1948, 38 patients with Subacute Thyroiditis were seen at the Cleveland Clinic, as compared with only 27 patients in the ten year period 1936 through 1945. Lindsay and Dailey (1954), on the other hand, could find no significant change in incidence in each of the three decades from 1920 to 1950.

The Clinical Aspects

1. Age and Sex Distribution

Subacute Thyroiditis occurs most commonly between 30 and 50 years of age. The disease is seen most frequently in women: Crile and Rumsey (1950) had only five males in 38 cases, Lindsay and Dailey (1954) four males in 25 cases.

2. Symptomatology

The classical case of Subacute Thyroiditis commences fairly acutely with symptoms of sore throat, malaise, fever and pain in the thyroid gland. In an undetermined but apparently high proportion of cases, the disease is preceded by an acute upper respiratory infection. The pain, in addition to being felt in the anterior region of the neck, frequently radiates to the jaw, ear or occiput on one or both sides and on occasion has led to the patient being referred early in the disease for a dental or aural opinion. As the disease progresses prominent constitutional manifestations become apparent. These include fatigue, weakness and lassitude which are often so severe as to be incapacitating. Night sweats and chills are sometimes noted. The temperature, often considerably elevated in the earlier stages, thereafter settles to a low grade fever which may persist for weeks or months. Considerable weight may be lost and a serious state of ill-health develop. In certain instances symptoms simulating hyperthyroidism such as nervousness, tremor, excessive perspiration, heat intolerance and palpitation may be observed. Pressure

/ symptoms

symptoms are not in evidence although swallowing may be difficult and painful.

While such is the symptomatology of the classical case, Grile has emphasised that many cases are of a milder type, with little if any fever, slight pain and insignificant systemic symptoms. Between the two extremes, all combinations of local and systemic reaction have been described.

The interval between the onset of the disease and the time the patient presents for treatment may vary considerably, being largely dictated by the severity of the illness.

3. Physical Signs

The thyroid gland is usually diffusely though not greatly enlarged perhaps to twice its normal size. Its consistency is characteristically firm or hard. In the severe case the gland is exquisitely tender, but tenderness is variable and later in the course of the disease and in the milder forms, may be slight or indeed altogether absent.

Although the entire gland is usually involved, the process may be focal within the thyroid involving one lobe only or part of a lobe. When this is so, the disease may continue to spread involving successive portions of the gland, with corresponding continuation or recrudescence of symptoms and to this form has been applied the term "creeping" or "migratory" thyroiditis.

The remainder of the physical examination is negative, apart from confirming varying degrees of ill-health, fever and tachycardia.

Laboratory Investigations1. Sedimentation Rate

The sedimentation rate is consistently elevated in Subacute Thyroiditis and constitutes a useful diagnostic and prognostic index in this disorder.

2. Leucocyte Count

Leucocytosis is not a feature of the disease.

3. Anaemia

Skillern et al. (1956) described a significant normochromic, normocytic anaemia in 11 of 66 patients with Subacute Thyroiditis, the blood findings returning to normal as the disease subsided.

4. Basal Metabolism

The basal metabolic rate is not materially affected in the majority of cases and is difficult to interpret in a painful, febrile illness.

5. Serum Protein Abnormalities and Serum Flocculation Reactions

Electrophoretic studies of the plasma proteins have not, to date, been applied to Subacute Thyroiditis with any frequency, and the results have so far been of a non-specific character. Fromm et al. (1953) reported a decrease in serum albumin and a significant increase in alpha, beta and gamma globulin levels in one patient with Subacute Thyroiditis. Skillern et al. (1956) found a moderate decrease in serum albumin in five of six patients, a slight increase of gamma globulin in two of six patients and an increase in alpha and beta globulins in one patient. They also performed the serum colloidal gold test in 11 patients

/ with

with this disease and found it normal in nine. Stemmermann (1956) reported an elevation of the alpha₂ globulin fraction in four patients suffering from Subacute Thyroiditis.

6. Radioactive Iodine (¹³¹I) Studies

¹³¹I studies in Subacute Thyroiditis have provided an extremely valuable diagnostic index for this disease. Werner et al. (1949) first drew attention to the very depressed uptake of ¹³¹I by the thyroid in the early stages of this disorder and all subsequent investigators have confirmed this - Hamilton et al. (1950), Robbins et al. (1951), McConahey and Keating (1951). This depression of ¹³¹I uptake is a very marked and characteristic feature of the disease in its early stages. Crile and Rumsey (1950) have observed that this depression occurs even when only one thyroid lobe is involved clinically. Furthermore this low uptake is seen in the presence of clinical euthyroidism and normal basal metabolism findings. As the pathological process subsides and coincident with clinical improvement, ¹³¹I uptake by the thyroid returns to normal.

The serum protein-bound iodine (PBI) has frequently been reported to be elevated in the early stages of the disease and co-existent with the depressed thyroidal uptake of ¹³¹I, - Hamilton et al. (1950), Robbins et al. (1951) and Lindsay and Dailey (1954). In no other thyroid disease does this paradox exist and it has naturally a great diagnostic significance. Where serum PBI is elevated it returns to normal levels as the disease subsides.

To explain these findings it has been suggested that, as a result of the pathological process in the gland, preformed colloid is absorbed into the circulation and brings about a secondary suppression of iodine uptake via the pituitary. Robbins et al. (1951), however, have pointed out that, since depression of uptake of ^{131}I may occur even when the level of the protein-bound iodine is not elevated, perhaps the disease itself depresses pituitary function non-specifically. Low uptake of ^{131}I might be accounted for solely by damage to thyroid epithelium, due to the action of the primary aetiological factor whatever that might be, but such a hypothesis does not explain those cases where the disease process is focal within the gland, although Fraser and Harrison (1952) have suggested that injury to thyroid epithelium might be general and yet not produce clinically evident thyroiditis in the entire gland.

The only two reports of studies with thyroid-stimulating hormone (TSH) in Subacute Thyroiditis have been conflicting. Robbins et al. (1951) treated six patients with TSH in doses of 25 to 150 mg. over a one-day to five-day period, and induced an increase in the uptake of ^{131}I by the thyroid in all instances, although in only two patients did this reach normal levels. Skillern et al. (1956) failed to influence ^{131}I uptake in ten of twelve patients, but the dose of TSH used was much smaller - 10 mg. - and this doubtless accounts for the discrepancy.

/ Diagnosis

Diagnosis

As has already been indicated Subacute Thyroiditis is now being diagnosed quite regularly in certain parts of the world and in the classical case the symptomatology and physical signs are such as to render this a matter of no great difficulty. The increased sedimentation rate provides confirmation, while the finding of a greatly depressed ^{131}I uptake in the presence of a normal or elevated serum protein-bound iodine is virtually pathognomonic. The condition may and in the past has undoubtedly and frequently been mistaken for an acute thyroiditis of bacterial origin: in Subacute Thyroiditis, however, no organism can be demonstrated and there is no leucocytosis. Haemorrhage into a nodule or cyst in a simple goitre may cause acute pain and swelling in the neck, but the pain is usually short-lived, there is no elevation of sedimentation rate and the characteristic ^{131}I findings of Subacute Thyroiditis are lacking.

In the milder type of case, with relatively slight local and systemic manifestations, and also in the more severe form when the patient has delayed seeking medical advice and the initial reaction has largely resolved, the diagnosis may be much more difficult and, faced with a hard, enlarged thyroid gland, the clinician may suspect a malignant condition. In such cases careful questioning may be required to elicit a history of local thyroid pain and tenderness and systemic upset at the onset of the illness.

The condition is unlikely to be confused with Struma Lymphomatosa, in which thyroid pain and tenderness are infrequent findings. Here again, however, the mild or resolving case of Subacute Thyroiditis, with, as its most prominent feature, a firm or hard, diffusely enlarged gland, may offer greater difficulty in its differentiation from that disorder. Subacute Thyroiditis has, in the past, been quite regularly misdiagnosed as Riedel's Thyroiditis. This is a point of considerable importance and will be dealt with more fully in the discussion of the latter condition.

The final diagnostic measure is biopsy of the thyroid and demonstration of the characteristic histo-pathological picture and for this purpose, as with Struma Lymphomatosa, Crile has advocated the technique of needle biopsy.

Clinical Course

Subacute Thyroiditis is a self-terminating disorder and even without treatment the natural course of the disease is towards spontaneous recovery. It may, however, be many weeks or months before final resolution occurs and during this time the patient may experience recurrent flares of the disease, successive involvement of different parts of the gland - "creeping" or "migratory" form - and may be considerably incapacitated by the local and systemic reaction. In the majority of reported cases, thyroid function has been found to be normal after the pathological process has subsided and recovery has taken place.

/ Aetiology

Aetiology

The cause of Subacute Thyroiditis is unknown. The most popular theory of causation is that the primary epithelial injury is due to a virus infection of the gland. The acute onset with fever, pain and tenderness and the frequent history of an antecedent upper respiratory infection would appear to support this hypothesis, although to date no confirmation of virus infection has been obtained. The fact that the disease frequently enjoys a prolonged and what might be called "grumbling" course, is explained on the basis of the colloid which is liberated into the tissue spaces and which may or may not be altered in composition, acting as a foreign body and provoking a granulomatous reaction, thereby superimposing a secondary chemical inflammation and so perpetuating the disorder until such time as the extravasated colloid has been resorbed.

Lindsay and Dailey (1954) have suggested that a hypersensitivity response might be involved and have further observed that more than one aetiological agent may cause the original thyroid epithelial injury. They have demonstrated histological changes identical with those of Subacute Thyroiditis in scattered follicles in colloid goitres and in a gland irradiated with ^{131}I .

Bacterial invasion of the thyroid has never been demonstrated and antibiotic therapy has been regularly unsuccessful in arresting the course of the disease or ameliorating its clinical manifestations. That the disease

may represent a form of "toxic" thyroiditis, however, as suggested by the work of de Quervain and later of Schilling, remains a possibility.

Pathology

1. Operative Findings

While thyroidectomy offers a satisfactory means of controlling Subacute Thyroiditis, it is nevertheless an undesirable form of treatment in a disease which is essentially self-limited, for which effective forms of conservative management exist and in which the patient is left with normal thyroid function at the conclusion of the illness. Consequently reports of gross operative pathology are infrequent and have been made principally in those earlier cases submitted to operation in ignorance of the true nature of the condition. Lindsay and Dailey (1954) have, however, reported on a group of 25 cases treated by thyroidectomy and their findings are of interest. The majority (22 of 25) were extremely adherent to adjacent structures including the trachea and cervical muscles. The muscles and adhering connective tissues were often oedematous and in such cases the thyroid capsule could not be distinguished from the surrounding tissues. One hard, fibrous gland caused severe tracheal constriction. The majority of glands had smooth surfaces, displaying nodular bosselations in a few instances, but no discrete superficial nodules were observed.

Not all authors appear to have found the same high incidence and marked degree of glandular adherence as have

the foregoing. Crile (1948) regarded the capsule as being only very lightly adherent to surrounding structures and de Quervain and Giordanengo (1936), in their eight cases, commented upon adherence in only three. It is to be noted, also, that in the material of Lindsay and Dailey, despite their gross findings, thyroidectomy was uniformly possible. It seems therefore that, while the gland of Subacute Thyroiditis may be adherent to surrounding structures, the disease is not productive of the invasive extra-glandular fibrosis which has been held to be so characteristic of Riedel's Thyroiditis.

2. Gross Appearance

The thyroid may be uniformly or focally involved. The associated presence of nodules or adenomata is highly unusual. When the gland shows diffuse involvement, it is rarely enlarged to more than two or three times its normal size. Lindsay and Dailey (1954) reported the mean weight of the excised tissue as 22.7 gm. with a range of 8.5 to 74 gm.: only ten of their specimens weighed 25 gm. or more. The cut surface is abnormally white, avascular and fibrotic, while the consistency varies from firm and resilient to woody or stony hard. Varying degrees of yellow, grey or white fibrous replacement of the thyroid parenchyma are observed, with corresponding decrease in the amounts of visible colloid.

3. Histo-pathology

(a) Changes in the thyroid vesicle

The initial lesion in Subacute Thyroiditis appears to

/ consist

disappears. Micro-abscesses may be found. (Fig. 91).

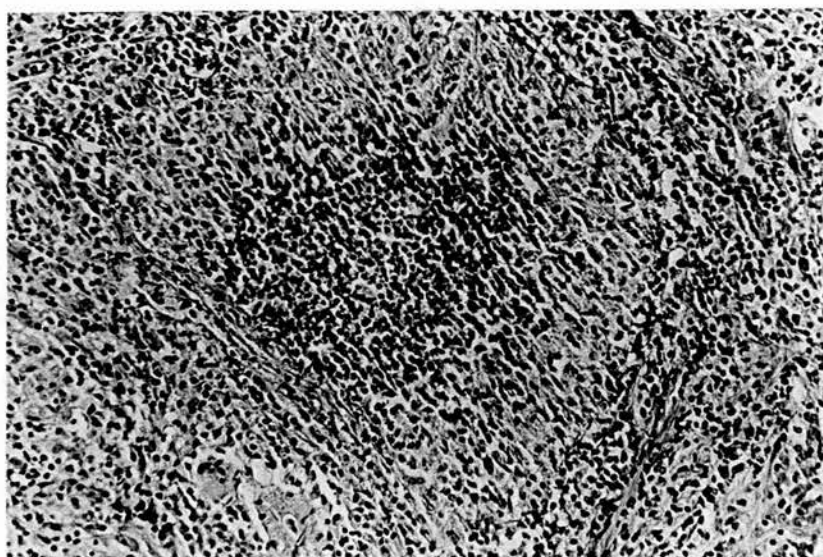


Fig. 91

Subacute Thyroiditis - further stage showing loss of colloid, inflammatory reaction and formation of micro-abscess. H. & E. X 150.

The most characteristic cell observed in the thyroid vesicle, however, is the multi-nucleated giant cell, concerning the origin and nature of which there is no uniform agreement, there being a division of competent pathological opinion as to whether they are derived from desquamated vesicular epithelial cells or in fact represent true foreign-body giant cells of the Langhans type. Certainly they constitute a distinctive feature of the histo-pathological picture. (Figs. 90, 92 and 93).

/ In

consist of an acute degeneration of the vesicular epithelium, the degenerating epithelial cells being shed into the vesicular lumen. This degeneration is accompanied by a polymorphonuclear and mononuclear infiltration in and around the vesicle, with the production of an inflammatory exudate. (Fig. 90).

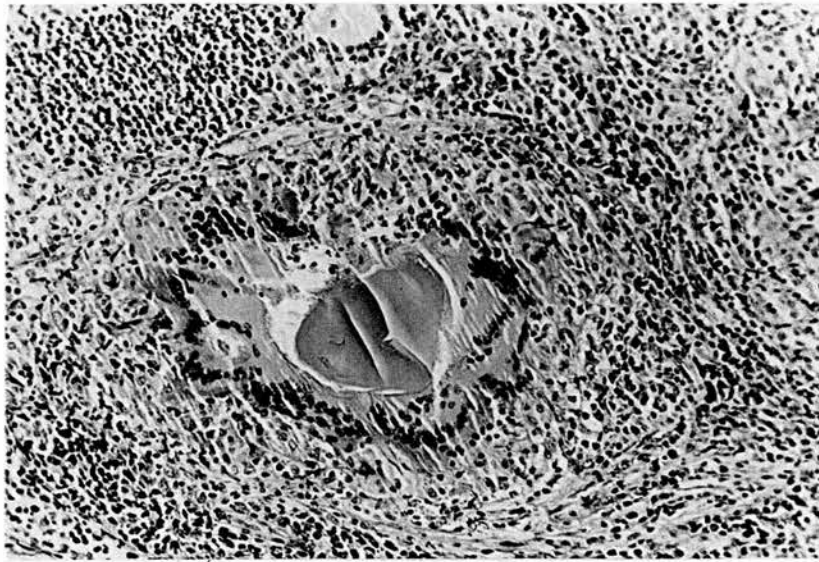


Fig. 90

Subacute Thyroiditis - the central thyroid vesicle shows degeneration and desquamation of its lining epithelium and the formation of multinucleated giant cells. There is an accompanying intra- and peri-vesicular infiltration of mononuclear and polymorph type. H. & E. X 150.

The disease would appear to be essentially focal and lesions of differing age may be seen in different parts of the same gland. As the disease advances, however, more of the parenchyma is involved by this epithelial change and leucocytic infiltration and colloid progressively

/ disappears.

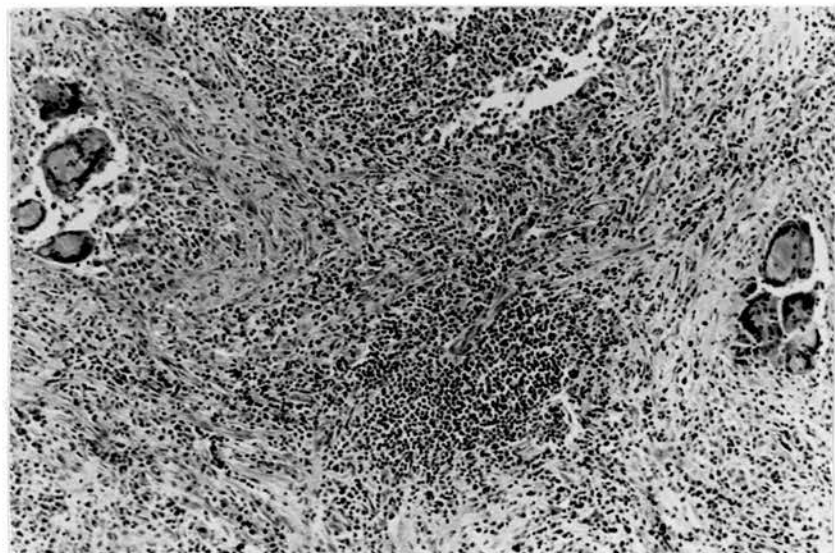


Fig. 92

Subacute Thyroiditis - general view showing loss of thyroid structure, granulomatous reaction with multiple giant cells, round cell infiltration and fibrosis. H. & E. X 90.

In later stages of the disease, the foregoing vesicular appearances have been reported to regress and the thyroid epithelium to regenerate to some extent and become reorganised as groups of small vesicles. Nowhere does the thyroid vesicular structure approximate to the Askanazy type, seen in a majority of cases of Struma Lymphomatosa.

(b) Changes in the stroma

The foregoing vesicular changes are accompanied by a considerable peri-vesicular and stromal inflammatory reaction, characterised by a polymorphonuclear, lymphocytic and plasma cell infiltration. (Fig. 93). The formation of discrete lymphoid follicles with germinal centres, so

/ characteristic

characteristic of Struma Lymphomatosa, is very rarely observed. Finally, in later stages of the disease there may be considerable fibrosis with extensive scarring of the gland.

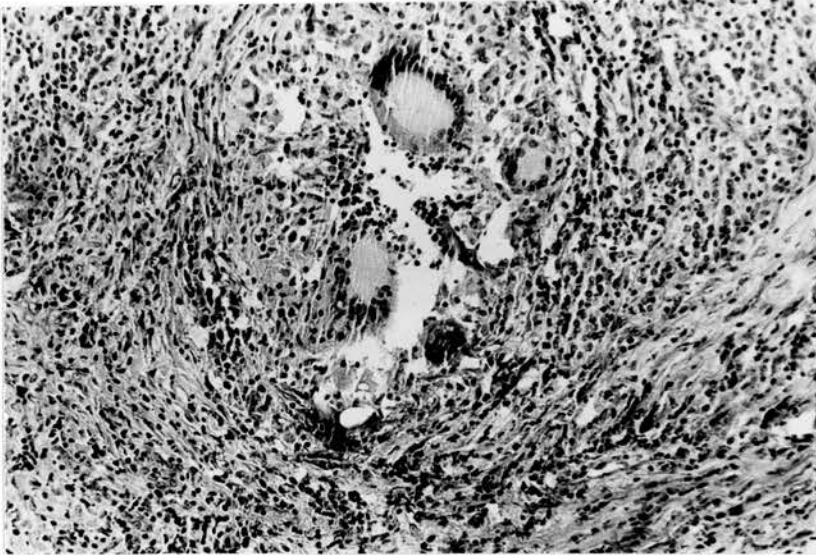


Fig. 93

Subacute Thyroiditis - vesicular and stromal changes. H. & E. X 160.

(c) Comment

The histo-pathological picture of Subacute Thyroiditis is distinctive and now well recognised. The tubercle-like arrangement of the numerous focal areas of granulomatous reaction has been responsible for the terms pseudo-tuberculous, granulomatous and giant cell thyroiditis which have been applied to the disorder and for much confusion in the past in misinterpreting the condition as tuberculosis of the thyroid gland.

/ Treatment

Treatment

1. Introduction

As has already been stressed, Subacute Thyroiditis is a self-terminating disorder and one which appears to leave the patient with normal thyroid function after it has resolved. Consequently radical forms of treatment, notably thyroidectomy, are to be avoided and the aim must be suppression of the clinical manifestations of the disease until such time as resolution has occurred. To this end numerous and apparently quite unrelated therapeutic measures have enjoyed success, but in such a disorder showing spontaneous remission, their true efficacy is difficult to assess.

2. Operation

Thyroidectomy and more localised forms of resection, the customary treatment in the past and at a time when the disease was less well recognised, are to be avoided for the reasons already given. Operative measures perhaps retain a small place in the rare, recalcitrant case where conservative methods fail.

3. Anti-thyroid Drugs

King and Rosellini (1945) first reported on the successful treatment of Subacute Thyroiditis using thiouracil. They obtained a satisfactory response as judged by relief of symptoms and disappearance of glandular enlargement. Since then various other authors have employed anti-thyroid drugs successfully in the management of this disorder - Cantwell (1948), Harvill (1948), Reveno and Rosenbaum (1951)

/ and

and Fraser and Harrison (1952). The last mentioned authors believed the thiouracil to prevent or block the viral action and so interrupt the course of the disease. If the foreign body reaction is indeed expressed in response to colloid, however, it may be that the beneficial action of anti-thyroid drugs is due to their interference with the formation of this substance. Some authors have, however, expressed dissatisfaction with the results of anti-thyroid drug treatment - Lindsay and Dailey (1954).

4. Thyroid-stimulating Hormone (TSH)

Robbins et al. (1951) treated six patients with thyroid-stimulating hormone (TSH) and observed clinical improvement in five. In four of these, however, the disease had relapsed within a week after treatment. They employed a dosage of 25 to 150 mg. over a one-day to five-day period. Why this substance should have produced improvement is obscure.

5. Irradiation

de Quervain and Giordanengo (1936) first mentioned the possibility of irradiation of the thyroid in Subacute Thyroiditis, while Schilling (1945) suggested that radiotherapy might be effective. It remained for Crile, however, to demonstrate that X-ray therapy was in fact an effective form of treatment - Crile (1948) and Crile and Rumsey (1950). Osmond and Portmann (1949) have also given a good account of this therapeutic measure. The response, as judged by
/ symptomatic

symptomatic relief and shrinkage and softening of the gland, appears to be dramatic. Crile and Rumsey (1950) treated 35 patients with an average total dose of 800 r. Fourteen patients obtained complete relief within a week and in general, pain, tenderness and systemic symptoms had disappeared by the thirteenth day, by which time the thyroid was smaller and softer. By the end of one month the thyroid was no longer palpable. In six cases, after a short remission averaging six weeks, a recrudescence of the disease occurred, but responded to a second, less intensive course of therapy. They had no instances of subsequent hypothyroidism when dosage was restricted to 800 r. Osmond and Portmann (1949) obtained complete cure with one course of X-ray therapy in 40 of their 55 patients and the experience of Allen and Reeves (1951) has been similar.

6. Cortisone and Adrenocortico-trophic Hormone (ACTH)

It would appear that the above therapeutic measures have now been largely replaced by the use of cortisone and/or adrenocortico-trophin (ACTH). Numerous reports of the excellent subjective and objective response of Subacute Thyroiditis to this form of treatment have appeared in the literature in recent years - Lasser (1953), Clark et al. (1953), Teitelman and Rosenberg (1953), Kahn et al. (1953), Izak and Stein (1956) and Moldover (1956). The response is immediate, pain and tenderness disappear, the gland shrinks in size and the temperature settles. Skillern et al. (1956) have shown that prednisone is equally effective and is

is to be preferred because of the lesser disturbance of electrolyte balance with this drug. Relapses have often been reported upon cessation of steroid therapy but have usually responded to further courses. Treatment should be controlled not only by estimation of clinical response, but also by return of sedimentation rate and ^{131}I uptake to normal values and dosage should be gradually tapered off. Taylor (1956), dissatisfied with the response to cortisone in certain of his patients, suggested that combined therapy with cortisone and irradiation may have a place in the more difficult and prolonged case. The action of steroids in Subacute Thyroiditis appears to be by suppression of tissue response and is in no way specific.

7. Other Measures

None of the antibiotics at present available have been found to appreciably alter the course of Subacute Thyroiditis. There are on record some remarkable instances of antibiotic administration in this disease before its true nature has been recognised and more appropriate treatment instituted.

Simple measures for the relief of pain and discomfort may be required in the more severe cases.

Prognosis

The prognosis in Subacute Thyroiditis appears to be good. The natural course of the disease is towards spontaneous recovery, and while short-term relapses have frequently been reported with most forms of treatment,

/ these

these would seem an inherent part of what is essentially a subacute or chronic, "grumbling" process; with the final and complete resolution of the disease, the patient is restored to normal health. Furthermore, in the great majority of reported cases, the patient has been left with normal thyroid function and hypothyroidism has not been a serious complication. This is in marked contrast to the findings in Struma Lymphomatosa. Hypothyroidism has, however, been reported as a sequel to Subacute Thyroiditis on more than one occasion. Lindsay and Dailey (1954) found 10 of 25 cases treated by thyroidectomy to be hypothyroid, while 3 of 12 cases in their non-operative group developed this complication. Other isolated reports have confirmed hypothyroidism as an occasional, though unusual, end-point of the disease.

Relationship to other Thyroid Diseases

Subacute Thyroiditis, whatever its true nature, is characterised in its typical form by an almost unique clinical presentation and pathological appearance and at present occupies an isolated position in the spectrum of thyroid disease. Under certain circumstances, already noted, it may mimic and be confused with other thyroid disorders, including other forms of Thyroiditis, but it does not appear to have any true or fundamental relationship to any other recognised thyroid condition.

Case Report

The following case, seen recently, merits consideration in this section dealing with Subacute Thyroiditis.

Mrs. G.I. Age 45 years. Housewife. Admitted R.I.E. - 30.12.57.

History of Present Illness. The patient was referred from the E.N.T. Department. Six days before admission she developed a sore throat which became worse for two days and then eased a little. This was unaccompanied by cough, nasal discharge or headache. Two days after the onset, there was an exacerbation of the rawness in her throat and this became associated with pain in her neck, greatest anteriorly, but also radiating round both sides of the neck to the back. The pain did not, however, radiate beyond the neck. The pain was temporarily relieved by aspirin but returned with greater severity 24 hours later. She felt as if her neck were greatly swollen, but had no dysphagia, hoarseness or difficulty with breathing.

Past History. She had been perfectly well up to the onset of her sore throat and in particular had had no previous neck swelling or recent infective episode.

Clinical Examination. The patient was distressed and weeping from the severe pain in her neck.

The Thyroid. The gland was enlarged to between two and three times normal size, exquisitely tender, smooth and hard in consistence. It moved freely on swallowing and there was no evidence of extra-thyroid extension or fixation. The overlying soft tissues showed none of the features of inflammation.

Temperature 100.2°F; Pulse rate, 120 per minute; Respiratory rate, 20 per minute.

Otherwise physical examination was negative.

E.S.R., 72 m.m. in first hour: White blood cell count, 14,000 per c.m.m.

An X-ray of the neck showed a slight increase in the soft tissue shadow of the thyroid but no constriction or deviation of the trachea.

E.N.T. examination showed pharynx and larynx to be healthy, with normal cord movement.

Laboratory Investigations. Serum cholesterol, 268 mg. per 100 ml.

/ Electrophoresis

Electrophoresis:-

	<u>g. per</u> <u>100 ml.</u>	<u>% of</u> <u>Total</u>
Total Protein	6.0	-
Albumin	2.0	33
Alpha ₁ Globulin	0.5	8
Alpha ₂ "	1.0	16
Beta "	1.0	17
Gamma "	1.6	27

Liver Function Tests:-

Colloidal Gold,	0
Thymol Turbidity,	2 units

Serology:-

Complement-fixation and precipitation tests were negative: the tanned-cell test was positive at a dilution of 1/80.

¹³¹I Investigations:-

4 hour gland uptake,	9.7%
4.8 " " "	19.6%
Urinary excretion - 0- 8 hour fraction,	32.9%
8-24 " "	26.6%
24-4.8 " "	1.9%
0-4.8 " "	61.4%
	T. Index, 2.0
Protein-bound Iodine (PBI),	6.9 micro-grams %

Progress

Over the five days after admission, temperature and pulse rate gradually settled and pain lessened, although the gland remained enlarged, hard and tender. On 9.1.58 an open biopsy of the thyroid was carried out and the findings are recorded below. From this procedure the patient made an uneventful recovery with disappearance of pain and tenderness and temperature and pulse rate remaining at normal levels. A second ¹³¹I investigation was carried out on 16.1.58 with the following results:-

/ 4 hour

4 hour gland uptake,	7.1%
48 hour " " "	11.1%
Urinary excretion - 0- 8 hour fraction,	44.5%
8-24 " "	23.6%
24-48 " "	6.5%
0-48 " "	74.6%
	T. Index, 2.5
48 hour P.B. ¹³¹ I,	0.03% of the dose per litre.

The patient was discharged asymptomatic on 22.1.58.

Follow-up

When seen on 19.2.58, she felt very well and had returned to work. All pain and tenderness had gone and there was little or nothing to be made out in the neck. Clinically she appeared euthyroid; the 48 hour uptake of ¹³¹I was 38.0% and the protein-bound iodine (PBI), 8.1 micro-grams %.

Pathology

Gross Appearance. When exposed at biopsy, the thyroid was lightly, but quite definitely, adherent to the infra-hyoid muscles, diffusely enlarged and firm to hard in consistence. Its surface was smooth and reddish-white in colour.

Histo-pathology

Overall the vesicles were diminished in number and colloid reduced in amount. Some groups of vesicles, however, appeared relatively normal, being lined with flat epithelium and containing ample, homogeneous eosinophilic colloid. (Fig. 94).

In the damaged vesicles, the lining epithelium was swollen and desquamated giving an impression of giant cell formation, the colloid in such vesicles appearing basophilic. (Fig. 95).

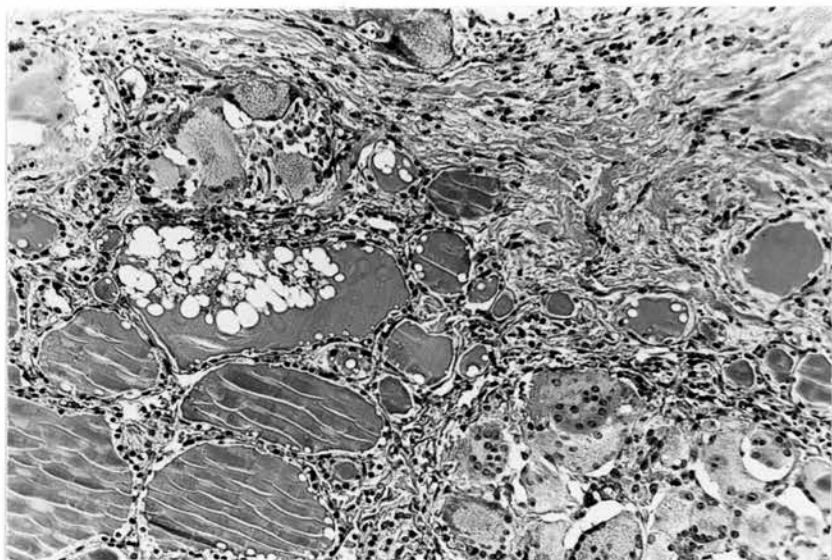


Fig. 94

Relatively uninvolved area - the majority of vesicles appear fairly normal, are lined by flat epithelium and contain homogeneous eosinophil colloid. Groups of damaged vesicles are, however, seen in addition. H. & E. X 160.

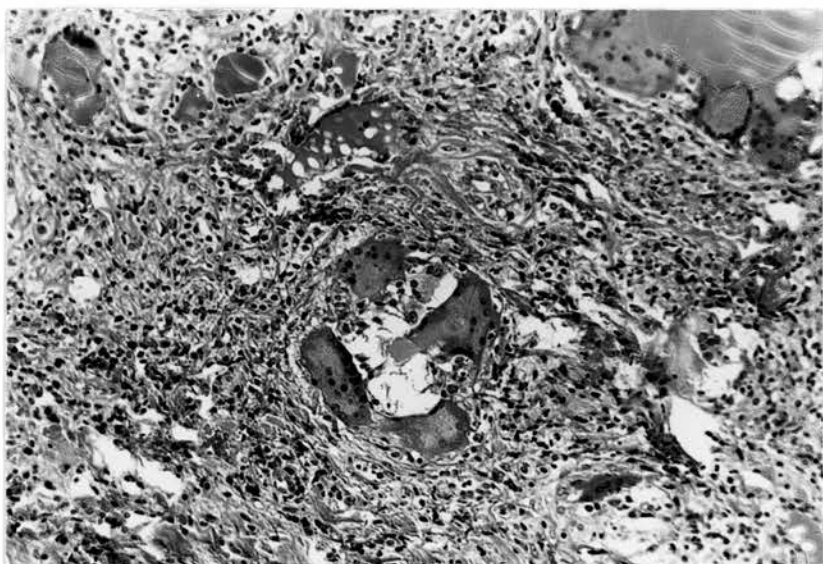


Fig. 95

The vesicles are diminished in number: the epithelium is swollen and desquamated giving the impression of giant cells. Colloid is basophilic. There is a relatively light stromal infiltration of lymphocytes and plasma cells, but virtually no polymorphonuclears. H. & E. X 160.

The stroma showed a scanty cellular infiltration composed of lymphocytes and plasma cells with essentially no polymorphonuclears. Approximately half of the section revealed virtually complete replacement of the thyroid parenchyma by mature fibrous tissue and there was also considerable evidence of fibrosis elsewhere throughout the gland. (Fig. 96).



Fig. 96

Replacement by fibrous tissue.
H. & E. X 160.

Comment

The foregoing case is difficult to classify but is included here because it would appear to show certain similarities to true Subacute Thyroiditis. Thus, although the history of illness was short, the patient's presenting complaint was of pain, of sufficient severity to reduce her

/ to

to tears. The enlarged thyroid was hard in consistence and exquisitely tender to the touch, while the systemic reaction was evidenced by pyrexia and increased pulse rate. The sedimentation rate was high. The white blood cell count, 14,000 per c.m.m. on admission fell to 4,400 per c.m.m., seven days later.

A number of points, however, weigh against a diagnosis of true Subacute Thyroiditis. Thus the uptake of ^{131}I by the thyroid did not show the marked suppression usually found in this disease and which might have been expected judging from the clinical severity of the patient's illness. Clinically the condition resolved rapidly and apparently completely (although the follow-up is obviously still incomplete) without specific therapy of any kind. Perhaps most important, however, are the biopsy findings. These show certain differences from the classical histopathological picture of Subacute Thyroiditis, where one would have anticipated a more granulomatous picture, a greater abundance of giant cells and a heavier polymorphonuclear infiltration.

At the same time the case illustrates none of the features, clinical or pathological, of either Struma Lymphomatosa or Riedel's Struma. For the present, therefore, it must remain unclassified, although of considerable interest in the present context as a painful form of Thyroiditis.

PART V

RIEDEL'S THYROIDITIS

Introduction

Although Semple (1869) and Bowlby (1884) had both reported cases of a fibrotic type of thyroid enlargement producing respiratory difficulty, associated in the latter instance with a remarkable degree of extra-thyroid extension of the pathological process, Riedel of Jena (1896, 1897 and 1910) first focused attention on the condition which has subsequently become known by his name and for which a considerable number of synonyms have been evolved including such terms as Eisenharte or Iron-hard Struma, Ligneous or Woody Thyroiditis, Chronic Productive Thyroiditis and Primary Chronic (Canceriform) Inflammation of the Thyroid. Throughout the sixty years which have elapsed since Riedel's earliest description, a considerable number of cases have been reported under one or other of these titles, many erroneously so. Despite this, constant argument has surrounded the condition particularly concerning its possible relationship to Struma Lymphomatosa and while knowledge of other forms of Thyroiditis has made considerable progress particularly in recent years, the same cannot be said of Riedel's Struma around which there still remains a halo of mystery. A similar clinico-pathological description has been systematically handed down from textbook to textbook and article to article, the same loose thinking has been perpetuated, no significant advance has been made in the understanding of the essential nature of the lesion and doubt even remains as to whether there does in fact exist a

/ particular

particular thyroid condition to which this title may be applied.

Discussion of the problem can only proceed against a review of the historical background in which many of the present misconceptions have had their origin.

Historical Summary (See also Part I)

It is important first to determine exactly what Riedel did in fact describe (Part I, pp. 5-14 and Fig. 97). He recorded three patients, two males and one female, all of whom gave a history of thyroid enlargement of duration one year or less, associated with moderate or severe pressure symptoms and in particular respiratory embarrassment. In each case the thyroid was diffusely enlarged and of very hard consistency. Operation was undertaken in all three cases but in each, after the resection of a small piece of the gland, had to be abandoned because of extensive and intimate adhesion of the latter to the cervical muscles, vessels and nerves. On this point Riedel was quite adamant:- "All these adhesions have something tough and leather-like about them; they bleed extremely profusely; one cannot make any headway with the resection of the tumour. The large blood vessels (carotid artery and jugular vein) appear as if walled in, the recurrent laryngeal nerve is hardly to be found, embedded as it is in callous tissue. Even the most malignant tumour can be more easily separated than this tumour" In each case, despite the limited removal of thyroid tissue, the

AGE	SEX	PREVIOUS HISTORY	ONSET	SYMPTOMS	THYROID	OPERATION	FOLLOW-UP	MICROSCOPY
42 YRS.	MALE	-	6 MONTHS	INCREASING GOITRE. PRETTY ACUTE DYSPNOEA.	IMMOVABLE BILATERAL SWELLING. NOT VERY BIG. EXTRAORDINARILY HARD.	30.11.82 EXTRAORDINARILY FIRMLY ADHERENT ON BOTH SIDES TO THE CAROTID ARTERY & INTERNAL JUGULAR VEIN. PIECE AS BIG AS A WALNUT REMOVED AND RESECTION OF PART OF THE INTERNAL JUGULAR VEIN. OPERATION ABANDONED.	RELIEF OF DYSPNOEA. COM- PLETELY HEALTHY AND FIT FOR WORK IN SIX MONTHS. NINE MONTHS AFTER OPERA- TION, DEVELOPED NEPHRI- TIS AND HAD REPEATED STROKES, SUCCEEDING TO THE FOURTH OF THESE ON 7.3.85. NO POST-MORTEM.	ROUND CELL INFILTRATION. NO TUMOUR, SYPHILIS OR TUBERCULOSIS. COLLECTIONS OF ROUND CELLS INTERSPERSED AMONG NORMAL THYROID TISSUE, WHEREBY THE LATTER IS MORE OR LESS DESTROYED. "BY JUST LOOKING AT THE PREPARATION, ONE HAS NO IDEA OF HOW HARD THE TUMOUR IS; ONE EXPECTS SOLID FIBROUS TISSUE TO CONSTITUTE THE TUMOUR, BUT AS HAS ALREADY BEEN SAID, ONE SEES ONLY EMBOSSED "ROUND CELLS".
25 YRS.	FEMALE	-	1 YEAR	INCREASING GOITRE. MORE RAPID ENLARGEMENT FOR 8-10 WEEKS, BECOMING STRIKINGLY FIRM AND SOLID. DYSPNOEA ON EXERTION. SLIGHT PALPITATION. DYSPNOEA. "GOITRE VOICE". SLIGHT BRONCHITIS. PULSE 90.	VERY HARD GOITRE. R. LOBE = HEN'S EGG. L. LOBE = SMALL APPLE. MOBILE WITH TRACHEA. CORDS NORMAL.	8.1.96 OPERATION DISCONTINUED ON ACCOUNT OF EXTENSIVE COALESCENCE OF TUMOUR WITH BLOOD VESSELS AND RECURRENT NERVE. PARTIAL RESECTION.	RECURRENT NERVE PARALYSIS. OTHERWISE WELL AFTER OPERATION AND BREATHING IMPROVED. SUDDEN DEATH 3 MONTHS AFTER OPERATION, THOUGHT TO BE DUE TO EMBOLISM. NO POST-MORTEM.	INFLAMMATORY TISSUE.
29 YRS.	MALE	COM- PLETELY HEALTHY	4 WEEKS	SMALL, HARD SWELLING ON R. SIDE, ENLARGING AND CROSSING OVER TO L. SIDE TO DEVELOP TO SAME EXTENT AS ON R. SEVERE DYSPNOEA.	-	21.7.96 GOITRE MOSTLY HARD BUT SOFTER IN PLACES, IN- SEPARABLY FEMED WITH MUSCLES, VESSELS AND NERVES. GREYISH-WHITE COLOUR. RESECTION OF WALNUT-SIZED PIECE. 11.1.97 WEDGE RESECTION OF ISTHMUS FOR CONTINUING RESPIRATORY DIFFICULTY.	DYSPNOEA REMAINED AND BECAME WORSE, WITH CYANOSIS, COUGH AND NOCTURNAL CHOKING ATTACKS. SLOW RECOVERY. DYSNOEA REMAINED BUT NOCTURNAL CHOKING ATTACKS CEASED. SPEECH ROUGH AND HOARSE, BUT CORDS INTACT. GOITRE BECAME SMALLER. IN 1901 COMPLAINTS CEASED & PATIENT RESUMED WORK. JAN. 1905 - HAEMATEMESIS. ATTACKS OF NOCTURNAL DYSNOEA RETURNED & LASTED FOR 4 YRS. THEN IMPROVING. 1909 WORKING AS A WOOD- CUTTER. NO TRACE OF GOITRE. CORDS NORMAL, BUT STENOSIS OF SUB-GLOTTIC SPACE AND TRACHEA.	SPINDLE AND ROUND CELLS. SLIGHT ENDARTERITIS.

FIG. 97. DETAILS OF NIEDEL'S THREE CASES.

goitre regressed and pressure symptoms were relieved, although only slowly in Case 3 where there was apparently an associated sub-glottic stenosis. Two of the cases, however, died shortly after operation under rather peculiar circumstances which were never satisfactorily explained. Riedel's description of the histo-pathological findings in the resected tissue is scanty and his illustrations poor, but it is important to note that he did not describe dense fibrous tissue replacement but instead, round cell infiltration, - "By just looking at the preparation, one has no idea of how hard the tumour is; one expects solid fibrous tissue to constitute the tumour but, as has already been said, one sees only embedded round cells." Few modern authorities seem aware of these, Riedel's personal, observations.

Hashimoto (1912) considered his Struma Lymphomatosa a distinct entity, quite different from and unrelated to Riedel's Thyroiditis.

In 1922, Ewing, basing his opinion on the pathological study of four cases, concluded that Hashimoto and Riedel had described the early and late stages of the same pathological process, to which he applied the term "Benign Granuloma of the Thyroid". This pronouncement undoubtedly did much harm and led to considerable subsequent confusion. Ewing's opinion was widely accepted in the ensuing years and differentiation between the two conditions ceased. Thus many case reports appeared in the literature under the title

of Riedel's Struma, the clinico-pathological descriptions of which coincide exactly with the classical features of Struma Lymphomatosa (vide infra).

In 1924, Bohan recorded a case of Ligneous Thyroiditis which was associated with high-grade dental infection. Cultures from the abscessed teeth grew streptococcus viridans and staphylococcus, which, injected into rabbits, produced extensive haemorrhages in the thyroid and marked oedema, thus leading the author to conclude that oral or focal sepsis might be the aetiological factor. As a piece of scientific evidence, Bohan's experimental work has never received confirmation, while there are many features in his case report which suggest that the patient was, in fact, suffering from Subacute and not Ligneous, Thyroiditis.

Meeker (1925) reported a case of Riedel's Struma associated with remnants of the post-branchial body, and postulated a possible extension of inflammation from the pharynx along the ultimo-branchial duct system - a hypothesis which has never received subsequent confirmation and would not appear to merit serious consideration. Moreover, Meeker was a disciple of Ewing and the case which she reported was undoubtedly a fibrotic Struma Lymphomatosa, areas of squamous metaplasia being misinterpreted as "post-branchial remnants".

The first serious attempt to differentiate between Struma Lymphomatosa and Riedel's Thyroiditis was by Graham (1931). He collected and analysed 104 reported cases of

/ Thyroiditis

Thyroiditis from 82 original publications in the world literature up to that time, accepting 41 as examples of Riedel's and 24 as examples of Hashimoto's struma. An analysis of the two groups led Graham to the conclusion that it was highly improbable that there existed any relationship between these conditions, for the reasons that:- (1) Struma Lymphomatosa is almost exclusive to women, while Riedel's Thyroiditis is not much commoner in women than in men; (2) Riedel's Thyroiditis occurs at an earlier age period than does Struma Lymphomatosa; (3) Struma Lymphomatosa gives a bilateral thyroid swelling limited by the capsule of the gland, whereas in Riedel's Thyroiditis the pathological process is unilateral in a high proportion of cases and spreads beyond the confines of the gland; (4) Struma Lymphomatosa is associated with a high incidence of hypothyroidism, the converse being true of Riedel's Thyroiditis (Fig. 1).

The observations of de Quervain (1936) are of the greatest importance and merit the closest consideration. By his work, this author established the condition of Subacute Thyroiditis as a clinical and pathological entity. He did, however, draw attention to certain points of similarity between this condition and Riedel's Thyroiditis, particularly in respect of the gross appearance of the thyroid and its adhesion to surrounding tissues. Further, he made the profound observation - "It will be a question for the future to ascertain whether a particular histological

type corresponds to the clinical notion of Riedel's illness, or whether this conception is to be used simply as a collective term for the solid, fibrous degeneration in illnesses of the thyroid family varying in origin and histological character." There can be little doubt that, in the past, many cases of Subacute Thyroiditis have been reported as examples of the Riedel type, largely due to unawareness of the existence of the former condition on the part of the authors concerned (*vide infra*).

McClintock and Wright (1937) and Joll (1939) elaborated the work of Graham and reported similar findings and conclusions.

The report of Renton, Charteris and Heggie (1938) of the successful treatment of Riedel's Thyroiditis with radium is erroneous inasmuch as these authors subscribed to the views of Ewing and the cases they reported and treated were examples of Struma Lymphomatosa, which condition is of course, at least partly, responsive to irradiation.

In 1943, de Courcy advanced the theory that Riedel's Thyroiditis was the result of a previous perithyroiditis which caused a partial constriction of the thyroid vessels and resulted in a progressive sclerosis. de Courcy's cases were, however, clear-cut examples of Subacute Thyroiditis, concerning the existence of which the author was unaware at that time.

Grile (1948) introduced a rather different concept of the pathology of Riedel's Thyroiditis. In seven of his

eleven cases, adenomas or remnants of degenerating adenomas were present in the centre of the proliferating fibrous tissue, which appeared to be laid down in concentric rings around the adenoma. He suggested that it was often possible to split the lobe open and emucleate the central adenomatous core, a procedure which, in three of his cases, produced relief of pressure symptoms, diminution of the bulk of the swelling and arrest of the inflammatory and productive process. Crile suggested the possibility of some change in the adenoma initiating a fibrosis resembling that seen in a keloid. While Crile's observations are of undoubted importance, it would seem wrong to include such cases under the title of Riedel's Thyroiditis.

The final result of a large amount of clinico-pathological description and discussion concerning this disorder is a state of almost indescribable confusion. Much that has been written on the subject has proved erroneous and the accurate definition of a specific thyroid disease with uniform clinical course and pathological findings which might be entitled Riedel's Thyroiditis has not been satisfactorily achieved.

A. Struma Lymphomatosa and Riedel's Thyroiditis

As already emphasised, many cases have been and still are being reported in the literature under the title of Riedel's Thyroiditis, which, on closer scrutiny and more accurate interpretation, prove to be undoubted examples of Struma Lymphomatosa. Such confusion has arisen in two main ways.

/ First,

First, the blind acceptance of Ewing's unitarian concept concerning the two diseases led many authors to publish florid examples of Struma Lymphomatosa as instances of Riedel's Thyroiditis in the belief that the former was simply the earlier stage of the latter condition. The literature abounds in such misrepresentations; by way of example, Figs. 98 and 99, are reproduced from the report of five cases of Riedel's Thyroiditis by Renton et al. in 1938 and it is at once obvious that the histo-pathological appearances are those of classical Struma Lymphomatosa. If the concept of a separate disease entity is to be established for Riedel's Thyroiditis, then obviously such cases and others like them must first be rigorously excluded.

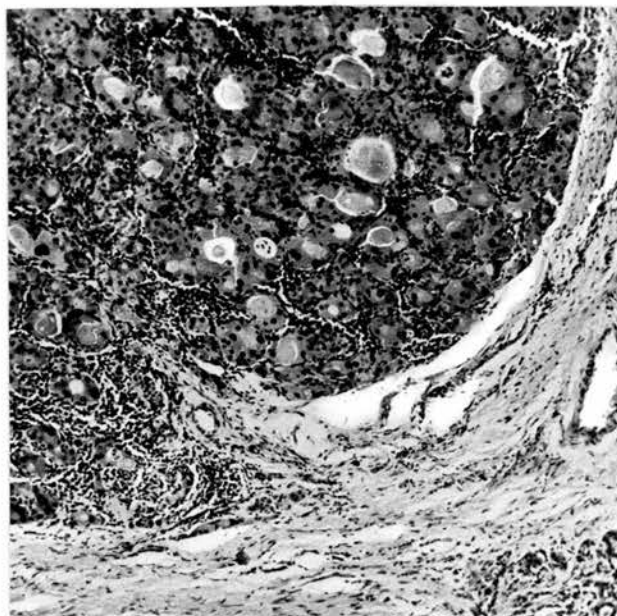


Fig. 98

Reproduced from Renton et al. B.J.S. 1938. 26. 54.

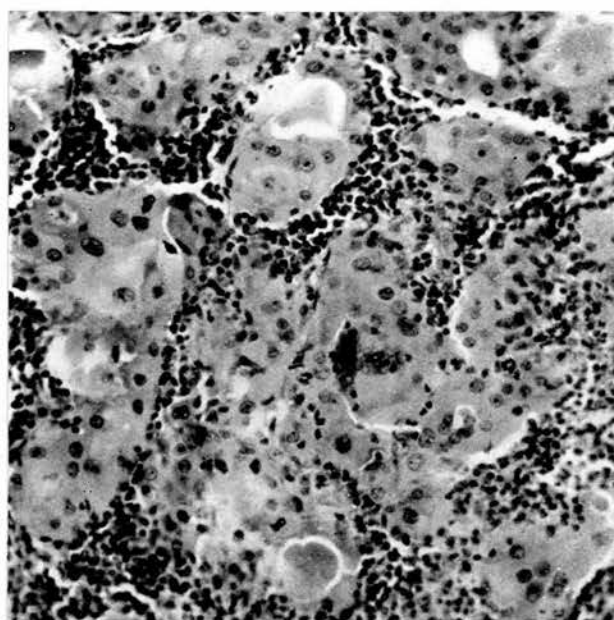


Fig. 99

Reproduced from Renton et al. B.J.S. 1938. 26. 54.

The second and perhaps more important source of confusion has been the failure, at least until recent times, to recognise that in many cases of Struma Lymphomatosa the clinico-pathological picture may differ markedly from the classical description by virtue of widespread replacement of thyroid parenchyma by dense, acellular and frequently hyalinised connective tissue. Thus, from the clinical viewpoint, the gland may not show an extravagant degree of enlargement and its consistence may indeed be stony hard. Exposed at operation, its external and cut surfaces may have a homogeneous, dense, white fibrotic appearance. Histopathologically, when fibrosis predominates, the amount of residual parenchyma is minimal, while lymphoid follicle

/ formation

formation and round cell infiltration generally, well marked in earlier stages, is little in evidence. Squamous metaplasia of vesicular epithelium may be encountered and is sometimes extensive. These points have been repeatedly emphasised in foregoing pages and the view has been expressed that the pathological end-point in untreated Struma Lymphomatosa is very probably one of uniform thyroid fibrosis. Despite this, many surgeons and pathologists, confronted with a thyroid gland in which fibrosis is a significant feature of the clinical, operative and pathological picture, continue to record a diagnosis of Riedel's Thyroiditis, even when such classically accepted features of this disorder as severe pressure symptoms and extra-thyroid extension may be lacking. The same lack of knowledge of the pathology of Struma Lymphomatosa and in particular of the possible occurrence of marked fibrosis, has been responsible for reports such as those of Means (1948) and Merrington (1948) claiming to show the occurrence of Hashimoto and Riedel changes in the same gland. Such cases are to be regarded as examples of Struma Lymphomatosa and offer no proof of a transition from the one condition to the other or of their essential unity. It is, therefore, of the utmost importance to realise that the occurrence per se of extensive fibrosis is not sufficient warrant for a diagnosis of Riedel's Thyroiditis, although unfortunately such has been the case all too frequently in the past.

It must be admitted, however, that when fibrous replacement of the thyroid is virtually complete, it becomes a matter of great difficulty to formulate a concrete diagnosis. The pathologist is then confronted with the end result of a process, the earlier stages of which have been completely effaced. In illustration of this the following case is most instructive and is reproduced here in full.

Mrs. A.B. Age 40 years. Housewife and Clerkess.
Admitted R.I.E. - 18.10.56.

History of Present Illness

On 23.9.56, the patient noticed a swelling in her neck, more prominent on the right side. To her knowledge there had never been any swelling in this situation prior to that time. For the two weeks before admission, she thought her face had been "rather puffy" and for several weeks, her eyes had been watering. Her voice had become slightly hoarse over the previous fortnight and she found that if she spoke for any length of time her voice became tired. There was a doubtful complaint of dysphagia for one week.

Otherwise she had no complaints being in fact a very active woman. In particular, there had been no systemic upset, no complaint of pain and her general health had been in no way impaired.

Past History

Four years before the present admission, she had received oral and intravenous iron therapy for tiredness and anaemia associated with a heavy menstrual loss. Otherwise there was nothing of significance.

Family History

One child, alive and well.
One brother, alive and well.
Father had died at the age of 70 years from
"heart trouble": mother, alive and well.

Clinical Examination showed an apparently healthy middle-aged woman.

Weight 8 st. 11 lb. (55.9 kg.).

/ Temperature

Temperature 98°F.: Pulse rate, 68 per minute;
Respiratory rate, 18 per minute.

Blood pressure - 130/78 m.m. of mercury.

There was a visible and palpable, diffuse enlargement of the thyroid involving both lobes and the isthmus, but more prominent on the right side. Four independent observers recorded the gland as being - hard; hard and slightly irregular; hard and craggy; stony hard and slightly nodular. It was not tender and there was no restriction of mobility. There were no enlarged lymph glands in the neck. The trachea was central in position.

Thyroid function, assessed clinically, was normal. The liver was palpable at the costal margin. The remainder of the examination was essentially negative.

X-rays of the neck showed an increase in the pre- and post-tracheal shadows, but no narrowing or displacement of the trachea.

Laryngoscopy revealed a healthy pharynx, a very mild degree of catarrhal laryngitis, normal cord movements and a normal hypopharynx.

Laboratory Investigations. Serum cholesterol was 420 mg. per 100 ml.; thymol turbidity was 2 units.

Diagnosis. ? Carcinoma of Thyroid.

Management. A test dose of X-rays (500 r) was given on 19.10.56 and the response assessed in 72 hours. There was no change in the size or nature of the thyroid enlargement, the initial neck circumference of 37 cms. remaining unaltered. Accordingly, on 23.10.56 the neck was explored.

Operative Findings. When the lobes were first seen, a diagnosis of Struma Lymphomatosa was made from the colour and obvious enlargement of the whole gland including the pyramidal lobe. When, however, the strap muscles were mobilised from the gland, it was found that there was dense adhesion to the muscle sheath requiring sharp dissection and in view of this somewhat unusual finding, the diagnosis of Struma Lymphomatosa was considered untenable and the possibility of carcinoma was raised again. In particular, the consistence of the gland was rather more hard than had been previously encountered in Struma Lymphomatosa. In view of these doubts it was considered that a total thyroidectomy should be carried out without any incision into the thyroid tissue. As

/ mobilisation

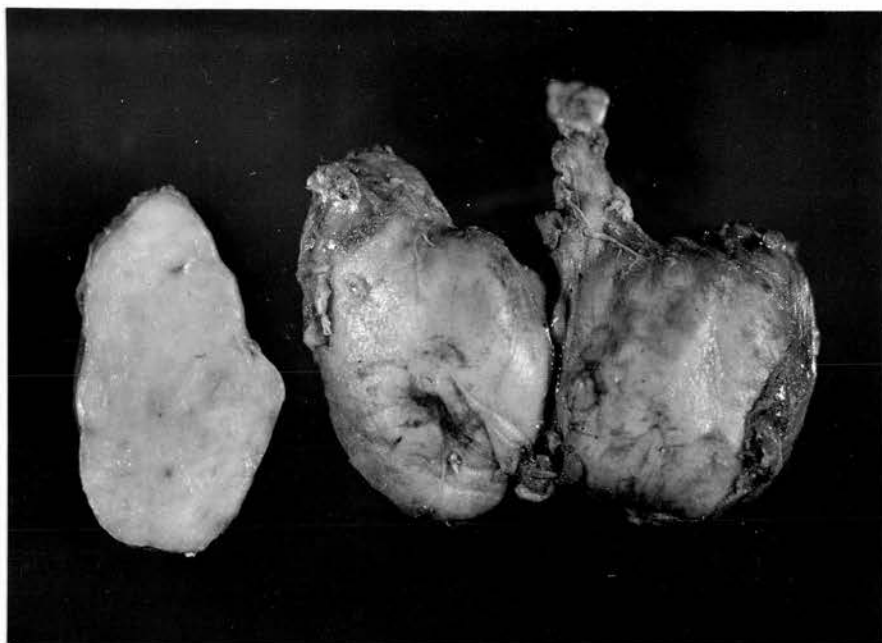

Fig. 100

Mrs. A. B. Total Thyroidectomy. Showing
appearance of thyroid gland.

mobilisation of the gland proceeded, the posterior part of the right lobe was found to be densely adherent to the trachea, being separated only by sharp dissection through what appeared to be dense white fibrous tissue. Otherwise the operation was completed without incident and with visualisation and preservation of both recurrent nerves and the parathyroid glands.

Pathology

The resected specimen (Fig. 100) showed a diffusely enlarged thyroid gland which had been removed in toto. All parts of the organ, including the external and cut surfaces, presented the same appearance, namely one of uniform, dense, white fibrous tissue from which all trace of thyroid structure had been effaced.

Microscopically, the findings were identical in multiple sections examined. The outstanding feature was the extensive replacement of the gland by dense, acellular connective tissue to such a degree that, under lower powers of magnification, no recognisable thyroid tissue appeared to remain. (Fig. 101).

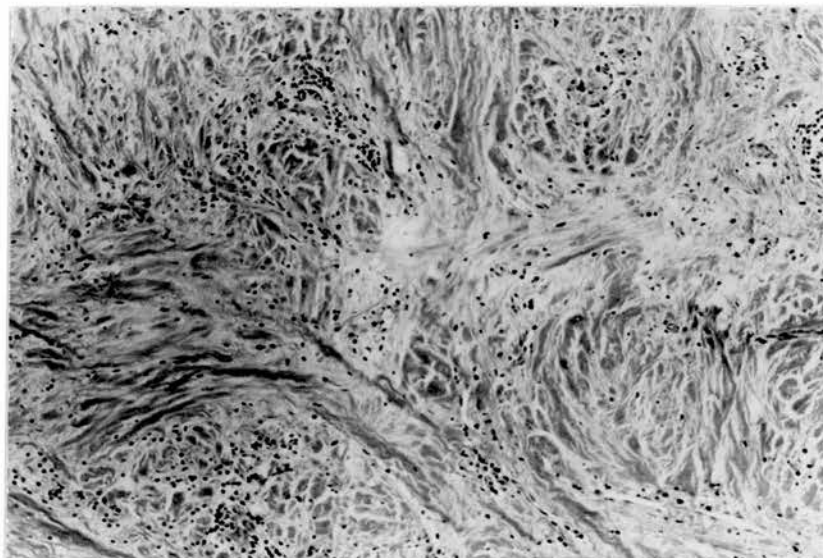


Fig. 101

Extensive fibrosis. Structure not recognisable as thyroid. H. & E. X 85.

Scattered throughout this connective tissue background and usually in situations where the last traces of thyroid vesicular structure could just be discerned, were small foci of lymphocytes and plasma cells. No lymphoid follicles were, however, discernible. (Fig. 102).

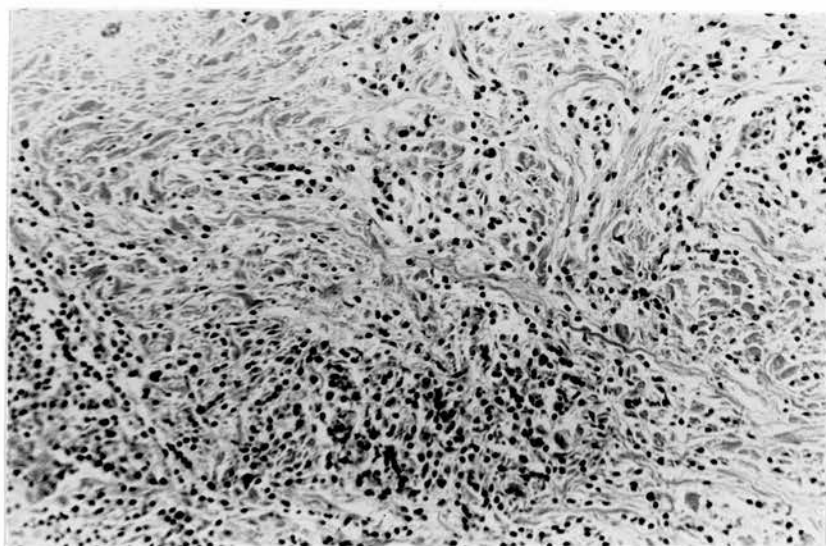


Fig. 102

Focus of round cell infiltration. Thyroid vesicular structure is essentially non-existent, but under higher magnification, scattered epithelial cells may be seen and occasionally the residual outline of disorganised vesicles. H. & E. X 160.

Squamous metaplasia of vesicular epithelium was much in evidence (Fig. 103).

Finally, in one or two very restricted areas, such as that depicted in Fig. 104, the last traces of thyroid parenchyma persisted and allowed some impression to be formed concerning its appearance. Tiny residual droplets of colloid might be observed and in general the epithelium

/ showed

showed some resemblance to the Askanazy type with eosinophilic cytoplasm and large vesicular nuclei.

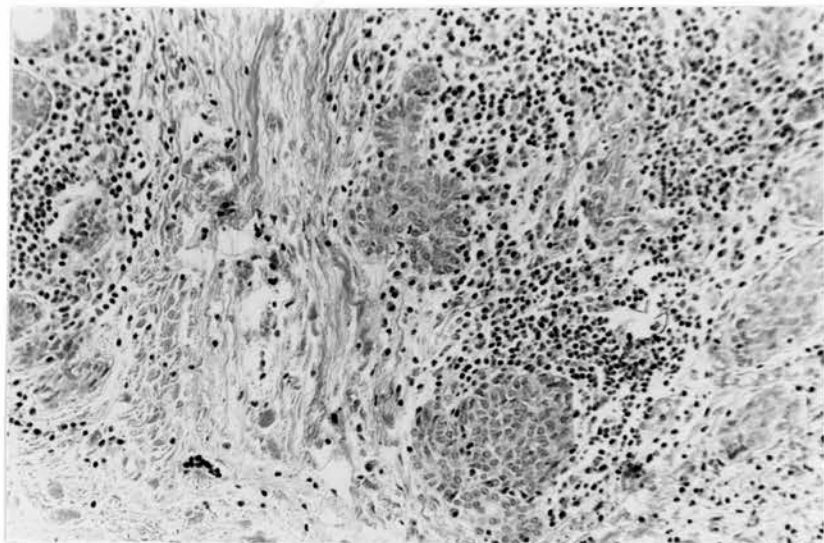


Fig. 103

Focus of squamous metaplasia.
H. & E. X 160.

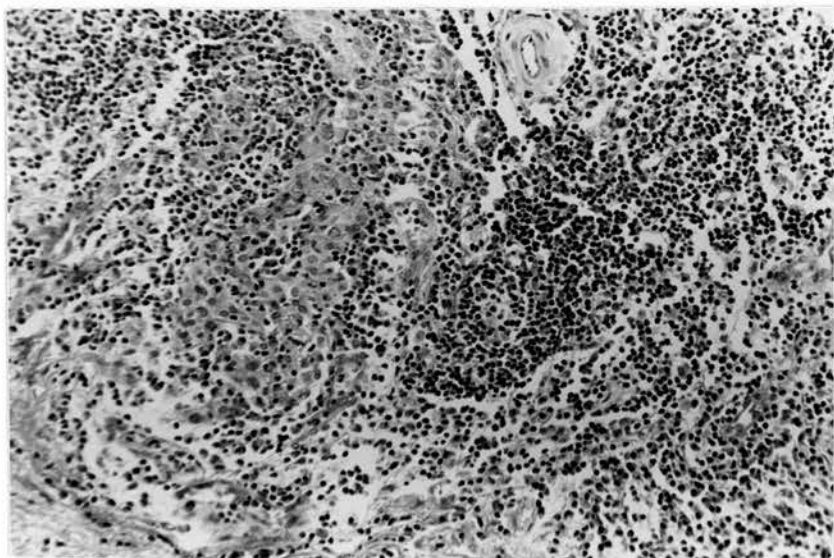


Fig. 104

Focus of residual parenchyma with associated round cell infiltration and surrounding fibrosis. The general appearance shows a resemblance to the Askanazy type of epithelio-vesicular structure.
H. & E. X 160.

Post-Operative Course

Immediately following operation the patient passed into an acute hypothyroid state with a striking fall in temperature, pulse and respiration rates. A ^{131}I investigation on the thirteenth post-operative day showed a 48-hour excretion of 87.3% and a T. Index of 1.2. The basal metabolic rate was depressed and remained so. There was a disappointing response to a short trial course of Tri-iodothyronine, although some clinical improvement took place. Prior to discharge she was started on Thyroxine in a dosage of 0.2 mg. daily which she continues to take (Fig. 105). Otherwise her convalescence from operation was uneventful and without signs of tetany or recurrent nerve injury.

Comment

The foregoing case effectively illustrates many of the points previously raised. The clinical presentation is quite compatible with a diagnosis of Struma Lymphomatosa, if it is borne in mind that the thyroid in this condition may have a consistency quite unusually hard. Pressure symptoms were minimal or absent, although hoarseness, a common accompaniment of this condition, was noted. There was no associated systemic upset or complaint of pain in the neck and the gland showed no tenderness on palpation, all or any of which might otherwise have led to a suspicion of Subacute Thyroiditis; indeed the well-being and activity of the patient and the lack of clinical evidence of subnormal thyroid function contrasts almost incredibly with the virtual absence of functioning thyroid tissue, although, of course, a pre-operative serum cholesterol determination gave a high reading.

The failure to make a correct clinical diagnosis is hardly surprising in the light of the subsequent pathological

/ findings

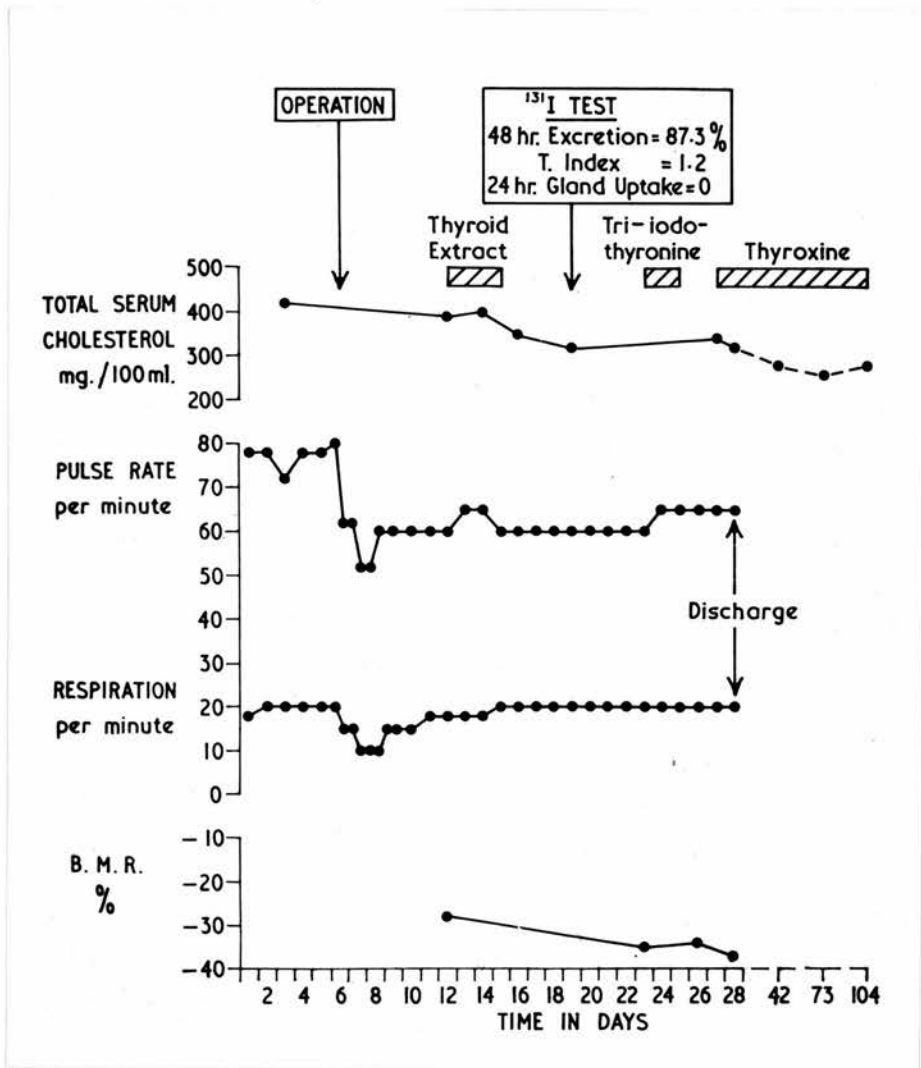


Fig. 105

Mrs. A. B. Post-operative record of B.M.R., Respiration, Pulse and Cholesterol values, with details of therapy.

findings, while the failure of response to a test dose of irradiation is what might be anticipated of a gland showing this degree of fibrosis.

At operation, the surgeon, initially disposed to regard the gland as consistent with a diagnosis of Struma Lymphomatosa by virtue of its colour and the diffuse nature of the process, was however confused by its consistency and the finding of adhesion to the strap muscles. At a later stage in the operation, the posterior part of the right lobe was found to be densely adherent to the trachea, requiring sharp dissection for its separation. As will be discussed presently, these latter findings may quite well occur in Struma Lymphomatosa.

The pathologist's report was of Riedel's Thyroiditis. In fact, however, the histo-pathological findings were not those of a progressive sclerotic process replacing normal thyroid tissue, as has long been the popular concept of this disorder, but rather indicated the end result of an earlier and diffuse process throughout the gland. Admittedly, and this is the difficulty in such cases, insufficient parenchyma remained upon which to formulate a concrete opinion concerning the nature of this earlier process, but in the light of modern knowledge regarding the pathology of Struma Lymphomatosa and from the appearances in the minimal amount of extant thyroid tissue, it is reasonable to infer that the earlier changes were indeed those of this latter condition. Indeed, the overall appearance showed a close

/ similarity

similarity to the small group of cases reviewed in Part III, Group 2 (pp.167-171). None of the characteristic histopathological findings of Subacute Thyroiditis were noted.

Thus, from a consideration of all the facts concerning the case, clinical, surgical and pathological, a diagnosis of Struma Lymphomatosa must be recorded. This case has been presented in some detail since it illustrates well the many and less well recognised variants of this disorder and the facility with which such material may be recorded erroneously under the title of Riedel's Thyroiditis.

Extra-thyroid Extension in Struma Lymphomatosa

One of the classical arguments for considering Struma Lymphomatosa and Riedel's Thyroiditis as distinct and unrelated entities has been the oft-repeated concept that extra-thyroid extension of the disease process, resulting in adhesion and fixation of the gland to surrounding structures, so typical of the latter condition, never occurs in the former. This view is undoubtedly, in part, erroneous. It is true that in the great majority of cases of Struma Lymphomatosa the process is confined within the capsule of the gland and indeed it is classical that thyroid resection in this condition is a simple technical procedure. It is equally true, however, that in a certain proportion of cases, extra-thyroid extension may occur, resulting usually in adhesion to the overlying muscles and trachea and furthermore that such adhesion may be of a dense, fibrous nature requiring sharp dissection for its separation

and not merely a flimsy attachment. One does not have to seek far in the literature of reported cases to establish this truth, although many of the cases exhibiting such adhesion have been wrongly recorded as examples of Riedel's Thyroiditis. Lindsay et al. (1952) recorded the thyroid gland as being adherent in some degree to surrounding cervical structures, including muscles and trachea, in 37 of 168 patients (22 per cent.) with Struma Lymphomatosa. The adherent muscles were occasionally fibrous. The adherent glands were generally those having a fibrotic parenchyma, but many fibrous glands were not adherent. They further reported extensions of fibrous and lymphoid tissue into the perithyroid tissues in glands showing moderate or severe degrees of fibrosis. Operative experience with the 60 cases previously reviewed in this work did not show the same high incidence of adhesion as that reported by these authors. In five of the cases, however, adhesion of varying degree was observed. In four of these - Part III, Groups 1 and 2, pp. 159 & 172 - the gland was lightly but quite definitely adherent to the overlying strap muscles. In the fifth case - Part III, Group 1, p. 159 - where total thyroidectomy was carried out personally, an extreme degree of fixation between the gland and the trachea was encountered and dense fibrous tissue had to be left on the anterior surface of the latter structure, a finding not dissimilar to that met with in the case reported in the immediately preceding pages. It should be noted, however, that in none of these cases was

/ there

there any evidence of a diffuse spreading fibrosis in the neck, such as to render ablation of the gland an impossibility. The question of whether such a state of affairs can, in fact, develop in Struma Lymphomatosa must, for the moment, remain unsettled. The important point requiring emphasis, however, and recognition of which is long overdue, is that extra-thyroid extension of the disease process may occur in Struma Lymphomatosa, resulting in dense, albeit perhaps local, fixation of the gland to muscles and trachea and that such findings, per se, do not permit of a diagnosis of Riedel's Thyroiditis.

Repeat Biopsy in Struma Lymphomatosa

A further argument which is much quoted as a basis for regarding Struma Lymphomatosa and Riedel's Thyroiditis as separate entities has been the observation that, in certain cases of the former condition in which the opportunity has arisen for examination at a varying interval of time, there appears to have been no progression of the pathological process, which might reasonably have been expected to occur if in fact Struma Lymphomatosa were the precursor of Riedel's Thyroiditis. Illustrative of this line of reasoning is the case report by McClintock and Wright (1937) in which they recorded identical clinical and pathological findings in a case of Struma Lymphomatosa investigated on two occasions at an interval of two years and from which they inferred - "If struma lymphomatosa were the precursor of Riedel's struma, sufficient time had certainly elapsed in

/ this

this case for the changes to have become evident,"

Other authors, e.g. Heyd (1929), finding on the contrary, evidence of diminished round cell infiltration and increased fibrosis on the second occasion, have invoked these findings in support of the exactly opposite argument for progression from the one condition to the other and so, for their essential unity.

The truth would seem to be that both these inferences are fallacious and offer proof for neither theory. As previously emphasised the natural life history of Struma Lymphomatosa is still largely a mystery, but at least it seems certain that the rate of progression of the pathological process may vary considerably. In certain cases identical histo-pathological findings may persist in the gland for a very long time and Furr and Crile (1954) have even recorded no change after an interval of 21 years, while in others it would appear that the process is much accelerated and within a matter of months the thyroid may be converted into a fibrous tissue mass.

B. Subacute Thyroiditis and Riedel's Thyroiditis

Just as many cases of Struma Lymphomatosa have been erroneously reported as examples of Riedel's Thyroiditis for the reasons given above, so also has Subacute Thyroiditis been confused with the Riedel form. In this instance, confusion has arisen in two main ways - firstly, due to unawareness of the existence of Subacute Thyroiditis on the part of the authors concerned and secondly, because of

/ certain

certain resemblances between this condition and the popular concept of what constitutes Riedel's disorder.

In illustration of the first type of error, the following report of a case of Riedel's Thyroiditis by McKnight (1936) is instructive, and is reproduced here.

The patient was a female aged 34 years. She was first seen on 9.9.35 complaining of pain and swelling in the right side of the neck in the region of the right thyroid lobe. She had first noticed enlargement and pain three weeks before and had consulted an otolaryngologist as she thought she had "throat trouble". Examination revealed nothing abnormal in the mouth or upper respiratory passages and she was referred with a tentative diagnosis of goitre. Pain was the predominant complaint. It was a dull, constant ache and when first seen her temperature was normal. There had been some dyspnoea, especially when recumbent. She had lost five pounds in weight in about three weeks. Some symptoms of hyperthyroidism were present such as nervousness, moderate palpitation, emotional instability characterised by a tendency to cry easily and a slight, fine tremor of the fingers. These had been present only during her illness.

She appeared well nourished but pale. Examination was negative except for a very hard and extremely painful tumour of the right thyroid lobe. The blood pressure was within normal limits and the basal metabolic rate was +10% of normal. The weight was 152 pounds. Examination of the urine showed nothing significant, the haemoglobin was 50% and the white blood cell count, 6,400 per c.m.m.

On 13.9.35, an almost total lobectomy was carried out on the right side, leaving only a minute amount of tissue at the upper pole. The isthmus and left lobe were explored and found to be entirely normal in size, colour and consistency and were not disturbed. The operation was quite easy. The right lobe was symmetrically enlarged, very hard, well-encapsulated and pale in colour.

The resected tissue measured 3 x 3 x 5 cms., and consisted mostly of very firm, whitish tissue with small radiations extending into the thyroid tissue.

Microscopically, there was much fibrous tissue, in which there was an eosinophilia, round cell

/ infiltration,

infiltration, polynucleosis, foreign body giant cells and islands of thyroid acini undergoing atrophy at the periphery. On one side was some fairly normal thyroid tissue.

The post-operative course was entirely normal and the patient left hospital on the fifth day. In less than two weeks the wound had healed and she had complete relief of her symptoms.

Exactly three weeks later, she noticed pain and swelling in the left side of the neck, this time accompanied with an irregular fever ranging from 98.6°F. to 102°F. Her complaint was pain, excruciating in character and requiring narcotics for relief. Other symptoms were of minor importance. She was treated at home for two weeks. Ice bags gave little or no relief and hot water bottles produced equally unsatisfactory results. She was admitted to the hospital on 22.10.35, where local treatment could be carried out more effectively.

On admission the temperature was 99.4°F. and soon rose to 102°F. It then subsided only to flare up again. The haemoglobin was 80% and the white blood cell count 8,700 per c.m.m. A differential count showed 82% neutrophils, 3% eosinophils, 12% lymphocytes and 3% mononuclears. Nothing of importance was found in the urine and estimation of the basal metabolism was not repeated. The pain became so intense that the patient actually demanded surgical intervention.

On 28.10.35, an almost complete left lobectomy was done with considerable difficulty. There was much oozing from the bed, due undoubtedly to the pericapsular inflammation. This was controlled with iodoform gauze packing. There was some pericapsular inflammation, the capsule was thicker than it had been on the right side and the tumour was extremely hard. Otherwise it presented practically the same picture as the right lobe had shown, six weeks before.

In the gross, the resected specimen was an ovoid structure 2.5 x 2.5 x 4.0 cms. It was mostly composed of firm white tissue with a mottled cut surface; there was some soft, brown tissue at one end.

Microscopically, the findings were similar to those in the right lobe.

After operation, the temperature returned to normal except for a slight post-operative rise and the patient made a rapid recovery. Within a month

the wound had healed. The patient was entirely well ten months after the second operation and with no clinical evidence of hypothyroidism. She had no complaints and was clinically a normal woman.

The foregoing case, a clear example of Subacute Thyroiditis, has been chosen for reproduction because of its classical presentation and the clarity with which it has been reported. Not all cases are so immediately apparent, particularly in respect of the severity of the pain, but even so there can be no doubt that many instances of this disorder have, in the past, masqueraded as Riedel's Thyroiditis. As previously mentioned, de Courcy's concept of a new aetiology for Riedel's Thyroiditis was based on his observations in Subacute Thyroiditis. It cannot be emphasised too strongly that where pain, pyrexia and constitutional disturbance constitute significant features of a particular case, the closest scrutiny should be afforded before the Riedel label is attached to it.

There are, however, certain pathological similarities between the two conditions and de Quervain himself drew attention to these. Thus the gland of Subacute Thyroiditis is characteristically firm or hard, whether diffusely or focally involved, exposed at operation it is white and avascular, while fibrosis is always a dominant part of the histo-pathological picture. Furthermore, the thyroid may be adherent to surrounding cervical structures. Reference has already been made (p.211) to the experience of Lindsay and Dailey (1954) in this connection, who found 22 of 25 such glands extremely adherent to adjacent structures

/ including

including the trachea and cervical muscles, although not of sufficient degree to prohibit thyroidectomy. de Quervain observed that, while adhesion with the surrounding tissues may be comparatively pronounced, the gland is not adhered into a solid mass to the same degree as is depicted in most descriptions of Riedel's Thyroiditis. Concerning extra-capsular extension, therefore, the position seems analogous to Struma Lymphomatosa, namely that, while the gland may be adherent and densely so to adjacent cervical structures, it is not generally allowed that the disease process is capable of producing that diffuse spreading fibrosis, rendering ablation of the gland an impossibility and held to be so characteristic of Riedel's disorder.

C. Other conditions and Riedel's Thyroiditis

Crile (1948) has made a great point of the presence of a central adenoma with concentric surrounding fibrosis as being the salient feature of Riedel's Thyroiditis. Seven of his eleven cases presented this finding. Lindsay et al. (1952) had two cases of Riedel's disease out of 195 cases of Chronic Thyroiditis and both showed this particular type of pathological change. (Fig. 106). The peripheral portion of the mass consisted of dense, gritty, white fibrous tissue, with a concentrically layered appearance, the central portion of degenerating, friable tissue with the appearance of an involutionary nodule. Microscopy confirmed this interpretation.

While such a pathological process may apparently give

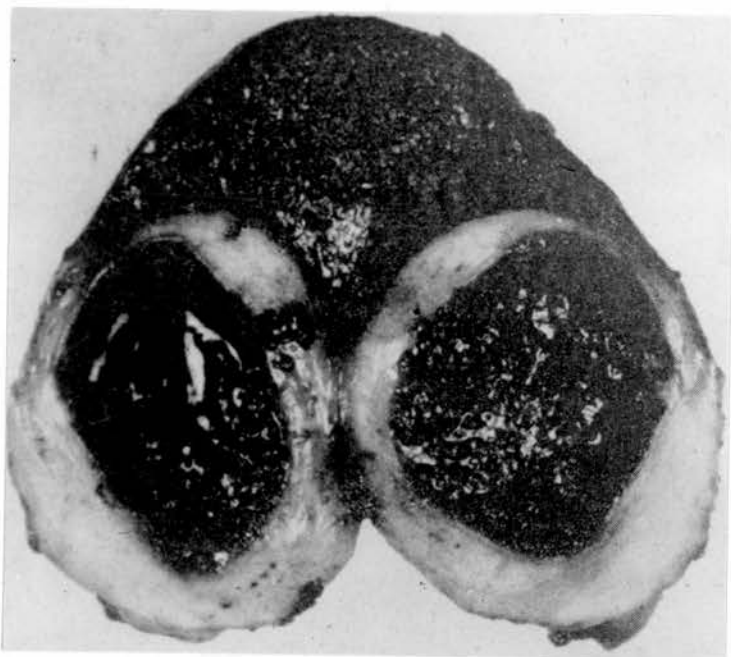


Fig. 106

Reproduced from Lindsay, et al., (1952).
J. Clin. Endocrinol. 12(2). 1578.

rise to a dense, hard, unilateral thyroid swelling, with invasive extra-glandular fibrosis and pressure symptoms, such is not the commonly accepted concept of Riedel's Thyroiditis and it would seem better, for the present at any rate, to assign cases showing such features to a separate and individual category.

D. Riedel's Thyroiditis

In 1,008 consecutive thyroidectomies carried out in Edinburgh under the charge of Mr. K. Paterson Brown between 1943 and 1957, no case satisfied the requirements, clinical and/or pathological, necessary for classification under this title, although on a number of occasions such a diagnosis was erroneously recorded by the pathologist. In view of this negative experience of the disorder, an attempt has been made to obtain a more accurate picture of its clinico-pathological manifestations by sampling the literature of reported cases. This has been done by collecting and analysing a total of 218 cases of thyroid disease reported as examples of Riedel's Thyroiditis from 61 separate sources in the Anglo-American literature between 1869 and 1956. With the exception of Riedel's original three cases, which are included in the analysis, no attempt has been made to review the Continental or other world literature. While it is admitted that such an omission might involve a possible source of error, there is good reason to believe that the additional information accruing from a complete world survey would not be proportional to the magnitude of the task involved, unless one postulate a strictly localised

/ geographical

geographical distribution of the disease and there are no good grounds for this belief. Thus such a sample is regarded as being representative of the general position concerning this disease.

The material was divisible into six groups as follows:-

1.	Struma Lymphomatosa reported as Riedel's Thyroiditis.....	76 cases
2.	Subacute Thyroiditis reported as Riedel's Thyroiditis.....	10 cases
3.	Fibrosis surrounding an adenoma reported as Riedel's Thyroiditis...	9 cases
4.	Other conditions reported as Riedel's Thyroiditis.....	7 cases
5.	Definite conclusion impossible.....	92 cases
6.	Admissible as true Riedel's Thyroiditis.....	24 cases
	Total.....	<u>218 cases</u>

1. Struma Lymphomatosa reported
as Riedel's Thyroiditis

Of the 218 cases reported as examples of Riedel's Thyroiditis, no less than 76 proved, on review, to be clear-cut instances of Struma Lymphomatosa. This source of error and the reasons for it have already been fully discussed and these figures simply serve to emphasise the frequency with which it has occurred.

2. Subacute Thyroiditis reported
as Riedel's Thyroiditis

In ten of the cases it was possible to make a firm diagnosis of Subacute Thyroiditis.

3. Fibrosis surrounding an adenoma reported as Riedel's Thyroiditis

Nine of the cases fitted into this group.

4. Other conditions reported as Riedel's Thyroiditis

This small and heterogeneous group comprised seven cases variously interpreted as instances of thyrotoxicosis, simple goitre etc.

5. Definite conclusion impossible

It proved impossible to reach a definite conclusion concerning the nature of 92 of the 218 cases. This was largely due to insufficient or absent details concerning individual cases, but the group includes a small number with fuller clinico-pathological data, consideration of which yet resulted in uncertainty concerning their true nature (Fig. 107).

While it is impossible to be dogmatic, it seems highly probable that not one of these cases is a true example of Riedel's Thyroiditis. Berry's case had no pressure symptoms of any kind, pain was a distinctive feature, there was no evidence at operation of extra-thyroid extension and while no histo-pathological details are available, the facts would appear to fit a Subacute Thyroiditis much more than the Riedel form. In St. George's case the pathological findings are highly suggestive of the combination of a central adenoma with surrounding fibrosis, as suggested and described subsequently by Crile. Tucker and Gertz subscribed to Ewing's hypothesis and while, again,

AUTHOR	DATE	NO. OF CASES	SEX	AGE	SYMPTOMS			THYROID		TREATMENT AND OPERATIVE FINDINGS	PATHOLOGY		POST-TREATMENT
					PAIN	OTHER	CONSISTENCE	INVOLVEMENT	GROSS		MICROSCOPIC		
MERRY	1921	1	F.	46	0	+	PAINFUL LUMP IN NECK OF 2 MTHS. DURATION.	HARD AND KNOBBY.	UNILATERAL (R.) "HAZEL-NUT" OPPOSITE LOBE APPEARED HEALTHY.	R. LOBECTOMY. NO DIFFICULTY.	SMOOTH, WHITE, FIRM & OPAQUE. INTERLACING FIBROUS STRANDS. NO VISIBLE COLLOID.	NO NORMAL TISSUE. CHRONIC INFLAMMATORY CHANGES.	- : 6½ YRS.
F. GEORGE	1924	1 (2)*	M.	25	+	+	NO MEN- TION OF THYROID EN- LARGEMENT, DYSPNOEA AND DYSPHAGIA.	INTENSELY HARD	UNILATERAL (R.) "HEN'S EGG"	R. HEMIHYROIDEC- TOMY AND RADIUM. ADHERENT TO MUSCLE, TRACHEA AND OESOPHAGUS.	CENTRAL, SOFT, SUCCULENT MATERIAL, SUR- ROUNDED BY HARD, FIRM TISSUE.	DIFFUSE, DENSE CONNECTIVE TISSUE AND SPARSE ROUND CELLS.	- : 4 YRS.
BUCKER AND BERTZ	1927	1	M.	48	+	+	6 MTHS. HISTORY OF THYROID EN- LARGEMENT, GRADUALLY INCREASING IN SIZE.	STONY HARD.	BILATERAL.	THYROIDECTOMY ADHERENT TO SURROUNDING STRUCTURES AND TRACHEA.	-	RIEDEL'S STRIATA (NO DETAILS)	NO FOLLOW-UP
DETSCH	1940	1	F.	52	0	0	15 YR. HISTORY OF THYROID EN- LARGEMENT. 1 MTH. PRIOR TO ADMIS- SION, AFTER "GRIP AND HEAD COLD", THYROID ENLARGED AND BECAME DEFINITELY TENDER.	UNUSUALLY FIRM. HOT TENDER.	BILATERAL	SUBTOTAL THYROIDECTOMY. CONSIDERABLE EXTRACAPSULAR FIBROSIS.	WHITISH COLOUR. INTERLACING FIBROUS BANDS. SEVERAL DISCRETE NODULES.	FIBROSIS. ROUND CELLS. GIANT CELLS.	NO FOLLOW-UP
COCKMAN	1941	2-4.	F.	46	0	0	2 YR. HISTORY OF NECK SWELLING. AT TIMES, NERVOUS, IRRITABLE AND PALPITATIONS. RECENT AWARENESS OF SENSE OF WEIGHT IN NECK & HARDNESS OF GOITRE.	STONY HARD	BILATERAL SYMMETRICAL. SMOOTH SURFACE AND MOBILE.	HALF OF EACH LOBE RESECTED. NO MENTION OF ADHESION.	FREE SURFACE BOSSELATED. CUT SURFACE HARD, GREYISH-WHITE AND HOMOGENEOUS.	EXTENSIVE FIBRO- SIS. MINOR TUBERCLES CON- TAINING GIANT CELLS.	- : 5 MTHS.
		B.	F.	42	+	+	NO MEN- TION OF TIGHT- NESS IN NECK, OCCASIONAL	STONY HARD	BILATERAL SMOOTH SURFACE AND FULLY MOBILE.	"DECOMPRESSIVE" RESECTION TO EXPOSE TRACHEA. EARLY EVIDENCE OF FIXATION.	CUT SURFACE FIRM, HOMO- GENEUS AND GREYISH.	PARENCHYMA DIVIDED INTO ISLANDS BY FIBROUS OVER- GROWTH. INFILTRA- TION OF FLASHA CELLS & LYMPHO- CYTES. TUBERCLE- LIKE	NO FOLLOW-UP

no pathological information is available, their patient probably suffered from a fibrotic Struma Lymphomatosa. Goetsch's case is difficult of interpretation but pressure symptoms were again absent, the patient's thyroid trouble commenced following an upper respiratory infection, distinct tenderness was noted at one point and the very full, if somewhat confusing, pathological description is suggestive of Subacute Thyroiditis. Both of Goodman's patients were almost certainly suffering from Struma Lymphomatosa. The limited resection in the second case was not imposed because of irremovability of the gland, but because - "Keeping in mind the possibility of a Riedel, a classical resection was not attempted". In fact there was only early evidence of fixation. Indeed it is a feature of the three cases in the group in which significant extra-thyroid extension is depicted, that, in each, a major resection was possible.

A partial analysis of the 92 cases is given in Fig.108. In such a heterogenous group of cases, undoubtedly composed of more than one type of Thyroiditis although reported under a common title, statistical analysis means little or nothing. The object in preparing such a table, however, has been to illustrate certain facts which emphasise the polyglot nature of the cases and must preclude many of them from the classical concept of Riedel's disease. Thus in 51 of the cases it was possible to obtain some impression regarding pressure symptoms, commonly considered severe and

/ almost

AUTHOR	DATE	NO. OF CASES	AUTHOR'S CASE NO.	SEX	AGE	SYMPTOMS		THYROID INVOLVEMENT	SURGICAL TREATMENT	EXTRA-THYROID EXTENSION	
						PRESSURE	PAIN				
HERRY ST. GEORGE SCHULTZ	1921	1.	-	F.	46	0	+	UNILATERAL	LOBECTOMY	0	
	1924	1.	2	M.	25	+	N.M.	UNILATERAL	HEMITHYROIDECTOMY	+	
	1926	3.A.	-	F.)					NO FURTHER DETAILS		
		B. C.	-	F.)							
TUCKER AND GERTZ CROTTI	1927	1.	-	M.	48	+	0	BILATERAL	THYROIDECTOMY	+	
	1938	8.A.	-	F.	44	0	N.M.	N.M.	N.M.	BILATERAL CUNEIFORM RESECTION	N.M.
		B.	-	F.	44	+	N.M.	N.M.	N.M.	BILATERAL CUNEIFORM RESECTION	N.M.
		C.	-	M.	50	+	N.M.	N.M.	N.M.	BILATERAL CUNEIFORM RESECTION	N.M.
		D.	-	M.	57	0	N.M.	N.M.	N.M.	BILATERAL CUNEIFORM RESECTION	N.M.
		E.	-	F.	48	+	N.M.	N.M.	N.M.	BILATERAL CUNEIFORM RESECTION	N.M.
		F.	-	F.	37	+	N.M.	N.M.	N.M.	BILATERAL CUNEIFORM RESECTION	N.M.
		G.	-	M.	43	+	N.M.	N.M.	N.M.	BILATERAL CUNEIFORM RESECTION	N.M.
		H.	-	F.	57	0	N.M.	N.M.	N.M.	BILATERAL CUNEIFORM RESECTION AND ISTHMOCTOMY	N.M.
9.	-	-	F.				NO DETAILS				
HARRY GOETSCH GOODMAN PATTERSON & STARKEY	1940	1.	-	F.	52	0	0	BILATERAL	SUBTOTAL THYROIDECTOMY	+	
	1940	1.	-	F.	46	0	N.M.	BILATERAL	RESECTION OF HALF OF EACH LOBE	N.M.	
	1941	2.A.	-	F.	42	+	N.M.	N.M.	BILATERAL	RESECTION TO EXPOSE TRACHEA	+
		B.	-	F.							
	1948	11.A.	2	-	F.	50	N.M.	+	UNILATERAL	PARTIAL THYROIDECTOMY	N.M.
		B.	3	-	F.	50	N.M.	+	BILATERAL	SUBTOTAL THYROIDECTOMY	N.M.
		C.	8	-	F.	35	+	N.M.	BILATERAL	PARTIAL THYROIDECTOMY	N.M.
		D.	9	-	F.	56	N.M.	+	BILATERAL	BILATERAL PARTIAL THYROIDECTOMY	N.M.
		E.	10	-	F.	21	+	N.M.	BILATERAL	RESECTION OF Isthmus and Wedge from Each Lobe	+
		F.	11	-	F.	20	N.M.	+	BILATERAL	SUBTOTAL THYROIDECTOMY	N.M.
		G.	13	-	E.	47	N.M.	N.M.	BILATERAL	TOTAL THYROIDECTOMY AND TRACHEOTOMY	+
		H.	19	-	F.	73	N.M.	N.M.	BILATERAL	SUBTOTAL THYROIDECTOMY	N.M.
		I.	21	-	F.	48	+	N.M.	BILATERAL	SUBTOTAL THYROIDECTOMY	N.M.
J.		22	-	F.	38	N.M.	+	BILATERAL	BISECTION OF Isthmus and Resection of Wedge from Each Lobe	N.M.	
1946 1950	K.	23	-	F.	47	N.M.	0	BILATERAL	RESECTION OF Isthmus and Wedge from Each Lobe	+	
	4.	-	-					NO DETAILS			
	9.	-	-					NO DETAILS			
1951	8.	-	-					NO DETAILS			

AUTHOR	DATE	NO. OF CASES	AUTHOR'S CASE NO.	SEX	AGE	SYMPTOMS		THYROID INVOLVEMENT	SURGICAL TREATMENT	EXTRA-THYROID EXTENSION
						PAIN	PRESSURE			
ALLEN AND REEVES	1951	15.A.	-	F.	24	+	N.M.	UNILATERAL	N.M.	N.M.
				F.	32	+	N.M.	UNILATERAL	N.M.	N.M.
				F.	45	N.M.	N.M.	BILATERAL	N.M.	N.M.
				F.	54	N.M.	N.M.	BILATERAL	N.M.	N.M.
				F.	22	+	N.M.	BILATERAL	N.M.	N.M.
				F.	42	N.M.	N.M.	UNILATERAL	N.M.	N.M.
				N.M.	59	+	N.M.	UNILATERAL	N.M.	N.M.
				N.M.	50	N.M.	N.M.	UNILATERAL	N.M.	N.M.
				F.	54	+	N.M.	UNILATERAL	N.M.	N.M.
				F.	60	+	N.M.	UNILATERAL	N.M.	N.M.
				F.	52	N.M.	N.M.	BILATERAL	N.M.	N.M.
				F.	48	N.M.	N.M.	BILATERAL	N.M.	N.M.
				F.	48	N.M.	N.M.	UNILATERAL	N.M.	N.M.
				F.	52	+	N.M.	UNILATERAL	N.M.	N.M.
				F.	53	+	N.M.	UNILATERAL	N.M.	N.M.
JOLL	1951	8.A.	-	F.	53	+	0	BILATERAL	RESECTION OF WEDGE FROM ONE LOBE	N.M.
				F.	53	+	0	BILATERAL	RESECTION OF WEDGE FROM ONE LOBE	N.M.
				F.	44	+	0	UNILATERAL	REMOVAL OF LOBE	N.M.
				F.	38	+	+	BILATERAL	REMOVAL OF WHOLE OF L. LOBE AND LOWER PART OF R. LOBE	N.M.
				F.	45	0	0	UNILATERAL	REMOVAL OF MASS	N.M.
				F.	44	+	N.M.	BILATERAL	RESECTION THREE-QUARTERS OF EACH LOBE	N.M.
HEPPESTALL & EASTCOTT	1954	3.A.	-	F.	50	0	N.M.	UNILATERAL	REMOVAL OF MASS	N.M.
				F.	37	N.M.	N.M.	UNILATERAL	REMOVAL OF LOBE	N.M.
				M.	31	+	0	UNILATERAL	REMOVAL OF WHOLE OF L. LOBE AND PORTION OF RIGHT	N.M.
				F.	42	0	N.M.	N.M.	LOBECTOMY	N.M.
				M.	23	+	N.M.	N.M.	SUBTOTAL THYROIDECTOMY	N.M.
				F.	64	+	N.M.	N.M.	BIOPSY	N.M.
HARLAND AND FRAVITZ	1956	8.	-	NO DETAILS						
				NO DETAILS						
		92.	-	54	51	51	51	51	51	51
				F=45	M=10	N.M.=17	N.M.=36	UNILATERAL=18	MAJOR RESECTION = 22	0 = 1
				M=9	M=9	N.M.=9	N.M.=9	BILATERAL=23	LIMITED RESECTION = 14	N.M.=15
						+	+	N.M.=10	N.M.=15	N.M.=17
						+	+			N.M.=35

FIG. 108

PARTIAL ANALYSIS OF 92 CASES REPORTED AS REIDEL'S THYROIDITIS.

N.M. = NO HENTON

almost indispensable to a diagnosis of this condition. Yet in ten of the cases they were conspicuous by their absence, while in 17 no mention is made of their occurrence and they may be assumed mild or absent. In at least seven of the 24 cases reported as having pressure symptoms, these were mild and consisted of no more than a choking sensation or a feeling of tightness in the neck. Concerning the degree of thyroid involvement, of 51 cases in which such an assessment could be made, this was diffuse in 23, 31 if Crotti's eight cases are added, all of whom had a bilateral operative procedure although no specific mention is made of the extent of the process. Of 51 cases, a major thyroid resection, classically considered impossible in this condition, was effected in 22, 12 of which demonstrated extra-thyroid extension of the disease process.

Concerning individual authors, it is impossible to be certain of the nature of Schultz's three cases, but in one of these the author found that the thyroid had not been completely transformed into the hard, ligneous tissue present in the other two glands, but showed the follicles compressed by a large amount of moderately cellular connective tissue and richly infiltrated with lymphocytes and plasma cells. The follicular epithelium was high, frequently surrounding a small amount of inspissated colloid. In many follicles colloid and lumen had disappeared, the epithelium forming a multinucleated syncytial mass - altogether a description suggestive of

Struma Lymphomatosa. Details of clinical and operative findings necessary to confirm this suspicion are, however, not reported.

Crotti's eight cases are incompletely reported and no pathological details are available. Pressure symptoms are reported in five, but simply referred to as "choking". All eight cases appear to have shown diffuse thyroid involvement judging from the extent of the surgical procedure.

Harry gives absolutely no details of his nine cases, preferring to discuss the problem from a general standpoint. In one of his cases, however, the patient had a persistent and otherwise unexplained rise in temperature, up to 100°F. at night, for several weeks prior to thyroidectomy; this subsided promptly when the diseased gland was removed - a well-recognised phenomenon in Subacute Thyroiditis and it seems possible that this author may have, at least partly, confused the two conditions.

There is little evidence for Riedel's Thyroiditis in Patterson and Starkey's eleven cases. This material is fairly fully reported with the exception of pathological details. All the patients were female. Pressure symptoms were evident in only three, while pain was a feature of five of the cases. The gland was diffusely involved in ten, a major resection was undertaken in eight and only in three of the cases is mention made of extra-thyroid extension.

A complete absence of individual case details renders

/ assessment

assessment of Crile's four patients and Wright's nine patients, impossible. Likewise, Chesky, Dreese and Hellwig simply record eight cases of the condition without description, but it is of interest that these authors consider Riedel's Thyroiditis the later stage of Struma Lymphomatosa and their interpretation of the former may be modified accordingly.

Details of Allen and Reeves' 15 cases are sketchy. Their patients were all treated surgically but no mention is made of the extent of resection or operative findings. There is no record of pressure symptoms in eight of the cases, while six had a complaint of choking or choking sensation and one of smothering. Only two of the cases were males. The process was unilateral in ten of the cases.

Of Joll's eight cases, seven were female. Pressure symptoms were significant in only two of the patients. The thyroid was unilaterally involved in five of the cases. Extra-thyroid extension was noted in seven, rendering removal impossible in one case, but otherwise an in toto or major resection was effected. No pathological data are given.

Heptinstall and Eastcott make only brief reference to their three cases. Two had pressure symptoms, a major resection was possible in two and adhesion to adjacent muscles was present in all three. They comment upon the pathological picture as one of extreme fibrosis with great

/ diminution

diminution of epithelial elements and moderate lymphocytic infiltration.

Harland and Frantz had eight cases and remark that symptoms were minimal, except in one patient in whom severe tracheal compression developed. They found the E.S.R. usually elevated and the thyroid uptake of ^{131}I was depressed in the only case in which it was estimated. Operation was usually difficult because of dense fibrous adhesions binding the gland to the surrounding tissues. Pathologically they found a dense hyaline fibrosis and chronic inflammatory cell infiltrate. They could find no resemblance between this picture and that of Struma Lymphomatosa, but the similarity of the clinical, operative and pathological findings suggested a possible relationship to Subacute Thyroiditis.

6. Admissible as true Riedel's Thyroiditis

Of the 126 cases in which it proved possible to form some conclusion, (Groups 1, 2, 3, 4 and 6), 24 presented an unfamiliar clinico-pathological picture, which, it was felt, corresponded most closely to the concept of Riedel's Thyroiditis and were thus, for the purpose of investigation, admissible as such. These cases are analysed in Fig. 109.

Of the 24 cases, 19 were women (79.2%) and five men (20.8%). The average age was 39.9 years. Pressure symptoms were present in 20 cases, but in seven of these were mild. Dyspnoea was much commoner than dysphagia, 17 patients complaining of respiratory embarrassment and only

AUTHOR	DATE	NO. OF CASES	AUTHOR'S CASE NO.	SEX	AGE	STRIKES		THYROID		SURGICAL TREATMENT	EXTRA-THYROID EXTENSION	COMMENTS
						PRESSURE	PAIN	INVOLVEMENT	TENDERNESS			
SEIPLE	1869	1.	-	F.	50	+++	N.M.	BILATERAL	N.M.	NONE	+	DIED OF TUBERCULOSIS.
BOWLEY	1884	1.	-	F.	42	+++	N.M.	BILATERAL	0	TRACHEOTOMY	+++ (P.M.)	DIED AFTER TRACHEOTOMY.
RIEDEL	1896	2.A.	-	M.	42	++	N.M.	BILATERAL	N.M.	PARTIAL RESECTION	+++	DIED 9 MRS. LATER OF "STROKE".
		B.	-	F.	23	++	N.M.	BILATERAL	N.M.	PARTIAL RESECTION	+++	DIED 3 MRS. LATER OF "EBULLISM".
BERRY	1901	2.A.	2	F.	63	+++	N.M.	BILATERAL	N.M.	TRACHEOTOMY	++	DIED AFTER TRACHEOTOMY.
RIEDEL	1910	B.	3	F.	40	+	N.M.	UNILATERAL	N.M.	LOBECTOMY	0	
MURRAY AND SUTHER	1912	1.	-	M.	29	+++	N.M.	BILATERAL	N.M.	PARTIAL RESECTION PIECEMEAL	+++	
THOMAS AND WEBB	1923	1.	-	M.	23	+++	N.M.	BILATERAL	N.M.	RESECTION SUBTOTAL	++	
ST. GEORGE	1924	2.A.	1	F.	35	+++	N.M.	BILATERAL	N.M.	TRACHEOTOMY	0	DIED AFTER TRACHEOTOMY. SYPHILITIC.
		B.	3	M.	31	++	N.M.	UNILATERAL	N.M.	LOBECTOMY	++	
BONIAN	1924	1.	-	F.	30	+++	+	BILATERAL	+	(PARTIAL RESECTION (TRACHEOTOMY) PIECEMEAL	N.M.	
HAYTHES	1927	1.	-	F.	38	+	N.M.	BILATERAL	N.M.	RESECTION SUBTOTAL	+++	
KENT	1929	2.A.	-	F.	25	N.M.	+	BILATERAL	N.M.	THYROIDECTOMY	+++	
		B.	-	F.	32	+	N.M.	BILATERAL	N.M.	"	N.M.	
WHITE	1932	1.	-	F.	44	N.M.	N.M.	BILATERAL	N.M.	PARTIAL RESECTION	++	
LEE	1935	1.	4	F.	42	0	0	BILATERAL	0	SUBTOTAL	++	SYPHILITIC.
McCLINTOCK AND WRIGHT	1937	4.A.	5	F.	53	+	N.M.	N.M.	N.M.	THYROIDECTOMY	N.M.	
		B.	6	F.	45	++	+	BILATERAL	+	N.M.	N.M.	ADHERENT
		C.	7	F.	42	++	N.M.	BILATERAL	N.M.	PARTIAL RESECTION	N.M.	
		D.	8	F.	35	++	+	BILATERAL	N.M.	PARTIAL RESECTION	+	
SCHILLING	1945	2.A.	7	F.	57	+	N.M.	BILATERAL	N.M.	NONE	++ (P.M.)	DIED OF CO-EXISTENT CAL. CERVIX WITH METASTASES.
		B.	8	F.	37	+	N.M.	BILATERAL	0	SUBTOTAL	++	
BRAYTON	1948	1.	-	M.	52	N.M.	0	BILATERAL	0	THYROIDECTOMY	++	
		2A.	-	F=19	39.9	N.M. = 3	N.M. = 16	N.M. = 1	N.M. = 17	N.M. = 1	N.M. = 5	
				M=5		0 = 1	0 = 2	UNILATERAL=2	0 = 5	MAJOR RESECTION=9	0 = 2	
						+	+	BILATERAL=21	+	LEIOTED RESECTION=9	+	
						++ = 6	+		+	OTHER = 5	++ = 6	
						+++ = 7					+++ = 6	

N.M. = NO MENTION

P.M. = POST-MORTEM FINDING

six of difficulty in swallowing. Cord paresis was noted in only one of the five cases in which such a record was available. A positive record of pain in the thyroid was obtained in six of the cases, but thyroid tenderness was positively reported in only two. The thyroid was diffusely involved in 21 of the 24 cases; in two the condition was unilateral, while in the remaining case there was no definite statement. A major resection was carried out in nine of the cases, six of which exhibited moderate or severe degrees of extra-thyroid extension of the disease process. Altogether, 17 of the cases showed fixation of the thyroid to surrounding structures, but in three this appeared of slight degree. Of the remaining seven cases, there was no extra-thyroid extension in two and no record in five.

The pathology of these cases is extremely difficult, if not impossible, to interpret. No single, clearly defined picture emerges from a consideration of the gross and microscopic findings. Fibrous replacement of the thyroid, frequently of a hyaline nature, is, as might be expected, an almost universal finding, but is accompanied in the great majority by a round cell infiltration, frequently of marked degree. Lymphoid follicle and giant cell formation are, on the other hand, almost never reported. In practically all cases such changes are associated with striking diminution in the amount of thyroid parenchyma, while that which remains is frequently reported as atrophied

or otherwise pathological; residual normal parenchyma is seldom reported. In other words, the general impression gained from a study of the pathological features of these 24 cases, is of a diffuse and not a focal process.

Criticism of the Concept of Riedel's Thyroiditis

1. Incidence

Figures purporting to show the incidence of this disorder are essentially valueless when the frequency with which it has been erroneously reported is considered. A healthy scepticism must be exercised concerning all large series of reported cases.

2. Age and Sex

There would seem little doubt that the age and sex incidence in any group of cases designated Riedel's Thyroiditis differs from that in Struma Lymphomatosa. (Fig. 110). The statement frequently made, however, that Riedel's Thyroiditis occurs in young adults and is only slightly commoner in females than in males, obviously requires revision. All the later series confirm the view that the average age of occurrence is around 40 years, and that females are affected four times more commonly than males. The exact age and sex incidence of Subacute Thyroiditis has not so far been worked out. It is said, however, to occur most commonly between 30 and 50 years of age, while a significant number of the cases are male.

3. Pathology

Riedel's Thyroiditis has been described as essentially

/ focal

		Struma Lymphomatosa				Riedel's Thyroiditis			
		Graham 1934 24 Cases	McClintock and Wright 1937 50 Cases	Joll 1939 81 Cases	Present Series 1957 60 Cases	Graham 1934 44 Cases	McClintock and Wright 1937 60 Cases	Joll 1939 5 Cases	Present Series 1957 24 Cases
Sex	Male	4.2%	1.4%	3.7%	10%	4.1.5%	18.2%	20%	20.8%
	Female	95.8%	98.6%	96.3%	90%	58.5%	81.8%	80%	79.2%
Average Age		52.4 Yrs.	49.2 Yrs.	57.6 Yrs.	50.9 Yrs.	36.2 Yrs.	40.3 Yrs.	44.4 Yrs.	39.9 Yrs.

Fig. 140

Comparison of Age and Sex Incidence in Struma Lymphomatosa and Riedel's Thyroiditis.

focal in its origin and distribution, yet in 24 fully reported cases, the gland was diffusely involved in at least 21 (87.5%). Figures relating to the degree of thyroid involvement have varied a good deal - Graham, 50% of 41 cases were bilateral, McClintock and Wright, 69.5% of 60 cases, Joll, 20% of five cases - and the truth is difficult to establish, but probably some two-thirds show diffuse involvement of the gland. Extreme fibrosis, round cell infiltration, foci of lymphoid tissue, squamous metaplasia of vesicular epithelium and giant cell formation have all been described as elements of the histo-pathological picture of this disorder, but, as has been shown, such features may also constitute a prominent finding in Struma Lymphomatosa and/or Subacute Thyroiditis. Despite Joll's assertion to the contrary, no single, clearly defined picture emerges from a consideration of the findings in reported cases and no justification can be found for the conclusion that Riedel's Thyroiditis is a definite, specific pathological entity. One exception to this statement is the pathological type, described by Crile and others and illustrated by relatively few of the reported cases, of a dense fibrosis centring upon a degenerating adenoma: this may, if necessary be regarded as one form of Riedel's Thyroiditis, but it only serves to confirm the view just expressed concerning the heterogeneous nature of this group of material.

4. Symptoms and Signs

Pain, both in the gland and referred locally, tenderness and pyrexia have all been noted from time to time as clinical manifestations of Riedel's Thyroiditis, but the occurrence of such findings, either collectively or separately, should excite suspicion of Subacute Thyroiditis and entail great caution in the interpretation of the particular case.

Symptoms of severe pressure, and in particular dyspnoea, have always been regarded as virtually indispensable to a diagnosis of Riedel's Thyroiditis and there can be no doubt that many of the cases so designated have demonstrated such symptomatology. It is one of the inexplicable mysteries of the disorder that the removal of a negligible amount of thyroid tissue should relieve such pressure when present. It is equally certain, however, that in a considerable proportion of cases pressure symptoms have been slight or absent.

It is classical to regard the goitre of Riedel's Thyroiditis as small: in fact, reference to reported cases shows it to be one of moderate or considerable size. Its hardness is not in dispute. Sinus formation has been rarely reported.

5. Operative Findings and Treatment

Extra-thyroid extension of the disease process resulting in dense fixation of the gland to surrounding muscles, trachea, oesophagus, vessels and nerves and

/ precluding

precluding major surgical resection, has long been considered a classical attribute of Riedel's Thyroiditis. In certain of the reported cases, particularly those of the last century, the degree of extra-thyroid fibrosis has been quite remarkable and appears to have assumed an almost "malignant" quality of permeation, reaching limits which have included the mediastinum and base of the skull. At the same time, however, a certain number of the reported cases have shown a relatively minor degree of fixation and in a not inconsiderable number a major thyroid resection has been effected without untoward results. It is a point worthy of consideration and one which makes for some difficulty in assessing reported cases, that the interpretation of the degree of extra-thyroid extension and the facility or otherwise of operation must depend, at least to some extent, upon the dexterity of the surgeon concerned and his familiarity with the operation of thyroidectomy, and in this connection it is not uncommon to encounter a considerable discrepancy between the description of operative findings and the extent of resection achieved. Furthermore, as already emphasised, great caution must be exercised in respect of any case exhibiting lesser degrees of extra-thyroid extension and fixation and particularly where only muscle or trachea is involved, since such a condition may well exist in both Struma Lymphomatosa and Subacute Thyroiditis.

6. Thyroid Function

Considerable importance has been attached to the relative infrequency of subnormal thyroid function in Riedel's Thyroiditis, both before and after surgical treatment, and in this respect this type of case shows a marked difference from what is found in Struma Lymphomatosa. Thus Graham found an incidence of post-operative hypothyroidism in 19% of cases, McClintock and Wright in 27% and Joll in 20%. Details of follow-up were insufficiently complete to permit of a conclusion concerning the incidence of this complication in the 24 cases reviewed above, but judging from the degree and extent of glandular destruction, there would seem some grounds for the belief that the foregoing figures under-estimate the frequency of its occurrence.

Summary

Over the years since Riedel described his original cases a concept of a specific disease process has evolved to which his name has become attached. Analysis of reported cases, however, while agreeing in certain findings, in respect of others show striking discrepancies, both with this concept and with what, in fact, Riedel himself described. As has been shown, many cases of Struma Lymphomatosa and Subacute Thyroiditis have been erroneously reported as examples of this disorder for one reason or another. Much discussion has been lavished on the controversy concerning the unity or otherwise of Struma

/ Lymphomatosa

Lymphomatosa and Riedel's Thyroiditis and much evidence, statistical or otherwise, has been brought forward in favour of the view that no relationship exists. In a sense this controversy is redundant and effort would be more profitably expended in a more accurate clinical and scientific attempt to define the exact nature of those cases of Thyroiditis, and such must exist, which do not conform to the known facts concerning the Hashimoto and Subacute types of the disease. In this respect, the availability of laboratory aids to diagnosis, lacking in the past, may help in some measure. In this way, much of the naive thinking which has surrounded Riedel's Thyroiditis up until now might be dissipated, a clearer picture of one or possibly more specific thyroid disorders might emerge and it might finally become possible to decide whether the perpetuation of the Riedel eponym is justified.

PART VI

THYROIDITIS AND MALIGNANT DISEASE

Introduction

As has been repeatedly emphasised and illustrated throughout the foregoing pages, the three major forms of Thyroiditis are, from the clinical viewpoint, not infrequently confused with malignant disease of the thyroid gland. The differentiation of Thyroiditis and malignancy is very often a matter of considerable difficulty, even to the clinician constantly engaged in dealing with thyroid disease. Thus the resemblance of Struma Lymphomatosa to malignancy may on occasion be very close, particularly when the goitre is very hard in consistence and where, in addition, such suspicious features as pressure symptoms, hoarseness and radiological evidence of retro-tracheal extension exist. When malignancy is suspected and a test dose of radiotherapy given with assessment at 48 or 72 hours, it is important to remember that the gland of Struma Lymphomatosa will usually show little or no response in this time, as compared with the frequently marked reduction in size of a radiosensitive tumour. At operation also, even the experienced surgeon may have difficulty in formulating a concrete opinion concerning the nature of the process from the gross appearance of the gland and ample testimony of this is given by the unfortunate sequelae of total thyroidectomy for Struma Lymphomatosa in the mistaken belief that the resection was being carried out for a malignant condition. Such mistakes and difficulties are likely to be much less frequent in the future with the increased accuracy of diagnosis of Struma Lymphomatosa

/ resulting

resulting from laboratory tests, but even so the hazards still exist to some extent. Similarly the mild or resolving case of Subacute Thyroiditis with relatively slight local and systemic manifestations and as its most prominent feature a firm or hard, diffusely enlarged gland, may offer considerable difficulty in diagnosis and arouse the suspicion of a malignant condition. Where diffuse extra-thyroid extension of the disease process has taken place with resultant fixation, as in the classical (but apparently extremely rare) concept of Riedel's Thyroiditis, the diagnostic difficulty would appear almost insuperable.

Such general considerations apart, however, it is now necessary to discuss whether any actual relationship exists between Thyroiditis and malignant disease and in this connection only Struma Lymphomatosa would appear to merit serious attention. In any series of malignant goitres, one is impressed by the not inconsiderable frequency with which malignant disease is reported as arising in a gland also showing the features of Struma Lymphomatosa and in recent years a small but increasing literature has appeared purporting to show a relationship between the two conditions. The problem is a difficult one and the following six cases have been selected to illustrate its complexities.

Case Reports

Case 1

Mrs. M.D. Age 58 years. Admitted R.I.E.-
18.7.49.

/ History

History of Present Illness. One year prior to admission she noticed a slight swelling in the left side of her neck, which thereafter gradually increased in size. Over the same period she was breathless on exertion. She had observed no change in her voice, but tended to be hoarse, mainly, she thought, as a result of heavy smoking.

Clinical Examination showed a slight generalised enlargement of the thyroid gland. In the left lobe and extending into the isthmus was a firm swelling, 5 x 3 cm., not fixed to skin or muscles. There was a 1 cm. mobile gland in the left supraclavicular region.

The hair was dry, the eyebrows scanty and the voice hoarse.

An X-ray of the neck showed an increase in the soft tissue shadow of the thyroid, both in front of and behind the trachea, which was deviated slightly to the right and compressed in its antero-posterior diameter. Chest X-ray was negative.

Laryngoscopy showed slightly diminished movement of the left cord with very slight abductor paresis.

Clinical Diagnosis. Carcinoma.

Operative Findings. At open biopsy, the left lobe was inspected. It was found to be firm and in its posterior part, hard. The surgeon found it impossible to be certain whether the features were those of Struma Lymphomatosa or malignant disease and while the appearance in some ways resembled the former, the gland did not mobilise quite so easily as usual.

Treatment and Follow-up. Wide-field X-ray therapy was given from 15.8.49 to 23.9.49 to a maximum incident dose of 2,000 r. The tumour in the thyroid disappeared very quickly and at the end of treatment no abnormality could be palpated in the neck. By 5.4.50 there was a visible recurrence, the whole of the left lobe and greater part of the isthmus being involved and fixed. Further X-ray therapy was given between 25.4.50 and 29.6.50 to a dose of 1,800 r, the tumour again responding and by 24.8.50, the thyroid had a normal contour and was freely mobile and of soft consistence. She finally died, however, on 17.1.51. There was no autopsy.

Histo-pathology

The gland showed a diffuse cellular infiltration with thickening of the interlobular septa and a number of small islands of surviving thyroid parenchyma (Fig. 111).



Fig. 111

General view showing diffuse cellular infiltration, thickening of interlobular septa and centrally, one surviving island of thyroid parenchyma. H. & E. X 50.

The structure of the residual parenchyma was uniform throughout the tissue examined and was seen to be of the Askanazy type with an associated intervesicular infiltrate of lymphocytes and plasma cells. No lymphoid follicles, however, were observed. The thyroid epithelium showed no evidence of mitotic activity. (Fig. 112).

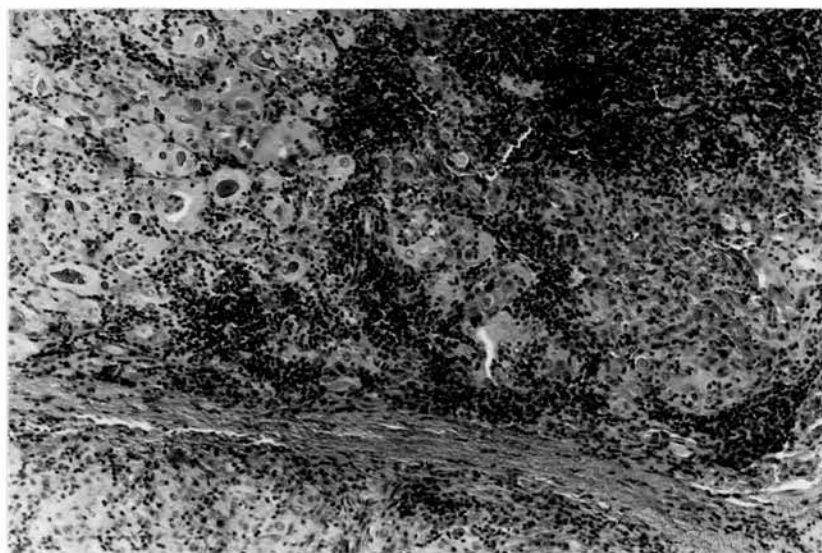


Fig. 112

Higher magnification of island of thyroid parenchyma shown in Fig. 111. Note Askanazy change and intervesicular infiltrate of lymphocytes and plasma cells. H. & E. X 80.

The major portion of the tissue, however, in which thyroid vesicular structure was no longer recognisable, was composed of an extremely dense cellular infiltration by very large numbers of plasma cells, lymphocytes and tumour cells, the latter possessing large, dark, round nuclei surrounded by a narrow rim of basophilic cytoplasm.

(Fig. 113).

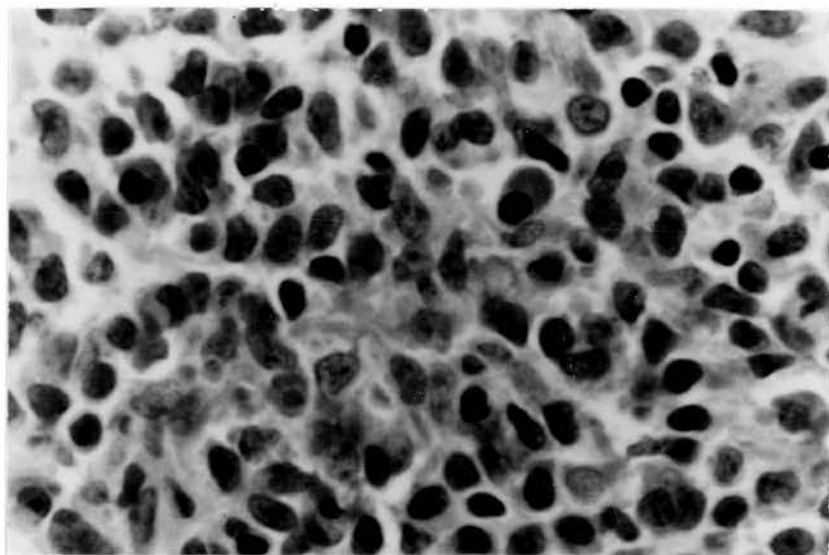


Fig. 113

Showing cellular infiltrate consisting of tumour cells, lymphocytes and plasma cells.
H. & E. X 700.

Case 2

Miss A. McD. Age 67 years. Admitted R.I.E. -
11.5.52.

History of Present Illness. She first became aware of a swelling in the neck two months prior to admission. She had become conscious of the act of swallowing and was doing so almost constantly on account of the feeling of something in her throat. She complained of occipital headaches of a few weeks duration. She had observed no difficulty with breathing. She had always had a dry voice and had

/ noted

noted no recent difference in its depth or quality.

Past History. She had suffered from angina pectoris for nine years and had undergone a cervical sympathectomy in 1947.

Clinical Examination showed a diffusely enlarged thyroid, more pronounced on the right side where the consistency was definitely hard. There was little movement of the gland on swallowing. The thyroid cartilage was displaced to the left. No enlarged cervical glands were noted. The voice was hoarse.

An X-ray of the neck showed some enlargement of the soft tissue shadow, both in front of and behind the trachea, the latter being somewhat narrowed in its antero-posterior and side to side diameters. Barium swallow showed deviation of the hypopharynx and upper oesophagus to the left, but no evidence of involvement of these structures.

Laryngoscopy showed the cords to be normal.

Clinical Diagnosis. Carcinoma.

Treatment and Follow-up. At operation the right lobe was found markedly enlarged, its appearance suggesting carcinoma. Posteriorly there was invasion of muscles, carotid sheath and pre-vertebral fascia. A total removal of the mass on the right side, including portions of the infra-hyoid muscles, carotid sheath and related glands, and of the isthmus and anterior part of the left lobe, was carried out. The patient died on the day following operation. Autopsy revealed a traumatic perforation of the oesophagus at the operative site with resultant widespread and severe mediastinitis. A searching examination revealed no metastatic spread of the tumour.

Pathology

Gross Appearance

The resected right lobe, 8.5 x 5.5 x 6 cm., had a smooth, slightly lobulated surface and was largely enclosed by a thin fibrous capsule. On section, its substance was moderately firm, grey and slightly translucent and marked by fairly large, irregular, pale green, soft areas and also a number of brownish-yellow streaks.

The resected portion of the left lobe, 3.5 x 1.25 cm., had a rough exterior and consisted, on section, of firm, grey substance with a delicate brown intersecting marking.

Histo-pathology

Tissue from the left lobe of the gland showed it to be divided into lobules by an exaggerated framework of fibrous tissue septa. The structure of the parenchyma was uniformly of the Askanazy type with attendant heavy round cell infiltration of lymphocytes and plasma cells.

(Figs. 114 and 115).

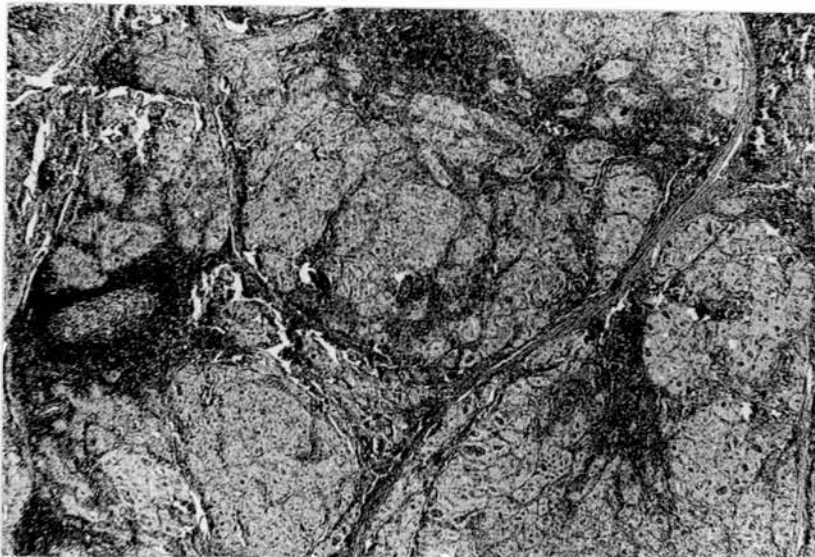


Fig. 114

Showing division of parenchyma into lobules by exaggerated fibrous tissue septa. Also round cell infiltration. H. & E. X 50.

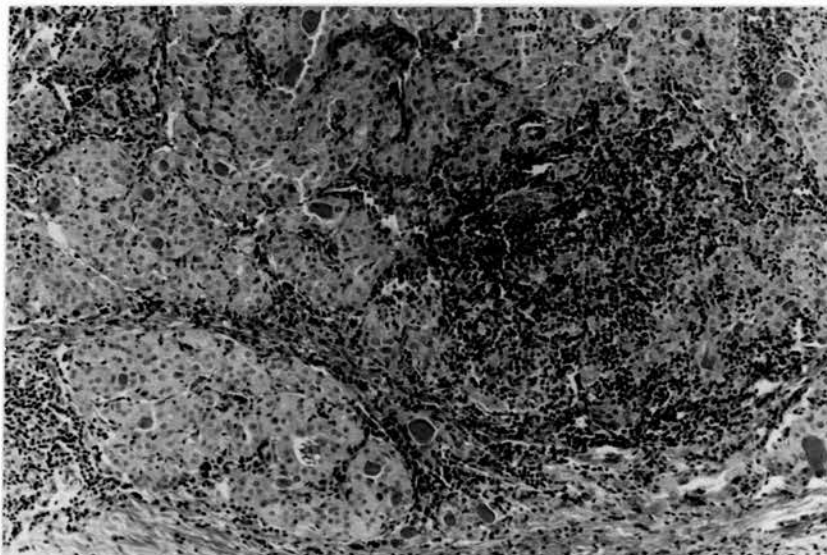


Fig. 115

Higher magnification of parenchymal structure showing Askanazy appearance. H. & E. X 80.

The right lobe showed little or no recognisable thyroid structure, but had been almost completely replaced by a highly cellular neoplastic tissue of similar composition to that found in Case 1, namely tumour cells possessing large, dark, round nuclei and scanty cytoplasm with intermingled lymphocytes and plasma cells. (Figs. 116 and 117).

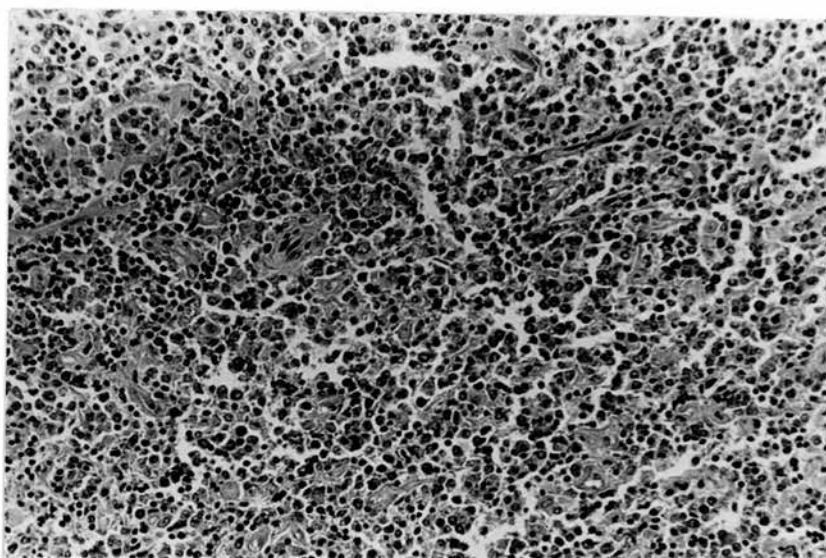


Fig. 116

Highly cellular neoplastic area with loss of thyroid structure. H. & E. X 150.

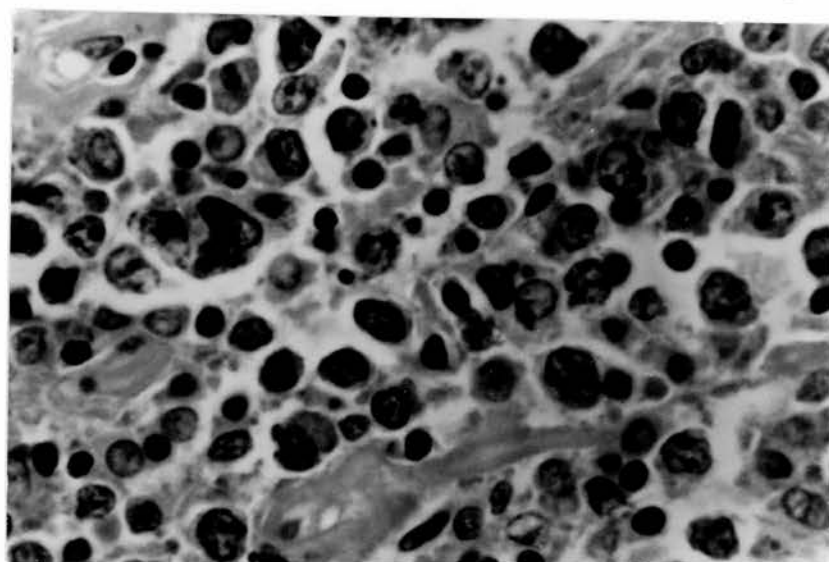


Fig. 117.

Higher magnification of Fig. 116. H. & E. X 700.

Case 3

Mrs. M. W. Age 65 years. Admitted R.I.E. - 29.1.54.

History of Present Illness. She had been aware of a small, hard lump on the right side of her neck for at least 30 years, but this had never caused her any trouble until some three to five months before admission during which time it had increased in size. She also developed a feeling of tiredness in the back of her neck and became breathless. In addition she complained of a gnawing pain in the upper part of the chest and stated that she had become more hoarse recently.

Past History. Pernicious anaemia had been diagnosed in 1951, for which she received injections of Cytamen monthly.

Clinical Examination showed a diffuse, hard enlargement of the thyroid, the main bulk of the swelling, in the right lobe and isthmus, measuring 7 x 7 cm. The left lobe was moderately enlarged and also hard in consistence. Movement of the gland was considerably restricted. There was no cervical lymphadenopathy.

The patient was rather slow in manner and the hair was very thin. The liver was enlarged three fingers below the costal margin with a firm, smooth edge. The left kidney was palpable. Otherwise physical examination was negative.

An X-ray of the neck showed a 3 cm. area of calcification in the right thyroid lobe. The trachea was compressed and deviated. Chest films revealed numerous small opacities throughout both lung fields, but it was not certain whether the appearances were due to vascular congestion or metastatic deposits.

Laryngoscopy showed no abnormality.

Clinical Diagnosis. ? Carcinoma.

Operative Findings, Treatment and Follow-up. There being no response to a test dose of 500 r of X-ray therapy to the gland, the neck was explored and total thyroidectomy carried out. Both lobes were considerably enlarged, especially the right, and obviously the seat of malignant disease. The patient made an uneventful recovery from this procedure and post-operative X-ray therapy was started on 22.2.54.

/ She

She rapidly deteriorated, however, and by 11.3.54, when therapy was discontinued, there were widespread metastatic deposits - pulmonary, hepatic, glandular and cutaneous. She died on 20.4.54. There was no autopsy.

Pathology

Gross Appearance

The resected gland weighed 175 g., and measured 9 x 9.5 x 5 cm. The right lobe was approximately twice the size of the left, while the isthmus formed a considerable part of the mass. The surface was lobulated and covered by a thin fibrous capsule with distended vessels. Section revealed an oval mass, 3 x 2.7 cm., in the substance of the right lobe. This mass was in large part margined by a narrow fibrous or calcified zone and was made up partly of firm, grey tissue and partly of softer, greyish-pink material. Apart from this area, both lobes and the isthmus were extensively replaced by firm, grey substance with a somewhat nodular structure. Small patches of pale brown, distinctly gelatinous tissue were present in the midst of the grey material. The remainder of the thyroid consisted of moderately firm, fleshy, reddish-brown tissue showing occasional rather poorly defined, degenerated nodules and small grey foci.

Histo-pathology

The gland showed widespread invasion by tumour tissue (Fig. 118). In some areas this was present as nodules surrounded by thick, fibrous capsules, in one of which calcification was present; elsewhere the tumour formed infiltrating cords.

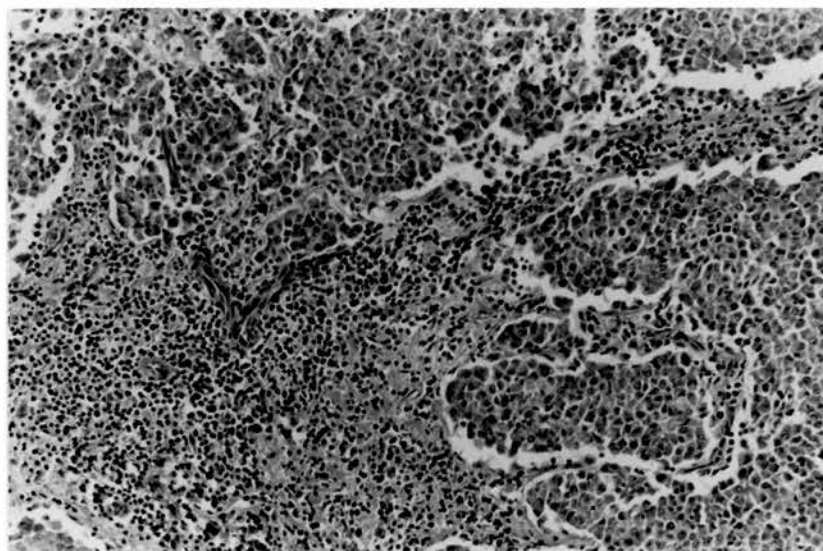


Fig. 118

Widespread invasion by tumour tissue.
H. & E. X 80.

The residual thyroid parenchyma showed three histopathological patterns. Firstly, there was a certain amount of established Askanazy change with associated round cell infiltration. (Fig. 119.)

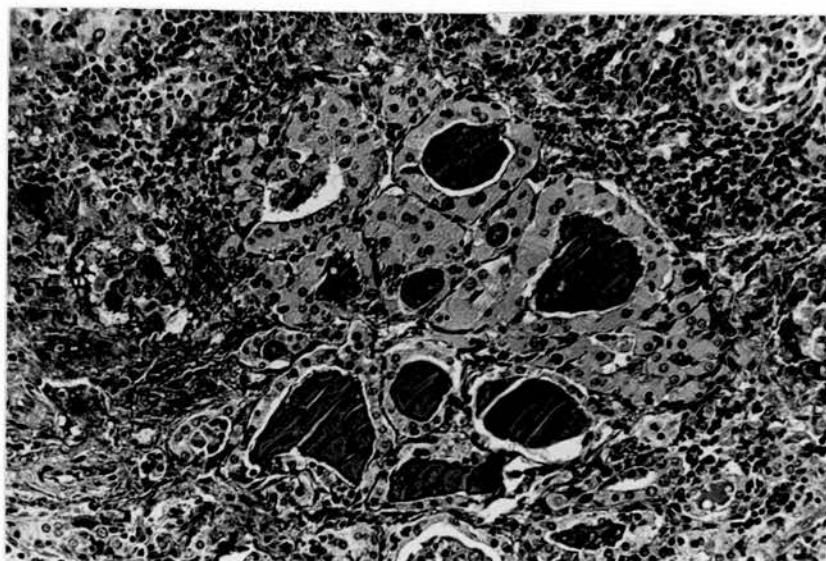


Fig. 119

View showing Askanazy change and round cell infiltration. H. & E. X 150.

Secondly, areas of considerable extent demonstrated the type of change previously described and illustrated in Part III, p. 153, Figs. 60 and 61, and shown here in Fig. 120.

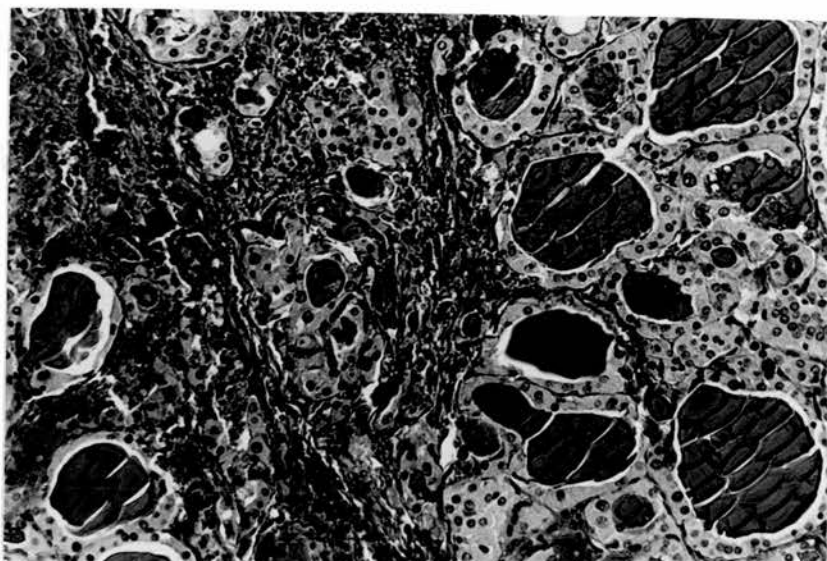


Fig. 120.

Field showing vesicular structure of "pre-Askanazy" type, with plentiful colloid and cuboidal epithelium. H. & E. X 150.

Finally, there was one small focus of hyperplastic tissue present (Fig. 121).

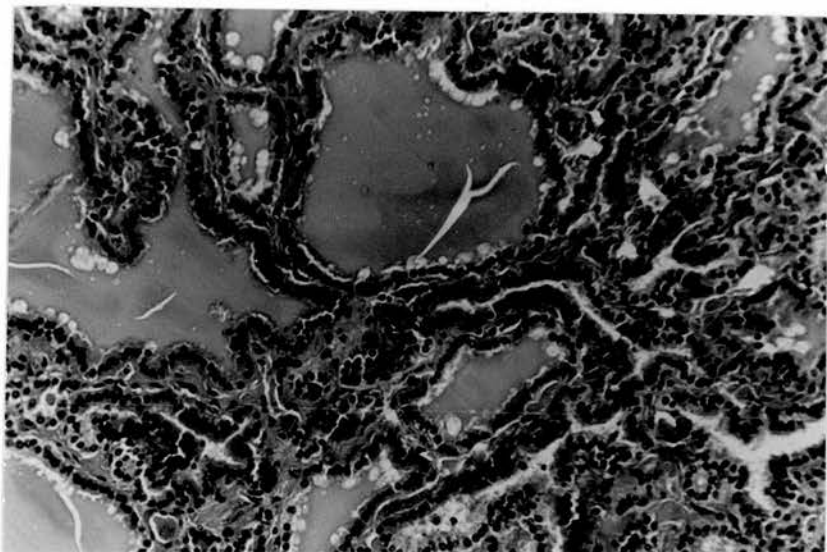


Fig. 121

Focus of hyperplasia. H. & E. X 150.

Case 4

Miss B. T. Age 54 years. Admitted R.I.E. -
3.7.56.

History of Present Illness. The patient was first seen on 3.7.56. She had been completely well until two months before that date when she became aware of an intermittent "chokiness" in her neck. Then, two weeks before presenting at hospital, she noticed a painless swelling of her thyroid which remained constant in size. She had no other symptoms.

Clinical Examination revealed a diffuse, firm, lobulated and mobile enlargement of the thyroid, the right lobe being slightly larger than the left. The trachea was central and no cervical glands were enlarged. Thyroid function was clinically normal and the remainder of the physical examination was negative.

An X-ray of the neck showed the soft tissue shadow of the thyroid, compressing the trachea and displacing it slightly to the left.

Laryngoscopy showed a normal larynx and cords. The tonsils were large, buried and infected.

Special Investigations

B.M.R.: -5%
¹³¹I Test: 0-8 hour fraction - 31.2%
 8-24 hour fraction - 14.5%
 24-48 hour fraction - 3.8%
 0-48 hour fraction - 49.5%
 T. Index - 4.3%

Clinical Diagnosis

Struma Lymphomatosa (confirmed by needle biopsy).

Progress

No treatment was given and the patient was seen at regular intervals. No change occurred in the symptomatology or physical examination and in December, 1956, repeat B.M.R. and ¹³¹I tests gave findings identical with those six months previously (B.M.R.: -4% and T. Index: 4.6). Electrophoresis of plasma proteins and liver function tests were first carried out in January, 1957, with the following results:-

/ Total

	<u>g. per</u> <u>100 ml.</u>	<u>% of</u> <u>Total</u>
Total Protein	5.7	-
Albumin	3.2	56
Alpha ₁ Globulin	0.3	6
Alpha ₂ "	0.5	9
Beta "	0.7	13
Gamma "	1.0	17

Colloidal Gold - 0
Thymol Turbidity - 2 units
Serum Cholesterol - 276 mg. per 100 ml.

The patient continued to attend regularly and no change took place in either her local or general condition. In June, 1957, electrophoresis, liver function tests and ¹³¹I studies were repeated, the results being as follows:-

	<u>g. per</u> <u>100 ml.</u>	<u>% of</u> <u>Total</u>
Total Protein	5.4	-
Albumin	2.8	52
Alpha ₁ Globulin	0.4	7
Alpha ₂ "	0.5	10
Beta "	0.7	13
Gamma "	1.0	19

Colloidal Gold - 0
Thymol Turbidity - 1 unit.

¹³¹I

	<u>Before</u> <u>T.S.H.</u>	<u>After</u> <u>T.S.H. (10</u> <u>U.S.P. units)</u>
0- 8 hour fraction	24.6%	17.9%
8-24 " "	9.9%	6.0%
24-48 " "	2.4%	1.7%
0-48 " "	36.9%	25.6%
T. Index	6.7	11.6
48 hour gland uptake	31.6%	13.6%
48 hour plasma P.B. ¹³¹ I	-	0.6% of the dose per litre.

On 15.8.57, she underwent tonsillectomy (the tonsils were not sent for pathological examination). Thereafter she did not feel well, with anorexia, increasing lassitude and loss of weight and when seen on 25.9.57, she complained for the first time of a swelling on the posterior aspect of the left shoulder.

/ She

She was re-admitted to hospital on 24.10.57.

Further questioning revealed that she had in fact been aware of this swelling one year previously, although it was very small at that time, and it had thereafter increased in size. Also, in the few days before admission, she had noticed further lumps in the right gluteal and supraclavicular regions. Examination revealed a hard mass, 6 x 7 cm., overlying the left scapula and fixed to skin and deep tissues. Further similar swellings were present in the right supraclavicular region and over the right posterior superior iliac spine. There was a firm, fixed enlarged gland in the right axilla. The thyroid was quite unchanged and showed the same diffuse, firm, smooth and mobile enlargement initially recorded when the patient was first seen 15 months previously. A full blood examination showed no abnormality. Chest X-ray revealed numerous tumour deposits in both lower lung fields. Open biopsy of the thyroid gland (at which the gross appearance was that of Struma Lymphomatosa) and of the supraclavicular mass was then carried out. Some palliative X-ray therapy was given thereafter, but her general condition steadily deteriorated and death occurred shortly after her discharge from hospital. There was no autopsy.

Histo-pathology

1. Thyroid

No evidence of malignancy could be discovered in the thyroid biopsy. The tissue was divided into islands by intersecting fibrous septa. Vesicular size was uniformly small and colloid reduced in amount. The lining epithelium was of cuboidal cells with clear, homogeneous cytoplasm, but no true Askanazy change was observed. There was a heavy attendant round cell infiltration, mostly of mature lymphocytes, and distributed in sheets and strands, but without true lymphoid follicle formation. (Fig. 122).

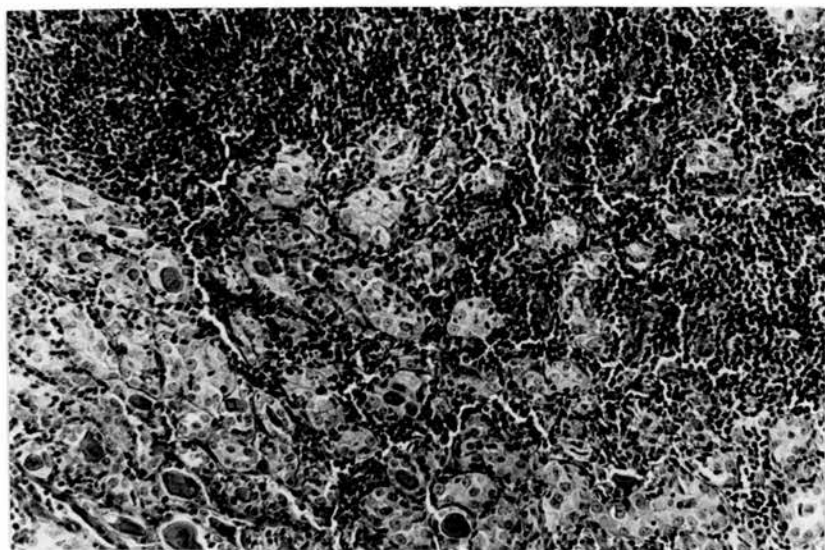


Fig. 122

Appearance of thyroid. H. & E. X 150.

2. Supraclavicular Mass

Sections from this tissue showed extensive invasion of fat by a highly cellular tumour having no particular arrangement. (Fig. 123).




Fig. 123

Highly cellular tumour invading fat.
H. & E. X 90.

The cells varied moderately in size, shape and nuclear configuration, while mitotic figures were fairly numerous. They were supported by an abundant, fine reticular framework. (Figs. 124 and 125).

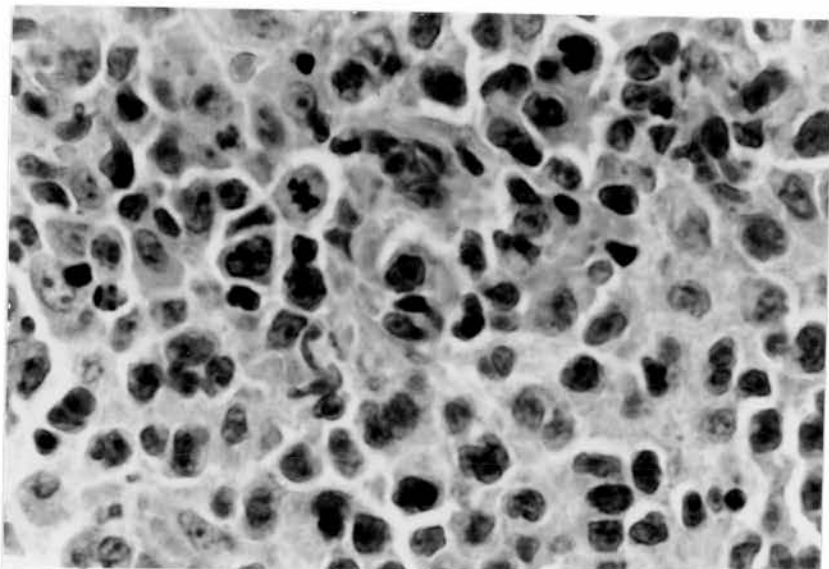


Fig. 124

Higher magnification of Fig. 123.
H. & E. X 700.

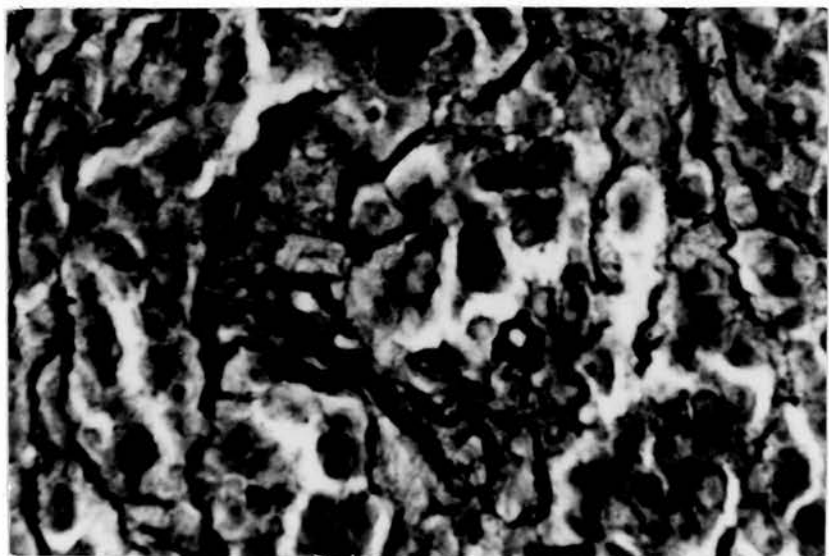


Fig. 125

Showing reticular network enclosing small groups of cells and also peri-cellular. Reticulum Stain X 700.

Case 5

Mr. W. B. Age 41 years. Admitted R.I.E. -
31.7.56.

History of Present Illness. He was completely well until December, 1955, at which time he became aware of a swelling in his neck which gradually increased in size over the next six months. He had slight difficulty in swallowing, but no difficulty with breathing except on exertion. He was aware of a tightening in his neck on raising his arms.

Clinical Examination showed a diffusely and markedly enlarged thyroid, extending retrosternally, and with considerable limitation of movement on swallowing. There were numerous distended veins on either side of the neck. There was a 2 cm. lymph node in the left supraclavicular region and a 1 cm. node in the right axilla. Examination of the chest revealed impairment of percussion note and poor air entry at the left base.

An X-ray of the neck showed the bulk of the thyroid swelling lying anterior to the trachea with only very slight antero-posterior compression of the latter, but marked displacement to the right. Chest films revealed that the mass extended down to the level of the hila and showed also some consolidation, with a small effusion, at the left costo-phrenic angle.

Laryngoscopy showed a normal larynx with the cords moving equally and freely.

Clinical Diagnosis. ? Struma Lymphomatosa:
? Carcinoma.

Operative Findings, Treatment and Progress

On 3.8.56 a test dose of 500 r of X-ray therapy was given to the thyroid and upper mediastinum. This resulted in a clinical and radiological decrease in gland size, with a difference of 2.5 cm., in neck measurement. Open biopsy of the thyroid was carried out on 9.8.56. The infra-hyoid muscles were slightly oedematous. The left lobe of the gland had a solid, firm consistence rather like tumour and was not easily separated from the overlying muscles, although the latter were not invaded in any way. As the biopsy was taken, the thyroid tissue appeared fibrous in nature and gritted under the knife. The right lobe had much more the appearance of Struma

/ Lymphomatosa,

Lymphomatosa, with again a similar hard, fibrous sensation on cutting into it. A number of small, soft lymph nodes were seen lying in relation to the isthmus, but they appeared simple in nature.

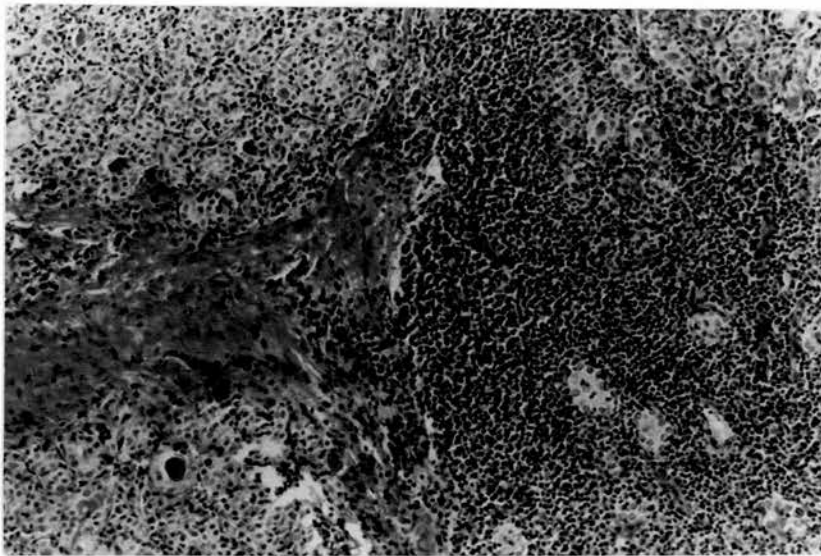
By 14.8.56, 11 days after the test dose of X-ray therapy and without further treatment of any kind, a considerable reduction in both the cervical and mediastinal masses had taken place. On the receipt of the pathologist's report that the thyroid showed the features of Struma Lymphomatosa and no malignancy was discoverable in it, the decision was taken to treat the condition by X-ray therapy and this the patient received during August and September, 1956, a total dose of 2,000 r. being delivered to the thyroid. This resulted in the complete disappearance of the cervical swelling and further reduction in size of the mediastinal shadow.

By 17.10.56, however, there was once again a large mediastinal mass and the patient had to be re-admitted to hospital on 14.11.56 because of increasing and very severe breathlessness. Examination showed him to be orthopnoeic. No thyroid enlargement could be detected in the neck and no glands were palpable. The neck veins were, however, distended and the hands blue and congested. The liver was enlarged 3 cm. below the costal margin and there was marked dullness at both lung bases with diminished air entry. Chest films showed a further increase in size of the mediastinal mass, with small effusions in the costo-phrenic angles and patchy atelectasis at both bases.

Further X-ray therapy, by chest baths, was given from 15.11.56 to 3.1.57 with improvement in his general condition and radiological evidence of shrinkage of the mediastinal mass. On 31.12.56, however, the patient complained of sore throat and difficulty in swallowing. Examination showed a huge mass, with a sloughing surface, in the right tonsillar region, a biopsy of which was taken on 3.1.57. From 4.1.57 to 18.1.57 X-ray therapy was continued by localised fields to the mediastinum and tonsillar mass, with complete disappearance of the latter. On 18.1.57 he was allowed home, but was sent back to hospital on 6.2.57 with a large, fixed mass in the right femoral triangle. At this time also there was diffuse induration over the upper part of the sternum. A further palliative dose of X-ray therapy was given to the right groin and death finally occurred on 22.2.57. There was no autopsy.

Histo-pathology1. Thyroid

No evidence of malignancy could be discovered in the thyroid biopsy. The gland was divided into lobules by thick fibrous tissue septa. Vesicular structure was uniformly small with diminished colloid content and a lining of cuboidal epithelium. No frank Askanazy change was present. There was a heavy round cell infiltration. This was present as sheets composed almost entirely of lymphocytes and also as strands of both lymphocytes and plasma cells. No true lymphoid follicles could be discerned. (Figs. 126 and 127).

Fig. 126

The gland is divided into lobules by thick fibrous septa. The round cell infiltration occurs diffusely and also as sheets, but no true lymphoid follicles are seen. H. & E. X 80.

2. Tonsillar Mass

This consisted of a highly cellular tumour, the cells
/ being

being characterised by large, round or oval, sharply defined nuclei with prominent nucleoli. (Fig. 128). Mitotic activity was marked. Special staining failed to reveal any supporting reticulum.

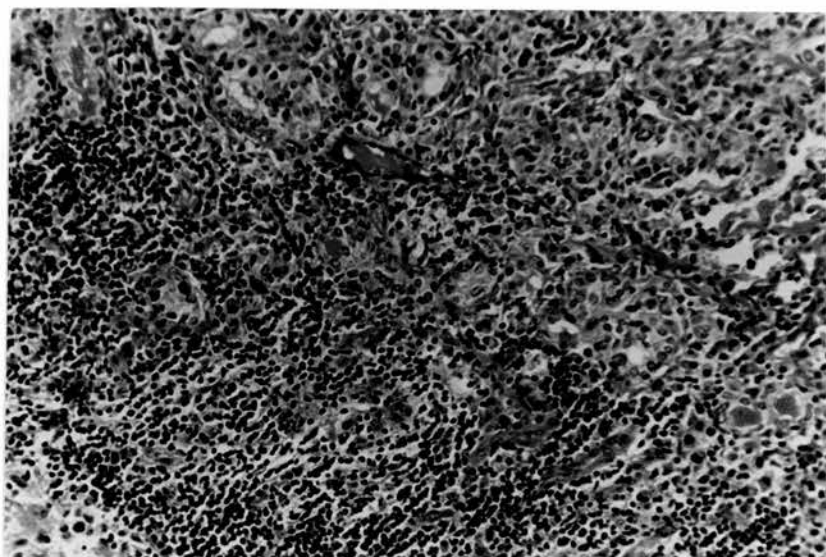


Fig. 127

Higher magnification of parenchyma: small vesicles, cuboidal epithelium and diminished colloid, but no Askanazy change. H. & E. X 150.

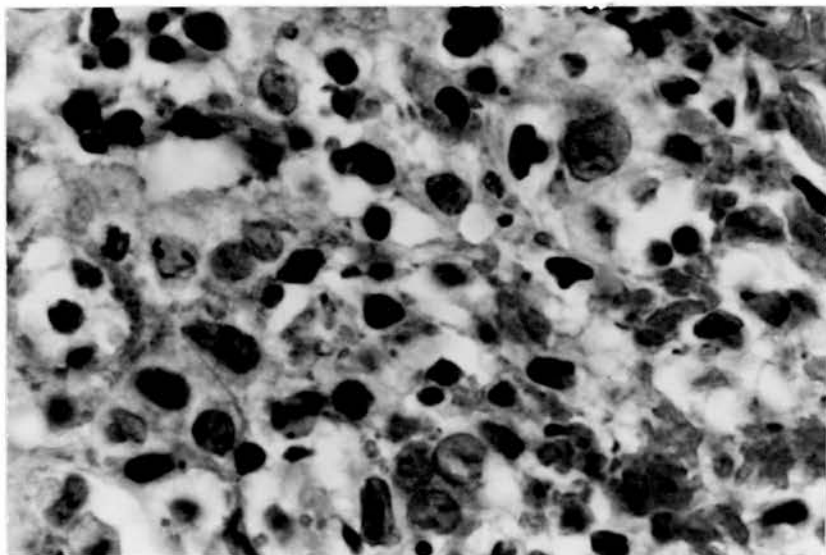


Fig. 128

Showing structure of tonsillar mass.
H. & E. X 800.

Case 6

(Reference to the follow-up of this case, included in the group reviewed in Part II, is made on p. 138).

Mrs. R. McD. Age 59 years. Admitted R.I.E. - 4.11.52.

History of Present Illness. She had had a thyroid enlargement for about 30 years, gradually increasing in size over that time, with some greater increase for a short period prior to admission. She had been treated with iodine many years previously. For two years she had suffered from severe headaches and been breathless. Over the six months prior to admission she had been very nervous, perspired easily and had hot flushes: she preferred cool weather to warm. She had, however, been gaining weight and was constipated.

Past History. An artificial menopause had been induced at the age of 44 years for menorrhagia.

Clinical Examination showed a diffusely enlarged, mobile thyroid. The trachea appeared central in position and there were no palpable cervical lymph nodes. No abnormality was detected in the abdomen and the remainder of the physical examination was negative.

An X-ray of the neck revealed enlargement of the thyroid anterior and mainly to the left of the trachea with, in addition, some retro-tracheal extension of the gland. The trachea was displaced to the right and narrowed in both diameters. There was no radiological evidence of retro-sternal extension or of calcification within the thyroid.

Clinical Diagnosis. Simple Goitre.

Treatment. In view of the possibility of certain "toxic" symptoms, iodine was given for a few days before operation, subtotal thyroidectomy being undertaken on 17.11.52. The gland was very markedly enlarged and very vascular. The immediate post-operative progress was marred by tetany: this was, however, satisfactorily controlled by calcium lactate and calciferol and there were no other untoward incidents.

/ Follow-up

Follow-up

The patient reported at regular intervals following operation and remained well for almost one year. Throughout this period none of the manifestations of hypothyroidism were observed and thyroid extract was not exhibited.

In October, 1953, however, she complained of a heavy feeling in the abdomen with anorexia and nausea, accompanied by extreme tiredness and weakness. Examination revealed an ill patient with hepatic and splenic enlargement, but no peripheral lymphadenopathy. The blood picture showed 18,000 white cells per c.m.m., of which 87% were lymphocytes: haemoglobin, 70%: platelets, 115,000 per c.m.m. She was re-admitted to hospital on 7.10.53. Sternal puncture was carried out on two occasions but no marrow was obtained. While in hospital and shortly before death, there were two episodes of pyrexia, severe sweating, anorexia and vomiting associated with marked abdominal tenderness and guarding. X-ray therapy was commenced on 14.10.53, but death occurred after only three treatments, on 17.10.53, being immediately preceded by severe vomiting and abdominal pain.

Pathology1. Thyroid(a) Gross Appearance

The tissue removed at operation consisted of the major portions of both lateral lobes. They possessed smooth, encapsulated, uncut surfaces and were grossly nodular throughout. The parenchyma was of pale, pinkish-brown colour and the vesicles were not within the range of naked-eye vision. Some portions showed stippling with ill-defined pale specks, resembling lymphoid follicles, while other portions were homogeneous. There was considerable increase in fibrous stroma and also patches of fibrosis at some sites. The tissue was poorly vascularised.

(b) Histo-pathology

No evidence of malignancy could be discovered in the thyroid. The parenchyma showed a homogeneous and striking Askanazy change with a light, diffuse, intervesicular round cell infiltration of lymphocytes and plasma cells. There were a considerable number of lymphoid follicles with germinal centres throughout the tissue, although not particularly numerous or closely aggregated. (Fig. 129).

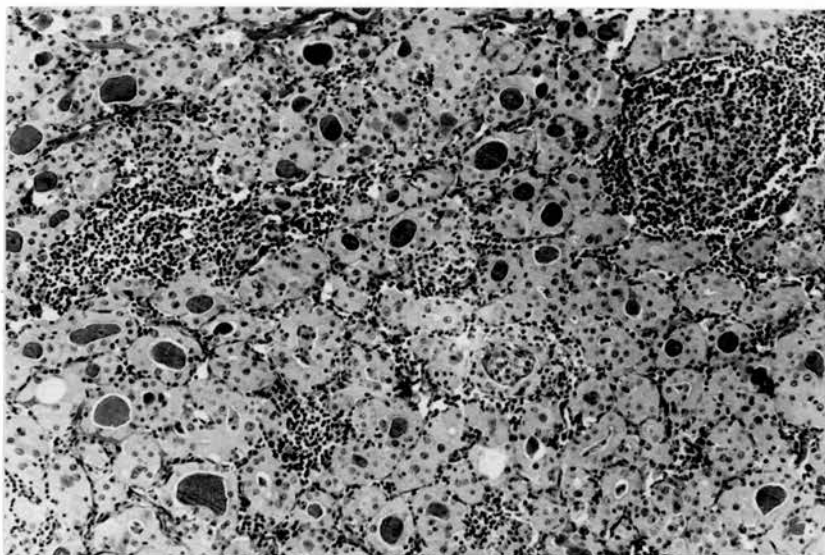


Fig. 129

Showing homogeneous Askanazy change, lymphoid follicle and round cell infiltration.
H. & E. X 90. (A higher magnification is shown in Fig. 6, p. 69.)

2. Autopsy Findings(a) Gross Appearance

The principal findings were as follows. The peritoneal cavity contained a quantity of turbid fluid and pus, with a small right subphrenic abscess. The coils of small intestine were matted together by fibrinous adhesions

with small beads of pus on the serous surface. Scattered over the whole of the small intestine, but especially in the jejunum, were small yellowish nodules under the serous surface. On opening the bowel, there was gross infiltration and thickening of the wall of both jejunum and ileum. The mesenteric lymph glands were enlarged, rubbery and, on section, yellowish-grey in colour. The liver, weighing 1,900 g., was pale in colour and firm in consistence. Section revealed obvious infiltration around the portal tracts. The spleen weighed 1,400 g., its capsule was thickened and it was extremely firm in consistence. On section, the lymphoid follicles stood out very clearly. The sternal, vertebral and femoral bone marrow was greyish-pink in colour with small areas of haemorrhage. The thyroid remains were firm and on section had a yellowish colour.

(b) Histo-pathology

(The sections and blocks from this case were no longer available for study and the following description is taken from the report of the original pathologist who performed the autopsy.)

- (i) The liver showed a marked degree of peri-portal infiltration. Many lymphocytes and a few lymphoblasts were seen diffusely infiltrating the portal tracts. The related vessels were full of these lymphocytes, which were also seen in abundance around the vessels.

- (ii) The lymphoid follicles of the spleen were prominent and here again large numbers of lymphocytes and lymphoblasts were seen. The sinusoids were filled with these cells.
- (iii) The renal glomeruli were congested and here again lymphocytes were present in large numbers. Sheets of lymphocytes were seen between the tubules and the vessels showed many lymphocytes within and surrounding their walls.
- (iv) A mesenteric lymph gland was packed with lymphocytes and lymphoblasts.
- (v) The thyroid showed small vesicles, the cells of which were hyperplastic. They contained small amounts of colloid. Infiltrating between the vesicles were lymphocytes in large numbers.
- (vi) The bone marrow examined was composed solely of fat.

Resumé of Cases

Cases 1-3

In Cases 1-3, all female and aged 58, 67 and 65 years respectively, a clinical diagnosis of malignant disease of the thyroid gland was made and subsequently substantiated by pathological examination. In Cases 1 and 2, the histopathological structure of the residual, non-involved parenchyma was uniformly that of Askanazy change and round cell infiltration, an appearance identical with and indistinguishable from that classically seen in Struma

/ Lymphomatosa.

Lymphomatosa. In Case 3, the histo-pathological appearances in the non-malignant portion of the gland were more varied, but overall showed a similar composition to the cases reviewed in Part III, Group 1, pp. 145-154.

In two of the cases, 1 and 3, there was a clinical suggestion of hypothyroidism.

Various authors have reported the co-existence of malignant disease and the changes of Struma Lymphomatosa in the same thyroid gland. Vaux (1937) recorded a reticulosarcoma of the thyroid, the remaining gland showing numerous large foci of lymphadenoid tissue. Dinsmore et al., (1949), reviewing eight cases of lymphosarcoma of the thyroid, had one instance in which the thyroid tissue presented an appearance compatible with Struma Lymphomatosa, in so far as this could be determined from the available remaining structure. Lindsay and Dailey (1955), in eight patients with malignant lymphoma of the thyroid, found the glands of seven to show also the characteristic appearances of Struma Lymphomatosa. Cureton et al., (1957) recorded two cases of reticulosarcoma of the thyroid which appeared to develop in glands affected by Struma Lymphomatosa. While in most of the reported cases the malignant process has been interpreted as sarcomatous in nature, Dailey et al., (1955) found 37 carcinomas in 302 glands which also displayed the features of Struma Lymphomatosa.

The difficulty in making a distinction between sarcoma and anaplastic carcinoma is well known, nowhere more so than

in the thyroid gland, and in the face of such difficulty the opinion of anything less than a qualified pathologist is valueless. Concerning the nature of the malignant process in the present three cases, therefore, while it was fairly easy to be certain that Case 3 showed widespread invasion by an anaplastic carcinoma, in Cases 1 and 2, in which the tumours showed a similar cytological structure, the interpretation was much more difficult and although the appearances were compatible with those described by other observers as sarcomatous, this point could not be determined with any certainty.

Cases 4-6

In Cases 4-6, two females and one male and aged 54, 41 and 59 years respectively, malignant disease of the thyroid was suspected clinically in only one, while in none did subsequent pathological examination disclose any evidence of malignancy in the gland. All three succumbed, however, and the nature and distribution of the advancing neoplastic process together with the cellular morphology of the subsequent deposits, strongly suggested a reticulotic or reticulosarcomatous pathology.

In Cases 4 and 5 the appearances in the thyroid were similar, the tissue being divided into islands consisting of small vesicles with diminished colloid content and cuboidal epithelial lining, but with no true Askanazy change. The attendant round cell infiltration showed no lymphoid follicle formation. In Case 6, however, the thyroid

/ appeared

appeared to show the classical picture of Struma Lymphomatosa.

In Case 4, repeated electrophoretic studies and liver function tests gave normal results.

Discussion

The foregoing cases would appear to illustrate two different problems.

In the first place and as exemplified by Cases 1-3, there seems little doubt that malignant disease, be it carcinoma or sarcoma, may be present in the thyroid and the non-involved portion of the gland show changes indistinguishable from those of Struma Lymphomatosa. Moreover, there is some reason to believe that this combination of appearances occurs more frequently than might otherwise appear from routine pathological reports and it would seem an interesting and possibly fruitful line of additional investigation to conduct a histo-pathological survey of a large series of malignant goitres with this point in mind. From the clinical standpoint this type of case would not appear to constitute a difficult problem, since, by virtue of its readily recognisable malignant characteristics, the diagnosis is usually clearly indicated and the conduct straight forward. It would seem important for the future, however, to apply these laboratory tests which are presently proving of diagnostic value in Struma Lymphomatosa to all malignant goitres, in order to see if any correlation emerge between the findings obtained and the histo-pathological appearances in the residual thyroid / parenchyma.

parenchyma.

The problem of whether some actual relationship exists between Struma Lymphomatosa and malignant disease of the thyroid remains as yet unsolved and opinion is somewhat divided on this point. Lindsay and Dailey (1955) and Dailey et al., (1955) have claimed a significant relationship between this condition and both malignant lymphoid and benign and malignant epithelial tumours of the thyroid. Kellett and Sutherland (1949) on the other hand, reporting five cases of primary reticulosarcoma of the thyroid in elderly women, concluded that, while such a neoplasm certainly arises from lymphoid tissue in the thyroid, it might do so in various conditions of the gland in which lymphoid hyperplasia was a feature and that Struma Lymphomatosa per se had not been identified with certainty as its precursor. Brewer and Orr (1953), in a review of undifferentiated thyroid tumours, found ten cases which appeared to correspond with the reticulosarcoma of other writers: six of these patients had died within one year but the remaining four had survived for considerable periods, yet the histo-pathological appearances seemed identical. They coined the term Struma Reticulosa for such cases and pointed out the unusually high incidence of involvement of the wall of the intestine, frequently without metastases elsewhere, in those which had come to autopsy. They raised the question of whether the process was genuinely neoplastic or possibly some unusual type of granulomatous condition and perhaps a variant of Struma

/ Lymphomatosa.

Lymphomatosa.

Cases 4-6 pose a more difficult and apparently somewhat different problem. To the clinician the diagnosis of malignant disease is by no means immediately apparent, the thyroid may retain the physical characteristics of simplicity throughout the course of the illness and the clinical conduct of the case is complicated. Case 4, in particular, illustrates the necessity for a searching and exhaustive physical examination, no matter how conclusively the local findings in the gland might suggest a diagnosis of Struma Lymphomatosa. Pathologically no evidence of malignancy is discoverable in major and representative biopsies from the thyroid, and while in Cases 4 and 5 the histo-pathological appearances lack the features of Askanazy change and lymphoid follicle formation, in seeking a pathological diagnosis there is no alternative to Struma Lymphomatosa. Notwithstanding, the subsequent clinical and pathological course is such as to suggest a reticulotic or reticulosarcomatous process. Patterson and Starkey (1948) recorded the case of a 30 year old woman with a diffuse swelling of the thyroid, difficulty in respiration and some pain of one month's duration. There was a marked symmetrical enlargement of the gland without fixation to the surrounding structures and the pre-operative diagnosis was diffuse non-toxic goitre. Subtotal thyroidectomy was performed and three different pathologists reported the tissue as showing the features of Struma Lymphomatosa. Within a few months the patient

/ died

died of generalised lymphosarcoma, known to involve the thyroid, neck, mediastinum and abdomen.

Whether the thyroid condition in these cases is an intrinsic part of the disease process, or an incidental finding or has an aetiological role (some malignant and presumably sarcomatous transformation having taken place), and whether the changes in the gland should in fact be labelled Struma Lymphomatosa, must remain for the present unsolved. From the implications involved, however, such cases must obviously merit the closest clinical, laboratory and pathological consideration in the future.

MAJOR CONCLUSIONSPART I

Three principal and separate conditions - Struma Lymphomatosa, Hashimoto's Disease or Lymphadenoid Goitre, Subacute or de Quervain's Thyroiditis and Riedel's Thyroiditis - are presently interpreted as constituting the disease complex, to which the essentially unsuitable title of Chronic Non-Specific Thyroiditis is applied. A historical survey reveals that many of the opinions concerning the subject have, with the passage of time, proved incorrect and the main impressions which emerge from such a survey are firstly, a failure of agreement concerning the identity, unity or inter-relationships of those disease processes, secondly, an ignorance of their fundamental nature and causation and thirdly, a lack of knowledge regarding the relationship of the subject as a whole to other forms of thyroid disease.

STRUMA LYMPHOMATOSAPART II

A majority of cases of this condition present a reasonably well defined clinico-pathological picture.

The histo-pathology of the thyroid gland is characterised by the uniform occurrence of a highly distinctive appearance of the thyroid parenchyma, known as the Askanazy change, which has lacked description and emphasis in the past and the significance of which has not yet been elucidated. Such change is associated with a

/ lymphoid

lymphoid follicular and diffuse inter-vesicular round cell infiltration. The overall process, however, is an evolving continuum of increasing degeneration, in which parenchymal structure is progressively lost and increasing degrees of connective tissue replacement make their appearance, so that the final pathological state of the gland in the untreated condition is almost certainly one of uniform fibrosis. Giant cell formation and squamous metaplasia of the vesicular epithelium are additional, though more rarely observed, features. These individual appearances are responsible for the remarkable intrinsic pleomorphism of the histo-pathological picture and this pleomorphism together with the failure to appreciate the frequently widespread occurrence of fibrosis, has been responsible for much difficulty and confusion in the earlier interpretation of many of the cases, resulting particularly in the erroneous inclusion of certain of these in the Riedel category.

These histo-pathological changes are associated with a characteristic and well recognised gross appearance of the gland, which shows a uniform, diffuse and anatomical type of enlargement, with a pronounced tendency to retro-tracheal extension of the lateral lobes and the formation of a "circular goitre". The gross appearance may, however, be influenced by the connective tissue content of the gland, resulting in varying and sometimes marked degrees of macroscopic fibrosis. True unilateral

/ involvement

involvement may occur, although rarely.

Clinically, the patient complains of a goitre of variable duration and certain, usually mild, pressure symptoms. The frequency of hoarseness and voice change, although not usually emphasised, is considerable and may be due to the well marked tendency of the gland to retro-tracheal extension or may possibly be an expression of the hypothyroid state of a proportion of these patients. Pain is not a feature of the disease. Concerning thyroid function, in cases of established Struma Lymphomatosa a searching clinical enquiry fails to reveal convincing evidence of remote, recent or present toxicity: a certain, although not accurately defined proportion of the cases, however, exhibit the features of hypothyroidism when they first present. In the physical examination the thyroid reflects its gross pathological characteristics: classically the gland is uniformly firm or rubbery, but its consistence may vary and in particular, it may be distinctly and unquestionably hard. Radiological examination confirms the frequently well marked posterior extension of the enlarged thyroid, resulting in an increase of the pre-vertebral soft tissue shadow. The purely clinical diagnosis of Struma Lymphomatosa is a matter of no small difficulty and it is frequently confused with other conditions, notably simple diffuse nodular goitre and malignant disease.

A considerable amount of diagnostic assistance in the

/ form

form of laboratory tests is now available to help confirm or refute a clinical suspicion of this condition - raised gamma globulin levels, abnormalities in the colloidal gold and thymol turbidity tests of liver function and positive serological reactions between the serum of patients and extracts of thyroid gland. While the full significance and diagnostic value of such findings awaits future interpretation, a limited experience has given a high percentage of positive results in classical Struma Lymphomatosa. Radioactive iodine (^{131}I) studies are, in general, of less diagnostic assistance, but confirm the state of thyroid function and appear to show that in Struma Lymphomatosa there is a small thyroïdal iodine pool with a high activity and rapid turnover, defective organic binding of iodine by the thyroid and, from the failure of thyrotrophic hormone to induce an increase in the uptake of ^{131}I by the gland, a failure at thyroid and not pituitary level.

The value and place of thyroid biopsy is difficult to assess in the present state of Struma Lymphomatosa. Once obligatory for the confirmation of the diagnosis, there is a current trend, arising principally from the availability of alternative diagnostic measures, either to dispense with it altogether or substitute the more restricted needle technique. While the necessity for pathological confirmation of the diagnosis may become less essential as laboratory methods become more firmly

/ established

established, it should continue for the present to constitute part of the diagnostic procedure and preferably by the open or formal method.

Surgical resection, for long the classical method of treatment of Struma Lymphomatosa, carries a small but definite risk, particularly as the result of misinterpretation of the gross findings at operation and the consequent infliction of a more radical procedure than is otherwise necessary or desirable. The response of the goitre of Struma Lymphomatosa to radiotherapy is variable, although generally slow and the subsequent exhibition of thyroid extract to patients so treated, may, in the light of more recent knowledge, have contributed to the final and complete resolution of the thyroid enlargement. Treatment by thyroid substitution, which induces a significant reduction in gland size and simultaneously corrects the associated hypothyroidism, offers a more rational therapeutic approach and is likely to supplant these earlier measures. The universal efficacy of such treatment awaits confirmation, however, and it may be premature to claim that surgery has no further part to play in the management of this disorder. It is hard to believe, in the light of histo-pathological findings, that the more fibrotic and degenerate examples of the disease can be altogether favourably influenced by such conservative measures and for these surgical ablation may still prove necessary.

The natural metabolic end-point of Struma Lymphomatosa is a state of hypothyroidism or frank myxoedema and in true examples of the disorder the incidence approaches 100 per cent.

PART III

In a minority of cases the appearances in the thyroid are much more variable. While exhibiting extensive areas of Askanazy change and round cell infiltration, such cases show a variable and sometimes equal admixture of alternative parenchymal appearances including foci of hyperplasia, colloid involution and an appearance which is interpreted as the precursor of the true Askanazy change. The problem of their diagnosis is insoluble on purely histo-pathological grounds and clinical findings may offer little further assistance in the individual case. It is to this particular group that laboratory aids to diagnosis would seem especially applicable in helping to solve the diagnostic category into which such cases should be placed. In this way and by means of a searching pathological, clinical and laboratory enquiry, the presently somewhat nebulous limits of Struma Lymphomatosa might be defined with greater accuracy.

Similar considerations apply to those cases in which, by virtue of extensive and sometimes almost complete connective tissue replacement, the total volume of the residual parenchyma is so restricted as to render impossible any assessment of the nature of the foregoing changes.

In such cases Askanazy change may be absent or no longer recognisable and squamous metaplasia much in evidence. Their clinical presentation is that of Struma Lymphomatosa, the only variations being in the excessively hard consistence and less extravagant degree of enlargement of the thyroid swelling.

In the present state of our knowledge, there is no definite proof of a direct aetiological relationship between thyrotoxicosis and Struma Lymphomatosa. From time to time, certain pathological and clinical evidence has been led in support of such a relationship, but the fact remains that in those cases exhibiting the established pathological picture of Struma Lymphomatosa clinical evidence of toxicity is sought in vain and conversely, when flagrant thyrotoxicosis is clinically manifest, complete identity of pathological appearance particularly in respect of the Askanazy change, is lacking.

The aetiology of Struma Lymphomatosa has been the subject of much discussion and speculation and still awaits a final solution, but the modern concept of an auto-immunisation seems likely to prove the most significant advance yet made in the understanding of this condition. Figures for the incidence of the disorder have varied considerably and almost certainly reflect the difficulties involved in the pathological interpretation and the differing diagnostic criteria applied thereto. A significant proportion of the cases occur in the male sex.

SUBACUTE THYROIDITISPART IV

Subacute or de Quervain's Thyroiditis, which has remained virtually unknown and unrecognised until the last decade, at present occupies an apparently isolated position in the spectrum of thyroid disease. It shows a peculiar geographical distribution which cannot be wholly or satisfactorily explained by differing degrees of clinical and pathological acumen in its recognition in different parts of the world. Although of unknown aetiology, it has, in its typical form, a characteristic clinical presentation and course and a distinctive pathological picture. It is a self-terminating disorder in which a variety of therapeutic measures have enjoyed success. In the past many cases have been erroneously reported as examples of Riedel's Thyroiditis.

RIEDEL'S THYROIDITISPART V

A historical survey reveals many inaccuracies in the interpretation of what is meant by this condition and shows that the accurate definition of a specific thyroid disease with uniform clinical course and pathological findings which might be so entitled has not been satisfactorily achieved. Struma Lymphomatosa, Subacute Thyroiditis and a variety of other conditions have been erroneously reported under this title and the principal causes of such misrepresentation have been ignorance of the existence of,

/ and

and unfamiliarity with the full clinico-pathological picture of these other conditions, together with much terminological confusion. Both Struma Lymphomatosa and Subacute Thyroiditis are capable of producing a densely hard, fibrotic thyroid enlargement, with well marked, albeit local, adhesion and fixation to surrounding structures. In the small residuum of cases which do not conform to the known facts concerning the better understood forms of Thyroiditis, the clinical and pathological features are frequently confusing and equivocal and for the future, effort must be directed towards a more accurate attempt to define the exact nature of such cases and so permit of a clearer picture of one or possibly more specific thyroid disorders.

PART VI

Concerning a possible relationship between Thyroiditis and malignant disease, only Struma Lymphomatosa merits serious consideration. While such a relationship can in no way be regarded as proven, a considerable number of cases have now been reported in which the co-existence of malignant disease, usually interpreted as sarcomatous in nature, and the changes of Struma Lymphomatosa have been noted in the same thyroid gland. Three such cases are here described and illustrated and there is some reason to believe that this combination may occur more frequently than is commonly supposed. In other patients succumbing finally to a generalised reticulotic or reticulosarcomatous process, the clinical and pathological findings in the

/ co-existent

co-existent and presenting thyroid enlargement appear to show the features of classical or atypical Struma Lymphomatosa without evidence of malignancy. The problem is a difficult one. While the course of Struma Lymphomatosa is manifestly benign, as testified by the uneventful follow-up of the vast majority of cases, the question of a malignant transformation cannot be altogether ignored and deserves closer consideration in the future.

REFERENCES

- Allen, A.L., and Reeves, R.J. (1951). W. Va. med. J., 47, 258.
- Anderson, J.R., Goudie, R.B., Gray, K.G., and Timbury, G.C. (1957). Lancet, 1, 1123.
- Benson, B.B. (1935). Amer. J. Surg., 27, 361.
- Berry, J. (1901). "Diseases of the Thyroid Gland", p. 137. Churchill: London.
- Berry, J. (1921). Brit. J. Surg., 8, 413.
- Bohan, P.T. (1924). Med. Clin. N. Amer., 7, 1069.
- Bothe, F.A. (1931). Surg. Clin. N. Amer., 11, 1445.
- Bowlby, A.A. (1884). Lancet, 2, 1001.
- Boyden, A.M., Collier, F.A., and Bugher, J.C. (1935). West. J. Surg., 43, 547.
- Brayton, D.F. (1948). West. J. Surg., 56, 417.
- Brenner, O. (1928). Quart. J. Med., 22, 121.
- Brewer, D.B., and Orr, J.W. (1953). J. Path. Bact., 65, 193.
- Bruce, H.A. (1931). Ann. Surg., 94, 562.
- Cameron, J.A.M. (1938). Trans. med.-chir. Soc. Glasg., 32-33, 99.
- Cantwell, R.C. (1948). Ann. Intern. Med., 29, 730.
- Chesky, V.E., Dreese, W.C., and Hellwig, C.A. (1951). Surg. Gynec. Obstet., 93, 575.
- Clark, D.E., Nelsen, T.S., and Raiman, R.J. (1953). J. Amer. med. Ass., 151, 551.
- Clute, H.M., and Lahey, F.H. (1932). Ann. Surg., 95, 493.
- Cooke, R.T., and Wilder, E. (1954). Lancet, 1, 984.
- Cooke, R.T., and Luxton, R.W. (1955). Lancet, 1, 968.
- de Courcy, J.L. (1942). Surgery, 12, 754.
- de Courcy, J.L. (1943). J. Amer. med. Ass., 123, 397.

- Crile, G., Jr. (1948). Ann. Surg., 127, 640.
- Crile, G., Jr. (1948). Arch. Surg., 57, 443.
- Crile, G., Jr., and Rumsey, E.W. (1950). J. Amer. med. Ass., 142, 458.
- Crile, G., Jr., and Hazard, J.B. (1951). J. Clin. Endocrinol., 11, 1123.
- Crile, G., Jr. (1952). Ann. intern. Med., 37, 519.
- Crile, G., Jr., and Schneider, R.W. (1952). Cleveland Clin. Quart., 19, 219.
- Crile, G., Jr., and Fisher, E.R. (1953). Cancer, 6, 57.
- Crotti, A. (1938). "Diseases of the Thyroid, Parathyroids and Thymus". 3rd Edn., p. 334. Kimpton: London.
- Cureton, R.J.R., Harland, D.H.C., Hosford, J., and Pike, C. (1957). Brit. J. Surg., 44, 561.
- Dailey, M.E., Lindsay, S., and Skahen, R. (1955). Arch. Surg., 70, 291.
- Dempsey, W.S., Dinsmore, R.S., and Hazard, J.B. (1949). Cleveland Clin. Quart., 16, 132.
- Dinsmore, R.S., Dempsey, W.S., and Hazard, J.B., (1949). J. Clin. Endocrinol., 9, 1043.
- Doniach, D., and Hudson, R.V. (1957). Brit. med. J., 1, 672.
- Dunhill, T.P. (1937). Trans. med. Soc. Lond., 60, 234.
- Eason, J. (1928). Trans. med. Chir. Soc. Edinb., 42, 169.
- Eden, K.C., and Trotter, W.R. (1942). Brit. J. Surg., 29, 320.
- Eisen, D. (1936). Amer. J. med. Sci., 192, 673.
- Ewing, J. (1922). "Neoplastic Diseases". Saunders: Philadelphia.
- Fraser, R., and Harrison, R.J. (1952). Lancet, 1, 382.
- Fraser, R., Hobson, Q.J.G., Arnott, D.G., and Emery, E.W. (1953). Quart. J. Med., 22, 99.
- Fromm, G.A., Lascano, E.F., Bur, G.E., and Escalanti, D. (1953). Rev. Asoc. med. argent., 67, 162.

- Furr, W.E., and Crile, G., Jr. (1954).
J. Clin. Endocrinol., 14(1), 79.
- Gilchrist, R.K. (1935). Arch. Surg., 31, 429.
- Goetsch, E. (1940). Arch. Surg., 41, 308.
- Goodman, H.I. (1941). Amer. J. Surg., 54, 472.
- Graham, A. (1931). West. J. Surg., 39, 681.
- Graham, A., and McCullagh, E.P. (1931). Arch. Surg.,
22, 548.
- Greene, R. (1950). J. Endocrin., 7, 1.
- Greene, R. (1953). Mem. Soc. Endocrin., 1, 16.
- Gribetz, D., Talbot, N.B., and Crawford, J.D. (1954).
New Engl. J. Med., 250, 555.
- Gürkan, K.I. (1945). Arch. Surg., 50, 125.
- Hamilton, H.E., Kirkendall, W.M., and Barker, S.B. (1950).
J. Clin. Invest., 29, 819.
- Harland, W.A., and Frantz, V.K. (1956).
J. Clin. Endocrinol., 16(2), 1433.
- Harry, N.M. (1940). Med. J. Aust., 2, 595.
- Harvil, T.H., (1948). Amer. J. Med., 5, 318.
- Hashimoto, H. (1912). Arch. klin. Chir., 97, 219.
- Hellwig, C.A. (1938). Arch. Path., 25, 838.
- Heptinstall, R.H., and Eastcott, H.H.G. (1954).
Brit. J. Surg., 41, 471.
- Heyd, C.J. (1929). Surg. Clin. N. Amer., 2, 493.
- Izak, G., and Stein, Y. (1956). Lancet, 1, 225.
- Joll, C.A. (1939). Brit. J. Surg., 27, 351.
- Joyce, T.M., Menne, F.R., and Zeller, W.E. (1941).
Arch. Surg., 42, 338.
- Kahn, J., Spritzler, R.J., and Shector, W.E. (1953).
Ann. Intern. Med., 39, 1129.
- Kellett, H.S., and Sutherland, T.W. (1949). J. Path. Bact.,
61, 233.

- Kent, G.B. (1929). Colo. Med., 26, 132.
- King, B.T., and Rosellini, L.J. (1945). J. Amer. med. Ass., 129, 267.
- Lake, W.F., and Ayers, A.J. (1936). Sth. med. J., 29, 665.
- Lasser, R.P., and Grayzel, D.M. (1949). Amer. J. Med. Sci., 217, 518.
- Lasser, R.P. (1953). J. Amer. med. Ass., 152, 1133.
- Lee, J.G. (1935). Arch. Surg., 31, 982.
- Lennox, B. (1948). J. Path. Bact., 60, 295.
- Lester, C.W. (1934). Amer. J. Cancer., 21, 103.
- Levitt, T. (1954). "The Thyroid". Livingstone: Edinburgh.
- Lindsay, S., Dailey, M.E., Friedlander, J., Yee, G., and Soley, M.H. (1952). J. Clin. Endocrinol., 12, 1578.
- Lindsay, S., and Dailey, M.E. (1954). Surg. Gynec. Obstet., 98, 197.
- Lindsay, S., and Dailey, M.E. (1955). J. Clin. Endocrinol., 15(2), 1332.
- Luxton, R.W., and Cooke, R.T. (1956). Lancet, 2, 105.
- Luxton, R.W. (1957). Lancet, 1, 441.
- McCarrison, R. (1927). Indian J. med. Res., 15, 247 and 909.
- McCarrison, R. (1929). Brit. med. J., 1, 5.
- McClintock, J.C., and Wright, A.W. (1937). Ann. Surg. 106, 11.
- McGonahey, W.M., and Keating, F.R. (1951). J. Clin. Endocrinol., 11, 1116.
- McKnight, R.B. (1936). Sth. Surg., 5, 375.
- McSwain, B., and Moore, S.W. (1943). Surg. Gynec. Obstet., 76, 562.
- Maloney, J.J. (1930). J. Med., Cincinnati, 10, 586.
- Marshall, S.F., Meissner, W.A., and Smith, D.C. (1948). New Engl. J. Med., 238, 758.

- Matthews, A.A. (1927). Med. Sent., 35, 148.
- Means, J.H. (1948). "The Thyroid and its Diseases".
2nd Edn., p. 480. Cope: Philadelphia.
- Meeker, L.H. (1925). Amer. J. Path., 1, 57.
- Merrington, W.R. (1948). Brit. J. Surg., 35, 423.
- Moldover, A. (1956). Arch. Intern. Med., 98, 322.
- Morgans, M.E., and Trotter, W.R. (1957). Lancet, 1, 553.
- Murray, G.R., and Southam, F.A. (1912). Lancet, 1, 1188.
- Nicholson, D. (1921). Canad. med. Ass. J., 11, 742.
- Oldfield, M.C. (1948). Brit. J. Surg., 35, 325.
- Osmond, J.D., Jr., and Portmann, U.V. (1949).
Amer. J. Roentgenol., 61, 826.
- Owen, C.A., and McConahey, W.M. (1956).
J. Clin. Endocrinol., 16(2), 1570.
- Paraley, C.C., and Hellwig, C.A. (1946). Arch. Surg.,
53, 190.
- Patterson, H., and Starkey, G. (1948). Ann. Surg., 128,
756.
- Folowe, D. (1934). Arch. Surg., 29, 768.
- de Quervain, F., and Giordanengo, G. (1936).
Mitt. Grenzgeb. Med. Chir., 44, 538.
- Renton, J.M., Charteris, A.A., and Heggie, J.F. (1938).
Brit. J. Surg., 26, 54.
- Reveno, W.S., and Rosenbaum, H. (1951). New Engl. J. Med.,
245, 364.
- Riedel, B.M.C.L. (1896). Verh. dtsh. Ges. Chir.,
25(1), 101.
- Riedel, B.M.C.L. (1897). Verh. dtsh. Ges. Chir.,
26, 127.
- Riedel, B.M.C.L. (1910). Munch. med. Wschr., 57, 1946.
- Robbins, J., Rall, J.E., Trunnell, J.B., and Rawson, R.W.
(1951). J. Clin. Endocrinol., 11, 1106.
- Roitt, I.M., Doniach, D., Campbell, P.N., and Hudson, R.V.
(1956). Lancet, 2, 820.

- Rose, N.R., and Witebsky, E. (1956). J. Immunol., 76, 417.
- Rundle, F.F. (1951). "Joll's Diseases of the Thyroid Gland". 2nd Edn. Heinemann: London.
- Rushton, J.G., Cragg, R.W., and Stalker, L.K. (1940). Arch. Intern. Med., 66, 531.
- St. George, A.V. (1924). Ann. Surg., 80, 25.
- Saphir, O., and Binswanger, H.F. (1930). J. Amer. med. Ass., 95, 1007.
- Schilling, J.A. (1945). Surg. Gynec. Obstet., 81, 533.
- Schultz, O.T. (1926). Trans. Chicago path. Soc., 12, 313.
- Semple, R.H. (1869). Trans. path. Soc. Lond., 2, 397.
- Shaw, A.F.B., and Smith, R.P. (1925). Brit. J. Surg., 13, 93.
- Sholl, P.R., and Black, B.M. (1954). Proc. Mayo Clin., 29, 259.
- Skillern, P.G., Crile, G., Jr., McCullagh, E.P., Hazard, J.B., Lewis, L.A., and Brown, H. (1956). J. Clin. Endocrinol., 16, 35.
- Skillern, P.G., Nelson, H.E., and Crile, G., Jr., (1956). J. Clin. Endocrinol., 16, 1422.
- Skirpan, P., Reich, A., and Crile, G. Jr., (1955). Amer. J. clin. Path., 25(2), 1274.
- Smith, L.W., and Clute, H.M. (1926). Amer. J. med. Sci., 172, 403.
- Sommers, S.C., and Meissner, W.A. (1954). Amer. J. clin. Path., 24, 434.
- Statland, H., Wasserman, M.M., and Vickery, A.L. (1951). Arch. Intern. Med., 88, 659.
- Stemmermann, G.N. (1956). J. Amer. med. Ass., 162, 31.
- Taylor, S. (1955). British Surgical Practice (Surgical Progress), p. 148. Butterworth & Co.: London.
- Teitelman, S.L., and Rosenberg, E.F. (1953). Ann. Intern. Med., 38, 1062.
- Thomas, W.S., and Webb, C.W. (1923). Clifton med. Bull., 2, 1.

- Tucker, W.J., and Gertz, M.A. (1927). Wis. med. J.,
26, 309.
- Vaux, D.M. (1937). J. Path. Bact., 44, 463.
- Vaux, D.M. (1938). J. Path. Bact., 46, 441.
- Warthin, A.S. (1926). Ann. clin. Med., 4, 686.
- Weller, G.L. (1936). Arch. Intern. Med., 57, 275.
- Wells, H.G. (1930). Arch. Path., 10, 499.
- Werner, S.C., Quimby, E.H., and Schmidt, C. (1949).
J. Clin. Endocrinol., 9, 342.
- White, C.S. (1932). Sth. Med. Surg., 94, 428.
- Whitesell, F.B., and Black, B.M. (1949).
J. Clin. Endocrinol., 9, 1202.
- Williamson, G.S., and Pearse, I.H. (1925). J. Path. Bact.,
28, 361.
- Williamson, G.S., and Pearse, I.H. (1929). Brit. med. J.,
1, 4.
- Wingate, H.F. (1929). Brit. J. Surg., 17, 264.
- Witebsky, E., and Rose, N.R. (1956). J. Immunol., 76, 408.
- Wright, A.W. (1950). N.Y. St. J. Med., 50, 2802.
- Zelle, O.L., Vass, A., and Steer, A.E. (1939).
Amer. J. Surg., 44, 453.