

**Towards a Comprehensive Resource for Elucidating the  
Pathogenesis of Inherited Keratodermas**

**Dr Mozheh Zamiri BSc (Hons), MB ChB, MRCP**

**Doctorate of Medicine  
University of Edinburgh  
2009**

Alan Lyell Centre for Dermatology, Glasgow  
&  
Section of Dermatology, University of Glasgow

## **ABSTRACT**

Keratoderma – pathological hyperkeratosis of palms and soles - is a cause of disability in many clinical situations, including the rare and heterogeneous group of inherited palmoplantar keratodermas (PPKs). The aim of this study was to work towards better understanding of molecular mechanisms active in the pathogenesis of PPK by the creation of a cell and tissue culture resource and its initial application to laboratory studies. My study was based on a diverse group of autosomal dominant disorders, previously ascertained in families from Scotland, in whom the precise genetic aetiology was known. I established a tissue and cell culture resource of inherited keratodermas of known single-gene aetiology from patients with proven keratin 1, 9, 17, loricrin and mitochondrial mutations. An additional pedigree with striate keratoderma with an unknown mutation was recruited, and the causative mutation identified as a novel heterozygous A-to-T transversion in exon 5 (c.430A>T) of the desmoglein 1 gene, converting an arginine residue to a premature termination codon (p.Arg144stop). The keratinocyte culture resource was established from patients with keratin 1, 9, 17 and loricrin mutations, as well as controls. Due to the pain associated with direct infiltration of plantar skin, biopsies were obtained using peripheral nerve block for plantar biopsy. The effectiveness of this approach, which may be useful for future administration of treatment, was made the subject of an open clinical trial. Histological and immunocytochemical studies were carried out on affected plantar skin obtained from PPK patients and compared to control tissue, in an attempt to identify common and distinct pathways resulting in hyperkeratosis. Histological changes, e.g. hypergranulosis, extent of hyperkeratosis, acanthosis or acantholysis, were not uniform across different subtypes of inherited PPK and varied

even between individuals within subtypes. Prominent eosin staining of spinous cells was a common feature in inherited PPK due to underlying K1 and K17 mutations. Electron microscopy showed abnormal keratin filaments in PPK with underlying keratin mutations only but was not a uniform finding within subtypes, and other electron microscopic features also varied between individuals. Immunocytochemical study did not demonstrate significant differences in expression of a selection of markers of differentiation (keratins 1, 9, 14 and 17), and cornified envelope protein filaggrin. Abnormal involucrin expression was observed, with premature expression in basal and lower spinous layers in all PPK subtypes raising the possibility of a common underlying mechanism in the development of hyperkeratosis. Prominent loricrin staining was noted in areas of acantholysis in K1 and K9 subtypes, but was uniform across other subtypes. Markers of proliferation and apoptosis demonstrated no overt change in epidermal turnover, although it is possible that only small changes in proliferative index are required to produce plantar hyperkeratosis. Overall, using morphological criteria, plantar hyperkeratosis was not readily distinguishable between inherited PPK of different underlying genetic causes. This raises the possibility that many of the reported structural features of inherited PPK are secondary phenomena as opposed to critical steps in the pathogenesis of hyperkeratosis. Initial attempts at RNA extraction using laser and manual microdissection have to date been unsuccessful in generating RNA of the quality and concentration to run a pilot microarray experiment, using standard RNA extraction kits. Plans for future projects include the further development of a possible microarray experiment in the Pachyonychia Congenita type 2 pedigree with the McLean laboratory in Dundee. The tissue resource has been made available for

collaborative study via the GENESKIN project, as well as through the McLean and Lane laboratories, Dundee for both functional studies and immortalisation of cell lines.

## **DECLARATION**

I declare that the thesis has been composed by myself, that with the exception of technical assistance in routine processing of biopsies for light and electron microscopy, and some aspects of RNA extraction, the work is my own, and that the work has not been submitted for any other degree or qualification.

Dr Mozheh Zamiri

25<sup>th</sup> March 2009

## **INDEX**

	<b>Page</b>
<b>Abstract</b>	<b>1</b>
<b>Declaration</b>	<b>4</b>
<b>Index</b>	<b>5</b>
<b>List of Figures</b>	<b>8</b>
<b>List of Tables</b>	<b>11</b>
<b>Acknowledgements</b>	<b>13</b>
<b>AIMS AND APPROACH TO STUDY</b>	<b>14</b>
<b>SECTION 1. LITERATURE REVIEW</b>	
<b>Chapter 1. The Palmoplantar Keratodermas</b>	<b>16</b>
1.1 Introduction	16
1.2 Overview of Epidermal Differentiation	17
1.3 Keratin intermediate filaments	21
1.4 Functions of keratins	23
1.5 Keratin expression in epidermis and epidermal appendages	26
1.6 Desmosomes	29
1.7 Connexins and gap junctions	31
1.8 Connexins and proliferation, differentiation and growth control	35
1.9 Palmoplantar Skin	36
1.10 Wound healing	37
1.11 Classification of Inherited PPK	39
1.12 Genotype/Phenotype Correlation	40
1.13 Keratins and Skin Disorders	45
1.14 Inherited PPK and keratins	46
1.15 Inherited PPK and desmosomes	50
1.16 Inherited PPK due to altered terminal differentiation: loricrin	52
1.17 Inherited PPK due to altered differentiation: connexins	53
1.18 Other PPKs	55
1.19 Conclusion	58
<b>SECTION 2. THE DEVELOPMENT OF A RESOURCE</b>	
<b>Chapter 2.1. Clinical Characterisation of PPKs with Known Mutations</b>	<b>59</b>
2.1.1 Introduction	59
2.1.2 Methods	59
2.1.3 Results	61

2.1.4 Discussion	70
2.1.5 Conclusion: Clinical issues	87
<b>Chapter 2.2. The Collection of the Resource</b>	<b>89</b>
2.2.1 Introduction	89
2.2.2 Methods	89
2.2.3 Results	91
2.2.4 Conclusion	92
<b>Chapter 2.3. Investigation of a Pedigree with Inherited Striate PPK</b>	<b>94</b>
2.3.1 Introduction	94
2.3.2 Methods	94
2.3.3 Results	104
2.3.4 Discussion	109
2.3.5 Conclusion	122
<b>SECTION 3. APPLICATION OF THE RESOURCE</b>	<b>123</b>
<b>Chapter 3.1. Morphological Analysis</b>	<b>123</b>
3.1.1 Introduction	123
3.1.2 Materials and Methods	123
3.1.3 Results	128
3.1.4 Discussion	140
3.1.5 Conclusion	146
<b>Chapter 3.2. Immunocytochemistry</b>	<b>148</b>
3.2.1 Introduction	148
3.2.2 Materials and Methods	148
3.2.3 Results	152
3.2.4 Discussion	166
3.2.5 Conclusion	187
<b>Chapter 3.3. Towards A Pilot Microarray Experiment</b>	<b>189</b>
3.3.1 Introduction	189
3.3.2 Methods	190
3.3.3 Results	192
3.3.4 Discussion	193
3.3.5 Conclusion and Future Prospects	195
<b>SECTION 4. FINAL DISCUSSION AND CONCLUSION</b>	<b>197</b>
4.1 Candidate mechanisms of hyperkeratosis in inherited PPK	197
4.2 Future Prospects: Therapeutic siRNA	203

4.3 Summary and Conclusion	205
<b>SECTION 5. BIBLIOGRAPHY</b>	<b>207</b>
<b>SECTION 6. APPENDIX A</b>	<b>257</b>
• The Use of Posterior Tibial Nerve Block as a Surgical Tool	257
<b>SECTION 7. ADDENDA</b>	<b>272</b>
• A: Patient Information Leaflet	272
• B: Patient Questionnaire	274
• C: Zamiri M., McLean W.H.I., Hodgins M.B. & Munro C.S. (2008). Pachyonychia congenita type 2: abnormal dentition extending into adulthood. <i>Br J Dermatol.</i> <u>159(2)</u> , 501.	277



## **LIST OF FIGURES**

	<b>Page</b>
Figure 1. Schematic representation of the palmoplantar epidermis.	<b>18</b>
Figure 2. Schematic diagram of basic intermediate filament structure.	<b>24</b>
Figure 3. Summary of major consensus patterns of keratin expression in epidermis and epidermal appendages.	<b>28</b>
Figure 4. Structural organisation of desmosomes and hemidesmosomes.	<b>30</b>
Figure 5. Schematic representation of connexins and gap junction channels.	<b>33</b>
Figure 6. Plantar keratoderma in inherited PPK due to underlying keratin 1, 9 and 17, DSG1, loricrin and mitochondrial mutations.	<b>64</b>
Figure 7. Clinical photographs of loricrin keratoderma, showing evidence of honeycomb pattern of palmar hyperkeratosis, pseudo-ainhum, hyperlinearity and erythema of the wrist.	<b>65</b>
Figure 8. Clinical photographs of pachyonychia congenita type 2 demonstrating onychodystrophy, pili torti and cysts.	<b>66</b>
Figure 9. Striate/focal palmar hyperkeratosis in underlying DSG1 mutation compared to diffuse hyperkeratosis in underlying K9 mutation.	<b>67</b>
Figure 10. Grossly thickened stratum corneum in plantar biopsy from inherited PPK patient.	<b>93</b>
Figure 11. Family with striate palmoplantar keratoderma (SPPK).	<b>95</b>
Figure 12. Pedigree of the family with SPPK.	<b>96</b>
Figure 13. DNA sequencing of the DSG1 gene.	<b>106</b>
Figure 14. Morphologic changes occurring in Haematoxylin and Eosin (H&E) stained affected plantar skin in proband.	<b>107</b>
Figure 15. Light microscopic changes occurring in 1% aqueous toluidine blue stained semithin sections of affected plantar skin in proband.	<b>107</b>
Figure 16. Electron micrographs of affected plantar skin in proband.	<b>108</b>
Figure 17. DSG1 staining of affected plantar skin in proband.	<b>108</b>

Figure 18. Predicted gene and protein details of human desmoglein 1.	<b>111</b>
Figure 19. Protein domain organisation of desmoglein 1 showing mutation sites.	<b>113</b>
Figure 20. Desmosomal cadherin expression patterns in epidermis.	<b>119</b>
Figure 21. Morphologic changes occurring in Haematoxylin and Eosin (H&E) stained affected plantar skin in PPK patients with underlying keratin 1, 17, 9, loricrin and mitochondrial mutations compared to normal unrelated plantar control.	<b>132</b>
Figure 22. Haematoxylin and Eosin (H&E) stained affected plantar skin in PC-2 patient with underlying K17 mutation showing prominent eosin staining in spinous layer.	<b>134</b>
Figure 23. Light microscopic changes occurring in 1% aqueous toluidine blue stained semithin sections of affected plantar skin, in PPK patients with underlying loricrin, mitochondrial, keratin 1, 9, and 17 mutations compared to normal unrelated plantar control.	<b>135</b>
Figure 24. Electron micrographs of affected plantar skin in PPK patients with underlying keratin 1, 9, 17, loricrin and mitochondrial mutations compared to normal unrelated plantar control.	<b>138</b>
Figure 25. Electron micrographs of affected plantar skin in PPK patients with underlying K9 and K17 mutations.	<b>139</b>
Figure 26. Cytokeratin 1 staining in affected plantar skin of inherited PPK patients with underlying keratin 1, 9, 17, loricrin and mitochondrial mutations compared to normal plantar control.	<b>156</b>
Figure 27. Cytokeratin 9 staining in affected plantar skin of inherited PPK patients with underlying keratin 1, 9, 17, loricrin mutations compared to normal plantar control.	<b>157</b>
Figure 28. Cytokeratin 14 staining in affected plantar skin of inherited PPK patients with underlying keratin 1, 9, 17, loricrin and mitochondrial mutations compared to normal plantar control.	<b>158</b>
Figure 29. Cytokeratin 17 staining in control non-acral skin and affected plantar skin of inherited PPK patients with underlying keratin 1, 9, 17 and loricrin and mutations compared to normal plantar control.	<b>159</b>
Figure 30. Filaggrin staining in affected plantar skin of inherited PPK patients with underlying keratin 1, 9, 17, loricrin and mitochondrial inherited mutations compared to normal plantar control.	<b>160</b>

Figure 31. Involucrin staining in affected plantar skin of inherited PPK patients with underlying keratin 1, 9, 17, loricrin and mitochondrial mutations compared to normal palmar control.	<b>161</b>
Figure 32. Loricrin staining in affected plantar skin of inherited PPK patients with underlying keratin 1, 9, 17, loricrin and mitochondrial mutations compared to normal plantar control.	<b>162</b>
Figure 33. Ki67 staining in affected plantar skin of inherited PPK patients with underlying keratin 1, 9, 17, loricrin and mitochondrial mutations respectively compared to normal plantar control.	<b>163</b>
Figure 34. Activated caspase 8 staining in breast carcinoma compared to affected plantar skin in inherited PPK patients with underlying K9 and K17 mutations.	<b>164</b>

## **LIST OF TABLES**

	<b>Page</b>
Table 1. Expression patterns of keratins and known keratin disorders.	<b>27</b>
Table 2. Principal hereditary palmoplantar keratodermas.	<b>41</b>
Table 3. Summary of inherited PPK patients recruited to the study.	<b>62</b>
Table 4. Summary of clinical findings in cohort of inherited PPK patients.	<b>62</b>
Table 5. Pattern of focal plantar hyperkeratosis in cohort of inherited PPK patients with underlying K1, K17, DSG1, loricrin and mitochondrial mutations.	<b>69</b>
Table 6. Summary of phenotypic symptoms in PC-2 recruited in this study compared to PC case studies, IPCRR and NRIRD data.	<b>72</b>
Table 7. Plantar specimens collected forming the bank of biopsy material	<b>91</b>
Table 8. Keratinocyte resource established from inherited PPK and control non-plantar skin samples.	<b>92</b>
Table 9. Desmoglein 1 primers.	<b>99</b>
Table 10. Desmoglein 1 primers for RT-PCR.	<b>101</b>
Table 11. Illustration of the autosomal-dominant and –recessive disease phenotypes associated with inherited mutations in structural components of desmosomes.	<b>110</b>
Tables 12a & b. Summary of histologic features in affected plantar skin of PPK patients compared to normal acral controls.	<b>129</b>
Table 13. Summary of morphologic changes in semithin sections of affected plantar skin of PPK patients and unrelated normal controls.	<b>137</b>
Table 14. Summary of electron microscopic features in affected plantar skin in PPK patients compared with normal unrelated plantar controls.	<b>137</b>
Table 15. List of antibodies, isotypes, sources, and dilutions.	<b>150</b>
Table 16. Cytokeratin 1 pattern of staining.	<b>153</b>

Table 17. Cytokeratin 9 pattern of staining.	<b>153</b>
Table 18. Cytokeratin 14 pattern of staining.	<b>153</b>
Table 19. Cytokeratin 17 pattern of staining.	<b>154</b>
Table 20. Filaggrin pattern of staining.	<b>154</b>
Table 21. Involucrin pattern of staining.	<b>154</b>
Table 22. Loricrin pattern of staining.	<b>155</b>
Table 23. Ki67 staining.	<b>155</b>

## **ACKNOWLEDGEMENTS**

Firstly and most importantly, I would like to thank my supervisors, Professor Colin S Munro and Dr Malcolm B Hodgins, for giving me the opportunity to develop my own research project and for their continual guidance.

I would like to thank all of my friends and colleagues in both Dermatology and Infection and Immunity, University of Glasgow. I would particularly like to thank Mrs Irene Campbell and Mrs Margaret Mullin for their technical assistance in histopathology and electron microscopy respectively. I would also like to thank the friends I have made at the Epithelial Genetics Unit, Ninewells Hospital, Dundee, especially Dr Frances JD Smith and Mrs Linda E Campbell for their guidance and support with genetic investigations.

I am very grateful to Professor Robin Eady, St John's Institute of Dermatology, St Thomas' Hospital, London, for his comments and help in interpretation of my electron microscopy work.

Finally, thank you to my parents for their encouragement, support and babysitting duties. Special thanks to my husband, James, for everything.

## **Aims and approach to study**

The underlying aim of the work described in this thesis is **to increase understanding of molecular mechanisms active in the pathogenesis of palmoplantar keratoderma**, in the hope that greater understanding will provide opportunities for better care. Towards this aim, the thesis describes both the creation of a cell and tissue culture resource, and the initial application of this resource to laboratory studies.

Inherited keratodermas (reviewed in Chapter 1) represent a well-defined model system in which a systematic approach to identification to common (or distinct) pathways causing palmoplantar hyperkeratosis should be possible.

Clinical features including response to previous treatment in the study population were characterised (Chapter 2.1). The collection of the resource is described in Chapter 2.2. I studied only families in whom the underlying molecular aetiology had already been established, and one family in whom I was able to identify it (Chapter 2.3).

Palmoplantar skin was obtained for study (Chapter 2.2), necessitating the development of an effective approach to regional anaesthesia (Appendix A). In addition, biopsies of non-palmoplantar skin were obtained, from which keratinocytes have been isolated with a view to study in conventional and organotypic culture.

In the initial application of the resource thus obtained, morphological studies using light and electron microscopy (Chapter 3.1), and immunocytochemical studies using markers of epidermal differentiation and turnover (Chapter 3.2), are described.

Finally I report preparation for pilot microarray studies of gene expression (Chapter 3.3).



## **Chapter 1 Literature Review - The Inherited Palmoplantar**

### **Keratodermas**

#### **1.1 Introduction**

Thickening of palmoplantar skin is a physiological response to repeated mechanical stress. Its inappropriate activation in a variety of pathological situations causes pain, orthopaedic problems, maceration and infection, with consequent disability.

Palmoplantar hyperkeratosis may be seen in generalised disorders of keratinisation such as ichthyosis vulgaris, epidermolysis bullosa, ectodermal dysplasias, dysmorphic syndromes or metabolic disorders, and in inflammatory disease, including psoriasis, eczema and lichen planus (Judge *et al.*, 2004).

The inherited palmoplantar keratodermas (PPKs) are a heterogeneous group of conditions, characterized by marked thickening of the epidermis of the palms and soles, caused by a variety of underlying genetic defects (Lucker *et al.*, 1994; Itin & Lautenschlager, 1995; Stevens *et al.*, 1996; Ratnavel & Griffiths, 1997; Judge *et al.*, 2004; Itin & Fistarol, 2005). Although rare, these are often severe disorders, causing physical, social and occupational disability. There are three main clinical patterns: diffuse, focal with hyperkeratosis at points of friction, and punctate (Itin & Fistarol, 2005). Many keratoderma syndromes are restricted to these sites although other ectodermal or systemic abnormalities may be associated.

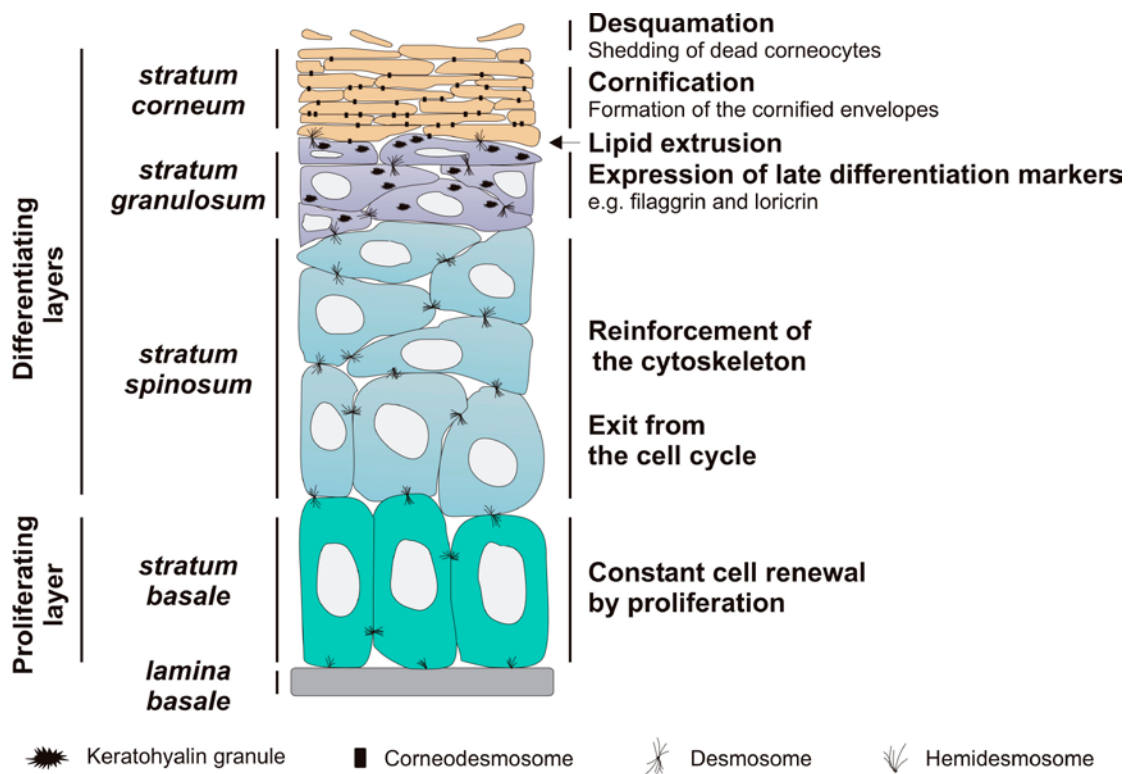
The genetic defects identified in many inherited forms of PPK provide important clues to the mechanisms which lead to pathological hyperkeratosis. Keratoderma has been associated with defects in keratin intermediate filaments,

desmosomes, gap junction communication, and the process of cornification. The variety of defective genes causing keratoderma does not preclude final common pathways in the thickening of epidermis and stratum corneum. These pathways may represent the activation of physiological responses to mechanical stress or wounding. Alternatively, without excluding these mechanisms, they may invoke aspects of the epidermal inflammatory response. In either case, it is possible that not only genetically distinct, inherited forms of PPK share pathological mechanisms, but that these mechanisms will also be activated in other commoner conditions in which keratoderma is an important clinical feature. Thus, an improved understanding of the pathways of pathological hyperkeratosis in inherited PPK may lead to better management of a wide spectrum of common conditions in which palmoplantar hyperkeratosis is a cause of significant morbidity.

In order to place in context pathogenic mutations in components of the epidermis, the physiology of normal epidermal formation and differentiation, and relevant structural elements, are discussed prior to considering what is already known about the major inherited PPKs. Most of the studies quoted have been conducted in hair-bearing skin, and their extrapolation to palmoplantar epidermis is a pragmatic assumption.

## **1.2 Overview of Epidermal Differentiation**

Human epidermis is a stratified epithelium in which the continual processes of proliferation and terminal differentiation are highly regulated. A constant balance between these processes is vital in ensuring the normal structure of the epidermis (Figure 1). Keratinization or cornification are terms used to describe the process of a keratinocyte migrating from the basal proliferative layer to the stratum corneum.



**Figure 1. Schematic representation of the palmoplantar epidermis.** (Denecker *et al.*, 2008). Formed from stem cells, basal keratinocytes proliferate into the suprabasal layers before developing into the squames of the stratum corneum, which flake off (desquamate). Desmosomes link keratinocytes by forming cell-cell junctions. Changes occur in gene regulation, such as in the keratins, during differentiation. (Reproduced by kind permission of Journal of Cell Biology).

This is the final step of differentiation for epidermal keratinocytes and involves dramatic cell condensation before death (Candi *et al.*, 2005). Epidermal homeostasis is driven by stem cells which replace keratinocytes lost through normal differentiation and tissue turnover or through cell death following injury. Stem cells are defined by their ability to self-renew and to give rise to different cell lineages (Blanpain & Fuchs, 2009). Stem cell progeny are known as transit amplifying cells, which differentiate after several rounds of cell division (Clayton *et al.*, 2007). Keratinocytes migrate into suprabasal layers, a key first step in the programme of terminal differentiation (Blanpain & Fuchs, 2009), with a switch from a cytoskeleton formed by keratins K5 and K14 to K1 and K10 (Fuchs & Green, 1980). Significant amounts of other keratins are expressed at other sites, such as K9 in palms and soles and K2e in thickened sites (see sections 1.4 and 1.5). Keratinocytes enlarge and start to express components of the cornified envelope, such as involucrin, loricrin and filaggrin or their precursors (Fuchs & Byrne, 1994).

The stratum corneum (SC) is a thin (12-15µm) tough, outermost layer of the epidermis composed of overlapping flattened, corneocytes and lipid-rich, intercellular lamellae. It fulfils the major epidermal function of protection of the host from the external environment (Watt, 1989; Fuchs & Byrne, 1994). The SC permeability barrier limits the transcutaneous movement of water and electrolytes (Elias & Choi, 2005).

The cornified envelope (CE) structure is built from one or many of the following components (Steinert & Marekov, 1997; 1999): annexin I, cystatin  $\alpha$ , elafin, filaggrin involucrin, loricrin, type II keratin intermediate filament proteins, pancornulins, small proline-rich proteins (or cornifins), trichohyalin, and various

junctional proteins, including desmoplakin, envoplakin and periplakin. These proteins cross-link together by disulfide bonds and N $\epsilon$ -( $\gamma$ glutamyl) lysine isopeptide bonds formed by the action of transglutaminases, thereby becoming insoluble (Nemes & Steinert, 1999; Steinert & Marekov, 1999). CE assembly is a precisely regulated and orderly process triggered by a rise of intracellular Ca<sup>2+</sup> concentration coincident with a signal to initiate terminal differentiation (Kalinin *et al.*, 2002). Corneocytes are embedded in the lipid-laden matrix which is composed of ceramides (Holleran *et al.*, 1991), cholesterol (Menon *et al.*, 1992a) and free fatty acids (Mao-Qiang *et al.*, 1993), together forming the lamellar membranes which limit water and electrolyte loss (Harris *et al.*, 1997; Candi *et al.*, 2005).

Morphologic changes of the keratinocytes at the transition from granular layer to the SC have led to suggestions that terminal differentiation is a specialized form of apoptosis (Maruoka *et al.*, 1997; Ishida-Yamamoto *et al.*, 1999). However, differences exist between apoptosis and terminal differentiation, and the two processes have been shown to be subject to different and distinct stimuli (Gandarillas *et al.*, 1999) (see chapter 3.2).

The final event in terminal differentiation of the epidermis is desquamation. Breakdown of lipids in the intercellular spaces and loss of residual intercellular desmosomal connections occurs due to the action of proteolytic enzymes. This results in cell shedding from the SC (Elias, 2005). The SC contains three families of proteases: the epidermal-specific serine proteases, SC tryptic enzyme kallikrein-5, SC chemotryptic enzyme kallikrein-7, which are able to degrade corneodesmosome proteins; the cysteine proteases, SC thiol protease; and aspartate protease, cathepsin D (Brattsand & Egelrud, 1999; Hansson *et al.*, 1994; Bernard *et al.*, 2003; Horikoshi

*et al.*, 1998). Kallikrein-7 and kallikrein-5 are highly expressed in the stratum granulosum and present in intercellular spaces of the SC (Sondell *et al.*, 1995). Serine protease activity increases in the SC following barrier disruption (Denda *et al.*, 1997), and serine protease/serine protease inhibitor balance has been shown to be important for normal permeability barrier homeostasis (Hachem *et al.*, 2006). The cysteine protease, SC thiol protease, is a product of late epidermal differentiation, which has been shown to be inhibited by cystatin M/E, a cysteine protease inhibitor expressed in the stratum granulosum (Zeeuwen *et al.*, 2001). Mouse models containing a null mutation for the cystatin M/E gene have been shown to have ichthyosiform skin changes and barrier disruption (Zeeuwen *et al.*, 2002). Human cathepsin V has also been shown to be a target for cystatin M/E, and both these molecules are thought to have an important role in epidermal differentiation and desquamation (Zeeuwen *et al.*, 2007).

When the permeability of the SC is disrupted, by mechanical injury or topical treatment removing extracellular lipids, the barrier function is repaired by a homeostatic response initiated by the epidermis (Taljebini *et al.*, 1996). Although this process is not fully understood, extracellular calcium and potassium levels surrounding stratum granulosum cells play a role (Menon *et al.*, 1992b).

### **1.3 Keratin intermediate filaments**

The main stress-bearing structure within the cytoplasm of epithelial cells is the keratin intermediate filament (KIF) cytoskeleton (Fuchs & Cleveland, 1998; Coulombe & Omary, 2002; Omary *et al.*, 2004; Magin *et al.*, 2007; Moll *et al.*, 2008). They make up the largest subgroup of intermediate filaments and represent the most abundant proteins in epithelial cells (Coulombe & Omary, 2002). These

proteins are encoded by a large multigene family whose at least 65 individual members can be partitioned into two major sequence types. The pairwise regulation of type I (K9-K23; Ha1-Ha8) and type II (K1-K8, Hb1-Hb6) keratin genes reflects the composition of keratin polymers, which are built from heterodimers (Coulombe & Omary, 2002). Since the first keratins were sequenced and identified as type I and II intermediate filaments proteins, the increasing numbers of keratins has provided an ongoing challenge for their clear identification and logical classification across species. A new nomenclature system has been structured to divide the 54 human keratins and their genes into three categories: (1) epithelial keratins/genes, (2) hair keratins/genes, and (3) keratin pseudogenes and a fourth category of nonhuman epithelial and hair keratins of other mammalian species (Schweizer *et al.*, 2006).

All intermediate filament proteins have a prototypical structure consisting of a coiled-coil,  $\alpha$ -helix rod domain (two polypeptide  $\alpha$ -helices wound around each other) that is interrupted by linkers and flanked by N-terminal head and C-terminal tail domains (Figure 2). This domain exists in four segments (1A, 1B, 2A and 2B) interrupted by three non-helical linkers (L1, L12, L2) and is flanked by globular head and tail domains, the functions of which are unclear. (Omary *et al.*, 2004; Lane & McLean, 2004; Parry *et al.*, 2007). The helix boundary peptides, at the start and end of the rod domain, are thought to be critical in mediating end-to-end overlap interaction during filament assembly (Steinert *et al.*, 1993). Type II keratins have two additional subdomains, H1 and H2 located between the rod and tail domains; the H1 subdomain is essential for polymerization (Geisler & Weber, 1982; Lane & McLean, 2004; Parry *et al.*, 2007).

The keratin cytoskeleton forms a network of filaments acting as protein scaffolds with structural and regulatory functions (Magin *et al.*, 2007). The assembly of this network involves several steps: firstly, the formation of obligate heterodimers by parallel alignment of a type I and type II keratins. Dimers align to form tetramers that then polymerize laterally and longitudinally to form 2-3nm protofilaments, although the precise mechanism is still uncertain (Steinert *et al.*, 1993). Two protofilaments then align to form a 4.5nm protofibril, and these inter-twine to form a complete 10nm keratin filament consisting of 32 monomer chains before assembling into structurally resilient cytoskeletal networks (Fuchs & Cleveland, 1998; Herrmann *et al.*, 2000; Herrmann & Foisner, 2003). These networks have been shown to be highly dynamic structures (Windoffer *et al.*, 2004).

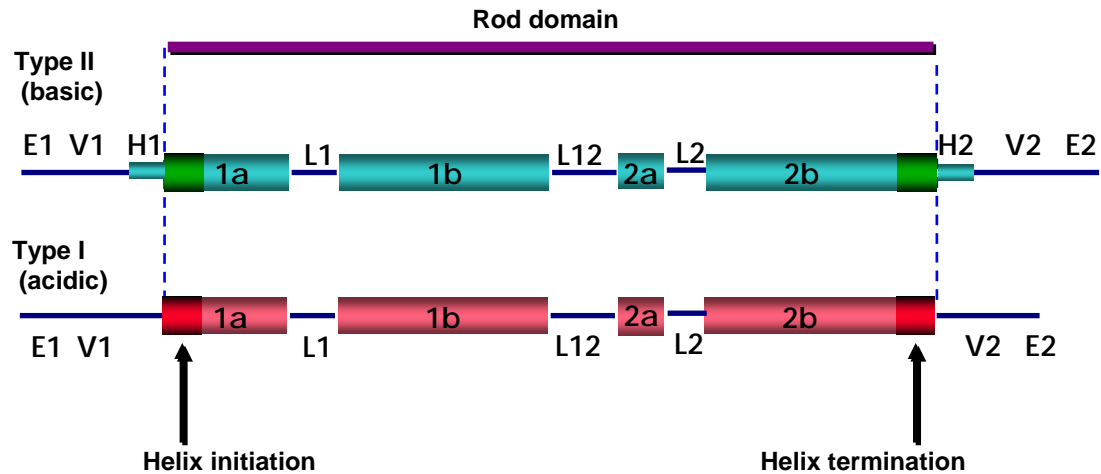
Keratin genes are clustered in two chromosomal regions in the human genome: type I keratins map to 17q12-q21 (except K18) and type II keratins are located in a gene cluster on chromosome 12q11q-14 (Moll *et al.*, 2008).

#### **1.4 Functions of keratins**

The keratin cytoskeleton not only acts as an important structural stabilizer of epithelial cells. It also allows rapid and localized restructuring, while being involved in all aspects of cell behaviour including migration, differentiation and proliferation (Magin *et al.*, 2007). The significance of their mechanical function is emphasised by both knock-out mouse models (Magin *et al.*, 2004; Gu & Coulombe, 2007) and a number of human hereditary keratin diseases (Omary *et al.*, 2004). Keratins are not simply static intracellular structures but are highly dynamic, even in stationary interphase cells (Yoon *et al.*, 2001; Windoffer *et al.*, 1999; 2004). Keratin intermediate filaments demonstrate high viscoelasticity and flexibility, yet



**Figure 2. Schematic diagram of basic intermediate filament structure.** Type I and Type II keratin intermediate filaments are shown, with the coiled-coil  $\alpha$ -helical segments of the central rod domain (1A, 1B, 2A and 2B) shaded in pink and turquoise, and non-helical segments (L1, L12 and L2) in blue. At the beginning and end of the rod domain are the highly conserved helix boundary motifs, the helix initiation peptide (HIP)(amino terminus) and helix termination peptide (HTP)(carboxy terminus) in the 1a domain and the end of helix 2B respectively. H1 and H2 subdomains are present in type II keratins (adapted from Irvine & McLean, 1999; Corden & McLean, 1996; Lane & McLean, 2004).



retain the ability to harden in response to stress, yield rapidly without breaking and recover quickly when deforming stress is removed (Janmey *et al.*, 1991; Ma *et al.*, 1999).

The contribution of keratins to the mechanical stability of tissues is apparent when considering the number of blistering diseases caused by single point mutations of keratin (Omary *et al.*, 2004; Lane & McLean, 2004; Gu & Coulombe, 2007). Mechanical trauma exacerbates blistering in diseases such as epidermolysis bullosa simplex (EBS) demonstrating the loss of mechanical resilience (Magin *et al.*, 2007). Keratins are anchored by desmosomes and their mechanical functions must be considered in conjunction (section 1.6 and chapter 2.3). Keratin knockout mouse models have further confirmed their essential mechanical role, such as deletion of K5 leading to pronounced cytolysis and neonatal death (Peters *et al.*, 2001), and K14 null mice demonstrating a less severe phenotype, probably due to compensation by K15, its related type I keratin (Lloyd *et al.*, 1995).

New functional roles of keratins have been defined and are emerging (Moll *et al.*, 2008), including protection from apoptosis (K17, Tong & Coulombe, 2006) and the regulation of protein synthesis and cell size during wound healing by intracellular signalling pathways (K8, Caulin *et al.*, 2000; Ku *et al.*, 2003a; K17, Kim *et al.*, 2006) (see chapter 3.2 and section 4). In addition, K8, K18 and K19 protect the placental and trophoblast barrier function (Hesse *et al.*, 2000; Jaquemar *et al.*, 2003) and K8 and K18 protect the liver from stress and injury (Zatloukal *et al.*, 2000; Ku *et al.*, 2003b). Beyond their biological functions, keratin expression patterns are distinct during different stages of epithelial differentiation and have thus evolved to be

important epithelial differentiation and tumour markers in cell biology, embryology and surgical pathology (Moll *et al.*, 2008).

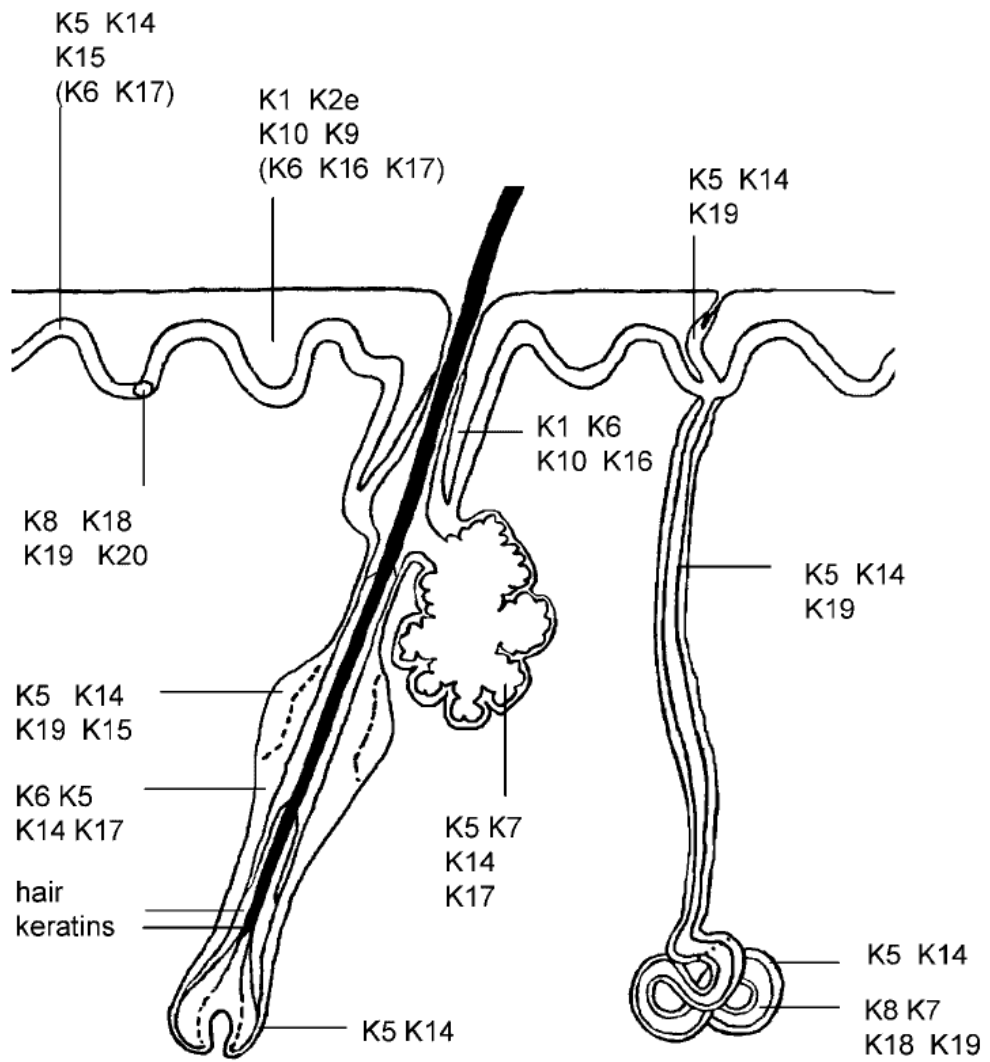
### **1.5 Keratin expression in epidermis and epidermal appendages**

Like other intermediate filaments, keratins are characterized by tissue-specific expression patterns which make them useful tools for diagnostic pathology (Lane & McLean, 2004). Selective expression in certain cell types and during differentiation is an important aspect of the genes encoding intermediate filaments and is relevant to the association of mutations in these genes with a broad range of tissue-specific diseases (Omary *et al.*, 2004) (Table 1). An overview ‘map’ of the major keratin expression patterns in the skin epithelia is shown in Figure 3. Keratin expression can define the differentiation status of keratinocytes (Patel *et al.*, 2006) e.g. K5 and K14 in basal cells, K1 and K10 in differentiating suprabasal cells and K6, K16 and K17 in “hyperproliferating” cells (Coulombe, 1997; Freedberg *et al.*, 2001) (see chapter 3.2). Changes in keratin expression occur in response to epidermal injury, with downregulation of differentiation-specific keratins K1 and K10, and expression of inducible keratins K6, K16 and K17 (Paladini *et al.*, 1996; Tomic-Canic *et al.*, 1998) (see chapter 3.2).

**Table 1. Expression patterns of keratins and known keratin disorders** (adapted from Smith *et al.*, 2005; Corden & McLean, 1996; Magin *et al.*, 2007).

<b>Keratin (pair)</b>	<b>Main expression pattern</b>	<b>Disorder</b>
K1, K10	Suprabasal cells of stratified, cornified epithelia	Bullous congenital ichthyosiform erythroderma (BCIE), Diffuse non-epidermolytic PPK
K2e	Late suprabasal cells of stratified, cornified epithelia	Ichthyosis bullosa of Siemens (IBS)
K2p	Hard palate specific keratin	-
K3, K12	Cornea specific keratins	Meesmann epithelial corneal dystrophy (MECD)
K4, K13	Mucosa, stratified non-cornified envelope	White sponge naevus (WSN)
K5, K14	Basal keratinocytes of epidermis and stratified epithelia	Epidermolysis bullosa simplex (EBS), EBS with mottled pigmentation, Dowling-Degos disease, Naegeli-Franceschetti-Jadassohn syndrome (K14)
K6a, K16	Palmoplantar epidermis (widespread), nail bed, oral mucosa, wound healing, epidermal appendages	PC-1, Focal non-epidermolytic PPK,
K6b, K17	Nail bed, palmoplantar epidermis (restricted), epidermal appendages, sebaceous gland, hair shaft, other epithelia, wound healing	PC-2, Steatocystoma multiplex,
K7	Myoepithelial cells, simple epithelia	-
K8, K18	Simple epithelia, hepatocytes	Cryptogenic cirrhosis, inflammatory bowel disease
K9	Palmoplantar epidermis	Epidermolytic PPK
K15	Basal keratinocytes	-
K19	Simple epithelia, epidermal appendages	-
K20	Gastrintestinal tract epithelia, Merkel cells	-
hHb6, hHb1, hHb3	Cortical trichocytes of the hair shaft	Monilethrix
K6hf	Companion layer of hair follicle	Pseudofolliculitis barbae
K6irs	Inner root sheath of hair follicle	-

**Figure 3. Summary of major consensus patterns of keratin expression in epidermis and epidermal appendages (Lane & McLean, 2004).** (Reproduced by kind permission of the authors).

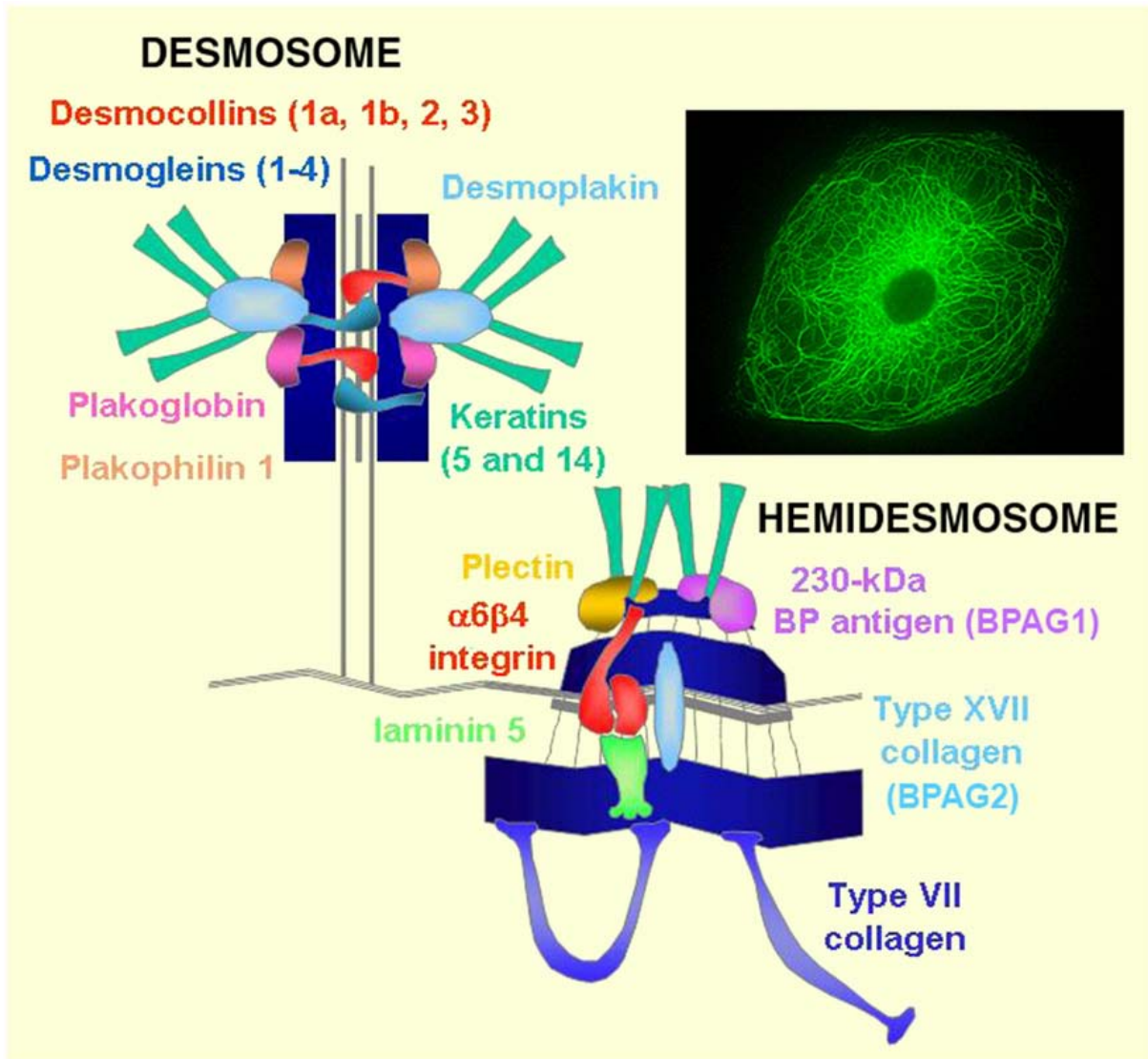


## 1.6 Desmosomes

Desmosomes are the most common type of intercellular junction which mediate stress-bearing intermediate filament anchorage at sites of cell-cell contact (Yin & Green, 2004). They are highly organised, disc-like structures, 0.1-0.5 $\mu$ m in diameter, that mechanically couple adjacent keratinocytes (Figure 4). A transcellular network is created throughout a tissue that is thought to resist forces of mechanical stress and this in turn attaches to the basal aspect of the cell by molecularly distinct junctional structures called hemidesmosomes (Green & Jones, 1996; Dusek *et al.*, 2007).

Desmosomes are formed by mirror image, tri-partite electron-dense plaques, each opposing the plasma membranes of neighbouring cells, and which exhibit tissue-specific differences in both structure and composition (Green & Simpson, 2007). Desmosomes consist of proteins from a number of distinct gene families, including cadherins, armadillo proteins and plakins (Yin & Green, 2004) (Figure 4). The cytoplasmic plaque comprises desmoplakin and plakoglobin, with desmoplakin being critical in linking keratin intermediate filaments to desmosomes forming a three-dimensional lattice throughout the cell (Green & Jones, 1996). The armadillo proteins include plakoglobin, plakophilins (PKP1-3) and p0071 (Hatzfeld, 1999; Yin & Green, 2004). Plakin family members include desmoplakins I and II, plectin, and the cell envelope proteins envoplakin and periplakin (Leung *et al.*, 2002). The plakins share a similar structure consisting of a central  $\alpha$ -helical coiled-coil rod domain flanked by globular N- and C-terminal domains. These domains mediate interaction with other proteins, the C-terminal region of desmoplakin binding to a conserved 18 amino-acid sequence at the N-termini of the keratin filaments and the

**Figure 4. Structural organisation of desmosomes and hemidesmosomes** (Uitto *et al.*, 2007), with attachment complexes at the cell-cell and cell-matrix interface, respectively. They are both connected to the keratin intermediate filament cytoskeleton, visualised by immunofluorescence on the upper right corner. (Reproduced by kind permission of the authors).



N-terminal portion of desmoplakin with the desmosomal cadherins (Kouklis *et al.*, 1995). The desmosomal cadherins, desmogleins (DSGs) and desmocollins (DSCs), are a family of glycoproteins which interact with the N-terminus of desmoplakin (Yin & Green, 2004). The cadherin genes are tightly clustered on chromosome 18 and consist of four DSGs and three DSCs (Kljuic *et al.*, 2003a; Whittock & Bower, 2003a; Getsios *et al.*, 2004).

Desmosomes not only form robust extracellular bonds essential in maintaining tissue integrity, but also play a role in the processes of differentiation and morphogenesis (Green & Simpson, 2007). This has been shown by mis-expression or targeted deletion of desmosomal cadherins (Allen *et al.*, 1996; Chidgey *et al.*, 2001; Elias *et al.*, 2001; Merritt *et al.*, 2002; Cheng & Koch, 2004; Hardman *et al.*, 2005) (see also chapter 2.3 & section 4).

### **1.7 Connexins and gap junctions**

The direct communication between cells is considered an indispensable mechanism in the maintenance of cellular homeostasis (Meşe *et al.*, 2006), which is mediated via intercellular channels that cluster in specialized regions of the plasma membrane to form gap junctions (Robertson, 1963; Revel & Karnovsky, 1967; Meşe *et al.*, 2006). Gap junctional intercellular communication is actively involved in virtually all aspects of the cellular life cycle (Vinken *et al.*, 2006), and is essential for many physiological events, including cell synchronization, differentiation, cell growth and metabolic coordination of avascular organs including epidermis and lens (White & Paul, 1999; Vinken *et al.*, 2006). Gap junction channels are formed of related proteins called connexins (Goodenough, 1974) encoded by a family of genes categorized as  $\alpha$ ,  $\beta$  and  $\gamma$  according to their gene structure, overall homology and

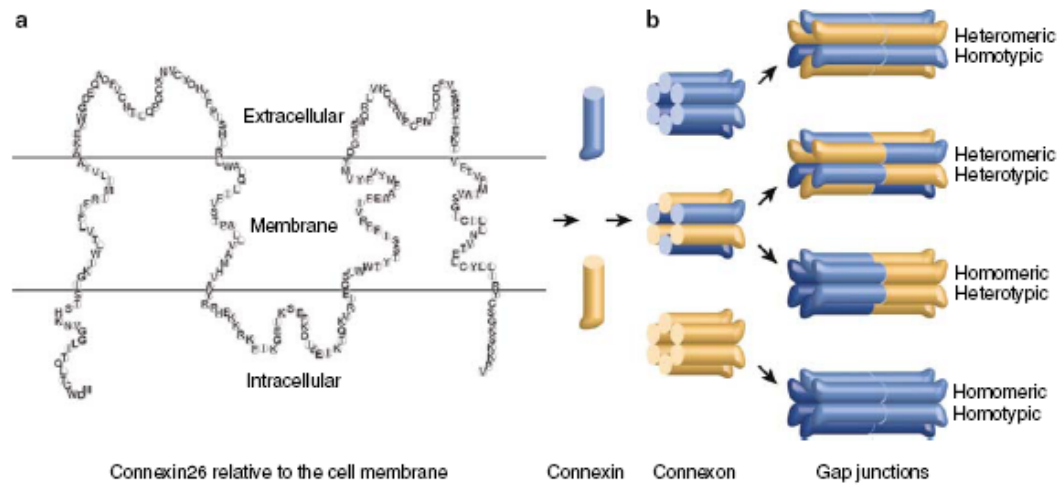


specific sequence motifs (Meşe *et al.*, 2006). Gap junctions typically gather in groups of 10 to 10,000, so-called plaques, at the membrane surface (Vinken *et al.*, 2006) (Figure 5). Members of the connexin (Cx) family of proteins contain four membrane-spanning domains, two extracellular loops, one cytoplasmic loop, one cytosolic N-terminal tail, and one C-terminal region. The extracellular loops play roles in cell-cell recognition and docking processes, with three cysteine residues in each loop solely forming intraconnexin disulfide bonds (Meşe *et al.*, 2006). Variation between the connexin family members is mainly due to structural differences within the cytosolic areas (Vinken *et al.*, 2006). Phosphorylation is thought to be important for the regulation of assembly and modulation of the physiological properties of the channels (Lampe & Lau, 2004; King & Lampe, 2005). In the plasma membrane, two opposing hemichannels or connexons are assembled as hexamers of protein subunits that dock in the intercellular space to form functional channels (Vinken *et al.*, 2006). Homomeric, heteromeric and heterotypic channels differ in their content and spatial arrangement of connexin subunits (Meşe *et al.*, 2006).

Two nomenclature systems are used to designate different connexin species, one distinguishing connexins by molecular weight, as predicted by cDNA sequencing (e.g. Cx32). The other divides connexins according to sequence similarity and cytoplasmic length domain, into subclasses  $\alpha$ ,  $\beta$  or  $\gamma$ , using the prefix “GJ” for gap junction and the order of their discovery (e.g. Cx32 is GJB1) (Vinken *et al.*, 2006).

There are at least 21 connexin isoforms in the human genome, with nearly all human cells expressing at least one type of these genes at some point, such as Cx26 in cochlea, liver, skin and placenta, compared to Cx46 and Cx50 in the eye alone

**Figure 5. Schematic representation of connexins and gap junction channels (Meşe *et al.*, 2006).**  
 (a) The connexin structure consists of two extracellular loops, four membrane-spanning domains, one cytoplasmic loop, one N-terminal tail, and one C-terminal tail. (b) Hexameric connexons (hemichannels) are composed of six connexins, which align in the extracellular space for form gap junctions. Homomeric, heteromeric and heterotypic channels differ in their content and spatial arrangement of connexin subunits. (Reproduced by kind permission of Nature Publishing Group)



(Meşe *et al.*, 2006). Connexins show overlapping expression patterns, with co-expression of multiple genes possibly providing compensatory mechanisms for the loss of one isoform (Kretz *et al.*, 2003). These patterns vary in response to various receptor activated signalling pathways, toxic agents, cellular proliferation and transformation (Richard, 2000).

An elaborate gap junction network exists within the skin, with Cxs expressed by keratinocytes in specific and often overlapping patterns within differentiating layers of the epidermis (Salomon *et al.*, 1994; Di *et al.*, 2001). Cx43 is the most broadly expressed in interfollicular epidermis, throughout the stratum spinosum and granulosum, as well as focally in stratum basale. It is found in sebaceous glands, and the lower portion, the cortex, inner and outer root sheet cells of hair follicles (Salomon *et al.*, 1988; Salomon *et al.*, 1994; Tada & Hashimoto, 1997; Lucke *et al.*, 1999). In contrast, Cx26 is usually patchily distributed in basal keratinocytes, most prominently in palms and soles, but is highly expressed in hair follicles and eccrine sweat glands (Lucke *et al.*, 1999; Salomon *et al.*, 1994).

The association of human genetic disease with specific connexin mutations is establishing a key role for gap junctions in a diverse range of physiological processes. The first disease-associated connexin was Cx32, in the X-linked form of Charcot-Marie-Tooth disease, a progressive neuropathy resulting from myelin disruption and axonal degeneration of peripheral nerves (Richard, 2000). A myriad of connexin mutations have been found to cause deafness and skin disease (Kelsell *et al.*, 2001), and in particular genodermatoses characterized by PPK (Maestrini *et al.*, 1999; Kelsell *et al.*, 2000; Richard *et al.*, 1998a; Lamartine *et al.*, 2000) (see section 1.17).

## 1.8 Connexins and proliferation, differentiation and growth control

Gap junctional communication plays a central role in keratinocyte growth and differentiation with the epidermis being highly coupled by intercellular channels (Meşe *et al.*, 2006). To date, nine connexin genes are known to be expressed during the keratinocyte differentiation process including Cx26, Cx30, Cx30.3, Cx31 and Cx43 (Kelsell *et al.*, 2000; Di *et al.*, 2001). Normal skin can regenerate after wounding or damaging, which involves proliferation, migration and differentiation of keratinocytes (Martin, 1997; Jacinto *et al.*, 2001). The dynamically regulated switch of the pattern of connexin expression in the skin correlates with changes in the program of proliferation and differentiation of keratinocytes (Richard, 2000). The expression of connexins in rat skin is altered in response to the repair process, with strong up-regulation of Cx26 in differentiated cells proximal to the wound edge compared to a simultaneous decline in Cx31 and Cx43 (Goliger & Paul, 1995). Cx26 expression was induced initially in a patchy pattern in the basal cell layer, then later extensively in basal and suprabasal cell layers, preceding an increase in cell proliferation in human skin following tape stripping (Lucke *et al.*, 1999). In connexin-deficient mice, the down-regulation of Cx43 appeared to be a prerequisite for the coordinated proliferation and mobilization of keratinocytes during wound healing (Kretz *et al.*, 2003).

Cx26 upregulation has been reported under hyperproliferative skin conditions such as psoriasis, despite normal levels of Cx43 expression (Labarthe *et al.*, 1998; Rivas *et al.*, 1997; Djalilian *et al.*, 2006). Cx37 and Cx31.1 are also induced in psoriasis and erythrokeratoderma variabilis (EKV)(Masgrau-Peya *et al.*, 1997), and Cx26 expression has been noted in viral warts, overlapping with Cx43 (Lucke *et al.*,

1999). A similar increase and coexpression of Cx26 and Cx43 has been noted during treatment of human epidermis with topical retinoic acid (Masgrau-Peya *et al.*, 1997). Although the expression of Cx26 seems characteristic of chronic epidermal hyperplasia, Cx26 positive cells have been shown not to proliferate, suggesting that Cx26 is associated with differentiation rather than proliferation (Lucke *et al.*, 1999). However, the relationship between Cx26 upregulation and keratinocyte proliferation and the signalling cascades involved in this process is not fully understood (Meşe *et al.*, 2006).

In contrast, the disruption of gap junction intercellular communication may be associated with abnormal cell growth and carcinogenesis (Richard, 2000). Cx26 and Cx43 are almost completely abolished in basal cell carcinoma and squamous cell carcinoma (Kamibayashi *et al.*, 1995; Sawey *et al.*, 1996). The loss of differentiation in tumour progression, invasion and metastasis is associated with a quantitative and qualitative reduction in expression of Cx43, Cx26 and Cx31.1 (Kamibayashi *et al.*, 1995; Budunova *et al.*, 1995, 1996). Thus there is increasing evidence for the critical role of Cx-mediated signalling in the control of epidermal morphogenesis, differentiation and growth (Richard, 2000). Connexins are also emerging as therapeutic targets to improve wound healing (Qui *et al.*, 2003; Coutinho *et al.*, 2005; Mori *et al.*, 2006).

### **1.9 Palmoplantar Skin**

Multiple studies have suggested that palm and sole skin is structurally different from skin in other sites (Fuchs & Green, 1980; Matoltsy *et al.*, 1983; Egelrud & Stigbrand, 1989). It has a number of unique features: it contains the highest density of eccrine sweat glands, it is devoid of pilosebaceous follicles and its surface is characterized

by alternating ridges and grooves forming a highly individual pattern, the dermatoglyphics (Swensson & Eady, 1996).

Study of the structure and physiology of palmoplantar epidermis has been relatively neglected compared with that of hair-bearing skin. Keratinocytes in ridged skin have an unusually large amount of keratin filaments in their cytoplasm compared to thin skin, with densely aggregated keratin filament bundles (Swensson & Eady, 1996), possibly due to the expression of palmoplantar-specific keratin (Knapp *et al.*, 1986; Moll *et al.*, 1987; Langbein *et al.*, 1993). Palm and sole epidermis demonstrates a complex pattern of keratin expression, with at least six different keratins being expressed suprabasally, among these, keratin 9 appears to be expressed almost exclusively in suprabasal keratinocytes of palms and soles (Knapp *et al.*, 1986). It is not clear whether the apparent abundance of keratin filament network in ridged epidermis is functionally significant, serving a protective function in a tissue that is vulnerable to exceptional forces (Swensson & Eady, 1996). Specific patterns of other keratins have also been documented in ridged skin, suggestive of regional adaptations of this epidermis to a high cell turnover rate (see chapter 3.2). These differences between ridged and thin skin highlight the potential pitfalls of misinterpreting site-related morphological features as pathological.

The expression pattern of connexins in palmoplantar epidermis is also distinct as discussed above (section 1.8).

### **1.10 Wound healing**

Epidermal wound healing provides permanent closure of a wound and a restoration of important functions of the skin, such as its barrier function (Brandner *et al.*, 2004). The process is complex, involving the proliferation and migration of keratinocytes in

the regenerated epidermis (Odland & Ross, 1968). For migration to occur, cells must become motile and modulate their adhesions with each other, and the process of “kick-starting” is of great interest (Martin, 1997). Keratinocytes at the wound edge withdraw from terminal differentiation in response to epidermal injury and undergo changes in morphology and gene expression (Grinnell, 1992). This process of “keratinocyte activation” involves cell hypertrophy, retraction of keratin filaments from the cell periphery, alterations of desmosomes and widening of intercellular spaces (Odland & Ross, 1968). Two theories of wound re-epithelialization have been proposed. “Leap-frogging” involves proliferating keratinocytes distant from the wound edge entering the suprabasal compartment, with suprabasal keratinocytes downregulating desmosome expression, migrating over adherent basal keratinocytes and reverting to a basal phenotype at the wound bed (Krawczyk, 1971). “Tractor-tread” suggests basal keratinocytes migrating over the wound bed, pulling the remaining epidermis, while desmosomal junctions are maintained (Woodley, 1996). Basal keratinocytes migrate as in epidermal cell culture with suprabasal cells having an ancillary role (Clark *et al.*, 1996).

Epidermal injury represents a dramatic change with keratinocytes required to become more flexible to facilitate epidermal migration across a wound bed and rapidly close the wound, when normally they would differentiate to form rigid structures (Patel *et al.*, 2006). Transplantation of culture keratinocytes into wounds induces and accelerates wound healing (Leigh *et al.*, 1991; Moll *et al.*, 1995; 1998). It is thought that this is due to cytokines produced by transplanted keratinocytes which activate epidermal and/or adnexal keratinocytes (Leigh *et al.*, 1991).

Growth factors including EGF, TGF $\alpha$ , heparin-binding EGF, and keratinocyte growth factor are involved in stimulating epithelial cell motility and proliferation in wounded epidermis (Marikovsky *et al.*, 1993). The keratin cytoskeleton also appears to play a role (Guo *et al.*, 1995; Paladini *et al.*, 1996). Epidermal injury is associated with changes in both keratin expression (Paladini *et al.*, 1996; Tomic-Canic *et al.*, 1998) (see 1.5 & chapter 3.2) and connexin distribution (Hodgins, 2004) (see 1.8). Cx43 is greatly reduced in keratinocytes migrating into the margins of healing wounds, with a subsequent induction of Cx26 and Cx30 near the wound margins (Brandner *et al.*, 2004). In mouse models, a reduction of Cx43 has been shown to accelerate incisional wound closure (Kretz *et al.*, 2003; Qiu *et al.*, 2003). In contrast, in hyperproliferative skin, an upregulation of Cx26 occurs. This suggests that a change in gap junction properties might be a requirement for effective wound closure (Hodgins, 2004).

### **1.11 Classification of Inherited PPK**

Clinical classification of the inherited PPKs has been difficult, based upon eponymous case reports of individual families, with lack of uniform nomenclature (Ratnavel & Griffiths, 1997). On historical grounds, PPKs are based on clinical descriptions and morphology of lesions, mode of inheritance, age of onset, presence of lesions in areas other than palms and soles and associated diseases or malformations (Itin, 1992). The molecular basis has been identified in the majority of PPK syndromes, however marked clinical overlap often exists (Itin & Fistarol, 2005). Consequently, no single classification system unites satisfactorily clinical presentation, pathology and molecular pathogenesis (Greither, 1977; Salamon, 1986; Zemstov & Veitschegger, 1993; Lucker *et al.*, 1994; Itin & Lautenschlager, 1995;



Stevens *et al.*, 1996; Ratnavel & Griffiths, 1997). The inherited PPKs discussed in this thesis are outlined (Table 2).

### **1.12 Genotype/Phenotype Correlation**

The association of a specific mutation in a given gene with a corresponding phenotype has great relevance in understanding mechanisms of disease and in facilitating truly informed genetic counselling. As more data are reported, the association of mutations in one gene with a distinct phenotype has become more complex. In the genodermatoses, clinical and genetic heterogeneity occurs. Clinical heterogeneity occurs when clinically distinct phenotypes are produced by different mutations in the same gene e.g. the range of phenotypes caused by mutations in the gene encoding desmoplakin 1 (see section 1.15 and chapter 2.3). Genetic heterogeneity refers to a situation where identical clinical phenotypes are attributed to mutations in several genes e.g. striate PPK caused by mutations in the genes encoding desmoglein 1, desmoplakin and keratin 1 (see section 1.5 and chapter 2.3) (Irvine & McLean, 2003).

Table 2. Principal hereditary palmoplantar keratodermas (adapted from Judge et al, in press)

Type	Eponym(s)	Inheritance (presumed)	Gene or locus	Onset (years)	Transgredient/ cicatrizing	Comments/special features
<b>Keratodermas and ectodermal dysplasias</b>						
<i>Diffuse group</i>						
Epidermolytic keratoderma	Vörner	AD	Keratin 9	0-3	N	Most common but histology needed to confirm
Diffuse non-epidermolytic keratoderma*	Thost-Unna	AD	Some 12q11-q13	2-5 or later	N	Likely to be heterogeneous
Loricrin keratoderma	Camisa; variant Vohwinkel	AD	Loricrin	2-5	Y	Mild ichthyosis; honeycomb pattern keratoderma
Autosomal dominant transgredient keratoderma*	Greither; Sybert	AD	Some 1p; Keratin 1	3-8	Y	Likely to be heterogenous
Keratoderma with scleroatrophy	Huriez	AD	4q23		Y	Squamous carcinomas
Mal de Meleda		AR	SLURP-1	0-3	Y	Dermatophyte infection common
Autosomal recessive transgredient keratoderma*	Gamborg-Neilsen	AR	-	8-10	Y	Likely to be heterogeneous
Palmoplantar and periorificial keratoderma	Olmsted	?AR	-	0-1	Y	Periorificial and flexural erythema and hyperkeratosis

Focal/areate/nummular keratoderma	Wachters	AD	-			Includes painful hereditary callosities
Focal keratoderma with oral leukokeratosis		AD	Keratin 16	3-5	N	Oral leukokeratosis
Pachyonychia congenita type 1	Jadassohn-Lewandowsky	AD	Keratins 6a, 16	3-5	N	Oral lesions, follicular keratoses
Pachyonychia congenita type 2	Jackson-Lawler	AD	Keratins 6b, 17	3-5	N	Natal teeth, multiple cysts, follicular keratoses
Striate keratoderma	Brunauer-Fuhs-Siemens	AD	Desmoplakin, Desmoglein 1, Keratin 1		N	
Hidrotic ectodermal dysplasia	Clouston	AD	Connexin 30		Y	Nail and hair dystrophy
<b>Keratodermas with extracutaneous features</b>						
Keratoderma with oesophageal carcinoma	Howel-Evans	AD	17q23		N	Focal PPK with oral lesions
Striate keratoderma, woolly hair and arrhythmogenic cardiomyopathy	Naxos disease	AR	Plakoglobin		N	
Striate keratoderma, woolly hair and dilated cardiomyopathy		AR	Desmoplakin		N	

Cicatrizing keratoderma with hearing loss	Vohwinkel	AD	Connexin 26	5-10	Y	Papular lesions becoming confluent, starfish keratoses. Mild hearing impairment
Keratoderma with prelingual deafness		AD	Connexin 26	0-5	Y	Mild diffuse PPK but profound deafness
Mitochondrial hearing loss with keratoderma		Matrilineal	A7445G		N	Variable mild focal PPK
Keratoderma with neuropathy*		Varies	(SNAP29)		N	Peripheral neuropathy; spastic paralysis
Keratoderma with periodontitis	Papillon-Léfavre	AR	Cathepsin C		N	Severe periodontal and other pyogenic infections
Keratoderma with eyelid cysts	Schöpf-Schulz-Passarge	AR	-		N	Diffuse keratoderma, hypotrichosis, nail fragility, loss of deciduous teeth, adnexal tumours
Oculocutaneous tyrosinaemia	Richner-Hanhart	AR	Tyrosine aminotransferase		N	Corneal ulcers, painful keratoses, progressive mental impairment
<i>Punctate group</i>						
Punctate keratoderma*	Brauer-Buschker-Fischer	AD	8q24; 15q22	10-40	N	Possible association with malignancy in some families
Punctate keratoderma of palmar creases		AD	-	10-40	N	Palmar creases, sometimes marginal lesions
Marginal papular keratoderma	Costa/David	AD	-	Childhood	N	Marginal crateriform papules with/without elastorrhexis

Papuloverrucous keratoderma	Touraine; Jakac-Wolf	AR	-	2-6	N	Follicular keratoses; dysplastic teeth
-----------------------------	----------------------	----	---	-----	---	--

\* These pragmatic clinical groupings encompass a variety of genetically distinct syndromes.

### 1.13 Keratins and Skin Disorders

Mutations in keratin genes underlie a variety of epidermal and non-epidermal cell-fragility disorders (Corden & McLean, 1996) and are the genetic basis of a number of the PPKs. The cell-type and tissue-specific expression profile of the mutated keratin dictates the cell type and body site that is affected in the disorder. The majority of these mutations are clustered, indicating that these ‘hotspot’ regions of the protein are important for normal keratin function (Kelsell & Stevens, 1999).

Most keratin diseases are inherited in an autosomal dominant fashion. Keratin filaments whose structural integrity is compromised by the presence of a mutated component are weaker, causing the filament network of a keratinocyte to collapse when the cell undergoes physical trauma. Mutations in K5 or K14 cause epidermolysis bullosa simplex (EBS), (Figure 3) in which the basal cells are fragile and may fracture if the epidermis is subjected to even quite mild physical trauma. All forms of EBS can show associated palmoplantar keratoderma, with the epidermis and stratum corneum becoming greatly thickened. K1 and K10 are the major secondary differentiation-specific keratins of interfollicular epidermis and are expressed by suprabasal epidermis and any other stratified squamous epithelia that becomes orthokeratinized (Lane & McLean, 2004). Mutations in K1 and K10 are associated with bullous congenital ichthyosiform erythroderma (BCIE), or EH (epidermolytic hyperkeratosis) in which suprabasal cells become fragmented easily. The keratin mutations in K1 and K10 which lead to these disorders are found predominantly in the helix boundary motifs of either keratin, in the H1 region of K1 and occasionally the L12 linker region (Lane & McLean, 2004). It is notable that in

BCIE, hyperkeratosis is a much more marked element of the phenotype than blistering.

In attempting to understand genotype-phenotype correlation in the inherited PPKs, the Human Intermediate Filament Database (HIFD) provides a useful resource (<http://www.interfil.org>). With the increasing number of pathogenic defects being reported in intermediate filament genes, the HIFD catalogues mutations and polymorphisms in parallel with data on protein structure, gene, and chromosomal location (Szeverenyi *et al.*, 2008).

#### **1.14 Inherited PPK and keratins**

K9 is a type I keratin expressed in suprabasal cells in the epidermis of palm and sole (Moll *et al.*, 1987), where it may contribute a specific reinforcing effect to withstand the greater stress at these sites (Swensson *et al.*, 1998). K9 was thus a strong candidate gene for palmoplantar specific keratoderma (Lane & McLean, 2004) and linkage of EPPK to the type I keratin cluster was demonstrated. With the cloning of the K9 cDNA and corresponding gene *KRT9*, missense mutations have been associated with EPPK, the autosomal dominant skin fragility disease **diffuse epidermolytic PPK (Vörner's syndrome)** (Vörner, 1901) and are continuing to be reported ([www.interfil.org](http://www.interfil.org)) (Reis *et al.*, 1994; Navsaria *et al.*, 1995; Covello *et al.*, 1998a; Coleman *et al.*, 1999; Lee *et al.*, 2003).

This disorder is characterized by a confluent keratoderma which is indistinguishable clinically from the **diffuse non-epidermolytic PPK (NEPPK)** described by Thost and Unna (Thost, 1880; Unna, 1883), but with histological features of epidermolytic hyperkeratosis. Infants may develop diffuse keratoderma. A confluent keratoderma sparing dorsal surfaces is present in adults, with a sharp

demarcation and erythematous edge. A history of blisters or fissuring of the palms may hint at reduced strength, although blistering is not a major feature. Hair, teeth and nails are not affected (Judge *et al.*, 2004). The degree of cytolysis present may result in proliferation signals to the epidermis in an aberrant wound response (Lane & McLean, 2004). A total of 65 mutations have been reported in K9 in association with EPPK (<http://www.interfil.org>) of which the majority occur in the region encoding the first half of helix 1A of K9, a mutation “hotspot” in other keratins. In general, these mutations are substitutions, but there has been one report of a 3-bp insertion designated 1362ins3 in exon 6 (Coleman *et al.*, 1999).

Although mutations in K1 and K10 are associated with BCIE, there are also reports of mutations in K1 causing PPK (Kimonis *et al.*, 1994; Hatsell *et al.*, 2001; Terron-Kwiatkowski *et al.*, 2004; 2006) both associated with/without epidermolysis, challenging the existence of NEPPK as a distinct entity. The phenotype in these families has been distinct from BCIE as they lack the generalized hyperkeratosis distributed over the entire body, and it was restricted to palmoplantar surfaces (Hatsell *et al.*, 2001). A mutation in the V1 subdomain of K1 resulted in a distinct phenotype being associated with diffuse NEPPK and limited hyperkeratosis of the areola, umbilicus, and knuckle pads of the dorsal aspects of the finger joints. This mutation changes residue lysine-72 to isoleucine, found in a highly conserved 22 residue sequence involved in cross-linking of the cornified cell envelope by transglutaminases present in all type II keratins except K7 and K8 (Kimonis *et al.*, 1994).

**Pachyonychia congenita (PC)** is a group of inherited disorders of the epidermis and its appendages which can be divided into two main clinical subtypes,



PC-1 (OMIM 167200) and PC-2 (OMIM 167210) (Munro, 2001). PC-1 (Jadassohn-Lewandowsky subtype) is characterised by hypertrophic dystrophy of the distal nail (pachyonychia) associated with focal PPK, follicular keratoses, oral leukokeratosis, angular cheilosis and hoarseness. PC-2 (Jackson-Lawler subtype) is similarly distinguished by pachyonychia, follicular keratoses and focal PPK, but is also associated with natal teeth, multiple pilosebaceous cysts, protruberant eyebrows, and (in children) unruly hair (Gorlin *et al.*, 1976; Jadassohn & Lewandowsky, 1906; Jackson & Lawler, 1951).

There were a number of reasons why PC was thought to be a keratin-related disease (Munro *et al.*, 1994). Blistering in some cases of PC was worse in warm weather and improved with age, resembling EBS, which was known to be due to mutations in genes for the keratins of the basal layer of the epidermis, K5 and K14 (Coulombe *et al.*, 1991; Bonifas *et al.*, 1991; Lane *et al.*, 1992). Marked increases of tonofilaments in the peripheral cytoplasm of keratinocytes from the basal layer upwards had been found in PC-1 (Thormann & Kobayasi, 1977; Thomas *et al.*, 1984).

Stress response keratins K6, K16 and K17 are rapidly induced on injury or inflammation, and are also constitutive components of the epithelium in several epidermal appendages such as hair follicle and nail (Fig.3)(Lane & McLean, 2004). Four keratins are associated with PC: mutations in K6a or K16 cause PC-1 (Bowden *et al.*, 1995; Mclean *et al.*, 1995; Shamsher *et al.*, 1995; Lin *et al.*, 1999; Smith *et al.*, 1999a; 2000; Terrinoni *et al.*, 2001; Zhou *et al.*, 2007) and mutations in K6b or K17 lead to PC-2 (McLean *et al.*, 1995; Smith *et al.*, 1998). There is so far only one reported exception to this rule, in a case where there was considerable clinical

overlap between PC-1 and PC-2 (Ward *et al.*, 2003). The two phenotypes are closely correlated with the cell and tissue types in which these keratins are constitutively expressed: whilst K16 is a major secondary keratin in orogenital epithelia and in palmoplantar epidermis, K17 is only a minor component of these tissues in the fully developed epidermis, whereas it is significantly expressed in the deep hair follicle where the hair shaft is being formed. In steatocystoma multiplex, the cysts are formed in association with the hair follicle, and are known to be caused by mutations in the same K6b and/or K17 genes as PC-2 (Lane & McLean, 2004).

In general, the mutations are either heterozygous missense mutations or small-in-frame deletion/insertion mutations. To date, the majority of those reported fall within the highly conserved helix boundary domains at either end of the  $\alpha$ -helical rod domain. These regions are thought to be vital for end-to-end overlap interactions during the elongation phase of filament assembly (Liao *et al.*, 2007). The N171 codon of K6a is emerging as a mutation hotspot in PC-1, and in PC-2, the majority of mutations are in the helix initiation motif of K17 with mutations at two codons, N92 and R94 accounting for more than 50% of cases (Smith *et al.*, 2005).

However, as more pedigrees of PC are studied, rarer genetic variants have emerged. One candidate variant is late onset PC or 'PC tarda' (Munro, 2001). PC usually begins in infancy, but onset as late as the 4<sup>th</sup> or 5<sup>th</sup> decade has been reported (Paller *et al.*, 1991). These have been associated with less disruptive mutations. Connors *et al.* (2001) report a novel mutation in the mid-region of the 2B helical domain of keratin 16 compared to previously reported mutations which have affected one of the highly conserved peptide sequences at either end of the helical rod domain common to all keratin molecules. As with many other genetic disorders,

identification of the underlying keratin gene defects in PC has raised further questions. It is not fully understood why phenotype and age of onset may vary with the same mutation, and why mutations that are theoretically highly disruptive to filament assembly may in some subjects cause little disease (Munro, 2001).

### **1.15 Inherited PPK and desmosomes**

As mutations in keratins result in epidermal fragility, similarly mutations in the structural desmosomal proteins have been found to underlie other disease phenotypes (Kelsell & Stevens, 1999). Desmosomal proteins are the target antigens in several autoimmune blistering disorders: pemphigus vulgaris (desmoglein 3), pemphigus foliaceus (desmoglein 1), IgA pemphigus (desmocollins), and paraneoplastic pemphigus (desmoplakins, envoplakin, periplakin, plakoglobin, and desmogleins 1 and 3) (Amagai *et al.*, 1998; Anhalt *et al.*, 1999; Ishii *et al.*, 2001).

Desmosomal mutations have been found to underlie **striate PPK**, a rare group of autosomal dominant genodermatoses characterized by PPK with both focal and streaking, linear hyperkeratosis of the palm of the hand and extending along each finger. Armstrong *et al.* (1999) demonstrated a heterozygous C to T transition in exon 4 of the desmoplakin gene, causing a premature termination codon in the amino-terminal region of the peptide and resulting in haploinsufficiency. Rickman *et al.* (1999) demonstrated that a mutation in the desmoglein 1 gene caused aberrant splicing of exon 3, which would be expected to compromise strand dimer formation and the function of the first calcium-binding site of desmoglein 1. Therefore mutations in both the cadherin and plakin components of epidermal desmosomes have been implicated as causes of autosomal dominant non-syndromic striate PPK. Further genetic heterogeneity of striate keratoderma has been demonstrated by the

identification of a frameshift mutation in the V2 domain of human keratin 1 in a four-generation family of British descent (Whittock *et al.*, 2002a) (see chapter 2.3). Thus, the disorder displays locus heterogeneity in that it has been associated with mutations in the desmoplakin gene (Armstrong *et al.*, 1999; Whittock *et al.*, 1999; Norgett *et al.*, 2006), the desmoglein 1 gene (Rickman *et al.*, 1999; Kljuic *et al.*, 2003b), and the keratin 1 gene (Whittock *et al.*, 2002a). It is believed that the striking hyperkeratotic lesions in patients with striate keratoderma result from impaired function of the desmosomes at sites where these cell-cell junctions are most critical, namely the palms and soles (Whittock *et al.*, 1999). Mutations in other desmosomal proteins have been found to be associated with syndromic PPK (see chapter 2.3). **PPK, woolly hair and dilated left ventricular cardiomyopathy** (syn. Carvajal syndrome, OMIM 605676) is characterized by striate keratoderma, woolly hair and dilated left ventricular cardiomyopathy developing in teenage years due to mutation in desmoplakin (Carvajal-Huerta, 1998; Norgett *et al.*, 2000). **Naxos disease** (OMIM601214) is an autosomal recessive disorder characterized by arrhythmogenic right ventricular cardiomyopathy causing heart failure and sudden death, congenital woolly hair, and development of progressive, nonepidermolytic diffuse PPK, first reported in seven pedigrees from the Greek island of Naxos, due to mutation in plakoglobin (Protonotarios *et al.*, 1986; 2001; McKoy *et al.*, 2000). **“Skin fragility-woolly hair syndrome”** (OMIM 607655) is another recessive desmoplakin phenotype, consisting of keratoderma, woolly hair and nail dystrophy, but without cardiac abnormalities, due to mutation in desmoplakin (Whittock *et al.*, 2002b). **Ectodermal dysplasia/skin fragility syndrome** (OMIM604536) is an autosomal recessive disease resulting in trauma-induced skin erosions, dystrophic

nails, sparse hair, and painful PPK, due to mutation in plakophilin 1 (McGrath *et al.*, 1997).

### **1.16 Inherited PPK due to altered terminal differentiation: loricrin**

Loricrin, a small basic protein synthesized in the upper granular layer, becomes a major constituent of the CE (Ishida-Yamamoto *et al.*, 2000b). It is widely distributed in the epidermis in the granular layer and above. It is expressed at the final stage during the process of epithelial differentiation and occurs later than involucrin and profilaggrin expression. It is a unique structural protein, which is glycine-, serine- and cysteine-rich, highly insoluble, and 26kDa, consisting of 315 amino acid residues (Ishida-Yamamoto *et al.*, 1998a). Its multiple glycine loop motifs and glutamine/lysine residues are thought to be necessary for cross-linking CE formation (Korge *et al.*, 1997). Calcium and retinoids are both crucial regulators of loricrin expression, and the transcriptional control of loricrin and profilaggrin expression in the epidermis is closely coordinated (Kalinin *et al.*, 2002). The intensity of loricrin expression varies in different body sites: it is abundant in foreskin and perianal skin, but less so in leg skin (Ishida-Yamamoto *et al.*, 1998a).

The physiological and pathological significance of loricrin was initially highlighted by discoveries of mutations in the loricrin gene in the variant form of Vohwinkel's syndrome (VS) associated with ichthyosis but not deafness (Maestrini *et al.*, 1996; Korge *et al.*, 1997; Ishida-Yamamoto *et al.*, 1998a). This disorder (syn. **Loricrin Keratoderma**, Camisa's syndrome) was described by Camisa & Rossana (1984). Generalized desquamation at birth and collodion babies may be a feature (Matsumoto *et al.*, 2001; Gedicke *et al.*, 2006). It is due to mutations in loricrin (Maestrini *et al.*, 1996; Korge *et al.*, 1997; Armstrong *et al.*, 1998; Takahishi *et al.*,

1999b; Matsumoto *et al.*, 2001; O'Driscoll *et al.*, 2002; Gedicke *et al.*, 2006). Eight families with four different mutations in the loricrin gene have been reported so far. In each of these, point insertion mutations result a shift of the reading frame and a termination codon delayed by 22 amino acids. In the elongated carboxy-terminal domain many of the glycine loops are replaced by arginine residues, thereby drastically altering the physical and chemical properties of the loricrin polypeptide (Korge *et al.*, 1997; Ishida-Yamamoto *et al.*, 1998a). The most frequent mutation, 730insG, has been found in families from the UK (Maestrini *et al.*, 1996; Korge *et al.*, 1997; O'Driscoll *et al.*, 2002), Japan (Takahashi *et al.*, 1999b ; Matsumoto *et al.*, 2001) and Germany (Gedicke *et al.*, 2006).

### **1.17 Inherited PPK due to altered differentiation: connexins**

Many inherited keratodermas are associated with defects in gap junction communication. Mutations in Cx26 (Kelsell *et al.*, 1997), Cx 30 (Xia *et al.*, 1998) and Cx31 (Liu *et al.*, 2000; Grifa *et al.*, 1999) have not only been shown to underlie non-syndromic sensorineural hearing loss but also hearing loss in association with disorders of epidermal keratinisation (Kelsell *et al.*, 2001).

**Vohwinkel syndrome** (OMIM 124500), independently reported by Vohwinkel (1929) and Wigley (1929), is characterized by honeycomb-like keratoderma, starfish-like keratoses on the knuckles and circumferential digital bands ("pseudoainhum"). The association of autosomal dominant sensorineural deafness has been confirmed as a feature in later reports (Nockemann, 1961; Gibbs *et al.*, 1966; Ocaña-Sierra *et al.*, 1975; McGibbon & Watson, 1977; Wereide, 1984). Germline mutations in Cx26, initially found in 3 unrelated families, underlie the condition (Maestrini *et al.*, 1999). A heterozygous missense mutation, p.D66H, was

identified in *GJB2*, which encodes Cx26, in a large British pedigree containing 10 affected members which was also found in unrelated Spanish and Italian pedigrees. Cx26 is expressed in a wide variety of tissues, including the epithelial supporting cells surrounding the sensory hair cells of the cochlea and in the fibrocytes lining the cochlear duct (see section 1.8).

**Bart-Pumphrey syndrome** (OMIM149200) is an autosomal dominant condition characterized by knuckle pads, PPK, mixed sensorineural and conductive deafness and leukonychia (Bart & Pumphrey, 1967). Mutations in the *GJB2* gene have been reported (Richard *et al.*, 1998a; 2004; Alexandrino *et al.*, 2005; Leonard *et al.*, 2005). As not all family members reported showed leukonychia (Alexandrino *et al.*, 2005; Leonard *et al.*, 2005), it has been questioned whether this is a diagnostic feature in this phenotype (Akiyama *et al.*, 2007). As most pathogenic *GJB2* mutations causing both sensorineural hearing loss and skin manifestations cluster in the first extracellular loop of the Cx26 peptide (Richard *et al.*, 1998a; 2004; Maestrini *et al.*, 1999; Alexandrino *et al.*, 2005; Leonard *et al.*, 2005; Akiyama *et al.*, 2007), it suggests that this is important for the correct formation and/or function of gap junctions (Akiyama *et al.*, 2007).

**Hidrotic ectodermal dysplasia** (syn. Clouston syndrome) (OMIM129500) is an autosomal dominant disorder characterized by progressive, diffuse PPK with punctiform accentuation and relative sparing of palms, alopecia ranging from focal alopecia to universal loss of hair starting after puberty, nail dystrophy and variable features including sensorineural deafness, and is particularly prevalent in the French-Canadian population of Quebec (Clouston, 1929; 1939). Clouston syndrome been confused with PC due to the thick, ridged and short nails (van Steensel *et al.*, 2003),

although hypotrichosis or alopecia is not usually a feature in the latter, and has only rarely been reported (Templeton & Wiegand, 1997). Thus, the presence of alopecia in addition to hypertrophic nail dystrophy may be more suggestive of an underlying connexin rather than keratin defect. Mutations in *GJB6* encoding Cx30 were first identified in 12 Clouston syndrome families of varying ethnicity, clustered in two mutation hotspots, G11R and A88V (Lamartine *et al.*, 2000). A further mutation, p.V37E, in a Scottish case of Clouston syndrome has also been documented (Smith *et al.*, 2002).

**Erythrokeratoderma variabilis** (EKV) (OMIM133200) belongs to the clinically and genetically heterogeneous group of erythrokeratodermas, and although not classified as an inherited PPK, may present with palmoplantar hyperkeratosis. Mutations in the *GJB3* gene encoding Cx31 have been identified (Richard *et al.*, 1998b; 2000; Morley *et al.*, 2005) as well as mutations in the *GJB4* gene encoding Cx30.3 (Macari *et al.*, 2000; Richard *et al.*, 2003). Mild palmoplantar keratoderma has also been reported in **oculodentodigital dysplasia** (ODDD) (OMIM164200) caused by a heterozygous mutation in Cx43 (Gong *et al.*, 2006).

### 1.18 Other PPKs

It is already apparent that PPK can be the result of a variety of different processes. Other rare keratoderma syndromes indicate that there are many other pathways involved.

**Papillon-Lefèvre syndrome** (PLS) (OMIM245000) is a rare autosomal recessive disease that is characterized by erythematous PPK and early-onset periodontitis resulting in loss of primary and secondary teeth, and frequent pyogenic skin infections (Papillon & Lefèvre, 1924; Gorlin *et al.*, 1964; Haneke, 1979). **Haim-**



**Munk syndrome** (HMS) (OMIM245010) is a rare autosomal recessive PPK with similar features as PLS, but distinguished by arachnodactyly, acro-osteolysis, onychogryphosis and pes planus (Haim & Munk, 1965).

The PLS and HMS disease locus was mapped to chromosome 11q14-q21, a region where the lysosomal protease cathepsin C gene (*CTSC*) maps, by three independent linkage studies (Fischer *et al.*, 1997; Laass *et al.*, 1997; Hart *et al.*, 1998). Cathepsin C (dipeptidylpeptidase I) is a lysosomal papain-like cysteine proteinase capable of removing dipeptides from the amino-terminals of protein substrates, and loss-of-function mutations were simultaneously reported in PLS (Toomes *et al.*, 1999; Hart *et al.*, 2000). Subsequently, more than 50 mutations in *CTSC* have been reported in families with both PLS (Selvaraju *et al.*, 2003; Hewitt *et al.*, 2004; Jouary *et al.*, 2008) and HMS (Hart *et al.*, 2000; Cury *et al.*, 2005). Missense and nonsense mutations are the most frequent, but small deletions, insertions and splice site mutations have also been reported (Selvaraju *et al.*, 2003; Jouary *et al.*, 2008).

**Mal de Meleda** (OMIM248300) is a rare autosomal recessive PPK characterized by erythematous PPK, palmoplantar hyperhidrosis, hyperkeratotic plaques over joints, perioral erythema, brachydactyly and nail abnormalities, first described on the Adriatic island of Meleda, now Mljet, in Croatia (Hovorka & Ehlers, 1897; Neumann, 1898; Schnyder *et al.*, 1969). Three different homozygous mutations in the gene encoding for SLURP-1 (secreted mammalian Ly-6/uPAR-related protein 1) were found to underlie Mal de Meleda in 19 Algerian and Croatian families (Fischer *et al.*, 2001). Subsequently, further mutations have been reported in Tunisian and Turkish families (Charfeddine *et al.*, 2003; Hu *et al.*, 2003). SLURP-1

is a secreted member of the Ly-6/uPAR superfamily of proteins that shares significant homology with secreted snake and frog cytotoxins. It potentiates the action of acetylcholine on the  $\alpha 7$  nicotinic receptor, which plays an important role in the differentiation of stratified squamous epithelia (Kurzen *et al.*, 2004).

Recombinant SLURP1 has a proapoptotic effect on keratinocytes and upregulates the expression of transglutaminase 1, keratin 10, p21, and caspase-3 (Arredondo *et al.*, 2002).

Mitochondrial mutations have been reported in association with a variety of multisystem disorders, often with sensorineural deafness as a common symptom (Wallace, 1993). A mitochondrial mutation A7445G has been reported that co-segregates with variable expressivity of PPK and progressive deafness in a number of pedigrees (Reid *et al.*, 1994; Seviior *et al.*, 1998; Martin *et al.*, 2000). Although Reid *et al.* did not report palmoplantar involvement, its presence in their family was confirmed (C Munro, personal communication). The A7445G point mutation in mtDNA consists of an adenine to guanine substitution found in homoplasmic form in leucocytes from patients with the NEPPK-deafness combination (Seviior *et al.*, 1998; Martin *et al.*, 2000) which serves to add serine to elongating protein chains during mitochondrial synthesis. The penetrance and expressivity of PPK and deafness varied in the pedigrees, suggesting that additional environmental and/or genetic factors are involved (Reid *et al.*, 1994).

Tyrosine aminotransferase deficiency causes PPK, dendritic corneal ulcers and progressive mental impairment in the condition **oculocutaneous tyrosinaemia** (syn. Tyrosinaemia type II, Richner-Hanhart syndrome). It is an autosomal recessive condition caused by homozygous defects of the tyrosine aminotransferase gene at

16q21.1-q22.3 (Fellman *et al.*, 1969). Deficiency of the enzyme leads to increased levels of serum tyrosine (Bonhert *et al.*, 1982).

### **1.19 Conclusion**

In pathological thickening of palmoplantar skin, even considering only those forms due to inherited gene mutation, it is apparent that a variety of mechanisms must be activated. Identifying underlying mutations has provided information about the functional importance of proteins involved in the differentiation of palmoplantar keratinocytes, but the mechanisms by which the molecular defects cause the clinical phenotype remain obscure. Nonetheless, the pathways of pathological hyperkeratosis in inherited PPK serve as a model for a wider spectrum of common conditions in which palmoplantar hyperkeratosis is a cause of significant morbidity, in the expectation that better understanding may lead to better management. While restricting this study to the inherited PPKs, in order to investigate the variety of possible mechanisms of palmoplantar hyperkeratosis, families representative of different underlying causes have been studied.





## **Chapter 2.1 Clinical Characterisation of the Inherited Palmoplantar**

### **Keratodermas**

#### **2.1.1 Introduction**

The inherited PPKs are an extremely heterogeneous group of skin diseases that can be classified on the basis of the pattern and age of onset of hyperkeratosis on the palm and sole, on their associated features and syndromes and, more recently, by their inherited genetic defect (Lucker *et al.*, 1994; Itin & Lautenschlager, 1995; Stevens *et al.*, 1996; Ratnavel & Griffiths, 1997; Judge *et al.*, 2004; Itin & Fistarol, 2005) (see chapter 1). Due to the rarity of these conditions, they have been difficult to characterize and investigate. It is known that clinical patterns may not be consistent within families, and indeed allocation to, for example, focal and diffuse forms may be difficult. No controlled prospective clinical trials have been published other than a comprehensive review and report of new phenotypic data undertaken for PC (Leachman *et al.*, 2005). Publications are biased towards extreme or unusual manifestations of these conditions, or unusual associations which in isolated cases may be coincidental. There has been relatively little exploration of the spectrum of clinical or pathological phenotypes that may be observed. This study provided an opportunity for systematic documentation and assessment of clinical features and response to treatment in this cohort of inherited PPKs.

#### **2.1.2 Methods**

Patients were recruited to the study from a tertiary referral genodermatoses clinic for the West of Scotland or from cases known to the department. For the purposes of

skin biopsy, patients who were pregnant, under the age of 18 years, receiving anticoagulants, with known arterial disease or peripheral neuropathy, or unable to give consent were excluded. A detailed explanation of the nature of the study was given to the patients in conjunction with a Patient Information Leaflet (Addendum A). Informed consent was obtained. Approval was obtained from the Ethical Committee of the Southern General Hospital, Glasgow. Documentation of the clinical phenotype in palmoplantar and other affected tissues was carried out, specifically looking at symptoms, signs and prior response to treatment. The clinical pattern of PPK was recorded in each individual studied. As the expression of several implicated genes (keratins, loricrin) is tissue and differentiation specific, the history and clinical findings were closely assessed in each case, specifically examining features such as hair and nail changes, mucosal, periodontal, and laryngeal disease, keratitis, sensorineural deafness, and other neuropathies. Family trees were documented for all pedigrees.

#### **2.1.2.1 History**

A standard questionnaire (Addendum B) was devised and used to ensure accurate documentation in all patients of the following: date of birth; gender; occupation; sites of hyperkeratosis (e.g. balls of feet, toes – plantar, lateral or dorsal aspects, palms, heels etc.); type of hyperkeratosis: focal, diffuse, striate, punctate, transgradient (keratoderma extending beyond palmoplantar skin); colour of palms and soles; texture (smooth, rough, fissured); presence or absence of erythema or blistering on palms or soles; associated pain; hair changes (e.g. woolly/unruly); nail changes; presence of knuckle pads; presence of mucosal, periodontal or laryngeal disease; history of keratitis; sensorineural deafness; other neuropathies; history of vaginal or

cervical abnormalities, or phimosis; difficulty with lactation or sweating. A full past medical history, drug history, any known drug allergies, and any previous therapies for keratoderma were also noted.

### **2.1.2.2 Examination**

A full physical examination of the skin was performed, including hair and nails. Where deemed appropriate, a physical examination of other systems was also performed. Clinical photography was performed, following informed consent.

## **2.1.3 Results**

### **2.1.3.1 Patients recruited**

Sixteen patients with inherited PPK (15 with known underlying mutations and one whose mutation was ascertained during the course of the study, chapter 2.3) were recruited to the study (Table 3) from known local pedigrees. Pedigrees had already been documented in those pedigrees with known mutations at the time of recruitment and were re-confirmed, but a full pedigree was documented for the striate PPK pedigree (chapter 2.3).

### **2.1.3.2 Clinical Findings**

Of the 16 patients recruited, 9 were female and 7 male. Their mean age was 48.1 years (range 34-78). The range of clinical features in the cohort of patients is summarised (Table 4). Occupational history revealed that 5/16 PPK patients had experienced some difficulty in a particular job, with deterioration of the hyperkeratosis due to the nature of the work e.g. metal sheet worker whose palmar hyperkeratosis worsened (K1). 2/5 had to change occupation as a result and 2/5 had taken early retirement on health grounds. All patients complained that the texture of



**Table 3. Summary of inherited PPK patients recruited to the study.**

Affected Gene	Type of PPK	Mutation	Reference	No. patients
Keratin 1	Mild Epidermolytic	G4124A	Hatsell <i>et al.</i> , 2001	2
Keratin 9	Epidermolytic	1362ins3	Coleman <i>et al.</i> , 1999	1
		R162Q	Covello <i>et al.</i> , 1998a	1
				<b>Total 2</b>
Keratin 17	PC-2	N92D	McLean <i>et al.</i> , 1995	6
	PC-2	N92S	Covello <i>et al.</i> , 1998b	2
				<b>Total 8</b>
Desmoglein 1*	Striate	p.Arg144stop	Chapter 2.3	1
Loricrin	Loricrin	InsG231	Korge <i>et al.</i> , 1997	2
Mitochondrial DNA	PPK and deafness	A7445G	Reid <i>et al.</i> , 1994	1
				<b>Grand Total 16</b>

PC-2= Pachyonychia congenita type 2; \*Mutation in Desmoglein 1 identified during course of study, see chapter 2.3

**Table 4. Summary of clinical findings in cohort of inherited PPK patients**

Phenotype	K1 (n=2)	K9 (n=2)	K17 (n=8)	DSG1 (n=1)	Loricrin (n=2)	Mitochondrial (n=1)
Focal hyperkeratosis palms	1/2	0/2	1/8	1/1	1/2	1/1
Diffuse hyperkeratosis palms	1/2	2/2	0/8	0/1	1/2	0/1
Focal hyperkeratosis soles	2/2	0/2	8/8	1/1	1/2	1/1
Diffuse hyperkeratosis soles	0/2	2/2	0/8	0/1	1/2	0/1
Hyperkeratosis knees/elbows	0/2	1/2	0/8	1/1	1/2	0/1
Presence of pseudoainhum	0/2	0/2	0/8	0/1	1/2	0/1
Toenails	1/2	1/2	8/8	0/1	0/2	0/1
Fingernails	0/2	1/2	8/8	0/1	0/2	0/1
History of blistering	0/2	2/2	6/8	1/1	0/2	1/1
Plantar pain	1/2	1/2	8/8	1/1	2/2	1/1
Erythema	0/2	2/2	2/8	1/1	2/2	0/1
Follicular keratoses	0/2	0/2	6/8	0/1	0/2	0/1
Cysts (any type)	0/2	0/2	8/8	0/1	0/2	0/1
Natal teeth	0/2	0/2	3/8	0/1	0/2	0/1
Laryngeal/Periodontal/Mucosal abnormalities	0/2	1/2	6/8*	0/1	1/2**	0/1
Hyperhidrosis	1/2	1/2	7/8	1/1	2/2	1/1
Knuckle pads	0/2	1/2	0/8	0/1	2/2	0/1
Sensorineural deafness	1/2	0/2	0/8	0/1	0/2	1/1
Unruly/wiry hair	0/2	0/2	1/8	0/1	0/2	0/1
Abnormal eyebrows	0/2	0/2	5/8	0/1	0/2	0/1
Abscesses	0/2	0/2	8/8	0/1	0/2	0/1

\* see section 2.1.3.3; \*\*upper dentures in later life

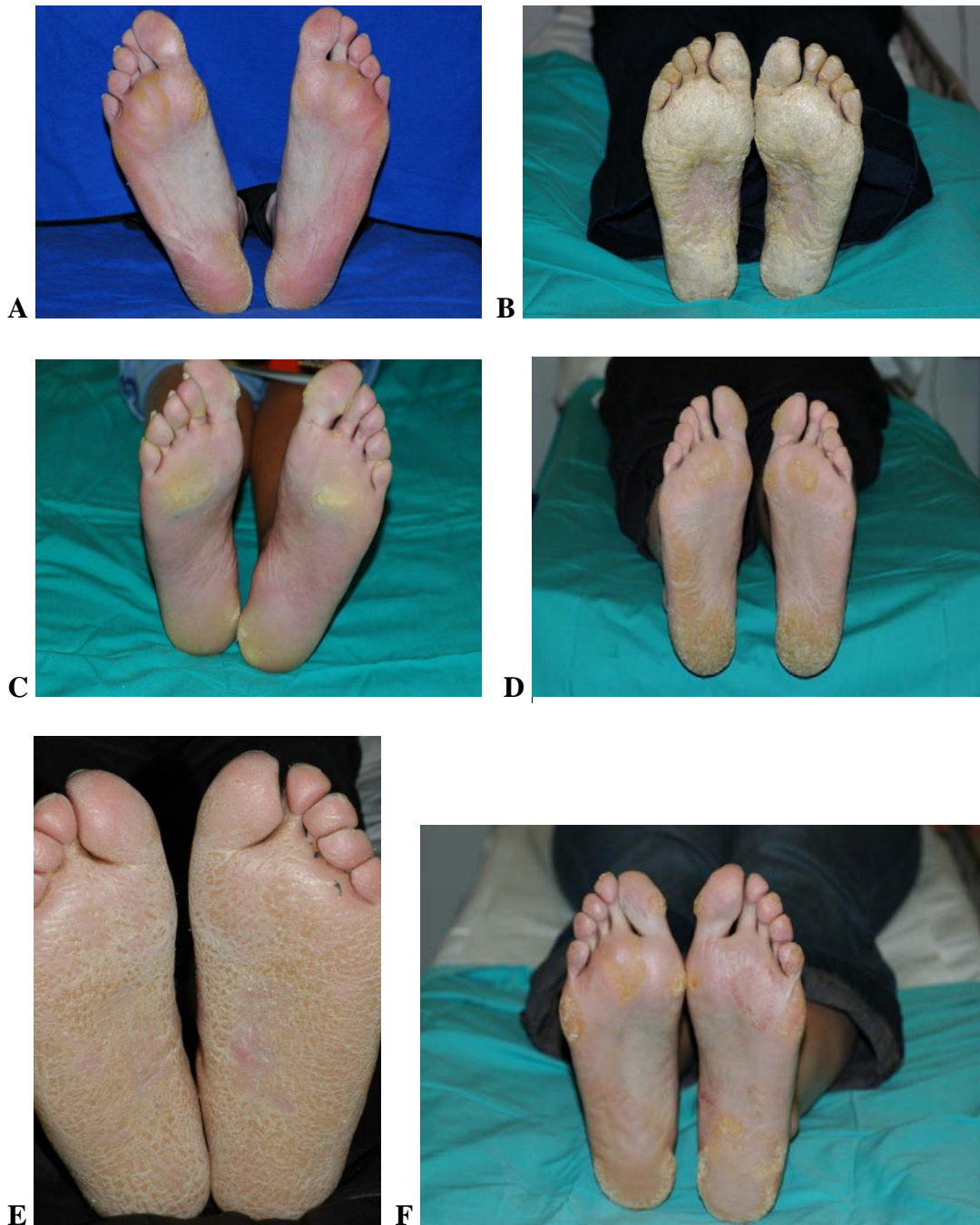their hyperkeratosis would become rough and fissured if not pared regularly, and 14/16 patients had smooth hyperkeratosis due to their own regular manual paring (Figures 6-9). All patients developed symptoms “in childhood”, with no clear differences in onset between different subtypes. Minimal information was available regarding the neonatal history of the patients recruited.

*Plantar pain and hyperhidrosis were the most common symptoms across all subtypes of inherited PPK; intermittent “shedding” of skin was specific to K9 subtype.*

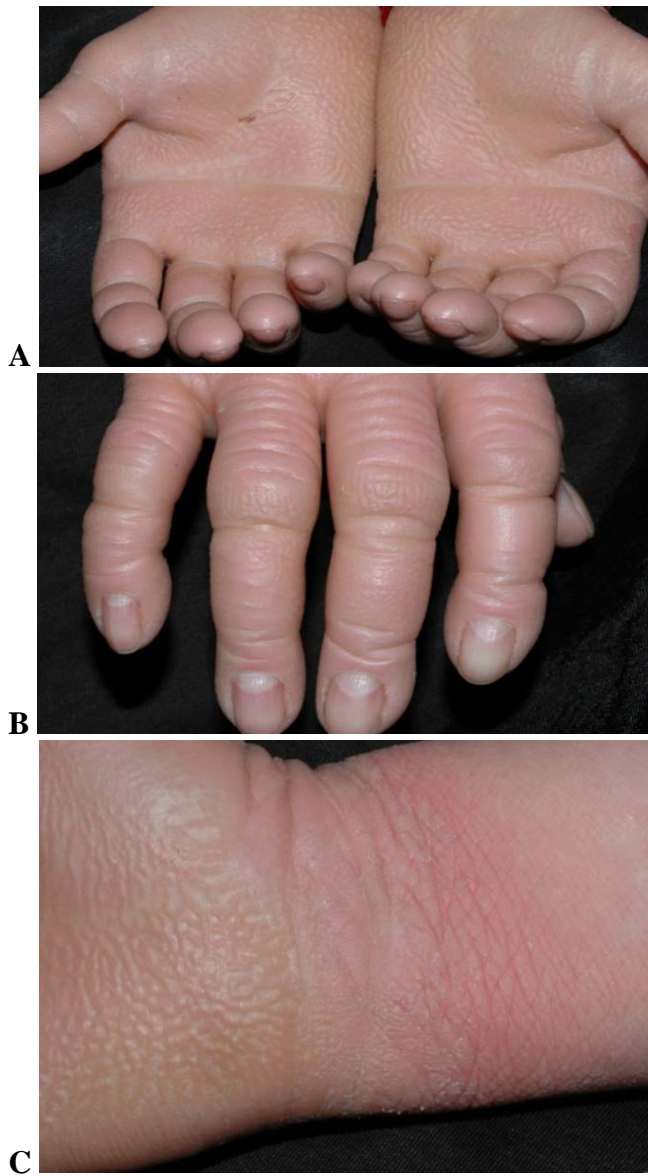
14/16 complained of plantar pain and 15/16 of hyperhidrosis (particularly palmoplantar). 10/17 patients complained of intermittent blistering, which was uniformly at pressure points/post trauma. 2/2 K9 patients experienced intermittent “shedding” of their skin, whereby the hyperkeratotic areas would simply peel off spontaneously every 6-12 months, a symptom specific to this subtype. 3/8 K17 and 1/2 Loricrin (both male and female) patients complained of very sparse axillary and pubic hair.

*Recurrent abscesses, cysts, toe and fingernail dystrophy were common features in pachyonychia congenita type 2*

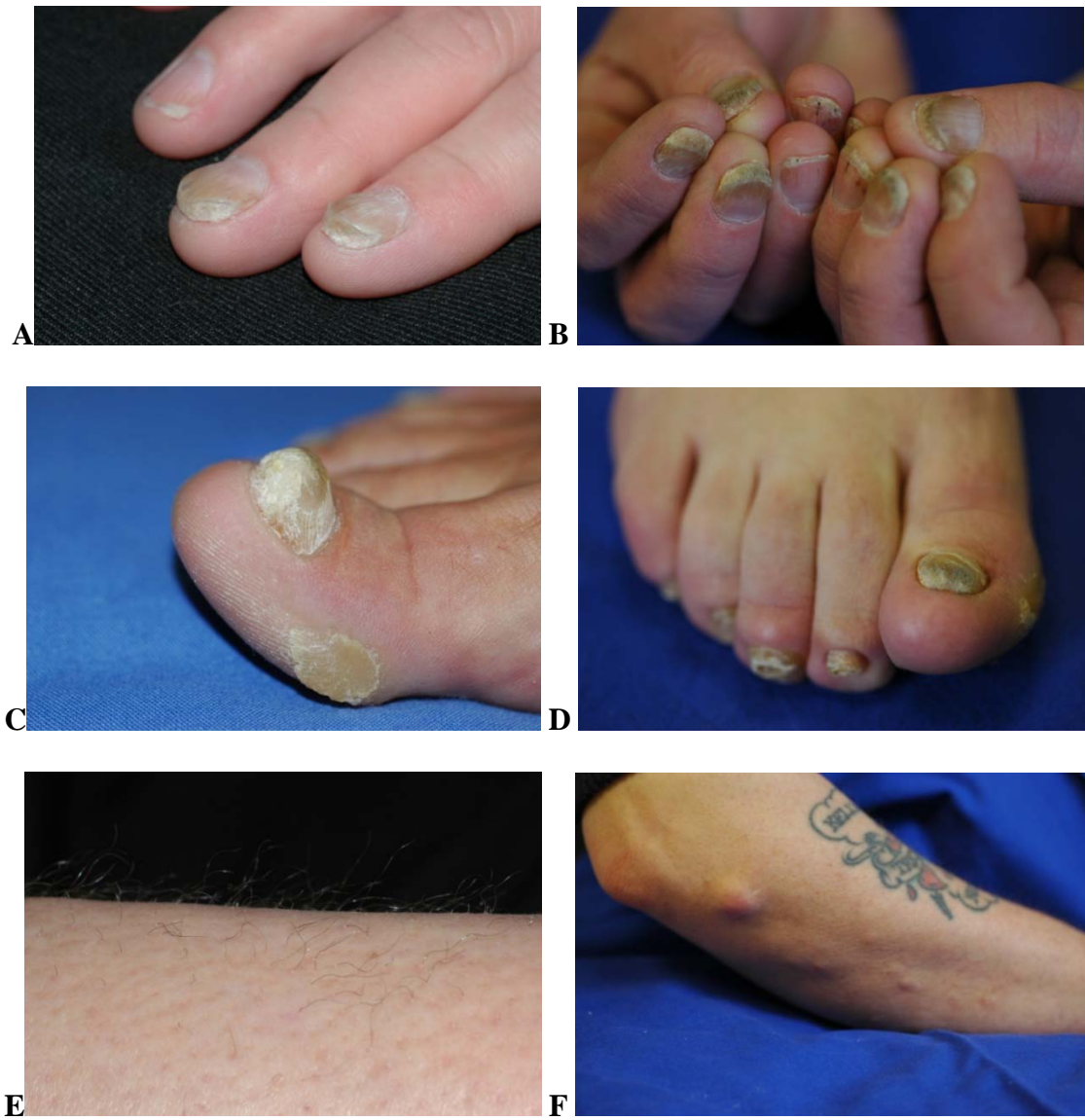Aside from focal plantar hyperkeratosis, the most common findings among the K17 patients were onychodystrophy (both finger and toenail) (100%), plantar pain (100%), recurrent abscesses (100%), recurrent cysts (100%) and hyperhidrosis – specifically plantar (87.5%) (Figure 8). All patients complained of recurrent abscesses in axillary and pubic regions, requiring multiple courses of antibiotics,



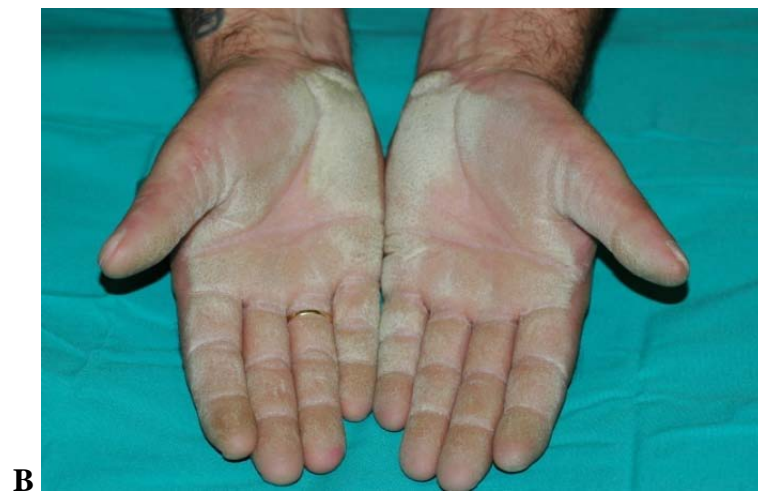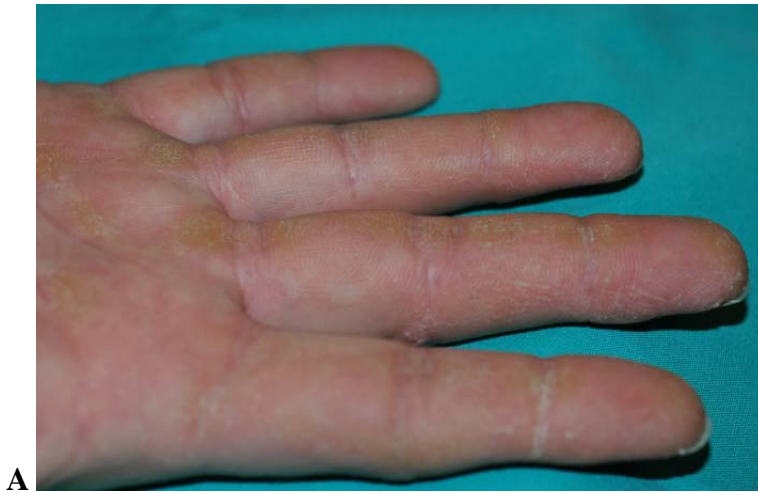**Figure 6. Plantar keratoderma in inherited PPK due to underlying K1, K9, K17, DSG1, loricrin and mitochondrial mutations (a, b, c, d, e and f respectively).** Diffuse hyperkeratosis evident in (b) and (e), with evidence of a honeycomb pattern in the latter. Focal hyperkeratosis in (a, c, d and f) involving the plantar surface and extending to the medial surface of the great toe, a site of friction. Distribution of pressure point hyperkeratosis is variable.



**Figure 7. Clinical photographs of loricrin keratoderma, showing evidence of honeycomb pattern of palmar hyperkeratosis (a), pseudo-ainhum (a, b) and hyperlinearity and erythema of the wrist (c).**



**Figure 8. Clinical photographs of pachyonychia congenita type 2 demonstrating onychodystrophy (a, b, c, d), pili torti (e) and cysts (f). Variation in nail thickness and subungal hyperkeratosis is apparent in (a, b, c, d).**



**Figure 9.** Striate/focal palmar hyperkeratosis (a) in underlying desmoglein 1 mutation (see chapter 2.3) compared to diffuse hyperkeratosis (b) in underlying K9 mutation.

incision and drainage, or excision. The history was consistent with secondarily infected cysts.

*The majority of inherited PPK patients were receiving minimal treatment other than manual paring.*

Previous treatments including manual paring (16/16); emollients (16/16); topical salicylic acid (3/16). 5/16 PPK patients had been prescribed oral retinoids (1/2 K9, 1/2 Loricrin, 2/8 K17, 1/1 DSG1) of whom 2 were still taking them. The average dose was 30mg (range 20-50mg), and duration of treatment ranged from 6 months to 15 years. Effect of treatment ranged from minimal effect (2/5), specific improvement in nail dystrophy (1/5) to moderate improvement in hyperkeratosis (2/5). 1/2 Loricrin patient stopped oral retinoids due to skin thinning and peeling; he had also undergone surgery for constricting digital bands. 1/8 K17 PPK patients had received cautery and 1/8 oral antibiotics, incision and drainage, for the treatment of cysts.

*Focal Hyperkeratosis is most common on the plantar surface of the metatarsal area, the ball and the heel of the foot*

Those patients with focal plantar hyperkeratosis were specifically assessed for particular patterns/sites where hyperkeratosis was most common or most severe (Table 5). 13/16 PPK patients had focal plantar hyperkeratosis, including one patient with loricrin keratoderma but with a milder phenotype resulting in focal, not diffuse, hyperkeratosis only. The plantar surface of the metatarsal area was uniformly affected, with the balls and heels being affected in the majority. Extension of hyperkeratosis to medial or lateral aspects of the toes/feet was not restricted to a

particular subtype. Keratoderma was uniformly more severe on plantar compared to palmar surfaces. Although accentuated in pressure points of feet, or areas of chronic use of the hands, no other clear patterns of distribution of hyperkeratosis became apparent.

**Table 5. Pattern of focal plantar hyperkeratosis in cohort of inherited PPK patients with underlying K1, K17, DSG1, loricrin and mitochondrial mutations.**

Pattern	K1 (n=2)	K17 (n=8)	DSG1 (n=1)	Loricrin (n=1)	Mitochondrial (n=1)
Plantar metatarsal area	2/2	8/8	1/1	1/1	1/1
Ball of foot	2/2	5/8	1/1	1/1	1/1
Heel	2/2	6/8	1/1	1/1	1/1
Medial aspect great toe	0/2	3/8	0/1	0/1	1/1
Extension to lateral surfaces	2/2	4/8	0/1	0/1	1/1

### 2.1.3.3 Abnormal adult dentition in PC-2

During clinical assessment of the pedigrees recruited, it was noted that a large multigeneration family (Figures 6 & 8) with PC-2, having a known heterozygous missense mutation in the helix initiation motif of K17 (Asn92Asp) (McLean *et al.*, 1995) exhibited abnormal adult dentition. Of 18 affected members over 2 generations available for interview, 7 reported having either full or upper dentures fitted in their late teenage years due to “crumbling” and exaggerated friability of their adult teeth. There was no history of increased caries. All affected patients had been initially treated with multiple crowns to prevent the disintegration of their teeth, without benefit. This history is suggestive of either enamel loss or attrition, but it has not been possible directly to assess any affected teeth. By contrast, none of their 9 unaffected siblings had dentures or any similar dental problems (Zamiri *et al.*, 2008; Addendum C).



### **2.1.3.4 Associated extracutaneous features**

1/1 patient with PPK due to mitochondrial DNA mutation had bilateral sensorineural deafness, diagnosed at the age of five. 1/2 K1 patients had a history of sensorineural deafness which had developed in later life, as had his affected father and daughter but other family members affected by PPK were not affected by hearing loss. 1/8 K17 patient had had a cerebral haemorrhage in her 20s, resulting in unilateral loss of vision and a history of treated hyperthyroidism. 1/8 K17 patient had a co-existent diagnosis of multiple sclerosis. 1/2 Loricrin and 1/8 K17 patients complained of recurrent gingivitis, and 1/8 K17 patient suffered recurrent mouth ulceration.

## **2.1.4 Discussion**

### **2.1.4.1 Clinical features of the inherited PPKs**

Phenotypic variations seen in affected PPK members who have inherited the same disease-causing mutation suggest that age, lifestyle and/or modifying genetic factors affect the clinical manifestation of PPK (Kelsell & Stevens, 1999). The findings of this study confirm the suspicion that the common clinical classification of PPKs may be a poor guide to the underlying mutation. Significant differences in the severity of disease in individuals within the same pedigree with the same underlying mutation were observed.

Mild diffuse keratoderma has generally been reported with underlying K1 mutations (Hatsell *et al.*, 2001; Terron-Kwiatkowski *et al.*, 2002; 2004; 2006) however at the time of clinical assessment, both K1 patients in our cohort displayed mild focal plantar keratoderma. One patient previously described more generalised hyperkeratosis prior to his retirement, when he was more active, indicative of the

variation of clinical features over time, and being dependent on lifestyle/modifying environmental factors. Atypical EPPK where the keratoderma was not strictly limited to the palms and soles but extended slightly on the wrists and flexures has been found in association with underlying K1 mutations (Terron-Kwiatkowski *et al.*, 2004).

Similarly, striate PPK (Whittock *et al.*, 2002a) and NEPPK associated with extension of hyperkeratosis from the sole along the Achilles tendon and occasionally the extensor tendon of the great toe have been reported (Kimonis *et al.*, 1994). EPPK (Vörner type) associated with underlying K9 mutations (Reis *et al.*, 1992; 1994) has been characterised clinically by a diffuse pattern of severe hyperkeratosis limited to the palms and soles and histologically by suprabasal epidermolysis (Vörner, 1901). These features were seen in both K9 PPK patients assessed in this cohort.

The most common clinical features of PC-2 in this cohort (plantar keratoderma, plantar pain, hyperkeratosis, cysts and onychodystrophy) correlate with the findings of an analysis of cases from the International Pachyonychia Congenita Research Registry (IPCRR), cases from the National Registry for Ichthyosis and Related Disorders (NRIRD) and new prospective data of 57 PC patients (Leachman *et al.*, 2005). The IPCRR data are strongly skewed to PC-1 (K6a/K16) cases, explaining some of the differences noted with this cohort of 8 K17 PPK patients (Table 6). Recurrent abscesses were uniformly a significant feature in this cohort most likely due to secondary infection of cysts. PC-2 patients have been found to develop all types of cysts, including epidermal inclusion cysts, pilosebaceous cysts, steatocystomas and vellus hair cysts (Leachman *et al.*, 2005). Follicular keratoses of

**Table 6. Summary of phenotypic symptoms in PC-2 recruited in this study compared to PC case studies, IPCRR and NRIRD data (table adapted from Leachman *et al.*, 2005).**

Phenotype	Case studies (n=481)	IPCRR (n=57)	NRIRD (n=11)	Current study (n=8)
Toenails	426 of 435 (98%)	55 of 57 (98%)	9 of 10 (90%)	8 of 8 (100%)
Fingernails	424 of 434 (97%)	56 of 57 (98%)	10 of 11 (91%)	8 of 8 (100%)
Plantar pain	71 of 74 (96%)	54 of 57 (95%)	10 of 11 (91%)	8 of 8 (100%)
Plantar keratoderma	288 of 312 (92%)	55 of 57 (96%)	10 of 11 (91%)	8 of 8 (100%)
Oral leukokeratosis	216 of 309 (95%)	43 of 57 (75%)	NR	0 of 8 (0%)
Palmar keratoderma	171 of 215 (80%)	35 of 57 (60%)	7 of 11 (63%)	1 of 8 (12.5%)
Follicular keratoses	149 of 189 (79%)	37 of 57 (65%)	NR	6 of 8 (75%)
Cysts (any type)	72 of 100 (72%)	20 of 57 (35%)	NR	8 of 8 (100%)
Larynx (hoarseness)	31 of 44 (70%)	9 of 57 (16%)	NR	0 of 8 (0%)
Hyperhidrosis	111 of 169 (66%)	42 of 53 (79%)	4 of 11 (36%)	7 of 8 (87.5%)
Hair abnormalities	64 of 120 (53%)	15 of 57 (26%)	0 of 11 (0%)	6 of 8 (75%)
Natal/prenatal teeth	54 of 108 (50%)	1 of 53 (2%)	0 of 11 (0%)	3 of 8 (37.5%)

IPCRR = International Pachyonychia Congenita Research Registry; NRIRD = The National Registry for Ichthyosis and Related Disorders; NR = not reported

variable severity were reported by the majority in this cohort. However, both studies may be subject to ascertainment bias, because patients with more severe disease are probably more motivated to participate in surveys or studies.

Plantar hyperkeratosis was more severe than palmar hyperkeratosis in all subtypes of inherited PPK, reflecting their weight-bearing role and trauma due to mobility, although other patterns of distribution of hyperkeratosis did not emerge. It is probable that chronic manual work (e.g. post office sorting, metal sheet work) exacerbated palmar involvement in K1 and Loricrin subtypes, although this only occurred in 2 patients. It was clear from this cohort of 16 PPK patients that their choices of employment, and any subsequent changes in work, were influenced by their disease. A limitation of this study in comparison of clinical features between different subtypes of inherited PPK is the small number of each subtype recruited. In the IPCRR questionnaire, 12 of 57 participants reported that they were unable to work or attend school because of the severity of their condition, with plantar pain being identified as the most disabling feature (54 of 57) (Leachman *et al.*, 2005).

Significant differences in severity of disease were also seen within the loricrin pedigree e.g. in the uncle with severe diffuse palmoplantar hyperkeratosis with constricting digital bands (pseudoainhum) compared with his nephew with mild focal palmoplantar hyperkeratosis. Honeycomb keratoderma was apparent in both cases, but very mild in the latter case with only very subtle clinical features of ichthyosis which could easily have been overlooked if the family history was not known. These two features have previously been reported in all families with loricrin mutations to date (Maestrini *et al.*, 1996; Korge *et al.*, 1997; Armstrong *et al.*, 1998; Takahishi *et al.*, 1999b; Matsumoto *et al.*, 2001; O'Driscoll *et al.*, 2002; Gedicke *et*

*al.*, 2006). Other features including pseudoainhum, prominent knuckle pads and collodion baby were not uniformly present in the two patients recruited in this study, reflecting previous reports, where autoamputations/mutilating keratoderma were only observed in three families (Maestrini *et al.*, 1996; Korge *et al.*, 1997; O'Driscoll *et al.*, 2002).

#### **2.1.4.2 Abnormal adult dentition in PC-2**

One of the striking features of PC-2 is the frequent first presentation with primary dentition erupted at birth (pre-natal or natal) or within the first 30 days of life (neonatal). Frontal teeth are typically affected; they are soft, friable, and said to be prone to caries, usually being lost within the first few months of life (Clementi *et al.*, 1986; Feinstein *et al.*, 1988; Munro, 2001). In addition to natal teeth, early multiple tooth development at 4-5 months and in one case, early natal tooth loss without immediate permanent tooth replacement, have been reported (Leachman *et al.*, 2005). Hutchinson-like tooth deformity in the absence of congenital syphilis, in a 6 year old boy with PC-2 due to a missense mutation in K17 has also been reported (Oh *et al.*, 2006).

In some cases, second primary teeth, non-permanent teeth occurring after the loss of natal teeth, will develop in addition to the natal teeth but have been thought to be ultimately replaced by normal permanent teeth during childhood. Histologically, the polypean dental papillae of these natal teeth show mucosal hyperplasia and irregular rete ridge proliferation. Cytoplasmic vacuolization and oedema are seen in the upper and spinous layers of the mucosa. Irregular osteodentine-like structures with cell inclusions and interglobular dentine are seen (Anneroth *et al.*, 1975). K17

expression has been described in the early stages of epidermal appendage development (McGowan & Coulombe, 1998) and in the predominantly hard portion of the hair shaft (McGowan & Coulombe, 2000), but its expression in tooth progenitors is not known.

Although the premature loss of primary teeth in conjunction with early eruption may be of no clinical significance, the clinician should not overlook loss of primary or permanent teeth in the absence of trauma (Hartsfield, 1994). Non-traumatic early loss of adult dentition is usually caused by caries or destructive periodontal disease. It is possible that the abnormal dentition in PC-2 may be a result of dentine abnormality, which is non-keratin related, instead of a keratin-related enamel abnormality.

Abnormalities in adult teeth have not previously been described in PC-2. However, we were only able to obtain a history of unusual increased friability, suggesting a dentine abnormality, and not of caries. Dental friability has not previously been noted and as only some members were affected, it may be multifactorial with K17 mutation contributing indirectly. The effect might alternatively be specific to the Asn92Asp mutation. The presence in PC-2 of structurally abnormal, premature teeth and possibly adult teeth suggests that K17 expressing keratinocytes play an important role in odontogenesis and tooth eruption and is an area for further study (McLean *et al.*, 1995). It is possible that this finding is unique to this particular family or their circumstances as it has not been supported by the PC database (Leachman, personal communication). However, it would still be advisable to ensure that PC-2 patients have appropriate dental examination and care.

### **2.1.4.3 Pain, hyperhidrosis and the inherited PPKs**

Pain and hyperhidrosis were the most important symptoms for many patients.

Hyperhidrosis has been commonly described in association with the inherited PPKs.

The feet most usually are involved as often they are malodorous and sweaty as well as hyperkeratotic and often complicated by a high ambient temperature (Schönfeld, 1980; Feinstein *et al.*, 1988; Judge *et al.*, 2004; Itin & Fistarol, 2005; Leachman *et al.*, 2005). Water retention by abnormally keratotic and porous stratum corneum probably contributes to maceration and microbial overgrowth, although it is possible that in addition, there is a real increase in sweat excretion (Judge *et al.*, 2004). It is thought that plantar pain is also exaggerated by excessive plantar sweating, especially at high ambient temperatures, as frank blistering may occur below the hyperkeratosis, with friction from footwear and tissue maceration from sweating being contributing factors (Swartling & Vahlquist, 2006).

Hyperhidrosis, even in the absence of other associated conditions such as PPK, is an embarrassing condition and poses a management challenge. Specific recommendations for the treatment of plantar hyperhidrosis include education regarding local hygiene, using an absorbent foot powder twice daily, and avoiding occlusive boots or sports shoes; the use of topical aluminium chloride (AlCl<sub>3</sub>); tap water iontophoresis and intradermal botulinum toxin with appropriate analgesia (Hornberger *et al.*, 2004). Lumbar sympathectomy has been reserved for severe cases but condemned due to severe side-effects e.g. sexual dysfunction (May *et al.*, 1969). Systemic anticholinergic agents commonly give side-effects of dry mouth, visual disturbance, urinary retention and urgency, flushing and constipation (Kim *et al.*, 2003) limiting their use.

Far fewer studies have been directed at the treatment of plantar compared to other forms of focal hyperhidrosis as it is thought to be less common or perceived as less problematic than axillary or palmar disease (Hornberger *et al.*, 2004). Of 139 patients in a larger observational study, 84% had a good or excellent response to topical 30-40% AlCl in a salicylic acid gel (Benohanian *et al.*, 1998). A study of topical 25% AlCl in absolute ethanol resulted in 10/11 patients achieving euhidrosis (Jensen & Karlsmark, 1980). Response rates to tap water iontophoresis were in excess of 90% in 5 observational studies (Bouman, 1952; Grice *et al.*, 1972; Abell & Morgan, 1974; Shrivastava & Singh, 1977; Akins *et al.*, 1987). Treatment of plantar hyperhidrosis in inherited PPK has been reported with standard topical therapies including aluminium chloride which may reduce blistering (Tidman & Wells, 1988), and plantar injections of botulinum toxin using Bier's block for anaesthesia have also been described in PC, giving both dryness and relief of plantar pain for approximately 3 months (Swartling & Vahlquist, 2006) (see Appendix A).

However, data on the prevalence of hyperhidrosis may differ depending on how it is defined. Primary focal hyperhidrosis is defined as focal, visible, excessive sweating of at least 6 months duration without apparent cause with at least two of the following characteristics: bilateral and relatively symmetric, impairs daily activities, frequency of at least one episode per week, age of onset less than 25 years, positive family history and cessation of focal sweating during sleep (Hornberger *et al.*, 2004). Although plantar hyperhidrosis has been reported in inherited PPK, and this was confirmed by 15 of 16 patients in this study, no formal, objective assessment of plantar sweating in PPK has been reported.



Tests quantifying sweat production are not practically or routinely performed in clinical practice, and verbal reporting/estimation of symptoms by patients is used to assess benefit of treatment. No controlled studies on the sensitivity and specificity of history, physical examination, or laboratory testing in accurately diagnosing or characterising the severity of primary focal hyperhidrosis are available (Hornberger *et al.*, 2004). Most studies on focal hyperhidrosis are clinical trials providing only measurement values before and after treatment e.g. botulinum toxin therapy (Odderson, 1998). Gravimetric assessment provides an appropriate tool to objectify hyperhidrosis and has been used to compare the sweat production of healthy control subjects with patients suffering disabling axillary sweating (Naumann *et al.*, 1998; Hund *et al.*, 2002). Interestingly, no definite cut-off value was found that clearly distinguished patients with hyperhidrosis from normohidrotic individuals. Minor's starch-iodine test has also been described in mapping areas of excessive sweating prior to treatment with botulinum toxin (Naumann & Lowe, 2001) and surgery (Swinehart, 2000), however this does not provide accurate information on the quantity of sweat produced. A more detailed clinical and physical evaluation of plantar hyperhidrosis in inherited PPK is warranted .

#### **2.1.4.4 Quality-of-life issues**

Quality-of-life (QoL) questions were not specifically addressed in this study, but a number of points were raised by participants during their involvement with this study. These included the impact of plantar pain and hyperkeratosis on their employment (sections 2.1.4.1 and 2.1.4.3) and mobility which often impacted on family life; cosmetic concerns about skin and nail care; embarrassment regarding sweaty, malodorous feet and limitations in footwear selection.

By attempting to measure QoL, the effects of disease upon individuals can be ascertained, and subsequently, to judge the benefit of therapeutic intervention. Health-related QoL is defined as the subjective perception of the impact of health status, including disease and treatment, on physical, psychological and social functioning and well-being (Leidy *et al.*, 1999). According to standardized and validated QoL surveys, the negative effects of hyperhidrosis alone, without associated PPK, are comparable to other conditions such as severe psoriasis, end-stage renal disease, rheumatoid arthritis and multiple sclerosis (Cina & Clase, 1999; Swartling *et al.*, 2001). The IPCRR questionnaire specifically asked about time required for grooming and concerns about the cosmetic appearance of their skin and nails, with 38 of 57 participants reporting that this negatively impacted on their quality of life. Several participants also reported electing not to have children because of their fear of having a child with PC (Leachman *et al.*, 2005), although first trimester prenatal diagnosis for individuals with known mutations is now a possibility (Smith *et al.*, 1999b). Disease-specific health related QoL measures are felt to be the most accurate way of measuring the impact of a particular disease (Beattie & Lewis-Jones, 2006), and the development and validation of an appropriate QoL questionnaire for inherited PPK is an important area for future study.

#### **2.1.4.5 Treatment of PPK**

This study highlights the inconsistency and inadequacy of treatment of PPK. The goals of treatment of patients with inherited PPK are aimed at combating a number of features of the disease: hyperkeratosis of the skin, nails or mucous membranes; blisters; pain; hyperhidrosis; pseudoainhum (mutilating PPKs); cysts and infection (PC). There have previously been no specific treatments targeted at the inherited

PPKs but rather the same therapies are used or recommended for many hyperkeratotic conditions, including callosities, psoriasis or ichthyosis (Milestone *et al.*, 2005). More recently therapeutic siRNAs specifically for PC have been developed (Smith *et al.*, 2008) (see Section 4).

Mechanical paring remains a mainstay of treatment, either by the individual, using pumice stones, emery boards, paring knives etc. or by regular attendance to podiatry/chiropractic departments. In our cohort, the majority of patients performed their own manual paring at home, on approximately a weekly basis. Efforts to distribute weight, pressure and friction, using specially constructed shoes, orthotics, insoles or simply socks and gloves are mechanical approaches that many patients find useful (Milestone *et al.*, 2005). One PC-2 patient in this study needed access to a wheelchair at times when plantar pain was severe. Twenty-nine of 57 participants in the IPCRR questionnaire also reported an inability to walk without an aid (Leachman *et al.*, 2005). Easy access to podiatry, physiotherapy and orthotic services is thus essential in the treatment of these conditions.

Keratolytics e.g. salicylic acid in white soft paraffin or propylene glycol may facilitate removal of outer keratin layers (Milestone *et al.*, 2005), but no patients in this cohort found this a useful or practical treatment given the extent of their hyperkeratosis (see section 2.1.4.6). Benzoic acid compound ointment is mildly keratolytic and may be useful in reducing fungal and bacterial overgrowth and the resulting bad odour. Topical retinoids have little effect (Judge *et al.*, 2004). Systemic retinoids may be beneficial for patients with marked functional impairment, but response is unpredictable. Isotretinoin (Thomas *et al.*, 1984), tretinoin (Lucker & Steijlen, 1991) and acitretin (Judge *et al.*, 2004) have all been used (see section

2.1.4.7). Increasing tenderness, skin thinning and blistering is a limitation however, and only 2/16 PPK patients in this study were currently taking retinoids. Systemic retinoids may be beneficial for nail care as well as palmoplantar hyperkeratosis, but other treatments range from topical pastes of 20-40% urea or 15-20% salicylic acid to ablation of the nail matrix (Thomsen *et al.*, 1982). Reduction in periodontal swelling and erythema has also been reported following treatment with oral isotretinoin in Papillon-Lefèvre syndrome (Sethuraman *et al.*, 2005). Surgical intervention may also be necessary for the treatment of pseudoainhum in order to try to avoid autoamputation, as in the case of one loricrin PPK patient in the cohort. The commonest specific chemical interventions in PPK are the use of topical salicylic acid and of oral retinoids. The relevance of their actions to possible disease mechanisms is therefore considered further.

#### **2.1.4.6 The action of salicylic acid**

Salicylic acid is used in concentrations of 0.5% to 60% in almost any vehicle (Fluhr *et al.*, 2008), with concentrations of 20-50% being used as superficial chemical peeling agents (Zakopoulou & Kontochristopoulos, 2006). It is thought that it may exert a direct solubilizing effect on the stratum corneum, with dissolution of intercellular cement and reduction of adhesive forces within the stratum corneum (Marks *et al.*, 1975; Huber & Christophers, 1977; Loden *et al.*, 1995). Corneocyte intercellular bonding, corneocyte desquamation, stratum corneum hydration, corneocyte swelling and stratum corneum softening have also all been proposed as mechanisms of action (Lebwohl, 1999). Antihyperplastic properties of salicylic acid on pathologic hyperproliferation of the epidermis (Fluhr *et al.*, 2008) contrast with a promotion of epidermopoiesis in normal guinea pig skin, where epidermal thickness

was increased by 40% and deep epidermis by 19% (Weirich *et al.*, 1978). In humans, a reduction of stratum corneum cell layers after 3 weeks of application was shown (Roberts *et al.*, 1980), as well as alteration of intercellular structure resulting in desquamation of corneocytes (Huber & Christophers, 1977).

Salicylic acid is absorbed after topical application (Lin & Nakatsui, 1998; Schwarb *et al.*, 1999; Benfeldt *et al.*, 1999), which is confirmed by the development of systemic toxicity after percutaneous absorption after application onto large areas of skin (Schwarb *et al.*, 1999). Epidermal barrier damage, achieved by repeated tape stripping, irritant dermatitis due to sodium lauryl sulphate and by delipidization, has a pronounced effect on the cutaneous penetration of salicylic acid in both humans and shed snake skin models (Harada *et al.*, 1992; Benfeldt *et al.*, 1999). This is relevant clinically in the treatment of inflamed hyperkeratotic skin such as in PPK, as well as in hyperproliferative conditions such as psoriasis. The topical bioavailability of salicylic acid in the stratum corneum varies substantially both with different original concentrations and among different formulations, dependent on the base used (Tsai *et al.*, 1999).

#### **2.1.4.7 The action of retinoids**

The one intervention able to affect hyperkeratosis significantly is oral retinoid therapy. Retinoids define a class of compounds comprising vitamin A (retinol) and its natural and synthetic derivatives (Sorg *et al.*, 2006). They are lipophilic molecules which diffuse through cellular and other phospholipid membranes, so easily penetrate the epidermis. Retinoids are involved in regulation of cell proliferation, cell differentiation and morphogenesis. Their biological effects are mediated by their interaction with the nuclear retinoic acid receptors (RARs,  $\alpha$ ,  $\beta$  and  $\gamma$ ) and retinoid X

receptors (RXRs,  $\alpha$ ,  $\beta$  and  $\gamma$ ). Adult human skin predominantly expresses the isoforms RAR- $\gamma$  and RXR- $\alpha$  (Elder *et al.*, 1991; Fisher *et al.*, 1994), and it is thought that the binding affinity of retinoids to various RAR subtypes contributes to their relative potency. These ligand-receptor complexes modulate the expression of genes involved in cellular differentiation and proliferation (Fisher *et al.*, 1996) by mainly participating together as heterodimers, to regulate transcription (Chambon, 1996; Chawla *et al.*, 2001). Principally all-*trans* retinoic acid, the active vitamin A derivative, is the endogenous ligand for RARs, whereas its 9-*cis* isomer (9-*cis*-retinoic acid) activates both RARs and RXRs (Levin *et al.*, 1992; Allenby *et al.*, 1994).

There are two types of cellular retinoid binding proteins, the cellular retinoic acid binding proteins (CRABPs I and II) and the cellular retinol binding proteins (CRBPs). These proteins act as intracellular storage sites for retinoids and may facilitate retinoid transport from the cytoplasm into the nucleus (Donovan *et al.*, 1995). In normal human skin, CRABPII protein levels are much higher in the epidermis than dermis and CRABPI in the dermis than epidermis (Roos *et al.*, 1998).

Vitamin A deficiency in humans and animal models results in epithelial squamous metaplasia prone to malignant conversion (Hong & Itri, 1994) and natural and synthetic retinoids are used as chemopreventive agents for epidermal cancers (Altucci & Gronemeyer, 2001). Altered expression of RARs and RXRs during carcinogenesis is thought to reduce the ability of epidermal cells to respond to retinoic acid and contribute to carcinogenesis (Sun & Lotan, 2002). Retinoids have not only been used in the treatment of skin cancer, but also psoriasis, acne, skin ageing and pigmentation (Zouboulis, 2001). Drugs that increase retinoic acid

concentration in the skin have regulatory effects on epidermal keratinisation, proliferation and inflammation (Orfanos *et al.*, 1997).

All-*trans*-retinoic acid increases basal keratinocyte proliferation with accelerated turnover of epidermal cells and thickening of epidermis (Varani *et al.*, 2001). Epidermal growth factor receptor activation has been shown to be central in this retinoid-induced epidermal hyperplasia (Rittié *et al.*, 2006). In contrast, in psoriatic skin, the number of cycling epidermal cells is reduced thereby normalizing hyperproliferation. Enhanced epidermal differentiation and reduced cell-mediated inflammation were unexpected outcomes observed in 10 psoriatic patients treated with oral etretinate (Gottlieb *et al.*, 1996). A reduction in epidermal thickness and keratinocyte proliferation were seen, but also, increased keratinocyte differentiation, as indicated by increased filaggrin production, numbers of keratohyaline granules, greater abundance of keratin filaments and increased secretion of intercellular lipids. The stratum corneum was unusually thin, thought to be due to retinoid-induced shedding of corneocytes.

Retinoids improve dermal functions when used in the treatment of skin aging *in vitro*. Fibroblast proliferation and collagen production are increased (Griffiths *et al.*, 1993; Varani *et al.*, 2000) and matrix metalloproteinase-mediated extracellular matrix degradation is decreased (Fisher *et al.*, 1996). Topical retinoid also partially ameliorates epidermal atrophy induced by topical corticosteroid, in both humans (McMichael *et al.*, 1996) and mice (Lesnik *et al.*, 1989). However, *in vivo*, retinoid application can induce epidermal hyperplasia resulting in erythema and scaling (retinoid dermatitis) limiting its use (Kang *et al.*, 1995).

Retinoids have an effect on the expression of cytokeratins, altering the differentiation process towards a nonkeratinizing, mucosa-like epithelium (Kopan *et al.*, 1987; Rosenthal *et al.*, 1990; 1992; Steijlen *et al.*, 1991; Eichner *et al.*, 1992; Griffiths *et al.*, 1996). Keratins which are not usually present in adult human skin e.g. K4, K13 and K19 are induced. In association with epidermal thickening, stratum granulosum thickening, parakeratosis and a marked increase in the number of cell layers expressing epidermal transglutaminase, other distinct changes in differentiation are seen. These include an increased number of cell layers expressing both involucrin and filaggrin in acute and chronic treatment, and an increased number of layers expressing loricrin in chronic treatment alone. Three major epidermal differentiation products K1, K10 and K14 were not altered, suggesting that retinoids reprogramme some, but not all, aspects of human epidermal differentiation *in vivo* (Rosenthal *et al.*, 1990; 1992).

Other characteristics of mucosal epithelia acquired following treatment with retinoic acid include glycosaminoglycans accumulation, a decrease in the mucin-type cell surface carbohydrate structure T antigen, and an alteration in the differentiation pattern of cell surface carbohydrates (Griffiths *et al.*, 1996). Retinoids also produce changes in CRABP-II and retinoic acid 4-hydroxylase, both of which are significant in retinoic acid metabolism (Elder *et al.*, 1993). Acitretin, an aromatic synthetic retinoid, has high affinity for CRABPs and low affinity for RARs (Norris *et al.*, 1994). A shift in tretinoin binding from CRABPs to RAR $\gamma$  heterocomplexes is induced, suggesting that acitretin treatment results in a redistribution of endogenous tretinoin from cytoplasmic to nuclear compartments, thus indirectly potentiating retinoid activity (Tian *et al.*, 1997).



Evidence for the clinical efficacy of oral retinoids in inherited PPK is limited, with most reported studies being open or anecdotal, with small numbers of patients treated. Both acitretin and etretinate have been reported as effective in disorders of keratinisation, with optimal dosage varying between patients (Happle *et al.*, 1987; Blanchet-Bardon *et al.*, 1991; Katugampola & Finlay, 2006). As an increasing number of people with severe disorders of keratinisation are relying on oral retinoids as a single systemic treatment, longer follow-up data is essential in counselling those embarking on long-term treatment (Katugampola & Finlay, 2006), with intermittent treatment recommended when possible (Happle *et al.*, 1987).

The effects of retinoids on keratin expression in disorders of keratinisation have been examined in patients with ichthyosis and Darier's disease (Kanerva *et al.*, 1984; Steijlen *et al.*, 1991) and BCIE due to K1 and K10 mutations (Virtanen *et al.*, 2001). 3 of 9 patients with either Darier's disease, non-erythrodermic lamellar ichthyosis or autosomal dominant ichthyosis vulgaris were found to have an induction of K4 and 1 of 9, of K13 (Steijlen *et al.*, 1991). In a single case of ichthyosis hystrix, a clinical response to etretinate in the first year of treatment was associated with a thinning of the thick horny layer only, with persistence of phenotypic changes in the keratinocytes histologically and ultrastructurally (Kanerva *et al.*, 1984). In the BCIE group, 5 of 6 patients with K10 mutations benefited from oral acitretin or topical retinoid therapy (none of whom had palmoplantar hyperkeratosis), compared to none of the 6 patients with K1 mutations with associated PPK. Quantitative analysis of mRNA expression of K2e, a normal constituent of upper epidermis, was diminished especially in non-responders. It was postulated that retinoid therapy was more effective in K10 mutations as they may be

less vulnerable to a down-regulation of K2e, which may be potentially functioning as a substitute for the mutated protein in patients with K1 mutations.

Although the induction of different keratins may be a mechanism for correcting defects in keratin genes affecting palms and soles, there is little data on the effects of retinoid treatment in keratoderma. Lesional and non-lesional skin (from the knee) was studied before and after treatment with oral isotretinoin in a father and son with PC, demonstrating an alteration of glycoprotein distribution in only lesional epidermis (Thomas *et al.*, 1984). Further clinical studies studying retinoid use in inherited PPK and their effects on differentiation of palmoplantar skin are warranted.

### **2.1.5 Conclusion: Clinical issues**

The inherited PPKs are a highly heterogeneous group of disorders presenting with thickening of palmoplantar epidermis. They demonstrate both clinical and genetic heterogeneity, as confirmed by our study of this cohort from the West of Scotland. In the study population, we have confirmed a high degree of social and occupational disability due to keratoderma. Pain and hyperhidrosis are major symptoms.

Treatment options remain limited particularly with respect to hyperhidrosis and plantar pain. Retinoids remain a mainstay of treatment however benefits are variable between patients, and limited by side-effects such as skin thinning and subsequent blistering.

A previously unreported feature of abnormal adult dentition was noted in this cohort of PC-2 patients with an underlying K17 mutation. Pending further evidence, we recommend that dermatologists caring for children with PC-2 should bear in mind a possible effect on permanent dentition and consider appropriate dental

examination and care. Moreover, the presence in PC-2 of structurally abnormal, premature teeth and possibly adult teeth suggests that K17 expressing keratinocytes play an important role in odontogenesis and tooth eruption and is an area for further study.

## **Chapter 2.2 The Collection of a Resource**

### **2.2.1 Introduction**

In pursuit of the primary aim of the work described in this thesis, I sought to establish a tissue and cell culture resource for elucidating the pathogenesis of the inherited PPKs. In attempting to establish a bank of biopsy material from patients and controls, I concentrated on a small but varied group of disorders with known genetic aetiology. Whenever possible, several patients with the same known genetic mutation were recruited to aim to distinguish between changes due to variation between individuals and samples with that specifically due to the disease.

### **2.2.2 Methods**

#### **2.2.2.1 Collection of specimens**

Approval was obtained from the Research Ethics Committee of the Southern General Hospital, Glasgow. Fifteen patients with an inherited PPK discussed in chapter 2.1 were recruited for establishment of the resource. One patient with an inherited PPK with a mutation which was initially unknown but which was identified during the course of the project (chapter 2.3) was also recruited. Affected or control subjects were given an appropriate Patient Information Leaflet (Addendum A).

Plantar samples were obtained following informed consent, using the posterior tibial and saphenous nerve block (Appendix A). Single or duplicate elliptical biopsies were taken from both affected skin and, where keratoderma was focal, unaffected skin. The skin specimens were processed for light microscopy, immunocytochemistry (both paraffin embedded and frozen sections) and electron microscopy (morphology and immunostaining) (chapters 3.1 and 3.2). Control

samples of palmoplantar skin were taken, with informed consent, from four healthy individuals of similar age and sex undergoing minor surgery for other reasons.

Seven samples of non-palmoplantar skin (lower back) were obtained from the cohort of recruited keratoderma patients for keratinocyte culture, to provide a resource for functional studies in conventional and organotypic skin model culture systems. Five control biopsies were taken from non-palmoplantar skin, with informed consent, from healthy individuals of similar age and sex undergoing minor surgery for other reasons.

#### **2.2.2.2 Primary Keratinocyte Culture**

Subcutaneous tissue was trimmed from skin samples if necessary, transferred to dispase solution (25 units/ml) (Cascade Biologics, Invitrogen, CA, USA) and left at 4-6°C overnight. Using sterile forceps, the epidermis was peeled from the dermis and placed in 0.025% trypsin/0.01% EDTA solution (Cascade Biologics) at 37°C for 3-4 minutes, before removing the dermis. Defined trypsin inhibitor (DTI) (Cascade Biologics) was added in a 1:1 volume to the trypsin, followed by 10 mls of Epilife® Medium with 60µM Calcium chloride with Growth Supplement (Cascade Biologics) (containing 5 mls Penicillin/Streptomycin per 500 mls Epilife). The mixture was then centrifuged, the supernatant removed and a further 10mls Epilife added to the pellet, centrifuged and the supernatant removed. 5 mls Epilife was finally added and mixed, and then placed in a sterile 6cm<sup>2</sup> Petri dish which had been previously coated with Coating Matrix (Cascade Biologics) 20 minutes before use. The Petri dish was incubated at 37°C in a humidified atmosphere of 5% CO<sub>2</sub> in air, with Epilife medium changed every 2-3 days. Once confluent, the keratinocytes were split at a 1:4 ratio into Epilife, and at later passage, into 75cm<sup>2</sup> flasks.

#### 2.2.2.4 Freezing of cells

Confluent keratinocytes were trypsinised and resuspended in DTI (1:1 ratio to trypsin) and 10mls Epilife. Following gentle washing twice with Epilife, keratinocytes were resuspended in 2mls of Synth-a-Freeze® cryopreservation medium containing 10% dimethylsulfoxide (DMSO) (Cascade Biologics). 1ml aliquots of suspension were placed in each sterile cryovial, with approximately  $1 \times 10^6$  cells per vial. The vials were wrapped in cotton wool, then bedded down in a sealed insulated box for 5-6 hours in  $-20^{\circ}\text{C}$ , followed by 24-48 hours in  $-70^{\circ}\text{C}$ , before being transferred to liquid nitrogen for long-term storage.

### 2.2.3 Results

#### 2.2.3.1 Collection of Specimens

Plantar skin specimens (Figure 10) from all 16 keratoderma patients and four controls recruited, and non-plantar skin specimens from selected patients from each pedigree and five controls, were collected. A bank of biopsy material is now established (Tables 7&8).

**Table 7. Plantar specimens collected forming the bank of biopsy material; numbers of samples from each pedigree with underlying genetic mutation are listed.**

Patient Subtype (Number of patients, n)	Paraffin blocks	Snap frozen tissue (affected skin)	Snap frozen tissue (unaffected skin)	EM (morphology)	EM (immunoEM)
<b>KRT1 (2)</b>	2	2	-	2	2
<b>KRT9 (2)</b>	2	2	-	2	2
<b>KRT 17 (8)</b>	8	8	8	8	8
<b>DSG1 (1)</b>	1	1	0	1	1
<b>Loricrin (2)</b>	2	2	-	2	2
<b>Mitochondria (1)</b>	1	1	1	1	1
<b>Controls (4)</b>	3	-	1	4	4

**Table 8. Keratinocyte resource established from inherited PPK and control non-plantar skin samples.**

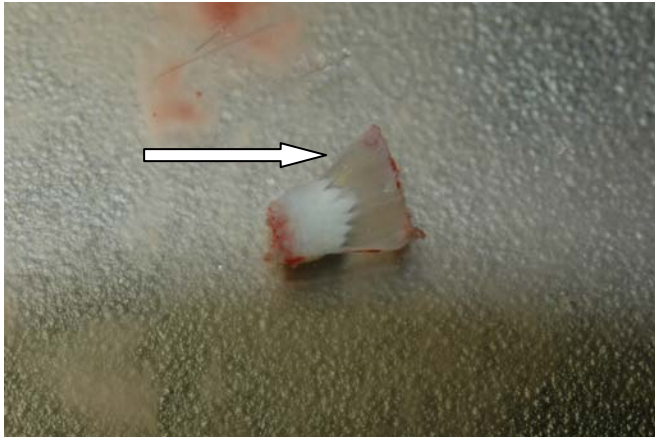<b>PPK Subtype</b>	<b>Number of patients</b>
<b>KRT1</b>	1
<b>KRT9</b>	2
<b>KRT17</b>	3
<b>Loricrin</b>	1
<b>Controls</b>	5

### **2.2.3.2 The Keratinocyte Resource**

Non-plantar skin was used to establish a keratinocyte culture resource from 7/16 of the recruited inherited PPK patients, and 5 healthy individuals for controls (Table 8).

### **2.2.4 Conclusion**

A bank of biopsy material was obtained from inherited PPK patients and controls, successfully establishing a tissue and cell culture resource in this rare group of genodermatoses. I proceeded to use the tissue resource to try to identify common and distinct pathways of hyperkeratosis by morphological, immunocytochemical and gene expression studies (Chapter 3). The keratinocyte resource has been made available for collaborative study, initially both to the Lane and McLean laboratories, Dundee, and via the European Geneskin network ([www.geneskin.org](http://www.geneskin.org)) for functional studies and immortalisation of cell lines.



**Figure 10. Grossly thickened stratum corneum in plantar biopsy from inherited PPK patient (indicated by arrow).**





## **Chapter 2.3 Investigation of a Pedigree with Striate Palmoplantar**

### **Keratoderma**

#### **2.3.1 Introduction**

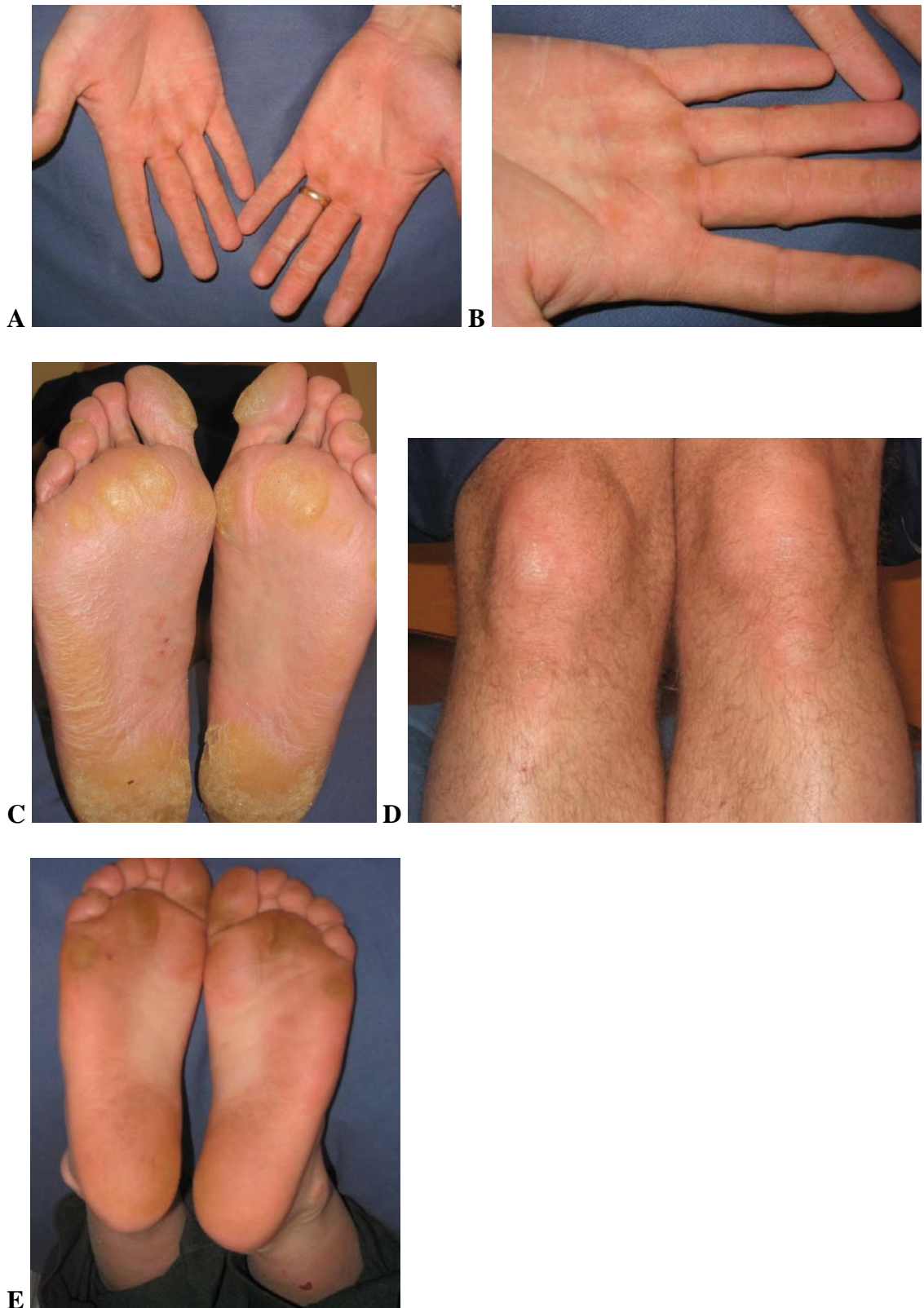During the course of this study, a 3 generation pedigree presenting with striate keratoderma was encountered. In order to fulfil the criteria for inclusion it was necessary to establish the mutation underlying the disease in this family. This also provided the opportunity to explore the means by which such families are investigated.

Striate palmoplantar keratodermas (SPPKs; OMIM 148700) are rare, mainly autosomal dominant, genodermatoses characterized by linear hyperkeratosis of the volar aspects of the fingers, extending onto the palm (Judge *et al.*, 2004). There is strong evidence that SPPK is due to defects in desmosomes, the major epithelial intercellular adhesion junctions, which confer strength and rigidity to tissues that experience high mechanical stress. Twenty causative mutations in desmosomal proteins desmoglein 1 (DSG1) and desmoplakin (DP), and in keratin 1(K1) which links to desmosomes, have been reported (Rickman *et al.*, 1999; Armstrong *et al.*, 1999; Hunt *et al.*, 2001; Lai-Cheong *et al.*, 2007; Hershkovitz *et al.*, 2009; Dua-Awereh *et al.*, 2009).

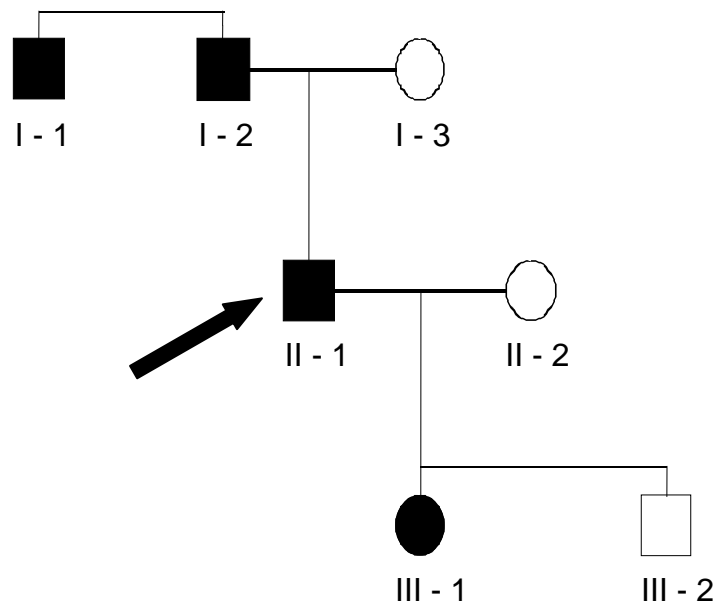
#### **2.3.2 Methods**

##### **2.3.2.1 SPPK pedigree**

The proband (II-1) was a 40-year-old Scot (Figure 11) who presented with painful thickening of the skin on his palms and soles, hyperhidrosis, and intermittent associated blistering, since childhood. There was no history of abnormal hair, nails or



**Figure 11.** Family with striate palmoplantar keratoderma (SPPK). Clinical pictures of the proband II-1: striate keratoderma on (a, b) palms, (c) soles, (d) bilateral hyperkeratosis of knees and (e) proband's daughter's soles.



**Figure 12. Pedigree of the family with SPPK.** Filled symbols represent affected individuals. Proband demonstrated by arrow.

dentition, or cardiac disease. At the time of presentation, he was on no oral medication and managed his hyperkeratosis only with emollients and manual paring.

Clinical examination showed linear hyperkeratosis of the volar aspects of fingers, more extensive focal plantar hyperkeratosis and mild hyperkeratosis of the knees. His father, paternal uncle and 8 year old daughter were similarly affected (Figures 11 & 12), in keeping with an autosomal dominant inheritance pattern.

#### **2.3.2.2 DNA extraction**

Following informed consent, genomic DNA was extracted from saliva samples from the proband, his affected daughter and his unaffected son (II-1, III-1 and III-2) using Oragene™ DNA Self-Collection Kit (DNA Genotek Inc., Canada), following the protocol recommended by the manufacturer. The mixed saliva/Oragene sample was incubated at 50°C for a minimum of 2 hours, before adding 40 µl Oragene Purifier™ per 1 ml sample, vortexing for several seconds, incubating on ice for 10 min and centrifuging for 10 min. The supernatant was removed carefully, without disturbing the pellet, and an equal volume added of 96-100% ethanol at room temperature and mixed by inversion. This was centrifuged at 2,500g (3,600rpm) for 10 min and the ethanol removed, not disturbing the DNA pellet. This was inverted onto tissue paper for 5 min and then turned upright to air dry for 5 min. 125 µl TE buffer (10 mM Tris-HCl, pH 8.0, and 1 mM EDTA) per 1 ml sample was used for resuspension and DNA dissolved by incubating at 50°C for 1 hour.

#### **2.3.2.3 Mutation detection**

Based on previous studies implicating genetic mutations of desmosomal proteins in PPK (Armstrong *et al.*, 1999; Whittock *et al.*, 1999; Hunt *et al.*, 2001), we first carried out mutational analysis of the DSG1 gene. Polymerase chain reaction (PCR)

amplification of each exon of DSG1, including exon/intron boundaries was performed, using primers previously described (Hunt *et al.*, 2001) (Table 9) on two affected individuals, one unaffected family member and one normal unrelated control. PCR products were sequenced on an ABI 3130 or 3730 automated sequencing machine, as per standard protocols (Milingou *et al.*, 2006).

The PCR reactions were carried out in 50 µl volume containing: 1 µl DNA, 5 µl each primer at 5 µM (10µl total), 5 µl 10x PCR buffer containing 1.5 mM MgCl<sub>2</sub> (High Fidelity PCR buffer, Roche, Mannheim, Germany) or buffer previously described (Whitlock *et al.*, 2002a), 5 µl dNTPs (0.25 mM each), and 29 µl H<sub>2</sub>O, and 0.2 µl (1U) Taq polymerase (Bioline Limited, London, UK). The PCR reaction was carried out under the following conditions: 94°C for 2 min, then 94°C for 15 sec (strand separation), 55°C for 30 sec (primer annealing), 72°C for 60 sec (strand elongation) for 35 cycles (primers 9 and 11 for 40 cycles) and 72°C for 5 min.

#### **2.3.2.4 DNA agarose gel electrophoresis and purification**

Agarose gel electrophoresis was used for the separation, size determination and relative quantification of DNA fragments. 1% analytical grade agarose (Melford, UK) was dissolved in 1xTBE (890 mM Tris, 890 mM boric acid and 10 mM EDTA) by microwaving. After cooling 4 µl of Invitrogen SYBR Safe DNA Gel stain was added per 80 ml agarose gel. 5 µl aliquot of each DNA sample was mixed with 2 µl DNA loading buffer into the wells along with the appropriate DNA molecular weight marker (Hyperladder IV Bioline). The electrophoresis was carried out at 150 volts. DNA was visualized under UV light and images were captured with an Ultra Violet Products Gel documentation System, Image Store 7500. DNA was then purified using the QIAquick PCR purification kit protocol (Qiagen, Crawley, UK) using a

**Table 9. Desmoglein 1 primers**

<b>Primer</b>	<b>Sequence 5'-3'</b>	<b>PCR size (bp)</b>	<b>Annealing temp (°C)</b>
DSG1.1F DSG1.1R	CAGCTGGAGGAAGGGTGTG GGCATTAAACATGATCTTGAGTC	529	55
DSG1.2F DSG1.3R	GACTCACAAGCCTATGGTTTC GTAGCTTCTCGGTGAGACATG	635	55
DSG1.4F DSG1.4R	CAAGGTCATCACATGCAACAAC CAGTCGTGGGATGCTCGTG	401	55
DSG1.5F DSG1.5R	CACAGTGCTAGCATAATGCTC GGAGCTGCTCCGTAGTTG	379	55
DSG1.6F DSG1.6R	CAGTGAAGTCCACATCATAAGG GGACATATAGCAAGTCATTCC	647	55
DSG1.7F DSG1.7R	GGCTGTCTACGTCAAGTGTG CATAACATGTGCCTCTGTAAG	271	55
DSG1.8F DSG1.8R	ATCAACATTCCAGTATAAGCC CTGTATTGACAAACTGTCTCCAG	494	55
DSG1.e8F2 DSG1.e8R2	GTTTTCACTTCTTGTTCAG ACCATACCTTAACAACCTTT	213	55
DSG1.9F DSG1.9R	GGTGAACAATCAGAGCTCAC GACGAATCACGGCCTGTGG	829	55
DSG1.9F2 DSG1.9R	GATTTTCTTTACCTGGAACG GACGAATCACGGCCTGTGG	636	55
DSG1.10F DSG1.10R	CTCCATATTGCTAAGACTGCC GGACTCATGGTCTTAGCTAC	487	55
DSG1.11F DSG1.11R	CTGTGTTGTCCAACCATTCC CCCAGTGCCAAACACAGAAG	492	55
DSG1.12F DSG1.13R	GTCTGACCATCATTGAGCTTG CTAAGTACTCTTTGATGGTTGAG	928	55
DSG1.14R DSG1.14R	CACATATTACAAGGCAAGTTGTTA GAATCTAGTTAGGAGACTCCTG	398	55
DSG1.15F1 DSG1.15R1	CATTCCTCTTTGGAAATGCTCTG CATCTCGCAAGTCAGGCATC	672	55
DSG1.15F2 DSG1.15R2	GACCAGCATCAAACGTGGTAG GCTGGAGATGGACTACAGG	855	55

microcentrifuge, and was carried out according to the manufacturer's instructions, prior to sequencing.

#### **2.3.2.5 mRNA isolation**

Following informed consent, an elliptical biopsy of normal arm skin was obtained from the proband under local anaesthetic, which was snap frozen in liquid nitrogen and stored at -70°C. This was bisected; one piece was used for mRNA extraction, and the other for protein extraction (see 2.3.2.7). mRNA was isolated using a QuickPrep micro mRNA purification kit (Amersham Biosciences, UK) as specified by the manufacturer's instructions. Tissue was manually homogenized in extraction buffer (buffered aqueous solution containing guanidinium thiocyanate), until a uniform suspension was obtained. This was diluted by adding 2 volumes of elution buffer (10 mM TrisHCL, pH 7.5, 1 mM EDTA) to the extract and centrifuging for 1 min to obtain a clear homogenate. The homogenate was added to a pellet of oligo(dT)-cellulose which was then resuspended and centrifuged for 10 seconds. This was washed in 1 ml of high salt buffer (10 mM TrisHCl, pH 7.5, 1 mM EDTA, 0.5 M NaCl) five times, followed by two washes using 1 ml of low salt buffer (10 mM TrisHCl, pH 7.5, 1 mM EDTA, 0.1 M NaCl). The washed oligo(dT)-cellulose pellet was resuspended in 0.3 ml low salt buffer and transferred to a MicroSpin column. This was centrifuged for 5 sec, washed with 0.5 ml low salt buffer 3 times, then eluted with 2 x 0.2 ml elution buffer at 65°C. Following ethanol precipitation, RNA was dried and resuspended in 5 µl DEPC-treated H<sub>2</sub>O.

#### **2.3.2.6 RT-PCR**

A 20 µl reaction containing 5 µl mRNA, 1 µl Oligo (dT) 0.5 mg/ml (Roche), 1 µl RNAsin® (40 U/ µl, Promega, Madison, WI, USA) was heated to 70°C for 10 min



and cooled to 42°C. This solution was mixed with 4 µl 5x Avian Myeloblastosis Virus (AMV) buffer, 2 µl 10 mM dNTPs and 7 µl H<sub>2</sub>O, followed by 1 µl of AMV reverse transcriptase (Promega, Madison, WI, USA) and mixed. The reaction was incubated at 42°C for 1 hour; then heated to 70°C to inactivate the reaction.

Following cooling to 42°C, 1 µl AMV reverse transcriptase (10U/ µl) was added and incubated at 42°C for 1 hour. cDNA was stored at -20°C.

2 sets of primers were designed using Oligo 6.8 software, and produced by MWG, in order to amplify exon 5. DSG1 cDNA primers are described in Table 10. The primers were designed to span at least one intron to check for any genomic contamination in the cDNA. The RT-PCR reactions were carried out in 50 µl volume containing: 5 µl each primer, 5 µl dNTP (0.25 mM each) , 5 µl 10 x High Fidelity

**Table 10. Desmoglein 1 primers for RT-PCR**

Primer	Sequence 5'-3'	PCR size (bp)	Annealing temp (°C)
DSG1.E5F1	CAATCCGAAGGCAGAAACGTG	638	55
DSG1.E5R1	GCACTCACATTCCGCTGACAT		
DSG1.E5F2	CCGCATCTCTGGAGTAGGA	321	53
DSG1.E5R2	GAGTTCAAATTGTTTCGGTTCA		

PCR buffer II (Roche, Mannheim, Germany), 2 µl DMSO, 3 µl MgCl<sub>2</sub>, 23 µl H<sub>2</sub>O, 2 µl cDNA and 0.25 µl Expand High Fidelity Enzyme Mix. The RT-PCR reaction was carried out under the following conditions: 94°C for 5 min, then 94°C for 30 sec (strand separation), 50°C for 1 min (primer annealing), 72°C for 2 min (strand elongation) for 38 cycles before 72°C for 5 min. Control cDNA from an unaffected

individual, cDNA from HaCaT cells (a keratinocyte cell line) and a negative sample were also used.

### **2.3.2.7 Protein isolation and Western Blotting**

Normal arm skin from the proband (see 2.3.2.5) was also used for protein isolation to be compared with a normal control. The skin biopsy was homogenised in 150 µl urea extraction buffer (8 M urea, 50 mM Tris-HCl pH 7.5, 10 mM reducing agent DTT, protease inhibitor cocktail, Roche). Homogenates were centrifuged at 16,000g, 4°C for 10 min to pellet debris. The supernatant was removed and protein concentration determined using Coomassie Protein Assay (Pierce, IL, USA). Skin extracts were diluted 1/25 with extraction buffer and 1.5 mls Coomassie Reagent added to each sample, left for 4 min at room temperature and absorbance measured at 595nm and converted to mg protein using a graph plotted using known quantities of BSA.

Proteins were separated on 4-12% Bis-Tris NuPAGE® Novex Gel (Invitrogen, CA, USA). ~5 µg of protein was loaded, SeeBlue® Plus2 Pre-Stained Standard (Invitrogen) was run alongside. Samples were run on 2 gels which were run in MOPS SDS Running buffer at 200V for 50 min. SimplyBlue™ Safe Stain (Invitrogen) was used to stain one gel. Separated proteins on the second gel were transferred to nitrocellulose membranes NuPage® transfer buffer, for 1 hour at 30V. Blots were stained with Ponceau Stain (Sigma USA) a reversible stain, for 5 min to verify equivalent transfer of proteins. The membranes were washed with water to remove Ponceau Stain and were then blocked with 5% non-fat dried milk (Marvel) in PBS with gentle shaking for 1 hour at room temperature. Mouse monoclonal antibody to human desmoglein 1 (MCA2271, AbD Serotec, UK), clone 27B2,

isotype IgG1 was diluted 1:500 in PBS containing 0.05% Tween and 5% dried milk and the blot incubated with shaking for 1 hour at room temperature. After 3 x 5 min rinses in PBS-Tween, either rabbit anti mouse alkaline phosphatase conjugated D0314 or goat anti mouse horse radish peroxidase conjugated D0447 (DakoCytomatin, Denmark) secondary antibodies were used. These were diluted 1:1000 in PBS- 0.05% Tween, and incubated for 1 hour to detect bound monoclonal primary antibody. Blots were washed 3 x 5 min in PBS- 0.05% Tween. Proteins were detected either with BCIP/NBT (5-bromo-4-chloro-3-indolyl-phosphate/nitro blue tetrazolium, Promega) if incubated with alkaline phosphatase conjugated secondary antibody or by ECL if incubated with horse radish peroxidase conjugated secondary antibody. For NBT/BCIP staining - 10 ml buffer (100 mM Tris, pH 9.5; 100 mM NaCl; 5 mM MgCl<sub>2</sub>) 66 µl of NBT (50 mg/ml) and 33 µl BCIP (50 mg/ml) was added. Blot was incubated with substrate until bands appeared (within 2-10 mins). For ECL staining - blots were covered with fresh detection substrate; a 1:1 mixture of solution I and II, (Solution I - 1 ml luminol stock; 0.44 ml coumaric acid stock, 10 ml 1M Tris pH 8.5 in 100 ml, Luminol 250 mM stock Fluka in DMSO): Solution II 64 µl of 30% H<sub>2</sub>O<sub>2</sub>; 10 ml 1 M Tris pH 8.5 in 100ml (p-coumaric acid, 90 mM stock in DMSO, Sigma) for 2.5 min. Substrate was removed and blot was placed between 2 pieces of cling film, and X-ray film placed against the blot and exposed for 3 sec to 30 min before being developed.

### **2.3.2.8 Light and electron microscopy**

Fresh elliptical plantar biopsies of affected plantar skin were obtained under peripheral nerve block (Appendix A), dissected into three pieces (chapter 2.2), two of which were prepared for paraffin-embedding and transmission electron microscopy

(chapter 3.1.2.1 and 3.1.2.3). Haematoxylin and Eosin (H&E) staining was performed as described (chapter 3.1.2.2).

### **2.3.2.9 Immunohistochemistry**

Fresh affected plantar skin was snap frozen in liquid nitrogen and stored at -70°C.. Serial frozen sections were cut at 5 µm, attached to Silane-coated glass microscope slides and stored at -20°C prior to use. Mouse monoclonal antibody to human desmoglein 1 (MCA2271, AbD Serotec, UK), clone 27B2, isotype IgG1, was used (dilution 1:50). Negative controls omitted primary antibody.

Sections were allowed to come to room temperature, then incubated in fresh acetone (BDH Laboratory supplies, Poole, England) for 10 mins at room temperature. After washing twice in phosphate buffered saline, PBS (Sigma, UK) over 5 min, sections were incubated for 10 min in fresh 3% hydrogen peroxide to block endogenous peroxidase. After blocking with normal rabbit serum (see chapter 3.2.2.5), the sections were incubated with primary antibody diluted in PBS at 37°C for 1 hour. The following steps are as described in chapter 3.2.2.5.

## **2.3.3 Results**

### **Desmoglein 1 gene analysis**

Sequence analysis of the DSG1 gene revealed a novel heterozygous A-to-T transversion in exon 5 (c.430A>T), converting an arginine residue to a premature termination codon (p.Arg144stop). The mutation was also detected in cDNA following extraction of RNA from skin biopsy of the proband. The mutation was

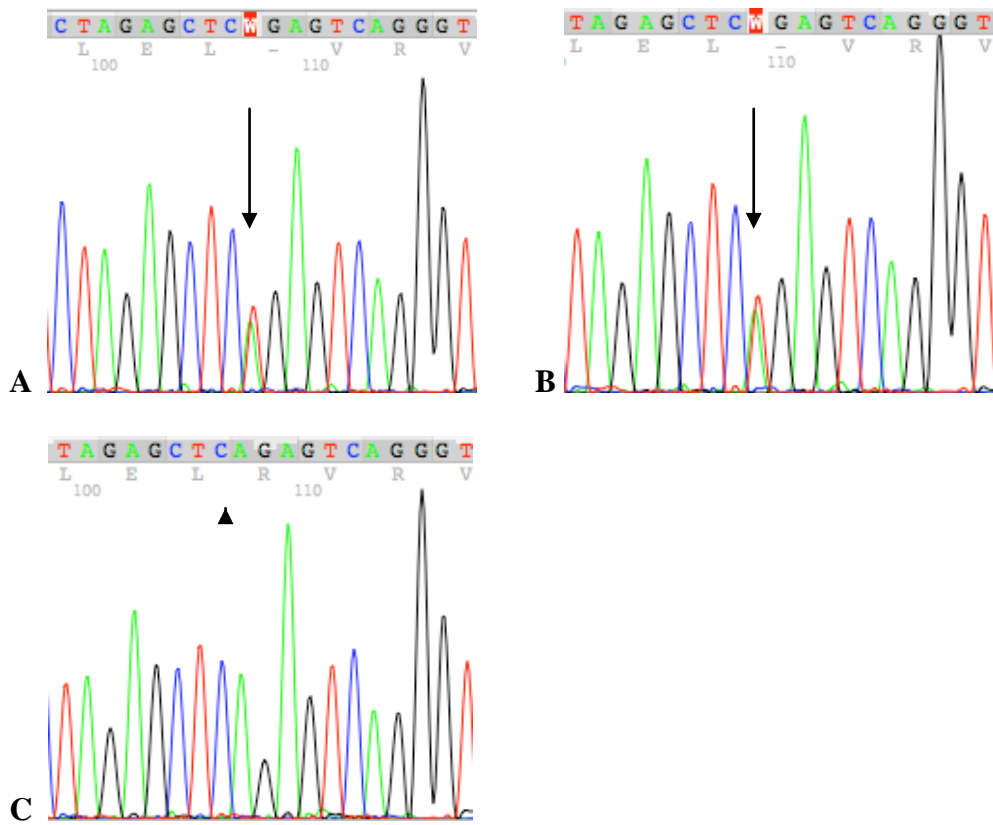
present in his affected daughter and absent in his unaffected son (Figure 13). Five other sequence variants detected were known, synonymous polymorphisms.

### **Protein isolation**

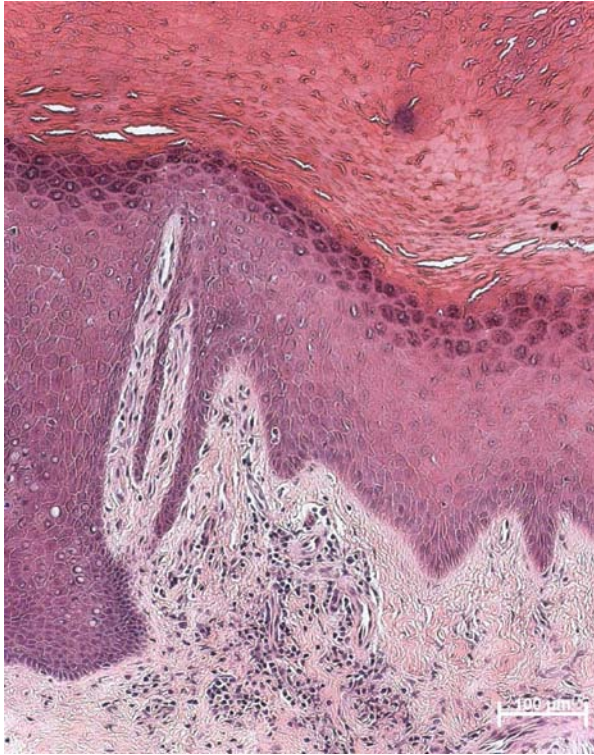
Protein extractions were successful, as confirmed by running the samples on the gel and staining with SimplyBlue™ Safe Stain. Initial results showed a reduction in protein in the proband, however, antibody staining needed to be optimised further, using different dilutions and more stringent washing steps to interpret results fully.

### **Light and Electron Microscopy**

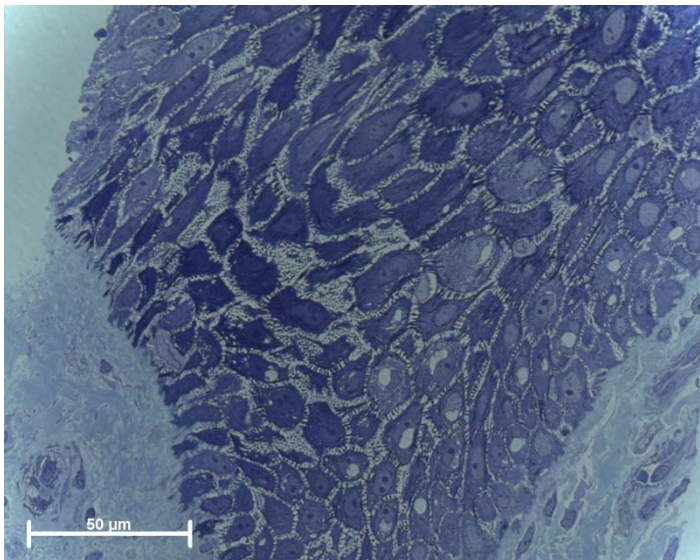
Light microscopy of affected plantar epidermis showed acanthosis with mild spongiosis and intracellular vacuolation. The granular layer was thickened and hyperkeratosis was present. A mild upper dermal perivascular chronic inflammatory cell infiltrate was noted and the presence of suprabasal cell-cell disadhesion (Figure 14). Comparative histological results/measurements are described in chapter 3.1.3.1. Light microscopic analysis of semithin sections stained with 1% toluidine blue demonstrated orthohyperkeratosis, acanthosis and cell-cell separation in the spinous layers resulting in intercellular widening, suggestive of a possible underlying desmosomal abnormality (Figure 15). Electron microscopy revealed normal keratin intermediate filaments but separation of keratinocytes in the spinous layer resulting in loss of cell contact in places. Cell vacuolation was a non-specific feature also observed. Desmosomes appeared normal in size and number (Figure 16). Immunohistochemistry revealed prominent desmoglein 1 staining in suprabasal and spinous layers, with some weak basal staining (Figure 17). This was closely comparable to affected plantar skin from 3 PPK patients with underlying mutations in loricrin, K9 and mitochondrially inherited mutations, and normal plantar skin.



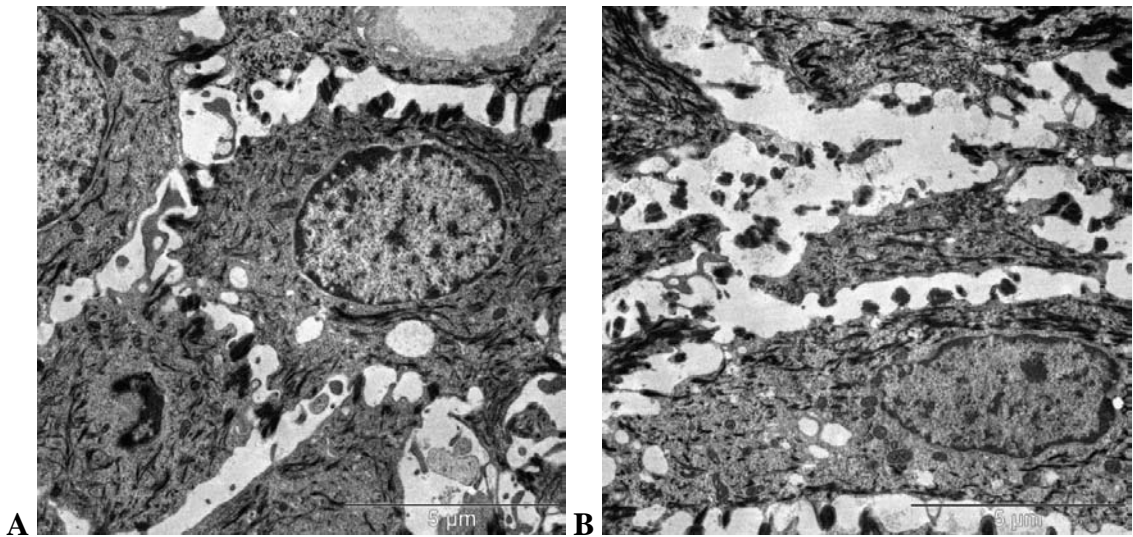
**Figure 13. DNA sequencing of the DSG1 gene.** Sequencing reveals a heterozygous A-to-T transversion in exon 5 of the DSG1 gene (designated c.430A>T), converting an arginine residue (AGA) to a premature termination codon (TGA; designated p.Arg144stop) in the proband (a). The mutation was present in his affected daughter (b) and absent in his unaffected son (c).



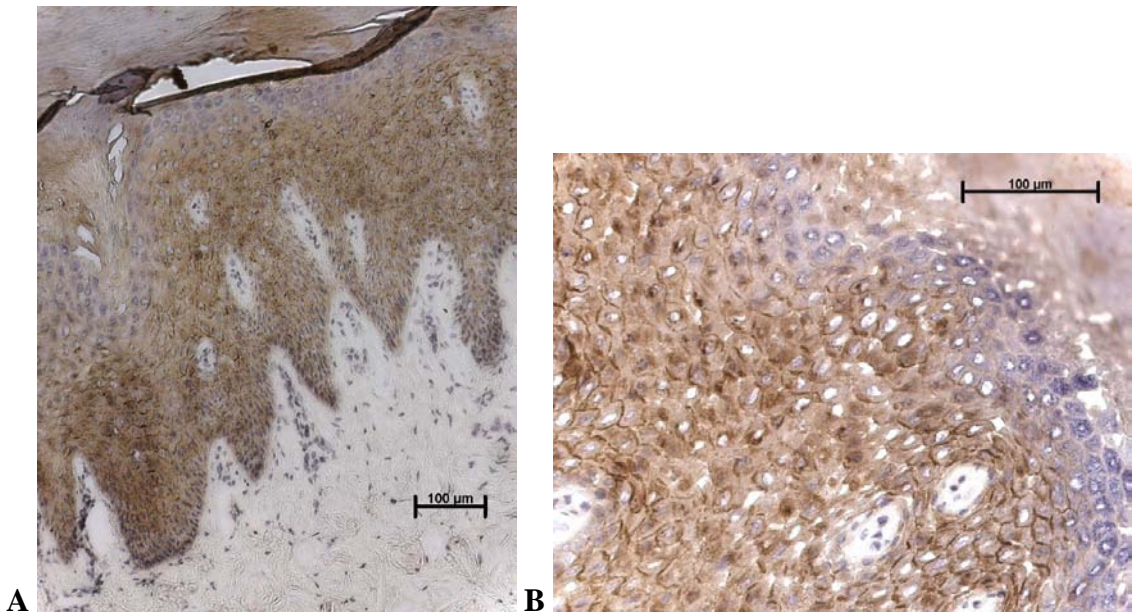
**Figure 14. Morphologic changes occurring in Haematoxylin and Eosin (H&E) stained affected plantar skin in proband,** demonstrating acanthosis, mild spongiosis and intracellular vacuolation, hypergranulosis and hyperkeratosis. A mild upper dermal perivascular chronic inflammatory cell infiltrate is also present. Scalebars=100 $\mu$ m.



**Figure 15. Light microscopic changes occurring in 1% aqueous toluidine blue stained semithin sections of affected plantar skin in proband.** Abnormalities in spinous layer of the epidermis; the intercellular space is widened causing cell-cell separation. Scalebar=50 $\mu$ m.



**Figure 16. Electron micrographs of affected plantar skin in proband.** Normal keratin intermediate filaments (a) and cell separation in spinous layers with loss of cell contact in places (b). Desmosomes appear normal in size and number. Scalebars=5µm.



**Figure 17. Desmoglein 1 staining of affected plantar skin in proband.** Prominent staining of suprabasal and spinous layers observed (a and b). Scalebars=100µm.



## **2.3.4 Discussion**

### **2.3.4.1 <sup>▲</sup>Desmosome structure**

Desmosomes are intercellular junctions abundantly expressed in a variety of epithelia including epidermis (see chapter 1) and cardiac muscle. They are found in great abundance in tissues that experience mechanical stress. They contain two types of cadherin (three desmocollins, DSCs, and four desmogleins, DSGs) and other cytoplasmic proteins including desmoplakin, envoplakin, periplakin, plectin, bullous pemphigoid antigen 1, corneodesmin (CDSN) and microtubule actin cross-linking factor (plakin family), and plakoglobin (PG) and certain plakophilins (PKP) (armadillo family)(Green & Jones, 1996; Yin & Green, 2004) (Figure 4, chapter 1). These molecules are assembled in highly organised cell membrane complexes and serve in both cell-cell adhesion and in the peripheral anchorage of keratin intermediate filaments, conferring resistance to mechanical stress.

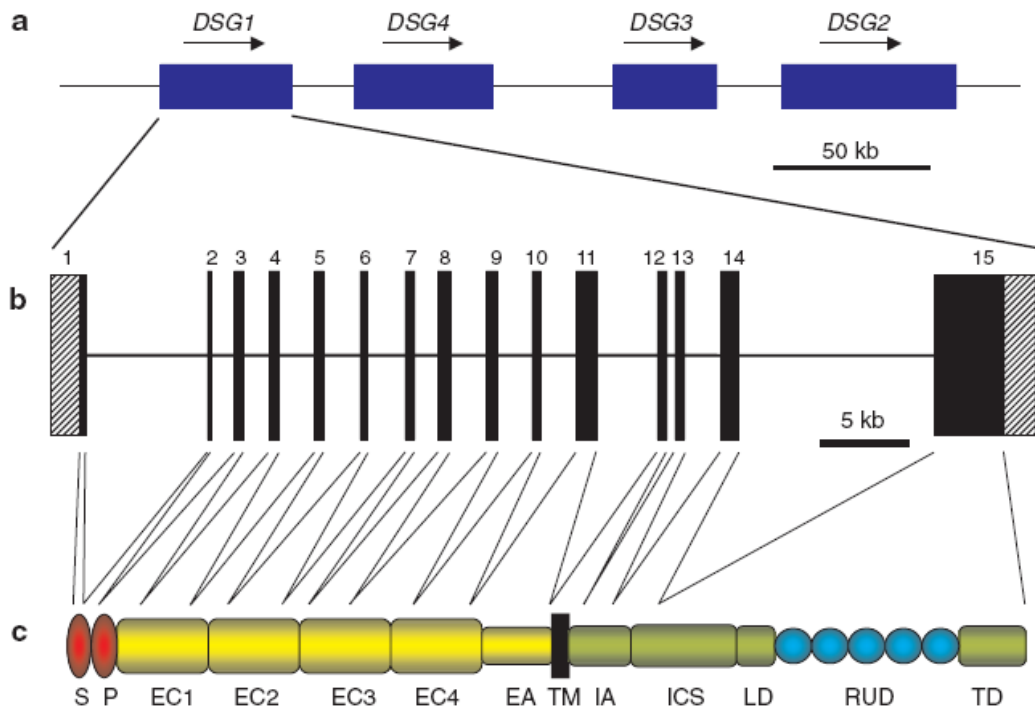
### **2.3.4.2 Desmosomal diseases**

Mutations in genes encoding desmosome components underlie a number of autosomal recessive or dominant skin disorders characterized by skin fragility, hyperkeratosis and in some cases, nail, hair and cardiac abnormalities (Lai-Cheong *et al.*, 2007) (Table 11). A relationship between some forms of genetic skin disease and abnormalities in desmosomes had been previously suggested in disorders such as Darier disease and Hailey-Hailey disease, but linkage studies in these conditions have not mapped to known desmosome gene loci (Richard *et al.*, 1995; Wakem *et al.*, 1996). The first human mutations in a desmosome were identified in the PKP1 gene (McGrath *et al.*, 1997). Subsequent autosomal-recessive mutations have been

identified in DSP, plakoglobin and DSG4 and autosomal dominant mutations reported in PKP2, DSP, DSG1 and 2, and CDSN (Table 11). The genomic organization of DSCs and DSGs is similar to that of classic cadherins, suggesting evolution from a common ancestor through multiple gene duplication and divergent evolutionary events (Nollet *et al.*, 2000). Specifically, the desmosomal cadherins are all clustered within a 650-kb region of chromosome 18 at locus 18q12.1 (Arneemann *et al.*, 1991). This organisation has promoted speculation that a master regulator region controls desmosomal cadherin genes (Dusek *et al.*, 2007). The human DSG1 comprises 15 exons spanning approximately 45kb (Hunt *et al.*, 2001) and is situated within a 250-kb cluster on 18q12.1 containing the four genes arranged in the order 5'-cen-DSG1-DSG4-DSG3-DSG2-Tel.3' (Whittock & Bower, 2003a) (Figure 18).

**Table 11. Illustration of the autosomal-dominant and –recessive disease phenotypes associated with inherited mutations in structural components of desmosomes (Adapted from Lai-Cheong *et al.*, 2007).**

<b>Inheritance: Autosomal Dominant</b>	<b>Protein</b>	<b>Inheritance: Autosomal Recessive</b>
	Plakophilin 1	Skin fragility ectodermal dysplasia syndrome
Arrhythmogenic right ventricular cardiomyopathy	Plakophilin 2	
Woolly hair, keratoderma, cardiomyopathy Arrhythmogenic right ventricular cardiomyopathy Striate palmoplantar keratoderma	Desmoplakin	Woolly hair keratoderma +/- cardiomyopathy
	Plakoglobin	Naxos disease
Striate palmoplantar keratoderma	Desmoglein 1	
Arrhythmogenic right ventricular cardiomyopathy	Desmoglein 2	
	Desmoglein 4	Localised recessive hypotrichosis Recessive monilethrix
Hypotrichosis simplex	Corneodesmin	



**Figure 18. Predicted gene and protein details of human desmoglein 1 (Whittock & Bower, 2003b).** (a) The desmoglein 1 complex occupies ~250kb, with *DSG1* lying between *DSG4* and the desmocollin gene cluster. (b) *DSG1* genomic organization: the human gene consists of 15 exons spanning ~45kb genomic DNA. Exons shown by vertical boxes, introns by horizontal lines. (c) The encoded protein desmoglein 1 (see figure 19): domains represented as signal (S), preprotein (P), five extracellular domains (EC1-4, EA), transmembrane domain (TM), intracellular anchor domain (IA), intracellular cadherin-typical segment domain (ICS), linker domain (LD), repeat unit domain (RUD) containing five repeats and terminal domain (TD). (Reproduced by kind permission of Wiley-Blackwell).

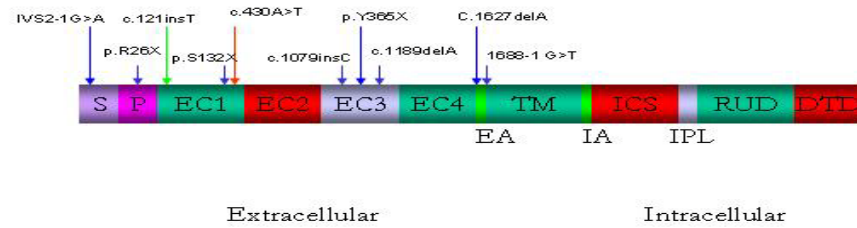
#### **2.3.4.3 Striate PPK**

Of 20 previously identified mutations, fifteen are in the DSG1 gene, four in the DP gene and one is in K1 (Rickman *et al.*, 1999; Armstrong *et al.*, 1999; Hunt *et al.*, 2001; Lai-Cheong *et al.*, 2007; Hershkovitz *et al.*, 2009; Dua-Awereh *et al.*, 2009). SPPK1 and SPPK2 refer to disease associated with mutations in genes encoding DSG1 and DP, respectively (Armstrong *et al.*, 1999; Rickman *et al.*, 1999; Hunt *et al.*, 2001; Whittock & Bower, 2003b; Kljuic *et al.*, 2003b; Milingou *et al.*, 2006; Hershkovitz *et al.*, 2009; Dua-Awereh *et al.*, 2009). SPPK3, reported in a large British kindred, is associated with a frameshift mutation in the V2 domain of K1 (Whittock *et al.*, 2002a). Thus SPPK can result from a perturbation in either the intermediate filament network (K1), the desmosomal plaque (DP) or the transmembrane cadherin (DSG1). One further case involving a DSG1 mutation has been reported in which the PPK was focal rather than striate (Milingou *et al.*, 2006) (Figure 19).

#### **2.3.4.4 Syndromic striate PPK**

DP mutations have also been described in association with syndromic SPPK presenting with either right or left ventricular cardiomyopathy, woolly hair and SPPK (Norgett *et al.*, 2000; 2006). Striate keratoderma, woolly hair and dilated left ventricular cardiomyopathy developing in teenage years was first described by Carvajal (Carvajal-Huerta, 1998). The first recessive pathogenic mutation found in the DP gene was a homozygous frameshift mutation, c.7901delG, identified in affected members of three Ecuadorean families with Carvajal syndrome (Norgett *et al.*, 2000). All affected family members presented with a striate form of PPK, with

some non-volar involvement particularly at sites of pressure or abrasion. The associated



**Figure 19. Protein domain organisation of Desmoglein 1 showing mutation sites:** site of our mutation (red arrow) in EC1, the first eight previously reported autosomal dominant mutations in DSG1 in striate PPK (blue arrows), and one case of focal keratoderma with additional non-acral hyperkeratosis (green arrow). Abbreviations as Figure 18, and DTD=Desmoglein-specific terminal domain.

dilated left ventricular cardiomyopathy was characterized by cardiac enlargement and disrupted cardiac contraction. Subsequently, a family with a novel dominant mutation in DP, an insertion of 10 amino-acid residues, starting in codon 608, designated c.1822ins30, has been reported with striate PPK, woolly hair and biventricular cardiomyopathy resulting in early death (Norgett *et al.*, 2006).

Clinically, mutations in DP result in a variable combination of skin, hair and cardiac abnormalities. The pattern is not always striate, but sometimes more focal or more diffuse. Moreover, the age of onset is variable and the degree of trauma to the palms and soles clearly has an influence on the clinical severity and presentation (Lai-Cheong *et al.*, 2007).

#### **2.3.4.5 Diseases associated with plakoglobin, desmoplakin and plakophilin mutations**

Autosomal recessive arrhythmogenic right ventricular cardiomyopathy causing heart failure and sudden death, congenital woolly hair, and development of progressive, nonepidermolytic diffuse PPK, or Naxos disease, was first reported in seven pedigrees from the Greek island of Naxos (Protonotarios *et al.*, 1986; 2001).

Approximately 1 in 1,000 of the population are affected (Antoniades *et al.*, 2006) although additional cases have been documented on the neighbouring island of Milos and in Bologna, Italy (Lai-Cheong *et al.*, 2007). Coonar *et al.* (1998) mapped the gene to 17q21 and subsequently a homozygous 2-base pair deletion, c.2157delTG, in the PG gene was identified in affected individuals (McKoy *et al.*, 2000). This deletion caused a frameshift mutation resulting in premature termination of the

protein by 56 amino acid residues. The dermatologic features of PPK and woolly hair are present in all individuals who are homozygous for the mutation but there are no reports of skin or hair abnormalities in heterozygous carriers. In homozygous individuals, over 90% have electrocardiographic abnormalities (mostly T wave inversion in V1-V3 leads), associated with arrhythmias, syncope, heart failure, and sudden death, but heterozygotes show no overall increased cardiac morbidity or mortality (Antoniades *et al.*, 2006).

Other DP mutations have been described in association with cardiac and cutaneous syndromes (Alcalai *et al.*, 2003; Uzumcu *et al.*, 2006): the phenotype in affected individuals involves abnormalities in the skin (blisters or PPK), hair (woolly), and heart (arrhythmogenic right ventricular cardiomyopathy). Two unrelated cases of “skin fragility/woolly hair syndrome” were found to be compound heterozygotes for different combinations of nonsense/missense mutations in desmoplakin, p.C809X/p.N287K, and p.Q664X/p.R2366C. These consist of keratoderma, woolly hair and nail dystrophy, but without cardiac abnormalities (Whittock *et al.*, 2002b).

Mutations in PKP are responsible for ectodermal dysplasia/skin fragility syndrome which results in trauma-induced skin erosions, dystrophic nails, sparse hair and painful PPK. Premature termination codons affecting both alleles of the PKP1 gene were found (McGrath *et al.*, 1997). Clues to the desmosomal pathology came from skin biopsy analysis, which showed widening of spaces between keratinocytes throughout most of the epidermis (apart from the basal layer) with ultrastructural evidence of a reduced number of small, poorly formed desmosomes. In total, nine different PKP1 mutations have been published (Lai-Cheong *et al.*, 2007), which

collectively, with cell biologic studies on keratinocytes lacking PKP1, demonstrate the importance of PKP1 in the formation of desmosomal plaques and in stabilizing desmosomal proteins (South *et al.*, 2003).

#### **2.3.4.6 Autoantibodies and DSG 1**

Pemphigus foliaceus and vulgaris are autoimmune disorders characterized by blisters and erosions of the skin with additional involvement of mucous membranes in pemphigus vulgaris. In pemphigus foliaceus, blistering occurs high in the epidermis, either in the granular layer or just beneath the stratum corneum, whereas in pemphigus vulgaris, the blistering occurs just above the basal layer of the epidermis (Whittock & Bower, 2003b). Compelling evidence has accumulated that IgG autoantibodies against DSG1 and DSG3 are pathogenic and play a primary role in inducing blister formation (Amagai, 2003).

Staphylococcal scalded skin syndrome (SSSS) is a generalized, confluent, superficially exfoliative disease that is caused by at least three serotypes of the exfoliative toxin (ET) of *Staphylococcus aureus*. The splits occur in the superficial epidermis, at the level of the granular layer (Amagai, 2003). Molecular modelling, crystallographic, and recombinant desmoglein cleavage studies have demonstrated that these toxins belong to a family of glutamic acid-specific serine proteases which target glutamic acid 383 within EC3 of DSG1 resulting in its cleavage (Whittock & Bower, 2003b). Thus circulating autoantibodies towards the extracellular domains of DSG1 can compromise essential cell-cell adhesion.

#### **2.3.4.7 Desmogleins and desmosome size and number**

It is believed that the distinctive distribution of lesions in patients with striate keratoderma result from impaired desmosome function where they are most stressed,



namely the palms and soles (Whittock *et al.*, 1999; Hunt *et al.*, 2001), although differences in desmosome structure and protein expression at these weight-bearing sites may be responsible for localisation (Wan *et al.*, 2003). Electron microscopy of involved skin has shown reduced numbers of desmosomes in suprabasal layers in both DP and DSG1 mutations with decreased desmosome size evident only in DSG1-associated SPPK (Wan *et al.*, 2004). Expression of keratins K5, K14 and K10 were also reduced in DSG1-associated SPPK, demonstrating perturbations in epidermal differentiation accompanied by a marked disruption of components of the epidermal scaffold including desmosomes and the keratin intermediate filament network. However, Wan *et al.* (2004) found that cell-cell adhesion and perinuclear aggregation of keratin intermediate filaments were less marked in DSG1-associated disease, postulating a possible compensation by other desmosomal cadherin family members. In our pedigree, although cell-cell dysadhesion was clearly evident in suprabasal layers on electron microscopy, desmosomes appeared normal in size and number. It is still not fully understood how a particular DSG1 mutation will result in such a specific phenotype. Although human and mouse models have given some insight, understanding the precise role of desmosomes in cell biology has been difficult owing to the heterogeneity of their molecular composition.

#### **2.3.4.8 DSG1 expression**

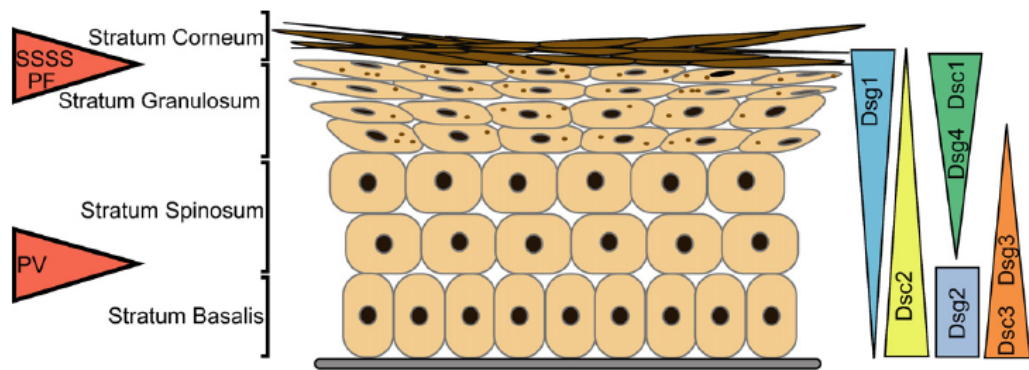
DSG1 expression is restricted to certain specialized epithelia such as epidermis, tongue, tonsil and oesophagus (Whittock & Bower, 2003b). Within the epidermis, desmoglein isoforms are expressed in a tightly regulated cell type- and differentiation-specific manner. The expression of DSC1/DSG1 and DSC3/DSG3 is restricted to certain stratified, squamous epithelia, in contrast to DSC2 and DSG2

which are expressed ubiquitously in all tissues that contain desmosomes, and can be found in simple epithelia, as well as in the myocardium and basal layer of complex epithelia (Dusek *et al.*, 2007). DSG1 and 3 are expressed in a graded and reciprocal fashion (Figure 20), with DSG1 being first expressed in the suprabasal layers of the epidermis but becomes more concentrated in the upper, most differentiated layers (Arneemann *et al.*, 1993). DSG2 is expressed in basal layers, DSG3 in basal and first suprabasal layers (Schmidt *et al.*, 1994) and DSG4 concentrated in the granular and cornified layers (Bazzi *et al.*, 2006). It has been suggested that the differentiation-specific pattern and ratios of desmosomal cadherins may regulate epidermal development and differentiation (Getsios *et al.*, 2004; Green & Simpson, 2007).

Immunohistochemistry of affected plantar skin of our patient demonstrated predominant spinous staining, with some weaker staining of the lower layers, which paralleled staining in PPK patients with other underlying mutations. Further study is required to assess fully the effect of the mutation on DSG1 expression.

#### **2.3.4.9 Desmoglein regulation influences tissue morphogenesis**

The specific distribution pattern of desmosomal components is not merely a result of differentiation but may drive tissue morphogenesis and function (Yin & Green, 2004). This differential expression pattern of desmosomal cadherins may indicate functions beyond adhesion, perhaps regulating cell behaviour (Dusek *et al.*, 2007). Transgenic mice in which the ratio of DSG3 to DSG1 in the suprabasal epidermis was altered by forced expression of DSG3 using an involucrin promoter, resulted in a lamellar histology resembling normal mucous membrane, and perinatal lethality due to severe dehydration following excessive transepidermal water loss. Premature loss of cohesion of corneocytes was evident on ultrastructural examination of the stratum



**Figure 20. Desmosomal cadherin expression patterns in epidermis (Dusek *et al.*, 2007).** Desmogleins (DSG) and desmocollins (DSC) are present in different layers of the epidermis, with relative levels shown by arrows (right hand side). Pemphigus vulgaris (PV), pemphigus foliaceus (PF)/staphylococcal scalded skin syndrome (SSSS) are associated with blisters at different locations, as shown by red arrows (left hand side). (Reproduced by kind permission of Elsevier Journals).

corneum (Elias *et al.*, 2001). These data demonstrate that differential expression of desmoglein isoforms affects stratum corneum structure and function.

A similar mouse model resulted in epidermal hyperproliferation and abnormal differentiation, using a K1 suprabasal promoter to drive abnormal differentiation (Merritt *et al.*, 2002). This phenotype had some features in common with human ichthyosiform diseases, again supporting the view that desmoglein isoform distribution contributes to the regulation of epidermal differentiation.

Multiple DSG isoforms confer similar levels of adhesion when expressed in undifferentiated human keratinocytes. Getsios *et al.* (2004) found that DSG1 uniquely promoted stratification and differentiation of cells growing in submerged culture of undifferentiated keratinocytes, with the ratio of DSG1:DSC1 being a critical determinant of desmosomal adhesion of fibroblasts. In DSG1-deficient organotypic epidermal “rafts” using siRNA-mediated knockdown, the intermediate layers and markers of spinous differentiation were under-represented (Green & Simpson, 2007). Specific removal of DSG1 adhesive ectodomain by chronic exposure to exfoliative toxin A did not inhibit stratification, which suggests that DSG1 is required for normal epidermal morphogenesis, independent of its adhesive role.

Furthermore, a number of cell adhesion proteins have been identified as caspase substrates involved in the programmed cell death pathway apoptosis. DSG1 has been shown to be a novel caspase and metalloproteinase substrate whose cleavage contributes to the dismantling of desmosomes and plays a role in regulation of keratinocytes undergoing UV-mediated apoptosis (Dusek *et al.*, 2006). Decreased expression of DSG1 in keratinocytes is associated with increased cytoplasmic and

nuclear levels of plakoglobin (Simpson *et al.*, 2007), upregulating Bcl2 expression and thus inhibiting apoptosis (Hakimelahi *et al.*, 2000). Although epidermal cornification does not involve induction of canonical apoptotic pathways (Lippens *et al.*, 2005), DSG1 deficiency may result in downregulation of pro-apoptotic signalling, possibly contributing to the pathogenesis of SPPK.

DP has been shown to cause increased keratinocyte proliferation, enhancing G<sub>1</sub> to S phase entry in the cell cycle (Wan *et al.*, 2007) suggesting that deficient desmosomal plaque function may trigger cell proliferation. The role of DSG1 in the regulation of cellular proliferation has not been explored to date.

Thus, DSG1 participates in both epithelial morphogenesis as well as being the target of differentiation-specific enzymes that remodel keratinocytes during the final stages of stratification and desquamation (Yin & Green, 2004). It is possible that this may play a role in how hyperkeratosis is transduced in DSG1-associated SPPK.

#### **2.3.4.10 DSG1 Mutation Sites**

As in most reported pedigrees, the novel mutation we have found in DSG1 is in the extracellular domain of the protein (Figure 19). In the majority of reports, premature termination codons are predicted to result in haploinsufficiency secondary to degradation of the aberrant DSG1 mRNA by nonsense mediated mRNA decay (NMD) (Cui *et al.*, 1995). Mutations in the DSG1 gene may affect the number and size of desmosomes (Wan *et al.*, 2004) although this was not detected using electron microscopy in our case. However the actual mechanism whereby desmosomal disruption due to DSG1 mutations results in this phenotype needs further molecular and cellular studies.

Similarly, premature termination codons are responsible for the majority of DP-associated cases although two exceptions were reported by Norgett *et al.* (section 2.3.4.5) (Norgett *et al.*, 2000; 2006). In SPPK associated with K1, an out-of-frame deletion results in the formation of a mutant protein lacking a portion of the glycine loop motif in the V2 domain but gaining 70 amino acids, causing disease either by a dominant negative effect or haploinsufficiency due to NMD.

Similar to the classical cadherins, DSG1 comprises a signal peptide to direct it to the endoplasmic reticulum, and a preprotein domain that ends in a basic cleavage recognition site RRQKR resulting in a mature protein of 1000 amino acids. The first three extracellular domains of desmogleins (EC1-3) are required for heterophilic binding to the first two extracellular domains of desmocollins. Within the desmosome, the cytoplasmic tails of desmogleins bind 'arm' repeats of PG (Whittock & Bower, 2003b).

### **2.3.5 Conclusion**

The novel mutation we report in the DSG1 gene in SPPK adds to the preponderance of mutations in this gene and emphasises the key role played by desmoglein 1 in the structure and function in the epidermal desmosomes. The phenotype is likely to be due to haploinsufficiency at points of maximum stress, but DSG1 mutations may have more subtle consequences for protein expression and desmosomal function yet to be identified.



## **Chapter 3.1 Morphological Analysis of Affected Plantar Skin in Inherited Palmoplantar Keratoderma**

### **3.1.1 Introduction**

Morphologic observation, investigation and nosologic distinction have always been important tools in dermatology (Anton-Lamprecht, 1994). Some of the defective molecules involved in inherited keratodermas have a primary role in maintaining the mechanical integrity of the epidermis and its appendages in the face of persistent physical trauma (Judge *et al.*, 2004), and defects may be expected to affect morphology. Moreover, analysing the structure of the epidermis may provide clues to the pathways involved in the pathogenesis of these diseases.

The pathogenesis of site-specific disorders, such as the inherited PPKs, and the underlying predilection factors are poorly understood (Swensson & Eady, 1996). In attempting to identify structural alterations in different forms of inherited PPK, it is also essential to understand the morphology of normal human palm and sole skin. A systematic study of histological and ultrastructural features in normal plantar skin and affected plantar skin from this cohort of inherited PPK was undertaken in an attempt to better identify common and distinct pathogenic pathways.

### **3.1.2 Materials and Methods**

Fresh elliptical plantar biopsies of affected skin were dissected into three pieces (chapter 2.2), two of which were prepared for paraffin-embedding and transmission electron microscopy respectively.



### **3.1.2.1 Tissue processing and sectioning of plantar skin: light microscopy**

The first piece of skin was processed for light microscopy at the Departments of Pathology, Southern General Hospital and Western Infirmary, Glasgow. The following steps were undertaken for routine specimen preparation, processing, embedding and cutting.

Specimens were fixed for 24 hours in 10% paraformaldehyde, and processed in a Shandon "Citadel 2000" automatic dehydration and wax machine. Embedding of the tissue was carried out using a Shandon Histocentre at 60°C. Paraffin sections (4µm) were cut with a Leitz 1501 rotary microtome. Sections were floated out on a water bath at 56°C and lifted onto 1% silane (Sigma Chemical Co., USA) coated glass microscope slides. The slides were allowed to dry on a 60°C hot plate and then incubated for 30 minutes at 80°C.

### **3.1.2.2 Haematoxylin and Eosin (H & E) staining**

The sections were deparaffinised and hydrated through a gradient of xylene (5 min), 95% ethanol (3min), 99% methanol (2min) and water (1 min). The slides were stained as follows:

- 4 min in Haematoxylin (CellPath)
- 1 min water
- 10 dips in acid/alcohol (1% hydrochloric acid in 70% methanol)
- 1 min in water
- 1 min in Scott's tap water substitute (0.04M NaHCO<sub>3</sub>, 0.16M MgSO<sub>4</sub>) to enhance the development of the haematoxylin colour
- 2 min in Putt's Eosin (CellPath)
- 10-20 dips in water

Slides were dehydrated in a gradient of 99% methanol (3min), 95% ethanol (3 min) and xylene (5min), before being finally fixed with Pertex mounting solution (CellPath, UK) using a coverslip. All pictures were taken with a Zeiss Axiovert S100 upright microscope.

A number of specific features were assessed: hypergranulosis (number of cell layers containing granules counted at 5 random points per section, mean and range recorded for 2 different sections); hyperkeratosis (thickness of stratum corneum, mm, measured at 5 random points per section, mean and range recorded for 2 different sections; ortho/parakeratosis or both, and corneum compact or basket-weave pattern); presence of acantholysis (either basal or suprabasal); presence of inflammatory infiltrate (dermal or dermal+epidermal; diffuse or focal); capillary enlargement in rete ridges; acanthosis (cell count from basal to granular layer at 5 random points per section, mean and range recorded for 2 different sections); quality of granules of granular layer (dust-like or coarse at high magnification); dermal papillae to rete ridges (measurement,  $\mu\text{m}$ , taken at 5 random points per section where possible, mean and range recorded for 2 different sections); sweat glands (any abnormalities noted, presence of parakeratosis in corneum around glands); spinous cells (even-ness of eosin staining/uneven prominent eosin staining); presence of mitotic figures in basal layer (number of mitotic figures counted/number of basal cells per section, mean and range recorded for 2 sections). A random selection of slides were also scored by a blinded second observer and results compared.

### **3.1.2.3 Light and electron microscopy**

The second piece of skin was further bisected and processed for transmission electron microscopy (TEM).

1. One piece was processed for morphological assessment by suspending in fixative which consisted of 2.5% glutaraldehyde in 0.1M phosphate buffer, pH 7.4 at 20°C for 1 hour. This was followed by further fixation in aqueous 1% osmium tetroxide for 60 minutes. The specimens were dehydrated in alcohol, then processed with propylene oxide and embedded in ARALDITE/Embed 812 (Cat.#13940) epoxy resin (Hayat, 1989).

**Semi-thin sections:** Thick resin sections (0.35-1µm) were cut with a glass knife (Reichert Ultracut E machine), mounted on glass slides and stained with 1% aqueous toluidine blue for examination preparatory to selecting an area for ultrathin sectioning. Gold or silver interference colour sections were cut using a diamond knife and mounted on Formvar coated copper grids (100-300 mesh).

**Ultra-thin sections:** The thin sections were stained with 2% methanolic uranyl acetate for 5 minutes and then with Reynold's lead citrate for 5 minutes before examination. Thin sections were examined in a Zeiss 902 transmission electron microscope operating at 80kV.

2. The second piece was processed for immunostaining by suspending in fixative which consisted of 0.25% glutaraldehyde/4% paraformaldehyde in phosphate buffer solution at 4°C for 1 hour. Specimens were dehydrated in alcohol, and processed for embedding in LR White resin for immunocytochemistry (Robertson *et al.*, 1992).

Ultrathin sections (60-80nm) were cut with a diamond knife and mounted on Formvar coated nickel grids (300 mesh). The sections were stained with 0.5% aqueous uranyl acetate (in 50% ethanol) and Reynolds lead citrate before observation in a Zeiss 902 transmission electron microscope operating at 80kV.

A number of specific features were assessed: abnormalities in keratin intermediate filaments e.g. loss of normal alignment, reduced number or keratin aggregation; desmosomes (discussed in Chapter 2.3); the presence of prominent keratohyaline granules and whether bipartite granules were seen; cytolysis; abnormalities in cornified cell envelope formation e.g. severe hyperkeratosis, loosely versus densely compacted stratum corneum; cell vacuolation and evidence of cell-cell separation.

#### **3.1.2.4 Control specimens**

Ethical approval was obtained from the Western Infirmary and the Southern General Hospital, Glasgow, to use the normal edges of acral skin biopsies (either plantar or palmar skin) in patients undergoing biopsy for other reasons, where the additional skin was being removed for surgical closure. Two biopsies of normal plantar skin and one of normal palmar skin from unaffected patients were obtained from the Department of Pathology, Western Infirmary for light microscopy, and processed in the same way as the PPK specimens.

Specimens of normal plantar skin from four unaffected patients (two of which were obtained at post-mortem) were kindly provided by Dr Patricia JC Dopping-Hepenstal, Department of Cell and Molecular Pathology, St John's Institute of Dermatology, where they had been processed for transmission electron microscopy to the embedding stage using standard methods (Eady RAJ, 1985). Processing differed only in the use of half-strength Karnovsky fixative (2% formaldehyde with 2.5% glutaraldehyde in Sørensen's phosphate buffer pH 7.4) as primary fixative immediately after biopsy, and in embedding in TAAB 812 (medium hardness) epoxy resin. Mounting onto Formvar coated copper grids was completed as above.

### 3.1.3 Results

Plantar skin biopsies were obtained from 16 subjects affected by keratoderma, and 3 controls.

#### 3.1.3.1 Light microscopy: H&E staining

*Histological changes are not uniform across different subtypes of inherited PPK and even vary between individuals within subtypes, other than the presence of prominent eosin staining of spinous cells in inherited PPK due to underlying K1 and K17 mutations.*

Hypergranulosis was most striking in Loricrin, K17 and DSG1 subtypes, with K1, K9 and Mitochondrial subtypes being comparable to normal acral controls (Tables 12a & b; Figure 21). There was evidence of alternating hypogranulosis evident in the Mitochondrial subtype (1/1), which was associated with alternating areas of parakeratosis and orthokeratosis. Stratum corneum was most markedly thickened in K17 and Loricrin subtypes, with K1, DSG1 and Mitochondrial subtypes comparable to normal acral controls. Acantholysis was noted in 1/2 K1, 2/2 K9, 2/8 K17, 1/2 Loricrin and 1/1 Mitochondrial patients and was not consistent within subtypes but varied between individuals. A dermal inflammatory infiltrate present in 5/8 K17, 2/2 Loricrin, 1/2 K9, 1/1 DSG1 and 1/1 Mitochondrial subtypes, was thus not unique to a specific subtype or uniform within subtypes. Acanthosis was most prominent in K17, DSG1, Loricrin and Mitochondrial subtypes with K1 and K9 subtypes comparable to normal acral controls. Deep epidermal ridges were present K17, DSG1, Loricrin and Mitochondrial subtypes only, in comparison to normal acral controls. Intense eosin

**Table 12a. Summary of histologic features in affected plantar skin of PPK patients compared to normal acral controls.**

<b>Patient/Underlying Mutation</b>	<b>Hyper-granulosis: mean (range)</b>	<b>Stratum Corneum: mm, mean (range)</b>	<b>Acantholysis: Basal or Suprabasal</b>	<b>Presence of Infiltrate (Y/N)</b>	<b>Capillary enlargement (Y/N)</b>
<b>KRT1 (n=2) Overall Mean</b>	<b>3.2 (1-5)</b>	<b>0.945 (0.5-1.4)</b>	<b>1/2</b>	<b>1/2</b>	<b>2/2</b>
Patient 1	2.8 (1-5)	0.9 (0.8-1.1) BW, Ortho	-	Y (D)	Y
Patient 2	3.6 (3-4)	0.99 (0.5-1.4) BW, Ortho, Prominent stratum lucidum	SB (focal)	N	Y
<b>KRT9 (n=2) Overall Mean</b>	<b>3.2 (2-4)</b>	<b>1.185 (0.32-1.5)</b>	<b>2/2</b>	<b>1/2</b>	<b>2/2</b>
Patient 3	3 (2-4)	0.42 (0.32-0.5) BW, Ortho	SB (extensive)	Y (D)	Y
Patient 4	3.4 (2-4)	1.95 (1.5-2.2), BW, Ortho	SB (focal)	N	Y
<b>KRT17 (n=8) Overall Mean</b>	<b>5.775 (1-10)</b>	<b>2.33 (0.8-3.8)</b>	<b>2/8</b>	<b>5/8</b>	<b>2/8</b>
Patient 5	4.4 (3-6)	1.7 (1.1-2.0) BW, Ortho/Para	-	N	N
Patient 6	7 (4-10)	2.5 (2.3-2.8) BW, Ortho	-	Y (D)	N
Patient 7	5.6 (3-8)	0.96 (0.8-1.1), BW, Ortho	-	N	N
Patient 8	7.4 (4-10)	2.9 (2.6-3.3), BW, Ortho/Para	SB (focal)	Y (D + E)	Y
Patient 9	5.2 (1-9)	3.6 (3.2-3.8), BW, Ortho	SB (focal)	Y (D)	N
Patient 10	6.8 (4-10)	2.7 (2.4-3.0) C, Ortho	-	Y (D)	N
Patient 11	3.8 (2-5)	1.4 (1.1-1.7), C, Ortho	-	N	Y
Patient 12	6 (4-9)	2.9 (2.6-3.2), BW, Ortho	-	Y (D)	N
<b>DSG1 (n=1) Overall Mean</b>	<b>5.4 (4-7)</b>	<b>0.8 (0.7-1.1)</b>	<b>0/1</b>	<b>1/1</b>	<b>0/1</b>
Patient 13	5.4 (4-7)	0.8 (0.7-1.1), BW, Ortho	-	Y (D)	N
<b>Loricrin (n=2) Overall Mean</b>	<b>7.1 (3-12)</b>	<b>2.55 (1.7-4.1)</b>	<b>1/2</b>	<b>2/2</b>	<b>2/2</b>
Patient 14	8 (6-12)	3.0 (2.4-4.1), BW, Ortho	SB (focal)	Y (D + E)	Y
Patient 15	6.2 (3-7)	2.1 (1.7-2.2), BW, Ortho	-	Y (D)	Y
<b>Mitochondrial Overall Mean</b>	<b>3.4 (1-6)</b>	<b>0.67 (0.3-1.4)</b>	<b>1/1</b>	<b>1/1</b>	<b>1/1</b>
Patient 16	3.4 (1-6) *alternating	0.67 (0.3-1.4), BW, Ortho, Prominent stratum lucidum, areas of parakeratosis	SB (focal)	Y	Y
<b>Controls (n=3) Overall Mean</b>	<b>3.6 (1-5)</b>	<b>0.92 (0.66-1.2)</b>	<b>0/3</b>	<b>0/3</b>	<b>0/3</b>

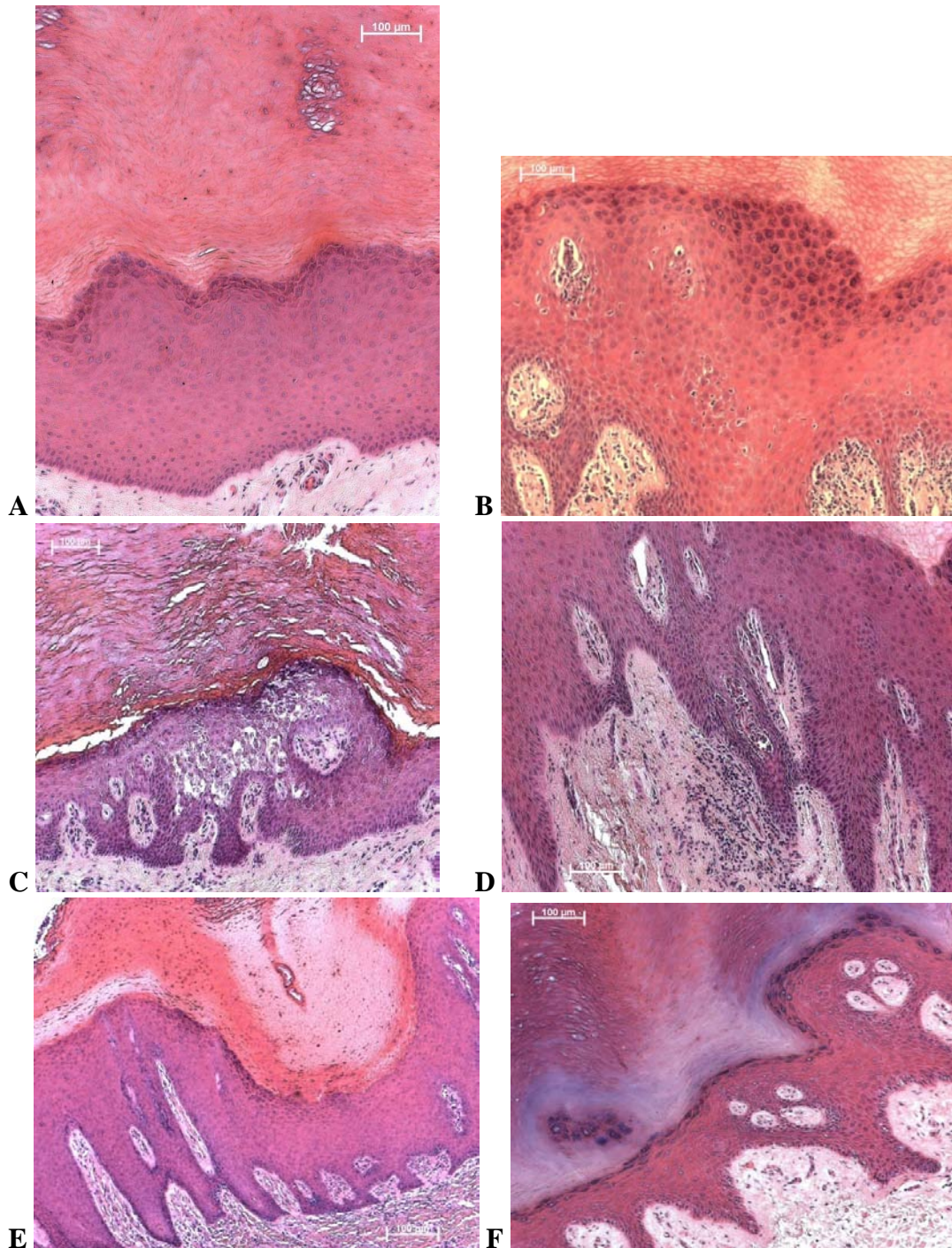
Subject 17	2.8 (1-5)	1.1 (0.9-1.2), BW, Ortho	-	N	N
Subject 18	4 (2-4)	1.0 (0.8-1.2), BW, Ortho	-	N	N
Subject 19 (palmar)	4 (4-4)	0.65 (0.66-0.67), C, Ortho	-	N	N

BW=Basket-weave pattern stratum corneum; C=Compact stratum corneum; B=Basal;  
SB=Suprabasal; D=Dermal infiltrate; E=Epidermal infiltrate:

**Table 12b. Summary of histologic features in affected plantar skin of PPK patients compared with normal acral controls.**

<b>Patient/Underlying Mutation</b>	<b>Acanthosis: Mean (range)</b>	<b>Granules: Coarse or Fine</b>	<b>Dermal papillae to rete ridges <math>\mu\text{m}</math>: mean (range)</b>	<b>Sweat glands</b>	<b>Spinous cells: Eosin staining even/prominent</b>	<b>Mitotic figures (per 1000 basal cells)</b>
<b>KRT1 (n=2) Mean Total</b>	<b>10.8 (5-16)</b>	<b>2/2 Coarse</b>	<b>186 (100-280)</b>		<b>2/2 Prominent eosin</b>	
Patient 1	10.4 (6-15)	Fine - Coarse	202 (100-280)	Normal	Prominent	<5
Patient 2	11.2 (5-16)	Fine - Coarse	170 (150-190)	None present	Prominent	6
<b>KRT9 (n=2) Mean Total</b>	<b>10.4 (6-15)</b>	<b>2/2 Coarse</b>	<b>146 (110-230)</b>		<b>0/2 Prominent eosin</b>	
Patient 3	7.6 (6-9)	Fine - Coarse	140 (130-160)	None present	Even	<5
Patient 4	13.2 (11-15)	Fine - Coarse	152 (110-230)	Normal	Even	5
<b>KRT17 (n=8)</b>	<b>17.1 (7-29)</b>	<b>8/8 Coarse</b>	<b>324 (120-630)</b>		<b>8/8 Prominent eosin</b>	
Patient 5	12.2 (9-16)	Fine - Coarse	148 (120-160)	Normal	Prominent	<5
Patient 6	13.8 (7-18)	Fine - Coarse	594 (520-630)	Normal	Prominent	<5
Patient 7	16.2 (8-24)	Fine - Coarse	310 (250-350)	Normal	Prominent	7
Patient 8	16.6 (8-26)	Fine - Coarse	405 (250-560)	Normal	Prominent	Difficult to assess
Patient 9	25 (15-34)	Fine - Coarse	285 (280-290)	None present	Prominent	2
Patient 10	17.6 (12-26)	Fine - Coarse	280 (170-430)	Normal	Prominent	7
Patient 11	17.8 (11-29)	Fine - Coarse	320 (300-330)	None present	Prominent	<5
Patient 12	17.8 (12-25)	Fine - Coarse	253 (290-360)	Normal	Prominent	<5
<b>DSG1 (n=1)</b>	<b>27.6 (10-35)</b>	<b>1/1 Coarse</b>	<b>460 (310-550)</b>			
Patient 13	27.6 (10-35)	Fine - Coarse	460 (310-550)	Normal	Even	<5
<b>Loricrin (n=2)</b>	<b>17.7 (10-44)</b>	<b>2/2 Coarse</b>	<b>318 (180-420)</b>		<b>0/2 Prominent eosin</b>	
Patient 14	19.4 (14-44)	Fine - Coarse	296 (180-420)	Normal	Even	Difficult to assess
Patient 15	16 (10-24)	Fine - Coarse	340 (300-380)	Normal	Even	<5
<b>Mitochondrial</b>	<b>20.6 (14-27)</b>	<b>1/1 Coarse</b>	<b>460 (310-550)</b>		<b>0/1 Prominent eosin</b>	
Patient 16	20.6 (14-27)	Fine - Coarse	460 (310-550)	Normal	Even	<5
<b>Controls (n=2)</b>	<b>10.5</b>	<b>3/3 Coarse</b>	<b>169 (130-220)</b>		<b>0/3 Prominent eosin</b>	
Subject 17	14.2 (9-17)	Fine - Coarse	184 (150-220)	Normal	Even	5
Subject 18	12.4 (8-16)	Fine - Coarse	172 (150-220)	Normal	Even	<5
Subject 19 (palmar)	4.8	Fine - Coarse	152 (130-170)	Normal	Even	<5





**Figure 21. Morphologic changes occurring in Haematoxylin and Eosin (H&E) stained affected plantar skin in PPK patients with underlying keratin 1, 17, 9, loricrin and mitochondrial mutations (a,b,c,d,e respectively) compared to normal unrelated plantar control (f).** (a) Hyperkeratosis present but no evidence of acanthosis or dermal inflammatory infiltrate; (b) hypergranulosis and diffuse dermal inflammatory infiltrate extending to epidermis; (c) hyperkeratosis and epidermolysis mainly in spinous layer; (d) localised dermal inflammatory infiltrate; (e) alternating hypergranulosis and absent granular layer associated with parakeratosis around sweat glands, with deep rete ridges; (f) prominent stratum corneum in normal plantar skin. Scale bar (a-f) = 100µm.

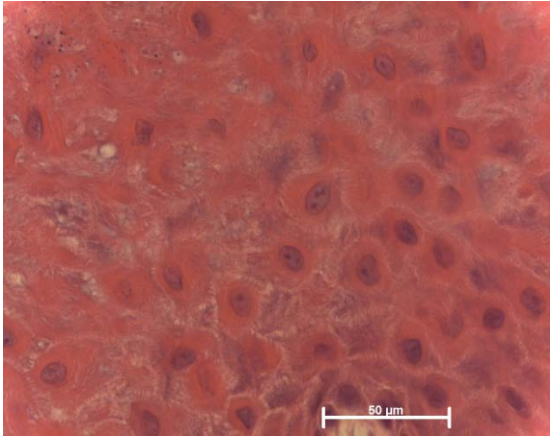
staining of spinous cells was particularly noted in all K17 and K1 patients (Figure 22) although pyknotic nuclei were not noted.

Scores were closely comparable with those of a blinded second observer. It was impossible accurately to score mitotic figures on 2/16 PPK patients due to the presence of a dermal and epidermal infiltrate, which penetrated the basal layer of the epidermis.

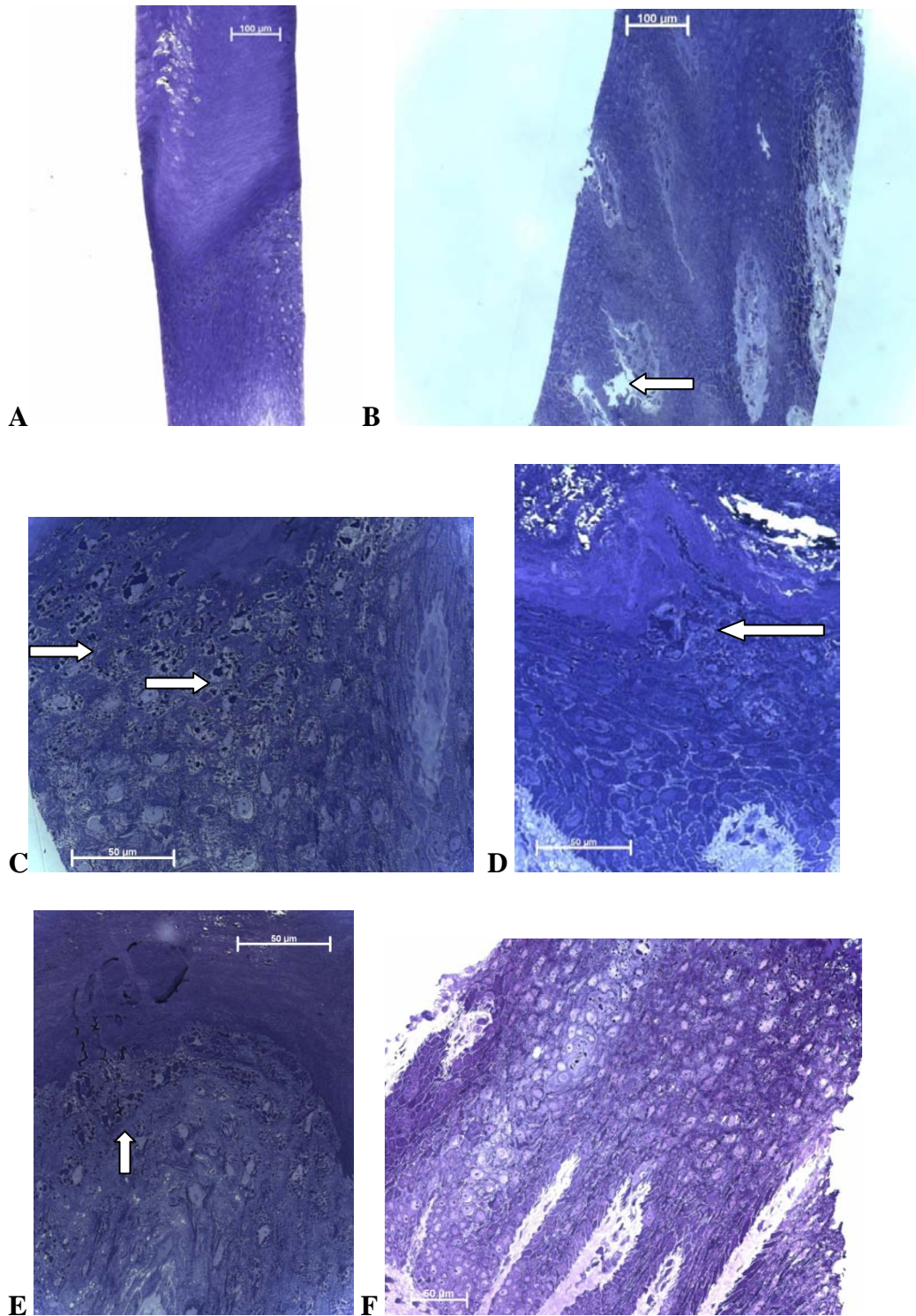
### **3.1.3.2 Light microscopy: semithin sections**

*Light microscopic analysis of semithin sections confirms prominent granules in PPK patients with underlying keratin mutations, suggestive of the presence of keratin aggregates, but is not a uniform feature in these subtypes.*

Skin from all PPK specimens showed orthohyperkeratosis, with no clear evidence of parakeratosis (Figure 23), and was a consistent feature on semithin analysis compared to normal plantar controls. Intercellular separation was detectable in both samples from patients with underlying K9 mutations, with one showing evidence of epidermolysis correlating to the H&E findings. The DSG1 patient also showed evidence of cell-cell separation/intercellular widening. Coarse inclusions in the granular layer were noted in 1/2 K1, 1/2 K9 and 6/8 K17 patients, suggestive of the presence of keratin aggregates; however coarse inclusions were also present in 1/4 plantar controls and 1/1 DSG1 patient (Table 13).



**Figure 22. Haematoxylin and Eosin (H&E) stained affected plantar skin in PC-2 patient with underlying K17 mutation showing prominent eosin staining in spinous layer. Scalebar 50μm.**



**Figure 23. Light Microscopic changes occurring in 1% aqueous toluidine blue stained semithin sections of affected plantar skin, in PPK patients with underlying lorcrin, mitochondrial, keratin 1, 9, and 17 mutations (a,b,c,d and e respectively) compared to normal unrelated plantar control (f). (a and b) Hyperkeratosis and acanthosis present, suggestion of acantholysis in (b); (c and e) demonstrate coarse inclusions in granular layer suggestive of keratin aggregates; (d) epidermolysis correlating to changes on H&E stained sections; (f) acanthosis of normal plantar skin, with some prominent granules. Scalebar: (a) =100  $\mu$ m; (b-e) =50  $\mu$ m.**

### 3.1.3.3 Electron microscopy

*Electron microscopy shows abnormal keratin filaments in PPK with underlying keratin mutations only but is not a uniform finding within subtypes, with other electron microscopic features also variable between individuals.*

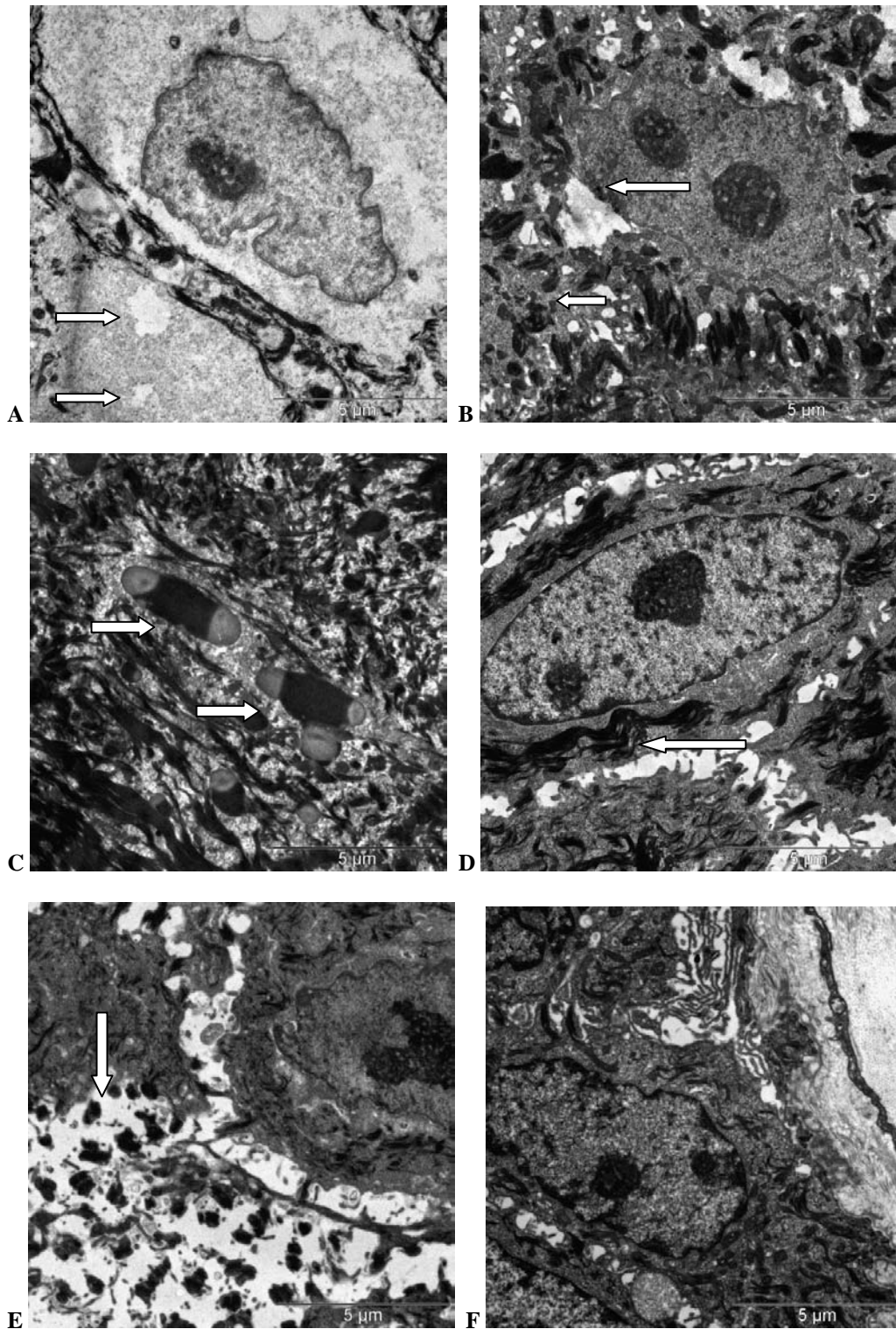
Despite the presence of coarse inclusions in the granular layer in 9/16 PPK and 1/4 plantar control on semithin sections, abnormal keratin filaments, such as keratin aggregates or loss of normal filament structure, were only confirmed by electron microscopy in 7/16 PPK patients and 0/4 controls (Table 14). Notably, the keratin filaments were condensed and compacted in a perinuclear distribution. Cytolysis was a feature in only 1/2 K1 and 1/2 K9 patients electron microscopically, despite both K9 patients showing acantholysis on H&E sections. Cell-cell separation was noted in 1/2 K9, and 1/1 DSG1 and Mitochondrial patients. Loosely compacted stratum corneum was evident in 3/16 PPK patients and cell vacuolation in 3/8 K17 and 1/1 DSG1 patients (Figures 24 & 25).

A lack of clarity of ultrastructural features was observed in plantar samples in 3/16 PPK patients (underlying mutations keratin 1, 17 and loricrin) and 1/4 plantar controls processed at St John's Institute of Dermatology. It was thought that the most likely reason for this was poor infiltration of fixative during processing. As patient samples were collected sequentially, adjustments were made in the timing of alcohol dehydration steps after each of these cases, but with minimal impact on infiltration quality. It was concluded that the difficulties encountered in infiltration occurred immediately at the time the biopsy was suspended in fixative (2.5% glutaraldehyde, Glasgow and half-strength Karnovsky's fixative, London) and possibly related to the

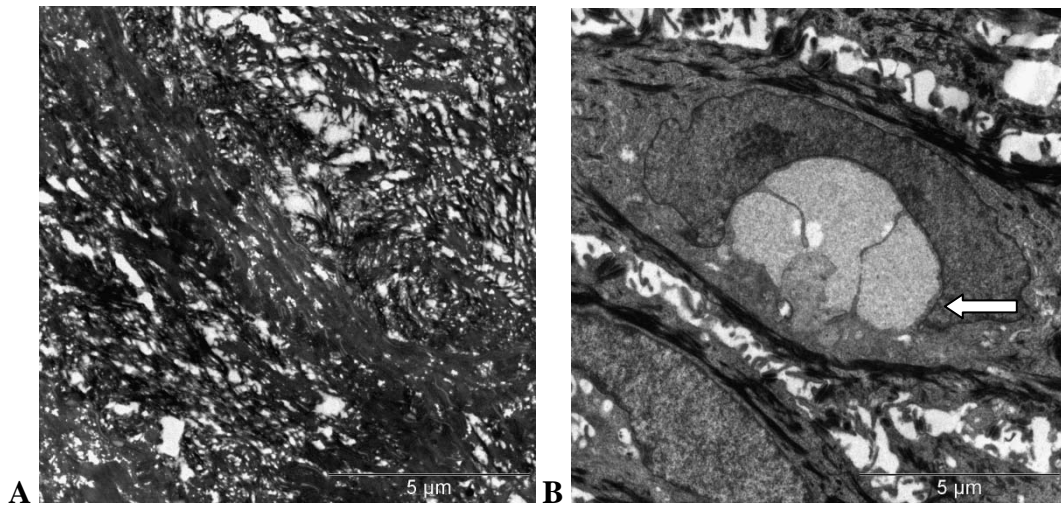
**Table 14. Summary of Electron Microscopic Features in Affected Plantar skin in PPK patients compared with normal unrelated plantar controls.**

<b>Patient Subtype (Number of patients, n)</b>	<b>Abnormal keratin filaments</b>	<b>Abnormal Desmosomes</b>	<b>Keratohyaline granules</b>	<b>Cytolysis</b>	<b>Hyper-keratosis</b>	<b>Cell Vacuolation</b>	<b>Cell-cell Separation</b>
<b>KRT1 (2)</b>	1/2	0/2	1/2	1/2	2/2	0/2	0/2
<b>KRT9 (2)</b>	1/2	0/2	0/2	1/2	2/2 (1 LC)	0/2	1/2
<b>KRT17 (8)</b>	5/8	0/2	2/8 (2 bipartite)	0/8	8/8 (2 LC)	3/8	0/8
<b>DSG1 (1)</b>	0/1	See ch. 3.4	1/1	0/1	1/1	1/1	1/1
<b>Loricrin (2)</b>	0/2	0/2	0/2	0/2	2/2	0/2	0/2
<b>Mitochondria (1)</b>	0/1	0/1	0/1	0/1	1/1	0/1	1/1
<b>Controls (4)</b>	0/4	0/4	0/4	0/4	0/4	0/4	0/4

LC= Loosely compacted stratum corneum



**Figure 24. Electron micrographs of affected plantar skin in PPK patients with underlying keratin 1, 9, 17, loricrin and mitochondrial mutations (a, b, c, d, e respectively), compared to normal unrelated plantar control (f). (a) Lucent area suggestive of cytolysis within cytoplasm; (b) keratin aggregates (short arrow) and areas of cytolysis (long arrow); (c) presence of bipartite keratohyaline granules; (d) normal keratin filaments and no prominent granules; (e) evidence of cell-cell separation correlating to area of acantholysis on semithin and (f) normal filaments and intercellular connections at dermo-epidermal junction. Scalebars = 5µm.**



**Figure 25. Electron micrographs of affected plantar skin in PPK patients with underlying K9 and K17 mutations (a, b respectively). (a) Loosely compact stratum corneum; (b) vacuolation within keratinocytes.**



thickness of the specimen itself. The number of samples in which this was encountered was comparable between Glasgow and London processing (ratio approximately 1:4) despite using different fixatives, suggestive of a physical problem with penetration of the fixative in these cases. Optimal infiltration of acanthotic and hyperkeratotic acral skin was achieved when the skin biopsy was physically dissected as thinly as possible.

### **3.1.4 Discussion**

#### **3.1.4.1 Ridged or glabrous skin of palms and soles**

The ridged epidermis of palmoplantar skin is a unique tissue because of the amount of physical stress which it has to endure. To endure this stress, it has evolved structural specializations which bring their own hazards. For instance, the epidermis normally grows thicker in response to physical stress: palmoplantar skin also becomes abnormally thickened and keratotic in many skin disorders caused by mutations in genes which weaken the cell cytoskeleton (Swensson *et al.*, 1998) (see chapter 1).

#### **3.1.4.2 Structural clues to genetic disorders of the epidermis**

Hereditary skin diseases, such as the inherited PPKs, have been characterized by a variety of histological and ultrastructural features. Indeed, a morphologic approach, using light microscopy, transmission electron microscopy in combination with immunofluorescence and immunoelectron microscopy, provided vital clues to candidate proteins and genes prior to their identification (Eady *et al.*, 1994; Anton-Lamprecht, 1994).

### 3.1.4.3 Keratin aggregation in inherited PPK

Condensation of tonofilament bundles in suprabasal keratinocytes, with aggregation and a reduction of intermediate filaments in the perinuclear cytoplasm has been noted in inherited PPK due to underlying keratin mutations, including K16 in PC-1 (McLean *et al.*, 1995; Smith *et al.*, 1999a), K17 in PC-2 (McLean *et al.*, 1995), K1 in epidermolytic PPK (Hatsell *et al.*, 2001), and K9 in epidermolytic PPK (Navsaria *et al.*, 1995). Aggregates have been noted to be present in whorl-like configurations (McLean *et al.*, 1995), sparse amounts of thin and short keratin filament bundles being present in the periphery of the cytoplasm (McLean *et al.*, 1995) and tight clumps being present at the cell surface often adjacent to desmosomes (Hatsell *et al.*, 2001). Less dense and shorter keratin intermediate filaments have been reported in K1 mutations in striate PPK (Whitlock *et al.*, 2002a) and interestingly, perinuclear keratin aggregation and compaction has also been noted in striate PPK caused by desmoplakin mutations (Armstrong *et al.*, 1999; Whitlock *et al.*, 1999).

Unusual ultrastructural changes in keratin morphology have been observed in suprabasal keratinocytes in two Dutch EPPK families with underlying K1 mutations (Teron-Kwiatkowski *et al.*, 2006), two German EPPK families with the same underlying mutation (Wevers *et al.*, 1991; Grimberg *et al.*, 2009), diffuse PPK of unknown molecular aetiology (Anton-Lamprecht, 1994) and a further German family with a novel K1 mutation two residues upstream from the original one reported in the 1B domain (Grimberg *et al.*, 2009). Rather than forming bundles, the suprabasal keratin instead formed tubular structures, seen in both longitudinal and transverse sections, coining the term “tonotubular” keratin aggregation. Teron-Kwiatkowski *et al.* (2006) postulated that a single amino-acid substitution in the 1B domain of the K1

rod domain was responsible for generating the tonotubular phenotype, due to an abnormal hydrophobic dimer-dimer and/or filament interaction

Keratin aggregation is not a structural change which is unique to the inherited PPKs, but is present in a number of other disorders of keratin proteins, including epidermolysis bullosa Dowling-Meara (Anton-Lamprecht, 1996), where it is associated with electron-dense aggregates of K5/K14 in the cytoplasm of some basal keratinocytes (Anton-Lamprecht & Schnyder, 1982; Ishida-Yamamoto *et al.*, 1991) which may or may not predispose those particular cells to rupture. EH or BCIE due to K1 and K10 mutations is characterized by suprabasal keratin clumping, originally thought to relate to increased amounts of filaggrin but shown to relate to K1 and K10 (Ishida-Yamamoto *et al.*, 1992; 1994; Anton-Lamprecht, 1994). Ichthyosis bullosa of Siemens demonstrates keratin clumping in granular layers only and ichthyosis hystrix Curth-Macklin in suprabasal layers (Anton-Lamprecht, 1994).

Intermediate filaments are highly dynamic structures, with the entire keratin network being in constant motion despite bundle size and desmosomal anchorage (Yoon *et al.*, 2001). In order to examine the effect on keratin dynamics by EBS-type mutations, epithelial cells were transfected with mutant K14, revealing keratin aggregates to be highly dynamic whereas filaments were extremely static (Werner *et al.*, 2004). This data points to the transient nature of keratin aggregates in cells.

In our cohort, perinuclear keratin aggregation was present in a majority of patients with underlying keratin mutations, but this was not a uniform finding. This raised the possibility that this is a secondary phenomenon as opposed to a critical step in the development of plantar hyperkeratosis, although it is also possible that the absence of keratin aggregation was a sampling phenomenon and may have been

present in other areas of hyperkeratotic plantar skin, particularly given the transient nature of aggregates. The presence of keratin aggregates in pedigrees with desmoplakin and not keratin mutations (Whittock *et al.*, 1999; Armstrong *et al.*, 1999) also raises the possibility that this structural abnormality is a secondary finding.

#### **3.1.4.4 Granular layer abnormalities, keratohyaline granules and acanthosis in inherited PPK**

Acanthotic ridged epidermis with markedly reduced granular layer in places has been reported in PC-2 due to K16 and K17 mutations with granular cells showing reduced amounts of keratohyalin ultrastructurally (McLean *et al.*, 1995). However, hypergranulosis and acanthosis are more commonly reported features (Camisa & Rossana, 1984; Sybert *et al.*, 1988; Navsaria *et al.*, 1995; Magro *et al.*, 1997; Kljuic *et al.*, 2003b). However, a comparison of acanthosis in inherited PPK to control plantar tissue has not been made in the majority of these reports. Although in some inherited PPK subtypes in our cohort, acanthosis was notably more severe than in acral controls, in others there was very little difference, emphasising the need to assess the structural features of keratoderma in relation to normal glabrous skin.

Darkly stained perinuclear inclusions in upper spinous layers or darkly staining granular or filamentous material have been noted by light microscopy in PC-2 due to K16 and K17 mutations (McLean *et al.*, 1995), SPPK due to desmoplakin mutations (Armstrong *et al.*, 1999), EPPK due to K1 mutation (Terron-Kwiatkowski *et al.*, 2006), and large and variable granules noted on electron microscopy of inherited PPK of unknown aetiology (Magro *et al.*, 1997). In comparison, keratohyaline granules have also been described as not overtly abundant in EPPK

due to K9 mutation (Navsaria *et al.*, 1995). Hypergranulosis and prominent keratohyaline granules are a feature in some cases of loricrin keratoderma (Maestrini *et al.*, 1996; Korge *et al.*, 1997; Ishida-Yamamoto *et al.*, 1998a) and granules in these cases are loricrin-positive aggregates (Ishida-Yamamoto *et al.*, 1998a).

Ultrastructurally, vacuolization in suprabasal keratinocytes is a non-specific finding documented in a number of subtypes of inherited PPK, as are intracellular and intercellular oedema of the stratum spinosum (Smith *et al.*, 1999a), which was consistent with the findings in our cohort. Intercellular oedema or loosening of intercellular connections has been commonly reported in SPPK due to desmoplakin mutations (Armstrong *et al.*, 1999; Whittock *et al.*, 1999; Norgett *et al.*, 2000) and desmoglein 1 mutations (Wan *et al.*, 2004).

The findings in our cohort are consistent with the variations between individuals and subtypes in the literature. Although acanthosis is commonly reported, the degree of acanthosis compared to normal controls is variable. Both hypogranulosis and hypergranulosis with prominent granules are both features of inherited PPK and not specific to particular subtypes. This is suggestive that these epidermal changes are secondary as opposed to primary pathogenic phenomena.

#### **3.1.4.5 Cytolysis/epidermolysis in inherited PPK**

Epidermolysis is a feature of inherited PPK limited to subtypes caused by K1 and K9 mutations (Navsaria *et al.*, 1995; Hatsell *et al.*, 2001; Terron-Kwiatkowski *et al.*, 2006). However, epidermolysis has not always been identified by all methods of structural examination e.g. light and electron microscopy, and may indeed be a subtle finding (Hatsell *et al.*, 2001). Although evidence of epidermolysis was seen in all 4 of the K1 and K9 patients in our cohort either on light or electron microscopy, this

was not a feature that was uniformly apparent for each patient in all sections or by all methods. This highlights the limitations of structural analysis: epidermal changes may not be uniform across all areas of affected plantar skin and accurate documentation of structural features is limited by the size of tissue obtained, the site biopsied and also they may change over time. Ideally, serial biopsies should be performed although this is clinically impractical.

#### **3.1.4.6 Cornified envelope in inherited PPK**

Although always thickened in the inherited PPKs, the stratum corneum has often been reported as appearing intact morphologically (Sybert *et al.*, 1988; Navsaria *et al.*, 1994; Magro *et al.*, 1997; Armstrong *et al.*, 1999; Hatsell *et al.*, 2001; Kljuic *et al.*, 2003b). Orthohyperkeratosis (McLean *et al.*, 1995; Smith *et al.*, 1999) and prominent stratum lucidum have been noted in PC-2 due to K16 and K17 mutations (McLean *et al.*, 1995). In EPPK due to K9 mutation, some extension of keratin aggregates into lower parts of the stratum corneum were noted (Navsaria *et al.*, 1995) although the enlarged stratum corneum was otherwise normal. Parakeratosis has been noted in some cases of loricrin keratoderma (Ishida-Yamamoto *et al.*, 1998a). Ultrastructurally, little comment has previously been made on the degree of compaction of the stratum corneum; 3/16 PPK patients in our cohort had evidence of loosely compacted stratum corneum although the significance of this remains unclear.

#### **3.1.4.7 Inflammatory infiltrate in inherited PPK**

There is a paucity of evidence of inflammation in affected plantar skin in inherited PPK. Two cases of unknown molecular aetiology show evidence of inflammatory cells surrounding capillary loops extending into the dermal papillae (Sybert *et al.*,

1988) and mild perivascular dermal inflammatory infiltrate (Kabashima *et al.*, 2008). The presence of inflammation probably will vary with time and the severity of clinical features at the time of biopsy, however this was not an uncommon feature in our cohort and often associated with some capillary prominence in the dermal papillae. As this is not a uniform feature however, it is not likely to be a primary mechanism in the development of hyperkeratosis.

#### **3.1.4.8 Dyskeratosis**

The term “dyskeratosis” denotes imperfect keratinisation of individual epithelial cells whose histological features on H&E stains include nuclear pyknosis and condensed, intensely eosinophilic cytoplasm (Bergman *et al.*, 2008). Epidermal dyskeratosis characterizes other hereditary skin diseases associated with keratin clumping ultrastructurally, such as Darier disease and ichthyosis hystrix of Curth-Macklin (Mann & Haye, 1970; Gottlieb & Lutzner, 1973; Kanerva *et al.*, 1984). It has more recently been described in EH/ BCIE (McKee, 1996; Bergman *et al.*, 2008), EPPK due to K9 mutations (Bergman *et al.*, 2008) and in one inherited PPK case of unknown molecular aetiology (Magro *et al.*, 1997). Although dyskeratosis was not a feature in our cohort, with no evidence of nuclear pyknosis, there was striking evidence of prominent, homogenous, eosinophilic cytoplasm throughout the spinous layers of the K1 and K17 subtypes. Although this may reflect intracellular aggregates of tonofilaments, ultrastructurally this was not confirmed in all cases.

#### **3.1.5 Conclusion**

Plantar hyperkeratosis is not readily distinguishable between inherited PPK of different underlying genetic causes by morphological study. In studying multiple specimens and multiple subtypes, it is clear that there is considerable histological

variation both within and between subtypes. Although certain specific features may be more common in particular subtypes e.g. keratin aggregates in inherited PPK due to underlying keratin mutations, these features are not uniformly found and are not pathognomonic. This raises the possibility that many of the structural features of inherited PPK reported in previous studies are secondary phenomena rather than critical steps in the pathogenesis of hyperkeratosis. Previous study has also been hampered by the lack of comparison with appropriate control material, and the important differences in normal glabrous/ridged skin.





## **Chapter 3.2 Immunocytochemical Analysis of Affected Plantar Skin in Inherited Palmoplantar Keratoderma**

### **3.2.1 Introduction**

Proliferation and terminal differentiation are tightly controlled in human epidermis (chapter 1) and a constant balance between these processes is critical in maintaining normal epidermal structure and function. Alterations in this balance are likely to contribute to a variety of skin diseases, such as the inherited PPK.

Changes in the expression pattern and distribution of markers of differentiation and turnover were anticipated in PPK, whatever the aetiology. Following the initial histological and ultrastructural analysis, an immunocytochemical study was performed examining a selection of markers of differentiation including a selection of keratins representative of different stages of differentiation (keratins 1,9,14 and 17) and markers of late differentiation (filaggrin, loricrin and involucrin). Markers of proliferation (Ki67) and apoptosis (activated caspase-8) were also studied.

### **3.2.2 Materials and Methods**

#### **3.2.2.1 Patients and tissue specimens**

Immunocytochemical analysis of affected plantar skin in all 16 patients recruited was undertaken. Fresh elliptical plantar biopsies of affected skin were dissected into three pieces (chapter 2.2), one of which was prepared for paraffin-embedding.

#### **3.2.2.2 Tissue processing and sectioning**

Affected plantar skin was processed for light microscopy at the Departments of Pathology, Southern General Hospital and Western Infirmary, Glasgow. Routine

specimen preparation, processing, embedding and cutting was performed as in chapter 3.1.2.1.

### **3.2.2.3 Control Specimens**

Control specimens used were obtained as for H&E staining, chapter 3.1.2.4. Two biopsies of normal plantar skin and one of normal palmar skin from unaffected patients were obtained from the Department of Pathology, Western Infirmary for light microscopy, and processed in the same way as the PPK specimens.

### **3.2.2.4 Antibodies**

Sections were stained with the following markers of differentiation, epidermal proteins and markers of proliferation/apoptosis (Table 15).

### **3.2.2.5 Immunocytochemistry on paraffin-embedded tissue**

Paraffin-embedded tissue sections (4 $\mu$ m) were incubated for 30 min at 80°C and rehydrated (as described for H&E staining). Rehydrated sections were then gently put into a pressure cooker containing 1 litre pre-heated 10mM citrate buffer (LabVision, pH=6.0). The sections were then microwaved on full power for 10 min and then left to cool for 20 min. After washing twice in phosphate buffered saline, PBS (Sigma, UK) over 5 min, sections were incubated for 10 min in fresh 3% hydrogen peroxide. After washing in PBS over 5 min, sections were incubated with normal rabbit serum, 1:5 dilution in PBS (DakoCytomation, UK) for primary mouse antibodies or normal goat serum, 1:5 dilution in PBS (DakoCytomation, UK) for primary rabbit antibodies. The blocking solution was removed and then the sections were incubated with appropriate primary antibodies diluted in PBS (Table 15) at 37°C for 1 hour. After 3x5min washes in PBS, the sections were incubated for 20 min with biotinylated rabbit anti-mouse antibody (DakoCytomation, UK) diluted

**Table 15.** List of antibodies, isotypes, sources, and dilutions

Antibody Against	Antibody Type	Isotype	Catalogue or clone no.	Dilution	Source
CK1	Mouse M AH	IgG1	NCL-CK1	1:50	Novo Castra, UK
CK9	Mouse M AH	IgG1, IgG3	Ab19124	1:25	Abcam, UK
CK14	Mouse M AH	IgG3	NCL-LL002	1:50	Novo Castra, UK
CK17	Mouse M AH	IgG2b	NCL-CK17	1:50	Novo Castra, UK
Filaggrin	Mouse M AH	IgG1, kappa	NCL- FILAGGRIN	1:50	Novo Castra, UK
Involucrin	Mouse M AH	IgG1	NCL-INV	1:200	Novo Castra, UK
Loricrin	Rabbit P AH/AM	IgG	Ab24722	1:500	Abcam, UK
Ki-67	Mouse M AH	IgG1, kappa	MIB-1, M7240	1:25	DakoCytomation, UK
Caspase-8	Mouse M AH	IgG1	NCL-CASP-8	1:50	Novo Castra, UK

CK=cytokeratin; M=Mouse monoclonal; Rabbit P=Rabbit Polyclonal; AH=Anti-human; AM=Anti-mouse

1:100 in PBS for primary mouse antibodies, or biotinylated goat anti-rabbit antibody (DakoCytomation, UK) diluted 1:100 in PBS for primary rabbit antibodies. The sections were again washed 3x5 min in PBS. Avidin horse-radish peroxidase conjugate (DakoCytomation, UK) diluted 1:100 in PBS was added and incubated for 20 min. Samples were washed 3x5min in PBS and colour developed using Liquid DAB+ Substrate Chromagen System (DakoCytomation, UK). Negative controls were established omitting the primary antibody. Sections were counterstained with haematoxylin, dehydrated and fixed (as described in 3.1.2.2). Sections were observed and photographed using a Zeiss Axiovert S100 microscope. All sections were stained in duplicate or triplicate per antibody, except for CK9 and CK17 where sections were stained a minimum of 6 times per antibody using a variety of different conditions (see below). A selection of sections per antibody used were analysed by a blinded

second observer for comparison of analysis. 2/8 K17 PPK samples were not used in the final analysis due to the poor quality of epidermal sections obtained.

#### *Involucrin*

High temperature antigen unmasking technique using citrate buffer/microwave was not required, and this step was omitted.

#### *Cytokeratins 9 and 17*

A variety of conditions were altered for these two antibodies in an attempt to optimise staining, including incubation periods with the primary antibody of 2 hours at room temperature and overnight at 4°C. Optimal staining was obtained at incubation for 1 hour at 37°C. Microwave times were also altered (reduced and increased) for the citrate buffer high temperature antigen retrieval step, but optimal conditions were achieved at 10 min full power.

Enzyme digestion was also performed for CK 9 staining, using either trypsin or pronase, in an attempt to optimise conditions. The sections were incubated in 0.1% Trypsin Type II-S (Sigma Chemical Co) and 0.1% calcium chloride in distilled water for 30 min at 37°C, washed in running tap water to stop enzyme digestion, then washed in Tris-buffered saline for 5 min prior to immunocytochemical staining. Sections were also incubated in 0.1% Pronase Type XIII (Sigma Chemical Co) in PBS for 15-20 min at room temperature, washed in running tap water to stop enzyme digestion, then washed 2x5 min in PBS prior to immunocytochemical staining. Optimal staining for CK9 was achieved using the high temperature antigen retrieval step using citrate buffer and incubating with primary antibody for 1 hour at 37°C. Repeat antibodies were purchased from Abcam and Novocastra for CK9 and CK17 respectively, and staining repeated with minimal improvement in quality of staining.

### **3.2.3 Results**

#### **3.2.3.1 Markers of differentiation**

Cytokeratin 1 staining was predominantly suprabasal in both inherited PPK and control specimens, and essentially cytoplasmic in pattern. Weak patchy basal nuclear staining was also noted in 1/2 Loricrin, 1/6 K17 and 1/1 Mitochondrial PPK subtypes (Figure 26; Table 16)

Cytokeratin 9 staining showed patchy spinous layer cytoplasmic staining in inherited PPK and control specimens. Despite multiple attempts at staining using different conditions (see methods), the intensity of staining remained weak throughout (Figure 27; Table 17). Alternating vertical bands of K9 positive cells was seen in 1/2 Loricrin subtype.

Cytokeratin 14 staining showed continuous predominantly cytoplasmic staining of basal and spinous layers in both inherited PPK and control specimens (Figure 28; Table 18).

Normal non-acral skin demonstrated strong positive cytokeratin 17 staining for sebaceous glands and hair follicles with no epidermal staining. Staining of inherited PPK showed weak patchy suprabasal or spinous layer staining only and the mitochondrial PPK subtype showed no staining despite repeated attempts using slightly altered conditions (see methods) (Table 19). Plantar control revealed similar staining patterns to inherited PPK plantar samples, compared to palmar control which showed positive staining of glands (Figure 29).

**Table 16.** Cytokeratin 1 pattern of staining

PPK Subtype (Number, n)	Distribution of Staining	Pattern of Staining	Intensity (-/+ /++ /+++)
KRT1 (2)	SB (2/2) *(1/2)	C; patchy N (1/2)	+++
KRT9 (2)	SB (2/2)	C	+++
KRT17 (6)	SB (6/6); B patchy (1/6)	C	SB++ B+
DSG1 (1)	SB (1/1)	C	++
Loricrin (2)	SB (2/2); B patchy (1/2)	C; B=N	C +++ B +
Mitochondria (1)	SB + B patchy (1/1)	C; B=N	C +++ B +
Controls (3)	SB (3/3)	C	++

SB=Suprabasal; B=Basal; C=Cytoplasmic; N=Nuclear;  
\* Suggestion of cytoplasmic clumps of staining

**Table 17.** Cytokeratin 9 pattern of staining

PPK Subtype (Number, n)	Distribution of Staining	Pattern of Staining	Intensity (-/+ /++ /+++)
KRT1 (2)	Sp (2/2)	C	+
KRT9 (2)	Sp+SB (2/2)	C	+
KRT17 (6)	Sp (6/6)	C	+
DSG1 (1)	Sp (1/1)	C	+
Loricrin (2)	Sp (2/2)	C	+
Mitochondria (1)	Sp (1/1)	C	+
Controls (3)	Sp (3/3)	C	+

Sp=Spinous; SB=Suprabasal; C=Cytoplasmic;

**Table 18.** Cytokeratin 14 pattern of staining

PPK Subtype (Number, n)	Distribution of Staining	Pattern of Staining	Intensity (-/+ /++ /+++)
KRT1 (2)	B+Sp (2/2) *(1/2)	C+M	+++
KRT9 (2)	B+Sp (2/2)	C+M	+++
KRT17 (6)	B+Sp (6/6)	C+M	++
DSG1 (1)	B+Sp (1/1)	C+M	+++
Loricrin (2)	B+Sp (2/2)	C+M	++
Mitochondria (1)	B+Sp (1/1)	C+M	++
Controls (3)	B+Sp (3/3)	C+M	++

B=Basal; Sp=Spinous; C=Cytoplasmic; M=Membranous  
\*Suggestion of cytoplasmic clumps of staining

**Table 19.** Cytokeratin 17 pattern of staining

PPK Subtype (Number, n)	Distribution of Staining	Pattern of Staining	Intensity (-/+ /+++ /+++)
KRT1 (2)	SB patchy (2/2)	C	+
KRT9 (2)	Sp patchy (2/2)	C	+
KRT17 (6)	Sp patchy (6/6)	C	+
DSG1 (1)	Sp patchy (1/1)	C	++
Loricrin (2)	SB patchy	C	+
Mitochondria (1)	Nil	-	-
Controls (3)	SB patchy	C	+

SB=Suprabasal; Sp=Spinous; C=Cytoplasmic

**Table 20.** Filaggrin pattern of staining

PPK Subtype (Number, n)	Pattern of Staining	Keratohyaline Granules	Intensity (-/+ /+++ /+++)
KRT1 (2)	Gr; Cont (2/2)	C (2/2)	++
KRT9 (2)	Gr; Cont (2/2)	C (2/2)	++
KRT17 (6)	Gr; Cont (2/2)	C (5/6); F (1/6)	++
DSG1 (1)	Gr; Cont (1/1)	C (1/1)	++
Loricrin (2)	Gr; Cont (1/2); P (1/2)	C (2/2)	++
Mitochondria (1)	Gr; P (1/1)	C (1/1)	++
Controls (3)	Gr; Cont (3/3)	C (3/3)	++

Gr=Granular; Cont=Continuous staining; P=Patchy; C=Coarse; F=Fine;

**Table 21.** Involucrin pattern of staining

PPK Subtype (Number, n)	Distribution of Staining	Pattern of Staining	Intensity (-/+ /+++ /+++)
KRT1 (2)	Sp; B/Gr weaker (2/2)	M+C	Sp +++ B/Gr +
KRT9 (2)	Sp; B/Gr patchy (2/2)	M+C	Sp +++ B/Gr +
KRT17 (6)	Sp; B/Gr patchy (6/6)	M+C	Sp+++ B/Gr +
DSG1 (1)	Sp; B patchy (1/1)	M+C	Sp +++ B +
Loricrin (2)	Sp; B/Gr patchy (2/2)	M+C	Sp +++; B ++; Gr +
Mitochondria (1)	Sp; B/Gr weaker (1/1)	M	Sp +++; B/Gr ++
Controls (3)	Sp; Gr weaker (3/3)	M+C	Sp++, Gr +

Sp=Spinous; B=Basal; Gr=Granular; M=Membranous; C=Cytoplasmic;



**Table 22.** Loricrin pattern of staining

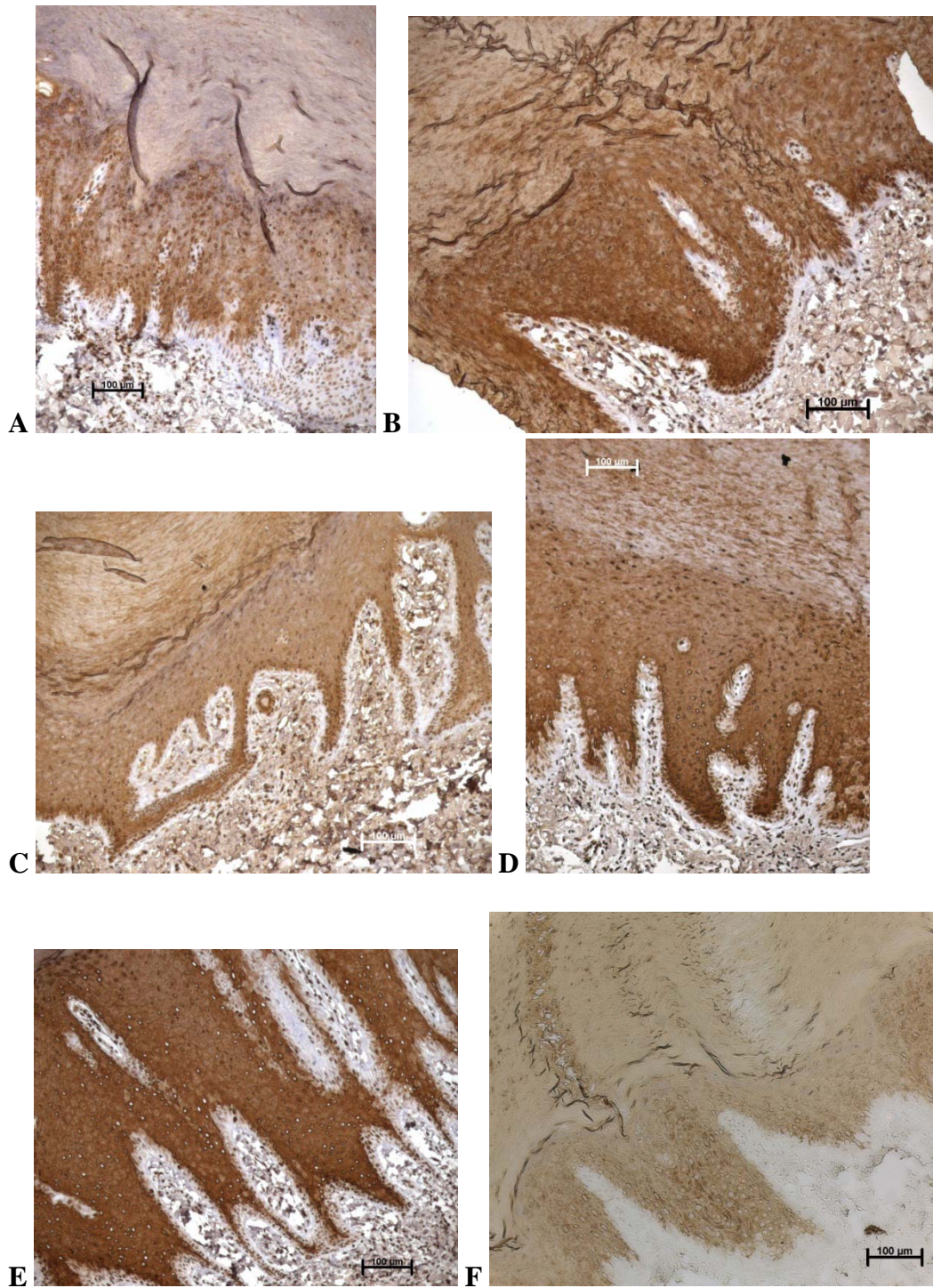
PPK Subtype (Number, n)	Distribution of Staining	Pattern of Staining	Intensity (-/+ /++ /+++)
KRT1 (2)	USp+Gr (2/2)	C (2/2)	++
KRT9 (2)	USp+Gr (2/2) *	C (2/2)	++
KRT17 (6)	USp+Gr (6/6)	C (6/6); +N (2/6)	+ / ++
DSG1 (1)	USp+Gr (1/1)	C (1/1)	+
Loricrin (2)	USp+Gr (2/2)	C (2/2); N (2/2) **	+ / ++
Mitochondria (1)	USp+Gr (1/1)	C (1/1)	++
Controls (3)	USp,Gr (3/3); SC (1/3)	C (3/3);	++

USp=Upper Spinous; Gr=Granular; C=Cytoplasmic; N=Nuclear; SC=Stratum corneum

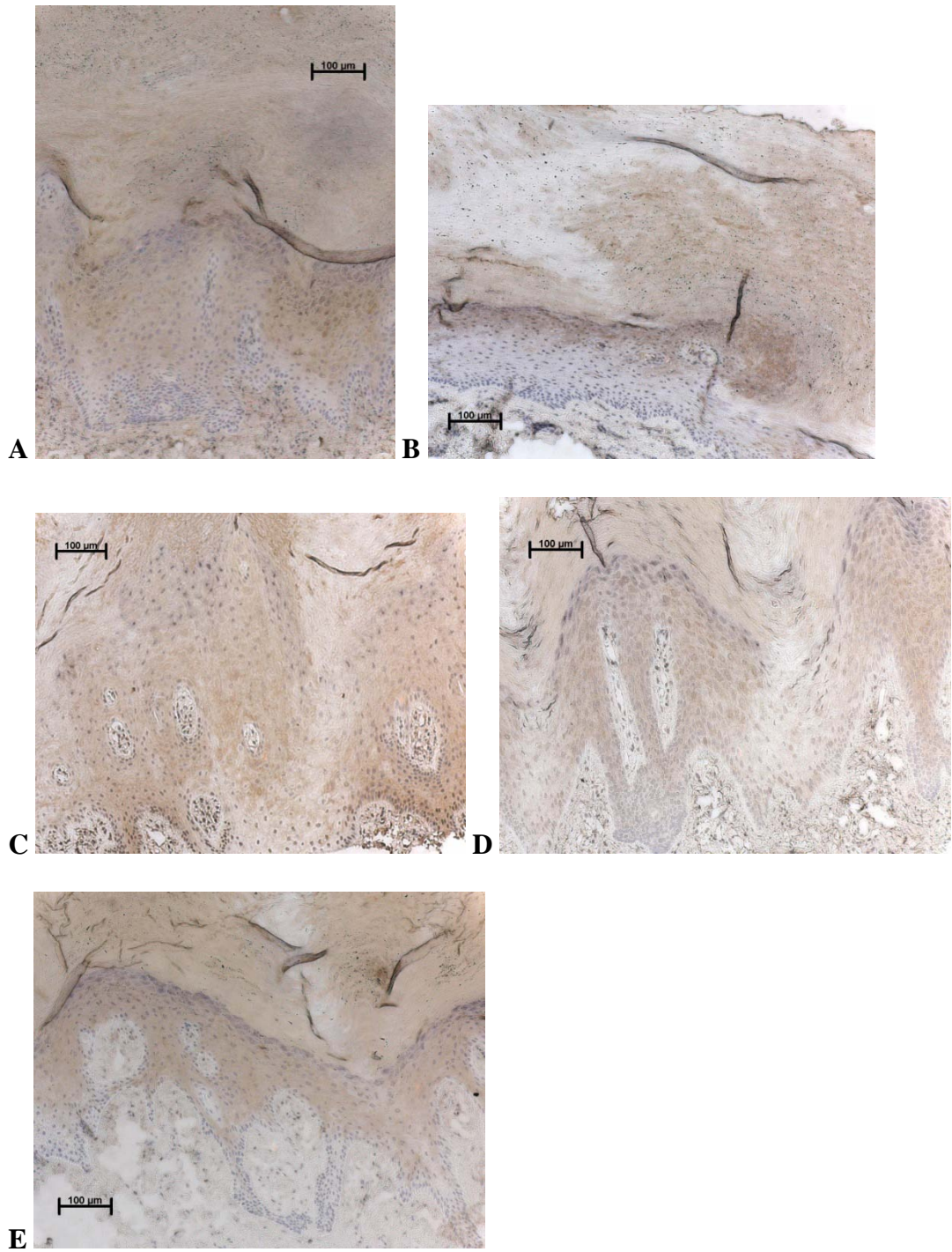
- \*Strongly positive staining in areas of acantholysis
- \*\*Positive nuclear staining around sweat duct

**Table 23.** Ki67 staining

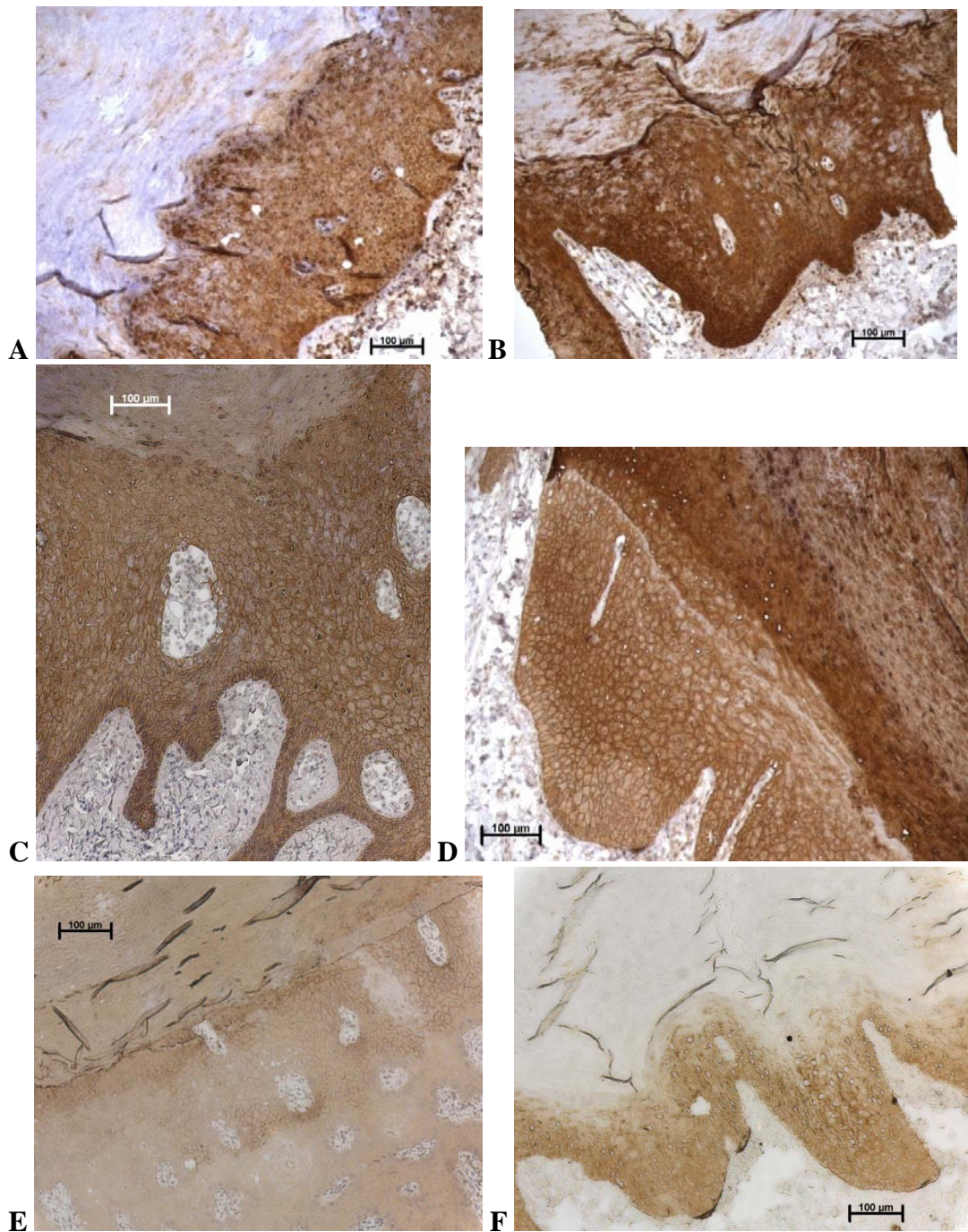
PPK Subtype (Number, n)	Mean positive nuclei/100 basal cells (range)
KRT1 (2)	10.79 (8.72-12.86)
KRT9 (2)	17.53 (12.63-28.14)
KRT17 (6)	12.46 (8.0-25.8)
DSG1 (1)	15.5 (8.7-21.25)
Loricrin (2)	13.43 (9.0-19.3)
Mitochondria (1)	9.82 (7.9-11.75)
Controls (3)	16.6 (7.3-28.1)



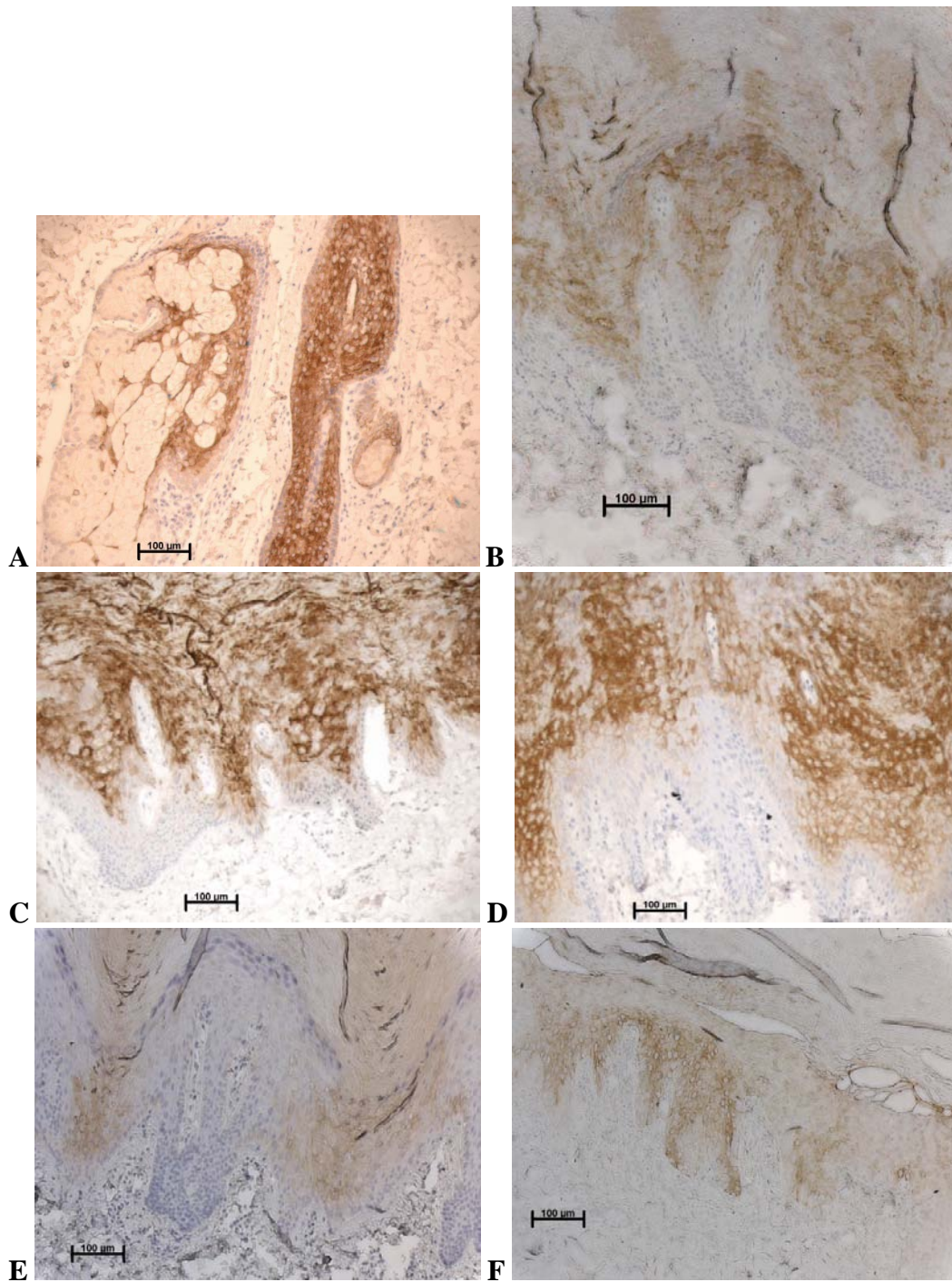
**Figure 26. Cytokeratin 1 staining in affected plantar skin of inherited PPK patients with underlying keratin 1, 9, 17, loricrin and mitochondrial mutations (a, b, c, d, e) respectively compared to normal plantar control (f). Predominantly suprabasal cytoplasmic staining throughout samples, with variations in intensity of staining. Scalebars=100µm.**



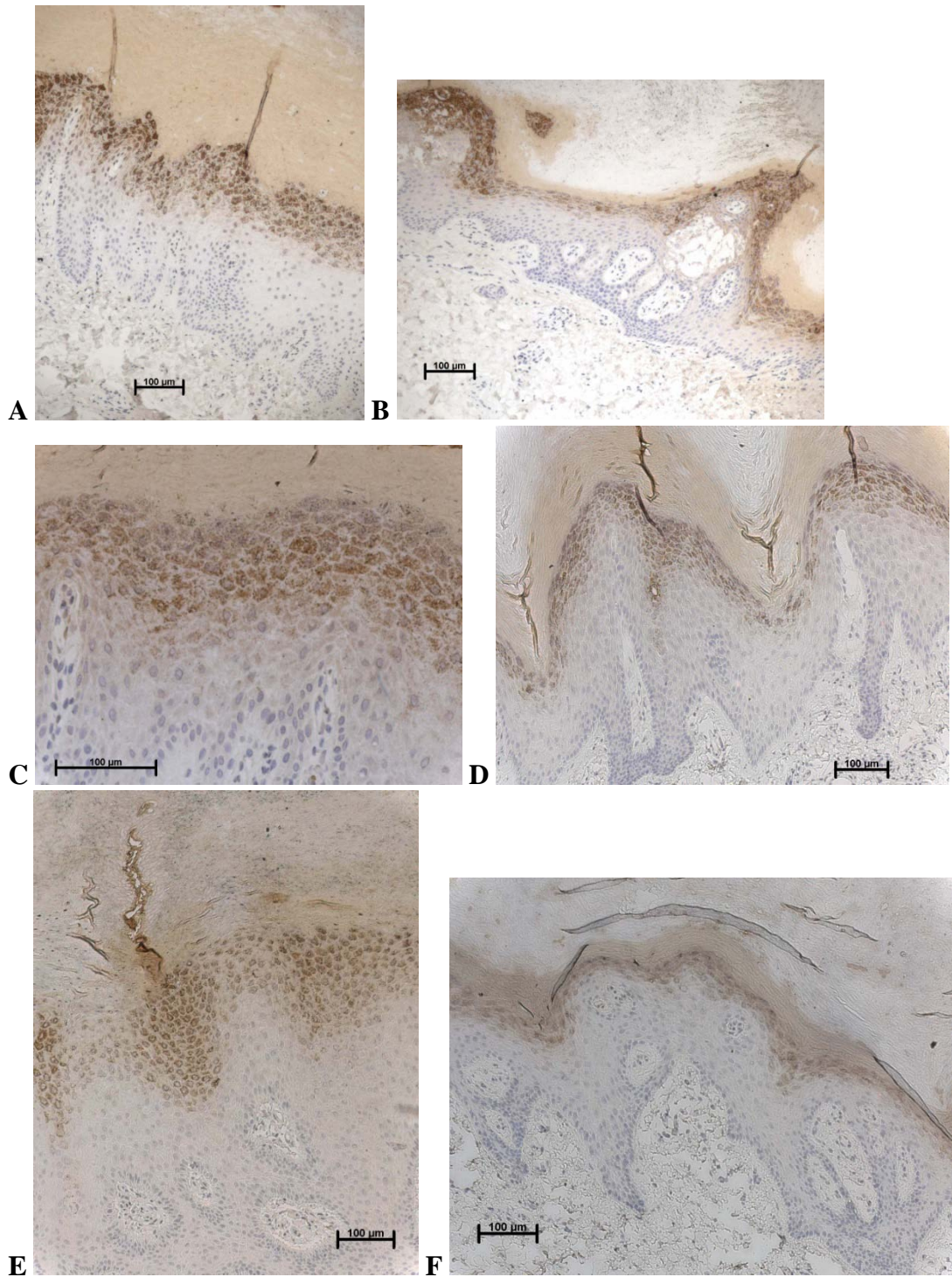
**Figure 27. Cytokeratin 9 staining in affected plantar skin of inherited PPK patients with underlying keratin 1, 9, 17, loricrin mutations (a, b, c, d) respectively compared to normal plantar control (e). Patchy spinous cytoplasmic staining demonstrated. Scalebars=100μm.**



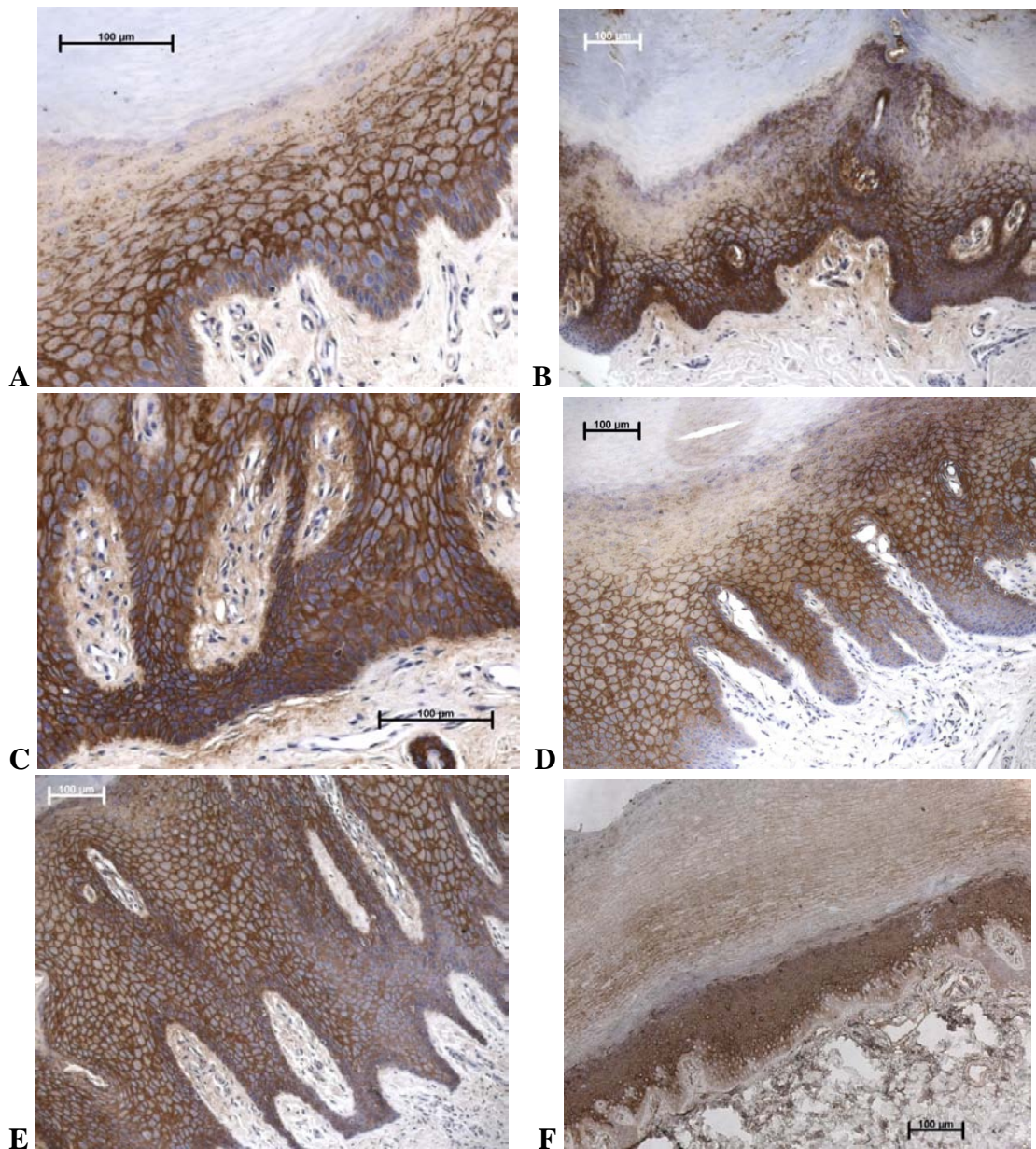
**Figure 28. Cytokeratin 14 staining in affected plantar skin of inherited PPK patients with underlying keratin 1, 9, 17, loricrin and mitochondrial mutations (a, b, c, d, e) respectively compared to normal plantar control (f). Predominantly cytoplasmic staining of basal and spinous layers shown. Scalebars=100µm.**



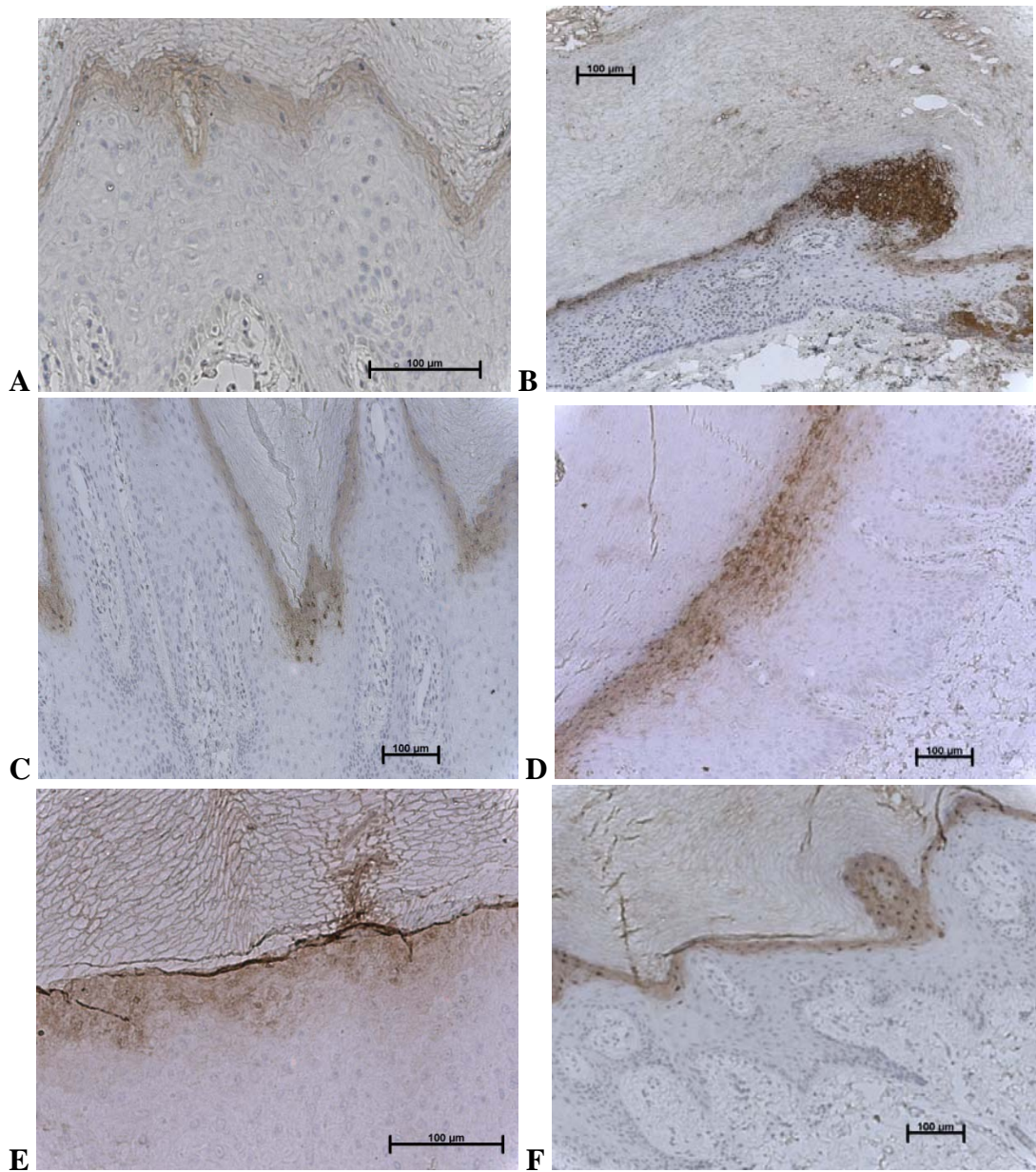
**Figure 29. Cytokeratin 17 staining in control non-acral skin (a) and affected plantar skin of inherited PPK patients with underlying keratin 1, 9, 17 and loricrin and mutations (b, c, d, e) respectively compared to normal plantar control (f). Patchy suprabasal and spinous staining demonstrated. Scalebars=100µm.**



**Figure 30. Filaggrin staining in affected plantar skin of inherited PPK patients with underlying keratin 1, 9, 17, loricrin and mitochondrial mutations (a, b, c, d, e) respectively compared to normal plantar control (f). Staining restricted to granular layer with positive coarse staining of keratohyaline granules. Scalebars=100µm.**

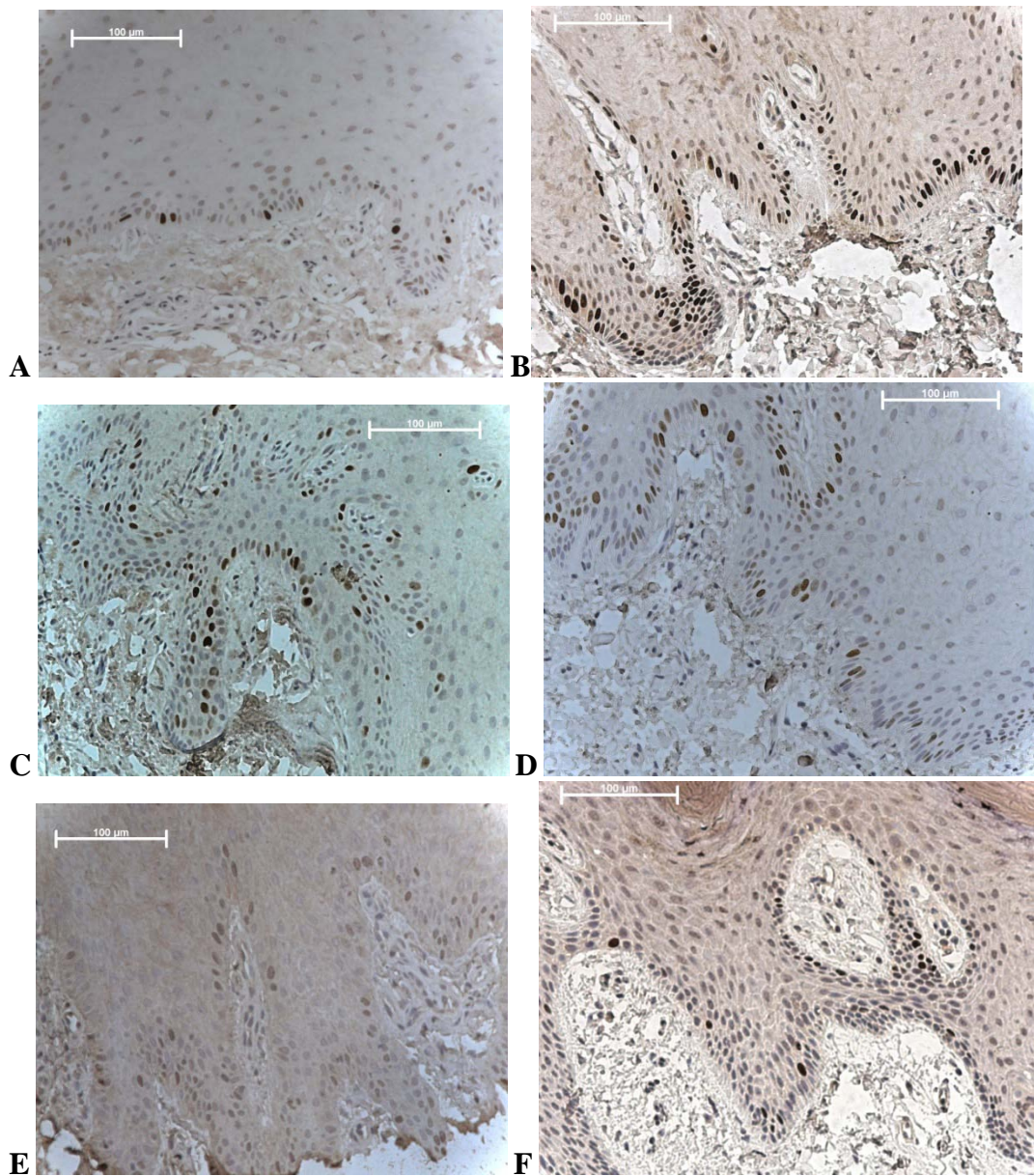


**Figure 31. Involucrin staining in affected plantar skin of inherited PPK patients with underlying keratin 1, 9, 17, loricrin and mitochondrial mutations (a, b, c, d, e) respectively compared to normal palmar control (f). Membranous and cytoplasmic staining of spinous layers predominantly, with some staining of basal layer (c). Scalebars=100µm.**

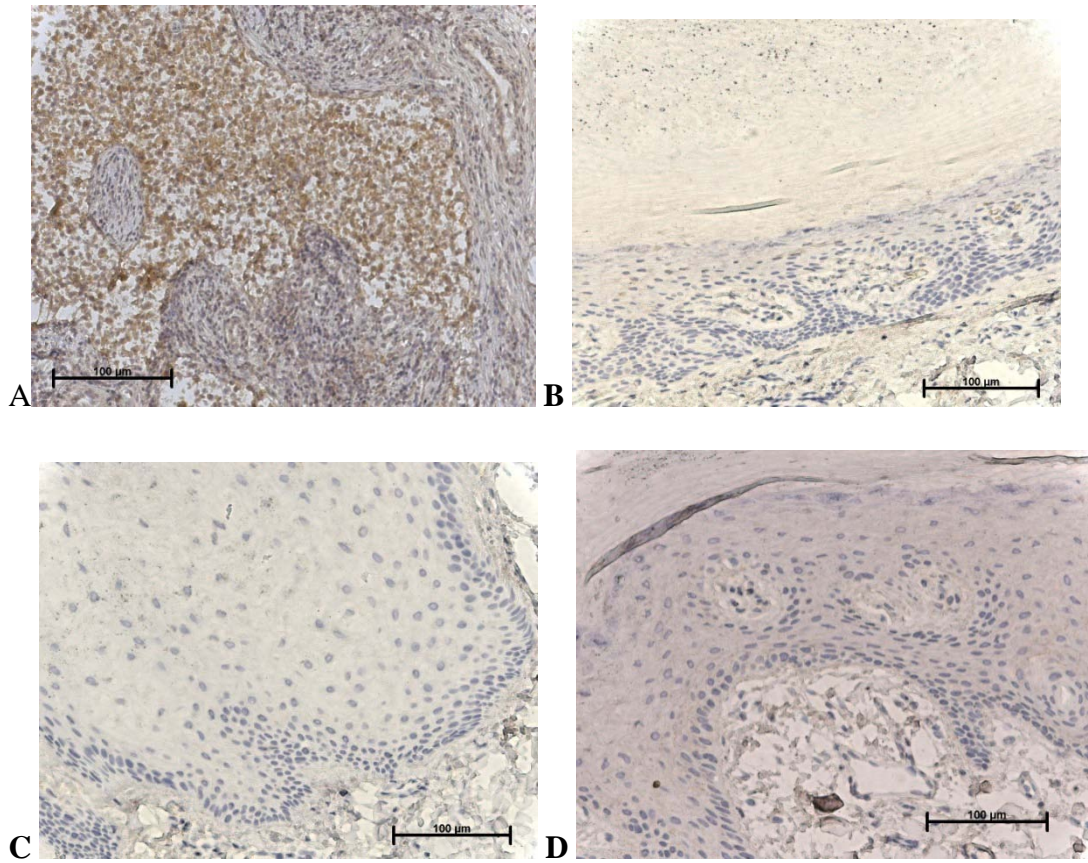


**Figure 32. Loricrin staining in affected plantar skin of inherited PPK patients with underlying keratin 1, 9, 17, loricrin and mitochondrial mutations (a, b, c, d, e) respectively compared to normal plantar control (f). Cytoplasmic staining of upper spinous and granular layers throughout, with some areas of nuclear staining. Strong positive staining of acantholytic areas in (b). Scalebars=100μm.**





**Figure 33. Ki67 staining in affected plantar skin of inherited PPK patients with underlying keratin 1, 9, 17, loricrin and mitochondrial mutations (a, b, c, d, e) respectively compared to normal plantar control (f). Scalebars=100µm.**



**Figure 34. Activated caspase 8 staining in breast carcinoma (a) compared to affected plantar skin in inherited PPK patients with underlying K9 and K17 mutations (b, c) and (d). Scalebars=100µm.**

### **3.2.3.2 Cornified envelope proteins**

Filaggrin staining in inherited PPK and control samples were largely comparable, with staining restricted to the granular layer, being mainly continuous, and keratohyaline granules generally staining positively and appearing coarse (Figure 30; Table 20). 1/2 patients with Loricrin and 1/1 Mitochondrial PPK subtypes showed patchy filaggrin staining, which correlated to alternating areas of hyper- and hypogranulosis on H&E staining.

Involucrin staining was predominantly and uniformly in the upper spinous layer in all inherited PPK patients, with variations of staining of basal and granular layers. The pattern of staining was both membranous and cytoplasmic, other than in the mitochondrial subtype, where it was membranous only. Control samples showed no basal staining but otherwise were closely comparable (Figure 31; Table 21).

Loricrin staining was limited to the upper spinous and granular layers in all inherited PPK patients and was mainly cytoplasmic, other than the Loricrin PPK subtype, where there was also nuclear staining around sweat ducts. In addition, one control sample demonstrated a diffuse staining of the stratum corneum. There were only subtle differences of intensity of staining between individuals. Loricrin staining was also strongly positive in all areas of acantholysis in K9 patients (Figure 32; Table 22).

### **3.2.3.3 Markers of proliferation/apoptosis**

#### *Ki67*

Ki67 staining was restricted to the basal and epibasal cell layers of the epidermis. Ki67 demonstrated a range of scores from 9.82 per 100 basal cells in the mitochondrial PPK subtype to 17.53 per 100 basal cells in K9 subtypes, which

compared to palmoplantar controls' score of 16.6 (Figure 33; Table 23). There was some variation between individuals and also between different sections for the same individual. There was a modest correlation between Ki67 counts on the duplicate sections using linear correlation and regression analysis ( $r^2=0.302$ , p value < 0.05). Blinded second observer scores of Ki67 counts were performed, with close correlation in scoring between observers using linear correlation and regression analysis ( $r^2=0.921$ , p value=0.09).

#### *Activated Caspase 8*

Positive controls (breast carcinoma and testis) showed strong positive nuclear staining (Figure 34). All inherited PPK and 2/3 control specimens showed an absence of positive staining. 1/3 plantar control specimen showed low numbers of positive darkly stained nuclei.

### **3.2.4 Discussion**

#### **3.2.4.1 Keratins as markers of differentiation**

It is well recognised that changes occur in the expression of keratin intermediate filaments during epidermal differentiation (Galvin *et al.*, 1989). Keratins are useful markers for the differentiation of epithelial cells and facilitate evaluation of the origin of epithelial tumours, as keratin expression varies depending on the type of cells, hyperproliferative state, the stage of differentiation and the disease state (Moll *et al.*, 1982). Similarly, each of the many different epithelial cells and tissues in the human body express particular combinations of keratins (Lane, 1993) (see Table 1, chapter 1).

The type-II keratins K5 and K14 are the primary keratin pair of keratinocytes of stratified epithelia (Moll *et al.*, 1982). They are strongly expressed in the

undifferentiated basal cell layer and down-regulated in the differentiating suprabasal cell layers (Fuchs & Green, 1980). The process of terminal differentiation and keratinization is associated firstly with a transition of keratinocytes from the proliferative basal layer to the postmitotic suprabasal spinous layers (see chapter 1 & 3.2.4.7), with a switch in expression to the suprabasal epidermal keratins, type II keratins K1 and K10 (Moll *et al.*, 1982; Stoler *et al.*, 1988). However, other keratins are selectively expressed. For example, the type I keratin K17 has a unique cell type distribution, and is selectively expressed in basal and myoepithelial cells (Trojanovsky *et al.*, 1989; 1992) (see 3.2.4.3). The type I keratin K9 also shows highly specific expression in terminally differentiating keratinocytes of palmoplantar epidermis (Moll *et al.*, 1987; Langbein *et al.*, 1993) (see 3.2.4.2). Underlying keratin defects in our cohort of patients included mutations in K1, K9 and K17 genes. The keratins studied in the present cohort were specifically chosen due to these underlying mutations (K1, K9 and K17) and as a selection of markers of differentiation and hyperproliferation. A more exhaustive study of keratins was limited by tissue available for study, and the need to study a range of non-keratin markers.

K1 is expressed in suprabasal cells of stratified, cornified epithelia and is a marker of terminal differentiation in stratified epithelium (Gown & Vogel, 1982; Leigh *et al.*, 1993). Unlike mouse epidermis, where a significant number of basal cells express K10, only small numbers of basal cells in human epidermis express K1 and K10, and these are co-expressed in epidermal and mucosal sites (Leigh *et al.*, 1993). Basal cells have been shown to react to K1 in ichthyosis hystrix Curth-Macklin (Niemi *et al.*, 1990), suggestive that the basic fault of the keratinisation

process may be in ultrastructurally normal basal cells. In my study, significant differences in K1 staining patterns were not seen between inherited PPK subtypes, even in 2 patients with underlying K1 causative mutations, demonstrating normal K1 expression in plantar skin. However, 1/2 of these patients demonstrated abnormal keratin filaments on electron microscopy (chapter 3.1). A suprabasal pattern of K1 staining was observed throughout subtypes, although in addition, 1/6 K17, 1/2 Loricrin and 1/1 Mitochondrial PPK subtypes showed patchy nuclear basal staining, although this did not correlate with any corresponding ultrastructural abnormality.

K14, a basal keratin and marker of undifferentiation (Purkis *et al.*, 1990), is expressed in basal keratinocytes of epidermis and stratified epithelia. Significant differences in its expression were not found between inherited PPK and control acral tissues in this study. Changes in keratin expression associated with hyperproliferation in hair-bearing epidermis include the induction of K6, K16, and K17 (Weiss *et al.*, 1984; Stoler *et al.*, 1988; Wilson *et al.*, 1994), although this is not a consistent finding (Kopan & Fuchs, 1989). Upregulation of K16 has been observed in BCIE (Ishida-Yamamoto *et al.*, 1992). In PC due to K6 mutations, diffuse epidermal staining including the basal layer was observed for K6, K16, K17 and K14, in association with prominent ortho and parakeratosis surmounting an acanthotic epidermis, suggestive of rapid keratinocyte proliferation and differentiation, although specific markers of proliferation were not studied (Leachman *et al.*, 2005). This is in keeping with other reports in PC (Su *et al.*, 1990; Wollina *et al.*, 1991). Although K17 was not found to be qualitatively increased or altered in distribution in our cohort compared to acral controls (section 3.2.4.3), a more detailed study including K6 and K16, tissue permitting, would also help to confirm these findings.

#### **3.2.4.2 Specialised keratin expression pattern in normal human ridged skin**

The epidermis of normal human ridged skin normally grows thicker in response to physical stress. It also expresses a more complex pattern of keratins than thin skin, which is again probably due to the greater stress that ridged skin has to withstand (Swensson *et al.*, 1998). Keratinocytes in ridged skin have an unusually large number of keratin filaments in their cytoplasm compared with thin skin (Swensson & Eady, 1996) (chapter 1). K9 is expressed in terminally differentiated palmoplantar epidermis (Knapp *et al.*, 1986; Moll *et al.*, 1987; Langbein *et al.*, 1993), and weak expression was noted in both inherited PPK and acral control samples in this study, irrespective of the presence of an underlying K9 mutation in two patients, one of whom demonstrated keratin aggregates ultrastructurally (see chapter 3.1).

K9 is abundantly yet heterogeneously expressed in palmoplantar epidermis (Moll *et al.*, 1987; Langbein *et al.*, 1993), where it is only expressed in suprabasal cell layers, often arranged in vertical columns but sometimes also forming extending continuous sheets. Weak K9 staining was observed in all samples in this study with discontinuous labelling and alternating vertical bands in 1/2 Loricrin subtypes. K1/K10 have in contrast been found to be uniformly distributed in suprabasal keratinocytes in palmoplantar skin (Moll *et al.*, 1987), but these were not analysed in this study.

In contrast, K9 was expressed strongly above the primary epidermal ridges and in the centre of the papillary ridge in one study of normal human palmoplantar skin (Swensson *et al.*, 1998). This was not clearly seen in this study in either PPK or control samples although both demonstrated weak epidermal staining throughout.

Swensson *et al.* (1998) observed that K6 and K16 were expressed in some basal cells and most suprabasal keratinocytes in palmoplantar samples of six healthy controls, compatible with a constitutively high proliferative activity of normal ridged epidermis. Nests of K17-positive cells were present at the bottom of deep primary epidermal ridges, supporting the notion of functional heterogeneity of basal cells, although this was not a feature found in PPK or control acral tissue in this study, where expression was suprabasal. K16 expression has previously been noted in palmoplantar skin in a complementary pattern in intervening secondary ridge zones (Swensson *et al.*, 1998), although this was not studied in this cohort. More detailed keratin staining, including K16, in a larger number of control palmoplantar samples is warranted to assess whether this is not a consistent feature of acral tissue or if staining varies between sites of palmoplantar skin, as the medial sole was consistently used in this study (see Appendix A).

#### **3.2.4.3 K17 expression**

K17, a hyperproliferative keratin, is present in suprabasal layers (Troyankovsky, 1989; Leigh *et al.*, 1995; Kurokawa *et al.*, 2002) and is expressed in the nail bed (McGowan & Coulombe, 2000), palmoplantar epidermis (restricted) (Swensson *et al.*, 1994), epidermal appendages, sebaceous glands, hair shaft, other epithelia and during wound healing (Smith *et al.*, 2005). In particular, it is found basally in myoepithelial cells, basal glandular cells and in the deep outer root sheath (Lane *et al.*, 1991) and suprabasally in hyperproliferative psoriasis (Leigh *et al.*, 1995).

The hair follicle has a complex pattern of keratin expression, with more than half the known keratin genes expressed, often with overlapping patterns (Langbein *et al.*, 2003; Tong & Coulombe, 2004). Despite this, K17 null mice fail to develop a



full pelage hair coat neonatally, which is correlated with hair shaft fragility (McGowan *et al.*, 2002) and alterations in apoptosis (Tong & Coulombe, 2006). These findings demonstrate both the structural support conferred by K17 and its role in regulating hair cycling. Thus K17 expression in hair shaft and epidermal appendages may be relevant with respect to the follicular symptoms of PC-2. However, K17 expression in both PC-2 and other PPK subtypes in this study did not demonstrate significant differences in staining to acral controls, despite the presence of keratin aggregates in 5/8 PC-2 patients ultrastructurally (see chapter 3.1).

#### **3.2.4.4 Keratins and wound healing**

Transient alterations in keratin composition have been studied in wounding of non hair bearing epidermis *in vitro* and in cultured keratinocytes. *KRT6/16/17* gene transcription is induced and *KRT1/10* reduced possibly resulting in a more pliable cytoskeleton favouring keratinocyte migration, essential to wound closure (Paladini *et al.*, 1996; DePianto & Coulombe, 2004). K6a knockout mice have shown delayed re-epithelialization upon partial thickness skin wounding although healing of full thickness wounds was normal (Wocjik *et al.*, 2000). Similarly, K17 knockout mice demonstrated delayed wound closure (Mazzalupo *et al.*, 2003). It is thought that in the context of epidermal wound healing, K16 acts by promoting reorganization of the cytoplasmic array of keratin filaments, which precedes the onset of keratinocyte migration into the wound site (Paladini *et al.*, 1996) (see chapter 1). Although the response to wounding in palmoplantar epidermis has not been studied, similar patterns of altered gene expression were not identified in PPK in this cohort. In particular, there was no evidence for increased expression of K17, previously reported to be induced in regenerating and migrating epidermal keratinocytes in

studies of wound healing in hair-bearing skin (Paladini *et al.*, 1996; DePianto & Coulombe, 2004).

#### **3.2.4.5 Keratinocyte proliferation and epidermal thickening**

Ki67 is a protein thought to be associated with chromosomes in mitotic cells (Verheijen *et al.*, 1989) and is expressed during G1, G2 and M phase of the cell cycle (Sasaki *et al.*, 1987; Wersto *et al.*, 1988). In this study, although there was some variation in Ki67 staining between PPK individuals and between subtypes, the scores were relatively close to those of palmoplantar controls, suggesting that increased epidermal turnover was not a significant factor in the development of hyperkeratosis at these sites.

Epidermal thickening is a clinical feature common to the many keratin disorders, but there have been limited investigations into changes in keratinocyte proliferation in these disorders. Early studies in ichthyosiform dermatoses showed a 3-fold increase in the number of cells labelled with tritiated thymidine (Frost *et al.*, 1966) and an increase in the number of mitoses in BCIE. Proliferation has been investigated in a number of skin disorders using immunostaining for proliferating nuclear antigen PCNA and biochemical staining for nucleolar organiser-region associated argophylic proteins AGNORs. This demonstrated increased staining in psoriasis, congenital non bullous ichthyosiform erythroderma, BCIE and chronic dermatitis, and a decrease in ichthyosis vulgaris, X linked ichthyosis and pityriasis rubra pilaris (Kanitakis *et al.*, 1993). The relationship between hyperproliferation and epidermal thickening in a mouse model for BCIE has suggested that hyperproliferation is only partly responsible for morphologic changes (Porter *et al.*, 1998).

Keratinocyte proliferation and acanthosis has been reported in other conditions associated with epidermal thickening, such as psoriasis (Iizuka *et al.*, 1996; 1997). Histopathologically, hyperproliferation, an aberrant keratinisation process and the infiltration of immunocytes in the dermis and epidermis are characteristic (Krueger, 2002; Bovenschen *et al.*, 2005). The most marked epidermal hyperproliferation (Ki67+ nuclei) has been shown in psoriasis, compared to atopic dermatitis and lichen planus (Kawahira, 1999; Bovenschen *et al.*, 2005), although disease severity (extent and phase of the disease) were thought to be critical in the absolute scores investigated, with severe atopic dermatitis showing more substantial Ki67 expression in one comparative study (Bovenschen *et al.*, 2005).

It has been observed that proliferating cells can vary between body sites quite considerably in mouse models (Porter *et al.*, 1998) and that this should be considered in any study of proliferation *in vivo*. Comparative expression of Ki67 in normal skin, lesional psoriatic skin and normal plantar epidermis showed positivity ranging from 2.27, 10.8 to 9.76 positive nuclei/100µm epidermis respectively (Lucke *et al.*, 1999), thus there was approximately a four-fold increase in proliferation index between normal plantar and non-plantar epidermis. In our study, normal acral control tissue showed a mean stratum corneum thickness of 0.92mm in comparison to mean PPK stratum corneum of 0.945, 1.185, 2.33, 0.8, 2.55 and 0.67mm for K1, K9, K17, DSG1, loricrin and mitochondrial subtypes respectively. Thus, absolute thickness of stratum corneum histologically did not reflect the clinical feature of hyperkeratosis in PPK compared to normal acral skin. Similarly, the mean Ki67 count for normal acral tissue was 16.6 positive nuclei/100 basal cells compared to 10.79, 17.53, 12.46, 15.5, 13.43 and 9.82 positive nuclei/100 basal cells in K1, K9, K17, DSG1, loricrin and

mitochondrial subtypes respectively. Normal palmoplantar skin demonstrated a higher proliferative index than clinically hyperkeratotic skin. It is possible that only a relatively small change in proliferative index might result in changes in differentiation, as demonstrated by premature expression of involucrin in all subtypes of PPK in this study (see 3.2.4.9), resulting in palmoplantar skin becoming hyperkeratotic, and this change may be hidden in the variance of our data. A more detailed study including other proliferative markers e.g. PCNA and BrdU would be necessary to reinforce the conclusion that there is no major change in proliferative index in PPK. Although late differentiation events have not been studied in this cohort, it is possible that an alteration in mechanisms of shedding may be important in the development of hyperkeratosis in inherited PPK.

#### **3.2.4.6 Apoptosis and inherited PPK**

Although staining with caspase-8 was not observed in this study, a more detailed study of apoptotic markers including caspase-3 would be warranted to further assess the role of apoptosis in the pathogenesis of inherited PPK. Caspases, a family of cysteinyl aspartate proteases, are considered the effector enzymes for apoptosis, activated in a cascade-like fashion, with many caspases being expressed in the epidermis (Villa *et al.*, 1997). Multiple caspases are synthesized in human keratinocytes and are involved in terminal differentiation (Takahashi *et al.*, 1998; Weil *et al.*, 1999; Raj *et al.*, 2006).

Caspase-8 was discovered in the course of exploration of the mechanisms by which members of the TNF/NGF receptor family induce death of cells (Boldin *et al.*, 1996). It was chosen for this study as a representative of the upstream initiator caspases, which also include caspases-2, -4, -5, -9, -10, -11, -12 and -13, in contrast

to effector caspases -3, -6, -7 and -14 (Oliver & Vallette, 2005). Initiator caspases activate downstream effector caspases when induced by the trimerized Fas antigen which transduces a signal to Fas-associating protein with death domain (FADD) (Boldin *et al.*, 1995; Chinnaiyan *et al.*, 1995). Caspase-8 is first activated followed by caspase 3 (Chinnaiyan *et al.*, 1996; Boldin *et al.*, 1996), which subsequently stimulates caspase 3-activated DNase (CAD) by proteolytic elimination of the inhibitor of CAD (ICAD) (Enari *et al.*, 1998; Sakahira *et al.*, 1998). UVB irradiation induces apoptosis of keratinocytes with increased caspase-8, -9 and -3 activities (Takahishi *et al.*, 1999a; Takahishi *et al.*, 2001b). Caspase-14 is a unique, non-apoptotic caspase (Denecker *et al.*, 2008), only expressed in skin (Van de Craen *et al.*, 1998) by differentiating but not proliferating keratinocytes (Lippens *et al.*, 2000; Rendl *et al.*, 2002).

Relationships between caspases and keratinocyte terminal differentiation are not fully understood, and caspase expression in the epidermis has shown incomplete or contradictory results (Raymond *et al.*, 2007). Caspase-1, -2, -3, -4 and -7 mRNAs have been detected in human keratinocytes by RT-PCR, but not caspase-5 and -6 (Takahishi *et al.*, 1998). Caspase-2, -3, -6, -8, -9 and -14 mRNAs have been detected in mouse epidermis but not caspase-1, -7, -11 and -12 (Kuechle *et al.*, 2001).

Caspase-3 has been shown to be expressed in the active form at the granular layer, at the transition to the stratum corneum, and pro-caspase-3 may be activated during late keratinocytes differentiation (Dale *et al.*, 1997; Weil *et al.*, 1999). In contrast, processed forms of caspase-3, -6 and -7 have not been detected in human epidermis (Lippens *et al.*, 2000). A further study of human epidermis detected mRNAs encoding caspase-1, -2, -3, -4, -6, -7, -8, -9, -10 and -14 by RT-PCR but

immunohistological expression of caspase-2 and -8 was not seen, suggesting that caspase-8 expression is controlled at the post-transcriptional level (Raymond *et al.*, 2007). A more detailed study of caspases, particularly activated caspase-3, in inherited PPK is therefore necessary.

Most skin diseases or cutaneous lesions characterized by epidermal hyperplasia or hyperkeratosis, such as psoriasis, skin cancer and lichen simplex chronicus are thought likely to involve decreased keratinocyte apoptosis (Raj *et al.*, 2006). Survivin, an apoptotic inhibitor, is expressed in the upper third of the epidermis in psoriasis and lichen simplex chronicus, whereas basal cell and squamous cell carcinoma demonstrate staining in all epidermal layers (Bowen *et al.*, 2004). In psoriasis, spontaneous keratinocyte apoptosis is decreased (Laporte *et al.*, 2000). Keratinocytes in psoriatic plaques demonstrate resistance to apoptosis and a lack of p53 activation (Wrone-Smith *et al.*, 1999; Qin *et al.*, 2002). A number of factors probably contribute to this resistance: resistance to TNF signalling; upregulation of other cytokines, such as IL-15 (Ruckert *et al.*, 2000) and increased levels of Bcl-x (Fukuya *et al.*, 2002). Aberrant expression of apoptosis-related molecules Fas, Bcl-xL, Bax and ICAD (inhibitor of caspase 3-related DNase) was noted, suggestive of a suppressed apoptotic process (Takahishi *et al.*, 2002).

#### **3.2.4.7 Terminal differentiation and apoptosis are distinct processes**

In order to maintain epidermal structural homeostasis, proliferation, differentiation and cell death of keratinocytes needs to be modulated. Epidermal terminal differentiation has been thought of as a specialized form of apoptosis (Haake & Polakowska, 1993), but there are some distinct differences between these processes (Gandarillas *et al.*, 1999; Takahishi *et al.*, 2000).

Terminal differentiation and apoptosis are both metabolically active processes provoking dramatic cellular changes leading ultimately to cell death, which are tightly controlled by extracellular matrix interaction via integrins (Gandarillas, 2000). Differentiating keratinocytes in the granular layer exhibit degraded DNA, fragmented by endonucleases, (Gandarillas *et al.*, 1999), and display terminal deoxynucleotidyl transferase-mediated dUTP-biotin nick end labelling (TUNEL)-positive cells (Polakowska *et al.*, 1994; Haake & Polakowska, 1993; Maruoka *et al.*, 1997). Activation of transglutaminases, essential for the production of the CE and suppression of the nucleus, is also a feature common to both apoptosis and terminal differentiation (Gandarillas, 2000). Apoptosis regulators, Bcl-2, Bcl-x, Bax and Bak, are differentially expressed in keratinocytes (Mitra *et al.*, 1997; Rodriguez-Villanueva *et al.*, 1998). Bcl-2 has been found associated with proliferative keratinocytes in both normal skin and basal cell carcinomas (Morales-Ducret *et al.*, 1995) and Bax expression reduced the latter (Tomkova *et al.*, 1998). Transcription factor c-Myc induces apoptosis in a variety of cell types when growth factor deprived, and promotes differentiation of epidermal stem cells (Gandarillas & Watt, 1997, Gandarillas *et al.*, 2000). p53, a paradigmatic pro-apoptotic factor, (Gandarillas, 2000), delays cell cycle progression (Harris & Levine, 2005). It may activate transcription of pro-apoptotic factors affecting mitochondrial pathways (Bax, Noxa, Puma, Apaf-1) and death receptor pathways (Fas, death receptors 4 and 5), and repress antiapoptotic molecules (Bcl-2, Bcl-x, Survivin) (Yu & Zhang, 2005).

Keratinocytes respond to internal, extracellular and environmental death signals through coordinating sensors which integrate apoptotic responses via a number of pathways. UVB, binding of Fas ligand (Fas-L), tumour necrosis factor, or

other cytokines to death receptors stimulates the extrinsic pathway, resulting in activation of caspase-8 (Takahishi *et al.*, 1999a; Takahishi *et al.*, 2001a; 2001b). Fas-ligand induces apoptosis through Fas (CD95), a 45-kDa cell surface protein (Itoh *et al.*, 1991; Oehm *et al.*, 1992; Watanabe-Fukunaga *et al.*, 1992), is marginally expressed in normal basal keratinocytes (Sayama *et al.*, 1994) but induced by TH1 type cytokine interferon  $\gamma$  (Takahishi *et al.*, 1995).

UVB, cytotoxic drugs and DNA damage trigger the intrinsic pathway resulting in mitochondrial release of cytochrome c, which combines with the cofactor Apaf-1 in the formation of activated caspase-9 (Schwartz *et al.*, 1995; Takahishi *et al.*, 1995). Activation of the upstream caspases 8 or 9 leads to activation of downstream caspases 3 or 7, which causes intracellular substrate cleavage, cellular condensation and nuclear fragmentation (Raj *et al.*, 2006).

However, there are clear differences between terminal differentiation and apoptosis. In the former, corneocytes are neither phagocytized, nor do they exhibit membrane blebbing, a morphologic criteria of apoptosis, and the process is relatively slow. In contrast, apoptosis is rapidly executed, resulting in elimination of individual cells within hours, often neighbouring cell phagocytosis (Mitra *et al.*, 1997; Gandarillas, 2000). Gandarillas *et al.* (1999) examined terminal differentiation (differentiation marker involucrin expression, formation of CE and anucleation), and apoptosis (nuclear condensation, apoptotic DNA fragmentation by TUNEL staining, electrophoresis and ELISA, and cell rounding) in primary human keratinocytes and found that differentiation and apoptosis were independent of each other.

Despite the failure to detect changes in this study, mutations in genes causing keratoderma might also affect apoptosis. For example, keratins moderate apoptosis



by both death receptor and intrinsic pathways, with K8 and K18 interacting with TNF receptor 1 (Caulin *et al.*, 2000). Loss of maternal TNF $\alpha$  increased the survival of keratin-deficient embryos (Jaquemar *et al.*, 2003) possibly via a cell-autonomous mechanism involving K18 binding to TRADD, TNFR-1-associated death domain protein (Inada *et al.*, 2001). K17 similarly modulates hair follicle cycling, possibly by its interaction with TRADD (Tong & Coulombe, 2006). Desmosomal defects also have the ability to alter apoptosis (see chapter 2.3).

#### **3.2.4.8 Filaggrin and terminal differentiation**

In the later stages of differentiation, during the formation of the CE, epidermal keratinocytes express unique proteins including filaggrin, loricrin and involucrin (Fuchs & Byrne, 1994). Filaggrin is a crucial component of the CE in the outer layer of epidermis. It is an abundant protein that functions to aggregate keratin intermediate filaments into tightly aligned bundles or macrofibrils in the stratum corneum of the epidermis and other stratified keratinizing epithelia (Dale *et al.*, 1978). It is synthesized in suprabasal granular cells, as a large, highly phosphorylated precursor, profilaggrin, that consists of multiple filaggrin repeats flanked by N- and C-terminal domains (Presland *et al.*, 1992; 1997; Pearton *et al.*, 2002). Profilaggrin is converted to filaggrin by site-specific proteolysis and dephosphorylation, during the transition from the granular layer to stratum corneum (Resing *et al.*, 1989), and its expression as this precursor suggests that filaggrin expression may be regulated to prevent cytotoxic effects (Presland *et al.*, 2001; Kuechle *et al.*, 2000).

The gene that encodes profilaggrin, *FLG*, comprises three exons, the initiation codon for translation being located in exon 2, and the bulk of the profilaggrin protein is encoded by exon 3. *FLG* resides on human chromosome 1q21

within the epidermal differentiation complex, a region that harbours genes for several other proteins that are expressed during terminal differentiation of keratinocytes (South *et al.*, 1999). Null mutations in the *FLG* gene cause the common keratinizing disorder ichthyosis vulgaris (Smith *et al.*, 2006) as well as a being a major susceptibility gene for atopic dermatitis (Palmer *et al.*, 2006).

Filaggrin staining in this study revealed relatively consistent and uniform staining of the granular layer in all PPK subtypes, other than in 2 individuals with alternating areas of reduced filaggrin staining. This correlated with alternating areas of hyper and hypogranulosis on H&E sections associated with alternating ortho- and parakeratotic stratum corneum. This did not relate to clinical severity of hyperkeratosis.

Reduced expression of filaggrin has been noted using immunohistochemical labelling of skin in autosomal dominant ichthyosis vulgaris and atopic dermatitis (Fleckman & Brumbaugh, 2002; Manabe *et al.*, 1991). Keratohyalin granules, which consist mainly of profilaggrin, were absent in all ichthyosis vulgaris individuals by light microscopy and electron microscopy, as well as a consistently absent granular layer. Clinical severity usually correlated with the lack of granular layer and keratohyalin granules. Profilaggrin expression of cultured keratinocytes in these individuals was virtually absent. These disorders are characterized by a markedly thickened stratum corneum (orthohyperkeratotic), which further lends support to a role for filaggrin in terminal differentiation (Kuechle *et al.*, 2000). Filaggrin is expressed at a point in epidermal differentiation where keratinocytes lose their nuclei and other organelles and cease synthetic activity (Resing *et al.*, 1989). It has been

suggested that filaggrin aids in the terminal differentiation process by facilitating apoptotic machinery, due to its keratin binding ability (Kuechle *et al.*, 2000).

#### **3.2.4.9 Premature involucrin expression in inherited PPK**

Involucrin was the first protein to be identified as a likely constituent of the insoluble CE of stratified squamous epithelia and is considered a major protein of terminally differentiating keratinocytes (Steinert & Marekov, 1997). It is covalently attached as an “early” component of the CE, with a small part of involucrin remaining soluble (Ishida-Yamamoto & Iizuka, 1995). Transglutaminase 1 is involved in the formation of a lipid-bound envelope by esterification of long chain  $\omega$ -hydroxyceramides onto involucrin (Nemes *et al.*, 1999). It is a 68kDa protein that is expressed in the spinous and granular layers of the epidermis, several layers above the stratum basale, extending up to the stratum corneum, and can be detected in the cell periphery (Rice & Green, 1979).

In this study, I observed abnormal involucrin distribution in all PPK subtypes, being prematurely expressed in the lower spinous and even basal layers in some cases, which was distinct from plantar controls. This was a uniform immunohistochemical feature of all PPK subtypes in keeping with an altered process of epidermal differentiation, raising the possibility of a common mechanism underlying hyperkeratosis. This is in keeping with involucrin staining in all epidermal layers in 4 cases of Mal de Meleda (Kassar *et al.*, 2008). Involucrin immunolocalisation has been already studied and found to be altered in various keratinisation disorders such as psoriasis (Ishida-Yamamoto and Iizuka, 1995), atopic dermatitis (Jensen *et al.*, 2004), lamellar ichthyosis (Hohl *et al.*, 1993; Pena-Penabad *et al.*, 1999), and Darier’s disease (Kanitakis *et al.*, 1987; Kassar *et al.*,

2008), but not BCIE (Ishida-Yamamoto *et al.*, 1995). Psoriasis shows aberrant expression of differentiation-related molecules, with increased expression of involucrin and cystatin A, a cysteine protease inhibitor, and decreased expression of loricrin (Takahishi *et al.*, 1996). In Darier's disease, differences in staining between non-acantholytic and acantholytic epidermis have been reported (Kassar *et al.*, 2008), with peripheral and diffuse cytoplasmic staining in non-acantholytic areas compared to diffuse cytoplasmic labelling in acantholytic areas. However, in my study, involucrin staining was not particularly prominent in areas of acantholysis, in K1 or K9 patients, in comparison to loricrin staining (see 3.2.4.10).

In a study of Hailey-Hailey disease and Mal de Meleda PPK due to mutation in the *ARS* gene encoding a secreted Ly6/ $\mu$ PAR related protein-1 (SLURP-1) (Fischer *et al.*, 2001), both were found to have premature expression of involucrin. A study on involucrin expression in HHD keratinocytes has shown a decreased involucrin protein level caused by lower involucrin mRNA levels due to increased rates of involucrin mRNA degradation (Aberg *et al.*, 2007). Involucrin mRNA transcription is controlled by cytosolic  $Ca^{2+}$ , with increased  $Ca^{2+}$  stimulating RNA synthesis via activation of an AP-1 promoter site (Ng *et al.*, 2000). Mutations in SLURP-1 are responsible for Mal de Meleda, which modulates intracellular calcium content in keratinocytes (Chimienti *et al.*, 2003), and mutations in the *ATP2C1* gene encoding a  $Ca^{2+}$  pump for Hailey-Hailey disease (Hu *et al.*, 2000). Mutations in *ATP2A2* gene have been shown to be responsible for Darier's disease encoding the type 2 isoform of sarco/endoplasmic reticulum  $Ca^{2+}$ -ATPase (SERCA2), a calcium pump. However, Hailey-Hailey keratinocytes expressed lower involucrin protein levels at both low and high extracellular  $Ca^{2+}$ . Premature involucrin expression was

found in our study in PPKs of varying underlying mutations raising the possibility of other mechanisms affecting epidermal differentiation. Further studies on involucrin expression in PPK keratinocytes and its relationship to signalling may help to elucidate the significance of the altered involucrin cytoplasmic staining in our cohort.

#### **3.2.4.10 Loricrin expression in inherited PPK**

Loricrin is a small basic protein synthesized in the upper granular layer and becomes a major constituent of the CE (Ishida-Yamamoto *et al.*, 1998a). It is highly insoluble perhaps due to its high glycine-content and intra-molecular disulfide bonds. The human loricrin protein is 26kDa, consisting of 315 amino acid residues and is expressed in the granular layer of orthokeratotic squamous epithelia (Hohl *et al.*, 1991). It is expressed at the final stage during the process of epithelial differentiation, occurring later than involucrin and profilaggrin expression, and is a specific marker for keratinisation (Mehrel *et al.*, 1990). The intensity of loricrin expression varies between body sites: it is abundant in foreskin and perianal skin, but less so in leg skin (Hohl, 1993). In adult human epidermis, loricrin is diffusely distributed within the superficial granular cells with some accumulation at desmosomes. L-granules, eosinophilic granules distinct from the basophilic filaggrin-containing keratohyalin granules (F-granules), are scarcely found in adult human skin (Ishida-Yamamoto *et al.*, 1993).

In this present study, loricrin distribution was essentially limited to upper spinous and granular layers in all PPK subtypes, with additional nuclear staining around sweat ducts noted in Loricrin PPK. Loricrin staining was particularly prominent in areas of acantholysis in K1 and K9 patients, where the disruption of cell-to-cell adhesion was associated with both intense cytoplasmic staining and focal

areas of stratum corneum breakdown. This raises the possibility that loricrin is upregulated at sites of epithelial injury. Loricrin immunolocalisation has been studied and found to be decreased in situations of hypo- or agranulotic parakeratotic keratinisation including psoriasis, dermatitis, pityriasis lichenoides, porokeratosis and precancerous and malignant lesions (Hohl *et al.*, 1993; Juhlin *et al.*, 1992). In contrast, normal loricrin staining has been demonstrated in nonbullous congenital ichthyosiform erythroderma, in association with thick, compact cornified layers with parakeratosis (Kawashima *et al.*, 2005). In this study, uniform loricrin staining was observed in 2 PPK patients with alternating areas of ortho- and parakeratosis.

High levels of loricrin are found in hypergranulotic and orthokeratotic lesions in lichen planus, benign papillomas and pseudocarcinomatous hyperplasia (Hohl *et al.*, 1993). Interruption of loricrin expression in porokeratosis was associated with early apoptosis of epidermal keratinocytes thought to result in the dysregulation of keratinisation (Shen *et al.*, 2002). In this study, both loricrin and apoptotic marker expression appeared normal (3.2.4.6) although more detailed study of a range of apoptotic markers is warranted. Ichthyosis vulgaris skin shows normal loricrin staining in the granular layer, compared to lamellar ichthyosis with deficient expression of transglutaminase 1, both loricrin and involucrin are expressed but not incorporated into the CE (Hohl *et al.*, 1993). In this study, normal loricrin staining was observed in Loricrin, K17 and DSG1 patients with evidence of hypergranulosis.

Strong immunohistochemical staining for loricrin, involucrin and SPPR1 were found in BCIE, with some premature labelling associated with the plasma membrane of granular cells, possibly relating to abnormal keratin filament aggregation and cellular vacuolization (Ishida-Yamamoto *et al.*, 1995). Loricrin

expression in EKV without Cx31 or 30.3 gene mutations was increased, thought to reflect the presence of hypergranulosis (Arita *et al.*, 2003), but in another case without Cx31 mutation loricrin expression was greatly diminished suggesting a disruption of keratinisation at a very late stage (Ishida-Yamamoto *et al.*, 2000a). In this study, the normal expression of loricrin across all PPK subtypes compared to the uniformly premature expression of involucrin (3.2.4.9) is suggestive of a disruption at an earlier stage of differentiation.

#### **3.2.4.11 Disease mechanisms in loricrin keratoderma**

Loricrin is thought to lead to cutaneous disease by a number of disease mechanisms. The first is through abnormalities in CE development; the second is through dysfunctional apoptosis of differentiating keratinocytes (Ishida-Yamamoto *et al.*, 1998c; 1999; 2000b). The loricrin protein is elongated as a result of the 1-bp insertion, leading to a frameshift and delayed termination in *LOR* (Maestrini *et al.*, 1996). In the epidermis of patients carrying a loricrin mutation, the profilaggrin amino-terminal domains aggregate with loricrin in the nuclei (Ishida-Yamamoto *et al.*, 1998c). The mutant loricrin is translocated into the nucleus instead of the CE, with the mutant C-terminus probably functioning as a nuclear targeting sequence. It is thought that a delay in apoptosis occurs as a result of interactions with nucleic acids in the nucleus leading to cross-linking of nuclear transgluaminases (Ishida-Yamamoto *et al.*, 1998c; 1999; 2000b). This delay in apoptosis is suggested as one of the main causes of the phenotype (Gedicke *et al.*, 2006).

Immunoelectron-microscopic studies of loricrin keratoderma have revealed sparse staining for loricrin in thin CE with abnormal intranuclear granules in granular and cornified layer cells, positive for both C- and N-terminal loricrin, compared to

Vohwinkel's keratoderma which demonstrated normal loricrin distribution (Korge *et al.*, 1997). Mutant loricrin in loricrin keratoderma has been noted not to crosslink into the CE, but translocates into the nucleus of differentiated epidermal keratinocytes (Ishida-Yamamoto *et al.*, 2000b). Electron microscopy of 2 Loricrin patients in this study did not reveal any clear nuclear abnormalities but further immunoelectron-microscopic studies specifically staining for loricrin are warranted (see chapter 3.1).

To better understand the link between the loricrin genotype and skin pathology in loricrin keratoderma, several murine models have been developed with either loss or gain of loricrin function, which produce only modest skin phenotypes (Yoneda and Steinert, 1993; Koch *et al.*, 2000; Suga *et al.*, 2000; Jarnik *et al.*, 2002). These have supported the hypothesis that synthesis of mutant loricrin is responsible for the phenotype rather than the lack of wild-type loricrin. A mouse model overexpressing human loricrin resulted in a normal phenotype, with all loricrin incorporated into the CE (Yoneda & Steinert, 1993). A mild, transient phenotype was present in loricrin knock-out mice, which disappeared 4-5 days after birth (Koch *et al.*, 2000; Jarnik *et al.*, 2002), with only a transgenic mouse model showing a more lasting phenotype (Suga *et al.*, 2000). Mice which were homozygous for the mutant transgene had more severe features in the absence of wild-type loricrin, when transgenic mice were bred with knockout mice. This suggests that mutant loricrin is functional but does not need the wild type to produce the typical phenotype (Suga *et al.*, 2000). Gedicke *et al.* (2006) reported a family with loricrin keratoderma due to the previously reported 730insG mutation in whom pseudoainhum were not a



feature. Pyrosequencing of transcript of *LOR* revealed an equal expression of mutant and wild-type alleles underlining the gain-of-function theory for loricrin mutations.

In contrast, the consequences of mutations in loricrin on epidermal function and morphology have been studied in skin from patients previously genotyped for mutations in the loricrin gene (Schmuth *et al.*, 2004; Maestrini *et al.*, 1999). This revealed abnormal corneocyte fragility and basal permeability barrier function, but accelerated repair kinetics, possibly explicable by amplified lamellar body secretion. Partial normalisation of the CE in the outer stratum corneum correlated with persistence of abundant calcium in the extracellular spaces, positioned to activate transglutaminase-1 (Schmuth *et al.*, 2004). These results suggest that the barrier abnormality in loricrin keratoderma is linked to a defective cornified envelope scaffold, resulting in increased extracellular permeability. In this study, 2/2 loricrin patients demonstrated markedly thickened stratum corneum compared to other subtypes (see chapter 3.1), and further studies of stratum corneum function are needed.

### **3.2.5 Conclusion**

Immunocytochemical study of affected plantar skin in inherited PPK due to a variety of underlying molecular aetiologies, does not demonstrate significant differences in expression of a selection of markers of differentiation, cornified envelope proteins or markers of proliferation and apoptosis. Premature keratinocyte differentiation was suggested by altered cytoplasmic staining of involucrin in all subtypes, suggestive of a common mechanism of hyperkeratosis, and prominent loricrin staining was noted in acantholytic areas in EPPK due to K9 mutation. Further ultrastructural and functional studies would be beneficial. Overt changes in epidermal turnover were not

apparent, with no major change in proliferative index. More detailed analysis of proliferative and apoptotic markers, as well as examination of late differentiation events and shedding, would be needed further to exclude the relevance of these processes to the PPK phenotype.



## **Chapter 3.3 Towards a Pilot Microarray Experiment**

### **3.3.1 Introduction**

Biological research has been revolutionised by the complete genome sequences of hundreds of organisms, giving rise to the new science of genomics. Microarray analysis takes advantage of the vast amount of sequence information and allows investigators to examine alterations in the gene expression of thousands of genes simultaneously in a single experiment (Wong & Chang, 2005). Several published studies have reported attempts to carry out gene expression profiling by microarrays or real time RT-PCR using RNA extracted from small skin biopsies or laser capture microdissected skin sections (Storz *et al.*, 2003; Nomura *et al.*, 2003; Baumgarth *et al.*, 2004). While promising, the technology for producing reproducible data from small amounts of tissue is still at a developmental stage and requires validation in each laboratory.

The initial aim was to test different methods of RNA extraction to optimise yield and quality of RNA extracted from whole biopsies, separated epidermis and microdissected tissue using control biopsy material. Having optimised RNA preparation and cDNA synthesis for microarray analysis, a comparison of gene expression profiles was planned using involved and uninvolved palmoplantar skin in the PC-2 family members recruited with an underlying K17 mutation (McLean *et al.*, 1995).

### **3.3.2 Methods**

#### **3.3.2.1 Samples**

Fresh elliptical plantar biopsies of affected skin from all 16 inherited PPK patients recruited were dissected into three pieces (chapter 2.2), one of which was snap frozen in liquid nitrogen and stored at -70°C. Where the keratoderma was focal (all PC-2 family members, n=8), a 4mm punch biopsy of unaffected skin was also obtained. Normal control samples of non-plantar skin were also snap frozen in liquid nitrogen and stored at -70°C, in the same way as the PPK specimens.

#### **3.3.2.2 Laser microdissection attempts**

Comparison between the Arcturus and Leica lasers for laser microdissected samples of control tissue epidermis was carried out.

##### *Leica Laser Microdissection System*

Frozen sections (5 µm) were cut and mounted on glass slides covered with PEN foil (2.5 µm thick; Leica Microsystems, Wetzlar, Germany). Samples were washed with 5 µl RNAsin® (40 U/ µl, Promega, Madison, WI, USA) prior to fixing with 70% ethanol at -20°C for 10 seconds. They were gently washed twice with diethylpyrocarbonate (DEPC)-treated water, and thoroughly air-dried.

Circular discs of epidermis were traced on the monitor with the computer mouse, and dissected from the frozen sections with the LMD system using a 337-nm nitrogen ultraviolet (UV) laser (Leica Laser Microdissection System, Leica Microsystems) and dropped immediately into a microcentrifuge tube cap filled with 200 µl RNeasy lysis buffer (Buffer RLT) (Qiagen, Valencia, CA, USA) containing guanidine isothiocyanate, per disc. Variations in laser aperture, intensity and speed were made in an attempt to optimise speed and ease of microdissection of the

epidermis. A total of 1 - 4 discs of epidermis were dropped into microcentrifuge tube caps, and RNA isolation step (see section 3.3.2.4) performed in order to identify the volume of microdissected epidermis required for sufficient RNA isolation to perform a microarray analysis.

#### *Arcturus Laser Microdissection System*

Frozen sections (5 µm) were cut and mounted on untreated glass slides and prepared thereafter as per Leica Laser Microdissection specimens. Epidermal cells were traced and microdissection attempted using Arcturus<sup>XT</sup>® Laser Capture Microdissection and UV Laser Cutting System (MDS Analytical Technologies, CA, USA).

#### **3.3.2.3 Manual microdissection of epidermis**

Comparison between laser microdissected samples of control tissue epidermis and manual microdissection of epidermis was carried out. Frozen sections were cut and prepared as for Leica Laser Microdissection (see section 3.3.2.2). Full thickness epidermis was manually dissected using a dissecting microscope, sterile blades and needles under RNase-free conditions and dropped into a microcentrifuge tube cap filled with 350 µl Buffer RLT.

#### **3.3.2.4 RNA isolation**

Total RNA was extracted from both Leica laser microdissected and manually dissected samples of epidermis, and whole biopsies using an RNeasy® mini kit (Qiagen) following the protocol recommended by the manufacturer, in the presence of DNase I (Qiagen). Whole biopsies were cut into slices less than 0.5cm thick and immersed in 600 µl of Buffer RLT. All samples were disrupted and homogenized in Buffer RLT, up to 600 µl per sample. Samples were also homogenised by three alternative methods: (1) rotor-stator sonicator, using Buffer RLT for 20-40 seconds,

until the sample was uniformly homogenous; (2) with the use of a Pyrex tissue grinder and addition of Buffer RLT, and homogenizing by passing lysate through an 18-20 gauge needle fitted to an RNase-free syringe several times; (3) immersion in 1 ml Trizol (Invitrogen, CA, USA) (ratio 10:1 Trizol: tissue) and then vortexing. The tissue lysate was centrifuged for 3 minutes at maximum speed in a microcentrifuge. The supernatant was transferred to a new microcentrifuge tube by pipetting, and 1 volume of 70% ethanol added to the cleared lysate, mixed and transferred immediately to an RNeasy mini column placed in a 2 ml collection tube and centrifuged for 15 seconds at > 10,000rpm. The flow-through was discarded. 700 µl Buffer RW1 (Qiagen) was added to the RNeasy column, and centrifuged for 15 seconds at >10,000 rpm to wash the column. The flow-through and collection tube was discarded. The RNeasy column was transferred into a new 2 ml collection tube, and 500 µl Buffer RPE pipetted onto the column. This was centrifuged for 2 minutes at >10,000rpm to dry the RNeasy silica-gel membrane. The column was transferred to a new 1.5ml collection tube, 30-50 µl RNase-free water pipetted directly onto the membrane, and centrifuged at >10,000rpm for 1 minute to elute. RNA concentration was tested on an Agilent Bioanalyser.

### **3.3.3 Results**

Initial attempts at laser capture/microdissection of frozen epidermal cells using the Arcturus Laser Microdissection system were unsuccessful and all subsequent laser microdissection was performed using the Leica Laser Microdissection System. More aggressive vacuum dessication of frozen sections might improve the success of the Arcturus Laser microdissection.

Attempts at RNA isolation, whether using the Leica laser microdissected epidermis (up to 4 discs), manually dissected epidermis or full thickness biopsies, failed to yield sufficient RNA for microarray analysis. Extractions from laser microdissected discs revealed no RNA peak for 1 disc of epidermis only, 2 discs degraded RNA only, and 4 discs produced very low concentrations of RNA at 11.4ng/μl. To date, attempts to extract RNA from full thickness epidermis have also produced only very low concentrations (5ng/μl; 8.6ng/μl).

### **3.3.4 Discussion**

#### **3.3.4.1 Microarray technology**

Global gene expression patterns have the potential to better define biologic phenomena and human disease states at the molecular level. Microarray analysis has been applied to several dermatologic diseases, including melanoma (Bittner *et al.*, 2000; Busam *et al.*, 2005), mycosis fungoides (Tracey *et al.*, 2003), cutaneous B cell lymphoma (Storz *et al.*, 2003), psoriasis (Bowcock *et al.*, 2001; Oestreicher *et al.*, 2001; Zhou *et al.*, 2001), atopic dermatitis (Nomura *et al.*, 2003), alopecia areata (Carroll *et al.*, 2002), scleroderma (Zhou *et al.*, 2003, 2007; Whitfield *et al.*, 2003) and ultra-violet irradiated skin (Becker *et al.*, 2001; Enk *et al.*, 2006).

One major application of DNA microarray technology has been the sequence-specific detection and quantification of mRNA expression. Oligonucleotide DNA microarrays were able to identify a few mRNA molecules per cell, within a wide linear range. In parallel, cDNA microarrays have been developed using cDNA molecules (of about 600-2000 bases in length) to interrogate mRNA samples. Owing to the high specificity of DNA sequence detection, the exchange of even one single



base may be detected using short oligonucleotides, and thus oligonucleotide DNA microarrays have been used for DNA sequencing. Similarly, DNA microarrays may detect single nucleotide polymorphisms (SNPs), which may contribute to tumour development/progression and predispose to a variety of different diseases (Kunz *et al.*, 2004).

Although *in vitro* cell culture experiments might be well controlled, growth factors present in cell culture media may impact on gene expression, making interpretation of results difficult. Similarly, whole biopsy material analysis does not allow for attributing gene expression to certain cell types (Kunz *et al.*, 2004). Laser-dissection microscopy can facilitate the *in situ* study of biological processes in solid tissues and organs by precisely isolating cells and tissue substructures for further analysis. Individual gene expression studies for multi-gene microarray technologies from cells isolated by laser-dissection microscopy have been reported (Fink *et al.*, 2002; Luzzi *et al.*, 2003; Inoue *et al.*, 2003; Baumgarth *et al.*, 2004). Although microarray analysis provides the most comprehensive approach to date for gene expression studies, the volumes of starting RNA required have at times resulted in the need for extensive pre-amplification with complex quality control issues because of possible bias introduced by non-linear amplification (Baumgarth *et al.*, 2004). Manual microdissection of skin samples prior to RNA isolation has been reported as an alternative method of isolating specific material in prokeratosis (Hivnor *et al.*, 2004).

#### **3.3.4.2 Towards a microarray experiment in PC-2**

To date, we have established the tissue resource for running a potential microarray experiment in PC-2. Due to the thickness of plantar skin, repeated attempts at RNA

extraction are required using alternative RNA extraction methods, including the RNeasy fibrous tissue kit (Qiagen) containing proteinase K. Laser microdissection using the Leica/Arcturus systems is no longer being pursued but rather continuing with full thickness biopsies for RNA extraction. Experimentation with the P.A.L.M. Laser Microdissection and Pressure Catapulting technology (Carl Zeiss MicroImaging, GmbH, Munich, Germany) is being investigated. Other possible methods to increase the yield of RNA from plantar samples include trying to increase solubilisation by not only pipetting RNA pellet in DEPC-treated water but heating to 55°C for 10-15 minutes. Also ensuring that the pellet is incubated with Trizol for 5 minutes at room temperature may assist homogenisation.

Where total RNA yield was insufficient to meet the required input for direct labelling cDNA microarrays, RNA amplification has also been described (Storz *et al.*, 2003). Total RNA samples were cleaned using the QIAamp RNA Mini Protocol (Qiagen) to create a high-quality template for subsequent RNA amplification.

Gene expression profiling may be controlled in one manner by comparing lesional tissue directly with proximal uninvolved epidermis from the same patient, as previously reported (Hivnor *et al.*, 2004). We aim to control a future microarray project in PC-2 in the same way, although obtaining further control plantar samples from unaffected patients would be a second method of experimental control.

### **3.3.5 Conclusion and future prospects**

Despite the use of different approaches, RNA was not successfully extracted from biopsy material during the time available. Nonetheless, gene expression profiling remains a highly promising approach to addressing the original question posed by this study. Further attempts to isolate RNA from these tissue sections for gene

expression profiling by microarray is underway, in collaboration with the McLean laboratory, Ninewells Hospital, Dundee, as is RNA preparation from normal epidermis for optimal yield and quality of RNA. Once completed, we aim to run a full microarray experiment on the large K17 mutation pedigree of PPK patients using the Affymetrix U133A chip at the Sir Henry Wellcome Functional Genomics Unit, University of Glasgow.

## **Section 4: Final Discussion And Conclusion**

### **4.1. Candidate mechanisms of hyperkeratosis in inherited PPK**

The inherited PPKs demonstrate both clinical and genetic heterogeneity, and improved understanding of their underlying molecular defects have helped provide information about the functional significance of proteins involved in the terminal differentiation of palmoplantar keratinocytes. However, the pathways by which the different genetic defects identified cause the common clinical phenotype remain obscure. In some cases, the reasons for the preferential involvement of palms and soles due to defects in widely expressed genes are still to be elucidated.

It is possible that a common pathologic defect exists in inherited PPK in the final stages of keratinocyte maturation into squames. In this study, I have sought to provide a resource for addressing this problem and to begin to investigate mechanisms which may be activated in the affected tissues in a variety of genetic defects. A broad range of underlying gene defects of inherited PPK were studied, including mutations in K1, K9, K17, DSG1, Loricrin and mitochondrial DNA

Three broad groups of mechanisms suggest themselves as candidates for the pathological hyperkeratosis seen in inherited PPKs. Firstly, increased thickening of the skin may simply be a physiological response to trauma, which is activated by, for example, a structural weakness in intermediate filaments. Normal palmar and plantar epidermis ordinarily undergoes hypertrophy at sites of friction or with use, and therefore it is part of its normal function to respond in this way. The adaptation of epidermal thickening as a response to mechanical stress in these specialised tissues may thus explain its localisation. Consistent with this possibility, the evidence presented in this thesis is generally of minimal change in the parameters studied. The

stratum corneum was greatly thickened, but not commonly parakeratotic; there was no alteration in a marker of proliferation, and the keratin expression profile was not obviously hyperproliferative. It is therefore possible that molecular studies will not show major qualitative changes in gene expression. This suggestion is also consistent with the fact that while oral retinoids suppress the hyperkeratosis, they often result in epidermis which is too thin and sensitive (Milstone *et al.*, 2005), and patients may not tolerate their use. Against this hypothesis, the very gross hyperkeratosis seen in some forms of keratoderma seems beyond what might be considered physiological.

The second possibility is that disruption of the epidermis, whether due to epidermolytic blistering or desmosomal defects, results in activation of the processes of wound healing. Although wound healing has not been studied in palmoplantar skin, it is reasonable to predict that there would be similar changes to those seen in skin in other sites. There has been considerable study of the effects of defects in keratins, desmosomes and gap junctions, all of which may be responsible for PPK, on wound healing, as discussed below.

In the case of keratin defects, epidermal thickening is common to many keratin disorders but changes in the epidermis due to keratinocyte dysfunction are not clearly understood due to limited knowledge of epidermal tissue homeostasis (Porter *et al.*, 1998). The impact of various keratin subtypes on differentiated functions of epithelial cells is not fully understood (Magin *et al.*, 2007), although there is evidence that changes in keratin expression may affect cell size, cell proliferation and the response to stress (Pallari & Eriksson, 2006; Gu & Coulombe, 2007). Keratin expression changes rapidly during differentiation and tissue injury, with differentiated keratinocytes repressing K1 and K10 during wound healing yet

keratinocytes proximal to the wound edge induce K6, K16 and K17. However, in this study there was limited evidence that these changes were present in affected palmoplantar skin.

Desmosomal proteins have been shown to have an important role in cell proliferation, motility and differentiation (Yin & Green, 2004; Green & Simpson, 2007). Alteration of desmosome structure correlates with wound healing, and desmosomal adhesion may be rapidly modulated in response to wounding (Wallis *et al.*, 2000). Mouse models lacking DSC1 resulted in epidermal hyperplasia due to increased cell proliferation (Chidgey *et al.*, 2001). Altered expression of DSC3a, 3b and DSG3 results in an increase in suprabasal keratinocyte proliferation (Merritt *et al.*, 2002; Hardman *et al.*, 2005). Normal embryonal stem cell proliferation appears dependent on DSG2 (Eshkind *et al.*, 2002). Keratinocyte cell proliferation is increased when DP is downregulated, suggesting a regulatory role in cell cycle progression (Wan *et al.*, 2007). Altered expression of DSG2 leads to epidermal hyperplasia and the development of pre-cancerous papillomas, as well as an increase in the activity of multiple cell growth and survival pathways (Brennan *et al.*, 2007).

DP and DSG1 haploinsufficiency in striate PPK exhibited increased keratinocyte proliferation and altered differentiation, suggesting that normal desmosome function was not maintained (Wan *et al.*, 2004). It is thought that the effects of structural component changes may relate to their role in stabilizing desmosome and classic adherens junction assembly while establishing and maintaining keratinocyte architecture. It is possible that subsequently intracellular signalling processes are affected (Wan *et al.*, 2007). This is further supported by the phosphorylation of DSG3 and its dissociation from plakoglobin, and the transient

increase in intracellular calcium concentrations and protein kinase C activity seen in human keratinocytes cultured with anti-DSG3 containing sera from pemphigus vulgaris patients (Aoyama *et al.*, 1999). In the present study, in one case of striate PPK associated with underlying DSG1 mutation there was premature expression of involucrin, suggestive of altered differentiation. This change was a uniform feature of all PPK subtypes studied, including underlying K1, K9, K17, Loricrin and Mitochondrial mutations. In contrast, loricrin expression was normal, raising the possibility that late differentiation is not affected but that the change in differentiation occurs at an earlier stage. Normal keratin expression, the lack of uniformity of keratin aggregates ultrastructurally despite the presence of underlying keratin mutations, and plantar hyperkeratosis being indistinguishable morphologically between subtypes suggests that many of the reported structural features of PPK are secondary phenomena as opposed to critical steps in the development of hyperkeratosis.

Mutations in the gap junction connexin proteins Cx26 and Cx30 are also associated with keratoderma (chapter 1). It is not clear how subtle changes in intercellular signal transmission within the epidermis result in epidermal thickening (Meşe *et al.*, 2006), but under pathological conditions, the normal distribution of connexins may be altered. Abnormal gap junction communication may modify the natural response pattern of keratinocytes both to stress/injury and during terminal differentiation (Rouan *et al.*, 2001). The role of specific Cxs in cell migration and proliferation responses remain unresolved but there is good evidence of their involvement as a response to wounding. (Kandyba *et al.*, 2008).

Interestingly, there is a high carrier frequency of Cx26 (*GJB2*) gene mutations in many ethnic groups (Gasparini *et al.*, 2000; Lucotte & Dieterlen, 2005). It has recently been suggested that such defects may provide a heterozygote advantage (D'Adamo *et al.*, 2008). Carriers of R134W allele show a thicker epidermis than wild-type ones (Meyer *et al.*, 2002) and cells expressing this allele form a significantly thicker epidermis in an organotypic co-culture skin model, show increased migration, and are less susceptible to cellular invasion by enteric pathogen *Shigella flexneri* (Man *et al.*, 2007). Transfection of deafness-associated mutant constructs has resulted in a reduction in cell death compared to wild-type ones (Common *et al.*, 2004). It has been hypothesized that a thicker epidermis, due to an extended terminal differentiation program and increased cell survival, may lead to an improved barrier against infection (D'Adamo *et al.*, 2008). It is postulated that alterations in gap junction structure might disturb cell-to-cell interaction, leading to epidermal thickening and hyperkeratosis, resulting in a stronger mechanical barrier.

Unfortunately, it was not possible to obtain samples from families affected by PPK due to connexin defects in time for inclusion in this study, but previous studies offer some evidence of the effects of such mutations. In an animal model of a connexin skin disorder mimicking Vohwinkel syndrome created by expression of Cx-D66H in transgenic mice (Bakirtzis *et al.*, 2003) found epidermal thickening or hyperkeratosis similar to the clinical features of humans. They also found premature keratinocyte cell death, in contrast to the theory of increased cell survival proposed by D'Adamo *et al.* (2008). Accumulation of Cx26-D66H protein in keratinocyte cytoplasm was noted, suggestive of defective trafficking of the protein to the plasma membrane (Bakirtzis *et al.*, 2003). In *in vitro* studies using Cx26 mutations G59A



and D66H in Vohwinkel syndrome, Lucifer yellow dye transfer experiments demonstrated that mutants did not form functional channels, with mutations exerting a dominant-negative action on Cx26, but having selective *trans*-dominant effects on Cx43 and Cx32 (Thomas *et al.*, 2004). Each mutation affected distinct connexins differentially which may explain variations in epidermal phenotypes (Meşe *et al.*, 2006).

The third group of possible mechanisms for palmoplantar hyperkeratosis is the activation of inflammatory mechanisms. These are likely to be relevant in hyperkeratotic forms of palmoplantar eczema and psoriasis. The livid marginal erythema characteristic of, for example, epidermolytic PPK (Vörner, 1901; Kuster *et al.*, 1995), may suggest paracrine inflammatory mediators. In some forms of keratoderma, for example mal de Meleda, inflammatory change is a major clinical feature (Niles & Clump, 1949; Salamon *et al.*, 1988). In other conditions, such as Papillon-Lefèvre syndrome due to homozygous loss of function mutations in the granulocyte enzyme Cathepsin C (Toomes *et al.*, 1999), it is easier to postulate altered inflammatory responses, and indeed pyogenic periodontitis is a feature of this disorder. In severe forms of epidermolysis bullosa simplex such as Dowling Meara syndrome, rupture of basal layer keratinocytes may be responsible for the inflammation of bullous lesions (McGrath *et al.*, 1992). However, while many patients, particularly with focal keratoderma, suffer from pain, inflammation and secondary infection, this is often localised and many keratodermas, including those with microscopic vacuolation, do not appear inflamed. Although in the present study, markers of inflammation and immune activation were not investigated in detail, there was no consistent histological evidence to suggest these were present. Consistent

with this, topical steroid and systemic immunosuppressive agents have not found a role in the management of keratodermas. Nonetheless, keratinocytes have a broad capacity to initiate inflammatory and immune responses and further study would be needed to exclude the possibility that the genetic defects in keratinocytes directly or indirectly induce autocrine or paracrine mediators of altered differentiation.

MicroRNAs studies, which it is still hoped to undertake, may allow distinction between these possibilities.

#### **4.2 Future prospects: therapeutic siRNA**

It is clear that whatever the mechanism of this group of disorders, their management is unsatisfactory. This study has sought to explore pathological mechanisms active in PPK, but for inherited disorders, and particularly if the pathogenesis is in fact an appropriate activation of a physiological response, an ideal treatment would remove the underlying cause rather than seeking to disrupt the pathways which it activates. This implies gene-directed therapies. Many disorders of keratinisation, including nearly all the human keratin disorders, are associated with dominant mutations, typically causing either haploinsufficiency or toxic gain-of-function mutations. Genetic therapies for the latter diseases must either suppress the production of the mutant proteins or correct the genetic defect in the chromosome (Lewin *et al.*, 2005). RNA interference (RNAi) is a highly evolutionarily conserved process that is used by cells to selectively regulate and silence gene expression, and is widely used as an experimental tool (Rugg, 2008). It is increasingly apparent that RNAi also has great potential as a therapeutic strategy for treating many human disorders, including genetic diseases, viral infections and cancer (Ryther *et al.*, 2005). Skin disorders represent a good model for RNAi therapy development because localized cutaneous

application of small interfering siRNA (siRNA) may be easier to achieve than systemic administration or use of integrating viral vector systems, both for proof-of-concept experiments in cell culture or animal models and ultimately, treatment of human subjects (Lewin *et al.*, 2005). siRNAs act via the RNA-induced silencing complex (RISC) to specifically degrade target RNAs, with inhibition of gene expression mediated by hybridized RNAs, typically containing a 19bp complementary region with two nucleotide 3' overhangs (19+2 design) that are sufficiently small so as to avoid immune surveillance (Leachman *et al.*, 2008).

PC is caused by mutations in one of four keratin genes (chapter 1), with most patients carrying K6a mutations. Knockout mouse studies of the two major K6 genes, K6a and K6b, have shown these genes exhibit functional redundancy ie. knocking out one of these keratins is tolerated owing to compensatory expression of the others (Wojcik *et al.*, 2000, 2001; Wong *et al.*, 2000; Wong & Coulombe, 2003). It has been shown that the human genome exhibits far more structural variation between individuals in the population than previously recognized (Kehrer-Sawatzki, 2007) and Smith *et al.*(2008) hypothesize that ablation of K6a in humans does not produce a PC-like phenotype and have developed potent RNAi against K6a as a paradigm for treating a localised skin disorder. They have shown that targeting the 3'-UTR of the K6a gene allows both potent and specific inhibition of K6a expression both in cultured cells and early *in vivo* studies. Coupled with a suitable epidermal delivery system, these reagents could provide a potential route to therapy for PC. Smith *et al.*(2008) have delivered siRNA by injection to keratinocytes in the mouse foot pad, however, whether this will prove to be a viable method for treatment of PC patients will depend on a number of factors, including how many injections are

needed and how often they will be repeated to maintain gene silencing (Rugg, 2008).

### **4.3 Summary and Conclusion**

The aim of the work reported in this thesis was to develop a tissue and cell culture resource, with the ultimate goal of increasing understanding of molecular mechanisms active in the pathogenesis of palmoplantar keratoderma. A large resource of palmoplantar biopsy material, and of keratinocyte cultures derived from skin biopsies from affected individuals, has successfully been established. Other avenues explored in the course of the work have included documentation of clinical aspects of the palmoplantar keratodermas and associated ectodermal features; the inadequacy of current management; the use of regional nerve block to reduce the discomfort of biopsying plantar epidermis; and genetic investigation of a pedigree with an unknown mutation.

The potential of the resource was demonstrated by application in initial laboratory studies. Previous studies have reported findings in small numbers of samples, without controls. With few exceptions, the present comparative studies of morphology at light and electron microscopic level, or using immunocytochemistry with a range of markers of differentiation, proliferation and apoptosis, failed to identify reliable and consistent differences between keratodermas of markedly different molecular aetiologies. Only aberrant involucrin expression was a uniform feature of the different keratodermas raising the possibility of a common abnormality of differentiation. Indeed the variation from normal palmoplantar epidermis was often minimal. It may be that study of a wider range of pathologies, such as those due to gap junction defects, would have provided evidence of other mechanisms in

play. Equally, the lack of evidence of differences may indicate that there is indeed a common final pathway for hyperkeratosis in palmoplantar keratoderma, but that it is simply a variation in degree of the normal function of palmoplantar skin, i.e. hypertrophy in response to mechanical stress.

It is hoped that future studies, for example of gene expression, may clarify this issue. A pilot study of the potential of cDNA microarray analysis to achieve this was thwarted by failure to extract RNA, but it is hoped to overcome these technical difficulties. Moreover, the tissue and tissue culture resource established will also serve to identify and explore manipulation of genetic or other molecular targets for better future care in this challenging group of conditions.

## **SECTION 5. BIBLIOGRAPHY**

- Abell E. & Morgan K. (1974). The treatment of idiopathic hyperhidrosis by glycopyrronium bromide and tap water iontophoresis. *Br J Dermatol.* 91, 87-91.
- Aberg K.M., Racz E., Behne M.J. & Mauro T.M. (2007). Involucrin expression is decreased in Hailey-Hailey keratinocytes owing to increased involucrin mRNA degradation. *J Invest Dermatol.* 127, 1973-1979.
- Akins D.L., Meisenheimer J.L. & Dobson R.L. (1987). Efficacy of the drionic unit in the treatment of hyperhidrosis. *J Am Acad Dermatol.* 16, 828-832.
- Akiyama M., Sakai K., Arita K., Nomura Y., Ito K., Kodama K., McMillan J.R., Kobayashi K., Sawamura D. & Shimizu H. (2007). A novel *GJB2* mutation p.Asn54His in a patient with palmoplantar keratoderma, sensorineural hearing loss and knuckle pads. *J Invest Dermatol.* 127, 1540-1542.
- Alcalai R., Metzger S., Rosenheck S., Meiner V. & Chajek-Shaul T. (2003). A recessive mutation in desmoplakin causes arrhythmogenic right ventricular cardiomyopathy, skin disorder and woolly hair. *J Am Coll Cardiol.* 16, 319-327.
- Alexandrino F., Sartorato E.L., Marques-de-Faria A.P. & Steiner C.E. (2005). G59S mutation in the *GJB2* (connexin 26) gene in a patient with Bart-Pumphrey syndrome. *Am J Med Genet.* 136A, 282-284.
- Allen E., Yu Q.C. & Fuchs E. (1996). Mice expressing a mutant desmosomal cadherin exhibit abnormalities in desmosomes, proliferation, and epidermal differentiation. *J Cell Biol.* 113, 1367-1382.
- Allenby G., Janocha R., Kazmer S., Speck J., Grippo J.F. & Levin A.A. (1994). Binding of 9-*cis*-retinoic acid and all-*trans*-retinoic acid to retinoic acid receptors alpha, beta, and gamma. Retinoic acid receptor gamma binds all-*trans*-retinoic acid preferentially over 9-*cis*-retinoic acid. *J Biol Chem.* 269, 16689-16695.
- Altucci L. & Gronemeyer H. (2001). The promise of retinoids to fight against cancer. *Nat Rev Cancer.* 1, 181-193.
- Amagai M., Nishikawa T., Nousari H.C., Anhalt G.J. & Hashimoto T. (1998). Antibodies against desmoglein 3 (pemphigus vulgaris antigen) are present in sera from patients with paraneoplastic pemphigus and cause acantholysis in vivo in neonatal mice. *J Clin Invest.* 102, 775-782.
- Amagai M. (2003). Desmoglein as a target in autoimmunity and infection. *J Am Acad Dermatol.* 48, 244-252.
- Anhalt G.J. (1999). Making sense of antigens and antibodies in pemphigus. *J Am Acad Dermatol.* 40, 763-767.

- Anneroth G., Isacson G., Lagerholm B., Lindvall A.-M. & Thyresson N. (1975). Pachyonychia congenita. A clinical, histological and microradiographic study with special reference to oral manifestations. *Acta Derm Venereol.* 55(5), 387-394.
- Antoniades L., Tsatsopoulou A., Anastasakis A., Syrris P., Asimaki A., Panagiotakos D., Zambartas C., Stenfanadis C., McKenna W.H. & Protonotarios N. (2006). Arrhythmogenic right ventricular cardiomyopathy caused by deletions in plakophilin-2 and plakoglobin (Naxos disease) in families from Greece and Cyprus: genotype-phenotype relations, diagnostic features and prognosis. *Eur Heart J.* 26, 2208-2216.
- Anton-Lamprecht I. (1994). Ultrastructural identification of basic abnormalities as clues to genetic disorders of the epidermis. *J Invest Dermatol.* 103, 6s-12s.
- Anton-Lamprecht I. (1996). Keratin clumping in epidermolysis bullosa, Dowling-Meara type. *Br J Dermatol.* 134, 184-185.
- Anton-Lamprecht I. & Schnyder U.W. (1982). Epidermolysis bullosa herpetiformis Dowling-Meara. Report of a case and pathomorphogenesis. *Dermatologica.* 164(4), 221-235.
- Aoyama Y., Owada M.K. & Kitajima Y. (1999). A pathogenic autoantibody, pemphigus IgG, induces phosphorylation of desmoglein 3, and its dissociation from plakoglobin in cultured keratinocytes. *Eur J Immunol.* 29, 2233-2240.
- Arita K., Akiyama M., Tsuji Y., Onozuka T. & Shimizu H. (2003). Erythrokeratoderma variabilis without connexin 31 or connexin 30.3 gene mutation: immunohistological, ultrastructural and genetic studies. *Acta Derm Venereol.* 83(4), 266-270
- Armstrong D.K.B., McKenna K.E., Purkis P.E., Green K.J., Eady R.A.J., Leigh I.M. & Hughes A. (1999). Haploinsufficiency of desmoplakin causes a striate subtype of palmoplantar keratoderma. *Hum Mol Genet.* 8(1), 143-148.
- Arnemann J., Spurr N.K., Wheeler G.N., Parker A.E. & Buxton R.S. (1991). Chromosomal assignment of the human genes coding for the major proteins of the desmosome junction, desmoglein 1 (DSG), desmocollins DGII/III (DSC), desmoplakins (DPI/II) and plakoglobin DPIII (JUP). *Genomics.* 10, 640-645.
- Arnemann J., Sullivan K.H., Magee A.I., King I.A. & Buxton R.S. (1993). Stratification-related expression of isoforms of the desmosomal cadherins in human epidermis. *J Cell Sci.* 104, 741-750.
- Arredondo J., Nguyen V.T., Chernyavsky A.I., Bercovich D., Orr-Urtreger A., Kummer W., Lips K., Vetter D.E. & Grando S.A. (2002). Central role of alpha7 nicotinic receptor in differentiation of the stratified squamous epithelium. *J Cell Biol.* 159, 325-336.

Bakirtzis G., Choudhry R., Aasen T., Shore L., Brown K., Bryson S., Forrow S., Tetley L., Finbow M., Greenhalgh D. & Hodgins M. (2003). Targeted epidermal expression of mutant Connexin 26(D66H) mimics true Vohwinkel syndrome and provides a model for the pathogenesis of dominant connexin disorders. *Hum Mol Genet.* 12, 1737-1744.

Barber A.G., Wajid M., Columbo M., Lubetkin J. & Christiano A.M. (2007). Striate palmoplantar keratoderma resulting from a frameshift mutation in the desmoglein 1 gene. *J Dermatol Sci.* 45, 161-166.

Bart R.S. & Pumphrey R.E. (1967). Knuckle pads, leukonychia and deafness – a dominant inherited syndrome. *N Engl J Med.* 276, 202-207.

Baumgarth N., Szubin R., Dolganov G.M., Watnik M.R., Greenspan D., Da Costa M., Palefsky J.M., Jordan R., Roederer M. & Greenspan J.S. (2004). Highly tissue substructure-specific effects of human papilloma virus in mucosa of HIV-infected patients revealed by laser-dissection microscopy-assisted gene expression profiling. *Am J Pathol.* 165, 707-718.

Bazzi H., Getz A., Mahoney M.G., Ishida-Yamamoto A., Langbein L., Wahl J.K. 3rd. & Christiano A.M. (2006). Desmoglein 4 is expressed in highly differentiated keratinocytes and trichocytes in human epidermis and hair follicle. *Differ.* 74, 129-140.

Beattie P.E. & Lewis-Jones M.S. (2006). A comparative study of impairment of quality of life in children with skin disease and children with other chronic childhood diseases. *Br J Dermatol.* 155, 145-151.

Becker B., Vogt T., Landthaler M. & Stolz W. (2001). Detection of differentially regulated genes in keratinocytes by cDNA array hybridization: Hsp27 and other novel players in response to artificial ultraviolet radiation. *J Invest Dermatol.* 116, 983-988.

Benfeldt E., Serup J. & Menné T. (1999). Effect of barrier perturbation on cutaneous salicylic acid penetration in human skin: in vivo pharmacokinetics using microdialysis and non-invasive quantification of barrier function. *Br J Dermatol.* 140, 739-748.

Benohanian A., Dansereau A., Bolduc C. & Bloom E. (1998). Localized hyperhidrosis treated with aluminium chloride in a salicylic acid gel base. *Int J Dermatol.* 37, 701-708.

Bernard D., Mehul B., Thomas-Collignon A., Simonetti L., Remy V., Bernard M.A. & Schmidt R. (2003). Analysis of proteins with caseinolytic activity in a human stratum corneum extract revealed a yet unidentified cysteine protease and identified the so-called “stratum corneum thiol protease” as cathepsin L2. *J Invest Dermatol.* 120, 592-600.



- Bergman R., Khamaysi Z. & Sprecher E. (2008). A unique pattern of dyskeratosis characterizes epidermolytic hyperkeratosis and epidermolytic palmoplantar keratoderma. *Am J Dermatopathol.* 30, 101-105.
- Bittner M., Meltzer P., Chen Y., Jiang Y., Seftor E., Hendrix M., Radmacher M., Simon R., Yakhini Z., Ben-Dor A., Sampas N., Dougherty E., Wang E., Marincola F., Gooden C., Lueders J., Glatfelter A., Pollock P., Carpten J., Gillanders E., Leja D., Dietrich K., Beaudry C., Berens M., Alberts D. & Sondak V. (2000). Molecular classification of cutaneous malignant melanoma by gene expression profiling. *Nature.* 406, 536-540.
- Blanchet-Bardon C., Nazzaro V., Rognin C., Geiger J.M. & Puissant A. (1991). Acitretin in the treatment of severe disorders of keratinisation. Results of an open study. *J Am Acad Dermatol.* 24(6Pt1), 982-986.
- Blanpain C. & Fuchs E. (2009). Epidermal homeostasis: a balancing act of stem cells in the skin. *Nature.* 10, 207-217.
- Boldin M.P., Goncharov T.M., Gotsev Y.V. & Wallach D. (1996). Involvement of MACH, a novel MORT1/FADD-interacting protease, in Fas/APO-1- and TNF receptor-induced cell death. *Cell.* 85, 803-815.
- Boldin M.P., Varfolomeev E.E., Pancer Z., Mett I.L., Camonis J.H. & Wallach D.A. (1995). Novel protein that interacts with the death domain of Fas/APO1 contains a sequence motif related to the death domain. *J Biol Chem.* 270, 7795-7798.
- Bonhert A. & Anton-Lamprecht I. (1982). Richner-Hanhart's syndrome: ultrastructural abnormalities of epidermal keratinisation indicating a causal relationship to high intracellular tyrosine levels. *J Invest Dermatol.* 79, 68-74.
- Bonifas J.M., Rothman A.L. & Epstein E.H. (1991). Epidermolysis bullosa simplex: evidence in two families for keratin gene abnormalities. *Science.* 254, 1202-1205.
- Bouman H. (1952). The treatment of hyperhidrosis of hands and feet with constant current. *Am J Phys Med.* 31, 158-169.
- Bovenschen H.J., Seyger M.M., van de Kerkhof P.C. (2005). Plaque psoriasis vs. atopic dermatitis and liche planus: a comparison for lesional T-cell subsets, epidermal proliferation and differentiation. *Br J Dermatol.* 153, 72-78.
- Bowcock A.M., Shannon W., Du F., Duncan J., Cao K., Aftergut K., Catier J., Fernandez-Vina M.A. & Menter A. (2001). Insights into psoriasis and other inflammatory diseases from large-scale gene expression studies. *Hum Mol Genet.* 10, 1793-1805.
- Bowden P.E., Haley J.L., Kansky A., Rothnagel J.A., Jones D.O. & Turner R.J. (1995). Mutation of a type II keratin gene (K6a) in pachyonychia congenita. *Nat Genet.* 10, 363-365.

- Bowen A.R., Hanks A.N., Murphy K.J., Florell S.R. & Grossman D. (2004). Proliferation, apoptosis, and survivin expression in keratinocyte neoplasms and hyperplasias. *Am J Dermatopathol.* 26, 177-181.
- Brandner J.M., Houdek P., Hüsing B., Kaiser C. & Moll I. (2004). Connexins 26, 30 and 43: Differences among spontaneous, chronic, and accelerated human wound healing. *J Invest Dermatol.* 122, 1310-1320.
- Brattsand M. & Egelrud T. (1999). Purification, molecular cloning, and expression of a human stratum corneum trypsin-like serine protease with possible function in desquamation. *J Biol Chem.* 274, 30033-30040.
- Brennan D., Hu Y., Joubeh S., Choi Y.W., Whitaker-Menezes D. & O'Brien T. (2007). Suprabasal Dsg2 expression in transgenic mouse skin confers a hyperproliferative and apoptosis-resistant phenotype to keratinocytes. *J Cell Sci.* 120, 758-771.
- Budunova I.V., Carbajal S. & Slaga T.J. (1995). The expression of gap junctional proteins during different stages of mouse skin carcinogenesis. *Carcinogenesis.* 16, 2717-2724.
- Budunova I.V., Carbajal S., Viaje A. & Slaga T.J. (1996). Connexin expression in epidermal cell lines from SENCAR mouse skin tumours. *Mol Carcinog.* 15, 190-201.
- Busam K.J., Zhao H., Coit D.G., Kucukgol D., Jungbluth A.A., Nobrega J. & Viale A. (2005). Distinction of desmoplastic melanoma from non-desmoplastic melanoma by gene expression profiling. *J Invest Dermatol.* 124, 412-419.
- Camisa C. & Rossana C. (1984). Variant of Keratoderma Hereditaria Multilans (Vohwinkel's syndrome). *Arch Dermatol.* 120, 1323-1328.
- Candi E., Schmidt R. & Melino G. (2005). The cornified envelope: a model of cell death in the skin. *Nat Rev Mol Cell Biol.* 6, 328-340.
- Carroll J.M., McElwee K.J., King L.E.Jr., Byrne M.C. & Sundberg J.P. (2002). Gene array profiling and immunomodulation studies define a cell-mediated immune response underlying the pathogenesis of alopecia areata in a mouse model and humans. *J Invest Dermatol.* 119, 392-402.
- Carvajal-Huerta L. (1998). Epidermolytic palmoplantar keratoderma with woolly hair and dilated cardiomyopathy. *J Am Acad Dermatol.* 39, 418-421.
- Caulin C., Ware C.F., Magin T.M. & Oshima R.G. (2000). Keratin-dependent, epithelial resistance to tumor necrosis factor-induced apoptosis. *J Cell Biol.* 149(1), 17-22.

- Chambon P. (1996). A decade of molecular biology of retinoic acid receptors. *FASEB J.* 10, 940-954.
- Charfeddine C., Mokni M., Ben Mousli R., Elakres R., Bouchlaka C., Boubaker S., Ghedamsi S., Baccouche D., Ben Osman A., Dellagi K. & Abdelhak S. (2003). A novel missense mutation in the gene encoding SLURP-1 in patients with Mal de Meleda from northern Tunisia. *Br J Dermatol.* 149, 1108-1115.
- Chawla A., Repa J.J., Evans R.M. & Mangelsdorf D.J. (2001). Nuclear receptors and lipid physiology: opening the X-files. *Science.* 294, 1866-1870.
- Chen J. & Roop D. (2005). Mouse models in preclinical studies for pachyonychia congenita. *J Invest Dermatol Symp Proc.* 10, 37-46.
- Cheng X. & Koch P.J. (2004). *In vivo* function of desmosomes. *J Dermatol.* 31, 171-187.
- Cheng J., Syder A.J., Yu Q.C., Letai A., Paller A.S. & Fuchs E. (1992). The genetic basis of epidermolytic hyperkeratosis: a disorder of differentiation-specific epidermal keratin genes. *Cell.* 70, 811-819.
- Chidgey M., Brakebusch C., Gustafsson E., Cruchley A., Hail C., Kirk S., Merritt A., North A., Tselepis C., Hewitt J., Byrne C., Fassler R. & Garrod D. (2001). Mice lacking desmocollin 1 show epidermal fragility accompanied by barrier defects and abnormal differentiation. *J Cell Biol.* 155, 821-832.
- Chimienti F., Hogg RC., Plantard L., Lehmann C., Brakch N., Fischer J., Huber M., Bertrand D. & Hold D. (2003). Identification of SLURP-1 as an epidermal neuromodulator explains the clinical phenotype of Mal de Meleda. *Hum Mol Genet* 12, 3017-3024
- Chinnaiyan A.M., O'Rourke K., Tewari M. & Dixit V.M. (1995). FADD, a novel death domain-containing protein, interacts with the death domain of FAs and initiates apoptosis. *Cell.* 81, 505-512.
- Chinnaiyan A.M., Tepper C.G., Seldin M.F., O'Rourke K., Kischkel F.C., Hellbardt S., Krammer P.H., Peter M.E. & Dixit V.M. (1996). FADD/MORT1 is a common mediator of CD95 (Fas/APO-1) and tumor necrosis factor receptor-induced apoptosis. *J Biol Chem.* 271, 4961-4965.
- Chipev C.C., Korge B.P., Markova N., Bale S.J., DiGiovanna J.J., Compton J.G. & Steinert P.M. (1992). A leucine-proline mutation in the H1 subdomain of keratin-1 causes epidermolytic hyperkeratosis. *Cell.* 70, 821-828.
- Christiano A.M. (1997). Frontiers in keratodermas: pushing the envelope. *Trends Genet.* 13, 227-233.

- Cina C.S. & Clase C.M. (1999). The Illness Intrusiveness Rating Scale: A measure of severity in individuals with hyperhidrosis. *Qual Life Res.* 8, 693-698.
- Clark R.A.F., Ashcroft G.S., Spencer M.-J., Larjava H. & Ferguson M.W.J. (1996). Re-epithelialization of normal human excisional wounds is associated with a switch from  $\alpha\beta 5$  to  $\alpha\beta 6$  integrins. *Br J Dermatol.* 135, 46-51.
- Clayton E., Doupé D.P., Klein A.M., Winton D.J., Simons B.D. & Jones P.H. (2007). A single type of progenitor cell maintains normal epidermis. *Nature.* 446, 185-189.
- Clementi M., Cardin de Stefani E., Dei Rossi C., Avventi V. & Tenconi R. (1986). Pachyonychia congenita Jackson-Lawler type: A distinct malformation syndrome. *Br J Dermatol.* 114(3), 367-370.
- Clouston H.R. (1929). Hereditary ectodermal dystrophy. *Can Med Assoc J.* 21, 18-31.
- Clouston H.R. (1939). Major forms of hereditary ectodermal dysplasia. *Can Med Assoc J.* 40, 1-7.
- Coleman C.M., Munro C.S., Smith F.J.D., Uitto J. & McLean W.H.I. (1999). Epidermolytic palmoplantar keratoderma due to a novel type of keratin mutation, a 3bp insertion in the keratin K9 helix termination motif. *Br J Dermatol.* 140, 486-490.
- Common J.E., Di W-L., Davies D. & Kelsell D.P. (2004). Further evidence for heterozygote advantage of GJB2 deafness mutations: a link with cell survival. *J Med Genet.* 41, 573-575.
- Connors J.B., Rahil A.K., Smith F.J.D., McLean W.H.I. & Milstone L.M. (2001). Delayed-onset pachyonychia congenita associated with a novel mutation in the central 2B domain keratin 16. *Br J Dermatol.* 144(5), 1058-1062.
- Coonar A.S., Protonotarios N., Tsatsopoulou A., Needham E.W., Houlston R.S., Cliff S., Otter M.I., Murday V.A., Mattur R.K. & McKenna W.J. (1998). Gene for arrhythmogenic right ventricular cardiomyopathy with diffuse non-epidermolytic palmoplantar keratoderma and woolly hair (Naxos disease) maps to 17q21. *Circulation.* 97, 2049-2058.
- Corden L.D. & McLean W.H.I. (1996). Human keratin diseases: Hereditary fragility of specific epithelial tissues. *Exp Dermatol.* 5, 297-307.
- Coulombe P.A. & Omary M.B. (2002). 'Hard' and 'soft' principles defining the structure, function and regulation of keratin intermediate filaments. *Curr Opin Cell Biol.* 14, 110-122.
- Coulombe P.A. (1997). Towards a molecular definition of keratinocyte activation after acute injury to stratified epithelia. *Biochem Biophys Res Commun.* 236, 231-238.

- Coulombe P.A., Hutton M.E., Letain A., Herbert A., Paller A.S. & Fuchs E. (1991). Point mutations in keratin 14 genes of epidermolysis bullosa simplex patients: genetic and functional analyses. *Cell*. 66, 1301-1311.
- Coutinho P., Qui C., Frank S., Wang C.M., Brown T., Green C.R. & Becker D.L. (2005). Limiting burn extension by transient inhibition of connexin43 expression at the site of injury. *Br J Plast Surg*. 58, 658-667.
- Covello S.P., Irvine A.D., McKenna K.E., Munro C.S., Nevin N.C., Smith F.J.D., Uitto J. & McLean W.H.I. (1998a). Mutations in keratin K9 in kindreds with epidermolytic palmoplantar keratoderma and epidemiology in Northern Ireland. *J Invest Dermatol*. 111, 1207-1209.
- Covello S.P., Smith F.J.D., Smitt H.S.S., Paller A.S., Munro C.S., Uitto J. & McLean W.H.I. (1998b). Keratin 17 mutations cause pachyonychia congenita type 2 or steatocystoma multiplex. *Br J Dermatol*. 139, 475-480.
- Cui Y., Hagan K.W., Zhang S. & Peltz S.W. (1995). Identification and characterization of genes that are required for the accelerated degradation of mRNAs containing a premature translational termination codon. *Genes Dev*. 9, 423-436.
- Cury V.F., Gomez R.S., Costa J.E., Friedman E., Boson W. & De Marco L. (2004). A homozygous cathepsin C mutation associated with Haim-Munk syndrome. *Br J Dermatol*. 152, 353-356.
- D'Adamo P., Guerri V.I., Fabretto A., Faletra F., Grasso D.L., Ronfani L., Montico M., Morgutti M., Guastalla P.P. & Gasparini P. (2008). Does epidermal thickening explain GJB2 high carrier frequency and heterozygote advantage? *Eur J Hum Genet*. Epub advance online.
- Dale B.A., Presland R.B., Lewis S.P., Underwood R.A. & Fleckman P. (1997). Transient expression of epidermal filaggrin in cultured cells causes collapse of intermediate filament networks with alterations of cell shape and nuclear integrity. *J Invest Dermatol*. 108, 179-187.
- Dale B.A., Holbrook K.A. & Steinert P.M. (1978). Assembly of stratum corneum basic protein and keratin filaments in macrofibrils. *Nature*. 276, 729-731.
- Demerjian M., Hachem J.P., Tschachler E., Denecker G., Declercq W., Vandenaabeele P., Mauro T., Hupe M., Crumrine D., Roelandt T., Houben E., Elias P.M. & Feingold K.R. (2008). Acute modulations in permeability barrier function regulate epidermal cornification. Role of caspase-14 and the protease-activated receptor type 2. *Am J Pathol*. 172, 86-97.
- Denda M., Kitamura K., Eliase P.M. & Feingold K.R. (1997). trans-4-(aminomethyl)-cyclohexane carboxylic acid (T-AMCHA), an anti-fibrinolytic agent, accelerates barrier recovery and prevents the epidermal hyperplasia induced by epidermal injury in hairless mice and humans. *J Invest Dermatol*. 109, 84-90.

- Denecker G., Ovaere P., Vandenabeele P. & Declercq W. (2008). Caspase-14 reveals its secrets. *J Cell Biol.* 180(3), 451-458.
- DePianto D. & Coulombe P.A. (2004). Intermediate filaments and tissue repair. *Exp Cell Res.* 301, 68-76.
- Di W.L., Rugg E.L., Leigh I.M. & Kelsell D.P. (2001). Multiple epidermal connexins are expressed in different keratinocyte subpopulations including connexin 31. *J Invest Dermatol.* 117, 958-964.
- Djalilian A.R., McGaughey D., Patel S., Seo E.Y., Yang C., Cheng J., Tomic M., Sinha S., Ishida-Yamamoto A. & Segre J.A. (2006). Connexin 26 regulates epidermal barrier and wound remodelling and promotes psoriasiform response. *J Clin Invest.* 116, 1243-1253.
- Donovan M., Olofsson B., Gustafson A.L., Dencker L. & Eriksson U. (1995). The cellular retinoic acid binding proteins. *J Steroid Biochem Mol Biol.* 53, 459-465.
- Dua-Awereh M.B., Shimomura Y., Kraemer L., Wajid M. & Christiano A.M. (2009). Mutations in the desmoglein 1 gene in five Pakistani families with striate palmoplantar keratoderma. *J Derm Sci.* 53(3), 192-197.
- Dusek R.L., Godsel L.M. & Green K.J. (2007). Discriminating roles of desmosomal cadherins: Beyond desmosomal adhesion. *J Dermatol Sci.* 45, 7-21.
- Dusek R.L., Getsios S., Chen F., Park J.K., Amargo E.V., Cryns V.L. & Green K.J. (2006). The differentiation-dependent desmosomal cadherin desmoglein 1 is a novel caspase-3 target that regulates apoptosis in keratinocytes. *J Biol Chem.* 281(6), 3614-3624.
- Eady R.A.J., McGrath J.A. & McMillan J.R. (1994). Ultrastructural clues to genetic disorders of skin: the dermal-epidermal junction. *J Invest Dermatol.* 103, 13s-18s.
- Eady R.A.J. (1985). Transmission electron microscopy. In: Skerrow DSC, ed. *Methods in Skin Research*. Chichester: John Wiley & Sons.
- Egelrud T. & Stigbrand T. (1989). Regional variations in cytokeratin expression in palmo-plantar epidermis. *Acta Derm Venereol (Stockh).* 69, 373-379.
- Eichner R., Kahn M., Capetola R.J., Gendimenico G.J. & Mezick J.A. (1992). Effects of topical retinoids on cytoskeletal proteins: Implications for retinoid effects on epidermal differentiation. *J Invest Dermatol.* 98, 154-161.
- Elder J.T., Fisher G.J., Zhang Q.Y., Eisen D., Krust A., Kastner P., Chambon P. & Voorhees J.J. (1991). Retinoic acid receptor gene expression in human skin. *J Invest Dermatol.* 96, 425-433.

- Elder J.T., Cromie M.A., Griffiths C.E.M., Chambon P. & Voorhees J.J. (1993). Stimulus selective induction of CRABP-II mRNA: a marker for retinoic acid action in human skin. *J Invest Dermatol.* 100, 356-359.
- Elias P.M. & Choi E.H. (2005). Interactions among stratum corneum defensive functions. *Exp Dermatol.* 14, 719-726.
- Elias P.M. (2005). Stratum corneum defensive functions: an integrated view. *J Invest Dermatol.* 125, 183-200.
- Elias P.M., Matsuyoshi N., Wu H., Lin C., Wang Z.H., Brown B.E. & Stanley J.R. (2001). Desmoglein isoform distribution affects stratum corneum structure and function. *J Cell Biol.* 153(2), 243-249.
- Elias P.M., Ahn S.K., Denda M., Brown B.E., Crumrine D., Kimutai L.K., Kömüves L., Lee S.H. & Feingold K.R. (2002). Modulations in epidermal calcium regulate the expression of differentiation-specific markers. *J Invest Dermatol.* 119, 1128-1136.
- Enari M., Sakahira H., Yokoyama H., Okawa K., Iwamatsu A. & Nagata S. (1998). A caspase-activated DNase that degrades DNA during apoptosis, and its inhibitor ICAD. *Nature.* 391, 43-50.
- Enk C.D., Jacob-Hirsch J., Gal H., Verbovetski I., Amariglio N., Mevorach D., Ingber A., Givol D., Rechavi G. & Hochberg M. (2006). The UVB-induced gene expression profile of human epidermis in vivo is different from that of culture keratinocytes. *Oncogene.* 25, 2601-2614.
- Eshkind L., Tian Q., Schmidt A., Franke W.W., Windoffer R. & Leube R.E. (2002). Loss of desmoglein 2 suggests essential functions for early embryonic development and proliferation of embryonal stem cells. *Eur J Cell Biol.* 81, 592-598.
- Feinstein A., Freidman J. & Schewach-Millet M. (1988). Pachyonychia congenita. *J Am Acad Dermatol.* 19, 705-711.
- Fellman J.H., Vanbellin ghen P.J., Jones R.T. & Koler R.D. (1969). Soluble and mitochondrial forms of tyrosine aminotransferase. Relationship to human tyrosinaemia. *Biochemistry.* 8, 615-622.
- Fink L., Kohlhoff S., Stein M.M., Hanze J., Weissmann N., Rose F., Akkay-agil E., Manz D., Grimminger F., Seeger W. & Bohle R.M. (2002). cDNA array hybridization after laser-assisted microdissection from nonneoplastic tissue. *Am J Pathol.* 160, 81-90.
- Fischer J., Blanchet-Bardon C., Prud'homme J.F., Pavek S., Steijlen P.M., Dubertret L. & Weissenbach J. (1997). Mapping of Papillon-Lefèvre syndrome to the chromosome 11q14 region. *Eur J Hum Genet.* 5, 156-160.

- Fischer J., Bouadjar B., Heilig R., Huber M., Lefevre C., Jobard F., Macari F., Bakija-Konsuo A., Ait-Belkacem F., Weissenbach J., Lathrop M., Hohl D. & Prud'homme J.F. (2001). Mutations in the gene encoding SLURP-1 in Mal de Meleda. *Hum Mol Genet.* 10(8), 875-880.
- Fisher G.J., Talwar H.S., Xiao J.H., Datta S.C., Reddy A.P., Gaub M.P., Rochette-Egly C., Chambon P. & Voorhees J.J. (1994). Immunological identification and functional quantitation of retinoic acid and retinoid X receptor proteins in human skin. *J Biol Chem.* 269, 20629-20635.
- Fisher G.J., Datta S.C., Talwar H.S., Wang Z.Q., Varani J., Kang S. & Voorhees J.J. (1996). Molecular basis of sun-induced premature skin ageing and retinoid antagonism. *Nature.* 379, 335-339.
- Fleckman P. & Brumbaugh S. (2002). Absence of the granular layer and keratohyalin define a morphologically distinct subset of individuals with ichthyosis vulgaris. *Exp Dermatol.* 11, 327-342.
- Fluhr J.W., Cavalotti C. & Berardesca E. (2008). Emollients, moisturizers, and keratolytic agents in psoriasis. *Clin Dermatol.* 26, 380-386.
- Freedberg I.M., Tomic-Canic M., Komine M. & Blumenberg M. (2001). Keratins and the keratinocyte activation cycle. *J Invest Dermatol.* 116, 633-640.
- Frost P. & Van-Scott E.J. (1966). Ichthyosiform dermatoses. Classification based on anatomic and biometric observations. *Arch Dermatol.* 94, 113-126.
- Fuchs E. & Green H. (1980). Changes in keratin gene expression during terminal differentiation of the keratinocyte. *Cell.* 19, 1033-1042.
- Fuchs E. & Byrne C. (1994). The epidermis: rising to the surface. *Curr Opin Genet Dev.* 4, 725-736.
- Fuchs E. & Cleveland D.W. (1998). A structural scaffolding of intermediate filaments in health and disease. *Science.* 279, 514-519.
- Fukuya Y., Higaki M., Higaki Y. & Kawashima M. (2002). Effect of vitamin D3 on the increased expression of Bcl-xL in psoriasis. *Arch Dermatol Res.* 293, 620-625.
- Galvin S., Loomis C., Manabe M., Dhouailly D. & Sun T.T. (1989). The major pathways of keratinocyte differentiation as defined by keratin expression: an overview. *Adv Dermatol.* 4, 277-300.
- Gandarillas A., Goldsmith L.A., Gschmeissner S., Leigh I.M. & Watt F.M. (1999). Evidence that apoptosis and terminal differentiation of epidermal keratinocytes are distinct processes. *Exp Dermatol.* 8, 71-79.



- Gandarillas A. (2000). Epidermal differentiation, apoptosis, and senescence: common pathways? *Exp Gerontol.* 35, 53-62.
- Gandarillas A. & Watt F.M. (1997). c-Myc promotes differentiation of human epidermal stem cells. *Genes Dev.* 11, 2869-2882.
- Gandarillas A., Davies D. & Blanchard J.M. (2000). Normal and c-Myc-promoted human keratinocyte differentiation both occur via a novel cell cycle involving cellular growth and endoreplication. *Oncogene.* 19, 3278-3289.
- Gasparini P., Rabionet R., Barbujani G., Melchionda S., Petersen M., Brøndum-Nielsen K., Metspalu A., Oitmaa E., Pisano M., Fortina P., Zelante L. & Estivill X. (2000). High carrier frequency of the 35delG deafness mutation in European populations. Genetic analysis Consortium of GJB2 35delG. *Eur J Hum Genet.* 8, 19-23.
- Gedicke M.M., Traupe H., Fischer B., Tinschert S. & Hennies H.C. (2006). Towards characterization of palmoplantar keratoderma of a family and review of the literature. *Br J Dermatol.* 154, 167-171.
- Geisler N. & Weber K. (1982). The amino acid sequence of chicken muscle desmin provides a common structural model for intermediate filament proteins. *EMBO J.* 1(12), 1649-1656.
- Getsios S., Amargo E.V., Dusek R.L., Ishii K., Sheu L., Godsel L.M. & Green K.J. (2004). Coordinated expression of desmoglein 1 and desmocollin 1 regulates intercellular adhesion. *Differ.* 72, 419-433.
- Gibbs R.C. & Frank S.B. (1966). Keratoma hereditaria mutilans (Vohwinkel). *Arch Dermatol Syph.* 94, 619-625.
- Goliger J.A. & Paul D.L. (1995). Wounding alters epidermal connexin expression and gap junction-mediated intercellular communication. *Mol Biol Cell.* 6, 1491-1501.
- Gong X.Q., Shao Q., Lounsbury C.S., Bai D. & Laird D.W. (2006). Functional characterization of a *GJA1* frame-shift mutation causing oculodentodigital dysplasia and palmoplantar keratoderma. *J Biol Chem.* 281, 31801-31811.
- Goodenough D.A. (1974). Bulk isolation of mouse hepatocyte gap junctions. Characterization of the principal protein, connexin. *J Cell Biol.* 61, 557-563.
- Gorlin R.J., Pindborg J.J. & Cohen M.M. (1976). Syndromes of the head and neck. New York; McGraw-Hill.
- Gorlin R.J., Sedano H. & Anderson V.E. (1964). The syndrome of palmo-plantar hyperkeratosis and premature periodontal destruction of the teeth: a clinical and genetic analysis of the Papillon-Lefèvre syndrome. *J Pediatr.* 65, 895-908.

Gottfried I., Landay M., Glaser F., Di W.L., Ophir J., Mevorah B., Ben-Tal N., Kelsell D.P. & Avraham K.B. (2002). A mutation in GJB3 is associated with recessive erythrokeratoderma variabilis (EKV) and leads to defective trafficking of the connexin 31 protein. *Hum Mol Genet.* 11, 1311-1316.

Gottlieb S., Hayes E., Gilleaudeau P., Cardinale I., Gottlieb A.B. & Krueger J.G. (1996). Cellular actions of etretinate in psoriasis: enhanced epidermal differentiation and reduced cell-mediated inflammation are unexpected outcomes. *J Cutan Pathol.* 23, 404-418.

Gottlieb S.K. & Lutzner M.A. (1973). Darier's disease. *Arch Dermatol.* 107, 225-230.

Gown A.M. & Vogel A.M. (1982). Monoclonal antibodies to intermediate filament proteins of human cells: unique and cross-reactivity antibodies. *J Cell Biol.* 95, 414-424.

Green K.J. & Jones J.C. (1996). Desmosomes and hemidesmosomes: structure and function of molecular components. *FASEB J.* 10, 871-881.

Green K.J. & Simpson C.L. (2007). Desmosomes: New Perspectives on a Classic. *J Invest Dermatol.* 127, 2499-2515.

Greither A. (1977). Erbliche Palmoplantarkeratosen. *Hautarzt.* 28, 395-403.

Grice K, Sattar H. & Baker H. (1972). Treatment of idiopathic hyperhidrosis with iontophoresis of tap water and poldine methosulphate. *Br J Dermatol.* 86, 72-78.

Grifa A., Wagner C.A., D'Ambrosio L., Melchionda S., Bernardi F., Lopez-Bigas N., Rabionet R., Arbones M., Monica M.D., Estivill X., Zelante L., Lang F. & Gasparini P. (1999). Mutations in *GJB6* cause nonsyndromic autosomal dominant deafness at *DFNA3* locus. *Nat Genet.* 23, 16-18.

Griffiths C.E.M., Russman A.N., Majmudar G., Singer R.S., Hamilton T.A. & Voorhees J.J. (1993). Restoration of collagen formation in photodamaged human skin by tretinoin (retinoic acid). *N Eng J Med.* 329, 530-535.

Griffiths C.E.M., Dabelsteen E. & Voorhees J.J. (1996). Topical retinoic acid changes the epidermal cell surface glycosylation pattern towards that of a mucosal epithelium. *Br J Dermatol.* 134(3), 431-436.

Grimberg G., Hausser I., Müller F.B., Wodecki K., Schaffrath C., Krieg T., Oki V., Traupe H. & Arin M.J. (2009). Novel and recurrent mutations in the 1B domain of keratin 1 in palmoplantar keratoderma with tonotubules. *Br J Dermatol.* 160(2), 446-449.

Grinnell F. (1992). Wound repair, keratinocyte activation and integrin modulation. *J Cell Sci.* 101, 1-5.

- Gu L.H. & Coulombe P.A. (2007). Keratin function in skin epithelia: a broadening palette with surprising shades. *Curr Opin Cell Biol.* 19, 13-23.
- Guo L., Degenstein L., Dowling J., Yu Q.C., Wollmann R., Perman B. & Fuchs E. (1995). Gene targeting of BPAG1: abnormalities in mechanical strength and cell migration in stratified epithelia and neurologic degeneration. *Cell.* 81, 233-243.
- Haake A.R. & Polakowska R.R. (1993). Cell death by apoptosis in epidermal biology. *J Invest Dermatol.* 101(2), 107-112.
- Hachem J.P., Houben E., Crumrine D., Man M.Q., Schurer N., Roelandt T., Choi E.H., Uchida Y., Brown B.E., Feingold K.R. & Elias P.M. (2006). Serine protease signalling of epidermal permeability barrier homeostasis. *J Invest Dermatol.* 126, 2074-2086.
- Haim S. & Munk J. (1965). Keratosis palmo-plantaris congenita, with periodontosis, arachnodactyly and a peculiar deformity of the terminal phalanges. *Br J Dermatol.* 77, 42-54.
- Hakimelahi S., Parker H.R., Gilchrist A.J., Barry M., Li Z., Bleackley R.C. & Pasdar M. (2000). Plakoglobin reul gates the expression of the anti-apoptotic protein BCL-2. *J Biol Chem.* 275, 10905-10911.
- Haneke E. (1979). The Papillon-Lefèvre syndrome: keratosis palmoplantaris with periodontopathy. *Hum Genet.* 51, 1-35.
- Hansson L., Stromqvist M., Backman A., Wallbrandt P., Carlstein A. & Egelrud T. (1994). Cloning, expression, and characterization of stratum corneum chymotryptic enzyme. A skin-specific human serine proteinase. *J Biol Chem.* 269, 19420-19426.
- Happle R., van de Kerkhof P.C. & Traupe H. (1987). Retinoids in disorders of keratinisation: their use in adults. *Dermatologica.* 175(S1), 107-124.
- Harada K., Murakami T., Yata N. & Yamamoto S. (1992). Role of intercellular lipids in stratum corneum in the percutaneous permeation of drugs. *J Invest Dermatol.* 99, 278-282.
- Hardman M.J., Liu K., Avilion A.A., Merritt A., Brennan K., Garrod D.R. & Byrne C. (2005). Desmosomal cadherin misexpression alters (beta)-catenin stability and epidermal differentiation. *Mol Cell Biol.* 25, 969-978.
- Harris I.R., Farrell A.M., Grunfeld C., Holleran W.M., Elias P.M. & Feingold K.R. (1997). Permeability barrier disruption co-ordinately regulates mRNA levels for key enzymes of cholesterol, fatty acid, and ceramide synthesis in the epidermis. *J Invest Dermatol.* 109, 783-787.
- Harris S.L. & Levine A.J. (2005). The p53 pathway: positive and negative feedback loops. *Oncogene.* 24, 2899-2908.

- Hart T.C., Bowden D.W., Ghaffar K.A., Wang W., Cutler C.W., Cebeci I., Efeoglu A. & Firatli E. (1998). Sublocalization of the Papillon-Lefèvre syndrome locus on 11q14-q21. *Am J Med Genet.* 79, 134-139.
- Hart T.C., Hart P.S., Michalec M.D., Zhang Y., Firatli E., Van Dyke T.E., Stabholz A., Zlorogorski A., Shapira L. & Soskolne W.A. (2000). Haim-Munk syndrome and Papillon-Lefèvre syndrome are allelic mutations in cathepsin C. *J Med Genet.* 37, 88-94.
- Hartsfield J.K. Jr. (1994). Premature exfoliation of teeth in childhood and adolescence. *Adv Pediatr.* 41, 453-470.
- Hatsell S.J., Eady R.A., Wennerstrand L., Dopping-Hepenstal P., Leigh I.M., Munro C.S. & Kelsell D.P. (2001). Novel splice site mutation in keratin 1 underlies mild epidermolytic palmoplantar keratoderma in three kindreds. *J Invest Dermatol.* 116(4), 606-609.
- Hatsell S.J., Eady R.A., Wennerstrand L., Dopping-Hepenstal P., Leigh I.M., Munro C., Irvine A.D. & McLean W.H.I. (2003). The molecular genetics of the genodermatoses: progress to date and future directions. *Br J Dermatol.* 148, 1-13.
- Hatzfeld M. (1999). The armadillo family of structural proteins. *Int Rev Cytol.* 186, 179-224.
- Hayat M.A. (1989). Chapter 2. Rinsing, dehydrating and embedding. In: Principles and techniques of electron microscopy; biological applications. Basingstoke: MacMillan Press.
- Herrmann H., Strelkov S.V., Feja B., Rogers K.R., Brettel M., Lustig A., Haner M., Parry D.A., Steinert P.M., Burkhard P. & Aebi U. (2000). The intermediate filament protein consensus motif of helix 2B: its atomic structure and contribution to assembly. *J Molec Biol.* 298(5), 817-832.
- Herrmann H. & Foisner R. (2003). Intermediate filaments: novel assembly models and exciting new functions for nuclear lamins. *Cell Mol Life Sci.* 60, 1607-1612.
- Hershkovitz D., Lugassy J., Indelman M., Bergman R. & Sprecher E. (2009). Novel mutations in *DSG1* causing striate palmoplantar keratoderma. *Clin Exp Dermatol.* 34, 224-228.
- Hesse M., Franz T., Tamai Y., Taketo M.M. & Magin T.M. (2000). Targeted deletion of keratins 18 and 19 leads to trophoblast fragility and early embryonic lethality. *EMBO J.* 19(19), 5060-5070.
- Hewitt C., McCormick D., Linden G., Turk D., Stern I., Wallace I., Southern L., Zhang L., Howard R., Bullon P., Wong M., Widmer R., Gaffar K.A., Awawdeh L., Briggs J., Yaghmai R., Jabs E.W., Hoeger P., Bleck O., Rudiger S.G., Petersilka G., Battino M., Brett P., Hattab F., Al-Hamed M., Sloan P., Toomes C., Dixon M.,

- James J., Read A.P. & Thakker N. (2004). The role of cathepsin C in Papillon-Lefèvre syndrome, pubertal periodontitis, and aggressive periodontitis. *Hum Mutat.* 23, 222-228.
- Hivner C., Williams N., Singh F., VanVoorhees A., Dzubow L., Baldwin D. & Seykora J. (2004). Gene expression profiling of porokeratosis demonstrates similarities with psoriasis. *J Cutan Pathol.* 31, 657-664.
- Hodgins M.B.(2004). Connecting wounds with connexins. *J Invest Dermatol.* 122(5), ix-x.
- Hohl D. (1993). Expression patterns of loricrin in dermatological disorders. *Am J Dermatopathol.* 15(1), 20-27.
- Hohl D., Huber M. & Frenk E. (1993). Analysis of the cornified envelope in lamellar ichthyosis. *Arch Dermatol.* 129, 618-624.
- Hohl D., Mehrel T., Lichti U., Turner M.L., Roop D.R. & Steinert P.M. (1991). Characterization of human loricrin. Structure and function of a new class of epidermal cell envelope proteins. *J Biol Chem.* 266, 6626-6636.
- Holleran W.M., Man M.Q., Gao W.N., Menon G.K., Elias P.M. & Feingold K.R. (1991). Sphingolipids are required for mammalian epidermal barrier function. Inhibition of sphingolipid synthesis delays barrier recovery after acute perturbation. *J Clin Invest.* 88, 1228-1245.
- Hong W.K. & Itri L.M. (1994). Retinoids and human cancer. In: The Retinoids. Sporn M.B., Roberts A.B., Goodmens D.S., eds. Raven Press, New York, NY.
- Horikoshi T., Arany I., Rajaraman S., Chen S.H., Brysk H., Lei G., Tying S.K. & Brysk M.M. (1998). Isoforms of cathepsin D and human epidermal differentiation. *Biochimie.* 80, 605-612.
- Hornberger J., Grimes K., Naumann M., Glaser D.A., Lower N.J., Naver H., Ahn S. & Stolman L.P. (2004). Recognition, diagnosis, and treatment of primary focal hyperhidrosis. *J Am Acad Dermatol.* 51, 274-286.
- Hovorka O. & Ehlers E. (1897). Mal de Meleda. *Arch Derm Syph (Berlin).* 40, 251-256.
- Hu G., Yildirim M., Baysal V., Yerebakan O., Yilmaz E., Inaloz S., Martinex-Mir A., Christiano A.M. & Celebi J.T. (2003). A recurrent mutation in the ARS (component B) gene encoding SLURP-1 in Turkish families with Mal de Meleda: evidence of a founder effect. *J Invest Dermatol.* 120, 967-969.
- Hu Z., Bonifas J.M., Beech J., Bench G., Shigihara T., Ogawa H., Ikeda S., Mauro T. & Epstein Jr. E.H. (2000). Mutations in *ATP2C1*, encoding a calcium pump, cause Hailey-Hailey disease. *Nat Genet.* 24, 61-65.

- Huber C. & Christophers E. (1977). Keratolytics: effect of salicylic acid. *Arch Dermatol Res.* 257, 293-297.
- Hund M., Kinkelin I., Naumann M. & Henning H. (2002). Definition of axillary hyperhidrosis by gravimetric assessment. *Arch Dermatol.* 138(4), 539-541.
- Hunt D.M., Rickman L., Whittock N.V., Eady R.A., Simrak D., Dopping-Hepenstal P.J., Stevens H.P., Armstrong D.K., Hennies H.C., Kuster W., Hughes A.E., Arnemann J., Leigh I.M., McGrath J.A., Kelsell D.P. & Buxton R.S. (2001). Spectrum of dominant mutations in the desmosomal cadherin desmoglein 1, causing the skin disease striate palmoplantar keratoderma. *Eur J Hum Genet.* 9, 197-203.
- Iizuka H., Ishida-Yamamoto A. & Honda H. (1996). Epidermal remodelling in psoriasis. *Br J Dermatol.* 135, 433-438.
- Iizuka H., Honda H. & Ishida-Yamamoto A. (1997). Epidermal remodelling in psoriasis (II): a quantitative analysis of the epidermal architecture. *J Invest Dermatol.* 109, 806-810.
- Inada H., Izawa I., Nishizawa M., Fujita E., Kiyono T., Takahashi T., Momoi T. & Inagaki M. (2001). Keratin attenuates tumor necrosis factor-induced cytotoxicity through association with TRADD. *J Cell Biol.* 155, 415-426.
- Inoue K., Sakurada Y., Murakami M., Shiota M. & Shiota K. (2003). Detection of gene expression of vascular endothelial growth factor and flk-1 in the renal glomeruli of the normal rat kidney using the laser microdissection system. *Virchows Arch.* 442, 159-162.
- Irvine A.D. & McLean W.H.I. (1999). Human keratin diseases: the increasing spectrum of disease and subtlety of the phenotype-genotype correlation. *Br J Dermatol.* 140, 815-828.
- Irvine A.D. & McLean W.H.I. (2003). The molecular genetics of the genodermatoses: progress to date and future directions. *Br J Dermatol.* 148, 1-13.
- Ishida-Yamamoto A., Tanaka H., Nakane H., Takahashi H., Hashimoto Y. & Iizuka H. (1999). Programmed cell death in normal epidermis and loricrin keratoderma. Multiple functions of profilaggrin in keratinisation. *J Invest Dermatol.* 4, 145-149.
- Ishida-Yamamoto A., Kato H., Kiyama H., Armstrong D.K.B., Munro C.S., Eady R.A.J., Nakamura S., Kinouchi M., Takahashi H. & Iizuka H. (2000b). Mutant loricrin is not crosslinked into the cornified cell envelope but is translocated into the nucleus in loricrin keratoderma. *J Invest Dermatol.* 115, 1088-1094.
- Ishida-Yamamoto A., Takahashi H. & Iizuka H. (1998a). Loricrin and human skin diseases: molecular basis of loricrin keratodermas. *Histol Histopathol.* 13, 819-826.

Ishida-Yamamoto A., McGrath J.A., Chapman S.J., Leigh I.M., Lane E.B. & Eady R.A. (1991). Epidermolysis bullosa simplex (Dowling-Meara type) is a genetic disease characterized by an abnormal keratin-filament network involving keratins K5 and K14. *J Invest Dermatol.* 97, 959-968.

Ishida-Yamamoto A., McGrath J.A., Judge M.R., Leigh I.M., Lane E.B. & Eady R.A.J. (1992). Selective involvement of keratins K1 and K10 in the cytoskeletal abnormality of epidermolytic hyperkeratosis (bullous congenital ichthyosiform erythroderma). *J Invest Dermatol.* 99, 19-26.

Ishida-Yamamoto A. & Iizuka H. (1995). Differences in involucrin immunolabelling within cornified cell envelopes in normal and psoriatic epidermis. *J Invest Dermatol.* 104, 391.

Ishida-Yamamoto A., Hohl D., Roop D., Iizuka H. & Eady R.A.J. (1993). Loricrin immunoreactivity in human skin: Localization to specific granules (L-granules) in acrosyngia. *Arch Dermatol Res.* 285, 491-498.

Ishida-Yamamoto A., Kelsell D., Common J., Houseman M.J., Hashimoto M., Shibaki H., Asano K., Takahishi H., Hashimoto Y., Senshu T., Leigh I.M. & Iizuka H. (2000a). A case of erythrokeratoderma variabilis without mutations in connexin 31. *Br J Dermatol.* 143, 1283-1287.

Ishida-Yamamoto A., Takahashi H., Presland R.B., Dale B.A. & Iizuka H. (1998c). Translocation of profilaggrin N-terminal domain into keratinocyte nuclei with fragmented DNA in normal human skin and loricrin keratoderma. *Lab Invest.* 78, 1245-1253.

Ishida-Yamamoto A., Eady R.A.J., Underwood R.A., Dale B.A. & Holbrook K.A. (1994). Filaggrin expression in epidermolytic ichthyosis (epidermolytic hyperkeratosis). *Br J Dermatol.* 131, 676-779.

Ishida-Yamamoto A., Iizuka H., Manabe M., O'Guin W.M., Hohl D., Kartasova T., Kuorki T., Roop D.R. & Eady R.A.J. (1995). Altered distribution of keratinisation markers in epidermolytic hyperkeratosis. *Arch Dermatol Res.* 287, 705-711.

Ishida-Yamamoto A. & Iizuka H. (1998b). Structural organization of cornified cell envelopes and alteration in inherited skin disorders. *Exp Dermatol.* 7, 1-10.

Ishii M., Izumi J., Fujiwara H., Ito M. & Hamada M. (2001). Immunoblotting detection of gamma-catenin (plakoglobin) antibody in the serum of a patient with paraneoplastic pemphigus. *Br J Dermatol.* 144, 377-379.

Itin P.H. & Lautenschlager S. (1995). Palmoplantar keratoderma and associated syndromes. *Semin Dermatol.* 14, 152-161.

Itin P.H. & Fistarol S.K. (2005). Palmoplantar keratodermas. *Clinics Dermatol.* 23, 15-22.

- Itin P.H. (1992). Classification of autosomal dominant palmoplantar keratoderma: past-present-future. *Dermatology*. 185, 163-165.
- Itoh N., Yonehara S., Ishii A., Yonehara M., Mizushima S., Sameshima M., Hase A., Seto Y. & Nagata S. (1991). The polypeptide encoded by the cDNA for human cell surface antigen Fas can mediate apoptosis. *Cell*. 66, 233-243.
- Jacinto A., Martinez-Arias A. & Martin P. (2001). Mechanisms of epithelial fusion and repair. *Nat Cell Biol*. 3, E117-E123.
- Jackson A.D.M. & Lawler S.D. (1951). Pachyonychia congenita: a report of six cases in one family. *Ann Eugen*. 16, 142-146.
- Jadassohn J. & Lewandowsky F. (1906). Pachyonychia congenita. In: Jacobs Kongraphia Dermatologica. Berlin: Urban and Schwarzenberg.
- Janmey P.A., Euteneuer U., Traub P. & Schliwa M. (1991). Viscoelastic properties of vimentin compared with other filamentous biopolymer networks. *J Cell Biol*. 113, 155-160.
- Jaquemar D., Kupriyanov S., Wankell M., Avis J., Benirschke K, Baribasult H. & Oshima R.G. (2003). Keratin 8 protection of placental barrier function. *J Cell Biol*. 161(4), 749-756.
- Jarnik M., de Viragh P.A., Scharer E., Bundman D., Simon M.N., Roop D.R. & Steven A.C. (2002). Quasi-normal cornified cell envelopes in loricrin knockout mice imply the existence of a loricrin backup system. *J Invest Dermatol*. 118, 102-109.
- Jensen O. & Karlsmark T. (1980). Palmoplantar hyperhidrosis. Treatment with alcohol solution of aluminium chloride hexahydrate: a simple method of transpiration measurement. *Dermatologica*. 161, 133-135.
- Jensen J.M., Fölster-Holst R., Baranowsky A., Schunck M., Winoto-Morbach S., Neumann C., Schutze S. & Proksch E. (2004). Impaired sphingomyelinase activity and epidermal differentiation in atopic dermatitis. *J Invest Dermatol*. 22(6),1423-1431.
- Jouary T., Goizet C., Coupry I., Redonnet-Vernhet I., Levade T., Burgelin I., Toutain A., Delaporte E., Douillard C., Lacombe D., Taieb A. & Arveiler B. (2008). Detection of an intragenic deletion expands the spectrum of CTSC mutations in Papillon-Lefèvre syndrome. *J Invest Dermatol*. 128, 322-325.
- Judge M.R., McLean W.H.I. & Munro C.S. (2004). Disorders of Keratinisation. In: Rook's Textbook of Dermatology (Burns DA, Breathnach SM, Cox NH, Griffiths CEM, eds), 7<sup>th</sup> edn, Vol 2. Oxford: Blackwell Publishing.
- Juhlin L., Magnoldo T. & Darmon M. (1992). Expression of loricrin in skin disorders. *Acta Derm Venereol*. 72, 407-409.



- Kabashima K., Sakabe J., Yamada Y. & Tokura Y. (2008). "Nagashima-type" keratosis as a novel entity in palmoplantar keratoderma category. *Arch Dermatol.* 144, 375-379.
- Kalinin A., Kajava A.V. & Steinert P.M. (2002). Epithelial barrier function: assembly and structural features of the cornified cell envelope. *BioEssays.* 24, 789-800.
- Kamibayashi Y., Oyamada Y., Mori M. & Oyamada M. (1995). Aberrant expression of gap junction proteins (connexins) is associated with tumor progression during multistage mouse skin carcinogenesis *in vivo*. *Carcinogenesis.* 16, 1287-1297.
- Kandyba E., Hodgins M. & Martin P.E. (2008). A murine living skin equivalent amenable to live-cell imaging: analysis of the roles of connexins in the epidermis. *J Invest Dermatol.* 128, 1039-1049.
- Kanerva L., Karvonen J., Oikarinen A., Lauharanta J., Ruokonen A. & Niemi K.M. (1984). Ichthyosis hystrix (Curth-Macklin). Light and electron microscopic studies performed before and after etretinate treatment. *Arch Dermatol.* 120(9), 1218-1223.
- Kang S., Duell E.A., Fisher G.J., Datta S.C., Wang Z.Q., Reddy A.P., Tavakkol A., Yi J.Y., Griffiths C.E.M., Elder J.T. & Voorhees J.J. (1995). Application of retinol to human skin *in vivo* induces epidermal hyperplasia and cellular retinoid binding proteins characteristic of retinoic acid but without measurable retinoic acid levels or irritation. *J Invest Dermatol.* 105, 549-556.
- Kanitakis J., Hoyo E., Chouvet B., Thivolet J., Faure M. & Claudy A. (1993). Keratinocyte proliferation in epidermal keratinocyte disorders evaluated through PCNA/cyclin immunolabeling and AgNOR counting. *Arch Dermatol Venereol.* 73, 370-375.
- Kanitakis J., Zmbruno G., Viac J. & Thivolet J. (1987). Involucrin expression in keratinisation disorders of the skin – a preliminary study. *Br J Dermatol.* 117, 479-486.
- Kassar S., Charfeddine C., Zribi H., Tounsi-Kettiti H., Mbaraka B., Abdelhak S., Osman B. & Boubaker S. (2008). Immunohistological study of involucrin expression in Darier's disease skin. *J Cut Pathol.* 35, 635-640.
- Katugampola R.P. & Finaly A.Y. (2006). Oral retinoid therapy for disorders of keratinisation: single-centre retrospective 25 years' experience on 23 patients. *Br J Dermatol.* 154, 267-276.
- Kawahira K. (1999). Immunohistochemical staining of proliferating cell nuclear antigen (PCNA) in malignant and non-malignant skin diseases. *Arch Dermatol Res.* 291, 413-418.

- Kawashima J., Akiyama M., Takizawa Y., Takahishi S., Matsuo I. & Shimizu H. (2005). Structural, enzymatic and molecular studies in a series of nonbullous congenital ichthyosiform erythroderma patients. *Clin Exp Dermatol.* 30, 429-431.
- Kehrer-Sawakski H. (2007). What a difference copy number variation makes. *Bioessays.* 29(4), 311-313.
- Kelsell D.P. & Stevens H.P. (1999). The palmoplantar keratodermas: much more than palms and soles. *Mol Med Today.* 5(3), 107-113.
- Kelsell D.P., Wilgoss A.L., Richard G., Stevens H.P., Munro C.S. & Leigh I.M. (2000). Connexin mutations associated with palmoplantar keratoderma and profound deafness in a single family. *Eur J Hum Genet.* 8, 141-144.
- Kelsell D.P., Dunlop J. & Hodgins M.B. (2001). Human diseases: clues to cracking the connexin code? *Trends Cell Biol.* 11, 2-6.
- Kelsell D.P., Dunlop J., Stevens H.P., Lench N.J., Liang J.N., Parry G., Mueller R.F. & Leigh I.M. (1997). Connexin 26 mutations in hereditary non-syndromic sensorineural deafness. *Nature.* 387, 80-83.
- Kim S., Wong P. & Coulombe P.A. (2006). A keratin cytoskeleton protein regulates protein synthesis and epithelial cell growth. *Nature.* 441 (7091), 362-365.
- Kim W.O., Kil H.K., Yoon D.M. & Cho M.J. (2003). Treatment of compensatory gustatory hyperhidrosis with topical glycopyrrolate. *Yonsei Med J.* 44, 579-582.
- Kimonis V., DiGiovanna J.J., Yang J.M., Doyle S.Z., Bale S.J. & Compton J.G. (1994). A mutation in the V1 end domain of keratin 1 in non-epidermolytic palmar-plantar keratoderma. *J Invest Dermatol.* 103(6), 764-769.
- Kimyai-Asadi A., Kotcher L.B. & Jih M.H. (2002). The molecular basis of hereditary palmoplantar keratodermas. *J Am Acad Dermatol.* 47, 327-343.
- King T.J. & Lampe P.D. (2005). Temporal regulation of connexin phosphorylation in embryonic and adult tissues. *Biochim Biophys Acta.* 1719, 24-35.
- Kljuic A., Bazzi H., Sundberg J., Martinex-Mir A., O'Shaughnessy R., Mahoney M., Levy M., Montagutelli X., Ehmadi W. & Aita V. (2003a). Desmoglein 4 in hair follicle differentiation and epidermal adhesion: evidence from inherited hypotrichosis and acquired pemphigus vulgaris. *Cell.* 113, 249-260.
- Kljuic A., Gilead L., Martinz-Mir A., Frank J., Christiano A.M. & Zlotogroski A. (2003b). A nonsense mutation in the desmoglein 1 gene underlies striate keratoderma. A nonsense mutation in the desmoglein 1 gene underlies striate keratoderma. *Exp Dermatol.* 12, 523-527.

Knapp A.C., Franke W.W., Heid H., Hatzfeld M., Jorcano J.L. & Moll R. (1986). Cytokeratin no.9, an epidermal type I keratin characteristic of a special programme of keratinocyte differentiation displaying body site specificity. *J Cell Biol.* 103, 657-667.

Koch P.J., de Viragh P.A., Scharer E., Bundman D., Longley M.A., Bickenbach J., Kawachi Y., Suga Y., Zhou Z., Huber M., Hohl D., Kartasova T., Jarnik M., Steven A.C. & Roop D.R. (2000). Lessons from loricrin-deficient mice. Compensatory mechanisms maintaining skin barrier function in the absence of a major cornified envelope protein. *J Cell Biol.* 151(2), 389-400.

Kopan R., Traska G. & Fuchs E. (1987). Retinoids as important regulators of terminal differentiation: Examining keratin expression in individual epidermal cells at various stages of keratinisation. *J Cell Biol.* 105, 427-440.

Kopan R. & Fuchs E. (1989). The use of retinoic acid to probe the relation between hyperproliferation-associated keratins and cell proliferation in normal and malignant epidermal cells. *J Cell Biol.* 109, 295-307.

Korge B.P., Ishida-Yamamoto A., Punter C., Dopping-Hepenstal P.J.C., Iizuka H., Stephenson A., Eady R.A.J. & Munro C.S. (1997). Loricrin mutation in Vohwinkel's Keratoderma is unique to the variant with ichthyosis. *J Invest Dermatol.* 109(4), 604-610.

Kouklis P.D., Hutton E. & Fuchs E. (1995). Making a connection: direct binding between keratin intermediate filament and desmosomal proteins. *J Cell Biol.* 127, 1049-1060.

Krawczyk W.S. (1971). A pattern of epidermal cell migration during wound healing. *J Cell Biol.* 49, 247-263.

Kretz M., Euwens C., Hombach S., Eckardt D., Teubner B., Traub O., Willecke K. & Ott T. (2003). Altered connexin expression and wound healing in the epidermis of connexin-deficient mice. *J Cell Sci.* 116, 3442-3452.

Kreuger J.G. (2002). The immunologic basis for the treatment of psoriasis with new biologic agents. *J Am Acad Dermatol.* 46, 1-23.

Ku N.O., Soetikno R.M. & Omary M.B. (2003a). Keratin mutation in transgenic mice predisposes to Fas but not TNF-induced apoptosis and massive liver injury. *Hepatology.* 37(5), 1006-1014.

Ku N.O., Darling J.M., Krams S.M., Esquivel C.O., Keeffe E.B., Sibley R.K., Lee Y.M., Wright T.L. & Omary M.B. (2003b). Keratin 8 and 18 mutations are risk factors for developing liver disease of multiple etiologies. *Proc Natl Acad Sci USA.* 100(10), 6063-6068.

- Kuechle M.K., Predd H.M., Fleckman P., Dale B.A. & Presland R.B. (2001). Caspase-14, a keratinocytes specific caspase: mRNA splice variants and expression pattern in embryonic and adult mouse. *Cell Death Differ.* 8, 868-870.
- Kuechle M.K., Presland R.B., Lewis S.P., Fleckman P. & Dale B.A. (2000). Inducible expression of filaggrin increases keratinocyte susceptibility to apoptotic cell death. *Cell Death Differ.* 7, 566-573.
- Kunz M., Ibrahim S.M., Koczan D., Scheid S., Thiesen H.J. & Groos G. (2004). DNA microarray technology and its applications in dermatology. *Exp Dermatol.* 13, 593-606.
- Kurokawa I., Nishijima S., Suzuki K., Kusukoto K., Sensaki H., Shikata N. & Tsubura A. (2002). Cytokeratin expression in pilonidal sinus. *Br J Dermatol.* 146(3), 409-413.
- Kurzen H., Berger H., Jager C., Hartschuh W., Naher H., Gratchev A., Goerdts S. & Deichmann M. (2004). Phenotypical and molecular profiling of the extraneuronal cholinergic system of the skin. *J Invest Dermatol.* 123, 937-949.
- Kuster W., Zehender D., Mensing H., Hennies H.C. & Reis A. (1995). Vörner keratosis palmoplantaris difusa: clinical, formal genetic and molecular biology studies of 22 families. *Hautarzt.* 46, 705-710.
- Laass M.W., Hennies H.C., Preis S., Stevens H.P., Jung M., Leigh I.M., Wienker T.F. & Reis A. (1997). Localisation of a gene for Papillon-Lefèvre syndrome to chromosome 11q14-q21 by homozygosity mapping. *Hum Genet.* 101, 376-382.
- Labarthe M.P., Bosco D., Saurat J.H., Meda P. & Salomon D. (1998). Upregulation of connexin 26 between keratinocytes of psoriatic lesions. *J Invest Dermatol.* 111, 72-76.
- Lai-Cheong J.E., Arita K. & McGrath J.A. (2007). Genetic diseases of junctions. *J Invest Dermatol.* 127, 2713-2725.
- Lamartine J., Munhoz Essenfolder G., Kibar Z., Lanneluc I., Callouet E., Laoudj D., Lemaitre G., Hand C., Hayflick S.J., Zonana J., Antonarakis S., Radhakrishna U., Kelsell D.P., Christianson A.L., Pitaval A., Der Kaloustian V., Fraser C., Blanchet-Bardon C., Rouleau G.A. & Waksman G. (2000). Mutations in GJB6 cause hidrotic ectodermal dysplasia. *Nat Genet.* 26, 142-144.
- Lampe P.D. & Lau A.F. (2004). The effects of connexin phosphorylation on gap junctional communication. *Int J Biochem Cell Biol.* 36, 1171-1186.
- Lane E.B. & McLean W.H.I. (2004). Keratins and skin disorders. *J Pathol.* 204, 355-366.

- Lane E.B., Rugg E.L., Navasaria H., Leigh I.M., Heagerty A.H.M., Ishida-Yamamoto A. & Eady R.A.J. (1992). A mutation in the conserved helix terminating peptide of keratin 5 in hereditary skin blistering. *Nature*. 356, 244-246.
- Lane E.B. (1993). Keratins. In: Royce PM, Steinmann B (eds). *Connective tissue and its heritable disorders molecular*. New York: Genetic and Medical Aspects Wiley-Liss Inc.
- Lane E.B., Wilson C., Hughes B.R. & Leigh I.M. (1991). Stem cells in hair follicles: cytoskeletal studies. *Ann NY Acad Sci*. 642, 197-231.
- Langbein L., Heid H.W., Moll I. & Franke W.W. (1993). Molecular characterization of the body site specific human epidermal cytokeratin 9; cDNA cloning, amino acid sequence, and tissue specificity of gene expression. *Differ*. 55, 57-71.
- Laporte M., Galand P., Fokan D., de Graef C. & Heenen M. (2000). Apoptosis in established and healing psoriasis. *Dermatology*. 200, 314-316.
- Leachman S.A., Kaspar R.L., Fleckman P., Florell S.R., Smith F.J.D., McLean W.H.I., Lunny D.P., Milstone L.M., van Steensal M.A.M., Munro C.S., O'Toole E.A., Celebi J.T., Kansky A. & Lane E.B. (2005). Clinical and pathological features of pachyonychia congenita. *J Invest Dermatol Symp Proc*. 10(1), 3-17.
- Leachman S.A., Hickerson R.P., Hull P.R., Smith F.J.D., Milstone L.M., Lane A.B., Bale S.J., Roop D.R., McLean W.H.I. & Kaspar R.L. (2008). Therapeutic siRNAs for dominant genetic skin disorders including pachyonychia congenita. *J Dermatol Sci*. 51, 151-157.
- Lebwohl M. (1999). The role of salicylic acid in the treatment of psoriasis. *Int J Dermatol*. 38, 16-24.
- Lee J.H., Kwang-Sung A., Lee C.H., Youn S.J., Kim J.W., Lee D.Y., Lee E.S., Steinert P.M. & Yang J.M. (2003). Keratin 9 gene mutations in five Korean families with epidermolytic palmoplantar keratoderma. *Exp Dermatol*. 12(6), 876-881.
- Leidy N.K., Revicki D.A. & Genesté B. (1999). Recommendations for evaluating the validity of quality of life claims for labelling and promotion. *Value Health* 2, 113-127.
- Leigh I.M., Navasaria H., Purkis P.E. & McKay I. (1991). Clinical practice and biological effects of keratinocyte grafting. *Ann Acad Med Singapore*. 20, 549-555.
- Leigh I.M., Purkis P.E., Whitehead P. & Lane E.B. (1993). Monospecific monoclonal antibodies to keratin 1 carboxyterminal (synthetic peptide) and to keratin 10 as markers of epithelial differentiation. *Br J Dermatol*. 129(2), 110-119.

- Leigh I.M., Navsaria H., Purkis P.E., McKay I.A., Bowden P.E. & Riddle P.N. (1995). Keratins (K16 and K17) as markers of keratinocyte hyperproliferation in psoriasis *in vivo* and *in vitro*. *Br J Dermatol.* 133(4), 501-511.
- Leonard N.J., Krol A.L., Bleoo S. & Somerville M.J. (2005). Sensorineural hearing loss, striate palmoplantar hyperkeratosis, and knuckle pads in a patient with a novel connexion 26 (GJB2) mutation. *J Med Genet.* 42, e2.
- Lesnik R.H., Mezick J.A., Capetola R.J. & Kligman L.H. (1989). Topical all-trans retinoic acid prevents corticosteroid-induced skin atrophy without abrogating the anti-inflammatory effect. *J Am Acad Dermatol.* 21, 186-190.
- Leung C.L., Green K.J. & Liem R.K. (2002). Plakins: a family of versatile cytolinker proteins. *Trends Cell Biol.* 12(1), 37-45.
- Levin A.A., Sturzenbecker L.J., Kazmer S., Bosakowski T., Huselton C., Allenby G., Speck J., Kratzeisen C., Rosenberger M., Lovey A. & Grippo J.F. (1992). 9-*cis* retinoic acid stereoisomer binds and activates the nuclear receptor RXR alpha. *Nature.* 355, 359-361.
- Lewin A.S., Glazer P.M. & Milstone L.M. (2005). Gene therapy for autosomal dominant disorders of keratin. *J Invest Dermatol Symp Proc.* 10(1), 47-61.
- Liao H., Sayers J.M., Wilson N.J., Irvine A.D., Mellerio J.E., Baselga E., Bayliss S.J., Uliana V., Fimiani M., Lane E.B., McLean W.H.I., Leachman S.A. & Smith F.J.D. (2007). A spectrum of mutations in keratins K6a, K16 and K17 causing pachyonychia congenita. *J Dermatol Sci.* 48(3), 199-205.
- Lin M.T., Levy M.L., Bowden P.E., Magro C., Baden L., Baden H.P. & Roop D.R. (1999). Identification of sporadic mutations in the helix initiation motif of keratin 6 in two pachyonychia congenita patients: Further evidence for a mutational hot spot. *Exp Dermatol.* 8, 115-119.
- Lin A.N. & Nakatsui T. (1998). Salicylic acid revisited. *Int J Dermatol.* 37, 335-342.
- Lippens S., Denecker G., Ovaere P., Vandenabeele P. & Declercq W. (2005). Death penalty for keratinocytes: apoptosis versus cornification. *Cell Death Differ.* 12 (S2), 1497-1508.
- Lippens S., Kockx M., Knaepen M., Mortier L., Polakowska R. & Verheyen A. (2000). Epidermal differentiation does not involve the pro-apoptotic executioner caspases, but is associated with caspase-14 induction and processing. *Cell Death Differ.* 7, 1218-1224.
- Liu X.Z., Xia J.X., Xu L.R., Pandya A., Liang C.Y., Blanton S.H., Brown S.D.M., Steel K.P. & Nance W.E. (2000). Mutations in connexion 31 underlie recessive as well as dominant non-syndromic hearing loss. *Hum Mol Genet.* 9, 63-67.

- Lloyd C., Yu Q.C., Cheng J., Turksen K., Degenstein L., Hutton E. & Fuchs E. (1995). The basal keratin network of stratified squamous epithelia: defining K16 function in the absence of K14. *J Cell Biol.* 129, 1329-1344.
- Loden M., Bostron P. & Kneezke M.(1995). Distribution and keratolytic effect of salicylic acid and urea in human skin. *Skin Pharmacol.* 8, 173-8.
- Lucotte G. & Dieterlen F. (2005). The 35delG mutation in connexin 26 gene (GJB2) associated with congenital deafness: European carrier frequencies and evidence for its origin in ancient Greece. *Genet Test.* 9, 20-25.
- Lucke T., Choudhry R., Thom R., Selmer I.S., Burden A.D. & Hodgins M.B. (1999). Upregulation of connexin 26 is a feature of keratinocyte differentiation in hyperproliferative epidermis, vaginal epithelium, and buccal epithelium. *J Invest Dermatol.* 112, 354-361.
- Lucker G.P.H., Van de Kerkhof P.C.M. & Steiljen P.M. (1994). The hereditary palmoplantar keratoses: an updated review and classification. *Br J Dermatol.* 131, 1-14.
- Lucker G.P. & Stiejlen P.M. (1995). Pachyonychia congenita tarda. *Clin Exp Dermatol.* 20, 226-229.
- Luzzi V., Mahadevappa M., Raja R., Warrington J.A. & Watson M.A. (2003). Accurate and reproducible gene expression profiles from laser-capture microdissection, transcript amplification, and high density oligonucleotide microarray analysis. *J Mol Diagn.* 5, 9-14.
- Ma L., Xu J., Coulombe P.A. & Wirtz D.(1999). Keratin filament suspensions show unique micromechanical properties. *J Biol Chem.* 274, 19145-19151.
- Macari F., Landau M., Cousin P., Mevorah B., Brenner S., Panizzon R., Schorderet D.F., Hohl D. & Huber M. (2000). Mutation in the gene for connexin 30.3 in a family with erythrokeratoderma variabilis. *Am J Hum Genet.* 67, 1296-1301.
- Maestrini E., Korge B.P., Ocana-Sierra J., Calzolari E., Cambiagli S., Scudder P.M., Hovnanian A., Monaco A.P. & Munro C.S. (1999). A missense mutation in connexin 26, D66H, causes mutilating keratoderma with sensorineural deafness (Vohwinkel's syndrome) in three unrelated families. *Hum Mol Genet.* 8(7), 1237-1243.
- Maestrini E., Monaco A.P., McGrath J.A., Ishida-Yamamoto A., Camisa C., Hovnanian A., Weeks D.A., Lathrop M., Uitto J. & Christiano A.M. (1996). A molecular defect in loricrin, the major component of the cornified cell envelope, underlies Vohwinkel's syndrome. *Nat Genet.* 13, 70-77.
- Magin T.M., Vijayaraj P. & Leube R.E. (2007). Structural and regulatory functions of keratins. *Exp Cell Res.* 313, 2021-2032.

- Magin T.M., Reichelt J. & Hatzfeld M. (2004). Emerging functions: diseases and animal models reshape our view of the cytoskeleton. *Exp Cell Res.* 301, 91-102.
- Magro C.M., Baden L.A., Crowson A.N., Bowden P.E. & Baden H.P. (1997). A novel nonepidermolytic palmoplantar keratoderma: A clinical and histopathologic study of six cases. *J Am Acad Dermatol.* 37, 27-33.
- Man Y.K., Trollove C., Tattersall D., Thomas A.C., Papakonstantinopoulou A., Patel D., Scott C., Chong J., Jagger D.J., O'Toole E.A., Navsaria H., Curtis M.A. & Kelsell D.P. (2007). A deafness-associated mutant human connexin 26 improves the epithelial barrier *in vitro*. *J Membr Biol.* 218, 29-37.
- Manabe M., Sanchez M., Sun T.T. & Dale B.A. (1991). Interaction of filaggrin with keratin filaments during advanced stages of normal human epidermal differentiation and in ichthyosis vulgaris. *Differentiation.* 48, 43-50.
- Mann P.R. & Haye K.R. (1970). An electron microscope study on the acantholytic and dyskeratotic processes in Darier's disease. *Br J Dermatol.* 82, 561-566.
- Mao-Qiang M., Elias P.M. & Feingold K.R. (1993). Fatty acids are required for epidermal permeability barrier function. *J Clin Invest.* 92, 791-798.
- Mao-Qiang M., Fowler A.J., Schmuth M., Lau P., Chang S. & Brown B.E. (2004). Peroxisome-proliferator-activated receptor (PPAR)-gamma activation stimulates keratinocyte differentiation. *J Invest Dermatol.* 123, 305-312.
- Marikovsky M., Breuing K., Liu P.Y., Eriksson E., Higashiyama S., Farber P., Abraham J. & Klagsbrun M. (1993). Appearance of heparin-binding EGF-like growth factor in wound fluid as a response to injury. *Proc Natl Acad Sci USA.* 90, 3889-3893.
- Marks R., Davies M. & Cattell. (1975). An explanation for the keratolytic effect of salicylic acid. *J Invest Dermatol.* 64, 283.
- Martin P. (1997). Wound healing – aiming for perfect skin regeneration. *Science.* 276, 75-81.
- Martin L., Toutain A., Guillen C., Haftek M., Machet M.C., Toledano C., Arbeille B., Lorette G., Rötig A. & Vaillant L. (2000). Inherited palmoplantar keratoderma and sensorineural deafness associated with A7445G point mutation in the mitochondrial genome. *Br J Dermatol.* 143, 876-883.
- Maruoka Y., Harada H., Mitsuyasu T., Seta Y., Kurukawa H., Kajiyama M. & Toyoshima K. (1997). Keratinocytes become terminally differentiated in a process involving programmed cell death. *Biochem Biophys Res Commun.* 238, 866-890.



- Masgrau-Peya E., Salomon D., Saurat J.H. & Meda P. (1997). *In vivo* modulation of connexins 43 and 26 of human epidermis by topical retinoic acid treatment. *J Histochem Cytochem.* 45, 1207-1215.
- Matoltsy A.G., Matoltsy M.N. & Cliffler P.J. (1983). Characterization of keratin polypeptides of normal and psoriatic horny cells. *J Invest Dermatol.* 80, 185-188.
- Matsumoto K., Muto M., Sekin S., Saida T., Horiuchi N., Takahishi H., Ishida-Yamamoto A. & Iizuka H. (2001). Loricrin keratoderma: a cause of congenital ichthyosiform erythroderma and collodion baby. *Br J Dermatol.* 145, 657-660.
- May G.M., DeWeese J.A. & Rob C.G. (1969). Changes in sexual function following operation on abdominal aorta. *Surgery* 65, 41-47.
- Mazzalupo S., Wong P., Martin P. & Coulombe P.A. (2003). Role for keratins 6 and 17 during wound closure in embryonic mouse skin. *Dev Dyn.* 226, 356-365.
- McGibbon D.H. & Watson R.T. (1977). Vohwinkel's syndrome and deafness. *J Laryngol Otol.* 91, 853-857.
- McGowan K.M. & Coulombe P.A. (1998). Onset of keratin 17 expression coincides with the definition of major epithelial lineages during mouse skin development. *J Cell Biol.* 143, 469-486.
- McGowan K.M. & Coulombe P.A. (2000). Keratin 17 expression in the hard epithelial context of the hair and nail, and its relevance for the pachyonychia congenita phenotype. *J Invest Dermatol.* 114(6), 1101-1107.
- McGowan K.M., Tong X., Colucci-Guyon E., Langa F., Babinet C. & Coulombe P.A. (2002). K17 null mice exhibit age- and strain-dependent alopecia. *Genes Dev.* 16, 1412-1422.
- McGrath J.A., McMillan J.R., Shemanko C.S., Runswick K.M., Leigh I.M., Lane E.B., Garrod D.R. & Eady R.A. (1997). Mutations in the plakophilin 1 gene result in ectodermal dysplasia/skin fragility syndrome. *Nat Genet.* 17(2), 240-244.
- McGrath J.A., Ishida-Yamamoto A., Tidman M.J., Heagerty A.H., Schofield O.M. & Eady R.A. (1992). Epidermolysis bullosa simplex (Dowling-Meara): a clinicopathological review. *Br J Dermatol.* 126, 421-430.
- McGrath J.A. (1999). Hereditary diseases of desmosomes. *J Dermatol Sci.* 20(2), 85-91.
- McKee PH (1996). In: *Pathology of the Skin*. 2<sup>nd</sup> edn. London, Mosby-Wolfe.
- McKoy G., Protonotarios N., Crosby A., Tsatsopoulou A., Anastasakis A., Coonar A., Norman M., Baboonian C., Jeffery S. & McKenna W.J. (2000). Identification of

a deletion in plakoglobin in arrhythmogenic right ventricular cardiomyopathy with palmoplantar keratoderma and woolly hair (Naxos disease). *Lancet*. 355, 2119-2124

McLean W.H.I., Rugg E.L., Lunny D.P., Morley S.M., Lane E.B., Swensson O., Dopping-Hepenstal P.J.C., Griffiths W.A.D., Eady R.A.J., Higgins C., Navsaria H.A., Leigh I.M., Strachan T., Kunkeler L. & Munro C.S. (1995). Keratin 16 and keratin 17 mutations cause pachyonychia congenita. *Nat Genet*. 9, 273-276.

McMichael A.J., Griffiths C.E.M., Talwar H.S., Finkel L.J., Rafal E.S., Hamilton T.A. & Voorhees J.J. (1996). Concurrent application of tretinoin (retinoic acid) partially protects against corticosteroid-induced epidermal atrophy. *Br J Dermatol*. 135, 60-64.

Mehrel T., Hohl D., Rothnagel J.A., Longley M.A., Bundman D., Cheng C., Lichti U., Bisher M.E., Steven A.C., Steinert P.M., Yuspa S.H. & Roop D.R. (1990). Identification of a major keratinocytes cell envelope protein, loricrin. *Cell*. 61, 1103-1112.

Menon G.K., Feingold K.R., Mao-Qiang M., Schauder M. & Elias P.M. (1992a). Structural basis for the barrier abnormality following inhibition of HMG CoA reductase in murine epidermis. *J Invest Dermatol*. 98, 209-219.

Menon G.K., Feingold K.R. & Elias P.M. (1992b). Lamellar body secretory response to barrier disruption. *J Invest Dermatol*. 98, 279-289.

Merritt A.J., Berika M.Y., Zhai W., Kirk S.E., Ji B., Hardman M.J. & Garrod D.R. (2002). Suprabasal desmoglein 3 expression in the epidermis of transgenic mice results in hyperproliferation and abnormal differentiation. *Mol Cell Biol*. 22(16), 5846-5858.

Meşe G., Richard G. & White T.W. (2006). Gap junctions: basic structure and function. *J Invest Dermatol*. 127, 2516-2524.

Meyer C.G., Amedofu G.K., Brandner J.M., Pohland D., Timman C. & Horstmann R.D. (2002). Selection for deafness? *Nat Med*. 8, 1332-1333.

Milingou M., Wood P., Masouye I., McLean W.H. & Borradori L. (2006). Focal palmoplantar keratoderma caused by an autosomal dominant inherited mutation in the desmoglein 1 gene. *Dermatol*. 212, 117-122.

Milstone L.M., Fleckman P., Leachman S.A., Leigh I.M., Paller A.S., van Steensel M.A.M. & Swartling C. (2005). Treatment of pachyonychia congenita. *J Invest Dermatol Symp Proc*. 10(1), 18-20.

Mitra R.S., Wrone-Smith T., Simonian P., Foreman K.E., Nunez G. & Nickoloff B.J. (1997). Apoptosis in keratinocytes is not dependent on induction of differentiation. *La Invest*. 76, 99-107.

- Moll R., Divo M. & Langbein L. (2008). The human keratins: biology and pathology. *Histochem Cell Biol.* 129, 705-733.
- Moll I., Heid H.W., Franke W.W. & Moll R. (1987). Distribution of a special subset of keratinocytes characterized by the expression of cytokeratin 9 in adult and fetal human epidermis of various body sites. *Differ.* 33, 254-265.
- Moll I., Schönfeld M. & Jung E.G. (1995). Applikation von Keratinozyten in der Therapie von Ulcera crurum. *Hautarzt.* 46, 548-552.
- Moll I., Houdek P., Schmidt H. & Moll R. (1998). Characterization of epidermal wound healing in a human skin organ culture model: Acceleration by transplanted keratinocytes. *J Invest Dermatol.* 111, 251-258.
- Moll R., Franke W.W., Schiller D.L., Geiger B. & Krepler R. (1982). The catalog of human cytokeratins: patterns of expression in normal epithelia, tumors and cultured cells. *Cell.* 31(1), 11-24.
- Mori R., Power K.T., Wang C.M., Martin P. & Becker D.L. (2006). Acute downregulation of connexin43 at wound sites leads to a reduced inflammatory response, enhanced keratinocyte proliferation and wound fibroblast migration. *J Cell Sci.* 119, 5193-5203.
- Morley S.M., White M.I., Rogers M., Wasserman D., Ratajczak P., McLean W.H. & Richard G. (2005). A new, recurrent mutation of GJB3 (Cx31) in erythrokeratoderma variabilis. *Br J Dermatol.* 123, 1143-1148.
- Morley S.M. & Lane E.B. (1994). The keratinocyte cytoskeleton. In: Leigh IM, Lane EB, Watt FM (eds). *The Keratinocyte Handbook*. Cambridge: Cambridge University Press.
- Morales-Ducret C.R., Van de Rijn M., LeBrun D.P. & Smoller B.R. (1995). Bcl-2 expression in primary malignancies of the skin. *Arch Dermatol.* 131, 909-912.
- Munro C.S. (2001). Pachyonychia congenita: Mutations and clinical presentations. *Br J Dermatol.* 144, 929-930.
- Munro C.S., Carter S., Bryce S., Hall M., Rees J.L., Kunkeler L., Stephenson A. & Strachan T. (1994). A gene for pachyonychia congenita is closely linked to the keratin gene cluster on 17q12-q21. *J Med Genet.* 31, 675-678.
- Nagashima M. (1977). Palmoplantar keratoses. *Clin Genet.* 9, 23-27.
- Naumann M., Hofmann U., Bergmann I., Hamm H., Toyka K.V. & Reiners K. (1998). Focal hyperhidrosis: effective treatment with intracutaneous botulinum toxin. *Arch Dermatol.* 134, 301-304.

- Naumann M. & Lowe N.J. (2001). Botulinum toxin type A in treatment of bilateral primary axillary hyperhidrosis: randomised, parallel group, double blind, placebo controlled trial. *BMJ*. 323, 1-4.
- Navsaria H.A., Swensson O., Ratnavel R.C., Shamsher M., McLean W.H., Lane E.B., Griffiths D., Eady R.A. & Leigh I.M. (1995). Ultrastructural changes resulting from keratin-9 gene mutations in two families with epidermolytic palmoplantar keratoderma. *J Invest Dermatol*. 104(3), 425-429.
- Nemes Z. & Steinert P.M. (1999). Bricks and mortar of the epidermal barrier. *Exp Mol Med*. 31(1), 5-19.
- Nemes Z., Marekov L.N., Fesus L. & Steinert P.M. (1999). A novel function of transglutaminase 1: attachment of long-chain  $\omega$ -hydroxyceramides to involucrin by ester bond formation. *Proc Natl Acad Sci USA*. 96, 8402-8407.
- Neumann I. (1898). Ueber keratoma hereditarum. *Arch Derm Syph*. 42, 163-174.
- Ng D.C., Shafae S., Lee D. & Bikle D.D. (2000). Requirement of an AP-1 site in the calcium response region of the involucrin promoter. *J Biol Chem*. 275, 24080-24088.
- Niemi K.M., Viranen I., Kanerva L. & Muttillainen M. (1990). Altered keratin expression in ichthyosis hystrix Curth-Macklin. *J Dermatol Res*. 282, 227-233.
- Niles H.D. & Klump M. (1939). Mal de Meleda: review of the literature and report of four cases. *Arch Derm Syph*. 39, 409-421.
- Nockemann P.E. (1961). Erbliche Hornhautverdickung mit Schnürfurchen an Fingern und Zehen mit Innenohrschwerhörigkeit. *Med Welt*. 37, 1894-1900.
- Nollet F., Kools P. & van Roy F. (2000). Phylogenetic analysis of the cadherin superfamily allows identification of six major subfamilies besides solitary members. *J Mol Biol*. 299, 551-572.
- Nomura I., Gao B., Boguniewicz M., Darst M.A., Travers J.B. & Leung D.Y. (2003). Distinct patterns of gene expression in the skin lesions of atopic dermatitis and psoriasis: a gene microarray analysis. *J Allergy Clin Immunol*. 112, 1195-1202.
- Norgett E.E., Lucke T.W., Bowers B., Munro C.S., Leigh I.M. & Kelsell D.P. (2006). Early death from cardiomyopathy in a family with autosomal dominant striate palmoplantar keratoderma and woolly hair associated with a novel insertion mutation in desmoplakin. *J Invest Dermatol*. 126, 1651-1654.
- Norgett E.E., Hatsell S.J., Carvajal-Huerta L., Ruiz Cabezas J.C., Common J., Purkis P.E., Whittock N., Leigh I.M., Stevens H.P. & Kelsell D.P. (2000). Recessive mutation in desmoplakin disrupts desmoplakin-intermediate filament interactions and

causes dilated cardiomyopathy, woolly hair and keratoderma. *Hum Mol Genet.* 9, 2761-2766.

Norris A.W., Cheng L., Giguere V., Rosenberger M. & Li E. (1994). Measurement of subnanomolar retinoic acid binding affinities for cellular retinoic acid binding proteins by fluorometric titration. *Biochim Biophys Acta.* 1209, 10-18.

O'Driscoll J., Muston G.C., McGrath J.A., Lam H.M., Ashworth J. & Christiano A.M. (2002). A recurrent mutation in the loricrin gene underlies the ichthyotic variant of Vohwinkel syndrome. *Clin Exp Dermatol.* 27, 243-246.

Ocaña-Sierra J., Blesa G. & Montero E. (1975). Syndrome de Vohwinkel. *Ann Dermatol Syph.* 102, 41-45.

Odderson I.R. (1998). Axillary hyperhidrosis: treatment with botulinum toxin A. *Arch Phys Med Rehabil.* 79, 350-352.

Odland G. & Ross R. (1968). Human wound repair I. Epidermal regeneration. *J Cell Biol.* 39, 135-151.

Oehm A., Behrmann I., Falk W., Pawlita M., Maier G., Klas C., Li-Weber M., Richards S., Dhein J., Trauth B.C., Ponsting H. & Krammer P.H. (1992). Purification and molecular cloning of the APO-I cell surface antigen, a member of the tumor necrosis factor/nerve growth factor receptor superfamily. *J Biol Chem.* 267, 10709-10715.

Oestreicher J.L., Walters I.B., Kikuchi T., Gilleaudeau P., Surette J., Schwertschlag U., Dorner A.J., Krueger J.G. & Trepicchio W.L. (2001). Molecular classification of psoriasis disease-associated genes through pharmacogenomic expression profiling. *Pharmacogenomics J.* 1, 272-287.

Oh S.W., Kim M.Y., Lee J.S. & Kim S.C. (2006). Keratin 17 mutation in pachyonychia congenital type 2 patients with early onset steatocystoma multiplex and Hutchinson-like tooth deformity. *J Dermatol.* 3, 161-164.

Oliver L. & Vallette F.M. (2005). The role of caspases in cell death and differentiation. *Drugs Resist Update.* 8, 163-170.

Omary M.B., Coulombe P.A. & McLean W.H.I. (2004). Intermediate filament proteins and their associated diseases. *N Engl J Med.* 351, 2087-2100.

Orfanos C.E., Zouboulis C.C., Almond-Roesler B. & Geilen C.C. (1997). Current use and future potential role of retinoids in dermatology. *Drugs.* 53, 358-388.

Paladini R.D., Takahachi K., Bravo N.S. & Coulombe P.A. (1996). Onset of re-epithelialization after skin injury correlates with a re-organization of keratin filaments in wound edge keratinocytes defining a potential role for keratin 16. *J Cell Biol.* 132, 381-397.

- Pallari H.M. & Eriksson J.E. (2006). Intermediate filaments as signalling platforms. *Sci STKE*. 2006, pe53.
- Paller A.S., Moore J.A. & Scher R. (1991). Pachyonychia congenita tarda. A late-onset form of pachyonychia congenita. *Arch Dermatol*. 127, 701-703.
- Palmer C.N., Irvine A.D., Terron-Kwiatkowski A., Zhao Y., Liao H., Lee S.P., Goudie D.R., Sandilands A., Campbell L.E., Smith F.J., O'Regan G.M., Cecil J.E., Bale S.J., Compton J.G., DiGiovanna J.J., Fleckman P., Lewis-Jones S., Arseculeratne G., Sergeant A., Munro C.S., El Houate B., McElreavey K., Halkjaer L.B., Bisgaard H., Mukhopadhyay S. & McLean W.H. (2006). Common loss-of-function variants of the epidermal barrier protein filaggrin are a major predisposing factor for atopic dermatitis. *Nat Genet*. 38(4), 441-446.
- Papillon M.N. & Lefèvre B. (1924). Deux cas de keratodermie palmaire et plantaire symetrique familiale (maladie de maleda) chez le frèreet la soeur. C'existence dans le des cas d'alteration. *Bull Soc Fr Dermatol Syphiligre*. 31, 81-84.
- Parmentier L., Steijlen P.M. & van Steensel M.A.M. (2008). Recessive palmoplantar keratodermas: a fertile biological hunting ground. *Arch Dermatol*. 144, 384-385.
- Parry D.A., Strelkov S.V., Burkhard P., Aebi U. & Hermann H. (2007). Towards a molecular description of intermediate filament structure and assembly. *Exp Cell Res*. 313 (10), 2204-2216.
- Patel G.K., Wilson C.H., Harding K.G., Finlay A.Y. & Bowden P.E. (2006). Numerous keratinocyte subtypes involved in wound re-epithelialization. *J Invest Dermatol*. 126, 497-502.
- Pearton D.J., Dale B.A. & Presland R.B. (2002). Functional analysis of the profilaggrin N-terminal peptide: Identification of domains that regulate nuclear and cytoplasmic distribution. *J Invest Dermatol*. 119, 661-669.
- Pena-Penabad C., Unamuno P.D., Garcia Silva J., Ludena M.D., Gonzalez Sarmiento R. & Perez-Arellano J.L. (1999). Altered expression of immunoreactive involucrin in lamellar ichthyosis. *Eur J Dermatol*. 9, 197-201.
- Peters B., Kirfel J., Bussow H., Vidal M. & Magin T.M. (2001). Complete cytolysis and neonatal lethality in keratin 5 knockout mice reveal its fundamental role in skin integrity and in epidermolysis bullosa simplex. *Mol Biol Cell*. 12, 1775-1789.
- Polakowska R.R., Piacentini M., Bartlett R., Goldsmith L.A. & Haaker A.R. (1994). Apoptosis in human skin development: morphogenesis, periderm, and stem cells. *Dev Dyn*. 199, 176-188.
- Porter R.M., Reichelt J., Lunny D.P., Magin T.M. & Lane E.B. (1998). The relationship between hyperproliferation and epidermal thickening in a mouse model for BCIE. *J Invest Dermatol*. 110, 951-957.

- Presland R.B., Haydock P.V., Fleckman P., Nirunsuksiri W. & Dale B.A. (1992). Characterization of the human epidermal profilaggrin gene. Genomic organization and identification of an S-100-like calcium binding domain at the amino terminus. *J Biol Chem.* 267(33), 23772-23781.
- Presland R.B., Kimball J.R., Kautsky M.B., Lewis S.P., Lo C.Y. & Dale B.A. (1997). Evidence for specific proteolytic cleavage of the N-terminal domain of human profilaggrin during epidermal differentiation. *J Invest Dermatol.* 108(2), 170-178.
- Presland R.B., Kuechle M.K., Lewis S.P., Fleckman P. & Dale B.A. (2001). Regulated expression of human filaggrin in keratinocytes results in cytoskeletal disruption, loss of cell-cell adhesion, and cell cycle arrest. *Exp Cell Res.* 270, 199-213.
- Presland R.B. & Dale B.A. (2000). Epithelial Structural Proteins of the Skin and Oral Cavity: Function in Health and Disease. *Crit Rev Oral Biol Med.* 11(4), 383-408.
- Protonotarios N., Tsatsopoulou A., Patsourakos P., Alexopoulos D., Gezerlis P., Simitsis S. & Scampardonis G. (1986). Cardiac abnormalities in familial palmoplantar keratosis. *Br Heart J.* 56, 321-326.
- Protonotarios N., Tsatsopoulou A. & Fontaine G. (2001). Naxos disease: keratoderma, scalp modifications, and cardiomyopathy. *J Am Acad Dermatol.* 44, 309-311.
- Purkis P.E., Steel J.B., MacKenzie I.C., Nathrath W.B., Leigh I.M. & Lane E.B. (1990). Antibody markers of basal cells in complex epithelia. *J Cell Sci.* 97, 39-50.
- Qin J.Z., Chaturvedi V., Denning M.F., Bacon P., Panella J. & Choubey D. (2002). Regulation of apoptosis by p53 in UV-irradiated human epidermis, psoriatic plaques and senescent keratinocytes. *Oncogene.* 21, 2991-3002.
- Qui C., Coutinho P., Frank S., Franke S., Law L., Martin P., Green C.R. & Becker D.L. (2003). Targeting connexin43 expression accelerates the rate of wound repair. *Curr Biol.* 13, 1697-1702.
- Raj D., Brash D.E. & Grossman D. (2006). Keratinocyte apoptosis in epidermal development and disease. *J Invest Dermatol.* 126, 243-257.
- Ratnavel R.C. & Griffiths W.A.D. (1997). The inherited palmoplantar keratodermas. *Br J Dermatol.* 137, 485-490.
- Raymond A.-A., Méchin M.-C., Nachat R., Toulza E., Tazi-Ahnin R., Serre G. & Simon M. (2007). Nine procaspases are expressed in normal human epidermis, but only caspase-14 is fully processed. *Br J Dermatol.* 156, 420-427.

- Reid F. M., Vernham G.A. & Jacobs H.T. (1994). A novel mitochondrial point mutation in a maternal pedigree with sensorineural deafness. *Hum Mutat.* 3, 243-247.
- Reis A., Hennies H.C., Langbein L., Digweed M., Mischke D., Drechsler M., Schrock E., Royer-Pokora B., Franke W.W., Sperling K. & Kuster W. (1994). Keratin 9 mutations in epidermolytic palmoplantar keratoderma (EPPK). *Nat Genet.* 6, 174-179.
- Reis A., Kuster W., Eckardt R. & Sperling K. (1992). Mapping of a gene for epidermolytic palmoplantar keratoderma to the region of acidic keratin gene cluster at 17q12-q21. *Hum Genet.* 90, 113-116.
- Rendl M., Ban J., Mrass P., Mayer C., Lengauer B., Eckhart L., Declerq W. & Tschachler E. (2002). Caspase-14 expression by epidermal keratinocytes is regulated by retinoids in a differentiation-associated manner. *J Invest Dermatol.* 119, 1150-1155.
- Resing K.A., Walsh K.A., Haugen-Scofield J. & Dale B.A. (1989). Identification of proteolytic cleavage sites in the conversion of profilaggrin to filaggrin in mammalian epidermis. *J Biol Chem.* 264, 1837-1845.
- Revel J.P. & Karnovsky M.J. (1967). Hexagonal array of subunits in intercellular junctions of the mouse heart and liver. *J Cell Biol.* 33, C7-C12.
- Rice R.H. & Green H. (1979). Presence in human epidermal cells of a soluble protein precursor of the cross-linked envelope: activation of the cross-linking by calcium ions. *Cell.* 11, 681.
- Richard G. (2000). Connexins: a connection with the skin. *Exp Dermatol.* 9, 77-96.
- Richard G., White T.W., Smith L.E., Bailey R.A., Compton J.G., Paul D.L. & Bale S.J. (1998a). Functional defects of Cx26 resulting from a heterozygous missense mutation in a family with dominant deaf-mutism and palmoplantar keratoderma. *Hum Genet.* 103, 393-399.
- Richard G., Brown N., Ishida-Yamamoto A. & Krol A. (2004). Expanding the phenotypic spectrum of Cx26 disorders: Bart-Pumphrey syndrome is caused by a novel missense mutation in GJB2. *J Invest Dermatol.* 123, 856-863.
- Richard G., Smith L.E., Bailey R.A., Itin P., Hohl D., Epstein E.H. Jr, DiGiovanna J.J., Compton J.G. & Bale S.J. (1998b). Mutations in the human connexin gene GJB3 cause erythrokeratoderma variabilis. *Nat Genet.* 20, 366-369.
- Richard G., Brown N., Smith L.E., Terrinoni A., Melino G., MacKie R.M., Bale S.J. & Uitto J. (2000). The spectrum of mutations in erythrokeratodermias – novel and de novo mutations in GJB3. *Hum Genet.* 106, 321-329.



Richard G., Brown N., Rouan F., Van der Schroeff J.G., Bijlsma E., Eichenfield L.F., Sybert V.P., Greer K.E., Hogan P., Campanelli C., Compton J.G., Bale S.J., DiGiovanna J.J. & Uitto J. (2003). Genetic heterogeneity in erythrokeratoderma variabilis: novel mutations in the connexin gene GJB4 (Cx30.3) and genotype-phenotype correlations. *J Invest Dermatol.* 120, 601-609.

Richard G., Korge B.P., Wright A.R., Mazzanti C., Harth W., Annicchiarico-Petruzzelli M., Compton J.G. & Bale S.J. (1995). Hailey-Hailey disease maps to a 5cM interval on chromosome 3q21-p24. *J Invest Dermatol.* 105, 357-360.

Rickman L., Simrak D., Stevens H.P., Hunt D.M., King I.A., Bryant S.P., Eady R.A., Leigh I.M., Arnemann J., Magee A.I., Kelsell D.P. & Buxton R.S. (1999). N-terminal deletion in a desmosomal cadherin causes the autosomal dominant skin disease striate palmoplantar keratoderma. *Hum Mol Genet.* 8(6), 971-976.

Rittié L., Varani J., Kang S., Voorhees J.J. & Fisher G.J. (2006). Retinoid-induced epidermal hyperplasia is mediated by epidermal growth factor receptor activation via specific induction of its ligands heparin-binding EGF and Amphiregulin in human skin in vivo. *J Invest Dermatol.* 126, 732-739.

Rivas M.V., Jarvis E.D., Morisaki S. (1997). Identification of aberrantly regulated genes in diseased skin using the cDNA differential display technique. *J Invest Dermatol.* 108, 188-194.

Roberts D.L., Marshall R. & Marks R. (1980). Detection of the action of salicylic acid on the normal stratum corneum. *Br J Dermatol.* 103, 191-196.

Robertson J.D. (1963). The occurrence of a subunit pattern in the unit membranes of club endings in mauthner cell synapses in goldfish brains. *J Cell Biol.* 19, 201-221.

Robertson D., Monaghan P., Clarke C. & Atherton A.J. (1992). An appraisal of low temperature embedding by progressive lowering of temperature into Lowicryl HM20 for immunocytochemical studies. *J Microsc.* 168 (Pt 1), 85-100.

Rodriguez-Villanueva J., Greenhalgh D., Wang X.J., Bundman D., Cho S., Delehedde M., Roop D. & McDonnell T.J. (1998). Human keratin-1.bcl-2 transgenic mice aberrantly express keratin 6, exhibit reduced sensitivity to keratinocyte cell death induction, and are susceptible to skin tumor formation. *Oncogene.* 16, 853-863.

Roos T.C., Jugert F.K., Merk H.F. & Bickers D.R. (1998). Retinoid metabolism in the skin. *Pharmacol Rev.* 50, 315-333.

Rosenthal D.S., Roop D.R., Huff C.A., Weiss J.S., Ellis C.N., Hamilton T., Voorhees J.J. & Yuspa S.H. (1990). Changes in photo-aged human skin following topical application of all-trans retinoic acid. *J Invest Dermatol.* 95, 510-515.

Rosenthal D.S., Griffiths C.E.M., Yuspa S.H., Roop D.R. & Voorhees J.J. (1992). Acute or chronic topical retinoic acid treatment of human skin in vivo alters the

expression of epidermal transglutaminases, loricrin, involucrin, filaggrin, and keratins 6 and 13 but not keratins 1, 10, and 14. *J Invest Dermatol.* 98, 343-350.

Rothnagel J.A., Dominey A.M., Dempsey L.D., Longley M.A., Greenhalgh D.A., Gagne T.A., Huber M., Frenk E., Hohl D. & Roop D.R. (1992). Mutations in the rod domains of keratins 1 and 10 in epidermolytic hyperkeratosis. *Science.* 257, 128-130.

Rouan F., White T.W., Brown N., Taylor A.M., Lucke T.W., Paul D.L., Munro C.S., Uitto J., Hodgins M.B. & Richard G. (2001). Trans-dominant inhibition of connexin-43 by mutant connexin-26: implications for dominant connexin disorders affecting epidermal differentiation. *J Cell Sci.* 114, 2105-2113.

Ruckert R., Asadullah K., Seifert M., Budagian V.M., Arnold R. & Trombotto C. (2000). Inhibition of keratinocyte apoptosis by IL-15: a new parameter in the pathogenesis of psoriasis? *J Immunol.* 165, 2240-2250.

Rugg E.L. (2008). Therapeutic interference: a step closer for pachyonychia congenital. *J Invest Dermatol.* 128, 7-8.

Runswick S.K., O'Hare M.J., Jones L., Streuli C.H. & Garrod D.R. (2001). Desmosomal adhesion regulates epithelial morphogenesis and cell positioning. *Nature Cell Biol.* 3, 823-830.

Ryther R.C., Flynt A.S., Phillips J.A. 3<sup>rd</sup> & Patton J.C. (2005). siRNA therapeutics: big potential from small RNAs. *Gene Ther.* 12, 5-11.

Sakahira H., Enari M. & Nagata S. (1998). Cleavage of CAD inhibitor in CAD activation and DNA degradation during apoptosis. *Nature.* 391, 96-99.

Salamon T. (1986). An attempt at classification of inherited disorders of keratinisation localized mainly, not exclusively on the palms and soles. *Dermatol Mantsschr.* 172, 601-605.

Salamon T., Berberovic L., Topic B. & Basic V. (1988). Mal de Meleda: data and remarks on a series. *G Ital Dermatol Venereol.* 123, 649-655.

Salomon D., Masgrau E., Vischer S., Ullrich S., Dupont E., Sappino P., Saurat J.H. & Meda P. (1994). Topography of mammalian connexins in human skin. *J Invest Dermatol.* 103, 240-247.

Salomon D., Saurat J.H. & Meda P. (1988). Cell-to-cell communication within intact human skin. *J Clin Invest.* 82, 248-254.

Sasaki K., Murakami T., Kawasaki M. & Takahashi M. (1987). The cell-cycle associated change of the Ki-67 reactive nuclear antigen expression. *J Cell Physiol.* 133, 579-584.

- Sawey M.J., Goldschmidt M.H., Risek B., Gilula N.B. & Lo C.W. (1996). Perturbation in connexin 43 and connexin 26 gap-junction expression in mouse skin hyperplasia and neoplasia. *Mol Carcinog.* 17, 49-61.
- Sayama K., Yonehara S., Watanabe Y. & Miki Y. (1994). Expression of Fas antigen on keratinocytes in vivo and induction of apoptosis in cultured keratinocytes. *J Invest Dermatol.* 103, 330-334.
- Schwartz A., Bhardwaj R., Aragane Y., Mahnke K., Riemann H., Metze D., Luger T.A. & Schwartz T. (1995). Ultraviolet B-induced apoptosis of keratinocytes: evidence for partial involvement of tumour necrosis factor- $\alpha$  in the formation of sunburn cells. *J Invest Dermatol.* 104, 922-927.
- Schmidt A., Heid H.W., Schafer S., Nuber U.A., Zimbelmann R. & Franke W.W. (1994). Desmosomes and cytoskeletal architecture in epithelial differentiation: cell type-specific plaque components and intermediate filament anchorage. *Eur J Cell Biol.* 65, 229-245.
- Schmuth M., Fluhr J.W., Crumrine D.C., Uchida Y., Hachem J.P., Behne M., Moskowitz D.G., Christiano A.M., Feingold K.R. & Elias P.M. (2004). Structural and functional consequences of loricrin mutations in human loricrin keratoderma (Vohwinkel syndrome with ichthyosis). *J Invest Dermatol.* 122(4), 909-922.
- Schnyder U.W., Franceschetti A.T., Cezarovic B. & Segedin J. (1969). Genetic linkage of Meleda disease to chromosome 8qter. *Eur J Hum Genet.* 6, 542-547.
- Schönfeld P. (1980). The pachyonychia congenita syndrome. *Acta Derm Venereol (Stockh).* 60, 45-49.
- Schwarb F.P., Gabard B., Ruffi T. & Surber C. (1999). Percutaneous absorption of salicylic acid in man after topical administration of three different formulations. *Dermatology.* 198, 44-51.
- Schweizer J., Bowden P.E., Coulombe P.A., Langbein L., Lane E.B., Magin T.M., Maltais L., Omary M.B., Parry D.A.D., Rogers M.A. & Wright M.W. (2006). New consensus nomenclature for mammalian keratins. *J Cell Biol.* 174, 169-174.
- Selvaraju V., Markanday M., Prasad P.V., Sathyan P., Sethuraman G., Srivastava S.C., Thakker N. & Kumar A. (2003). Mutation analysis of the cathepsin C gene in Indian families with Papillon-Lefèvre syndrome. *BMC Med Genet.* 4, 5.
- Sethuraman G., Malhota A.K., Khaitan B.K. & Sharma V.K. (2005). Effectiveness of isotretinoin in Papillon-Lefèvre syndrome. *Pediatr Dermatol.* 22(4), 378-379.
- Seviour K.B., Hatamochi A., Stewart I.A., Bykhovskaya Y., Allen-Powell D.R., Fischel-Ghodsian N. & Maw M.A. (1998). Mitochondrial A7445G mutation in two pedigrees with palmoplantar keratoderma and deafness. *Am J Med Genet.* 75, 179-185.

- Shamsher M.K., Navsaria H.A., Stevens H.P., Ratnavel R.C., Purkis P.E., Kelsell D.P., McLean W.H.I., Cook L.J., Griffiths W.A.D., Gschmeissner S., Spurr N. & Leigh I.M. (1995). Novel mutations in keratin 16 gene underlying focal non-epidermolytic palmoplantar keratoderma (NEPPK) in 2 families. *Hum Mol Genet.* 4, 1875-1881.
- Shen C.-S., Tabata K., Matsuki M., Goto T., Yokochi T. & Yamanishi K. (2002). Premature apoptosis of keratinocytes and the dysregulation of keratinisation in porokeratosis. *Br J Dermatol.* 147, 498-502.
- Shrivastava S.N. & Singh G. Tap water iontophoresis in palmoplantar hyperhidrosis. *Br J Dermatol.* 96, 189-195.
- Simpson C.L., Getsios S. & Sheu L.(2007). Desmoglein 1 governs subcellular allocation of plakoglobin, coordinating adhesion-dependent and –independent roles in epidermal morphogenesis. *J Invest Dermatol.* 127, S33.
- Smith F.J.D., Liao H., Cassidy A.J., Stewart A., Hamill K.J., Wood P., Joval I., van Steensal M.A.M., Björck E., Callif-Daley F., Pals G., Collins P., Leachman S.A., Munro C.S. & McLean W.H.I. (2005). The genetic basis of pachyonychia congenita. *J Invest Dermatol Symp Proc.* 10, 21-30
- Smith F.J.D., Del Monaco M., Steijlen P.M., Munro C.S., Morvay M., Coleman C.M., Rietveld F.J.R., Uitto J. & McLean W.H.I. (1999a). Novel proline substitution mutations in keratin 16 in two cases of pachyonychia congenita type 1. *Br J Dermatol.* 141, 1010-1016.
- Smith F.J.D., Fisher M.P., Healy E., Rees J.L., Bonifas J.M., Epstein E.H.Jr., Tan E.M.L., Uitto J. & McLean W.H.I. (2000). Novel keratin 16 mutations and protein expression studies in pachyonychia congenita type 1 and focal palmoplantar keratoderma. *Exp Dermatol.* 9, 170-177.
- Smith F.J.D., Jonkman M.F., van Goor H., Coleman C.M., Covello S.P., Uitto J. & McLean W.H.I. (1998). A mutation in human keratin K6b produces a phenocopy of the K17 disorder pachyonychia congenita type 2. *Hum Mol Genet.* 7(7), 1143-1148.
- Smith F.J., Morley S.M. & McLean W.H. (2002). A novel connexin 30 mutation in Clouston syndrome. *J Invest Dermatol.* 118, 530-2.
- Smith F.J.D., McKusick V.A., Nielsen K., Pfendner E., Uitto J. & McLean W.H.I. (1999b). Cloning of multiple keratin 16 genes facilitates prenatal diagnosis of pachyonychia congenita type 1. *Prenatal Diagn.* 19, 941-946.
- Smith F.J.D., Hickerson R.P., Sayers J.M., Reeves R.E., Contag C.H., Leake D., Kaspar R.L. & McLean W.H.I.(2008). Development of therapeutic siRNAs for pachyonychia congenita. *J Invest Dermatol.* 128, 50-58.

Smith F.J.D., Irvine A.D., Terron-Kwiatkowski A., Sandilands A., Campbell L.E., Zhao Y., Liao H., Evans A.T., Goudie D.R., Lewis-Jones S., Arseculeratne G., Munro C.S., Sergeant A., O'Regan G., Bale S.J., Compton J.G., DiGiovanna J., Presland R.B., Fleckman P. & McLean W.H. (2006). Loss-of-function mutations in the gene encoding filaggrin cause ichthyosis vulgaris. *Nat Genet.* 38(3), 337-342.

Sondell B., Thornell L.E. & Egelrud T. (1995). Evidence that stratum corneum chymotryptic enzyme is transported to the stratum corneum extracellular space via lamellar bodies. *J Invest Dermatol.* 104, 819-823.

Sorg O., Antille C., Kaya G. & Saurat J.H. (2006). Retinoids in cosmeceuticals. *Dermatol Ther.* 19, 289-296.

South A.P., Wan H., Stone M.G., Dopping-Hepenstal P.J., Purkis P.E., Marshall J.F., Leigh I.M., Eady R.A., Hart I.R. & McGrath J.A. (2003). Lack of plakophilin 1 increases keratinocyte migration and reduces desmosomal stability. *J Cell Sci.* 116, 3303-3314.

South A.P., Cabral A., Ives J.H., James C.H., Mirza G., Marenholz I., Mischke D., Backendorf C., Ragoussis J. & Nizetic D. (1999). Human epidermal differentiation complex in a single 2.5Mbp long continuum of overlapping DNA cloned in bacteria integrating physical and transcript maps. *J Invest Dermatol.* 112, 910-918.

Steinert P.M. & Marekov L.N. (1997). Direct evidence that involucrin is a major early isopeptide cross-linked component of the keratinocyte cornified cell envelope. *J Biol Chem.* 272, 2021-2030.

Steinert P.M. & Marekov L.N. (1999). Initiation of assembly of the cell envelope barrier structure of stratified squamous epithelia. *Molec Biol Cell.* 10, 4247-4261.

Steinert P.M. (1993). Structure, Function, and Dynamics of Keratin Intermediate Filaments. *J Invest Dermatol.* 100(6), 729-734.

Steinert P.M., Marekov L.N., Fraser R.D.B. & Parry D.A.D. (1993). Keratin intermediate filament structure: Crosslinking studies yield quantitative information on molecular dimensions and mechanism of assembly. *J Mol Biol.* 230, 436-452.

Steinert P.M. (1990). The two-chain coiled-coil molecule of native epidermal keratin intermediate filaments is a type I-type II heterodimer. *J Biol Chem.* 265, 8766-8774.

Steinert P.M. (2000). The Complexity and Redundancy of Epithelial Barrier Function. *J Cell Biol.* 151(2), F5-F7.

Steijlen P.M., Happle R., van Muijen G.N. & van de Kerkhof P.C. (1991). Topical treatment with 13-cis-retinoic acid improves Darier's disease and induces the expression of a unique keratin pattern. *Dermatologica.* 182(3), 178-183.

Stevens H.P., Kelsell D.P., Bryant S.P., Bishop T.D., Spurr N.K., Weissenbach J., Marger D., Marger R.S. & Leigh I.M. (1996). Linkage of an American Pedigree with Palmoplantar Keratoderma and Malignancy (Palmoplantar Ectodermal Dysplasia Type III) to 17q24: Literature Survey and Proposed Updated Classification of the Keratodermas. *Arch Dermatol.* 132(6), 640-651.

Stoler A., Kopan R., Duvic M. & Fuchs E. (1988). Use of mono-specific antisera and cRNA probes to localise the major changes in keratin expression during normal and abnormal epidermal differentiation. *J Cell Biol.* 107, 427-446.

Storz M.N., van de Rijn M., Kim Y.H., Mraz-Gernhard S., Hoppe R.T. & Kohler S. (2003). Gene expression profiles of cutaneous B cell lymphoma. *J Invest Dermatol.* 120, 865-870.

Su W.P., Chun S.I., Hammond D.E. & Gordon H. (1990). Pachyonychia congenita : A clinical study of 12 cases and review of the literature. *Pediatr Dermatol.* 7, 33-38.

Suga Y., Jarnik M., Attar P.S., Bundman D., Steven A.C., Koch P.J. & Roop D.R. (2000). Transgenic mice expressing a mutant form of loricrin reveal the molecular basis of the skin diseases, Vohwinkel syndrome and progressive symmetric erythrokeratoderma. *J Cell Biol.* 151(2), 401-412.

Sun S.Y. & Lotan R.Y. (2002). Retinoids and their receptors in cancer development and chemoprevention. *Crit Rev Oncol Hematol.* 41, 41-55.

Swartling C. & Vahlquist A. (2006). Treatment of pachyonychia congenita with plantar injections of botulinum toxin. *Br J Dermatol.* 154, 763-765.

Swartling C., Naver H. & Lindberg M. (2001). Botulinum A toxin improves life quality in severe primary focal hyperhidrosis. *Eur J Neurol.* 8, 247-252.

Swensson O., McMillan J.R., Churchill L.J., Egelrud T., Leigh I.M. & Eady R.A.J. (1994). Immunolabelling studies for keratins in normal human palm and sole skin: another prerequisite to studying palmoplantar keratoderma (abstract). *J Invest Dermatol.* 102, 865.

Swensson O., Langbein L., McMillan J.R., Stevens H.P., Leigh I.M., McLean W.H.I., Lane E.B. & Eady R.A.J. (1998). Specialized keratin expression pattern in human ridged skin as an adaptation to high physical stress. *Br J Dermatol.* 139, 767-775.

Swensson O. & Eady R.A.J. (1996). Morphology of the keratin filament network in palm and sole skin: evidence for site-dependent features based on stereological analysis. *Arch Dermatol Res.* 288, 55-62.

Swinehart J.M. (2000). Treatment of axillary hyperhidrosis: Combination of the starch-iodine test with the tumescent liposuction techniques. *Dermatol Surg.* 26, 392-396.

Sybert V.P., Dale B.A. & Holbrook K.A. (1988). Palmar-plantar keratoderma: A clinical, ultrastructural, and biochemical study. *J Am Acad Dermatol.* 18, 75-86.

Szeverenyi I., Cassidy A.J., Chung C.W., Lee B.T.K., Common J.E.A., Ogg S.C., Chen H., Sim S.Y., Goh W.L.P., Ng K.W., Simpson J.A., Chee L.L., Eng G.H., Li B., Lunny D.P., Chuon D., Venkaesh A., Khoo K.H., Mclean W.H.I., Lim Y.P. & Lane E.B. (2008). The human intermediate filament database: comprehensive information on a gene family involved in many human diseases. *Hum Mutat.* 29, 351-360.

Tada J. & Hashimoto K. (1997). Ultrastructural localization of gap junction protein connexin 43 in normal human skin, basal cell carcinoma, and squamous cell carcinoma. *J Cutan Pathol.* 24, 628-635.

Takahishi H., Ishida-Yamamoto A., Kishi A., Ohara K. & Iizuka H. (1999b). Loricrin gene mutation in a Japanese patient of Vohwinkel's syndrome. *J Dermatol Sci.* 19, 44-47.

Takahashi T., Ogo M. & Hibino T. (1998). Partial purification and characterization of two distinct types of caspases from human epidermis. *J Invest Dermatol.* 111, 367-372.

Takahishi H., Nakamura S., Asano K., Kinouchi M., Ishida-Yamamoto A. & Iizuka H. (1999a). Fas antigen modulates ultraviolet B-induced apoptosis, sequential activation of caspase8, 3 and 1 in the apoptotic process. *Exp Cell Res.* 249, 291-298.

Takahishi H., Ishida-Yamamoto A. & Iizuka H. (2001b). Ultraviolet B irradiation induces apoptosis of keratinocytes by direct activation of Fas antigen. *J Invest Dermatol Symp Proc.* 6, 64-68.

Takahishi H., Manabe A., Ishida-Yamamoto A., Hashimoto Y. & Iizuka H. (2002). Aberrant expression of apoptosis-related molecules in psoriatic epidermis. *J Dermatol Sci.* 28, 187-197.

Takahishi H., Aoki N., Nakamura S., Asano K., Ishida-Yamamoto A. & Iizuka H. (2000). Cornified cell envelope formation is distinct from apoptosis in epidermal keratinocytes. *J Dermatol Sci.* 23, 161-169.

Takahishi H., Honna M., Ishida-Yamamoto A., Namikawa K., Miwa A., Okado H., Kiyama H. & Iizuka H. (2001a). In vitro and in vivo transfer of bcl-2 gene into keratinocytes suppresses UVB-induced apoptosis. *Photochem Photobiol.* 74, 579-586.

Takahishi H., Kobayashi H., Hashimoto Y., Matsuo S. & Iizuka H. (1995). Interferon- $\gamma$ -dependent stimulation of Fas antigen in SV40-transformed human keratinocytes: modulation of the apoptotic process by protein kinase C. *J Invest Dermatol.* 105, 810-815.

Takahishi H., Kinouchi M., Tamura T. & Iizuka H. (1996). Decreased beta2-adrenergic receptor-mRNA and loricrin-mRNA, and increased involucrin-mRNA transcripts in psoriatic epidermis: analysis by reverse transcription-polymerase chain reaction. *Br J Dermatol.* 134, 1065-1069.

Taljebini M., Warren R., Mao-Qiang M., Lane E. & Elias P.M. (1996). Cutaneous permeability barrier repair following various types of insults: kinetics and effects of occlusion. *Skin Pharmacol.* 9, 111-119.

Templeton S.F. & Wiegand S.F. (1997). Pachyonychia congenita associated alopecia. A microscopic analysis using transverse section technique. *Am J Dermatopathol.* 19, 180-184.

Terrinoni A., Smith F.J.D., Didona B., Canzona F., Paradisi M., Huber M., Hohl D., David A., Verloes A., Leigh I.M., Munro C.S., Melino G. & McLean W.H.I. (2001). Novel and recurrent mutations in the genes encoding keratins K6a, K16 and K17 in 13 cases of pachyonychia congenita. *J Invest Dermatol.* 117, 1391-1396.

Terrinoni A., Leta A., Pedicelli C., Candi E., Ranalli M., Puddu P., Paradisi M., Angelo C., Bagetta G. & Melino G. (2004). A novel recessive connexin 31 (GJB3) mutation in a case of erythrokeratoderma variabilis. *J Invest Dermatol.* 122, 837-839.

Terron-Kwiatkowski A., Terrinoni A., Didona B., Melino G., Atherton D.J. & Irvine A.D. (2004). Atypical epidermolytic palmoplantar keratoderma presentation associated with a mutation in the keratin 1 gene. *Br J Dermatol.* 150, 1096-1103.

Terron-Kwiatkowski A., van Steensel M.A.M., van Geel M., Lane E.B., McLean W.H.I. & Steijlen P.M. (2006). Mutation S233L in the 1B domain of keratin 1 causes epidermolytic palmoplantar keratoderma with "tonotubular" keratin. *J Invest Dermatol.* 126, 607-613.

Terron-Kwiatkowski A., Paller A.S., Compton J., Atherton D.J., McLean W.H.I. & Irvine A.D. (2002). Two cases of primarily palmoplantar keratoderma associated with novel mutations in keratin 1. *J Invest Dermatol.* 119, 966-971.

Tian K., Norris A.W., Lin C.L. & Li E. (1997). The isolation and characterization of purified heterocomplexes or recombinant retinoic acid receptor and retinoid X-receptor ligand binding domains. *Biochem.* 36, 5669-5676.

Tidman M.J. & Wells R.S. (1988). Control of plantar blisters in pachyonychia congenita with topical aluminium chloride. *Br J Dermatol.* 118, 451-452.

Thomas D.R., Jorizzo J.L., Brysk M.M., Tschien J.A., Miller J. & Tschien E.H. (1984). Pachyonychia congenita. Electron microscopic and epidermal glycoprotein assessment before and during isotretinoin treatment. *Arch Dermatol.* 120, 1475-1479.



Thomas T., Telford D. & Laird D.W. (2004). Functional domain mapping and selective *trans*-dominant effects exhibited by Cx26 disease-causing mutations. *J Biol Chem.* 279, 19157-19168.

Thomsen R.J., Zuehlke R.L. & Beckman B.I. (1982). Pachyonychia congenita. Surgical management of the nail changes. *J Dermatol Surg Oncol.* 8, 24-28.

Thormann J. & Kobayasi T. (1977). Pachyonychia congenital Jadassohn-Lewandowsky. *Acta Derm Venereol (Stockh).* 57, 63-67.

Thost A. (1880). Über erbliche Ichthyosis palmaris et plantaris cornea. Heidelberg: Inaug diss.

Tomic-Canic M., Komine M., Freedberg I.M. & Blumenberg M. (1998). Epidermal signal transduction and transcription factor activation in activated keratinocytes. *J Dermatol Sci.* 17, 167-181.

Tomkova H., Fujimoto W. & Arata J. (1998). Expression of the bcl-2 homologue bax in normal human skin, psoriasis vulgaris and non-melanoma skin cancers. *Eur J Dermatol.* 8, 256-260.

Tong X. & Coulombe P.A. (2006). Keratin 17 modulates hair follicle cycling in a TNFalpha-dependent fashion. *Genes Dev.* 20(10), 1353-1364.

Tong X. & Coulombe P.A. (2004). A novel mouse type I intermediate filament gene, keratin 17n (K17n), exhibits preferred expression in nail tissue. *J Invest Dermatol.* 122, 965-970.

Toomes C., James J., Wood A.J., Wu C.L., McCormick D., Lench N., Hewitt C., Moynihan L., Roberts E., Woods C.G., Markham A., Wong M., Widmer R., Ghaffar K.A., Pemberton M., Hussein I.R., Temtamy S.A., Davies R., Read A.P., Sloan P., Dixon M.J. & Thakker N.S. (1999). Loss-of-function mutations in the cathepsin C gene result in periodontal disease and palmoplantar keratosis. *Nat Genet.* 23, 421-424.

Torchard D., Blanchet-Bardon C., Serova O., Langbein L., Narod S., Janin N., Goguel A.F., Bernheim A., Franke W.W., Lenoir G.M. & Feunteun J. (1994). Epidermolytic palmoplantar keratoderma cosegregates with a keratin gene mutation in a pedigree with breast and ovarian cancer. *Nature Genet.* 6, 106-110.

Tracey L., Villuendas R., Dotor A.M., Spiteri I., Ortiz P., Garcia J.F., Peralto J.L., Lawler M. & Piris M.A. (2003). Mycosis fungoides shows concurrent deregulation of multiple genes involved in the TNF signalling pathway: An expression profile study. *Blood.* 102(3), 1042-1050.

Troyanovsky S.M., Guelstein V.I., Tchipyshcheva T.A., Tchipyshcheva T.A., Krutovskikh V.A. & Bannikov G.A. (1989). Patterns of expression of keratin 17 in human epithelia : dependency on cell position. *J Cell Sci.* 93, 419-426.

- Troyanovksy S.M., Leube R.E. & Franke W.W. (1992). Characterization of the human gene encoding cytokeratin 17 and its expression pattern. *Eur J Cell Biol.* 59(1), 127-137.
- Tsai J.C., Chuang S.A., Hsu M.Y. & Sheu H.M. (1999). Distribution of salicylic acid in human stratum corneum following topical application in vivo: a comparison of six different formulations. *Int J Pharmaceut.* 188, 145-153.
- Uitto J., Richard G. & McGrath J.A. (2007). Diseases of epidermal keratins and their linker proteins. *Exp Cell Res.* 313, 1995-2009.
- Ullbro C., Crossner C.G., Nedefors T., Alfadley A. & Thestrup-Pederson K. (2003). Dermatologic and oral findings in a cohort of 47 patients with Papillon-Lefevre syndrome. *J Am Acad Dermatol.* 48, 345-351.
- Unna P.G. (1883). Über das Keratoma palmare et plantare hereditarum: eine Studie zur Kerato-Nosologie. *Arch Derm Syph (Berlin).* 72, 120-122.
- Uzumcu A., Norgett E.E., Dindar A., Uyguner O., Nisli K., Kayserili H., Sahin S.E., Dupont E., Severs N.J., Leigh I.M., Yeksel-Apak M., Kelsell D.P. & Wollnik B. (2006). Loss of desmoplakin isoform I causes early onset cardiomyopathy and heart failure in a Naxos-like syndrome. *J Med Genet.* 43, e5.
- Van de Craen M., Van Loo G., Pype S., Van Criekinge W., Van den Brande I., Molemans F., Fiers W., Declercq W. & Vandenabeele P. (1998). Identification of a new caspase homologue: caspase-14. *Cell Death Differ.* 5, 838-846.
- van Steensel M.A.M., Jonkman M.F., van Geel M., Steijlen P.M., McLean W.H.I. & Smith F.J.D. (2003). Clouston syndrome can mimic pachonychia congenita. *J Invest Dermatol.* 121, 1035-1038.
- Varani J., Zeigler M., Dame M.K., Kang S., Fisher G.J., Voorhees J.J., Stoll S.W. & Elder J.T. (2001). Heparin-binding epidermal-growth-factor-like growth factor activation of keratinocyte erbB receptors of retinoid therapy. *J Invest Dermatol.* 117, 1335-1341.
- Varani J., Warner R.L., Gharaee-Kermani M., Phan S.H., Kang S., Chung J.H., Wang Z.Q., Datta S.C., Fisher G.J. & Voorhees J.J. (2000). Vitamin A antagonizes decreased cell growth and elevated collagen-degrading matrix metalloproteinases and stimulates collagen accumulation in naturally aged human skin. *J Invest Dermatol.* 114, 480-486.
- Verheijen R., Kuijpers H.J.H., van Driel R, Beck J.L.M., van Dierendonck J.H., Brakenhoff G.J. & Ramaekers F.C.S. (1989). Ki-67 detects a nuclear matrix-associated proliferation-related antigen II. Localisation in mitotic cells and association with chromosomes. *J Cell Sci.* 92, 531-540.

- Villa P., Kaufman S.H. & Earnshaw W.C. (1997). Caspases and caspase inhibitors. *TIBS*. 22, 388-393.
- Vinken M., Vanhaecke T., Papelu P., Snykers S., Henkens T. & Rogiers V. (2006). Connexins and their channels in cell growth and cell death. *Cell Signal*. 18, 592-600.
- Virtanen M., Geed-Dahl T. Jr, Mörk N.M., Leigh I., Bowden P.E. & Vahlquist A. (2001). Phenotypic/genotypic correlations in patients with epidermolytic hyperkeratosis and the effects of retinoid therapy on keratin expression. *Acta Derm Venereol*. 81, 163-170.
- Vohwinkel H. (1929) Keratoma hereditarium mutilans. *Arch Dermatol Syphilol*. 158, 354-364.
- Vörner H. (1901). Zur Kenntniss des keratoma hereditarium palmare et plantare. *Arch Derm Syph*. 56, 3-31.
- Wakem P., Ikeda A., Haake A., Polakowska R., Ewing N., Sarret Y., Duvic M., Berg D., Bassett A., Kennedy J.L., Tuskis A., Epstein E.H. Jr & Goldsmith L.A. (1996). Localisation of the Darier disease gene to a 2-cM portion of 12q23-24.1. *J Invest Dermatol*. 106, 365-367.
- Wallace D.C. (1993). Mitochondrial diseases; genotype versus phenotype. *Trends Genet*. 9, 123-128.
- Wallis S., Lloyd S., Wise I., Ireland G., Fleming T.P. & Garrod D. (2000). The alpha isoform of protein kinase C is involved in signalling the response of desmosomes to wounding in culture epithelial cells. *Mol Biol Cell*. 11, 1077-1092.
- Wan H., Dopping-Hepenstal P.J.C., Gratian M.J., Stone M.G., McGrath J.A. & Eady R.A. (2003). Desmosomes exhibit site-specific features in human palm skin. *Exp Dermatol*. 12, 378-388.
- Wan H., Dopping-Hepenstal P.J.C., Gratian M.J., Stone M.G., Zhu G., Purkis P.E., South A.P., Keane F., Armstrong D.K.B., Buxton R.S., McGrath J.A. & Eady R.A.J. (2004). Striate palmoplantar keratoderma arising from desmoplakin and desmoglein 1 mutations is associated with contrasting perturbations of desmosomes and the keratin filament network. *Br J Dermatol*. 150, 878-891.
- Wan H., South A.P. & Hart I.R. (2007). Increased keratinocyte proliferation initiated through downregulation of desmoplakin by RNA interference. *Exp Cell Res*. 313, 2336-2344.
- Ward K.M., Cook-Bolden F.E., Christiano A.M. & Celebi J.T. (2003). Identification of a recurrent mutation in keratin 6a in a patient with overlapping clinical features of pachyonychia congenita types 1 and 2. *Clin Exp Dermatol*. 28, 434-436.

- Watanabe-Fukunaga R., Brannan C.I., Itoh N., Yonehara S., Copeland N.G., Jenkins N.A. & Nagata S. (1992). The cDNA structure, expression, and chromosomal assignment of the mouse Fas antigen. *J Immunol.* 148, 1274-1279.
- Watt F.M. (1989). Terminal differentiation of epidermal keratinocytes. *Curr Opin Cell Biol.* 1, 1107-1115.
- Weil M., Raff M.C. & Braga V.M. (1999). Caspase activation in the terminal differentiation of human epidermal keratinocytes. *Curr Biol.* 9, 361-364.
- Weirich E.G., Longauer J.K. & Kirkwood A.H. (1978). Effect of topical salicylic acid on animal epidermopoiesis. *Dermatologica.* 156, 89-96.
- Weiss R.A., Eichner R. & Sun T.T. (1984). Monoclonal antibody analysis of keratin expression in epidermal diseases: a 48- and 56-kdalton keratin as molecular markers for hyperproliferative keratinocytes. *J Cell Biol.* 98(4), 1397-1406.
- Wereide K. (1984). Mutilating palmoplantar keratoderma successfully treated with etretinate. *Acta Dermatovenereol. Scand.* 64, 564-569.
- Werner N.S., Windoffer R., Strand P., Grund C., Leube R.E. & Magin T.M. (2004). Epidermolysis bullosa simplex-type mutations alter the dynamics of the keratin cytoskeleton and reveal a contribution of actin to the transport of keratin subunits. *Molec Biol Cell.* 15, 990-1002.
- Wersto R.P., Herz F., Gallagher R.E. & Koss L.G. (1988). Cell cycle-dependent reactivity with the monoclonal antibody Ki-67 during myeloid cell-differentiation. *Exp Cell Res.* 179, 79-88.
- Wevers A., Kuhn A. & Mahrle G. (1991). Palmoplantar keratoderma with tonotubular keratin. *J Am Acad Dermatol.* 24, 638-642.
- White T.W. & Paul D.L. (1999). Genetic diseases and gene knockouts reveal diverse connexin functions. *Annu Rev Physiol.* 61, 283-310.
- Whitfield M.L., Finlay D.R., Murray J.I., Troyanskaya O.G., Chi J.T., Pergamenschikov A., McCalmont T.H., Brown P.O., Botstein D. & Connolly M.K. (2003). Systemic and cell type-specific gene expression patterns in scleroderma skin. *Proc Natl Acad Sci USA.* 100, 12319-12324.
- Whittock N.V. & Bower C. (2003a). Genetic evidence for a novel human desmosomal cadherin, desmoglein 4. *J Invest Dermatol.* 120, 523-530.
- Whittock N.V., Smith F.J., Wan H., Mallipeddi R., Griffiths W.A., Dopping-Hepenstal P., Ashton G.H., Eady R.A., McLean W.H.I. & McGrath J.A. (2002a). Frameshift mutation in the V2 domain of human keratin 1 results in striate palmoplantar keratoderma. *J Invest Dermatol.* 118, 838-844.

- Whittock N.V., Ahston G.H.S., Dopping-Hepenstal P.J.C., Gratian M.J., Keane F.M., Eady R.A.J. & McGrath J.A. (1999). Striate palmoplantar keratoderma resulting from desmoplakin haploinsufficiency. *J Invest Dermatol.* 113, 940-946.
- Whittock N.V., Wan H., Morley S.M., Garzon M.C., Kristal L., Hyde P., McLean W.H.I., Pulkkinen L., Uitto J., Christiano A.M., Eady R.A. & McGrath J.A. (2002b). Compound heterozygosity for non-sense and mis-sense mutations in desmoplakin underlies skin fragility/woolly hair syndrome. *J Invest Dermatol.* 118, 232-238.
- Whittock N.V. & Bower C. (2003b). Targetting of desmoglein 1 in inherited and acquired skin diseases. *Clin Exp Dermatol.* 28, 410-415.
- Wigley J.E.M. (1929). A case of hyperkeratosis palmaris et plantaris associated with ainhum-like constriction of the fingers. *Br J Dermatol.* 41, 188-191.
- Wilson C.L., Dean D., Lane E.B., Dawber R.P.R. & Leigh I.M. (1994). Keratinocyte differentiation in psoriatic scalp: morphology and expression of epithelial keratins. *Br J Dermatol.* 131, 191-200.
- Windoffer R., Woll S., Strand P. & Leube R.E. (2004). Identification of novel principles of keratin filament network turnover in living cells. *Mol Biol Cell.* 15, 2436-2448.
- Windoffer R. & Leube R.E. (1999). Detection of cytokeratin dynamics by time-lapse fluorescence microscopy in living cells. *J Cell Sci.* 112, 4521-4534.
- Wojcik S.M., Bundman D.S. & Roop D.R. (2000). Delayed wound healing in keratin 6a knockout mice. *Mol Cell Biol.* 20, 5248-5255.
- Wojcik S.M., Longley M.A. & Roop D.R. (2001). Discovery of a novel murin keratin 6 (K6) isoform explains the absence of hair and nail defects in mice deficient for K6a and K6b. *J Cell Biol.* 154, 619-630.
- Wollina U., Schaarschmidt H., Funfstuck V. & Knopf B. (1991). Pachyonychia congenita. Immunohistologic findings. *Zentralbl Pathol.* 137, 372-375.
- Wong D.J. & Change H.Y. (2005). Learning more from microarrays: insights from modules and networks. *J Invest Dermatol.* 125, 175-182.
- Wong P., Colucci-Guyon E., Takahashi K., Gu C., Babinet C. & Coulombe P.A. (2000). Introducing a null mutation in the mouse K6alpha and K6beta genes reveals their essential structural role in the oral mucosa. *J Cell Biol.* 150, 921-928.
- Wong P. & Coulombe P.A. (2003). Loss of keratin 6 (K6) proteins reveals a function for intermediate filaments during wound repair. *J Cell Biol.* 163, 327-337.
- Woodley D.T. (1996). Re-epithelialisation. In: The molecular and cellular biology of wound repair. Clark R.A.F., ed. 2<sup>nd</sup> edn., London: Plenum Press.

Wrone-Smith T., Bergstrom J., Quevedo M.E., Reddy V., Gutierrez-Steil C. & Nickoloff B.J. (1999). Differential expression of cell survival and cell cycle regulatory proteins in cutaneous squamoproliferative lesions. *J Dermatol Sci.* 19, 53-67.

Xia J.H., Liu C.Y., Tang B.S., Pan Q., Huang L., Dai H.P., Zhang B.R., Xie W., Hu D.X., Zheng D., Shi X.L., Wang D.A., Xia K., Yu K.P., Liao X.D., Feng Y., Yang Y.F., Xiao J.Y., Xie D.H. & Huang J.Z. (1998). Mutations in the gene encoding gap junction protein beta-3 associated with autosomal dominant hearing impairment. *Nat Genet.* 20, 370-373.

Yin T. & Green K.J. (2004). Regulation of desmosome assembly and adhesion. *Semin Cell Dev Biol.* 15, 665-677.

Yoneda K. & Steinert P.M. (1993). Overexpression of human loricrin in transgenic mice produces a normal phenotype. *Proc Nat Acad Sci USA.* 90, 10754-10758.

Yoon K.H., Yoon M., Moir R.D., Khuon S., Flitney F.W. & Goldman R.D. (2001). Insights into the dynamic properties of keratin intermediate filaments in living epithelial cells. *J Cell Biol.* 153, 503-516.

Yu J. & Zhang L. (2005). The transcriptional targets of p53 in apoptosis control. *Biochem Biophys Res Commun.* 331, 851-858.

Zakopoulou N. & Kontochristopoulous M.D. (2006). Superficial chemical peels. *J Cosmet Dermatol.* 5, 246-253.

Zamiri M., McLean W.H.I., Hodgins M.B. & Munro C.S. (2008). Pachyonychia congenita type 2: abnormal dentition extending into adulthood. *Br J Dermatol.* 59(2), 500-501.

Zatloukal K., Stumftner C., Lehner M., Denk H., Baribault H., Eshkind L.G. & Franke W.W. (2000). Cytokeratin 8 protects from hepatotoxicity, and its ratio to cytokeratin 18 determines the ability of hepatocytes to form Mallory bodies. *Am J Pathol.* 156, 1263-1274.

Zeeuwen P.L.J.M., Van Vlijmen-Willems I.M.J.J., Jansen B.J., Sotiropoulou G., Curfs J.H., Meis J.F., Janssen J.J., Van Ruisen F. & Schalkwijk J. (2001). Cystatin M/E expression is restricted to differentiated epidermal keratinocytes and sweat glands: a new skin-specific proteinase inhibitor that is a target for cross-linking transglutaminase. *J Invest Dermatol.* 116, 693-701.

Zeeuwen P.L.J.M., Van Vlijmen-Willems I.M.J.J., Hendriks W., Merckz G.F.M. & Schalkwijk J. (2002). A null mutation in the cystatin M/E gene of *ichq* mice causes juvenile lethality and defects in epidermal differentiation. *Hum Molec Genet.* 11, 2867-2875.

Zeeuwen P.L.J.M., Ishida-Yamamoto A., Van Vlijmen-Willems I.M.J.J., Cheng T., Bergers M., Iizuka H. & Schalkwijk J. (2007). Colocalisation of cystatin M/E and cathepsin V in lamellar granules and corneodesmosomes suggests a functional role in epidermal differentiation. *J Invest Dermatol.* 127, 120-128.

Zemstov A. & Veitschegger M. Keratodermas. *Int J Dermatol.* 32, 493-498.

Zhou H.L., Yang S., Gao M., Zhao X.Y., Zhu Y.G., Li W., Ren Y.Q., Liang Y.H., Du W.H. & Zhang X.J. (2007). A novel missense mutation L468Q of keratin 6a in pachyonychia congenita type 1. *J Eur Acad Dermatol Venereol.* 21, 351-355.

Zhou X., Tan F.K., Xiong M., Milewicz D.M., Feghali C.A., Fritzler M.J., Reveille J.D. & Arnett F.C. (2001). Systemic sclerosis (scleroderma): Specific autoantigen genes are selectively overexpressed in scleroderma fibroblasts. *J Immunol.* 167(12), 7126-7133.

Zhou X., Krueger J.G., Kao M.C., Lee E., Du F., Menter A., Wong W.H. & Bowcock A.M. (2003). Novel mechanisms of T-cell and dendritic cell activation revealed by profiling of psoriasis on the 63, 100-element oligonucleotide array. *Physiol Genomics.* 13, 69-79.

Zhou L., Askew D., Wu C. & Gilliam A.C. (2007). Cutaneous gene expression by DNA microarray in murine sclerodermatous graft-versus-host disease, a model for human scleroderma. *J Invest Dermatol.* 127, 281-292.

Zouboulis C.C. (2001). Retinoids – which dermatological indications will benefit in the near future? *Skin Pharmacol Appl Skin Physiol.* 14, 303-315.

## **Appendix A. Peripheral Nerve Block for Plantar Skin Biopsy**

### **1. Introduction**

#### **1.1 Peripheral nerve blockade**

Plantar skin is more often involved than palmar skin in the inherited PPKs, and may require biopsy in the assessment of these conditions. Biopsy of plantar skin is particularly challenging, due to the pain associated with direct/local infiltration of macerated, hyperkeratotic and often blistered skin. There is therefore a need for effective methods of anaesthesia.

Recently, there has been a growing interest in regional anaesthesia, particularly in peripheral nerve blockade, in a wide range of surgical areas, from orthopaedic and breast surgery to hernia repairs (Singelyn & Capdevila, 2001; Mulroy, 2002). Peripheral nerve blockade is being used not only to provide surgical anaesthesia but also postoperative analgesia and the treatment of pain related to non-surgical causes, particularly with the introduction of long-acting local anaesthetics. Lower extremity peripheral nerve blocks (PNBs) have never been as widely taught or used as other forms of regional anaesthesia. Transient neurologic symptoms associated with spinal anaesthesia, increased risk of epidural haematoma with the introduction of antithromboembolic prophylaxis regimens, and evidence of improved rehabilitation outcome with lower extremity PNBs has led to an increased interest in lower extremity PNBs (Enneking *et al.*, 2005).

#### **1.2 Nerve supply to the foot**

Sensory efferents of the foot are located in five nerve branches: the posterior tibial nerve, the deep peroneal nerve, the superficial peroneal nerve, the sural nerve (all four from the sciatic nerve) and the saphenous nerve (from the femoral nerve). The



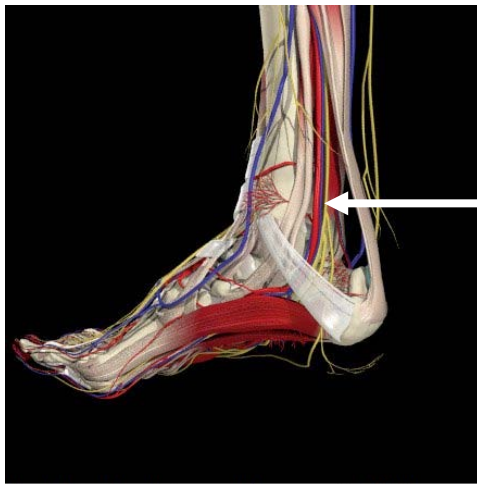posterior tibial nerve is the terminal branch of the sciatic and tibial nerves. It descends vertically in the posterior aspect of the leg, deep to the soleus muscle, and enters the tarsal tunnel just behind the posterior tibial vessels (Figure 1a). The posterior tibial nerve trifurcates into the medial and lateral plantar nerves and the calcaneal nerve, which provide cutaneous innervation to most of the plantar surface of the foot (Keifer & McQuillan, 1996) (Figure 1b & c).

### **1.3 Ankle block and anaesthesia to the sole of the foot**

Ankle block, involving all 5 nerve branches to the foot, is a well described and successful means of providing surgical anaesthesia and postoperative analgesia for midfoot and forefoot surgery (Levecque *et al.*, 1999; Doty *et al.*, 2006), as well as being an established treatment for plantar fasciitis and chronic heel pain (Pavier & Liggins, 2001; Govindarajan *et al.*, 2003). Although there are no important variants in the innervation of the distal musculature, there is considerable variation in the branching and distribution of the sensory nerves of the foot (Enneking *et al.*, 2005). For foot surgery, blockade of all 5 nerves has been advocated (Delgado-Martinez *et al.*, 2001). Analgesia is achieved for the sole of the foot by blocking the posterior tibial nerve and the sural nerve (Keifer & McQuillan, 1996). The majority of the sole of the foot is supplied by the former other than the lateral aspect of the sole and a small area proximal to the great toe being supplied by the deep peroneal nerve (Figure 1c & 1d). Thus for anaesthetizing the medial aspect of the sole, we postulated that posterior tibial nerve block alone may be sufficient.

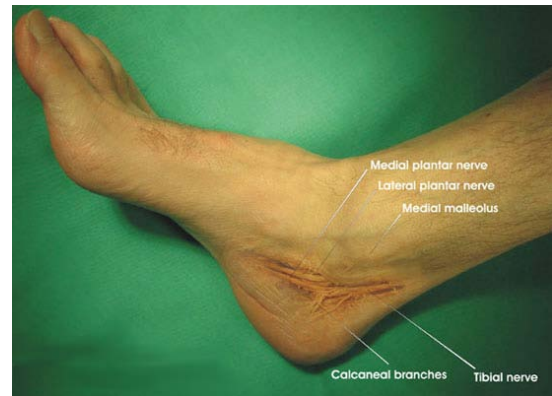### **1.4 Aim**

Our aim was to assess the efficacy of posterior tibial nerve blockade as an alternative to local infiltration in plantar skin biopsy.

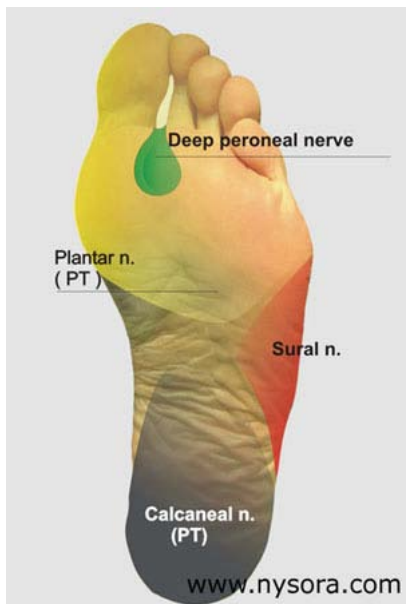


Podiatric Medicine and Surgery © 2001

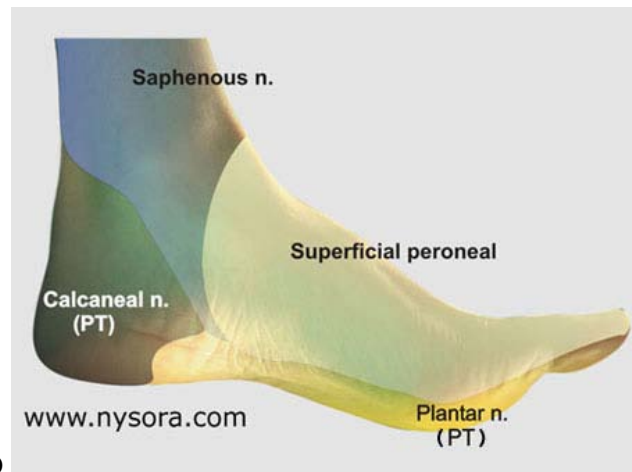
A Primal Pictures Ltd



B



C

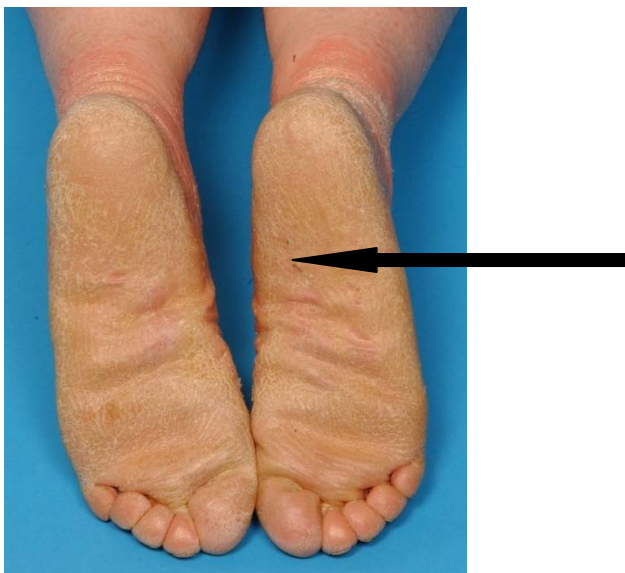


D

**Figure 1a). The path of the posterior tibial nerve in the lower leg (Podiatric Medicine and Surgery, 2001).** It descends vertically in the posterior aspect of the leg, deep to the soleus muscle, and enters the tarsal tunnel just behind the posterior tibial vessels (identified by arrow, nerves shown in yellow). **1b) The terminal trifurcation of the posterior tibial nerve in the foot.** **1c) Sensory innervation of the sole of the foot.** Branches of the posterior tibial (PT) and sural nerve supply the majority of the sole. **1d) Sensory supply to foot.** There is considerable variation in the branching and distribution of the sensory nerves of the foot; cutaneous branches extending from the saphenous nerve may supply part of the medial aspect of the sole. Images reproduced by kind permission of a) Primal Pictures Ltd, and b),c),d) www.nysora.com.

## 2. Methods

Following informed consent, all sixteen inherited PPK patients recruited to the study underwent elliptical plantar skin biopsy from the medial aspect of the heel (Figure 2) using posterior tibial nerve block in a standard, distal manner (Doty et al, 2006). Additional local anaesthetic was delivered by direct infiltration (23G x 1¼ in/0.60 x30mm needle, BD Microlance™) using 1% plain xylocaine if there was any concern about the efficacy of the block. The first five patients biopsied received posterior tibial nerve block alone, and the following eleven patients a combined posterior tibial and saphenous nerve block. As the posterior tibial nerve is a combined motor and sensory nerve, patients were pre-warned about the forthcoming numbness in order to avoid neurological trauma. No premedication was given. All nerve blocks were delivered by a podiatric surgeon with experience of the technique in the treatment of chronic plantar fasciitis.



**Figure 2.** Site of plantar skin biopsy in inherited PPK patients (shown by arrow).

### **2.1 Injection technique: Posterior tibial nerve block**

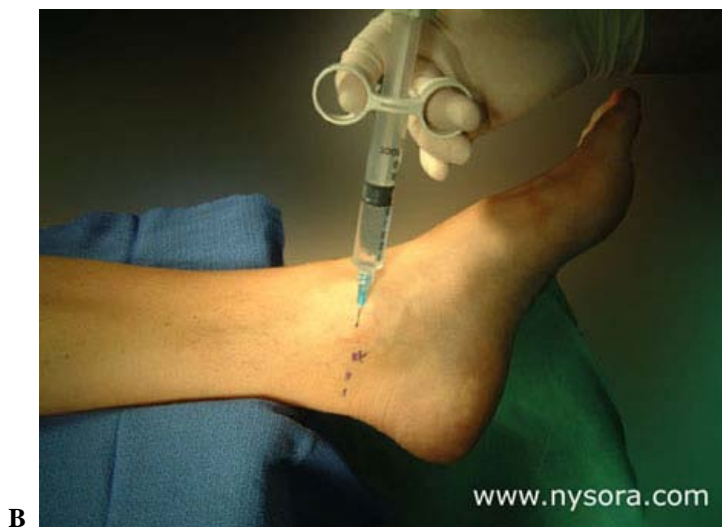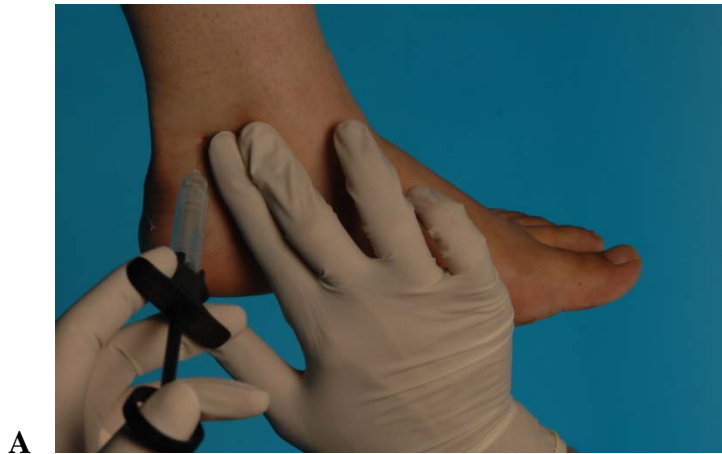The distal block site was 2cm proximal to the tip of the medial malleolus midway between the medial border of the Achilles tendon and the medial malleolus, posterior to the posterior tibial artery pulsation when palpated. With the patient supine and lower leg laterally rotated by 45<sup>0</sup>, the needle (27G x 1<sup>3</sup>/<sub>8</sub> in/0.40x35mm needle, Safety Plus XL™ Septodent) was inserted at 90<sup>0</sup> to the surface of the skin and advanced until resistance was felt (Figure 3a). Prior to the delivery of anaesthetic, the needle was withdrawn 1-2mm and aspirated, as an essential safeguard when injecting in this site due to the proximity of the posterior tibial artery and vein. Nerve block was performed using up to a maximum dose of 4.4mls of 3% mepivocaine. The area around the posterior tibial nerve was then massaged.

### **2.2 Injection technique: Saphenous Nerve Block**

The saphenous nerve was anaesthetised at the level of the medial malleolus. The needle (27G x 1<sup>3</sup>/<sub>8</sub> in/0.40x35mm needle, Safety Plus XL™ Septodent) was inserted at the medial malleolus and a “ring” of local anaesthetic raised from the point of needle entry to the Achilles tendon, and anteriorly to the tibial ridge (Figure 3b). Nerve block was performed using up to a maximum dose of 4.4mls of 3% mepivocaine.

### **2.3 Assessment of Anaesthesia**

After performance of the nerve block, subjects were evaluated by the surgeon and an independent observer for adequate anaesthesia at the planned surgical site before incision. Sensory block was evaluated by the pinprick test on a 3-point scale (0 =



**Figure 3a) Injection technique for delivery of posterior tibial nerve block.** The distal block site was 2cm proximal to the tip of the medial malleolus midway between the medial border of the Achilles tendon and the medial malleolus, posterior to the posterior tibial artery pulsation when palpated. **b) Injection technique for saphenous nerve block.** The needle was inserted at the medial malleolus and a “ring” of local anaesthetic raised from the point of needle entry to the Achilles tendon, and anteriorly to the tibial ridge (3b reproduced by kind permission of [www.nysora.com](http://www.nysora.com)).

normal sensation; 1 = blunt sensation; 2 = no perception). The surgical procedure was not started until the patient had a pinprick score of 2. Additional local anaesthetic was used by direct infiltration of the skin if necessary, until a pinprick score of 2 was achieved.

## **2.4 Outcomes**

The main primary outcome was pain control using visual analogue scales and verbal pain scores. All patients were given thorough instructions preoperatively in these methods. Ten-centimetre visual analogue scales were marked only “no pain” at one end of the scale and “worst possible pain” at the other. Pain associated with posterior tibial nerve block as well as the actual biopsy were scored. If additional local infiltration was required, they were also asked to score their level of plantar pain associated with this injection. Verbal pain scores (Reinhart *et al.*, 2000) were completed for the posterior tibial nerve block procedure. A set of descriptions randomly placed on a page, were presented to the patient, who selected the best description from the following: no pain, just noticeable, weak, mild, moderate, strong, severe or excruciating.

Patients were also asked to compare the pain level of this procedure with any previous palmoplantar biopsies. Patients were instructed to record their pain scores, both visual analogue and verbal pain, in the first 48 hours after the biopsy, to record any additional analgesics required during this period, and any initial problems, and return this information by post. All patients were telephoned within the first week post biopsy, and were routinely seen in outpatient clinic thereafter.

### 3. Results

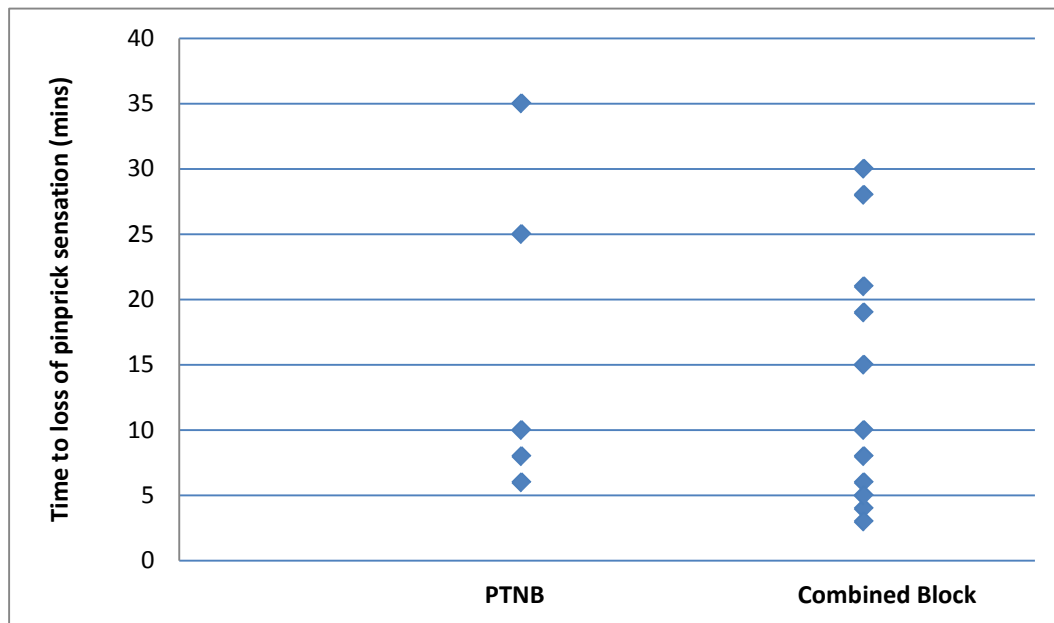
#### 3.1 Efficacy of Anaesthesia

3/5 (60%) of patients receiving posterior tibial nerve block alone failed to achieve complete loss of pinprick sensation at the biopsy site, despite using the maximum dose of mepivocaine, and allowing up to 35 minutes for the block to become efficacious. This may have been due to cutaneous branches from the saphenous nerve extending to the biopsy site (Figure 1d). Accordingly, the next 11 inherited PPK patients were anaesthetized using a combined posterior tibial and saphenous nerve block.

Table 1 lists the mean time in minutes from the performance of the block to loss of sensation to pinprick at the surgical site (also see Figure 4), the number of patients requiring additional local anaesthetic to achieve loss of sensation to pinprick, the mean duration of surgery, the number of patients reporting pain in the first 48 hours post biopsy. 2 patients receiving the posterior tibial nerve block alone and 1 receiving a combined block failed to reach loss of sensation to pinprick after 30 minutes so additional local anaesthetic was given by direct infiltration.

**Table 1. Summary of median time to loss of pinprick sensation for posterior tibial compared to combined posterior tibial and saphenous nerve blocks.** Requirement of additional local anaesthetic and pain experienced post-biopsy are also shown. Range of times to loss of pinprick sensation shown in Figure 4.

	<b>Posterior Tibial Nerve Block Alone (n=5)</b>	<b>Combined Posterior Tibial and Saphenous Nerve Blocks (n=11)</b>
<b>Median time to loss of pinprick sensation (mins)</b>	10 (range 6-35)	10 (range 3-30)
<b>Additional local anaesthetic needed</b>	3 (60%)	5 (40%)
<b>Volume of additional local anaesthetic (mls)</b>	5	2
<b>Pain in first 48 hours post biopsy</b>	3 (60%)	5 (40%)



**Figure 4. Range of times to loss of pinprick sensation for posterior tibial nerve block alone and combined posterior tibial and saphenous nerve blocks.**

### 3.2 Outcomes: Pain Scores

The mean pain scores for the posterior tibial and saphenous nerve blocks, any additional local anaesthetic used, any discomfort during the actual biopsy, and first 48 hours post procedure are shown in Figure 5. Verbal pain scores for the posterior tibial nerve block procedure, any additional local anaesthetic given and the first 48 hours post biopsy are shown in Figure 6.

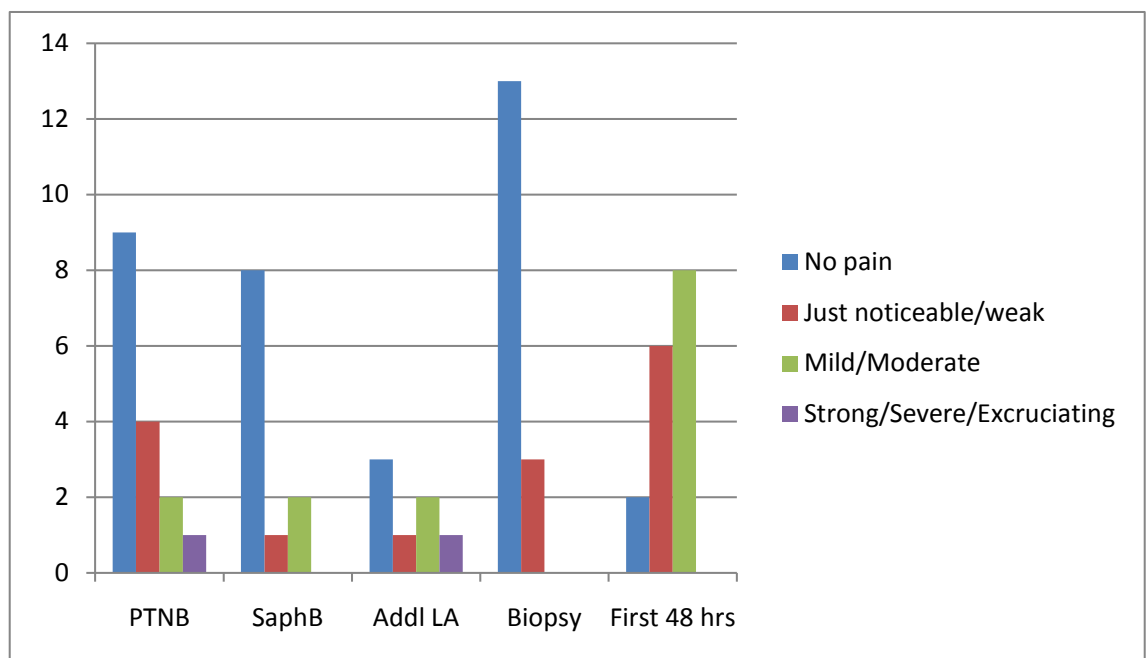
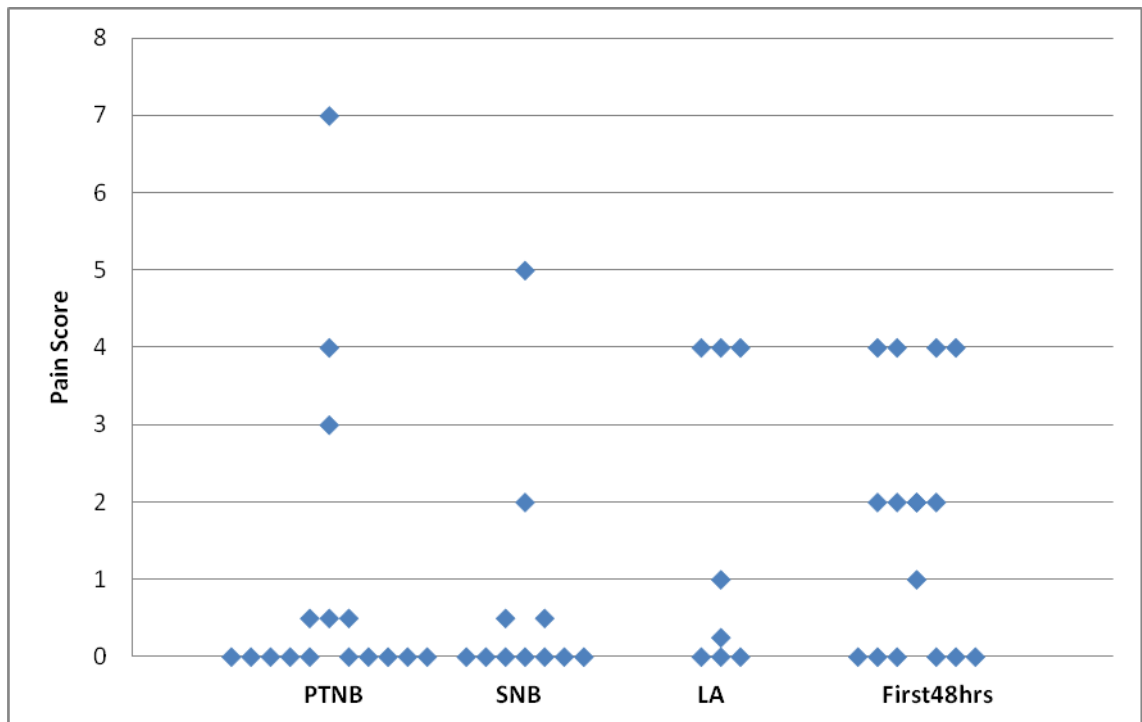
All 5 patients who had previously had palmoplantar biopsies with direct infiltration of local anaesthetic alone found posterior tibial nerve block significantly less painful. 8 patients found it necessary to take paracetamol to co-codamol in the first 48 hours post procedure.

### 3.3 Complications

No complications occurred as a result of delivery of either nerve block (infection, haematoma, vascular puncture of greater saphenous vein, or nerve injury).



**Figure 5. Summary of median pain scores (visual analogue scale) for posterior tibial and saphenous nerve blocks, delivery of additional local anaesthetic, and the 48 hours post biopsy.** The biopsy itself was associated with no pain by 15/16 and was scored 0.5 by 1/16 patients.



**Figure 6. Verbal pain scores for posterior tibial nerve block procedure (PTNB) (n=16), additional saphenous nerve block (SNB) (n=11), additional infiltration of local anaesthetic (Addl LA) (n=8), the biopsy itself (n=16) and the first 48 hours post biopsy (n=16).**

## **4. Discussion**

### **4.1 Non-invasive anaesthesia**

Biopsying hyperkeratotic or inflamed plantar skin poses an anaesthetic challenge. Different regional anaesthesia methods, both invasive and non-invasive, are available for palmar skin, mainly used for the administration of Botulinum toxin for hyperhidrosis. Non-invasive methods generally involve treatment with a topical application of local anaesthetic (eg. EMLA cream) (Naumann *et al.*, 1998). Local anaesthetics diluted in tap water have been used in an iontophoretic procedure for palmar skin (Selander, 1995). However, even though these techniques are easy to apply, topical use of anaesthetics provides little relief, and does not eliminate the pain of needle pricks, the main disadvantage of this non-invasive anaesthesia technique (Blaheta *et al.*, 2002).

### **4.2 Intravenous regional anaesthesia**

In order to achieve sufficient anaesthesia, invasive regional techniques such as peripheral nerve blocks have also been used. Although serious morbidity related to anaesthetic blocks is extremely infrequent, damage to peripheral nerves has been reported (Selander, 1995). Intravenous regional anaesthesia (Bier's block) has mainly been reported for palmar (Blaheta *et al.*, 2002; Hornberger *et al.*, 2004) and plantar skin (Blaheta *et al.*, 2003; Swartling & Vahlquist, 2006). Bier's block was found to be well tolerated by patients primarily because of the rapid recovery of motor function and sensation after tourniquet release. Bier's block has been used in 3 patients with PC-1 prior to the delivery of plantar injections of botulinum toxin without any complications (Swartling & Vahlquist, 2006). However it is not a

procedure without risks, namely, toxic reactions attributed to tourniquet leak of local anaesthetic into the systemic circulation (Rosenberg *et al.*, 1983; Heath, 1983).

### **4.3 Peripheral Nerve Block**

The results of this open study suggest that posterior tibial nerve block alone or in conjunction with a saphenous nerve block greatly reduces the pain of direct infiltration of local anaesthetic in this site. The additional time required prior to surgery for the administration of the nerve block was in keeping with previous reports (Pavier & Liggins, 2001), although there was a wide range (3 to 30 minutes). 8/16 patients required no further analgesia other than the nerve block for the completion of the biopsy, although 5/16 required additional local anaesthetic for biopsy of the dermis with inadequate anaesthesia at deeper levels and 3 patients not achieving loss of sensation to pinprick without it. The mean pain scores for injection of local anaesthetic were low (Table 2) with the nerve block already in place. As this is an uncontrolled study, it is not possible to be certain of the degree of benefit of the nerve block but the previous experience of a few patients and clinical experience suggests that the pain associated with direct infiltration is much greater.

Variable efficacy of both single and, to a lesser extent, combined blocks may be overcome by delivery of a total ankle block, given the considerable variation in the branching and distribution of sensory nerves to the foot, however, small volumes of direct local anaesthetic were well tolerated once the dual combined block was in place. Although the combined dual block resulted in a slightly lower percentage of patients requiring direct infiltration, and a smaller volume of anaesthetic was used in these cases, it is difficult to firmly conclude that the combined block was definitely more effective than single block alone, given the small numbers. Other possible

methods of improvement of efficacy include an operator who has experience of nerve blockade for surgery as opposed to pain relief, and the use of nerve stimulators (Hadzic *et al.*, 2003).

## **5. Conclusion**

Providing more prolonged anaesthesia when biopsying painful weight-bearing sites may be advantageous in patients with diseased plantar skin, such as in the inherited PPKs. Posterior tibial nerve blockade using a longer acting anaesthetic (bupivocaine 0.5%) has been successfully used in the treatment of chronic plantar fasciitis to reduce pain (Pavier & Liggins, 2001; Govindarajan *et al.*, 2003) and in treating postoperative pain after hallux valgus surgery (Levecque *et al.*, 1999). It is possible that its role in the inherited PPKs may extend beyond that of a surgical tool, and provide a therapeutic option for those patients with limited mobility due to plantar pain. It also provides an alternative method of anaesthesia for those patients requiring treatment for hyperhidrosis with botulinum toxin injections or therapeutic siRNAs (Smith *et al.*, 2007).

## 6. References

- Blaheta H.J., Vollert B., Zuder D. & Rassner G. (2002). Intravenous regional anesthesia (Bier's block) for botulinum toxin therapy of palmar hyperhidrosis is safe and effective. *Dermatol Surg.* 28(8), 666-672.
- Blaheta H.J., Deusch H., Rassner G. & Vollert B. (2003). Intravenous regional anaesthesia (Bier's block) is superior to a peripheral nerve block for painless treatment of plantar hyperhidrosis with botulinum toxin. *J Am Acad Dermatol.* 48(2), 302-4.
- Crawford F., Atkins D., Young P. & Edwards J. (1999). Steroid injection for heel pain: evidence of short-term effectiveness. A randomized controlled trial. *Rheumatol.* 38, 974-977.
- Delgado-Martinez A.D. & Marchal-Escalona J.M. (2001). Supramalleolar ankle block anesthesia and ankle tourniquet for foot surgery. *Foot Ankle Int.* 22, 836-838.
- Doty R. Jnr, Sukhani R., Kendall M.C., Yaghmour E., Nader A., Brodskaja A., Kataria T.C. & McCarthy R. (2006). Evaluation of a proximal block site and the use of nerve-stimulator-guided needle placement for posterior tibial nerve block. *Anesth Analg.* 103(5), 1300-1305.
- Enneking F.K., Chan V., Greger J., Hadzic A., Lang S.A. & Horlocker T.T. (2005). Lower Extremity Peripheral Nerve Blockade: Essentials of Our Current Understanding. *Reg Anesth Pain Med.* 30(1), 4-35.
- Govindarajan R., Bakalova T., Doss N.W., Splain S.H., Michael R. & Abadir A.R. (2003). Posterior tibial nerve block in the therapeutic management of painful calcaneal spur (plantar fasciitis): a preliminary experience. *Can J Anesth.* 50(8), 862-863.
- Hadzic A., Vloka J., Hadzic N., Thys D.M. & Sanots A.C. (2003). Nerve stimulators used for peripheral nerve blocks vary in their electrical characteristics. *Anesthesiology* 98, 969-74.
- Heath M.L. (1983). Bupivocaine toxicity and Bier blocks. *Anesthesiology* 59, 481.
- Hornberger J., Grimes K., Naumann M., Glaser D.A., Lowe N.J., Naver H., Ahn S. & Stolman L.P. (2004). Recognition, diagnosis, and treatment of primary focal hyperhidrosis. *J Am Acad Dermatol.* 51, 274-286.
- Keifer J.C. & McQuillan P.M. (1996). Peripheral nerves at the ankle. In: Regional anesthesia – an atlas of anatomy and techniques. Hahn M.C., MacQuillan P.M., Sheplock G.J., eds. St Louis, MO: Mosby.
- Lévecque J.P., Borne M. & Saïssy J.M. (1999). Analgesia with continuous lateral posterior tibial nerve block. *Reg Anesth Pain Med.* 24(2), 191-192.

- Mulroy M. (2002). Advances in regional anaesthesia for outpatients. *Curr Opin Anaesthesiology* 15, 641-645.
- Naumann M., Bergmann I., Hofmann U., Hamm H. & Reiners K. (1998). Botulinum toxin for focal hyperhidrosis: technical considerations and improvements in application. *Br J Dermatol.* 139(6), 1123-1124.
- Pavier J.C.S. & Liggins W.J. (2001). The use of 0.5% bupivocaine hydrochloride plain solution injections in the treatment of chronic plantar fasciitis. *Br J Podiatry.* 4(3), 90-94.
- Reinhart D.J., Stagg K.S., Walker K.G., Wang W.P., Parker C.P., Jackson H.H. & Walker E.B. (2000). Postoperative analgesia after peripheral nerve block for podiatric surgery: clinical efficacy and chemical stability of lidocaine alone versus lidocaine after ketorolac. *Reg Anesth Pain Med.* 25(2), 506-513.
- Rosenberg P.H., Kalso E.A., Tuominen M.K. & Linden H.B. (1983). Aucte bupivocaine toxicity as a result of venous leakage under the tourniquet cuff during a Bier block. *Anesthesiology.* 58, 95-8.
- Selander D. (1995). Peripheral nerve damage and regional anaesthesia. *Br J Anaesth.* 75(1), 116-117.
- Singelyn F.J. & Capdevila X. (2001). Regional anaesthesia for orthopaedic surgery. *Curr Opin Anaesthesiology.* 14, 733-740.
- Smith F.J.D., Hickerson R.P., Sayers J.M., Reeves R.E., Contag C.H., Leake D., Kaspar R.L. & McLean W.H.I. (2007). Development of therapeutic siRNAs for pachyonychia congenita. *J Invest Dermatol.* 128, 50-58.
- Swartling C. & Vahlquist A. (2006). Treatment of pachyonychia congenita with plantar injections of botulinum toxin. *Br J Dermatol.* 154(4), 763-765.



## **Addendum A**

### **Patient Information Sheet**

Information for Patients: Please read carefully

#### Study of the Mechanisms of Keratoderma:

You are being asked to take part in a study of the function of the outermost layer of the skin, the epidermis. We are trying to understand why in some people the epidermis of the hands and feet becomes abnormally thickened and hard.

We are studying people who have inherited disorders which cause extreme and often painful thickening of the hands and feet. This condition is called keratoderma. Many people also suffer from hard skin on their feet for other reasons, like corns and callosities, and we hope to understand these better too.

To find out what is going on in these disorders, we also need to study normal skin samples.

We are asking you to help by allowing us to take either small samples (biopsies) of the affected or unaffected skin of your feet, or biopsies of normal-appearing skin from other body sites. Local anaesthetic will be used to numb the skin.

We will be freezing or preserving the skin samples to study the cell machinery using special techniques. In some cases, we would like to grow the skin cells for short periods in our laboratory. The use of living cells is necessary for us to study the way these systems work.



Your participation in the study is entirely voluntary, if you decide not to have this biopsy, it will not alter your future treatment.

All information gathered from the study will be confidential.

We will ask you to read carefully and sign a consent form for the procedure, to show that it has been explained to you, and that you understand what is being asked of you.

The study, this information sheet, and the consent form have been approved by the Research Ethics Committee of the South Glasgow Hospitals University NHS Trust.

If you would like further information to help you decide whether or not to take part in the study, we will be pleased to answer any questions.

Prof Colin Munro; Dr Mozheh Zamiri

Department of Dermatology

Southern General Hospital

Glasgow G51 4TF

Telephone: 0141 201 1567

## **Addendum B**

### **Patient Questionnaire: Palmoplantar Keratoderma Medical History and Clinical Findings Form**

Name:

First Name:

Hospital Number:

Date of Birth:

Male/Female:

Diagnosis:

Implicated Gene:

#### **History and Clinical Features:**

Sites of hyperkeratosis (plantar/palmar/other):

Age of onset of hyperkeratosis:

Plantar pain:

Nail abnormalities:

Teeth abnormalities:

Knuckle pads/callosities:

Digital constrictions:

History of cysts:

History of excessive sweating:

Hoarseness/History of Mucosal, Peridontal or Laryngeal disease:

Deafness:

History of Malignancy (e.g. SCCs/other)

Cardiomyopathy (Arrhythmogenic RV/LV/Dilated):

Keratitis:

Other neuropathies:

Vaginal/Cervical abnormalities:

Difficulties with Lactation:

History of Phimosis:

Clinical course to date:

Other past medical history:

If history available: Pregnancy/Preterm birth/Birth weight/Collodion membrane/Desquamation/Natal teeth/Atrophic skin/Absence of dermatoglyphics/Blisters/Difficulties in first few weeks of life

Drug history: Local/Systemic

Family history:

Affected relatives:

Any consanguineous family:

Ethnic origin of parents:

Family tree:

Family history of deafness/dental abnormalities/other findings

Examination:

Palmoplantar keratoderma:

Pattern: Diffuse/Focal/Honeycomb/Striate/Punctate/Transgradient/

Sites: Heel/Ball/Anterior arch/Toes/Palms

Other sites of hyperkeratosis: Knees/Elbows/Wrists/Forearms/Natal cleft/Achilles tendon/Glove and stocking

Circumferential hyperkeratosis

Digital constrictions

Autoamputation

Palmoplantar hyperhidrosis

Blistering

Knuckle pads

Nail anomalies: Fingernails/Toenails/Subungal hyperkeratosis/Nail  
pigmentation/other

Cysts: Epidermal inclusion/Steatocystomas/Vellus hair cysts

Hair abnormalities:

Oral leukokeratoses:

Dental abnormalities: (Gingivitis/Periodontitis/Loss of permanent teeth)

Follicular keratoses:

Hearing disorder (right/left/bilateral):

Neurological symptoms:

## **Addendum C**

skin involvement of extracutaneous lymphoma. Nevertheless, prognosis and overall treatment are different. A specific question is asked with isolated medullary infiltration. Primary cutaneous medullary MZL does not exist, therefore medullary involvement is secondary to another lymphoma. Frequency of medullary involvement may be underestimated in some studies, consequent to patient selection in order to fulfil the definition of PCMZL. Moreover, methods of analysis of medullary biopsy are not often specified. Medullary infiltration is found in 0–53%.<sup>3–9</sup> Our study is the largest one to evaluate the frequency of isolated medullary infiltration in cutaneous MZL.

The consequence of this infiltration for cutaneous MZL is rarely studied. Zucca et al.,<sup>9</sup> as in our series, did not find an adverse influence of bone marrow involvement on survival.

In conclusion, we present a retrospective study of 44 patients with cutaneous MZL. Isolated medullary involvement was found in 10 patients (23% of the total). The lack of data in the literature concerning cutaneous MZL with isolated medullary involvement does not permit prognosis. The significance and therapeutic implications of this asymptomatic bone marrow involvement are to be defined in the future.

\*Department of Dermatology,  
Claude Bernard University Lyon 1,  
Hospices Civils de Lyon, Hôpital de l'Hôtel-Dieu,  
69288 Lyon cedex 02, France  
Departments of †Pathology and  
‡Clinical Haematology and §Haematology Laboratory,  
Centre Hospitalier Lyon-Sud,  
69495 Pierre-Bénite cedex, France  
¶UMR 5239 'Pathologie des Cellules Lymphoïdes',  
Lyon, France  
\*\*Department of Haematology, Centre Léon Bérard,  
69008 Lyon, France  
Correspondence: Stéphane Dalle.  
E-mail: stephane.dalle@chu-lyon.fr

E. BATHELIER\*  
L. THOMAS\*  
B. BALME\*†  
B. COIFFIER‡  
G. SALLES‡¶  
F. BERGER†¶  
M. FFRENCH§¶  
C. SEBBAN\*\*  
P. BIRON\*\*  
S. DALLE\*

## References

- 1 Willemze R, Jaffe ES, Burg G et al. WHO–EORTC classification for cutaneous lymphomas. *Blood* 2005; **105**:3768–85.
- 2 Thomas X, Le QH, Danaila C et al. Bone marrow biopsy in adult acute lymphoblastic leukemia: morphological characteristics and contribution to the study of prognostic factors. *Leuk Res* 2002; **26**:909–18.
- 3 de la Fouchardiere A, Balme B, Chouvet B et al. Pathological and clinical correlations in primary cutaneous B-cell lymphomas: a series of 44 cases. *Ann Pathol* 2005; **25**:8–17.
- 4 de la Fouchardiere A, Balme B, Chouvet B et al. Primary cutaneous marginal zone B-cell lymphoma: a report of 9 cases. *J Am Acad Dermatol* 1999; **41**:181–8.
- 5 Bailey EM, Ferry JA, Harris NL et al. Marginal zone lymphoma (low-grade B-cell lymphoma of mucosa-associated lymphoid tissue type) of skin and subcutaneous tissue: a study of 15 patients. *Am J Surg Pathol* 1996; **20**:1011–23.

- 6 Zinzani PL, Magagnoli M, Galieni P et al. Nongastrointestinal low-grade mucosa-associated lymphoid tissue lymphoma: analysis of 75 patients. *J Clin Oncol* 1999; **17**:1254.
- 7 Thieblemont C, Bastion Y, Berger F et al. Mucosa-associated lymphoid tissue gastrointestinal and nongastrointestinal lymphoma behavior: analysis of 108 patients. *J Clin Oncol* 1997; **15**:1624–30.
- 8 Thieblemont C, Berger F, Dumontet C et al. Mucosa-associated lymphoid tissue lymphoma is a disseminated disease in one third of 158 patients analyzed. *Blood* 2000; **95**:802–6.
- 9 Zucca E, Conconi A, Pedrinis E et al. Nongastric marginal zone B-cell lymphoma of mucosa-associated lymphoid tissue. *Blood* 2003; **101**:2489–95.

Key words: B-cell lymphoma, bone marrow, cutaneous lymphoma, MALT lymphoma, marginal zone lymphoma, retrospective study

Conflicts of interest: none declared.

## Pachyonychia congenita type 2: abnormal dentition extending into adulthood

DOI: 10.1111/j.1365-2133.2008.08662.x

SIR, Pachyonychia congenita (PC) is a group of hereditary disorders characterized by hypertrophic nail dystrophy and associated ectodermal features.<sup>1</sup> Two main clinical syndromes have been distinguished.<sup>2</sup> In PC type 1 (PC-1; Jadassohn–Lewandowsky syndrome, OMIM 167200) pachyonychia is associated with focal palmoplantar keratoderma (PPK), follicular keratoses and oral leukokeratosis. In PC type 2 (PC-2; Murray–Jackson–Lawler syndrome, OMIM 167210) associations include multiple pilosebaceous cysts. Focal PPK in PC-2 may be milder than in PC-1, and follicular keratoses, bushy eyebrows, angular cheilosis, hoarseness and (in children) unruly hair can also occur. Mutations in keratins have been found to be the molecular basis for both these disorders, affecting one of the paired keratins of specialized epidermis, K6a/K16 (PC-1) and K6b/K17 (PC-2).<sup>3,4</sup>

One of the striking features of PC-2 is the frequent first presentation with primary dentition erupted at birth (prenatal or natal) or within the first 30 days of life (neonatal). Frontal teeth are typically affected; they are soft, friable, and said to be prone to caries, usually being lost within the first few months of life.<sup>5–7</sup> In addition to natal teeth, early multiple tooth development at 4–5 months and, in one case, early natal tooth loss without immediate permanent tooth replacement, have been reported.<sup>4</sup>

In some cases, second primary teeth, nonpermanent teeth occurring after the loss of natal teeth, will develop in addition to the natal teeth but have been thought to be ultimately replaced by normal permanent teeth during childhood. Histologically, the polypean dental papillae of these natal teeth show mucosal hyperplasia and irregular rete ridge proliferation. Cytoplasmic vacuolization and oedema are seen in the

upper and spinous layers of the mucosa. Irregular osteodentine-like structures with cell inclusions and interglobular dentine are seen.<sup>8</sup> K17 expression has been described in the early stages of epidermal appendage development<sup>9</sup> and in the predominantly hard portion of the hair shaft,<sup>10</sup> but its expression in tooth progenitors is not known.

We now report for the first time possible effects on adult as well as infantile dentition of PC-2. We studied a multi-generation family with PC-2 due to a heterozygous missense mutation in the helix initiation motif of K17 (Asn92Asp) presenting with classical features of dystrophic nails, focal plantar keratoderma, multiple epidermal cysts, abnormal eyebrow and body hair (pili torti) and natal teeth.<sup>3</sup> Of 18 affected members over two generations whom we were able to interview, seven reported having either full or upper dentures fitted in their late teenage years due to 'crumbling' and exaggerated friability of their adult teeth. There was no history of increased caries. All affected patients had initially been treated with multiple crowns to prevent the disintegration of their teeth, without benefit. This history is suggestive of either enamel loss or attrition, but it has not been possible directly to assess any affected teeth. By contrast, none of their nine unaffected siblings had dentures or any similar dental problems.

Although the premature loss of primary teeth in conjunction with early eruption may be of no clinical significance, the loss of primary or permanent teeth in the absence of trauma should not be overlooked by the clinician.<sup>11</sup> Nontraumatic early loss of adult dentition is usually caused by caries or destructive periodontal disease. It is possible that the abnormal dentition in PC-2 may be a result of dentine abnormality, which is nonkeratin related, instead of a keratin-related enamel abnormality.

Abnormalities in adult teeth have not previously been described in PC-2. However, we were able to obtain a history only of unusual increased friability, suggesting a dentine abnormality, and not of caries. Dental friability has not previously been noted and as only some members were affected, it may be multifactorial with K17 mutation contributing indirectly. The effect might alternatively be specific to the Asn92Asp mutation.

Pending further evidence, we recommend that dermatologists caring for children with PC-2 should bear in mind a possible effect on permanent dentition and consider appropriate dental examination and care. Moreover, the presence in PC-2 of structurally abnormal, premature teeth and possibly adult teeth suggests that K17-expressing keratinocytes play an important role in odontogenesis and tooth eruption: this is an area for further study.<sup>3</sup>

## Acknowledgments

This work was supported by a grant from Medical Research Scotland. The McLean laboratory is supported by DEBRA UK and the Pachyonychia Congenita Project (<http://www.pachyonychia.org/>).

\*Department of Dermatology, Southern General Hospital, Glasgow G51 4TF, U.K.

†Section of Squamous Cell Biology and Dermatology, Division of Cancer Sciences and Molecular Pathology, University of Glasgow, Glasgow G12 8QQ, U.K.

‡Epithelial Genetics Group, Human Genetics Unit, University of Dundee, Dundee, U.K.

E-mail: m.zamiri@clinmed.gla.ac.uk

M. ZAMIRI\* †

W.H.I. McLEAN ‡

M.B. HODGINS †

C.S. MUNRO\*

## References

- 1 Stevens HP, Kelsell DP, Bryant SP et al. Linkage of an American pedigree with palmoplantar keratoderma and malignancy (palmoplantar ectodermal dysplasia type III) to 17q24. Literature survey and proposed updated classification of the keratodermas. *Arch Dermatol* 1996; **132**:640–51.
- 2 Gorlin RJ, Pindborg JJ, Cohen MM. *Syndromes of the Head and Neck*. New York: McGraw-Hill, 1976.
- 3 McLean WHI, Rugg EL, Lunny DP et al. Keratin 16 and keratin 17 mutations cause pachyonychia congenita. *Nat Genet* 1995; **9**:273–6.
- 4 Leachman SA, Kaspar RL, Fleckman P et al. Clinical and pathological features of pachyonychia congenita. *J Invest Dermatol Symp Proc* 2005; **10**:3–17.
- 5 Clementi M, Cardin de Stefani E, Dei Rossi C et al. Pachyonychia congenita Jackson–Lawler type: a distinct malformation syndrome. *Br J Dermatol* 1986; **114**:367–70.
- 6 Feinstein A, Freidman J, Schewach-Millet M. Pachyonychia congenita. *J Am Acad Dermatol* 1988; **19**:705–11.
- 7 Munro CS. Pachyonychia congenita: mutations and clinical presentations. *Br J Dermatol* 2001; **144**:929–30.
- 8 Anneroth G, Isacson G, Lagerholm B et al. Pachyonychia congenita. A clinical, histological and microradiographic study with special reference to oral manifestations. *Acta Derm Venereol (Stockh)* 1975; **55**:387–94.
- 9 McGowan KM, Coulombe PA. Onset of keratin 17 expression coincides with the definition of major epithelial lineages during mouse skin development. *J Cell Biol* 1998; **143**:469–86.
- 10 McGowan KM, Coulombe PA. Keratin 17 expression in the hard epithelial context of the hair and nail, and its relevance for the pachyonychia congenita phenotype. *J Invest Dermatol* 2000; **114**:1101–7.
- 11 Hartsfield JK Jr. Premature exfoliation of teeth in childhood and adolescence. *Adv Pediatr* 1994; **41**:453–70.

Key words: abnormal dentition, pachyonychia congenita type 2

Conflicts of interest: none declared.

---

## No association between HLA-B and cutaneous reactions to sulphonamides in human immunodeficiency virus-infected patients

DOI: 10.1111/j.1365-2133.2008.08660.x

STR, Sulphonamides are commonly used antibiotic drugs. The sulphonamide family includes drugs used to treat the most common opportunistic infections in patients with AIDS. Their use is complicated by the unusually high rate of cutaneous