

MICROBIC DISSOCIATION IN THE ACID-FAST BACILLI
WITH SPECIAL REFERENCE TO THE
BIOLOGICAL CHARACTERS AND VIRULENCE
OF THE
BACILLUS OF CALMETTE AND GUÉRIN (B.C.G.)

BY

RALPH STOCKMAN BEGBIE,

M.B., Ch.B., D.P.H., D.T.M.& H.

A T H E S I S

submitted for the degree of Doctor of Medicine,

Edinburgh University, March 1931.



TABLE OF CONTENTS.

Introduction	p. 1.
Brief Review of the Work of Calmette and Guérin on B.C.G.	p. 6.
The Results of a Study of B.C.G. by Petroff, Branch and Steenken	p. 9.
Rough or 'R' Form	p. 12.
Pathogenicity of 'R' Form	p. 12.
Smooth or 'S' Colony	p. 14.
Pathogenicity of 'S' Form	p. 14.
Transmutation of 'R' to the 'S' Type of Colony	p. 18.
Personal Observations on B.C.G.	p. 18.
Pathogenicity Experiments on Guinea-pigs ..	p. 19.
'R' Type of Growth	p. 20.
'S' Type of Growth	p. 28.
The Intermediate Type of Growth - Umbilicated Colony	p. 36.
Pathogenicity of Subculture of B.C.G. - Undissociated	p. 39.
Pathogenicity Experiments with a Fresh Culture of B.C.G.	p. 45.
Tables	pp. 23a, 27a, 27b, 32a, 32b, 35a, 35b, 37a, 38a, 41a, 44a, 45a and 48a.
Evidence of Microbic Dissociation of the Smegma Bacillus and One of Clegg's Lepra Bacilli	p. 49.
Summary	p. 50.
Conclusions	p. 54.
References	p. 57.
Illustrations	pp. 58 to 70.
Author's Publications	p. 71.
Acknowledgements	p. 72.

INTRODUCTION.

Microbic dissociation is a term including several types of variation from the known "normal" of a species of micro-organism, and is defined by Hadley (1) "as embracing those distinctly transformatory processes occurring in bacterial cultures, in vitro or in vivo, through which there arise one or more new culture forms which differ from the parent type, and which (1) may persist for a variable time in an apparently stable state, or (2) may become transformed into still another culture type, or (3) may revert to the original form".

He deals with the extent of the dissociative phenomena in a recent monograph (2), stating among examples:-

1. The production of secondary colonies, manifestly different from the original growth on a background of old or dying culture.
2. The production of different types of colony by various organisms.
3. The non-agglutinative, or spontaneously agglutinative growth of certain organisms.

4. The power of certain organisms to adapt themselves to grow in broth containing antiseptics or other unusual substances, which are either lethal or inhibitory to the original type.
5. The loss or gain of capsules by certain organisms.
6. The changes of virulence of cultures in vitro or in the bodies of immune or naturally refractory animals.
7. The changes in type and biochemical and serological properties of organisms when grown in, or subjected to, the action of homologous immune serum, or normal serum if it is bactericidal to the organisms concerned.
8. Serological differences of culture and changes of biochemical reactions of different colonies in a single pure line.
9. The possible connection with the generation from normal cultures of filter-passing forms of bacteria.
10. That dissociation, and resulting so-called rough culture production, is responsible for resistance against the bacteriophage.

The significance of microbial dissociation is still imperfectly understood.

Evidence of dissociation in a culture can be found on plating a suspension prepared from it; two or more types of colony develop. Those originally described by Arkwright are:-

1. S. Smooth type of colony - with circumscribed area of growth, dome-like in structure, slimy consistence, and emulsifying in physiological saline to form a stable suspension.
2. R. Rough type of colony - very irregular in appearance, friable and dry, forming an unstable suspension in physiological saline.
3. I. Intermediate types of colonies which are sometimes seen.

Since Koch's discovery of the Tubercle Bacillus in 1882, efforts have been made to find a specific remedy for tuberculosis and a vaccine which would give effective protection against infection. The effort to find a specific remedy has so far been unsuccessful, but in recent years Calmette and Guérin have claimed to have produced a form of tubercle bacillus, B.C.G., which is capable of producing a distinct/

distinct immunity when administered orally in specified doses to infants within a few days after birth, and which is nevertheless incapable of producing progressive tuberculosis in the recipient. This claim has been founded on experimental inoculation of animals and supported by statistical evidence following oral administration to infants. The statistical evidence, however, has been shown to be incomplete, and the results of animal inoculation with cultures of B.C.G. by independent workers have not been uniform.

In his "General Review of Experimental Infection and Immunisation against Tuberculosis", Long (3) has given an account of the progress of experimental work since Trudeau in 1894 vaccinated rabbits with avian tubercle bacilli and then inoculated them with attenuated human tubercle bacilli in the anterior chamber of the eye (4); this was the first sustained work on vaccination. Trudeau found that in vaccinated animals there was an immediate inflammatory reaction to the second inoculation lasting for about a fortnight and usually healing, a result never seen in unvaccinated controls, but the immunity conferred was only relative and uncertain. He regarded hypersensitivity as an index of resistance, and found that although animals vaccinated with dead tubercle bacilli were/

were hypersensitive, the eye lesion following inoculation with living organisms progressed to total destruction. Increased resistance to tuberculosis following vaccination with tubercle bacilli attenuated by different methods has since been demonstrated by other workers, numerous attempts having been made to find a suitable vaccine for cattle.

The conclusions arrived at by Krause (5) were as follows:-

- (a) Specific immunity exists only in animals with tuberculosis produced by the injection of living tubercle bacilli.
- (b) It first appears on the development of palpable foci.
- (c) It only persists as long as the infection remains, waning as the lesion heals.
- (d) It increases with increase in activity and spread of the infection.
- (e) It probably disappears with enucleation of all foci.
- (f) It varies directly with the virulence of the vaccinating organism.
- (g) The development of allergy is directly associated with the development of immunity, but immunity persists even when tuberculin/

tuberculin sensitivity is at a low ebb.

BRIEF REVIEW OF THE WORK OF
CALMETTE AND GUÉRIN ON B.C.G.

Since 1907 Calmette and Guérin have carried out extensive experiments on cattle. In the first place they found that sensitivity to tuberculin and a relative immunity to tubercle bacilli could be obtained by the oral administration of small graduated doses of tubercle bacilli, and that following this method of administration, no living organisms could be found in any lymph glands after three to four months, whereas on intravenous administration, living tubercle bacilli could be recovered from bronchial and mediastinal lymph glands after ten months (6). They then investigated the effect of growing a bovine strain of tubercle bacilli on glycerol potato medium to which had been added sterile ox bile (7). The first culture on this medium was more virulent to guinea-pigs than the original strain but after fifteen subcultures the virulence diminished and an intraperitoneal injection in a guinea-pig produced a localised lesion, the animal surviving for five months or longer. On subcutaneous injection of 1 mg. in the thigh of guinea-pigs, the inguinal glands enlarged but remained discrete, and sometimes a small localised abscess formed which burst/

burst and then healed up, but no generalised tuberculosis resulted. The forty-second subculture gave similar results in guinea-pigs, but was virulent to horses. In cattle, however, results similar to those obtained with guinea-pigs were observed and experiments were carried out on calves. An intravenous injection of virulent tubercle bacilli which was fatal to controls produced an immediate febrile reaction followed by perfect recovery in calves which had received a vaccinating dose of B.C.G. eight months previously. Nevertheless virulent organisms were found in the bronchial and mediastinal lymph glands, the tuberculin test was positive, and many months after infection tuberculosis occurred in some of the vaccinated animals. This was interpreted by Calmette as evidence of waning immunity. In doses of 100 mg., however, the fifteenth subculture on glycerol-bile-potato medium did not produce death in calves, whereas 5 mg. of the original strain was fatal in thirty days. From experiments with later subcultures it was found that on administration of virulent organisms intravenously in vaccinated cattle, the excretion of the organisms by the bowel commenced soon after such inoculation and that cattle suffering from tuberculosis gave similar results, whereas non-tuberculous cattle receiving virulent/

virulent organisms intravenously only excreted them by the bowel during the late febrile stages of the disease.

In summarising the work on B.C.G. in 1924 (8), Calmette and Guérin stated that after thirteen years' repeated subculture of the original bovine strain on glycerol-bile-potato every fifteen days, the culture was avirulent to all animals even in large doses, and did not produce tuberculosis however administered. Moreover, if subcultured on any other medium it still remained avirulent. On injection of 3 mg. subcutaneously in guinea-pigs, small local abscesses formed which burst and healed, no spread occurred and the tuberculin test became positive and remained so for about six months. On vaccinating cattle subcutaneously a small localised nodule formed which did not suppurate but which remained palpable from ten to eighteen months during which time the tuberculin test was positive, and the animals did not develop tuberculosis on injection of virulent organisms.

In laboratory animals, rabbits and guinea-pigs, vaccination did not confer complete immunity, but the disease produced on inoculation with virulent tubercle bacilli was of a chronic type, and the vaccine itself never produced tuberculosis.

Vaccination of infants with B.C.G. by the mouth has/

has been carried out since 1921. Statistics brought forward by Calmette supporting the method have been shown by Greenwood, Rosenfeld, and Petroff to be incomplete and based on errors. Recently the avirulence of the organism has been disputed by Petroff, Watson, and others "who observed not only definite tuberculous changes in guinea-pigs inoculated with B.C.G., but were able to pass the disease from animal to animal and by such passage to increase its virulence" (9).

THE RESULTS OF A STUDY OF B.C.G. BY
PETROFF, BRANCH, AND STEENKEN. (10).

Three cultures were examined; one was obtained from Dr E.A.Watson in Ottawa, one from Dr Lawrason Brown, and one from Dr Calmette.

Commencing with Dr Watson's strain subcutaneous inoculations were given to eight guinea-pigs, two receiving 2 mg., two 4 mg., two 8 mg. and two 16 mg., dry weight suspended in saline. One of each pair was killed on the 84th day; all had definite tubercles in lymphatic glands and spleen; in addition one had tubercles in the lungs and liver and one had involvement of the liver. Acid-fast bacilli were present in the lesions/

lesions. Of the four remaining guinea-pigs, the one which had received 4 mg., died on the 165th day from generalised tuberculosis, and the one which had received 16 mg. died on the 196th day from the same cause. The intracutaneous tuberculin test was positive in all guinea-pigs on the 50th day. The remaining two guinea-pigs were tested again on the 244th day and gave doubtful reactions. They were killed and a fibrous mass at the site of inoculation and one or two depressed areas in the liver were found, but no other evidence of tuberculosis was present.

Attempts were made to raise the virulence of the strains received from Dr Lawrason Brown and Dr Calmette by animal passage, and resulted in the production of a strain which produced generalised tuberculosis in guinea-pigs and rabbits and which on culture resembled the 'S' form of colony described later.

Nine guinea-pigs were inoculated with the strain obtained from Dr Calmette in doses varying from 1 to 10 mg., and up to the time of writing six had died or had been killed. One showed generalised tuberculosis, three showed lesions in internal organs and two showed local lesions only. The other guinea-pigs were still alive after 212 days. On peroral administration of 15 mg. two out of four guinea-pigs showed lesions in the/

the lungs, one probably dying from this cause.

The varying nature of the results suggested to Petroff that the cultures consisted mainly of avirulent organisms, but that virulent organisms were also present. Acting on this assumption and on the knowledge of the recent work on microbial dissociation steps were taken to separate the virulent from the avirulent organisms.

In the first place it had been noted that when B.C.G. was inoculated on Sauton's fluid medium the growth consisted of small raised wrinkled islands surrounded by a veil-like pellicle. Some of this growth was removed, emulsified in physiological saline of pH 7.8, filtered through two layers of "Whatman No.5" sterile filter, paper and the filtrate inoculated on plates of Petroff's egg medium containing gentian violet (1 in 20,000 parts), which were sealed by tight-fitting rubber bands to prevent dehydration and contamination. At the end of forty-eight days single colonies appeared, a few of which differed from the majority, and by picking off single colonies and again emulsifying in saline and plating out several times, pure cultures of two distinct forms of colony were obtained, corresponding in structure to the Rough and Smooth forms originally noted by Arkwright among other micro-organisms.

Rough/

Rough or 'R' Form.

On examination the colony was found to be very waxy in appearance with large raised folds, smooth on the surface, starting from the centre and running towards the periphery. The periphery was clean cut, rounded and slightly raised and did not show any tendency to spread over the medium. The growth was difficult to emulsify in saline of pH 7.2. Growth was readily obtained in glycerol beef broth (11) and in Sauton's medium but not in Proskauer and Beck's alkaline synthetic medium.

When a filtered suspension was inoculated on glycerol-bile-potato medium in Petri dishes the colonies at first were small, smooth and round, and remained so for the first month. Between the fourth and sixth week a small papilla appeared at the edge of the colony, and gradually covered the whole surface. In the 2nd or 3rd month several secondary papillae developed, and the appearance was changed to that of the mature 'R' form. An interesting point is that when the colony surface was perfectly smooth it was easy to emulsify the growth in saline, whereas in the later stages it was impossible to emulsify the growth entirely.

Pathogenicity of 'R' Form.

1. Inoculation of 2 mg. subcutaneously in the groin of guinea/

guinea-pigs produced a local abscess and enlargement of the corresponding inguinal glands, but the whole condition subsided in three months. Two animals which were killed after 328 days showed no pathological changes of tuberculosis.

2. Inoculation into the left ventricle was carried out in three guinea-pigs, doses of 1.25 - 2 mg. being used. One died on the 30th day from intercurrent disease and showed no macroscopic evidence of tuberculosis. The second died on the 266th day of a tuberculin allergic reaction, following a skin test, and showed well marked tuberculosis of the liver and spleen. The third died on the 375th day of generalised tuberculosis. On inoculating a guinea-pig subcutaneously with triturated diseased tissue from the third guinea-pig, only a local lesion and involvement of the local lymph glands were found on the death of the animal from pneumococcal pneumonia on the 41st day.
3. Intra-testicular inoculation of 2.5 mg. produced tuberculosis of the inoculated testis, inguinal and iliac lymph glands and spleen in two guinea-pigs which were slaughtered on the 51st and 75th days respectively.
4. Intra-ocular inoculation of 0.25 mg. in three guinea-pigs resulted in tuberculous lesions of the selected eye, but no dissemination of tuberculosis occurred/

occurred.

Rabbits: Inoculation by intra-cardiac, intra-spinal and intravenous routes did not cause tuberculosis, and intra-ocular inoculation only caused destruction of the eye.

Smooth or 'S' Colony.

This colony had many smooth, irregular wrinkles which did not appear waxy; the centre was raised, and the surface sloped gradually towards the periphery which was irregular, and at some points extending over the medium. The growth was readily emulsified in saline of pH 7 - 7.2, and the organism grew readily on glycerol broth, Sauton's fluid medium, and Proskauer and Beck's alkaline synthetic medium. On glycerol-bile-potato, however, no visible growth appeared, but scrapings from a twenty-six days old culture on this medium, when inoculated on gentian-violet egg, yielded growth. After forty-one days incubation on glycerol-bile-potato, scrapings from the surface of the medium produced tuberculosis in guinea-pigs on subcutaneous inoculation, and subcultures from scrapings on gentian violet egg medium also produced tuberculosis in guinea-pigs.

Pathogenicity of 'S' Form.

Subcutaneous/

Subcutaneous inoculation.

Four guinea-pigs received 0.25 mg. One died on the 51st day from otitis but showed tuberculous changes at the site of inoculation and in the spleen, liver, and lungs; another died on the 103rd day from generalised tuberculosis; the third died on the 105th day from otitis, and showed tuberculosis of the lymph glands, liver and lungs; the fourth was alive after ten months.

A second group of four guinea-pigs were inoculated with 5 mg. One died on the 21st day from otitis and showed well marked tubercular changes in the lymph glands, omentum, spleen and liver; the second died on the 103rd day from similar changes; the third died on the 151st day from generalised tuberculosis; the fourth still survived at the end of ten months.

Two guinea-pigs received 1 mg. One died from an undetermined cause on the 33rd day, but showed tubercular changes of the omentum, liver, spleen, lungs and kidney; the other died on the 103rd day from generalised tuberculosis. Two guinea-pigs received 2 mg. and one died on the 33rd day, cause of death undetermined, but tuberculosis affecting the site of injection, lymph glands, spleen, and liver was present, and on inoculating guinea-pigs with emulsions of diseased/

diseased tissues, generalised tuberculosis resulted. The other died on the 109th day from generalised tuberculosis.

Intra-cardiac inoculation.

Three guinea-pigs were inoculated with doses varying from 1.25 to 2 mg. into the left ventricle. One died on the 26th day from snuffles but generalised tuberculosis was present, the second died on the 27th day from generalised tuberculosis, and the third was slaughtered when moribund, on the 36th day, and was found to have generalised tuberculosis.

Intra-testicular inoculation.

In doses of 1.25 mg. generalised tuberculosis was produced in two guinea-pigs and was transmissible in series.

Intra-ocular inoculation.

In doses of 0.2 to 0.25 mg. into the vitreous humour and the anterior chamber of the right eye of three guinea-pigs, generalised tuberculosis resulted, killing them on the 42nd, 76th, and 91st day respectively.

Experiments on Rabbits.

Intra-ocular inoculation.

Complete involvement of the inoculated eye resulted in two rabbits following injection of 0.1 mg..

Intra/

Intra-cardiac inoculation.

Two rabbits received 0.8 mg. On slaughter on the 86th and 87th days respectively, one was found to have a tuberculous pyelitis and tubercles in the kidney, lungs, and pericardium: the other showed a few tubercles in one kidney only.

Intravenous inoculation.

In the course of preparation of an anti-S serum, rabbits which had received a large dose of heat-killed organisms were one month later inoculated with doses of living organisms varying from 2.5 - 5 mg. Two animals died from undetermined causes on the 73rd and 106th days and one was slaughtered on the 66th day: two showed tubercles of lungs and kidney, and a few tubercles were present in the lungs of the third.

Intra-spinal inoculation.

In doses of 0.16 mg. no clinical signs of a lesion were visible on two rabbits after five months.

The type of lesion obtained.

Mononuclear tubercles with, or without, caseation or surrounding fibrosis were the prevalent lesions, but giant cell formation was occasionally seen after inoculation with the undissociated culture and the 'R' strain. No giant cell formation was noted after inoculation with the 'S' strain.

Transmutation/

Transmutation of 'R' to the 'S' type of colony.

Cultivation in a medium containing anti-R serum resulted in an increase of virulence of the 'R' strain after several subcultures in the medium, and a colony change from the 'R' to 'S' type.

PERSONAL OBSERVATIONS ON B.C.G.

In January 1929 a culture of B.C.G. was received from the Pasteur Institute, Paris. It was a heavy growth on a glycerol-bile-potato slope, very rough on the surface, dry and friable, and light brown in colour. An emulsion was prepared from it in sterile saline. This was filtered through two layers of sterile Whatman No. 5 filter paper, and the filtrate inoculated on to plates of Petroff's gentian violet egg medium, rubber bands being used to prevent contamination and drying. At the end of six weeks, growth was apparent on a few plates and after ten weeks one plate showed three distinct forms of colony. These were:-

1. A colony consisting of a raised central dome and a spreading fringe or margin. The surface of the central dome was smooth and the surface of the fringe of the colony consisted of numerous small, smooth, round elevations. This colony resembled an 'S' type, but did not/

not fully conform with the description of the 'S' type demonstrated by Petroff.

2. A smaller type of colony with an umbilicated centre and an irregular narrow fringe, which did not spread over the medium. This appeared to be an intermediate type of colony.
3. One colony was obtained which was composed of heaped up coils without a fringe, and corresponded to the 'R' type of colony described by Petroff.

On the 25th of April, slopes of Dorset's egg medium were inoculated from each type of colony. Growth was very slow; none was visible for a month, and from the scanty growth obtained, subcultures were made on the 25th of July and again on the 25th of October. It was found advisable to plug the tubes with melted paraffin wax to prevent drying of the medium. On each subculture there was a lag of about a month before growth was visible. From the subcultures of the 15th of October plates of Petroff's medium were inoculated and the colonies obtained were true to type.

PATHOGENICITY EXPERIMENTS ON GUINEA-PIGS.

Doses of organisms were made up by standardising emulsions to an opacity equal to that of a suspension prepared/

prepared by emulsifying dried organisms in the proportion of 2 mg. to 1 c.c. of sterile saline.

'R' Type of Growth.

Twelve guinea-pigs were weighed and tested by an intra-cutaneous injection of 1 in 500 Old Tuberculin. All of them were tuberculin negative.

The first six received 2 mg. of 'R' culture suspended in 1 c.c. of saline by injection into the left ventricle and the remainder received 2 mg. subcutaneously in the left groin. The condition and weights of the animals were noted weekly, and tuberculin reactions ascertained until positive. Surviving guinea-pigs were killed after sixty nine days, and post-mortem examinations were made.

Intra-cardiac inoculation of 2 mg. 'R' culture.

(See Table I).

Guinea-pig No. 1.

Weight before inoculation was 26 ozs. and remained steady throughout. The tuberculin test was positive 19 days after inoculation, but no other evidence of tuberculosis was detected and the animal appeared healthy before it was killed on the 69th day. Its weight then was 25 ozs.

On post-mortem examination, no macroscopic or microscopic evidence of tuberculosis was found.

Guinea/

Guinea-pig No. 2.

This guinea-pig died 18 days after inoculation from some intercurrent disease.

Post-mortem examination showed acute congestion of internal organs but no evidence of tuberculosis was found.

Guinea-pig No. 3.

Death occurred 65 days after inoculation. Before inoculation its weight was 20 ozs., and it fell steadily to 14 ozs., while the general condition became poor. On the 33rd day it developed a transient paralysis of the hind limbs which persisted for a week. The tuberculin test was positive on the 19th day.

No macroscopic lesions could be found on post-mortem examination in the brain, spinal cord, or internal organs, but slight general congestion was present. On microscopic examination, small miliary tubercles were found in the spleen, liver, and subcapsular area of the kidney, but no acid-fast organisms were found. The lesions were aggregations of endothelial cells apparently in a process of healing, and death could not with certainty be attributed to tuberculosis.

Guinea-pig No. 4.

Weight before inoculation 30 ozs. The tuberculin/

tuberculin test was positive on the 26th day after inoculation. The weight diminished slightly, and the animal died on the 46th day, weighing 27 ozs.

On post-mortem examination, the lymphatic glands were enlarged in all areas and the left axillary gland was inflamed and contained caseous pus. There was blood stained serous effusion into the pleural and peritoneal cavities, the spleen and liver were enlarged, and small tubercles were visible on the surface of the liver. The lungs were not affected.

On microscopic examination, small miliary tubercles were found in the spleen, liver, and peritoneum. They were composed of lymphocytes and endothelial cells with degeneration in the centres. Acid-fast bacilli were present in small numbers. Death was apparently due to generalised tuberculosis.

Guinea-pig No. 5.

Weight before inoculation was 27 ozs. The tuberculin test was positive on the 26th day after inoculation, and loss of weight was steadily progressive. The animal died on the 66th day weighing 18 ozs.

On post-mortem examination, the spleen was found to be greatly enlarged, and large areas of degeneration were present. The kidneys showed subperitoneal thickened/

thickened patches about 2 mm. in diameter, and the pericardium showed a nodule at the site of inoculation. The lower lobes of the lungs were consolidated.

On microscopic examination the spleen showed large amorphous areas of degeneration, and tubercles composed of lymphocytes and endothelial cells, but no acid-fast organisms were found. Tubercles were present in the kidney capsule, the pericardial nodule was composed of tuberculous granulation tissue with acid-fast bacilli, and the lungs showed patchy tuberculous consolidation. Death was attributed to chronic progressive tuberculosis.

Guinea-pig No. 6.

Weight before inoculation was 21 ozs.. The tuberculin test was positive on the 19th day after inoculation. The weight remained steady for a month and had slowly increased to 25 ozs. when the animal was killed on the 69th day.

Post-mortem examination showed a little patchy consolidation of the lungs. A few tubercles were present on the surface of the liver, and the spleen was slightly enlarged.

On microscopic examination a few small tubercles, composed mainly of endothelial cells were found in the spleen, liver, and lung, but no acid-fast bacilli were found/

232.
TABLE I.

B.C.G.

Subculture from R-colony Variant.

Intra-cardiac Inoculation of 6 Guinea-pigs.

(Dose - 2 mgs.)

Serial No. of Guinea-pig.	Weight in Ozs.		No. of days before Tuberculin Test positive	Day of Death	Organs in which Tuberculous lesions were found post-mortem.
	Before inoculation	At Death			
1	26	25	19	69*	Nil.
2	-	-	-	18	(Death from intercurrent disease).
3	20	14	19	65	Spleen, liver, subcapsular area of kidney.
4	30	27	26	46	All lymphatic glands. Abscess in left axillary lymph gland. Blood-stained serous effusion in pleura and peritoneum. Spleen, liver. (Acid-fast bacilli present).
5	27	18	26	66	Spleen, lungs, kidneys, pericardium. (Acid-fast bacilli present).
6	21	25	19	69*	Spleen, lung, liver.

*animal killed.

found. The lesions appeared to be of a resolving nature.

Subcutaneous inoculation of 2 mg. 'R' culture

(See Table II).

Guinea-pig No. 7.

Weight before inoculation was 19 ozs. The tuberculin test was positive after 19 days, and a localised abscess with enlargement of the inguinal gland was present at the site of inoculation. The abscess burst and discharged 7 days later, and from that time the lesion slowly receded, and the glands diminished in size. Before the animal was killed on the 69th day, they were barely palpable, and the weight was 24 ozs.

Post-mortem examination showed induration at the site of inoculation, and the inguinal gland was enlarged. There was no macroscopic evidence of tuberculosis of the internal organs. On microscopic examination the left inguinal gland was found to be definitely tubercular with central necrosis. Acid-fast bacilli were demonstrated. The spleen, liver, and lungs showed no change.

Guinea-pig No. 8.

Weight before inoculation was 24 ozs. The tuberculin test was positive after 26 days, and an abscess formed at the site of inoculation which burst on/

on the 28th day after inoculation. The glands in the left inguinal region were enlarged. The weight remained steady and was 24 ozs. when the animal was killed on the 69th day.

Post-mortem examination showed that two left inguinal glands contained caseous material, and the lungs showed consolidation of their bases, with pleurisy and adhesions at the right base. The spleen was not enlarged.

Microscopic examination showed tubercles in the lung composed of lymphocytes and endothelial cells, and well-marked thickening of the pleura. No acid-fast bacilli were found. No lesions were found in the spleen or liver.

Guinea-pig No. 9.

Weight before inoculation 22 ozs. The tuberculin test was positive after 19 days when a nodule had formed at the site of inoculation. The weight increased steadily, and the nodule gradually resolved. When killed the animal weighed 25 ozs.

Post-mortem examination showed some fibrous thickening at the site of inoculation, and softening of a left inguinal gland. The spleen was slightly enlarged, and small patches of consolidation were present in the lungs.

On/

On microscopic examination, definite tubercles were found in the spleen and lungs, composed of endothelial cells and a few lymphocytes, but no acid-fast bacilli were found. They appeared to be chronic resolving lesions.

Guinea-pig No. 10.

Weight before inoculation was 26 ozs. The tuberculin test was positive on the 19th day after inoculation when an abscess had formed at the site of inoculation, and the inguinal glands were enlarged. The local lesion spread, and formed a large abscess, which burst on the 47th day. The weight remained steady and was 26 ozs. when the animal was killed.

Post-mortem examination showed thickening at the site of inoculation, softening of the left inguinal glands and enlargement of a right inguinal gland. The spleen was enlarged and both lungs showed patches of consolidation.

On microscopic examination, tubercles were found in the spleen, and in the lungs, composed mainly of endothelial cells. Acid-fast bacilli were present in the spleen. The lesions appeared to be of a chronic non-progressive nature.

Guinea/

Guinea-pig No. 11.

On inoculation the animal was pregnant. After parturition on the 40th day the weight was 24 ozs. The tuberculin test was positive 19 days after inoculation, and a local nodule at the site of inoculation was palpable on the 26th day. An abscess formed, which burst on the 47th day when the left inguinal gland was enlarged. The weight before death was 27 ozs.

The animal was killed and at post-mortem examination slight thickening at the site of inoculation and some enlargement of the left inguinal lymph glands were present. No macroscopic or microscopic evidence of invasion of the internal organs was found.

Guinea-pig No. 12.

The weight before inoculation was 21 ozs. The tuberculin test was positive on the 19th day, at which time a nodule was present at the site of the inoculation, and a left inguinal gland was palpable. The weight remained steady, and a local abscess formed, bursting on the 45th day, and gradually healing after that date. When the animal was killed the weight had increased to 26 ozs., and glands in the left inguinal region were palpable.

On post-mortem examination, induration at the site of/

TABLE II.B.C.G.Subculture from R-colony Variant.Subcutaneous Inoculation of 6 Guinea-pigs.

(Dose - 2 mgs.)

Serial No. of Guinea- pig.	Weight in Ozs.		No. of Days be- fore Tubercul- :in Test positive	Day of Death	Lesions found post-mortem.
	Before in- :oculation	At Death			
7	19	24	19	69*	Abscess at site of inoculation. Local lymphaden- :itis. (Acid-fast bac- :illi present).
8	24	24	26	69*	Abscess at site of inoculation. Local lymphaden- :itis. Pleur- :isy with adhes- :ions.
9	22	25	19	69*	Nodule at site of inoculation. Local lymphaden- :itis. Spleen, lungs (microscopic tubercles).
10	26	26	19	69*	Abscess at site of inoculation. Enlarged inguin- :al glands on both sides. Spleen and lungs showed micro- :scopic tuber- :cles. (Acid-fast bac- :illi present).

TABLE II continued.B.C.G.Subculture from R-colony Variant.Subcutaneous Inoculation of 6 Guinea-pigs.

(Dose - 2 mgs.)

Serial No. of Guinea- pig.	Weight in Ozs.		No. of days be- fore Tubercul- :in Test Positive	Day of Death	Lesions found post-mortem.
	Before in- :oculation	At Death			
11	24	27	19	69*	Abscess at site of inoculation. Local lymphaden- :itis. (Acid- fast bacilli present).
12	21	26	19	69*	Abscess at site of inoculation. Local lymphaden- :itis. Tuber- :cles in spleen and lungs. (Acid-fast bac- :illi present).

*animal killed.

of inoculation and enlarged glands were found, the spleen was not enlarged, but the lungs showed one or two consolidated patches.

On microscopic examination, the lungs showed typical tubercles, composed mainly of lymphocytes, and the spleen showed similar tubercles with central necrosis and acid-fast bacilli. The lesions appeared to be active and progressive.

'S' Type of Growth.

The same procedure was followed with the 'S' as with the 'R' strain.

Twelve guinea-pigs were tested intra-cutaneously with Old Tuberculin in dilution of 1 in 500 and all were negative on the 10th of January. Six were inoculated with 2 mg. of 'S' culture suspended in 1 c.c. of saline into the left ventricle, and six received the same amount subcutaneously in the left groin. They were weighed and examined weekly, and tested with tuberculin until positive; surviving animals were killed after 67 days.

Intra-Cardiac Inoculation of 2 mg. 'S' Culture. (See Table III).

Guinea-pig No. 13.

Before inoculation the weight was 18 ozs. The tuberculin/

tuberculin test was positive on the 15th day, and the animal died 32 days after inoculation, its weight having diminished to 15 ozs.

On post-mortem examination, the spleen was found to be enlarged, pin-point white dots were seen on the surface of the liver, and the lungs were congested.

On microscopic examination, tubercles composed of mononuclear cells with acid-fast bacilli were seen in the spleen and liver, and perisplenitis was present. The lung section showed catarrhal exudate in the alveoli, and a few tubercles were seen, but no acid-fast bacilli were found. Death was due to generalised tuberculosis.

Guinea-pig No. 14.

Before inoculation the weight was 20 ozs. The tuberculin test was positive on the 15th day. On the 36th day an enlarged lymphatic gland was palpable in the left inguinal region, and on the 43rd day enlarged lymphatic glands were palpable in both groins and both axillae. The weight remained steady and on the 67th day was 21 ozs.

On post-mortem examination, the lymphatic glands throughout the body were found to be enlarged, the spleen was enlarged and soft; pin-point white dots were/

were present on the surface of the liver, and there was slight patchy consolidation of the lungs.

On microscopic examination, small mononuclear tubercles were present in the spleen, liver, and lung, but no acid-fast bacilli were found.

Guinea-pig No. 15.

Before inoculation the weight was 19 ozs. The tuberculin test was positive on the 22nd day. The animal grew feeble, its weight diminished, and it died 40 days after inoculation, weighing 14 ozs.

On post-mortem examination, the spleen was found to have enlarged and ruptured, death being due to haemorrhage into the peritoneal cavity. The kidneys were congested, and pyelitis was present; the lymph glands throughout the body were enlarged, and the lungs showed areas of consolidation. Tubercles were present on the pericardium at the site of inoculation.

On microscopic examination, tubercles were found in the spleen, liver, and kidney; extensive sub-pleural consolidation and tubercle formation was present in the lung, and acid-fast bacilli were found in the involved areas of the above organs. The tubercles were composed mainly of lymphocytes and death was attributed to generalised active tuberculosis.

Guinea/

Guinea-pig No. 16.

Before inoculation the weight was 27 ozs. The tuberculin test was faintly positive on the 22nd day. The weight diminished slightly and was 22 ozs. when the animal died on the 31st day after inoculation.

On post-mortem examination, congestion and patchy consolidation of the lungs was found, and a few pin-point white dots were visible on the surface of the liver; the spleen appeared to be normal.

On microscopic examination, tubercles were found in the spleen, liver, and lungs, and acid-fast bacilli were present. The tubercles were composed mainly of lymphocytes. Death was attributed to tuberculosis.

Guinea-pig No. 17.

Before inoculation the weight was 28 ozs. The tuberculin test was positive on the 15th day. The animal died on the 25th day weighing 25 ozs.

On post-mortem examination, the lymphatic glands were enlarged, the liver and spleen were enlarged and congested, and pin-point white dots were present on their surface. The lungs were congested, the pleura was thickened and inflamed, and blood stained serous effusion was present in the pleural cavities. No growth was obtained from spleen and pleural fluid on inoculation of blood-agar plates.

On/

On microscopic examination, tubercles and acid-fast bacilli were found in spleen, liver, and a lymph gland, necrosis was present in the lymph gland, and the lungs showed tubercles in the pleura and subpleural tissue with acid-fast bacilli. The tubercles were composed mainly of lymphocytes; death was attributed to generalised tuberculosis.

Guinea-pig No. 18.

The weight before inoculation was 23 ozs. The tuberculin test was faintly positive on the 22nd day. The weight diminished steadily, and the animal died on the 26th day weighing 18 ozs.

On post-mortem examination, congestion of internal organs was present, the spleen and liver were enlarged, and thick pus was present on the pericardium at the site of injection. Numerous acid-fast bacilli were found in the pus, and underlying the area a nodule was found in the heart wall about 2 mm. in diameter.

On microscopic examination, the nodule in the heart wall was seen to consist of tubercles which were packed with acid-fast bacilli. Tubercles with acid-fast bacilli were also found in the spleen, liver, and lungs, composed mainly of lymphocytes. There was therefore generalised tuberculosis, but the cause of death was probably the lesion in the heart wall produced by the incomplete/

TABLE III.B.C.G.Subculture from S-colony Variant.Intra-cardiac Inoculation of 6 Guinea-pigs.

(Dose - 2 mgs.)

Serial No. of Guinea- pig.	Weight in Ozs.		No. of days be- fore Tubercul- :in Test positive.	Day of Death	Organs in which Tuberculous les- :ions were found post-mortem.
	Before in- :oculation	At Death			
13	18	15	15	32	Spleen, liver, lungs. (Acid- fast bacilli present).
14	20	21	15	67*	All lymphatic glands. Spleen, liver, lung.
15	19	14	22	40	All lymphatic glands. Spleen, kidneys, lungs and pericardium. (Acid-fast bac- :illi present).
16	27	22	22	31	Spleen, liver, lungs. (Acid- fast bacilli present).
17	28	25	15	25	All lymphatic glands. Spleen, liver, lungs and pleura. Acid- fast bacilli present).

18/

* animal killed.

TABLE III continued.B.C.G.Subculture from S-colony Variant.Intra-cardiac Inoculation of 6 Guinea-pigs.

(Dose - 2 mgs.)

Serial No. of Guinea- pig.	Weight in Ozs.		No. of Days be- fore Tubercul- :in Test Positive	Day of Death	Organs in which Tubercul- :ous lesions were found post-mortem.
	Before in- :oculation	At Death			
18	23	18	22	26	Spleen, liver, lungs, heart- wall and peri- :cardium. (Acid-fast bac- :illi present).

TABLE III.

B.C.G.

Subculture from S-colony Variant.

Intra-cardiac Inoculation of 6 Guinea-pigs.

(Dose - 2 mgs.)

Serial No. of Guinea-pig.	Weight in Ozs.		No. of days before Tuberculin Test positive.	Day of Death	Organs in which Tuberculous lesions were found post-mortem.
	Before inoculation	At Death			
13	18	15	15	32	Spleen, liver, lungs. (Acid-fast bacilli present).
14	20	21	15	67*	All lymphatic glands. Spleen, liver, lung.
15	19	14	22	40	All lymphatic glands. Spleen, kidneys, lungs and pericardium. (Acid-fast bacilli present).
16	27	22	22	31	Spleen, liver, lungs. (Acid-fast bacilli present).
17	28	25	15	25	All lymphatic glands. Spleen, liver, lungs and pleura. Acid-fast bacilli present).

18/

* animal killed.

increased, and was 18 ozs. before slaughter on the 67th day.

On post-mortem examination, a small abscess was present at the site of inoculation, the spleen was enlarged and small pin-point nodules were present on the surface of the liver.

On microscopic examination, tubercles composed of lymphocytes and endothelial cells were present in the spleen, liver, and lung; acid-fast bacilli were found in the spleen only.

Guinea-pig No. 21.

Before inoculation the weight was 23 ozs. The tuberculin test was positive on the 15th day, and a large mass was palpable at the site of inoculation. The glands were palpable in both inguinal regions on the 43rd day, but the weight increased to 27 ozs. before the animal was killed on the 67th day.

On post-mortem examination, the superficial inguinal glands on both sides were enlarged, but no macroscopic lesions were found in the internal organs.

On microscopic examination, a few aggregations of large and small mononuclear cells were found in the lung, but no acid-fast organisms were seen. No lesions were found in the spleen or liver.

Guinea/

Guinea-pig No. 22.

Before inoculation the weight was 16 ozs. After 15 days the tuberculin test was positive, and there was a swelling with enlarged lymph glands at the site of inoculation. Later an abscess formed which ruptured on the 41st day, leaving an ulcer. The weight increased to 20 ozs. before the animal was killed 67 days after inoculation.

On post-mortem examination, the superficial inguinal glands were enlarged on both sides, and the site of inoculation was a fibrosed scar. No other macroscopic or microscopic evidence of tuberculosis was found.

Guinea-pig No. 23.

Before inoculation the weight was 16 ozs. The tuberculin test was positive on the 15th day, and a large mass was palpable at the site of inoculation. The weight increased slightly and was 20 ozs. on the 67th day.

On post-mortem examination, there was a fibrous mass at the site of inoculation with slight enlargement of the regional lymph glands, but there was no macroscopic or microscopic evidence of tuberculosis of the internal organs.

Guinea/

TABLE IV.B.C.G.Subculture from S-colony Variant.Subcutaneous Inoculation of 6 Guinea-pigs.

(Dose - 2 mgs.)

Serial No. of Guinea- pig.	Weight in Ozs.		No. of days be- fore Tubercul- :in Test Positive.	Day of Death	Lesions found post-mortem.
	Before in- :oculation	At Death			
19	20	20	15	67*	Induration at site of inocul- :ation with local lymphadenitis.
20	16	18	22	67*	Abscess at site of inoculation. Tubercles in spleen, liver and lung. (Acid-fast bac- :illi present).
21	23	27	15	67*	Enlargement of inguinal glands at site of inoc- :ulation.
22	16	20	15	67*	Abscess at site of inoculation leading to ulcer- :ation. Local lymphadenitis.
23	16	20	15	67*	Fibrosis at site of inocul- :ation with local lymphaden- :itis.

24/

* animal killed.

TABLE IV continued.B.C.G.Subculture from S-colony Variant.Subcutaneous Inoculation of 6 Guinea-pigs.

(Dose - 2 mgs.)

Serial No. of Guinea- pig.	Weight in Ozs.		No. of days be- fore Tubercul- :in Test Positive.	Day of Death	Lesions found post-mortem.
	Before in- :oculation	At Death			
24	17	20	15	67*	Fibrosis at :site of inocul- :ation with local lymphaden- :itis.

* animal killed.

Guinea-pig No. 24.

Before inoculation the weight was 17 ozs. The tuberculin test was positive on the 15th day, and a large mass was palpable at the site of inoculation. The weight increased to 20 ozs. before the animal was killed on the 67th day.

On post-mortem examination, there was a fibrous mass at the site of inoculation with slight enlargement of the regional lymphatic glands, but no macroscopic or microscopic evidence of tuberculosis of internal organs was found.

The 'Intermediate' Type of Growth - Umbilicated Colony.

Six guinea-pigs were tested by intra-cutaneous injection of 1 in 500 tuberculin and all were negative. The first three received 2 mg. of the intermediate strain in 1 c.c. of saline by intra-cardiac injection, and three received 2 mg. subcutaneously in the left groin. Surviving animals were killed after 99 days. (See Tables V and VI).

Intra-Cardiac Inoculation.Guinea-pig No. 25.

Before inoculation the weight was 30 ozs. The tuberculin reaction was indefinite on the 18th day but faintly positive on the 25th day. The weight remained/

remained steady, and was 30 ozs. when noted on the 99th day. The tuberculin test was strongly positive when applied two days earlier.

On post-mortem examination, two lymphatic glands in the right groin were enlarged, but no other evidence of tuberculosis was found.

On microscopic examination, the glands were found to contain microscopic tubercles consisting of large endothelial cells but no acid-fast organisms were found. The liver and spleen did not contain any lesions.

Guinea-pig No. 26.

This animal unfortunately died three days after injection from haemorrhage from the needle puncture into the pericardial cavity.

Guinea-pig No. 27.

Before inoculation the weight was $29\frac{1}{2}$ ozs. The tuberculin test was positive on the 25th day. The animal's weight remained steady, and was 30 ozs. on the 99th day. The tuberculin reaction was indefinite when retested on the 97th day.

On post-mortem examination, the lymph glands of the left and right inguinal and axillary regions were found to be enlarged and matted, there were white patches on the surface of the liver, but no microscopic

TABLE V.B.C.G.Subculture from "Intermediate" Colony Variant.Intra-cardiac Inoculation of 3 Guinea-pigs.

(Dose - 2 mgs.)

Serial No. of Guinea- pig.	Weight in Ozs.		No. of days be- fore Tubercul- :in Test Positive.	Day of Death	Organs in which Tuberculous lesions were found post- mortem.
	Before in- :oculation	At Death			
25	30	30	25	99 *	Enlarged lymphat- :ic glands in right groin.
26	-	-	-	3	(Death from haemorrhage following heart puncture).
27	29½	30	25	99*	Enlarged lymphat- :ic glands of axillary and in- :guinal regions.

* animal killed.

microscopic evidence of tuberculosis was found in the spleen, liver, or lungs.

Subcutaneous Inoculation. (See Table VI).

Guinea-pig No. 28.

Before inoculation the weight was 20 ozs. The tuberculin reaction was weakly positive 18 days after inoculation, but there was no palpable lesion at the site of inoculation before the 45th day when slight thickening could be detected. The weight remained steady, and was 22 ozs. before the animal was killed on the 99th day. The tuberculin test was strongly positive on the 97th day.

On post-mortem examination, fibrosis with a matted group of enlarged glands was found at the site of inoculation.

On microscopic examination, the glands were found to contain tubercles consisting of lymphocytes and endothelial cells, but no acid-fast bacilli were found. No other evidence of tuberculosis was present.

Guinea-pig No. 29.

Before inoculation the weight was 23 ozs. On the 27th day the tuberculin reaction was positive and slight induration at the site of inoculation with some enlargement of the regional lymphatic gland was palpable. Before slaughter the weight was 24 ozs. and/

TABLE VI.B.C.G.

Subculture from "Intermediate" Colony Variant.

Subcutaneous Inoculation of 3 Guinea-pigs.

(Dose - 2 mgs.)

Serial No. of Guinea- pig.	Weight in Ozs.		No. of days be- fore Tubercul- :in Test Positive.	Day of Death	Lesions found post-mortem.
	Before in- :oculation	At Death			
28	20	22	18	99*	Lymphatic glands at site of inoc- :ulation en- :larged and matted together.
29	23	24	27	99*	Fibrosis at site of inocul- :ation only.
30	26	33	25	99*	Nil.

* animal killed.

and the tuberculin reaction remained positive.

On post-mortem examination, localised fibrosis at the site of inoculation and enlargement of the right inguinal lymphatic gland were found.

On microscopic examination, the gland showed increase in the lymphocytes, but no definite tubercles and no acid-fast organisms. There was no other macroscopic or microscopic evidence of tuberculosis.

Guinea-pig No. 30.

Before inoculation the weight was 26 ozs. The tuberculin reaction was positive after 25 days, and a small nodule was present at the site of inoculation. The weight increased and was 33 ozs. on the 99th day. The tuberculin reaction was positive when retested on the 97th day.

On post-mortem examination, a fibrous mass was present at the site of inoculation, but no lymphatic glands were enlarged. The lung showed small areas of consolidation and, on microscopic examination, small areas of consolidation due to the aggregation of large endothelial cells were found, but no acid-fast organisms were seen.

PATHOGENICITY OF SUBCULTURE OF B.C.G.-- UNDISSOCIATED.

The original culture received from the Pasteur Institute in January 1929 was subcultured on Dorset's egg/

egg medium on the 27th of July 1929, incubated for eight weeks, and put aside.

On observing the results of inoculation of the 'R' and 'S' strains of dissociated culture, it was decided to inoculate guinea-pigs with the undissociated subculture.

Six guinea-pigs whose tuberculin reactions were found to be negative were inoculated with 2 mg. of the subculture, three by intra-cardiac route and three subcutaneously, on the 28th of January 1930. Observations and tuberculin tests were carried out as in the previous experiments.

Surviving guinea-pigs were killed on the 10th of May, i.e. after 102 days. The results are tabulated in Tables VII and VIII.

Intra-Cardiac Inoculation.

Guinea-pig No. 31.

Before inoculation the weight was $20\frac{1}{2}$ ozs. The tuberculin test was positive 11 days after inoculation. The animal lost weight steadily, and weighed 15 ozs. on the 31st day when it was seen to be very feeble. It died on the 33rd day.

On post-mortem examination, a fibrinous exudate was present in the peritoneal and pleural cavities, the spleen/

spleen was congested and slightly enlarged, and the lungs were consolidated.

On microscopic examination, lymphocytic hyperplasia was present in the spleen but no acid-fast organisms were found; the lungs were congested, a fibrinous pleurisy was present, but no definite tubercles or acid-fast bacilli were found. Death was probably due to the lung condition, but this was not definitely tuberculous.

Guinea-pig No. 32.

Before inoculation the weight was 21 ozs. The tuberculin test was positive on the 11th day. The weight remained steady, but lymphatic glands were palpable in both groins on the 39th day. The tuberculin test was positive, and the weight was 21 ozs. 102 days after inoculation when the animal was killed.

On post-mortem examination, the right inguinal lymphatic gland was enlarged, and petechial haemorrhages were present on the surface of the pleura.

On microscopic examination, tubercle formation was found in the spleen, lung, and right inguinal lymphatic gland, but no acid-fast bacilli were found. The tubercles were formed by large endothelial cells and lymphocytes.

Guinea/

TABLE VII.

B.C.G.Undissociated Subculture.8 Weeks' Growth on Dorset's Egg Medium.Intra-cardiac Inoculation of 3 Guinea-pigs.

(Dose - 2 mgs.)

Serial No. of Guinea- pig.	Weight in Ozs.		No. of days be- fore Tubercul- :in Test Positive.	Day of Death	Organs in which Tuberculous les- :ions were found post- mortem.
	Before in- :oculation	At Death			
31	20½	15	11	33	Pleura, periton- :eum, spleen, lung.
32	21	21	11	102 *	Inguinal glands, spleen, lung.
33	22	18	12	34	Liver (abscess), lung. (Acid- fast bacilli present).

*animal killed.

Guinea-pig No. 33.

Before inoculation the weight was 22 ozs. The tuberculin test was positive on the 12th day. For 25 days after inoculation the animal appeared to be in good condition and maintained its weight, but on the 31st day it weighed only 18 ozs. and was feeble. Death occurred 3 days later.

On post-mortem examination, a large abscess was found on the lower edge of the right lobe of the liver, with overlying peritonitis and adhesions to the colon and small intestine. There was about 2 c.c. of creamy pus in the abscess cavity, and on staining, acid-fast bacilli were abundant and no other organisms were seen. The lungs were congested and firm.

On microscopic examination, no evidence of tuberculous change was found in the spleen, but there was patchy consolidation of the lung with tubercle formation, though no acid-fast bacilli were seen. The liver abscess wall showed tuberculous tissue with acid-fast bacilli. Death was attributed to tuberculous abscess of the liver.

Subcutaneous Inoculation.Guinea-pig No. 34.

Before inoculation the weight was 24 ozs. The tuberculin test was faintly positive on the 18th day.

A/

A distinct nodule at the site of inoculation was present on the 11th day. The nodule increased in size, but did not break down and before slaughter it had resolved and was barely palpable. The tuberculin reaction was doubtful when the animal was killed 99 days after inoculation, and the weight was 27 ozs.

On post-mortem examination, there was no evidence of emaciation, and only a fibrous mass was found at the site of inoculation. No evidence of tuberculosis of internal organs was found either on macroscopic or microscopic examination.

Guinea-pig No. 35.

Weight before inoculation was 28 ozs. The tuberculin test was positive, and a distinct nodule present at the site of inoculation on the 12th day. The animal's weight remained fairly steady, and was 27 ozs. on the 102nd day. The tuberculin test was still definitely positive at that time, and the nodule had increased in size but had not ulcerated.

On post-mortem examination, an enlarged gland which had broken down, forming an abscess was found in the left groin. The pus contained numerous acid-fast bacilli. The right inguinal gland was also enlarged, and on microscopic examination tubercles but no acid-fast bacilli were found. No other macroscopic/

macroscopic or microscopic evidence of tuberculosis was found.

Guinea-pig No. 36.

Before inoculation the weight was 23 ozs. The tuberculin test was positive, and a distinct nodule was present at the site of inoculation on the 12th day after inoculation. The nodule increased in size, and lymphatic glands were palpable in both groins on the 31st day, and then the local lesion gradually resolved. The weight remained steady and was 24 ozs. when the animal was killed on the 101st day.

On post-mortem examination, the animal was found to be well nourished, a gland in the right groin was enlarged, but the lesion in the left groin was barely visible. The spleen was slightly enlarged and congested, there were necrotic patches on the surface of the liver and punctate haemorrhages on the pleura.

On microscopic examination, tubercles composed of endothelial cells were found in the lung and spleen with scanty acid-fast bacilli. The liver showed aggregations of lymphocytes, but no acid-fast bacilli; the gland from the right groin showed similar tubercles but no acid-fast organisms were found.

PATHOGENICITY/

TABLE VIII.

B.C.G.Undissociated Subculture.8 Weeks' Growth on Dorset's Egg Medium.Subcutaneous Inoculation of 3 Guinea-pigs.

(Dose - 2 mgs.)

Serial No. of Guinea- pig.	Weight in Ozs.		No. of days be- fore Tubercul- :in Test Positive.	Day of Death.	Lesions found post-mortem.
	Before in- :oculation	At Death			
34	24	27	18	99*	Fibrous mass at site of inocul- :ation.
35	28	27	12	102*	Inguinal lymph- :adenitis with abscess. (Acid-fast bac- :illi present).
36	23	24	12	101*	Local lymphad- :enitis. Tub- :ercles in lung, spleen, liver. (Acid-fast bac- :illi present).

*animal killed.

PATHOGENICITY EXPERIMENTS WITH A FRESH CULTURE OF B.C.G.

A fresh culture on glycerol-bile-potato medium was obtained from the Pasteur Institute on the 25th of February, 1930. On the 27th of February it was opened, and six guinea-pigs, which had been tested with tuberculin and found to be non-reactors, were inoculated with 2 mg., three by the intra-cardiac route, and three by subcutaneous injection in the left groin. The experiment was carried out exactly as with previous tests. Surviving animals were killed on the 3rd of June, that is, after 95 days.

Intra-Cardiac Inoculation. (See Table IX).Guinea-pig No. 39.

Before inoculation the weight was 20 ozs. The tuberculin test was positive on the 17th day, the animal lost weight steadily, and died on the 34th day.

On post-mortem examination, marked fatty degeneration of the liver was found, and tubercle-like nodules were present on the surface of the spleen, but no microscopic evidence of tuberculosis was found.

Guinea-pig No. 40.

Before inoculation the weight was 14 ozs. The tuberculin reaction was positive on the 17th day. The weight increased to 19 ozs. on slaughter 95 days after/

TABLE IX.B.C.G.Culture on Glycerol-Bile-Potato Medium.(As received from the Pasteur Institute, Paris).Intra-cardiac Inoculation of 3 Guinea-pigs.

(Dose - 2 mgs.)

Serial No. of Guinea- pig.	Weight in Ozs.		No. of days be- fore Tubercul- :in Test Positive.	Day of Death	Organs in which Tuberculous lesions were found post- mortem.
	Before in- :oculation	At Death			
39	20	-	17	34	Fatty degener- :ation of liver, No definite evidence of tub- :erculosis.
40	14	19 (Preg- :nant)	17	95*	Lung, spleen. (Acid-fast bac- :illi present).
41	20	15	-	21	Viscera showed evidence of in- :tercurrent disease.

* animal killed.

after inoculation, but it was found that the animal was pregnant. The tuberculin reaction was strongly positive just before the guinea-pig was killed.

No macroscopic evidence of tuberculosis was found on post-mortem examination, but on microscopic examination, tubercles composed of large endothelial cells and lymphocytes were found in the lung and spleen, and scanty acid-fast bacilli were found in the section of the spleen.

Guinea-pig No. 41.

Before inoculation the weight was 20 ozs. The tuberculin reaction was negative on the 17th day, but the animal had lost 5 ozs. in weight and died on the 21st day.

Post-mortem examination showed marked congestion of the kidneys and enlargement of the lymphatic glands in both groins.

On microscopic examination, lymphocytic hyperplasia was found in the glands and the kidneys showed the changes of acute nephritis. Death was probably due to some intercurrent disease.

Subcutaneous Inoculation. (See Table X).

Guinea-pig No. 42.

Before inoculation the weight was 19 ozs. The tuberculin/

tuberculin test was positive on the 17th day, and a small nodule was palpable at the site of inoculation. The tuberculin test was strongly positive on the 92nd day, and the weight was 25 ozs. The animal was killed on the 95th day.

On post-mortem examination, there was an enlarged lymphatic gland in the left groin, but no other macroscopic evidence of tuberculosis.

Microscopic examination showed tubercles composed of endothelial cells and lymphocytes in the gland, but no acid-fast organisms were present and no tuberculous lesions in internal organs were found.

Guinea-pig No. 43.

Before inoculation the weight was 16 ozs. On the 17th day the tuberculin reaction was positive, and a nodule was palpable at the site of inoculation. The tuberculin reaction was strongly positive on the 92nd day, and the animal weighed 21 ozs. It was killed on the 95th day.

Post-mortem examination showed a fibrous mass and an enlarged lymphatic gland at the site of inoculation. The gland contained tubercles composed of endothelial cells and lymphocytes but no other evidence of tuberculosis was present.

Guinea/

Guinea-pig No. 44.

Before inoculation the weight was 20 ozs. The tuberculin reaction was positive on the 17th day, when a nodule was present at the site of inoculation. On the 92nd day the weight was 26 ozs. and the tuberculin reaction was strongly positive.

On post-mortem examination, the animal, when killed on the 95th day, was found to be pregnant. There was fibrosis at the site of inoculation, but no enlarged lymphatic glands or evidence of tuberculosis of internal organs was seen.

On microscopic examination, however, tubercles were found in the spleen and there was a slight fibrinous pleurisy and subpleural consolidation in the lung. No acid-fast bacilli were found.

EVIDENCE/

TABLE X.B.C.G.Culture on Glycerol-Bile-Potato Medium.(As received from the Pasteur Institute, Paris).Subcutaneous Inoculation of 3 Guinea-pigs.

(Dose - 2 mgs.)

Serial No. of Guinea-	Weight in Ozs.		No. of days be- fore Tubercul- :in Test Positive.	Day of Death	Lesions found post-mortem.
	Before in- :oculation	At Death			
42	19	25	17	95*	Lymphatic glands enlarged at site of inoculation.
43	16	21	17	95*	Induration at site of inocul- :ation.
44	20	26	17	95*	Fibrous mass at site of inocul- :ation. Tub- :ercles in spleen. Fib- :rinous pleurisy. Sub-pleural con- :solidation of the lungs.

* animal killed.

EVIDENCE OF MICROBIC DISSOCIATION OF THE SMEGMA
BACILLUS AND ONE OF CLEGG'S LEPROSY BACILLI.

In December 1928, variation in the form of colonies was noted in a subculture from an old stock culture of one of Clegg's leprosy bacilli. One type of colony was dry and friable with a wrinkled surface, whereas the other type was smooth and moist. Each was subcultured on Dorset's medium, and from the subcultures intra-cutaneous inoculations were performed on two guinea-pigs. In 48 hours small pustules formed in both animals at the site of injection. They discharged, and then resolved, leaving no trace. On the 26th of January Petroff's medium in petri dishes was inoculated with emulsions in saline which had been filtered through two layers of sterile filter paper, and growth was true to the original type. On transference of single colonies to tubes of Dorset's egg medium and again plating from the subculture, the same result was obtained.

I attempted to find evidence of microbic dissociation of the smegma bacillus and the Timothy grass bacillus, from cultures about three months old, by plating filtered emulsions. Repeated attempts with the Timothy grass bacillus were unsuccessful, but/

but with the smegma bacillus definite rough and smooth types of colony were found, which were allowed to grow till they were 2 cms. in diameter.

SUMMARY.

Three types of colony have been obtained from a culture of B.C.G., namely:-

1. Smooth type.
2. Rough type.
3. Intermediate type.

The smooth type varied from that described by Petroff in that there were no corrugations on the surface. Experiments were carried out on guinea-pigs to test the pathogenicity of the different types, and also the pathogenicity of a fresh culture of B.C.G. and a subculture of B.C.G. on Dorset's egg medium. Intra-cardiac and subcutaneous injections with a dose of 2.0 mg. were performed.

RESULTS:-

1. Rough type.
 - (a) Six animals were inoculated by intra-cardiac route/

route. Two died from generalised tuberculosis on the 45th and 66th days respectively; two died from intercurrent disease, one showing chronic tuberculous lesions; two survived till slaughter on the 67th day, when one was found to have chronic tuberculous lesions in internal organs, while the other showed no evidence of disease.

- (b) Six animals were inoculated by the subcutaneous route. None died before the 67th day, but local lesions occurred in all, with abscess formation in five. At autopsy, four animals were found to have tuberculous lesions in internal organs, and two had local lesions only.

2. Smooth Type.

- (a) Six animals were inoculated by the intracardiac route. Five animals died from tuberculosis within forty days, one from a local lesion in the heart wall at the site of the needle puncture but also showing lesions in internal organs, the other four from generalised tuberculosis. The surviving animal was killed/



killed on the 67th day when chronic lesions were found in the internal organs.

- (b) Six animals were inoculated by the subcutaneous route. Local lesions developed in all of them, proceeding to abscess formation in four cases, but no animal died before the 67th day. On post-mortem examination, spread to internal organs had occurred in two animals, the remaining four showing local lesions only.

3. Intermediate Type.

- (a) Three guinea-pigs were inoculated by the intracardiac route, but one unfortunately succumbed from haemorrhage from the needle puncture. The other two survived till the 99th day, when the experiment was terminated, and showed at autopsy chronic lesions in one or two lymph glands but not in internal organs.
- (b) Three guinea-pigs were inoculated by the subcutaneous route. None died before the 99th day, when one was found to have chronic lesions in the lung as well as a local lesion, and the other two showed local lesions only.

4. Subculture from B.C.G. (undissociated) on Dorset's egg medium.

- (a) /

- (a) Three guinea-pigs received the inoculation by the intra-cardiac route. One animal died on the 34th day from a tuberculous abscess of the liver, and foci were present in the lungs: one when killed on the 102nd day showed tuberculous lesions in the glands and internal organs. The other died on the 33rd day from some intercurrent lung affection - no evidence of tuberculosis was found.
- (b) Three guinea-pigs were inoculated by the subcutaneous route. All survived till slaughter on the 102nd day, when all three showed local lesions, but only one showed evidence of invasion of internal organs.

5. B.C.G. - fresh culture on glycerine-bile-potato medium from the Pasteur Institute.

- (a) Three animals were inoculated by the intra-cardiac route. No animal died of tuberculosis, but one died on the 21st day from intercurrent renal disease, and one on the 34th day from some undetermined cause. No evidence of tuberculosis was found in either of them, but in the third which was killed on the 98th day, lesions were found in the liver and spleen.

(b)/

- (b) Three animals received the inoculation subcutaneously. No death occurred before the 98th day, when one showed chronic lesions in spleen and lungs as well as a local lesion; the other two showed local lesions only.

CONCLUSIONS.

1. Evidence of microbic dissociation as shown by variation in colonial form has been found. The types found were 'rough', 'smooth', and 'intermediate'. The great majority of colonies were of the 'intermediate' type. The 'rough' type of colony corresponded closely with that described by Petroff, but the 'smooth' type did not.
2. Evidence of microbic dissociation was also found with two other acid-fast bacilli, namely the smegma bacillus, and one of Clegg's leprosy bacilli, 'rough' and 'smooth' colonies being found.
3. Experiments on guinea-pigs have not shown clean cut lines of demarcation between the 'rough' and 'intermediate' types of colony, but definite variation was found, the 'smooth' type being most virulent/

virulent, the 'rough' type second in virulence, and the 'intermediate' type the least virulent. Evidence of invasion of internal organs following subcutaneous injection was found in all types.

Petroff, though finding the 'R' type relatively avirulent, found evidence of tuberculosis following intra-ventricular inoculation with 'R' type, two animals dying from this cause on the 266th and 375th days, and in one animal lesions were found in the spleen following intra-testicular injection with 'R' type.

He considers that these results may have been due to 'S' type organisms still remaining in the 'R' culture, and as there are considerable difficulties in separating them completely, this may be an explanation in my own experiments.

4. On inoculating guinea-pigs with a subculture of B.C.G. on Dorset's egg medium, results showed that the culture was more virulent than the 'intermediate' type of growth. This would seem to be explained by Petroff's finding that the 'S' type of organism did not grow on glycerol-bile-potato medium, but that it grew on ordinary media.

Subcultures of B.C.G., therefore, on ordinary media would tend to grow more and more virulent.

5. In the time at my disposal no guinea-pigs died following subcutaneous inoculation of any of the types of organism, although many showed active lesions in internal organs which might have lead to a fatal issue had time permitted. Petroff, on the other hand, did have deaths following subcutaneous inoculation of the 'S' type, but on the 103rd day, a longer period than I allowed in my experiments.

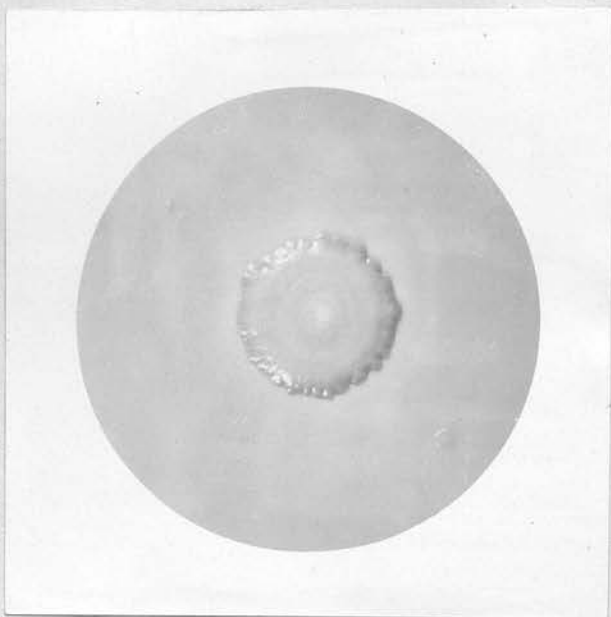
Another interesting point is that of forty-two guinea-pigs five died of ill-defined intercurrent diseases and these five were among the 21 which received intra-ventricular inoculations.

Death occurred on the 18th day or later, and it is possible that these deaths were due to pathological conditions produced by the inoculations although not, apparently, tuberculosis.

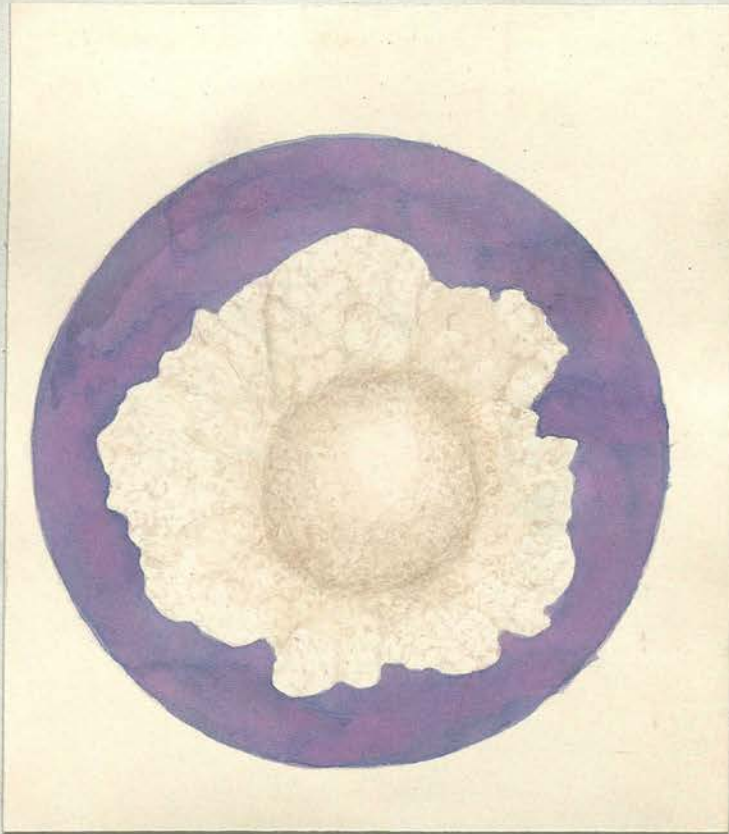
6. The types of lesion found were aggregations of lymphocytes and large mononuclear cells, but no giant cells were found. Occasionally necrosis, and in many cases fibrosis, was present.

REFERENCES.


- (1) "The Newer Knowledge of Bacteriology and Immunology"
by Jordan, E.O., and Falk, I.S. (Chicago, 1928),
page 84.
- (2) Hadley, P. (1927) Journal of Infectious Diseases,
Volume 40, page 1.
- (3) Long, E.R. (1926) Archives of Pathology, Volume 1,
page 918.
- (4) Trudeau, E.L. (1894) Transactions of the Assoc-
iation of American Physicians,
Volume 9, page 168.
- (5) Krause, A.K. "Environment and Resistance in Tub-
erculosis", page 96.
- (6) Calmette, A., and Guérin, C. (1908) Annales de
l'Institut Pasteur, Volume 22,
page 689.
- (7) Calmette, A., and Guérin, C. (1911) Annales de
l'Institut Pasteur, Volume 25,
page 625.
- (8) Calmette, A., and Guérin, C. (1924) Annales de
l'Institut Pasteur, Volume 38,
page 371.
- (9) Petroff, S.A. (1929) American Review of Tubercul-
osis, Volume 20, page 275.
- (10) Petroff, S.A., Branch, A. and Steenken, W.Jr.
(1929) The American Review of Tub-
erculosis, Volume 19, page 9.
- (11) Proskauer, B. and Beck, M. (1894) Zeitschrift für
Hygiene und Infektionskrankheiten,
Volume 18, page 128.



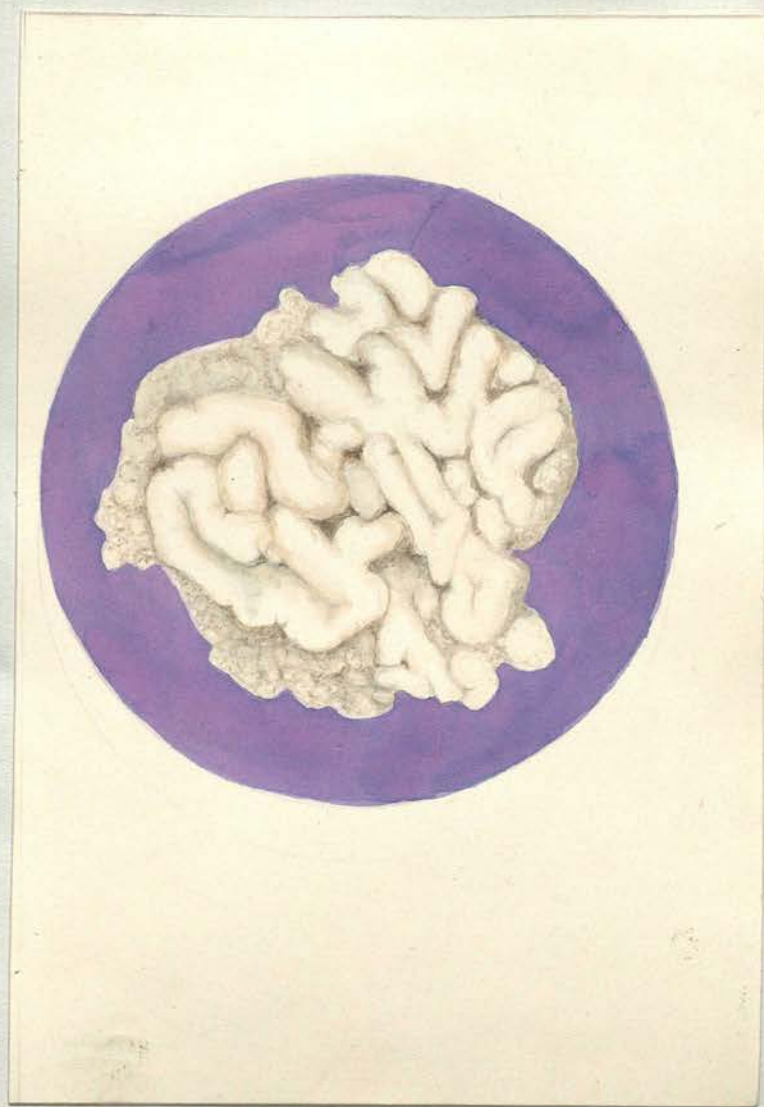
B.C.G. - Smooth type of colony.



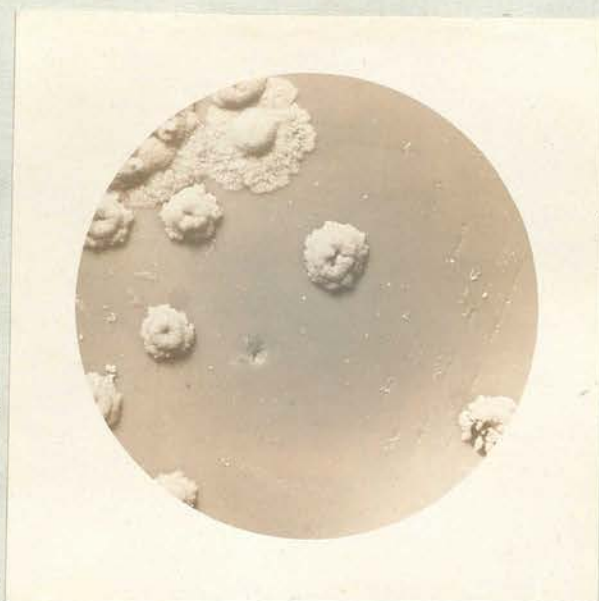B.C.G. - Smooth type of colony.



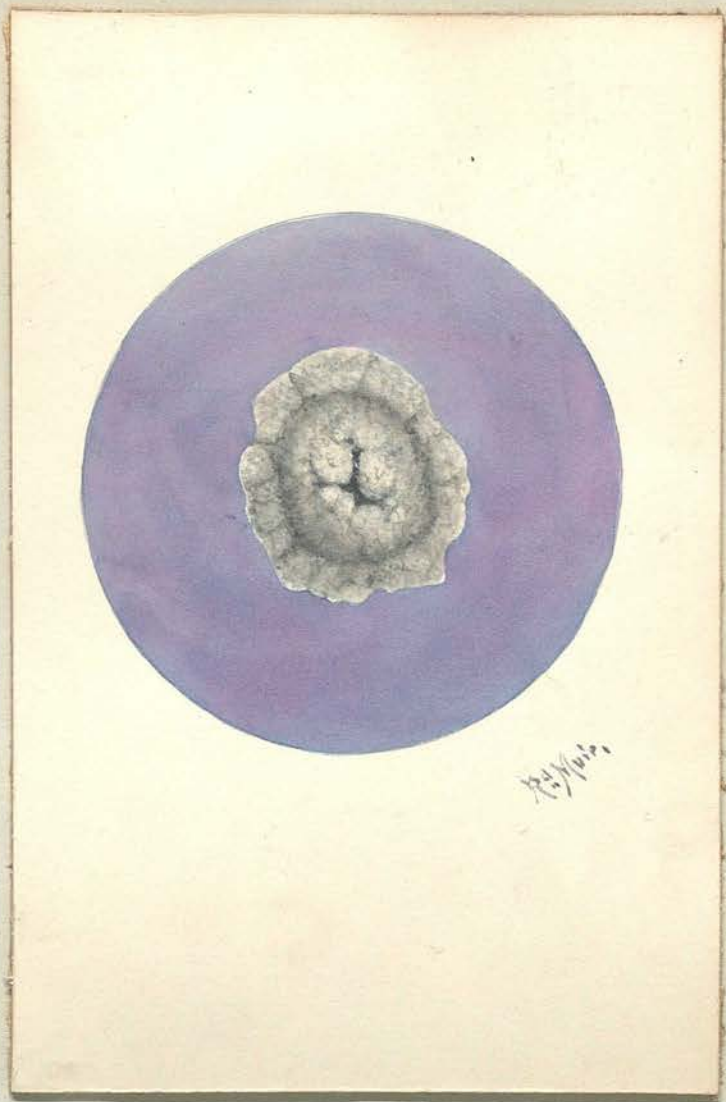
B.C.G. - Rough type of colony.



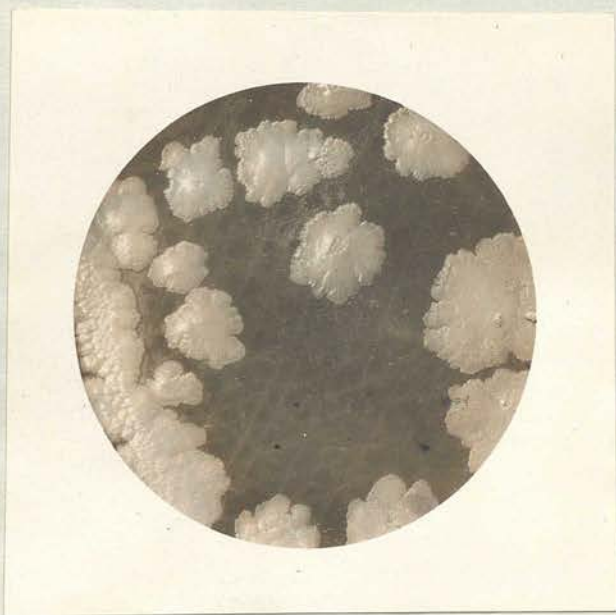
B.C.G. - Rough type of colony.



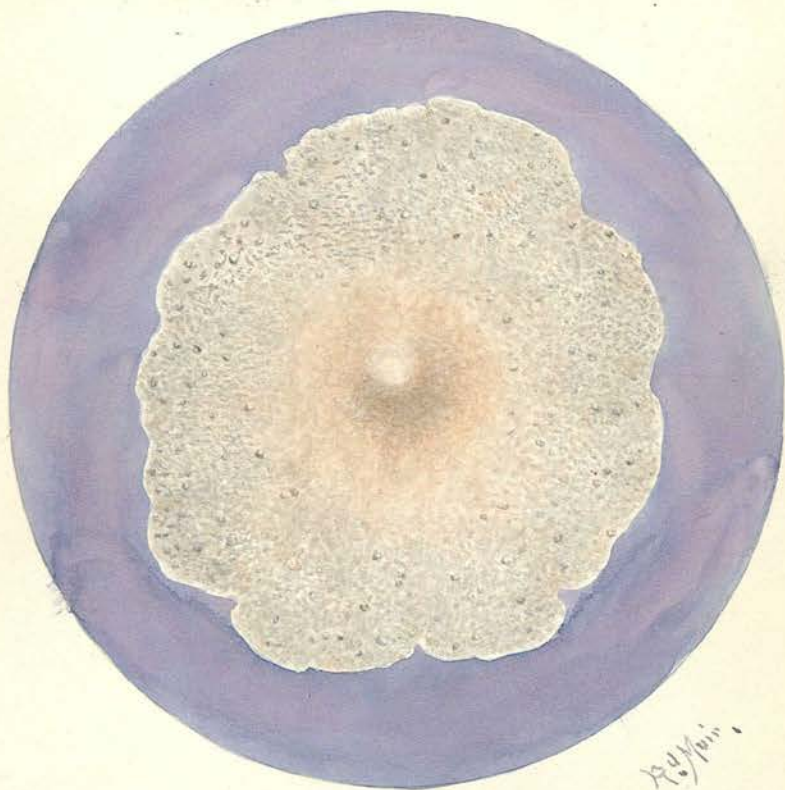
B.C.G. - Umbilicated colonies and one
smooth colony.



B.C.G. - Intermediate type of colony.

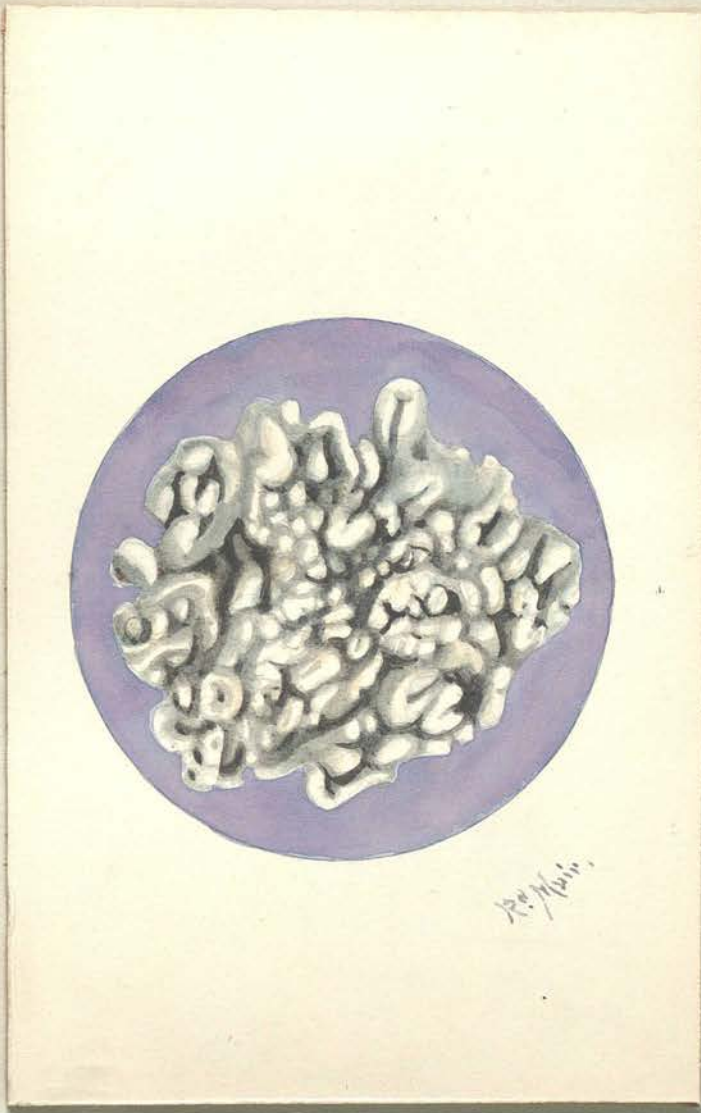


Smegma Bacillus - Smooth type of colony.



Smegma Bacillus - Smooth type of colony.

X 5 diameters.




Smegma Bacillus - Rough type of colony.


X 8 diameters.



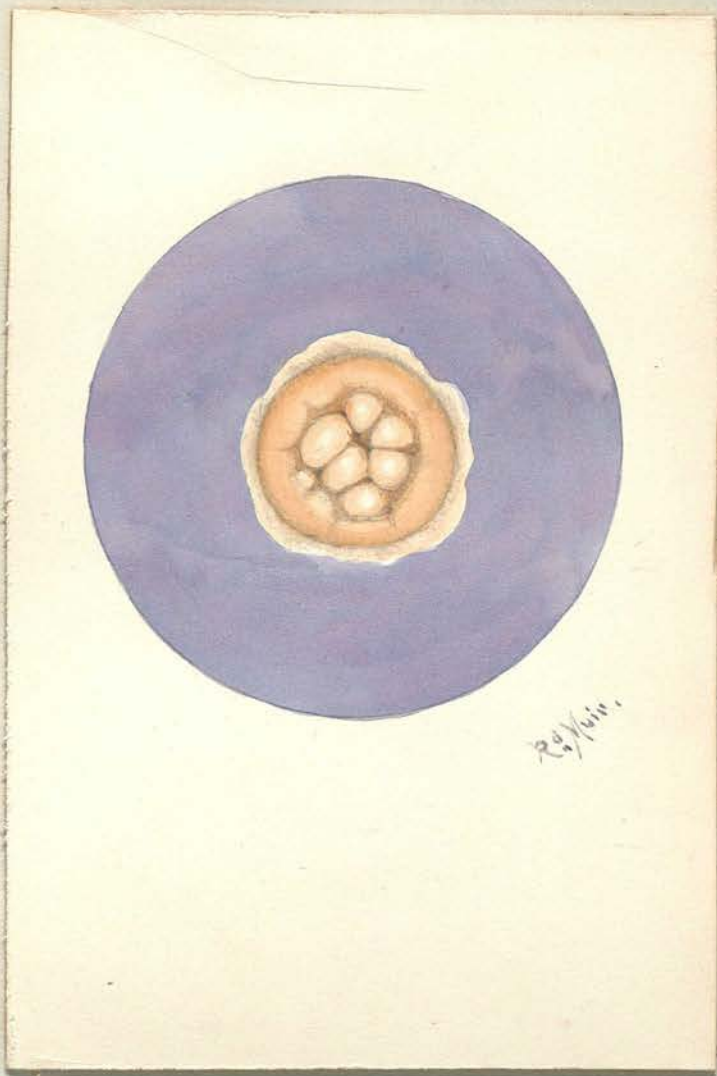
One of Clegg's lepra bacilli - Smooth type of colony.



One of Clegg's lepra bacilli - Smooth type of colony.
X 8 diameters.



One of Clegg's lepra bacilli - Rough type of colony.



One of Clegg's lepra bacilli - Rough type of colony.

X 8 diameters.

AUTHOR'S PUBLICATIONS.

The results of this work have been embodied in two publications, viz.:-

- (i) "Microbic Dissociation with Special Reference to Certain Acid-fast Bacilli".

A communication to the Tuberculosis Society of Scotland published in the Edinburgh Medical Journal, 1930, Volume 37, page 187:

and

- (ii) "Microbic Dissociation with Reference to the Attenuated Tubercle Bacillus of Calmette and Guérin (B.C.G.)".

Transactions of the Tuberculosis Society of Scotland, 1929-30, page 30; also published in the Edinburgh Medical Journal, 1931, Volume 38, page 174.

ACKNOWLEDGEMENTS.

The author has to acknowledge financial assistance received from the Moray Fund of the University of Edinburgh.

Grateful acknowledgement is also made of the encouragement and advice given by SIR ROBERT W. PHILIP and PROFESSOR T.J. MACKIE throughout the work.
