

A STUDY OF 50 CASES OF CARCINOMA OF THE LUNG

FROM THE POINT OF VIEW OF EARLY DIAGNOSIS

by

I. J. FREEDMAN, M.B., Ch.B.

A Thesis

submitted for the Degree of

Doctor of Medicine

in

The University of Edinburgh



INTRODUCTORY

Carcinoma of the lung has now assumed a position of great importance in the work of all hospitals devoted to diseases of the chest and our aim at present is to diagnose the disease at a stage in which radical cure may be attempted. Unfortunately this is very rarely possible at present. With this in mind an endeavour has been made to study the cases of carcinoma of the lung which the writer has seen in the wards of the Royal Chest Hospital during the past three years and he is greatly indebted to Dr. F.E.Saxby Willis to whom he acted as clinical assistant for permission to publish the cases in this thesis. A series of 50 cases of primary carcinoma of the lungs is described in the following pages. The writer has interpreted the symptoms, physical signs and radiograms from his own viewpoint but has relied for any other special investigations upon the reports from the various special departments of the Hospital. He has endeavoured to analyse these findings and to compare them with those of various workers on the subject of cancer of the lung and also to show that the examination of the sputum for carcinoma cells is a valuable aid in the diagnosis of cancer of the lung and that it should be employed at the earliest possible moment in suspected cases of the disease. With our present methods of treatment the only hope of cure lies in early diagnosis

and to attain this end it is essential in most cases to make the diagnosis before abnormal physical signs are present. This means that we must rely upon symptoms in the first instance as a clue to the diagnosis of pulmonary carcinoma, and in a case with suspicious symptoms we must be prepared to call in immediately the aid of the pathologist, bronchoscopist, the radiologist and the surgeon.

A cough in a person over forty which does not improve in a week or so with treatment, should be regarded as suspicious and subject to routine methods of diagnosis. Similarly with other symptoms to be mentioned later. One of the difficulties with which we are faced is that patients often wait too long before seeking medical advice for their symptoms. An endeavour is now being made to warn the general public of the danger of neglecting certain symptoms. The following notice, which is being prominently exhibited in many London boroughs is a very good example of the way in which this problem is already being tackled.

The Borough of Willesden has established two cancer clinics. The purpose of these clinics is (1) is to give simple information on the subject of cancer to anyone who desires it. (2) To advise as to how and where to get treatment for any irritation or discharge which may lead to cancer if neglected. (3) To arrange for immediate treatment because every day counts.

AETIOLOGY

The cause of carcinoma of the lung is still unknown, although the literature abounds with various suggestions no definite evidence of the cause is forthcoming. The most striking work which has been done with a view to discovery of the cause is that in the Schneeberg mining districts of Saxony. Rostoski and Saupe⁽¹⁾ investigated 154 cases amongst the miners of this district. They work underground in damp conditions and inhale a great deal of dust. This dust contains metallic sulphides of iron, and arsenides of cobalt and nickel. It also contains quartz and other silicates and the particles have sharp edges. 21 of the 154 cases observed died in three years and of those who died, 13 were found to have carcinoma of the lung at autopsy. The other who died were found to have pneumokoniosis. It would appear from these observations that inhalation of this dust can cause carcinoma of the lung.

SEX

Another factor which appears to have a bearing on the aetiology is sex. In this series only six cases or twelve per cent were females, but the number of cases is too small to draw accurate conclusions. Seyfarth⁽²⁾ in a series of 303 cases, found that the proportion of males to female was 5.7 to 1 and all workers are agreed that the disease is at least three

times as common in males as in females.

AGE

The age at which carcinoma of the lung occurs is similar to that of cancer in other parts of the body.

A Table is given below showing the age incidence in this series. The ages of the patients are divided into groups according to decade.

TABLE

Decades Years	Number of Cases
1-10	0
11-20	1
21-30	0
31-40	1
41-50	14
51-60	18
61-70	16

It will be seen that 96 per cent of the patients were over the age of forty. However, it must be remembered that carcinoma of the lung can occur in very young people, but for all practical purposes we may confine our suspicions to patients of over forty years who present suspicious symptoms.

HISTORY OF PREVIOUS CHEST DISEASE

Chronic bronchitis is another factor of importance in the aetiology of cancer of the lung in the cases of this series. In cancer generally it is thought that the disease very often arises in an organ which has been the site of chronic inflammation, for example,

cancer of the stomach can develop in a chronic gastric ulcer and many people believe that it also may arise in a long standing but symptomless low acid form of gastritis. Similarly cancer of the rectum has been shown to arise in a simple polypus. It is possible that carcinoma of the bronchus could be caused by chronic bronchitis. In this series 11 cases or 22 per cent gave a history of chronic cough with sputum of over three years duration, some of them for as long as 20 years. In practice these cases form a group in which the development of cancer of the lung on chronic bronchitis is easily overlooked. In such cases, when malignancy develops, the symptoms always become much more severe. It is suggested that a routine examination of the sputum for carcinoma cells every three months would help us in the diagnosis of malignancy in these cases.

INCIDENCE OF CARCINOMA OF THE LUNG

There is no doubt that carcinoma of the lung is diagnosed with much greater frequency now than it was thirty years ago. Whether this is due to the increased incidence of the disease or to improved diagnosis by modern methods, it is difficult to say with certainty.

Maxwell⁽³⁰⁾ is of opinion that we see more cases because of the improved diagnostic methods, but when one consults the statistics which are based upon post-mortem findings which have been done as a routine in many hospitals on every possible case no matter what

the disease, one finds that the gross numbers and percentage of carcinoma of the lung have increased considerably during the past thirty years and it is difficult to see how these could be affected by improved methods of diagnosis. One is therefore justified in concluding that there has been a real increase in the incidence of carcinoma of the lung.

The statistics are very numerous and it will suffice to mention some of the most striking. In Germany Kikuth and Dora Hanf have drawn up the largest series. Kikuth⁽²⁶⁾ surveyed 246 cases of primary carcinoma of the lung which came to autopsy in the Eppendorf Hospital, Hamburg in the 35 years before 1923 and found that the incidence has increased greatly in recent years. The Table following shows the

number of cases in twelve-year periods.

1889-1899 10 cases

1900-1911 90 cases

1912-1923 146 cases

He found that in 1923 the number of cases of pulmonary carcinoma numbered one-third of all the cases of carcinoma of the stomach and came second in order of frequency in the whole list of carcinoma of various organs. D. Hanf in a analysis of the cases of cancer which came to autopsy at the Charity Hospital Berlin, between 1903 and 1923, found a similar increase in a number of cases of carcinoma of the lung. In America E.J.Simons⁽²⁷⁾ collected the figures presented by eleven well-known workers. He found that between 1899 and 1930 in spite of fluctuations, there was a gradual increase in the percentage of pulmonary carcinomata in total autopsies from 0.0 in 1899 to 1.55 in 1930 and a similar increase in the percentage of cancer of the lung in total cancers from 5.88 in 1910 to 1914 to 8.28 from 1925 to 1928.

Author	Years	Total autopsies	Total Cases	Cancer of Lung	% of all Autopsies	Pulmonary Cancers % of all Cancers
Barron	1899-1911	1333		0	0.00	
Klotz	1910-1920	1000		5	0.05	
Rosahn	1910-1914	438	34	2	0.46	5.88
Hueper	1911-1921	5000		33	0.67	
Barron	1912-1918	2026		4	0.20	
Rosahn	1915-1919	526	42	2	0.38	4.44
Fried	1915-1925	1400	136	5	0.35	3.67
Scott & Forman	1916	302		3	0.99	
Grove & Kramer	1917-1924	3659		21	0.57	
Barron	1919-1921	1003		9	0.89	
Rosahn	1920-1924	874	90	5	0.57	5.55
Klotz	1920-1927	1900		19	1.00	
Moire	1921	375	29	5	1.38	17.00
MacLachlan	1921	231		4	1.7	
MacCrae, Funk & Jackson	1924-1927	621	53	4	0.64	
Rosahn	1925-1928	1166	145	12	1.03	8.28
Boyd	1930	900		14	1.55	

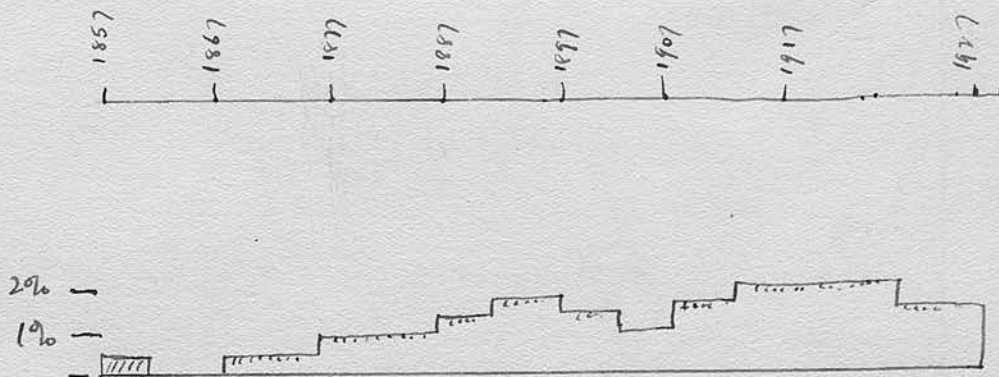
In Great Britain a very large number of autopsy records were surveyed by J.S.Dunn and C.P.White⁽²⁸⁾. They were compiled from records from six centres, Birmingham, Edinburgh, Glasgow, Leeds, University College Hospital, London, and Manchester. The following table shows their results: A certain number of these were not primary carcinoma of the lung.

INTRA-THORASIC CANCERS

A total for 25 years - 1903-1927.

	Total P.Ms.	Intra-thoracic Cancers	I.T.Cancer % of P.Ms.
Birmingham	13,592	163	1.18
Leeds	13,310	148	1.11
Glasgow	5,776	65	1.36
London	6,064	88	1.45
Manchester	5,322	124	2.33
Edinburgh	<u>10,687</u>	<u>122</u>	<u>1.14</u>
	53,757	710	1.32

The following is a graph of the cases of Edinburgh Royal Infirmary.



The Edinburgh and Glasgow cases are peculiar in that both show an earlier increase in the percentage of cases culminating in the period 1893-7 with a subsequent drop and later still a further rise. The graphs of the other centres show a steady increase. The authors conclude that: "At present all that can be concluded with a fair degree of certainty is the increase in the incidence of primary intra-thoracic growths which is shown from a large body of figures to have progressed during the past 25 years at any rate."

SYMPTOMS OF CARCINOMA OF THE LUNGI. COUGH.

Cough is the most constant symptom in carcinoma of the lung and this was present in every case in the series. One may say, therefore, that pulmonary carcinoma need not be suspected without cough. This excludes a certain number of cases where metastasis to a distant organ is the first symptom of which the patient complains. As regards the character of the cough, there was nothing distinctive. In nearly four-fifths of the cases the cough came on suddenly in a person over forty without any history of previous chest disease, but the remainder had had a cough for many years. Once the cough had commenced it was persistent and did not yield to treatment. The following table illustrates the duration of the cough before the patient came to hospital for diagnosis: (Table I).

It will be seen from Table I that 42 cases of the series or 84 per cent had had cough for six months at least before coming to hospital for investigation and in many of these the cough had been present for a longer period of time, ranging up to two years. This includes the cases of chronic bronchitis which were 11 in number, so that if we exclude these, 30 cases or 60 per cent had suddenly developed a cough from

six months to two years before coming to hospital for investigation. Many of these patients had had other symptoms suspicious of carcinoma of the lung as well. It appears then that there had been a delay between the initial symptom and investigation. This is due to two causes. The first is the delay of the patient in seeking medical advice for symptoms. This is difficult to overcome and can only be done by acquainting patients with the necessity of getting treatment for cancer of the lung early.

The second cause of the delay is that we, as doctors, do not arrange for investigation early enough for suspicious symptoms but are inclined to wait for abnormal physical signs.

TABLE I

Duration of Cough	Number of Cases
2 months	1
3	3
4	4
5	0
6	6
7	2
8	3
9	4
10	2
11	1
12	5
13	0
14	1
15	1
16	0
17	0
18	2
19	0
20	0
21	0
22	0
23	0
24	3
Over 24	2

II. SPUTUM.

The examination of the sputum is of great value in the diagnosis of cancer of the lung. As regards the naked eye appearance it was mucoid or mucopurulent in all the cases and was blood-stained in 35 cases. There was, however, nothing pathognomonic.

The microscopic examination of the sputum for carcinoma cells has received very little attention as an aid in the diagnosis of this disease. In most of the standard text books of medicine the examination of the sputum for carcinoma cells is not mentioned and in other works on the subject it is dismissed as being of no practical value. The writer has learned, on personal inquiry, that the sputum is not examined for carcinoma cells in any of the London teaching hospitals except St. Thomas's Hospital. It is, however, used as a routine method of examination in suspected cases of cancer of the lung at the Royal Chest Hospital.

In this series the sputum was examined in 48 cases and carcinoma cells were found in 36 of these, or 75%, 1 case had no sputum. The examination of the sputum was done by Dr. N. Schuster, pathologist to the Hospital, and the writer had the opportunity of seeing a great many of them with her. The method used was the one devised by Dr. Schuster. It is very simple but requires an experienced worker to identify

the malignant cells. The method is a wet film one and although several micro-photographs are included here it is not meant primarily for micro-photographs. The staining solution is a watery solution of methylene blue with 20 per cent glycerine. A small portion of the sputum is placed on a slide and teased up with a few drops of the methylene blue solution for one minute. A cover slip is placed over it and it is then examined. It takes about fifteen minutes to make a thorough search for the carcinoma cells. They can often be identified by reason of their nuclei being larger than those of the normal bronchial epithelial cells and the nuclei also stain a darker blue than the normal nuclei. The malignant cells are sometimes vacuolated and have fatty granules in their cytoplasm. Sometimes the malignant cells become keratinised and are very easy to identify. Sometimes one finds large fat cells in the slide and this is always highly suggestive that one will find malignant cells.

The value of the microscopic examination of the sputum was first demonstrated by L.S.Dudgeon and C.H.Wrigley.⁽³⁾ Their method is not so simple. They examined the sputum in 58 cases of suspected malignancy and found that in 68 per cent of proved cases of carcinoma of the lung it was possible to establish the diagnosis by sputum examination. On one occasion only a mistaken diagnosis of malignant disease was

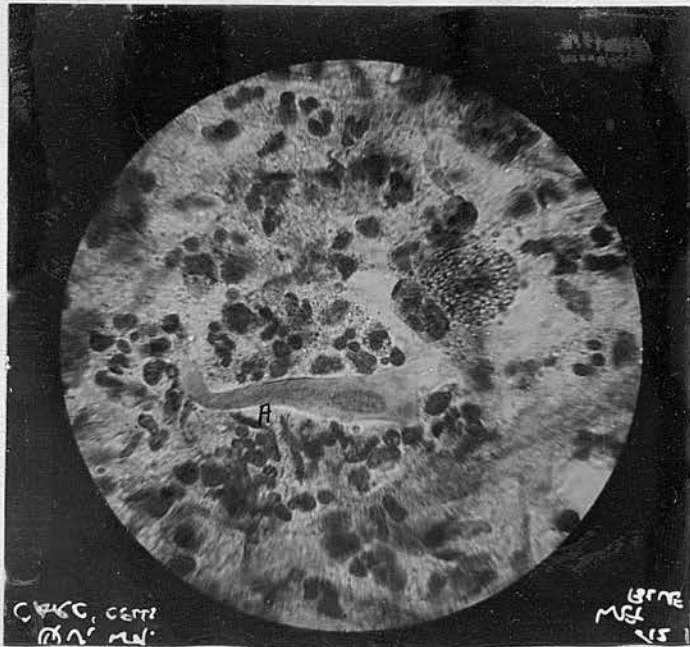
made. Maurice Davidson⁽⁴⁾ is of opinion that the microscopical examination of the sputum is of very little use. He states, however, that very little systematic work has been done in this matter. Fried⁽⁵⁾ states that the cytological examination of the sputum will rarely furnish a diagnostic criterion except when a bit of tissue is coughed up which may be fixed and shown to be malignant, but this is a very rare occurrence.

The evidence in the cases of this series shows that the value of the sputum examination is much greater than any of the authors of text books or other works on cancer of the lung appear to believe. It seems to the writer that the busy practitioner has in this test one which he can utilise very easily whenever he suspects pulmonary carcinoma. He has only to send a specimen of sputum to a laboratory as a first line of investigation in a suspected case. One often meets such cases which cause anxiety; e.g. a patient of middle-age with cough, perhaps breathlessness, and perhaps a streak of blood noticed in the sputum, and in whom the disease may be in such an early stage that no abnormal physical signs are present in the chest and possibly no abnormality found in a straightforward radiogram. Instead of waiting and watching such a case, the doctor could arrange for repeated examination of the sputum for carcinoma cells. It seems to be almost as important to examine the sputum for carcinoma cells as for Tubercle bacilli in such a case.

Every doctor would examine the sputum for Tubercle bacilli and as Tubercle bacilli are found in the sputum of about 10 per cent of cases of carcinoma of the lung, this sometimes causes the co-existing cancer to be overlooked.

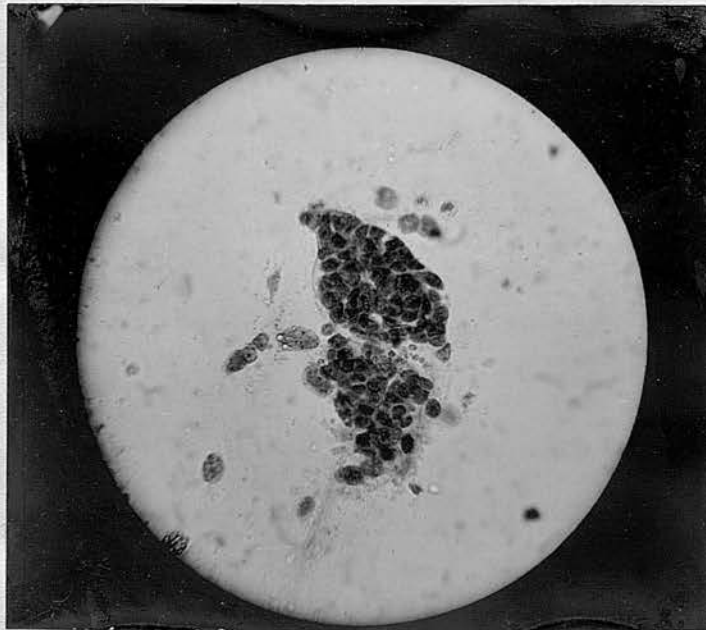It seems, therefore, reasonable to hope that if we examine the sputum for carcinoma cells without delay in all middle-aged patients who present themselves with symptoms suspicious of cancer of the lung, we should find these cells at a fairly early stage and so be able to diagnose a certain number of cases at an earlier stage than we do at present.

MICROPHOTOGRAPHS OF Sputum stained by Dr N. Schuster's
METHOD



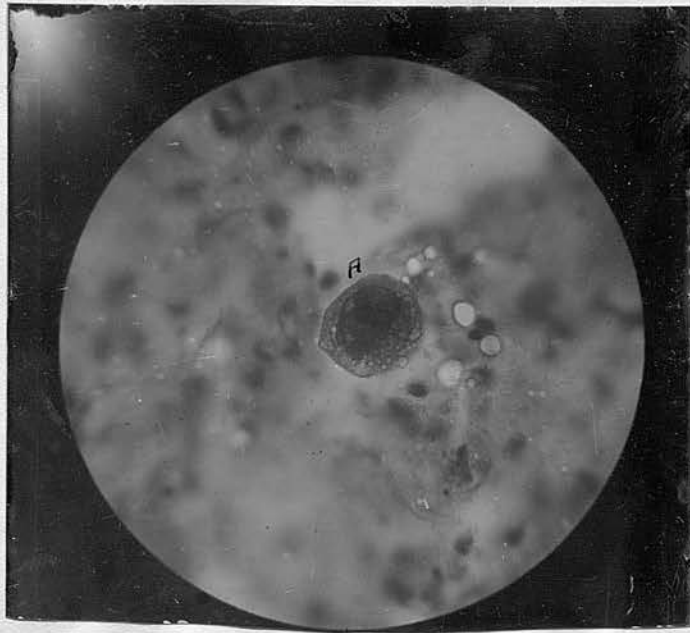
(1)

A is a large malignant cell. found
in Case No. 1. see E.G.



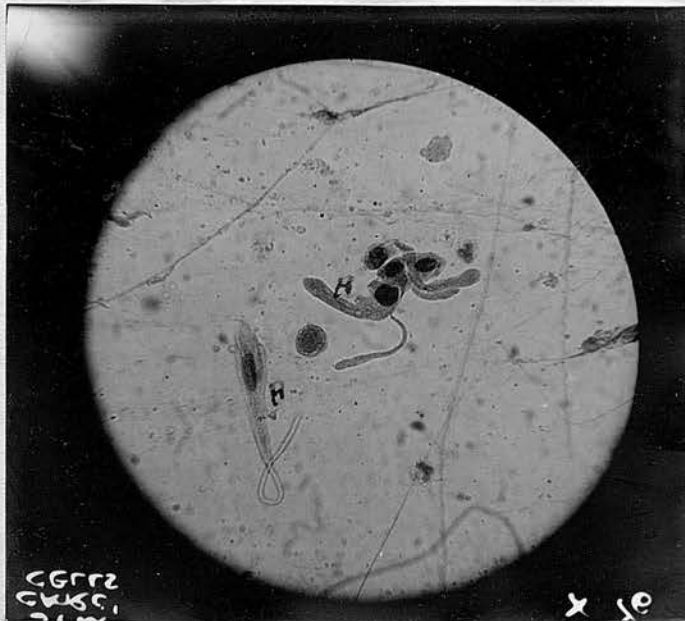(2)

A clump of malignant cells, very diagnostic.
Rather spheroidal type.



(3)

A is a typical malignant cell with vacuoles and a large nucleus which stains deep blue.



(4)

A = Columnar celled type. Larger than normal epithelial cells. No cilia Long tails. Deformed with bulbous ends

III. HAEMOPTYSIS.

Haemoptysis occurred in 35 cases, or 70 per cent, of the series. This is a higher figure than is found in many statistics but it is agreed that the greater number of cases of carcinoma of the lung have haemoptysis at some stage or other. The largest series analysed is that of Simons⁽⁷⁾ who collected the statistics of 1,456 cases of cancer of the lung from various workers and found that haemoptysis had occurred in 583, or 40 per cent. Whichever may be the closer approximation to the real incidence of haemoptysis, it occurs frequently enough to be a very important symptom. Furthermore it is a symptom which will very often cause a patient to seek medical advice.

The quantity of blood coughed up varied in quantity from a streak to a pint. Most of the cases showed streaks in their sputum which were repeated on several occasions. The writer, however, has seen a case of fatal haemoptysis from carcinoma of the lung.

In assessing the value of haemoptysis as a symptom in pulmonary cancer one must remember that the commonest causes of haemoptysis in a middle-aged patient are tuberculosis and bronchiectasis.

Haemoptysis is of great value also because it is an early symptom in many cases which may help us

to diagnose the condition at a stage when it may be amenable to surgical treatment. It is difficult to estimate the period of time between the development of the growth and the first bleeding from it. This latent period varies in different cases.

A Table has been drawn up to show the time which elapsed between the first haemoptysis and the arrival of the patient at hospital for investigation. (Table II).

It will be seen that in 20 cases, or 40 per cent, six months or more had lapsed and it seems that we should make it a definite rule that the occurrence of haemoptysis in a patient over 40 for which no definite cause can be found is an event which necessitates immediate investigation by radiology, by sputum examination for carcinoma cells and by bronchoscopy.

TABLE II

Number of months
elapsed between
first haemoptysis
and investigation

Number of
Cases

1 month	2
2	2
3	7
4	3
5	1
6	10
7	0
8	1
9	0
10	0
11	1
12	2
13	1
14	0
15	0
16	0
17	0
18	1
19	1
20	0
21	0
22	0
23	0
24	1
Over 24	2

IV. DYS-PNOEA.

Shortness of breath was complained of by 41 out of 50, or 82 per cent, of the patients in the series. The remainder did not have this symptom even on direct leading question about it. It is, therefore, an important symptom and should cause us to suspect cancer of the lung when it occurs in a patient over forty with a cough. The dyspnoea was progressive and in many cases severe in character.

The cause of the dyspnoea and its severity is difficult to explain. It is partly due to the diminution in vital capacity caused by the failure of oxygen to reach the collapsed lung tissue distal to the growth which is blocking the bronchus. But in many of these cases the dyspnoea observed was out of all proportion to the amount and degree of the collapsed lung tissue. Many of these patients who had collapse of one lower lobe, were far more breathless than patients I have seen who had had a lobectomy for bronchiectasis or a selective collapse of one or more lobes by artificial pneumothorax induced for pulmonary tuberculosis. There must be another factor in carcinoma of the lungs which increases the dyspnoea. Beaumont and Dodds⁽⁶⁾ have made a large number of estimations of the vital capacity of patients suffering from different diseases of the chest. They found that:

Patients suffering with active Tubercle and sputum positive. 63 cases.	Average vital capacity - 36%
--	------------------------------

14 cases bronchiectasis	Average vital capacity - 36 %
27 cases chronic bronchitis	Average vital capacity - 32%
5 cases carcinoma of the lung	Average vital capacity - 50%

They are of opinion that the diminution in vital capacity found in cancer of the lung does not depend only on the area of lung tissue damaged by disease but that there is another factor possibly a diminished entrance of air into the bronchioles and alveoli which may be influenced by the toxæmia.

Breathlessness coming on in a patient over forty accompanied by cough should make us suspect cancer of the lung. The two other and most common conditions which must be excluded are cardiovascular disease, which is the commonest cause of dyspnoea at this age, and emphysema. The history of a patient with emphysema is very helpful. He nearly always has had a cough for many years and the breathlessness has gradually increased over a number of years and by the time he seeks advice on account of dyspnoea the physical signs will be quite obvious.

There were, however, 10 cases in this series in which carcinoma of the lung had developed in a patient with a long history of bronchitis so that we must be on the lookout for cancer even although we find signs of bronchitis and emphysema.

As regards the duration of the dyspnoea before the patients came to the hospital for investigation Table III shows that 28 cases showed this symptom for six months or more. It is, therefore, a fairly early symptom and of value to us in arriving at an early diagnosis.

TABLE III

Duration of Dyspnoea
before investigation

Number of Cases

1 month	1
2	1
3	7
4	4
5	1
6	13
7	1
8	2
9	4
10	1
11	1
12	2
13	0
14	0
15	0
16	0
17	0
18	1
19	0
20	0
21	0
22	0
23	0
24	2

V. PAIN IN THE CHEST.

Pain in the chest which was always on the same side as the growth was complained of by 21 patients, or 42 per cent, and it was the first symptom of all in two cases. The character of the pain varied. It was severe and persistent in about half the cases and in the remainder it was brought on or made worse by coughing or deep breathing. The pain may be caused by involvement of the pleura by new growth, by pressure on intercostal nerves or rarely by erosion of the ribs. In six of the cases the growth had spread to the pleura giving rise to pleura effusion. In some cases the pain is probably caused by muscular strain due to the cough.

Pain in the chest of this nature is complained of by a great many patients with chest disease and so it is not a very specific symptom, but it is nevertheless a symptom which should put us on the alert for pulmonary carcinoma. Regarding its value, from the point of view of early diagnosis, Table VI shows the duration of the pain in months before the patients came to hospital.

It will be seen that 10 per cent of the cases had pain for over six months before coming to hospital and pain in the chest is a symptom which generally causes a patient to seek medical advice early, but from the

V. PAIN IN THE CHEST.

Pain in the chest which was always on the same side as the growth was complained of by 21 patients, or 42 per cent, and it was the first symptom of all in two cases. The character of the pain varied. It was severe and persistent in about half the cases and in the remainder it was brought on or made worse by coughing or deep breathing. The pain may be caused by involvement of the pleura by new growth, by pressure on intercostal nerves or rarely by erosion of the ribs. In six of the cases the growth had spread to the pleura giving rise to pleura effusion. In some cases the pain is probably caused by muscular strain due to the cough.

Pain in the chest of this nature is complained of by a great many patients with chest disease and so it is not a very specific symptom, but it is nevertheless a symptom which should put us on the alert for pulmonary carcinoma. Regarding its value, from the point of view of early diagnosis, Table VI shows the duration of the pain in months before the patients came to hospital.

It will be seen that 10 per cent of the cases had pain for over six months before coming to hospital and pain in the chest is a symptom which generally causes a patient to seek medical advice early, but from the

nature of the pathological processes producing it one would not expect it to be an early symptom in many cases.

TABLE VI

Duration of Pain	Number of Cases
1 month	4
2	3
3	5
4	3
5	0
6	1
7	0
8	0
9	1
10	0
11	1
12	0
Over 12	2

VI. LOSS OF WEIGHT.

Thirty of the patients in this series had lost weight, two-thirds of them showed a marked loss of weight, and one-third a small loss. The loss of weight had been noticed to commence at about the same time as the other symptoms. It is worth while keeping a check on the weight of patients who show symptoms suspicious of carcinoma of the lung as loss of weight forms additional evidence in completing the clinical picture of the disease.

PHYSICAL SIGNS

The physical signs found in the chest in carcinoma of the bronchus must of necessity vary in different cases and in the same case at different stages of the disease because we are dealing with a tumour which is growing in contact with soft and easily compressed tissue like the lung and the physical signs depend upon the effect of pressure on the lung, bronchi and other surrounding tissues. The physical signs described here are those which were found when the patient was first admitted to hospital.

In the interpretation of both the physical signs in the chest and the radiograms the reproduction of the diagram drawn up by F.G.Chandler⁽²⁹⁾ has been of great help. It represents what happens in the lung at various stages of the disease. Figure A represents a small growth in the bronchus. The only symptom may be cough or haemorrhage. There would be no abnormal physical signs nor would the radiogram show any abnormality. This is a very early stage. The sputum might show carcinoma cells and bronchoscopy might reveal the small excrescence of growth. If found at this stage the growth can be removed by lobectomy or pneumonectomy. Eventually the tumour will completely occlude the bronchus and an area of atelectasis will be produced. This may show as a band in the radiogram (B). Soon a wider area is involved, a whole lobe

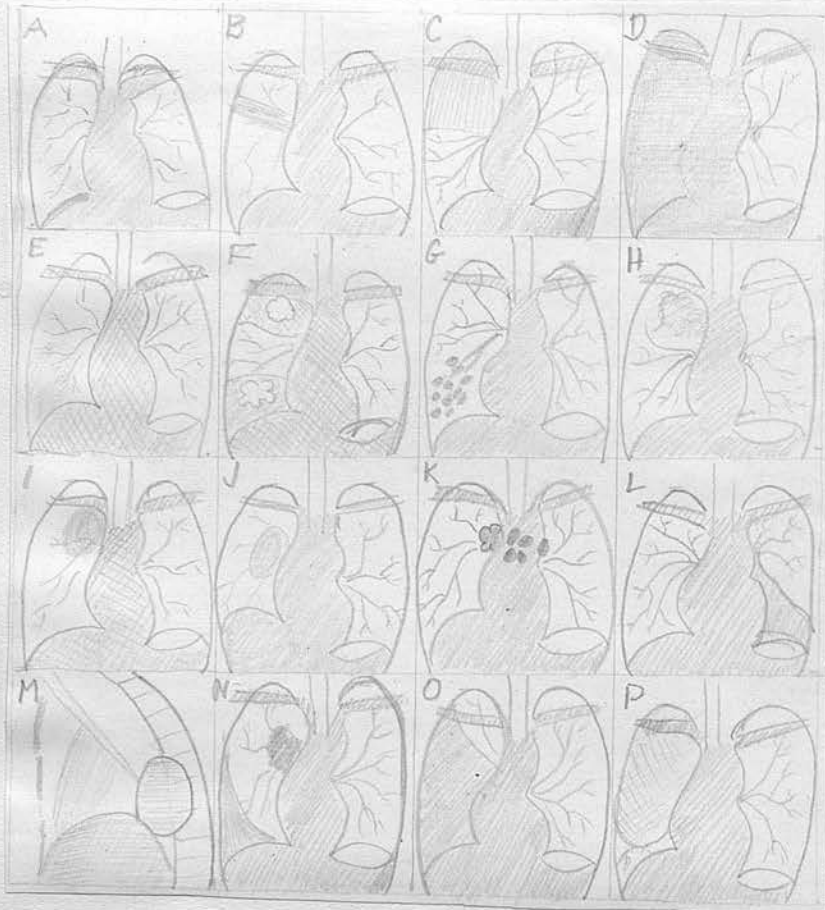PHYSICAL SIGNS

The physical signs found in the chest in carcinoma

the bronchus must of necessity vary in the extent

CHANDLER'S DIAGRAM

and in the same case at different stages of the



Physical signs now would the radiogram show any

abnormality. This is a very early stage. The sputum

might show carcinoma cells and bronchoscopy might reveal

the small excrescence of growth. If found at this

stage the growth can be removed by lobectomy or

pneumonectomy. Eventually the tumor will completely

occlude the bronchus and an area of atelectasis will

be produced. This may show as a band in the radiogram

and soon a wider area is involved, a whole lobe

becomes airless and draws the trachea towards it (C), or the main bronchus is involved and the whole lung becomes atelectatic drawing the mediastinum and its structures toward the affected side (D). Figure E shows another, though in my experience, rare mode of onset of carcinoma of the bronchus, pneumonia distal to the tumour. There was one case in this series. Figure F shows breaking down with abscess formation in the tumour or in the lung distal to the tumour. Figure G shows bronchiectasis distal to the tumour. Figure H shows the type of growth which infiltrates the lung tissue. Figure I shows an obvious mass of growth. Figure J shows a growth spreading out from the hilum and is difficult to interpret in the early stages in the radiogram. Figure K shows the early invasion of the mediastinal gland. Figure L shows the growth causing shadow in the left lower lobe behind the heart. Figure M shows a lateral view of the same type of growth. Figure N shows a central growth with commencing pleural effusion. Figure O shows a large pleural effusion. Figure P shows a huge growth in the right lung pushing the heart to the opposite side. This is very rare.

In this series six cases were found to have signs of pleural effusion on admission. One case showed signs of bilateral bronchiectasis and as abnormal physical signs are practically always

unilateral, this was very misleading. One case showed no abnormal physical signs at all. 42 cases showed physical signs which were suggestive of deficient aeration of lung tissue and these signs were confined to one side of the chest. This is important in suggesting carcinoma of the lung.

As regards the site in which the abnormal physical signs were noted it was found that:

- 5 cases signs in whole of left lung.
- 3 cases signs in whole of right lung.
- 3 cases signs at left upper zone.
- 9 cases signs at right upper zone.
- 10 cases signs at left lower zone.
- 11 cases signs at right lower zone.

Abnormal signs were found in the right lung in 27 cases and in the left lung in 21, so that the disease was fairly evenly distributed.

ABNORMAL PHYSICAL SIGNS IN ONE UPPER ZONE.

Percussion note was impaired to a greater or a lesser extent depending upon the degree of collapse of lung tissue and the amount of infiltration of the lung tissue by the growth or the mass of growth itself. The area in which impaired percussion was demonstrated extended generally from the clavical above to the fourth rib below in the front of chest and behind over a small area above the upper border of the scapula and sometimes between the vertebral border of the scapula

and the vertebral column. The breath sounds were diminished in this area in every case. Tactile and vocal fremitus were diminished also. Rales were present occasionally but were not constant. In addition to the above signs deviation of the trachea to the side of the collapsed lung tissue could be demonstrated in some cases. It was best shown by palpation of the space between the trachea and the attachment of the sterno-cleido-mastoid muscle to the sternum. Displacement of the heart to the side of the collapsed lung was very difficult to make out and was discarded as being of no practical value unless it was very gross. This is, of course, quite easily demonstrated by screening or in a radiogram. In practice one finds that the discovery of impaired percussion note and weak breath sounds at one upper zone in a patient over forty with a cough is very often due to carcinoma of the lung. Aneurysm and fibrocaceous tuberculosis of one upper zone cause exactly similar physical signs and the radiographical appearance must be seen to decide which condition is present.

SIGNS AT LOWER ZONE.

In Twenty-two cases the following physical signs were found at one or other base behind, impaired percussion note, weak breath sounds, diminished tactile and vocal fremitus and occasionally rales, but one is constantly finding such physical signs especially in an out-patient

department of a chest hospital. So much so that the writer has found it worth while to draw up the table set out below as an aid to his memory when differential diagnosis of the above physical signs is being considered.

TABLE

Impaired percussion note, weak breath sounds, diminished tactile vocal fremitus, possible rales at one lower zone may be caused by:

1. Disease in the lung.
2. Disease in the pleura.
3. Disease in the bronchus.

1. Disease in the lung.

- (a) Tubercle.
- (b) Fibrosis.
- (c) Abscess.
- (d) Pneumonia.
- (e) Infarct.

2. Disease in the pleura.

- (a) Effusion.
- (b) Thickened pleura.
- (c) Tumour.

3. Disease in the bronchus.

- (a) Bronchiectasis.
- (b) Growth.
- (c) Foreign body.
- (d) Plug of mucus.

Collapse of whole lung.

Collapse of one lung was found in eight cases the physical signs demonstrated were, diminished excursion, impaired percussion note, weak breath sounds, diminished tactile vocal fremitus all over one lung.

Pleural effusion.

Pleural effusion was present in six cases, or 12 per cent of the series. This is generally agreed to be about the percentage of cases in which it is found by most workers. The effusion was blood-stained in two cases. This is always highly suggestive of malignant disease in the lung. It was pale straw-coloured in the others. Microscopic examination of the fluid revealed carcinoma cells in two cases. The infusions were incipiduous in onset and this itself in a person over forty for which no other cause can be found, such as tuberculosis or cardiovascular disease is almost pathognomonic of pulmonary carcinoma.

Pleural effusion is, therefore, a very valuable diagnostic sign in this disease. MacDonald and Broder⁽¹⁰⁾ have examined 94 serous effusions, pleural and peritoneal. Nineteen of the pleural effusions were found to contain malignant cells and they came to the conclusion that:

1. Examination of the sediment obtained from effusions is of definite value in cases of suspected malignancy involving the serous cavities.
2. Where malignant cells can be identified definitely

in serous effusions such a diagnosis carries a high degree of accuracy.

The signs enumerated above are very suggestive of pulmonary carcinoma, a helpful point being that they are unilateral, but one must remember that they are suggestive of deficient aeration of lung tissue and that we infer from this that carcinoma of the lung may be present. The physical signs afford suggestive evidence but nothing which is at all specific for that disease. The finding of these abnormal signs should, therefore, immediately lead us to examine the lung by other methods, namely, sputum examination, radiological and bronchoscopical examination.

Regarding the above physical signs from the point of view of early diagnosis they are only present when the growth has been developing for some time and has led to collapse of lung tissue. No case in this series was diagnosed early enough for radical surgery to be successful. We must therefore regard these signs as rather late ones and must look elsewhere for the early signs which will enable us to attempt cure by radical surgery.

Clubbing of the Fingers.

Clubbing of the fingers was present in 11 cases, or 22 per cent, . How much of this was due to the growth itself and how much to infection in the bronchi, it is difficult to say. It seems probable, however,

that as none of these cases showed evidence of much bronchial sepsis that carcinoma of the lung itself can cause clubbing of the fingers. As, however, it occurs in only the minority of cases and as it can be caused by lung sepsis which often accompanies bronchial carcinoma it cannot be considered as a very valuable diagnostic sign.

SEDIMENTATION RATE

The sedimentation rate was estimated in 20 cases of the series and it was found to be raised in every case except one and moreover the figures were considerably higher. The method used was that of Westergren. Very little systematic work has been done on the effect of cancer of the lung on the sedimentation rate of the red cells. R. Fahraeus⁽¹²⁾ has investigated the effect of various diseases upon the blood sedimentation rate. He found that the figures vary in cases of malignant tumours and in 12 cases, which he investigated, he found two with normal figures. Fahraeus is of the opinion that it is difficult to say whether the pathological generation of tissue itself produces reduction of the suspension stability or if this change is only a consequence of tissue reduction or infection. It must be remembered that in carcinoma of the lung at a certain stage there is often infection in the

bronchial tree distal to the growth. Syphilis was present in four cases of the series and this is also a cause of raised sedimentation rate. In ten cases of chronic bronchitis in which the writer estimated the blood sedimentation rate it was within normal limits so that one can conclude that a very definite sepsis in the bronchi is necessary to cause a raised sedimentation rate. The sedimentation rate is raised in such a large number of diseases and cannot be regarded as a specific test for any disease so that it is really not of great value in the diagnosis of cancer of the lung.

PATHOLOGICAL CONSIDERATIONS

It is useful here to give a brief description of the modern conception of the pathology of carcinoma of the lung. It was customary until recently to divide carcinoma of the lung into two groups: 1. Those arising in the bronchus, 2. those arising from the alveoli of the lung. The present-day view is that all carcinoma of the lung really arises from bronchial mucosa. The type of cell found in the growth does not necessarily indicate its site of origin as was thought to be the case at one time. As Boyd⁽²⁴⁾ remarks all the epithelium of the lung is originally of the same type and it derived from

that lining the bronchi as can be seen from a glance at a microscopic section of foetal lung.

The type of cells found can be divided into three groups roughly: (1) the cylindrical type which are tall cells; (2) small cell type in which the cells may be round, oval, pleomorphic or spindle shaped; (3) squamous type with flattened cells.

Macroscopically carcinoma of the lung may be divided into three types; (1) hilus tumour, (2) miliary tumour, (3) diffused tumour. Hilus tumours are the commonest variety and comprise over 90 per cent of all. All the cases of my series fell into this group. They have their origin in a bronchus and may spread into the lung tissue either by inhalation or by spreading along the bronchi into the alveoli, or they may spread out into the lung tissue by way of the lymphatics. They may spread into the regional lymph nodes in the mediastinum and to the cervical and axillary glands, or they may invade neighbouring structures such as the heart and diaphragm. Or they may give rise to metastasis in any part of the body. The miliary form consists of tiny nodules scattered throughout the lung. In the diffused form a lobe or a whole lung is converted into a firm grey mass.

RADIOLOGICAL DIAGNOSIS

The radiological diagnosis of cancer of the lung is by no means a simple matter and one sees many radiograms which, although suggestive of carcinoma do not give any conclusive evidence upon which to base a diagnosis. Nevertheless in many cases a picture is seen which affords strong presumptive evidence of pulmonary carcinoma. Radiologists themselves have adopted different classifications to aid the description of the radiograms. The one which the writer has adopted is that of the late Dr. Stanley Melville because he has seen a fairly large number of films interpreted by Dr. Melville and has found it the most useful classification. Melville⁽⁸⁾, for convenience of description divides carcinoma of the lung into the following groups.

- (a) Upper lobe carcinoma.
- (b) Hilar carcinoma.
- (c) Lower lobe carcinoma.

(a) Upper Lobe Carcinoma:

What one sees in the early stage of a stenosed bronchus is not the growth itself but the opacity due to collapsed lung. The collapsed upper lobe of the lung is sometimes sharply demarcated by the interlobum septum. At a later stage the growth itself in addition to collapse may be seen as a shadow projecting into the lung tissue.

(b) Hilar Carcinoma:

The growth arises from a main bronchus and may

cause collapse of one lung or lobe. The growth may be seen as an opacity spreading into the lung tissue which is either circumscribed or diffused. In the circumscribed form the opacity has a fairly well defined border. The diffused form shows an opacity spreading fan-wise from the hilum into the lung, the outer edge being blurred and somewhat irregular.

(c) Basal or Lower Lobe Carcinoma:

Here we may get collapse of a lower lobe. Sometimes the lower lobe appears somewhat triangular in form with the interlobar septum curving from the mid-line down towards the diaphragm. Sometimes, however, it is not so definite and the lower zone appears irregularly opaque and there is peaking of the diaphragm due to adhesions and the picture is indistinguishable from that due to bronchiectasis or fibrosis of the lung. At other times there is abscess formation distal to the growth or there may be a dense opacity due to a solid mass of tumour filling almost the whole of the lower lobe. By far the commonest picture is that of some degree of atelectasis of the lower lobe.

Peter Kerley⁽⁹⁾ has formulated another classification. He divides carcinoma of the lung into six types from the radiological appearance.

1. Pneumonic form in which the affected lobe is seen as a moderately dense shadow sharply delineated by the interlobar septum.

2. Hilar form in which the hilum appears enlarged with a mass spreading from it.

3. Nodular form, very rare.

4. Cavernous type.
5. Metastatic type.
6. Diffuse type.

The descriptions in the case histories are based upon Melville's classification. An analysis of the radiological appearance showed that the commonest finding was an opacity suggesting atelectasis of part or of the whole of one lung. One case showed nothing abnormal whatever and it is interesting to note that a malignant cell was discovered in the sputum at this time.

It was found on analysis of the radiographical appearances in this series that they suggested:

Collapse of lung tissue	39 cases
Tumour infiltrating lung sometimes with collapse as well	2 cases
Pleura effusion	6 cases
Bronchiectasis	2 cases
Nil abnormal	1 case

The other suspicious findings in these cases were raising of one dome of the diaphragm, paralysis of the diaphragm on one side seen on the screen, and shifting of the heart and mediastinum to the side of the collapsed lung tissue.

A picture of lung collapse causes us to be very suspicious of carcinoma of the lung but it must be

remembered that it is not specific for that disease and in actual practice it is not always easy to differentiate between the picture of collapsed lung, consolidation of lung, fibrosis of lung or pleural thickening and bronchiectasis. It does indicate to us what further investigation is necessary. With such a picture further X-ray, after the introduction of lipiodol and bronchoscopy, should be done as a routine.

When collapse of the lung has taken place as a result of blockage of the bronchus by the growth the case is nearly always too far advanced for radical surgery. All the cases in this series fell into this category. It seems that we may have to look elsewhere than to radiology for diagnosis at a stage when lobectomy or pneumonectomy can be successfully carried out.

Case No.1 in the series and also the following case described by M. Davidson⁽³¹⁾ bare this out. A woman of twenty-seven who had been complaining of repeated slight attacks of haemoptysis in consequence of which she had been suspected of pulmonary tuberculosis. No abnormality was found on physical examination and the X-ray examination showed nothing abnormal. No Tubercle bacilli were found in her sputum. Lipiodol showed that in one of the smaller divisions of the branch of the right main bronchus, which supplies the lower lobe, the oil had failed to enter satisfactorily. Bronchoscopy revealed no block of the bronchus but the site of the bleeding was seen. It originated from a small reddish nodule, the size of a lentil or less, on the wall of one of the smallest bronchial divisions. No histological evidence was obtainable as the result of the bronchoscopy but the chest was explored and lobectomy performed. On macroscopic section of the lobe a small circumscribed fibrous mass was visible quite distinctly marked off from the surrounding lung tissue which looked normal. Microscopic sections of it presented the typical appearances of a carcinoma. The patient recovered and was alive and well without symptoms three years later.

LIPIODOL.

The introduction of Lipiodol into the bronchial tree is extremely valuable for demonstrating that there is stenosis or blockage of a bronchus. Sometimes also splaying of the main bronchi at the carina due to the presence of a mass of malignant glands can be seen and informs us that the mediastinal glands are heavily involved and the case inoperable. Lipiodol was used in 25 cases of the series and showed blocking of the bronchus in 22. In 3 cases no evidence of stenosis or obstruction was seen although a growth was seen later through the bronchoscope. As the demonstration of blocking of the bronchus in the X-ray film means that bronchoscopy must be performed immediately it is the custom now to proceed straight to bronchoscopy in many cases if the straight radiogram suggests collapse of lung tissue.

BRONCHOSCOPY

Bronchoscopy was performed in 36 cases and the malignant growth was seen in 33 cases and a piece of it was removed and showed carcinomatous tissue in all of these. In 3 cases the growth was not seen by means of the bronchoscope. Bronchoscopy is the best method we have of definitely proving that a growth is present in the bronchus. It also enables us to exactly locate the tumour and the histological type of growth and the degree of malignancy can be determined. The possibility of removing a malignant growth through the bronchoscope does not offer very much hope because of the risk of leaving some malignant tissue behind and it has not been used very much in treatment. Chevalier Jackson⁽⁴⁾ reports one case in which he successfully removed a malignant growth by the bronchoscope.

Although in the cases in this series the growth was of considerable size when seen through the bronchoscope, there is no reason why it should not be seen when it is at a much earlier stage and very much smaller. It would then offer much greater hope for radical surgical treatment.

The bronchoscope has this limitation, however, that one cannot see growths which arise peripherally. These are very much easier to remove than those which are situated near the hilum. It is necessary to have

at least one inch of normal tissue medial to the growth to perform a pneumonectomy. Bronchoscopy should, therefore, not be done only to verify a diagnosis of carcinoma of the lung which has been suspected because of abnormal physical signs and radiograms but should be used in every case at the earliest moment whenever suspicious symptoms are present.

THORACOSCOPY.

Thoracoscopy was not performed in any of the cases of this series and it does not appear to be of much use except for visualizing growth which has invaded the pleura.

THORACOTOMY.

Thoracotomy is not a more dangerous operation than laparotomy and whenever there is the slightest hope that surgery may cure the condition it should be performed. It was carried out in 5 cases in the series, and all were found to be unsuitable for pneumonectomy.

TREATMENT

In no case in this series was the growth successfully removed with cure of the condition. It must be admitted that we are faced with a difficult problem namely, to diagnose the condition early enough, but whereas a few years ago the mortality from lobectomy and pneumonectomy was so high that these operations were scarcely ever attempted, surgical technique is now so much improved that chest surgeons are performing these operations more and more. If radical surgery is to be successful there are three important conditions which must be fulfilled. First, there must be no evidence of metastasis to distant organs. This is difficult to be certain of clinically and indeed too often the first symptom of all is that caused by metastasis. This, however, was not the case in this series. Secondly, the mediastinal lymph glands must not be involved to a very great extent. This also is sometimes difficult to be sure of clinically and early diagnosis is important here again, and thirdly, the growth must not have infiltrated any other organ but must be confined to lung tissue.

That the trend of treatment is in the direction of radical extirpation is obvious from a study of the literature in which an increasing number of successful pneumonectomies is to be found. The actual surgical

technique is beyond the scope of this thesis but it is accepted that the best operation is a radical pneumonectomy with removal of the adjacent lymph glands. R. Brock⁽¹³⁾ was of this opinion in 1935 and after three years further experience stresses it even more strongly. W.E. Burnett⁽¹⁴⁾ had collected from the literature 12 successful cases of pneumonectomy for carcinoma of the lung up to 1934, subsequently he was able to collect another 13 successful cases after 1934. Graham and Singer⁽¹⁵⁾ reported the first successful removal of the entire left lung for carcinoma in 1933. Sauerbruch⁽¹⁷⁾ as long ago as 1920 reported a successful pneumonectomy for carcinoma of the lung in which the patient was alive and well three years later, after which he was not followed. Tudor Edwards⁽¹⁸⁾ described a pneumonectomy for carcinoma of the lung free from symptoms two years later and also a lobectomy of the right middle lobe for carcinoma which was free from symptoms 13 months later. Allen and Smith⁽¹⁹⁾ described in 1932 a case of lobectomy for carcinoma alive and symptomless two years later. R. Overholt⁽²⁰⁾ reported in 1935 that he had operated on 13 patients for carcinoma of the lung, but seven of them were found to have metastatic involvement. Pneumonectomy was performed in the other six cases with three recoveries. Two additional successful pneumonectomies were performed on patients with suppurated disease of the lung giving a total of five

successful operations.

At the Brompton Hospital⁽²¹⁾ in 1936, three successful lobectomies and two pneumonectomies were done for carcinoma of the lung, and in 1937 three lobectomies and four pneumonectomies for carcinoma of the lung.

The following Table shows the figures of three surgeons who may be considered as pioneers of modern chest surgery. Reinhoff's figures are most striking.

TABLE⁽²²⁾

Operative results for total pneumonectomy.

Surgeon	Total Cases	Patients surviving Operation	Remarks
Tudor Edwards	11	6	All 6 alive without evidence of recurrence.
Overholt	13	9	7 still alive without recurrence.
Reinhoff	(18	12	First series 1 stage operation.
	{		
	(12	12	Second series 2 stage operation. No deaths.

Before operation can be considered the clinical condition of the patient and age must be carefully gone into. Also a complete neurological examination to exclude metastasis to the central nervous system should be made and radiograms of the long bone, spine and skull should be taken. Sufficient evidence

is available, therefore, that pneumonectomy in the hands of some surgeons is a fairly safe and successful operation in properly selected cases of cancer of the lung and as the diagnosis of this disease in a patient is otherwise tantamount to signing a death warrant, it should, and I think will be carried out in increasing numbers. It is not forgotten, however, that the number of cases which fulfil the conditions of suitability is at the present time very small.

Other Methods of Treatment.

Nine cases in this series were treated by means of radium or X-rays. The opinion of the staff of the Royal Chest Hospital is that this method of treatment is not of much value. Of the four cases treated by the insertion of radon seeds by the bronchoscope, 2 were improved clinically for a time and only 1 of the cases treated by deep X-ray showed any improvement. In no case has life ever been saved by radium or X-rays in carcinoma of the lung.

CASE 1: E.G. Female. Age 58. Housewife.

She was sent up to hospital 15.11.36, complaining of cough of three months duration. One month previously she had coughed up about a teaspoonful of blood. There was no pain or loss of weight but she had been breathless on exertion for 2 months before coming to hospital.

On Examination:

Finger clubbing was present. No abnormal physical signs were found in the chest.

X-ray:

X-ray showed a normal appearance of the lungs. Lipiodol did not show an occlusion of the bronchus.

Sputum:

One cell was found which appeared malignant.

Progress: She was seen at the out-patient department at monthly intervals during the next 9 months as a diagnosis of ? bronchiectasis was made in spite of the normal appearance with lipiodol. The cough persisted. Two further straight X-rays at 2-monthly intervals were normal. In October 1937 X-ray film showed for the first time an increased hilar shadow and an opacity at the left base suggesting some collapse of the left lower lobe. Sputum at this time contained carcinoma cells. Bronchoscopy revealed a mass in the left main bronchus, section of a piece showed carcinomatous tissue. Thoracotomy was performed immediately but a hard lump was found in the left lower lobe and the diaphragm was adherent and thick due to the invasion of malignant tissue. Nothing further was done and the wound was closed. Deep X-ray therapy was tried and three months later the collapse at the

left base appeared to be less but the cough was just as bad. This patient is still alive at the time of writing. This case illustrates the necessity of investigating by all the accessory methods in spite of the absence of abnormal physical signs and abnormal radiographical appearances.

CASE 2: A.G.P. Male. Age 59. Clerk.

He was admitted to hospital 20.1.38, complaining of a cough which had started four years ago and had been continuous since and had not been relieved by medicine from his doctor. Six months ago he noticed red streaks in his sputum on several occasions. He coughed up about half an ounce of yellow sputum daily. He became breathless on exertion six months ago and this had become more severe. He had had no pain nor had he lost any weight.

History of Previous Illness:

Erysipelas 5 years ago.

On Examination:

Temperature 99°. A breathless man with clubbed fingers of the drum-stick type. Trachea was displaced to left. There were diminished air entry, tactile and vocal fremitus at the left base posteriorly.

X-ray:

Showed a haemogenous opacity at the left lower zone suggesting consolidation or collapse of lung. Lipiodol showed a filling defect in the left main bronchus.

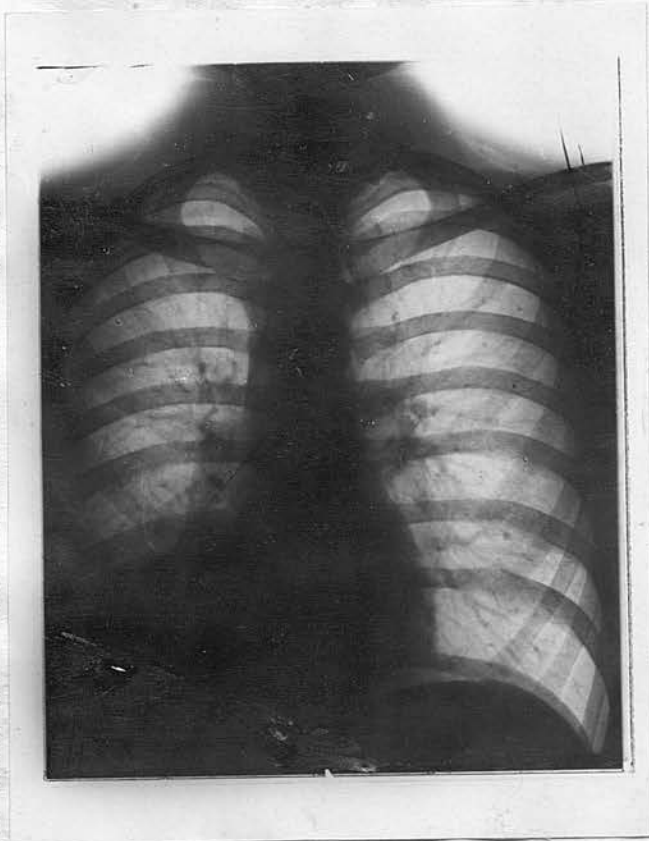
Sputum:

Carcinoma cells present.

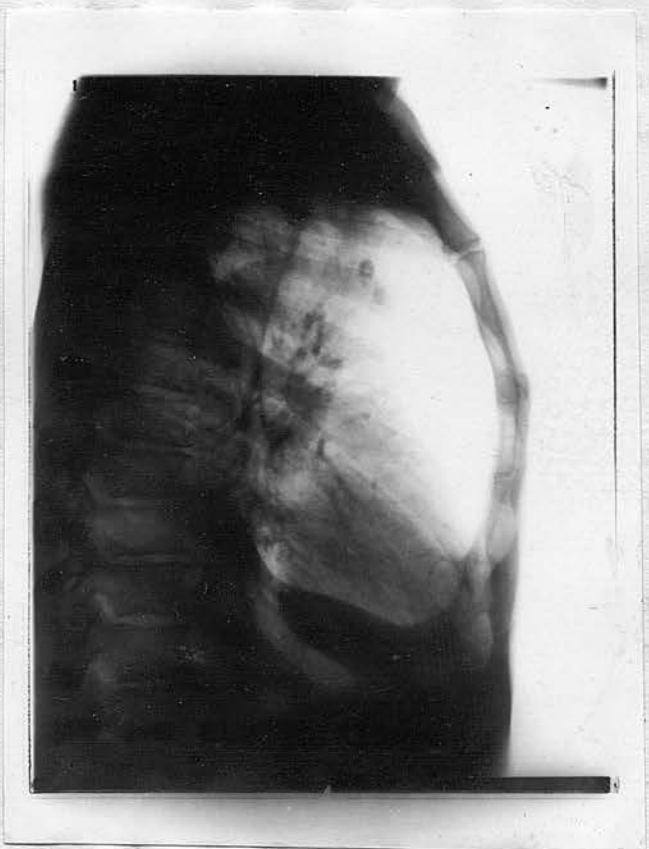
Bronchoscopy:

The lower end of the left bronchus was occluded by a necrosing mass of tissue. A piece removed for section showed necrotic tissue without structure but suspicious of carcinoma. Radon seeds were inserted intra-bronchially but without any improvement. He was discharged with a hopeless prognosis.

Sedimentation rate: 51 mm. First hour.



Case 3.
Collapse of Right Lower Lobe



Lateral view
showing collapse
of Right Lower Lobe

CASE 3: J.H. Male. Age 20. Bookstall Assistant.

He was admitted to hospital 6.2.36, complaining of a cough of three years duration. At the beginning he had had pain in the right chest which had not been relieved by his doctor's medicine. He coughed up half an ounce of mucoid sputum, but two months before admission there had been blood in it for a few days. He had been sent to sanatorium, thought to be suffering from pulmonary tubercle from 18.12.35 until 2.2.36. Tubercle bacilli had never been found in his sputum on many examinations. He had lost some weight during the past 6 months but was not short of breath.

On Examination:

Trachea displaced to the right. The breath sounds all over the right lung were weak. The percussion note was impaired at the right lower zone and occasionally fine rales could be heard in this area. Temperature 99.5°.

X-ray:

Showed an opacity in the right lower zone suggesting collapse of the right lower lobe. Lipiodol showed obstruction in the right lower lobe bronchus.

Sputum:

No carcinoma cells seen and no tubercle bacilli on ten examinations.

Sedimentation rate: 29 mm. first hour, 48 mm, second hour.

Bronchoscopy:

Showed a mass obstructing the right lower lobe bronchus. Section of a piece of it showed a typical highly malignant growth of undifferentiated cell type. He was given deep X-rays without any improvement in his condition and was rapidly going down-hill when last seen but did not die in hospital.

CASE 4: J.H. Male. Age 53. Engineer.

He was admitted to hospital 27.2.36, complaining of cough of 18 months duration which had not been helped by medicine. 3 months previously he had noticed streaks of blood in his sputum which was yellow and 2 ounces daily. He had lost 2 stone in weight during the past 18 months and had first noticed breathlessness on exertion 8 months before admission. He had no pain.

On Examination:

There were rhonchi in both lungs and the percussion note was impaired and breath sounds were weak at the right base posteriorly.

X-ray:

Showed an opacity at the right lower zone suggesting collapsed right lower lobe. The hilar shadow was increased on the right side. Lipiodol showed a filling defect in the right lower lobe bronchus.

Sputum:

Carcinoma cells present.

Bronchoscopy:

Revealed a mass in the lower part of the right bronchus. Section of a piece showed carcinomatous tissue. He refused radium treatment and was discharged, 18.3.36.

CASE 5: E.E. Male. Age 52. Gardener.

He was admitted to hospital 4.7.37, complaining of cough which had commenced 9 months before accompanied by pain in the lower part of the right chest. Five months before admission he had been sent to sanatorium, thought to be suffering from pulmonary tubercle and remained there for 9 weeks during which time he gained 12 lbs. in weight. Five weeks before admission he noticed streaks of blood in his sputum. He was slightly short of breath on exertion.

History of Previous Illness:

Malaria in 1902, pneumonia in 1925.

Family History:

Mother died cancer of the breast, father died carcinoma of larynx.

On Examination:

Temperature 99.8°. Early clubbing of fingers. At the right base breath sounds were weak and rales were present, tactile and vocal fremitus were diminished, percussion note was impaired.

Sputum:

Carcinoma cells present. No tubercle bacilli.

X-ray:

Showed an opacity at the right lower zone suggesting collapsed lung or bronchiectasis.

Sedimentation rate: 48 mm. first hour.

Bronchoscopy:

Revealed a large mass at the opening of the right lower lobe bronchus. Section of a piece of it showed squamous celled malignant tissue. He refused radon seeds, and was discharged 30.7.37.

CASE 6: A.W.N. Male. Age 65. Draughtsman.

He was admitted to hospital 6.1.38, complaining of cough and breathlessness on exertion which had come on 3 months previously. He coughed up half an ounce of mucoid sputum daily and had noticed streaks of blood in it occasionally for the past 2½ months. He had got thinner during the last 3 months.

History of Previous Illness: Nil.

Family History:

Father died of carcinoma of the stomach.

On Examination:

Trachea deviated to the left. There was diminished excursion of the left chest and the percussion note was impaired, breath sounds were very weak, tactile and vocal fremitus both diminished. It suggested collapsed lung or pleural effusion but deviation of the trachea to the same side as the abnormal signs favoured collapse.

Sputum:

Carcinoma cells present.

X-ray:

An opacity over the whole left lung. Heart and mediastinum shifted to left. Lipiodol showed blockage of the left main bronchus.

Bronchoscopy:

Revealed a large mass blocking the upper end of the left bronchus. Section of the piece showed carcinomatous tissue very active. Wasserman Reaction negative. From the time of admission he grew steadily worse and died after 2 weeks in hospital.

CASE 7: J.H.J. Male. Age 57. Porter.

He was admitted to hospital 2.3.34. He had developed a cough 2 years before and had become rather weak and easily tired one year before admission. He coughed up half an ounce of yellow sputum daily and had noticed streaks of blood in it occasionally for 3 months. He had lost 1½ stone in weight in the previous year and had been breathless on exertion for the past 6 months or so. No pain.

On Examination:

No clubbing. Temperature 99.2°. There was a dull note on percussion of the right upper zone in front. Breath sounds were diminished in this area.

Sputum:

Carcinoma cells present. No tubercle bacilli on 7 examinations.

X-ray:

Showed an opacity in the right upper zone suggesting collapse of right upper lobe.

Bronchoscopy:

Showed the right bronchus to be small in calibre. There appeared to be a narrowing due to pressure on the wall. A right artificial pneumothorax was induced and further X-ray showed the tumour with lung well collapsed around it. Mr. Hunter endeavoured to do a lobectomy. The pleura cavity was widely opened, the right upper lobe was ligatured medial to the new growth but owing to there being insufficient normal tissue medial to the ligature it was impossible to remove the lobe. He went down-hill and died in hospital 27.6.35.

CASE 8: J.G. Male. Age 46. Painter.

He was admitted to hospital 27.5.36, complaining of a very troublesome cough which had been constantly present for 7 months before admission and had not yielded to the medicine his doctor had given him. He had had previous attacks of cough during the past 12 years but these had only lasted for a week or two. His sputum was mucoid and occasionally he coughed up as much as 5 ounces daily. Six months before admission he coughed up a teaspoonful of blood and had occasionally seen streaks since. Shortness of breath on exertion and pain in the left chest had been present for 6 months. He had had pain on swallowing for 3 months the food seeming to stick at the lower end of the sternum.

History of Previous Illness:

Perforated gastric ulcer in 1923.

On Examination:

Temperature normal. Early clubbing of the fingers. There were diminished breath sounds at the left base and rales were audible at both places but more on the left than on the right.

Sputum:

Carcinoma cells present.

X-ray:

Showed an opacity suggesting collapse of the left lower lobe. Lipiodol did not enter the left lower lobe bronchus.

Bronchoscopy:

Showed a rounded mass obstructing the left lower lobe bronchus. Oesophagoscopy showed a normal oesophagus. A section of a piece of the mass removed from the bronchus showed a very proliferative carcinoma. He gradually became weaker and died in hospital 1.7.35. Necropsy was performed and showed a carcinoma of the left lower lobe bronchus infiltrating the oesophageal wall only.

CASE 9: F.M. Male. Age 60. Milk roundsman.

He was admitted to hospital 3.10.37. 3 months before he had developed a cough with sputum which was streaked at times. He had had pain in the right lower chest on deep breathing for 3 months. He had lost about 1 stone in weight, and was not short of breath.

History of Previous Illness: Nil.

Family History:

Brother died carcinoma of the stomach.

On Examination:

No clubbing. Diminished breath sounds, tactile and vocal fremitus at the right base behind.

Sputum:

Carcinoma cells present.

X-ray:

Showed a rather dense opacity in the right ^{upper} lower zone with a definite edge suggesting collapse of the right ^{upper} lower lobe. Lipiodol showed obstruction in the right main bronchus. The right diaphragm was raised.

Bronchoscopy:

Showed a ragged mass in the lateral wall of the lower end of the right bronchus. Section of a piece showed carcinomatous tissue. Wasserman Reaction ++

Sedimentation rate: 38 mm. first hour. Radon seeds were implanted, but patient gradually went downhill and died in hospital.

CASE 10: W.E. Male. Age 64. Plasterer.

He was admitted to hospital 12.8.37. He had had winter cough for many years. 3 months before admission the cough had become much worse and there were some blood clots in his sputum at this time. He coughed up 2 ounces of yellow sputum daily. He had been short of breath on exertion for 3 months and had lost a little weight.

On Examination:

His chest was rather rigid and very emphysematous. The breath sounds were harsh with prolonged expiration except at the left base behind where they were diminished. A few rales were audible here. Very suggestive of bronchiectasis following on prolonged bronchitis.

X-ray:

Showed emphysematous chest with an ill-defined opacity in the left lower zone which appeared to be spreading out from the mid-line behind the heart and had a rather blurred edge.

Bronchoscopy:

Revealed a hard sub-mucous swelling occluding the distal end of the left bronchus. Section of a piece showed malignant tissue.

Sedimentation Rate: 40 mm. first hour. He became much weaker in hospital and developed signs of metastasis in the brain and went into coma and died 29.9.37.

CASE 11: T.H. Male. Age 69. Builder.

He was admitted to hospital 11.11.37. 6 months previously he had developed a cough and shortness of breath on exertion. 3 months later he had a rather severe pain in the upper part of the left chest which had continued ever since. He coughed up 1 ounce of yellow sputum daily. No haemoptysis. He had been losing weight for 1 year before admission.

On Examination:

No clubbing. There was diminished excursion in the lower half of the left chest with weak breath sounds and diminished tactile and vocal fremitus.

Sputum:

No carcinoma cells found.

X-ray:

Showed a moderately dense opacity at the left base extending to about half way up the left border of the heart suggesting collapse of the left lower lobe. Lipiodol showed blockage of the left bronchus.

Bronchoscopy:

Showed a flat mound in the posterior and internal aspect of the lower part of the left bronchus. Section of a piece showed bronchial epithelium with some malignant tissue underneath.

Sedimentation Rate: 59 mm. first hour. No treatment was given and he was discharged.

CASE 12: G.S. Male. Age 46. Nightwatchman.

He was admitted to hospital 18.4.35, complaining of a pain in the chest which had come on suddenly one month ago on the right side. It had persisted but had become a little easier one week before admission. He had lost considerable weight during the past year. No breathlessness, no haemoptysis but he coughed up about 2 ounces of greyish sputum daily.

History of Previous Illness:

Cough since childhood. Nephritis 1915.

On Examination:

No clubbing. There was stoney dullness on percussion over the lower half of the right lung and tactile and vocal fremitus greatly diminished. Breath sounds were not heard in this area.

Sputum:

No carcinoma cells seen.

X-ray:

Showed a dense shadow on the right side suggesting effusion. Lipiodol showed no obstruction in the bronchial tree.

Bronchoscopy:

Revealed a mass projecting into the lower end of the right main bronchus. Section of a piece showed carcinomatous tissue. The pleural effusion was aspirated and a cloudy orange-coloured fluid was found. 30 ounces were removed. Microscopically it contained red blood cells and other cells which were suspicious of carcinoma. No tubercle bacilli were found in the fluid. He was discharged as no treatment was considered to be of any use.

CASE 13: W.W. Male. Age 49. Labourer.

He was admitted to hospital 26.10.36, complaining of cough which came on suddenly 11 months previously. At that time he coughed up a teaspoonful of blood. His cough had continued in spite of medicine from his doctor at various times and he had had frequent small haemoptyses. He coughed up half an ounce of yellow sputum daily and he had been breathless on exertion for 6 months. He had no pain but had got much thinner during the past year.

On Examination:

Clubbing of fingers and toes. There was stoney dullness to percussion over the lower half of the right lung and breath sounds were inaudible. Tactile and vocal fremitus greatly diminished.

Sputum:

Carcinoma cells present.

X-ray:

There was a moderately dense opacity in the lower half of the right lung suggesting tumour or fluid. Lipiodol showed obstruction of the right main bronchus.

Bronchoscopy:

Revealed a mass in the lower end of the right bronchus overlying the opening of the right lower lobe bronchus. Section of a piece showed carcinomatous tissue.

Sedimentation Rate. 66 mm. first hour, 70 mm.

second hour. No tubercle bacilli were found in the sputum. 20 ounces of fluid was aspirated from the chest. It was clear in colour and no carcinoma cells were found in it. He was discharged as he was considered too advanced for surgical treatment.

CASE 14: A.T. Male. Age 59. Driver.

He was admitted to hospital 22.10.35, complaining of a cough of two years duration which had not yielded to treatment by his doctor. He coughed up 1 ounce of yellow sputum daily and had first noticed streaks of blood in it 6 months before admission. Ny dyspnoea, no pain.

History of Previous Illness:

Pleurisy on the right side 20 years ago.

On Examination:

No clubbing. The right upper zone in front was very dull on percussion and a few rales could be heard. Trachea was displaced to the right side.

Sputum:

Carcinoma cells present.

X-ray:

Showed a dense shadow suggesting a growth spreading into the right upper lobe.

Bronchoscopy:

No new growth was seen in the lumen of the bronchus. He refused to have any treatment and was discharged.

CASE 15: J.R.H. Male. Age 66. Labourer.

He was admitted to hospital 26.6.36, complaining of a cough which had commenced 6 months previously. He coughed up one ounce of yellow sputum daily and had been breathless on exertion for 1 month. No haemoptysis, no pain, no loss of weight.

History of Previous Illness:

Diphtheria aged 24. ? Pleurisy on left side, aged 14, Hydrocoele 5 years previously, treated at St. Bartholomew's Hospital.

On Examination:

No clubbing. Temperature 99.5°. There were diminished breath sounds and rales at the right base behind. No other abnormality.

Sputum:

Carcinoma cells present.

X-ray:

Showed some old calcified tuberculous foci in both lungs and an opacity at the right base suggesting collapse or consolidation of the right lower lobe with some pleural thickening and peaking of the diaphragm. Lipiodol showed complete obstruction of the right lower lobe bronchus.

Bronchoscopy:

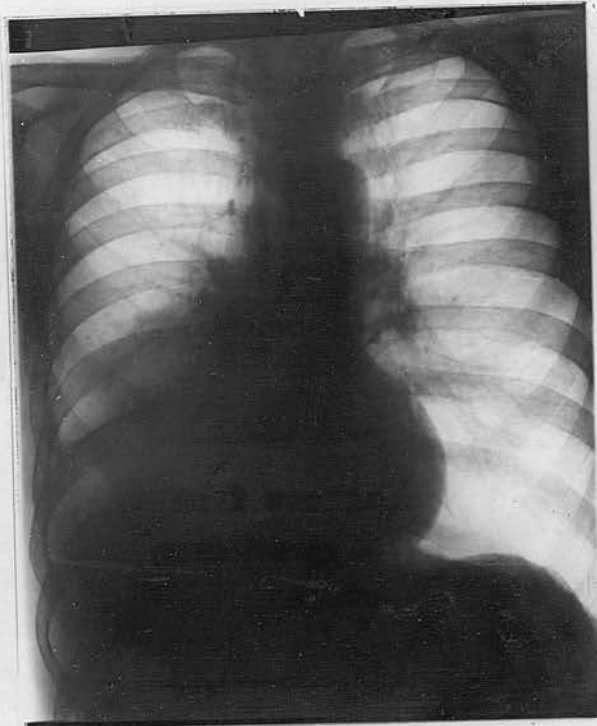
Revealed a large necrotic mass filling the lower end of the right bronchus. Section showed carcinomatous tissue.

Sedimentation Rate: 44 mm. first hour, 48 mm. second hour. It was thought to be advanced with probable spread to the diaphragm and he was discharged.

Case 15: J. B. E. White, Age 66, Laborer.

He was admitted to hospital 27.1.36, complaining of a cough which had come and gone previously. He coughed up one ounce of yellow sputum daily and has been breathless on exertion for 1 month. He has been treated with antibiotics, but with no effect. No haemoptysis, no pain, no loss of weight.

History of previous illness:



Case 16.

Collapse of Right lower lobe with
Some infiltration of lung tissue by
Growth spreading out from Right Hilum

hour. It was thought to be advanced with
probable spread to the diaphragm and to be
discharged.

Case 16: W.M. Male. Age 50. Engine Driver.

He was admitted to hospital 6.10.36, complaining of cough of three months duration. Pain in the right side of the chest and breathlessness on exertion had appeared at the same time. He coughed up half an ounce of mucoid sputum daily. No haemoptysis. No loss of weight.

On Examination:

No clubbing. Breath sounds were weak at the right lower zone and vocal and tactile fremitus diminished.

Sputum:

Carcinoma cells present.

X-ray:

Showed an opacity spreading out from the mid-line on the right side with a blurred edge suggesting infiltration or collapse of lung tissue.

Bronchoscopy:

Revealed a nodulated mass at the lower end of the right bronchus. Section of a piece showed malignant tissues. Lipiodol showed obstruction of the right main bronchus.

Sedimentation Rate: 31 mm. first hour, 47 mm. second hour. He refused radon seeds and was discharged.

CASE 17: J.P. Male. Age 67. Railway Fitter.

He was admitted to hospital 4.11.35, complaining of cough and shortness of breath which had started 14 months previously and had become progressively worse in spite of treatment. He coughed up $\frac{1}{2}$ ounce of yellow sputum daily. He noticed streaks of blood in the sputum shortly after the cough started. Breathlessness on exertion had suddenly become much worse about 6 months previous to admission. He had lost a great deal of weight he thought, in the last year. No pain.

On Examination:

No clubbing. There was impaired percussion note and breath sounds were weak over the lower half of the right lung behind. Course rales were numerous in this area. Vocal and tactile fremitus were diminished.

Sputum:

Carcinoma cells present.

X-ray:

Showed an opacity at the right lower zone suggesting infiltration of lung tissue and partial collapse. Lipiodol showed some obstruction in the right main bronchus and right basal bronchiectasis.

Bronchoscopy:

Showed stricture of the right main bronchus and a mass obstructing the right lower lobe bronchus. Section of a piece showed malignant tissue.

Sedimentation Rate: 34 mm. first hour. It was considered that the growth was too near the mediastinum for surgical intervention and he was discharged.

CASE 18: H.H. Male. Age 61. Labourer.

He was admitted to hospital 28.6.37. He had had an attack of 'influenza' 7 months before admission. This had left him with a cough which had persisted. He coughed up about ½ ounce of mucopurulent sputum daily. He had coughed up some clots of blood 5 months before admission. Pain had been present on the right side of his chest on coughing for 3 months and he had been breathless on exertion and had lost 7 lbs. in weight during the past 4 months. He had to give up work 4 months ago on account of the severe cough and breathlessness for which he had received treatment without improvement.

History of Previous Illness:

Mastoid operation 1933.

On Examination:

No clubbing. Dull percussion note and weak breath sounds at the right upper zone in front.

Sputum:

Carcinoma cells present.

X-ray:

Showed a haemogenous opacity limited to the right upper lobe suggesting collapse.

Bronchoscopy:

Showed the right bronchus to be narrowed immediately after its beginning and the right upper lobe bronchus was occluded by a mass. Section of a piece showed carcinomatous tissue.

Sedimentation Rate. 23 mm. first hour. The growth was too near the mid-line to do anything and he was discharged.

CASE 19: T.W. Male. Age 63. Warehouseman.

He was admitted to hospital 9.12.35, complaining of cough of six months duration. He coughed up half an ounce of yellow sputum daily. He had had pain in the left axillary region for 4 months which had been treated as fibrositis. He had lost some weight in the last year. No haemoptysis. No dyspnoea.

On Examination:

No clubbing. Weak breath sounds and a few rales at the right base posteriorly.

Sputum:

No carcinoma cells present.

X-ray:

Showed an opacity at the lower half of the right lung suggesting collapse of right lower lobe. Lipiodol showed obstruction in the right main bronchus.

Bronchoscopy:

Showed a cauliflower growth projecting from the right lower lobe bronchus. Section of a piece showed carcinomatous tissue. He died in hospital one month later. Necropsy revealed a bronchiectasis secondary to carcinoma surrounding one of the primary tributaries of the main bronchus to the lower lobe of the right lung. The only secondary deposit was a small one in the mediastinal connective tissue.

CASE 20: J.C. Male. Age 59. Commission Agent.

He was admitted to hospital 5.8.35, complaining of cough which had come on 2 years before admission and he brought up half an ounce of yellow sputum daily. 3 months before admission he suddenly became short of breath on exertion and developed a pain in the left lower chest. Medicine from his doctor had not helped him. He had lost about 1 stone in weight during the past year, 10 days before admission he coughed up a large quantity of blood, about 1 pint he thought.

On Examination:

Temperature 99.6°. No clubbing. Trachea displaced to the left. Diminished excursion. Impaired percussion and weak breath sounds over the whole of the left lung.

Sputum:

Carcinoma cells present.

X-ray:

Showed trachea and heart displaced to the left and an opacity suggesting collapse of the left lung.

Bronchoscopy:

Showed the left main bronchus was partially obstructed by an irregular mass of board-like rigidity. Section of a piece showed carcinomatous tissue. Lipiodol showed a filling defect of the left main bronchus. No treatment was given and he was discharged.

CASE 21: E.W. Female. Age 50. Housewife.

She was admitted to hospital 28.8.35, complaining of a cough which had been present for 8 months and shortness of breath which had commenced 5 months before admission. She coughed up half an ounce of clear mucoid sputum daily. No pain, no haemoptysis, no loss of weight.

On Examination:

The trachea was displaced to the left, there was stoney dullness on percussion on the right side to within 2 inches of clavicle. Breath sounds were inaudible over this area. 80 ounces of clear fluid were aspirated with gas replacement.

X-ray:

Showed a hydropneumothorax with collapsed lung but no growth was visible. Thoractomy was performed by Mr. Hunter and a hard lump was felt in the collapsed lung tissue, also a mass was felt in the diaphragm and another in the parietal pleura. A piece was removed for section and proved to be carcinomatous tissue. The wound was closed as surgery was considered hopeless on account of the secondary masses in the pleura and diaphragm.

Sputum:

No carcinoma cells but carcinoma cells were found in the pleural effusion.

CASE 22: H.T.C. Male. Age 64. Painter.

He was admitted to hospital 9.8.36, complaining of a cough which had been present for 3 years. At the very beginning of his cough he had noticed streaks of blood in his sputum on several occasions. He coughed up one ounce of yellow sputum daily and had been very short of breath on exertion 4 months before admission. He had lost about 2 stone in weight during the past year. No pain.

On Examination:

Finger clubbing was present. Breath sounds were weak over the whole of the right lung and percussion note was impaired on the right side.

Sputum:

Carcinoma cells present.

X-ray:

Showed collapse of the right lung and trachea deviated to the right. Lipiodol showed a block in the right main bronchus.

Bronchoscopy:

Showed a mass in the right main bronchus. Section of a piece showed carcinomatous tissue. The growth was too near the mid-line for anything surgical to be done and he was discharged.

CASE 23: T.A. Male. Age 59. Nightwatchman.

He was admitted to hospital 8.11.35, complaining of a cough which had started 9 months previously and had gradually become worse inspite of treatment from his doctor. Breathlessness had appeared at the same time as the cough. He coughed up half an ounce of clear mucoid sputum daily. He had lost 2 stone in weight during the past year. No haemoptysis, no pain.

On Examination:

No clubbing. There was impaired percussion note and the breath sounds were very weak at the right upper zone in front.

Sputum:

No carcinoma cells found.

X-ray:

Showed a haemogenous opacity suggesting collapse of the right upper lobe.

Bronchoscopy:

Revealed a hard mass projecting into the upper and postero-lateral part of the right bronchus. Section of a piece showed carcinomatous tissue. It was thought to be too near the mid-line for operation and he was discharged.

CASE 24: S.C. Male. Age 46. Hat Manufacturer.

He was admitted to hospital 19.10.36. Cough suddenly came on 10 months before admission. He felt ill and his doctor kept him in bed for 4 weeks but the cough had not improved. He had been very short of breath for 3 months before admission. One ounce of yellow sputum daily. No haemoptysis, no pain.

On Examination:

His face and neck were swollen and oedematous. There was also slight oedema of the chest wall. It was very difficult to make out any abnormal physical signs in the lung.

Sputum:

Carcinoma cells were present.

X-ray:

Showed an opacity in the right upper zone suggesting a mass of tumour. He was considered unsuitable for bronchoscopy and died after 3 weeks in hospital.

CASE 25: C.H.G. Male. Age 54. Engineer.

He was admitted to hospital 13.12.35. His cough had started 3 years before admission and gradually became worse and worse. 11 months ago he had had an attack of pain in the left side with fever which his doctor diagnosed as pleurisy. He was kept in bed for 8 weeks. 4 months before admission he noticed streaks of blood in his sputum for several days. He coughed up $\frac{1}{4}$ ounce of yellow sputum. He had been breathless and had lost 1 stone during the past year.

On Examination:

Marked finger clubbing. Temperature 99.6° . The lower half of the left chest was stoney dull on percussion, breath sounds were inaudible and vocal and tactile fremitus greatly diminished. 20 ounces of fluid was removed and his chest was then X-rayed, but there was still an opacity due to fluid.

Sputum:

No carcinoma cells found. The fluid which was aspirated contained endothelial cells but no malignant cells were found.

Bronchoscopy:

Revealed a mass obstructing the entrance of the left lower lobe bronchus, section of a piece showed carcinomatous tissue. 3 radon needles were inserted into the growth and he became less breathless for 2 months but then began to lose ground and went down-hill.

Sedimentation Rate: 4 mm. first hour.

CASE 26: A.G.H. Male. Age 42. Gardener.

He was admitted to hospital 7.1.36. 9 months before admission he had developed a cough with temperature and had been sent to bed by his doctor. The cough disappeared for several weeks at this time but then re-appeared and had persisted ever since in spite of treatment. He coughed up one ounce of yellow sputum daily and three months before admission it had been blood-stained for 7 days. He had been very short of breath on exertion and had lost 8 lbs. in weight during the past 9 months. No pain.

On Examination:

Slight clubbing of the fingers. The percussion note was impaired and breath sounds were very weak at the right base posteriorly.

Sputum:

No carcinoma cells found.

X-ray:

Showed an opacity at the right lower zone suggesting infiltration of lung or collapse. Lipiodol showed partial obstruction of the right main bronchus.

Bronchoscopy:

Revealed a large rounded mass at the lower end of the right main bronchus. Section of a piece showed carcinomatous tissue. Radon seeds were inserted into the growth with temporary improvement of his clinical condition but 3 months later he died.

CASE 27: C.S. Male. Age 65. Theatrical.

He was admitted to hospital 28.8.35, complaining of a cough which had been present for 7 years. For 2 years before admission he had noticed streaks of blood in his sputum on many occasions. He coughed 3 ounces of sputum daily and it was yellow in colour. He had suffered with pain on the left side of the chest for 2 years before admission and on several occasions had been treated by his doctor for fibrositis. He had been breathless for 2 years and had gradually lost 2 stone in weight in the past 2 years.

On Examination:

No clubbing. Temperature 100° . At the left base the percussion note was impaired, breath sounds were weak and tactile and vocal fremitus diminished.

Sputum:

Carcinoma cells present.

X-ray:

Showed an irregular opacity at the left lower zone suggesting tumour or collapse of lung.

Bronchoscopy:

Showed the left lower lobe bronchus was occluded by an irregular mass. Section of a piece showed carcinomatous tissue. Wasserman Reaction ++. He refused any treatment and was discharged from hospital with a hopeless prognosis.

CASE 28: F.W. Male. Age 51. Mantle Manufacturer.

He was admitted to hospital 26.11.35. He had started to cough suddenly 9 months before admission and the cough had continued in spite of treatment. He coughed about one ounce of clear mucoid sputum daily. Breathlessness on exertion had commenced at the same time as the cough and it had gradually become very severe. He had had continuous pain in the left chest for the past 2 months and had become much thinner during the last year. No haemoptysis.

On Examination:

Slight clubbing. Temperature 99°. There was impaired percussion note over the lower half of the left lung behind. Breath sounds were very weak over this area, tactile and vocal fremitus diminished.

Sputum:

No carcinoma cells found.

X-ray:

showed an opacity in the left lower zone suggesting collapse of the left lower lobe.

Bronchoscopy:

Showed a mass occluding the left lower lobe bronchus. Section of a piece showed carcinomatous tissue.

Sedimentation Rate. 54 mm. first hour. He

rapidly went down-hill and died in hospital 9.12.35. At necropsy it was found that the lower half of the left lung was very oedematous and small white necrotic masses were scattered throughout this area. A mass was found at the opening of the left lower lobe bronchus but no metastases in glands or elsewhere.

CASE 29: W.C. Male. Age 61. Taxi Driver.

He was admitted to hospital 24.7.36. He had had a cough for many years but it had become very much worse 6 months before admission and 1 year before admission he had coughed up large clots of blood for 5 days. He coughed one ounce of yellow sputum daily. Breathlessness had been present for the past 6 months and pain in the right chest for 5 weeks before admission.

On Examination:

No clubbing. There were no signs of emphysema but there were weak breath sounds at the right lower zone behind and a few rales. Blood-pressure 230/120.

Sputum:

Carcinoma cells present.

X-ray:

Showed an opacity suggesting infiltration or collapse of the right lower lobe. Wasserman negative.

Bronchoscopy:

Showed a mass occluding the opening of the right lower lobe bronchus. Section of a piece showed carcinomatous tissue. Lipiodol did not enter the right lower lobe bronchus.

Sedimentation Rate. 55 mm. first hour. No treatment was given and he was discharged from hospital.

CASE 30: A.J.H. Male. Age 61. Engineer.

He was admitted to hospital 17.9.36. He had had a cough for 15 years but it had become much worse one year previously when he coughed up about 1 teaspoonful of blood. He was treated by his doctor at this time without improvement. He had become very short of breath on exertion 4 months before admission and had lost 1 stone in weight during the past year. No pain.

On examination:

No clubbing. There were diminished breath sounds and rales at the right base posteriorly.

Sputum:

Carcinoma cells present.

X-ray:

Showed an increased bronchial striation at both lower zones but much more on the right side. Lipiodol showed bronchial dilatation at both bases but no evidence of block.

Bronchoscopy:

Revealed an irregular mass occluding the posterior branch of the right main bronchus. Section of a piece showed carcinomatous tissue. Wasserman Reaction doubtful. He did not wish to have any surgical treatment and was discharged.

CASE 31: A.B. Male. Age 49. Carpenter.

He was admitted to hospital 6.1.37 on account of a cough which had started suddenly 10 months before and had persisted in spite of medicine given him by his doctor at that time. 10 weeks before admission he had been forced to give up work because it was so troublesome. 6 months before he had coughed up a cupful of blood and his sputum had been blood-stained for several days after this. Straight X-ray at this time revealed no abnormality. He coughed up one ounce of yellow sputum daily and had been short of breath on exertion for 10 months. He had no pain but had lost some weight.

On Examination:

Fingers clubbed. Percussion note was impaired at the left base behind and breath sounds were very weak in this area.

Sputum:

Carcinoma cells present.

X-ray:

Showed an opacity at the left base suggesting collapse of lung tissue. Heart and mediastinum shifted to the left. Lipiodol showed some stenosis of the left lower lobe bronchus.

Bronchoscopy:

Did not reveal any organic obstruction in the bronchi.

Sedimentation Rate: 33 mm. first hour.

Wasserman Reaction negative. He was treated with deep X-rays and with some slight improvement but I have been unable to find out what became of him.

CASE 32: E.E. Male. Age 65. Newsagent.

He was admitted to hospital 1.9.37. One year before admission he had a febrile attack which kept him in bed for three weeks and it was accompanied by cough which had persisted in spite of treatment from his doctor. 6 months before admission he coughed up some green sputum with blood in it and this had continued for some days. He had gradually become thinner, weaker and breathless during the past 9 months. No pain.

On Examination:

Clubbing of fingers. Weak breath sounds at the left base behind, percussion note was impaired and tactile and vocal fremitus greatly diminished over this area.

Sputum:

Carcinoma cells present.

X-ray:

Showed an opacity in the left lower zone suggesting collapse of lung. The mediastinal shadow was increased. Lipiodol did not enter the left lower lobe bronchus.

Wasserman Reaction negative. He was not well enough for bronchoscopy and gradually became weaker and died after 4 weeks in hospital.

CASE 33: H.N. Male. Age 61. Butcher.

We was admitted to hospital 14.5.37, complaining of cough of 6 months duration accompanied by yellow sputum which had been blood-stained on and off for six months. He had been breathless on exertion for six months and had had severe continuous pain in the left chest for two months before admission. He had lost 2 stone in weight during the past six months.

On Examination:

No clubbing. Temperature 99.2° . The left side of the chest was flatter than the right and its excursion was diminished. Percussion note was impaired all over the left chest and breath sounds were weak over the lower half in front and behind. No added sounds were heard. Tactile and vocal fremitus were slightly diminished.

Sputum:

Carcinoma cells present.

X-ray:

Showed shift of the heart and trachea to the left and collapse of the left lung.

Bronchoscopy:

Showed a large mass in the proximal part of the left main bronchus. Lipiodol showed a block in the left main bronchus. Section of a piece of the growth showed carcinomatous tissue. The growth was too near the mid-line for surgery.

CASE 34: M.C. Female. Age 64. Housewife.

She was admitted to hospital 1.3.37. One year previously she had developed a cough and had been in bed for 3 weeks but the cough had persisted ever since. X-ray at this time had revealed no abnormality. She had been very breathless on exertion since this attack. She coughed up $\frac{1}{2}$ an ounce of mucoid sputum and 4 months before admission had coughed $\frac{1}{2}$ an ounce of blood. She had no pain but had lost some weight.

On Examination:

No clubbing. There was stoney dullness to percussion on the right side extending up to the clavicle in front and breath sounds were not audible in this area. Behind dullness extended half way up the lung. Tactile and vocal fremitus were absent.

Sputum:

No carcinoma cells found.

X-ray:

Showed an opacity over the whole of the right side of the chest. 50 ounces of coffee-coloured fluid were aspirated and malignant cells were found in the fluid. She went down-hill rapidly and died in hospital. At necropsy a growth was found in the right main bronchus and deposits on the pleura and diaphragm. Section of a piece showed carcinomatous tissue.

CASE 35: J.H. Male. Age 49. Scaffolder.

He was admitted to hospital 31.10.36. He had had a cough all his life but it had become rather worse and for the past year he had contracted numerous 'colds'. He had lost some weight during the past year. No breathlessness, no haemoptysis. He coughed up about 2 ounces of yellow sputum daily and had had a severe and continuous pain in the lower part of his right chest for 3 weeks before admission.

On Examination:

No clubbing. Temperature 99.6°. Breath sounds were weak at the right lower zone behind and a few rales were audible.

Sputum:

No carcinoma cells found.

X-ray:

Showed an opacity in the right lower zone suggesting collapse.

Bronchoscopy:

Showed a mass in the right bronchus. Section of a piece showed carcinomatous tissue. Thoracotomy was performed and the right lower lobe was found collapsed and a small hard lump could be felt in it. A lump was also felt in the liver which was thought to be a secondary deposit and so nothing radical was done.

CASE 36: J.F. Male. Age 38. Lorry Driver

He was admitted to hospital 11.8.37. He developed a cough suddenly 8 months before admission and this had persisted in spite of treatment by his doctor. At the same time he had become breathless on exertion. He had no sputum, no pain and no haemoptysis but had lost a good deal of weight.

On Examination:

No clubbing. There was impaired percussion note in the right lower zone and breath sounds were weak in this area.

X-ray:

Showed an opacity suggesting collapse of the right lung. Lipiodol showed stenosis of the right bronchus.

Bronchoscopy:

Showed a mass in the right main bronchus. Section of a piece showed carcinomatous tissue. The situation of the growth was considered too high and medial for surgery to be successful.

CASE 37: C.E. Male. Age 58. Lorry Driver.

He was admitted to hospital 12.12.37.

He had had a cough for 20 years and had brought up about 1½ ounces of clear sputum for many years. Pain suddenly developed in the left upper chest in front 4 months before admission and it had been continuous ever since. The pain was not affected by coughing or deep breathing. He had been breathless on exertion for 4 months before admission. 2 months previous to admission he had noticed streaks of blood in his sputum and on several occasions since. He had lost 1 stone in the last year.

History of Previous Illness:

6 months before admission he was confined to bed for 2 weeks with a febrile attack diagnosed as pneumonia by his doctor and had felt ill ever since. 6 years ago he had had an operation for perforation of gastric ulcer.

On Examination:

Percussion note in the left upper zone in front and behind was dull and breath sounds were weak in this area.

Sputum:

Carcinoma cells present.

X-ray:

Showed an opacity in the left upper zone suggesting collapse of left upper lobe. His condition prevented bronchoscopy. He became much weaker and died after one week in hospital.

CASE 38: E.J.H. Male. Age 45. Tram Conductor

He was admitted to hospital 2.6.37. He developed a cough 1½ years before admission and this had persisted in spite of treatment on several occasions by his doctor. Soon after the cough commenced he had coughed up a teaspoonful of blood. He was sent to a sanatorium thought to be suffering with pulmonary tuberculosis and remained there for 5 months. No tubercle bacilli were ever found in his sputum. He had lost about 2 stone in weight in 2 years and had continuous pain in the left chest for 3 months before admission. He coughed up about 1 ounce of yellow sputum daily.

On Examination:

No clubbing. There was stoney dullness on percussion over the left chest in front and behind and the breath sounds were inaudible.

Sputum:

Carcinoma cells present. No tubercle bacilli were found.

X-ray:

Showed a dense opacity over the whole of the left chest. Fluid was aspirated on many occasions from the left chest. It was thick and yellow and contained numerous polymorphonuclear leucocytes but no malignant cells. He went down-hill and died after 3 weeks in hospital. He was too ill for bronchoscopy. At necropsy empyema was found and a mass in the left bronchus with a large abscess and breaking down lung tissue beyond it.

CASE 39: G.W. Male. Age 50. Guard.

He was admitted to hospital 19.10.37, complaining of cough and shortness of breath and continuous sub-sternal pain which had been present for 8 weeks before admission. He coughed up 1 ounce of yellow sputum daily and had never seen any blood in it. He had lost a good deal of weight in the 6 months previous to admission.

On Examination:

No clubbing. There was impaired percussion note and weak breath sounds at the right lower zone behind.

Sputum:

Carcinoma cells present.

X-ray:

Showed an opacity at the right base suggesting collapse of the right lower lobe.

Sedimentation Rate: 36 mm. first hour.

His clinical condition prevented bronchoscopy and he died in one week.

CASE 40: T.S. Male. Age 64. Fishmonger.

He was admitted to hospital 3.9.35. He complained of a cough which had come on suddenly 5 years previously and had persisted in spite of treatment. He brought up $\frac{1}{2}$ an ounce of clear sputum daily and had noticed streaks of blood in it on many occasions about 6 months ago. He had lost 2 stone in weight in the past year and had become very breathless on exertion 6 months before admission.

On Examination:

Clubbing of the fingers. Diminished excursion on the left side of the chest, percussion note was impaired and breath sounds were weak all over the left chest. Trachea deviated to the left.

Sputum:

No carcinoma cells found.

X-ray:

Showed an opacity suggesting collapse of the left lung. Lipiodol showed block of the left main bronchus.

Bronchoscopy:

There was a large mass in the upper end of the left main bronchus. Section of a piece showed carcinomatous tissue. The growth was too high and medial for surgery to be successful.

CASE 41: J.W. Male. Age 54. Clerk.

He was admitted to hospital 16.10.35. He had had a severe cough which had started 1½ years before admission and about this time he had coughed up a teaspoonful of blood. He had had continuous pain in the right chest for 1 year. Sputum 1 ounce daily, yellow in colour. He had been short of breath for 7 months before admission and had lost weight. Before admission to hospital he had just spent 8 months in a sanatorium thought to be suffering with pulmonary tubercle although no tubercle bacilli had been found in his sputum on many examinations.

On Examination:

Well marked finger clubbing. There was a mass of hard fixed glands in the right axilla. The percussion rate was impaired in the right upper zone. Breath sounds were weak and rales present in this area both in front and behind.

Sputum:

Carcinoma cells present.

X-ray:

Showed dense shadow in the right upper zone suggesting a mass of tumour. Nothing else was done on account of the secondary deposit in axilla.

CASE 42: H.F. Male. Age 55. Dustman

He was admitted to hospital 1.8.35. He had had cough for 20 years but had become very much worse 1 year before admission. Sputum 1 ounce of clear mucoid type daily. No haemoptysis. He had lost considerable weight and had been breathless on exertion for 1 year. No pain.

History of Previous Illness:

Pneumonia 1911, gastric ulcer 1928.

On Examination:

No clubbing. The percussion note was hyper-resonant all over the chest, expansion was only $\frac{3}{4}$ of an inch, rhonci were numerous and the breath sounds were harsh in quality. Breath sounds were very weak at the lower half of the right chest.

Sputum:

Carcinoma cells present.

X-ray:

Showed some healed tubercle at the left apex. There was an opacity in the whole of the right chest suggesting collapse of the right lung. No tubercle bacilli found in the sputum. Wasserman Reaction negative.

Sedimentation Rate: 45 mm. first hour.

Bronchoscopy was not performed owing to his poor condition and he died after 12 days in hospital.

CASE 43: E.M. Male. Age 52. Laborer.

He was admitted to hospital 6.3.36. He had developed a cough 2 years before admission and it had persisted in spite of treatment at various times by his doctor. He had been breathless on exertion for 2 years. Sputum $\frac{1}{2}$ an ounce clear mucoid in type daily and haemoptysis of 1 teaspoonful 6 months before admission. He had no pain but had lost a little weight.

On Examination:

Fingers were clubbed. There were weak breath sounds and rales at the left base behind.

Sputum:

Carcinoma cells present.

X-ray:

Showed an opacity suggesting collapse of the left lower lobe. Lipidol showed stenosis of the left lower lobe bronchus.

Bronchoscopy:

Revealed a mass occluding the left lower lobe bronchus. Section of a piece showed carcinomatous tissue. Wasserman Reaction negative. Radon seeds were advised but he refused treatment.

CASE 44: A.H. Male. Age 56. Carpenter.

He was admitted to hospital 25.5.36. He had had a cough for 40 years and it had become much worse one year before admission. He coughed up 1½ ounces of yellow sputum daily and 8 months previously there were small clots of blood in it every day for a month. He had been short of breath for 3 months and had lost some weight in the last year. No pain.

On Examination:

No clubbing. There were signs of emphysema and a few scattered bronchi on both sides of the chest. The percussion note was dull at the right upper zone in front.

Sputum:

Carcinoma cells present.

X-ray:

Showed an emphysematous chest with an opacity in the right upper zone suggesting collapse of the right upper lobe. Lipiodol showed a filling defect of the eparterial bronchus.

Sedimentation Rate: 64 mm. first hour. He was given deep X-ray therapy but died 4 months later.

CASE 45: J.L. Male. Age 54. Plumber.

He was admitted to hospital 13.5.36. He complained of a cough which had been present every winter for 10 years but had become much worse 6 months before admission. He coughed up 1 ounce of clear sputum daily and about 4 months before admission he noticed streaks of blood in his sputum on several occasions. He had pain in the left upper chest, worse on breathing, for 4 months before admission and had become very breathless during the past 6 months. He had lost some weight.

History of Previous Illness:

Pneumonia 1921.

On Examination:

No clubbing. Percussion note was impaired and breath sounds were weak in the left upper zone in front.

Sputum:

Carcinoma cells present

X-ray:

Showed a dense opacity in the left upper zone suggesting collapse of left upper lobe. Liliodpl showed obstruction in the middle branch in the left upper lobe bronchus.

Sedimentation Rate: 60 mm. first hour. Wasserman Reaction negative. He refused any further treatment.

CASE 46: S.S. Female. Age 69. Housewife.

She was admitted to hospital 29.5.36. Cough had started suddenly 4 months before admission and had persisted and at the same time a dull pain in the upper part of the right chest had come on. She coughed up $\frac{1}{2}$ an ounce of clear sputum. No haemoptysis. She had been short of breath on exertion and had lost a good deal of weight during the past 6 months.

On Examination:

No clubbing. There were weak breath sounds and impaired percussion note in the right upper zone in front and behind.

Sputum:

Carcinoma cells present.

X-ray:

Showed an opacity in the right upper zone suggesting collapse of right upper lobe. Her condition was very poor and she died in 2 weeks. At necropsy there was a large growth in the right upper lobe bronchus which had spread into the lung tissue and was breaking down. The lung was collapsed around it. No metastases were found. Section of a piece of the growth showed carcinomatous tissue.

CASE 47: E.F. Male. Age 47. Painter.

He was admitted to hospital 13.12.37. He had been well until October 1928 when he had broncho-pneumonia, thereafter he had several attacks of bronchitis every winter. In 1931 he coughed up $\frac{1}{2}$ an ounce of blood on one occasion only but since 1932 he had coughed up clots of blood on many occasions. For $1\frac{1}{2}$ years before admission the cough had been continuous and severe in spite of treatment by his doctor and he had become short of breath at this time. He had lost considerable weight in the last year. No pain.

On Examination:

No clubbing. Trachea displaced to the left.

Diminished excursion of the left chest.

Impaired percussion note and very weak breath sounds on the left side of the chest.

Sputum:

Carcinoma cells present.

X-ray:

Showed collapse of the left lung, heart and trachea shifted to the left.

Bronchoscopy:

Revealed a large hard mass high up the left bronchus and occluding it. Section of a piece showed carcinomatous tissue. The growth was too high and medial for surgery to be successful. No treatment was given.

CASE 48: E.G. Female. Age 50. Cleaner.

She was admitted to hospital 14.4.36. Six months before admission she had been an in-patient at Middlesex Hospital for 9 weeks with an illness which was at first diagnosed as pneumonia. As the condition did not clear up bronchoscopy was performed there and a growth was seen and she was advised to transfer to Brompton Hospital with the idea that something surgical might be done, but she refused. She had no pain and was not short of breath and her cough had persisted until she was admitted.

On Examination:

There were weak breath sounds and rales in the right upper zone in front and the percussion note was impaired in this area.

Sputum:

Carcinoma cells present.

X-ray:

Showed an opacity in the right upper zone suggesting collapse.

Sedimentation Rate: 35 mm. first hour.

It was decided to operate and she agreed. The chest was opened and the posterior part of the right upper lobe was felt and a very hard lump the size of a walnut was felt in it. This lump was adherent to the pleura. It was felt on account of this that lobectomy would not be successful and the wound was closed.

CASE 49: H.M. Female. Age 45. Cook.

She was admitted to hospital 13.8.36. Cough came on suddenly 6 months before admission and she had coughed up 5 ounces of blood 3 months before admission. 9 weeks before admission she developed a severe pain in the right lower chest for which she attended St. Bartholomew's Hospital, but at this time X-ray showed no abnormality. She had lost about 8 lbs. in weight and had been very breathless on exertion during the past 3 months. She coughed up about 4 ounces of yellow sputum daily.

On Examination:

No clubbing. Breath sounds were weak and percussion note impaired at the right upper zone in front.

Sputum:

Carcinoma cells present.

X-ray:

There was an opacity in the right upper zone suggesting a mass of tumour.

Thoracotomy:

Thoracotomy was performed, the pleura was exposed and found to be thickened and adherent and a large hard mass was felt in the right upper lobe. Nothing radical was done as it was thought that the pleura was heavily involved with malignant disease.

Bronchoscopy:

No evidence of new growth was seen.

Sedimentation Rate: 65 mm. first hour.

CASE 50: J.F.P. Male. Age 56. Labourer.

He was admitted to hospital 21.2.36. Cough had developed suddenly 1 year before admission. At the onset his doctor had kept him in bed for 3 weeks but the cough had not improved much. After this attack he had noticed that he was short of breath on exertion. He coughed up 1 ounce of yellow sputum daily and had noticed streaks of blood in it on many occasions during the 6 months before admission. He had lost weight during the last year. He had no pain but his voice had been husky for 3 months before admission.

On Examination:

No finger clubbing. A hard mass of glands was palpable in the left supra-clavicular region. Percussion note was very dull in the left upper zone and breath sounds very weak on this side.

Sputum:

Carcinoma cells present.

X-ray:

There was an opacity in the left upper zone suggesting a tumour mass.

Bronchoscopy:

Showed left recurrent laryngeal nerve paralysis. Biopsy was performed in one of the glands in the neck and it showed carcinomatous tissue. No treatment was given.



SUMMARY and CONCLUSIONS

Fifty cases of primary carcinoma of the lung have been described and it has been found that:

1. Carcinoma of the lung occurred practically always in people over 40.
2. It was 7 times as common in males as in females.
3. In 22 per cent of cases it occurred in people who had had a cough for a number of years.
4. Pleural effusion appeared in 12 per cent of the cases.
5. Clubbing of the fingers occurred in 22 per cent of the cases and it appears probable that carcinoma of the lung alone can cause it.
6. The symptoms of greatest importance for diagnosis were cough, haemoptysis, dyspnoea, pain in the chest and loss of weight. They occurred fairly early in most of the cases.
7. The physical signs of greatest importance for diagnosis were those suggesting collapse of lung tissue, by the time these were present the disease was too advanced for surgery to be successful.
8. Examination of the sputum for carcinoma cells was a very valuable aid in diagnosis and it deserves to be used more than it is at present.
9. The radiographical appearance of collapse of lung tissue is very suggestive of carcinoma of the lung; by the time this was apparent in the radiograms the disease was too advanced

for surgery to be successful.

10. Bronchoscopy was the most valuable method of diagnosis. It revealed the exact site of the growth which is important when the possibility of pneumonectomy is being considered. It also furnished conclusive proof of the nature of the growth. It should be done at the earliest possible moment whenever the symptoms are at all suspicious of carcinoma of the lung. If this is done there is hope that we will be able to diagnose the condition at an early stage more frequently. It is the duty of all medical practitioners to send cases at the earliest possible moment.
11. The Sedimentation rate was considerably raised in every case except one in which it was estimated but it is not of great value in diagnosis because of the large number of diseases which can cause a raised blood sedimentation rate.
12. None of the cases in this series was cured. The only hope of cure at present lies in early diagnosis. We can only hope to diagnose the minority of cases early enough for surgery to be successful. One of the difficulties is that patients often ignore symptoms for a long time before seeking medical advice and this can only be partly overcome by warning the public of the danger of neglecting them. A certain number of cases do come to us soon after the development of symptoms and we must be prepared to call in the aid of the radiologist, pathologist and bronchoscopist when we hear suspicious symptoms in spite of the fact that there are no abnormal physical signs, ~~or other suspicious symptoms~~. Every patient over the age of 40 with a cough which does not improve with

treatment after a week or so should be subjected to the routine accessory methods of diagnosis. If this is done we would discover more cases at a stage in which surgery would be successful.

BIBLIOGRAPHY

1. Rostoski and Saupe and Schmorl; Zeits f. Krebsforsch 1926, xxiii, 360.
2. Seyfarth, C.; Deutch Med. Woch. 1, p.1497, 1924.
3. Dudgeon, L.S. and Wrigley, C.H.; Journal of Laryngology and Otology, p.752, 1925.
4. Davidson, Maurice; Cancer of the Lung, p.53, 1930.
5. Fried, B.M.; Primary Carcinoma of the Lung, p.128.
6. Beaumont and Dodds; Recent Advances in Medicine, p.285, 1936.
7. Simons, E.; Primary Carcinoma of the Lung, p.139, 1937.
8. Melville, S.; Practitioner, 1929, p.304.
9. Kerley, P.; British Journal of Radiology, 1925, xxx p.333.
10. MacDonald & Broder; Proceedings of Staff Meeting of Mayo Clinic, Sept. 1938.
11. Jackson, Chevalier; American Journal of Medical Science, cliii, p.371, 1917.
12. Fahraeus, R.; Acta Medica Scandinavica, 1921, 55 p.83.
13. Brock, R.C.; Pulmonary New Growths, Lancet, Nov.1938, p.1108.
14. Burnett, W.E.; Journal of Thoracic Surgery 1936-7, p.458.
15. Graham and Singer; Journal of the American Medical Assn. 101, 1371, 1933.
16. Rienhoff; Bulletin, Johns Hopkins Hospital, 53, 390, 1933.
17. Sauerbruch; Chir. der Brustorgan. Vol.I, p.849, 1920.
18. Tudor Edwards; B.M.J. Vol.I, p.827, 1932.
19. Allen and Smith; Surgical, Gynaecological and Obstetrical Journal, Vol.55, p.151, 1932.
20. Overholt, R.; Journal of Thoracic Surgery, Vol.V, p.54, 1935.
21. Brompton Hospital Reports, p.123, 1936.

22. Lancet, Nov.12, 1938. p.1108. R. Brock.
 23. Leddy and Vinson; Annals of Otology, Rhinology and Laryngology, Vol.41, 1267, 1932.
 24. Boyd; Pathology of Internal Diseases, p.240, 1930.
 25. Tudor Edwards; Journal of Thoracic Surgery, 1934, Vol.IV. p.117.
 26. Davidson, M.; Cancer of the Lung, 1930, p.4.
 27. Simons, E.; Primary Carcinoma of Lung, 1937, p.27.
 28. Dunn, J.S. and White, C.P.; Report of the International Conference on Cancer, 1928, p.400.
 29. Chandler, F.G.; B.M.J. 1935, p.1310
 30. Maxwell, J.; Introduction to Diseases of the Chest, 1938, p.156.
 31. Davidson, M.; A Manual of Diseases of the Chest, 1935, p.461.
-