

INTRODUCTION.

In this thesis I propose, after reviewing the historical aspect of ectopic gestation, and discussing the etiology, to examine the mode of implantation and growth of the impregnated ovum, to follow its subsequent course and fate, with special reference to the various conditions and relations which it may assume, and to submit a classification.

ECTOPIC GESTATION.

A STUDY
ILLUSTRATED BY 25 CASES.

BY
HUGH NETHERSOLE FLETCHER.



INTRODUCTION.

HISTORICAL.

In this thesis I propose, after reviewing the historical aspect of ectopic gestation, and discussing the etiology, to examine the mode of implantation and growth of the impregnated ovum, to follow its subsequent course and fate, with special reference to the anatomical positions and relations which it may assume, and to submit a classification.

I shall then go into the signs, symptoms and differential diagnosis of the various conditions, largely based on 25 cases.

I shall close my thesis with the history of these cases, and a brief commentary on each. I have personally observed and taken the histories of all of them and have assisted or been present at most of the operations.

For permission to use their cases I would express my obligation to my former chiefs at St. Mary's Hospital for Women, Manchester, and the Sussex County Hospital, Brighton, and offer them my sincere thanks.

Between primary and secondary abdominal gestation by the Abbé de la Roche, Courtial, and others. In the same century cases of simultaneous intra- and extra-uterine gestation were recorded.

Interstitial pregnancy was first clearly described by Bionis in 1718.

In 1741 Bianchi, a great authority at that time, first recognized that the pregnant tube could rupture into the broad ligament, and at the end of that century Madame Lefort demonstrated and published such

HISTORICAL.

The first recorded case of extra-uterine pregnancy was described by Albucasis in the 11th century. He observed an abscess to form at the umbilicus, from which, after it had burst, were extruded foetal bones. He had previously noted the woman to be pregnant and the child to have died "in utero". During the succeeding centuries several similar cases of foetal bones escaping from abscesses were recorded, and it was not until 1604 that the first case of a foetus being found in a tube was described by Riolanus.

In the 16th century abdominal pregnancy was described and Cordaeus records a case of a first pregnancy at the age of forty, labour pains without the birth of a child, and subsequently, after death at the age of 71, the discovery of a lithopaedion in the abdomen.

In the 17th century a distinction was drawn between primary and secondary abdominal gestation by the Abbé de la ^{Rogue} Rogne, Courtial, and others. In the same century cases of simultaneous intra- and extra-uterine gestation were recorded.

Interstitial pregnancy was first clearly described by Dionis in 1718.

In 1741 Bianchi, a great authority at that time, first recognised that the pregnant tube could rupture into the broad ligament, and at the end of that century Madame Lefort demonstrated and published such a case, showing how the peritoneum was stripped off the uterus by the effused blood.

Ovarian pregnancy was included in Josephi's classification in his treatise of 1803.

In 1837 Dezeimeris published the most important study, up to that time, of extra-uterine foetation, described and laid stress upon the extra-peritoneal development of the foetus, after rupture of the tube into the broad ligament, a subject then little understood, and introduced a minute classification.

Parry's exhaustive work appeared in 1876, and at last, in 1883, a new era dawned in this disease when Lawson Tait operated on his first case.

Since the condition of extra-uterine pregnancy has been brought into the domain of abdominal surgery, great advances in the anatomy and pathology of the disease have taken place, diagnosis has improved, and by the intervention of operation many lives have been saved that must otherwise have been lost.

There has been much research during the last itself by its own exertions within the maternal tissues, and thereafter developed milli for

15 years into the site and method of implantation of the ovum, the relations of maternal and foetal tissues which secure its fixation and nourishment, and its development.

Up to 1898 it was held that the ovum was situated and developed in the lumen of the tube and was attached to the tube wall by a surface interlocking of the maternal and foetal tissues, and was covered, on its surface which projected into the tube, by a decidua reflexa.

Fürth, however, in 1898 first described a two and a half weeks old tubal gestation in which the foetus was embedded in the muscular tissue of the tube wall, and separated from the lumen of the tube by a thin layer of muscular tissue.

In 1899 Hubrecht in his work on the placentation of the hedgehog described how the fertilised ovum became embedded in a crypt, and rapidly developed an outer epiblastic covering of cells several rows deep, which he named the "Trophoblast". He demonstrated that this outer Trophoblastic coat of the ovum had a phagocytic action on the epithelial and sub-epithelial layers of the maternal mucosa, and by virtue of this action embedded itself by its own exertions within the maternal tissues, and thereafter developed villi for

4
fixation and nourishment.

It was left for Peters in 1899 to shew that the same process takes place in human intra-uterine development of the ovum, viz: that it was a process of embedding, the ovum having burrowed its way through the lining epithelium by means of its irregular trophoblastic layer, destroying and absorbing the tissues which it meets. Further work on the placenta of the anthropoid apes by Selenka and Strähl confirmed Peters' observation.

It was soon after demonstrated that what took place in the uterus took place similarly in the tube, but with certain modifications. These modifications depend on the fact that there is little or no sub-mucosa in the tube, and that immediately under its epithelial lining lies the circular muscular coat, and that therefore the ovum, having penetrated the epithelium, may, and often does burrow into and embed itself in the muscular coat.

This has been amply established by such investigators as Wärrth, Lockyer, Whitridge Williams, Berkeley and Victor Bonney, and it is now generally accepted that the early developing tubal ovum is intra-mural, and not in the lumen of the tube.

favour decidual formation and arrest of the ovum.

(1) ETIOLOGY.

The suggested causes of extra-uterine pregnancy are numerous. When we examine them we find much conflicting evidence, and as yet we know of no single definite causative factor which will cover all cases. Much time has been devoted during recent years to the histological study of sections of the tube wall and of the early developing ovum, and its method of implantation. In many cases not only the appearances of the pregnant tube have been studied but also those of the opposite tube.

Again we often find the observations and interpretations of different observers at variance, but some of the old theories have been sifted out, and we are probably nearer the truth than before.

We may divide the theories into two main classes:-

(A) Those depending on physical or developmental conditions which favour decidual formation in the tubes, and arrest of the ovum.

(B) Those depending on conditions which mechanically interfere with the downward passage of the ovum.

A. Physical or developmental conditions which

favour decidual formation and arrest of the ovum.

- (1) Atavism, or reversion to a lower developmental type of tube.

Clarence Webster in his book on "Ectopic Gestation" points out that both tubes and uterus were originally derived from the Müllerian ducts, and that, to quote his own words: "in those animals possessing a genital track, the least specialised condition is that in which there is no distinction between oviduct and uterus, in which the tract is bilateral and in which the ova may develop practically along its whole extent" He states that in some higher forms, e.g., the cow, with bicornate uterus, when an ovum develops in one horn, the mucosa of both horns undergoes marked decidual changes. He states that the same thing occurs in the uterus bicornis in the human female. (This is denied by Victor Bonney). Continuing, he avers that though in normal uterine pregnancy the tubal mucosa does not ^{usually} respond to the genetic influence, yet in some instances it does do so to a greater or less extent. This response of the tubal mucous membrane he looks upon as a reversion to the earlier type, when that portion of the Müllerian duct corresponding to the tube took part in the decidual reaction along with the rest of the tract.

We must grant therefore that in certain cases,

He advances the theory that such decidual reaction is essential to the establishment of a relationship between the maternal mucosa and the fertilised ovum, in order that development may proceed. He claims to have shewn decidual reaction in greater or less degree in all his sections of pregnant tubes.

Considerable doubt has been thrown upon the views of Webster as to the formation of a decidua in the pregnant tube. Bland Sutton long ago denied its existence, and has been supported by Kühner and Aschoff, Berkeley and Bonney and others. They contend that Webster mistook masses of foetal trophoblastic cells, or their descendents, for decidual cells, and it is impossible on reading Webster's description of these cells and their arrangement, to doubt that he did make such mistakes in his interpretation on many occasions. At the same time it must be admitted that Webster and other important observers have found characteristic decidual cells, not only in the pregnant tube, but also in the tube of the opposite side, and Lange has observed such a reaction in the tubes in 5 out of 50 cases of uterine pregnancy, which he examined.

We must grant therefore that in certain cases, the formation of the ovary.

due possibly to a "throwing back", the tube can develop a decidual reaction, though always in limited degree, and sometimes only affecting certain portions of the tube.

Even when this is admitted, the problem is still unsolved. Webster's theory is that decidual reaction is essential to the establishment of a relationship between the maternal mucosa and the fertilised ovum and to the further development of the ovum. I take him to mean that the decidual reaction is the primary factor - the implantation and development a secondary one.

In Peters' specimen however, one of from 3 - 5 days old, the ovum had burrowed its way deep into the endometrium without, up to that time, the development of any characteristic decidual cells.

Apparently therefore the decidual reaction, when the capacity for its occurrence is present, results from influence of the implanted fertilised ovum, rather than is the cause which makes such implantation possible. It could not be the invariable cause, as Webster states, for in a number of cases of tubal pregnancy, no trace of decidual cells are found.

Again, the theory of atavism will not account for the now well-authenticated fact of ovarian pregnancy, for the Müllerian ducts take no part in the formation of the ovary.

Webster considered that bad hygiene and ill-nourishment was responsible for this "throwing back" and thought that the frequency of tubal gestation among the poorer classes of our towns supported this. Many women however suffer from this condition who are in excellent health and live among good surroundings.

2. Berry Hart holds that salpingitis plays an important part as a causative agent by virtue of its action in denuding the tube of its epithelial lining at any rate in portions of its extent. This he considers produces a condition somewhat analagous to that of the endometrium after menstruation. Against this theory however is the fact that on many occasions the tubal mucosa has been found to be entirely normal.

B. Conditions which interfere mechanically with the downward passage of the ovum.

- (1) Tubal polypi. On several occasions a polypus has been found between the ovum and the uterus, entirely blocking the tube, e.g. in the cases reported by Dührssen and Wyder.
- (2) Fibroids or other tumours in the tube wall, or pressing upon it from without, e.g. a fibroid

(5) "External wandering" of the ovum. That the extending from the uterus into the broad ligament, ovum from an ovary often finds its way across to the opposite tube is certain. Many cases have been are described by varicous authors.

(3) Persistence of infantile type of tube. Freund observed in which the corpus luteum has been in the in 1888 first advanced the theory that the winding and kinking of the tube in the persistent infantile has occurred in a tube after an operation in which type might be responsible for the arrest of the the ovary of the same side and the tube of the oppo- ovum. Dührssen points out, however, that if this site side were removed. were a cause, we should expect extra-uterine preg- nancy most frequently in primiparae. It has been suggested that during its transit across the abdominal cavity the ovum enlarges and becomes too big for the tube and therefore sticks.

Opitz also observes that though the tubes of rabbits are much more tortuous than are those of the human infantile type, and though the rabbits' enlarge until it is impregnated. That external ovum is relatively and absolutely larger, yet wandering is not in itself sufficient to cause extra-uterine pregnancy in the rabbit has never been extra-uterine pregnancy is proved by Kustner's case satisfactorily demonstrated.

(4) Kinking of the tube by adhesions. This condi- tion is sometimes observed at operations for tubal gestation. The adhesions and kinking may have been

(6) Obstruction of twin ova. Barnes thought that the result of the pregnancy or may have been pre- when two ova get into the tube together, one might exist to it. This explanation of the arrest of obstruct the other, and so cause a twin pregnancy the ovum is not a satisfactory one, for if a tube in the tube, or the development of one in the tube kinked by adhesions be cut across at the site of and the other in the uterus. However in several the bend, the lumen will almost invariably be found cases of combined pregnancy careful investigation to be patent in spite of the kinking. has shown the presence of a corpus luteum in either

ovary, so that the ova passed down by separate tubes.

- (5) ~~We see~~ "External wandering" of the ovum. That the
 (7) ovum from an ovary often finds its way across to the opposite tube is certain. Many cases have been observed in which the corpus luteum has been in the ovary opposite to the pregnant tube, and pregnancy has occurred in a tube after an operation in which the ovary of the same side and the tube of the opposite side were removed.

It has been suggested that during its transit across the abdominal cavity the ovum enlarges and becomes too big for the tube and therefore sticks. Fritsch points out that the ovum does not begin to enlarge until it is impregnated. That external wandering is not in itself sufficient to cause extra-uterine pregnancy is proved by Küstner's case in which the ovary of one side and the tube of the other were left after an operation, and an intra-uterine pregnancy subsequently took place.

- (6) ~~also~~ "Obstruction of twin ova." Barnes thought that when two ova got into the tube together, one might obstruct the other, and so cause a twin pregnancy in the tube, or the development of one in the tube and the other in the uterus. However in several cases of combined pregnancy careful investigation has shewn the presence of a corpus luteum in either ovary, so that the ova passed down by separate tubes.

theory.

(8) We may therefore discard this theory as unimportant.

(7) Puerperal atrophy of the tubes. Dührssen

remarked that there is marked atrophy of the muscular wall of the tubes after uterine pregnancy, whether suckling has taken place or not, and that the lumen is widened.

He suggests that the diminished peristaltic activity of the tube wall might slow the downward movement of the ovum and the enlarged lumen favour the entrance of the spermatozoon, and thinks that this might account for the fact that out of his 29 cases, 7 women developed extra-uterine pregnancy within a year of a previous uterine pregnancy.

Many women, however, have uterine pregnancies following closely the one upon the other, so that there is no difficulty in the passages of the ovum downwards, and the less so if the lumen is widened. Further, there is no evidence that the cilia are diminished in number or activity in such post-partum atrophy and it is probable that they play a more important part in the transit of the ovum than does peristaltic action.

As the spermatozoon can normally enter the tube, we need not suppose that the widening of the lumen is a factor of any importance on that score. It would not seem wise to attach any weight to this theory.

(8) Diverticula from the lumen of the tube. These diverticula are by no means rare and are probably of congenital origin. They are considered by Whitridge Williams to probably represent abortive attempts at the formation of accessory tubal ostia. They may extend from the lumen of the tube and continue parallel to it for a varying distance, and then rejoin it or end blindly. Several authors have described cases in which the ovum was almost certainly arrested in such diverticula. In one remarkable case described by Herzog and Heⁿrotin, pregnancy occurred in a small accessory tube, its entrance on the outside of the tube, its extremity ending blindly without communicating with the lumen of the tube.

This leads us to examine lastly the view held by so many writers that salpingitis has preceded extra-uterine pregnancy in a large number of cases and is often a causative factor.

(9) Salpingitis. The view that salpingitis is the etiological factor of considerable importance in tubal pregnancy is no new one. It was first suggested by Virchow in 1850 and since then many German, and not a few English and American investigators have supported it on various grounds.

Shroeder in 1872 suggested, and Lawson Tait upheld the view that desquamative salpingitis, causing destruction of the ciliated epithelium of the tubal mucosa, delayed the ovum in its journey to the uterus. He believed that the ovum was normally impregnated in the uterus, and that the downward current of the tubal cilia prevented the entrance of spermatozoa into the tube, and that consequently when they, the cilia, were destroyed, it was easy for the spermatozoon to stray into forbidden regions.

Orthmann, in 1890, widened the theoretical causative scope of salpingitis by stating his opinion that not only did it destroy the ciliated epithelium, but that it caused the formation of pockets in the tube lumen by the adhesion of neighbouring plicae or mucosal folds, and further by causing the formation of fibrous tissue in the muscular walls it diminished peristaltic activity, and that if the inflammation extended to the peritoneal coat, it might set up adhesions and kinking of the tube. He opposed the view of Warth that these changes in the tube wall might be secondary to the pregnancy.

The frequent occurrence of a considerable period of sterility preceding tubal pregnancy, has been adduced as evidence in favour of salpingitis.

It is very probable that in some cases the fimbriated end of the tube may have become closed by an inflammatory process, that absorption of the products of inflammation has after a time taken place and the ostium again become patent. We have again many papers supporting the salpingitic theory on the ground of the previous history, the appearances of the pregnant and non-pregnant tubes at the time of operation, and the microscopic appearances of both. Mendl and Schmit found that in 24 out of 77 cases there was a clear history of previous gonorrhoea.

Engström operated on 4 women whom he had previously treated for salpingitis.

Glitsch found in 17 out of 43 cases definite evidence of inflammatory changes in the non-pregnant tube.

Dührssen in 24 out of 35 cases, and Obt in 19 out of 22, found microscopic evidence in the pregnant tube of pre-existing salpingitis.

Schantz examined 49 pregnant tubes and in 46 he satisfied himself as to the presence of old salpingitis, while in 32 of these cases there were microscopic signs of the same on the opposite non-gravid side.

Opitz examined serial sections of the pregnant tube in 23 cases and C. Williams a number of others

and both found signs of old salpingitis in all their cases.

Bland Sutton states that tubal gestation in the lower animals is extremely rare. He has never come across an instance in his wide experience. This, coupled with the fact that inflammatory conditions of the tubes in these animals are also very uncommon is held as negative evidence in favour of the salpingitic theory.

So also is the co-existing frequency of gonorrhoea and ectopic gestation among the poorer classes of the large towns and the comparative rarity of both in country districts.

When we attempt to weigh up these various theoretical causes, we find fallacies in most of them. It has been proved experimentally in the lower animals that a few hours after coitus, spermatozoa can be found in the lateral parts of the tubes and in some instances, upon the surface of the ovaries. Fertilization of the ovum therefore, in these animals, takes place in the tube and every pregnancy is extra-uterine in the earliest stage. Why then does not the pregnancy continue in the tube in some instances? It is almost unknown in the lower animals. There is apparently some influence or favouring condition supplied by the uterus to the fertilised ovum which

The part played by the loss of cilia in

the normal tubal tissues of these animals ^{does} ~~did~~ not possess. Even when artificially obstructed the impregnated ovum will not develop in the tube. In this connection, we may quote the interesting experiments of Mendl and Schmit, performed on rabbits, guinea-pigs, and a bitch. From one to three days after coitus the tubes were ligatured at their junction with the uterine horns. No tubal pregnancy occurred in any case.

In another set of animals one tube was obstructed by ligature at the junction of tube and horn as before. The ligature was placed lower down on the other side, leaving on the tube side of the ligature a greater or less extent of horn. In every instance the ovum developed in this piece of uterine cornu. On the other side there was no development in any instance.

Again, a tube was ligatured, removed four to ten days later and examined by serial sections. There was no decidual reaction, and the ovum was found to be degenerating. At first on the strength of the analogy between the lower animals and the human, and later, as the result of examination of the tubes of women who had been recently raped and murdered, the view that the human ovum is also fertilized in the tube, has been generally accepted.

The part played by the loss of cilia in

favouring the ascent of the spermatozoon is therefore a negligible one.

CLASS But why, it may be asked, if the ovum arrested in the tube of the lower animals does not develop, why should the human ovum develop under similar circumstances? What is the additional and apparently essential influence in the human being which is wanting in the lower animals? It may be suggested that the tubes of the animals experimented on were healthy and normal, whereas in many of the pregnant tubes in the human there have been signs of old salpingitis.

As we have already shewn, there is strong evidence in favour of salpingitis being an etiological factor of some importance. Hence Berry Hart's theory may apply in some instances. We must not forget, however, that Whitridge Williams, Berkeley and Bonney, and others have examined in serial section early pregnant tubes in which there was no trace of salpingitis; in which, in fact, the tube walls were apparently quite healthy.

Webster's theory of atavism would not be satisfying, for as we have already seen, those animals occupying the position between the lower type with the bilateral genital track, and the human, practically never "throw back" and develop tubal pregnancy.

as the ovum is extruded into the peritoneal cavity or not.

CLASSIFICATION OF ECTOPIC GESTATION.

- A. Primary forms: 1. Ovarian.
2. Tubo-ovarian.

SITE OF IMPLANTATION OF 3. Tubal. { Ampullary
Isthmic
Interstitial.

The fertilised ovum may be arrested at any

- B. Secondary forms: 1. Ligamentous - Extra-peritoneal, from rupture of the tube between the layers of the broad ligament. It develops in the ovary itself. It is implanted on the fibriated extremity of the broad ligament.
2. Peritoneal - (a) from rupture of any of the primary forms into the peritoneal cavity.
- (b) from rupture of the ligamentous form into the peritoneal cavity.

In any form, primary or secondary, pregnancy may be brought to an end in various ways, chief amongst which are haemorrhage or rupture, or both combined.

In tubal pregnancy rupture is (1) Intra-tubal, i.e., into the lumen of the tube, so-called "tubal abortion", which is complete, or incomplete, according

as the ovum is extruded into the peritoneal cavity or not.

(2) Extra-tubal. (a) into the peritoneal cavity. (b) between the layers of the broad ligament.

SITE OF IMPLANTATION OF THE OVUM .

The fertilised ovum may be arrested at any part of the genital track between its follicle in the ovary and the uterine cavity. Thus we may find it developing in the ovary itself. It may become implanted on the fimbriated extremity of the tube and develop between tube and ovary or in a tubo-ovarian cyst (tubo-ovarian pregnancy). Or it may become implanted in the ampulla, the isthmus, or that part of the tube which traverses the uterine wall, the interstitial portion. As the result of rupture of the tube wall, or the follicle in the ovary, or after the escape of the ovum through the ostium abdominale of the tube, secondary varieties may develop. These will be referred to later.

OVARIAN PREGNANCY.

Mercerus in 1614 was the first to describe ovarian pregnancy. Although from time to time cases

Williams considers that ovarian has a better chance were reported, and though the condition was included in their classifications by various writers, its existence was held not to be definitely proved till 1902, when an undoubted case was published by Thompson. It was thought before this date that so-called ovarian pregnancies might be cases in which the ovum, after rupturing from the tube into the broad ligament, had there developed, and as it grew, had flattened out the ovary on its surface, till the thus thinned out ovary had become incorporated with the sac wall. From among a number of cases reported as ovarian pregnancy W. Williams has collected 13 which he considers beyond all question to be genuine. The ovum is probably fertilised before its escape from the Graafian follicle. The foetal trophoblast burrows into the ovarian tissue and having opened up blood sinuses there establishes itself by means of villi, as in uterine and tubal gestation. Pregnancy usually terminates at an early date, although 2 of the 13 cases collected by Williams went to term. In one the pregnancy had become converted into a lithopaedion which was removed 33 years later. The other occurred along with an intra-uterine pregnancy and after the latter was over, a living child and its sac was removed by laparotomy and proved to be an ovarian pregnancy.

Williams considers that ovarian has a better chance of going on to term than has tubal pregnancy. If pregnancy ends within the early months it may be with or without rupture. If rupture takes place, the foetus will escape into the peritoneal cavity, with or without its amnion. In a case reported by Croft the foetus was found in the abdomen attached by the umbilical cord to the placenta in the interior of the ovary. If no rupture has occurred, a blood clot will be found in the ovary, surrounded by a capsule of ovarian tissue. The foetus may or may not be found in the clot. In all such cases of ovarian haematomata, microscopic search should be made for chorionic villi, or remains of them broken up in the blood clot.

Spiegelberg laid it down that the following conditions must be fulfilled before an absolutely reliable diagnosis of ovarian pregnancy is made:

- (1) That the tube on the side of the pregnancy be intact.
- (2) That the foetal sac occupy the position of the ovary.
- (3) That it be connected by the ovarian ligament to the uterus.
- (4) That definite ovarian tissue be found in its wall.

TUBO-OVARIAN PREGNANCY.

This variety is primarily tubal or ovarian, and is said to occur when the fimbriated end of the tube is adherent to the ovary at the time of fertilisation; or it may occur as the result of an ovum developing in a tubo-ovarian cyst (W. Williams). Probably the site of implantation is usually the fimbriated extremity of the tube, and the growing ovum comes into close contact with the ovary till the latter forms part of the sac wall. Adhesions may also form between the sac and other neighbouring organs.

Tubo-ovarian cysts, and the occasional occurrence of pregnancy in them, form an interesting subject. They are caused, to quote Webster, by the persistence of a sac of peritoneum which is found in different animals in different degrees of completeness. In some, such as the hyaena, the rat and the mouse, it quite surrounds the ovary, and the end of the tube opens into it. In the baboon and porcupine it is partly formed. In the human subject it is found only as a recess in the mesosalpinx, varying in depth in different women. In some it is deep enough to hold the whole ovary. An ovum may rupture into this cyst and then pass into the

decidual cells are present in very different quantities and there be fertilised (Martin reports 5 such cases), or the spermatozoon may meet the ovum in the cyst itself.

MODE OF IMPLANTATION OF THE OVUM.

In the section devoted to the historical aspect of extra-uterine gestation a short description has already been given of the modern view of the implantation and early development of the ovum, and of the theories which attempt to explain its arrest in the tube. We have seen how the blastocyst develops an outer phagocytic coat of epiblast, by means of which it eats its way through the epithelium lining the tube. In Berkeley's and Bonney's sections there was at the point of entrance a plug of fibrin which marked the breach in the first line of maternal defence. This entrance through the epithelium is usually in the deepest part of a depression between neighbouring folds of mucous membrane. It may however on rare occasions be on the free surface of one of the mucosal folds.

Decidual Reaction. Before tracing the development of the foetus further it might be convenient to discuss the vexed question as to whether true decidual cells are present in the tubes in this condition, or not. It is a difficult subject, partly because the cells which might be considered

had chronic salpingitis of both tubes. In sections

decidual cells are present in very different quantity in different cases - in some there are hardly any; in others they are comparatively numerous - and partly because different observers vary in their interpretation of what they see. Many observers considered at one time that a well-marked and typical decidua vera and serotina were developed in every case of tubal pregnancy, and also a more or less complete decidua reflexa. Others, and notably Bland Sutton, denied this absolutely, and supposed that there had been a misinterpretation of the supposed decidual cells, and that they were in reality of foetal epiblastic origin.

As Berkeley and Bonney say, there is no decidual reaction in the sense of a definite massive proliferation of a supposed sub-epithelial stroma, causing decidual hypertrophy of the tubal mucous membrane analagous to that occurring in the uterine mucosa. There is, however, in many cases a proliferative reaction of the connective tissue cells in the mucosal folds, in which the cells become larger and epithelioid in appearance, and have nuclei, either round or deeply staining, or oval, vesicular looking, and less deeply staining. (W. Williams).

In one of my sections I found a marked cellular proliferation in the stroma of the mucosal folds, answering exactly to this description. The woman had chronic salpingitis of both tubes. In sections

of two other tubes, one in serial section, I could find no trace of such reaction. Berkeley and Bonney remarked on its absence in all their sections. It may apparently be absent or present only in slight extent. Many observers have noticed it, and some have found it occurring in the opposite tube. Mandl and Lange noted this reaction in the tubes in 5 out of 50 cases of intra-uterine pregnancy.

DECIDUA REFLEXA.

The conception of a membrane formed by the proliferation of cells reflected up over the ovum from a decidua vera, is no longer accepted. From the way in which we have seen that the ovum embeds itself in the tube wall, it is obvious that there will be a layer separating it from the lumen. This may be merely a layer of mucosal epithelium, with perhaps some proliferation of connective tissue cells, or, if the ovum has burrowed deeper, it may include muscle tissue. It is not of decidual origin, nor is it reflected. It would be better, therefore, to call it by some other name, the best of which is, perhaps, the "capsular membrane" or, as some would call it, the "pseudo-reflexa".

We must now examine the trophoblast and its action.

It is, as has been mentioned, the outer epiblastic

layer of the early ovum, and consists of two kinds of cells:

- (1) Large, mononuclear epithelioid cells, irregularly polyhedral in shape, with round or oval, deeply staining nuclei. The cytoplasm of these cells stains well.
- (2) Irregular, multinuclear masses of cells, which exhibit no definite cell boundary - the Syncytium.

It is the well-defined mononuclear cells which are the primitive cells of the trophoblast, and the true invading cells. They are much more numerous than the syncytial masses and are seen in great numbers at the periphery of the invading margin of the ovum. The syncytial masses only appear after a definite cavity has begun to form. They are always found on a free surface bathed in blood, e.g. forming part of the wall of a blood vessel which has been invaded, or in an inter-villous space. They thus appear to depend on blood contact for their development and are probably derived from the large mononuclear cells, for all stages between the two are seen. (Berkeley and Bonney)

The further course of the ovum, after it has penetrated the maternal epithelium, will depend partly on the portion of the tube it has invaded. In the

isthmus portion, the lumen is narrow and the muscular coat thick. The ovum will have little room to enlarge inwards and therefore in most cases invades the muscular coat and makes its way towards the peritoneal covering. Extra-mural rupture is, as might be expected, very common in this part of the tube.

In the ampulla the lumen is considerably wider. There is more room for the ovum to enlarge towards the lumen, and this it commonly does. The lumen is gradually encroached upon, and, if no interruption of the pregnancy takes place, becomes obliterated by the pushing of the "capsular membrane" or "pseudoreflexa", against the epithelium of the opposite wall. These two may become blended, so that at this point all trace of the lumen may be lost. At the same time, in this variety there may be marked invasion of the muscular coat, as in the isthmus. Rupture into the lumen of the tube (tubal abortion) is, however, by far the most common ending in the ampullary portion of the tube. In my 15 cases of tubal abortion, the position of the pregnancy was noted definitely in 10, and in 9 of the 10 it was in the ampullary portion. In the other it was early and in the isthmus portion. The results of interstitial pregnancy will be considered later.

haemorrhage in the already weakened wall.

As the ovum makes its way outwards, it meets first of all the circular muscle coat. The muscle cells with which the trophoblast comes into contact appear to undergo a fibrinous degeneration. They lose their staining reaction and are eventually changed into laminated layers of fibrin, which along with the numerous trophoblastic cells burrowing their way between them, form the outer capsule of the ovum, the so-called "cell-sheet". As the trophoblast advances it appears to absorb the fibrinised muscle cells and during the early stages, before the formation of villi, is probably thus partly nourished. Having penetrated the circular coat the trophoblast of the growing ovum reaches the outer longitudinal coat, and the ovum enlarges its coats by splitting the one from the other. In this way it may separate the two round almost the whole circumference, a condition well shown in Berkeley's and Bonney's sections. At the same time the trophoblast cells insinuate themselves between the bundles of muscle fibres, delaminating them in a concentric fashion, so that there may be seen several such laminae undergoing degeneration, separated by trophoblast cells. The peritoneal coat may eventually be penetrated so as to cause rupture, but this alone is rare. It is generally brought about by a

haemorrhage in the already weakened wall.

C. PLACENTA.

The ovum is usually found in its earliest stages making its way towards the richest blood supply, that is to say, towards the attached side of the tube. The veins and arteries of the tube shew marked enlargement. Blood sinuses are opened up by the trophoblast, and the irregular processes of the latter become bathed in maternal blood and form primitive villi. Soon delicate branching connective tissue cells grow down from the mesoblastic layer of the ovum into the epiblastic processes, and these shortly become vascularised from the vessels of the chorion. Thus rudimentary chorionic villi are formed. Presently these villi give off secondary outgrowths at their sides and these again branch till at last the true chorionic villi forming the "chorion frondosum" are formed. Finally towards the end of the 2nd month many of these villi have undergone degeneration, while over a certain localised area they have persisted to form the placenta; a few here and there still remain outside the placental area and help to fix the ovum to the maternal tissues. In the blood spaces of the placenta, and sometimes into the peritoneal. The placental attachment is often

lumen of a blood vessel part of whose wall it has destroyed and absorbed, masses of syncytial cells may be seen projecting. These cells were said by Webster to spread along the lumen of the blood vessels, but this is now denied. Particles may, however, be broken off and carried in the blood stream to other parts of the body. They have been found in the veins of the tube remote from the ovum and the plugging of veins by such masses, either broken off or still attached to their villi, has been suggested by Veit as a cause of rise of blood pressure in the inter-villous spaces, with consequent rupture. It should here be mentioned that small extravasations of blood are frequently seen in sections of the wall of pregnant tubes in an early stage.

If the tube ruptures ^{outwards} and the placenta escapes serious damage, the pregnancy may continue, and the placenta may then spread from its intra-tubal site into the peritoneal cavity and on to other organs, e.g. the outside of the uterus or the intestines, etc. Or if the rupture be between the layers of the broad ligament it may spread in any direction, and establish connections with the floor or side of the pelvis, the side of the uterus or bladder, or to the rectum, being of course entirely extra-peritoneal. The placental attachment is often

their way towards the lumen and come into direct contact with the foetal epiblast. It has been shown, however, that no such proliferation takes place and that the cells which were thought to have this origin are in reality masses of foetal epiblast which have invaded the sinus and vessel walls. The extent to which it is damaged will depend the further prospects of life of the foetus. In the great majority of cases the foetus dies, either from defective blood supply, or because it has been destroyed by the extravasated blood, or by the pressure caused by it. *the latter*

d/
The placenta has been said to grow after death of the foetus. This opinion was based on cases where it had been advisable at operation to leave the placenta "in situ" after removing the foetus. In a few such cases it was noted at a later date that the placenta was larger. Berry Hart came to the conclusion that there is no proof of placental growth after the death of the foetus and shewed that when enlargement occurs, it is due to extravasations of maternal blood into it.

TROPHOSPONGIA FORMATION.

It has been stated by some writers that there is a proliferation of the endothelium of the maternal blood-vessels and sinuses, analagous to the "trophospongia" formation described by Hubrecht in his work on the placenta of the hedgehog, and that processes formed from these cells may make

their way towards the lumen and come into direct contact with the foetal epiblast. It has been shewn, however, that no such proliferation takes place and that the cells which were thought to have this origin are in reality masses of foetal epiblast which have invaded the sinus and vessel walls.

INTERSTITIAL PREGNANCY.

This is the last of the primary forms of extra-uterine pregnancy, and occurs in that part of the tube which traverses the uterine wall. It is a very rare condition and has several points of interest peculiar to itself. Hypertrophy and hyperplasia of the muscular tissue in the ampullary or isthmic portions takes place only to a very limited extent, if at all. Hence rupture, if it occurs, is early. In the interstitial portion, however, the muscle responds to the genetic impulse and there is said to be marked hyperplasia and hypertrophy. This, together with the normally greater thickness of the wall, accounts for the ~~much~~ later occurrence of rupture than in the other part of the tube.

The gestation sac, being imbedded in the uterine wall is not distinct from that organ. The whole uterus appears enlarged, but in an irregular manner.

The gestation sac lies internal to the round ligament of the side in which it is developing, whereas the great majority of extra uterine pregnancies develop outside that ligament. The sac as it enlarges, pushes its way more and more to the opposite ^{side} and almost obliterates the uterine cavity. It may rarely enlarge outwards between the two layers of the broad ligament. Pregnancy may be interrupted by rupture inwards, into the lumen of the tube, so-called "tubal abortion", or outwards, into the peritoneal cavity, or between the layers of the broad ligament. Rarely the gestation sac and the foetus are effused into and around it may remain intraperitoneal, simply enlarging and pulsating up the abdominal cavity much in the way of a dissecting aneurysm.

Interstitial pregnancy may go on to the later months and even to term, but usually rupture occurs in the 3rd or 4th month. It may of course take place earlier than this. Two cases have been recorded by Klob and Rokitansky in which pregnancy went on to full time and a dead foetus was removed 7 months later. The wall may on rare occasions rupture inwards into the uterine cavity, but more commonly does so into the peritoneal cavity at the upper and posterior part of the sac.

Maschka has recorded a case in which rupture of a tubal pregnancy, which Williams collected, occurred at $4\frac{1}{2}$ months, and in which the placenta, head, and part of the neck, escaped into the abdomen, and the rest of the body into the uterine cavity, and through the vagina. Rupture is also said to very rarely take place between the layers of the broad ligament. In 100 cases, 80% ended in tubal abortion & (36) in extra-uterine rupture, 4 into the broad ligament, and 32 into the peritoneal cavity.

Owing to the late date at which rupture usually occurs, the blood vessels are large, and bleeding is

profuse and in most cases leads rapidly to a fatal issue. The death rate in this form of extra-uterine pregnancy is far higher than in any other.

TERMINATIONS OF TUBAL PREGNANCY.

We have seen that the ovum develops in the wall of the tube itself. Pregnancy may be interrupted by rupture inwards, into the lumen of the tube, so-called "tubal abortion", or outwards, into the peritoneal cavity, or between the layers of the broad ligament. Rarely the gestation sac and the blood effused into and around it may remain intra-mural, simply enlarging and ploughing up the existing cavity much in the way of a dissecting aneurism.

TUBAL ABORTION, OR INTRA-TUBAL RUPTURE.

This is by far the most frequent ending of tubal pregnancy. Whitridge Williams collected 289 cases reported by various authors which terminated in rupture. Of these no less than 78% ended in tubal abortion or intra-mural rupture and 22% by rupture into the peritoneal cavity or between the layers of the broad ligament. In my 25 cases, 15 (60%) ended in tubal abortion, 9 (36%) in extra-mural rupture, 4 into the broad ligament, and 5

into the peritoneal cavity, while the remaining one was unruptured and still in the tube at 6 months.

Tubal abortion is the result of rupture of the capsular membrane or "pseudo-reflexa", and occurs owing to either a perforation of that membrane by the foetal epiblast, or, and much more commonly, owing to a sudden rise in the intra-mural pressure. This rise in pressure is brought about by the sudden perforation of a large sinus or a blood vessel by the trophoblast, or, as suggested by Veit, by a blocking of the veins by masses of decidual cells which have invaded their walls, or by pieces of these decidual cells which have been broken off and carried further afield as emboli. I have also been struck by the fact that rupture has on several occasions occurred at the time for the menstrual period. In $\frac{3}{4}$ of my cases there had been no symptoms whatever of extra-uterine pregnancy. The period the month before had been normal and on the day when it was expected again, the sudden catastrophe occurred. The extra congestion which occurs at this time may have had an influence in determining the giving way of a blood vessel.

The haemorrhage is usually primarily between the chorion and the maternal tissues, and great tearing up of the foetal attachment may occur. The

haemorrhage often makes its way into the amniotic sac and destroys the foetus, so that it is frequently difficult to find it. I only found it in 5 of my 15 cases of tubal abortion.

If the separation of the ovum from its bed is complete, it, and the blood clot which has formed from the haemorrhage, may be extruded through the fimbriated end of the tube, if the latter has not become sealed up. This extrusion probably occurs chiefly as the result of pressure of effused blood behind the ovum, pushing it towards the ostium abdominale. It seems highly probable from the history that in 5 out of 6 of my cases a condition of complete abortion found at operation, did not result from the first rupture and haemorrhage, but that the ovum remained for some time in the lumen, and that a second haemorrhage, perhaps some weeks later, raised enough pressure to complete its extrusion.

The part played by peristaltic action in forcing the ovum out of the tube probably depends on the degree to which the muscular coat is stretched or damaged. If suddenly over-distended by a large effusion, it may quite lose its tone. If the haemorrhage is small and gradual it will probably stimulate contraction.

Complete abortion probably is the most favourable termination of tubal pregnancy as far as the mother is concerned. The site of the growing ovum is usually in the comparatively capacious outer half, the ostium abdominale affords a ready safety valve, as it were, for heightened pressure within the tube, and it is seldom closed in the early months. Further, in the ampullary portion the muscular coat is less likely to be seriously invaded and damaged and it can therefore more readily contract upon and close the bleeding placental site. When once, too, the ovum has been completely expelled, further haemorrhage is less likely to occur than in any other form. The ovum and blood clot seldom cause any serious trouble in the abdomen unless the bleeding has been very extensive. Sometimes adhesions may be set up between neighbouring organs, but usually the blood clot, and the foetus, if under 3 months, are absorbed.

If the ovum is situated on the fimbriae themselves, closing of the bleeding vessels and sinuses by contraction and retraction of the muscular coat does not take place so readily, the blood effused escapes at once into the peritoneal cavity and does not therefore so easily clot against the bleeding site, and the chances of ^{quick} ~~quite~~ cessation of haemorrhage are not so good as if the bleeding site were

Therefore have accounted for the absence of the a little more within the tube. In one of my cases the operation took place 24 hours after the first agonising pain, the abdomen was full of blood, and a continuous trickle of bright blood was taking place from the chorionic site. The foetus was found in the amnion, in the centre of a blood clot, lying in the pouch of Douglas.

It is not uncommon to find the tube after complete abortion, empty and retracted, and showing but few signs of having been pregnant. Blood clot, sometimes quite small, may be found clinging to the outside of the fimbriae, or in the immediate neighbourhood, perhaps attached to the ovary or the back of the broad ligament, or in the Pouch of Douglas. The foetus was found in only 2 of the 6 cases of complete abortion in this series, on each occasion in its amniotic sac in the centre of a blood clot.

Besides its destruction by haemorrhage, there is another reason why it may have disappeared.

Leopold in his interesting experiments of putting young foetuses into the abdominal cavity, found that under the age of 3 months they were quickly absorbed, even in some cases in 3 or 4 days, and that in no case did they live. This phagocytic and absorptive power of the peritoneal cells may

therefore have accounted for the absence of the foetus in certain cases, where some days have elapsed between the abortion or rupture and the operation. Blood clot is in like manner rapidly absorbed, and in many cases the amount found at operation by no means represents all that has escaped.

INCOMPLETE ABORTION.

The separation of the ovum is not always complete, in fact, in most cases it is not, and the whole or part of the ovum, together with some blood clot, is retained in the tube. This sometimes dries up, is partly absorbed, and remains as a so-called "mole" without giving rise to further symptoms.

In most cases, however, there is a continuance of trouble. This condition is somewhat analagous to intra-uterine pregnancy and abortion. If in the latter, the ovum and membranes were completely expelled, the haemorrhage, brisk, perhaps for a short time, will probably stop soon after expulsion of the ovum. If however the latter is wholly or partially retained, continued loss of blood is the rule. Much the same thing occurs in incomplete tubal abortion. Blood may continually trickle away from the fimbriated end, and cause a large pelvic

The time at which intra-tubal rupture or abortion usually occurs is in the first or second month, or may escape from the uterine end and cause the dark ~~black~~ ^{brown} discharge which is so characteristic a symptom, in either case with progressive pallor of the patient.

Nor is the presence of an incomplete abortion in the tube without risk to the mother, quite apart from the slow loss of blood just described. There may be, and often are, further sudden haemorrhages. It is in this class of case, ^{especially} I believe, that we get the repeated attacks of severe pain due to repeated haemorrhages, not sufficient at first to cause rupture of the tube, or extrusion of the ovum, but often, if left, ending in complete abortion, or rupture, and possibly in the latter case, in death of the mother.

Hirst reports a case in which rupture of the sac or of a blood vessel in its wall, with profuse haemorrhage, occurred two years after the destruction of the embryo and cessation of growth. The embryo had been retained in the tube.

HAEMATO- SALPINX.

This condition is occasionally found where the blood has not clotted, and where both ends of the tube are occluded.

The time at which intra-tubal rupture or abortion usually occurs is in the first or second month.

In 32 cases reported by Mackenrodt it occurred in 8 cases in the 1st month.

19	"	"	"	2nd	"
4	"	"	"	3rd	"
1	"	"	"	4th	"

In 29 cases operated on by Martin it occurred in 13 cases in the 1st month.

10	"	"	"	2nd	"
4	"	"	"	3rd	"
2	"	"	"	4th	"

In my own 15 cases it occurred in 1 case at 3 weeks.

4	"	"	4	"
2	"	"	4 1/2	"
6	"	"	5	"
1	"	"	6	"

and in 1 the date was uncertain.

So that it may be said that a large number of tubal abortions occur in the first month, and the great majority, in any case, during the first two months.

EXTRA-TUBAL RUPTURE.

This may occur:-

(1) RUPTURE INTO THE BROAD LIGAMENT.

(1) Between the layers of the broad ligament
(extra peritoneal).

(2) Into the peritoneal cavity (intra-peri-
toneal).

(1) may later undergo a secondary rupture and become (2). Rupture outwards, it has already been remarked, is more likely to occur in the isthmic and interstitial portions of the tube than in the ampulla, and this for the anatomical reasons stated. Indeed, in these two varieties it is almost the rule. Although the main cause is the thinning and absorption of the tube wall by the foetal elements, yet in most cases the immediate cause is sudden haemorrhage, resulting from causes described under tubal abortion. The foetus may, however, be slowly extruded in the manner of a hernia through a weakened spot, without haemorrhage. There are occasionally traumatic causes - I have twice known rupture to occur as the result of a fall from a chair, and on another occasion there was sudden pain and faintness after a gynaecological examination.

Coitus is a well-authenticated cause. In the great majority of cases, however, the woman is quietly doing her work, or sitting at a meal, or in bed.

It does not necessarily mean that it escapes per-
tomb into the meso-salpinx at the time of rupture.

(1) RUPTURE INTO THE BROAD LIGAMENT.

Various names have been used to denote the different positions and stages of this variety; e.g Broad-ligament Gestation, Tubo-ligamentary Gestation, Sub-peritoneo-pelvic, Sub-peritoneo-abdominal, and so on.

We will here call it "ligamentary pregnancy", and according as it develops in front of, or behind the peritoneal cavity, we will sub-divide it into "anterior" and "posterior" varieties. The foetus usually perishes at the time of rupture of the tube. If rupture is early (in the 1st or 2nd month), haemorrhage is not likely to be so great as after this time. Fortunately for the mother, the blood escaping between the two layers of the meso-salpinx is in a comparatively confined space, and quickly raises enough resistance and pressure to stop any excessive bleeding. It may however dissect widely, and one of my cases had formed a large retro-peritoneal tumour well above the brim of the pelvis on the left side.

Thus an extra-peritoneal haematocoele of varying size is formed which may be entirely or partially absorbed and which may rarely suppurate through infection from the rectum. If the foetus survives, it does not necessarily mean that it escapes pell-mell into the meso-salpinx at the time of rupture.

Probably it much more gradually enlarges its coasts through the rent and takes advantage of the extra space at its disposal, as it grows.

It may extend down to the pelvic floor, or out to the side wall of the pelvis, and as it increases in size will cause displacements of the uterus, bladder, rectum, etc., according to the direction it takes. If it pushes up the anterior layer of the broad ligament it comes eventually to lie entirely in front of the peritoneal cavity, between it and the abdominal wall, and is known as "anterior ligamentary pregnancy".

When it pushes up the posterior layer of the broad ligament it gets entirely behind the peritoneal cavity. This is the most usual direction of enlargement.

ANTERIOR LIGAMENTARY PREGNANCY.

The foetal sac, as it rises, lifts the peritoneum off the bladder and the anterior surface of the fundus uteri, displacing the latter back and to the opposite side. In one of Berry Hart's cases, which he examined in frozen sections, the anterior parietal peritoneum was stripped from the back of the anterior abdominal wall for a distance of $7\frac{3}{8}$ inches above the brim. The sac is seldom infected

during the life of the foetus, as it is far away from the intestines; it may be incised, and the foetus extracted without wounding the peritoneum at all. Care must be taken when doing this, not to wound the bladder.

POSTERIOR LIGAMENTARY PREGNANCY.

The sac in this variety becomes retro-peritoneal - as it rises it has the broad ligament in front of it, and dissects the peritoneum off the rectum and posterior wall of the pelvis and abdomen. Behind it is bounded by the rectum and thus runs grave danger of becoming infected, with consequent death of the embryo. From an abscess thus formed the bones of such a suppurating foetus may be discharged by various routes. If the placenta becomes adherent to the rectum it may give rise to symptoms suggestive of acute colitis or proctitis. It must always be remembered that an intermediate condition may occur, in which the two layers of the broad ligament are equally displaced and the foetal sac lies between them like a par-ovarian cyst.

Berry Hart has laid much stress on the position of the placenta in ligamentous pregnancy. Alban states that it always lies above the foetus at first, and that later the sac may so develop as to allow the foetus to rise above the placenta.

If the foetus is below, and the placenta above, the placenta becomes pushed upwards. During the first three or four months it is protected to a large extent by the pelvis. As it rises above the pelvis it is much more exposed to injury and the mother lives in great peril of her life. If rupture takes place the large fleshy placenta is much more likely to be torn than if it lies below the foetus in the pelvis, and tearing of its big vessels means rapid out-pouring of blood into the peritoneal cavity, which will be opened by the tear, and, probably death of the mother.

When the placenta lies below the foetus, it is well protected, and moreover, being less disturbed by the growth of the foetus, gives the latter better nourishment and a better chance of going to term. If the sac does rupture, the placenta is usually not implicated, and fatal haemorrhage is much less likely to occur. This is, in fact, the only condition in which, after rupture of a ligamentary sac, the pregnancy has much chance of continuing. The foetus may be extruded into the abdominal cavity, and the placenta being undisturbed, the foetus may continue to grow. Its further development, however, must be exceedingly rare, for the amniotic cavity will have been torn during rupture, with escape of the waters,

and it is a disputed point as to whether a foetus can live without its protecting amnion.

It should be mentioned that secondary rupture of a ligamentous pregnancy is not necessarily into the peritoneal cavity. It may be into the extra-peritoneal connective tissue, so-called "secondary extra-peritoneal rupture". This is very rare in the later months.

RUPTURE OF THE TUBE INTO THE PERITONEAL CAVITY.

If the foetus lives the condition is called "tubo-peritoneal" pregnancy. The time at which rupture of the tube into the peritoneal cavity takes place is later on the average than in tubal abortion. Out of 334 cases reported by various authors, 38 ruptured in the first month, 141 in the second, 74 in the third, and 49 in the fourth. In my five cases, one was at three weeks, and the other four at two, two and a half, three, and three and a half months respectively. We have seen that when the tube ruptures into the peritoneal cavity, the placental site is often seriously damaged and as a rule death of the foetus takes place, and not uncommonly death of the mother also. It has been stated by Webster that the mother will usually die within twenty-four hours of the rupture, unless

operation is performed. This is perhaps rather overstated. It is, of course, unwise to form a judgment from small numbers, but of the five cases in my series only one was operated on within this period, and all recovered. This one probably owed her life to early interference, twelve hours after the catastrophe.

In the other four cases, two days, three days, two weeks and five weeks respectively had elapsed before operation.

There was a very large quantity of free blood in the peritoneal cavity of three of them. In another the blood had formed a very large localised haematoma outside the rent, limited by adhesions between uterus, intestines and great omentum. In the fifth, there was a very little bleeding and as in one of the others, the foetus was floating outside the rent, attached by its umbilical cord to the inside of the tube.

The rent in the tube is sometimes quite small. If the placenta has become differentiated and lies below, it is not so likely to be damaged, and the foetus may obtain a sufficient blood supply for its further development. When it lives, it is probably slowly extruded or herniated out through the rent into the peritoneal cavity, still enveloped in

its amnion. From this time forward its risks are much the same as those of the ligamentous pregnancy in which the placenta lies below and out of the way of injury, and in both forms secondary rupture into the peritoneal cavity is so similar in its effects that a separate description is not necessary.

Webster has given an instructive description of a case of tubo-peritoneal pregnancy which was operated on by Halliday Croom in 1890. The woman died after operation and Webster was able to study the condition of affairs afterwards. The gestation sac was a double one; the lower or primary one, which lay in an enormously distended Fallopian Tube, contained the placenta and was lined by amnion. The amnion passed through a constriction in the tube wall where the rent had occurred to be continued as the lining of the upper or secondary sac, in which lay the foetus. The umbilical cord connecting foetus and placenta, passed from one compartment to the other. In this case, as probably in others like it, the foetus in its amnion must have escaped into the peritoneal cavity very gradually through a weakened spot in the tube wall for there was nothing in the clinical history to indicate sudden rupture.

DEATH OF THE FOETUS.

Apart from rupture or haemorrhage, the foetus may die before term owing to defective nutrition from ~~a~~ partially damaged placenta. It is not unlikely, even when the liquor amnii is still present, to develop such deformities as club foot, anencephalus, etc. Death is said to occur also from infection of the sac. Some hold that death of the foetus must occur first before this can take place.

Berry Hart thinks that two factors are essential to termination of an ectopic gestation by suppuration, viz: -

- (1) Extra-peritoneal development after rupture of the tube into the broad ligament.
- (2) Uppermost position of the placenta and its consequent displacement as pregnancy advances.

The ovum lying extra-peritoneally, comes into close connection with the bowel and especially the rectum, while displacement of the placenta upwards often leads to extravasations of blood into it, and impairment of the nutrition of the foetus.

Death may also occur from intercurrent disease of the mother. Finally, if the child has survived these dangers death awaits it at term.

Spurious labour takes place at or before full time. Why it should always have a fatal issue to the child is not known. There is no separation of the placenta as in uterine pregnancy. Possibly some degenerative changes occur in the placenta at this time in accordance with time-honoured habit or precedent, which profoundly affect the nourishment of the foetus.

Küstner's explanation is that death is due to interference with circulation by contractions of the sac wall, and by partial separation of the placenta with escape of blood into its substance. Although the sac wall is chiefly made up of fibrous tissue and one would hardly expect that the small quantities of muscle fibre scattered through it could have much power of contraction, yet contraction of the sac wall has been observed at operation on more than one occasion.

Webster suggests that the violent straining efforts often made by the patient during spurious labour is a factor of importance in the separation of the placenta. This possibly is true, but it does not explain the start of the process.

The pains of spurious labour vary much in severity. They closely resemble the pains of normal labour, so much so, that both patient and doctor may think

that ordinary labour is in process, unless something abnormal had been suspected. They may last for a few hours, or for two or three days. Having passed off they seldom return, but are said to do so occasionally, at varying periods. The cause of the pains is not definitely known - some think that they are caused by contractions of the uterus, others that contractions of the sac wall produce them. More or less uterine haemorrhage, accompanied by shreds and sometimes a complete decidua, occurs during spurious labour. This may stop suddenly or gradually - Alban reports a case in which haemorrhage continued for 6 weeks. After labour the liquor amnii dries up, the foetus shrinks and becomes a foreign body. It may then undergo various changes presently to be described.

Rupture of the sac occasionally, though rarely, occurs during spurious labour.

Decidual cast. In every case of extra-uterine pregnancy a decidual reaction takes place in the uterine mucosa, and sooner or later shreds of decidual membrane or a complete cast of the uterine cavity are passed "per vaginam". This separation and extrusion is said to be a certain indication that the death of the foetus has occurred. The escape of decidual membrane often passes unnoticed.

It was observed in only 3 of my cases.

ish in colour. Chemically it is a soap and is
CHANGES IN THE DEAD FOETUS.

The foetus may undergo: (1) Mummification.
 (2) Adiposcere formation.
 (3) Calcification.
 (4) Suppuration.

Mummification. In this condition water is absorbed from the tissues of foetus, placenta and membranes, and all three shrink up. In a case described by Chiari, a mummified full-time foetus was found at death in an old woman of 82, which she had carried for 50 years. It was the remains of an extra-uterine pregnancy. The shrivelled membranes and placenta formed a fibrous capsule for the foetus, and were in parts adherent to it. Many of the tissues of the body could still be recognised microscopically. The chief changes were in the fat-containing organs, where the fat was changed into margarin and cholesterin. Most noticeable of all was the brain, which was converted into a red-brown pulp containing margarin and cholesterin and the remains of ganglion cells. Calcareous concretions were found in the placenta and membranes.

Adiposcere formation. Adiposcere is a

is a structureless, soaplike mass, white or yellowish in colour. Chemically it is a soap and is formed by the union of a fatty acid with ammonia. Fat is therefore essential to its formation. The ammonia is derived from the decomposition of the tissues. Moisture is also essential to its formation. In a foetus which is undergoing or has undergone this change, bones, or fragments of them, are often found, either in their normal relations to one another or irregularly arranged. Bland Sutton remarks that the foetus in these cases shows a marked tendency to adhere to the sac wall. Lime salts are liable to be deposited in the superficial tissues and membranes of foetuses, which have undergone both this change and mummification. In this way a lithopaedion is formed.

Calcification. The deposit of lime salts may take place in different parts of the ovum. Generally merely the placenta and membranes are infiltrated, but the deposit may be in the foetus itself, generally in the superficial parts only, but sometimes throughout the body. The body may have undergone calcification without the membranes being affected.

Dean and Marnoch believe that there is a preliminary coagulative necrosis in the tissues, that the necrosed layers become infiltrated by maternal

lymph, which is followed by the deposition of insoluble lime salts. Müller found the deposit to contain the salts of sodium potassium, calcium, and magnesium in a case in which he made an analysis. The lithopaedion may be carried for many years. The well-known example described by Cheston and preserved in the Royal College of Surgeons' Museum, was carried in the abdomen for 52 years without discomfort. A lithopaedion is generally quiescent. Inflammation may be set up by its presence however, and if there is any organic matter still remaining, septic complications may arise.

Suppuration. This is most likely to occur in those cases in which pregnancy is continuing in the broad ligament after rupture of the tube, and in which the placenta is above the foetus. The posterior ligamentous form is more likely to be infected than the anterior, because of its closer proximity to the rectum. Infection may take place at any time. The gestation sac becomes a bag of pus, which, along with the foetal bones, attempts to find an outlet along the line of least resistance. Of 248 cases recorded by various authors, 133 escaped by the intestinal canal, 58 through the abdominal wall, 30 through the vagina and in 27 ~~the~~ rupture into the bladder took place. Statistics shew that

escape by the abdominal wall is much the most favourable route as far as the mother is concerned. The mortality is very high in cases which rupture into the intestinal canal, vagina and bladder. Other suppuration may occur in the early months, e.g. in a broad ligament haematoma, but is rare previous to mid-term.

Of the cases described in this thesis, 7 (28%) were under 30; 13 (52%) were between 30 and 40, while 5 (20%) were 40 and upwards. The youngest was 25 and the oldest 42.

PREVIOUS PREGNANCIES. Two of my cases were primigravidas, 21 were multigravidas. In 2 this detail was not recorded.

HISTORY OF MARRIED LIFE. Of 23 cases in which the period of sterility preceding ectopic gestation was noted, it was under 2 years in 4, and over 2 years in 19. Of these 19, 8 had not been pregnant for 5 years. The shortest period of sterility was 16 months, the longest 10 years.

The families of these women were smaller than usual, on the whole, considering the proliferative class from which they were drawn, the early age at which they usually marry, and the comparative

advanced period of the child-bearing period at which

GENERAL CONSIDERATIONS.

half of my cases had had 3 or more pregnancies.

AGE. Hirst states that the commonest age for ectopic gestation is between 25 and 30. Most other authors seem to agree, however, that more cases occur between 30 and 40, than before or after that period. Of the cases described in this thesis, 7 (28%) were under 30; 13 (52%) were between 30 and 40, while 5 (20%) were 40 and upwards. The youngest was 23 and the oldest 42.

PREVIOUS PREGNANCIES. Two of my cases were primigravidae, 21 were multigravidae. In 2 this detail was not recorded.

HISTORY OF MARRIED LIFE. Of 23 cases in which the period of sterility preceding ectopic gestation was noted, it was under 2 years in 4, and over 2 years in 17. Of these 17, 8 had not been pregnant for 5 years. The shortest period of sterility was 16 months, the longest 18 years.

The families of these women were smaller than usual, on the whole, considering the proliferative class from which they were drawn, the early age at which they usually marry, and the comparatively

advanced period of the child-bearing period at which they develop extra-uterine pregnancy. Only 12, or half of my cases had had 3 or more pregnancies.

probably the explanation of the small number of cases of bilateral ectopic pregnancy is that which the embryos differ in their position. The uterine embryo may of course be removed for years, while other pregnancies proceed. In one case reported by Bland Sutton, the woman had an extra-uterine gestation (her first pregnancy) removed, and 18 months later was pregnant in the other tube, which was also removed along with the foetus.

It has been doubted whether ectopic pregnancy can be repeated in the same tube. Bland Sutton believes it to be impossible owing to changes in the tube induced by the first pregnancy.

R.C.Coffey describes a case in which he operated and found a pregnancy in both tubes. He removed one tube, incised the other and removed the ovum. The woman bore two children subsequently. If, therefore, the ovum could pass down the incised tube into the uterus and become impregnated, there is no reason why it should not be arrested in the tube.

CONCURRENT UTERINE AND ECTOPIC GESTATION.

Case 20, Mrs S., illustrates this condition. Where there is a discrepancy between the ages of the embryos, one must have died before the other, for when once a pregnancy has started and is in progress,

no further ova are shed. Should the ovum perish
 however, ovulation will start again, and the uterus
 or the other tube may become pregnant. This is
 probably the explanation of the considerable number
 of cases of bilateral tubal pregnancy reported, in
 which the embryos differ in size. A dead extra-
 uterine embryo may of course be carried quiescent
 for years, while other intra-uterine pregnancies
 proceed.

Coe reported a case in which a tubal gestation
 occurred in the outer end of a tube which was already
 blocked up nearer the uterus by a tubal gestation
 which had been carried for 12 years. The corpus
 luteum was in the opposite ovary, so that external
 migration had taken place, and the ovum had been
 fertilised by a spermatozoon which came up the
 opposite tube.

PLURAL ECTOPIC GESTATION. (1) Each tube may
 contain a foetus; (2) One tube may contain two or
 more foetuses; (3) One tube may contain one foetus
 and the other two or more. McCalla has collected
 25 cases of the first variety and 36 of the second
 and third. Salin reports a case in which one tube
 contained triplets, and Trent of Amsterdam a case
 in which a single tube contained no less than five
 embryos.

RIGHT SIDE OF PREGNANCY. Statistics differ very much,

and there is no obvious reason why one tube should

become impregnated more than another. In my cases, the R. tube was affected on 16 occasions, the L. on 9.

cause sudden distention of the tube... rupture of the sac... wards into the peritoneal cavity... They are urgent and require attention.

We must recognize... its way into the tube... sinuses, with lesser... amount of damage... generally been... tubes. These... their symptoms... the losses of blood... lesser pains which...

The distention... also excite... tube. We must...

In Case 17, after... rupture had... lower abdomen... losses of blood... thighs or moving...

In Case 3, Mrs. J. had symptoms...

rupture, viz. very dark bloody discharge, dragging
SIGNS AND SYMPTOMS OF ECTOPIC GESTATION.
pains in the R. iliac fossa, and pain on passing

Wats The symptoms which usually first draw attention to a condition of ectopic gestation are those associated with intra-mural haemorrhage, sufficient to cause sudden distention of the tube and in most cases, rupture of the sac inwards into the lumen, or outwards into the peritoneal cavity or broad ligament. They are urgent and compel attention.

Supo We must recognise that as the trophoblast eats its way into the tube wall, it may open up smaller sinuses, with lesser haemorrhages, varying in the amount of damage they do. Microscopically they are generally seen scattered through sections of pregnant tubes. These smaller haemorrhages can also produce their symptoms and they are probably responsible for the losses of bright or dark blood P.V. and ^{partly for} the lesser pains which sometimes precede the rupture. The distention of the tube by the growing ovum may also excite painful peristaltic contractions of the tube. We have instances of these warning symptoms in Case 17, Mrs C., who for three months prior to rupture had had aching and twinging pains in the lower abdomen. In Case 21, Mrs O'H. had two small losses of blood and griping pain on extending the thighs or moving about, for 5 days before rupture. In Case 2, Mrs W. had symptoms a month before

they should not at the same time arouse suspicion of rupture, viz. very dark treacly discharge, dragging pains in the R. iliac fossa, and pain on passing water. In No.8, Mrs C. had for 10 weeks before operation, continuous small bright losses, P.V., with very slight pain and was diagnosed before "rupture" occurred. (It is as implying sudden severe pain that I take it most authors use the term rupture).

It has been frequently stated that it is almost impossible to diagnose ectopic gestation before rupture occurs. Strong exception must be taken to this statement. True it is that these cases very often rupture before a medical man has been called in, but if he is called in, it should surely be possible sometimes to make a correct diagnosis. If a woman, usually quite regular and in good health, goes over her time, even only a day or two, it is strong presumptive evidence that she is pregnant. If in addition she has pains variously described as griping, dragging, twinging, aching, etc. and especially if they are referred to one side, suspicion of extra-uterine pregnancy should always be aroused. Suspicion should be strengthened if there are small losses of blood P.V. and particularly if the colour is dark or brownish. No doubt such symptoms would suggest threatened abortion of an intra-uterine foetus, but it implies a weakness of diagnosis, that

they should not at the same time arouse suspicion of a possible ectopic gestation. Surely it would be a good rule, in a matter of such importance, that before diagnosing threatened uterine abortion, ectopic gestation should be excluded first.

Unfortunately, most of the women suffering from this condition do not place themselves in a doctor's hands till rupture has occurred. Curiously enough, a very large proportion of them have no suspicion that they are pregnant. Of 14 patients who were asked specially, only one in my series thought so. Most of them repudiated the suggestion with some degree of confidence. In 4 cases this was not to be wondered at, for in one, rupture occurred 3 weeks after the last normal period, and in the other three, exactly a month after, viz. at the right time for the next period. Nine of the others, however, always perfectly regular, went over their time - some it is true only a few days, but some 2 - 3 months, without suspecting that they were pregnant. If the suspicion had occurred, it was dismissed as groundless. None of them were primigravidae, so that in the absence of the signs which they had been used to, they had not apparently attached much importance to a period of amenorrhoea. They commonly regarded a loss of blood, if it came on, as a delayed period.

Further symptoms depend on the site of the implantation and will be discussed presently.

It is, of course, well known that the absence of a period of amenorrhoea by no means negatives ectopic gestation. There is a greater tendency for the periods to continue for the first month or two of tubal pregnancy than there is in intra-uterine.

The history of the last period or so should always be enquired into. Sometimes a woman states that she has been quite regular and it will be found on careful questioning that it was not quite the same as usual, scantier perhaps, or of rather a different colour.

The majority of cases of ectopic gestation rupture early. A typical history is as follows:-

After a varying period of amenorrhoea, the patient, having gone perhaps only a few days over the right time for her menstrual flow, and having had possibly some slight pain in the hypogastrium or in one side, and possibly some slight losses of blood P.V., is suddenly seized with an agonising pain in the lower abdomen, which doubles her up. The pain is often referred to one or other side. She feels faint, or may actually become unconscious for a minute or two, and often vomits. The very severe pain may pass off in an hour or two, leaving a dull aching, or may continue severe for a day or two.

Further symptoms depend on what has happened and will be discussed presently.

pain, as in Case 8. (Mrs C.), but usually there is very bad pain.

The sudden, intense, agonising pain is an outstanding feature of this disease. There are comparatively few conditions which produce pain so acute; renal, biliary or intestinal colic, volvulus or other sudden forms of acute intestinal obstruction, twisted ovarian cyst, ruptured gastric or duodenal ulcer may do so. Patients differently describe the pain as griping, gripping, tearing, sharp like a knife, intense burning, and so on. The initial pain is due to the sudden distention of the tube with blood, and stretching of the peritoneum covering it. Rupture into the peritoneal cavity with implication and tearing of the peritoneal coat of the tube and out-pouring of blood may also cause severe pain and shock, as in ruptured gastric ulcer.

The pain of extra-tubal rupture is said to be worse than that of intra-tubal (tubal abortion). Patients vary very much, of course, in their appreciation of pain, but so far as I have been able to gather from those whose cases I have taken, I should say that the initial pain of intra-tubal rupture can be every bit as agonising as that of extra-tubal. The degree of pain itself is not a reliable guide as to what has happened. Separation of the ovum by small haemorrhages may take place slowly and without much

pain, as in Case 8. (Mrs C.), but usually there is very bad pain.

The site of the pain varies. It is frequently referred to the side of the rupture, but in a fair proportion of cases it is felt as an intense pain across the lower abdomen, not one side more than another.

I would draw attention to another site of pain, which though not uncommon, does not seem to attract much attention, viz: the rectum.

Several of the women in this series of cases told me that the first sensation was one of intense bearing down in the rectum. One described it as "burning". It does not seem to be associated with one kind or site of rupture more than another.

In my cases the pain was referred to one side in 15, across the lower abdomen, not one side more than another in 6, to the rectum in 2, and to the rectum and one side in 2.

Faintness. The initial faintness, is, I believe, not due to haemorrhage, but is reflex and due to the sudden pain and shock of distention of the tube or implication of the peritoneum, for it occurs in cases where there is little haemorrhage.

The faintness due to loss of blood will come on later, the time depending on the amount and rapidity with which it is lost. In a rupture, e.g.

with free haemorrhage into the peritoneal cavity
 bleeding from the site of rupture may be very
 the patient may, after recovering from the initial
 considerable and sometimes rapid.
 faintness, soon come over "swimmy" and faint again,
 Generally, however, the blood escapes slowly
 or the faintness may not come on for several hours
 and anaemia is gradual and progressive. If very
 or even a day or two.

slowly escaping, the blood will clot as it enters
 This returning faintness should always suggest
 the peritoneal cavity and form a haematoma around
 that whatever the lesion has been, there is internal
 the fibrinated and the centre fluid, the periphery
 haemorrhage accompanying it.

Vomiting often accompanies the onset, just as
 This peri-tubal clotting is favourable for
 it so often does in other abdominal catastrophes,
 it localises the bleeding process and may stop it
 e.g. acute appendicitis, biliary and renal colic,
 altogether by raising the pressure around the
 twisted ovarian cyst, etc.

Haemorrhage. It is the danger of haemorrhage
 bleeding point
 into the peritoneal cavity which makes ectopic ges-
 tation so perilous a condition. Internal haemorrhage,
 if present, may be rapid and copious, leading, if
 unchecked, to profound collapse and possibly speedy
 death. Generally speaking, in the early months the
 bleeding which accompanies rupture into the peri-
 toneal cavity is more dangerous and rapid than
 which takes place in rupture into the lumen of the
 tube (tubal abortion) or into the broad ligament.

In tubal abortion the blood collecting and
 clotting in the tube causes a rise of intra-tubal
 pressure, and has a haemostatic effect. In intra-
 tubal rupture, however, and especially if the ovum
 is not completely separated and expelled, or if the

chorionic site is on the fimbriae themselves, the bleeding from the ostium abdominale may be very considerable and sometimes rapid. Generally, however, the blood escapes slowly and anaemia is gradual and progressive. If very slowly escaping, the blood will clot as it enters the peritoneal cavity and form a haematoma around the fimbriated end, the centre fluid, the periphery laminated clot.

This peri-tubal clotting is favourable, for it localises the bleeding process and may stop it altogether by raising the pressure around the bleeding point. This will seldom progress to a dangerous pitch or to one producing profound collapse, for the blood being more or less confined, raises the pressure around the bleeding point and stops the flow.

The effect of effused blood on the peritoneum.

This is very distinctly irritating. If poured out in quantity into the peritoneal cavity it produces many of the signs and symptoms with which we are familiar in general peritonitis, though in a less marked degree. So marked are they on occasion, that if we had not the history and other symptoms of internal haemorrhage to help us, a diagnosis of general peritonitis might easily be made.

Thus we notice limited excursion of the abdominal walls, rigidity and tenderness over the lower time for adhesions to be set up between the tube and the neighbouring organs, or between the neighbouring organs themselves. Thus we may find a peri-tubal haematoma shut in between uterus, broad ligament, that on several occasions I have noticed coils of neighbouring coils of bowel, and perhaps the rectum small intestine showing a distinct pattern through on the L. side, and very frequently the omentum, the abdominal wall.

attracted in the same way that it is in an acute inflammatory process, bears an important share in palpation of the lower abdomen above the pubes - an imprisoning the blood.

In rupture into the broad ligament, after the first severe pain and shock are over the haemorrhage will seldom progress to a dangerous pitch or to one producing profound collapse, for the blood being more or less confined, raises the pressure around the bleeding point and stops the flow.

The effect of effused blood on the peritoneum.

This is very distinctly irritating. If poured out in quantity into the peritoneal cavity it produces many of the signs and symptoms with which we are familiar in general peritonitis, though in a modified degree. So marked are they on occasion, that if we had not the history and other symptoms of internal haemorrhage to help us, a diagnosis of general peritonitis might easily be made.

Thus we notice limited excursion of the abdominal walls, rigidity and tenderness over the lower abdomen sometimes dullness in the flanks, and almost invariably a greater or less degree of intestinal distention. So considerable is the irritation that on several occasions I have noticed coils of the small intestine shewing a distinct pattern through the abdominal wall.

In some cases there is a peculiar feeling on palpation of the lower abdomen above the pubes - an ill-defined resistance as of some underlying swelling without outline and shading off above; the percussion note over it is semi-dull. This is due to the presence of masses of blood clot among coils of bowel. It gives such a peculiar sensation that once felt it cannot be mistaken.

If the blood has been slowly poured out and has formed a peri-tubal haematocoele of any size, it may be felt as a soft, tender, rather ill-defined swelling on one or other side of the middle line.

Although setting up so much irritation, free blood seldom becomes infected so as to become purulent. The staphylococcus albus may however be present and in 20 cases of intra-peritoneal haemorrhage studied bacteriologically by Dudgeon and Sargent, 17 of which were from extra-uterine

absorption. There will therefore be a

pregnancies, this organism was isolated by culture from the blood clot in every case, while from the fluid part of the blood it was only found 3 times. I took cultures from several cases but they were all sterile except one. The fluid only was taken, unfortunately, so that this observation is of little value. I have confirmed Dudgeon's and Sargent's observations as to the presence of this organism in the fluid from some cases of intestinal obstruction, twisted ovarian cyst, intus-susception, etc. and although it has in most such cases but feeble pathological properties, yet it may be responsible for some such occurrence as the ready formation of adhesions between coils of bowel, the well-marked irritation of peritoneum as evidenced by intestinal distention etc. and more particularly for the raised temperature which almost invariably accompanies a ruptured ectopic gestation.

The effused blood tends to gravitate into the pouch of Douglas, where it may be felt P.V. as a diffuse boggy tender swelling in the posterior fornix. It is also found free among the coils of small intestine, and there is a tendency for it to collect in the extra-caecal fossa on the R. side and the descending colonic fossa on the L. side. The fate of the effused blood is usually rapid absorption. Here and there masses of clot may

the tough aponeurosis of the abdominal muscles at persist for a long time, and may set up adhesions between various organs. Especially is this the case in the pouch of Douglas, and a clot may be responsible for a retro-version, glueing down the body of the uterus to the rectum, as in case 10, Mrs M'C. where it was found 5 months after the rupture.

The intra-peritoneal haematoma seldom suppurates. If it does do so it is in the pouch of Douglas, where it follows the course of a pelvic abscess.

The "Tubal point". Before leaving the abdominal signs, mention should be made of an important one, viz. tenderness of the cutaneous nerve of the same dorsal segment, as supplies the tube and broad ligament. This dorsal segment is the 11th. If the area of skin in the front of the abdomen between the levels of the umbilicus and pubes be divided into 3 bands of more or less equal width, running very slightly obliquely from above downwards and inwards, and, as they approach the middle line, almost horizontally, the upper will represent the area of skin supplied by the 10th dorsal segment, the middle by the 11th and the lower one by the 12th. The 10th, 11th and 12th cutaneous nerves supplying these respective areas of skin pierce

the tough aponeurosis of the abdominal muscles at the outer border of the rectus abdominis. It is here that they are most accessible to pressure, and in many inflammatory or pathological conditions of the organs supplied by the respective dorsal segments, we find these corresponding cutaneous nerves exceedingly tender when pressed upon at the outer border of the rectus muscle. Thus the 10th dorsal segment supplies the ovary and one has become accustomed to refer to the point at the outer border of the rectus as the "ovarian" point. Similarly, the 11th dorsal segment supplies the tube and broad ligament, and one refers to the corresponding "tubal" point. The 12th dorsal segment supplies the uterus and we refer sometimes to the "uterine" point. It is often very tender on the L. side after curetting. These particular points, which can be localised to the area of the circumference of a lead pencil may be of great assistance in diagnosis. They are not always reliable, but over and over again I have relied upon them as a help in diagnosis, and have seen their evidence confirmed at operation.

When the parietal peritoneum is largely involved, these tender points may become obscured in the general tenderness.

In one case of rupture of the R. tube, I found a very definite area of hyperaesthesia of the skin

exactly corresponding to the dorsal segment. This is the only sign of which I have observed this pregnancy to be a constant sign.

Signs per vaginam. The sign of the vagina is rare in the early stages of pregnancy.

is rare in the early stages of pregnancy. The sign of the vagina is rare in the early stages of pregnancy.

free and the sign of the vagina is rare in the early stages of pregnancy. The sign of the vagina is rare in the early stages of pregnancy.

often with the sign of the vagina is rare in the early stages of pregnancy. The sign of the vagina is rare in the early stages of pregnancy.

constant sign. The sign of the vagina is rare in the early stages of pregnancy. The sign of the vagina is rare in the early stages of pregnancy.

the pregnancy is the sign of the vagina is rare in the early stages of pregnancy. The sign of the vagina is rare in the early stages of pregnancy.

certainly before the sign of the vagina is rare in the early stages of pregnancy. The sign of the vagina is rare in the early stages of pregnancy.

the other, but the sign of the vagina is rare in the early stages of pregnancy. The sign of the vagina is rare in the early stages of pregnancy.

the further sign of the vagina is rare in the early stages of pregnancy. The sign of the vagina is rare in the early stages of pregnancy.

of life is the sign of the vagina is rare in the early stages of pregnancy. The sign of the vagina is rare in the early stages of pregnancy.

but DIAGRAM ILLUSTRATING SITUATIONS of TENDER POINTS.

appear. The sign of the vagina is rare in the early stages of pregnancy. The sign of the vagina is rare in the early stages of pregnancy.

quickly, for the sign of the vagina is rare in the early stages of pregnancy. The sign of the vagina is rare in the early stages of pregnancy.

it, the fetus is the sign of the vagina is rare in the early stages of pregnancy. The sign of the vagina is rare in the early stages of pregnancy.

weeks. The sign of the vagina is rare in the early stages of pregnancy. The sign of the vagina is rare in the early stages of pregnancy.

swellings, etc. but the sign of the vagina is rare in the early stages of pregnancy. The sign of the vagina is rare in the early stages of pregnancy.

cysts, etc. but the sign of the vagina is rare in the early stages of pregnancy. The sign of the vagina is rare in the early stages of pregnancy.

setopic gestation, etc. but the sign of the vagina is rare in the early stages of pregnancy. The sign of the vagina is rare in the early stages of pregnancy.

of pregnancy. The sign of the vagina is rare in the early stages of pregnancy. The sign of the vagina is rare in the early stages of pregnancy.

The uterus is the sign of the vagina is rare in the early stages of pregnancy. The sign of the vagina is rare in the early stages of pregnancy.

softened, but the sign of the vagina is rare in the early stages of pregnancy. The sign of the vagina is rare in the early stages of pregnancy.

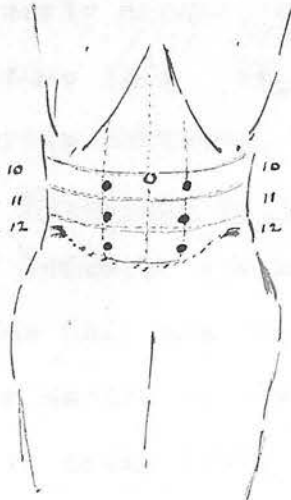


DIAGRAM ILLUSTRATING SITUATIONS
OF TENDER POINTS.

exactly corresponding to the band of the 11th R. dorsal segment. This is the only occasion on which I have observed this phenomenon in ectopic gestation.

Signs per vaginam. Discolouration of the vulva is rare in the early months, but may appear if the pregnancy continues late. Vaginal secretion may be free and the cervix softened, but these signs are often wanting. Pulsation in the fornices is a very constant sign. Hofmeier states that it is felt on the pregnant side only and not on the other. It is certainly better marked on the pregnant side than the other, but is often found on both. He makes the further statement that, if present, it is a sign of life in the foetus and disappears after its death, but does not state how long it takes for it to disappear. Certainly it does not disappear very quickly, for in all the cases in which I have found it, the foetus has been dead, in some cases for weeks. Pulsation may be present in other pelvic swellings, e.g. salpingitis, dermoid and ovarian cysts, etc. but seldom in so marked a degree as in ectopic gestation, and it is a suggestive symptom of pregnancy.

The uterus is usually somewhat enlarged and softened, but has not the globular shape and the peculiar consistence of a pregnant uterus. It is sometimes displaced to the opposite side.

A swelling may be felt in front of or behind the cervix, or to one side. Its shape and disposition will vary according to the pathological condition. If the tube is still unruptured or contains blood clot inside, it may be felt as a soft, rounded or sausage-shaped swelling, to one side of and generally rather behind the uterus. In most cases more or less of a gap or groove can be felt between the two; sometimes it is so closely continuous with the side or back of the uterus that it is difficult to make out where one ends and the other begins. The swelling has a very distinctive boggy feeling, which no other pelvic swelling possesses. It is usually very tender, sometimes exquisitely so.

If there is blood or clot in the pouch of Douglas an extensive, soft, boggy, tender swelling will be felt behind the cervix, and the uterus may be displaced forwards. When the rupture has occurred into the broad ligament and has burrowed behind the uterus, it will cause still greater displacement forwards of the uterus and may be mistaken for a retroverted gravid uterus.

If some time has elapsed since the effusion, and the blood clot has lost its fluid, the signs are practically those of a pelvic exudation.

A decidual cast complete, or fragments of decidual membrane, are often passed after the death of the foetus, sometimes shortly after, sometimes not for some time.

Pain on micturition. Often after rupture, and sometimes before, there is pain on passing water. This may be just a difficulty in starting but in most cases is felt just at the end of the act. Occasionally also there is frequency. It is a symptom which is often observed in other pelvic conditions and more especially inflammatory ones such as salpingitis, pelvic appendix abscess etc. Probably in cases where there is a painful swelling within the broad ligament, the explanation is to be found in the drag of the bladder on the tender parts as it becomes empty or on the peritoneum covering them. When there is free blood in the peritoneal cavity, there may be referred pain from the irritated peritoneum covering the bladder.

Pain on defaecation, is sometimes a troublesome symptom and may lead to constipation. If present it is usually in those cases where rupture is on the L. side or where clot is present in the pouch of Douglas.

Loss of blood per vaginam. This sign is an important one. It may be present before rupture and is a frequent one after, particularly where the

gestation sac has ruptured into the lumen of the tube and the abortion is incomplete, and in rupture into the broad ligament. When abortion has been complete or where rupture has taken place into the peritoneal cavity, it is much less likely to be present. The losses of blood are usually small and may continue for months if the source of irritation, e.g. an incomplete abortion in the tube, still remains. The blood probably dribbles slowly down from the tube. Hence it may be retained in the tube or uterus long enough to become a brown or even an almost black colour. Too much stress is apt to be laid on the brown colour of the discharge. It is certainly the most common colour but in a very fair proportion of instances the colour is a bright red. It may start as one and gradually become the other, as in 3 of my cases.

Temperature. There is almost invariably a rise of temperature after rupture of the tube whether intra or extra-tubal, and is likely to be highest when there is a large extravasation of blood. I have had opportunity of observing it before and immediately after rupture and there is not, as far as I have been able to observe, that subnormal temperature which some writers have described as a sequence to a haemorrhage from a

ruptured tube, and which they have emphasised as a point in the differential diagnosis between ectopic gestation and salpingitis.

The cause of the rise of temperature may be, as some have suggested, the absorption of albumoses or other substances from the effused blood, or may, as Dudgeon and Sargent believe, depend on the presence of the staphylococcus albus in the blood clot.

Supposing then that rupture has taken place in the early weeks of tubal pregnancy, say 4-8 weeks, have the resulting conditions sufficiently distinctive characters to allow us to make a diagnosis between them? There are points which will aid us in making a distinction, but which are often common to one or more of them.

Tubal abortion and early rupture into the peritoneal cavity both commonly occur before the end of the second month; at 5 weeks is a very favourite time. Both may give rise to severe pain and shock, but if there are rapid symptoms of collapse and internal haemorrhage coming on after, the chances are in favour of its being rupture into

the peritoneal cavity.

If there are symptoms of slow and gradual internal haemorrhage, small losses of blood P.V, pain on micturition, and continued lesser pain on one side after the primary rupture, the odds are on incomplete abortion. In incomplete abortion, too, there is a great tendency for repeated haemorrhages into the tube to occur with other sudden, violent pains as at the onset. They may be only a day or two apart, or sometimes weeks intervene.

Rupture of the tube into the peritoneal cavity may, of course, be later than the first two months, and its signs will be much the same as if it occurred earlier. The interstitial form of tubal pregnancy usually ruptures in the 4th month or the end of the 3rd. There will probably be the same rapidity of onset of symptoms of intra-peritoneal haemorrhage, especially if the interstitial form. Rupture into the peritoneal cavity takes place till after the 2nd month. The third month is a favourable time for it to occur. Rupture, however, occurring in the 3rd or 4th month is likely to be one of these forms and a clear distinction may be drawn between them. With

On examination P.V. we shall find signs corresponding to the amount of blood poured out, i.e. if there is a large soft boggy tender swelling in the pouch of Douglas within a few hours of the catastrophe, it is in favour of rupture outwards into the peritoneal cavity. If we have an incomplete tubal abortion to deal with we shall probably find a smaller more localised swelling, to one side of the uterus, and perhaps somewhat behind it.

the former there is the...
gressive haemorrhage...

These distinctions are, however, only based on probabilities, for in incomplete tubal abortion a quantity of blood may rapidly escape into the peritoneal cavity with all the signs described as being in favour of rupture into the peritoneal cavity.

LATER RUPTURE.

Rupture of the tube into the peritoneal cavity may, of course, be later than the first two months, and its signs will be much the same as if it occurred earlier. The interstitial form of tubal pregnancy usually ruptures in the 4th month or the end of the 3rd. There will probably be the same rapidly oncoming symptoms of intra-peritoneal haemorrhage, especially urgent in the interstitial form. Rupture into the broad ligament seldom takes place till after the 2nd month is over. The third month is a favourite time for it to occur.

Rupture, therefore, occurring in the 3rd or 4th months is likely to be one of these forms and a clear distinction may be drawn between them. With

associated with...
signs and symptoms...

the former there is the probability of rapid progressive haemorrhage and its symptoms.

In rupture into the broad ligament, the pressure of the blood in a somewhat confined space tends to stop the bleeding before it becomes urgent.

After the initial shock has passed therefore, the patient rallies, though left with very considerable pain on one side, till very possibly another sharp attack comes on, with repeated shock and recovery. That is to say, in rupture into the broad ligament, as in incomplete tubal abortion, there is a great tendency to repeated haemorrhages. In both, between the attacks there is often pain referred to the affected side, and a loss of bright or more commonly dark blood, P.V. Pain on micturition is also frequently present.

It will be noticed, therefore, that the symptoms of incomplete abortion and rupture into the broad ligament differ very little, except in two respects:-

(1) Time of occurrence - in incomplete abortion rupture is early as a rule. Rupture into the broad ligament is usually not till after the 2nd month.

(2) Incomplete abortion is not infrequently associated with intra-abdominal bleeding and its signs and symptoms, and these do not occur in

rupture into the broad ligament unless there is secondary rupture into the peritoneal cavity soon after.

In the ^{still} later months symptoms pointing to ruptured ectopic gestation may result from later rupture of any of the primary or secondary forms into the peritoneal cavity. In all these cases the shock will be severe.

The urgency of symptoms of haemorrhage will depend on the position of the placenta. If above, it will probably be torn and death may take place in a short time. If below, the symptoms will be less urgent, as the placenta will probably escape.

In the later months the signs and symptoms of intra-peritoneal and ^{of} ~~in~~ extra-peritoneal ligamentous pregnancies which have reached above the pubes, will differ little from those of a normal pregnancy. The mother complains sometimes that the child is very "rough" in its movements, and if examination is made, the foetal parts may be felt with great distinctness.

In such a condition a careful enquiry into the previous history may confirm the suspicions of an extra-uterine pregnancy.

Ovarian and tubo-ovarian pregnancies have not been considered in the signs and symptoms, for their occurrence is so rare, and it would confuse the

practical issue to give them much prominence.

Ovarian pregnancy may be terminated by haemorrhage into the cyst without rupture, in which case the sign and symptom would only be amenorrhoea and a sudden severe pain on one side, or by rupture into the peritoneal cavity with the same symptoms of rapid bleeding as in tubal rupture. The time of rupture is said to be usually the 2nd or 3rd month.

If development proceeds till the later months the signs will not differ from those of other forms.

On examination, although the uterus of extra-uterine pregnancy is enlarged it lacks the globular shape and characteristic weight of the pregnant uterus.

In the former, too, the ectopic sac may be felt to one side of the uterus, especially if an anaesthetic is given. If the tube has ruptured, the sudden severe catastrophic pain of rupture should seldom be confused with the pains of threatened abortion.

When we have a history of a sudden intense pain in the lower abdomen our mind naturally runs over the various possibilities. The localisation of the pain to the lower abdomen and pelvis, together with other symptoms will at once put us on our guard.

out of count, leaving others, chief among which are
DIFFERENTIAL DIAGNOSIS.

Early months. Before rupture has occurred, ectopic gestation may closely resemble threatened intra-uterine abortion. In both there is probably a period of amenorrhoea, both may have slight pains and losses of blood. If the pains are referred to one side suspicion should be aroused that ectopic gestation is present. If, moreover, the loss of blood is dark or brown it will point strongly to ectopic gestation, and in threatened abortion the loss is usually much more copious than in ectopic. On examination P.V. although the uterus of extra-uterine pregnancy is enlarged it lacks the globular shape and characteristic doughy feel of the pregnant uterus. In the former, too, the ectopic sac may be felt to one side of the uterus, especially if an anaesthetic is given. If the tube has ruptured, the sudden severe catastrophic pains of rupture should seldom be confused with the pains of threatened abortion.

When we have a history of a sudden intense pain in the lower abdomen our mind naturally runs over the various possibilities. The localisation of the pain to the lower abdomen and pelvis, together with other symptoms will at once put several

ruptured ectopic gestation with a pelvic haematocoele.

out of count, leaving others, chief among which are twisted ovarian cyst or dermoid, or ~~pedimentated~~ ^{pedunculated} fibroid, acute salpingitis, tubo-ovarian abscess, acute appendicitis with the Appendix in the pelvis.

Tubo-ovarian abscess may most closely resemble ectopic gestation. Both may have amenorrhoea, pain on one side, small losses of blood P.V., often brown, raised temperature and a soft tender swelling in one fornix.

The most reliable point of distinction is a total and differential leucocyte count. This is of the greatest assistance in deciding between ectopic gestation and any inflammatory condition such as salpingitis, tubo-ovarian abscess, pelvic appendix etc.

If the total leucocyte count is raised and at the same time the differential count shows the case a diagnosis may be almost impossible if the pregnancy is in the first two months. The following it may be assumed with some confidence that the condition is an acute inflammatory one, and not ectopic.

Twisted ovarian cyst. Confusion is most likely to arise when the cyst is of moderate size and can be contained in the pelvis. There is the sudden severe pain, if twist is acute, collapse, vomiting, and perhaps fainting, and tender abdomen. If not seen for two or three days the cyst may have become adherent, e.g. in the pelvis and closely resemble a ruptured ectopic gestation with a pelvic haematocele,

or a rupture into the broad ligament with considerable retroperitoneal extravasation. The temperature may be raised in both. In twisted ovarian there will be no history of amenorrhoea, but slight pulsation in the fornix, and if the uterus is made out, it will not be enlarged. The vomiting of twisted ovarian cyst is likely to be more prolonged and continuous than in ectopic, and the tender points, of the tube and ovary, may be of value. The boggy feeling of the ectopic gestation is always a valuable symptom. The passage of a decidual cast may help very greatly in any of these conditions in deciding for ectopic gestation. Intra-uterine pregnancy may be present along with some pelvic swelling, such as a dermoid or ovarian cyst, or less commonly a salpingitis, or hydrocele of the tube. In such a case a diagnosis may be almost impossible if the pregnancy is in the first two months. The following is a case in point.

Mrs. B. 32. Last child 4 years ago. Amenorrhoea for 2 months. During this time for 1 day slight light brown "show". For last 4 months, has had a pain as of inflammation in R. iliac fossa off and on. During last two months, has had occasional sudden dragging pains in same place, which pull her to the floor and make her go into a cold sweat. Frequency of micturition for past month. Does not

think pregnant. ~~difficult to distinguish between~~
 pelvis. Tenderness in R. iliac fossa. P.V. Walls
 moist and lax. Uterus suggests that of 1½ months
 pregnancy. To the R. of it and distinct from it is
 a soft, round, boggy swelling, regular in outline,
 freely mobile, not very tender, about size of large
 orange. ~~very acute and often is felt on one side only~~

at the Pulsation very well marked in fornices. ~~no pain~~

must Operation revealed 2 months pregnant uterus,
 and soft, doughy, dermoid cyst, size of large orange,
 with a well-marked pedicule. This was removed. ~~by~~

Retroverted gravid uterus. about 2 - 3 months
 pregnant, may resemble an ectopic gestation which
 has ruptured, with a large haematoma in the pouch
 of Douglas. More especially however it is apt
 to be confused with a tube which has ruptured into
 the broad ligament, with considerable burrowing of
 blood behind the uterus. The blood may have pushed
 the uterus right forward, even to the extent of
 causing retention of urine. The history, though, will
 probably help to decide between the two, the
 sudden pain and loss of dark blood P.V. of ectopic
 gestation with rupture, will be absent in the retro-
 verted gravid uterus, and the mass felt will not be
 able to be pushed forward as in the retroverted
 gravid uterus.

It may be difficult to distinguish between pelvic haematoma of some standing and pelvic cellulitis due to salpingitis. A history of amenorrhea, possibly dark vaginal discharge, pain followed by faintness, etc., will help to distinguish the former. In salpingitis the onset of pain is sometimes very acute and often is felt on one side only at the beginning, so that the symptom of sudden pain must not be too much relied upon.

It is not proposed to enter into the question of treatment in this thesis. Operation is the only safe treatment, but the choice of the moment of its performance, the technique and the various difficulties met with, are beyond the scope of this paper.

P.V. Walls: dry and covered with exudate. Uterus slightly enlarged and tender. Not soft. Position normal. In R. fornix wall: cut on to pelvic wall, and separated by gap from uterus by a soft, tender, rounded swelling size of small apricot. In L. fornix similar rounded swelling, not so tender. Pulsionation noticed in both fornices.

Operation. R. tube contained blood clot in outer half. Bound by adhesions to lateral and ventr. Both removed. No free blood in abdominal cavity. L. ovary cystic - size of small apricot. Good recovery.

CASES OF INCOMPLETE ABORTION.

(1) Mrs S. 27. Last pregnant 2 years ago. Evidence of salpingitis following birth of last child. Regular. 5 weeks after last period taken

with severe pain across lower abdomen, not specially on one side. Bad pain passed off. Has recurred several times since. Constant slight pains coming and going. Started losing P.V. with onset of pain. 1st day clots - then dark fluid blood. Thought period coming on. This had continued pretty constantly till operation 9 weeks after onset. No fainting or vomiting. Pregnancy not suspected.

Abdomen. R.tubal point and L ovarian point tender. Nothing else to note.

P.V. Walls dry and covered with smegma. Uterus slightly enlarged and tender. Not soft. Position normal. In R. fornix well out on to pelvic wall, and separated by gap from uterus is a soft, tender, rounded swelling size of small apricot. In L.fornix similar rounded swelling, not so tender. Pulsation marked in both fornices.

Operation. R. tube contained blood clot in outer half. Bound by adhesions to bowel and ovary. Both removed. No free blood in abdominal cavity. L. ovary cystic - size of small apricot. Good recovery.

Special points. Incomplete tubal abortion, blood clot and destroyed foetus retained, with recurrent attacks of pain, and escape of dark blood P.V. No urgent shock or evidence of haemorrhage.

(2) Mrs W. 33. Last pregnant 7 years ago. No evidence of salpingitis. Irregular. Often goes a week over her time. 5 weeks after last period, started losing an almost black treacly discharge, which contained up to time of operation. 2 weeks after start of discharge, began dragging pains in R. iliac fossa on exertion and pain at end of micturition. A month after first symptom was suddenly seized, while dressing, with severe pain in R. lower abdomen which doubled her up and caused her to faint. Vomited twice soon after. Pain has continued in short bouts since, accompanied by turns of faintness and cold sweats. Defaecation painful since severe pain. Thought she had influenza. Did not think pregnant. Very pale. Temp. 99. Pulse 110. Breasts contain a little secretion.

Abdomen. Below umbilicus fullness on either side. Restricted movement, tender, rigid. R.tubal point most tender of all.

P.V. Walls moist. Fundus pushed forward and cervix backward by a mass lying behind and to R.

of them. Mass soft, boggy, tender. Marked pulsation.

Operation. Omentum bound down over mass consisting of gestation sac and clotted blood, lying behind and to R. of uterus. Great quantities of clotted and fluid blood free in peritoneal cavity. While getting up gestation sac into wound, a foetus apparently about 2 months old, complete in its amniotic sac escaped from the fimbriated end, and, following it, the chorion, now becoming differentiated into a placenta. Tube removed, and clot cleared out. Slow recovery. Very anaemic.

Remarks. Here the first symptom, loss of dark blood P.V., appeared a month before the sudden haemorrhage which caused the intra-tubal rupture and separation of the placental site. The dark blood probably came from the tube as the result of a series of small haemorrhages not sufficient to produce symptoms other than the dragging pains on exertion. Probably the foetus continued to grow, up to the sudden catastrophe, to judge by its size. The temperature was raised in spite of great loss of blood. The collapse was more profound and prolonged than in case (1). The "peritonitic" state of the abdomen from much effused blood was interesting. The breasts contained a little secretion at 2 months.

(3) Mrs L. 39. Last pregnant 7 years ago. Regular. 5 weeks after last period was suddenly seized with intense bearing-down pain in sacral region. Fainted and was carried home. Went to see her doctor next day - fainted twice while there and several times since from pain. For next 5 days considerable pain across lower abdomen not one side more than another. Went to bed on 2nd day and remained there till admission to hospital 2 months later. Pain gradually eased - very little during last 2 weeks. Occasional light red discharge P.V. since onset. Small in amount. 6 weeks after onset passed a flattened out pinkish piece of what looked like "flesh". Did not think pregnant.

Abdomen. Both tubal points tender. Nothing otherwise.

P.V. Uterus rather enlarged. Behind and to R. of it, a small, soft convex, very tender swelling. Marked pulsation in R. fornix.

Operation. Omentum down, forming with small intestine, uterus and rectum, a cavity, adherent to the inner wall of which was the R. tube. At the outer end of the tube was the foetus, about 1 month old, in its amnion, surrounded by a layer of blood clot, $\frac{1}{2}$ an inch thick; no free blood. Quick recovery.

Remarks. The first symptom, the sudden severe pain, was probably due to the sudden distention of the tube by blood. This no doubt killed the foetus by destroying its chorionic site. Fainting, as in this case, may be due to pain of sudden distention of tube and is not always from loss of blood. Subsequent attacks of pain and faintness were probably due to further slight haemorrhages. The site of the pain, in the sacral region, is interesting. Blood P.V. was bright - probably from the uterus. Note adhesion of omentum etc. round tube.

(4) Mrs S. 39. Last pregnancy 7 years before. No evidence of salpingitis. Regular. 5 weeks after last period, when in excellent health, was seized with a severe pain in hypogastrium, not one side more than another. Pain came in recurring spasms, like labour pains. No fainting or vomiting. Pain continued off and on for 7 weeks, till admission to hospital. Spent last 3 weeks in bed by doctor's orders. Bright red discharge, P.V, started 3 days after onset of pain, and continued daily in small amount for a month. Then came in clots till admission. Pain and difficulty in starting micturition and smarting pain at end during last fortnight. Pain on defaecation for similar period. Did not think pregnant. On admission

patient looked very ill. Is pale, sallow and "toxic". Temperature 103.6. Pulse 130.

Abdomen. General flatulent distention. Movement below umbilicus restricted. Here rigid and tender. Indefinite resistance over considerable area above Pubes, as if large quantity of blood clot.

P.V. Owing to exquisite tenderness, and the resistance above, nothing could be made out.

Operation. R. tube surrounded by huge mass of localised clot. ^{The peritoneal cavity} Contained blood clot. No foetus found.

Remarks. "Peritonitic" abdomen again present, due to irritation of effused blood. Continued loss P.V. of bright blood. Note high temperature, and tendency to localisation of blood coming from tube if not poured out too quickly.

(5) Mrs B. 36. Last pregnancy 12 years ago. Irregular. Often over her time. After 3 months amenorrh~~ea~~^{ea}, was suddenly prostrated with pain in L. iliac fossa, which doubled her up. Severe pain passed off, dull pain has remained since. At same time started dark brown discharge P.V. which continued till admission to hospital 3 weeks later. There has been sharp pain on micturition.

46
Abdomen. Some resistance to palpation in L. iliac fossa; otherwise normal.

P.V. Tender, ill-definable swelling in left posterior fornix.

Operation. L. tube distended with blood, unruptured. No blood in peritoneal cavity. L. tube and ovary removed.

Remarks. Foetus probably destroyed at first bad pain. Presence of mole in tube apparent cause of bad pain on micturition, and continued small haemorrhages trickling into uterus.

(6) Mrs S. 30. Last pregnancy 2 years ago. Evidence of salpingitis present. Irregular. Menorrhagia and metrorrhagia since abortion 18 months before. 10 days before admission to hospital was taken with severe pain in the R. lower abdomen which made her draw her R. leg up. She vomited, and there had been pain on micturition since onset. No loss of blood P.V. since onset.

On admission, patient looked ill. Pulse 116. Temperature 101.8. Lies on R. side with R. leg drawn up.

Abdomen. Tender swelling in R. iliac fossa.

P.V. Uterus normal size. To the R. of it and just distinguishable from it is a tender swelling the size of an orange.

Operation revealed the R. tube markedly distended with blood clot. Removed with ovary. No free blood. Good recovery.

Remarks. From the history and state on admission and examination this case might have easily been taken for one of acute salpingitis or appendicitis. The irregular metrorrhagia before made it the more difficult. A definite diagnosis was not made before operation. A total - and differential blood count would have been of value in diagnosis. Again we note a raised temperature, and without any marked loss of blood. It must be confessed that there is no positive evidence that this was a case of tubal pregnancy. No foetus was found and unfortunately, no sections of tube or clot were cut. It was, however, thought justifiable to include it in the series.

(7) Mrs V. 38. Last pregnancy $2\frac{3}{4}$ years before. No evidence of salpingitis. Regular. A year ago, exactly a month after the last normal period, was taken with a sudden "burning" pain in the L. iliac fossa. She did not faint or vomit. Pain passed off, and returned off and on in lesser degree for some days. After a fortnight, went to

bed for 2 months. Had been getting up for $9\frac{1}{2}$ months previous to admission and has had intermittent pains in L. iliac fossa, but not severe enough to lay her up. Brownish discharge P.V. started with sudden onset of pain, and continued without interruption for 6 months. Then became less and intermittent up to time of admission - more profuse at periods. Micturition normal throughout. Great pain on defaecation during first 2 months.

Abdomen. L.tubal point markedly tender. Nothing otherwise of note.

P.V. Fundus markedly anteverted, normal in size and consistence, and cervix pointing right back to rectum. Cervix fleshy and eroded. Uterosacral ligaments thickened and shortened. No definite mass felt. Brownish discharge on finger.

Operation. Ectopic gestation found rather to inner end of L. tube size of a tangerine orange; wall of tube $\frac{1}{2}$ of an inch thick, and full of yellowish brown blood clot. No sign of a foetus. Tube was swung round to the pouch of Douglas and adherent to the back of uterus and rectum. Quick recovery.

Remarks. A good example of retained mole keeping up continuous irritation, discharge of dark blood and intermittent pain while it persisted in the tube. Pain on defaecation was probably due to presence of distended tube in pouch of Douglas and adhesions

99
between it and rectum.

Remarks: This case illustrates the importance
of ex- (8) Mrs. C. 40. Last pregnancy 5 years before.
No evidence of salpingitis. Regular. Five weeks
after last period, commenced to lose small amounts
of bright blood each day. This continued for 10
weeks without intermission, gradually getting rather
more in quantity. Has had slight occasional pains,
felt no bearing down in the back; these are always
relieved by flow of blood. No trouble with mic-
turition or defaecation. Disclaimed all idea of
pregnancy. Without an anaesthetic nothing could
be made out P.V. or P.R. Ectopic gestation being
suspected an anaesthetic was given and a soft boggy
swelling, the size of a Victoria plum, could be made
out in the fornix. Uterus slightly enlarged.

Operation. The R. tube was elongated, thick-
ened and tortuous. Just internal to the fimbriated
end was a swelling $1\frac{1}{2}$ x 1 inch in which was a small
amniotic sac, containing blood clot. The fimbriated
end was widely patent, and lying just outside it,
resting in the angle formed between the outer $1\frac{1}{2}$
inches of the tube, and the ovary, was another
small clot 2 x $1\frac{1}{2}$ inches. No foetus was found.
The tube and ovary were removed. Sections of the
blood clot within the tube shewed scattered broken-
up villi.

Remarks: This case illustrates the importance of examining under an anaesthetic when there is doubt as to the presence of extra-uterine pregnancy. It, like the previous case, shews how a mole retained in the tube may keep up continued discharge P.V. for a long time. The absence of all severe pain is worthy of note, for there had evidently been considerable tearing up of the chorionic site. Probably this was done gradually and without any haemorrhage large enough to cause sudden marked distention of the tube.

(9) Mrs. M. 34. Last pregnancy 7 years ago. Evidence of salpingitis, from history, appearance at operation and sections of tube. Irregular, generally under time. 5 weeks after last period was suddenly seized with severe pain across lower abdomen, not one side more than the other, when getting out of bed. It doubled her up and made her shriek out. The power seemed to be taken out of her legs for the time being. Did not faint or vomit. Pain lasted quarter of an hour. Started losing a good deal of bright blood which continued for the next 7 weeks. No return of pain till the end of these 7 weeks. Then taken again, when washing, with another acute attack, which brought her to her knees, and made her vomit. A fusillade of sharp, stabbing

CASES OF COMPLETE ABORTION

pains in lower abdomen continued for three hours, and then eased off. Admitted same day to hospital.

Abdomen. Nil.

P.V. Uterus normal in size, position and consistence. Behind it and to the left is a soft tender swelling, apparently tubal; size of tangerine orange.

Operation. Both tubes matted by adhesions to back of uterus, preventing their immediate definition. By separating these L. tube was isolated. The outer third was found to be distended with blood clot to size of a large walnut and bound down to L. side in the Pouch of Douglas to a localised collection of blood clot, the size of a tangerine orange. L. tube and ovary removed. R. tube removed. On serial microscopic section no sign of membranes or decidua cells could be found in the wall of the blood cyst. In the intra-tubal clot itself, however, chorionic villi were found here and there. No foetus found. Well-marked old salpingitis seen microscopically.

Remarks. A further example of continuous loss of blood P.V. while there is a mole in the tube. Foetus was probably killed at the first attack. Shews that further haemorrhage can occur some time after formation of a mole (in this case 7 weeks) with very acute symptoms.

probably by 10th day. Pain then relieved - did

CASES OF COMPLETE ABORTION. V. continued for 3 weeks.

Possibly small piece of membrane left in tube kept -
 (10) Mrs McL. 29. Never pregnant before, ing up slight bleeding, and hyperaemia, or small married two years. No evidence of salpingitis. piece of clot, extruded later. Only moderate amount Regular. Five weeks after last period was suddenly of shock at onset. No fainting or vomiting. seized with pain low down on one side of abdomen. Did not faint or vomit. Pain continued for three days and then she began to lose P.V., with considerable relief of pain, the latter soon disappearing. She lost for three weeks, bright red at first, then gradually becoming dark brown, and then stopped. Periods regular during next 4 months, but excessive. No trouble with micturition or bowels. Sought advice for excessive periods. On examination, no milk in breasts, nothing of note in abdomen. Did not think pregnant.

P.V. Uterus slightly enlarged. A hard, irregular, rather fixed mass, size of a tangerine orange was felt in the pouch of Douglas.
Operation. Laminated clot size of large walnut found in pouch of Douglas, together with a few small remains of clot. It was adherent to rectum and bottom of pouch, and was removed. Outer end of R. tube contracted down but shewed signs of having been source of clot. Left in situ. No signs of foetus in clot. Quick recovery.
Remarks. Complete expulsion of destroyed ovum probably by third day. Pain then relieved - did

not recur. Loss of blood P.V. continued for 3 weeks. Possibly small piece of membrane left in tube keeping up slight bleeding, and hyperaemia, or small piece of clot, extruded later. Only moderate amount of shock at onset. No fainting or vomiting.

(11) Mrs H. 25. Last pregnancy $2\frac{1}{2}$ years ago. No evidence of salpingitis. Regular. Suddenly taken between periods with severe pain in R. iliac fossa. Sitting still at time. More or less pain for two months. None in succeeding two months before she sought advice. No loss P.V. The periods continued as usual. Abdomen showed nothing note-worthy.

P.V. Uterus slightly enlarged. Cervix eroded. In R. posterior fornix is an irregular soft cystic swelling, size of orange.

Operation. R. tube and ovary both adherent to back of uterus and R. broad ligament, by means of a blood clot, size of tangerine orange, which lay in the angle between them. Clot, tube and ovary removed. Tube rather thickened at outer third, well contracted down.

Remarks. No actual evidence that this was a tubal pregnancy, but highly probable that it was, and that complete abortion took place soon after onset, with contracting down of the tube on chorionic site.

(12) Mrs T. 36. Last pregnancy three years ago. No evidence of salpingitis. Regular. Last regular period 9 weeks before onset. Then a "period" 9 days late and very scanty, then a month later sudden agonising pain across lower abdomen, "like a knife". Had been feeling languid, with sensation of nausea in the mornings, for last two months. Pain came on when she was out for a walk; reached home with difficulty. Did not faint, vomit, or feel dizzy. Bad pain lasted 12 hours, then settled in R. iliac fossa as a dull ache, There have been several exacerbations during 5 weeks since onset. On night of first sudden pain a profuse, stringey discharge started, at first bright, becoming after 2 weeks a dark brown. Did not think she was pregnant in spite of nausea in mornings and interruption of normal regular menstruation.

On admission. Pale, has evidently lost a good deal of blood. Temperature 99. Pulse 104. Leucocytes 5100. Polymorfo-nuclear leucocytes 77%.

Abdomen. Moves well. Slight distention. Tender across abdomen above pubes, especially both 11th dorsal segments. R. tubal point exquisitely tender. A soft boggy swelling is felt in R. iliac fossa and is continuous with fullness high up in the R. anterior fornix.

P.V. Cervix hard and non-patulous. R. fornix

very tender. No pulsation felt. Swelling as above described. 3 pregnancies. 12 weeks after last

Operation: Outer half of R. tube somewhat thickened and dilated, and empty. Haematocoele size of large orange outside and adherent to its fimbriated end. In the centre of this clot was a small foetus in the amniotic sac. Much free blood clot in peritoneal cavity. R. tube and ovary removed along with clot. Slow recovery. A good deal of peritoneal irritation and flatulence during the first week after operation. No chorionic villi were found in microscopic sections from wall of tube.

Remarks: This was probably an incomplete abortion for some considerable time, and the continual oozing P.V. and per ostium admoninale, was probably kept up till the extrusion of the ovum some time after the first acute attack of pain. By this slow progressive loss of blood the woman had become profoundly anaemic. The tube had contracted down well after expulsion of the ovum.

In this case the blood lost P.V. was at first red and then gradually changed to brown - suggesting that whatever colour the blood, it comes from the same place, either the tube or uterus. The total and differential blood count negatively an acute inflammatory condition.

and stimulation of peristalsis forced the ovum into the peritoneal cavity. There also marked peritoneal irritation and raised temperature.

(13) Mrs. S. 35. No enquiry as to regularity or previous pregnancies. Six weeks after last period, fell off a chair, and was immediately seized with intense pain in the R. iliac fossa, and fainted. Slight intermittent pain on R. side for next three weeks, when it again came on severely and lasted more or less till admission 6 weeks later. One day's discharge of very dark blood with second attack a week before admission and also on day before admission.

Patient reached hospital very pale and in critical condition. Pulse 136, Temperature 99. Lower abdomen very tender and rigid.

P.V. Pulsation in both fornices. Such great tenderness above and P.V. that nothing definite could be made out.

Operation. Omentum down to tube. Tube empty. Large quantity of blood clot adherent to its fibrinated end. Much free blood and clot in peritoneal cavity. No foetus found. R. tube and ovary removed. Uneventful recovery, except that temperature and pulse kept up for a fortnight.

Remarks. In this case again the abortion was probably incomplete until the second bout of pain at any rate, when perhaps the further haemorrhage

and stimulation of peristalsis forced the ovum into the peritoneal cavity. Here also marked peritoneal irritation and raised temperature.

14. Mrs K. Last pregnancy 4 years ago. No evidence of salpingitis. Regular, but amount lost has become less and less during last 6 months, with progressive symptoms of anaemia. The last two periods were scanty and pale and only lasted for one day. 3 days after the last period, was suddenly doubled up by a violent "gripping, tearing" pain in the R. iliac fossa. She was washing at the time. One hour later pain returned so severely that she fainted. Did not vomit. Pain as if a hand tightened and, after a minute, relaxed its grip upon the intestines came every now and then during next 3 days. Then passed off. Alternate shiverings and hot perspirations. With the onset of this attack, appeared pain on micturition, lasting 3 days. Also constant bearing-down feeling in rectum. Pain etc. having passed off, patient felt well for a fortnight. Then loss of pale red blood for 1 day, and 3 days later a third attack of violent pain in the R. iliac fossa and rectum, lasting 6 hours, which caused her to faint. Pain on micturition returned. Dismisses the idea of pregnancy as absurd.

On admission, a month after onset, patient was anaemic but not blanched.

Abdomen. Tenderness over 11th and 12th Dorsal segments on both sides. No points of special hyperaesthesia.

P.V. Soft tender uterus just to R. of mid-line. Behind and to the L. of it was a soft, very tender, boggy mass. No pulsation felt.

Operation. L. tube twisted back into pouch of Douglas. In the pouch of Douglas and attached to the fimbriated end of the L. tube was a blood clot size of a closed fist. No sign of a foetus. Pregnancy had been in outer third of tube, which had contracted down and was empty.

Remarks. Here, as in other cases, the expulsion of the ovum was probably not completed at the first attack. The history would suggest that it, or some blood clot, had remained in the tube till the third attack of pain, and had then been forced out.

(15) Mrs O. 36. Last pregnancy 12 years before. No evidence of salpingitis. Regular. Last period exactly one month ago. Period started as usual one morning, and in the evening, after working all day, patient was seized with sudden acute pain in the R. iliac fossa. Felt faint. Did not vomit. Pain lasted with remissions through night; less severe next morning. Period, bright

coloured as usual, stopped with onset of pain.

On admission, day after onset, patient was blanched, facies anxious. Shallow quick respirations - vigorously working alae nasi. Temperature 101. Rapid small pulse. All appearances of internal haemorrhage.

Abdomen. Some distention. Restricted movement over whole lower abdomen, rigid and markedly tender, especially on R. side. Skin hyperaesthesia clearly defined over 11th R. dorsal segment.

P.V. A soft, very tender, swelling felt in pouch of Douglas and extends both to R. and L. fornix - chiefly to R.

Operation. 24 hours after onset. Large quantity of blood and clot free in peritoneal cavity, much in pelvis. R. tube brought up. Bright blood found to be trickling fairly smartly from the fimbriated extremity. Chorionic site was on the expanded fimbriated end of the tube. A small foetus was found in the blood clot in the pouch of Douglas, about 1 month old. R. tube and ovary removed. The following day a complete decidual cast of the uterus was passed P.V. Patient lost a good deal of bright blood till this happened.

Remarks. This case was slightly more difficult of diagnosis because of the complete absence of amenorrhoea. The sudden one-sided onset, the very

tender, bulging in the pouch of Douglas and the rigid tender abdomen, the raised temperature and pulse, might have conceivably been associated with a ruptured pyosalpinx, an acutely twisted ovarian cyst, a fulminating appendicitis with rupture, and so on. The manifest symptoms of internal haemorrhage, however, decided the diagnosis. The abortion appeared to be complete. The ovum had become implanted on the fimbriated end of the tube, and the small contractile power of the very end may have accounted for the continued and rather severe loss of blood. In this case again the temperature was raised (101). An interesting phenomenon was the hyperaesthesia of the skin of the dorsal segment which also supplies the R. tube. It was very definite in its boundaries and stopped at the mid-line. This is the only case of ectopic gestation in which I have observed it.

On admission. Looks ill - not blanched. Temperature 100.

Abdomen. No distention, no swelling felt. Tenderness in both iliac fossae, more so on the R. side.

F.V. Cervix normal in consistency. Uterus slightly enlarged. Behind and rather to the left of uterus is a soft, tender mass. Some tenderness in the R. fossa. No special signs.

(16) Mrs C. 42. Last pregnancy 18 years ago. Evidence of salpingitis. Regular. Exactly a month after last period, on day when it was again expected, patient was taken with a sudden very severe pain in the L. iliac fossa, shooting through to the sacral region, which doubled her up. No vomiting or fainting. Went to bed. Severe pain passed off after 2-3 hours, leaving a lesser sore pain for 3 days. Then another similar and severe attack lasting several hours. Fainted and vomited. No more bad attacks since, but for next 4 weeks up to admission to hospital was troubled with pain in the R. iliac fossa. After the 2nd severe attack a dark brown vaginal discharge started, containing clots, and continued up to time of operation - one month later. No shreds noticed in it. Pain on micturition and frequency since onset. No trouble when bowels move. On admission. Looks ill - not blanched. Temperature 100.

Abdomen. No distention, no swelling felt. Tenderness in both iliac fossæ, more so on the R. side.

P.V. Cervix normal in consistency. Uterus slightly enlarged. Behind and rather to R. of uterus is a soft, tender mass. Some resistance and tenderness in L. fornix. No special pulsation.

Per rectum. Apparently a good deal of pelvic exudation around either tube, and somewhat of a groove is felt between them.

There was a strong history of salpingitis, and although ectopic gestation was considered, it was thought that the pain, discharge and pelvic exudation might be due to ^{salpingitis} that cause, especially as the exudation was bilateral, and there was tenderness in both iliac fossae. The patient was therefore kept in bed for 7 weeks, and was given douches, Potassium Iodide, etc. The exudation having been largely absorbed, operation was performed.

The R. tube was found to be enlarged and thickened and the seat of chronic salpingitis. It was removed, leaving half the R. ovary. The L. tube and ovary were curled up behind uterus, to which they were adherent. The tube was the size of a small orange and contained a rounded mass which proved to be blood clot with a one month old foetus in its centre. L. Tube and ovary were removed. Anterior fixation of the uterus was performed and the abdomen closed. Uninterrupted recovery.

Remarks. There are several points of interest in this case. First of all the rupture occurred at the right time for the menstrual period, without any previous amenorrhoea. The foetus corresponded in size to one month's growth. The pain in both the

bad attacks was referred to the L. side, the side of the ectopic gestation. During the month which elapsed between the 2nd attack and admission to hospital (one month) pain of not so severe a nature was referred to the R. iliac fossa, and the temperature ranged from 100-101 most of the time. This, along with the double-sided pelvic exudation which she had on admission, make it highly probable that during that month she was also suffering from an attack of more or less acute salpingitis, as well as having the ectopic gestation. Possibly the presence of the latter was a factor in waking up a more or less dormant salpingitis. In this case we have another instance of the initial violent pain being referred to the sacral region.

P.V. Elastic tender swelling in R. anterior fornix. Harder swelling apparently uterus, pushed back in pouch of Douglas. Marked pulsation.

Operation:- Mass of blood clot size of large orange between layers of broad ligament, taking a somewhat anterior position. No fetus found.

Remarks. Long history of amenorrhoea was not corroborated by age of ovum, for the latter may have been not more than 2 - 3 months old at best. This case has been included as a probable case of tubal gestation, although there is no absolute evidence to prove it. Possibly the ovum was fertilized within the tube in the early months by small retained

haemorrhages not sufficient to cause pain, e.g. as in Case 3, and that the severe pain at 6 months

CASES OF RUPTURE INTO THE BROAD LIGAMENT .

(17) Mrs. M. 38. Last pregnancy 3 years ago. After 6 months amenorrhoea was suddenly taken with a severe pain across lower abdomen, not one side more than the other. Did not faint. After immediate pain had eased off, a severe aching pain continued for next three weeks till admission to hospital. During same period pain and difficulty in starting micturition, with a considerable daily loss of bright blood which persisted up to time of admission.

Abdomen. Tender swelling, regular in outline, reaching up to half way between pubes and umbilicus.

P.V. Elastic tender swelling in R. anterior fornix. Harder swelling apparently uterus, pushed back in pouch of Douglas. Marked pulsation.

Operation:- Mass of blood clot size of large orange between layers of broad ligament, taking a somewhat anterior position. No foetus found.

Remarks. Long history of amenorrhoea was not corroborated by age of ovum, for the latter must have been not more than 2 - 3 months old at most. This case has been included as a probable one of tubal gestation, although there is no absolute evidence to prove it. Possibly the ovum was destroyed within the tube in the early months by small repeated

haemorrhages not sufficient to cause pain, e.g. as in Case 8, and that the severe pain at 6 months was due to the later rupture of a blood vessel in the wall of the tube, or of a blood sinus, causing bursting into broad ligament.

(18) Mrs M. 40. No history as to last pregnancy, or as to evidence of salpingitis. Regular. After 2 months amenorrhoea, suddenly taken with severe griping pain in L. iliac fossa. Pain persisted off and on during the three weeks which elapsed before admission, and there were three more attacks as at onset. Each doubled her up but she did not faint or vomit. No loss of blood P.V.

On admission. No special pallor. Quiet pulse. Temperature 99. Lower abdomen is tender, especially in L. iliac fossa. No tumour felt. Some slight general distention.

P.V. Very tender in posterior and R. lateral fornices, and because of this a satisfactory bimanual examination was not possible without an anaesthetic. When cervix was pushed over to the R., putting L. broad ligament on the stretch, it caused exquisite pain.

Patient was kept under observation for 5 days. On 2nd day had severe pain in L. iliac fossa, and following day began to lose blood P.V. - at first

slot, were incised. It proved to be full of blood dark, and later brighter. From 2nd day, till operation on 5th, pain in L. iliac fossa has been continuous. The pulse hardly varied, but the temperature was raised and on the 5th day was 102.4. On this day there was a different state of affairs. There was a good deal of distention below umbilicus, with slight pattern of small intestine working round a point of greatest tenderness 2 inches above the middle of Poupart's ligament on the L. side, as if coils of bowel were adherent to some focus, either of blood clot or localised inflammation. From Poupart's ligament to about the level of the umbilicus on the L. side is a soft, boggy, ill-defined, tender swelling.

P.V. Marked boggy, bulging swelling in pouch of Douglas, behind cervix, exceedingly tender. Pulsation well marked in anterior fornix. Just as patient was going up for operation she passed a complete decidual cast.

Operation:- On opening the abdomen just to the L. of the mid line, the first thing encountered was the upper part of the rectum, pushed forward by a retro-peritoneal cystic mass, so that it almost reached the anterior abdominal wall. The peritoneum covering this cyst, and its wall of laminated blood

clot, were incised. It proved to be full of blood and blood clot, the result of a rupture of the tube between the two layers of the broad ligament. The latter were widely separated up. The blood had made its way downwards to the base of the broad ligament, outwards to the L. lateral wall of the pelvis, inwards to the uterus, burrowing behind it and pushing it forwards and to the R. It had also made its way backwards behind the rectum, pushing it forwards in the way described, and had dissected upwards behind the posterior parietal peritoneum to reach 3 inches above the brim of the pelvis. The blood clot was cleared out of the space. In the middle of this retro-peritoneal space coming from the uterus, its whole length and fimbriated end lying free in the space, and not connected with peritoneum in any way, was the Fallopian tube. It was ligatured and removed. Its walls were thickened and it was empty. Its fimbriated end was patent. No site of rupture could be found. The cavity was plugged with gauze and partially closed with cat-gut, and the abdominal wall closed over it, except where gauze came out. Drained for 3 days. Wound healed in 2 weeks. Went home after 5 weeks. No foetus was found. On microscopic examination of the tube no decidual reaction was found and no trace of chorionic villi. Unfortunately sections were only made from two parts of

118
the tube and not in serial section, so that the presence of chorionic villi may have been missed.

Remarks. This is a very interesting case. It illustrated in the first place how readily secondary haemorrhages may take place after the first severe one. In this case possibly actual rupture of the tube into the broad ligament did not take place till one of the later attacks of pain.

The temperature too was raised, and the more so, as the effusion of blood increased reaching 102.4. The irritation and displacement of the rectum probably accounted for the distention and "patterns" of the bowel. There was no diarrhoea.

The chief point of interest, however, is that the entire length of the tube was lying quite free and behind the peritoneum. One can understand that the effused blood might strip the peritoneum off the anterior and posterior, and upper surfaces of the tube during the greater part of its course, especially in the central part where it is loosely attached. When one follows the stripping process outwards to the fimbriated extremity, it arrives at a series of points in the circumference of the fimbriae where the peritoneum ends, and the mucous membrane of the tube begins. If therefore the fimbriated end were conceived as tearing itself free at these points, one would have to imagine a hole

left in just that part of the peritoneum, and even if such a hole healed, one would expect some of the blood which had caused its formation to escape into the peritoneal cavity. No free blood however was found at operation. It might have been absorbed. A possible explanation may be that the pregnancy was a tubo-ovarian one which had burst backwards behind the peritoneum. This would account for a continuity of the peritoneum covering the tube and that reflected on to the side wall of the pelvis, ^{from old adhesions.} and would also explain the absence of chorionic villi in the tube. Unfortunately the position of the ovary was not noted at the operation, but speaking from memory, I think it must have been flattened out on the wall of the cyst, for the latter was large and its anterior surface covered by posterior parietal peritoneum, was absolutely smooth, except where the rectum passed downwards behind it.

(19) Mrs P. 26. Last pregnancy 5 years ago. No evidence of salpingitis. Regular. After 5 weeks amenorrhea, was suddenly seized, while eating her dinner, with intense pain in the R. lower abdomen, which doubled her up and brought her to the ground. Vomited immediately after, but did not faint. Pain continued severe for 2 days, and then eased off, leaving a dull aching, which continued until admission to hospital 3 weeks after onset. There were

two further paroxysms, 3 and 5 days after the first, each lasting half an hour. Dark brown discharge, P.V. started 2 weeks after first attack and continued till admission. Pain during micturition and defaecation for first week. None after that.

On admission patient was a good colour and had a good pulse. Temperature 100.4.

Abdomen. Soft indefinite swelling felt above pubes, a little to the right. Very tender over this area. Not elsewhere.

P.V. Cervix soft and patulous. Free vaginal secretion. Soft boggy mass behind cervix, extending into R. fornix, apparently about the size of an orange. Exquisitely tender. Pulsation marked.

Operation. Mass found consisting of an ectopic gestation which had ruptured into the R. broad ligament, dissecting up the posterior layer as far as the entrance of small intestine into caecum. Also a little blood clot free in the peritoneal cavity matting uterus and L. broad ligament to rectum. Whole mass scooped out. Anterior layer of broad ligament with ovarian vessels tube and ovary transfixed and ligatured close to pelvic side wall and also to attachment at side wall of uterus. Gap in posterior parietal peritoneum closed with catgut, and abdominal wound sewn up. No foetus could be

difficult to define its outline, but is rounded above.

The left tubal point is tender on pressure. No tender- found in clct. Pregnancy had apparently taken place about the middle, or slightly to the inside of the middle.

Remarks:- The only thing that calls for remark in this case is the repeated paroxysms of pain. It is not possible to say whether the tube ruptured into the broad ligament at the first paroxysm, or at one of the later ones. It may have ruptured into the tube first and the broad ligament later. The rupture was in the isthmic portion of the tube; about where it becomes the ampullary portion. It will be noticed that the effused blood took a backward direction. The placenta was scraped away from

(20) Mrs. S. 40. Patient was confined two months before admission of a child (transverse) at 7 months. At the birth of the child the doctor remarked on the presence of another swelling in the lower abdomen, and after watching it for two months he sent her up to hospital. During these two months patient had "menstruated" twice, the first time going for 7 days and the second for 2 weeks. No pain. In the lower abdomen, rising from the pelvis and extending to 1 inch below the level of the umbilicus, is a boggy, non-tender tumour. Rather difficult to define its outline, but is rounded above.

Remarks:- Unfortunately the history of the
The left tubal point is tender on pressure. No tender-
ness elsewhere.

P.V. The cervix is soft and lax like that of
a full time pregnancy, and does not move with the
tumour. The body of the uterus cannot be made out.
In the anterior fornix and passing rather to the L.
side is felt the lower surface of the tumour felt
above in the abdomen. The swelling was thought to
be an ovarian cyst.

Operation. Pregnancy in L. broad ligament.
During the examination of the tumour it burst, and
a foetus which appeared to be 6 - 7 months old was
removed from the sac. It had evidently been dead
for some time. The placenta was scraped away from
the lower part of the cavity, and came away easily.
The sac also contained some brownish, dirty-looking
fluid. The wall of the sac was thin, and had con-
tracted adhesions with neighbouring organs, viz.
to the sigmoid behind, and several coils of small
intestine above and to the right. The edges of the
opening in the sac were sewn to the edge of the wound
in its lower half and the cavity packed. Upper
half of wound closed.

For a fortnight the temperature ranged between
98-100, the cavity slowly filled up and patient
made a complete recovery.

Remarks:- Unfortunately the history of the pregnancy was not recorded, and I cannot recall it. It is impossible therefore to say whether there were any symptoms to suggest the condition of affairs. The transverse presentation of the intra-uterine child was no doubt due to the presence of the extra-uterine foetus. Probably both foetuses were of the same age, and the extra-uterine one died at the birth of the other, for no movements were felt after the labour, and the appearance of the foetus and the ease with which the placenta stripped, suggested that death had taken place some time before. The sac in this case had enlarged neither anteriorly nor posteriorly, but more or less centrally, like a par-ovarian cyst.

RUPTURE INTO THE ABDOMINAL CAVITY.

(21) Mrs O'H. 23. No pregnancies. Married 16 months. No evidence of salpingitis. Regular. After 3 months amenorrhœa, patient noticed a small "shew"; light red in colour and the same two days later. With each was slight griping pain in the lower abdomen, not excessive, but troublesome when she moved about and extended the thighs. Five days later another "shew" and sudden severe hypogastric pain, which made her feel sick and faint. After a

While she managed to walk home from her work, and went to bed. For next week she went to work, troubled rather with small losses of bright red blood. At end of this week, i.e. 2 weeks since first bad pain, she went to a doctor. The examination P.V. brought on a sudden violent pain which doubled her up and made her turn faint. Pain went off and returned next evening. Never more one side than the other. Noticed abdomen rather more swollen than usual since examination P.V. Admitted to hospital 3 days after this examination.

On admission. Not blanched, slightly pale. No milk in breasts, no areola, no swelling.

Abdomen. Some fullness below umbilicus, more marked on R. side than L., with corresponding area of restriction of movement, rigidity, tenderness and impaired percussion note.

P.V. Body of uterus and cervix are pressed upwards and forwards, just behind symphysis pubis. Behind cervix, in pouch of Douglas, and extending into both lateral fornices, but more particularly to the L., is a soft, boggy, tender swelling. Very slight pulsation.

Operation:- Omentum and intestines matted over mass size of foetal head in pelvis. This mass consists of a huge haematoma, formed from rupture of the R. tube on its upper surface. No record of

which part of tube was pregnant. No foetus found. Adhesions separated. R. tube and blood clot removed. Uninterrupted recovery.

Remarks:- The initial rupture of the tube did not probably involve any large vessels, for the amount of blood which escaped was apparently small, and was so slowly poured out that strong adhesions had time to form between the tube and the organs, e.g. intestines, omentum, etc., around. The second paroxysm of pain came on with the vaginal examination, which was undoubtedly responsible for a further haemorrhage into the cavity localised by adhesions. An interesting point in the history was that there had been undoubted warnings in the shape of small bright losses, P.V., and slight grumbling, griping pains, before the first catastrophe occurred. These together with two months amenorrhoea in a woman always regular, would naturally suggest an oncoming abortion, but might possibly have led to a correct diagnosis before rupture.

(22) Mrs. L. 30. Last and only pregnancy 18 months ago, and this was a R-sided ectopic gestation, which was removed. No evidence of salpingitis. Regular. Two weeks after last period, which was normal, patient was seized with severe griping pain,

across lower abdomen, and there has been more or less pain there ever since. No history of discharge P.V.

Admitted to hospital 5 weeks after onset.

Abdomen shows nothing noteworthy.

P.V. Uterus soft and rather larger than normal.

Soft mass in anterior fornix.

Operation:- L. tube swollen to size of small orange, ruptured on superior surface, from which a foetus had escaped and was floating in peritoneal cavity, attached to the inside of the tubal sac by its umbilical cord. Ovary and tube removed.

Remarks:- This is a case of especial interest, in that the woman's first and second pregnancies were both extra-uterine. It also illustrates the fact that ectopic gestation is not always accompanied by amenorrhoea in the first month or two. I did not record the size of the foetus, but if my recollection serves, it was about 2 months. It is quite possible that the manipulations during operation forced it out of the tube, for there was no free blood in the peritoneal cavity at the time.

(23) Mrs. C. 33. Last pregnancy 18 months ago. History suggests salpingitis. Regular. Last normal period 3½ months ago. Period following

was urgent in the extreme. She was operated on at that, although at right time, was much smaller than usual - 2 days instead of 7. Since then amenorrhoea. of fluid and clotted blood. The rupture was in the For 3 months before sudden onset, patient had been outer half of the R. tube, on its upper and posterior having sore aching pains, with twinges every now and then, in the R. iliac fossa. Describes them as "like inflammation pains". She thought she was pregnant in the ordinary way, for there was constant morning sickness and swelling of the breasts. Then one day, while at her work, she was suddenly seized with an intense, agonising, "bearing-down" feeling in the rectum, and soon after in the hypogastrium, not one side more than the other. She did not faint, but turned cold and clammy, and vomited several times. No pain on passing water or on defaecation. Was quickly removed to hospital.

On admission. Very pale. Rapid shallow breathing. Pulse 140 and feeble. Much collapse. Breasts are turgid and contain milk. Abdomen rather distended and tympanitic. Great general tenderness and somewhat rigid. Both flanks dull. An indefinite mass felt above in R. iliac fossa dull to percussion, and to the L. of this in middle line another swelling, which was taken to be the bladder, as patient had not passed water all day. This, after catheterisation, it proved to be. No vaginal examination was made, as the patient's condition

after and in the morning became dazed and "swimmy" was urgent in the extreme. She was operated on at and fainted. Her doctor diagnosed renal colic and once, 12 hours after onset. The abdomen was full gave her morphia. She was easier till the third of fluid and clotted blood. The rupture was in the day when another attack of pain, vomiting and fainting occurred. From then up till admission to surface. No foetus was discovered. The R. tube and hospital two weeks later, patient has had no more ovary were removed. Temperature kept up to 100 or so severe pain, but whole lower abdomen has been sore for a week, then became normal. Patient slowly and tender. She kept in bed all the time after recovered.

Remarks. This illustrates the rapid bleeding defaecation has been painful since initial pain, and extreme urgency of some cases of rupture of the tube. It is one of the few cases I have come across No discharge of blood or fleshy bits P.V. Did not think she was pregnant. in which there was morning sickness, and in which On admission. Not markedly anemic but is the woman thought herself that she was pregnant. The an Italian and swarthy. Pulse fair. Temperature secretion of the breasts, too, was more than ordi- slightly raised. No milk in breasts. No areola. narily free. The considerable irritation of the Abdomen shows moderate general distention, with peritoneum by free blood was again very evident. coils of bowel standing out slightly. Tender and

Another symptom was of interest, viz. the rather rigid over whole abdomen below umbilicus, intense and painful feeling of bearing down in the most marked in R. iliac fossa. An irregular mass, rectum which signalled the rupture. without any definite edge, is felt extending from

R. (24) Mrs V. 41. Last pregnancy $3\frac{1}{2}$ years ago. No evidence of salpingitis. Regular. After $2\frac{1}{2}$ months amenorrhea was suddenly seized in the night while in bed, with a very severe pain in the R. lower abdomen, from whence it shot down the front of the R. leg to the knee. She vomited directly

after and in the morning became dazed and "swimmy" and fainted. Her doctor diagnosed renal colic and gave her morphia. She was easier till the third day, when another attack of pain, vomiting and fainting occurred. From then up till admission to hospital two weeks later, patient has had no more severe pain, but whole lower abdomen has been sore and tender. She kept in bed all the time after onset. A little pain on starting micturition and defaecation has been painful since initial pain. No discharge of blood or fleshy bits P.V. Did not think she was pregnant.

On admission. Not markedly anaemic, but is an Italian and swarthy. Pulse fair. Temperature slightly raised. No milk in breasts. No areola. Abdomen shews moderate general distention, with coils of bowel standing out slightly. Tender and rather rigid over whole abdomen below umbilicus, most marked in R. iliac fossa. An irregular mass, without any definite edge, is felt extending from R. iliac fossa, over to the L, and reaching roughly half way between symphysis and umbilicus. Doughy and tender. Flanks resonant.

P.V. Vaginal walls soft and moist. Uterus high up and enlarged to size of one month's pregnancy. In pouch of Douglas, and extending into R. fornix is a

boggy, soft, tender, ill-definable mass. Pulsation marked on R. side.

Operation. Peritoneal cavity full of blood and clot. R. tube ruptured. Unfortunately no note was made of site of pregnancy or rupture. No foetus found. R. tube and ovary removed. Slow recovery.

Remarks. In this case one can be pretty sure, from the symptoms of faintness and swimminess coming on a few hours after onset, that the tube ruptured at the very beginning. She probably owes her life to the fact that she stayed in bed. The symptom of pain passing down the front of the leg is interesting. On two or three occasions patients have complained of pain on extending the thigh, i.e. putting the psoas fascia on the stretch, and possibly both of these symptoms are due to irritation^{of}, or pressure upon the anterior crural or some other nerve of the lumbar plexus in close proximity to the outer end of the broad ligament.

(25) Mrs M. 27. Last pregnancy 20 months ago. No evidence of salpingitis. Regular. After two months amenorrhea she was suddenly, when at work, doubled up by a very severe pain in lower abdomen. She fainted soon afterwards and vomited several times. She took to bed. On the following day passed some very dark blood P.V. Since going

to bed has had pains all over body, and has felt feverish and thirsty. Thought she had influenza. Did not think she was pregnant.

On admission. Two days after onset, patient looked ill, pale and worn-looking. She had been nursing a sick child for some time past. Poor pulse 110. Temperature 100.6.

Abdomen. Distended. Coils of bowel shewing well marked pattern. Moves fairly well but marked general tenderness and moderate rigidity on palpation.

P.V. Vagina lax and moist. Uterus not palpable owing to tenderness of abdomen. Boggy mass in posterior and L. fornix.

Operation. Abdomen full of blood and clot. Portion of L. tube distended about centre. Ruptured on superior surface. Foetus, apparently about three months old, was floating free in peritoneal cavity, attached by the umbilical cord to the cavity within the tube, which was lined with amnion and contained a well-defined placenta. L. tube removed. Slow recovery.

Remarks. The foetus was a month older than period of amenorrhoea would suggest. The placenta was fortunately lying on inferior surface of tube and so escaped tearing at time of rupture. Otherwise typical case.