

THESIS

on

PSEUDOMYXOMA PERITONEI.

(Werth).



Roland Thomas Graves Aickin,  
M.B.Ch.B.  
(New Zealand).

I N D E X (1)

Pages.

INTRODUCTION..... 4-5.

HISTORY ..... 7-10.

TERMINOLOGY ..... 12-13.

ETIOLOGY ..... 15-23.

PATHOLOGY ..... 25-31.

(Description of Slides with micro-  
(photographs.

( Mary Fletcher ..... 33-48.

( Emma Chatwin ..... 50-56.

(Histological Summary of known  
(Authors..... 58-61.

(Deductions & Abstracts from the  
(Histology of:-

HISTOLOGY ( Werth ..... 63-68

( Donat (including Animal Ex-  
(periment..... 70-71.

( Histology of Rabbit's  
(Peritoneum..... 72.

( Westphalen Case No.1 ..... 74-77.

( Westphalen Case No.2 ..... 78-82.

( Strassmann ..... 84-85.

( Greenfield -(Histology of Cyst  
(Wall ..... 87-88.

( Fraenkel ..... 90.

(General Chemistry of Pseudomyxoma  
(Peritonei, with Analysis of Gelati-  
(nous Matter from Mary Fletcher's  
(Case ..... 92-93.

CHEMISTRY (

(Deductions & Abstracts from Donat's  
(Account of the Chemistry of Pseudo-  
(myxoma Peritonei ..... 95-97.

I N D E X. (2)

Pages.

<u>SYMPTOMATOLOGY</u> .....	99.
<u>DIAGNOSIS</u> .....	101-102.
<u>PROGNOSIS</u> .....	104.
<u>TREATMENT</u> .....	106.
(Mary Fletcher .....	108-136.
(Emma Chatwin .....	133-155.
(Werth's Own Case .....	157-160.
Cases Recorded by Werth;-	
<u>Pean</u> No.1 .....	161-163.
<u>Pean</u> No.2 .....	164-165.
<u>Mennig</u> .....	166-169.
<u>Beinlich</u> No.1 .....	170-172.
<u>Beinlich</u> No.2.....	173-175.
<u>CASES:-</u>	
<u>Atlee</u> .....	176.
<u>Schroder</u> .....	177.
<u>Netzel</u> .....	178-179.
<u>Strassmann</u> .....	181-183.
<u>Donat</u> .....	185-194.
<u>Westphalen</u> No.1.....	196-198.
<u>Westphalen</u> No.2.....	199-202.
<u>Macdonald</u> No.1 .....	204-206.
<u>Macdonald</u> No.2 .....	207-210.
<u>Mond</u> .....	212-214.
<u>Toth</u> .....	216.
<u>Backer</u> .....	218.
<u>Reuder</u> .....	220-221.

I N D E X ( 3 ) .

	<u>Pages.</u>
<u>CASES:-</u> (Lewitzki .....	223.
<u>Contd.</u> (Pawlik .....	225-226.
<u>GENERAL DEDUCTIONS</u> .....	228-234.
<u>CONCLUSION</u> .....	235.
<u>BIBLIOGRAPHY</u> .....	237-240.

---

(Numbers in Brackets refer to Bibliography)  
e.g. Werth (1); Strassmann (30) etc.



PSEUDOMYXOMA PERITONEI.

I N T R O D U C T I O N .

I N T R O D U C T I O N .

The subject of Ovarian Tumours and their effects is an exceedingly interesting and important one, especially in view of the efforts that are now being made to elucidate their origin and nature.

During my term of office as Resident and Medical Attendant to the Gynaecological Wards of the Birmingham General Hospital, exceptional opportunities have occurred for the study of a large variety of such Tumours.

I have lately had the good fortune to meet with, and thoroughly investigate, a remarkable case of a very rare disease of the Peritoneum, following rupture of an Ovarian Cyst. This proved to be an undoubted example of the affection known as Pseudomyxoma Peritonei, (WERTH). (Vide Case of Mary Fletcher page 108)

I have collected all the information that is at present known regarding this condition. So very little has been written in the English language, and that only of such a fragmentary nature, that I have been compelled to rely almost entirely upon the literature contributed by German Observers. This latter circumstance has added greatly to my task, more especially on account of the great difficulty I have had in obtaining and translating the various original German writings.



I have abstracted and epitomised the whole of the literature on Pseudomyxoma Peritonei, and present it here in what I believe to be the only complete and up-to-date account of the subject, in the hope that it may throw some light on this obscure condition, and serve as a foundation for future study.

I wish to draw attention to the Histological aspect of my subject, as it is of great importance, especially mentioning in this connection the works of WERTH, WESTPHALEN, STRASSMANN, GREENFIELD, and others.

For the more complete elucidation of the Histology of Pseudomyxoma Peritonei, I have endeavoured to give in full detail the separate accounts of these authorities, adding as opportunities presented themselves, deductions and abstracts of my own, together with a complete original Histological research, carried on by myself, and illustrated by a series of Micro-photographs.

The results of my Chemical Analysis of the Cyst contents, is also of interest.

The Bibliography has involved much trouble, but is, I believe, complete.

BRIEF HISTORICAL ACCOUNT OF

PSEUDOMYXOMA PERITONEI.

BRIEF HISTORICAL ACCOUNT OF  
PSEUDOMYXOMA PERITONEI.

The general features of all recorded cases of Pseudomyxoma Peritonei are alike.

Women, for the most part over forty, are affected with rapidly growing Ovarian Cysts, which, on operation are generally found to be thin walled, and often to have ruptured. These Cysts contain tenacious jelly-like material which has escaped into the Abdominal Cavity and adhered to the Parietal and Visceral Peritoneum.

The operation often ends FATALLY usually without symptoms of Peritonitis.

ATLEE (58) in 1873 was the first to report two cases where Ovarian Cysts produced curious changes in the Peritoneum, which was found to be covered by an adherent jelly-like mass, although Baker Brown in 1869 (35), and later Coblenz (36) in 1880, drew attention to the fact that the Peritoneum sometimes became infected after the removal of papillomatous Ovarian Tumours.

BEINLICH (59) was the first German authority to recognise the condition of Pseudomyxoma Peritonei, and in 1874 described in full two cases similar to those of Atlee; mentioning a third.

Following BEINLICH'S observations MENNIG of Germany (77) was the next to refer to the condition. He reported two cases.

- (26) PEAN, the eminent French Surgeon in 1880, in the course of his practice, came across cases which he called "Tumeurs par Maladie Gelatineuse du Peritone".
- (1) WERTH is of the opinion that these cases were similar in nature to his own, and states that PEAN, during a hastily performed operation, failed to trace the important connection existing between a Peritoneal affection and disease of the Ovaries; which latter condition, according to Werth, must have existed.
- (8) NETZEL in 1882, described a case of typical Pseudomyxoma Peritonei, the chief peculiarity of which was that his patient recovered.

For our present knowledge of this disease we are undoubtedly indebted to WERTH who in 1884, gave the first classical description, and became the pioneer in the recognition of the affection now known as Pseudomyxoma Peritonei (WERTH).

His account of the Histology and general features presented in such cases remains more or less unaltered to this day.

In the following year (1885), <sup>(2)</sup> DONAT augmented WERTH'S researches by experimental inoculation. He infected the Peritoneum of a rabbit with the gelatinous material from a case of Pseudomyxoma Peritonei in the human adult, and examined specially prepared sections of the rabbit's Peritoneum, presenting a complete Histological picture of the condition. We are also

indebted to DONAT for valuable information regarding the chemistry of this important disease.

As will be explained later, this authority agrees in the main with the crucial points of WERTH'S observations, differing only in small details.

ANGUS MACDONALD (29) of Edinburgh, in the same year (1885), published a series of ten Laparotomies in which he found two conditions analogous to those described by WERTH. In these cases (see page 204), gelatinous material from ruptured Ovarian Cysts was found in the Abdominal Cavity causing secondary infection of the Peritoneum.

PROFESSOR GREENFIELD examined the Cyst Wall in the former of MacDonal'd's cases, and furnished a complete account of its histological nature (see page 87).

OLSHAUSEN (32), also in 1885, made an important contribution to the pathology of the subject, putting forward a theory regarding Metastatic new formation.

PFANNENSTIEL (6) in 1890, wrote a treatise in which he chiefly dealt with the chemistry of the condition; he upheld OLDHAUSEN'S views regarding metastatic growth.

STRASSMANN (30), in 1891 published the results of his observations, and supported the statements made by WERTH in 1884.

In the lapse of time between 1884 and 1891, several new facts had come to light, enabling STRASSMANN to

write a most concise and up-to-date account of the Histology, Pathology, and general features of Pseudomyxoma Peritonei.

WESTPHALEN ( 4.) in 1889, placed the Histology of this disease on a still firmer basis by his complete and elaborate research on two cases dealing with the microscopical appearances of the Peritoneum, and their differences in various situations.

FRAENKEL (18) in 1902, to a certain extent, deals with the Histological side of the question, but chiefly assumes the position of critic to WERTH and others. He, on the whole, inclines to OLSHAUSEN'S theory.

---

In the above remarks, I have endeavoured to follow the contributions of the earlier observers as closely as possible up to the time of WERTH (1884). From that date to the present, so many observations -- (vide Bibliography) have been made, that I have deemed it inadvisable to give more than the outstanding features, and names of the more prominent observers connected with them.

---

TERMINOLOGY.

TERMINOLOGY.

WERTH ( 1 ) gives the special name of Pseudo-myxoma Peritonaei to a deposit everywhere permeated with fine capillaries, occurring on the Peritoneum after the rupture of a thin walled glandular cyst, the gelatinous tenacious contents of which enter the Abdominal Cavity and become widely spread by peristaltic movements. A thin layer in this way is spread over the serosa of the Abdominal organs, and results in a peculiar inflammatory irritation.

The name "Pseudomyxoma Peritonei" is objected to by many Authors.

HERMAN (100) says:- "The disease is not a Tumour, but a diffuse degeneration, therefore, the word "Myxoma" is unsuitable".

DONAT ( 2 ) says:- "This name is not correct, does not meet the case, and may easily be misleading. The whole change of the serosa is really nothing else but a peritoneal irritation produced by a diffuse dissemination of an aseptic, tenacious foreign body, which afterwards leads to an organised inflammatory reaction.

To give this a surgical name, though using the prefix "Pseudo", which does not even mention the principal change, viz:- that of Inflammation, is superfluous.

It suffices therefore, to classify such



cysts, the gelatinous contents of which ultimately succeed in producing an inflammatory reaction of the Peritoneum, in the category of ruptured Ovarian Tumours, and to name the peritoneal affection thus caused, "A Foreign-body Peritonitis".

FRAENKEL (18) says:- "This is not a disease of the Peritoneum itself, and consequently has a misleading name"

LEWITZKI (23) demands another name in place of Pseudomyxoma and strongly advocates experimental research. He, however, furnishes us with no suggestion.

NETZEL (8) proposes the name "Ovarian Myxoma" for the Cyst and its gelatinous contents.

STRASSMANN (30) of all authorities, seems to have been extremely fortunate in naming this disease, for it assuredly is a form of Peritonitis. He calls it "Peritonitis Pseudomyxomatosa".

---

ETIOLOGY.

E T I O L O G Y.

Pseudomyxoma Peritonei (WERTH) is a condition caused by the peculiar reaction of the serosa to the escaped gelatinous contents of a ruptured myxomatous Ovarian Cyst.

WERTH strongly urges that this disease is "A plastic foreign-substance peritonitis", and expresses surprise that this simple view of the case should have been disregarded by so many authorities who suppose it to be a peculiar myxomatous disease of the Peritoneum, set up by the liberated cyst contents; some even hold that the loose gelatinous secretion is a product of the resulting peritonitis.

BEINLICH (59) was the first, in Germany, to publish two cases of a so-called "Myxoma Peritonei et Ovarii". Both these cases according to WERTH and contrary to the opinion expressed by the Author himself, seem to admit the "plastic foreign-body peritonitis" theory.

MENNIG (77) recognises the inflammatory element, but looks upon it as an affection, sui generis, the peculiarity of which consists in the formation of mucous exudate; he believes that the cyst contents set up a myxomatous disease of the Peritoneum. - (MENNIG'S description of a case operated upon by Esmarch (-) 1880, - See Abstract of Cases, page 166 ).

From his own, MENNIG'S, and other recorded cases, WERTH holds that this disease is not a true myxomatous disease of the Peritoneum. In this view he is supported by DONAT who says, "Werth has certainly shewn that the former supposition of a Myxomatous inflammation of the Peritoneum, was based upon an error; the case cited by me (see later, page 185), affords yet another proof".

DONAT believes that Pseudomyxoma Peritonei is simply a Peritonitis set up by the irritation of exuded cyst contents, ("Fremdkorper Peritonitis").

If the deductions from PEAN'S (26) case could only be accepted, they would show that Myxomatous degeneration of the Peritoneum may occur independently of any Ovarian disease.

WERTH will not admit this, and says that PEAN, in haste, failed to trace a connection between a disease of the Peritoneum and one of the Ovary.

That this disease is not a diffused but a localised degeneration of the Peritoneum, caused by the presence of the gelatinous exudate on the surface of the serosa, is deduced by WERTH from the following report of ATLEE'S (58) case, to which BEINLICH & MENNIG refer, and agree, in regard to its circumscribed nature:-

"Portions of gut were covered by a loose membrane, which, when torn, allowed of the free separation of individual loops. Their

"contiguous peritoneal surfaces were seemingly intact.

This is a very important statement (WERTH) for here the surface of the visceral Peritoneum, was evidently protected by membrane from irritation set up by the jelly".

With a diffuse Peritonitis, such as is observed in Tuberculous or Carcinomatous disease, a membrane of this kind could not have formed such an efficient barrier to extension of the disease.

The limiting membrane in this form of Ovarian Cyst, which, according to GOTTSCHALK (17), develops from a fine cystic differentiation within the membrana granulosa of the Graafian follicle, is characterised by its slender structure, doubtless due to rapid growth; hence there is a liability for the Cyst Wall to burst.

It is noticeable that of all published cases up to July 1882, MENNIG'S alone, showed spontaneous rupture of the tumour before operation.

A glandular myxomatous cystoma exhibiting this feature, and thereby causing secondary Pseudomyxoma Peritonei, is described by GUNZBURGER (3), of Abel's Clinical Institute:-

(Double-walled dermoid cysts were con- )  
(tained within the principal cyst. )

This case is of special interest, as such diverse opinions exist regarding the Etiology.

Very few elastic fibres were found in the Cyst Wall GUNZBURGER ( 3 ), ( Compare with GREENFIELD'S report page 87. ), whereas the normal Ovary when stained by WEIGERT'S (71) method, shows large quantities of elastic elements. Spontaneous rupture, according to GUNZBURGER, is due to this lack of elastic elements. The aperture found was the size of a small plate.

For the development of Pseudomyxoma Peritonei, rupture of the wall, followed by escape of the gelatinous cyst contents, must invariably occur.

In WERTH'S ( 1 ) case, a breach of continuity in the Cyst Wall might easily have been overlooked, owing to unavoidable tearing, and a rather free use of the scalpel. The same applies to the first of BEINLICH'S cases. In this Author's second case, no description whatever is given of the tumour.

DONAT believes that in his patient, the Cyst had already ruptured before operation, probably at the time when loss of appetite and languor were complained of.

(14) HERR TOTH mentions two successful cases, where both Ovarian Cysts had ruptured.

(9) IN HERR.BACKER'S case, the Cyst Wall was very thin and easily tearable; no fissures however, could be found. That continuous oozing through old standing perforations occurs as opposed to a sudden emptying of the Cyst contents, is suggested by the large amount of

gelatinous material usually found in the Abdominal Cavity.

The lack of definite clinical evidence of sudden rupture, also supports this view.

---

ETIOLOGICAL SUMMARY.

Three theories have been advanced regarding the origin of Pseudomyxoma Peritonei:-

1. OLSHAUSEN (35) holds that it is a metastatic new formation; a true neoplasm occurring on the Peritoneum.
2. A view, supported by MENNIG (77) and WENDELER (16) that the disease is a productive Peritonitis; the serosa under irritation producing a connective tissue growth, which ultimately undergoes mucoid degeneration.
3. The foreign-body Peritonitis theory, upheld by WERTH ( 1 ), KRETCHMAR ( - ) and STRASSMANN (30).

The changes which occur in the Peritoneum are said to be due to attempts at absorption of the gelatinous exudate which has been formed within, and escaped from an Ovarian Cyst, a certain amount of new tissue formation occurring. According to WERTH this is the result of irritation caused by dead gelatinous material in contact

with living Peritoneum, the healthy tissue of which is ultimately supplanted by a low form of granulation tissue penetrating into, and blending with the above mentioned exudate.

---

The Productive Peritonitis theory of MENNIG (77) and WENDELER (16), can be dismissed in a few words.

STRASSMANN'S (30) histological results show the falacy of this view:-

"Only remnants of the original Peritoneal Epithelium could be found in sections cut from the affected Peritoneum".

This is strongly in favour of WERTH'S statement:-

"The deposit of foreign masses is PRIMARY: the affection of the Peritoneum, SECONDARY"

Clinically we find that after removal of the Tumour and diseased serosa, a marked tendency towards recovery is shewn.

This would not happen if a true degenerative change, or a new formation PRIMARILY affected the Peritoneum.

PFANNENSTIEL ( 6 ) and FRAENKEL (18) are supporters of OLSHAUSEN'S (32) metastatic formation theory.

Two cases quoted by FRAENKEL seem to shew that the disease is not merely a question of gelatinous matter



found adhering to the Peritoneum, but that, in addition, a new growth occurs.

In one case a cystic Vermiform Appendix ruptured, and gelatinous contents congregated in the lowermost parts of the Abdominal Cavity. That a marked reaction had occurred was shown by a shaggy chorion-like growth exhibiting on section, a decided involvement of the Peritoneum.

FRAENKEL (18) from another case, admits that the majority of results support WERTH'S view, but he distinctly affirms that in the latter case, a true metastatic implantation was found on the Peritoneum covering the Descending Colon, and hence he is inclined to uphold OLSHAUSEN'S (32) theory, believing that Implantation Metastases are usually found provided a thorough search is made.

A real Metastasis was also found in WESTPHALEN'S (4) second case. He describes this as an interesting secondary discovery, which might have become the starting point of a recurrent growth, had the patient lived.

One is strongly inclined to lay most stress upon WERTH'S views, as his explanation of a foreign-body Peritonitis seems most likely. It is necessary to bear in mind, however, that Myxomatous degeneration of the Peritoneum is much more rare than the tapping or bursting of tumours, nor is it clearly understood which tumours, when ruptured, confer the tendency to

Myxomatous growth.

That Implantation Metastases have been found, cannot be doubted, yet this does not appear to be the chief factor, as OLSHAUSEN (32) and PFANNENSTIEL (6) would have us believe.

WESTPHALEN'S (4.) two cases, together with those of WERTH (1) and KRETCHMAR (-) seem to coincide with observations made on the cases of Emma Chatwin and Mary Fletcher.

Two factors appear to cause this marked Peritoneal change:-

1. The occlusion of the lymph channels by inert gelatinous matter.
2. Organised Peritonitis.

For the most favourable metastatic conditions of development, it would be necessary for freshly liberated, living epithelium cells, to find a suitable nidus on the Peritoneum. If, however, the lymph spaces are blocked, and the Peritoneal surface covered with gelatinous exudate, wandering epithelial cells are not nearly so likely to meet with a soil favourable to their further development.

If we admit that the lymph channels do actually become occluded, a certain amount of peritoneal congestion must, of necessity, follow. There is not, therefore, much difficulty in understanding either the rapid

increase in Abdominal girth, or the connective tissue proliferation revealed by the Microscope. This latter would again divert the normal peritoneal activity, and further tend to prevent fluid absorption, since the secretory function of that membrane persists even when its powers of absorption have been suspended.

In conclusion, one is persuaded that Pseudomyxoma Peritonei is primarily a foreign-body Peritonitis, set up by the irritation of escaped gelatinous cyst contents, and that Implantation Metastases often occur as secondary complications.

---

PATHOLOGY.

P A T H O L O G Y.

The Pathology of Pseudomyxoma Peritonei was first elucidated by WERTH, who demonstrated that in all cases previously reported, the outpoured Cyst contents remained passive, and became attached to the Peritoneum by inflammatory processes in the latter.

DONAT ( 2 ) verified the statement of WERTH ( 1 ), and suggested the term "Foreign-body Peritonitis". But not all cases reported were of a similar character. In these the jelly-like coating of the Peritoneum was not the only pathological condition found, but Cysts similar to the original one had developed in various parts of the Peritoneal Cavity.

THORNTON'S (62) case was the first, then followed others by COLRAT (76), BAUMGARTEN (37) - three cases; OLSHAUSEN (32) - two cases; SCHLEGTENDAL (64); NETZEL (8 ), and RUNGE (21).

The behaviour of the outpoured Cyst-contents constitutes the chief distinction between the two classes of cases. In the first class the contents remain passive; in the second they are active, - epithelial elements become fixed in the Peritoneum and multiply, forming the new Cysts.

OLSHAUSEN'S (32) case No.1 is very interesting in this

connection. Epithelium was evidently transplanted, but did not succeed in forming cystic growths; it covered fibrous septa arising from the Peritoneum, and by secreting profusely, filled the Abdominal Cavity with gelatinous contents. This case occupies a position between the two classes.

The definite separation of true transplantation on the one hand, and peritoneal reaction against outpoured Cyst-contents (Pseudomyxoma - WERTH) on the other, is not referred to in the literature on the subject. It is an advance in the Pathology of the subject to keep such distinction clear.

On operation or Post Mortem, gelatinous matter is found in the Abdominal Cavity occurring free, or in thick semi-transparent layers on the inner aspect of the Anterior Abdominal Wall, or clinging tenaciously to the Intestines.

These tough and firmly fixed masses are permeated by connective tissue, and fine vessels, with small haemorrhagic dots often scattered between.

Where the masses occur in thick layers, limiting membranes form partitions, giving the whole a honey-combed appearance.

Occasionally the gelatinous material gives rise to polypoid formations enclosed in a web-like skin.

Some authorities would like to classify the Ovarian Cyst, the contents of which cause this Pseudomyxomatous change of the Peritoneum, as a special form of tumour, viz:- "Myxomatous Glandular Cystoma".

SCHRODER (7.) says that this condition is more infectious to the Peritoneum than even the Perforating Papilloma. He calls the affection "Cystoma Myxomatosum", and describes it as furnishing large masses of slimy webbing-like substance, emanating from the tumour and from the diseased Peritoneum.

VIRCHOW (61) appears to agree with the term "Peritonitis Myxomatosa", for, in a report of two cases of Myxoma Ovarii et Peritonei, by BEINLICH (59), the following statement is made:-

"VIRCHOW, in his discourse, spoke of the preparations as Myxomatous Degeneration of the Peritoneum, and if the Professor were rightly understood, he said it was "Peritonitis Myxomatosa Chronica".

In the other cases the diagnosis was "Peritonitis Gelatinosa".

Such a Peritonitis seems to have first been established by French Authors, for PEAN (26) in his "Tumeurs de l'Abdomen" gives this affection a special chapter where he calls it "Maladie gelatineuse du Peritoine". He quotes an observation made by VIDAL under the name of "Peritonite Colloide" but

unfortunately gives neither name nor date.

BARDELEBEN ( - ) who wrote the surgical works of VIDAL, does not even mention such a condition as "Peritonite Colloide".

PEAN also refers to CRUVEILHIER but this latter authority seems inclined to confound Colloid Cancer with Pseudomyxoma Peritonei.

From the general explanations as to the changes occurring in the Abdominal Cavity, comprising PEAN'S Maladie Gelatineuse, it is difficult to gather how far his views are based upon his own research. He further holds that these Peritoneal changes can occur independently of any Ovarian affection. He does not say definitely that there were no cases of true Colloid Cancer with secondary affection of the Peritoneum, amongst those on which he based his description. The insecurity of the view held by Peau regarding the Pathological nature of this disease, is proved by his conflicting statements as to its Prognosis and Treatment; for, on the one hand, the Prognosis is so grave that he holds the condition altogether unsuitable for Laparotomy; while, on the other, he believes in the prompt removal of the gelatinous matter from the Abdominal Cavity.

NETZEL ( 8 ) mentions two cases similar to his own where the Microscopic Diagnosis was Alveolar Carcinoma. One of the Patients, however, remained perfectly healthy for more than five years after the operation.



In NETZEL'S own case, as also in another seen by him in 1893, the microscopic diagnosis was not cancer.

In discussing the mucoid side of Pseudomyxomata Peritonei from the beginning, we are seriously handicapped by the obscurity relating to the origin of myxomata in general.

The existence of primary myxoma of the Ovary is doubtful. OLSHAUSEN (32) states that so far, no case has been demonstrated; COHN (33) collected 100 cases of malignant tumours of the Ovary from SCHROEDER'S clinique, and included three under the name of myxoma, without stating, however, what he meant by the term.

HIELT (70) also reported a 30-lb. myxoma of the Ovary, but the review in the Jahresbericht failed to give histological details. Myxoma of the Ovary secondary to Carcinoma, has been reported recently by GRIFFITH (95), and secondary to endothelioma by VON VELITS (34a).

Primary myxoma of the Peritoneum, though very rare, undoubtedly occurs. The oldest reported cases are by WALDEYER (54) and RITTER (55); more recent cases by EVE (63), MADELUNG (65), and LANGER (22).

TERILLON (-) collected together 16 cases, and describes a case in a male.

In BETTMANN'S report of Professor PAWLIK'S, (56) Case, he says, "that the closest study of the relations between the fibrinous and the mucoid structures on the one hand, and the mucoid and fatty on the other, fails to make the origin of mucoid tissue clear". We find the three different tissues mixed up without the slightest show of special arrangement. Part of our new growth we know to be the product of a bloody effusion. Is it not possible to refer the mucoid tissue to the same source?

It does not seem improbable that Myxomatous tissue arises directly from degeneration or other changes in plasmatic exudations or blood corpuscles. This process seems the most probable one in our case of Pseudomyxoma. Effused blood is found unchanged; here and there it has lost its normal condition, the corpuscles being no longer clearly defined. In other places degeneration has proceeded further: the corpuscles have fused together into hyaline masses which stain heavily with Eosin & Haematoxylin.

Still older parts have become perfectly homogeneous and take up no stain well. It were but another step to change into a perfectly unstainable transparent ground substance of mucoid tissue.

As to the origin of the stellate and fat cells, we have no clue.

We may believe that they are the changed leucocytes, but there is no proof in favour of such a view!

---

H I S T O L O G Y.

DESCRIPTION OF SLIDES.

(MARY FLETCHER'S CASE).

(Slides sent with Thesis)

DESCRIPTION OF SLIDE NO.(1).

(MARY FLETCHER'S CASE).

P E R I T O N E U M .

(Stained with Hæmatoxylin - Eosine).

1. Ehrlich's - Hæmatoxylin.
2. Water.
3. Dilute Lithium Carbonate Solution till blue.
4. Water.
5. Alcohol.
6. Alcoholic Eosine as contrast stain.
7. Dehydration in Absolute Alcohol.
8. Xylol.
9. Canada Balsam.

LOW POWER:--

On the Peritoneal surface there is a thin layer of a finely reticular deposit staining pink with Eosine; scattered here and there throughout its meshes are nuclei in scanty numbers staining blue with Hæmatoxylin.

This fine reticular layer lies upon the surface, generally intimately adherent, although in places it tends to become detached.

Below this superficial stratum we come upon a layer of loose areolar tissue, staining a very faint pink colour with Eosine.

In its meshes are a large number of fine blood vessels, capillaries and arterioles,

for the most part running at right angles to the surface.

Surrounding the blood vessels are groups of round cells, the nuclei of which stain blue.

The whole layer of loose areolar tissue is everywhere infiltrated with small round cells.

Externally, is seen a stratum of loose fibrous tissue containing in its meshes, bundles of non-striped muscular tissue.

(Transversalis Fascia).

This layer also shows a moderate degree of round celled infiltration; larger vessels occur here than are found in the areolar layer.

1. Reticular layer = Pseudomucin.
2. Areolar layer = Extra Peritoneal Tissue.
3. Fibrous layer = Transversalis Fascia.


( Vide Microphotograph ).

---

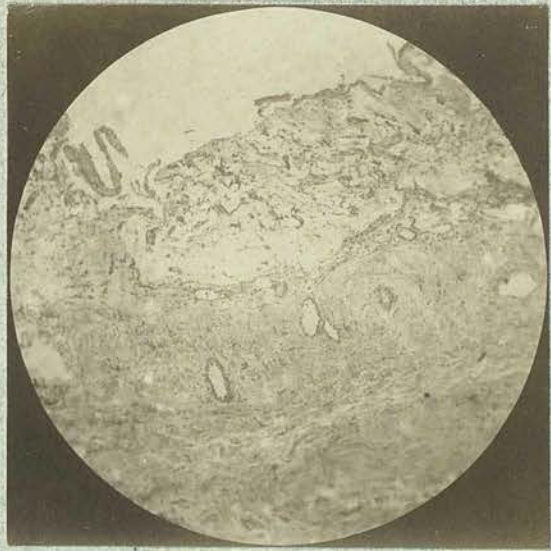
HIGH POWER:-

1. PSEUDOMUCINOUS LAYER - The surface layer does not stain homogeneously, but in a manner suggesting the presence of delicate meshworks. Within this polynuclear and uninuclear cells are seen. In many parts this fine reticular stratum has a laminated appearance, with flattened cells between the laminae.
  
  2. THE LOOSE AREOLAR LAYER - is very delicate and everywhere invaded by thin walled blood vessels the luminae of which are crowded with white blood corpuscles. Surrounding these vessels are numbers of Mononuclear and Polynuclear cells. Similar cells are scattered about the areolar tissue.
  
  3. THE LAYER OF FIBROUS TISSUE - is everywhere oedematous. In its deepest part, large blood vessels occur with numerous leucocytes in their lumina and around their walls. Non-striped muscular tissue is present in both the Fibrous and the Areolar Layer. Externally, is a layer of loose areolar fatty tissue apparently healthy. There is an entire absence of secreting Epithelial Cells.
-

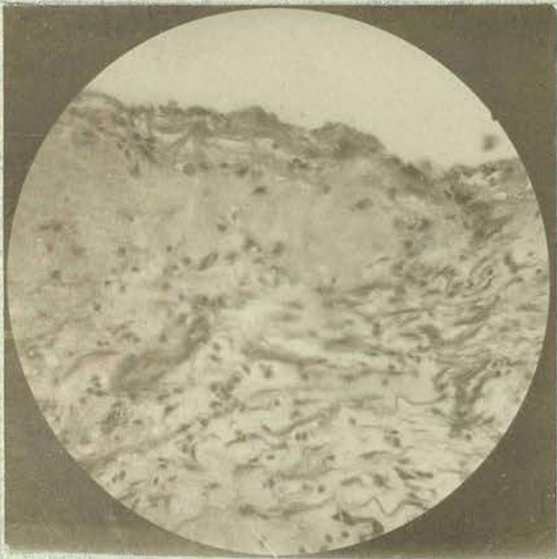
PERITONEUM. (FLETCHER).



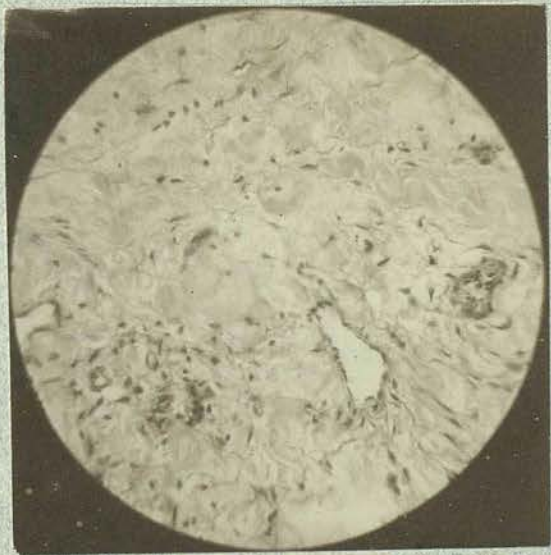Low Power.



Low Power.



High Power.



High Power.



DESCRIPTION OF SLIDE NO. (2).

(HAEMATOXYLIN - EOSINE).

OMENTUM.

LOW POWER:--

Beginning at the surface we note a moderately dense layer of a finely fibrous looking substance; this is generally of a pink colour, a faint purple occurring in places. This layer is very adherent and varies greatly in thickness. A more or less solid layer is formed though oval and rounded spaces occasionally exist with a clear lumen. There is no Cellular lining.

The whole layer even to the extreme margin is everywhere infiltrated with round cells, the nuclei of which stain blue. In certain situations evidences of recent haemorrhage exist.

A distinctly laminated structure is also occasionally observed.

The inner margin of this surface layer is very irregular indeed, owing to incursions of tongue-like masses composed of a more or less fully formed tissue.

This consists of a groundwork of areolar tissue, everywhere abounding in thin walled blood vessels and sinuses engorged with blood. Recent extravasations are not infrequent.

The whole areolar tissue is infiltrated with countless numbers of round cells.

There seems to be a rapid proliferation of cells and a formation of new blood vessels, which invade the reticular superficial layer previously described.

Deeper down the fatty tissue of the Omentum is recognisable, but is everywhere infiltrated with small round cells.

HIGH POWER:-

The superficial layer presents a fibrous appearance and has the following characters:-

It has a fine reticular structure staining red or faintly purple.

Scattered everywhere are cells for the most part polynuclear, but occasionally mononuclear. These without doubt are mostly emigrated white blood corpuscles.

Within this layer small capillaries also occur, many of which appear to have suffered destruction, for elongated cells, similar to those seen lining blood vessels are frequently seen.

In certain situations red blood corpuscles are heaped together indicating recent hæmorrhage.

The areolar layer of formed tissue is everywhere infiltrated with cells and rich in

thin walled blood vessels, for the most part engorged with blood.

Active division of cells appears to be taking place, especially is this the case with the connective tissue cells.

Young blood vessels are being formed.

Many of the blood vessels are crowded with leucocytes, which in places are observed to be migrating through the walls of the minute capillaries and sinuses.

The deeper parts are recognised as Omentum by the amount of fatty tissue present.

Here also there is increased vascularity and a considerable degree of round celled infiltration.

The red blood cells are stained yellow.

There are certain crevices of the Peritoneal surface (between folds) where no pseudomucin exists. These shew a beautiful layer of simple squamous epithelium and prove that at these points the peritoneum is quite intact and that the superficial cells are not destroyed by the reaction of the tissue beneath, such as is everywhere seen when the substance is found adhering to the surface.

N. B. One can nowhere observe any signs of secretory epithelium on the Omentum.

---

DESCRIPTION OF SLIDE NO.(3).

(THIONIN SPECIMEN).

OMENTUM.

This is a highly satisfactory section. The Pseudomucin is stained a rich purple colour and assumes the same reticular structure.

It is dense and laminated on the surface. Below it is becoming less dense.

The young connective tissue stains a deep blue colour and shows young blood vessels and a tremendous amount of small celled infiltration.

Small masses of purple Pseudomucin are shown isolated and surrounded by young connective tissue, which appears to be slowly absorbing the Pseudomyxomatous matter.

The red blood corpuscles are here stained a dull greenish colour rendering the engorgement of the vessels and extravasations plainly visible.

---

DESCRIPTION OF SLIDE NO. (4).

OMENTUM.

SECTION ( 4 ) Stained experimentally with  
Gram is of little value.

The Pseudomucin does not stain with Gram,  
nor indeed do any of the structures except  
a few of the nuclei.

---

DESCRIPTION OF SLIDE NO.(5).

OMENTUM.

SLIDE NO.(5).- is the best example I have yet obtained after repeated attempts at staining Pseudo-myxomatous Tissue by WESTPHALEN'S method.

(Page 74. ):

Pseudomucin according to this Authority should tenaciously retain Hæmatoxylin, even after the total decolorisation of the nuclei by Picric Acid.

WESTPHALEN merely makes a general statement, but omits all details.

The following was the method adopted in my case:-

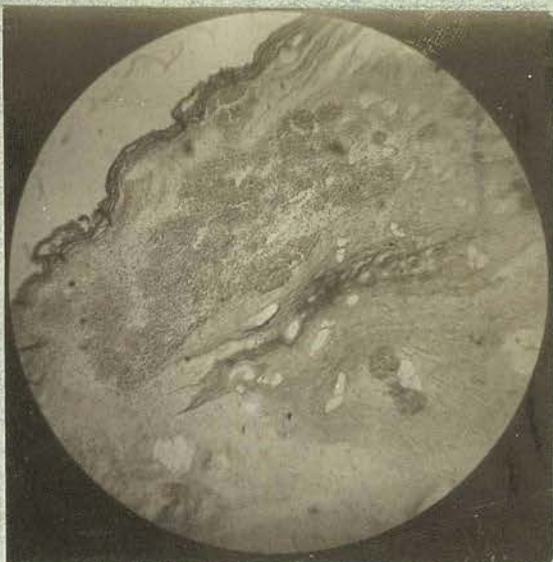1. The section stained in Hæmatoxylin till almost black.
2. Washed in watery Picric Acid.
3. Washed in Water.
4. Stained in Eosine.
5. Dehydrated - Clarified - Mounted.

The final result is disappointing, for on repeated examination of the section during the process, one is compelled to admit that no structure will resist the Picric Acid longer than the nuclei.

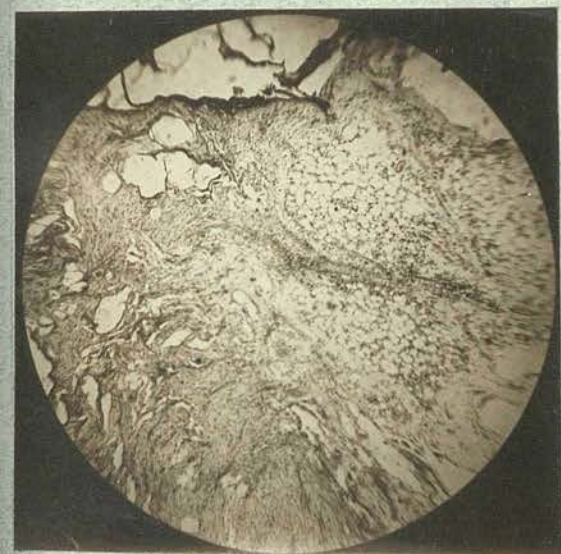---



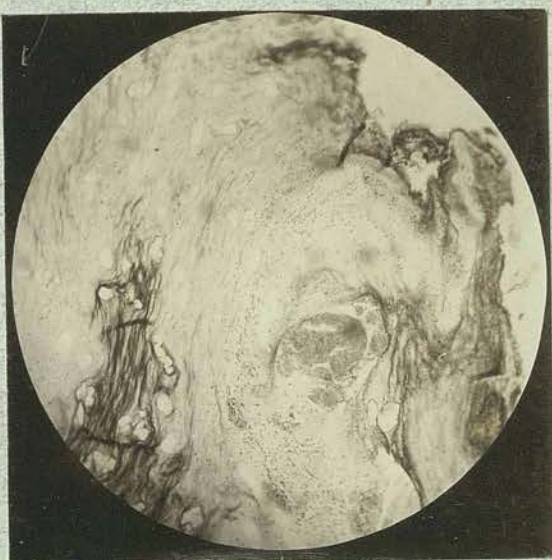Low Power.



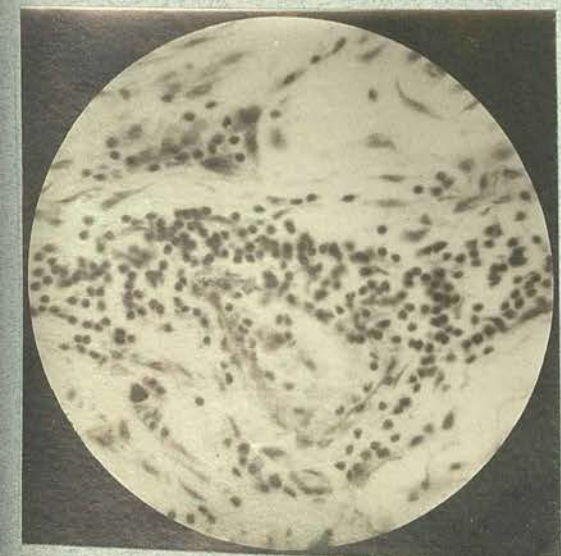
Low Power.



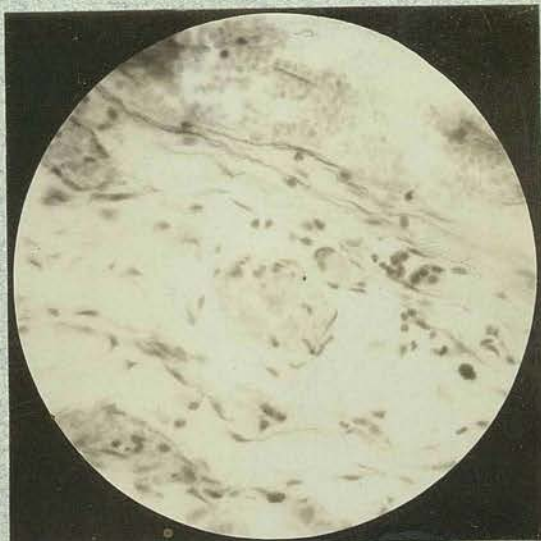Low Power.



Low Power.



High Power.



High Power.

DESCRIPTION OF SLIDE NO.(6).

"(WALL OF CYST)"

LOW POWER:-

The wall is everywhere composed of white fibrous tissue. This, however, is broken up by layers of the Pseudomyxomatous deposit. This material infiltrates the whole thickness of the Cyst Wall being deposited on the outer surface in a layer indetical with that seen covering the OMENTUM.

The inner surface of the Cyst Wall is similarly covered by a definite layer of this Pseudomyxomatous Tissue. No epithelial cells are anywhere visible. The Pseudomucinous material stains a faint violet colour, and runs in distinct trabeculae amongst the fibrous tissue; this stains a distinct pink colour and occurs in definite longitudinal layers. Bundles of this tissue are separated by trabeculae of Pseudomyxomatous Tissue.

In one or two distinct masses of a small celled infiltration occur; this, however, is rare.

---



HIGH POWER:-

The Pseudomyxomatous Tissue is laid down in a laminar manner, and presents a reticular structure in the meshes of which round cells with single or multiple nuclei are found scattered about in scanty numbers.

This Pseudomyxomatous Tissue everywhere infiltrates the whole cyst wall, breaking up the fibrous tissue into layers and isolated bundles.

The fibrous Tissue for the most part appears normal, and shows little or no round celled infiltration.

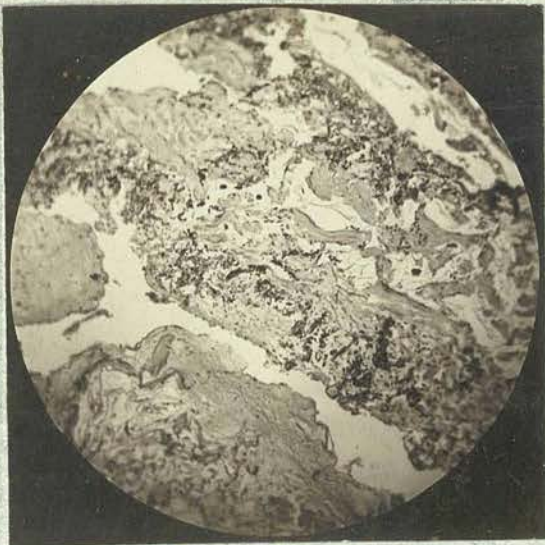A few masses of round cells are observed here and there. No large blood vessels can be seen in the cyst wall.

A few arterioles and venules occur; surrounded by round cells; but these are not nearly so numerous here as in the condition of periarteritis seen in the OMENTUM.

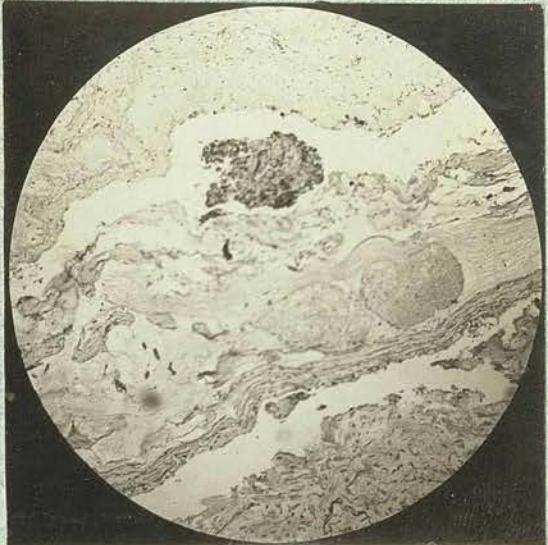No Epithelial Cells can be recognised anywhere in this section.

---

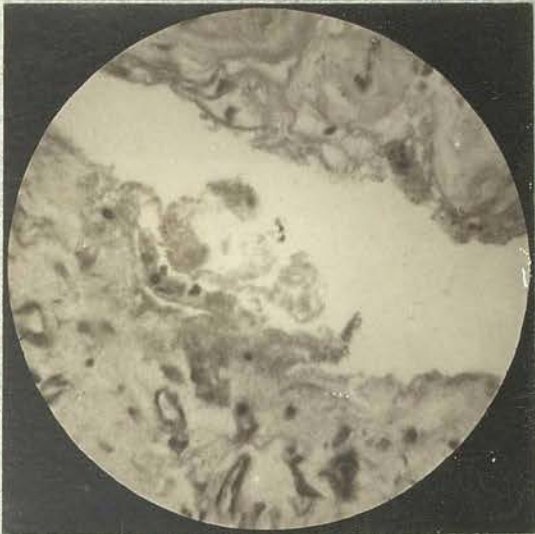
CYST WALL (Fletcher).



Low Power.



Low Power.



High Power.



High Power.

DESCRIPTION OF SLIDE NO. (7).

(MARY FLETCHER'S CASE).

P E D I C L E.

LOW POWER - This consists almost entirely of large arteries and veins for the most part perfectly healthy and empty.

One large vein, however, shews in its lumen a mass of Pseudomyxomatous deposit, richly infiltrated with round cells.

Beyond this intravenous deposit, there is little or no pseudomyxomatous tissue to be seen.

The venules and arterioles show a considerable amount of perivascular round celled infiltration.

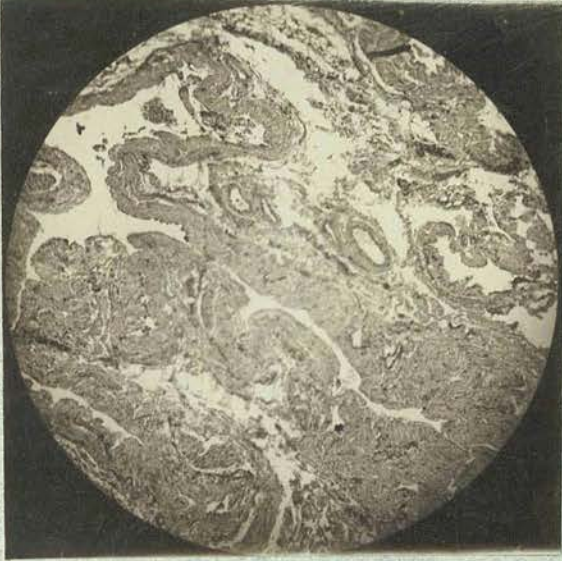HIGH POWER - The walls of the large vessels are to all appearances healthy.

Around the smaller vessels are groups of small round cells.

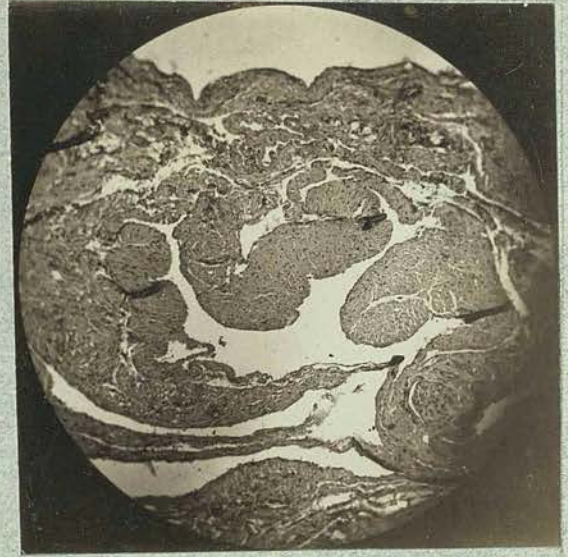
The lumen of one vein is partly filled by a mass of Pseudomyxomatous tissue taking on the usual violet stain and richly infiltrated with round cells possessing one or more nuclei.

---

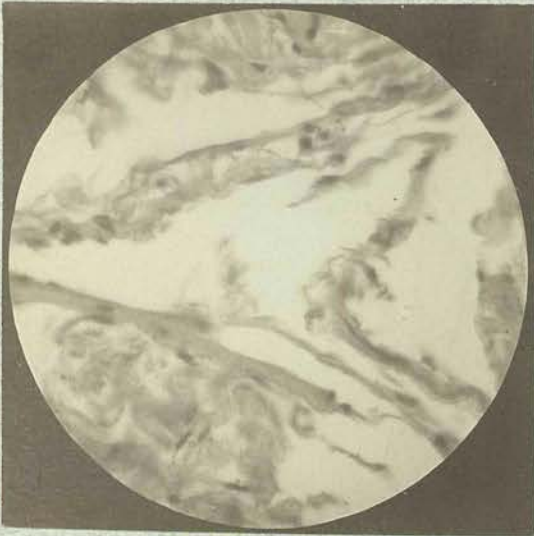P E D I C L E . ( F L E T C H E R )



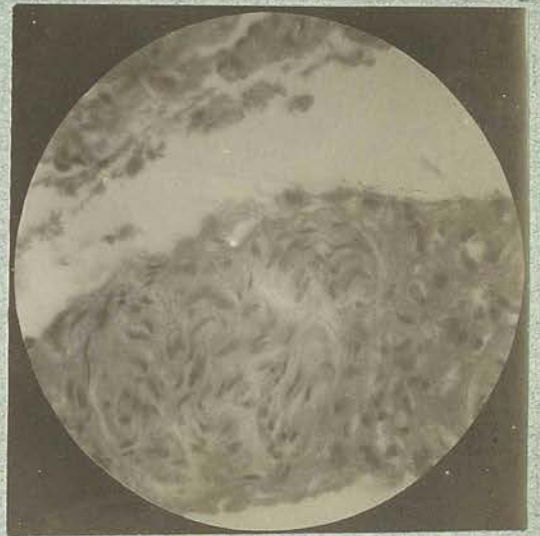
Low Power .



Low Power .



High Power .



High Power .

DESCRIPTION OF SLIDES.

(Emma Chatwin's Case).

Slides - (Omentum & Cyst Wall)

(Kindly lent by Dr. Thomas Wilson).  
(for description and comparison.)

E M M A C H A T W I N ' S C A S E .

OMENTUM.

(From a slide kindly lent by Dr. Thomas Wilson)

LOW POWER - Scattered in an irregular layer over the surface is the Pseudomucinous substance which stains in a reticular manner, and roughly assumes a laminar character.

In places this reticular stroma is studded with round cells.

In contrast to my case (Mary Fletcher), very beautiful columnar goblet cells are seen lying upon the surface of the Omentum in isolated spots, and in situ seem to be secreting this pseudomucin.

Embedded within the Omentum are one or two isolated acini lined by the same columnar epithelium.

HIGH POWER - In those areas where no pseudomucin exists, the Peritoneum is represented by a single layer of squamous epithelium. Where the Pseudomucin exists there appears to be an active proliferation of the epithelium presenting several layers of squamous cells. These are shed and apparently have the power of passing into the substance of the

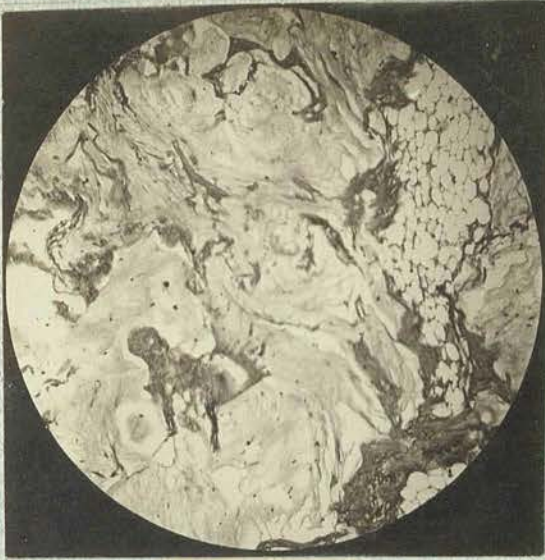Pseudomucin becoming ensnared in its reticular framework.

In the subperitoneal tissue and fat of the Omentum whereon a mass of Pseudomucin exists, there is an increased vascularity and an infiltration of the tissue by round cells - uninuclear and polynuclear.

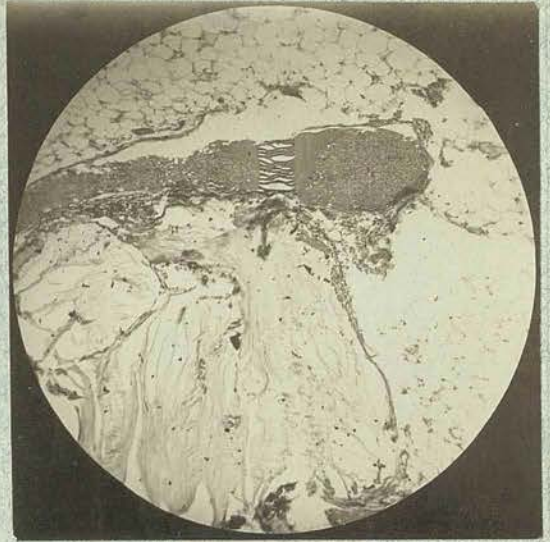
This small-celled aggregation is most marked around the smaller vessels.

The columnar cells which in places lie in a single layer upon the surface of the Peritoneum, and are occasionally arranged in perfect acini, in all respects resemble those seen in the Cyst Wall. They are practically goblet cells shewing:-

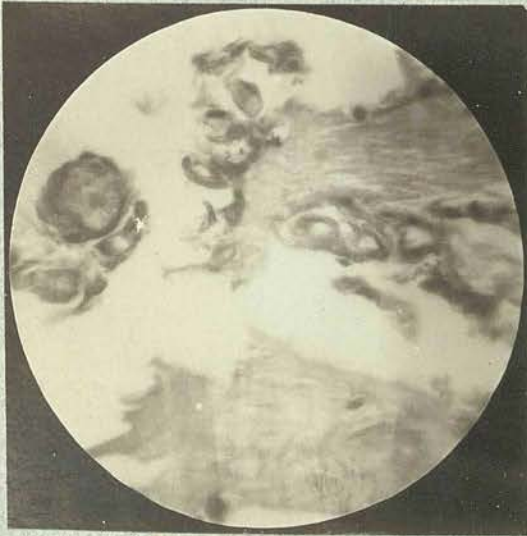
1. A clear, almost homogeneous, outer two-thirds retaining the stain very feebly, and -
2. A deeper part in which is an oval, occasionally elongated, darkly stained nucleus surrounded by a protoplasm that stains less faintly than the nucleus.



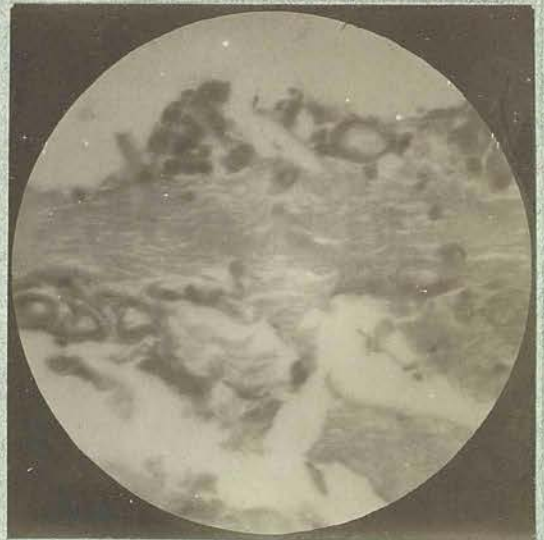
Low Power.



Low Power.



High Power.



High Power.



E M M A C H A T W I N ' S C A S E .

CYST WALL.

(From a Slide kindly lent by Dr. Thomas Wilson).

LOW POWER:- The section presents a connective tissue and an epithelial element.

The connective tissue is fibrocellular in character, and gives the appearance of an oedematous looking fibroma.

This part of the section occupies a very small proportion of the bulk of the tumour, the larger part of it being formed of epithelial acini and pseudomucinous material.

The epithelial element is laid down as racemose acini of considerable size lined by a single layer of high epithelium with the clear part of the cell next to the lumen of the acinus.

The acini contain a varying amount of clear material staining exactly similar to the Pseudomucin on the Peritoneum.

The Blood vessels are small and not numerous.

---

CYST WALL Contd.

HIGH POWER - The connective tissue framework consists of fibrous tissue moderately loose in character and fairly rich in connective tissue cells.

Throughout the whole of this stroma are small clear spaces containing what appears to be a single connective tissue cell. This apparent vacuolation is either an oedema or a form of degeneration.

The Epithelial cells are of a high columnar type with a cubical shaped nucleus at the base, surrounded by a protoplasm that stains a delicate pink colour with Eosine.

The outer three-fourths of the cell is clear and almost homogeneous, possessing only a very faint reticulum.

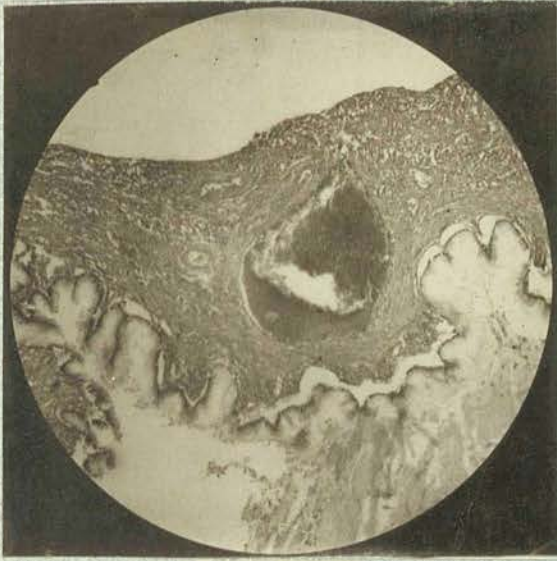The surface of the cell next to the lumen appears to be open just like the mouth of a goblet cell.

This epithelium is evidently of a secretory nature, and has the power of producing the pseudomucin previously described. The blood vessels are generally small and engorged with blood.

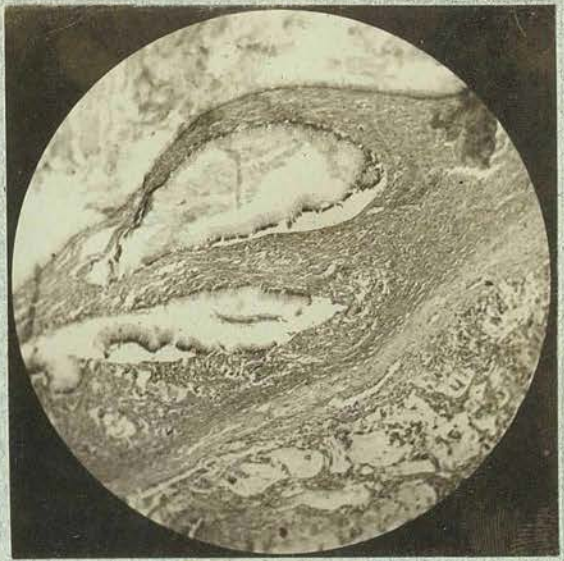There is little or no round celled

infiltration, either in the substance of  
the connective tissue or around the blood  
vessels.

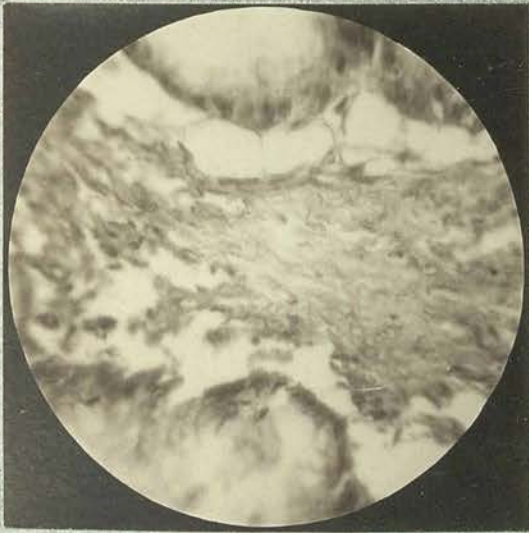
---



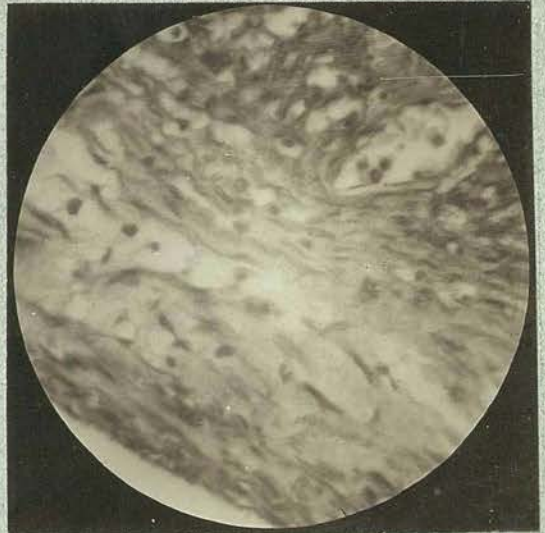
Low Power.



Low Power.



High Power.



High Power.

HISTOLOGICAL SUMMARY OF KNOWN AUTHORS.

HISTOLOGICAL SUMMARY OF KNOWN AUTHORS.

Insufficient original research has been made regarding the nature of OVARIAN CYSTOMATA, (Pseudo-kystomata of WERTH (1),) and their thick, gelatinous contents. GOTTSCHALK (17) thinks that the literature relating to them has been too much depended upon in the past, and holds that histological and chemical discoveries, prove that they are not always of so simple a nature as is generally accepted.

1. The CYST WALL is lined either by tall cylindrical epithelium, with goblet cells, (RUNGE (21) and others); or by,

2. a low cubical epithelium, among which occur cells, with large nuclei, and a small amount of protoplasm; (PFANNENSTIEL 6 )

(Vide GREENFIELD, page 87 ).

Mucin is occasionally found in the cyst contents (RUNGE 21), but Pseudomucin, in place of, or in addition to the former, usually occurs (PFANNENSTIEL 6 ) This author tried to explain the different Epithelia, by the hypothesis that the shortening resulted from pressure atrophy; he further believes that the cubical type is totally devoid of secretory power, and that all Cystomata originally possessed tall cylindrical epithelium.

GOTTSCHALK (17) opposes this view, and says that he is in a position to show that these gelatinous

HISTOLOGICAL SUMMARY OF KNOWN AUTHORS.

Cystomata can have, from the very commencement, a cubical epithelium yielding this characteristic secretion; furthermore, he states that these cysts emanate from the Graafian Follicle in the form of small multiple cystic growths.

From a histological, and probably also from a histogenetic point of view, it will in future be necessary to distinguish between two kinds of gelatinous Ovarian tumours.

1. Those which possess cubical epithelium emanating from the membrana granulosa of the Graafian Follicle.
2. And those with tall cylindrical epithelium, the histogenesis of which has not yet, with certainty, been proved.

Gottschalk (17) states that the free lying matter seen in the Abdominal Cavity, and that found adhering to the peritoneum, originated from an Ovarian Cyst, and therefore must be metastatic. A successful case was described by him, which he operated upon at Giessen. A cystadenoma of the Right Ovary attracted special attention, as the peritoneum in its vicinity, was covered with a thick gelatinous layer, evidently extruded cyst contents. The Left Appendages showed advanced gonorrhoeal disease. In this case, the Abdomen had to be re-opened 10 days after the

HISTOLOGICAL SUMMARY OF KNOWN AUTHORS.

operation on account of intestinal obstruction. The Sigmoid Flexure was found strangulated, and had to be removed. Convalescence continued without further incident.

(P.87). PROFESSOR GREENFIELD in his examination of the walls of the secondary cysts obtained from the former of Mac Donald's (29) cases, found an endothelial lining composed of large flattened cells. This case might be grouped under the first category.

A tumour removed at operation was made up of a principal cyst and several daughter cysts. Parts of the cyst wall showed remnants of Ovarian parenchyma, and were lined by a single layer of short cubical epithelium, actively participating in jelly production. Smaller cysts were found showing unmistakable signs of Graafian Follicles within the membrana granulosa of which a structureless membrane, (the vitelline membrane), occurred, lined by a single layer of cubical epithelium, and filled with myxomatous matter.

The above shows that Ovarian Cystomata can occur, in which, contrary to Pfannestiel's (6) opinion, the short cubical epithelial lining does secrete gelatinous material in exactly the same way as the tall variety. - In both, the final result is the same, viz:- "Pseudomyxoma Peritonei".

The OMENTUM of the case described by



GUNZBURGER ( 3 ) under the microscope, showed how this gelatinous matter was organised, and how this organi-  
sation originated from the Peritoneum. Round cells migrated into this gelatinous matter, followed by connective tissue bundles. Spindle cells, fibrils, and new capillaries, were found in these places.

The site of rupture, as well as the microscopical appearances of the peritoneal affection, uphold the view of WERTH, who is supported by STRASS-  
MANN, the last to furnish a detailed account of this subject:-

"That, after the bursting of a cyst, the gelatinous masses form a deposit upon the Peritoneum, which afterwards becomes organised by the Peritoneum".

---

DEDUCTIONS & ABSTRACTS

-- FROM --

WERTH'S ACCOUNT

OF

THE HISTOLOGY

OF

PSEUDOMYXOMA PERITONEI.

---

(Translated from the original German).

---

DEDUCTIONS AND ABSTRACTS FROM  
WERTH'S ACCOUNT OF THE HISTOLOGY  
OF  
PSEUDOMYXOMA PERITONEI.

(Translated from the original German).

During the operation on his Patient, WERTH removed portions of the Liver and Diaphragm covered by a gelatinous deposit.

Some were placed immediately in Alcohol; others were first hardened in Potassium Bichromate. The gelatinous substance on the specimens treated by the latter method remained transparent and would not stain. Those subjected to the former process showed a shrinking of the jelly, and on microscopical examination, gave a striped appearance. The condensed portions took on an intense colour.

(Werth makes no mention of the Histological Stains used for his sections, and it is not until Westphalen's excellent Histological Treatise is read, that we learn that Pseudomyxomatous (as opposed to true Myxomatous tissue, for example, Wharton's jelly), retains Haematoxylin most tenaciously, even after the total decolourisation of all the nuclei with Picric Acid).

The Peritoneum on the Liver and that adjoining the Liver parenchyma showed no change. Where the broader interacinous connective tissue approached the Liver capsule, a small cellular infiltration occurred. The larger Peritoneal vessels were separated by a densely lying zone of round cells.

A layer of thick spindle shaped cells occurred on the free surface of the Peritoneum.

At varying distances on the edge of the serosa, broad continuations were seen entering and permeating the gelatinous matter in the form of branching trabeculae, which everywhere appeared covered by a continuous layer of round and polygonal cells, with large oval nuclei. These in all respects, were similar to the endothelial cells of the serosa situated at the bases of the above continuations. Thin walled embryonic capillaries entered these trabeculae from the Peritoneum.

These rudimentary blood vessels were recognised by the red corpuscles contained in their lumina, and by the regular order in which the leucocytes occurred, comparable to that found in normal capillaries. The white cells could easily be distinguishable from surrounding epithelium by their smaller size and more deeply stained nuclei.

These trabeculae entering the gelatinous layer are, therefore, nothing but branching blood vessels covered by epithelium.

N.B. What DONAT found experimentally in the Rabbit, entirely supports Werth's discovery, for, embryonic branching vessels were distinctly seen in the animal's Peritoneum.

Echymoses were also observed.

Here and there vessels anastomosed; these on section appeared to form small cavities, lined by

epithelium and containing jelly. - Considering the difficult and hitherto unexplained nature of the growth, this may, in a measure, account for the divergent views on the subject.

These discoveries are of great histological importance and most distinctly show the commencement of a pathological connective tissue growth on serous membrane. This takes place in a manner altogether differing from many of the accepted views.

Werth now compares the above with what he observed on revision of Mennig's Specimens. The gelatinous masses adhering to the peritoneum were here found in a more advanced stage of organisation. Werth emphatically contends that in Mennig's case - "A simple inflammatory excitement of the peritoneum existed and nothing else."

On revision of these specimens he refutes the following statements of Mennig:-

1. That the gelatinous deposit occurred in the larger spaces of the fascial connective tissue of the Abdominal wall.
2. That there was no organised connection between the new gelatinous formation and the peritoneum.

This latter assertion is especially objected to by Werth, for, on the peritoneal surface of the Diaphragm, where the thickest layers of jelly occurred, a distinct connection between this organised gelatinous layer & the peritoneum was formed by means of broad bands of connective tissue.

From Microscopical examination of affected Abdominal organs and adjacent parts, Mennig concluded that the affection was a Myxomatous Degeneration of the Peritoneum, secondary to the "oozing out" of cyst contents.

The course of the disease he described as follows:-

"The process begins with a cellular infiltration of the connective tissue of the Serosa and Subserosa. The cells in the newly formed tissue are round, spindle or branching. When the existing connective tissue is thus increased, mucin is secreted, this separates tissues and vessels, causing an areolar formation in the degenerated peritoneum."

In the spaces between the adhesions no distinct endothelial lining could be observed.

A small zone of cellular infiltration occurred in the spaces surrounding the larger vessels. The peritoneum in connection with the gelatinous masses was slightly thickened.

The facial layer of the Diaphragm showed no change; the connective tissue entering the gelatinous matter from the serosa was distinctly fibrous in structure; a small portion, however, consisted of spindle cells. Round cells were only sparingly seen; but large branching capillaries occurred. Accompanying these, new connective tissue entered the spaces in the form of bundles of finely branched cells, which were distinctly seen in the transparent

jelly. In addition were anastomosing capillary shoots,- stellate connective tissue and roundish endothelial cells.

Werth thinks that it is here a question not of a degeneration, but of a new growth, the structure of which, whether arising in a normal way or as a pathological condition, is totally different from what Mennig described.

This process is exactly similar to that which takes place during the organisation of a Thrombus, the ultimate object of both being identical.

Furthermore, the new tissue formation is the result of irritation set up by dead gelatinous material; healthy tissues being ultimately supplanted.

Professor Heller examined Mennig's sections and thoroughly agreed with Werth's deductions.

In both cases, ( i.e. Werth's & Mennig's ), therefore, the supposition of a mere myxomatous degeneration of the peritoneum cannot be maintained. There remains the question, whether one is justified in applying the name Myxoma to such a cystic ovarian tumour.

Pathologically, a Myxoma is composed of loose connective tissue and mucus and is classified among the connective tissue tumours. (WERTH).

The mucoid material is part of the inter-cellular substance, and is not the product of a secretory activity or of tissue metabolism.

CYST WALL:- The tumour, in Mennig's case, producing the change in the peritoneum, showed all the anatomical characteristics of a glandular cystoma.

On the peritoneal surfaces of the Cyst wall, Werth found the same gelatinous deposit as that seen in the Abdominal cavity. A small epithelial layer of varying thickness lined the inner surface of the cyst.

The cavities were lined by a simple layer of tall cylindrical epithelial cells.

In Werth's own case, the cyst wall was not microscopically examined, but its appearance left no doubt as to its glandular nature. In these two cases, therefore, the name "Myxoma Ovarii" is not correct, and Werth does not accept any described under such a name.

Werth's conclusions, briefly, are as follows:-

1. In every case the process was identical.
2. Large quantities of gelatinous masses were found in the Abdominal cavity, mostly lying free.
3. Only a small portion of these masses adhered to the intestines.
4. In this adherent matter, newly formed vessels and miliary hæmorrhages occurred.
5. Adherent masses were found in layers of varying thickness; occasionally these were globular.
6. That portion of the peritoneum uncovered by deposit was in a state of chronic inflammation.



D O N A T ' S

ANIMAL EXPERIMENT.

--- ALSO ---

DEDUCTIONS & ABSTRACTS FROM

DONAT'S

ACCOUNT OF THE HISTOLOGY OF

PSEUDOMYXOMA PERITONEI.

---

DEDUCTIONS & ABSTRACTS FROM  
DONAT'S  
ACCOUNT OF THE HISTOLOGY OF  
PSEUDOMYXOMA PERITONEI.

---

ANIMAL EXPERIMENT.

To ascertain the effects and Peritoneal changes caused by the gelatinous matter removed from the ABDOMINAL CAVITY of his Patient, DONAT, assisted by DR. SANGER. made the following experiment:-

On the evening of June 26th, 1885, a small female Rabbit was opened in the Linea Alba, under strict antiseptic precautions.

A quantity of the fresh CYST CONTENTS was steeped in a 3% solution of warm Carbolic Acid, and, with disinfected hands, pushed into the Rabbit's Abdominal Cavity. The wound was then closed with four sutures, and well sprinkled with Iodoform.

The animal, placed with others soon after the operation, was cheerful, and ate well.

On JULY 1st - (i.e. 5 days after the operation) it became apathetic seemingly took no food, and was found DEAD towards evening.

---

DONAT'S

ANIMAL EXPERIMENT

Contd.

---

POST MORTEM.

The Post Mortem, made immediately, showed no change in the appearance or position of the gelatinous mass.

A loose opalescent deposit occurred where the jelly had been in contact with the parietal and visceral Peritoneum.

The serosa was slightly reddened, but no signs of an exudation, or of a general peritonitis, could be discovered.

THE INTESTINES were embedded in jelly. An Abscess, the size of a pea, occurred on the Anterior Abdominal Wall.

---

HISTOLOGY OF RABBIT'S PERITONEUM.

A piece of the Rabbit's Peritoneum was hardened in Alcohol, and stained with Bismark Brown.

Sections, on Microscopical Examination, showed a distinct Pyogenic membrane, loosely adherent to the Peritoneum, which had become densely infiltrated with pus cells.

Colonies of these were found among muscular fibres in the Anterior Abdominal Wall.

Nothing approaching this state of things is mentioned by WERTH.-- Perhaps the above condition requires a longer period for its development in the human body.

A genuine local suppuration certainly occurred; this may be due to a certain predisposition of the Rabbit to purulent infiltration; or to the fact, that organisms may have gained admission during Laparotomy.

In WERTH'S case the disease, of course, developed under conditions of perfect Asepsis, for the Abdominal Cavity all the while remained intact.

DONAT states that he entirely failed to produce the same form of PERITONITIS in the Rabbit as that found by WERTH in the human Peritoneum.

The microscopical results of both Authors, however, agree in the discovery of Slender branching vascular trabeculae and Echymoses permeating the Peritoneum.

DEDUCTIONS & ABSTRACTS FROM

WESTPHALEN'S

ACCOUNT OF THE HISTOLOGY OF

PSEUDOMYXOMA PERITONEI.

TRANSLATED FROM THE ORIGINAL GERMAN.

HISTOLOGY OF THE PERITONEUM

IN WESTPHALEN'S 1ST CASE.

A deposit of about 5 millimetres in thickness, with a wart-like surface, was found adhering to the peritoneum by cords, which contained fibrils of connective tissue and blood vessels.

The deposit itself was composed of young connective tissue, mingled with pseudo-myxomatous elements, among which miliary hæmorrhages appeared. In the denser parts, the new connective tissue was thicker, and capillaries more numerous. These latter were covered with peritoneal Epithelium and embedded in pseudo-myxomatous layers, containing round and spindle shaped cells, also small capillaries.

It is here a question of Pseudomucinous, not myxomatous degeneration. This is proved by the fact that the pseudo-mucinous secretion retains the Hæmatoxylin stain most tenaciously, even after all the cell nuclei have been decolourised by Picric Acid. Especially is this so, with the bands of more tenacious material, which mark the direction of the flow, and are found in almost every cyst. When all nuclei have been decolourised, these bands still retain a distinct bluish stain.

With true Myxomata originating from Connective Tissue, as with Wharton's jelly, the mucinous secretion always becomes decolourised before the nuclei. This

difference in the reaction to the hæmatoxylin stain is said by WERTH (1), to be due to a new form of Connective Tissue emanating from the Serosa.

A piece of parietal peritoneum, 5-6 millimetres in thickness, was taken from the Anterior Abdominal Wall. On section it presented a bacon-like appearance - flat frog-spawn like bodies were seen on its inner surface. In a vertical section, cellular infiltrated areas of subperitoneal fat, appeared. Also a thin layer of firmer connective tissue with the larger blood vessels.

The following became visible in the thickest portion of the remaining peritoneal layer when stained with Haematoxylin and Eosin:-

The pseudomucinous matter, stained blue, was deposited in a network of fine connective tissue, like trabeculae, carrying blood vessels.

The Connective Tissue of the Peritoneum, often as thick as the subserosa, had degenerated into a spongy network, brought about by extreme injection of the lymph spaces with the mucinous material, the layers of deposited pseudomucinous matter appeared thicker than the trabeculae.

The bundles of connective tissue ran obliquely or parallel to the surface, but in places they were vertical, so that in section a papillomatous appearance presented, reminding one of Epithelium-lacking chorionic remains. Later on, the fibres adopted a transverse course, showing that this appearance of papilloma was only simulated.

In the connective tissue of the superficial layer this was again noticeable. The connective tissue fibrils were swollen, infiltrated with small cells, and permeated by engorged vessels.

The superficial contour of the Peritoneum in many places was irregular, through the filling up or patency of the Lymph stomata.

The peritoneal Epithelium was everywhere recognisable.

In the earliest stages of the process, bulbs were found branching off from the peritoneum at an acute angle. These chiefly consisted of altered peritoneal Epithelium, accompanied by small bands of connective tissue.

Wherever pseudomucinous masses occurred, a new form of organising tissue was seen entering vertically from the Peritoneum, accompanied by new blood vessels, (as described by WERTH (1), STRASSMANN (30), and KRETSCHMAR (-);), even the gelatinous masses filling the lymph spaces showed changes equivalent to a commencing organisation process. The cavities containing these masses were not everywhere lined by typical Endothelial cells. Sometimes the jelly lay like a deposit around new connective tissue fibrils; in these very places, the stain was most tenaciously retained. Rows of elongated spindle cells and branching connective tissue elements were frequently found.

The swelling in the Left Tube was caused by a mass of slimy, cell-lacking material filling its lumen; this showed no similarity to the cell wall



itself, or to its Epithelium. The tube was passively dilated; the sparsely existing folds, covered by Epithelium, were pressed flat against the wall.

The Mesosalpinx on its surface, showed a commencing growth of organising tissue. Mucinous secretion, in considerable quantity, filled the peritoneal lymph spaces of the adjacent Anterior Abdominal wall. Similar masses might have been found in many parts of the Abdominal Cavity, had a thorough search been made.

In addition to the peritoneal organisation of new tissue noticed by WERTH (1), we have here an Endothelial organisation, altering the peritoneal membrane to a spongy network.

In any case, this is a stage of very early peritoneal disease, as the condition found at the operation showed. WESTPHALEN'S (4) theory of rupture following puncture cannot, with certainty, be proved.

It seems remarkable that the organisation process was, comparatively speaking, so much more advanced on the Mesosalpinx than on the other parts of the Peritoneum. One reason may have been that, after rupture, the Mesosalpinx, formerly tightly stretched, had become richer in blood owing to later relaxation. That a certain amount of surplus peritoneum occurred here, is demonstrated by the microscope, which plainly shows densely lying serosa possessing a wavy outline.

A second reason is, that, the peritoneal surface was here protected by the original tumour wall.

---

TRANSLATED FROM THE ORIGINAL GERMAN.

HISTOLOGY OF THE PERITONEUM

IN WESTPHALEN'S 2nd CASE.

(A section from a piece of Peritoneum, taken during operation from the Anterior Abdominal wall).

(a). Macroscopically, this showed a bacon-like appearance, and was 4-5 millimetres in thickness. On its inner surface were globular excrescences, somewhat infiltrated with blood.

(b). Microscopically, in a well differentiated Hamatoxylin section, many deeply stained lines were seen, running between the connective tissue layers and extending as far as the subserosa.

In the deeper layers the lines were thinnest and showed a more intense colour; these ran in the lymph spaces of the connective tissue, without, however, greatly distending them. Superficially, the lines gradually thickened out and showed fainter colouring, until they finally merged into the gelatinous deposit.

The connective tissue of the Peritoneum showed a small celled infiltration. Hæmorrhages and dilated, tortuous blood vessels were also seen. Organising connective tissue extended from this infiltration into the gelatinous mass.

(This organisation is much more advanced than in Case 1).

In parts, a network of cells was seen, with processes branching in such a manner, that the whole might be mistaken for true Myxomatous tissue, if other appearances did not remind one of its Epithelial origin.

The original Peritoneal surface could not be distinctly defined. The superficial granular masses, which macroscopically looked like a neoplasm, consisted of mucinous tissue and blood.

The peritoneal surface was covered by a layer of young connective tissue, upon which rested a layer of peritoneal Epithelium. Organised connective tissue entered the superficial granular masses from below and laterally. Beneath this granular layer was found a flattened stratum of similar organisation, but in a more advanced stage.

The surface view resembled the appearance of the well-known Pachymeningitis Hæmorrhagica (or Peritonitis Hæmorrhagica of Virchow 53), if only transparent clot be substituted for hæmorrhagic mucinous masses.

SPLEEN CAPSULE:- The spleen capsule was considerably thickened, and showed linear deposits of tense pseudomyxomatous material in the lymph spaces.

The capsule was clearly distinguishable from the infiltration, which in the deeper layers formed a close network of connective tissue. Superficially, the tissue was of a looser character, the matrix being everywhere filled with mucoid material. Signs of progressive organisation, were everywhere visible.

VERMIFORM APPENDIX:- The peritoneal surface of the Vermiform Appendix exhibited similar appearances, especially on its mesentery. The swollen Appendix was much changed and contained the same pseudomucinous contents as occur in Ovarian cysts. Here it is a question of Metastasis. In the lumen of the Appendix, as in parts of its wall, pseudomyxomatous cysts had formed. Small cysts with very tall Epithelium and larger ones with a degenerated variety, were met with. Others again, did not show any Epithelial degeneration, but contained young connective tissue with leucocytes invading the cyst contents.

In the interior of the follicles, an ingrowth from the lymph spaces was noticed.

Throughout the greater part of its length, the Appendix was dilated almost to the point of rupture, whilst towards the colon, it was defined by a hard membrane, the size of a 5/- piece; probably an old Atresia, which had existed at this point.

MESOSALPINX:- A cross section of the Mesosalpinx showed mucinous matter permeated by a regular network of wavy connective tissue, containing comparatively few blood vessels. Some of the thicker bundles of connective tissue were covered by a layer of flattened cells resembling somewhat the parietal Epithelium, which generally persisted, and was only absent where the connective tissue had infiltrated the serosa. Bands of connective tissue were found in the mucinous masses, also round and spindle shaped connective tissue corpuscles with multinuclear elements.

These cells were fewer in the denser portions of the mucinous matter.

In the Serosa of the Tube, small layers of a hyaline, structureless material were found (Carmin preparation). These retained the Hæmatoxylin stain, even after the nuclei had been completely decolourised.

N.B. Westphalen holds that the structureless material is thickened pseudomucin, occurring in the lymph spaces.

OMENTUM:--The whole of the Omentum had been thickened up to 3-4 centimetres. On sagittal section, the following appearances presented:-

Irregular masses of pseudomucin were deposited in a loose matrix of connective tissue, filled with degenerated fatty tissue - atrophic because of existing peritonitis.

The pseudomucinous deposit was in places surrounded by Epithelial cells resembling those of a proligerous Ovarian cyst. Here, it is manifestly a question of Metastasis.

Where the Epithelial cells occurred surrounding the pseudomucinous deposit, no connective tissue elements were visible; in many instances the Epithelial border was only found on one side or on a limited portion of the periphery of a mass; on the remainder, it had obviously degenerated. In such places, and on the smaller masses uncovered by Epithelium, an advancing, organising tissue occurred, showing various stages of development. Once or twice, at most, on an

area of 6 centimetres, small follicles of a young, active Epithelium were found.

WESTPHALEN thinks that the factor which caused the Omentum to become evenly thickened throughout its whole extent, was the absorption of gelatinous material into its wide and numerous lymph channels. Epithelial cells carried in with these masses have ultimately formed implantation metastases of little proliferative capacity. In most places these cells have formed proximate degeneration products to swell the growth, but only in a few places have they found suitable soil for a new formation.

CYST WALL:As regards the Ovarian tumour itself, the examination of several pieces showed that it was a typical pseudomucinous cystoma, having no tendency towards a malignant form.

The opposite Ovary had several small follicular cysts with gelatinous contents in the albuginea - here also it was a question of a pseudomucinous cystoma. The Epithelium of the smaller cysts, had partly or wholly disappeared, hence the difficulty in defining cyst contents from the surrounding stroma. Connective tissue cells and freely developing young blood vessels penetrated the gelatinous mass from the surrounding connective tissue (pseudo) membrane. This gelatinous mass was in places pressed into the lymph spaces of the connective tissue, (Vide Pfannenstiel L.C. P337), and even there was permeated by connective tissue.

---

DEDUCTIONS & ABSTRACTS FROM

STRASSMANN'S

ACCOUNT OF THE HISTOLOGY OF

PSEUDOMYXOMA PERITONEI.

STRASSMANN'S HISTOLOGY.

CYST WALL:- Strassmann found that the multilocular cysts were lined by cylindrical epithelium and Goblet cells. This clearly proves that the cyst wall has a definite secretory function.

It is interesting to find that STRASSMANN'S CASE agrees with those of WENDELER (16) and GUNGBURGER (3), in the discovery of Dermoid elements:- (Hairs, sweatglands, cartilage, teeth, and fat).

PERITONEUM:- In the Peritoneum covering the Liver, a comparatively recent stage of the disease was found.

Portions of the serosa remained intact, whilst others showed spaces from which the subserous tissue oozed, in the form of bud-like granulations. The older of these firmly adhered to the Myxomatous growth.

Cord like granulations surrounded branches from the vessels supplying the Liver Capsule, and ultimately became lost in the gelatinous matter, owing to the repeated branching of the capillaries.



STRASSMANN'S HISTOLOGY CONTD.

Many round cells accompanied the latter in their course.

It is important to note that between these capillaries, dissolved portions of the cyst wall occurred, closely resembling the Cavities referred to by WERTH.

The epithelium was found wanting on the adherent areas, doubtless due to the pressure of the cyst. Connective Tissue, with a rich blood supply, filled up these deficiencies.

This Connective Tissue vascularies the myxomatous matter, which is either absorbed, or becomes definitely implanted into the healthy organs.

---

"PROFESSOR GREENFIELD'S"

R E P O R T

on the

--- HISTOLOGY OF THE CYST WALL ---

-- from --

MACDONALD'S FIRST CASE.

(Included for reference and comparison)

(c.f. Strassmann - page 84. ).

HISTOLOGY OF CYST WALL

"GREENFIELD"

CYST WALL - "The portion of cyst examined was very unlike a common ovarian cyst.

In the thicker and older portions the structure was dense, composed of fibrous tissue, with a large number of yellow elastic fibres, and numerous bundles of unstriped muscle cells.

But for the most part the structure was very highly cellular, resembling actively growing granulation tissue, exhibiting in some parts many interlacing spindle cells; in others, masses of granulation cells of various shapes.

Towards the free surface, - i.e. the surface bounding the cyst cavity, the structure resembled that of an actively granulating wound, being composed of dense masses of cells, forming irregular bands, and containing numerous large irregularly dilated capillaries, filled with blood.

THE SECONDARY CYSTS appeared to be lined only by a layer of flattened cells, resembling an endothelium, and not distinguishable in character from the cell masses in which

Contd:-

HISTOLOGY OF CYST WALL.

"GREENFIELD"

they lay. In some places two or three layers of cells were present; in others the flattened cells were absent, the cell buds growing freely into the cavity".

---

DEDUCTIONS & ABSTRACTS FROM  
FRAENKEL'S  
ACCOUNT OF THE HISTOLOGY OF THE PERITONEUM.

DEDUCTIONS & ABSTRACTS FROM

FRAENKEL'S

ACCOUNT OF THE HISTOLOGY OF THE PERITONEUM.

FRAENKEL reports a case of Pseudomyxoma Peritonei, on which, in the space of three years, Laparotomy was performed three times.

The PERITONEUM was microscopically examined on each occasion, and presented the following characteristics:-

Only a very small portion of elastic elements occurred.

The peritoneal folds were filled with jelly, but no signs of organisation could be seen. Capsules, composed of pseudomembranes, permeated by capillaries, enclosed these gelatinous masses.

The cyst wall, in places, showed signs of Myxomatous degeneration.

These results, so far, support WERTH'S views, but FRAENKEL goes a step further and states that a true Metastatic Formation was found on the peritoneum covering the Descending Colon. He therefore inclines to Olshausen's (32) Theory, and says that Implantation Metastases are usually found on the Peritoneum, provided a thorough search be made.

C H E M I S T R Y

-- of --

PSEUDOMYXOMA PERITONEI.

with

ANALYSIS OF GELATINOUS MATTER.

(Mary Fletcher's Case).

CHEMISTRY.

M A R Y F L E T C H E R ' S C A S E .

Pseudo-mucin occurred in the gelatinous material removed at operation. I could not, however, succeed in forming a correct estimate as to the amount present.

Great difficulty at the very commencement was experienced in dissolving the gelatinous matter, although it is stated to be soluble in Normal Saline, and in a solution of Potassium Hydrate.

Masses of jelly were ultimately subjected to copious and prolonged washings of Alcohol. The residuum obtained on the filter paper was duly divided into three portions:-

No.1. Was heated over a waterbath for half an hour in a 10% solution of Hydrochloric Acid. When cool, sufficient Phosphotungstic Acid was added to precipitate all Albumin.

N.B. The filtrate gave a reduction of Fehling's solution (also Trommer) showing the presence of Mucin, or Pseudo-mucin.

No.2. Was treated with distilled water.

No.3. With a 1% Solution of Sodium Hydrate.

Both were left for two days in a cool place, and finally filtered.



Filtrate No.2. on addition of Concentrated Acetic Acid, gave a cloud, but not the characteristic thread-like flaky precipitate of Mucin.

Filtrate No.3, on addition of Dilute Acetic Acid gave the same result after standing.

The complete chemical Analysis of this gelatinous matter is as follows:-

QUALITATIVE:-      Specific Gravity = 1022.  
                          Blood Pigment and Blood Corpuscles.  
                          Crystals of Anhydrous Cholesterin.  
                          Gelatinous matter itself = Pseudomucin,  
                          also called Metalbumin and colloid substance.

QUANTITATIVE:-

(Water	92.74.	
(Proteid	4.17	(= 0.659% of Nitro (gen.
Solids = 7.26% (Mineral Salts	0.96	
(Cholesterin	2.13	
(Extractives &c.		
	<u>100.00.</u>	

---

DEDUCTIONS & ABSTRACTS FROM  
DONAT'S  
ACCOUNT OF THE CHEMISTRY OF  
PSEUDOMYXOMA PERITNOEI.

DEDUCTIONS & ABSTRACTS FROM  
DONAT'S  
ACCOUNT OF THE CHEMISTRY OF  
PSEUDOMYXOMA PERITONEI.

The Cyst contents and gelatinous masses weighed 9,200 grammes.

ANALYSIS performed by MENNEL & DONAT:-

33 grammes of gelatinous material were left in 1 litre of water for 24 hours. The matter swelled up considerably, and the lamella-like structure of the connective tissue became much plainer. (According to EICHWALD (Ann. Chem. Pharm. Bd. 134 s. 177 ff) the Mucin should now have been dissolved.)

The fluid was filtered; the larger part of the swollen matter, however, still remained undissolved.

The filtered fluid, on the addition of Acetic Acid (Conc) produced a cloudiness, but no deposit of FLAKES occurred even after standing for days, which certainly would have been the case had mucin been present to any appreciable extent.

DONAT found it impossible to estimate the amount of mucin. Albumin in large quantities was found during the various reactions.

---

DONAT SAYS:-

"It has been taken for granted that these slimy masses are composed, to a great extent, of Mucin. Whether Mucin in such large quantities can be absorbed in the Abdominal Cavity, has not, with certainty been proved"

EICHWALD (102) has shewn by his experiments with the dialysater that mucin does not pass through vegetable parchment. So far a record of no experiments can be found showing whether mucin can pass through animal membrane or not.

If much Mucin were contained in the jelly coating the Peritoneum, these masses - under the alkaline influence of the fluid, present to some small extent in the Abdominal Cavity - would tend to become greatly swollen, and might even remain in that condition.

Whether this latter supposition is correct, or whether the organisation is indifferent to such chemical bodies is UNKNOWN.

DONAT only found traces of Mucin, and states that the gelatinous mass consisted chiefly of water and Albuminous Bodies, all of which were easily deposited. He found that the Solution of Salicylic Acid used for washing out the Abdominal Cavity at the operation, precipitated these bodies in the form of a whitish deposit. An exactly similar result was obtained when the same

fluid, at the same Temperature, was poured over the gelatinous masses removed from the Abdominal Cavity.

DONAT holds that this whitish deposit was absorbed by the Peritoneum.

A large quantity of Albumin and a trace of mucin were found in the portion of this deposit adhering to the visceral serosa; hence the possibility of slow absorption becomes feasible.

The deposit caused no further irritation. All signs of Peritonitis gradually disappeared.

Perhaps the Albuminous bodies became absorbed at the same time.

This is the only explanation DONAT can advance to account for the recovery of his Patient.

---

S M Y P T O M A T O L O G Y .

S Y M P T O M A T O L O G Y.

The Anamnesis in all cases is similar. (Vide the case of Mary Fletcher, page 108).

The Cardinal symptoms are:-

1. Gradual and persistent Abdominal distension accompanied by rapid growth of the Ovarian Myxomatous Tumour, which reaches a great size within six to twelve months.
  2. Difficulty in Breathing (from "weight on chest").
  3. Dull pain in the Abdomen.
  4. Loss of Appetite.
  5. Gastric Disturbances caused by markedly insufficient peristalsis.
  6. No definite symptoms occur indicating cyst rupture; this fact affords support to Werth's theory, that the gelatinous matter gradually oozes through the cyst wall.
-

DIAGNOSIS.



D I A G N O S I S.

The diagnosis of Pseudomyxoma Peritonei presents much difficulty. The Symptomatology and History give us very little assistance in its elucidation.

No outstanding feature differentiating this Cyst with its gelatinous contents, from that of the ordinary Ovarian tumour, can be elicited by Inspection, Percussion, or Auscultation.

A pasty consistency felt while palpating the Anterior Abdominal Wall, is said to be of value.

Fluctuation is not always present.

On Bimanual examination a perforation in the Posterior fornix is sometimes felt.

Two thirds of recorded cases occur between the ages of 40 and 60. The youngest is aged 28 years, - the oldest 76.

HERMAN'S case was that of a virgin, under 40.

MARY FLETCHER'S age, was 48 years.

EMMA CHATWIN, 43 years.

The disease seems more common in Multiparae.

Menstruation is unaltered.

The diagnosis of Cyst rupture has seldom been made before operation. MENNIG states that his patient

exhibited signs of it, and HERR MOND is convinced that rupture occurred before his case was admitted.

STRASSMANN thinks this form of Ovarian Cyst bursts more frequently than has been described.

The extreme rate of tumour growth is characteristic, as only about 6 months is required for its full development.

Unusually rapid increase in Abdominal girth, therefore, may lead one to suspect Pseudomyxomatus disease of the Peritoneum, but this can only be definitely settled on Laparotomy, or by the previous introduction of an exploratory needle.

Jelly found blocking the lumen may be looked upon as a Pathognomonic sign.

---

PROGNOSIS.

P R O G N O S I S.

Prognosis is very unfavourable, as only about 44% of women affected with Pseudomyxoma Peritonei, recover.

All cases recorded by WERTH with the exception of NETZEL'S, ended fatally.

Convalescence is usually prolonged.

LOMER (11) states that all cases of Pseudomyxoma Peritonei, brought under his notice, DIED.

GRAPOW (12) reports a case operated upon by WAITZ in which FRAENKEL found evidence of malignant new formation. The patient, nevertheless, recovered.

SCHUTZ (13) saw two cases - both patients succumbed.

EMMA CHATWIN - DIED.

MARY FLETCHER is still alive and WELL.

STRASSMANN'S case who died of Cardiac weakness on the seventh day after operation, constitutes the 36th record up to the year 1891. Of these 36, 18 recovered, 15 died; and in 3 the outcome was not stated.

---

T R E A T M E N T .

T R E A T M E N T.

LAPAROTOMY should always be performed, - the Cyst removed, its pedicle firmly ligatured, the whole Abdominal Cavity thoroughly cleansed, and the Abdominal Wound sewn up.

DRAINAGE - is neither necessary nor desirable. It certainly cannot bring all the masses away.

Up to the present no advanced case has recovered, in spite of the total removal of tumour and gelatinous masses. The absorptive power of the Peritoneum must, therefore, suffer greatly.

The mode of procedure adopted in the ordinary operation for Ovariectomy is had recourse to. In addition, all gelatinous matter, as far as possible, must be removed from the Abdominal Cavity.

(Vide operation in Mary Fletcher's Case, page 122).

The treatment following operation is important. A free use of stimulants is necessary to overcome the shock in a patient whose vitality is lowered to an even greater extent than usually occurs after ordinary Ovariectomy.

(Vide Emma Chatwin & Mary Fletcher's Cases pages 146-123).

---

THESIS ON

PSEUDOMYXOMA PERITONEI.

( WERTH ).

The Case of

M A R Y F L E T C H E R .

Date of ADMISSION - November 24th, 1903.

Date of DISCHARGE - January 10th, 1904.

---

Case of

M A R Y F L E T C H E R.

Mary Fletcher, aged 43 years. Admitted November 24th, 1903. Married; six children.

STATE ON ADMISSION.

(Rapid notes made immediately on admission).

Patient is extremely thin, with a much enlarged abdomen. She lies more comfortably on her right side. Dulness is found over right side of anterior abdominal wall, and far back into the right flank. Resonance is obtained over whole of left, and also over the posterior part of the right flank, extending very far back. There is a thin band of resonance at the upper end of the swelling, above the lower margin of thorax.

The Umbilicus is flattened.

Enlarged veins are seen, especially up the right side of abdomen.

A very free fluctuation wave is obtained in all directions, in front of the above described dulness.

The heart is pushed up so that its lower border



corresponds to the level of the fourth rib.

The apex beat is indistinctly felt in the fourth interspace,  $\frac{1}{2}$ " internal to the mammary line.

Pain and tenderness is especially marked over that portion of tumour situated above the Umbilicus.

The margins of the swelling are moderately well defined.

UTERUS:- Recently delivered. Cervix soft and patulous. A Muco-purulent discharge is present. The body of the Uterus to the left, and in front, is decidedly enlarged. (= Puerperium)

---

COMPLAINT.

1. Abdominal swelling of six months' standing, which has all along been unproportionately large for the exact month of pregnancy, and has shewn an abnormally rapid increase in size even after patient's confinement.
  2. Difficulty in breathing.
  3. Indigestion, caused by "weight on chest"; loss of appetite.
  4. PAIN (dull) in lower abdomen, of some three months' duration.
  5. Dry cough for latter weeks previous to admission.
-

HISTORY OF PRESENT ATTACK.

About the 14th of May, 1903, when three months pregnant, patient noticed her abdomen abnormally distended. No pain was then felt, nor indeed did this symptom manifest itself until the end of the sixth month of pregnancy, when great pain came on, the tumour having gradually become very much enlarged. The patient was sent to bed by her Doctor, and experienced some relief from the rest, but Dyspnoea was soon caused owing to the rapidly increasing size of abdominal tumour.

At the end of the ninth month patient was delivered of a living female child, (Breech Presentation). The abdominal tumour still increased even after the child was born, and seemed now to spread across the left side, which was free of tumour before childbirth. No cause can be assigned for this abnormally large swelling in patient's lower abdomen, which she first noticed towards the end of the third month of pregnancy. Her digestion was much interfered with by the presence of this tumour, and gastric troubles ensued (especially towards the end of pregnancy) to such an extent that little else but milk was taken.

The PAIN which appears only to have manifested itself towards the end of the sixth month of pregnancy was of a dragging character, and would sometimes shoot up the right side, becoming worse after meals.

Towards evening it would come on suddenly, starting in lower part of chest, and lasting nearly all night, sometimes causing the patient to get out of bed and walk about in the hope of finding relief. After the sharp twinge had gone, severe pain was still felt in the upper abdomen, lasting for two or three hours, and even when this had disappeared, a constant dull aching pain remained.

At the end of the sixth month of pregnancy, an especially severe attack of a similar nature was felt in the upper abdomen.

The patient became pregnant in February, 1903, and noticed, in addition to the abnormally enlarged tumour, that her legs became much swollen and would pit on pressure; the left leg becoming more swollen than the right.

Patient has had to lie down every day since April, and took to her bed on November 9th, 1903, three days before labour began.

The tumour daily increased in size up to the 28th of November, '03, when laparotomy was performed.

A dry cough, lasting for some weeks, was relieved by medicine, shortly after admission.

PREVIOUS HEALTH.

Patient had Scarlet Fever at the age of fourteen years.

When 28 years of age, she had several attacks of Palpitation of the Heart, and felt physically weak - Chlorosis evidently was present at this time. - When a girl, fainting turns would sometimes occur. No chest complaint has ever troubled her beyond a slight occasional cough.

---

FAMILY HEALTH.

Mother was asthmatical, and died of Bronchitis at the age of 52 years.

Father, aged 76, still alive; has Bronchitic attacks every Winter.

Patient has one sister and two brothers, all alive and well. They have never been troubled with Bronchitis.

---

SOCIAL CONDITION AND HABITS.

Nothing specially to note.

Patient has always had good food and clothing. She has never taken alcohol, but drinks a lot of tea.

SEXUAL HISTORY.

A. Normal.

Commenced at 14 years of age.

Type 28-day.

Duration nine days.

Quantity about nine ounces.

Last Period - BEGAN 14th February, 1903.

ENDED 23rd April, 1903.

B. Morbid.

Amenorrhœa - none.

Menorrhagia - none.

Dysmenorrhœa. (PAIN)

Seat:- Chiefly in lower abdomen, shooting upward to Epigastrium, and down both legs as far as knees. An aching pain would sometimes occur in legs the day before, or two or three days after, flow began.

Onset:- Chiefly before the flow, and would remain for two or three days.

No pain experienced after flow.

Character. Constant dull aching, causing a sick feeling.

Patient can work during her periods, and is not compelled to lie down.

Intermenstrual Discharge - none.

SEXUAL HISTORY contd.

PREGNANCIES:- Six children - four female and two male, (the second and fourth).

First - female, 13th Jan: 1893. (11 years ago)

Last - female (6th), 12th November, 1903.

All are alive and well.

ABORTIONS - None.

CHARACTER OF LABOURS:-

All easy except the last. Children all born at the 9th month.

LAST LABOUR - Breech Presentation. Child was born healthy and at full term.

Labour pains not excessive, but the after pains were very severe.

PUERPERIA:-

All satisfactory, except the last. Patient usually got up on the eleventh day.

After pains not usually severe, and would last, as a rule, for three days.

During the last Puerperium, the after pains were of a very severe character, and patient has been in bed ever since, (i.e. from the 12th of November, 1903).

The abdomen still remained distended after the birth of child, and showed a daily increase in size up to time of operation.

LACTATIONS - Former ones, nothing to note. All five children were fed from breast.

After the birth of last (sixth) child, no milk could be squeezed from breasts, nor did they shew much enlargement.

---

LOCAL FUNCTIONAL DISTURBANCES.

BLADDER. Micturition - Nothing to note.

No pain, difficulty, nor increased frequency.

URINE:- Specific Gravity 1026. Acid. No abnormal constituents 1.8% Urea.

RECTUM:- Nothing to note.

No pain on defaecation, and nothing characteristic regarding motions.

PAIN IN GENITAL ZONE.

(i.e. between waist and knees).

Patient is often troubled by a shooting intermittent radiating pain (about every ten minutes), felt in the middle of lower abdomen. This pain is slightly relieved by lying on the right side. A single attack of the same kind of pain occurred

eighteen months ago, and lasted for about an hour; patient was working in the house at the time, and was compelled to sit down until it disappeared.

No Dyspareunia ever experienced.

---

PHYSICAL EXAMINATION.

General appearance and configuration.

Aspect. Drawn and anxious. Face is very thin, pinched and anaemic; slight pink is seen on cheeks. Lips are fairly red. There is marked emaciation, and appearance of suffering.

Build. Short and slight. Patient says she was quite fat three months ago.

Nutrition. Poor; patient is much wasted and thin.

General strength is not at all good. Patient can turn herself easily and without help in bed. She can also sit upright with a little help but feels giddy when up. There is no conspicuous general symptom.

MAMMAE:- Poorly developed, and little raised above level.



Adipose tissue, scanty.

Glandular tissue, small in amount.

NIPPLES very prominent, with reddened tips. No exudate on squeezing breasts.

AREOLAE are faintly pigmented. Three or four Montgomerries Tubercles are seen.

---

ABDOMEN - (before operation - 27th Nov: '03).

Inspection:-

Whole abdomen markedly distended, from Xiphoid Cartilage to Symphysis Pubis. The Umbilicus is level and flattened. Enlarged veins are observed, especially up right side.

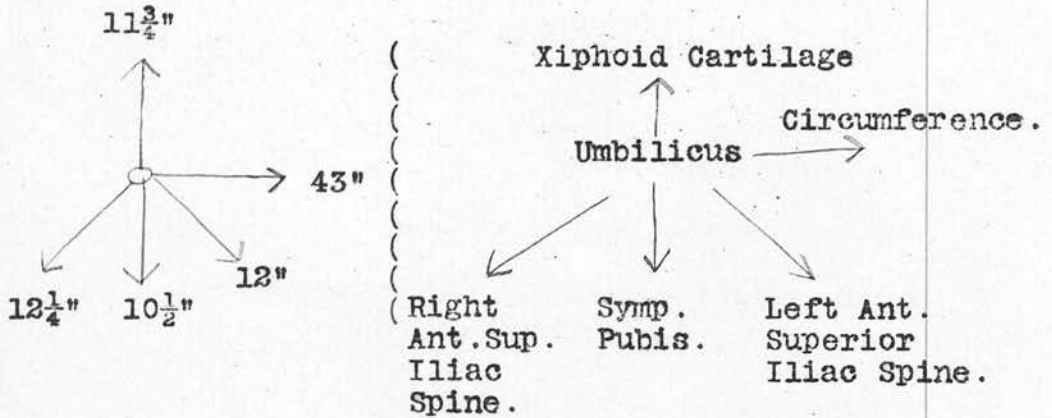
The Tumidity is ovoid, of even contour, and mesially placed.

Linea Nigra faint, and extends for a short distance above Umbilicus.

Numerous minute, flattened, lenticular, slightly raised bodies (Sudamina) are seen towards the lower abdomen, especially on the left side. These are very similar in appearance to the lenticels on the branches of a Maple Tree.

Physical Examination contd.

Mensuration (before operation, 27th Nov: 1903).



PERCUSSION (27th Nov: '03)

Marked dulness obtained over right side of Anterior Abdominal wall, and far back into right flank.

Resonance occurs over whole of left flank, and also over posterior part of right flank extending very far back.

A thin band of Resonance is obtained at the upper end of swelling, above the lower margin of thorax.

PALPATION:-- (27th Nov: '03)

A resilient mass is felt corresponding to the above described tumidity.

PALPATION Contd. (PHYSICAL EXAMINATION).

The margins of the swelling are moderately well defined.

Pain and tenderness are especially marked over portion of tumour situated above the Umbilicus.

The skin over tumour is freely movable.

A very free fluctuation wave is obtained in all directions in front of the dulness above described.

AUSCULTATION - Nil.

BIMANUALLY - (Examination is very difficult).

UTERUS:- Appears enlarged and anteverted. It is decidedly soft, very sensitive, and slightly movable.

FALLOPIAN TUBES AND OVARIES - Cannot be felt.

PERITNOEUM - See below.

CELLULAR TISSUE - Condition cannot be ascertained.

BLADDER & RECTUM - Empty.

PELVIC BONES - Present nothing abnormal.

PER RECTUM - Nil.

VAGINAL SPECULUM. (Os. fissured transversely).

There is no undue reddening of lips, nor discharge from cervix.

PHYSICAL EXAMINATION Contd.

VAGINAL WALLS are moist and healthy.

EXTERNAL PUDENA - Nothing worthy of note. Parts slightly atrophic.

PER VAGINAM.

ORIFICE readily admits 2 fingers. Walls moist.

CAVITY - Roomy.

ROOF - Nothing felt in fornices.

Patient feels pain in the small of back when the finger is pushed upwards into the left lateral fornix.

Os. Patulous, with deep lateral clefts.

CERVIX - points downwards, and slightly backwards.

---

PHYSICAL CHANGES IN THE VARIOUS SYSTEMS.

RESPIRATORY SYSTEM - Nothing abnormal to note. No physical signs of Bronchitis, etc.  
No œdema of bases.

URINARY SYSTEM - Urine shows no abnormal constituents.  
34 ozs. Specific Gravity = 1026. Acid.  
Urea = 2.4%.

PHYSICAL CHANGES contd.

DIGESTIVE SYSTEM - Appetite poor. Tongue not clean.

Bowels show an inclination to constipation.

Gastric disturbances are present to a slight degree.

NERVOUS SYSTEM - No conditions present for special note.

Reflexes - Normal.

Patient appears to be in rather an overstrung state.

NYSTAGMUS - None.

CIRCULATORY SYSTEM:-

Inspection - Præcordia shows slight bulging.

A little pulsation is seen in the supraclavicular region.

PALPATION:- Cardiac impulse is felt all over Præcordia.

Apex beat is indistinctly felt in the fourth interspace,  $\frac{1}{2}$ " internal to the mammary line.

PERCUSSION:- (deep dulness).

Right border  $1\frac{1}{4}$ " to right of Mid sternal line.

Upper border corresponds to upper border of 2nd rib.

PHYSICAL CHANGES (SYSTEMS) contd.

PERCUSSION contd.

Left border  $1\frac{1}{2}$ " internal to mammary line, sloping gradually down and out to the apex beat in the fourth interspace,  $\frac{1}{2}$ " internal to the mammary line.

AUSCULTATION - Sounds closed in all areas. The 2nd sound is accentuated in the Pulmonary area. In the Mitral Area the PAUSE is too short.

PULSE:- Not visable - 70. Regular; fairly full; not very forcible; gradual rise and fall. Apex not well sustained. No marked dichrotism. Arterial coats are slightly thickened. Vessel somewhat tortuous. The two Radials are synchronous and equal. The heart does not appear to be acting with great strength.

---

DESCRIPTION OF THE OPERATION.

(28th November, 1903) Patient was duly prepared, anaesthetised, and placed in the horizontal position; a four inch aseptic incision was then made in the middle line below the Umbilicus.

The cyst wall could not be defined, thus the knife went straight into a mass of firm jelly-like material

DESCRIPTION OF OPERATION contd.

which appeared to fill the whole abdominal cavity.

The cyst wall was very friable, - as thin as tissue paper - and adherent to the anterior abdominal wall, from which it had to be separated by the flat of the hand. The limiting cyst membrane had evidently ruptured widely, judging by its apparent incompleteness.

A bucketful of firm, gelatinous matter was squeezed and scooped out with both hands.

At the lower part of the cyst was a mass, the size of a football, composed of transparent greyish jelly contained in a very large number of small cysts, up to the size of a walnut, with delicate transparent walls in which vessels were seen coursing. This mass was delivered by traction and pressure.

The pedicle from the Right Broad Ligament, was caught up in forceps, and tied with silk in the usual manner. Finally it was transfixed and tied with two interlocking ligatures.

The Peritoneal cavity was then flushed out with four gallons of Normal Saline Solution, special attention being devoted to every recess in the Peritoneum. Large quantities of jelly were thus washed away; masses still kept coming up, even after the Peritoneal cavity appeared empty.

DESCRIPTION OF OPERATION contd.

The Omentum was now found to be adherent to, and infiltrated by, some of this gelatinous matter; it was therefore tied, and a large portion removed. The part left behind contained very little fat, and thus was thin and membranous.

Over the whole of the Anterior Abdominal wall, irregularly adherent jelly-like material occurred, causing the Peritoneum to become thickened in large patches, which were red, velvety, and granular.

Some coils of small Intestine, at its upper end, were closely glued together by thick jelly, which could not be stripped off without tearing and making the surface bleed from innumerable small points.

The body of the UTERUS - as large as the fist - had a velvety appearance, with a little adherent jelly, which also enveloped, but did not appear to adhere to, the left Ovary and Tube.

These latter, on close examination, were found to be normal.

The Abdominal wound was closed in three layers, with interrupted silk sutures.

The PATIENT bore the operation well.

OPERATION LASTED 1 hour and 20 minutes.



The gelatinous fluid measured 28 pints, and was generally of straw colour; in parts it had a distinctly reddish tinge.

It appeared to swell and become thinner in saline solution, and gave an alkaline reaction.

---

For the Chemical Analysis of the above gelatinous matter, see later; (page 92.)

NOTES ON THE PROGRESS AND TREATMENT OF  
MARY FLETCHER'S CASE AFTER OPERATION.

November 28th, '03 - DAY REPORT. (from 9 a.m. - 9 p.m)

The operation lasted from 9-10 to 10-30 a.m.

Patient was cold afterwards, but had a good Pulse; this was taken half hourly, and varied from 100 to 104, until 12-30 p.m. when it began to gradually lessen until, at 6 p.m. it was only 88 per minute.

Patient had a great deal of pain before 12-50 p.m. so a hypodermic of morphia (4 m.) had to be given. She was fairly comfortable all the afternoon.

At 8 p.m. 6 ozs. of urine were passed.

1½ ounces of Peptonised Milk was given hourly, by mouth, from 5-30, and caused no vomiting.

The Abdomen showed a distinct rounded fulness in the epigastrium, giving a tympanitic percussion note.

Patient passed no flatus.

---

Nov: 28th, '03 - NIGHT REPORT (9 p.m. - 9 a.m.)

Patient slept from 10-15 p.m. to 12-30 a.m.

(5 m. of Morphia injection again having been administered); from 2-30 to 3 a.m.; and from 4-15 to 5 a.m. She was fairly comfortable during the night, but complained of Abdominal soreness in the morning.

PROGRESS & TREATMENT contd.

Night Report contd. (Nov: 28th)

Half an ounce of Peptonised Milk was given hourly when awake.

No vomiting occurred.

Urine was passed at 6 a.m.

No Flatus was passed.

Distension showed no increase.

Temperature not over 100.

Pulse fairly good.

---

29th November, '03 - DAY REPORT.

Patient passed Flatus well during the day, and micturated in the early morning, but not since.

She complained of intermittent pains all day.

Distension slightly increased - part still extremely tender.

No vomiting. Took food unwillingly.

Dozed at times.

Temperature 100. Pulse fairly good.

Some œdema of feet.

---

29th Nov: NIGHT REPORT.

Patient slept for about  $4\frac{1}{2}$  hours. She has a slight cough, and some Abdominal pain.

The distension was less, and Flatus passed freely

PROGRESS & TREATMENT Contd.

29th Nov: NIGHT REPORT.

during night.

Patient had to be catheterised at 4 a.m. and 12 ozs. of urine were drawn off.

Patient was fairly well in the early morning.

Temperature 99. Pulse good.

---

Nov: 30th - DAY REPORT.

Patient's condition is good.

Pulse 96, full and strong.

Some cough still present. Mistura Expectorans has been given every four hours.

R/\_ Potass Bicarb (gr. 10)  
Ammon Carb, (gr. 2.)  
Vin Ipecac, (m. 5.)  
Tr. Scillae, (m. 15.)  
Aquam ad. (oz. 1.)

Skin over sacrum is bluish and discoloured in spite of the fact that patient was put on a water-bed immediately after the operation.

She still appears extremely thin.

Flatus was passed at 10 a.m. Catheter was used at 5 a.m.

Patient has not complained of much pain; has taken very light food; and dozed a little during the afternoon.

The distension is perhaps a little less marked.

Turpentine Enema was given towards evening.

---

PROGRESS & TREATMENT contd.

Nov: 30th - NIGHT REPORT.

Patient slept from 10 till 11 p.m.; and from 2 till 4 a.m.

Had some Abdominal pain.

Passed Urine at 1-30 a.m.

Had Turpentine Enema, with only slight result.

Slight cough still present.

Flatus passed.

Slept from 5 till 6-30 a.m.

She has less pain, and looks decidedly better this morning.

---

Dec: 1st. '03 - DAY REPORT.

Patient had a very fair day. Slept a little in the afternoon.

Took food well.

Passed Urine and Flatus freely.

The Distension remains the same.

---

Dec: 1st - NIGHT REPORT.

Nepenthe (m.30) administered at 11-45 p.m.

Patient slept for 5½ hours.

Passed Urine and Flatus.

Distension is now not so marked.

Patient fairly comfortable this morning.

PROGRESS & TREATMENT Contd.

Dec: 2nd, 1903 - DAY REPORT.

Patient had a very comfortable day.

No pain.

Still a little distension.

Passed Flatus and Urine.

Food taken well.

The bladder was washed out with a solution of Quinine,  
on account of slight cystitis.

R/- Quininae Sulphatis, 4 grains. )  
Acid Sulphuric Dil. 4 minims. ) M.D.U.  
Aquam ad. 1 ounce. )

---

Dec: 2nd - NIGHT REPORT.

Patient slept 5 hours.

Had a little Abdominal pain.

Took nourishment fairly well.

Distension absent.

Bowels opened, and some Urine was passed.

---

Dec: 3rd - DAY REPORT.

Patient had a very comfortable day, and took food  
well.

Passed Urine and Flatus.

PROGRESS & TREATMENT Contd.

Dec: 3rd - DAY REPORT Contd.

No distension.

Calomel, 5 grains, given towards evening.

---

Dec: 3rd - NIGHT REPORT.

Patient slept for four hours.

Slight pain felt in Abdomen.

Bowels were opened and Urine passed.

No distension.

Food taken well.

---

The Cystitis was gradually overcome by douches of Resorcin solution, 2 gr. to 1 oz. and Quinine Sulphate.

Urotropin, 10 gr., was taken by mouth, t.i.d.

From December 15th, patient improved daily until the date of her DISCHARGE (10th Jan: '04).

At home she is rapidly regaining strength, and has no return of former symptoms.

---

PROGRESS Contd.

STATUS PRAESENS.

(Made 10th January, '04, just before the patient was discharged).

The expression is less anxious, and face is fuller. Complexion is of a much better colour.

Patient is still thin, but shows a marked general improvement.

MAMMAE - Show no change.

ABDOMEN:- Inspection

Linear Cicatrix seen extending from 1" below Umbilicus to  $\frac{1}{2}$ " above Symphysis Pubis. The scar is pale red, and has healed by 1st intention, with well united edges.

There is no bulging in neighbourhood of scar when the patient's head is raised.

The Umbilicus is slightly depressed.

The above mentioned small lentcel-like bodies are still evident, as before.

The Linea Nigra is now only seen above the Umbilicus.

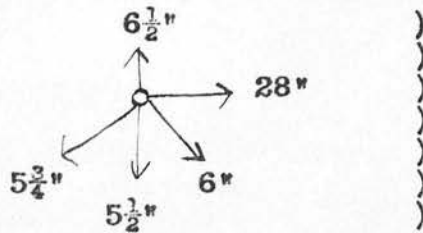
Lineae Albicantes are well marked, especially over flanks.



PROGRESS Contd. - 10th January, 1904.

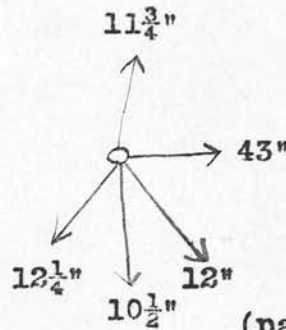
STATUS PRAESENS contd.

MENSURATION



)  
After  
Operation.

Compare this with  
Mensuration before  
Operation, Nov: 27th '03



(page 113)

PERCUSSION - Tympanitic note obtained in all areas.

PALPATION - Skin is very lax over Anterior Abdominal wall; no resistance felt; no undue tenderness.

AUSCULTATION - Nil.

DIGESTIVE SYSTEM - Shows a marked improvement. Appetite is now good, and Patient takes her dinner heartily.

The Bowels are satisfactory.

RESPIRATORY SYSTEM - Nil. Cough quite gone.

URINARY SYSTEM - Now normal. All signs of Cystitis have disappeared. Urine shows no abnormal constituents.

PROGRESS Contd. 10th January, 1904.

STATUS PRAESENS. Contd.

NERVOUS SYSTEM - Shows no abnormality

CIRCULATORY SYSTEM:-

INSPECTION - Pulsation seen in Supra  
Clavicular Region.

PALPATION - Cardiac impulse felt to a slight  
degree all over Praecordia. Apex beat felt  
in fifth Intercostal space  $\frac{1}{2}$ " internal to  
mammary line.

PERCUSSION - Deep dulness.

Right border: 1" to the right of mid sternal  
line.

Upper border: - Upper border of 3rd rib.

Left border: 1" internal to mammary line  
sloping gradually downwards, and outwards  
to the apex beat in fifth interspace,  $\frac{1}{2}$ "  
internal to mammary line.

AUSCULTATION - Cardiac sounds are closed in all areas.

The Pulmonary second sound is still accen-  
tuated.

PULSE:- Not visable; 86. Regular; full; forcible.

Gradual rise and fall.

Apex rather well sustained.

The two Radials are synchronous and equal.

Heart is acting fairly strongly.

November.

December.

Day of Month	24	25	26	27	28	29	30	1	2	3	4	5	6	7	8	9	10	11	12	13	14	
Day of Disease																						
R	42	155	107																			
P																						
T																						
39	145	106																				
36	135	105																				
33	125	104																				
30	115	103																				
27	105	102																				
24	95	101																				
21	85	100																				
18	75	99																				
15	65	98																				
12	55	97																				
Pulse	108	94	96	94	62	88	108	96	88	84	100	88	84	80	80	72	80	76	76	92	68	
Respiration	28	18	20	24	20	18	28	24	24	20	24	28	28	20	20	20	24	16	18	20	20	
Motion	0	0	1	E3	E2	0	0	0	0	0	1	1	1	0	0	E1	1	0	0	1	0	
Urine OZS	28	24+	32+	34+	30+	44+	28	30	34+	30+	14+	20	30	20+	24+	44+	18	20	24	24+	19	
Sp Gr	1026	1024	1026	1024	1024	1023	1023	1022	1020	1020	1017	1014	1014	1012	1014	1013	1014	1013	1012	1012	1012	1014
Reaction	ac.	ac	neutral	ac	ac	ac	ac.	ac	alk	alk	alk	alk	alk	alk	alk	alk	alk	alk	alk	alk	alk	
Albumen	0	0	0	0	0	0	0	0	+	+	+	+	+	+	+	+	+	+	+	0	0	
Blood	0	0	0	0	0	0	0	0	0	0	0	0	0	0	0	0	0	0	0	0	0	0
Sugar	0	0	0	0	0	0	0	0	0	0	0	0	0	0	0	0	0	0	0	0	0	0
Deposit	0	0	0	0	0	0	Trace	Trace	Pus	Pus	Pus	Pus	Pus	Pus	Pus	Pus	Pus	Pus	Pus	slight	0	

Operation

Urea Grams 24hrs. 294, 286, 299.5, 304, 296, 160, 294, 289, 282.4, 290, 110.18, 120, 284, 115, 119, 112, 115, 118.5, 122, 120, 126.5

November 03. 4 Hourly chart

December 03

Day of Month	28	29	30	1	2	3	4
Day of Disease	2,6,10,2,6,10	2,6,10,2,6,10	2,6,10,2,6,10	2,6,10,2,6,10	2,6,10,2,6,10	2,6,10,2,6,10	2,6,10,2,6,10
R	42	155	107				
P							
T							
39	145	106					
36	135	105					
33	125	104					
30	115	103					
27	105	102					
24	95	101					
21	85	100					
18	75	99					
15	65	98					
12	55	97					
Pulse	100	104	108	104	96	96	88
Respiration	16	18	20	24	28	24	24



THESIS ON

PSEUDOMYXOMA PERITONEI.

(WERTH).

The Case of

E M M A C H A T W I N.

Date of 1ST ADMISSION - 21st November, 1900.

Date of 2ND ADMISSION - 18th April, 1903.

DATE OF DEATH - - 22nd April, 1903.

---

Also: POST MORTEM REPORT.

The Case of

E M M A C H A T W I N.

Widow, aged 48 years. Admitted 21st. November. 1900.

COMPLAINT.- Since the last week in August, patient has been suffering from Abdominal Swelling with dull aching pain, also feeling of great weight in the lower abdomen of about two months' duration.

Patient has had three children & one miscarriage.

Labours were all natural; the last occurring in 1882.

CATAMENIA has been irregular during the last 18 months with less loss than usual.

Intervals were sometimes 2 months, and once, as long as four months, but the periods had been quite regular for three months previous to admission.

For two months the amount of urine passed has been very small.

STATUS:- Patient is well nourished, and of a healthy appearance.

A large swelling is seen in the Abdomen, chiefly below Umbilicus and rather more prominent on the right side.

STATUS Contd.

UMBILICUS - is natural; a few large veins are seen over the abdomen. Skin cracks are few, and badly marked.

The ABDOMINAL swelling is a soft elastic, not very well defined tumour, over which the percussion note is dull.

Resonance is obtained in both flanks.

A fluctuation wave is present from side to side of tumour, but it is not very free in character.

PER VAGINAM - The Cervix is found to have a broad opening, and to be fixed a little in front of the middle line of the pelvis.

Behind the Cervix, at the lower end of the Abdominal cavity, a non-movable cyst is felt.

Body of UTERUS not enlarged; somewhat movable. Anteverted, and situated below the cyst.

---

O P E R A T I O N .

November 24th, 1900. A four inch median incision was made below the Umbilicus.

OPERATION Contd. (Nov: 24th, '03).

THE PERITONEUM was thick, firm, and had lost its shiny appearance. A mass of clear, firm gelatinous matter, like calves-foot jelly, was found.

INTESTINES were normal.

A CYST with a very thin wall, and united by loose adhesions to the front of the Sacrum, was brought up from the pelvis, breaking a great deal in the process.

THE PERITONEUM over the UTERUS and BLADDER, was thickened, red and velvety.

THE UTERUS was dragged up into wound with difficulty.

The left appendages, covered with fairly adherent gelatinous material, were attached among themselves, to the side of pelvis and back of Broad Ligament, by old, dense, fibrous adhesions. Practically no bleeding occurred throughout this part of the operation.

At this stage the PATIENT suddenly became cyanosed; breathing almost stopped, and the PULSE got small, but continued slow and regular.

For the latter half of the operation, very



OPERATION Contd.

little anaesthetic was administered.

Subcutaneous injections of Strychnine, and Enemata of Saline Solution, with brandy, were given.

Broken remains of a Multilocular thin walled cyst, filled with thick gelatinous material, were attached to the UTERUS, by means of the Right Broad Ligament. Very firm adhesions were attached to this, and to the side of the pelvis.

It first appeared that the BROAD LIGAMENT was invaded by the cyst, but this was afterwards shewn not to be the case, and that the cyst was but firmly united to its surfaces.

To get below the cyst, the UTERUS had to be removed supravaginally, the left appendages being also removed at the same time. Silk sutures were applied to the left Ovario-pelvic, and the Round Ligament.

The ligaments on the right side were similarly secured, the Bladder stripped down, and the uterine vessels fastened on either side.

The CERVIX was then divided, and its anterior and posterior flaps brought together with silk sutures. A suture on each side then brought the peritoneum over the stump

OPERATION Contd.

and united the Ovario-pelvic Ligament to it.

THE OMENTUM was found to be transformed into a solid gelatinous cake, nearly an inch thick at its free extremity, becoming gradually thinned towards its attachment to the Transverse Colon. A narrow strip, close to the Colon, was free from infiltration; clear and transparent, but had numerous yellowish septa to fit the fibrous tissue. The OMENTUM was ligatured and divided close to its attachment.

The PERITONEAL CAVITY was now flushed out with hot salt solution, and the Abdominal wound closed by three layers of sutures:-

- ( Continuous catgut being applied to the
- ( Peritoneum.
- ( Interrupted silk to the fascia, - and -
- ( Continuous catgut to the skin.

NO DRAINAGE was employed.

There was much shock.

Nutrient Enemata, with  $\frac{1}{2}$  oz. of Rectified spirits of Wine, were given every four hours.

---

PROGRESS AFTER OPERATION.

Four hours after the operation, patient was warm, and comfortable.

PULSE - was 80; and the Temperature normal.

Patient made an excellent RECOVERY and went home WELL on the 20th day.

Incision healed by first intention.

The gelatinous matter removed at operation was clear and transparent, and measured over ten pints.

---

HISTORY OF PRESENT ATTACK.

On September 25th, 1901, Patient was very well and had no complaints to make. An elastic rounded body, the size of a tangerine orange was found to the right of the cervix, to which it was attached; it was also fixed to the side of pelvis.

Six months later, this lump was the same size and character, and the Patient appeared perfectly well. She continued so until about the middle of March, 1903.

On the 3rd of April, she was seen as an out-patient, complaining of severe pain in the lower abdomen, and down the right leg.

HISTORY OF ATTACK Contd. - (AFTER 1st OPERATION)

In the right iliac region, a firm inelastic lump, the size of a foetal head, was found, extending down to the right side of the cervix, which was pushed somewhat over to the left.

The right leg was drawn up and could not be extended.

Scar of former operation was flat and normal.

The Patient appeared cachectic, and stated she had been quite well up to fourteen days previously.

Patient was ADMITTED AGAIN on the 18th of April, '03. Her general condition was decidedly worse.

During the three days before the 2nd operation, the Temperature was almost continuously slightly raised, and varied from 98.8 F. to 100.2 F.

On the morning of the operation, Temperature was 99.4 F. - In the evening 102.4 F.

---

THE SECOND OPERATION.

On the 21st of April, an incision was made on the right side, parallel to, and about 1" above, Poupart's Ligament, and carried down through the Transversalis Fascia.

The subperitoneal space, and the subjacent structures appeared to be normal, although

2ND OPERATION Contd.

slight oedema of the deeper structures was present.

The Patient was now placed in the Trendelenburg POSITION, and the former incision was enlarged by an additional vertical cut at its outer end.

The PERITONEAL CAVITY - was now opened.

Some small collections of greyish gelatinous material were present, inside the right brim of the pelvis, between the coils of intestine.

A gelatinous cyst occurred, the size of a hen's egg, at the posterior part of the brim.

There had been wide-spread growth of the gelatinous cysts, over the peritoneum.

Rather free bleeding occurred from a coil of intestine that had been adherent, so due provision was therefore provided by a small strip of gauze.

THE ABDOMINAL WOUND was closed in three layers.

---

PROGRESS AFTER SECOND OPERATION.

(21st April, '03).

The operation lasted from 9-15 to 10-30 a.m.

There was much shock, and great collapse on return.

Saline Solution per rectum, and Strychnine Injection (m.5) were given at 11 a.m.

Also hot coffee per rectum at 11-30, and a Turpentine fomentation to chest at 11-40.

At 1 p.m. 10 ozs. of Saline Solution were given as before; and also another 5 minims of Strychnine subcutaneously.

Transfusion (2 pints) into the left Median Basilic had to be done at 1-30 p.m.

The following mixture was taken by Patient every four hours.

R/\_ Tr. Digitalis (m.10)  
Tr. Nucis Vom. (m.5).  
Aq. Chloroformi (ad 1 oz.)

3-30 P.M. Respiration 40. deep and free.

Radial Pulse was not felt since operation.

Cardiac 1st sound was sharp and short.

" 2nd sound not heard.

No murmurs. Rate was 144, and regular.

Patient felt warm and comfortable, there was no sickness, and lips were of a good colour.

PROGRESS AFTER 2nd OPERATION Contd.

10.P.M. Transfusion (2 pints) had to be repeated.

2 A.M.(April 22nd, '03) DEATH occurred.

The Radial pulse remaining imperceptible,  
although the body surface had been warm for  
hours.

---

TEMPERATURE.

(1903) 18th April = 100.5 F.  
19th " = 99 F.  
20th " = 100 F.  
21st " = 99.5 F.

---

MOTIONS.

18th April = 0.  
19th " = 2.  
20th " = 3.

---

URINE.

Specific Gravity 1020.

Acid.

Trace of Albumin.

A deposit of Phosphates.

---

POST MORTEM REPORT.

Made April 23rd, 1903.

DEATH 22nd April, '03, at 2 a.m.

Age 50 years.

---

EXTERNAL APPEARANCES - Body is poorly developed, but fairly well nourished.

A curved incision is seen in right iliac and hypogastric regions, four inches long.

RIGOR MORTIS is passing off.

POST MORTEM lividity well marked.

HEART - Weight,  $7\frac{1}{2}$  ozs.

PERICARDIUM:- 1 oz. of clear fluid is present in pericardial cavity.

Heart is small, and the myocardium shows considerable fatty infiltration.

Both ventricular walls, especially the right, are very thin - only 1/10th of an inch thickness of muscle occurs in some parts of the right ventricle.

Both ventricles are moderately dilated.

There is no adherent clot.

The mitral valve is thickened, but competent.



POST MORTEM REPORT Contd.

HEART Contd.

Some atheroma occurs at the base of Aortic valves.

The AORTA is markedly atheromatous.

LUNGS:- Right weighs 14 ozs. Left weighs  $13\frac{1}{2}$  ozs.

PLEURA shows old fibrous adhesions in places and is very firm round the left base.

Lower lobes are congested and oedematous.

Upper lobes are emphysematous and oedematous.

No consolidation found.

No signs of Tubercle.

LARYNX:- Healthy.

ABDOMEN:- Several coils of small intestine are adherent to the right side, and to part of pelvis and pelvic brim; the adhesions being firm, thick, and strongly attached to pelvic wall. Intestines are also adherent to each other, but the adhesions appear thin and more recent.

$\frac{1}{2}$  a drachm of thick creamy pus is seen between adhesions, just over the right pelvic brim.

POST MORTEM REPORT Contd.

ABDOMEN Contd. - The rest of the Peritoneum, outside the pelvis, is healthy, except around the Spleen and Liver, which, in places, adhere to the diaphragm.

The coats of the intestine are shiny; no pus, no ascites, and no metastatic growths are seen.

The OMENTUM had been removed by operation, and only a slight fringe  $\frac{1}{4}$  -  $\frac{3}{8}$ " long is left attached to the Colon, which appears quite healthy, and to the naked eye, shows no signs of metastatic growths.

STOMACH:- is healthy and not dilated. The mucous membrane appears normal.

SMALL INTESTINE - Normal, except for adhesions in pelvis.

LARGE INTESTINE & APPENDIX - Normal, except for adhesions round caecum.

RECTUM:- Normal.

LIVER:- Weighs 39 ozs.

The Capsule shows slight thickening in places, where it is adherent to the diaphragm.

Adhesions are old and moderately dense. In the middle of the anterior surface of

POST MORTEM REPORT Contd.

LIVER Contd.

the right lobe, is a nodule, the size of a shilling,  $1/3$ rd of an inch thick. This projects slightly from the liver surface, is opaque, white in colour, of a cartilaginous consistency, and is irregular in contour.

The rest of the liver substance shows moderate fatty degeneration.

PANCREAS - Healthy.

KIDNEYS - Right weighs  $4\frac{1}{2}$  ozs. Left, 4 ozs.

RIGHT is of normal size; capsule does not strip off readily; kidney substance is pale yellowish, and streaked by red lines.

The Cortex, in places, is irregularly diminished. Moderate fatty infiltration occurs around the hilum.

The Pelvis and Ureter are normal.

LEFT is smaller. Capsule and general kidney substance, as in right.

Pelvis is considerably dilated, and has encroached on the kidney substance, producing atrophy, especially at either end, where the tissue is only about half the normal thickness.

POST MORTEM REPORT Contd.

The Psoas, Iliacus, and Obturator Internus muscles, are almost entirely destroyed, only shreds remaining.

The Transversalis muscle and fascia are also destroyed, so that the transverse processes of the lumbar vertebrae project into the cavity.

The cavity has also penetrated for some distance downwards, behind and between the layers of the abdominal muscles.

The vertebrae and ribs show no caries, the periosteum being intact. Neither are there any signs of hydatid or actinomycotic disease.

N.B.

Perhaps the above described cavity is due to softening of extensive subperitoneal pseudomyxomatous growth.

---

POST MORTEM REPORT Contd.

URETER is dilated to the size of the thumb down to  $1\frac{1}{2}$ " above the bladder, where it becomes involved in the growth, and dense fibrous tissue; ureter here is only the size of crow quill, and its lumen is considerably narrowed.

SUPRARENAL BODIES - Appear healthy.

BLADDER:- Mucous membrane is dotted with black pigment spots, possibly from old cystitis.

SPLEEN:- weighs 3 ozs. and is firmly adherent to the diaphragm. Its upper end is very irregular in shape.

Its substance is fibrous, and the capsule is thickened.

UTERUS & RIGHT OVARY have been removed. The stump of cervix is about  $\frac{1}{2}$ " in depth in front, and 1" behind. The site of the scar is covered by a mass of cystic growth, the size of a small orange, and extends up the right side of pelvis.

On section the growth is seen to be made up of innumerable cysts, varying in size from a pea to a large marble.

The walls of the cyst are exceedingly thin,

POST MORTEM REPORT Contd.

and like tissue paper. They contain a pale jelly-like substance, slightly tinged with yellow. Beneath, and at the side of this growth, is thick, dense, white fibrous tissue.

Scattered over the floor of the Pouch of Douglas, are several sessile cysts, generally with smaller daughter cysts growing from them.

There are two cysts, each the size of a pigeon's egg, in the subserous tissue, beneath the floor of the pouch.

All up the right side of the pelvis, and between it and adherent intestine, are similar cystic growths, with firm fibrous tissue beneath them.

There is a bulging, fluctuating tumour, the size of closed fist, in the right iliac fossa, pushing forward the caecum.

Pressure on this causes some oozing of a thick, pus-like fluid, the colour of crushed strawberry. This oozing takes place at the right pelvic brim, where the intestines are adherent, and near where the mass of cysts was removed at the operation.

POST MORTEM REPORT Contd.

On incision into this tumour, it was seen to consist of a large abscess-like cavity, capable of containing at least a pint.

The cavity extends upwards to the last rib. Internally, it is bounded by the bodies of the lumbar vertebrae .

Behind, and externally, by the lumbar and abdominal muscles.

In front, by sheath of Psoas muscle.

Below, it passes beneath Poupart's Ligament for about an inch; and also passes over the brim of pelvis, along the inner surface of the bony wall, to the floor of the pelvis.

This cavity has a definite thickened wall,  $\frac{1}{8}$ " thick in some places, and  $\frac{1}{4}$ " in others. It is apparently composed mostly of thick, dense, fibrous tissue, but in places, especially in front over iliac fossa, it has a translucent appearance.

The inner surface of the wall is very ragged and rotten.

The contents consist of shreds of softened muscle, and of a thick pus-like fluid, the colour of crushed strawberry.

---

CASES TRANSLATED FROM THE ORIGINAL GERMAN

OF WERTH.



CASES TRANSLATED FROM THE ORIGINAL GERMAN  
OF WERTH.

&

Abstracted to bring out their important points.

DEATH OCCURRED IN ALL CASES DESCRIBED  
BY WERTH, EXCEPTING NETZEL'S.

---

WERTH'S OWN CASE:- (1).

HISTORY:- Patient, aged 37 years. Admitted 28th day  
of July, 1882.

Several attacks of lower Abdominal inflammation occurred before marriage; many previous illnesses have been suffered from.

Patient had two children. The first born in 1873; the second in 1876.

About the 28th of November, a rapid increase of Abdominal circumference occurred.

Sometimes pain was experienced on touching the Abdomen and whilst walking.

For seven weeks prior to admission, a rapid loss of strength was complained of.

STATUS PRAESENS:-The patient is anæmic, and has an appearance of great suffering and emaciation.

THE ABDOMINAL TUMOUR extends to a hand's

STATUS PRAESENS Contd:--

breadth above the Umbilicus and gives large waves of fluctuation.

THE TUMOUR is defined above by palpation; laterally by percussion.

A dull tympanitic note is obtained in the lowermost parts of the Abdomen.

THE UTERUS has a broad connection with the Tumour and a distinct grating is obtained over the posterior fornix.

OVARIOTOMY:--was performed on Aug 4th, 1882, by Litzmann and Werth.

The Tumour - the lower part of which was intraligamentous - reached right up to the left edge of the Uterus and had a connection with it, extending for a considerable depth underneath the posterior portion of pelvic Peritoneum.

Douglas's Pouch was pushed to the right and permeated by adhesions in which were embedded the otherwise normal right sided adnexa.

The tumour was composed of thin walled cyst cavities, about the size of the first, containing gelatinous matter.

No perforation of the cyst wall could be found.

OVARIOTOMY Contd:-

The same masses spread through the whole Abdominal cavity, some were free and easily movable, whilst others clung to the surfaces of the organs.

THE OMENTUM was dark red; easily tearable; and had extensively grown on to the Tumour.

The Serosa of the Gut, of a dull red felt colour was covered by a flaky exudation.

The Tumour was enucleated and a stump made of the Broad Ligament.

The defect in the Peritoneum was drawn together by catgut sutures in Douglas's Pouch.

AFTER OPERATION:-Fairly good progress was made with no marked rise of Temperature, but convalescence was very slow. Acute attacks of heart weakness occurred.

Sudden death took place on the 26th of August, from an embolus in the Pulmonary Artery.

(Patient was a weakened individual, having suffered from numerous illnesses, and repeated hæmorrhages from varicose veins).

POST MORTEM:- Uterus was large and hard; on its left and posterior aspects it was intergrown with

POST MORTEM Contd:-

its environs.

The defect in Douglas's Pouch was closed in the form of a scar; a few catgut sutures remained in situ.

Right Ovary was normal.

The Abdominal cavity contained several cups of jelly-like matter.

The posterior Abdominal wall, the serosa of all the adjacent organs and especially the loops of the small intestine, were all covered by an adherent gelatinous deposit, in this were seen numerous newly formed blood vessels.

The Spleen was coated by a similar layer.

The Liver was attached to the Diaphragm on the free surface of which, this tenacious jelly also occurred.

The Omentum and Pelvic Peritoneum exhibited similar characteristics.

---

CASES TRANSLATED FROM THE ORIGINAL GERMAN.

OF WERTH.

(26) PEAN'S CASE. NO.(1).

HISTORY:- Patient, aged 54 years.

Nine years ago, colicky pains without diarrhoea or vomiting were felt. Six similar attacks with dull pains in hypogastrium have since occurred. In 1870, a tumour, in the left Iliac Fossa was observed, the size of a hen's egg, painless, hard and movable. The Abdomen swelled gradually, the pains became continuous, and the general health grew visibly worse.

PEAN was consulted at the beginning of 1871.

STATUS:- There was much cachexia and considerable emaciation.

Feverish, fluctuating Temperature became marked at night.

Lasting, continuous pains and Dyspnoea were present.

Dulness was found chiefly in the Epigastrium reaching laterally to the Anterior Superior Iliac Spine on either side. No difference was obtained when the patient was rolled over on her side.

No distinct fluctuation was obtained even in the upper part of Abdomen.

STATUS Contd:-

UTERUS movable, anteverted and walled in amidst the masses filling Abdomen.

PUNCTURE - Exudation of gelatinous fluid.

LAPAROTOMY:- Performed on the 27th of July, 1871.

15 Litres of gelatinous dark brown material streaked with blood were withdrawn from the Abdominal cavity. No closed cyst could be found. A diverticulum was formed by the Peritoneum, which in places appeared covered by pseudomembranes.

The Serosa of the intestines was strongly injected, part of the gut was free and movable; but that portion which had lain in the true pelvis was caked in cystic matter.

The existing cavities had extremely thin walls; ranging from the size of a pea to that of an almond.

All the Abdominal organs were surrounded by gelatinous matter.

The Liver and Spleen were found covered by thick pseudomembranes.

Uterus, Tubes and Ovaries showed nothing abnormal.

AFTER OPERATION:- General state was better.

The pain and cachetic appearance disappeared, but the Abdomen gradually began to swell again.

The stitch holes became fistulous and through these, gelatinous matter continually flowed out.

The patient was now dismissed.

---

CASES TRANSLATED FROM THE ORIGINAL GERMAN  
OF WERTH.

PEAN'S CASE. NO. (2).

LAPAROTOMY:- Two Kilogrammes of gelatinous matter were scooped out of the Abdominal cavity, mostly from between the intestines.

During the next 10 days there was considerable improvement in patient's condition. Oozing out of the colloid substance now occurred through fistulous stitch holes. Three days later Gangrene, which manifested itself in a few hours, occurred in the whole of the lower Abdominal wall laying bare the intestines.

There were no signs of Peritonitis and no loss of Appetite.

A continuous exudation of the gelatinous matter occurred.

Gut paralysis was also present.

DEATH:- Death from exhaustion took place on the 21st. day after the operation.

POST MORTEM:- Peritoneum appeared to be lightly injected.

Large intestine was distended and overladen with faeces.



POST MORTEM Contd:-

No trace of any colloid material nor of the membranes that enclosed the Peritoneum and large intestine at the time of operation could be discovered.

---

N. B. THIS CASE is obscure, and there is suspicion of a gross error.

(WERTH).

---

TRANSLATED FROM THE ORIGINAL GERMAN

(OF WERTH).

(77) MENNIG'S CASE.

PATIENT aged 46 years. Nine children. Last child born 1st January, 1875.

After first birth in 1854, Parametric exudation occurred with rupture into the rectum.

From July 1878, there has been a marked swelling of the Abdomen. Since Autumn, pains in Abdomen and back, and a feeling of weight upon the chest has been complained of.

MENSTRUATION, which was formerly irregular, has lately been quite regular. The intervals, however, have been shorter, and amount somewhat increased.

PUNCTURE was twice tried, but gave no result.

ON ADMISSION - Abdomen was enormously and evenly distended.

Circumference at Umbilicus was 116 centimetres.

PERCUSSION NOTE was tympanitic in the Epigastrium, and in the anterior portion of the left Hypochondrium; everywhere else it was dull.

The Cyst Wall could not be defined by palpation.

PER VAGINAM & PER RECTUM -

THE UTERUS slanted, and was displaced to the left.

Cervix was felt close behind the Symphysis Pubis.

Fundus over-reached the left border of Pubes.

THE TUMOUR could not be defined from the Uterus.

OVARIOTOMY - 21st February, 1879. (ESMARCH ).

Brown gelatinous matter flowed from the former puncture.

On further opening of the wound a smooth walled tumour came out, accompanied by a small bowlful of yellow brown liquid.

The Abdominal Cavity appeared to be filled with this fluid, which was scooped out and soaked up with sponges.

THE TUMOUR had a mesial opening, (the size of a 4/- piece, and evidently of an old standing date), from which gelatinous matter spontaneously escaped.

Numerous daughter cysts filled with gelatinous matter were noticed.

THE TUMOUR was clothed with Serosa and extended between the layers of the Broad Ligament, raising and unfolding the adjacent peritoneal sections.

OVARIOTOMY. Contd.

The whole, with its peritoneal connections, was removed, leaving free the Vasa Iliaca and Psoas.

The whole peritoneal surface, parietal and visceral was covered by a rough gelatinous lumpy layer up to  $\frac{1}{2}$  a centimetre in thickness.

AFTER OPERATION - There was moderate collapse; Asthenia, and a rapidly rising Temperature.

On Feb: 22nd, the Pulse was rapid. Meteorismus, Vomiting, and a certain amount of Pyrexia were also present.

TEMPERATURE was 38. 4 C.

DEATH occurred at 3.0 a.m. February 24th.

---

POST MORTEM - Professor Heller (-).

Gelatinous masses of considerable size are seen in Abdominal Cavity.

The Peritoneum is everywhere studded with Pseudomembranes in layers of varying thickness.

These all enclose lumps, which stand out on the Peritoneum, and are met with on the Serosa of the Gut, Stomach, and lower surface of the Diaphragm.

Gelatinous layers, in parts, are permeated by numerous large and small hæmorrhagic spots, especially on the Anterior Abdominal wall.

The Right Ovary, Tube, and greater part of the Broad Ligament, are missing.

A broad stump laced in by Ligatures, occurs on the Uterus.

The Left Ovary shows many adhesions. It contains a fresh Corpus Luteum, and also a Cyst, the size of a cherry.

The Liver is much disfigured by thick gelatinously degenerated Pseudomembranes; it is firmly united to the Diaphragm.

Above, behind, and between the Liver and Diaphragm, a considerable quantity of loose lying jelly is found. This gives a distinct mucin reaction.

---

CASES TRANSLATED FROM THE ORIGINAL GERMAN

OF WERTH.

(59) BEINLICH'S CASE. NO. (1).

(Beinlich was the first in Germany to publish 2 cases).

CASE (1). Died on the third day.

CASE (2). Died on the fourth day.

HISTORY:- Patient, aged 50 years.

Formerly always healthy.

Menopause 9 months ago.

Had one child, when 22 years of age.

Since December, 1873, patient has had an Abdominal tumour, which has gradually increased in size; the growth has always been more marked on the right side.

General emaciation occurred at the same time.

STATUS:- Patient appeared very thin and had a suffering appearance.

Abdomen filled with an ovoid non-resilient tumour.

Slight fluctuation obtained.

Intestines were only palpable in the right Hypochondrium for an area of about 4 inches.

STATUS CONTD:-

Largest circumference = 111 centimetres.

Tumour could not be traced Per Vaginum.

LAPAROTOMY:-

JULY, 1874.

The thin walled cyst was injured by the knife and through the aperture thus made, a thick, light yellow, moderately clear and very tenacious gelatinous substance exuded.

The non-adherent cyst was ruptured in various places and came from the right ovary.

Cleansing of Peritoneum was difficult and imperfectly accomplished.

A portion of the gelatinous matter could not be removed from the Visceral and Parietal serosa, as it formed an integral part of the whole Peritoneal covering.

This firmly fixed layer, as well as the small cystic formations on the gut, contained granules, evidently originating from hæmorrhages.

Drainage was established by Douglas's Pouch.

The cyst consisted of four compartments with easily tearable partitions.

CYST CONTENTS were chiefly composed of Mucin and a small quantity of Alkali Albumin.

CONTENTS weighed 23 pounds.

THE TUMOUR with its adherent remains weighed  $2\frac{1}{4}$  pounds.

AFTER OPERATION:- Much blood stained serous fluid exuded from the drainage tube on the day following the operation. The tube, however, soon became blocked. General collapse, without any special reactionary symptoms of Peritonitis or rise of Temperature, soon came on.

DEATH occurred on the third day.

POST MORTEM:- The parietal and visceral Peritoneum was found thickly covered by a gelatinous hæmorrhagic, fibrinous matter.

Large masses of yellow jelly in the form of small cysts were found clinging to the visceral serosa. These were especially found between the Liver and Diaphragm, enclosed by pseudomembranes.

THE UTERUS was considerably enlarged.

THE RIGHT OVARY was wanting.

THE LEFT OVARY was occupied by a Dermoid cyst, the size of a walnut.



TRANSLATED FROM THE ORIGINAL GERMAN

(OF WERTH)

BEINLICH'S CASE, NO. 2.

HISTORY:- Patient, aged 26 years.

Menstruation at regular intervals since 14 years of age.

DYSMENORRHOEA in latter years.

Patient has had two children; the latter was born in May, 1874.

During the last pregnancy much pain was felt across the small of the back and in left side. A marked abdominal swelling noticed at this time.

Rapid growth of tumour occurred after birth of last child.

STATUS:- Marked emaciation.

Suffering anaemic appearance.

Abdomen occupied by a colossal non-resilient tumour, fluctuating only in certain directions and places.

Greatest circumference = 106 Centimetres.

Diaphragm stands out prominently.

STATUS Contd.

THE TUMOUR can only be indistinctly felt  
Per Vaginanam.

OVARIOTOMY - November 1st, 1874.

WEIGHT OF TUMOUR = 1-lb.

It was loosely adherent, unilocular, and had thin walls.

WEIGHT of emptied Jelly = 30-lbs.

The Abdominal Cavity presented the same features as in Case 1.

Drainage was employed.

There was but slight reaction and scarcely any rise of Temperature; vomiting, however, occurred.

Increasing and nonpreventable collapse became evident.

DEATH took place on the 4th day from exhaustion, without any signs of sepsis.

---

POST MORTEM:- Gelatinous masses covered the whole Peritoneal surface, which, in places, showed a small cystic formation.

A very thick coating of gelatinous material occurred on the Liver and Pancreas.

POST MORTEM Contd.

Hæmorrhages were seen in the Excavatio Vesico Uterina, as well as in the gelatinous mass on the Anterior Abdominal Wall.

On the lowermost portion of the Left Costal Margin, a jelly-like œdema occurred, closely simulating the above masses.

---

TRANSLATED FROM THE ORIGINAL GERMAN.

(OF WERTH)

---

(58) ATLEE'S CASE.

In Atlee's case the Post Mortem showed that the Loops of the gut were covered by a membranous exudation; when this was torn, single Loops could easily be drawn apart.

The PERITONEUM covering the contiguous surfaces of these Loops, was seemingly intact.

---

TRANSLATED FROM THE ORIGINAL GERMAN

(OF WERTH)

---

(7) SCHRODER'S CASE.

In Schroder's Case of "Myxoma of the Peritoneum and the Left Ovary", Laparotomy was successfully performed.

DEATH, however, occurred from loss of strength caused by the continuous growth of this new formation on the Peritoneum.

---

TRANSLATED FROM THE ORIGINAL GERMAN

(OF WERTH).

---

(8) NETZEL'S CASE.

(Netzel's case proves that Pseudomyxoma Peritonei after complete Ovariectomy, does not invariably lead to DEATH).

---

HISTORY:- Patient, aged 44 years. Single.

Twelve months previously, she noticed a rapidly growing Tumour in the lower Abdomen, causing marked emaciation.

ON LAPAROTOMY - a large quantity of free-lying sticky fluid was seen, containing gelatinous lumps.

The Tumour was free and had very thin walls.

(Netzel proposes the name "Ovarian Myxoma" for this kind of Tumour.)

Yellow gelatinous matter, totally different from the usual colloid ovarian fluid, was found in this cyst.

THE PEDICLE was long and thin.

TRANSLATED FROM THE ORIGINAL GERMAN

(OF WERTH).

---

NETZEL'S CASE Contd.

The other Ovary was in an atrophic condition.

The Tumour was covered by the GREAT OMENTUM which was infiltrated with gelatinous matter.

Numerous gelatinous little knots were found all over the Peritoneum.

Two days after the OPERATION, symptoms of Intestinal Obstruction occurred.

RECOVERY:- Patient was sent home five weeks afterwards in a perfectly healthy condition.

---

In this case as with a similar one in 1893, no signs of carcinomatous disease could be found under the microscope.

In two similar cases the Microscope showed distinct evidence of Alveolar Carcinoma.

One patient, however, was quite healthy five years after the operation.

STRASSMANN'S CASE.



TRANSLATED FROM THE ORIGINAL GERMAN

(30) STRASSMANN'S CASE.

HISTORY - Patient, aged 20 years.

Menstruation regular.

Two normal deliveries.

Ten months before admission Patient had:-

1. Attacks of Nausea and vomiting.
2. Swelling of the Abdomen and thighs.
3. Gradual increase in the Abdominal circumference.
4. Occasional attacks of Dyspnoea.

---

STATUS:- Marked emaciation and oedema of both Iliac regions.

The Abdomen also oedematous; its veins are in a varicose condition.

The greatest Abdominal circumference = 138 centimetres.

The Percussion Note is everywhere dull.

Fluctuation is obtained and Cystic resistance felt.

The Vaginal vault is deeply pressed down.

PULSE 120, but otherwise Normal.

Diagnosis = Cystoma Ovarii.

LAPAROTOMY - Large free lying gelatinous masses found in Abdominal Cavity.

CYST uninjured by knife, reached to the costal margin; upper part is rigidly adherent to the Transverse and partly to the Descending Colon.

Whole OMENTUM - embedded in the gelatinous masses.

UTERUS of normal size, but elevated by the gelatinous masses filling pelvis.

TUBES - unchanged.

FRONTAL CYST WALL had ruptured, and masses of Myxomatous matter had entered the Abdominal Cavity.

INTESTINES were freed, and the Adherent Omentum resected.

---

TUMOUR CONTENTS - Jelly, hairs, teeth and dermoid matter generally.

Torn Cyst Wall and Abdominal wound were duly sewn up.

---

POST MORTEM - Intestines often found adherent.

Double Hydronephrosis existed; also Atelectasis of both Lungs.

POST MORTEM Contd:-

No signs of Sepsis.

Whole of Douglas' Pouch filled with a tumour the size of a child's head. Outwardly it appeared myxomatous; inwardly a distinct multilocular Ovarian Cyst was seen.

BLADDER and TUMOUR had grown on to the UTERUS.

The much adherent tumour reached the parametrium.

The masses were easily wiped off the Liver, Intestines and Diaphragm, but could not be removed from the Peritoneum.

---

DONAT'S CASE.

TRANSLATED FROM THE ORIGINAL GERMAN.

(2) DONAT'S CASE.

HISTORY:- Patient, aged 38 years. Admitted 23rd June, 1885.

Previous health fairly satisfactory, - has suffered from Meningitis and Measles.

Menstruation commenced when 16 years of age, and has been regular since.

From December, 1884, slight Menorrhagia has occurred, but no Dysmenorrhoea.

Patient has had three children without artificial aid. Last, nine years ago.

Gradual increase of Abdomen observed since December; producing no discomfort; at times, after walking, pains have been felt in the right side of Abdomen.

Patient considered herself pregnant at the time.

During last weeks there has been much languor, with gradual loss of strength and falling appetite.

STATUS PRAESENS - Patient is of medium height. She is much run down.

The Abdomen is covered by loose brownish skin; only a small amount of subcutaneous fat is present.

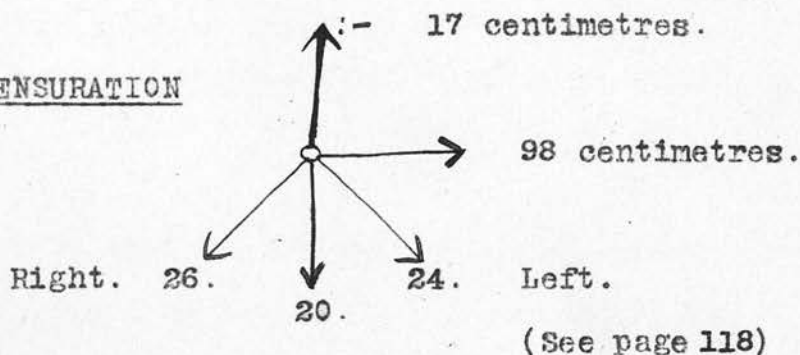
Temperature - Normal.

PULSE - 72. Strong, and moderately full.

BREASTS - Small and flabby; yielding no secretion on squeezing.

AREOLAE - Moderately pigmented.

MENSURATION



TUMOUR feels soft, elastic, and fluctuates markedly in all directions.

PERCUSSION note is tympanitic in the neighbourhood of the Tumour, but dull in both Lumbar Regions.

PALPATION - No pain is caused even on strong pressure.

INTEGUMENTS over Tumour are thin, and easily movable.

VULVA & MONS VENERIS are moderately oedematous.

STATUS PRAESENS Contd.

URINE - Contains no Albumin.

PER VAGINAM:-

UTERUS - Pressed forward; upright; is not freely movable.

Sound =  $3\frac{1}{2}$ ". Lowermost part of Tumour can be felt in the posterior fornix.

TRUE PELVIS - Empty.

DIAGNOSIS = Cystoma Ovarii.

PROGNOSIS of operation favourable.

OPERATION performed 25th June, 1885.

ON LAPAROTOMY - Rich, light yellow, gelatinous lumpy masses came through the Abdominal incision.

The Tumour appeared free from all adhesions, and covered by a thin layer of gelatinous matter.

THE DIAGNOSIS was now altered to Pseudo-myxoma Peritonei (WERTH) with ruptured cyst.

No result followed puncture of the Cyst.

The Cyst Wall was incised, and masses of a yellow opalescent tenacious material exuded.

The Cyst was emptied and drawn through the Abdominal wound.

ON LAPAROTOMY Contd.

A rupture admitting two fingers, and evidently of old standing date, occurred in the wall; the gelatinous contents had thus escaped into the Abdominal Cavity.

No adhesions nor trace of Ligaments or Tubes could be seen. The lowermost part of the Tumour was deeply inserted between the layers of the Broad Ligament.

The whole was duly removed, the Thermo-cautery and Iodoform being applied to the stem.

Large quantities of gelatinous matter were removed with sponges and hands; this appeared of looser consistency than the Cyst contents.

Most of the masses chiefly occurred:-

1. In the Vesico-Uterine Pouch.
2. In the Pouch of Douglas.
3. In the lateral recesses of Abdominal Cavity.
4. Below the Liver.
5. In the neighbourhood of the Spleen.
6. In the Kidney regions.

The parietal Peritoneum and Intestines were covered by a 1 to 3 millimetre layer of transparent gelatinous matter, permeated in



ON LAPAROTOMY Contd.

parts with firm, dark red Ecchymoses and vascular branching trabeculae. This jelly could not be separated from the Gut.

The same layer occurred on the UTERUS and its adnexa.

The serosa of both was much swollen, and even folded; it was of a deeper red than that covering the loops of Intestines.

Two, 3 to 4 centimetre long, pedunculated hydatiform bladders were removed from the Peritoneum on the anterior surface of the Uterus.

The Left Ovary had a covering of gelatinous matter, but appeared normal.

The Abdominal Cavity was washed out, - first with a 2% Saline Solution, and then with one of Salicylic Acid (1-500) at 38.C.

The thin gelatinous layer covering the parietal and visceral Peritoneum had received a whitish coating.

The Tumour was a multilocular glandular cystoma, containing daughter cysts with thin septa richly supplied with blood.

LAPAROTOMY Contd.

WEIGHT OF CYST = 900 grammes.

WEIGHT of gelatinous masses from the Cyst &  
Abdominal Cavity = 8.300 grammes.

TOTAL WEIGHT of new formation, therefore,  
= 9,200 grammes.

---

PROGRESS OF PATIENT AFTER OPERATION.

Patient bore the operation well, but vomiting soon occurred.

Tongue moist, but much thirst was complained of.

Slight rigors occurred towards evening.

Temperature = 39.6 C.

Pulse. = 96.

Patient's general condition remained the same for the next two days; vomiting continued, and appetite was quite absent.

Pulse remained at about 100.

Temperature did not rise above 38.5 C.

From the 27th of June, Milk, Wine, and Beef Solution had to be given per rectum.

AFTER OPERATION Contd.

On the 28th and 29th of June, frequent attacks of violent vomiting occurred; this had a bilious odour and appearance; at times it was decidedly feculent.

The Abdomen showed moderate distension.

There was much exhaustion and restlessness; also frequent evil smelling eructations.

Patient was apathetic, showing high inanition, and a dirty brown discolouration of the skin.

On 1st July, the appetite returned, and bowels were opened several times during the day; thin watery stools were passed. A small quantity of nourishment was given by mouth, but towards evening feculent vomiting again commenced.

Nutrient enemas, with a little opium, were again had recourse to; teaspoonfuls of Cognac were administered hourly by mouth.

On 3rd July, gut occlusion was thought present, owing to persistent vomiting. The stomach was twice washed out, and emesis finally ceased.

On 4th July, the bowels again opened; the following day patient was able to take a

little milk by mouth.

On the night of July 6th, (11 days after the Operation), severe vaginal bleeding occurred, evil smelling masses coming away.

One large lump in an advanced stage of decomposition, on section, showed a number of small cavities ranging up to the size of a pea.

Under the Microscope this lump was shown to consist of:-

1. Connective tissue.
2. Non-striped muscular fibres.
3. Cells with nuclei.
4. Atrophied Blood Corpuscles.

The Vagina was filled with congealed blood; from its walls more of these lumps were removed.

The Posterior Fornix was quite caked by these masses.

The Uterus could not definitely be defined; as it was pushed to the left. Bleeding stopped during that day, but appeared the next.

Three hourly vaginal douches of a 3% Carbolic lotion, stopped the bleeding and removed the smell.

AFTER OPERATION Contd.

Patient soon regained strength.

Temperature ranged from 37.4. to 38.C.

The Pulse remained at about 100; once, however, during an attack of hæmorrhage, it reached 128.

N.B. - DONAT observed no signs of collapse as mentioned in other described cases.

More nourishment was taken each day; the worn, famished appearance gradually disappeared; **there** was a daily increase of strength.

Palpation of the Abdomen caused no pain. The wound had healed by first intention.

Peristaltic movements, especially in the neighbourhood of the Large Intestine, were distinctly seen.

On July 18th, Patient got out of bed and walked about for a short time without help.

PER VAGINAM - The Posterior Fornix was represented by a scar-like shrinking, into this, the Vaginal portion of the Uterus was drawn.

The Uterine body was small, anteverted, and movable.

PER VAGINAM Contd.

The Vaginal Wall was smooth anteriorly, and showed per Speculum, a granulating purulent area, the size of a five shilling piece.

---

R E C O V E R Y

Patient was DISCHARGED on the 1st of August.

N.B. - This necrotic process occurring in the Vaginal Wall and Posterior Fornix, accompanied by haemorrhage and putrefaction, had, without doubt, been caused by spreading thrombosis.

(DONAT).

---

RABBIT DIED.

N.B. With the idea of forming some estimate of the effects and Peritoneal changes produced by the presence of the above described gelatinous material in the healthy Abdominal Cavity,

DONAT & SANGER inserted a quantity into the Abdomen of a female rabbit. The animal died five days afterwards.

(Vide Histology Rabbit's Peritoneum page 72 ).

---

WESTPHALEN'S CASES.

( TRANSLATED FROM THE ORIGINAL GERMAN.

(4) WESTPHALEN'S CASES.

CASE NO.1 - Widow, aged 67 years. Five children.

Menopause, twenty years ago.

Prolapse trouble for four years, with difficulty in Micturition.

Since December 1898, in connection with INFLUENZA, Patient observed a gradual increase in the size of her Abdomen.

Pains in both sides of lower Abdomen.

On the 15th June, puncture was tried, with no result.

The OPERATION itself was performed 12-13 days after this.

STATUS:- The Patient is poorly nourished, and old..

MAMMAE - Nil.

ABDOMEN is markedly distended, especially laterally.

PERCUSSION gives a tympanitic note, right up to epigastrium.

Flabby fluctuation is obtained.

There is total prolapse of VAGINA and UTERUS.

The Pouch formed by the prolapse contains fluid.



TRANSLATED FROM THE ORIGINAL GERMAN.

WESTPHALEN'S CASE

No.1 Contd.

LAPAROTOMY - 28th June.

Abdominal integuments were very thin.

Peritoneum was thick, and of a glassy appearance.

When it was opened, tenacious gelatinous lumps of a yellowish colour, oozed out.

A Multilocular Cystoma, the size of a man's head, and belonging to Right Ovary, was tied with silk and cut away.

The Left Ovary was small and atrophic.

The Left Tube in its lateral part, contained a soft tumour, the size of a walnut, which was removed.

ABDOMINAL CAVITY was cleared of its pseudomucinous contents, which, on a microscopical examination, nowhere showed a firm organic connection with the Peritoneum, not even in the depth of the prolapse.

Only a small amount of bleeding occurred during the wiping out of Abdominal Cavity.

THE OMENTUM was slimy and swollen. The

TRANSLATED FROM THE ORIGINAL GERMAN.

WESTPHALEN'S CASE

No.1 Contd.

Serosa of the small Intestine was in the same state, and slightly injected.

PROCESSUS VERMIFORMIS - Normal.

The PARIETAL PERITONEUM was thickened anteriorly.

The UTERUS and LIGAMEN TOUS stumps were sewn on to the Anterior Abdominal wall, and the wound closed.

---

RECOVERY:- Patient made a good recovery. On the 14th day she got up, as Hypostatic Congestion of the Lungs, was feared.

On the 24th Day she was DISCHARGED, without any sign of Ascites.

---

TRANSLATED FROM THE ORIGINAL GERMAN.

WESTPHALEN'S CASE NO. 2.

A washerwoman. Aged 65 years.

Swelling of Abdomen noticed from May, 1898; but since January, 1899, Abdominal circumference grew so rapidly that colossal dimensions were soon reached.

The Patient, nevertheless, worked until admission, (28th May).

STATUS:- Patient is of medium size, old, anaemic, and emaciated.

Much arterio sclerosis is present.

The Abdomen is enormously distended, and integuments tense.

PERCUSSION is everywhere dull.

FLUCTUATION is firm and elastic.

LAPAROTOMY - Parietal Peritoneum was much thickened, and in a gelatinous condition.

Large quantities of round jelly-like lumps, the size of a hen's egg, and of a greenish amber and opaque yellow, colour, occurred.

Less tenacious semi-fluid colloid masses were also found. After all were removed, a multilocular tumour, the size of a man's

TRANSLATED FROM THE ORIGINAL GERMAN.

WESTPHALEN'S CASE No.2 Contd.

LAPAROTOMY Contd.-

head, with very thin walls, and many ruptures, remained. The CONTENTS of this tumour were similar to the lumps found in the Abdominal Cavity.

Tumour showed a very vascular intergrowth with the UTERUS, the PARIETAL SEROSA of true pelvis, and with the SIGMOID FLEXURE.

The adhesions and the moderately broad stem, were removed. The true pelvis was almost completely filled with tenacious masses, permeated by meshy adhesions; these could not be separated from the Serosa without force and hæmorrhage.

The Right Adnexa appeared completely buried.

The upper portion of Abdominal Cavity, was also filled with colloid lumps, which clung to the Parietal serosa, leaving the surface of the small Intestine more or less free. These clung more firmly to the recesses of Abdominal Cavity, filling them up, and levelling the whole.

The frontal belly wall, in places, was much

TRANSLATED FROM THE ORIGINAL GERMAN.

WESTPHALEN'S CASE NO.2 Cd.

LAPAROTOMY Contd. -

reddened. The firmer lumps of colloid material, adhered so closely to the Peritoneum, that they almost appeared to be new formations.

The Vermiform Appendix was represented by a sausage shaped tumour, 16 centimetres long, by 6-7 centimetres broad. The gelatinous contents shone through its very thin walls.

OMENTUM. - A gelatinous looking tumour, 15 centimetres, by 3-4 centimetres thick.

It had a frog-spawn, glassy appearance, and a fairly smooth surface.

Abdominal wound was then closed.

DEATH:- PATIENT DIED three days after the operation.

There were symptoms of gut-paresis, without appreciable rise of Temperature.

ABDOMEN was again opened. In abdominal cavity, a large quantity of cloudy, evil smelling exudation was found, in which small slimy lumps were suspended.

The Small Intestine was injected.

TRANSLATED FROM THE ORIGINAL GERMAN.

WESTPHALEN'S CASE NO.2 CONTD.

The Peritoneum was of a dull colour, with almost no deposit upon it.

The SPLEEN was large and soft, and showed layers of deposit, the thickness of the finger, round its capsule. The deepest layer was similar to the capsule itself in consistency and appearance, but towards the surface shiny lumps were seen, embedded in a loosely formed network.

THE UTERUS was senile and atrophic.

THE CERVIX was patent.

THE ADNEXA of the RIGHT SIDE was deeply embedded in jelly.

The RIGHT TUBE was slightly thicker than the left, and its fimbriated extremity appeared swollen and patent.

Its lumen was empty.

THE RIGHT OVARY was the size of a hen's egg. On section, walnut shaped cavities were seen; these were filled with the same gelatinous material as found in the tumour of the left side.

---

MACDONALD'S CASES.

(29) MACDONALD'S CASE NO. (1).

Patient, aged 44 years. Admitted, September, 1884.

COMPLAINT - Pain in right side, with a swelling in Abdomen.

---

HISTORY OF PRESENT ATTACK.

No trouble until February, 1884.  
Slight uneasiness and swelling then occurred. Patient thought it due to Pregnancy, but menstruation had been regular and the mammae were unchanged.

---

PHYSICAL EXAMINATION.

Abdominal circumference = 39 inches. Free fluid thrill was felt all over Abdomen. Dull percussion obtained in flanks. Increased resistance felt in the lowermost part of the Abdomen.

UTERUS low in the pelvis, but no definite tumour could be felt per Vaginum.

SOUND  $2\frac{1}{2}$  INCHES tending upwards, and to the left.

ASPIRATOR yielded only 1 or 2 drops of gelatinous matter.

DIAGNOSIS - burst Ovarian Cyst with



gelatinous contents.

LAPAROTOMY - 10th September, 1884.

Large quantity of jelly-like material was observed.

Tumour was found to spring from the Right Broad Ligament.

Left Ovary was normal.

Tumour was tapped with no result.

An incision was made, and thick, gelatinous stringy matter of great tenacity, pulled out in ropy masses.

Tumour was ligatured and removed.

WEIGHT of Tumour and contents = 20-lbs.

---

RECOVERY - Uninterrupted recovery took place, patient being dismissed on the 3rd of October, all evidence of Abdominal fluid having disappeared.

TUMOUR had a rounded perforation in its upper part. A roughening and thickening of the parietal Peritoneum with some extra reddening of the visceral layer was seen.

During the operation a peculiar oblong, thick walled Cyst ( $2\frac{1}{2}$ " long by  $\frac{3}{4}$ " in diameter) was noticed, attached by a sort of mesentery to a portion of the intestine on the right side.

This appeared very like a distended condition of the Caput Caecum Coli, and hence was not removed.

---

MACDONALD'S CASE.

No.2.

Patient aged 58 years. Admitted 9th October, 1884.

COMPLAINT:- Swelling of Abdomen and a tumour which protruded through Vagina.

HISTORY:-About one year before admission patient first noticed a swelling above the Pubes, which gradually became larger growing upwards in the middle line, until it reached the pit of the stomach. Lately it seems to have fallen from its greatest height.

Patient is now unable to work: she has frequently had to lie on her back during the last six months.

Six months ago she suffered from diarrhoea; a swelling came down the Vagina at that time.

PHYSICAL EXAMINATION:- Abdomen extended to the size of full-term pregnancy. Distension more marked on the right side.

Umbilicus prominent.

Abdominal circumference = 39 inches.

Tumour feels smooth, firm and more irregular on the right than left side.

No friction is felt nor heard.

OPERATION:-- Abdominal Cavity was opened and a large quantity of gelatinous matter of a deep amber colour found.

A Transverse rent appeared in upper portion of the Tumour, which showed no adhesions and seemed connected with the right Broad Ligament by a thick short pedicle.

Left Ovary was Normal.

Tumour contents were extremely fibrous in character; it was removed without hæmorrhage from the pedicle.

A dense cyst 3 inches long by  $\frac{3}{4}$  inches in diameter was seen in relation to a portion of the Intestine, but forming no part of it.

Cyst was removed; the end nearest the bowel appeared blind. It had thick, apparently muscular walls lined by mucous membrane and contained glairy fluid. On its outer aspect were two or three shiny cyst-like bodies.

RECOVERY:-- Patient recovered well after the operation and passed flatus the next day.

The deep stitches were removed on the 6th day; union was perfect.

DISMISSED cured on the 15th day of November.

PHYSICAL EXAMINATION Contd:--

Tumour is movable under the Peritoneum.

Percussion Note dull in the middle line to  $1\frac{1}{2}$  inches above the Umbilicus, after that it is clear.

Some resonance is obtained in the left flank, passing up to the Iliac Fossa, where it vanishes, also far behind in the right flank; everywhere else it is dull.

When patient turns on left side, the mass sinks away to the left and gives resonance in the left groin.

FLUCTUATION and fluid thrill occurs in both right and left sides, but not from right to left.

PER VAGINAM:-- A large prolapse of bowel is felt in the shape of a vaginal rectocele.

Uterus is displaced upwards and towards the left.

Tumour, which does not descend into the pelvis, can be felt with difficulty, high up above the brim.

The sound,  $2\frac{1}{2}$  inches passes upwards & forwards.

---

POINTS OF SPECIAL INTEREST

IN

:MACDONALD'S TWO CASES.

1. Recovery in both cases.
  2. Both cysts had ruptured.
  3. An ovoid intestine-looking cyst seen in both.
  4. Cysts were tensely filled with fluid; had thick walls and were apparently connected directly with the Intestine by a sort of mesentery.
  5. The contents of the tumours were extremely tenacious and when extravasated adhered in a stringy fashion to the coils of Intestines.
  6. A membranous meshwork appeared to be formed round the bowels.
  7. No further change in the Peritoneum had occurred other than some extra thickness, redness and marked roughening.
-

HERR MOND'S CASE.

TRANSLATED FROM THE ORIGINAL GERMAN.

(103). HERR MOND'S CASE.

Patient, aged 50. Single.

HISTORY - Admitted in an extremely miserable worn-out condition, November, 1901.

Anamnesis and Laparotomy showed the presence of a large Ovarian Tumour, which had ruptured into the Abdominal Cavity.

N.B. - - Rupture occurred three weeks before admission.

---

OPERATION - (The operation was performed under Chloroform, notwithstanding the collapsed state of Patient).

The Abdominal Cavity was filled with thick glue-like gelatinous masses.

Peritoneum was leathery and permeated with gelatinous deposits.

The true Pelvis was also filled with tenacious mesh-like matter, which could only be removed with great difficulty from the Peritoneum.

The jelly evidently originated from a left-sided Ovarian Tumour, which had a small



OPERATION CONTD:--

plate-like rupture on its Posterior Wall.

Fully 16-lbs of gelatinous matter were scooped out with the hands.

The UTERUS, extending to the UMBILICUS, and the Tumour were removed supravaginally.

The UTERUS was soft, hard and lumpy, so that Malignant Disease could not be excluded. It was covered by a glossy deposit.

The operation lasted  $\frac{3}{4}$  of an hour.

---

PROGRESS -- Recovery for the first few days quite satisfactory.

PULSE 80. Good.

TEMPERATURE - Normal.

Flatus passed on second day.

On the fourth day Patient became worse.

PULSE 100 - Temperature normal.

On the 6th & 7th days, condition remained much the same, except for signs of increasing weakness.

ABDOMEN - soft and impressionable.

PALPATION caused no pain.

DEATH - - On the eighth day death occurred from exhaustion, without any symptoms of sepsis.

---

ABDOMEN OPENED - Wound had healed by first intention.

No peritonitis.

The surface of Intestines was slightly injected, but not adherent to the parietes.

The true Pelvis remained filled with gelatinous matter, in which the Uterine stump appeared embedded.

This presented a healthy appearance.

The rupture in the Cyst Wall was distinctly of an older date.

---

TOTH'S CASES.

TRANSLATED FROM THE ORIGINAL GERMAN.

(14) TOTH'S CASES.

TOTH - mentions two such cases of women, aged 43 and 51 years, respectively.

BOTH WERE CURED.

Both Ovarian Cysts had ruptured.

The whole Peritoneal surface was covered by a 3-4 millimeter layer of tenacious gelatinous substance.

The Cyst was double walled in one case.

---

BACKER'S CASE.

TRANSLATED FROM THE ORIGINAL GERMAN.

( 9 ) BACKER'S CASE.

BACKER - successfully operated on a woman aged 35 years.

A tumour, the size of a man's head, occupied the lower Abdomen.

ON LAPAROTOMY the Peritoneum was found covered by adherent gelatinous matter.

PERITONEUM was strongly injected.

CYST WALL was very easily torn, but no existing fissure could be seen.

PATIENT RECOVERED FOUR DAYS AFTER the operation.

All symptoms of Peritoneal trouble had then disappeared.

---

REUDER'S CASE.

TRANSLATED FROM THE ORIGINAL GERMAN.

(10) REUDER'S CASE.

REUDER - had a case of a woman aged 27 years. She complained of Abdominal pain of some months' duration.

Three months ago, swelling of the Abdomen was noticed, causing difficulty in breathing.

Patient was examined under an Anæsthetic, but no diagnostic conclusion was arrived at.

ON LAPAROTOMY, the whole Abdominal Cavity was found to be filled with gelatinous tenacious matter.

The true Pelvis contained cyst-like tumours. These, and the gelatinous matter, presented an inflamed appearance, a capillary network of vessels permeated the whole.

These tumours were not removed, on account of threatened bleeding, but the gelatinous matter in the Peritoneal Cavity was scooped out.

The Cysts contained the same gelatinous matter.

OPERATION gave much Ease to the Patient.



TRANSLATED FROM THE ORIGINAL GERMAN.

REUDER'S CASE Contd.

When dismissed, she had a cachectic appearance.

REUDER - mentions two other cases. In one, the gelatinous matter weighed 40 pounds.

---

LEWITZKI'S CASE.

LEWITZKI'S CASE. (23)

G. G. Lewitzki (of Kiew) describes a case of Pseudo-myxoma of the Peritoneum and Omentum.

A large multilocular Cyst of the Right Ovary was present. The Cyst had ruptured spontaneously with a resulting Peritonitis and high temperature.

LAPAROTOMY - In addition to the Cyst, a blood-like exudation mixed with colloid material was found.

The Peritoneum was thickened and permeated with haemorrhages and sago-like new-formations. All were covered by tenaciously adhering gelatinous matter.

Cystic growths occurred throughout the whole Omentum, which had to be resected.

The UTERUS and Left Appendages appeared normal.

The large multilocular Ovarian Cyst was easily removed after loosening the adhesions.

Convalescence was uninterrupted.

On DISMISSAL, neither Ascites nor any resistance in the Abdominal Cavity could be found.

---

BETTMANN'S REPORT

-- OF --

PROFESSOR PAWLIK'S CASE.

(56) BETTMANN'S REPORT  
OF  
PROFESSOR PAWLIK'S CASE.

A Cystic Tumour of the Ovary was removed from a woman aged 65 years.

The Abdominal Cavity was found filled with gelatinous masses.

DEATH - - Peritonitis developed, and the Patient DIED.

The AUTOPSY was made by Professor Obrzut.

Body of medium height; mesogastrium distended; a scar extends in median line from the Umbilicus nearly to the Symphysis Pubis.

Basilar ganglia of Brain somewhat oedematous.

In the Abdominal and pelvic cavities a large quantity of fibro-purulent exudation exists. Intestines distended. Serosa injected.

Omentum majus thickened, covered with diffuse gelatinous mass, which also coats the root of the mesentery.

Parietal Peritoneum thickened, pigmented and covered with many nodular gelatinous masses.

Spleen and Liver enlarged and soft.

Stone in pelvis of Right Kidney.

Gelatinous masses cover all the viscera of the true Pelvis.

Remaining Ovary small, fibrous.

---

PATHOLOGICAL ANATOMICAL DIAGNOSIS

Myxadenoma Ovarii dextri extirpatum per laparotomiam;  
peritonitis chronica adhaesiva et perulenta acuta;  
myxoma peritonei; urolithiosis; sepsis.

N.B. - - It will be seen that, apart from the acute peritonitis, the Post Mortem revealed the usual conditions - gelatinous masses covering all the Abdominal and pelvic viscera. This case, however, is unique in that its Microscopical examination SHOWED BOTH TRUE MUCOID TISSUE and HYALINE SUBSTANCE; NEITHER OF THESE have been found in any previously described case.

---

GENERAL DEDUCTIONS.

GENERAL DEDUCTIONS.

Pseudomyxoma Peritonei from a clinical standpoint is malignant in nature, for with the single exception of NETZEL'S case, all those recorded by WERTH ended fatally.

In BEINLICH'S cases no symptoms of Septic Peritonitis followed ovariectomy, nevertheless, both patients died on the third and fourth day respectively, from heart failure.

ESMARCH'S patient also succumbed, but in this case symptoms of Peritonitis became manifest after the operation accompanied by a high temperature, especially towards the end.

Acute sepsis, therefore, might have accounted for Death in this case, although strange to relate, the Post Mortem examination showed no signs of suppurative peritoneal inflammation.

SCHRODER (Kurzer Bericht uber 300 ovariectomien Berlin Klinische Wochenschrift 1882 Nr.16 ).

mentions a case of Myxoma of the Peritoneum and of the left Ovary in which, after a successfully performed operation, the patient died from Asthenia, the result of a continuous new Formation on the Peritoneum.

In WERTH'S case the retarded convalescence was conspicuous, notwithstanding the absence of fever following operation.



Marked attacks of heart failure were noticeable just before Death. A constitution weakened by former ailments, evidently hastened the end.

Marked emaciation, generally a prominent feature with all large ovarian cystomata, has been mentioned in nearly every case. WERTH, therefore, is fully justified in thus attributing the fatal result to a persistent lowering of vitality.

In most cases, with the exception of WERTH'S own, a comparatively long space of time elapsed between the spontaneous rupture of the tumour and the operation.

During this interval the Peritoneum must have suffered greatly in function, as might also be gathered from the highly advanced state of organisation exhibited by the adhering gelatinous masses.

The results of the Post Mortem examination in all these cases agree:-

A rich aggregation of gelatinous matter is found in the upper portion of the Abdominal cavity, the thickest deposit occurring on the Peritoneal covering of the neighbouring organs - Liver, Spleen and under surface of the Diaphragm. This is explained by the fact that the fluid contents move towards the Diaphragm. It is also clear that when once arrived in the roomy portion between Diaphragm and underlying organs; these masses can settle down comparatively far removed from the disturbing influence of Peristalsis.

The Peritoneal lesion in the vicinity of the Diaphragm must of necessity cause a marked functional disturbance, especially as in the upper portion of the Abdominal Cavity those organs, specifically endowed with absorptive powers and most concerned in the maintenance of a regular interchange of serous fluid, occur.

It is just these organs that one finds affected to the highest degree.

We are now in a position to understand how it is, that, in addition to the gelatinous masses, unabsorbed clear serum is often found on Post Mortem examination.

The large quantity of jelly usually found at the Autopsy, following a former laparotomy might find explanation in the fact, that varying pressure conditions occur during the interval of life following the operation.

Why should such a marked reaction on the part of the Peritoneum be caused by this chemically inert jelly?

When other cysts rupture, a quick absorption generally occurs (except in the case of Dermoids) without causing any inflammation of the Peritoneum worth mentioning. Such does not occur even after their contents have remained in contact with the serosa for some considerable time as must surely be the case, where there is prolonged oozing into the Abdominal Cavity.

This is explained by WERTH in the following manner:-

"The gelatinous matter contains chemical bodies, especially Mucin, (Vide BEINLICH'S and MENNIG'S cases, pages<sup>(72)</sup>). which is not soluble in water and therefore cannot disappear from the Abdominal Cavity in the usual diosmotic manner. By virtue of their tenacious nature these masses cannot even be got rid of through the larger lymph channels, as blockage would soon occur. The masses, therefore, by means of the motus peristalticus, remain spread out over the whole Abdominal Cavity and act as foreign bodies on the Peritoneum, causing irritation and ultimate production of a new formation of vessels and connective tissue.

These spread through the adherent jelly and grow into the serosa, altering even its chemical composition. Portions of the Peritoneum thus disappear and are replaced by this new formation".

#### WHY RECOVERY?

DONAT'S case was pre-eminently successful. He attributes its favourable course to the following:-

The operation was fortunately performed just as the Peritonitis was at its birth.

The patient's vitality, therefore, was not

lowered to too great an extent.

The usual digestive disturbances, the result of insufficient peristalsis, were gauged by the degree of emaciation present, this, however, was only noticed two weeks before operation.

ON LAPAROTOMY:-

The cyst and the greater part of the gelatinous masses were removed. The Peritoneum was thus relieved from further irritative inflammation and a chance of septic infection to a certain extent excluded.

The gelatinous deposit on the visceral Peritoneum - until it finally became absorbed, - would to a large degree retard peristalsis. This accounts for the difficulty in absorption of nourishment during the first week of convalescence.

The frequent vomiting, exclusive of Chloroform effects, was caused by peritoneal irritation combined with insufficient peristaltic movement.

The symptoms of Intestinal Obstruction that occurred, viz:- feculent vomiting and constipation might be taken for "Paralytic Ileus".

Washing out of the Stomach here proved of real value, such would not have been the case,

if the deposit on the visceral layer of the Peritoneum had not gradually become absorbed and so altered, that a greater capacity for peristaltic movement became possible. As already stated Intestinal movements were visible two weeks after operation; during this time the Patient certainly gave the impression of marked inanition.

A point not well brought to the fore by many Authors is the great rapidity of growth, which tumours display. Definite statements concerning this are made in nine cases. In two, (BAUMGARTEN (37) and SCHLEGTENDAL (64) the growth was slow. In the other seven the time between first symptoms and operation varied from several weeks; (KORN (20) case operated upon by Leopold) to eight months, - WERTH'S case was operated upon four months first symptoms. RUNGE'S (21) and one of BEINLICH'S (59) five. The high mortality has been referred to by all writers. NETZEL ( 8 ) thinks that early operation will lower the death rate.

In examination of reported cases, however, one cannot see that too much time was, as a rule, allowed to elapse before laparotomy was performed.

A Dermoid combination of the Pseudomyxomatous cyst has only occurred in three recorded cases, viz:- those of

1. GUNZBURGER. ( 3 )
2. STRASSMANN. ( 30 )
3. WENDELER ( 16 )

One-third of all recorded cases have followed rupture of Ovarian cysts. (STRASSMANN).

Nothing is known about the probability of recurrence.

The cyst is generally one-sided and frequently pedunculated. Sometimes, however, intraligamentous development occurs.

Mucin has almost always been found; this filters with much difficulty and tends to block the Stomata of the Peritoneum, thereby greatly hindering absorption.

---

In conclusion, I beg to heartily thank my chief, Dr. Thomas Wilson, Honorary Obstetric Officer and Gynaecologist to the Birmingham General Hospital; and Mr. Hewetson, Honorary Assistant Gynaecologist, for access to the Ward Notes on the Case of Emma Chatwin, and for their kindness in placing Mary Fletcher's Case entirely at my disposal for study and research.

General Hospital,

B I R M I N G H A M.

23<sup>rd</sup> / April 1904.

B I B L I O G R A P H Y .



B I B L I O G R A P H Y.

1. WERTH:-- Arch. f. Gyn., 1884. Bd. 24. p.100.  
Invented term "Pseudo-myxoma Peritonei".
2. DONAT:-- Arch F. Gyn. 1885. Bd.26. Heft.3.p.478.
3. GUNZBURGER:-- " " " 1899. " 59. " 1.p 1.
4. WESTPHALEN: " " " 1899. " " " 3.p.632.
5. GEYL:-- " " " 1887 " 31. p.373.
6. PFANNENSTIEL: " " " 1890 " 38.pp. 407-492.
7. SCHRODER:--(1) " " " 1882. No. 16. Kurzer  
Bericht über 300 Ovariectomien Berlin  
Klinische Wochenschrift.  
" (2) Krankheiten der weiblichen Geschlecht-  
sorgane 4 aufl S. 366.
8. NETZEL:-- Hygiea, 1882-1883. Nord. Med. Arch.17.  
4. No. 28. Reviewed in Centralbl. f.  
Gynak., 1883, p. 102; 1884, p.95; 1885,  
p. 144; 1886. p. 582. Also in Virch  
Jahresber. 1886. 2. p. 593.
9. BACKER:-- Centralbl. f. Gynak., 1896. No 28.p.747.
10. RUEDER:-- " " " 1896. " 6.p.173.  
Geburtshilfliche Gesellschaft zu Ham-  
burg. 9th. October. 1894.
11. LOMER:-- )  
12. GRAPOW: )  
13. SCHUTZ: )  
" " " " " "
14. TOTH:-- Centralbl. f. Gynak., 1896. Bd. 28. p747.
15. REH:-- " " " 1898. " 32. p886.
16. WENDELER:-- " " " 1897. " 11 p310.  
(Nonatschrift für Geburtshilfe und  
(Gynakologie. Bd. 3. Heft 3. ).
17. GOTTSCHALK: Central. f. Gynak., 1901. Bd.25. p.726.
18. FRAENKEL E. " " " 1902. " 7. p.188.
19. SWIĘCICKI: " " " 1885. pp.691-693.  
Zur Casuistik d. Pseudo-myxome Peri-  
tonei.
20. KORN:-- Centralbl. f. Gynak. December. 1885. Bd51.
21. RUNGE:-- " " " 1887. Bd. 15.  
pp. 233-237. Petersburg. Klin.  
Wochenschr., 1885. No. 51.
22. LANGER:-- Centralbl. f. Gynak." 11. p. 241. 1887.
23. LEWITZKI:-- " " " 1901. No.50 p. 1383.
24. PETERS:-- " " " 1900. " 43.p.1151.
25. OLIVER J. Liverpool Med. Chir. Jour. 1891. Vol 11.  
pp. 266-268.
26. PEAN:-- Tumeurs de L'Abdomen et du Bassin, Paris.  
1880.
27. EICHWALD:-- Ann. Chem. Pharm. Bd. 134. p. 177. ff.
28. PASSAVANT:--Virch Arch., Bd. 8. p. 40.
29. MACDONALD:--Edin. Med. Jour. May & June. 1885.  
Two cases.
30. STRASSMANN: Zeitschr f. Geburtsh. und Gyn. 1891.  
p. 319.
31. STRATZ:-- Zeitschr f. Geburtsh, und Gyn. Bd. 26.  
Heft 1.

## B I B L I O G R A P H Y. Contd.

32. OLSHAUSEN:-- Die Bosartige Geschwulste d. Eierstocke. Zeitschr. f. Gyn., 1886. Bd. 12. Zeitschr. f. Geburtsh. und Gyn. 1885. Bd. 11 pp. 238-245. Three cases.
33. COHN:-- Zeitschr. f. Geburtsh. und Gyn. 1886. Bd. 12. Bosartige Geschwulste d. Eierstocke.
34. DESIDERIUS) 1890. Bd. 18. p. 106. Zeitschr. f. 34a V. VELITS) Geburtsh. und Gyn.
35. BEIGEL:-- Virch Arch. 1869. Bd. 45. p. 103.
36. H. COBLENZ:-- " " 1880. " 82. p. 268.
37. BAUMGARTEN: Ein Fall von einfachem Ovarialcystom mit Metastasen. Virch Arch., 1884. Bd. 97. pp. 1-11. Quotes two similar cases in the practice of Dohrn.
38. ARNDT:-- Virch Arch., Bd. 41. p. 465.
39. RECKLINGHAUSEN:-- (a) Tageblatt d. 52ten Versamml. d. Naturforsch. u. Aerzte in Baden-Baden, 1879. p. 259; (b) Virch Arch. Bd. 35. p. 318. (c) Virch Arch., Bd. 84; (d) Arch. f. Ppth., 10. 84; (e) Allg. Path. d. Kreisl. Deutsche Chir., 1883.
40. WIEGER:-- Virch Arch., 1879. Bd. 78.
41. PETERS:-- Virch Arch., 1882. " 87. pp. 477-509. Ueber Hyaline Entartung bei d. Diphtheritis.
42. ARNOLD:-- Virch. Arch., Bd. 51. p. 441. Bd. 87. pp. 114-157. Ueber Tuberkulose d. Lymphdrusen u. Milz.
43. VALLAT:-- Virch Arch., 1882. Bd. 89. p. 193. Ueber Fibrinose od. Hyaline Degeneration im Tuberkel u. Gummi.
44. RAEHLMANN:-- 1882. Virch Arch., Bd. 87. pp. 325-335. Ueb. Hyaline u. Amyloide Degen. d. Conjunctiva. (b). Knapp's Arch. f. Augenheilk. 10. p. 129.
45. UHTHOFF:-- Virch Arch., 1881. Bd. 86. p. 322. Ein Fall v. ungewohnlicher Degen. d. Menschl. Conjunctiva.
46. OELLER:-- Virch Arch., 1881. Bd. 86. pp. 329-359. Ueber Hyaline Gefass Degen. als Ursache einer Amblyopie Saturnina.
47. HOLSCHEWNI+Virch Arch., 1888. pp. 552-568. Ueb. KOFF:-- Hyaline Degen. d. Hirngefasse.
48. SLAVJANSKY: Virch Arch., 1870. Bd. 51. p. 490.
49. WALDSTEIN:-- Virch Arch., 1885. " 85. p. 430.
50. DREYFUSS:-- " " 1888. " 113. pp. 554-558.
51. KRIEGE:-- " " 1889. pp. 64-84. Hyaline Degen. d. Haut durch Erfrierungen.
52. TAKACS:-- Virch Arch., Bd. 75. p. 431. Ueb. Multiple Neurome.
53. VIRCHOW:-- Virch Arch., Bd. 89. p. 384.
54. WALDEYER:-- " " " 32. p. 543. 1865.
55. RITTER:-- " " " 36. p. 591.
56. BETTMANN:-- Ann. Jour. Med. Sc. Oct. 1893. Vol. 106. p. 444.
57. GROHE:-- Virch Arch. Bd. 26. p. 303. 1863.
58. ATLEE:-- General and Different Diagnosis of Ovarian Tumors, 1873. pp. 372-374.
59. BEINLICH:-- Charite Annalen. 1874. Bd. 1. Two cases reported in detail; a third mentioned.

B I B L I O G R A P H Y. Contd.

60. MAYER:- Charite Annalen. 1880. Bd. 7.  
 61. VIRCHOW:- " " " " Bd. 6. p.663.  
 Gesamm. Abhandlungen, Frankfurt a. M.  
 1856. pp. 67. & 327. Handb. d. spez.  
 Path. u. Therap., 1854. 1. p. 304.  
 Virch. Arch., Bd.89. p.384.  
 62. THORNTON:- Trans Path. Soc. Lond., 1877. vol. 28.  
 p. 189.  
 63. EVE:- Trans Path. Soc. Lond., 1886, " 37.  
 64. SCHLEC-  
TENDAL:- Berl. Klin. Wochenschr. 1886. Nos. 2 u 3;  
 Zur Malign. d. Ovarial-Kystome.  
 65. MADELUNG:- Berl. Klin. Wochenschr. 1881, No.6.  
 66. BILLROTH:- Arch. f. Heilk., 1862.  
 67. NEELSON:- " " " " 1876. Bd.17. p.119.  
 68. WAGENMANN:-Virch. Hirsch. Jahresber. 1889.Bd.2.  
 p.547 .  
 69. KAMOCKI:- Virch. Hirsch. Jahresber. 1889." 2.  
 p.547.  
 70. HJELT:- Virch. Hirsch. Jahresber. 1871. p.181.  
 71. WEIGERT:- (a) Deutsch. med. Wochenschr., 1885,  
 Nos. 44-47; (b) Fortschr. d. Med.,1887,  
 No.7, pp.193-203; (c) Fortschr.d.Med.,  
 1887., No.8, pp.228-232.  
 72. SCHAEFFER:-Fortschr. d. Med., Bd.6. No.18. 1888.  
 73. HANAU:- Fortschr. d. Med. No. 12. 1886.No.3  
 1887.  
 74. EBERTH u.  
SCHIMMEL-  
BUSCH:- (a) Die Thrombose u. s. w. Stuttgart,  
 1888; (b) Fortschr. d. Med., 1886, No.  
 13; 1887. Nos. 6 and 15.  
 75. SMITH:- On Antiseptic Ovariectomy, Med. Times &  
 Gazette, May, 1878.  
 76. COLRAT:- Lyon Med., December, 1879, cited from  
 Schlegltenda;.  
 77. MENNIG:- Ueber Myxomatose Entartung des Bauch-  
 fells, u. s. w; Diss. Inaug., Kiel,1880.  
 78. NEGRI:- Annali di Ostetr., January & February,  
 1885.  
 79. THIERSCH:- Der Epithelkrebs, 1865, p.41.  
 80. SCHUEPPEL:-Untersuchungen ueber Lymphdrusen Tuber-  
 kulose. Tubungen. 1871.  
 81. GRANCHER:- Compt. Rend., 1872.  
 82. LANGHANS:- Untersuchungen b. d. Menschliche  
 Placenta. Arch. f. Anat. u. Phys., 1877,  
 pp.188-260.  
 83. SCHULTZ:- Vernarbung von Arterien nach Unterbin-  
 dung u. Verwundung. Diss. Inaug.,  
 Berne, 1870.  
 84. P. MEYER:- Role de l'Hyalin dans les Aneurismes.  
 Arch. d. Physiol. Norm., 1880.  
 85. VOSSIUS:- (a) Ueber Amyloid Degen. d. Conjunctiva.  
 Ziegler's Beitrage, 4. p.337, et seq.;  
 (b) Ueber Hyaline Degen. d. Conjunctiva.  
 Ziegler-Nauwerck Beitrage,1889. 5.  
 pp.293-328.  
 86. E. NEUMANN:-Ueb. d. Anwendung v. Pikrocarmin, u.s.w.  
 Arch. f. Mikrosk. Anat., Bd.18.p. 130.

B I B L I O G R A P H Y. Contd.

87. PORIWAEIO:--Michel's Jahresber. f.Opth., 1886.  
88. LEBER:-- Arch. f.Opth., Bd. 25., 1. p.301.  
89. REYMOND:-- Annali di Ottamologia, 1875, 4. p.349.  
90. OBRZUT:-- Origine des Produits Inflammatoires dans la Maladie de Bright. Arch. de Med. exper., May, 1889, p.429.  
Le Role du Sang dans la Genese des Produits Inflammatoires . Paris, 1889; Rueff et Cie., Editeurs, p.21.  
91. WILD:-- Beitr. zur Kenntniss der Amyloiden u. Hyalinen Degen. des Bindegewebes. Ziegler-Nauwerck's Beitr., 1886, 1. pp.175-199.  
92. SCHULE:-- Zeitschr. f. Psychiat., 1868. Bd.25. p.449.  
93. ADLER:-- Arch. f. Psychiat., Bd.5. p.346.  
94. ROKITANSKY:--Denkschr. der Wien. Akad. 1849. 1. Allgem.Wien. med. Zeit., 1859. 32.  
95. GRIFFITH:-- Lond. Obstet. Trans., 1886. 28. p.180.  
96. BAMBERGER:--Wiener med. Wochenschr., 1872. Nos.1&2.  
97. KLEBS:-- Allg. Pathol. Jena, 1889. pp.684-686.  
98. KLOB:-- Path. Anat d. Weibl. Sexualorgane, 1864.  
99. BREUS:-- Wien. med. Wochenschr., 1878, No. 28.  
100. HERMAN:-- Diseases of Women. 1903. p. 751.  
101. HART AND BARBOUR:-- Gynaecology. 1897. p. 251.  
102 EICHWALD Ann. Chem. Pharm. Bd. 134. s. 177. ff.  
103 MOND Centralbl. f. Gynak. 1st March, 1902.  
Geburtshilfliche Gesellschaft  
Zu. Hamburg, 17th December 1901.