

MORPHOLOGICAL STUDIES ON THE REPRODUCTIVE SYSTEM OF THE MALE FOWL

(Gallus domesticus)

By

MUDDATHIR D. TINGARI

B.V.Sc. (Khartoum), M.Sc. (Colorado)

A thesis presented for the degree of Doctor of Philosophy in the  
Department of Veterinary Anatomy, Royal (Dick) School of Veterinary  
Studies, University of Edinburgh.

September, 1971.



# ABSTRACT OF THESIS

Name of Candidate ..... Muddathir Darderi Tingari  
Address ..... Department of Anatomy, Royal (Dick) School of Veterinary Studies, Edinburgh 9.  
Degree ..... B.V.Sc., M.Sc. Date ..... 11th June 1971  
Title of Thesis ..... Morphological Studies on the Reproductive System of the Male Fowl  
..... (Gallus domesticus)

The genital tract of the male fowl was investigated by dissection, micro-injection, microradiography, and conventional histological methods. The distribution in the tissues of lipids, glycogen, some oxidative enzymes and cholinesterases was investigated histochemically. The intrinsic cholinergic and adrenergic innervation was also examined. A fine structural study of the epithelial lining of the efferent ducts was made and the ductus deferens was ligated with the object of studying the resorption of testicular fluids and the fate of unejaculated spermatozoa.

The fowl testis has no mediastinum or tubuli recti. The seminiferous tubules therefore lead directly into the rete testis which is drained by the ductuli efferentes. The latter are continued into the connecting ductules which open into the ductus epididymidis. The ductus epididymidis and ductus deferens are considered to be merely different segments of the same duct which increases in diameter from its beginning, at the cranial end of the epididymal region, to its caudal end in the pelvis. Thus, the avian epididymal region might be regarded as equivalent to the caput epididymidis of scrotal mammals; the main part of the ductus deferens and its dilated regions are considered analogous to the corpus and cauda respectively.

Lipids in the form of neutral, phospholipids and free fatty acids were detected in the seminiferous tubules and epithelial cells and lumina of the excurrent ducts. Small amounts of mucopolysaccharides were also detected but glycogen was absent. All oxidative enzymes studied were present; their highest activity was in the ductuli efferentes. True cholinesterase was confined to the neural structures and the basal parts of the epithelial lining of the large connecting ductules, ductus epididymidis and ductus deferens. Pseudocholinesterase was found throughout the cells of the same regions.

A rich supply of cholinergic and adrenergic nerves was found particularly in the lateral aspect of the epididymal region and along the ductus deferens.

Ultrastructurally, at least five different cell types were identified in the duct system, namely (1) low cuboidal cells lining the rete testis, (2) and (3) ciliated and non-ciliated, type I cells lining the ductuli efferentes and narrow connecting ductules, (4) non-ciliated, type II, cells lining the wide connecting ductules, ductus epididymidis and ductus deferens, and (5) basal cells found mainly with type II cells. The rete cells have an imbricated arrangement and their fine structure indicates a secretory function. The ciliated cells possess motile cilia and microvilli; they are non-secretory but they may play a role in the resorption of fluids. Type I cells carry microvilli and have electron-dense worm-like structures in the apical cytoplasm;

*Use other side if necessary.*

the structure and possible function of these structures were discussed. The main structural features of type II cells were similar to those of a protein secreting cell. They possess an abundance of distended rough and transitional endoplasmic reticulum, a well developed Golgi complex and dense secretory granules some of which were seen at the luminal margin. The basal cells have a large dense irregular nucleus and scanty cytoplasm containing a few organelles and fibrils; they are closely related to nerve endings in the subepithelial tissue.

Spermatozoa are taken up by the surface lining cells of the male tract in normal males. After ligation of the ductus deferens, its lumen contained many disintegrating spermatozoa and other cell debris; all the lining cells, except the basal, appear to phagocytose intact spermatozoa and cellular debris. Macrophages containing spermatozoa were found in the lumina of the ducts, in the subepithelial tissue and wedged between the basal lamina and the surface epithelia.

The functional implications of these findings in relation to secretion into the seminal plasma, storage of semen, resorption of testicular fluids, movement of spermatozoa along the duct system, disposal of unejaculated spermatozoa, and emission have been discussed.

TO THE SOULS OF MY PARENTS

DECLARATION

I hereby declare that the Thesis embodies the results of my own special work, and that it has been composed by myself.

TABLE OF CONTENTS.

	Page
SUMMARY	iv
1.0 INTRODUCTION	1
2.0 MATERIAL AND METHODS	4
2.1 Architecture and Histology of the Excurrent Ducts	4
2.2 Histochemistry	4
2.2.1 Glycogen and Mucopolysaccharides	5
2.2.2 Lipids	5
2.2.3 Oxidative Enzymes (Glutamic, succinic, lactic and Glucose-6- phosphate dehydrogenase)	6
2.2.4 Cholinesterases	6
2.3 Intrinsic Innervation of the Reproductive Tract	7
2.4 Electron Microscopy	8
2.5 Ligation of the Ductus Deferens	8
3.0 RESULTS	10
3.1 The Structure of the Excurrent Ducts as Revealed by Dissection and Light Microscopy	10
3.1.1 Gross Features	10
3.1.2 Histological Features	10
3.1.3 Luminal Contents	15
3.1.4 Mesonephric Vestiges	15
3.2 Histochemistry	17
3.2.1 Distribution of Glycogen, Mucopolysaccharides, Lipids and Dehydrogenases	17
3.2.2 Distribution of Cholinesterases	21

	Page
3.3 Intrinsic Innervation of the Reproductive Tract	23
3.3.1 General Distribution	23
3.3.2 Cholinergic Innervation	25
3.3.3 Adrenergic Innervation	25
3.3.4 The Fine Structure of the Intrinsic Nerve Supply of the Excurrent Ducts	27
3.4 Fine Structure of Epithelial Cell Types lining the Excurrent Ducts	31
3.4.1 Low Cuboidal Cell	31
3.4.2 Non-ciliated Type I Cell	34
3.4.3 Non-ciliated Type II Cell	39
3.4.4 Ciliated Cell	43
3.4.5 Basal Cell	46
3.5 Distribution of the Epithelial Cells Lining the Excurrent Ducts	48
3.6 Effects of Ligation of the Ductus Deferens	49
3.6.1 Gross Observations	49
3.6.2 Light Microscopy	50
3.6.3 Electron Microscopy	50
4.0 DISCUSSION	53
4.1 General Structure and Histology	53
4.2 Histochemistry	55
4.2.1 Glycogen, Mucopolysaccharides, Lipids and Dehydrogenases	55
4.2.2 Cholinesterases	58
4.3 Innervation	61
4.3.1 The General Intrinsic Innervation	61
4.3.2 The Fine Structure of the Innervation	63

	Page
4.4 The Fine Structure of the Epithelial Cells	66
4.4.1 Low Cuboidal Cell	66
4.4.2 Non-ciliated Type I Cell	68
4.4.3 Non-ciliated Type II Cell	72
4.4.4 Ciliated Cell	76
4.4.5 Basal Cell	78
4.5 Ligation Experiments	80
4.6 General Anatomical Aspects of the Excurrent Ducts in Relation to Function	83
ACKNOWLEDGEMENTS	85
REFERENCES	86
ILLUSTRATIONS	



## S U M M A R Y.

The genital tract of the male fowl was investigated by dissection, microinjection, microradiography, and conventional histological methods. The distribution in the tissues of lipids, glycogen, some oxidative enzymes and cholinesterases was investigated histochemically. The intrinsic cholinergic and adrenergic innervation was also examined. A fine structural study of the epithelial lining of the efferent ducts was made and the ductus deferens was ligated with the object of studying the resorption of testicular fluids and the fate of unejaculated spermatozoa.

The fowl testis has no mediastinum or tubuli recti. The seminiferous tubules therefore lead directly into the rete testis which is drained by the ductuli efferentes. The latter are continued into the connecting ductules which open into the ductus epididymidis. The ductus epididymidis and ductus deferens are considered to be merely different segments of the same duct, which increases in diameter from its beginning at the cranial end of the epididymal region to its caudal end in the pelvis. Thus, what has previously been known as the avian epididymal region might be regarded as equivalent to the caput epididymidis of scrotal mammals; the main part of the ductus deferens and its dilated regions are considered analogous to the corpus and cauda epididymidis respectively.

Lipids in the form of neutral, phospholipids and free fatty acids were detected in the seminiferous tubules and epithelial cells and lumina of the excurrent ducts. Small amounts of mucopolysaccharides were also detected but glycogen was absent. All oxidative enzymes studied (Glutamic dehydrogenase, lactic dehydro-

genase, succinic dehydrogenase and glucose-6-phosphate dehydrogenase) were present; their highest activity was in the ductuli efferentes. True cholinesterase was confined to the neural structures and the basal parts of the epithelial lining of the large connecting ductules, ductus epididymidis and ductus deferens. Pseudocholinesterase was found throughout the cells of the same regions.

A rich supply of cholinergic and adrenergic nerves was found particularly in the lateral aspect of the epididymal region, adjacent to the testis, and along the ductus deferens.

Ultrastructurally, at least five different cell types were identified in the duct system, namely, (1) low cuboidal cells lining the rete testis, (2) and (3) ciliated and non-ciliated, type I cells lining the ductuli efferentes and narrow connecting ductules, (4) non-ciliated, type II, cells lining the wide connecting ductules, ductus epididymidis and ductus deferens, and (5) basal cells found mainly with type II cells. The rete cells have an imbricated arrangement and their fine structure indicates a secretory function. The ciliated cells possess motile cilia and microvilli; they are non-secretory but appear to play a role in the resorption of fluids. Type I cells carry microvilli and have electron-dense worm-like structures in the apical cytoplasm; the structure and possible function of these structures were discussed. The main structural features of type II cells were similar to those of a protein-secreting cell. They possess an abundance of distended rough and transitional endoplasmic reticulum, a well developed Golgi complex and dense secretory granules some of which were seen at the luminal margin. The basal cells have a large dense irregular nucleus and scanty cytoplasm containing a few organelles and fibrils; they are

closely related to nerve endings in the subepithelial tissue and a possible contractile role for these cells has been discussed.

Spermatozoa are taken up by the surface lining cells of the male tract in normal males. The lumen contained many disintegrating spermatozoa and other cell debris after ligation of the ductus deferens; all the lining cells, except the basal cells appear to phagocytose spermatozoa and cellular debris. Macrophages containing spermatozoa were found in the lumina of the ducts, in the subepithelial tissue and wedged between the basal lamina and the surface epithelia.

The implications of the microanatomical findings in relation to secretion into the seminal plasma, storage of semen in vivo, resorption of testicular fluids, movement of spermatozoa along the excurrent duct system, disposal of unejaculated spermatozoa, and emission of semen in the fowl have been discussed.

## 1.0 INTRODUCTION.

There are many differences between the fowl (*Gallus domesticus*) and common domestic mammals in the biochemistry and composition of seminal plasma and spermatozoa (Mann, 1964; Lake, 1966). Likewise there are several features of the anatomy of the respective reproductive tracts that are different (Sisson and Grossman, 1953). Glover and Sale (1969) and Glover and Nicander (1971) emphasized the need to reappraise <sup>the</sup> ~~and~~ anatomy of, and the nomenclature applied to, apparently similar parts of the reproductive tract in different classes of <sup>vertebrates</sup> ~~animals~~. It was stressed that the same kind of study was necessary for making a comparison between mammals with scrotal and abdominal testes.

A more detailed knowledge of the anatomy and fine structure of the male genital tract of the bird would be useful for future comparative studies of reproductive physiology in vertebrates. It would contribute information which would be useful in determining the relative merits of prolonged discussions on ~~anatomical and functional analogies~~ <sup>homologies</sup> between reproductive organs of different species.

Aspects of the gross anatomy of the reproductive tract of the male fowl have been described by Kaupp (1915), Burrows and Quinn (1937), Gray (1937), Parker, McKenzie and Kempster (1942), Bradley and Grahame (1960) and Marvan (1969). Stoll and Maraud (1955) and Maraud (1963) reconstructed and described the development of the epididymis from the mesonephros during embryogenesis. A histological study of the tract was made by Lake (1957) chiefly to localise the possible sources of seminal cellular and fluid products in the fowl.

In the present investigation a detailed study of the gross architecture and histology of the excurrent ducts of the adult male

fowl was made to serve as a reference for simultaneous investigations on their fine structure, histochemistry and intrinsic innervation.

A detailed study of the fine structure of the epithelial lining of the duct system is necessary for a better understanding of the role of the individual cells in the physiology of avian reproduction. Electron microscopic investigations of the reproductive tract of the domestic cock are lacking, but ultrastructural studies of the developing and ejaculated spermatozoa have been made (Grigg and Hodge, 1949; Nagano, 1962; McIntosh and Porter, 1967; Nicander and Hellström, 1967; Lake, Smith and Young, 1968).

Knowledge of the intrinsic innervation of the reproductive system of the male domestic fowl is confined to two brief references, one to the presence of fine nerve fibres in the testis (Cavalié, 1902) and the other to fibres in the genital tract (Bennett and Malmfors, 1970). However, a general study was made of adrenergic nerve distribution in the genital tract of the male swan Cygnus olor (Baumgarten and Holstein, 1968).

The production of certain enzymes and other chemical compounds has been demonstrated in specific regions of the male tract of mammals (Nicander, 1957; Allen and Slater, 1961; Mann, 1964; Risley and Skrepetos, 1964 a,b; Stallcup and Roussel, 1965; Blackshaw and Samisoni, 1967). Certain histochemical tests were made in the present work to aid in drawing possible analogies between parts of the genital tract of the fowl and the mammal, and to aid in the interpretation of the function of the various epithelial cells in conjunction with studies of their fine structure.

A well established function of the head of the epididymis

including the ductuli efferentes in mammals is the absorption of some of the fluid produced in the seminiferous tubules (Setchell, 1970). It has also been suggested that a proportion of the spermatozoa produced by the testis of mammals is lost during passage through the genital tract. Spermatogenesis has been described in the mammal as a continuous process regardless of the degree of sexual activity of the male (Simeone and Young, 1931; Amann, 1962, 1970; Amann and Almquist, 1962; Orgebin-Crist, 1965). A review by Foote (1962) indicated that more spermatozoa are produced by the seminiferous tubules of mammals than can be obtained by exhaustive ejaculation. It implies a loss of spermatozoa within the tract. Two main views are held to account for the loss, i.e. they are either voided in urine (Oslund, 1928; Bielanski and Wierzbowski, 1961; Lino, Braden and Turnbull, 1967) or resorbed in the excurrent ducts (Young and Simeone, 1930; Young, 1931; Simeone and Young, 1931; Amann and Almquist, 1962; Glover, 1969; Paufler and Foote, 1969). A recent electron microscopic study by Holstein (1967) has revealed the presence of phagocytic cells containing spermatozoan fragments in the lumen of the epididymis of man which demonstrates a possible additional mechanism for the disposal of spermatozoa. Part of the present work was concerned with identifying possible mechanisms of resorption of seminal products in the genital tract of the male fowl.

That part of the work on the architecture and histology of the duct system was submitted and accepted for publication in the *Journal of Anatomy*. The fine structure of the basal cells was given as a demonstration to the Anatomical Society at its Edinburgh Meeting in July 1971. The preliminary results of the ligation experiments were presented jointly with Dr. P.E. Lake, to the April 1971 Meeting of the Anatomical Society in London, and later, after completion of the work, to the Nottingham Meeting of the Society for the Study of Fertility in July 1971.

## 2.0 MATERIAL AND METHODS.

### 2.1 ARCHITECTURE AND HISTOLOGY OF THE EXCURRENT DUCTS:

Thirty-two mature Leghorn cocks were used in this study, together with a few immature two-month-old cockerels. Good and poor producers (*sexually active and inactive*) were tested by cloacal massage and of semen ~~were~~ included amongst the mature birds.

Retrograde injection methods were used to establish the architecture of the epididymal region. For this purpose the lateral part of the testis was removed to assist the penetration of the injection media into the ducts. The seminal contents of the ductus deferens were milked out, sometimes followed by a saline wash, and each injection was made at a controlled pressure of 150-200mm Hg from the distal end of the ductus deferens. Injection media included micropaque (Damancy & Co. Ltd.) for X-ray examination and neoprene latex followed by corrosion in concentrated hydrochloric acid or clearing (Williams, 1943; Siller and Hindle, 1969).

Tissues for histology were obtained from the epididymal region, the cranial, middle and caudal segments of the ductus deferens and the ampullary portion of the ductus deferens. Bouin's fixative was found to be more satisfactory than either susa, Zenker's or 10% formalin and was thus used routinely. Tissues were embedded in paraffin wax and sectioned at 5-7 $\mu$ m. Sections were stained with haematoxylin and eosin and Masson's trichrome.

Transverse serial, 10 $\mu$ m, sections of the epididymal region of a mature bird were prepared for making a graphical reconstruction of the area.

### 2.2 HISTOCHEMISTRY:

Reproductively-active Brown and White Leghorn cocks were killed

by dislocation of the neck vertebrae and samples of tissue were obtained from the testis, the epididymal region, the ductus deferens (cranial, middle, caudal and ampulla), and the ejaculatory duct. Males with reduced sexual activity were also used for a comparative study of enzyme activity in these tissues. Material was either fixed in Bouin's fluid and processed for paraffin wax sections at a thickness of 5-7 $\mu$ m, or frozen in dry ice, dry ice and isopentane, dry ice and freon, or freon and liquid nitrogen and cut in a cryostat at a thickness of 10-15 $\mu$ m. The subsequent methods used to investigate various chemical compounds and enzyme activities in the male tract were as follows:

#### 2.2.1 Glycogen and Mucopolysaccharides:

The presence of glycogen was investigated in paraffin wax and frozen sections, treated with celloidin to prevent any possible diffusion of glycogen (Culling, 1963); control sections were treated with diastase or saliva. The periodic acid Schiff (PAS) and Best's carmine methods (Culling, 1963) were used to locate glycogen and mucopolysaccharides.

#### 2.2.2 Lipids:

To identify the presence of lipids, frozen sections were cut at 10 $\mu$ m thickness, from blocks of tissue fixed in 10% formol-calcium and stained for 30 min at 70°C in a 1% acid-hydrolyzed solution of Nile Blue sulphate (Dunnigan, 1968). Control sections were extracted in acetone for  $\frac{1}{2}$  to 1 h prior to treatment to test for phospholipids. Test and control sections were also stained in a saturated solution of Sudan Black B in 70% alcohol for 30 min at room temperature.



### 2.2.3 Oxidative Enzymes:

Those investigated were:

- (1) Glutamic dehydrogenase (GDH).
- (2) Lactic dehydrogenase (LDH).
- (3) Succinic dehydrogenase (SDH).
- (4) Glucose-6-phosphate dehydrogenase (G-6-PDH).

Sections of fresh-frozen tissue were examined according to the methods outlined by Pearse (1960). Sections were generally incubated at 37°C for 30 min; those for SDH study were incubated for 15 min. Control sections were incubated in solutions without substrates.

### 2.2.4 Cholinesterases:

Tissues were fresh-frozen and sections of 20µm thickness were examined by the method of Gomori (1952). Both acetylthiocholine (AThCh) iodide and butyrylthiocholine (BuThCh) iodide were used as substrates. Specific cholinesterase inhibitors, namely,  $2.5 \times 10^{-5}$ M-diisopropyl fluorophosphate (DFP) and  $2.5 \times 10^{-6}$ M-physostigmine salicylate (eserine), in 0.25 M-sodium acetate (pH 5.4), were used to identify the pseudo and true cholinesterases respectively.

For tests of specificity, the sections were immersed for 30 to 45 min in a solution of 0.25 M-sodium acetate with or without the appropriate inhibitor. They were then washed and incubated in Gomori's medium at 37°C. Preliminary tests had shown that it was not necessary to include the inhibitors in the final incubation stage.

Various periods of incubation ranging from 1 to 5 h were tested; 2 h was sufficient for staining with AThCh as a substrate but a 3 h period was needed with BuThCh and so the latter time was adopted for the routine investigation of the respective enzyme activities in the

tissues.

### 2.3 THE INTRINSIC INNERVATION OF THE REPRODUCTIVE TRACT:

Material was obtained from several parts of the male tract, including the testis, and treated according to the following methods:

- (1) The methylene blue method of Schabasch's as modified by Mitchell (1953). The reproductive tract was dissected out quickly after death and the desired parts were wholly immersed for 20 min in 0.01% methylene blue at 37°C. The methylene blue was buffered in a pH range of 5.6 to 6.6 (Gilbert 1961).
- (2) The method of Namba, Nakamura and Grob (1967).  
Tissues were fresh-frozen, sectioned at 25-45µm in the cryostat, mounted on coverslips and thawed in formalin vapour at room temperature. Subsequent steps followed exactly the procedure described by Namba *et al.* (1967).  
This combined cholinesterase and silver technique is claimed to impregnate more effectively than silver alone.
- (3) Histochemical method for acetylcholinesterase (section 2.2.4).
- (4) Formaldehyde-catecholamine condensation method.  
Tissues were fresh-frozen and treated according to the procedure described by Spriggs, Lever, Rees and Graham (1966). A positive reaction for catecholamines was revealed by a green or yellow-green fluorescence using a 1mm UG 1 filter on a Leitz 250 UV light with a barrier filter K470. To distinguish between formaldehyde-induced fluorescence of the catecholamines and the non-specific autofluorescence in the tissues, sections were observed with and without formaldehyde treatment.

#### 2.4 ELECTRON MICROSCOPY:

Fifteen males were used for ultrastructural studies. The abdominal cavity was opened immediately after killing, either by dislocation of the neck vertebrae or overdose of nembutal. Most of the organs were removed leaving the reproductive tract to be fixed for a few minutes in situ by filling the cavity with ice-cold fixative. The tract was then dissected out and small pieces from the epididymal region and different levels of the ductus deferens were transferred to the fixative so that the total fixation time did not exceed 30 min.

The fixative used was a mixture of 4% formaldehyde and 0.8% glutaraldehyde in a phosphate buffer at pH 7.4. The tissues were osmicated for 1 h in 1% osmium tetroxide in phosphate buffer (Millonig, 1962), dehydrated in alcohol, cleared in propylene oxide and embedded in Araldite.

Sections were cut with glass or diamond knives. Thick sections were stained with toluidine blue and examined with the light microscope. The desired regions were then selected and thin sections for electron microscopy were mounted on uncoated copper grids, stained with alcoholic uranyl acetate (Stempak and Ward, 1964) followed by lead citrate (Reynolds, 1963) and examined with an AEI EM 6B electron microscope.

#### 2.5 LIGATION OF THE DUCTUS DEFERENS:

Laparotomy was performed on six anaesthetized adult cocks and unilateral ligatures were applied to the ductus deferens either at its junction with the epididymal region (cranial ligature) or near its midpoint (caudal ligature) (Fig.1); the other side was left as a control. The birds were killed 1, 3, 4, 6 and 8 wk later.

The gross morphological changes on the operated side were compared with the control side after the specified periods following ligation. Samples were obtained from the different parts of the duct system and processed for light and electron microscopy according to the methods described earlier (Sections 2.1, 2.4). Paraffin wax sections were stained with haematoxylin and eosin; thick sections (1 $\mu$ m thick) of formaldehyde-glutaraldehyde fixed material were stained with toluidine blue.

## 3.0 RESULTS

3.1 THE STRUCTURE OF THE EXCURRENT DUCTS AS REVEALED BY DISSECTION AND LIGHT MICROSCOPY.3.1.1 Gross Features:

An active testis is large, white and soft (Lorenz, 1959; Lake and El Jack, 1966); in an inactive bird it is much smaller, greyer and harder. The epididymal region is about 2cm long in a sexually active bird (Figs. 1, 2). The ductus epididymidis appears as a short, coiled, white tubule in the juxta-testicular tissue (epididymal region) applied to the dorsomedial surface of the testis, (Figs. 1-3). The ductus deferens extends for about 14cm from the caudal end of the epididymal region to the base of the ejaculatory duct (Figs. 1, 2). It is white and turgid when full with semen, and when inactive contains a watery secretion. In the latter condition it is small and flaccid and difficult to dissect. The apparent coils of the ductus deferens cannot be pulled out into a straight tube; in longitudinal section the lumen appears to consist of a series of pockets.

3.1.2 Histological Features:

The seminiferous tubules of the testis pass directly into the channels of the rete testis (Figs. 3-6) which in turn connect with the ductuli efferentes. Initially the latter tubules are wide and they gradually taper before forming the connecting ductules. These ductules follow a tortuous course towards the medial aspect of the epididymal region where they interconnect and become wider; they eventually open into the ductus epididymidis (Figs. 2-4).

The whole duct complex immediately adjacent to the testis is

embedded in a fibrous stroma containing a few smooth muscle fibres (Fig. 7). In inactive (Fig. 8) and immature birds, a relative increase in the amount of connective tissue is observed and the tubules are smaller and more folded. These changes resemble those seen in lactating and non-lactating mammary glands.

Lymphocytes and macrophages are present in the intertubular connective tissue. Many large blood vessels supplying the testis pass through the lateral aspect of the epididymal region (Nishida, 1964). The blood supply is poor within the epididymal region itself.

#### Rete Testis:

The rete (Figs. 5, 6) is a network of thin-walled spaces embedded in connective tissue and located entirely outside but adjacent to the testis; it lies mainly in the lateral edge of the epididymal region, but also spreads over its ventral and dorsal aspects. The confluence of the seminiferous tubules with the rete is not along the entire length of the opposed surfaces of the testis and epididymal region but occurs at certain interspaced points forming definite bridges between them (Figs. 2, 3).

The epithelial lining ranges from simple squamous to low cuboidal (4-7 $\mu$ m high). Gray (1937) suggests that this is due to the pressure of the luminal contents but this seems unlikely as the lining is not affected by variations in sexual activity. There are abrupt changes in the epithelium at the connections of the rete with the ductuli efferentes.

#### Ductuli Efferentes:

These are the commonest and largest of the tubules in the epididymal region. The average luminal diameter in the initial wide

part is 500 $\mu$ m (range 250 to 700 $\mu$ m) reducing to about 100 $\mu$ m distally. The epithelial walls are folded involving the basal lamina and the luminal surface. The latter is the more extensively folded as groups of tall and low cells alternate (Fig. 9). In the low parts of the epithelium the height of the cells is 26 $\mu$ m. Tall, dark, slender cells are present in the epithelium with an expanded ciliated luminal border and they are connected to the basal lamina by narrow stalks (Fig. 9). Their elongated nuclei occupy the luminal half of the cytoplasm and have one or two nucleoli. There are also light and intermediately stained cells of variable heights which may reach the lumen; these possess spherical nuclei in the basal cytoplasm. Occasional short angular cells are wedged among the bases of the tall cells. Thus the general nuclear distribution in the epithelium produces pseudo-stratification.

The ductuli efferentes are narrower and more folded when sexual activity is minimal and epithelial height is then reduced to about 15 $\mu$ m (Fig. 8).

#### Connecting Ductules:

The initial parts of the connecting ductules resemble the ductuli efferentes except for their narrower lumina (60 $\mu$ m) and more regular and smoother outline (Fig. 10). They are lined by pseudo-stratified ciliated columnar epithelium, 15 $\mu$ m in height. The tufts of cilia of the dark staining cells are more prominent than those of the ductuli efferentes. Light staining cells and angular basal cells are present as in the ductuli efferentes.

The ductules of a sexually-poor bird are narrower (30 $\mu$ m) and their epithelial lining is thinner (10 $\mu$ m).

The ductules gradually widen as they join each other towards their confluence with the ductus epididymidis. In these parts the ciliated cells disappear and the ductules become indistinguishable from the ductus epididymidis (Fig. 11). A compact mass of spermatozoa is characteristically seen in the lumen of the connecting ductules.

Ductus Epididymidis and Ductus Deferens:

The ductus epididymidis is a very tortuous tube which starts at the cranial end of the epididymal region and courses along its medial border to continue past the caudal end as the ductus deferens (Figs. 1-3, 11). The ductus epididymidis is confined within the connective tissue of the juxta-testicular region, but the ductus deferens is free. Otherwise, macroscopically they appear to be different parts of the same duct; they are also histologically similar. The epithelial folds, which first appear in the wide connecting ductules, are continued into the ductus epididymidis and the cranial part of the ductus deferens (Figs. 11, 12).

The initial part of the ductus epididymidis is very narrow (300 $\mu$ m), but a gradual increase in diameter occurs caudally and continues into the ensuing ductus deferens. The average epithelial height of the ductus epididymidis is 30 $\mu$ m. With poor sexual activity the diameter of the lumen and the height of the epithelium are halved.

The ductus deferens has an average luminal diameter of 400 $\mu$ m at the cranial end which gradually increases to 550 $\mu$ m in the middle and 900 $\mu$ m in its caudal parts. At the extreme caudal end there is a dilatation, 2mm in diameter, which opens into the ejaculatory duct;



this is known as the ampulla. The epithelium of the ductus deferens at the beginning is as high as that of the ductus epididymidis (30 $\mu$ m), but steadily falls to 20 $\mu$ m in the middle and 15 $\mu$ m in the caudal parts; the height of the epithelium again rises in the ampulla to 25 $\mu$ m. (Figs. 12-15).

The lumen is lined by pseudostratified, non-ciliated columnar epithelium consisting of light and dark staining cells (Fig. 14). The dark cells have more slender nuclei, with denser packed chromatin, which occupy the luminal portion of their cytoplasm. The other cells have centrally-placed, oval, vesicular nuclei with one or two nucleoli. Some smaller angular cells next to the basal lamina are wedged among the bases of the tall cells. They have spherical nuclei, somewhat smaller than any others (Fig. 14). Bleb-like projections on the free surface of the epithelium are seen in the cranial segment of the ductus deferens.

In the ampulla of the ductus deferens, the epithelial lining is similar to the remainder, but the basal cells constitute a more definite layer (Fig. 15).

The ductus deferens has a relatively thin, 100 $\mu$ m, fibromuscular coat closely applied to the epithelium. In the ampulla it is 275 $\mu$ m thick. The whole ductus deferens is poorly vascularized.

In males of poor sexual activity the walls of the ductus deferens collapse and the cavity shrinks to half its usual diameter. The fibromuscular coat contracts and thus appears thickened (Fig. 16). The ampulla is only 1mm in diameter and similar halving occurs in the height of the lining epithelia.

### 3.1.3 Luminal Contents:

During normal sexual activity, the luminal contents of the excurrent ducts vary in the different parts. Spermatozoal density is lowest in the rete testis and in the ductuli efferentes (Figs. 6, 9), while a conspicuous dense mass of interwoven spermatozoa is found in the initial narrow part of the connecting ductules (Fig. 10). In the remainder of the tract the spermatozoa are uniformly distributed, occupying almost the entire lumen but leaving a narrow sperm-free zone separating them from the epithelial lining (Figs. 12-15). This probably represents a shrinkage artifact.

Spermatids at different stages of maturation are mixed with spermatozoa. Large numbers occur in the rete, a few in the ductuli efferentes, very few in the initial segment of the connecting ductules and only occasional ones elsewhere. Entire epithelial cells, as a third component of the luminal contents, are often seen in the ductuli efferentes.

In immature males and in those of poor sexual activity all these contents are reduced or absent (Fig. 8).

### 3.1.4 Mesonephric Vestiges:

Two similar types of tubules are found in the cranial and caudal parts of the epididymal region, (Figs. 3, 11, 17). They have smooth regular outlines with an average diameter of 280 $\mu$ m for the cranial and 440 $\mu$ m for the caudal tubule. They are lined by simple cuboidal or low columnar cells, 10 $\mu$ m high, with no surface specialisations (Fig. 17). The luminal content is a homogeneous material devoid of spermatozoa or any cellular constituents. These cysts are probably derived from the cranial and caudal mesonephric tubules and hence may be analogous

TABLE 1

Distribution of mucopolysaccharides, lipids and some dehydrogenases in the reproductive tract of the domestic fowl.

Organ	PAS (After diastase treatment)	Lipids	GDH	LDH	SDH	G P-6-PDH
<b>Testis</b>						
Seminiferous tubules	+	++	+	+++	+	+
Interstitial tissue	-	±	±	±	±	-
Blood vessels	-	-	±	±	+	-
<b>Epididymal Region</b>						
Rete Testis	-	±	±	+	+	+
Ductuli Efferentes	+	++++	++++	++++	++++	+++
Connecting Ductules	+	+++	+++	+++	+++	+++
Ductus epididymidis	+	+++	+++	+++	+++	+++
Intertubular tissue	-	+	+	±	±	-
Blood vessels	-	-	+	±	+	-
<b>Ductus Deferens</b>						
Cranial segment	+	+++	+++	+++	+++	+++
Middle segment	+	+++	+++	+++	+++	+++
Caudal segment	+	++	+++	+++	+++	+++
Ampullary region	+	+	++	++	++	+++
Subepithelial tissue	-	±	±	±	±	-
<b>Ejaculatory Duct</b>						
Internal epithelium	+	±	+	+	±	±
Fibromuscular layer	-	-	±	±	±	-
External epithelium	+++	-	+	++	+	+

Relationship holds only in vertical direction.

++++ - very strong

+++ - strong

++ - moderate

+ - weak

± - very weak or absent

- - Absent.

to the appendix of the epididymis and paradidymis of mammals (Bloom and Fawcett, 1968).

### 3.2 HISTOCHEMISTRY

#### 3.2.1 Distribution of Glycogen, Mucopolysaccharides, Lipids and Dehydrogenases:

The sites of the histochemical reactions investigated and the results are summarized in Table 1.

##### Glycogen and Mucopolysaccharides:

No glycogen can be detected in the entire male tract of the fowl. A strong PAS-positive reaction is found in the basal laminae of the different tubules and the external epithelium of the ejaculatory duct (Fig. 18); this is resistant to diastase and salivary digestion. Material giving very weak PAS-positive reaction of the same nature is demonstrable in the epithelial lining of all ducts but the rete testis; luminal contents and the seminiferous tubules also stain.

Negative results are obtained with Best's carmine stain, so confirming the absence of glycogen.

##### Lipids:

Sudanophilia is present in the seminiferous tubules of active males and confined mainly to the basal cells; it is weaker towards the lumen and in the interstitial tissue. It is not possible to determine whether the lipid material is in the Sertoli cells, spermatogonia or both. Sudanophilic droplets are scattered throughout the cells of all genital ducts and in the lumen, (Figs. 19-22) the highest content being found in the epithelial lining of the ductuli efferentes (Fig. 19); there is a gradual lessening of a lipid reaction caudally until only traces can be seen in the internal

epithelium of the ejaculatory duct. The external epithelium of the latter is negative. In the entire system the Sudanophilia is greatly reduced after acetone extraction.

Sections stained with Nile blue demonstrate the presence of red and blue droplets (Figs. 23-25). All droplets staining red and some staining blue disappear completely after acetone extraction. Dunnigan (1968) shows that the red droplets contain neutral lipids and free fatty acids, while the blue have phospholipids and also possibly free fatty acids. The partial removal of the blue staining following acetone treatment may therefore be due to extraction of fatty acids.

#### Dehydrogenases:

##### Glutamic dehydrogenase (GDH)

In the testis a weak reaction for this enzyme is detected in the basal cells of the seminiferous tubules and in the interstitial tissue. A strong reaction occurs in the ductuli efferentes (Fig. 26), and intermediate reactions of varying intensity occur in the narrow and wide connecting ductules, ductus epididymidis and ductus deferens (Table 1; Figs. 27-30). The internal and external epithelial linings of the ejaculatory duct and the rete testis give a weak GDH reaction (Fig. 31).

A slight reaction is seen in the intertubular tissue of the epididymal region and throughout the subepithelial tissue of the ductus deferens and ejaculatory duct; this is probably due to the presence of smooth muscle fibres and connective tissue components as a comparable reaction is shown in the blood vessels (Fig. 31).

In the epithelium of the connecting ductules, ductus epididymidis

and ductus deferens the granules showing the site of positive GDH enzyme activity tend to be in the luminal cytoplasm (Fig. 32), whereas in the efferent ductules they are commonly in the basal cytoplasm.

There is no essential difference in the enzymic activity between a good and a poor semen-producing cock except that in the former there is a definite activity in the lumina associated with the presence of seminal fluids and spermatozoa.

#### Lactic dehydrogenase (LDH)

The highest level of activity of LDH is seen in the ductuli efferentes (Fig. 33) with a slight reduction in the connecting ductules. This moderate reaction is also in the ductus epididymidis (Fig. 34), ductus deferens (Fig. 35) and seminiferous tubules (Fig. 36). A weaker reaction is encountered in the rete testis (Fig. 37) and the internal epithelial lining of the ejaculatory duct (Fig. 38); the external epithelial lining of the latter shows a slightly stronger reaction. In the testicular interstitial tissue, inter-tubular tissue of the epididymal region and subepithelial tissue of the ductus deferens and ejaculatory duct the reaction is very faint or absent.

There is a general tendency for the positive granular reaction due to LDH to be in the luminal tip of the cytoplasm, and it is especially noticeable in the ductus epididymidis (Fig. 39) and ductus deferens (Fig. 40).

The described reactions are present in the male tract irrespective of the degree of sexual activity displayed. However, luminal enzyme is again only present in good semen-producing cocks.

Succinic dehydrogenase (SDH)

As in the case of GDH and LDH the ductuli efferentes are the site of the most intense activity for SDH (Fig. 41), and there is a gradual loss of intensity of reaction caudally along the duct system (Figs. 42-44). The internal epithelium of the ejaculatory duct gives a very faint reaction (Fig. 45) and that of the external epithelium is slightly stronger. Positive granules are detected in the germinal epithelium of the testis, mainly in cells of the basal layer. A detectable reaction is seen in the rete testis and blood vessels whereas the subepithelial tissue gives hardly any reaction.

Granules tend to concentrate at the bases of the epithelial lining of the ductuli efferentes and connecting ductules, whereas they lie on the luminal side of the epithelium in the ductus epididymidis and ductus deferens (Fig. 46).

A reaction in the lumen of the excurrent ducts again depends upon the amount of spermatozoa and seminal fluids present and hence the degree of sexual activity.

Glucose-6-phosphate dehydrogenase (G-6-PDH)

There is moderate activity of G-6-PDH in all cells lining the ducts except in those of the rete testis and seminiferous tubules where the activity is reduced (Figs. 47-50). The activity in the seminiferous tubules appears to be confined mainly to the peripheral parts. A reduced G-6-PDH activity is also found in the ejaculatory duct, where the reactivity of the external epithelium is again slightly stronger than the internal (Fig. 51).

The pattern of granular distribution in the epithelial cells of the entire tract was fairly uniform (Fig. 52).

The enzyme reaction in the lumen varies in intensity according to the amount of seminal content present (Fig. 48).

### 3.2.2 Distribution of Cholinesterases:

Butyrylthiocholine is a suitable specific substrate for use in the identification of avian pseudo-cholinesterases (butyrylcholinesterase; BuChE) in spite of the fact that they are believed to be different from those of mammals (Earl and Thompson, 1952; Myers, 1953). These pseudo-cholinesterases are inhibited selectively by DFP. The residual fraction of the total cholinesterases, identified by activity towards acetylcholine in the presence of DFP, is considered to be due to true cholinesterases (Acetylcholinesterase; AchE).

Cholinesterase activity using butyrylthiocholine as a substrate is found mainly in the epithelial lining of the wide connecting ductules, ductus epididymidis and ductus deferens (Figs. 53, 54). There is also a faint staining in the intertubular tissue of the epididymal region and the subepithelial tissue of the remaining parts of the male tract. There is almost no staining in the presence of  $2.5 \times 10^{-5}$  M-DFP (Figs. 55, 56), but it is hardly affected by  $2 \times 10^{-6}$  M- eserine (Figs. 57, 58); the entire cholinesterase activity in these areas is therefore considered to be due to the presence of pseudo-cholinesterases.

Light and dark-staining areas are observed in tissue sections when acetylthiocholine is used as a substrate (Figs. 59, 60). The light staining corresponds to pseudo-cholinesterase-positive areas in both their distribution and their reaction towards DFP (Figs. 61, 62) and eserine (Figs. 63, 64). It is therefore concluded that the



light-staining areas contain pseudocholinesterases. Dark-staining areas have the same site of distribution as the light-staining areas but are confined mainly to the basal part of the epithelium (Figs. 59, 60), and also occur in structures resembling nerve fibres. The latter structures will be described and discussed in Sections 3.3 and 4.3. The dark-staining is partially masked by BuChE being present at the same site and it is clearly seen after incubation in DFP which inhibits BuChE (Figs. 61, 62). The dark-staining resisted DFP treatment of the tissue and is inhibited by eserine (Figs. 61-64) and thus indicates the presence of AChE. Accordingly incubation in AcThCh results in two types of staining due to AChE and BuChE.

The intensity of staining for both types of cholinesterases is comparatively stronger in the epididymal region (wide connecting ductules and ductus epididymidis) and the cranial segment of the ductus deferens. Caudally along the ductus deferens the staining fades away gradually until it becomes very weak in the ampulla of the ductus deferens and the ejaculatory duct. The seminiferous tubules, rete testis, ductuli efferentes and narrow connecting ductules show completely negative reactions for cholinesterases except for some staining in the interstitial tissue of the testis and the inter-tubular parts of the epididymal region (Figs. 53, 59).

Regardless of the degree of sexual activity of the cock, the pattern of staining for cholinesterases in the reproductive tract remains unchanged.

### 3.3 THE INTRINSIC INNERVATION OF THE REPRODUCTIVE TRACT:

#### 3.3.1 General Distribution:

The methylene blue technique on whole mounts is unsuccessful for closely following the nerve fibres in the genital tract because either the tissue is compact (e.g. testis and epididymal region) or irregular (e.g. ductus deferens). However, the distribution of the intrinsic nerve supply is clearly visualized by the method of Namba et al. (1967).

#### Testis:

Many of the fine testicular nerves are located in the interstitial tissue (Figs. 65-67). The fibres run singly or in the form of small trunks but large bundles are sometimes seen (Fig. 66); branches are closely related to the seminiferous tubules (Fig. 67). When blood vessels are found in the interstitial tissue, their association with nerve fibres is demonstrable.

#### Epididymal Region:

Nerves are distributed extensively in the lateral aspect of the epididymal region, which is anchored to the testis (Fig. 68). Here, numerous, large nerve trunks are related to blood vessels (Fig. 69). More muscle bundles are found here than in the intertubular tissue of other parts of the epididymal region and nerves are always seen in their vicinity (Fig. 70). Fine branches from the nerve trunks course between the tubules of the epididymal region (Fig. 71).

Some nerve fibres run directly in the walls of the rete testis (Fig. 72); many others run close to the epithelial lining of the tubular structures but there is no evidence that they course between the cellular components (Fig. 73)

Ductus Deferens:

Throughout its entire length, the ductus deferens is the most heavily innervated (Figs. 74-77). Short sections of thick nerves are mostly seen but long sections and single fibres are also common. Their disposition is in the immediate subepithelial tissue following the tortuous course of this tube. Fibres, commonly clumping together in small bundles, are seen at the base of the epithelial lining of the ductus deferens (Figs. 74, 75). Individual fibres branch off the bundles and appear to be in close association with the epithelial cells; others ramify in muscle tissue of this part of the tract and, further caudally, of the ejaculatory duct.

Nerve Ganglia:

One autonomic ganglion is found in juxta-position to the epididymal region (Fig. 78) and another close to the middle part of the ductus deferens (Fig. 79); the former ganglion is closely related to the adrenal gland. Each ganglion possesses a well-developed collagenous capsule. Large nerve bundles lead off the ganglia and course into the epididymal region (Fig. 80). Many nerve cells, singularly, in pairs or in the form of acapsular clusters, are interposed along the course of these nerves as well as in the space between the epididymal region and its ipsilateral adrenal gland. The nerve cells are predominantly multipolar, and each has a prominent nucleus with one or two nucleoli. Acapsular nerve cells not associated with nerve trunks or ganglia are seen also in the middle segment of the ductus deferens; none of these are encountered in the testis or the intertubular tissue of the epididymal region,

### Terminations of nerve fibres:

The most common type of ending seen in the reproductive tract of the domestic fowl is in close apposition either to epithelial cells or to walls of blood vessels and muscle fibres. Structures resembling free nerve endings are also seen. However, it is not certain whether all the free endings are actually free or whether they are apparent due to sectioning. The possibility that they may be single nerve fibres cut across cannot be excluded. Specialized sensory receptors like those described in the hen ovary (Gilbert, 1965) are not observed.

### 3.3.2 Cholinergic Innervation:

Following the use of acetylthiocholine as a substrate, a positive cholinesterase activity is depicted in neural elements located in the interstices of the testis (Fig. 81), the intertubular tissue of the epididymal region (Fig. 82) and in the subepithelial tissue of the entire wall of the ductus deferens (Figs. 83-87) and ejaculatory duct (Fig. 88). The pattern of distribution of these elements is similar to that visualized by the Namba *et al.* (1967) technique. Many cholinergic nerve elements are closely associated with the basal parts of the wide connecting ductules, ductus epididymidis and ductus deferens (Figs. 82-85).

The cholinesterase-positive staining is abolished by eserine but resists DFP. When butyrylthiocholine is used as substrate no positive staining of the nerve fibres was obtained. It is concluded then that the neural structures contain only true cholinesterase.

### 3.3.3 Adrenergic Innervation:

Fluorescence of varying intensity is seen in catecholamine-

containing nerve plexuses whose density and distribution are subject to regional variation. The testicular innervation is sparse and confined to the interstitial tissue. An abundance of fluorescent fibres in the form of networks or bundles is seen in the intertubular tissue of the epididymal region (Fig. 89). The nerve terminals supply blood vessels and ramify on muscle fibres; others are seen to course independently. There are a few varicose fluorescent fibres around the rete testis, the ductuli efferentes and the narrow connecting ductules. However, the wide connecting ductules (Fig. 90) and ductus epididymidis (Fig. 91) appear to have a rich adrenergic nerve supply closely applied to their epithelial linings in a manner comparable to that depicted by the thiocholine method. A similar pattern is also encountered in the disposition of the fluorescent nerves along the entire wall of the ductus deferens (Fig. 92). There is a rich plexus of nerve terminals which ramify freely in the muscle fibres of the ampulla of the ductus deferens (Fig. 93) and ejaculatory duct.

Autofluorescence is observed mainly in the epithelia of the seminiferous tubules and the ductuli efferentes (Fig. 89). In the seminiferous epithelia the fluorescence is rather weak and its general pattern corresponds to that of the nuclei of the germinal cells. The epithelia of the ductuli efferentes have a rich content of granules which vary in both size and quality of fluorescence. These granules are probably identical to the heterogeneous and lysosomal bodies contained in two cellular types which line these ducts (section 3.4). Baumgarten, Falk, Holstein, Owman and Owman (1968) studying the adrenergic innervation of the male reproductive

tract of man, observe a similar nonspecific fluorescence which they relate to lipofuscin pigment. Autofluorescence of the subepithelial structures is very faint and does not interfere with the specific fluorescence of catecholamines.

#### 3.3.4 The Fine Structure Of The Intrinsic Nerve Supply Of The Excurent Ducts:

Electron microscopical observations confirm the presence of nerve elements in the subepithelial tissue of the entire male tract, which also contains smooth muscle, collagenous fibres, fibroblasts and blood vessels. In the deeper layers, the muscular elements predominate and the whole tissue is compact. Intrinsic nerve fibres are distributed throughout the epididymal region and ductus deferens and are generally non-myelinated (Fig. 94); myelinated elements are seen occasionally in the epididymal region (Fig. 95). Axonal profiles vary widely in size and outline and are enveloped by Schwann cells. They are grouped together in bundles of various sizes and surrounded by distinct basal laminae separating them from the neighbouring non-neural structures. Exceptionally large bundles are supported by a collagenous framework which interdigitates with the axons (Fig. 94). A definite epineural sheath is not obvious.

In non-myelinated axons (Fig. 96) the neurofibrils or neurofilaments show a moderate electron opacity. The fibrillar arrangement is slightly irregular but there is a distinguishable longitudinal orientation. There are a number of mitochondrial profiles, mostly oval or elongated, which appear to be oriented in the direction of the long axis of the fibre. Other elements scattered in the axoplasm are neurotubules and some dense-cored microvesicles;

electron-lucent microvesicles are seen occasionally. The latter two structures will be considered in more detail later.

The myelinated axons (Fig. 95) are closely enwrapped by the Schwann sheath and show hardly any axoplasmic components except for neurofibrils and a few mitochondria.

The fine structure of the preterminal region of the nerve axons shows that there are fewer axoplasmic neurofibrils and mitochondria than in the main course of the nerve described above, but there are more dense-cored and electron-lucent microvesicles as well as some tiny spherical dense granules (Fig. 96).

#### Nerve Endings:

The nerve endings are either in the form of enlarged segments of the axon, or synaptic-type endings of about the same diameter as the axon (Fig. 97). The Schwann cell investment is absent or covers only the unapplied side of the axolemma at the region where a nerve ending is opposed to what is presumably its target organ. No particular morphological specialisations are observed at the areas of contact between the axolemma of the exposed parts of axons and the structures that are presumed to be their effector organs. Structures showing these intimate contacts include muscle fibres (Fig. 98) and the basal laminae beneath the epithelia lining the male tract; they occur from the rete testis down to the ampulla of the ductus deferens (Figs. 99-102). In many of these instances the basal lamina of a bare axon appears to be contiguous with that of the non-neural structure; the closest measured distance between the two plasma membranes is 70nm.

A few cases are observed in which the preterminal part of an axon <sup>appears to</sup> penetrate the basal lamina of the epithelial lining, and in its

subsequent course the nerve ending is completely free of Schwann cell cytoplasm (Fig. 103). The axolemma ~~can~~<sup>may</sup> be applied directly to the plasma membrane of the base of the epithelial cells and the two appear to interdigitate. Thus with no intervening basal laminae, the space separating the two cytoplasms is 23nm.

Two main types of nerve endings are distinguished by their axoplasmic components; one type has almost entirely agranular microvesicles and the other has a mixture of agranular microvesicles and several types of granular forms (Fig. 97). Granular vesicles in a nerve ending are never found without the agranular variety. Profiles of mitochondria are occasionally present.

#### Types of Microvesicles in Nerve Elements:

Microvesicles in the axoplasm are of two varieties, electron-lucent and dense-cored vesicles.

##### (a) Electron-lucent microvesicles (Figs. 96, 97).

These are small (40nm in diameter), spherical or slightly oval and possess an electron-lucent interior. Unlike the other type, they are agranular and more closely packed. They are rare in places where neurofibrils are present, but they abound in the terminal regions of axons (Fig. 96). Most of these vesicles are evenly-sized and uniformly distributed in the axoplasm, but they sometimes form clusters in the centre of the axon. Occasionally vesicles are seen at the periphery and they may fuse with the axolemma at an axonal ending (Fig. 97).

##### (b) Dense-cored microvesicles (Figs. 96, 97, 100, 104).

These are best seen after glutaraldehyde/formaldehyde-osmium tetroxide fixation. Few are present in the axoplasm before the preterminal region but they become more numerous towards the terminal



regions. The vesicles contain a core or granule showing various degrees of electron-opacity and separated from the limiting membrane by an electron-lucent halo. Like the electron-lucent vesicles, the limiting membrane shows contiguity with the axolemma (Fig. 100). The following features are observed in the size and shape of the vesicles as well as the enclosed granule:

- (1) Spherical or oval vesicles, 90nm wide (Fig. 104). The dense core almost fills the vesicle and occupies a central location reducing the halo to a small peripheral margin.
- (2) Elliptical or elongated forms of about the same width as those in (1) (Fig. 104). These are constricted in the middle; the dense core resembles that of the spherical type in its form and location but it is bifid in conformity with the vesicular shape. This probably implies a division or fusion.
- (3) Spherical, oval or frequently irregular vesicles, 120nm wide (Fig. 104). They contain a small eccentrically-located granule which resembles a remnant of the conspicuous core of the other types and tends to be less dense.

Microvesicles of similar appearance but devoid of any granules were seen occasionally (Fig. 104).

- (4) Minute, 25nm in diameter, spherical and exceedingly dense granules are seen (Figs. 96, 97). A limiting membrane is not easily recognized.

#### Schwann Cells:

The Schwann cells in the male fowl reproductive tract are found in association with the nerve axons chiefly in the immediate

subepithelial tissue. They resemble fibroblasts but could be identified by certain distinctive general morphological features as described by Coupland (1965b). For instance they are always related to nerve fibres and demarcated from the non-neural connective tissue elements by a distinct basal lamina.

The nucleus of the Schwann cell contains dense chromatin and is elongated and shaped irregularly. Its long axis is generally in the direction of the nerve axons with which it is associated. The chromatin is evenly distributed but occasionally it is marginated. A single nucleolus is invariably present. The cytoplasm in the immediate vicinity of the nucleus is reduced to a narrow rim connecting with the narrow processes destined to envelop nerve axons. The cytoplasm of a Schwann cell is more electron-dense than axoplasm and it contains some mitochondria, a few profiles of rough endoplasmic reticulum (RER) and some free ribosomes. Large lipid droplets are present commonly in the processes wrapped around axons and electron-dense granules are rarely encountered.

#### 3.4 THE FINE STRUCTURE OF THE EPITHELIAL CELL TYPES LINING THE EXCURRENT DUCTS:

The genital excurrent ducts of the domestic fowl are lined by different cells of which at least five types are distinguishable; (1) low cuboidal cells, (2) non-ciliated cells, type I, (3) non-ciliated cells, type II, (4) ciliated cells and (5) basal cells. A detailed cytological account for each of these will be presented under separate headings.

##### 3.4.1 Low Cuboidal Cell:

These cells constitute the epithelial lining of the rete testis. A schematic drawing of a typical cell is shown in Figure 105. The

cells have an imbricate arrangement and thus their shape as seen in ultra-thin sections is determined largely by the plane of section. The observed variations range from flat squamous-like types to typical cuboidal forms with many intermediate shapes (Figs. 106-108).

The free surface of the lining cells has a sparse covering of short microvilli and a few coated vesicles (Fig. 106). The lateral plasma membranes are straight and the opposed surfaces are held together by extensive junctional complexes located near the luminal surface. The basal cell membrane is moderately folded. In electron micrographs, some cells do not appear to reach the basal lamina and others do not abut the lumen. These appearances are attributed to the imbricated association of the cells and not a true construction of the epithelia.

An irregular nucleus with deep surface invaginations occupies the bulk of the cytoplasm (Fig. 109). Its chromatin is concentrated on the inner aspect of the nuclear membrane forming a narrow shell of a fairly uniform thickness. A nucleolus when seen in sections has a dense band in its outer part and a lighter central portion. A round vesicular structure is sometimes seen within the nucleus (Fig. 110). The one shown in Fig. 110 has a circular outline and is surrounded by a narrow rim of chromatin-like material. The luminal aspect of the rim is smooth whereas the outer surface is fuzzy due to fine radiating dense bars. The interior is electron-lucent, devoid of any detail and appears like lipid. Its significance is obscure.

The rete cell has a sizeable Golgi complex which consists of several parallel arrays of cisternae and vesicles of various sizes (Figs. 111-113). It is located at different sites in the cytoplasm.

Some of the cisternae dilated at their ends (Fig. 111) and occasionally an entire cistern is distended. The cavity of the dilated region is more electron-lucent than that of the narrow cisternae. There are large electron-opaque granules at the periphery of the array which seem to be associated with the complex (Fig. 112).

Long or ovoid mitochondria are distributed randomly in the cytoplasm (Fig. 111). They are much smaller than those of other cells in the excurrent ducts; possibly in proportion to the smaller size of the rete cells.

Few short profiles of rough endoplasmic reticulum (RER) are scattered throughout the cytoplasm (Figs. 111, 113). The continuity of these elements with small saccular expansions of smooth endoplasmic reticulum (SER), which is absent except in the Golgi region, was demonstrable (Fig. 113). Sometimes there is a direct communication between RER and cytoplasmic vacuoles. These vacuoles are numerous and irregularly oval and their cavity is either empty or contains electron-lucent lipid-like material. The vacuoles appear to coalesce to form large multiple bodies (Fig. 114). Free ribosomes are distributed in the cytoplasm.

Cytoplasmic electron opaque bodies are bound by a limiting membrane and they vary in shape, and size, ranging from the small ones found in the Golgi region, to others which are several times larger, (Fig. 112). Shapes include spherical, elongated and constricted forms. Some of the small granules are found also in the lumen. Vacuolated cytoplasmic bodies, of similar size to the electron-dense ones, occur; in some instances there is a large central cavity displacing the dense material to a thin rim in which additional small

peripheral vacuoles are embedded.

Several miscellaneous structures are found in the cell, e.g. sections of spermatozoa in the apical cytoplasm (Fig. 115), lipid droplets mainly in the basal cytoplasm, centrioles in the supra-nuclear region, randomly-scattered fine fibrillar elements not stacked in bundles, and small fuzzy vacuoles associated with the cell membrane.

The cytoplasmic matrix is more electron-opaque in some cells than in others (Fig. 116). Similar variations in density have often been reported in other organs and they may represent modifications of a single cell type at different phases of a metabolic cycle (Ladman and Young, 1958). This suggestion may apply to the lining cells of the rete testis.

The subepithelial tissue contains a few collagenous and smooth muscle fibres and is richly innervated. Nerve axons in close proximity to the basal lamina are observed (Fig. 112).

#### 3.4.2 Non-ciliated Type I Cell:

These cells are mainly present in the ductuli efferentes and the narrow parts of the connecting ductules where they alternate, singly or in groups, with the ciliated cells (section 3.4.4). They are rarely found in the wide connecting ductules; they are not present in any part of the ductus epididymidis or ductus deferens.

A schematic representation of this cell type is shown in figure 117. They are tall columnar cells and, compared to the ciliated cells, have lower electron density. The luminal border carries microvilli which are long, numerous and pleomorphic; some are club-shaped and resemble the bleb-like projections seen with the

light microscope and interpreted as phases in apocrine secretion. Others are long, slender, regular and closely packed and could be classified as stereocilia (Figs. 118, 119). The entire apical cytoplasm is occasionally thrown into a luminal projection devoid of microvilli. Between the bases of the microvilli, surface invaginations not unlike coated micropinocytotic vesicles, are closely associated with worm-like structures in the subjacent cytoplasm (Fig. 120). The latter structures are considered in more detail below.

The lateral plasma membranes of the non-ciliated type I cells are fairly straight with only moderate interdigitations being seen in the middle parts. The apical borders adhere to those of the neighbouring cell by fairly extensive junctional complexes (Fig. 119). The cell rests on the basal lamina and here there is little or no folding of the plasma membrane.

A large vesicular nucleus, which is sometimes slightly irregular in shape, occupies the basal cytoplasm. Its chromatin is almost uniformly distributed with slight peripheral concentration. A nucleolus is present and is dense except for a light central part.

Stacks of smooth-surfaced endoplasmic reticulum (SER) constitute a well-developed Golgi complex in the supranuclear region (Fig. 121). They consist of cisternae which may be concentrically arranged together with vesicles of varying sizes distributed around the periphery. Large vacuoles are occasionally present in the centre of the complex. Small electron-dense granules arising within the Golgi cisternae are observed, (Fig. 121); their electron-opacity is similar to that of the worm-like structures described below. In addition, there are smooth, flattened sacs arranged in parallel to

form stacks randomly distributed in the cytoplasm (Fig. 122). Agranular vesicles are associated with the periphery of these stacks, and vacuoles, like those of the Golgi, are scattered throughout the cytoplasm. Elements of rough endoplasmic reticulum (RER) are rare and are sometimes aligned end-to-end thus forming long chains. Their cavity is generally narrow with some irregular widening. Free ribosomes are also present.

The non-ciliated type I cell has a rich content of mitochondria located in the perinuclear cytoplasm particularly in the basal parts (Figs. 123, 124). They are usually slightly larger than those in the ciliated cells and circular, oval, elongated, branching and constricted forms are encountered. The cristae run in different directions but are mostly transversely oriented. Intramitochondrial electron-dense granules appear in some but not all mitochondrial profiles (Fig. 123); these may be associated with divalent cation storage (Greenawalt, Rossi and Lehninger, 1964).

A miscellany of large heterogeneous bodies varying in shape, size and composition are always seen in the cytoplasm of type I cells. Most of these bodies are membrane-bound, multigranular structures with an electron-dense matrix (Figs. 121, 122, 125) in which lipid droplets and granules of various sizes and densities are packed. The granular and lipid contents vary and so the overall electron-opacity of the body is affected. In some bodies the lipid droplets are large and one or two are located peripherally as if awaiting extrusion or incorporation (Fig. 121). The limiting membrane is dense and sharp, but occasionally it is not seen. Other bodies are large, irregular and membrane-bound but the matrix is vacuolated and possesses an

electron-opacity comparable to that of the cell cytoplasm (Fig. 125). These types also contain electron-dense granules in different shades of electron-opacity; an accumulation of lipid droplets is often seen in their neighbourhood. Homogeneously-dark bodies whose electron-opacity is similar to that of the worm-like structures also occur (Fig. 125). These possess a few, exceedingly dense granules scattered throughout their matrices.

Membrane-bound vacuoles with a content indistinguishable from that of the surrounding cytoplasm are occasionally seen (Fig. 122). Some of these contain mitochondria and are therefore considered to be autophagic vacuoles. Autophagic vacuoles occur in cells under functionally normal conditions and may represent a means of disposal of worn out organelles (Ericsson, 1969). Membranous residues or whorls also occur (Fig. 122) and these are probably myelinated bodies.

Apart from those granules and structures described in the heterogeneous bodies above, there are free electron-dense granules in the cytoplasm of type I cells (Figs. 124, 125) and they occasionally occur in the intercellular spaces. These granules are either free or enclosed within a membrane and many of them are similar to the granular elements constituting the heterogeneous bodies.

A few lipid droplets are located mainly in the basal cytoplasm (Figs. 124, 125) and small vesicular structures with a fuzzy outer surface are scattered in the peripheral cytoplasm close to the cell membrane.

#### Worm-like structures:

A characteristic feature of the type I cells is that the apical cytoplasm contains many electron-dense, worm-like structures (Figs. 118-



120) whose profiles vary in shape (Fig. 126). Most appear as rounded bodies of various sizes (75-350nm in diameter), arranged either singly, in pairs or more rarely, in rows (Fig. 126A). Rods are the next most frequent shape; they are either straight, slightly curved or sharply bent, with globular or tapering ends (Fig. 126B). The whole rod is not always of uniform electron density. A few globular forms have thin hair-like stalks which sometimes connect them together (Fig. 126C). Open and closed rings also occur (Fig. 126D). Some T- and Y-junctions are seen (Fig. 126E) as well as vesicular forms which merge with the surface membrane of the cell (Fig. 126F). Large thin-walled, electron lucent vesicular structures containing flocculent material (Figs. 126G, 127) share the same region in these cells and occasionally such organelles have worm-like extensions (Fig. 126H). Finally, large crescent-like bodies whose outlines are irregular, have granular material in the electron-lucent cavity on their concave side (Fig. 126I).

An occasional observation in birds with ligated ducti deferentes is that the apical cytoplasm of type I cell contained electron-dense, bilaminated, thick-walled vesicles which contained a flocculent material. Some of them appear to merge with thin-walled cytoplasmic vesicles which have ill-defined limiting membranes (Fig. 128), and so the two vesicular cavities become continuous. Independent thin-walled vesicles abound under conditions of ligation, and their lumina are full of flocculent material together with dense granules and large multi-granular bodies (Fig. 129).

The worm-like structures were studied in tissues fixed in glutaraldehyde-formaldehyde with or without osmication, phosphate buffered osmium tetroxide (Millonig, 1962) and 1% potassium permanganate. With

the exception of the permanganate-fixed material, sections were examined unstained and after staining with lead citrate, uranyl acetate, or both. The structures are not detectable in tissues fixed in glutaraldehyde-formaldehyde without osmication, and they are ill-defined after potassium permanganate fixation. After osmication or straight osmium fixation the structures are demonstrable without staining; the comparative contrast to other cytoplasmic contents is slightly better after straight osmium than after the aldehyde/osmium fixation. After both osmium methods, the contrast is improved by staining in lead citrate and this is augmented by uranyl acetate.

#### 3.4.3 Non-ciliated Type II Cell:

This is the main type of cell in the epithelial lining of large connecting ductules, the ductus epididymidis and the ductus deferens. A diagrammatic representation of its fine structural features is given in figure 130.

The cell is tall, slender and columnar, resting directly on the basal lamina. Several types of luminal surface specializations are seen, including long slender microvilli (Fig. 131) which represent the stereocilia described by light microscopists, other similar projections of variable shape, diameter and height, and bleb-like projections (Fig. 132). Coated vesicles, commonly considered to function in pinocytosis, are placed between the bases of the microvilli. Occasionally, cells with a single small cilium are present (Fig. 132). The overall surface picture resembles that of a type I cell except that the associated worm-like structures, characteristic of the latter type, are absent.

The opposed lateral plasma membranes of the type II cells are straight in the luminal half and firmly attached by junctional complexes

at the luminal tips (Figs. 131, 132); interspaced desmosomes occurred further down. In the basal half of the cells the membranes interdigitate with each other. The basal surface is usually folded and sometimes quite complex (Figs. 133, 134). The lateral interdigitations are interpreted as mechanical means of attachment while basal interdigitations may be concerned with water transport (Pease, 1956). Fuzzy vesicles and caveoli are associated with the membranes especially in the basal part (Fig. 134).

The non-ciliated type II cell has a large vesicular nucleus which is sometimes as wide as the cell itself (Fig. 135). It has no fixed position but is located generally within the basal two-thirds of the cell. Its density is homogeneous except for a few dense chromatin clumps. There is a single eccentrically placed nucleolus, with a finely granular centre.

Elements of smooth endoplasmic reticulum (SER) in the supra-nuclear cytoplasm form a large Golgi complex which often appear in the form of whorled lamellae (Fig. 136). The cisternae show fenestrations characteristic of the Golgi complexes of the rat and the mouse epididymides (Flickinger, 1969). The cisternal lumina are mostly narrow but large vacuoles are often present at the poles of the opposed cisternae, sometimes they interrupt the middle of a cistern (Fig. 136). A number of round vesicles are found in the centre of the Golgi complex and at the periphery. Small vesicles of SER are scattered in other parts of the cytoplasm. All dilated segments of SER have an electron-density lower than that of the narrow portions or the surrounding cytoplasmic matrix.

The mitochondrial content is generally less than that of the

ciliated and type I cells (Fig. 132). They are oval, round or elongate with numerous cristae transversely oriented, and in a few instances dense intramitochondrial granules were present (Fig. 137).

An abundance of well developed, rough endoplasmic reticulum (RER) is the principal characteristic of the type II cell, and it is uniformly distributed throughout the cytoplasm. Most RER profiles occur singly; branching, interconnected or chain-like forms are less common. The profiles vary in appearance, within the same cell, different cells or cells from different cocks, from narrow empty tubes (Fig. 137) to vacuolar forms distended to a varying degree with a flocculent material of a slightly lower electron density than the cell cytoplasm (Figs. 132, 136). The amount of distension is greatest in the cells lining the cranial segment of the ductus deferens and appears slightly less in the cells of the more caudal regions. This material is most likely an integral part of the endoplasmic reticulum as some of the distended cisternae of the reticulum are partly rough-surfaced and partly smooth-surfaced (Figs. 132, 136). Such forms, in the pancreatic acini of guinea-pigs, are considered as "transitional rough endoplasmic reticulum" (Palade, 1966; Jamieson and Palade, 1967 a,b). The transitional form of ER is found, in the pancreatic acini, along the boundary between the Golgi complex and the RER but in the present cell type it has no particular location. Sometimes distended forms of RER approach the surface and their limiting membranes are continuous with those of the cell, thus they appear to open directly into the lumen.

The amount of RER in the type II cell is always very large relative to the amount of mitochondrial material and there is an

intimate association between these two organelles (Figs. 132, 136, 137); a mitochondrion is often completely encircled by RER. Numerous free ribosomes are located in the cytoplasmic matrix.

A number of electron-dense bodies, generally smaller than mitochondria and often bound by membranes are found frequently in the apical cytoplasm (Figs. 131, 138). They vary in size and shape; some appear ovoid or spherical while some of the smaller bodies share a limiting membrane (Fig. 138). Most of the bodies examined are uniformly dense. However, some contain lighter areas which are either small and numerous or they may have coalesced to form one or two larger clear zones (Fig. 139); the dense matrix material in the latter case is reduced to a peripheral region of varying thickness. Scattered in the dense matrix of these vacuolated bodies are small dense granules (Fig. 139). The uniformly-dense bodies are found also within the cisternae of the Golgi complex (Figs. 139, 140) and in membrane-bound structures resembling autophagic vacuoles. When observed close to the cell surface their limiting membrane merges with the plasma membrane and they become extruded (Fig. 131); a number of these are seen lying free in the lumen.

Autophagic vacuoles, either of the same size as mitochondria or larger, are frequently seen in type II cells (Fig. 141); one large multiple form in figure 141 contains fragments of cell cytoplasm and is partly vacuolated. The formation of autophagic vacuoles generally indicates pronounced cellular involution (Farquhar, 1969) and is considered as a natural process for disposing of worn-out cell organelles (Ericsson, 1969).

Sections of spermatozoa are seen in the apical and basal cytoplasm

and in wide irregular vacuoles in the basal parts of type II cells. The cytoplasm also contains fine wavy fibrillar elements oriented with the long axis of the cell (Fig. 135); they do not form bundles and appear similar to those described in the rete cells. There is a profuse distribution of nerves in the subepithelial tissue and numerous nerve axons are seen in close contact with the basal lamina of the type II cells, a feature which this cell shares with the rete cells, basal cells and type I cells (section 3.3.4). Occasionally small lipid droplets are seen scattered randomly in the cell and centrioles appear in the supranuclear region (Fig. 142).

Cells have been observed occasionally among the type II cells that possess the same fine structural characteristics except that they are much more slender, appear more electron-dense, and their nuclei are somewhat irregular and much thinner (Fig. 143). These are not considered as a separate population of cells.

#### 3.4.4 Ciliated Cell:

Ciliated cells occur in equal proportion to the non-ciliated type I cells in the epithelia of the ductuli efferentes and connecting ductules; they are found less frequently in the ductus epididymidis. A diagram of the fine structure of this cell type is shown in figure 144. The cell has an expanded apical region which tapers off towards the bottom and often does not reach the basal lamina. The cytoplasm is more electron-opaque than that of type I cells.

Typical motile cilia arise from the luminal border (Fig. 145). The ciliary shaft is bound by an extension of the cell membrane enclosing "9 x 2 + 2" axial microtubules characteristic of motile cilia. The shaft is continuous with a basal body which is embedded

in the cytoplasm; it is slightly expanded and marked off from the shaft by a constriction. The axial 9 x 2 microtubules of the shaft are continuous with those of the basal body. Cross-striated rootlets extend from the basal body and run for variable distances into the deeper cytoplasm. Microvilli, which vary in height and size, lie between the cilia; some are branched and a number may arise from a common stem. Small microvilli often appear on luminal protrusions of the cytoplasm. Coated micropinocytotic vesicles are also present on the cell surface.

The lateral plasma membranes do not interdigitate deeply; moderate projections often appear in the middle parts of the cells and these adapt to others in adjacent cells. Junctional complexes are seen towards the luminal tips of the cells (Fig. 145).

There is a large irregularly shaped nucleus located within the basal two-thirds of the cell and separated from the lateral plasma membranes by a narrow zone of cytoplasm (Fig. 146). Invaginations are encountered and these are sometimes very deep. The nucleoplasm is almost homogeneous, with a slight increase at the margins, which is a feature shared with type I cells. When seen, a nucleolus is single and homogeneously dense.

The many mitochondria are concentrated mainly in the supranuclear cytoplasm (Fig. 146). They are slightly smaller than those of type I cells and their shape is predominantly oval, although elongate forms also occur. They are bound by the usual double membrane and contain numerous transverse cristae. Intramitochondrial dense granules are only occasionally seen.

The Golgi complex of the ciliated cell (Figs. 146, 147) is rather

small and found in the supranuclear region. It consists of closely-packed cisternae, vesicles and vacuoles in some form of concentric pattern; other elements of SER are lacking. RER is present in small quantities often in the form of short scattered profiles which are occasionally aligned end-to-end to form long twisting strands (Fig. 148). Clusters of free ribosomes are randomly distributed in the cytoplasm.

There are large, vacuolar spaces in the apical cytoplasm, which are irregular, thin-walled and contain electron-lucent droplets and some flocculent material (Fig. 149). Cytoplasmic buds, which protrude into the vacuoles, resemble those described by Nicander (1965) in the absorbing cells of the rabbit epididymis. The number and the size of the vacuolar spaces are increased after ligation of the ductus deferens and the subsequent accumulation of spermatozoa and seminal fluids in the lumina of the ducts (section 3.6). Also, the droplets contained in the vacuoles become larger and display a consistency and electron opacity similar to those of the seminal fluid in the duct lumen.

In the normal male, sections of spermatozoa are recognizable within intact cytoplasmic vacuoles of healthy ciliated cells as well as in basal invaginations related to the extensive intercellular spaces at this site (Fig. 150). The parts of the spermatozoa looked normal except for a loosening or loss of the covering membranes.

Bundles of fibrous material like those described in the ciliated cells of the hen oviduct (Wyburn, Johnston, Draper and Davidson, 1970) occur in a broken concentric arrangement closely associated with the apical and lateral aspects of the outer nucleolemma (Figs. 146, 151). Individual bundles are found in the apical cytoplasm amongst the concentrated organelles.



There are large electron-dense bodies located randomly in the cytoplasm. The following types are recognized (1) Finely granular, homogeneous dense bodies, usually without a limiting membrane (Fig. 149), (2) bodies similar to those in (1) but including some large very dense granules, (3) heterogeneous aggregates of lighter matrix in which are embedded granules of variable sizes and degrees of electron density, small vacuoles, and lipid droplets (Fig. 146). These are similar to the multigranular bodies of type I cells and those of the human ovary (Hertig and Adams, 1967; Hertig, 1968).

Myelinated bodies and autophagic vacuoles are absent. A few large granules, with or without a limiting membrane, are found in the apical cytoplasm (Fig. 149) and small dense granules were scattered around the ciliary rootlets (Fig. 145).

In addition to the foregoing the cell contains a few lipid droplets and small vesicles with a fuzzy outer surface.

#### 3.4.5 Basal Cell:

A few basal cells are present in the ductuli efferentes and connecting ductules and they become more numerous in the ductus epididymidis and ductus deferens. They are most abundant in the ampulla of the ductus deferens where they form an almost complete basal layer (Figs. 15, 152). A schematic representation of the fine structure of this cell type is illustrated by figure 153. They are located between the basal lamina and the surface epithelial cells.

The cell is irregularly cuboidal with an undulating surface contour. The apical and lateral plasma membranes are closely apposed to those of the over-lying surface epithelia and attached to them by desmosomes; there was little or no membrane folding (Fig. 154). The basal plasma

membrane is unfolded but some branching processes extend along the basal lamina (Fig. 155).

The nucleus is dense and large; it is irregularly ellipsoidal with one or more deep incisures (Figs. 154, 156). In many preparations its chromatin is concentrated on the inner aspect of the nuclear membrane where it forms a dense interrupted band of variable thickness; the interruptions correspond to the sites of nuclear pores. The chromatin is concentrated also in randomly-scattered clumps which may or may not be associated with a nucleolus. The latter when seen in favourable sections, is distinct with an electron-lucent centre and is eccentrically located.

The cytoplasmic matrix is more electron-dense than that of the other epithelial cells (Fig. 155). A characteristic feature of this cell type is the presence of thick bundles of fine non-striated fibrils concentrically arranged around the nucleus and running close to the outer nuclear membrane (Fig. 156). A few other bundles, some branching off the concentric stem, run parallel to the long axis of the cell. Fine fibrillar elements, independent of bundles, are seen elsewhere in the cytoplasm. A few large mitochondria, round or elongated, and some profiles of RER and free ribosomes are scattered randomly in the cytoplasm; a small Golgi complex (Fig. 157) and centrioles with the usual 9 x 2 microtubules are usually located in the supranuclear region. The cytoplasm contains also a few spherical, membrane-bound, electron-dense bodies together with a number of vacuolar spaces, some of which probably contain lipid. Occasional fuzzy vesicles are observed close to the cell membrane.

The distribution of nerves in the subepithelial tissue is extremely

rich and it is interesting to note that the basal part of the cell is often closely related to nerve endings (Fig. 158).

### 3.5 Distribution of the Epithelial Cells Lining the Excurrent Ducts:

The rete testis is lined by one type of cell, namely, low cuboidal cells. However, these cells have an imbricated arrangement, and their shape in an ordinary histological or ultra-thin specimen is determined by the plane of section.

The surface epithelial lining of the ductuli efferentes and the narrow connecting ductules consists of two main types; ciliated and non-ciliated type I cells. The two types of cells alternate, individually or in groups. In the ductuli efferentes there are equal proportions of the two cell types; in the narrow connecting ductules, however, the ciliated to non-ciliated ratio appears slightly higher. The cytoplasm of the ciliated cells is more electron-dense than that of the non-ciliated, and hence the occasional appearance of dark cells in paraffin wax sections (Fig. 9). The presence of a few basal cells wedged among the bases of the above cells seen in the light microscope, is confirmed in electronmicrographs.

As the narrow connecting ductules are followed caudally into the wide connecting ductules, their epithelial lining becomes identical to that of the ductus epididymidis and ductus deferens except for the infrequent presence of ciliated cells.

The non-ciliated type II cells constitute the surface epithelial lining of the wide connecting ductules, ductus epididymidis and the entire ductus deferens. Histologically, some of these cells are darker than others; this is confirmed by the electron microscope. However, the fine structure of both light and dark cells is the same

and they are therefore considered as one cell type, namely, non-ciliated type II cells. The basal cells are more common in these parts of the duct system especially in the caudal regions of the ductus deferens. They form an almost uninterrupted basal layer in the ampullary part of the ductus deferens, and the epithelial lining appears bistratified (Figs. 15, 152).

The subepithelial tissue consists of smooth muscle cells, collagenous fibres and fibroblasts. These elements are rather loose in parts lying next to the epithelial lining, but they are more compact in the deeper layers; the smooth muscle cells appear to abound in the ductus deferens. There is a rich distribution of nerves throughout this tissue but the blood supply is not remarkable.

### 3.6 EFFECTS OF LIGATION OF THE DUCTUS DEFERENS:

#### 3.6.1 Gross Observations:

There is a slight increase in the size of the testis on the operated side up to the fourth week post-ligation; thereafter no appreciable change is observed. Creamy-coloured streaks converging on the epididymal region are seen through the covering membrane of the testicular parenchyma; this is due to the accumulation of spermatozoa in the seminiferous tubules prior to their entry into the excurrent duct system.

The epididymal region is also slightly larger on the operated side than on the normal when cranial ligatures are used. When the ligatures are placed more caudally, the seminal products accumulate in the distended ductus deferens cranial to the site of ligation. In both cases the remaining part of the ductus deferens caudal to the ligature is empty and flaccid.

### 3.6.2 Light Microscopy:

A massive accumulation of spermatozoa occurs in the lumina of the excurrent duct system cranial to the site of ligation in those birds examined three or four weeks after the operation; in some cases the lumen is almost completely occluded and this is particularly striking in the ductuli efferentes which under normal conditions have a sparse content of spermatozoa. In the ligated tract free cells, debris and occasional desquamated epithelia are also seen scattered amongst the spermatozoa. Cells with eosinophilic granules are observed within the epithelial lining and lumen of the rete testis (Fig. 159).

The packed contents of the lumen appear to exert a mechanical pressure on the normally folded wall of the ductuli efferentes making it flatter than in a normal, good-semen producing cock.

Many vacuolar spaces are evident within the epithelial lining of ligated excurrent ducts, mainly in the ductuli efferentes and connecting ductules (Figs. 160, 161), and to a lesser extent in the rete testis.

### 3.6.3 Electron Microscopy:

#### (1) Luminal contents of excurrent ducts:

The lumen of the excurrent ducts, particularly the ductuli efferentes contains, after three weeks ligation, mainly a mixture of spermatozoa, cell debris and flocculent fluid (Figs. 162, 163); the latter probably originates in the testis as in mammals (Crabo and Gustafsson, 1964; Setchell, 1970). Degenerating spermatozoa appear showing disruption of head chromatin and disappearance of most of the covering membranes (Figs. 162, 163). Some of the cell debris may represent unidentifiable fragments of spermatozoa. No extra changes are observed in ducts beyond three weeks of ligation.

Free cells with an irregular shape and with or without extended processes are present in the lumen of the more proximal ducts, namely, rete testis and ductuli efferentes (Figs. 163, 164); they are less common in the ductus epididymidis and ductus deferens. These cells possess cytoplasmic vacuoles containing sections of spermatozoa which appear apparently normal or in various stages of breakdown. Profiles of RER, electron-dense bodies and membranous whorls are seen in the cytoplasm of the luminal phagocytic cells.

(2) Uptake of spermatozoa by the epithelial cells of the ducts:

Sections of spermatozoa are seen within the cytoplasm of four out of the five different cell types constituting the epithelial lining of the excurrent ducts in normal and ligated males (section 3.4). The four cell types are the low cuboidal cells (typical of the rete), the ciliated and the non-ciliated type I and type II cells (Figs. 165-167). Type II cells appear to be the least active in taking up spermatozoa. Sections of spermatozoa are observed lying in surface invaginations flanked by microvilli (Fig. 168), in definite vacuoles in the apical and basal cytoplasm (Figs. 165-167) and in deep invaginations of the lateral cell membranes, i.e. in intercellular spaces (Fig. 169).

Large cytoplasmic vacuoles, containing electron-lucent material similar to that of the luminal fluid, are commonly present in the apical parts of the ciliated cells lining the efferent and connecting ductules (Fig. 170); this is interpreted as fluid uptake which is a well-known function of the excurrent ducts of mammals (Mason and Shaver, 1952; Crabo and Gustafsson, 1964; Setchell, 1970). The vacuoles in cells of the ligated tract are more numerous and larger in size than those of the normal, which may indicate an intensified uptake of luminal



fluid under these circumstances.

The epithelium in the different regions of the ligated excurrent duct system shows no signs of mechanical damage or separation of the junctional complexes (Figs. 166, 169). However, the intercellular spaces are enlarged compared with the normal, particularly towards the basal poles of the cells. This feature, together with the cytoplasmic vacuoles, probably explains the vacuolation seen by light microscopy.

Phagocytic cells containing spermatozoa which are similar morphologically to the free phagocytic cells in the lumen, are seen in the ligated tract between the basal lamina and the base of the surface of the epithelia (Fig. 171). The spermatozoa within these cells are seen either incorporated wholly in cytoplasmic vacuoles or engulfed by pseudopodial processes (Fig. 171). The phagocytic cell is not an integral part of the epithelial wall. Its morphological features, taken in conjunction with its content of spermatozoal sections, suggests that it is a type of macrophage; a similar conclusion can be applied to the phagocytic luminal cells.

### (3) Subepithelial macrophages:

The subepithelial tissue of normal males contains a large number of macrophages but they are not seen to contain spermatozoa. However, after ligation of the ductus deferens they contain spermatozoa (Fig. 172). Some free spermatozoa are seen also in the vicinity of these cells.

## 4.0 DISCUSSION.

4.1 GENERAL STRUCTURE AND HISTOLOGY:

The juxta-testicular duct system of the avian genital tract, unlike that of most mammals, starts most obviously with the rete testis since no tubuli recti are evident. There is no distinct mediastinum testis. The rete network lies outside the testis, as pertains in the rat (Reid and Cleland, 1957).

The rete testis, ductuli efferentes, connecting ductules and ductus epididymidis of the fowl are embedded in connective tissue, which helps to anchor the testis to the dorsal body wall, and forms a tissue mass adjacent to the dorso-medial surface of the testis. Kaupp (1915), Gray (1937), Parker et al. (1942) and Bradley and Grahame (1960) refer to this collection of structures as the epididymis, but Lake (1957) later prefers to use the term, epididymal region.

The sequence of the different ducts, constituting the juxtatesticular system reported by Stoll and Maraud (1955), Maraud (1963) and Marvan (1969), is confirmed by the present study. After reconstructing an epididymal region of a two-month-old cockerel Stoll and Maraud (1955) can count fifty-one ductuli efferentes. They also report the existence of a number of aberrant ducts and fragmentary canaliculi which constitute the paradidymis.

Anatomical observation and etymological derivation cause the avian epididymis to be regarded as being composed of the duct system confined to the juxta-testicular region. From the present work there are cogent reasons for regarding the ductus deferens of the fowl as equivalent to the corpus and cauda of a mammalian<sup>n</sup> epididymis. Thus, most of the juxta-testicular region may be regarded as corresponding to



the caput epididymidis. This suggestion is supported by the similar tortuous course of both ducts, the identical appearance of their epithelium which merely reduces in height as it progresses caudally, and the continual widening of the lumen from the cranial end of the attached portion, the "ductus epididymidis", to the caudal end of the free portion, the "ductus deferens". These sequential changes in the avian "ductus epididymidis" and "ductus deferens" follow closely those described as being present only in the epididymis of the rat (Reid and Cleland, 1957). The epithelial types of these avian ducts are also similar to those of the epididymides of the rat (Martan and Risley, 1963, a,b; Kreth, 1965) and mouse (Martan and Allen, 1964). After studying the genital tract of the male hyrax, a mammal with intra-abdominal testes, Glover and Sale (1969) consider that the part of the mesonephric duct lying on the surface of the testis and its caudal continuation are both parts of the epididymis. Classically, these parts are always referred to as the epididymis and ductus deferens respectively. Thus the proposal outlined here for the fowl agrees with the one made for the anatomy of the excurrent ducts in the hyrax.

In the present investigation, clear and ciliated cells are demonstrable in the epithelia of both ductuli efferentes and the initial segments of connecting ductules. Basal cells are present mainly in the ductus deferens. There is no evidence of halo or apical cells which are associated with holocrine secretory activity in the epididymis of the rat (Reid and Cleland, 1957; Martan and Risley, 1963, a,b) and that of the mouse (Martan and Allen, 1964).

The significance of the epithelial cells often found in the lumina of the ductuli efferentes in the fowl is not clear. There is no

evidence that these are part of a holocrine secretion suggested by Lake (1957). Nevertheless, they may be exfoliated cells or fixation artifacts. Bleb-like projections from cells are found in the epithelium, particularly in the cranial segment of the ductus deferens. This may be a sign of apocrine secretory activity, but again fixation artifacts cannot be excluded (Bloom and Fawcett, 1968).

Spermatogenic cells, in various stages of maturation, present in the rete testis, and to a lesser extent in the ductuli efferentes, may be due to mechanical handling prior to fixation, but they can be a normal occurrence. The high density of spermatozoa observed in the lumen of the initial segments of the connecting ductules could be an indication of fluid resorption in the ductuli efferentes although there may be an accumulation of spermatozoa in this region because they are moving from the wide ductuli efferentes into the much narrower connecting ductules.

#### 4.2 HISTOCHEMISTRY:

##### 4.2.1 Glycogen, Mucopolysaccharides, Lipid and Dehydrogenases:

Glycogen is absent from the reproductive tract of the cock. The PAS-positive material present in small amounts in the epithelial cells of the excurrent ducts presumably contains mucopolysaccharides. In the external epithelia of the ejaculatory duct it is a constituent of a secretory product of the goblet cells (Lake, 1957) which most likely aids in the protection of the lining mucosa of the cloaca. In the excurrent ducts, the mucopolysaccharide will form part of the seminal secretions.

Phospholipids, neutral lipids and free fatty acids appear to be present in the epithelial lining and lumina of various parts of the

tract, particularly in the efferent ductules. The latter observation suggests that they constitute a secretory product forming part of the semen. Electron microscope studies (section 3.4) reveal the presence of lipid droplets and a fairly rich mitochondrial content, an observation which supports the present histochemical findings. Little is known about the function of phospholipids but in some tissues, notably brain and spermatozoa, they may be oxidized for energy (Datta and Ottaway, 1965). Glycerolphosphorylcholine (GPC), a metabolite of phospholipid production is synthesised in the epididymal cells of some mammals. Traces of GPC have been found in fowl semen (Lake, 1966).

The demonstration of LDH, SDH and G-6-PDH suggests the existence of three main pathways of glucose metabolism; the Embden-Meyerhof glycolytic pathway, the Krebs cycle and the pentose shunt pathway respectively. The pentose shunt is involved in the manufacture of the ribose needed for the synthesis of nucleic acids and provides also quantities of reduced NADP, which are needed for lipid synthesis.

There is a tendency for lactic dehydrogenase to be concentrated in the luminal tips of the epithelial cells. A similar feature has been noticed in the epididymis of the mouse (Allen and Slater, 1961) and the bull (Stallcup and Roussel, 1965). Allen and Slater are of the opinion that if this implies a secretory mechanism, either lactate or pyruvate could be the secretory material, and that the former is more likely to be produced since spermatozoa can metabolize lactate efficiently under partially anaerobic conditions. In view of the paucity of fructose in the cock semen (Lake, 1966), which is present in large amounts in many mammals, and important for the survival and motility of the mammalian spermatozoa (Mann, 1964), lactate in the avian

reproductive tract could be one source of energy for the maintenance of fowl spermatozoa.

In their studies on LDH in the bull epididymis, Stallcup and Roussel (1965) claim that the highest activity of the enzyme occurs in the corpus epididymidis whereas Blackshaw and Samisoni (1967) observe the highest degree of activity of this enzyme, as well as SDH and G-6-PDH, in the caput epididymidis. These findings imply a regional variation of enzyme activity in the excurrent ducts which has also been observed in the present study. The highest level of activity of the four oxidative enzymes investigated is found in the efferent ductules. This variation may indicate a specialization of function concerned with secretion into the lumen (Stallcup and Roussel, 1965).

Glutamic dehydrogenase (GDH) is a key enzyme of mitochondrial amino acid metabolism. It is involved in the Krebs cycle and associated with the production of glutamic acid. The presence of the enzyme therefore is in line with the finding that nine-tenths of the amino acid content of cock semen is due to glutamic acid (Lake and McIndoe, 1959; Mann, 1964).

The distribution and degree of activity of the dehydrogenases as indicated by histochemical studies on the reproductive tract of the cock agrees with the ultrastructural findings of large numbers of mitochondria; for example the cells of the ductuli efferentes have the highest enzyme activity and the predominant non-ciliated type I cells are rich in mitochondria (section 3.4.2). The occasional concentration of enzymes in the basal parts of cells seen in the present study is in accord with the observations on the fine structure when the mitochondria of type I cells, lining the efferent ductules and narrow

connecting ductules, are seen occupying a basal location. The location of enzymes in the tips of cells has been related to a secretory activity (Allen and Slater, 1961); it is possible that the enzymes formed in the basal poles of cells are transferred to the apical cytoplasm and shed into the lumen.

In his cytochemical studies on LDH in the seminal vesicle of the guinea-pig, Tatsumi (1969) suggests that the activity of the enzyme is correlated with the levels of production of androgenic hormones. However, variations in the sexual activity of the cocks studied in the present work, which could have been due to fluctuations in the levels of androgens, do not seem to influence the observed degree of activity of the enzymes. Allen and Slater (1961) studied the epididymis of normal and castrated mice, and report that the activity of LDH is independent of the influence of androgens; after castration and complete androgen depletion, there is a loss of enzymic activity which is not restored by testosterone treatment. It is possible that these conflicting results can be explained by the fact that within certain hormonal levels, probably like those reported in the guinea-pig by Tatsumi (1969), a positive hormone-enzyme relationship is maintained, but that when the level of hormone attains a certain threshold the relationship no longer holds. If this is true, it is possible that the androgen levels within all the cocks used in the present study were above the threshold value and hence show no correlation with the high observed enzyme activities.

#### 4.2.2 Cholinesterases:

Both true (AChE) and pseudocholinesterases (BuChE) can be demonstrated in the reproductive tract of the domestic fowl. AChE is

confined to the neural structures, and the basal parts of the epithelia lining the duct system caudal to the connecting ductules. BuChE activity is confined almost entirely to the same cells. These findings are similar to those of Risley and Skrepetos (1964a) who reported that the testis, rete testis, ductuli efferentes and upper caput epididymidis of the rat are mainly negative for cholinesterases. They suggest that the cholinesterases are not involved in the functional activity in these upper parts.

Considerable attention has been given to the role of cholinesterase activity in sodium transport in a number of organs from different species. Koch (1954) suggests that the enzyme is a component of the mechanism for the active transport of ions through the gill epithelium of the crab. He also shows that cholinesterases are important for sodium transport in the anal papillae of an insect, the larvae of Chironomus pulmosus. A correlation between cholinesterases and active sodium transport in the skin of the frog has been worked out by Koblick, Goldman and Pace (1962). Studies on the kidney of the rat, rabbit and cat (Fourman, 1966) suggest a similar correlation in the mammalian nephron. Recently Fourman (1969) reports a relationship between an increase in BuChE activity and a corresponding increase in sodium transport in the supra-orbital salt secreting gland of the duck. It is known that there is a dramatic shift in the amount of sodium in the luminal fluid of the epididymis of some mammals (Crabo and Gustaffson, 1964; Quinn, White and Wirrick, 1965). The presence of sodium in the seminal plasma of the fowl has been reported by El Jack and Lake (1969), and it would be interesting to find out whether the intense cholinesterase activity in the epididymis of the cock is associated

with similar ionic movements to those found in mammalian excurrent ducts.

AChE is known to play a role in the transmission of nerve impulses. It has been demonstrated by electron-microscopic methods (Lewis and Shute, 1965), that at the motor end plate there is little AChE activity associated with the nerve cell membrane, but that the main concentration of the enzyme is in the synaptic clefts. The cholinesterase positive epithelia of the avian tract contain not only a uniform distribution of BuChE throughout the entire cells but also AChE which is located chiefly in the basal parts of the cells, which are shown to be contiguous with the subepithelial nerve endings (section 2.3); a functional relationship between the latter two may therefore be established.

The activity and/or amount of the cholinesterases in the epithelial cells and neural elements of the reproductive ducts of the male rat is found to depend on male sex hormones (Risley, 1961; Risley and Skrepetos, 1964b). Castration results in a progressive decrease of cholinesterase reaction and its disappearance from the epithelia and musculature after 4-6 months; these are restored after testosterone treatment. In the present work the quality of cholinesterase staining in the reproductive tracts of good and poor semen producers is essentially the same. This is not interpreted as lack of correlation between avian cholinesterases and testosterone activity in the body since it is more likely that during reduced sexual activity the levels of the testicular hormones are still sufficient to maintain the activity of the enzymes. It would be interesting to study the cholinesterase content in the caudal part of the tract in castrated and caponized birds.

### 4.3 INNERVATION:

#### 4.3.1 The General Intrinsic Innervation:

It is evident that the entire male reproductive tract of the domestic fowl is extremely well innervated particularly in the lateral aspect of the epididymal region and in the ductus deferens. Both cholinergic and adrenergic components are demonstrable and the distribution of the two kinds of fibres is essentially the same.

The original work of <sup>Hsieh</sup>Hsieh (1951) on the autonomic nervous system of the fowl shows that the testicular plexus is derived from the aortic plexus and receives fibres from the three adrenal ganglia which themselves constitute the anterior part of the aortic plexus. This provides an explanation for the presence of the ganglion found in juxtaposition to the epididymal region in the present work, which is also associated with the adrenal gland. According to Hsieh the testicular plexus of nerves reaches the testis and epididymal region by following the course of the testicular arteries. This agrees with the present observations of a rich distribution of nerves particularly in the lateral aspect of the epididymal region where the testicular blood supply passes through (Nishida, 1964; section 3.1). The nerves undergo repeated branching to supply the testis laterally, they course in the intertubular tissue of the epididymal region medially, and innervate the blood vessels and muscle bundles which are more numerous in this region than elsewhere.

The caudal ganglion of the ductus deferens appears to correspond to those of the posterior aortic plexus described by <sup>Hsieh</sup>Hsieh (1951). Gilbert and Lake (1963) report small ganglia at the utero-vaginal junction of the hen, a position which is possibly analogous to the mid-



region of the ductus deferens. Most of the intrinsic nerve supply of the ductus deferens appears to be derived from these ganglia.

The distribution of intrinsic nerve fibres in the reproductive tract of the cock is subject to regional variations; testis, rete testis, ductuli efferentes and narrow connecting ductules are less well innervated than the remaining parts of the duct system, namely, wide connecting ductules, ductus epididymidis, ductus deferens and ejaculatory duct. The nerve fibres in the testis are found mainly in the interstitial tissue. As in the bull testis (Shioda and Nishida, 1966), a few fibres are seen close to the basal lamina but none appear within the seminiferous epithelia. Their function is probably in the control of the blood supply as suggested earlier by Cavalie' (1902). This is similar to the innervation described in the rat testis (Risley and Skrepetos, 1964a) and in man (Gray, 1947; Baumgarten et al., 1968) where the testicular nerves are believed to be exclusively vasomotor in function. Baumgarten et al. (1968) studied the adrenergic innervation in the testis of man and conclude that it has no functional importance in this organ. In contrast to what has been reported in most mammals (Hodson, 1970), Baumgarten and Holstein (1968) report that the Leydig cells of the swan are supplied by sympathetic nerve fibres. The significance of this in the physiology of the testis remains to be investigated.

The richness of the nerve supply to the wide connecting ductules, ductus epididymidis and the entire ductus deferens and ejaculatory duct parallels the comparatively rich content of muscular tissue and possible contractile basal cells described in sections 3.4.5 and 4.4.5. This resembles the pattern in the mammalian epididymis and ductus deferens

(Risley and Skrepetos, 1964a; Falk, Owman and Sjöstrand, 1965; Sjöstrand, 1965a; El-Badawi and Schenk, 1967; Baumgarten et al., 1968). In these reports, it is suggested that the cholinergic and adrenergic innervation are concerned in at least two functions, the regulation of the vascular supply to the organs and the contractility of periductal smooth muscles controlling the emission of semen. It is interesting to note that the lining epithelia of the avian ducts with the richest innervation and content of smooth muscle are the only cholinesterase-reactive cells in the entire duct system (section 3.2.2) and they are contiguous with the subepithelial neural structures; this may suggest a receptor function. All these observations could indicate collectively the presence of a mechanism for the propulsion of seminal contents in the excurrent ducts and/or control of exocrine cellular secretion. However, further physiological studies are required to substantiate this hypothesis.

#### 4.3.2 The Fine Structure Of The Innervation:

The electron microscopic observations confirm the findings made with the light microscope in showing that the reproductive excurrent ducts of the domestic fowl are richly supplied by nerve fibres, which are non-myelinated and located mainly in the immediate subepithelial tissue.

Furthermore, supporting evidence for the presence of cholinergic and adrenergic components has been obtained. The small agranular vesicles in the axoplasm correspond in both form and size to the synaptic vesicles described by De Robertis and Bennett (1955) and considered to be structural units associated with the acetyl choline system (De Robertis, De Lores Arnaz, Salganicoff, De Iraldi and

Zieher, 1963). It is now generally accepted that the presence of synaptic vesicles typifies cholinergic nerve fibres. The average vesicular diameter in this study was 40nm which is within the size range (20-65nm) of synaptic vesicles reported in various types of tissues (Richardson, 1962).

The dense-cored vesicles seen in the present study correspond with the ones described as catecholamine storage units (Coupland, Pyper and Hopwood, 1964; Coupland, 1965 a,b); they are considered to indicate an adrenergic innervation (Grillo, 1966; Hökfelt, 1968). Variations in the electron-opacity and size of the granules in the dense-cored vesicles may be due to fixation, plane of section or differences in chemical composition or physiological state (Matthews and Raisman, 1969). Coupland *et al.* (1964) identify, by using different methods of fixation, two types of granules in the rat adrenal medulla, namely, adrenaline- and noradrenaline-storing granules. It is interesting to note that noradrenaline has been identified in extracts of excurrent ducts of the male fowl (Sjöstrand, 1965 b) which is in accord with the present findings.

The apparent fusion of the vesicular membrane with the axolemma seen in the present work in both granular and agranular vesicles could signify the extrusion of the transmitter substance according to the evidence of Katz (1962) and Coupland (1965 b) in studies of the autonomic nervous system.

Although the intrinsic innervation is observed to be extensive in the excurrent ducts, morphologically specialized nerve endings are not seen, but the terminal axons, which may or may not be enlarged, lie in intimate contact with their presumed effector organs such as muscle and

epithelia. The terminal regions of axons are either completely devoid of Schwann cell investment, or only naked at the surface in contact with the effector cells. Fusion of the basal laminae on both neural and non-neural sides is the general rule; however, a direct contact of the axolemma with the plasma membrane on the effector side with no intervening basal laminae is sometimes observed. In the latter situation the gap between the cytoplasm of the two sides was only 23nm whereas in the former it is variable; the narrowest being 70nm wide. Direct contacts involving membrane-to-membrane apposition with a gap of 15-25nm have been reported in smooth muscle of the rat ductus deferens (Richardson, 1962) and adrenal medulla of the rat (Coupland, 1965 b). It is well known that these contacts in general involve an invagination of the plasma membrane of the effector cell and the contacting membranes lack specialisations (Coupland, 1965 b; Grillo, 1966); this is in accord with the present observations. Indirect contacts which are thought to be more common have gaps measuring from 40nm to almost a micrometre (Grillo, 1966). The distance such as the one measured in the present work (70nm) is short and thus could allow diffusion of the transmitter substance to effect precise neural control.

The presumed effector structures in the male fowl genital ducts involved with these neural contacts are the muscle fibres, either free or in relation to blood vessels, and the epithelia of the entire duct system. It would be interesting to know the significance of this intimate contact particularly with the epithelium, and to establish whether this is a direct innervation regulating the movement of spermatozoa along the excurrent ducts or controlling exocrine cellular secretion as

suggested above.

#### 4.4 THE FINE STRUCTURE OF THE EPITHELIAL CELLS:

##### 4.4.1 Low Cuboidal Cell:

The shape of the avian rete cells has been described as squamous to low cuboidal (Gray, 1937) and it is suggested that the pressure of the luminal content accounts for the variation in shape. However, light microscopy observations (section 3.1) show that the shape of the cells constituting the epithelial lining of the rete is unaffected by the fluctuating content of spermatozoa due to variations in sexual activity. The electron microscope shows an imbricate arrangement of the lining cells and stresses the importance of the effect of section plane in interpreting the shape of individual cells and their basal and luminal relationships. In the rat (Leeson, 1962) the height of the epithelial lining of the rete testis varies from squamous to cuboidal or even low columnar, and it is stated that the thinnest epithelium is found in the main cavity of the rete and the tallest towards the openings of the tubuli recti. In the domestic fowl however, mediastinum testis and tubuli recti are absent (section 3.1) and the encountered variations in the epithelial shape are not linked with any particular region.

The fine structure of these cells is similar to those in the rete testis of the guinea-pig which are described as very active cells (Ladman and Young, 1958). The avian rete cell possesses a prominent Golgi complex, uniformly electron-opaque granules of different sizes and shapes, and RER communicating with SER or large cytoplasmic vacuoles, some of which contain material. All these features provide strong morphological evidence of a significant secretory activity for

the rete cell. This is in contrast to the rete cell of the rat (Leeson, 1962) where the RER and free ribosomes are so sparse, and the Golgi complex so small, that no involvement in secretion is suggested. In a review by Farquhar (1969), it is stated that for secretion to be elaborated small secretory granules arise within the Golgi cisternae, pinch off and merge to form large aggregates of variable shape. The polymorphous images thus formed round up to form ovoid or elliptical mature granules. The granular content of the rete of the fowl fits this description well since the Golgi granules (Fig. 112) correspond to the smallest of the population, and the elliptical or round forms to the largest described by Farquhar (1969). The secretion is probably protein because of the involvement of the RER. If this is so, then the association of the RER and the vacuolar structures needs explanation. Secretory products are generally believed to be synthesized on ribosomes, transferred to the cavities of the endoplasmic reticulum, and conveyed via collections of intermediary vesicles to the Golgi complex, where they are concentrated into secretory granules (Farquhar, 1969). The material contained in the vacuoles in the rete cells of the fowl may thus represent an unconcentrated form of secretion. Also, vacuoles in the neighbourhood of the Golgi complex are numerous. However, the coalescence of some of the vacuoles seen in figure 114 could cast doubts on this suggestion. These cases may not represent the formation of secretory material for the Golgi complex.

The few vacuolated forms of electron-opaque bodies observed in the rete cells are presumably lysosomes, because in addition to their morphological structure, which cannot be a sole criterion for identification (Daems, Wisse, and Brederoo, 1969), acid phosphatase activity has

been demonstrated in this region (Lake, 1962). Also the present study reveals the presence of exogenous bodies, i.e. spermatozoa, the digestion of which is probably associated with lysosomal activity. The incorporation of spermatozoa in the cell cytoplasm indicates their uptake from the lumen, an observation that has not hitherto been reported in mammals or birds, except for a brief passing reference to intracellular spermatozoa in the ductuli efferentes of a bull and the epididymis of a rabbit (Nicander, 1963).

It is of a particular interest to find that there is an exceptionally rich distribution of nerves in the subepithelial tissue whereas the muscle fibres are few; also there is a close association between nerve axons and the basal lamina. It is possible that the axons as seen in the sections are merely passing by on the way to the muscle fibres or blood vessels; however, it is equally possible that they form synaptic contacts with the epithelial cells. When this observation is considered jointly with the presence of fibrils in the rete cells it might suggest a contractile mechanism. Thus, in addition to whatever other functions subserved by the rete cells they may collectively act as a pulsating organ. In the absence of a thick muscular coat or cilia, this mechanism could enhance the movement of spermatozoa from the seminiferous tubules to the ductuli efferentes.

#### 4.4.2 Non-ciliated Type I Cell:

This cell is present in the ductuli efferentes and the narrow parts of the connecting ductules. They contain many mitochondria which indicate an active metabolic role for the cell. The presence of a highly developed system of SER could indicate the production of a secretory material. The latter cannot be glycogen since none was

demonstrated in the histochemical (section 3.2.1) and electron microscopic investigations. Protein-rich secretory products are generally supposed to be elaborated from RER, but this is poorly developed in type I cells so it is unlikely that this cell is manufacturing protein secretion. SER occurs in cells with different functions (Fawcett, 1966); for example, in the liver it is concerned with detoxification mechanisms and with lipid and cholesterol metabolism; in the intestine it functions in lipid transport; in testis, ovary and adrenal it is involved in the biosynthesis of steroid hormones. Since the SER is morphologically similar in all these sites its significance in the non-ciliated type I cell remains to be studied.

The similar electron-opacity of the Golgi granules, the presence of cytoplasmic granules (with or without limiting membranes) worm-like structures and dense granules of the compound heterogeneous bodies and the dark homogeneous bodies in the type I cells raises the question as to whether all these cytoplasmic structures originate in the Golgi complex, and if so, as to whether they arise from the same Golgi granule or are derived from more than one type of granule in the Golgi.

The electron-dense granules within the Golgi cisternae, and the membrane-limited granules scattered in the cytoplasm of type I cells, may be secretory granules or primary lysosomes since membranes of both of these are generally considered to be derived from the Golgi complex and even from the same cisternae (Farquhar, 1969). In a review by De duve and Wattiaux (1966) it is stated that there is evidence in cells for the discharge of lysosomal enzymes into intra-cellular vacuoles or in the extra-cellular medium.



In their review on the morphological identification of lysosomes, Daems et al. (1969) state that they form an extremely heterogeneous population as a result of their functional activity and contain a number of acid hydrolases and exogenous material previously ingested by the cell. Further they add that lysosomes cannot be recognized solely from their fine structure. The demonstration of an intense acid phosphatase activity in the epithelial lining of the ductuli efferentes of the domestic fowl (Lake, 1962), which is partially constituted of type I cells, could be supporting evidence.

Thus, most, if not all of the heterogeneous bodies observed in type I cell could be considered as various forms of lysosomes. The granular material and vacuolation may well represent enzymes and the products of digestion (Holtzman, 1969). Structures identical to the multigranular bodies seen in type I cells are described in the human oocyte by Hertig and Adams (1967) and Hertig (1968) who suggest that they function in the transport of nutritive material in the compound aggregates, either from oocyte to follicle or vice versa. The multigranular bodies in the type I cell could be regarded as different forms of secondary lysosomes, an interpretation ruled out by Hertig and Adams for the oocyte because of the lack of demonstrable acid phosphatase activity therein.

The presence of the worm-like structures in type I cells is interesting. Different methods of fixation and staining procedures were employed to identify these structures and osmication appears to be primarily the factor necessary to demonstrate their presence. Their electron-opacity is enhanced by staining with lead and uranyl compounds. Therefore it is likely that lipids or phospholipids are incorporated in

their structure, and indeed the presence of both neutral and phospholipids in type I cells has been demonstrated histochemically (section 3.2). The worm-like structures are not likely to contain metal ions since they are not revealed after permanganate or aldehyde fixation.

The variety of profiles presented by the worm-like structures suggests they have three dimensional structure. This could be a largely tubular, but occasionally, lamellar reticulum; their contents are usually compact but dilated regions, containing less dense material, are also present. The observation of cellular debris and residues within the cavity of some could indicate that they have taken up material that was present in the lumen of the excurrent ducts. Indeed the contiguity of some of the structures with the cell surface suggests an uptake of testicular or other fluid secretions from the lumen by a process of pinocytosis; thus concentrating the seminal fluids as occurs in mammalian efferent and epididymal ducts (Mason and Shaver, 1952; Crabo and Gustafsson, 1964; Setchell, 1970). The process is aided by the presence of a large number of microvilli which increase the surface area. However, the interpretation of dynamic processes from static pictures is hazardous and the possibility that the worm-like organelles in type I cell represent a secretory activity cannot be excluded.

In the review of Daems et al. (1969), lysosomes are shown to have a certain affinity to staining with heavy metals such as phosphotungstic acid (PTA). On the application of the method to the mouse kidney the apical tubular invaginations of the epithelial cells of the proximal tubules, together with some fragmentary elements randomly scattered around them, are found to be PTA-positive. According to

Daems et al. (1969) these are the structures responsible for the ingestion of exogenous proteins. Although PTA was not employed in the examination of the worm-like structures in type I cell, their shape and electron-opacity are very similar to the phagosomal membranes of the mouse kidney. Moreover, elements identical to the worm-like structures are observed in the lining cells of the proximal convoluted tubule of the kidney of the fowl (Siller, 1971); such cells are well known for their absorptive function (Ericsson and Trump, 1969). The incorporation of the dense individual or multigranular bodies within the cytoplasmic vacuoles as seen in type I cell is considered as a normal process of fusion of a phagosome (vesicle) with a lysosome (granular structures) resulting in the formation of a secondary lysosome. This process is well known in cells and is described in detail by De duve and Wattiaux (1966).

#### 4.4.3 Non-ciliated Type II Cell:

This is the chief type of cell in the large connecting ductules, ductus epididymidis and ductus deferens. Their main structural features are a remarkable content of rough and transitional endoplasmic reticulum (mostly distended with a flocculent material), the presence of a Golgi complex, consisting of piled cisternae, vacuoles and numerous peripheral vesicles and many vacuoles of SER and dense membrane-bound bodies located in the apical cytoplasm. These cytological features are essentially similar to those of exocrine secretory glands, namely, the pancreas (Caro and Palade, 1964; Palade, 1966; Jamieson and Palade 1967 a,b) and salivary glands (Scott and Pease, 1959; Parks, 1961; Hand, 1970), which suggests a secretory function for the type II cells, and that the secretory product is proteinaceous. The intracellular

synthesis and transport of secretion appears to follow the steps postulated for zymogen granules.

In the pancreas, it has been established that the synthesis of secretory proteins occurs on ribosomes attached to the membranes of RER, the protein is then thought to be transferred to and segregated in the cavities of RER cisternae and transported from the latter to condensing vacuoles of the Golgi complex, possibly via small vesicles located in the periphery of the complex (Caro and Palade, 1964; Palade, 1966; Redman, Siekevitz and Palade, 1966; Jamieson and Palade, 1967 a,b). The Golgi complex concentrates the product into secretory granules and supplies them with surrounding membranes. Extrusion of a secretory granule takes place by the fusion of its membrane with that of the cell (Farquhar, 1969). In the type II cell the cisternae of the rough and the transitional forms of ER are observed with variable content of a flocculent material which is probably protein. The smooth-surfaced vesicles present in the type II cells can be assumed to bud off from the ribosome-free portions of the transitional ER (Jamieson and Palade, 1967 a,b; Hand, 1970) and ferry the secretion to the Golgi complex.

In the cytoplasm of type II cells two kinds of electron-opaque bodies occur. The homogeneously-dense type resemble the secretory granules which have been described for exocrine glands; the different shapes and forms of the granules may represent steps of their formation into a final secretory product (Farquhar, 1969). The small granules arising within the Golgi cisternae are possibly the result of the concentration of the secretory product. The granules in the type II cell, which are seen to share a common membrane, possibly indicate a merging together after they have pinched off from the Golgi. The ovoid

or elliptical granules could represent mature forms, the discharge of which is similar to that demonstrated for zymogen in the pancreatic exocrine cells.

The vacuolated electron-dense bodies in type II cell are probably lysosomes not only because they differ morphologically from secretory granules, but also because an intense acid-phosphatase activity has been found in those parts of the excurrent duct system lined by type II cells (Lake, 1962). The particular fine structure coupled with the demonstration of the presence of acid hydrolases can justifiably be used to identify lysosomes (Daems *et al.*, 1969). The vacuoles seen in the dense bodies are electron-lucent and may indicate the presence of lipid. Some of the bodies resemble the lipofuscin pigment described by Samarjski, Ordj and Keefe (1965) in the nervous system of aged mice.

It appears that the type II cells, like the cells of the rete and ciliated cells, take up spermatozoa from the lumen of the excurrent ducts. Spermatozoa are found in the apical and basal aspects of the cells and in wide intercellular spaces. A role of the abundance of lysosomes in the type II cells could be the digestion of phagocytosed spermatozoa.

The fine fibrillar elements embedded in the cytoplasmic matrix of type II cell is interesting. The subepithelial tissue is richly innervated and nerve endings were seen in an adjacent location to the basal lamina. It is tempting to suggest that these two facts may indicate the existence of a contractile mechanism in the epithelium serving to move spermatozoa along the duct system, and may also aid in the expulsion of the secretory granules from type II cell into the lumen.

The epithelial lining of the mammalian epididymis is composed of two cell types, a predominant stereociliated and a non-ciliated type. The latter is believed to be active in holocrine secretion (Martan and Risley, 1963b; Martan and Allen, 1964; Martan, Risley and Hruban, 1964). In electron micrographs, holocrine cells are identifiable by their lack of stereocilia, the presence of large clear vacuoles, filled with a finely granular material in the apical cytoplasm, and an overall density which is greater than that of the principal cells. The cells are distinguished also on the basis of various cytochemical properties. The mature cells may be discharged into the lumen or they may disintegrate in situ; they are then replaced by other cells of the same kind which develop from basal cells and the cycle is repeated. The dark slender cells in the fowl tract, essentially similar to the type II cells, but considered as merely a variation of the same cell type, are the only cells which could resemble the mammalian holocrine cells. However, they are not devoid of stereocilia and have no cytoplasmic vacuoles. Like the main cells (type II cells) they reach the basal lamina and are not related to the replacing basal cells of holocrine secretion. None of the dark avian cells are seen rupturing into the lumen or undergoing disintegration. Accordingly in the excurrent ducts of the cock it is considered that there is no evidence for the existence of a holocrine secretory activity.

The fact that type II cells constitute the epithelial lining of both the ductus epididymidis and ductus deferens of the domestic fowl could be considered as further support for an earlier suggestion (section 4.1) that the avian ductus epididymidis and ductus deferens are merely different segments of the same organ; an organ equivalent

to the epididymis of mammals.

#### 4.4.4 Ciliated Cells:

The ciliated cells occur in the epithelium of the ductuli efferentes and narrow connecting ductules. Most of the ciliated cells do not appear to reach the basal lamina, but as some are seen to reach the basal lamina, the first impression may be due to plane of section. The cilia are similar to those of the analogous mammalian cells and they obviously function in moving spermatozoa along the excurrent ducts. In view of the sparsity of muscle fibres in the walls of the avian ductuli efferentes and narrow connecting ductules and the presence of only very few presumed contractile basal cells, which are more abundant in other regions of the avian ducts, it is possible that ciliary action is more important for moving spermatozoa along these ducts of the fowl than in the mammal where there are comparatively more muscle cells.

The significance of the perinuclear fibrillar cytoplasmic bundles in the ciliated cells is not clear but it is feasible that they are contractile elements which would also play a part in the movement of spermatozoa. A nerve axon contact with these cells was not seen, possibly because they rarely reach the basal lamina.

The concentration of the mitochondria and other organelles in the supra-nuclear cytoplasm indicates a juxta-ciliary localized metabolic activity. Examination of the ultrastructure of the ciliated cell shows little or no secretory activity, but as a strong diffuse acid phosphatase reaction is demonstrated in the epithelium (Lake, 1962), it is possible that the electron-dense bodies are various morphological types of lysosomes. The small, heterogeneously-dense and membrane-bound granules are probably primary lysosomes, while the other heterogeneous

types of granules, like those of type I cells, are probably secondary lysosomes. The electron-opaque granules around the ciliary roots may be precursors associated with ciliogenesis (Steinman, 1968).

The appearance of the electron-lucent material in the vacuoles of the apical cytoplasm and its similarity to that of the accumulated seminal fluid in the lumen suggests that the vacuolar content is drawn from the lumen. This feature, taken in conjunction with the rough-coated vesicles present on the surface, implies an uptake of seminal fluid by pinocytosis. It is concluded then that these cells play a role in the resorption of testicular fluid, a function which they share with type I cells. In mammals (Mason and Shaver, 1952; Crabo and Gustafsson, 1964) most of the fluid produced in the seminiferous tubules, and in which the spermatozoa are carried, is resorbed in the efferent ductules and in the proximal part of the epididymal duct. The latter region corresponds to the avian connecting ductules in which the ciliated cells are also present. Reid and Cleland (1957) state that the testis of the rat produces large amounts of fluid, most of which is subsequently resorbed by the epididymal cells. Ample structural evidence for pinocytosis of luminal content by the epithelial cells of the mammalian epididymis is presented by Burgos (1964) and Nicander (1965).

The presence of sections of spermatozoa in cytoplasmic vacuoles and in invaginations of the plasma membranes of a normal, healthy ciliated epithelium is regarded as evidence for a phagocytic activity by this cell type. The presence of lysosomes which aid in the digestion of exogenous material is compatible with this cell functioning partly in the resorption of fluids, spermatozoa and probably the products of



sperm breakdown.

#### 4.4.5 Basal Cell:

There are at least three possible roles for the basal cells, viz. (1) they may be early forms of ciliated cells, (2) they may represent preliminary stages of holocrine cells, analogous to those found in the mammalian epididymides, or (3) they may be similar to myoepithelial cells.

Some of the fine structural features of the basal cells resemble those of the ciliated cells, e.g. the presence of electron-dense cytoplasm and fibrillar bundles. However, most basal cells are found where ciliated cells are absent. The ciliated cells are mainly in the ductuli efferentes and connecting ductules, where few basal cells are present.

Holocrine cells have been reported in the epididymides of several mammalian species, including the rat (Martan and Risley, 1963 a,b; Risley and Skrepetos, 1964 a), mouse (Martan and Allen, 1964) and man (Martan, Risley and Hruban, 1964). They are distinguished from other cells by their morphological appearance and by certain cytochemical properties. They appear to develop from basal cells and, during their differentiation, grow towards the lumen with an expanded apical portion while maintaining thin narrow connections with the basal lamina. They are supposed to finally disintegrate in situ or escape into the lumen. The basal cell in the bird is not regarded as a precursor stage of a holocrine cell for several reasons. The avian basal cells maintain generally the same shape. They have no association with the lumen whatsoever and indeed, the overlying tall epithelial cells provide an extensively wide barrier between the two. Furthermore, the basal cells

maintain desmosomal connections with the overlying epithelia, a feature which is unlikely to occur in a cell that is destined to be released into the lumen. Disintegrating basal cells were not seen.

Myoepithelial cells exist in a number of exocrine organs such as the salivary glands, mammary glands, sweat glands and Harderian glands. They are contractile elements similar to smooth muscle cells which expel the secretion. Accounts of their distribution, structure and function are given by a number of different workers (Linzel, 1955; Leeson, 1956, 1960; Scott and Pease, 1959; Parks, 1961; Rhodin, 1963; Shear, 1964; Tandler, 1965; Tamarin, 1966; Yamauchi and Burnstock, 1967; Helminen and Ericsson, 1968). On the basis of these reports, the basal cells observed in the present work seem to have the following features in common with myoepithelial cells: (1) a location between the basal lamina and the chief lining cells to which they are attached by desmosomes, (2) dense cytoplasm containing fibrillar bundles and electron-dense bodies, (3) large ellipsoidal nuclei occupying the major portion of the cell, (4) a few large mitochondria and a general paucity of RER, and (5) establish basal contacts with nerve endings.

The basal cells occurring in the cock genital ducts are not identical in shape to myoepithelial cells but the latter themselves seem to be subject to variation in different glands. In the submaxillary gland of the rat, for example, myoepithelial cells of acini are in the form of an irregularly-branched network and those of the intercalated ducts ramify less (Leeson, 1956; Tamarin, 1966). Spindle-shaped forms of myoepithelial cells exist and they give rise to the use of the term "basket cells" in light microscopy. Scott and Pease (1959) studied the salivary and lacrimal glands of the rat and note occasional branching of

the cells. Moreover, the fibrillar bundles seen in basal cells are different from those of myoepithelia and they look more like tonofibrils.

The close association of myoepithelial cells and effector nerves has been observed in the sublingual gland of the rat (Scott and Pease, 1959), submaxillary gland of the rat (Tamarin, 1966) and the lacrimal gland of sheep (Yamauchi and Burnstock, 1967). It seems reasonable to assume that the avian basal cells subserve a similar function to myoepithelia or transitional forms between myoepithelial and true epithelial cells. Whatever their nature the presence of fibrillar bundles in the cell cytoplasm, together with the intimate nerve-cell association, suggest an active contractile function analogous to that of myoepithelial cells. It is likely that the nerve-cell contacts are functional synapses through which activation of the cell may occur. It is possible that these cells aid in the expulsion of cellular secretion and/or ejaculation, especially, since they are found in abundance in the ductus deferens and its ampulla.

#### 4.5 LIGATION EXPERIMENTS:

It is well known that different cell types with phagocytic properties are found in the mammalian testes and their efferent duct systems (Shaver, 1954; Macmillan, 1957; Macmillan and Clegg, 1961, 1963; Clegg and Macmillan, 1961, 1965 a,b; Burgos, 1964; Nicander, 1965; Sedar, 1966; Carr, Clegg and Macmillan, 1968). A recent report by Atwal and McFarland (1971) shows that Sertoli cells in the quail have phagocytic properties. Suspensions of various particulate materials have been injected into the duct systems of mammals and subsequent examination by light or electron microscopy shows their uptake by the epithelial cells. Atwal and McFarland (1971) show that Sertoli cells

and the epithelial cells lining the excurrent ducts of the testis in the quail increase their absorption of cell debris and foreign particles when treated with the chlorinated insecticide, Kepone, which has oestrogenic properties. The present work provides conclusive evidence for cells of the surface epithelia of the avian male excurrent duct system being phagocytic towards spermatozoa. The fact that the lining epithelia maintain a healthy appearance and that the junctional complexes are quite intact is considered to rule out any possibility that the luminal spermatozoa may have entered the cell cytoplasm or the intercellular spaces as a result of mechanical damage of the epithelia. Spermatozoa are often found in apical invaginations, formed by microvilli, of the surface epithelia which illustrates the method of uptake.

Other observations suggest the fate of the spermatozoa once they have been engulfed by the epithelial cells. The epithelial cells contain lysosomes (section 3.4) which may digest some of the spermatozoa phagocytosed. However, many sections of spermatozoa are observed lying free in the intercellular spaces which could indicate that some spermatozoa escape the lysosomal action and are released from the basal poles of the cells. This could account for the appearance of macrophages laden with spermatozoa just above the basal lamina (Fig. 171). After ingesting spermatozoa, they probably return to their normal position and hence the appearance also of the sperm-containing subepithelial macrophages.

Disintegration of luminal spermatozoa is described in the epididymis and ductus deferens of the guinea-pig by Young and Simeone, (1930); Young, (1931) and Simeone and Young (1931). They suggest this is a method for eliminating unejaculated spermatozoa. Subsequent

investigations by Amann and Almquist (1962), Glover (1969) and Paufler and Foote (1969) working with a variety of mammals agree with Simeone and Young; these observations were made on epididymides and regional variations in activity within epididymal segments are reported between different species. The caput epididymidis is the main active site for the destruction of spermatozoa in the rabbit (Paufler and Foote, 1969), and the cauda epididymidis is the most active segment in the dairy bull (Amann and Almquist, 1962). In the domestic fowl luminal disintegration of spermatozoa appears mainly in the ductuli efferentes and is particularly noticeable three weeks after ligation of the ductus deferens.

The question of the ultimate fate of the products of breakdown of spermatozoa in normal animals is a fascinating one. Long ago, Young and Simeone (1930) and Simeone and Young (1931) considered the possibility of their voidance in urine and/or ingestion by epithelial cells of the excurrent ducts. The luminal macrophages in the fowl which ingest spermatozoa and which increase in number in a ligated tract may be similar to those described by Holstein (1967) in the epididymis of man. The mechanism by which these cells get access to the lumen remains unknown. Their final fate is also not clear; they could undergo disintegration in situ, and the cellular fragments of the intact cells may be disposed of in the same manner as the disintegrating spermatozoa.

It is concluded from this study that luminal disintegration, uptake by all surface epithelia and phagocytosis by luminal and tissue macrophages are among the factors dealing with the disposal of unejaculated spermatozoa in the reproductive tract of the domestic fowl.

#### 4.6 GENERAL ANATOMICAL ASPECTS OF THE EXCURRENT DUCTS IN RELATION TO FUNCTION:

The ductus epididymidis and ductus deferens of the fowl appear to have many features in common. They run a similar tortuous course, their lining epithelia are identical on light and electron microscopical evidence, and they are the only cholinesterase-positive cells in the entire tract. They possess a similar pattern of intrinsic innervation not seen in any of the other regions of the excurrent ducts. It is considered that this justifies a change of the classical nomenclature applied to the anatomy of the male genital tract of the domestic fowl, i.e. the epididymal region and the ampulla of the ductus deferens may be regarded as the caput and cauda epididymidis with the long coiled segment in between as the corpus. Examination of males of different sexual activity shows that good semen producers possess large testes and a turgid, creamy ductus deferens. In contradistinction, poor semen producers generally have small testes and a flaccid ductus deferens. This implies that the epididymis (ductus epididymidis and ductus deferens) acts as a storage organ for semen.

With the exception of the ciliated and basal cells, all the epithelial cells of the excurrent ducts are secretory (probably proteinaceous). This activity is particularly remarkable in the non-ciliated, type II cells, which may also secrete sodium into the seminal plasma.

Resorption of testicular fluids occurs in the efferent ductules of the fowl comparable to that of mammals; the ciliated cells appear to be chiefly active in this respect. This may offer partial explanation for the general sparsity of spermatozoa in the rete testis and ductuli efferentes and their great concentration in the ducts caudally after

the partial resorption of the fluid vehicle has occurred.

Mammalian spermatozoa leaving the seminiferous tubules are carried in a flow of testicular fluids, some of which is resorbed in the ductuli efferentes. It is likely that the same mechanism of movement, aided by the ciliary action of the cells in the ductuli efferentes and narrow connecting ductules, operates in driving spermatozoa along these parts of the duct system in the bird. Further caudally, their movement is aided by muscular contraction in which presumed contractile basal cells play a part.

The disposal of unejaculated spermatozoa occurs in the avian reproductive tract by luminal disintegration, uptake by the cells of the surface epithelia of the excurrent ducts and phagocytosis by luminal and tissue macrophages. Some of the disintegrating luminal contents may be voided in the cloaca. Spermatozoa taken up by the lining epithelia may be partly destroyed by intracellular lysosomes.

It is interesting to note that the intrinsic distribution of nerves is exceedingly dense in the ductus epididymidis and ductus deferens whereas the muscular coat of these organs is much thinner compared to that of mammals. The nerves are closely applied to the epithelium and appear to be closely associated with the basal cells (presumably contractile) and the non-ciliated, type II cells (actively secreting). It is therefore considered likely that the innervation is partly involved in the emission of semen and/or extrusion of cellular secretion. Future physiological studies will be necessary to substantiate or refute this hypothesis; it is a reasonable assumption on anatomical observation.

## ACKNOWLEDGEMENTS

I am greatly indebted to Professor A.R. Muir for his encouragement and the many facilities placed at my disposal in the Department of Veterinary Anatomy. It has been a most pleasant and instructive experience to be guided by Dr. P.E. Lake and Mr. P.G.D. Morris during the course of this work. I wish to thank Dr. A.B. Gilbert and Dr. W.G. Siller for their help and suggestions.

Thanks are due to Mr. E. Roberts, the Chief Technician of the Department, for his help and co-operation. The technical assistance of Messrs. N. Smith, W. Scott, J. Keillor, D. Wallace, J. Strathearn and G. Goodall is greatly acknowledged. I wish to acknowledge also the technical help of Mr. J.M. Stewart of the Poultry Research Centre, Edinburgh.

Sincere thanks and appreciation are extended to my wife Naila for her patience and understanding.

I am grateful to the University of Khartoum for granting the study leave and the ODA for awarding the scholarship.



## REFERENCES.

- ALLEN, J.M. and SLATER, J.J. (1961). A cytochemical analysis of lactic dehydrogenase-diphosphopyridine nucleotide-diaphorase system in the epididymis of the mouse. *J.Histochem. Cytochem.* 9, 221-233.
- AMANN, R.P. (1962). Reproductive capacity of dairy bulls.III.The effect of ejaculation frequency, unilateral vasectomy, and age on spermatogenesis. *Am.J.Anat.* 110, 49-67.
- AMANN, R.P. (1970). Sperm production rates. In: *The Testis. Development, anatomy and physiology*, vol.I, pp. 433-482, eds. A.D. Johnson, W.R. Gomes and N.L. Vandemark. New York and London: Academic Press.
- AMANN, R.P. and ALMQUIST, J.O. (1962). Reproductive capacity of dairy bulls. VI. Effects of unilateral vasectomy and ejaculation frequency on sperm reserves. Aspects of epididymal physiology.*J.Reprod. Fert.* 10, 241-268.
- ATWAL, O.S. and McFARLAND, L.Z. (1971). Carbon uptake response by Sertoli cells and epithelial cells lining the duct system of the Japanese quail (*Coturnix Coturnix Japonica*). *Poult. Sci.* 50, 159-166.
- BAUMGARTEN, H.G., FALK, B., HOLSTEIN, A.-F., OWMAN, Ch. and OWMAN, T. (1968). Adrenergic innervation of the human testis, epididymis, ductus deferens and prostate. A fluorescence microscopic and fluoremetric study. *Z.Zellforsch.mikrosk.* 90, 81-95.
- BAUMGARTEN, H.G. and HOLSTEIN, A.-F. (1968). Adrenergic innervation im Hoden und Nebenhoden vom Schwan (*Cygnus olor*). *Z.Zellforsch. mikrosk.* 91, 402-410.
- BENNETT, T. and MALMFORS, T. (1970). The adrenergic nervous system of the domestic fowl (*Gallus domesticus*). *Z.Zellforsch.mikrosk.* 106, 22-50.
- BIELANSKI, W. and WIERZBOWSKI, S. (1961). Attempts at determination of the daily output of spermatozoa in rams on the basis of the so-called "Depletion Test" carried out at varying intervals. *Proc.Fourth Intern.Cong.Anim.Reprod.* 2, 274-278.
- BLACKSHAW, A.W. and SAMISONI, J.I. (1967). Histochemical localization of some dehydrogenase enzymes in the bull testis and epididymis. *J.Dairy Sci.* 50, 747-752.
- BLOOM, W. and FAWCETT, D.W. (1968). *A Textbook of Histology*, 9th ed., pp. 709-714. Philadelphia, London and Toronto: W.B. Saunders Co.
- BRADLEY, O.C. and GRAHAME, T. (1960). *The Structure of the Fowl*, 4th ed., p.59. Edinburgh and London: Oliver and Boyd.

- BURGOS, M.H. (1964). Uptake of colloidal particles by cells of the caput epididymidis. *Anat. Rec.* 148, 517-525.
- BURROWS, W.H. and QUINN, J.P. (1937). The collection of spermatozoa from the domestic fowl and turkey. *Poult. Sci.* 16, 19-24.
- CARO, L.G. and PALADE, G.E. (1964). Protein synthesis, storage, and discharge in the pancreatic exocrine cells. An autoradiographic study. *J.Cell Biol.* 20, 473-495.
- CARR, I., CLEGG, E.J. and MEEK, G.A. (1968). Sertoli cells as phagocytes. An electron microscopic study. *J.Anat.* 102, 501-509.
- CAVALIÉ, M. (1902). Terminaisons nerveuses dans le testicule chez le lapin et chez le poulet, et dans l'épididyme chez le lapin. *C.R.Soc. Biol.* 54, 298-300.
- CLEGG, E.J. and MACMILLAN, E.W. (1961). Observations on the uptake of trypan blue by the seminiferous tubules of the rat testis. *J.Anat.* 95, 615,P.
- CLEGG, E.J. and MACMILLAN, E.W. (1965a). The uptake and storage of particulate matter by the interstitial cells of the rat testis. *J.Anat.* 99, 204,P.
- CLEGG, E.J. and MACMILLAN, E.W. (1965b). The uptake of vital dyes and particulate matter by the Sertoli cells of the rat testis. *J.Anat.* 99, 219-229.
- COUPLAND, R.E. (1965a). Electron microscopic observations on the structure of the rat adrenal medulla.I.The ultrastructure and organization of chromaffin cells in the normal adrenal medulla. *J.Anat.* 99, 231-254.
- COUPLAND, R.E. (1965b). Electron microscopic observations on the structure of the rat adrenal medulla.II.Normal innervation.*J.Anat.* 99, 255-272.
- COUPLAND, R.E., PYPER, A.S. and HOPWOOD, D. (1964). A method for differentiating between noradrenaline- and adrenaline-storing cells in the light and electron microscope. *Nature, Lond.* 201, 1240-1242.
- CRABO, B. and GUSTAFSSON, B. (1964). The distribution of sodium and potassium and its relation to sperm concentration in the epididymal plasma of the bull. *J.Reprod.Fert.* 7, 337-345.
- CULLING, C.F.A. (1963). *Handbook of Histopathological Techniques*, 2nd ed. London: Butterworths.
- DAEMS, W.Th., WISSE, E. and BREDEROO, P. (1969). Electron microscopy of the vacuolar apparatus. In: *Lysosomes in Biology and Pathology*, vol.I, pp.64-112, eds. J.T. Dingle and H.B. Fell. Amsterdam and London:North-Holland Publishing Co.

- DATTA, S.P. and OTTAWAY, J.H. (1965). Biochemistry. London: Bailliere, Tindall and Cassell.
- De DUVE, C. and WATTIAUX, R. (1966). Functions of lysosomes. Ann. Rev.Physiol. 28, 435-492.
- DeROBERTIS, E.D.P. and BENNETT, H.S. (1955). Some features of the submicroscopic morphology of synapses in frog and earthworm. J.Biophys. Biochem.Cytol. 1, 47-58.
- De ROBERTIS, E., De LORES ARNAIZ, G.R., SALGANICOFF, L., De IRALDI, A.P. and ZIEHER, L.M. (1963). Isolation of synaptic vesicles and structural organization of the acetyl-choline system within brain nerve endings. J.Neurochem. 10, 225-235.
- DUNNIGAN, M.G. (1968). The use of Nile blue sulphate in the histochemical identification of phospholipids. Stain Tech. 43, 249-256.
- EARL, C.J. and THOMPSON, R.H.S. (1952). The inhibitory action of tri-ortho-cresyl phosphate on cholinesterases. Brit.J.Pharmacol. 7, 261-269.
- El-BADAWI, A. and SCHENK, E.A. (1967). The distribution of cholinergic and adrenergic nerves in the mammalian epididymis. A comparative histochemical study. Am.J.Anat. 121, 1-14.
- El JACK, M.H. and LAKE, P.E. (1969). The distribution of the principal inorganic ions in semen from the vas deferens of the domestic fowl and the content of carbon dioxide in the seminal plasma. Q.Jl.exp.Physiol. 54, 332-340.
- ERICSSON, J.L.E. (1969). Mechanisms of cellular autophagy. In: Lysosomes in Biology and Pathology, vol.II, pp. 345-394, eds. J.T. Dingle and H.B. Fell. Amsterdam and London: North-Holland Publishing Co.
- ERICSSON, J.L.E. and TRUMP, B.F. (1969). Electron microscopy of uriniferous tubule. In: The Kidney, vol.I, pp. 353-447, eds. C. Rouiller and A.F. Muller. London: Academic Press.
- FALK, B., OWMAN, Ch. and SJÖSTRAND, N.O. (1965). Peripherally located adrenergic neurons innervating the vas deferens and the seminal vesicle of the guinea-pig. Experientia 21, 98.
- FARQUHAR, M.G. (1969). Lysosomal function in regulating secretion: disposal of secretory granule in cells of anterior pituitary gland. In: Lysosomes in Biology and Pathology, vol.II, pp. 462-482, eds. J.T. Dingle and H.B. Fell. Amsterdam and London: North-Holland Publishing Co.
- FAWCETT, D.W. (1966). An Atlas of Fine Structure. The Cell. Philadelphia and London: W.B. Saunders Co.
- FLICKINGER, C.J. (1969). Fenestrated cisternae in the Golgi apparatus of the epididymis. Anat.Rec. 163, 39-53.

- FOOTE, R.H. (1962). The use of radioactive isotopes to study spermatogenesis and transport of spermatozoa in mammals. *Symp.Gen.Biol. Italica*, 2, 55-73.
- FOURMAN, J. (1966). Cholinesterase in the mammalian kidney. *Nature*, Lond. 209, 812-813.
- FOURMAN, J. (1969). Cholinesterase activity in the supra-orbital salt secreting gland of the duck. *J.Anat.* 104, 233-239.
- GILBERT, A.B. (1961). The innervation of the inner portal valve of the domestic fowl. *J.Anat.* 95, 594-598.
- GILBERT, A.B. (1965). Innervation of the ovarian follicle of the domestic hen. *Q.Jl.exp.Physiol.* 50, 437-445.
- GILBERT, A.B. and LAKE, P.E. (1963). Terminal innervation of the uterus and vagina of the domestic hen. *J.Reprod.Fert.* 5, 41-48.
- GLOVER, T.D. (1969). Some aspects of function in the epididymis. Experimental occlusion of the epididymis in the rabbit. *Int.J.Fert.* 14, 215-221.
- GLOVER, T.D. and NICANDER, L. (1971). Some aspects of structure and function in the mammalian epididymis. *J.Reprod.Fert.Supp.* 13, 39-50.
- GLOVER, T.D. and SALE, J.B. (1969). The reproductive system of the male rock hyrax (*Procavia* and *heterohyrax*). *J.Zool.* 156, 351-362.
- GOMORI, G. (1952). *Microscopic Histochemistry: Principles and Practice*. Chicago: University of Chicago Press.
- GRAY, D.J. (1947). The intrinsic nerves of the testis. *Anat.Rec.* 98, 325-335.
- GRAY, J.C. (1937). The anatomy of the male genital ducts in the fowl. *J.Morph.* 60, 393-405.
- GREENAWALT, J.W., ROSSI, C.S. and LEHNINGER, A.L. (1964). Effect of active accumulation of calcium and phosphate ions on the structure of rat liver mitochondria. *J.Cell Biol.* 23, 21-38.
- GRILLO, M.A. (1966). Electron microscopy of sympathetic tissues. *Pharmacol. Rev.* 18, 387-399.
- GRIGG, G.W. and HODGE, A.J. (1949). Electron microscopic studies of spermatozoa. I. The morphology of the spermatozoon of the common domestic fowl (*Gallus domesticus*). *Aust.J.Sci.Res.Ser., B.* 2, 271-286.
- HAND, A.R. (1970). The fine structure of von Ebner's gland of the rat. *J.Cell Biol.* 44, 340-353.
- HELMINEN, H.J. and ERICSSON, J.L.E. (1968). Studies on the mammary gland involution. I. On the ultrastructure of the lactating mammary gland. *J.Ultrastruct.Res.* 25, 193-213.

- HERTIG, A.T. (1968). The primary human oocyte. Some observations on the fine structure of the Balbiani's vitelline body and the origin of the annulate lamellae. *Am.J.Anat.* 122, 107-138.
- HERTIG, A.T. and ADAMS, E.C. (1967). Studies on the human oocyte and its follicle. I. Ultrastructural and histochemical observations on the primordial follicle stage. *J.Cell Biol.* 34, 647-675.
- HODSON, N. (1970). The nerves of the testis, epididymis, and scrotum. In: *The Testis. Development, anatomy and physiology*, vol. I, pp 47-99, eds. A.D. Johnson, W.R. Gomes and N.L. Vandemark. New York and London: Academic Press.
- HÖKFELT, T. (1968). Invitro studies on central and peripheral monoamine neurons at the ultrastructural level. *Z.Zellforsch.mikrosk.* 91, 1-74.
- HOLSTEIN, A.-F. (1967). Spermiofagen im Nebenhoden des Menschen. *Naturwiss.* 54, 98-99.
- HOLTZMAN, E. (1969). Lysosomes in the physiology and pathology of neurons. In: *Lysosomes in Biology and Pathology*, vol. I, pp.192-216, eds. J.T. Dingle and H.B. Fell. Amsterdam and London: North-Holland Publishing Co.
- ~~HSIEH~~  
HSIEH, T.M. (1951). The sympathetic and parasympathetic nervous system of the fowl. Ph.D. Thesis, Edinburgh University.
- JAMIESON, J.D. and PALADE, G.E. (1967a). Intracellular transport of secretory proteins in the pancreatic exocrine cell. I. Role of peripheral elements of the Golgi complex. *J.Cell Biol.* 34, 577-596.
- JAMIESON, J.D. and PALADE, G.E. (1967b). Intracellular transport of secretory proteins in the pancreatic exocrine cell. II. Transport to condensing vacuoles and zymogen granules. *J.Cell Biol.* 34, 597-615.
- KATZ, B. (1962). The transmission of impulses from nerve to muscle, and the subcellular unit of synaptic action. *Proc.Roy.Soc.B.* 155, 455-479.
- KAUPP, B.F. (1915). Male reproductive organs of birds. *Am.J.Vet.Med.* 10, 461-464.
- KOBLICK, D.C., GOLDMAN, M.H. and PACE, N. (1962). Cholinesterase and active sodium transport in frog skin. *Am.J.Physiol.* 203, 901-902.
- KOCH, H.J. (1954). Cholinesterase and active transport of sodium chloride through the isolated gill of the crab. In: *Recent Development in Cell Physiology*, pp.15-31, ed. J.A. Kitching. London: Butterworths Scientific Publications.
- KRETH, H.W. (1965). Über die Hellen zellen im Ductus epididymidis der Ratte. *Z.Zellforsch. mikrosk.* 68, 28-42.

- LADMAN, A.J. and YOUNG, W.C. (1958). An electron microscopic study of the ductuli efferentes and rete testis of the guinea-pig. *J.Biophys. Biochem.Cytol.* 4, 219-226.
- LAKE, P.E. (1957). The male reproductive tract of the fowl. *J.Anat.* 91, 116-129.
- LAKE, P.E. (1962). Histochemical demonstration of phosphomonoesterase secretion in the genital tract of the domestic cock. *J.Reprod.Fert.* 3, 356-362.
- LAKE, P.E. (1966). Physiology and biochemistry of poultry semen. In: *Advances in Reproductive Physiology*, vol.I, pp.93-123, ed. A.McLaren, London: Logos Press.
- LAKE, P.E. and EL JACK, M.H. (1966). The origin and composition of fowl semen. In: *Physiology of the Domestic Fowl*, pp. 44-51, eds. C. Horn-Smith and E.C. Amoroso. Edinburgh: Oliver and Boyd.
- LAKE, P.E. and McINDOE, W.M. (1959). The glutamic acid and creatine content of cock seminal plasma. *Biochem.J.* 71, 303-306.
- LAKE, P.E., SMITH, W. and YOUNG, D. (1968). The ultrastructure of the ejaculated fowl spermatozoon. *Q.Jl.exp.Physiol.* 53, 356-366.
- LEESON, C.R. (1956). Localization of alkaline phosphatase in the sub-maxillary gland of the rat. *Nature, Lond.* 178, 858-859.
- LEESON, C.R. (1960). The electron microscopy of the myoepithelium in the rat exorbital lacrimal gland. *Anat.Rec.* 137, 45-55.
- LEESON, T.S. (1962). Electron microscopy of the rete testis of the rat. *Anat.Rec.* 144, 57-67.
- LEWIS, P.R. and SHUTE, C.C.D. (1965). Electron microscopic distribution of cholinesterase in cholinergic neurones. *J.Anat.* 99, 941,P.
- LINO, B.F., BRADEN, A.W.H. and TURNBULL, K.E. (1967). Fate of unejaculated spermatozoa. *Nature, Lond.* 213, 594-595.
- LINZEL, J.L. (1955). Some observations on the contractile tissue of the mammary glands. *J.Physiol.* 130, 257-267.
- LORENZ, F.W. (1959). Reproduction in the domestic fowl: Physiology of the male. In: *Reproduction in Domestic Animals*, vol.II, pp.343-396, eds. H.H. Cole and P.P. Cupps. New York: Academic Press.
- McINTOSH, J.R. and PORTER, K.R. (1967). Microtubules in the spermatids of the domestic fowl. *J.Cell Biol.* 35, 153-173.
- MACMILLAN, E.W. (1957). The caput epididymidis and trypan blue. *J.Anat.* 9, 616, P.
- MACMILLAN, E.W. and CLEGG, E.J. (1961). The transport of trypan blue by the seminiferous tubules of the rat testis. *J.Anat.* 95, 615, P.

- MACMILLAN, E.W. and CLEGG, E.J. (1963). Observations on the uptake of Indian ink by the seminiferous tubules and the excurrent duct system of the rat testis. *J.Anat.* 97, 154, P.
- MANN, T. (1964). *The Biochemistry of Semen and of the Male Reproductive Tract.* London: Methuen.
- MARAUD, R. (1963). Recherches expérimentales sur les facteurs inducteurs de la formation de l'epididyme du coq (*Gallus gallus*). *Archs.Anat.microsc.Morphol.exp.* 52, 83-128.
- MARTAN, J. and ALLEN, J.M. (1964). Morphological and cytochemical properties of the holocrine cells in the epididymis of the mouse. *J.Histochem.Cytochem.* 12, 628-639.
- MARTAN, J. and RISLEY, P.L. (1963a). The epididymis of mated and unmated rats. *J.Morph.* 113, 1-15.
- MARTAN, J. and RISLEY, P.L. (1963b). Holocrine secretory cells of the rat epididymis. *Anat. Rec.* 146, 173-189.
- MARTAN, J., RISLEY, P.L. and HRUBAN, Z. (1964). Holocrine cells of the human epididymis. *Fertil.Steril.* 15, 180-187.
- MARVAN, Fr. (1969). Postnatal development of the male genital tract of the *Gallus domesticus*. *Anat.Anz.* 124, 443-462.
- MASON, K.E. and SHAVER, S.L. (1952). Some functions of the caput epididymidis. *Ann.N.Y.Acad.Sci.* 55, 585-593.
- MATTHEWS, M.R. and RAISMAN, G. (1969). The ultrastructure and somatic efferent synapses of small granule-containing cell in the superior cervical ganglion. *J.Anat.* 105, 255-282.
- MILLONIG, G. (1962). Further observations on a phosphate buffer for osmium solutions in fixation. *Proc.Fifth Int.Cong.Electron Microsc.* vol. II, p. P-8, ed. S.S. Breese. New York and London: Academic Press.
- MITCHELL, G.A.G. (1953). Visceral nerves demonstrated by combined intravital and supravital techniques. *Acta Anat.* 18, 81-86.
- MYERS, D.K. (1953). Studies on cholinesterase. 9. Species variation in the specificity pattern of the pseudo cholinesterases. *Biochem.J.* 55, 67-79.
- NAMBA, T., NAKAMURA, T. and GROB, D. (1967). Stain of nerve fibre and cholinesterase activity in fresh frozen sections. *Am.J.Clin.Path.* 47, 74-77.
- NAGANO, T. (1962). Observations on the fine structure of the developing spermatid in the domestic chicken. *J.Cell Biol.* 14, 193-205.
- NICANDER, L. (1957). On the regional histology and cytochemistry of the ductus epididymidis in rabbits. *Acta morph.neerl.-Scand.* 1, 99-118.

- NICANDER, L. (1963). Resorption phenomena in the epididymis. *Int.J. Fert.* 8, 866.
- NICANDER, L. (1965). An electron microscopical study of absorbing cells in the posterior caput epididymidis of rabbits. *Z.Zellforsch. mikrosk.* 66, 829-847.
- NICANDER, L. and HELLSTRÖM, B. (1967). Increased thickness of the inner mitochondrial membrane during sperm maturation in the domestic rooster. *Exptl.Cell Res.* 48, 622-625.
- NISHIDA, T. (1964). Comparative and topographical anatomy of the fowl. XLII. Blood vascular system of the male reproductive organs. *Jap.J. Vet.Sci.* 26, 211-221.
- ORGBIN-CRIST, M.C. (1965). Passage of spermatozoa labelled with thimidine-<sup>3</sup>H through the ductus epididymidis of the rabbit. *J.Reprod. Fert.* 10, 241-251.
- OSLUND, R.M. (1928). The physiology of the male reproductive system. *J.Am.Med.Assoc.* 1, 829-830.
- PALADE, G.E. (1966). Structure and function at cell level. *J.Am.Med. Assoc.* 198, 815-825.
- PARKER, J.E., MCKENZIE, F.F. and KEMPSTER, H.L. (1942). Fertility in the male domestic fowl. *Bull.Univ.Mo.Agric.Expt.Stn.no.* 347.
- PARKS, H.F. (1961). On the fine structure of the parotid gland of mouse and rat. *Am.J.Anat.* 108, 303-329.
- PAUFLER, S.K. and FOOTE, R.H. (1969). Sperm retention and resorption in sexually active rabbits with epididymal ligatures. *Proc.Soc.Exp. Biol.Med.* 131, 1179-1183.
- PEARSE, A.G.E. (1960). *Histochemistry, Theoretical and Applied*, 2nd ed. London: Churchill.
- PEASE, D.C. (1956). Infolded basal plasma membranes found in epithelia noted for their water transport. *J.Biophys.Biochem.Cytol.Supp.* 2, 203-208.
- QUINN, P.J., WHITE, I.G. and WIRRICK, B.R. (1965). Studies on the distribution of the major cations in semen and male accessory secretions. *J.Reprod.Fert.* 10, 379-388.
- REDMAN, C.M., SIEKEVITZ, P. and PALADE, G.E. (1966). Synthesis and transfer of amylase in pigeon pancreatic microsomes. *J.Biol.Chem.* 241, 1150-1158.
- REID, B.L. and CLELAND, K.W. (1957). The structure and function of the epididymis. I. The histology of the rat epididymis. *Aust.J.Zool.* 5, 223-246.



- REYNOLDS, E.S. (1963). The use of lead citrate at high pH as an electron-opaque stain in electron microscopy. *J.Cell Biol.* 17, 208-212.
- RHODIN, J.A.G. (1963). *An Atlas of Ultrastructure*, p.54. Philadelphia and London: W.B. Saunders Co.
- RICHARDSON, K.C. (1962). The fine structure of autonomic nerve endings in smooth muscle of the rat vas deferens *J.Anat.* 96, 427-442.
- RISLEY, P.L. (1961). Effects of castration and testosterone on cholinesterases distribution in rat epididymis and ductus deferens. *Anat.Rec.* 139, 268.
- RISLEY, P.L. and SKREPETOS, C.N. (1964a). Histochemical distribution of cholinesterases in the testis, epididymis and vas deferens of the rat. *Anat.Rec.* 148, 231-249.
- RISLEY, P.L. and SKREPETOS, C.N. (1964b). Cholinesterase distribution in the rat epididymis and vas deferens after castration and sex hormone treatments. *Anat.Rec.* 150, 195-208.
- SAMARJSKI, T., ORDY, J.M. and KEEFE, J.R. (1965). The fine structure of lipofuscin age pigment in the nervous system of aged mice. *J.Cell Biol.* 26, 779-795.
- SCOTT, B.L. and PEASE, D.C. (1959). Electron microscopy of the salivary and lacrimal glands of the rat. *Am.J.Anat.* 104, 115-161.
- SEDAR, A.W. (1966). Transport of exogenous peroxidase across the epididymal epithelium. *Int.Conf.Electron Micros.Kyoto,Japan, vol.II*, pp. 591-592, ed. R.Uyeda, Tokyo: Maruzen Co.
- SETCHELL, B.P. (1970). Testicular blood supply, lymphatic drainage, and secretion of fluid. In: *The Testis. Development, anatomy and physiology*, vol. I, pp. 101-239, eds. A.D. Johnson, W.R. Gomes and N.L. Vandemark. New York and London: Academic Press.
- SHAVER, S.L. (1954). The role of stereocilia in removing India ink from the lumen of the rat epididymis. *Anat.Rec.* 119, 177-185.
- SHEAR, M. Histochemical localization of alkaline phosphatase and adenosine triphosphatase in the myoepithelial cells of rat salivary glands. *Nature, Lond.* 203, 770.
- SHIODA, T. and NISHIDA, S. (1966). Innervation of the bull testis. *Jap. J.Vet.Sci.* 28, 251-257.
- SILLER, W.G. (1971). Personal communication.
- SILLER, W.G. and HINDLE, R.M. (1969). The arterial blood supply to the kidney of the fowl. *J.Anat.* 104, 117-135.

- SIMEONE, F.A. and YOUNG, W.G. (1931). A study of the function of the epididymis. IV. The fate of non-ejaculated spermatozoa in the genital tract of the male guinea-pig. *Brit.J.Exp.Biol.* 8, 163-173.
- SISSON, S. and GROSSMAN, J.D. (1953). *The Anatomy of the Domestic Animals*, 4th ed. Philadelphia: W.B. Saunders Co.
- SJÖSTRAND, N.O. (1965a). The adrenergic innervation of the vas deferens and the accessory male genital glands. *Acta Physiol.Scand.* 65, Supp.257.
- SJÖSTRAND, N.O. (1965b). Noradrenaline in extracts of the reproductive tract of the domestic cock. *Experientia* 21, 96.
- SPRIGGS, T.L.B., LEVER, J.D., REES, P.M. and GRAHAM, J.D.P. (1966). Controlled formaldehyde-catecholamines condensation in cryostat sections to show adrenergic nerves by fluorescence. *Stain Tech.* 41, 323-327.
- STALLCUP, O.T. and ROUSSEL, J.D. (1965). Development of lactic dehydrogenase enzyme system in the testes and epididymis of young dairy bulls. *J.Dairy Sci.* 48, 1511-1516.
- STEINMAN, R.M. (1968). An electron microscopic study of ciliogenesis in developing epidermis and trachea in the embryo of *Xenopus laevis*. *Am.J.Anat.* 122, 19-56.
- STEMPAK, J.G. and WARD, R.T. (1964). An improved staining method for electron microscopy. *J.Cell Biol.* 22, 697-701.
- STOLL, R. and MARAUD, R. (1955). Sur la constitution de l'epididyme du coq. *C.r.Séanc.Soc.Biol.* 149, 687-689.
- TAMARIN, A. (1966). Myoepithelium of the rat submaxillary gland. *J. Ultrastruct.Res.* 16, 320-338.
- TANDLER, B. (1965). Ultrastructure of the human submaxillary gland. III. Myoepithelium. *Z.Zellforsch.mikrosk.* 68, 852-863.
- TATSUMI, A. (1969). Histochemical study on lactic dehydrogenase of the seminal vesicles. *Acta Urol.Jap.* 15, 428-446.
- WILLIAMS, T.W. Jr. (1943). A technique for the gross differential staining of peripheral nerves in cleared vertebrate tissues. *Anat. Rec.* 86, 189-196.
- WYBURN, G.M., JOHNSTON, H.S., DRAPER, M.H. and DAVIDSON, M.F. (1970). The fine structure of the infundibulum and magnum of the oviduct of *Gallus domesticus*. *Q.Jl.exp.Physiol.* 55, 213-232.
- YAMAUCHI, A. and BURNSTOCK, G. (1967). Nerve-myoepithelium and nerve-glandular epithelium contacts in the lacrimal gland of sheep. *J.Cell Biol.* 34, 917-919.

YOUNG, W.C. (1931). A study of the function of the epididymis.III. Functional changes undergone by spermatozoa during their passage through the epididymis and vas deferens in the guinea-pig. Brit.J. Exp.Biol. 8, 151-162.

YOUNG, W.C. and SIMEONE, F.A. (1930). Development and fate of spermatozoa in the epididymis and vas deferens in the guinea-pig. Proc.Soc.Exp.Biol.N.Y. 27, 838-841.

- Fig. 1. An X-ray after micropaque injection into the ampulla of the ductus deferens. T, testis; ER, epididymal region; DE, ductus epididymidis; DD, ductus deferens.
- Fig. 2. Neoprene cast of the epididymal region (ER) and cranial segment of the ductus deferens (DD). The flexuous course of the ductus epididymidis (DE) is continued into the ductus deferens. The connections between the epididymal region and testis (T) are at certain interspaced points (arrows).
- Fig. 3. A diagrammatic representation of the epididymal region showing an arbitrary number of ductuli efferentes (DEf). T, testis; CD, connecting ductules; DE, ductus epididymidis; AE, appendix epididymidis; P, paradidymis; RT, rete testis; DD, ductus deferens.
- Fig. 4. A drawing from a graphical reconstruction of a connection between the seminiferous tubules (ST) and the ductus epididymidis (DE). The rete testis (RT) joins a ductulus efferens (DEf) which in turn narrows to become a connecting ductule (CD1). It is joined by another connecting ductule (CD2).

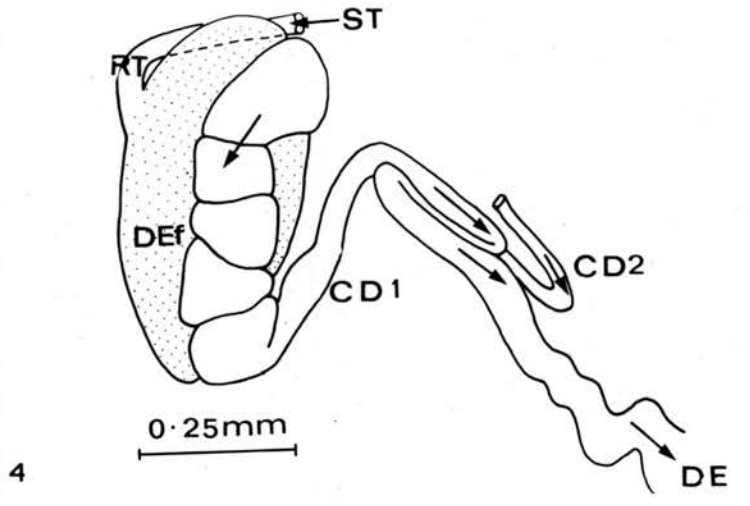
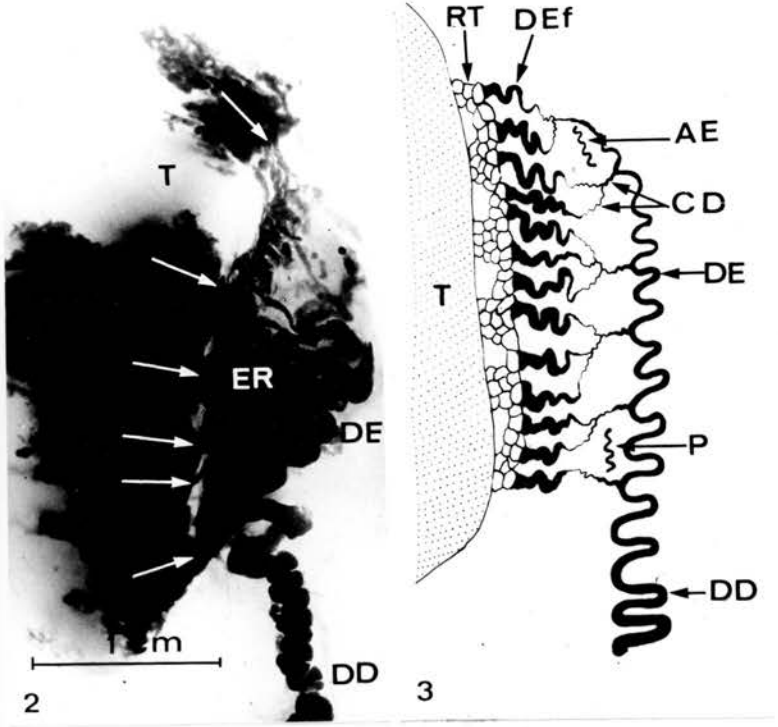

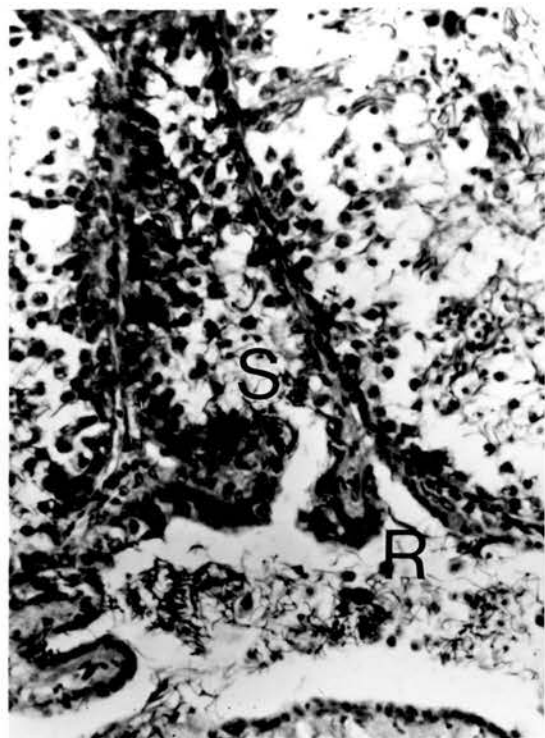

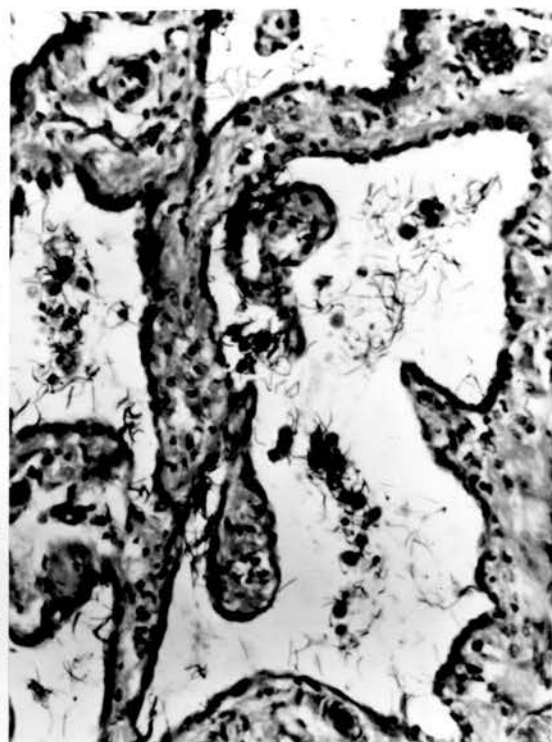
Fig. 5. Seminiferous tubule (S) opening directly into rete testis (R). x275.

Fig. 6. Rete Testis lined by simple squamous or low cuboidal cells. Spermatozoa and spermatids at various stages of development are dispersed in the lumen. x275.

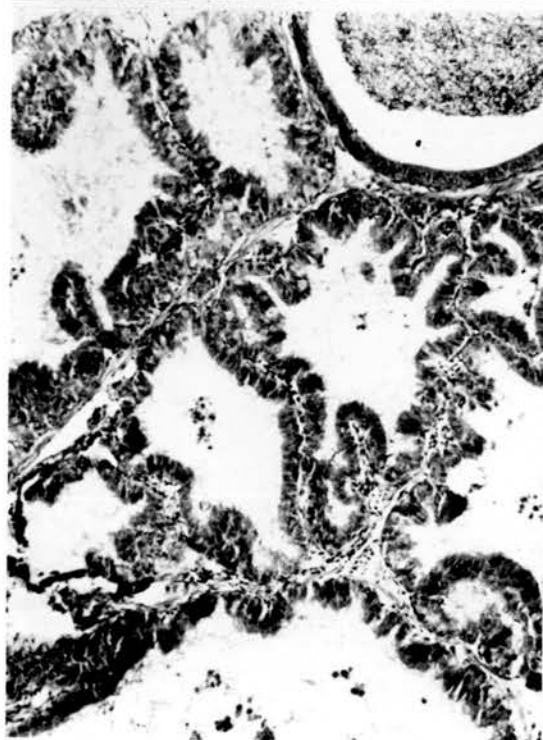
Fig. 7, 8. Epididymal region of sexually active (Fig. 7) and inactive (Fig. 8) birds. In the active state the ducts are wider and intertubular tissue is scanty. In the inactive region the tubules are more folded, have narrower lumina and comparatively more intertubular tissue; luminal content are reduced. x275.



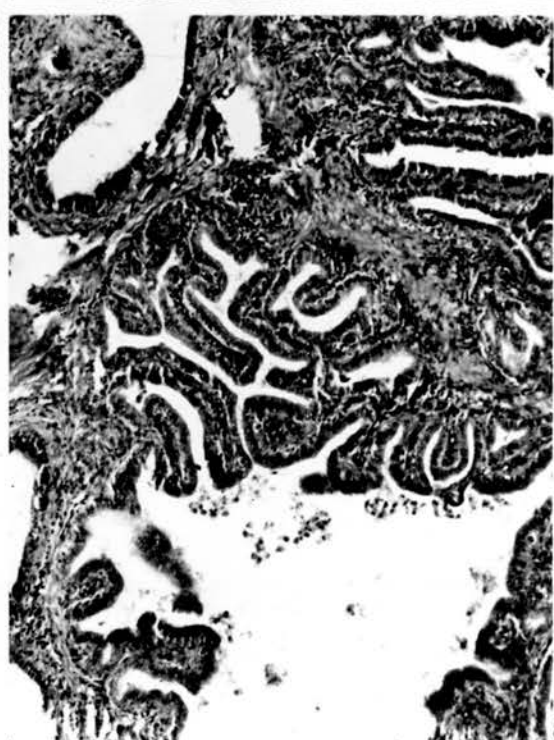5



6



7



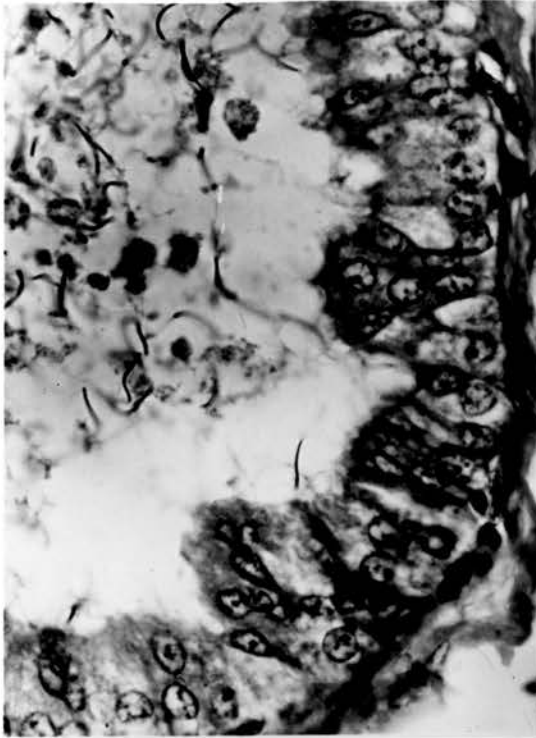
8

Fig. 9. Ductulus efferens. Among the lining cells are the dark staining ciliated cells, clear cells and some intermediate ones. Luminal content is similar to that of the rete. x690.

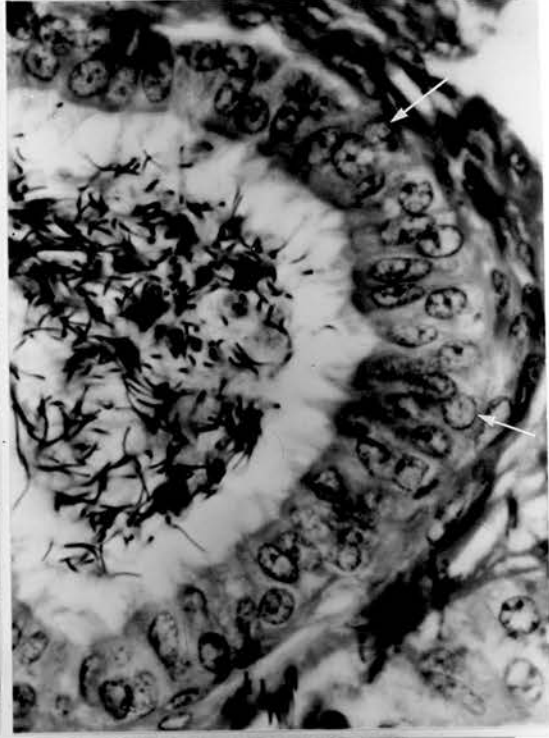Fig. 10. Initial part of a connecting ductule. Note the high concentration of spermatozoa in the lumen compared with that in the ductuli efferentes. Most of the lining cells are ciliated and basal cells (arrows) are occasionally present. x690.

Fig. 11. Connecting ductules on the left joining the caudal end of the ductus epididymidis, which is sectioned many times on the right. Note the epithelial folds in both ducts. The round tubule in the centre is the paradidymis. x46.

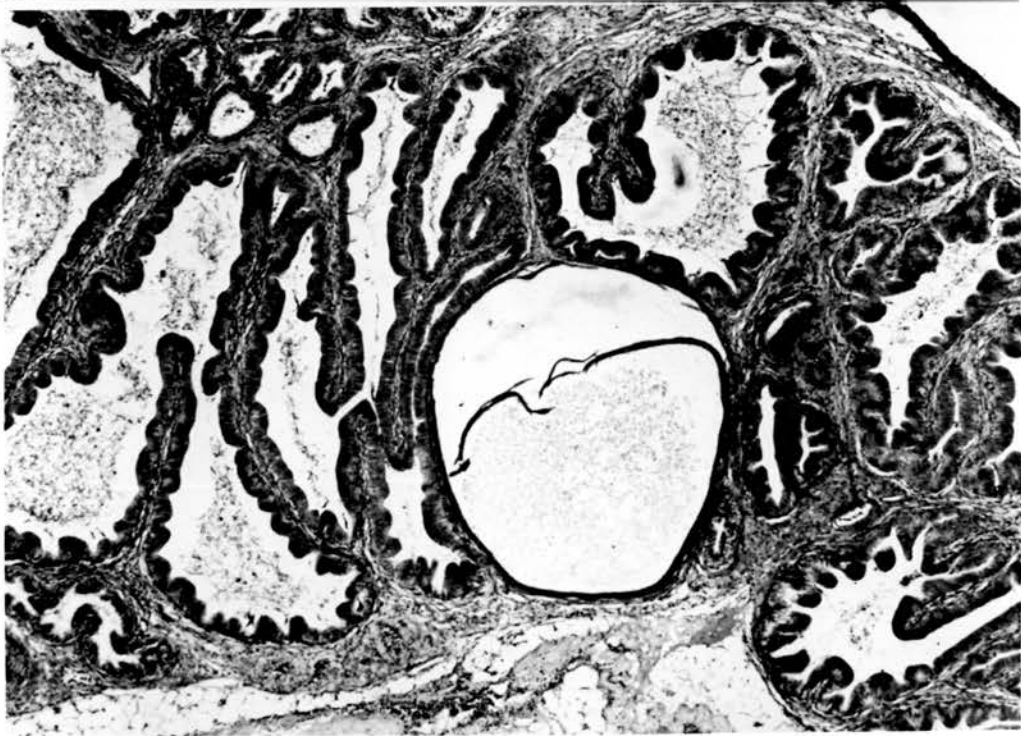



9



10

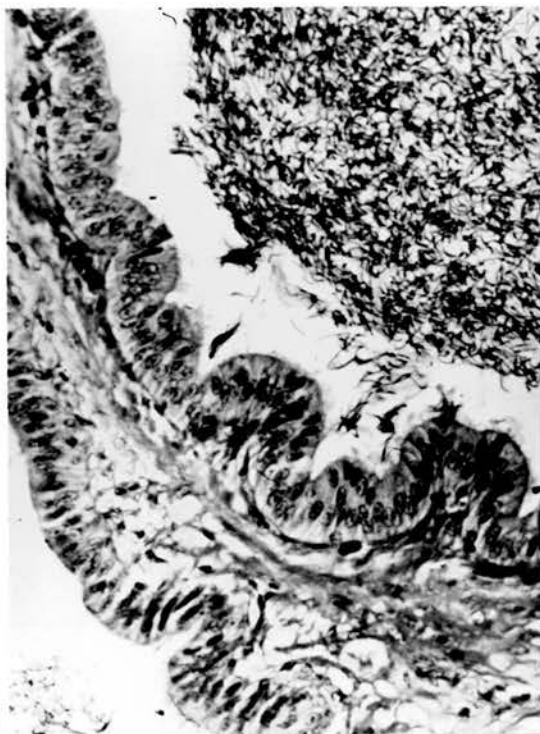


11

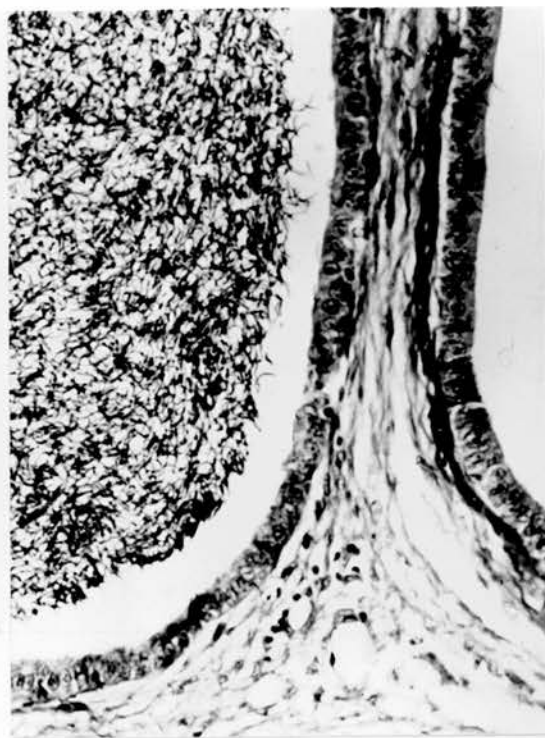Figs. 12, 13. Cranial (Fig. 12) and caudal (Fig. 13) segments of the ductus deferens. The epithelial folding of the connecting ductules and ductus epididymidis is continued in the cranial segment and disappears caudally. x275.

Fig. 14. Cranial segment of ductus deferens showing tall columnar cells, some of which stain darker than others. Basal cells (arrows) and bleb-like projections are present. x690.

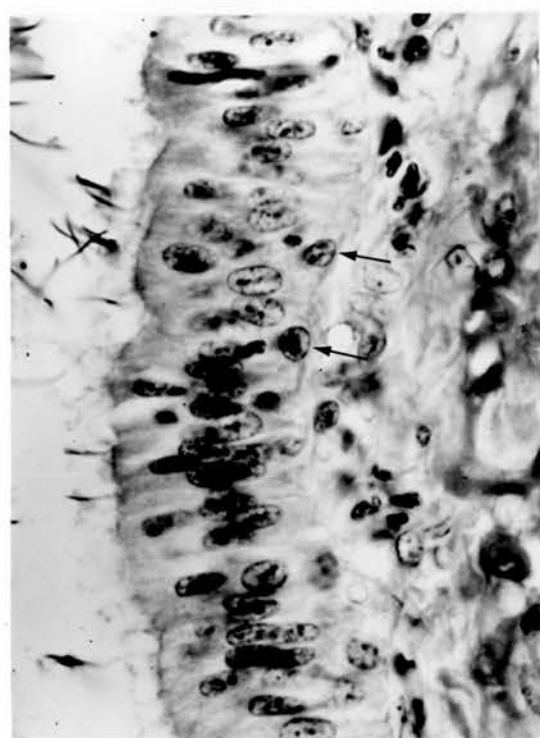
Fig. 15. Ampullary region of ductus deferens. Epithelial lining is similar to other parts of the ductus deferens, but the basal cells are numerous and seem to constitute a definite layer. x275.



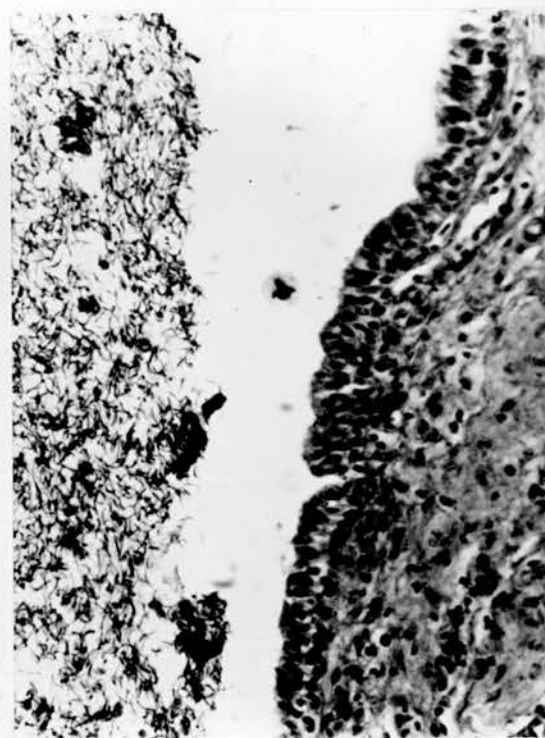
12



13



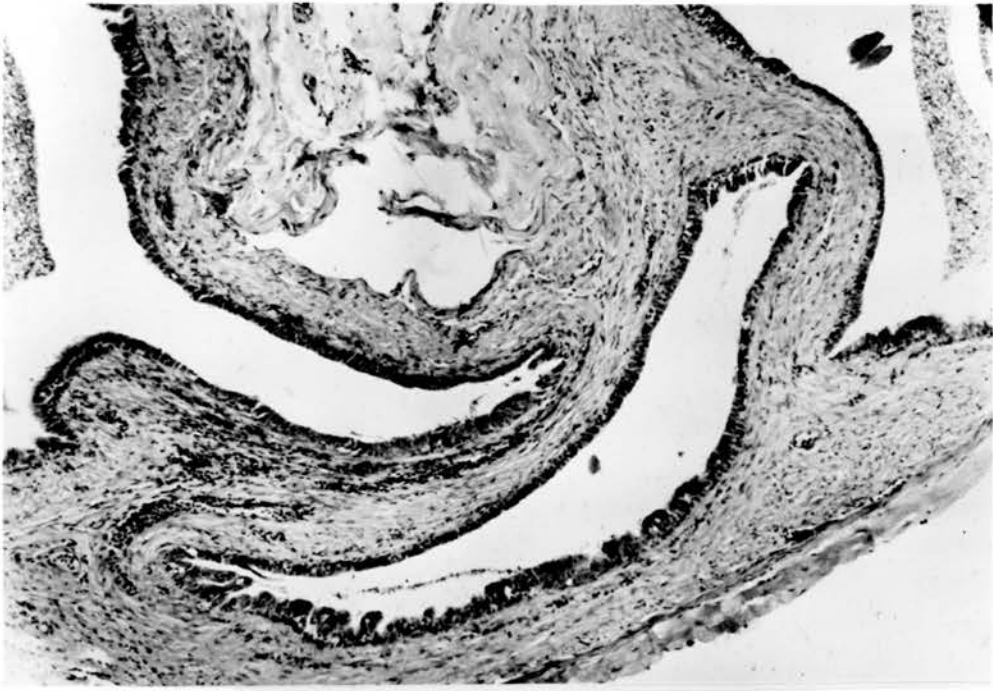14



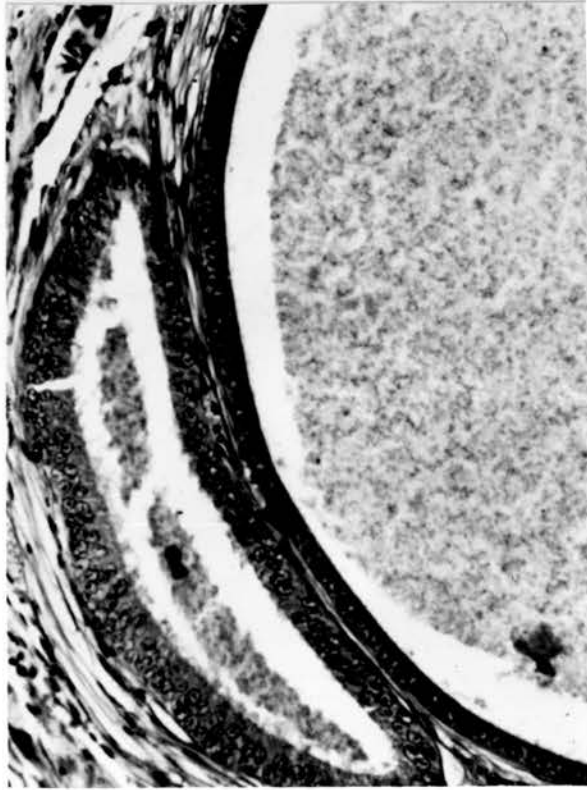
15

Fig. 16. Middle segment of ductus deferens from a poor semen producer. The walls are collapsed and the lumen nearly empty. x107.

Fig. 17. Appendix epididymidis with homogeneous luminal contents surrounded by simple cuboidal or low columnar epithelium. x275.

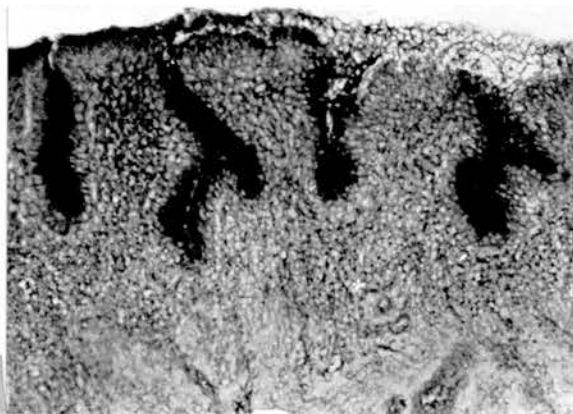


16

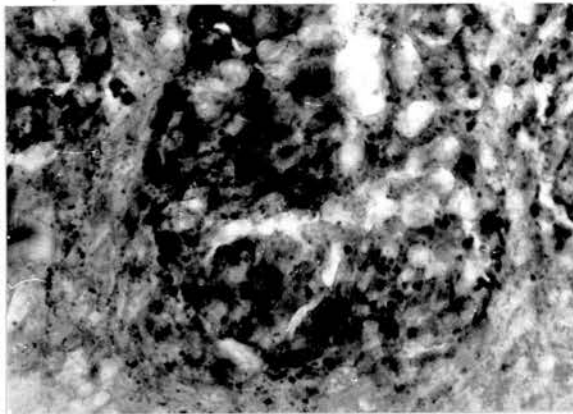


17

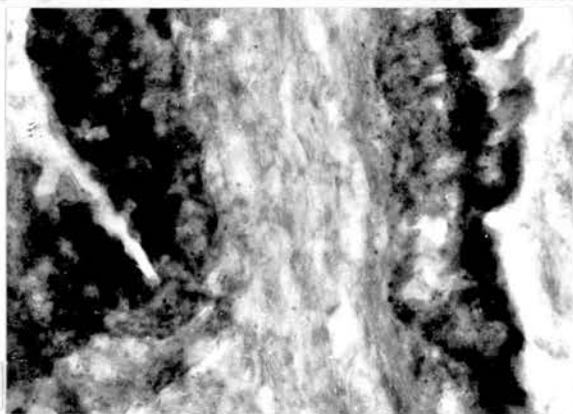
- Fig. 18. PAS-positive reaction in the external epithelium of the ejaculatory duct. Frozen section. x 140.
- Fig. 19-21. Unextracted sections of a ductulus efferens (Fig. 19), ductus epididymidis (Fig. 20) and middle part of ductus deferens (Fig. 21) showing lipid distribution. Sudan black B. x 560.
- Fig. 22. Unextracted section of the ampulla stained with Sudan black B. Note the luminal reaction. x 140.
- Fig. 23. Unextracted section of a ductulus efferens (left) and a connecting ductule (right) showing lipid distribution after staining with Nile blue. x 140.
- Figs. 24, 25. Caudal segment of ductus deferens (Fig. 24) and rete testis (Fig. 25) showing the same reaction as in Figure 23. Note the positive reaction in the lumen of the rete. x 140.



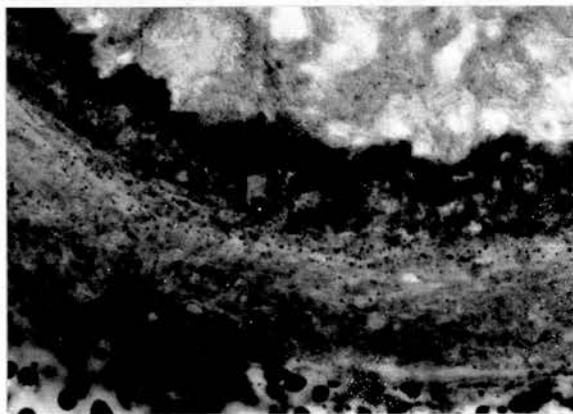
18



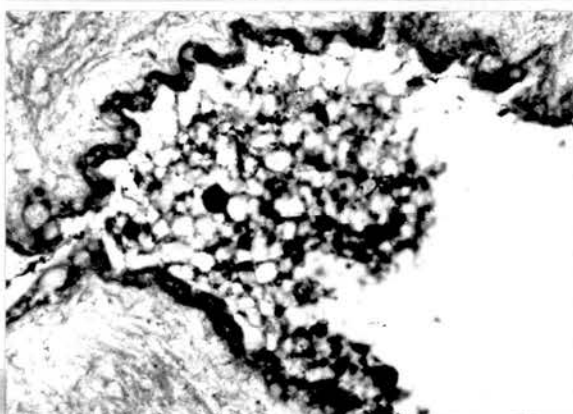
19



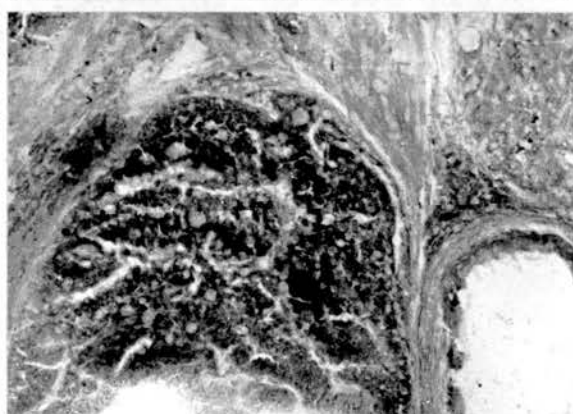
20



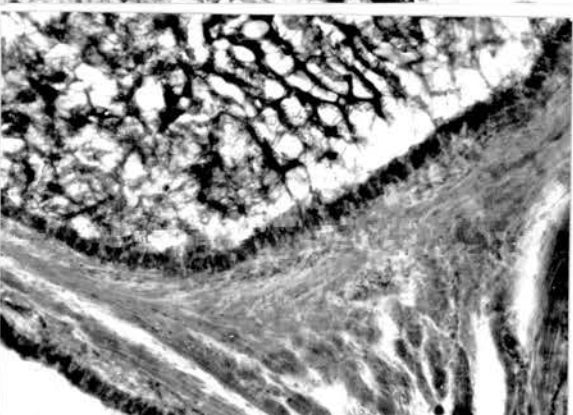
21



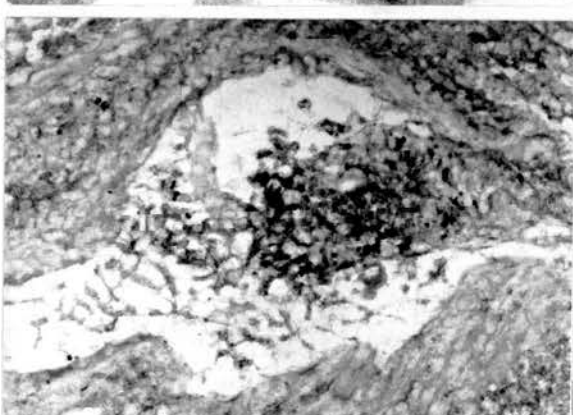
22



23



24



25

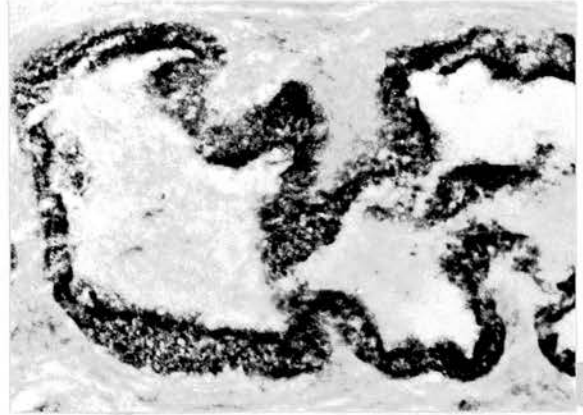Figs. 26-31. Distribution of glutamic dehydrogenase in different parts of the duct system. The reaction is strongest in the efferent ductules (Fig. 26) and much weaker in the rete testis (Fig. 31); in the narrow connecting ductules (Fig. 27), ductus epididymidis (Fig. 28) and the caudal (Fig. 29) and ampullary (Fig. 30) parts of ductus deferens, the reaction is intermediate. A slightly positive reaction is demonstrable in blood vessels (Fig. 31). x140.

Fig. 32. Reaction of glutamic dehydrogenase in the ductus deferens. Note the accumulation of granules in the apical parts of cells. x560.

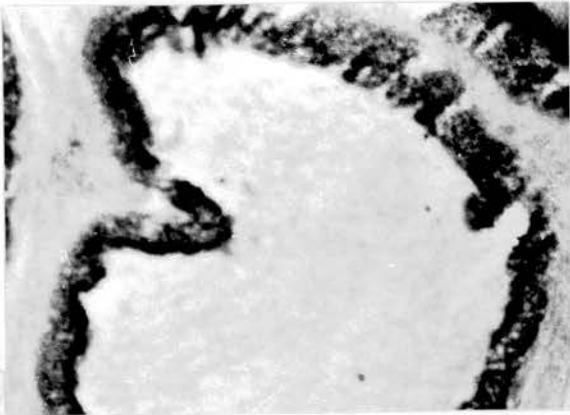



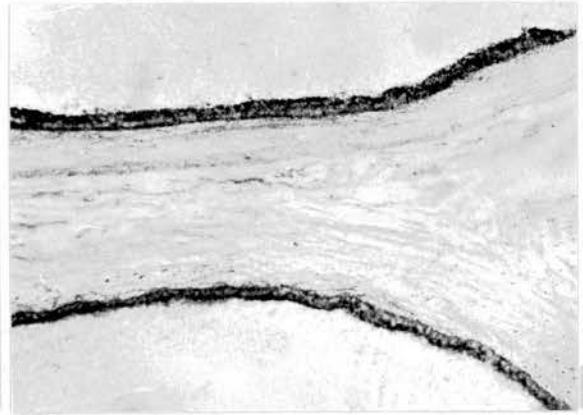
26



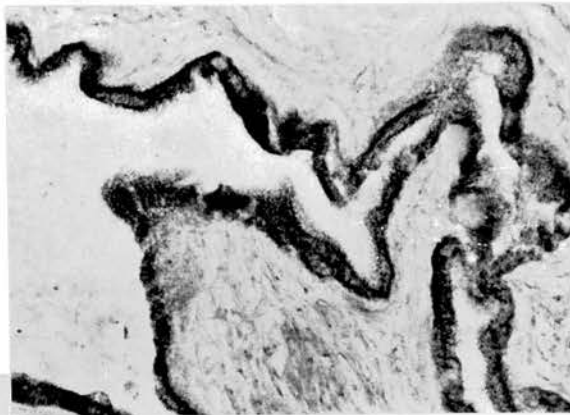27



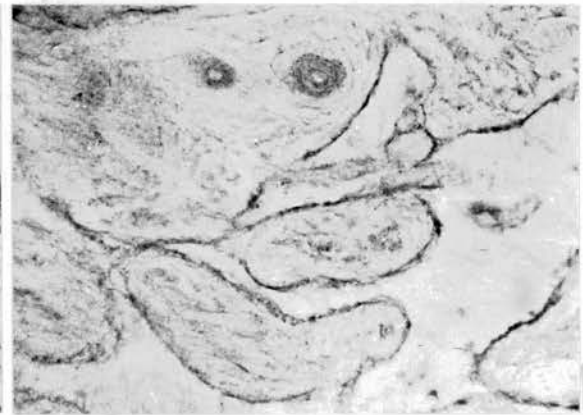
28




29



30



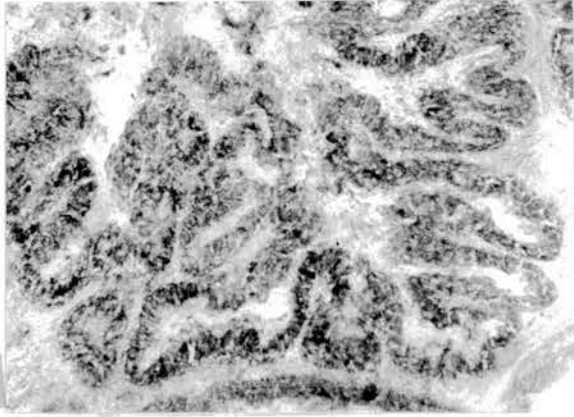
31



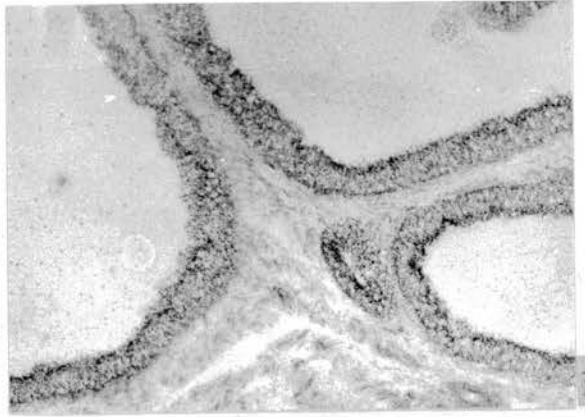
32

Figs. 33-38. Distribution of lactate dehydrogenase in different parts of the reproductive tract. The enzyme activity in the ductuli efferentes (Fig. 33) appears greater than in the ductus epididymidis (Fig. 34), middle segment of ductus deferens (Fig. 35), testis (Fig. 36), rete testis (Fig. 37) and ejaculatory duct (Fig. 38).  
x140.

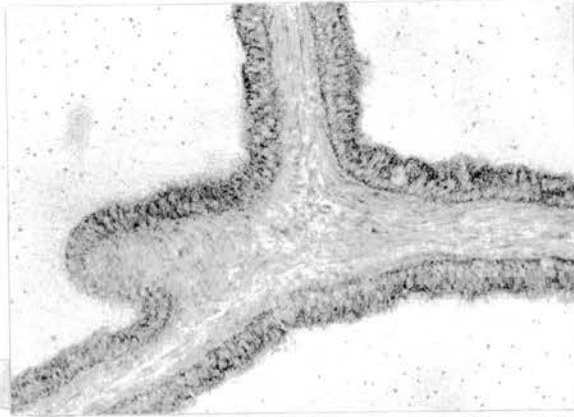
Figs. 39-40. Lactate dehydrogenase activity in the ductus epididymidis (Fig. 39) and middle segment of ductus deferens (Fig. 40) showing tendency of granules, which indicate the enzyme activity, to be located in the luminal tips of lining epithelia. x560.



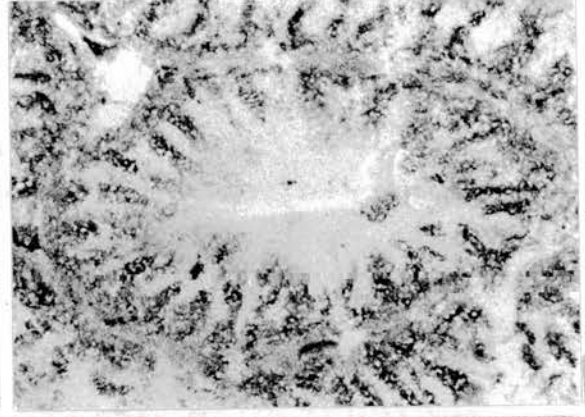
33



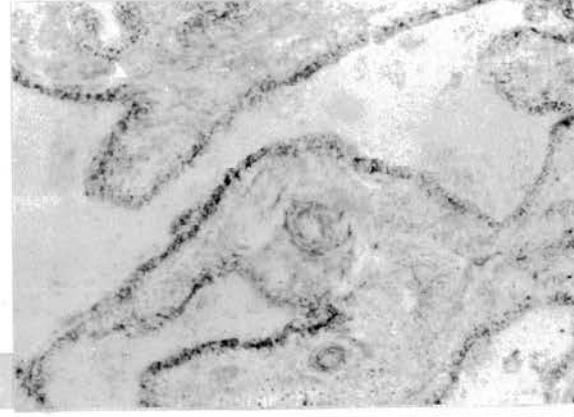34



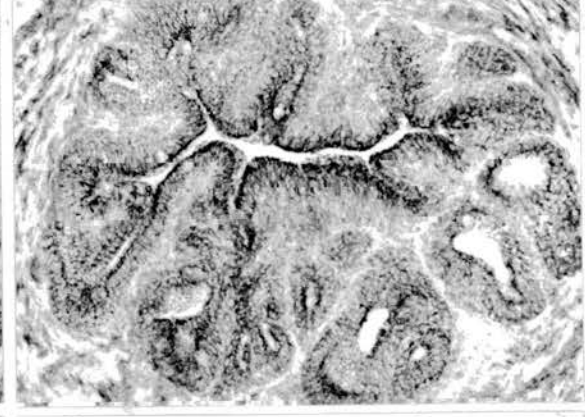35



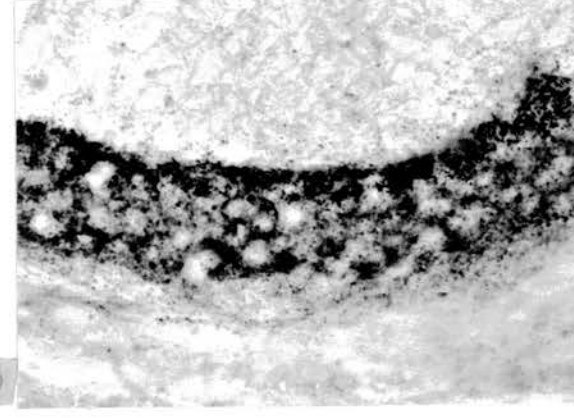
36



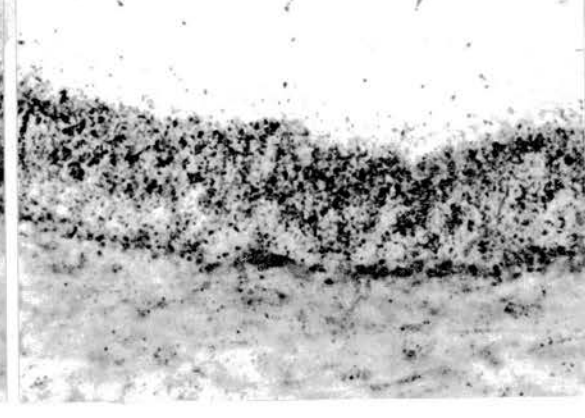
37



38



39



40

Figs. 41-45. Succinic dehydrogenase activity is highest in the ductuli efferentes (Fig. 41) with a gradual loss of intensity caudally in the narrow connecting ductules (Fig. 42), ductus epididymidis (Fig. 43), caudal segment of ductus deferens (Fig. 44) and ejaculatory duct (Fig. 45). x140.

Fig. 46. An apical accumulation of granular deposits showing succinic dehydrogenase activity is seen in the lining epithelia of the ductus epididymidis. x560.

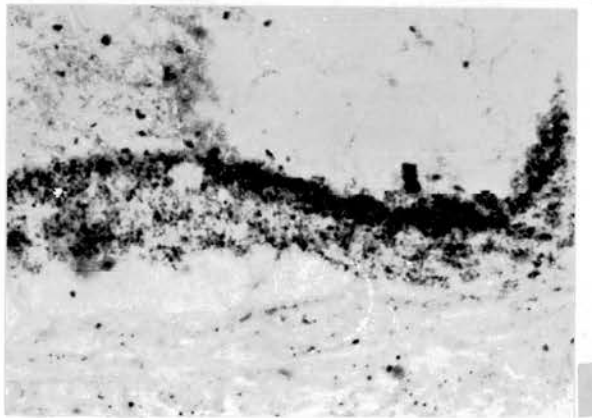
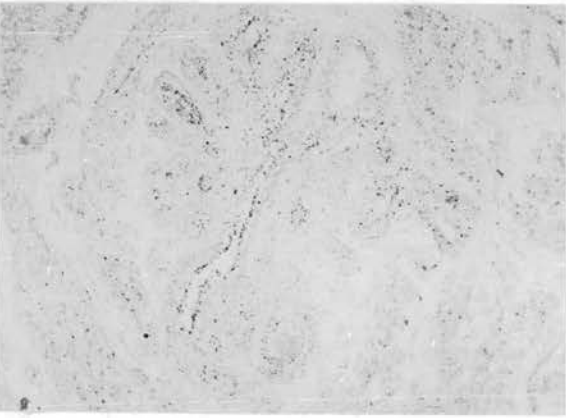
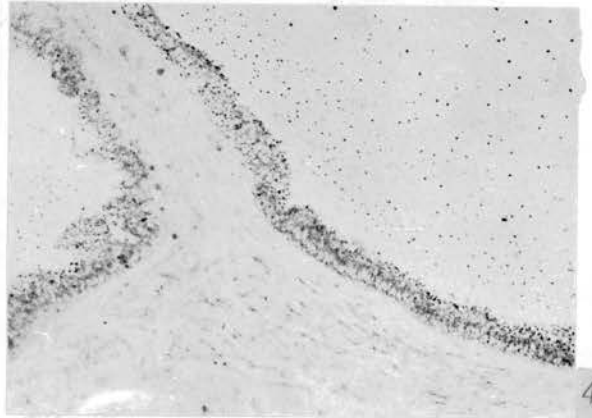
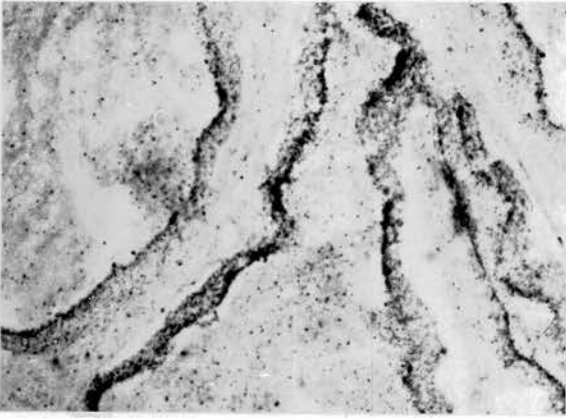
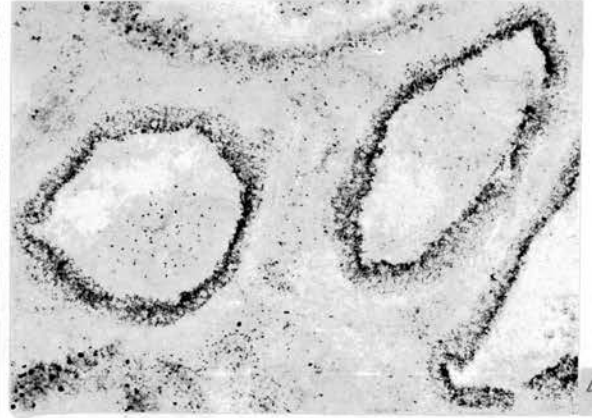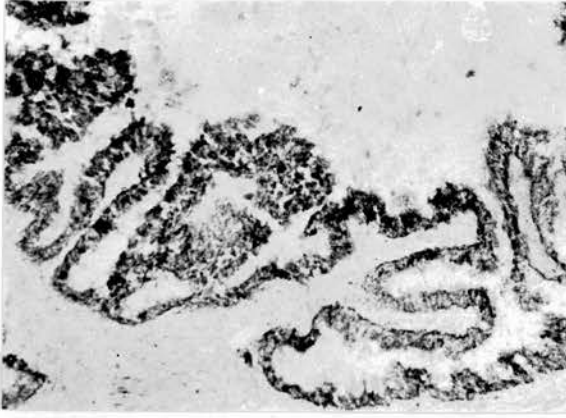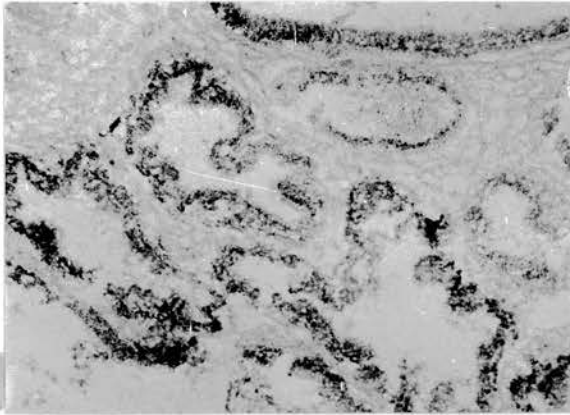


Fig. 47. Glucose-6-phosphate dehydrogenase activity in the epididymal region with an almost uniform distribution in the different tubules. x140.


Fig. 48. Glucose-6-phosphate dehydrogenase in the ductus epididymidis showing positive granules in the epithelia as well as in the lumen. x560.

Figs. 49-51. Distribution of glucose-6-phosphate dehydrogenase in the middle (Fig. 49) and ampullary part (Fig. 50) of the ductus deferens and the ejaculatory duct (Fig. 51). x140.

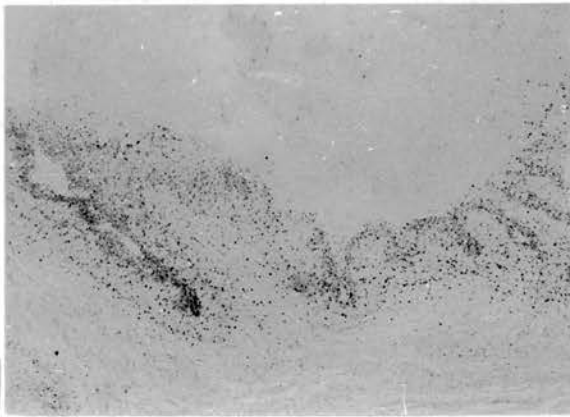
Fig. 52. A uniform distribution of glucose-6-phosphate dehydrogenase in the epithelia of the caudal part of ductus deferens. x560.



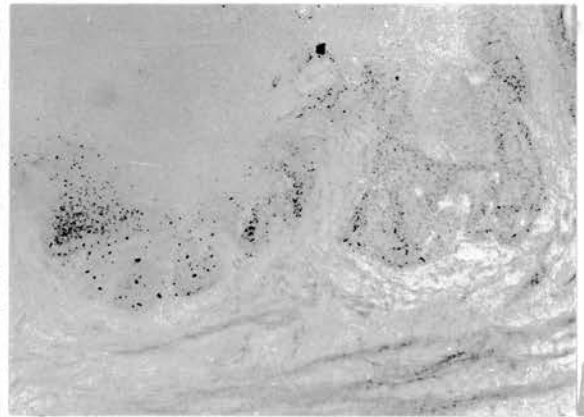
47



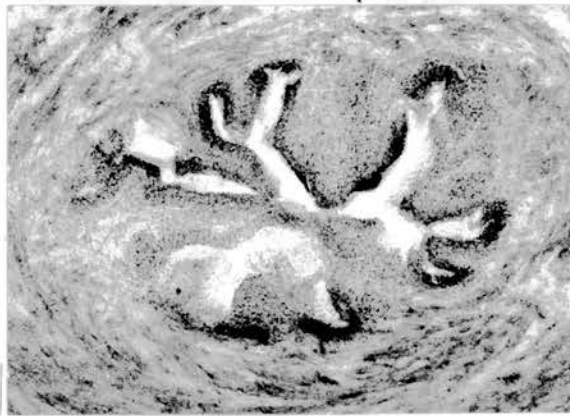
48



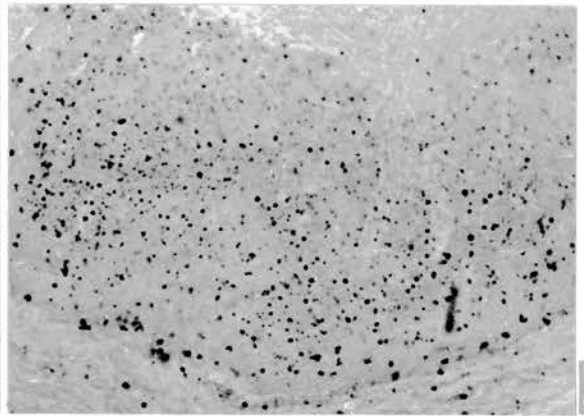
49



50



51



52

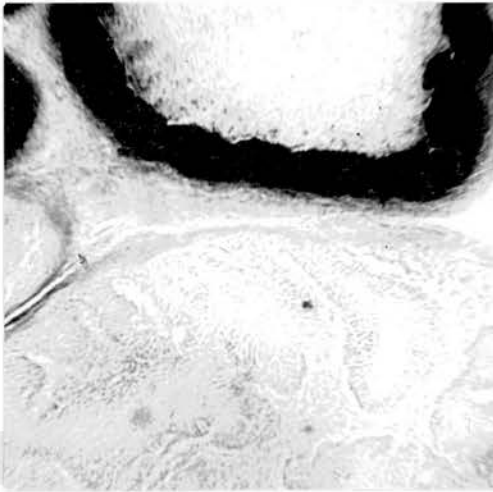
Fig. 53. Butyrylcholinesterase activity after incubation in butyrylthiocholine depicted in the ductus epididymidis (top). Ductuli efferentes (bottom) are negative. x175.

Fig. 54. Dense staining after incubation in butyrylthiocholine demonstrable in the middle segment of the ductus deferens. x175.

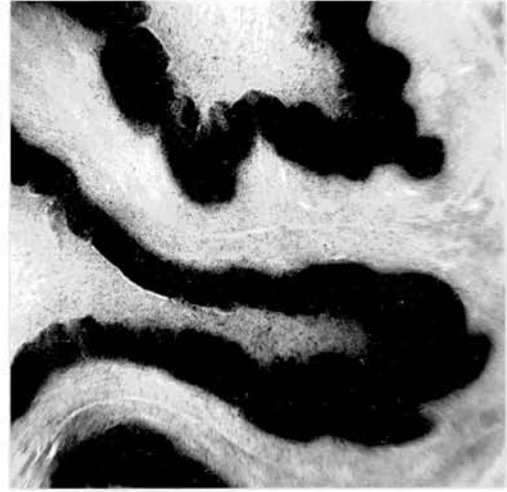Figs. 55, 56. Sections of ductus epididymidis (Fig. 55) and caudal segment of ductus deferens (Fig. 56), incubated in butyrylthiocholine and DFP. Butyrylcholinesterase activity is abolished. x175.

Figs. 57, 58. Sections of ductus epididymidis (Fig. 57) and middle segment of ductus deferens (Fig. 58), incubated in butyrylthiocholine and eserine. Activity due to butyrylcholinesterase is little affected. x 175

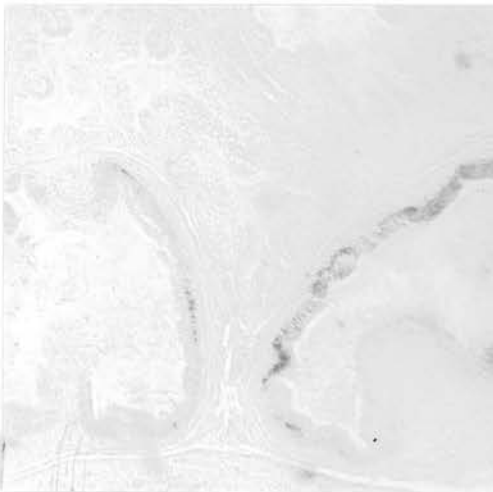




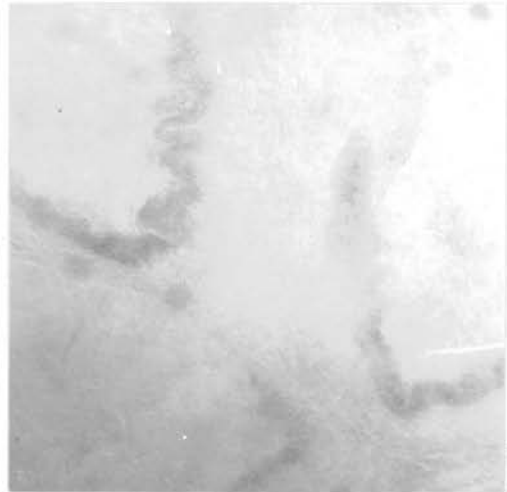
53



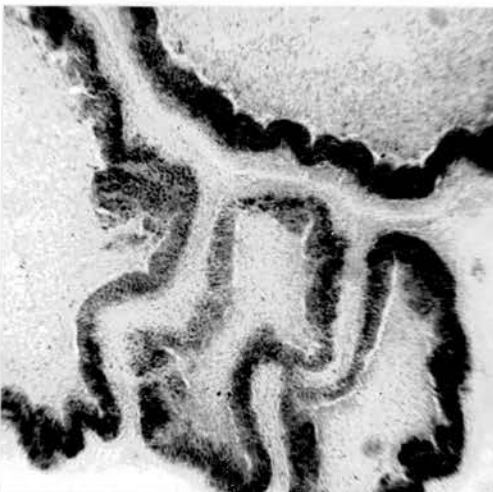
54



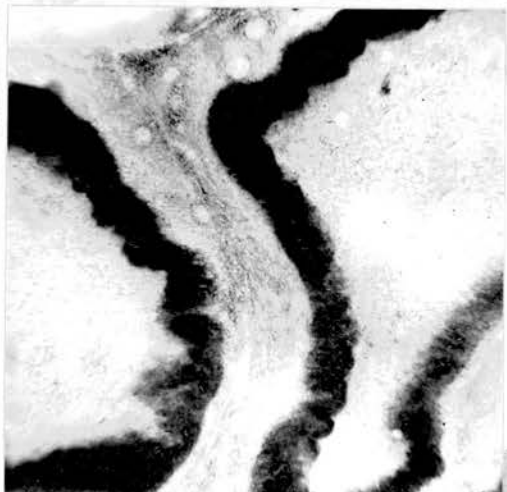
55



56



57

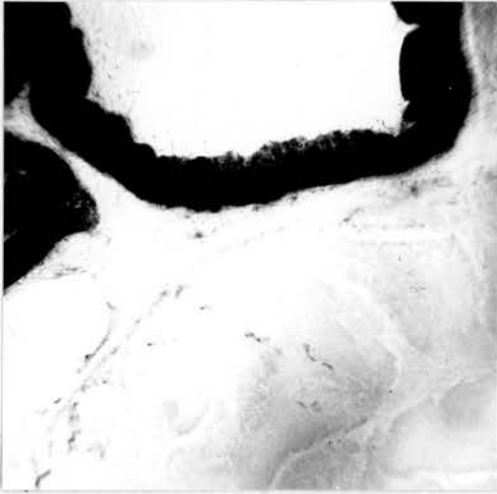


58

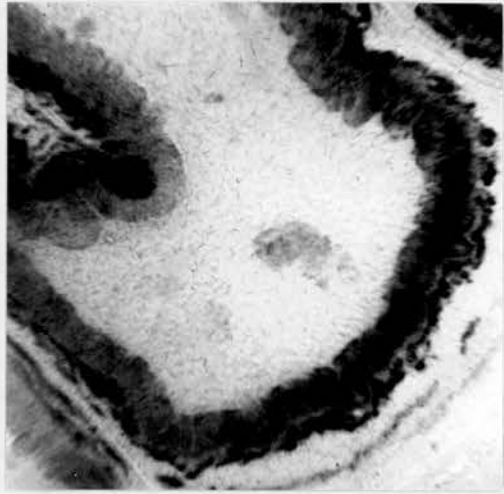
Figs. 59, 60. Cholinesterase staining of the ductus epididymidis (Fig. 59) and middle segment of ductus deferens (Fig. 60) after incubation in acetylthiocholine. Both acetylcholinesterase and butyrylcholinesterase contribute to the stain; ductuli efferentes are negative (Fig. 59, bottom). x175.

Figs. 61, 62. Ductus epididymidis (Fig. 61) and proximal part of ductus deferens (Fig. 62) incubated in acetylthiocholine and DFP; the resulting staining is entirely due to acetylcholinesterase and is confined to the bases of the cells. x175.

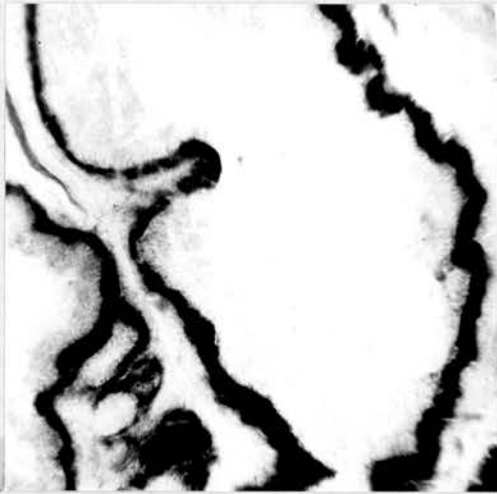Figs. 63, 64. Ductus epididymidis (Fig. 63) and proximal segment of ductus deferens (Fig. 64) incubated in acetylthiocholine and eserine. Staining due to acetylcholinesterase is abolished, that due to butyrylcholinesterase is unaffected. x175.



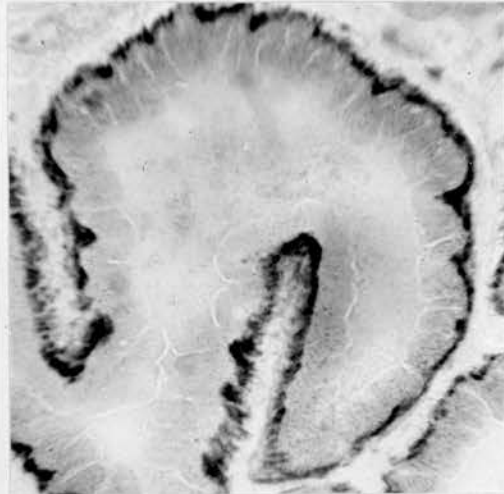
59



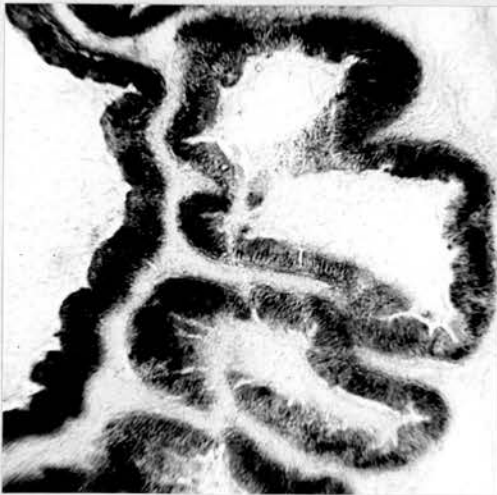60



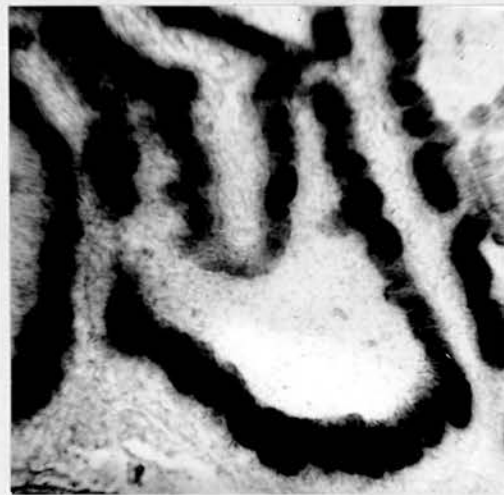61



62



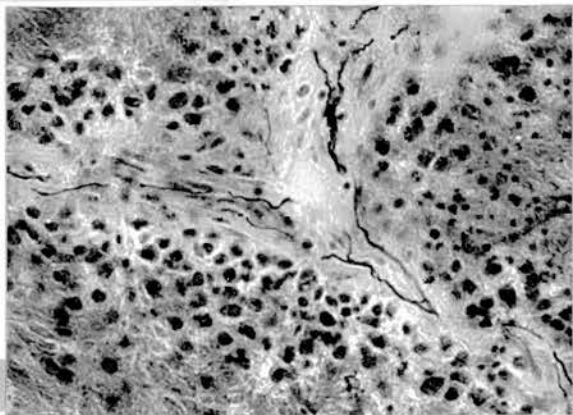
63



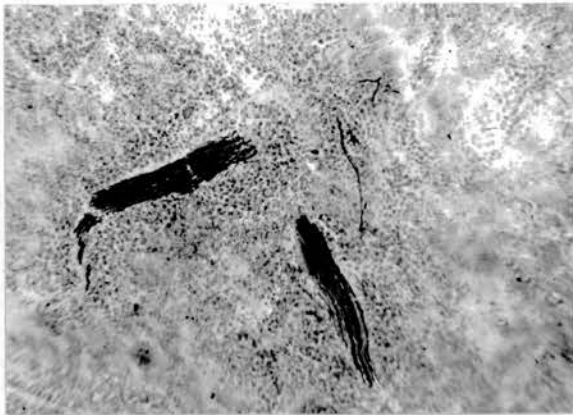
64

- Fig. 65. Nerve fibres in the testis are located primarily in the interstitial tissue. x700.
- Fig. 66. Large bundles of nerves are occasionally seen in the testis. x175.
- Fig. 67. Testicular nerve fibres showing some branching related to the seminiferous tubules. x700.
- Fig. 68. A rich distribution of nerves is seen in that part of the epididymal region which adheres to the testis. x175.
- Fig. 69. Large nerve trunks are seen near blood vessels (top right) in the epididymal region. x700.
- Fig. 70. Terminal nerve fibres supplying smooth muscle. x700.
- Fig. 71. Branches are given off the main trunk and course between the tubular components of the epididymal region. x175.
- Fig. 72. Nerve fibres shown in close relation to the wall of the rete testis. x700.

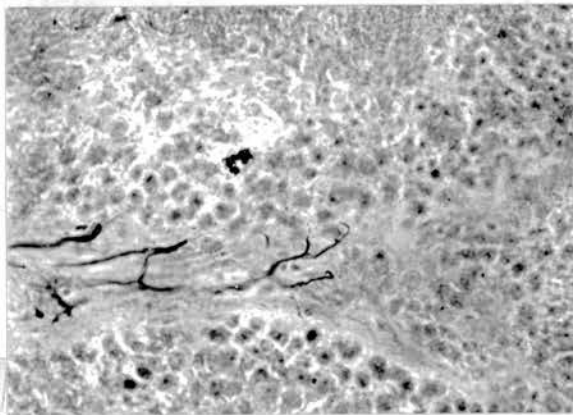
Figs. 65-72. Namba et al., silver and cholinesterase stain.




65



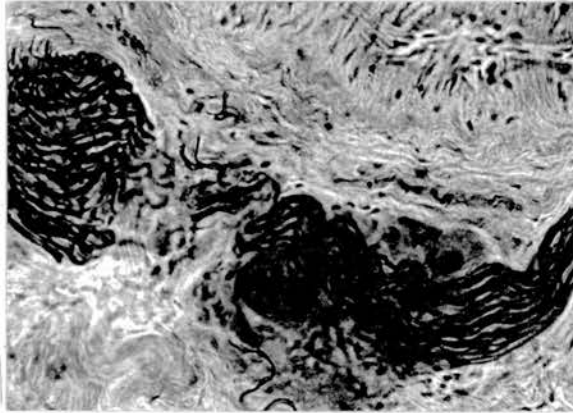
66



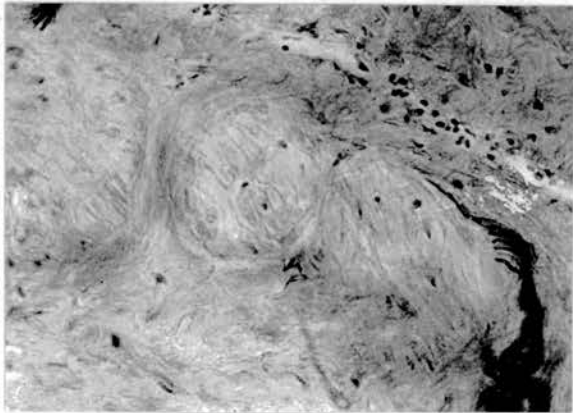
67



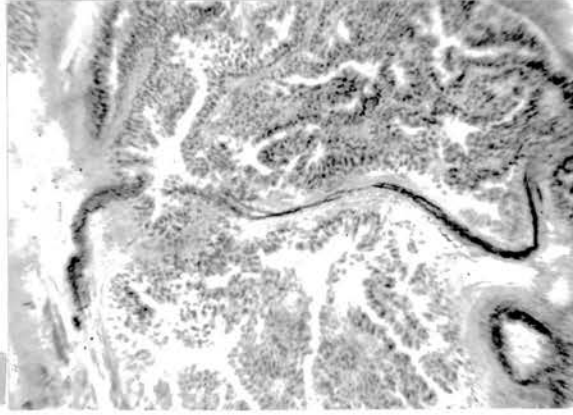
68



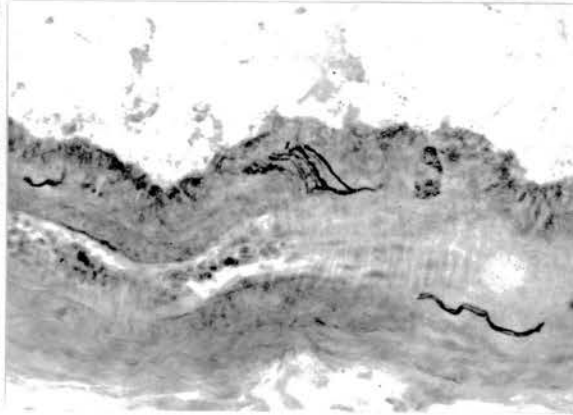
69



70

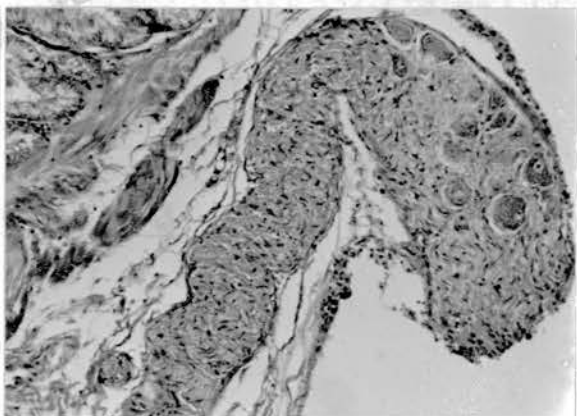
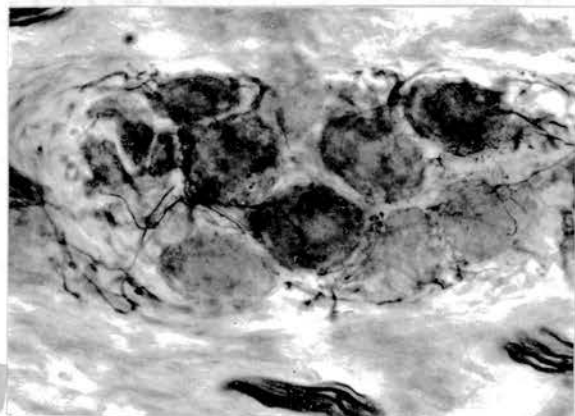
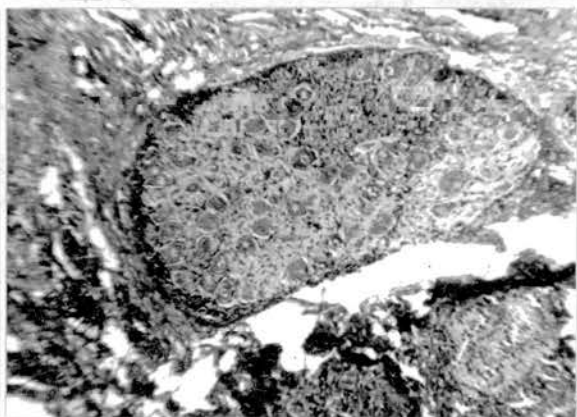

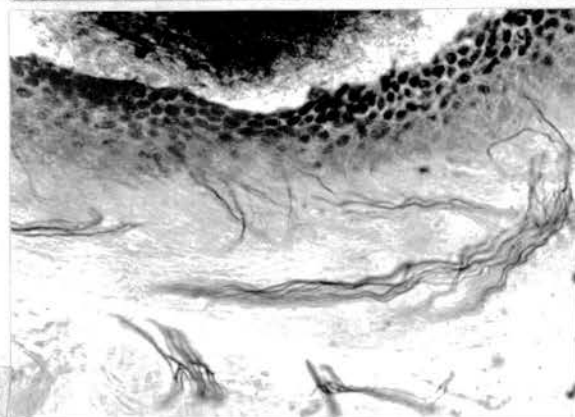
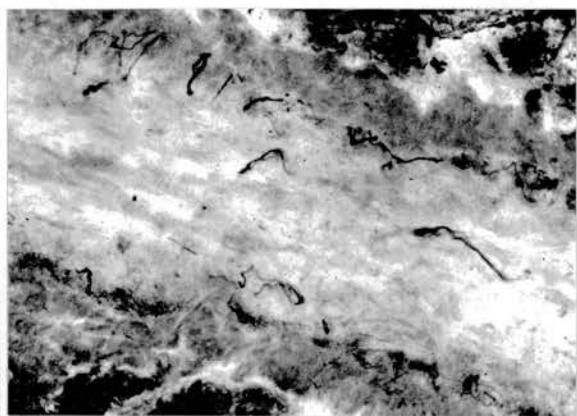
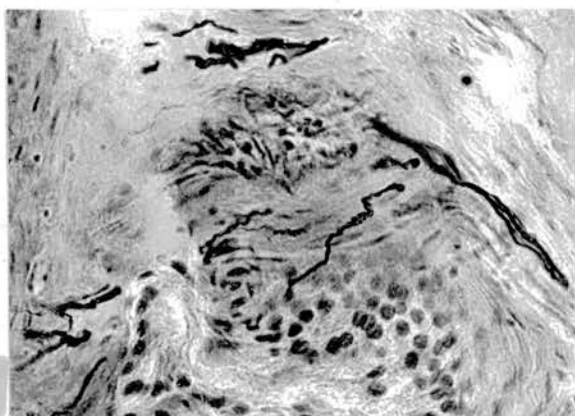


71



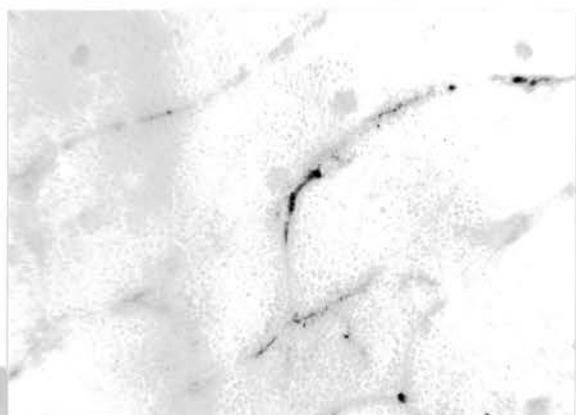72

- Fig. 73. Nerve fibres run very close to the lining cells of the ductuli efferentes. Namba et al., silver and cholinesterase stain. x700.
- Figs. 74-77. Nerves supplying the ductus deferens are either loosely arranged or may clump together into small bundles. Note their close association with the lining epithelia (Figs. 74, 75) and the course of bundles in the subepithelial tissue (Figs. 76, 77). Namba et al., silver and cholinesterase stain. x700.
- Fig. 78. Autonomic ganglion located immediately next to the epididymal region. Masson's trichrome, paraffin wax section. x175.
- Fig. 79. Autonomic ganglion in the subepithelial tissue of the middle part of ductus deferens. Namba et al., silver and cholinesterase stain. x700.
- Fig. 80. Tracts of large nerves with scattered nerve cells seen in the vicinity of the tubular components of the epididymal region. H & E, paraffin wax section. x107.




- Fig. 81. Acetylcholinesterase positive structures in the interstitial tissue of the testis. This activity may be due to the presence of nerve fibres. Cholinesterase preparation. Frozen section. x175.
- Fig. 82. Network of nerve fibres in the intertubular tissue of the epididymal region, many of which are closely related to the ductus epididymidis (right). Cholinesterase preparation; frozen section. x175.
- Figs. 83-85. Rich distribution of nerve fibres in the wall of the ductus deferens. Many of the fibres appear to connect with the basal parts of the lining epithelia. Cholinesterase preparation; frozen section. x175.
- Figs. 86, 87. Nerve fibres ramifying freely in the muscular layer of the ampullary part of ductus deferens (Fig. 86) and in relation to its epithelial lining (Fig. 87). Cholinesterase preparation; frozen section. x175.
- Fig. 88. Nerve fibres within the smooth muscle layer of the ejaculatory duct. Cholinesterase preparation; frozen section. x175.

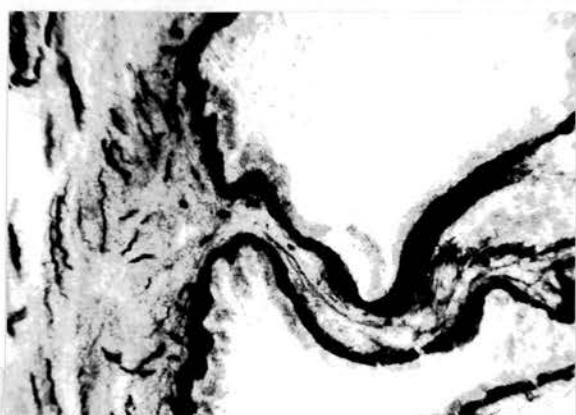




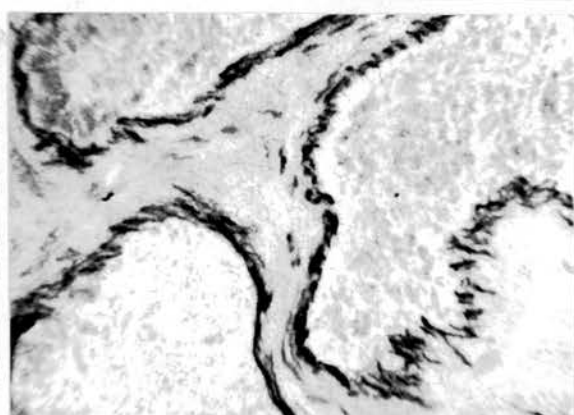
81



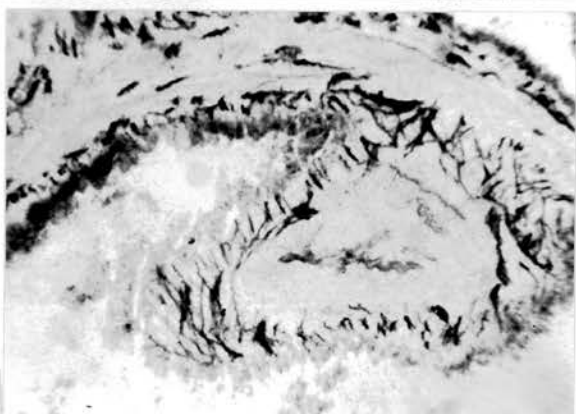
82



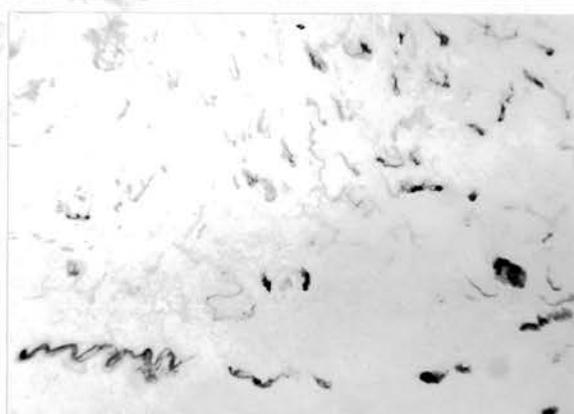
83



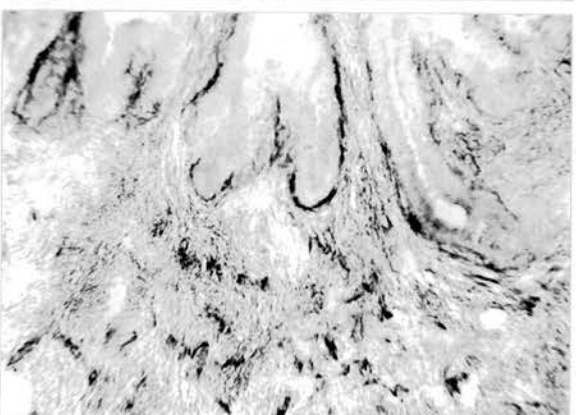
84



85



86



87

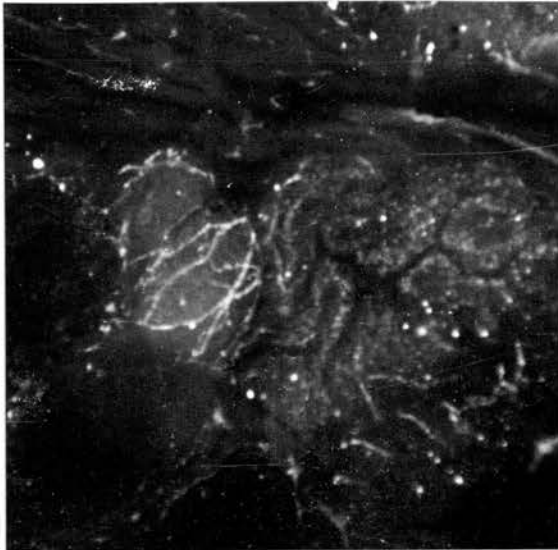


88

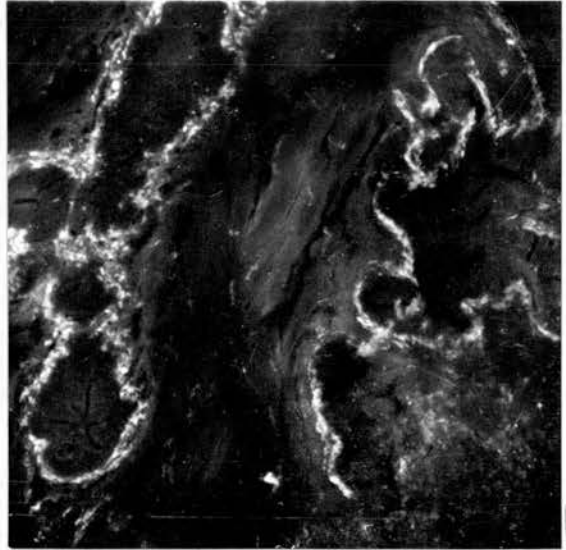
Fig. 89. Catecholamine fluorescent nerve fibres in the intertubular tissue of the epididymal region. Non-specific granular fluorescence is seen within the epithelia of the ductuli efferentes. Formaldehyde-catecholamine condensation method; frozen section. x140.

Figs. 90-92. There is a close relationship between catecholamine fluorescent nerve fibres and the epithelial wall of the wide connecting ductules (Fig. 90), ductus epididymidis (Fig. 91) and ductus deferens (Fig. 92). Formaldehyde-catecholamine condensation method; frozen section. x140.

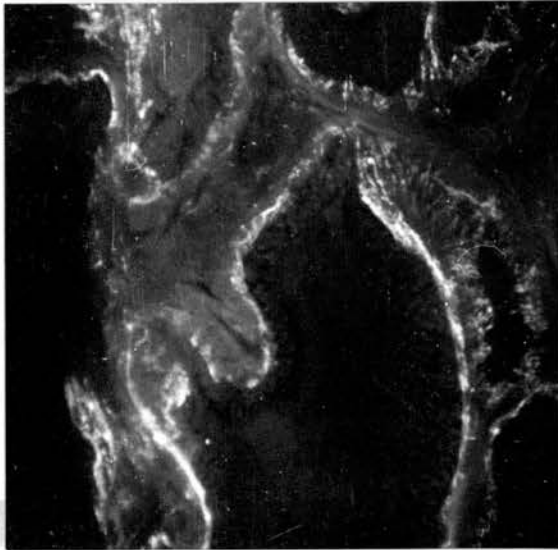
Fig. 93. A rich distribution of catecholamine fluorescent nerve fibres within the muscular layer of the ampulla of ductus deferens. Formaldehyde-catecholamine condensation method; frozen section. x140.



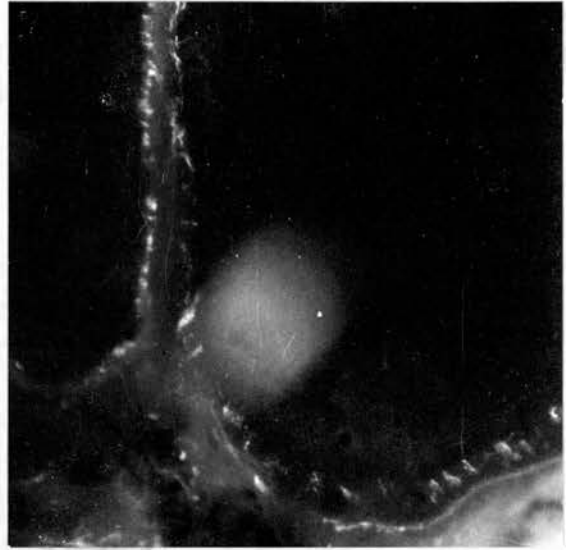
89



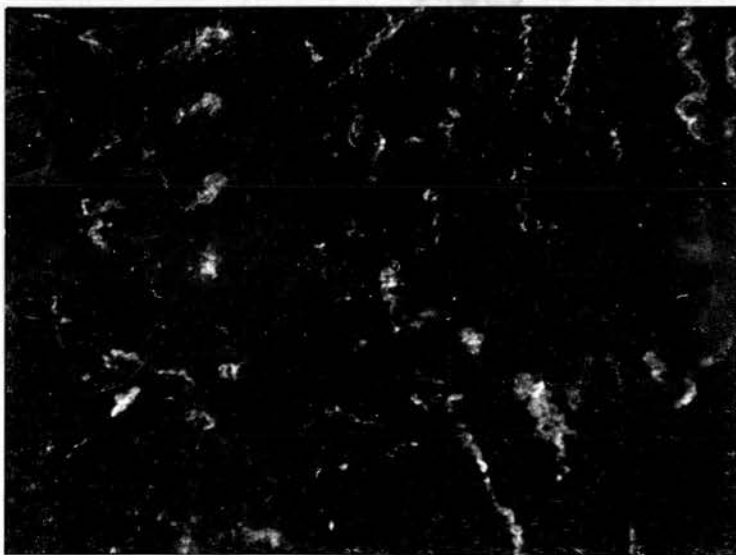
90



91



92



93

Fig. 94. A bundle of non-myelinated nerve fibres supported by interdigitating collagenous fibres. x18750.

Ampulla of ductus deferens.

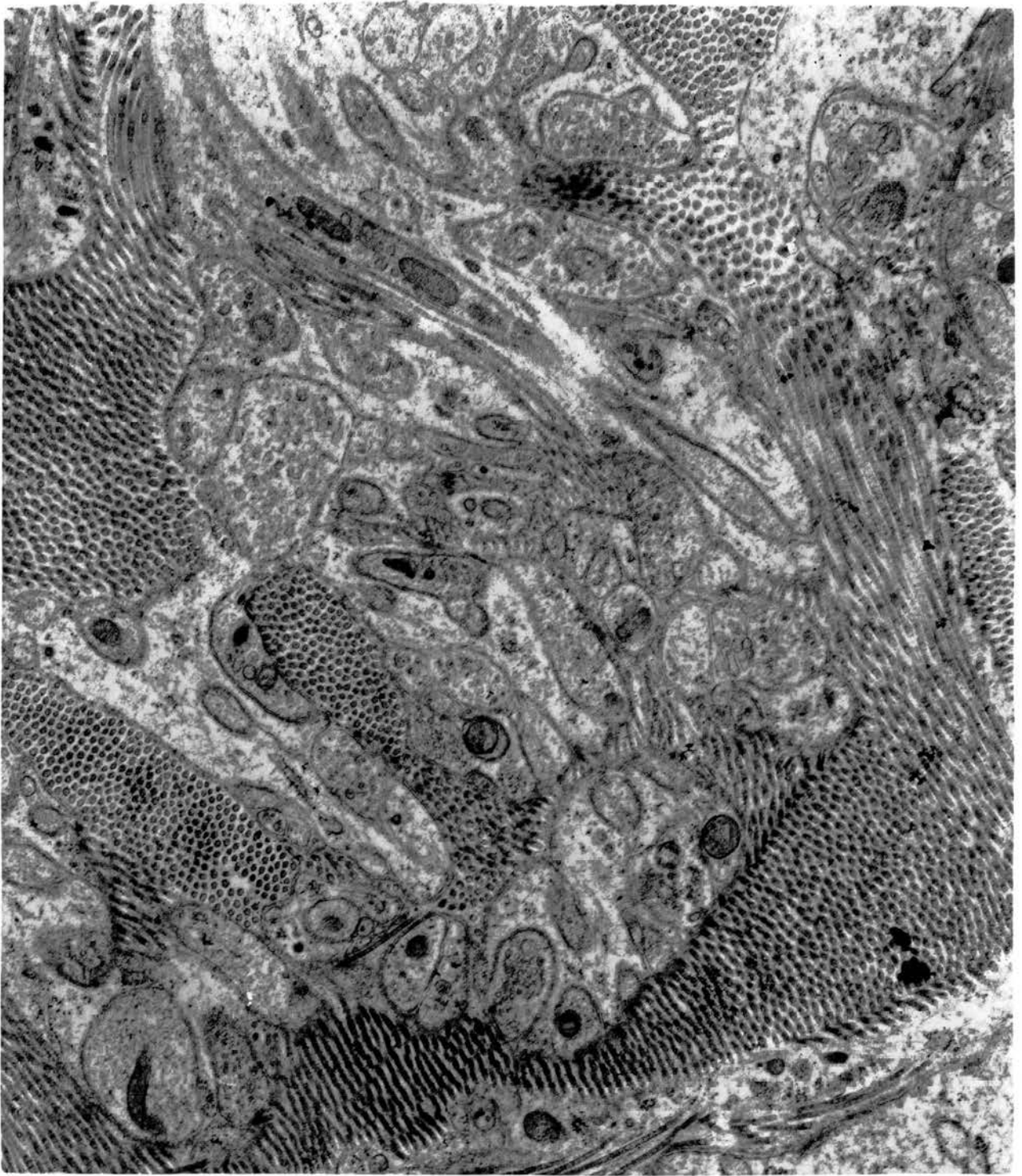


Fig. 95. A myelinated nerve axon in the epididymal region. Note the enwrapping Schwann sheath and sparsity of axoplasmic components. x37500.

Intertubular tissue of the epididymal region.

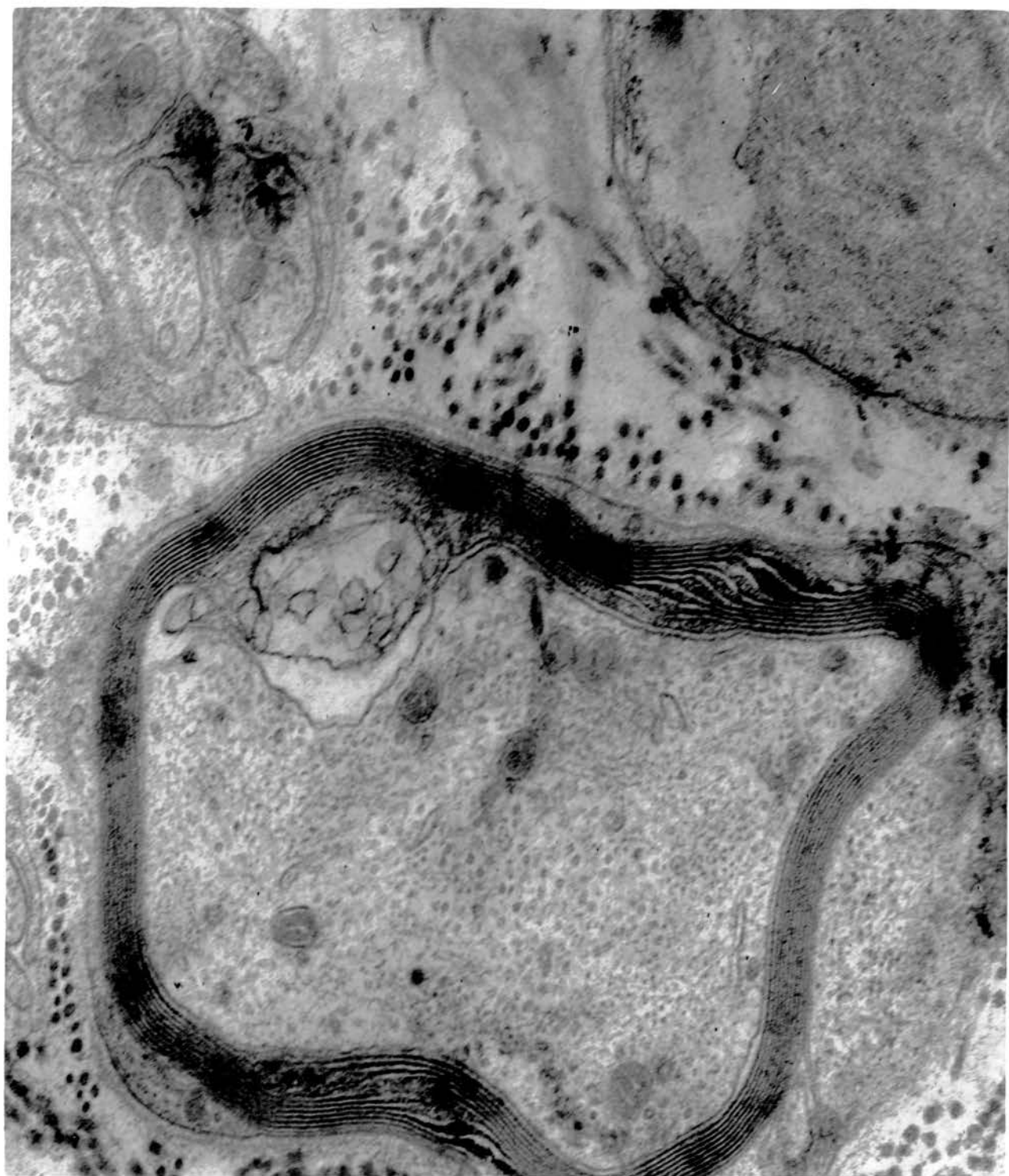


Fig. 96. Non-myelinated nerve bundle showing neurofibrils (F) of moderate electron-opacity and a few mitochondria. Dense-cored and electron-lucent microvesicles as well as dense granules are seen in nerve endings. x 25000.

Caudal segment of ductus deferens.



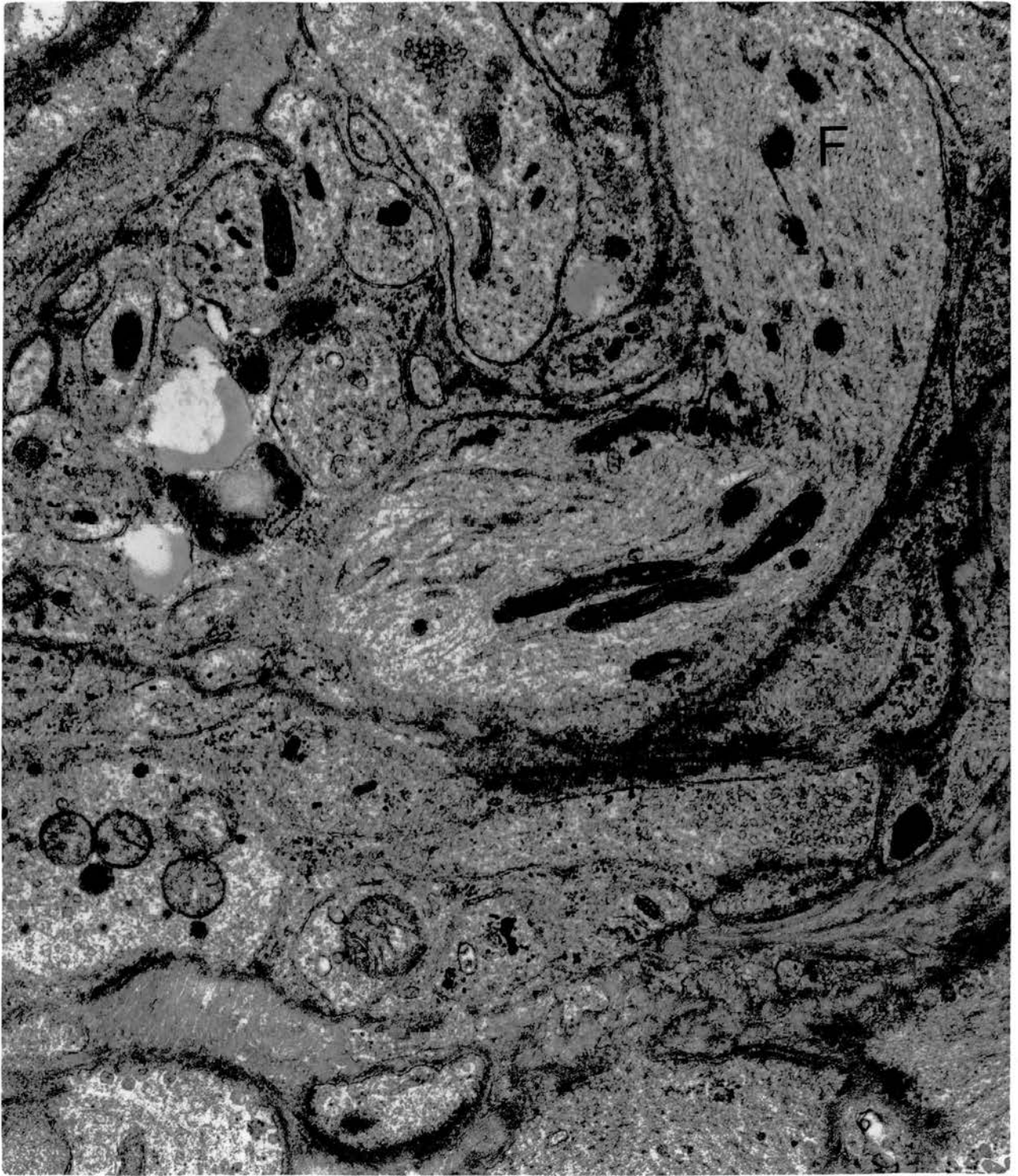


Fig. 97. At least three nerve endings (N) of variable size contain dense-cored and electron-lucent microvesicles. Note the fusion of an electron-lucent vesicle with the axolemma illustrated in the large nerve ending on the left (arrow). There are tiny dense granules in the centrally labelled ending which appear to lack a limiting membrane. x25000.

Caudal segment of ductus deferens.

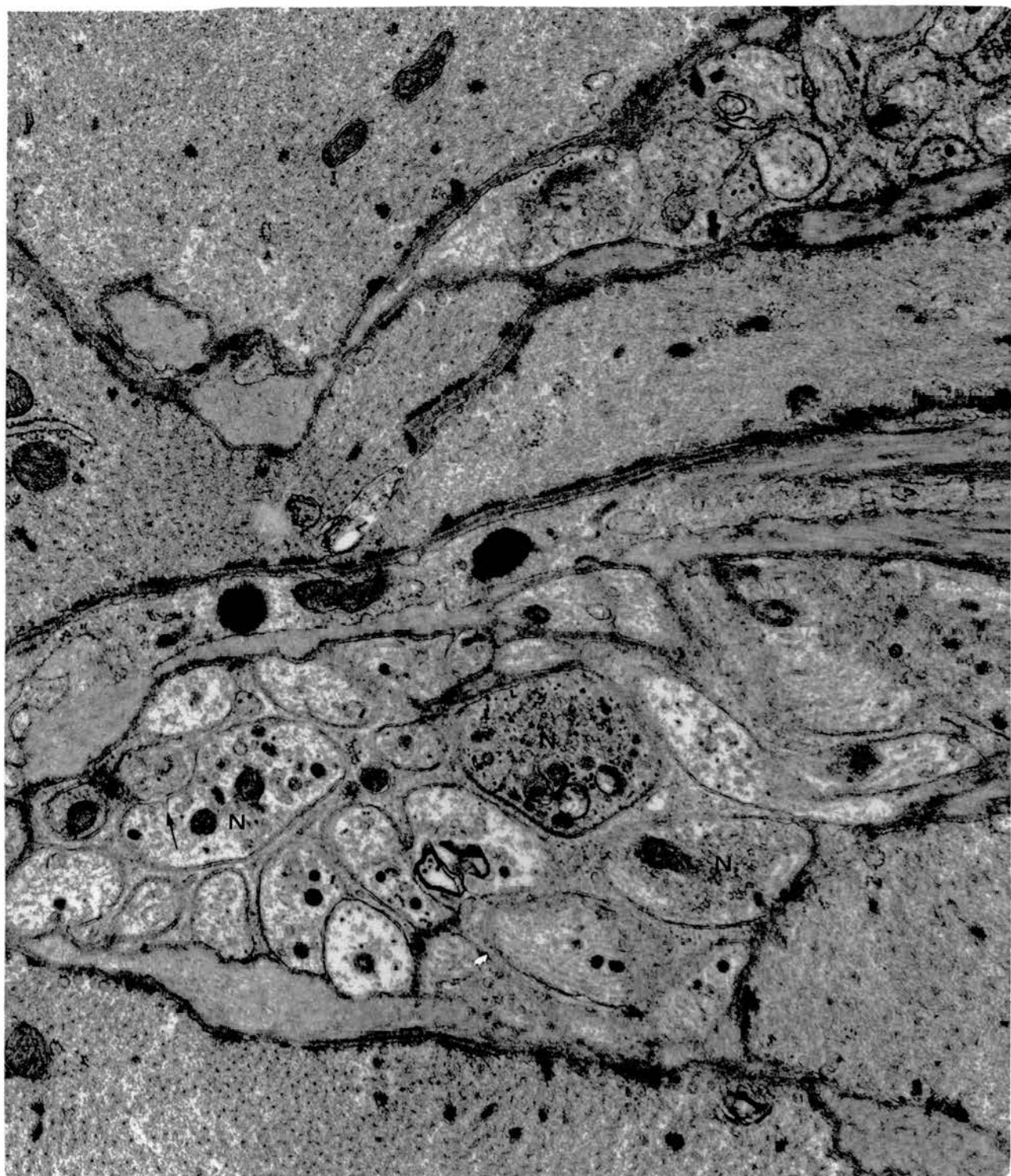


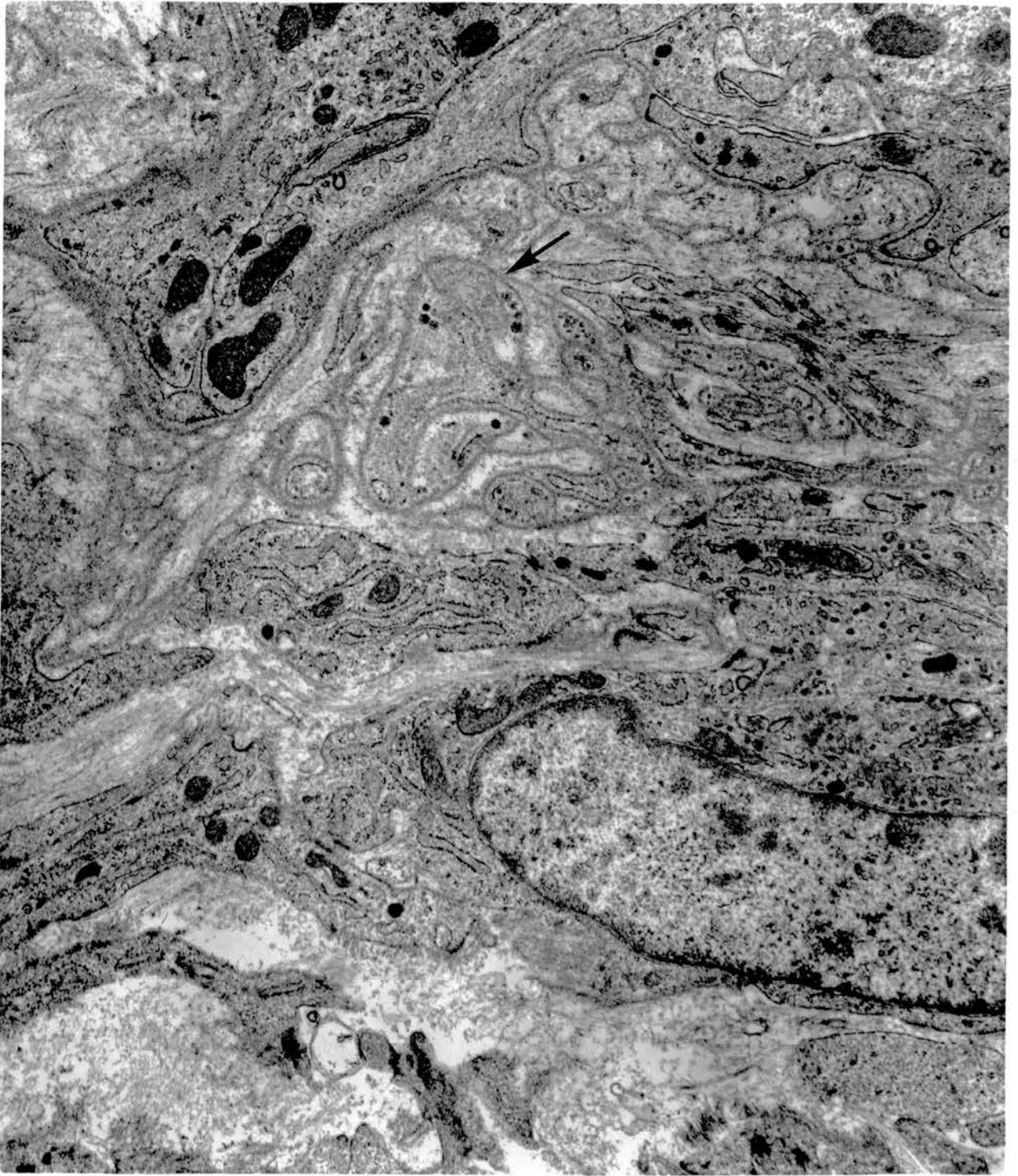
Fig. 98. Nerve ending apposed to a muscle fibre. There are no morphological specializations at the area of contact and the Schwann cell cytoplasm is absent. x37500.

Caudal segment of ductus deferens.

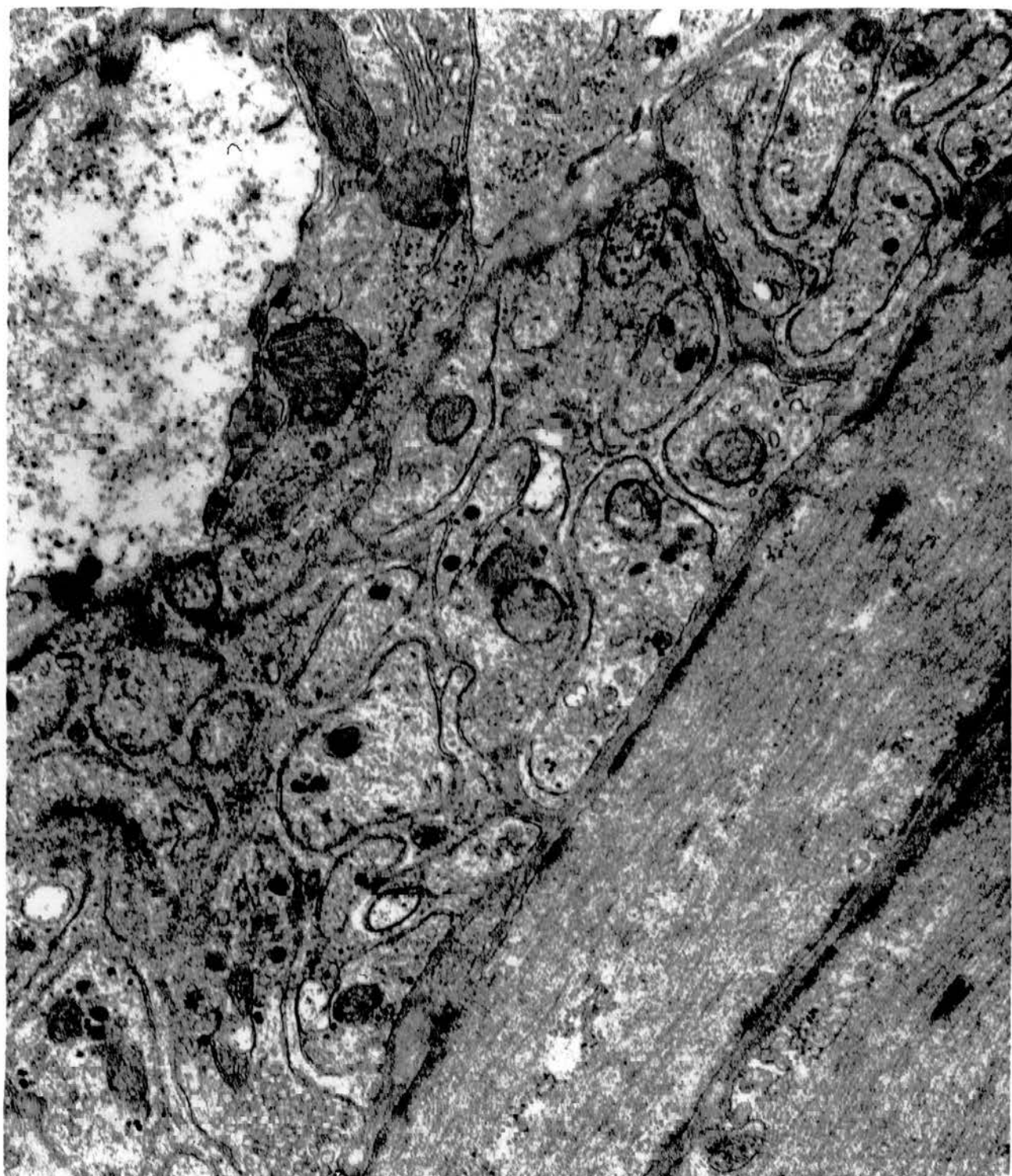

Fig. 99. Rich distribution of nerves in the subepithelial tissue of the rete testis. Note the association of a naked nerve ending (arrow) with the basal lamina beneath the epithelium.  
x 18750.

Epididymal region.






Fig. 100. A nerve ending containing granular and agranular microvesicles, devoid of investing Schwann cell; it is related to the basal lamina underlying a non-ciliated type I cell in an efferent ductule. x 25000.

Epididymal region showing part of an efferent ductule.



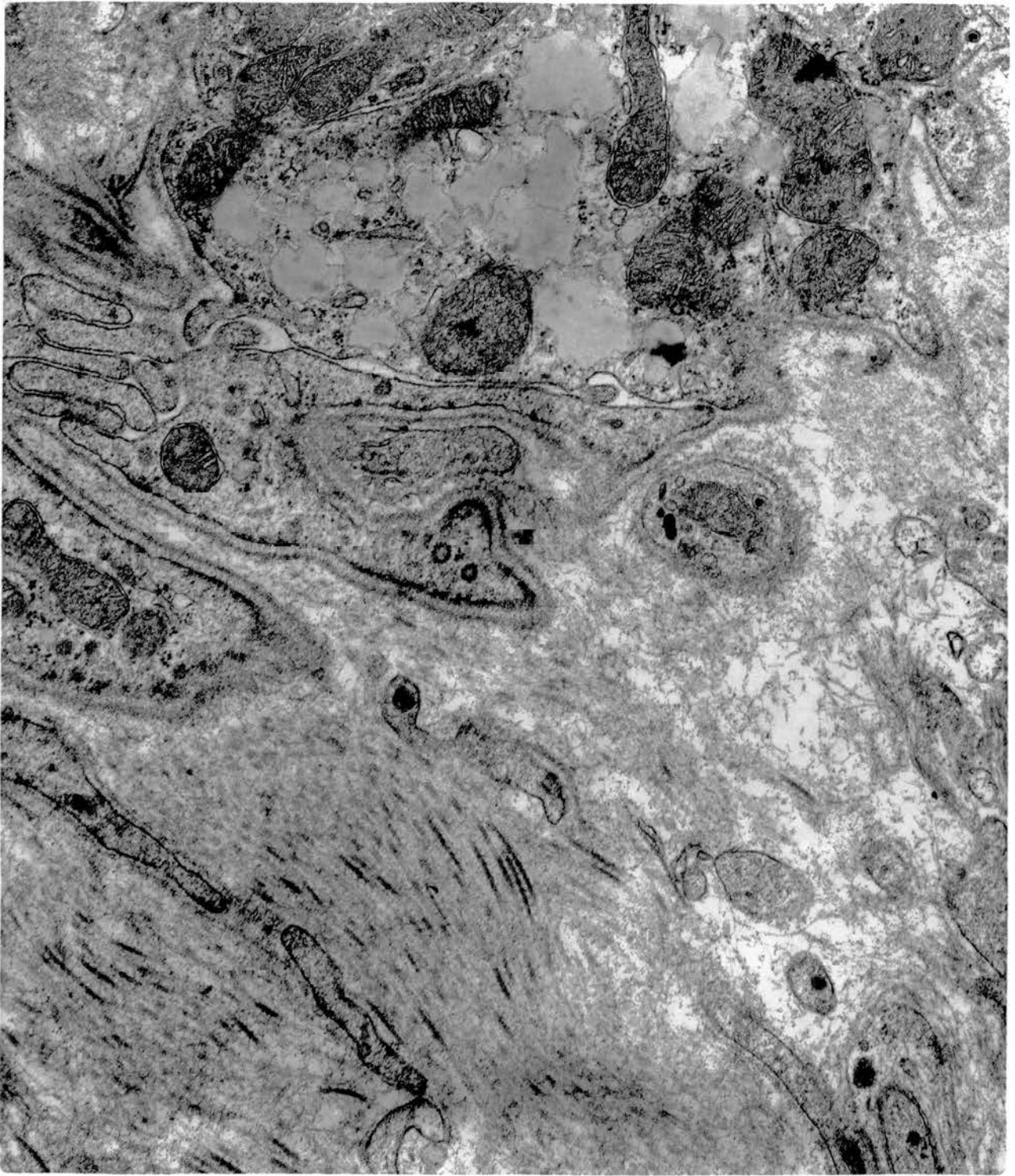


Fig. 101. An exceedingly rich distribution of nerve fibres applied to the basal lamina underlying the non-ciliated type II cells. Schwann cell cytoplasm is absent from the applied side of some endings. x 25000.

Basal parts of epithelial lining of ductus epididymidis.

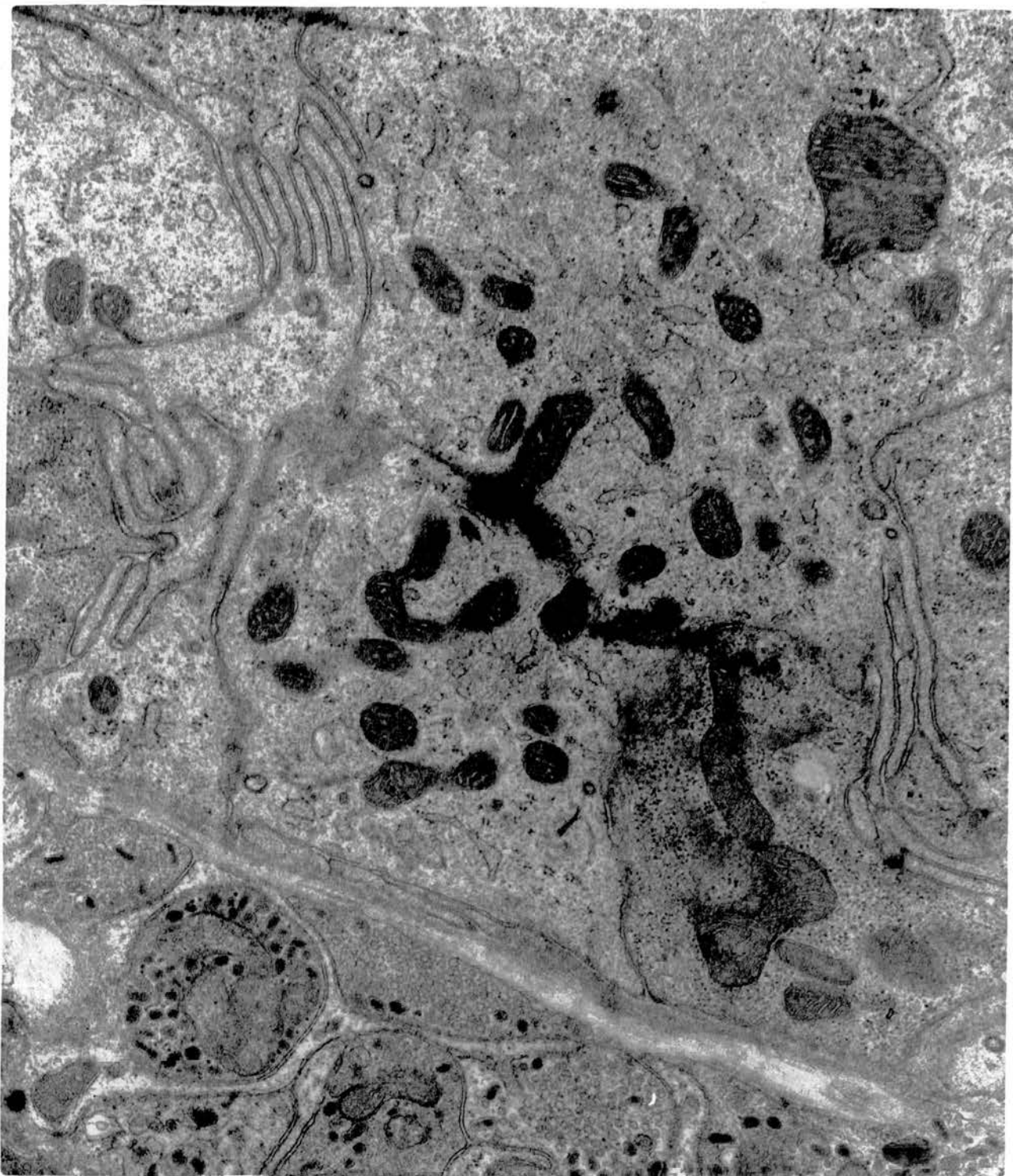


Fig. 102. A similar feature to that in figure 101 is also observed in relation to non-ciliated type II cells in the ductus deferens. x25000.

Basal parts of epithelial lining of cranial part of ductus deferens.

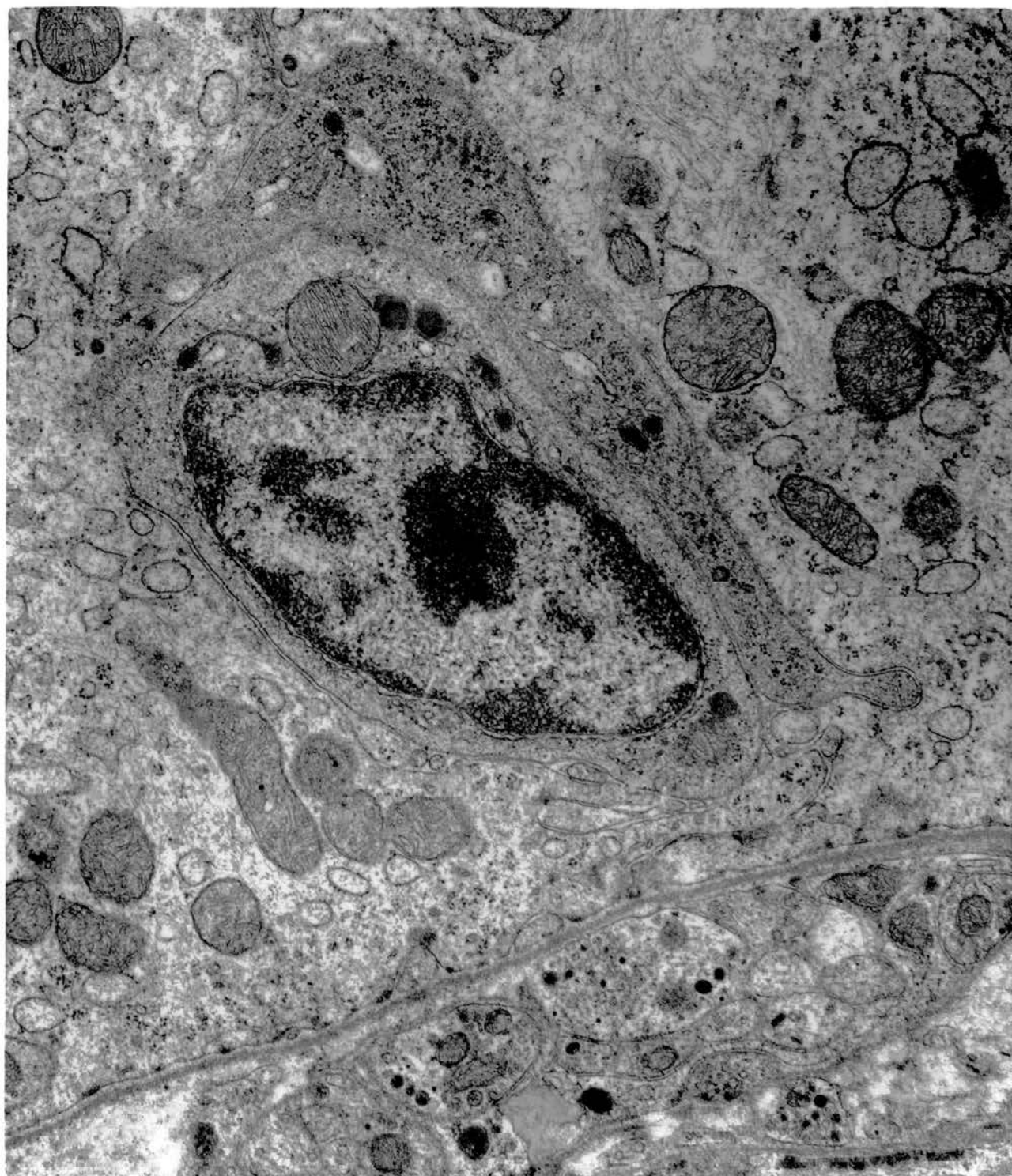


Fig. 103. Nerve endings devoid of Schwann cell investment <sup>appear to be</sup> applied directly to the plasma membrane of a non-ciliated type II cell. Note the absence of intervening basal laminae.  
x 18750.

Part of epithelial lining of ductus epididymidis.

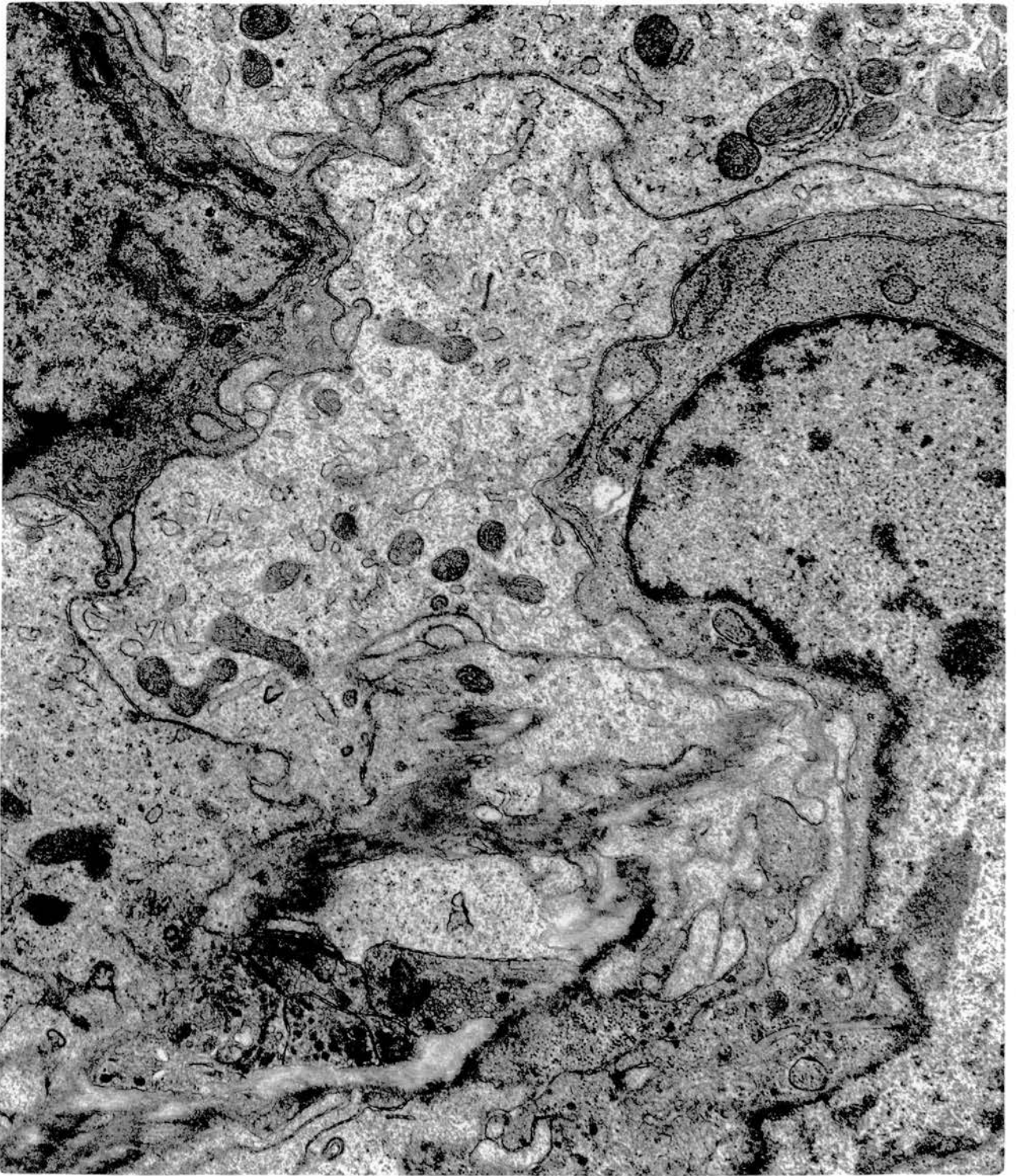


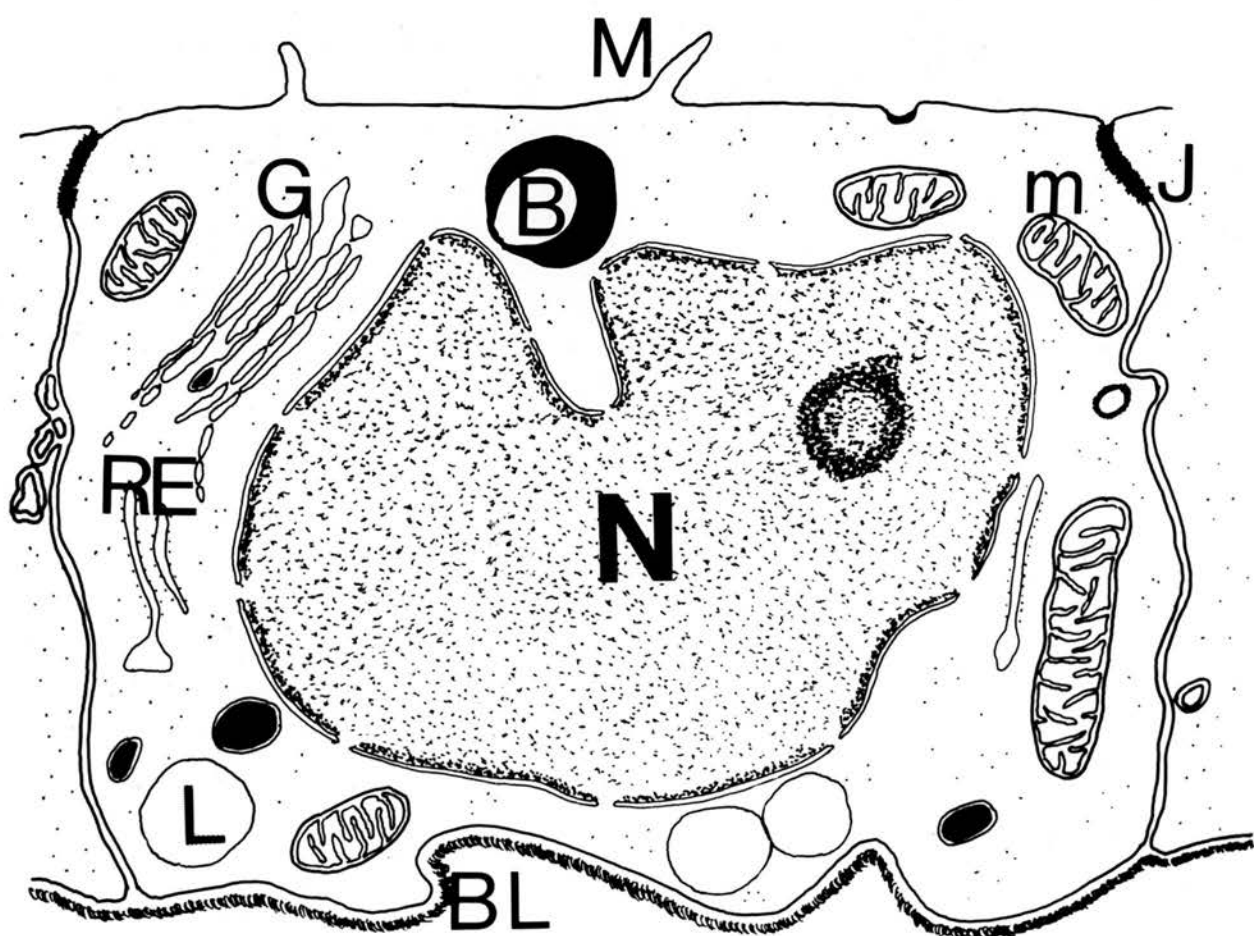
Fig. 104. Dense-cored vesicles seen in the form of spherical or oval shapes which may or may not be constricted; the dense material almost completely fills the vesicle. In other cases the vesicle contains only a portion of electron-dense material or it may appear quite empty. x50000.

Intertubular tissue of the epididymal region.



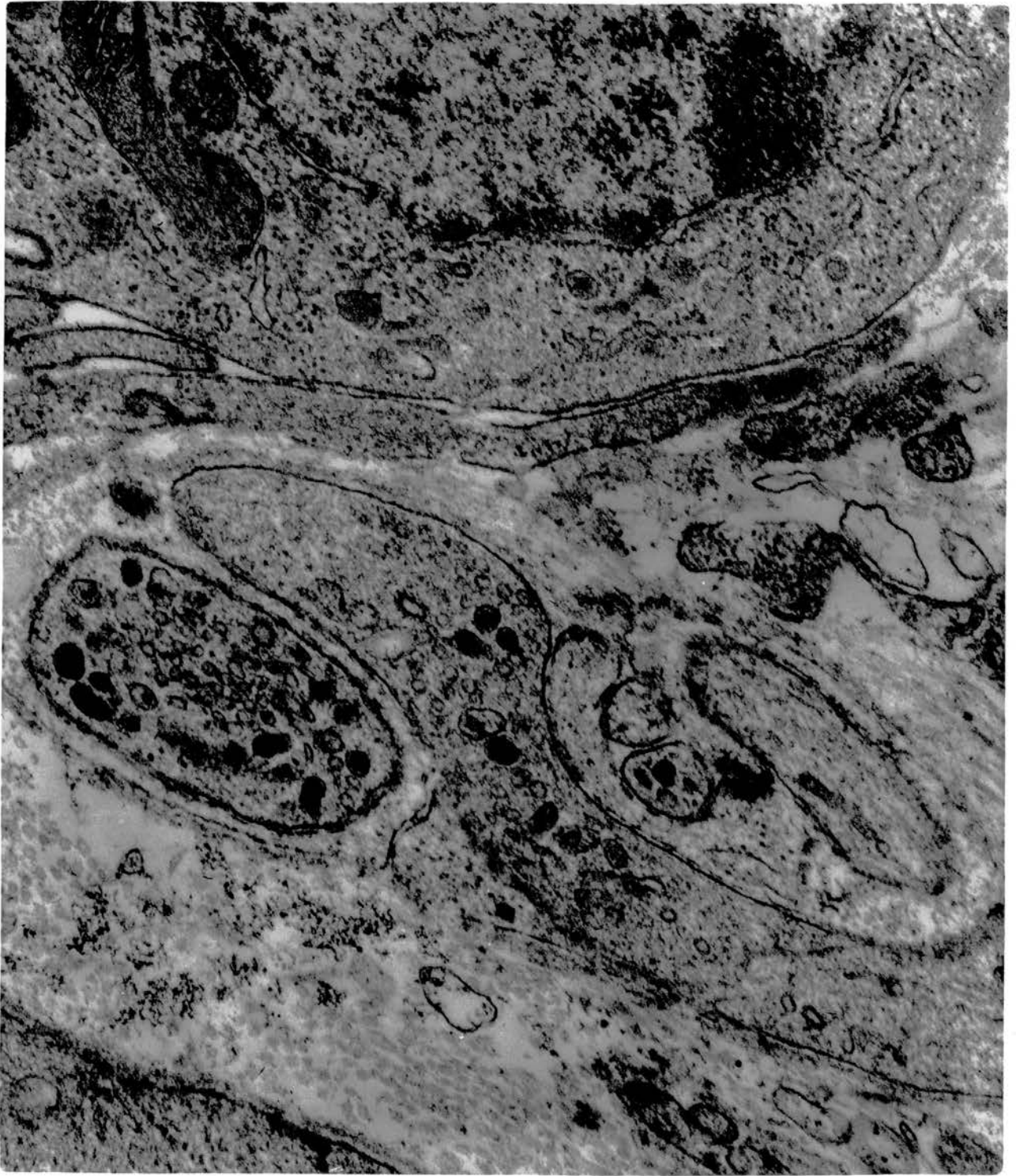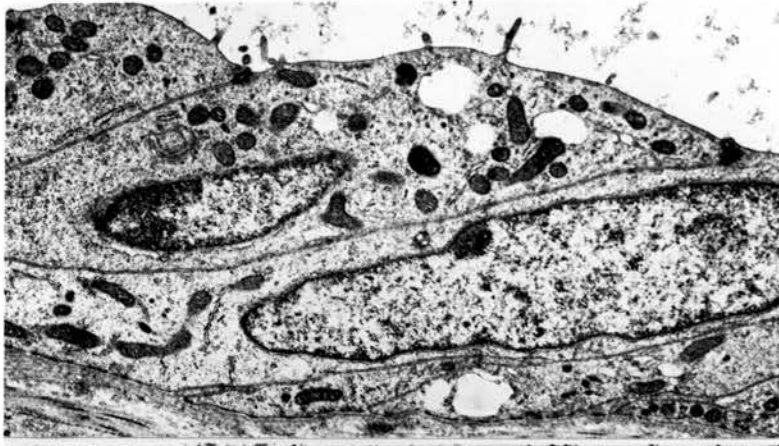


Fig. 105. Diagrammatic representation of the fine structure of the low cuboidal rete cells. M, microvilli; J, junctional complex; BL, basal lamina; N, nucleus; G, Golgi complex; RE, rough endoplasmic reticulum; m, mitochondria; B, electron-dense body; L, lipid.

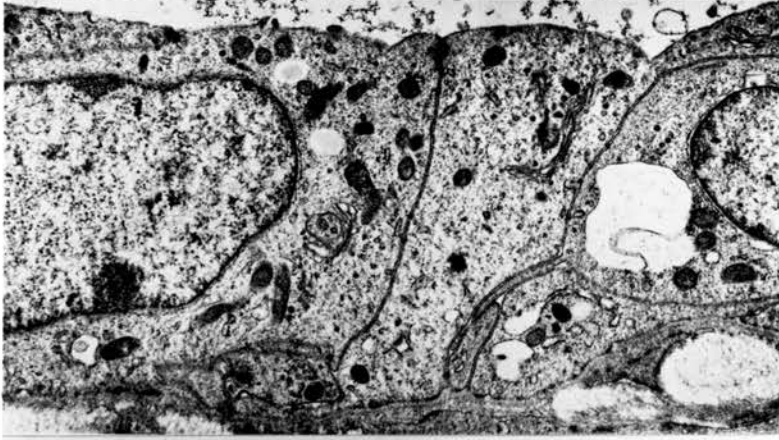

Figs. 106-108. Variations in the shape of the lining epithelia of the rete testis showing the imbricated arrangement of cells. Note the rudimentary microvilli in figure 106.  
x 10000.

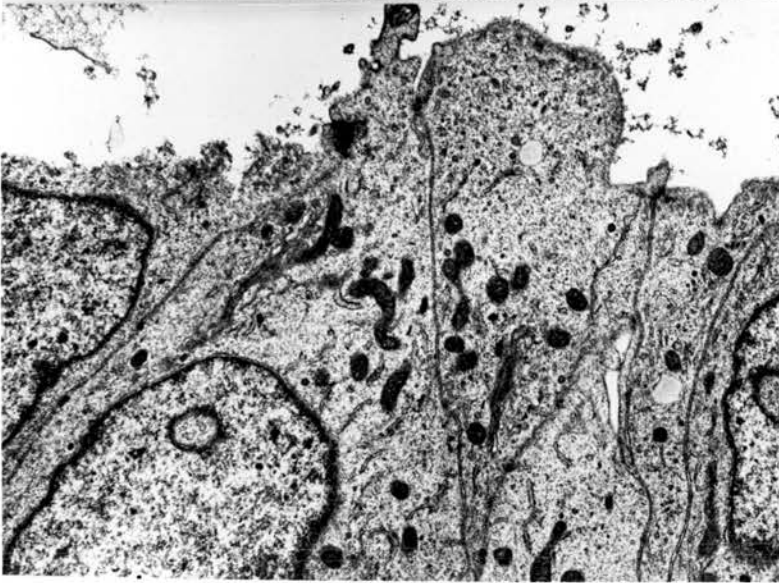
Epithelial lining of rete testis.



106



107



108

Fig. 109. Rete cells with a large irregular nucleus containing a distinct nucleolus. A Golgi complex and a few mitochondria are scattered in the cytoplasm. x 30000.

Rete testis.

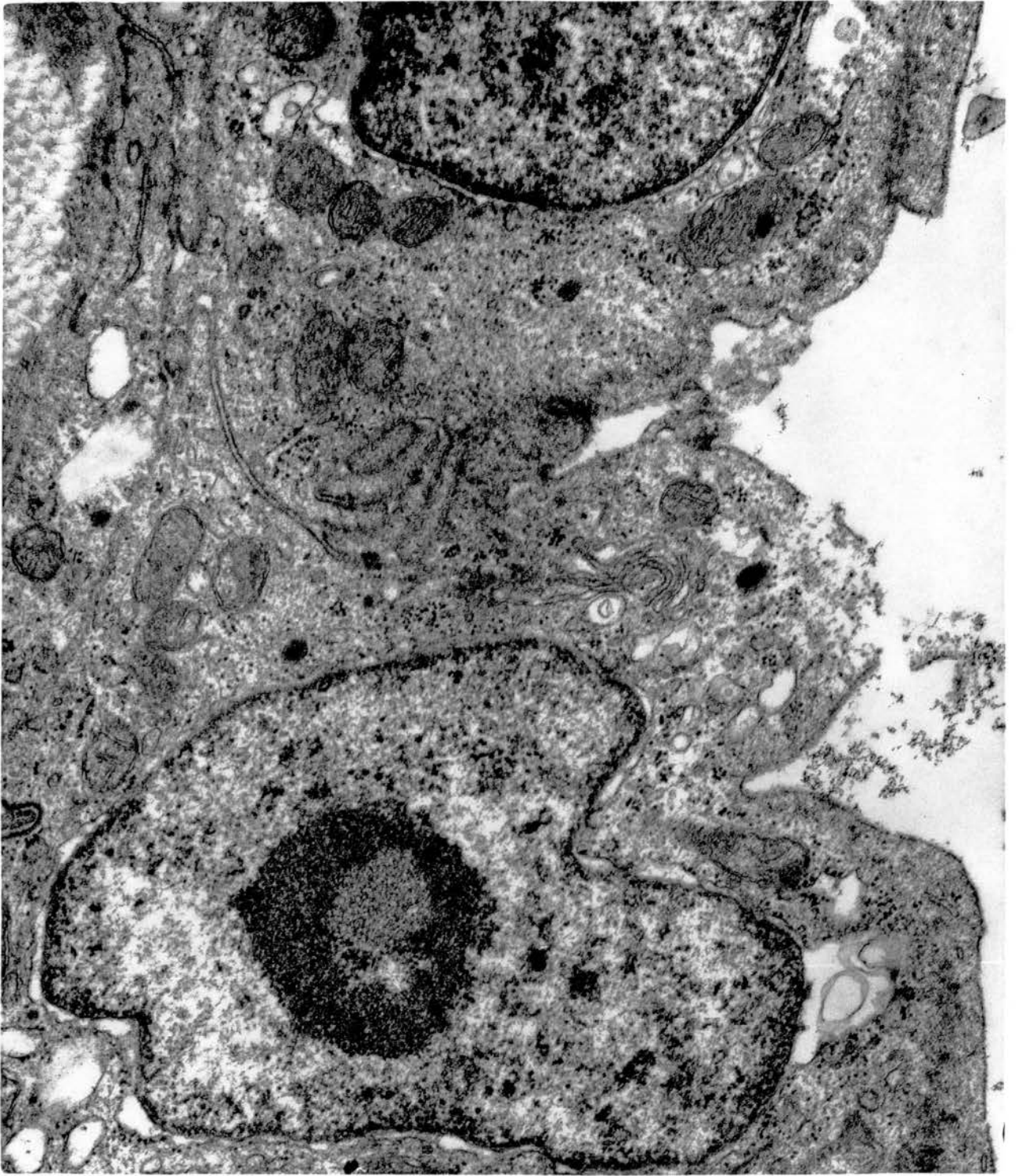

Fig. 110. Part of a rete cell showing a high nucleocytoplasmic ratio and a vesicular structure within the nucleus. Some spermatozoa are seen in the lumen. x 25000.

Rete testis.



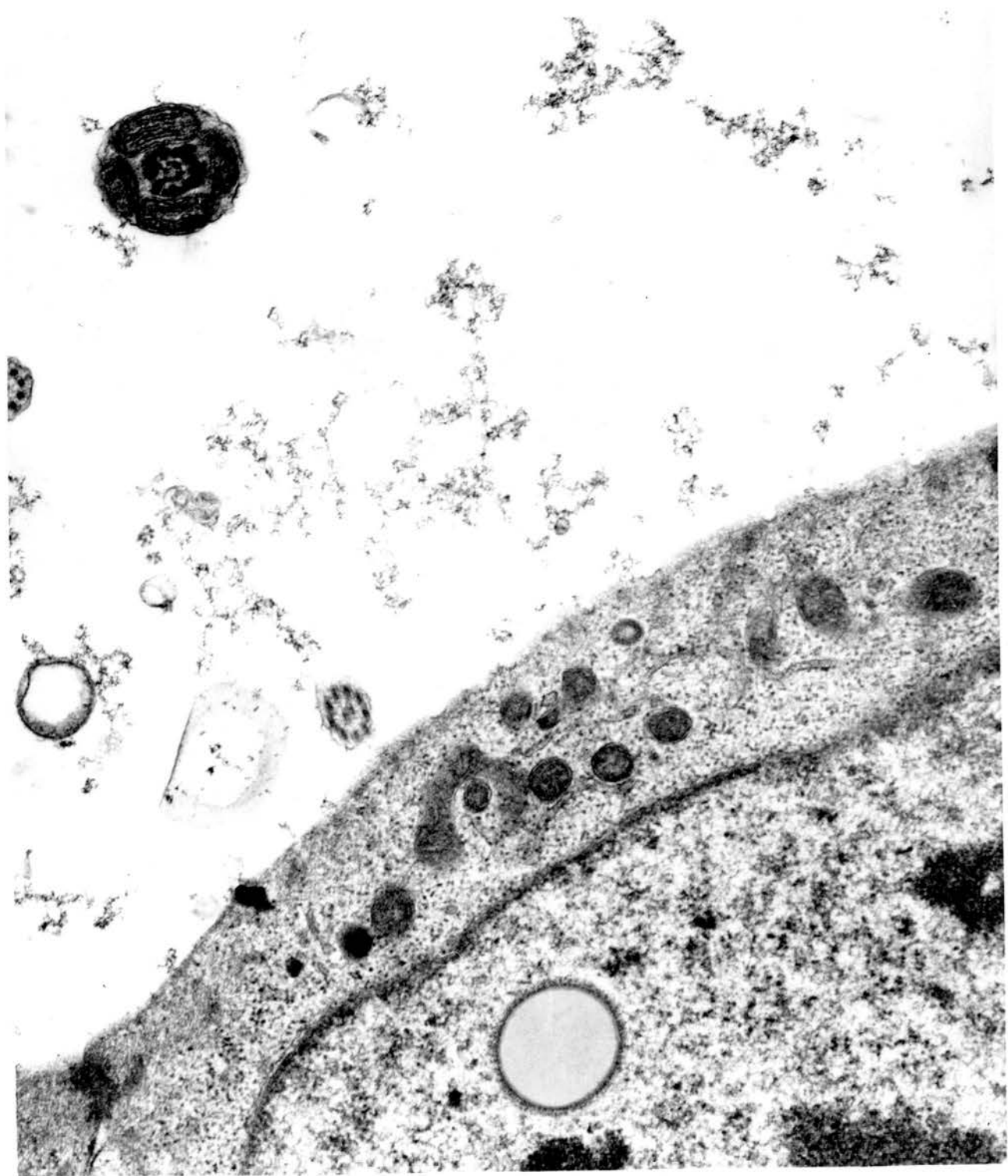


Fig. 111. Rete cells with a sizeable Golgi complex; some of the cisternae are enlarged at the periphery. A few mitochondria and RER are scattered in the cytoplasm. Collagenous fibres are seen in the subepithelial tissue.  
x 25000.

Rete cells and the underlying subepithelial tissue.

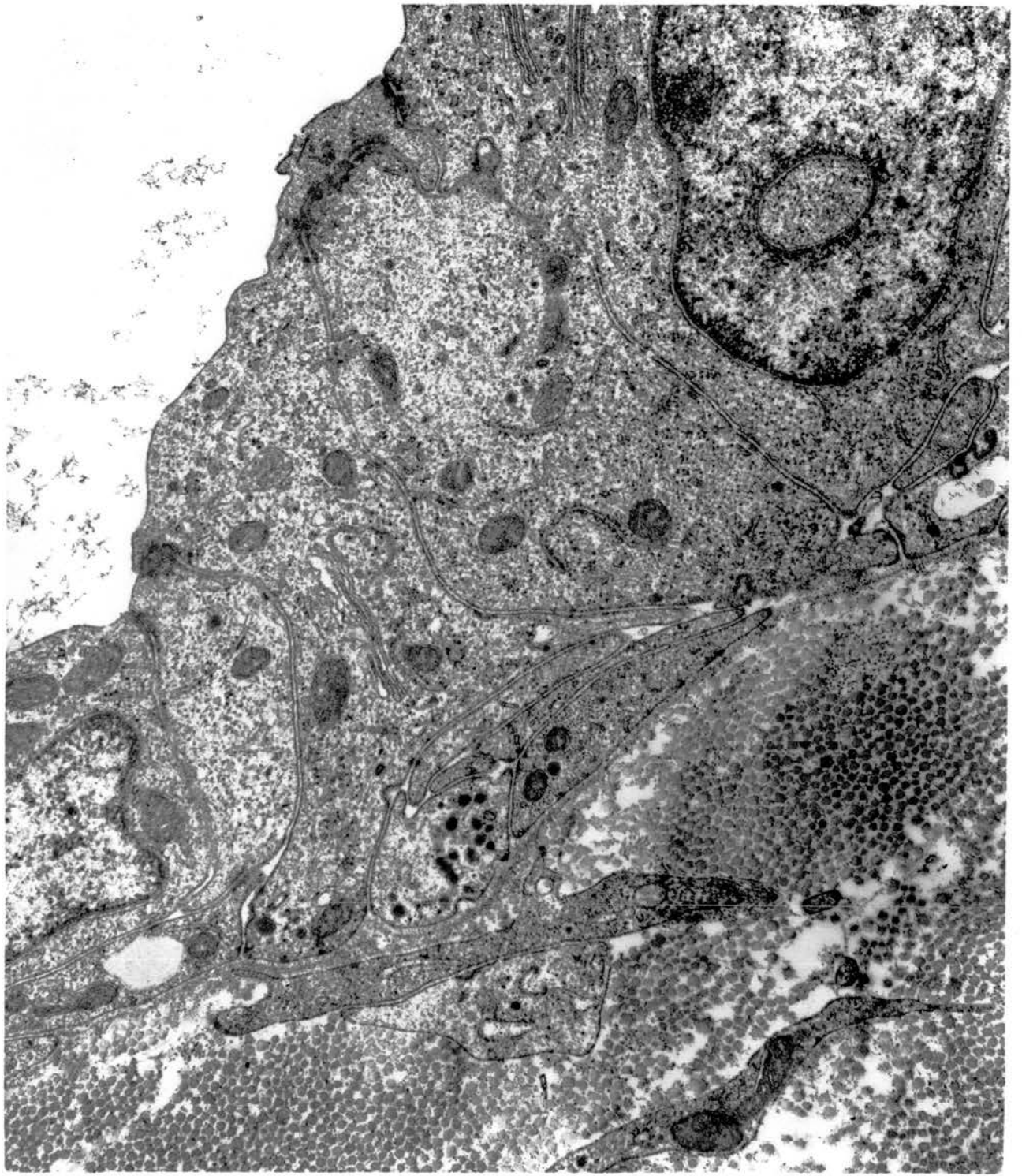


Fig. 112. Rete cells (left) and nerve bundle together with the associated Schwann cell in the immediate subepithelial tissue. Note the electron-dense bodies in the vicinity of the Golgi complex in the rete cells. x 25000.

Basal part of epithelial lining of rete testis and adjacent intertubular tissue.

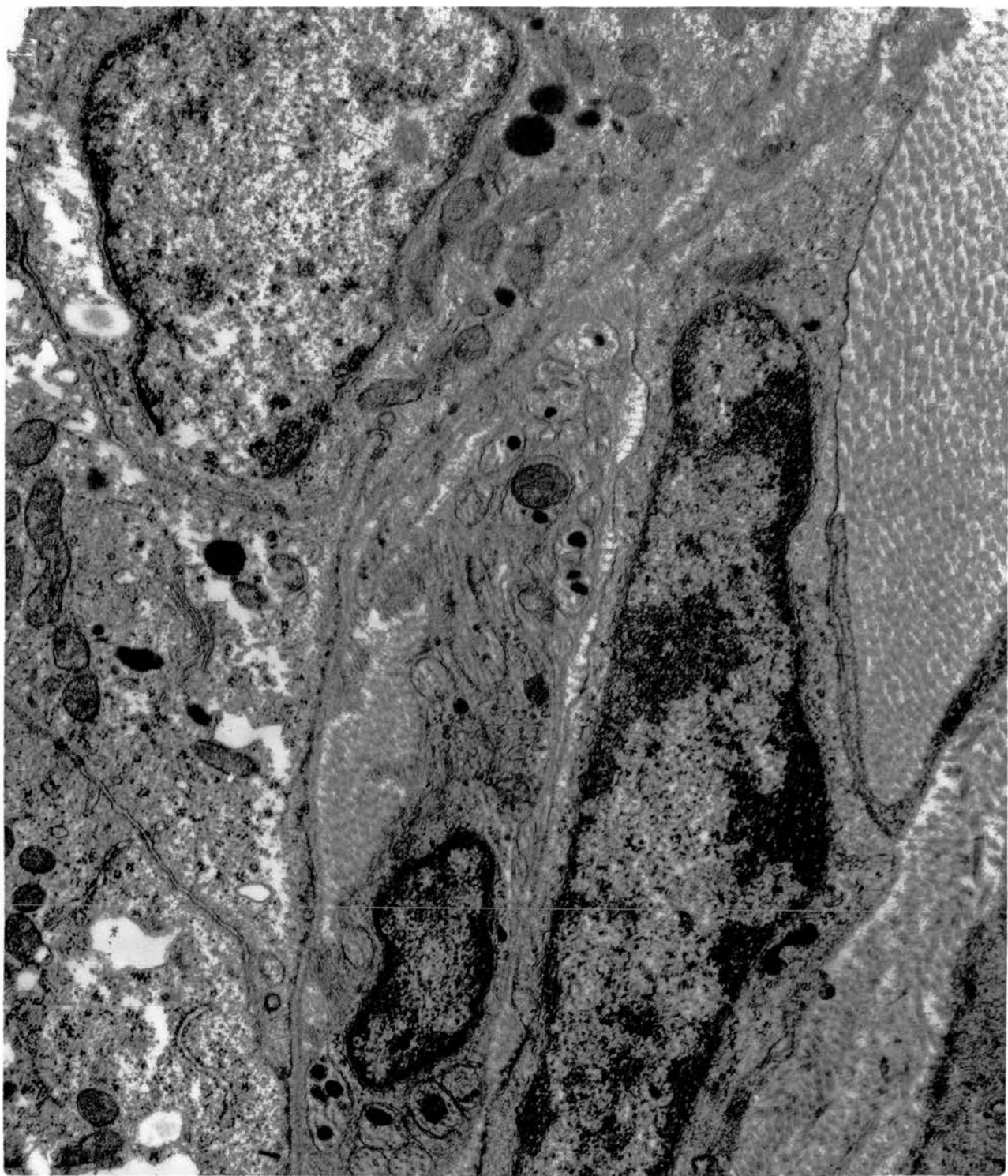


Fig. 113. Rete cells with many cytoplasmic organelles. There are many mitochondria and a large Golgi complex. Some of the RER appears to communicate with smooth saccular structures. x 25000.

Rete testis.

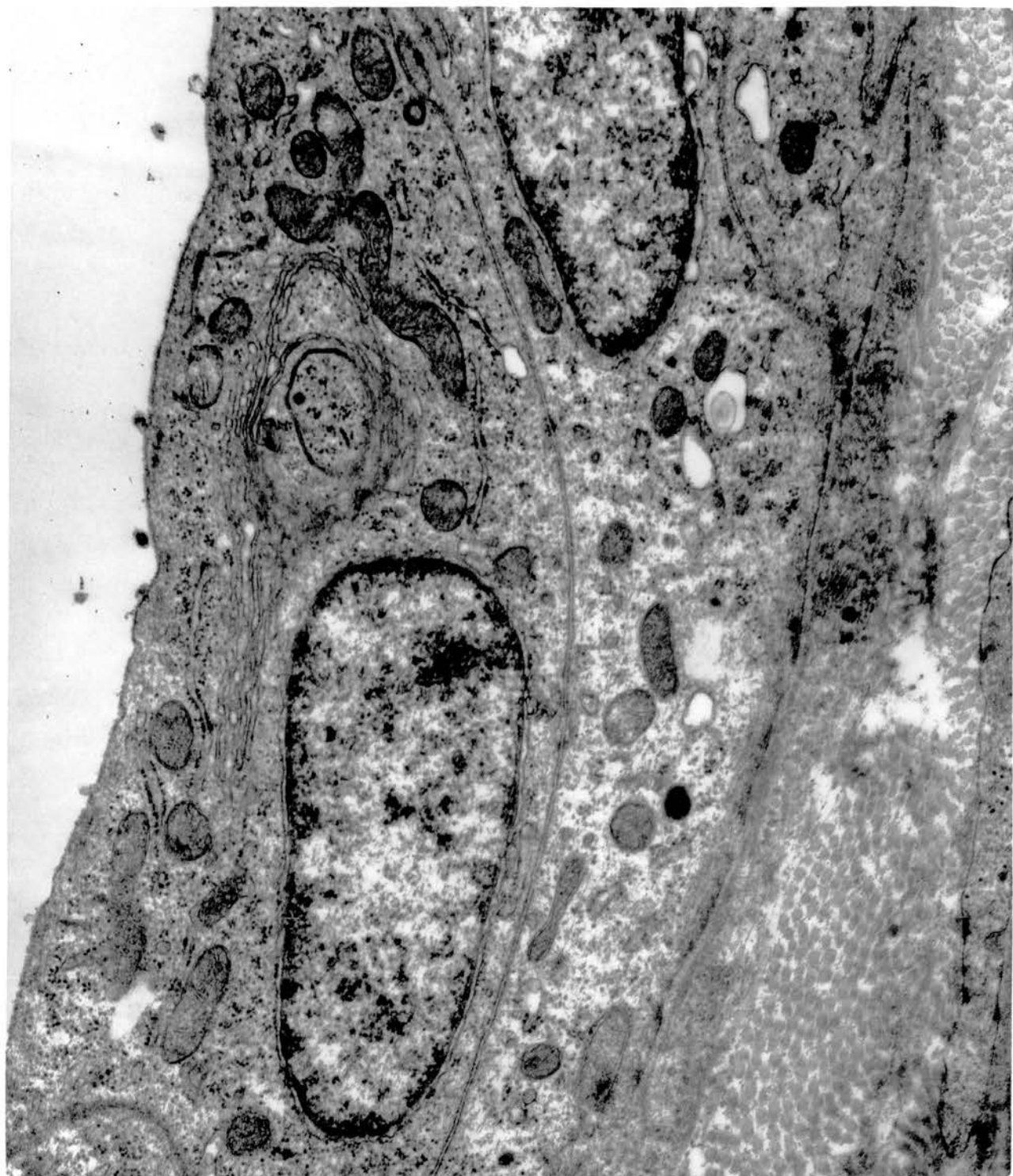

Fig. 114. Numerous cytoplasmic vacuoles are apparently coalescing and appear to contain lipid; many collagenous fibres are seen in the subepithelial tissue. x 25000.

Rete cells and adjacent subepithelial tissue.



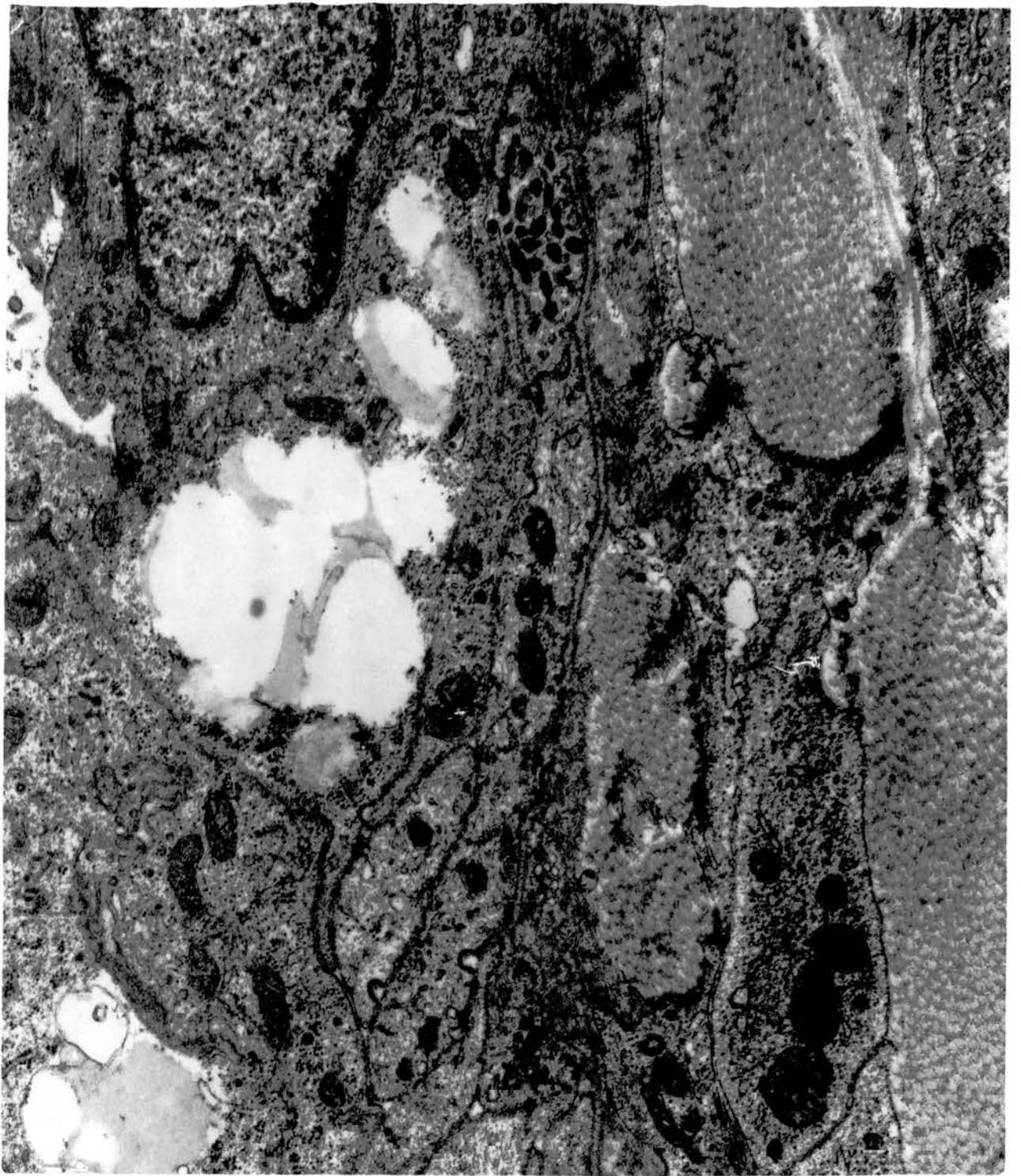


Fig. 115. A rete cell looks normal and contains intracytoplasmic sections of spermatozoa (left and bottom). x 25000.

Rete epithelium and adjacent subepithelial tissue.

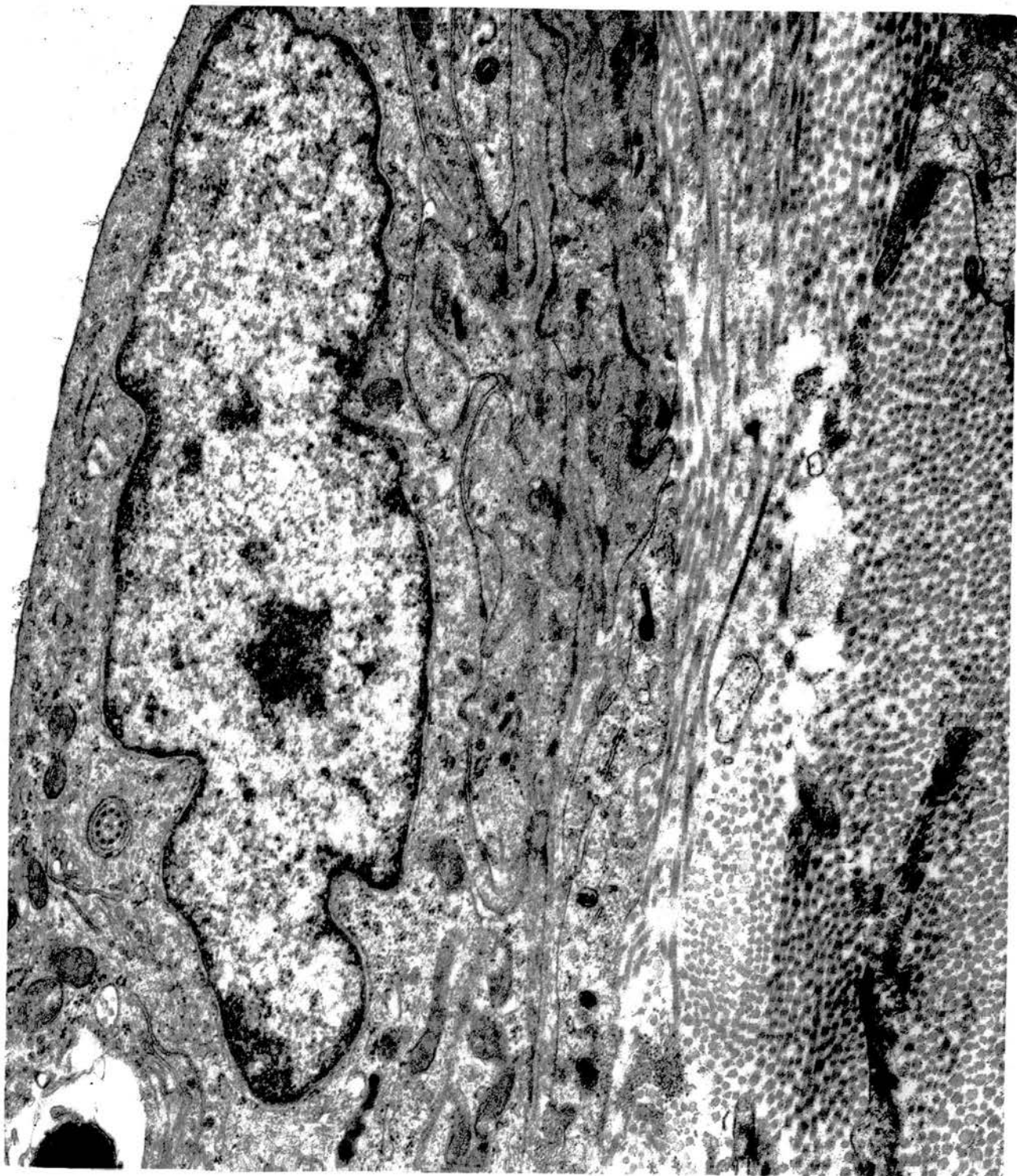


Fig. 116. Some of the rete cells are occasionally more electron-dense than others. x 18750.

Epithelial lining of rete testis.

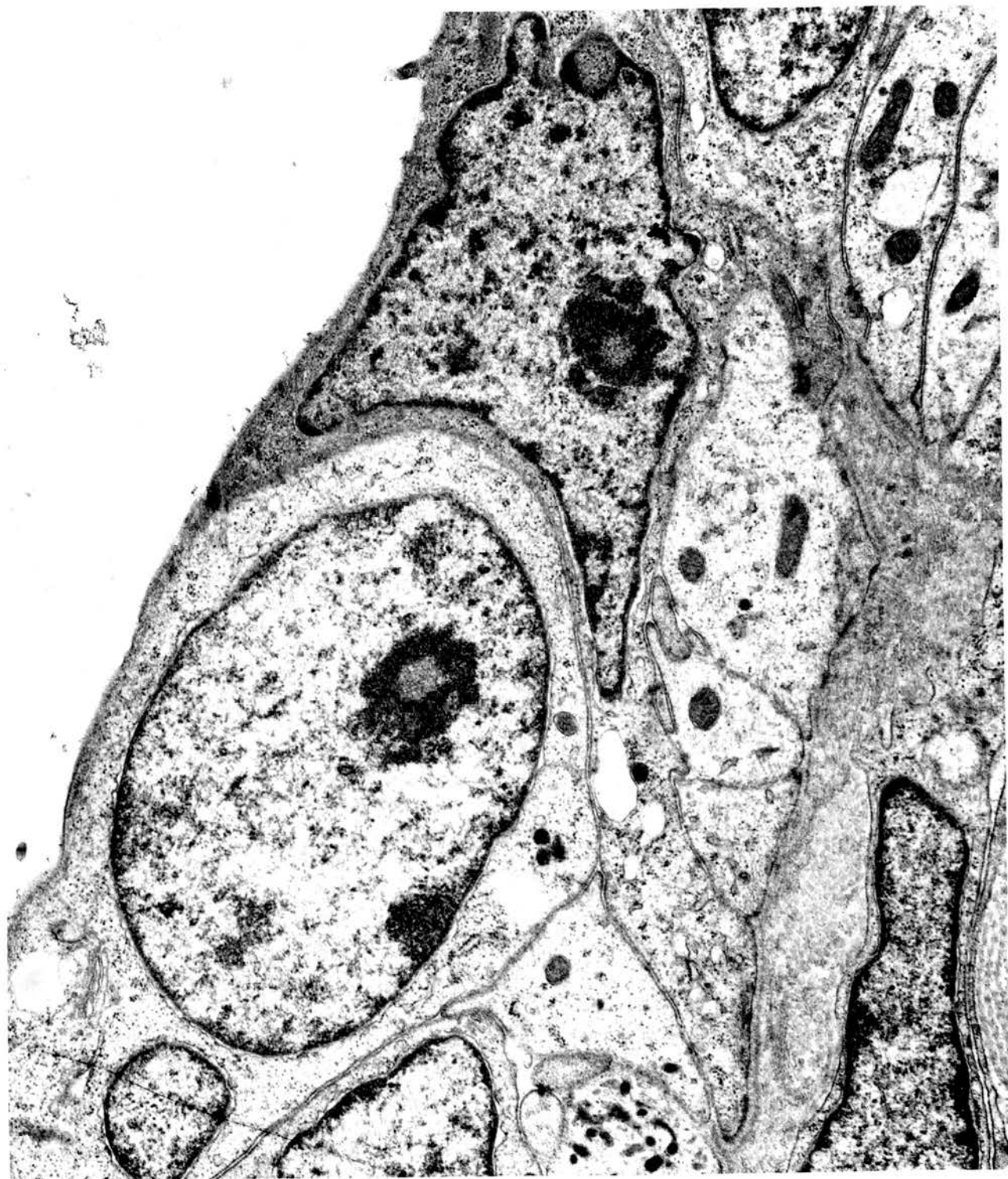

Fig. 117. Schematic representation of a non-ciliated type I cell. M, microvilli; BL, basal lamina; J, junctional complex; N, nucleus; G, Golgi complex; m, mitochondria; S, smooth endoplasmic reticulum; RE, rough endoplasmic reticulum; B, electron-dense body; V, vacuole; L, lipid; H, heterogeneous body.

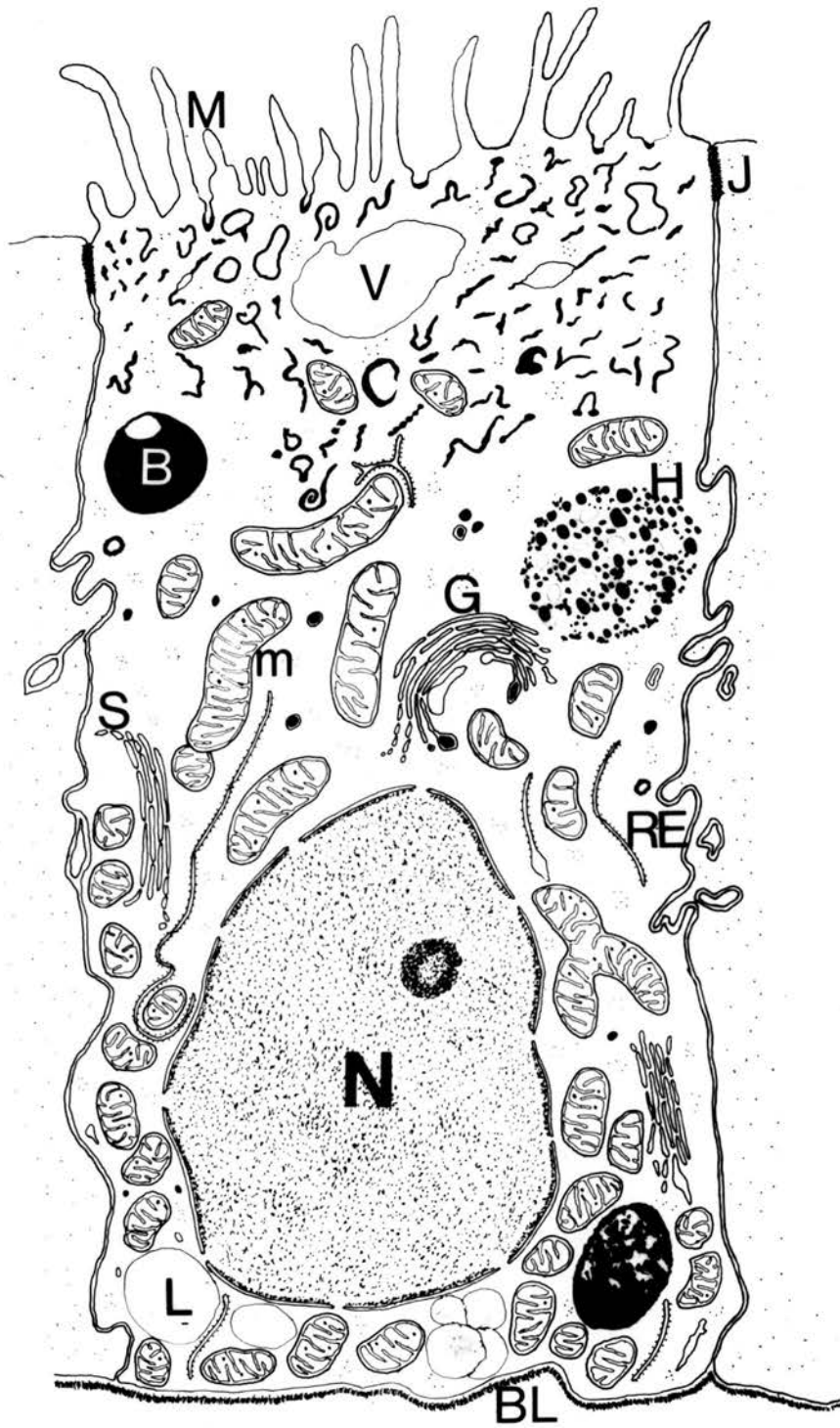


Fig. 118. Numerous microvilli project from the luminal border of a non-ciliated type I cell. Electron-dense structures are scattered in the apical cytoplasm. x 37500.

Ductulus efferens.



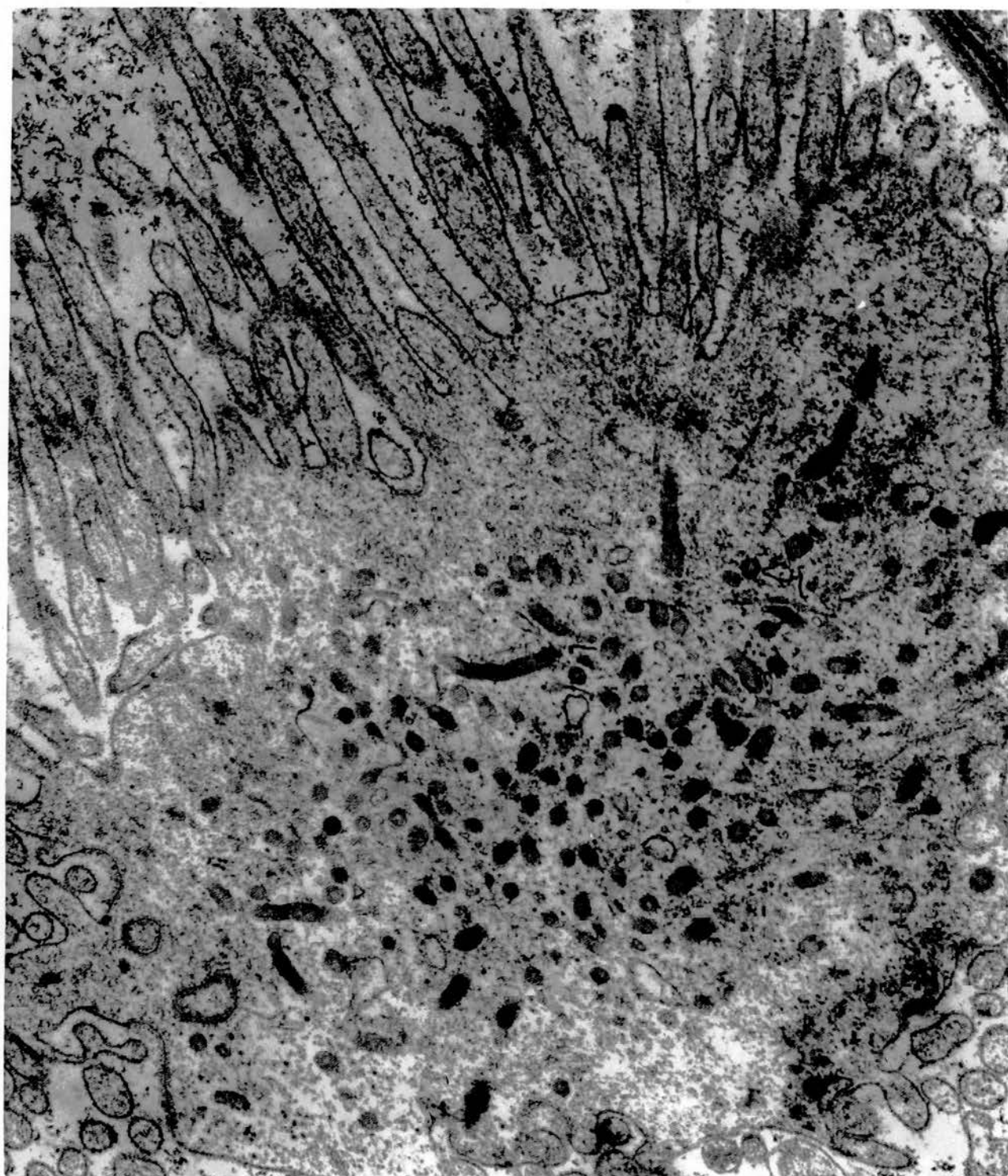


Fig. 119. Worm-like structures occupying the apical cytoplasm of non-ciliated type I cells in the upper right half of the field. Luminal microvilli of these cells are regular and closely packed. The lateral plasma membranes are attached to those of the neighbouring cells by extensive junctional complexes. x 18750.

Ductulus efferens.

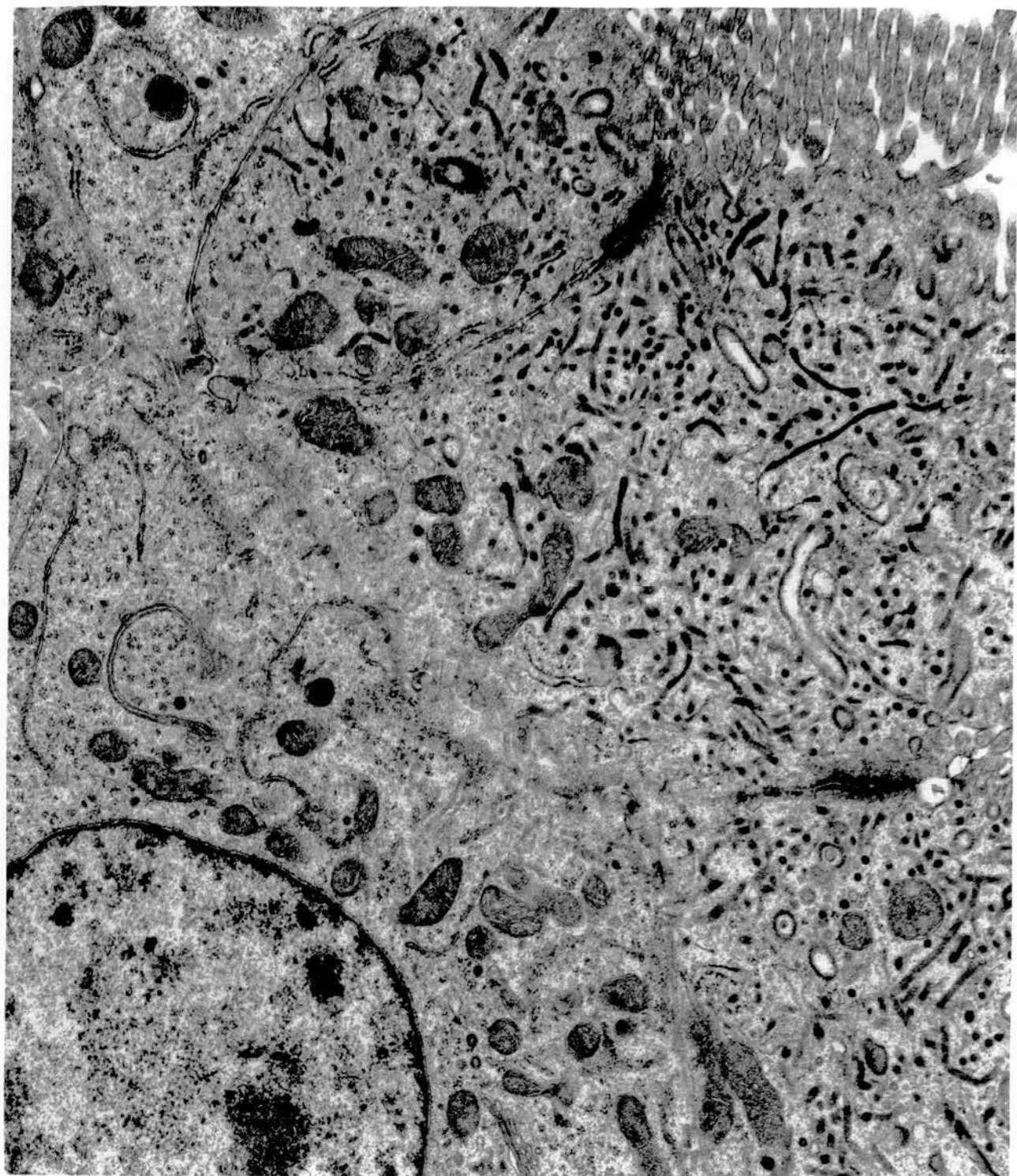


Fig. 120. Non-ciliated type I cell. Surface invaginations are spaced between the microvilli. They resemble micro-pinocytotic vesicles and also appear similar to some of the worm-like structures. x 37500.

Narrow connecting ductule.

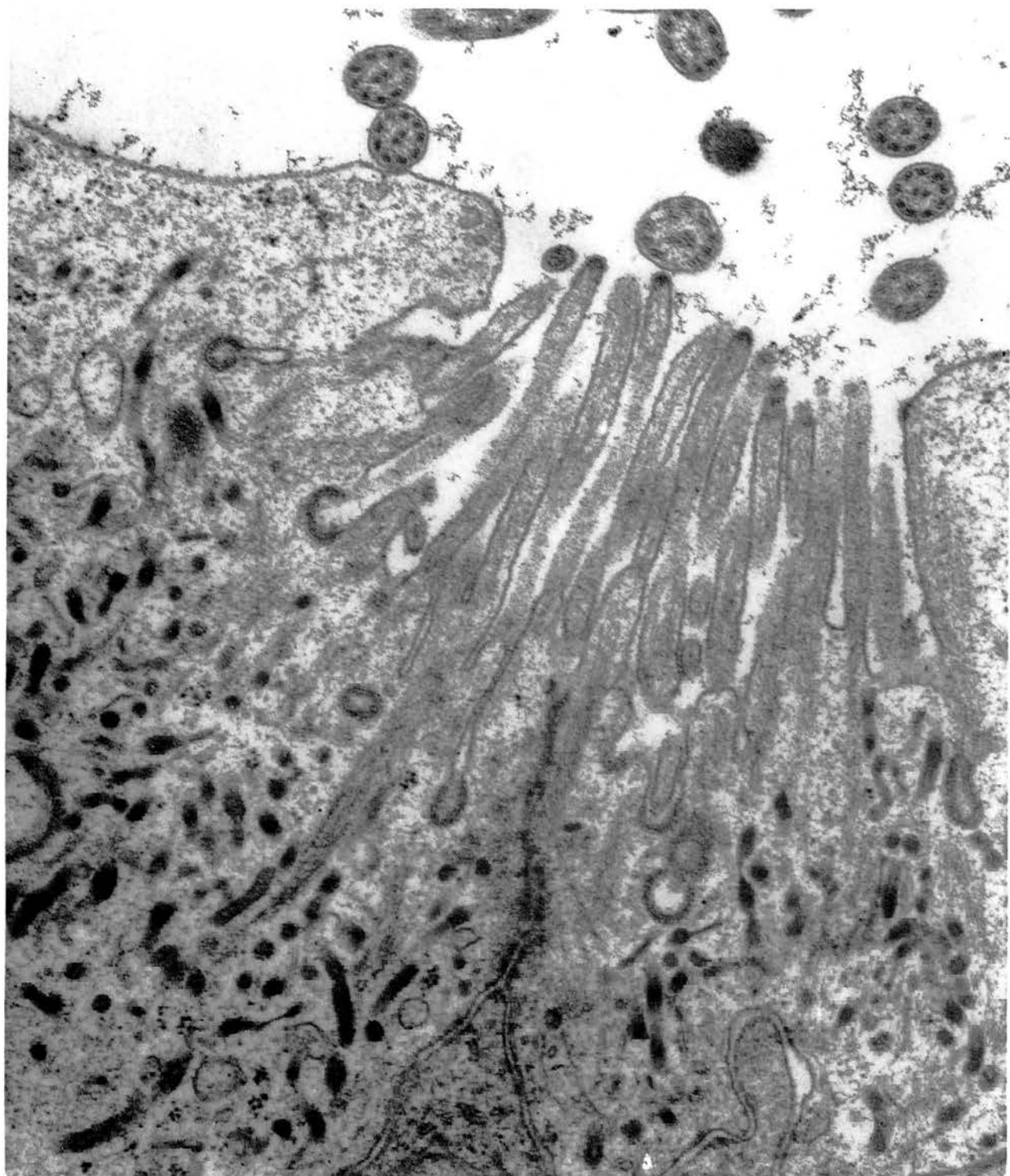


Fig. 121. A well developed Golgi complex is located in the supra-nuclear cytoplasm of a non-ciliated type I cell; an electron-dense granule is seen within its cisternae. Large multigranular heterogeneous bodies are commonly found in the cytoplasm. Note the variation in the granular and lipid content of these bodies. They occur in different shades of electron-opacity, and a limiting membrane is sometimes visible (bottom right).  
x 25000.

Ductulus efferens.

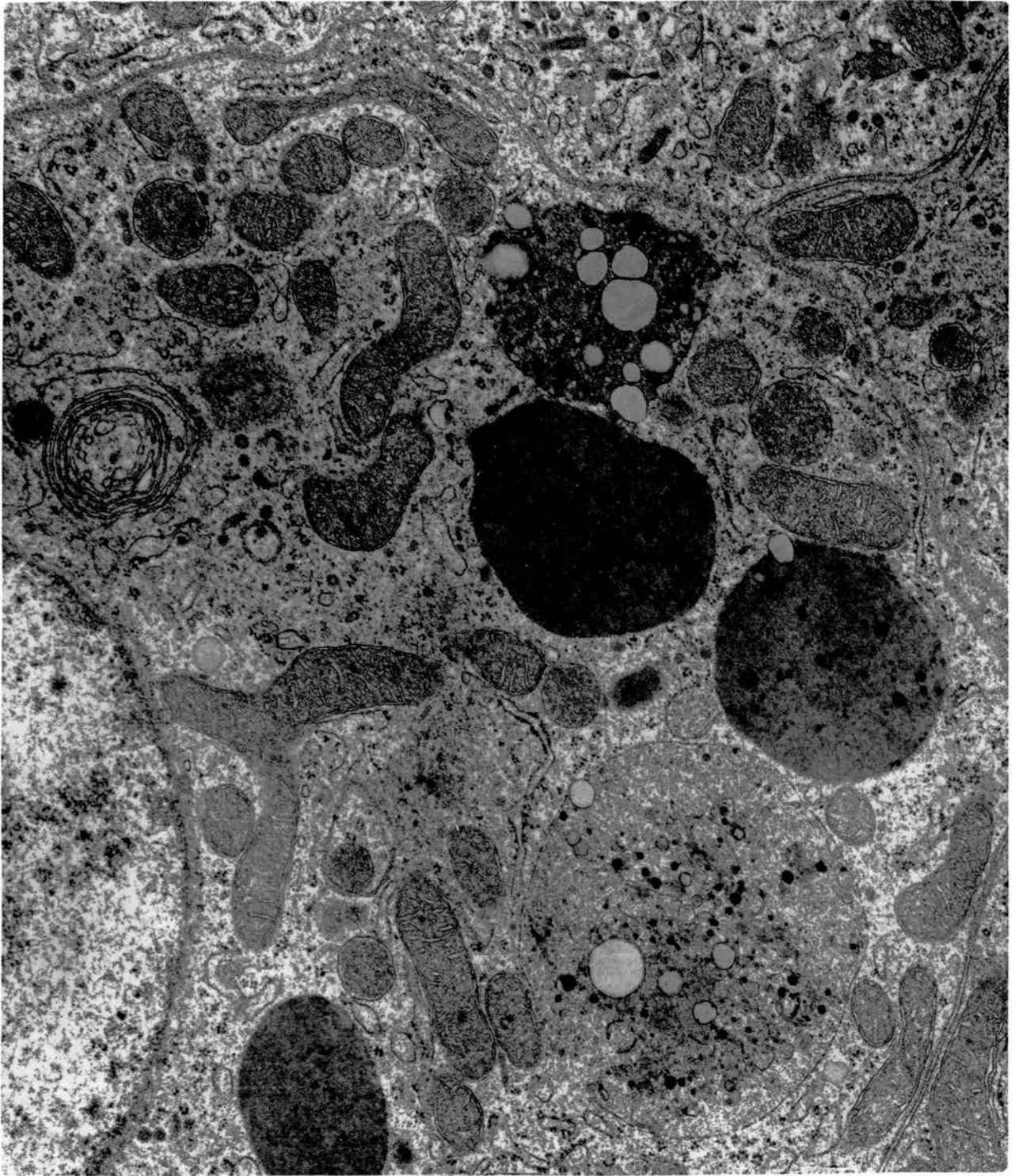


Fig. 122. Many stacks of SER and a number of mitochondria are randomly located in the cytoplasm of a non-ciliated type I cell. Note the electron-dense heterogeneous bodies, an autophagic vacuole (V) and an associated membranous whorl. x 18750.

Ductulus efferens.



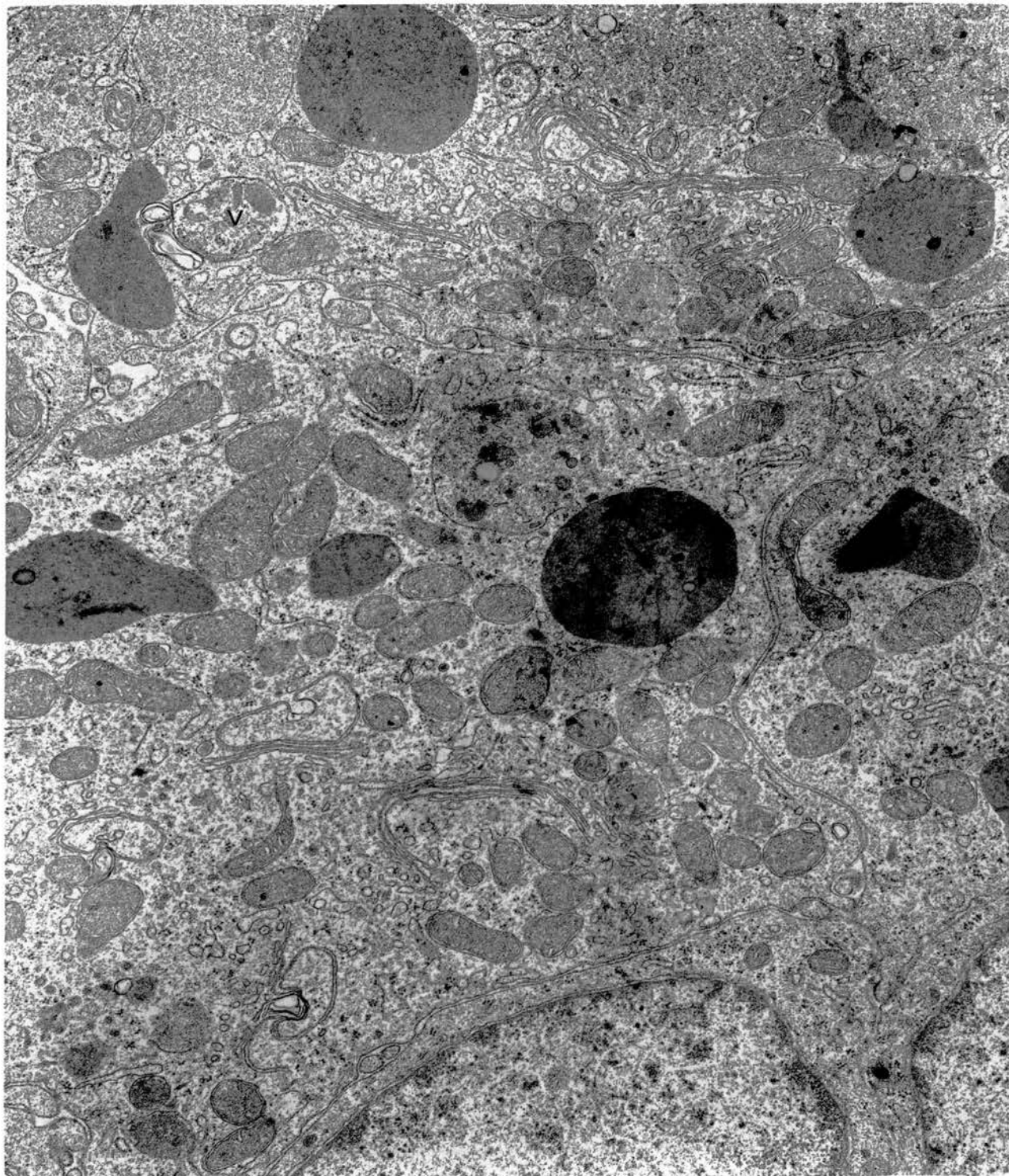


Fig. 123. A rich mitochondrial content in the basal cytoplasm of a non-ciliated type I cell. Dense intramitochondrial granules are seen in many of these organelles. x 25000.

Ductulus efferens.

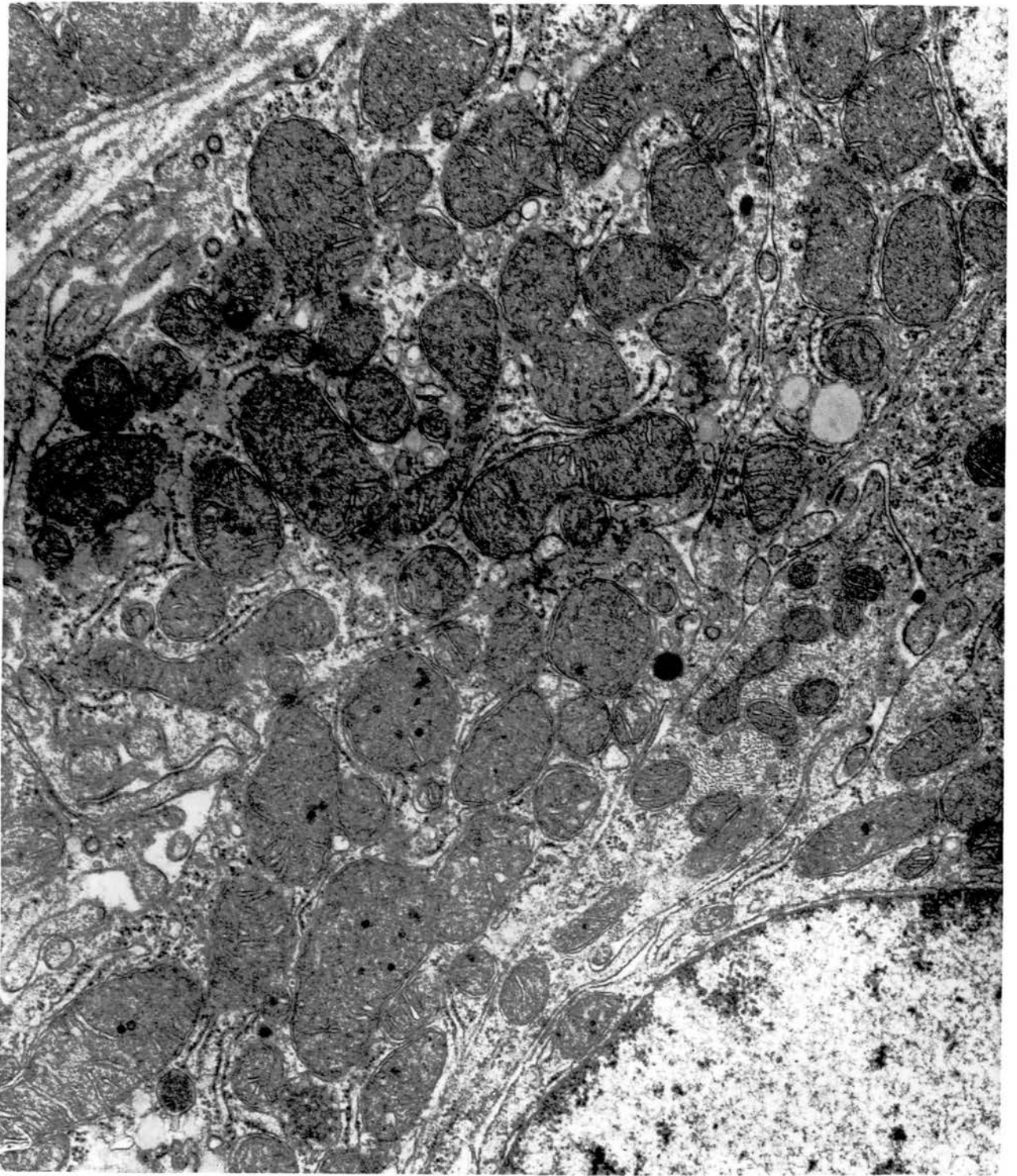


Fig. 124. Many mitochondria are located in the perinuclear and basal cytoplasm of non-ciliated type I cells. Some lipid droplets, large electron-dense heterogeneous bodies, and small dense granules are also present. Cytoplasm in the upper right of the field, with a few small mitochondria and a striated rootlet belongs to a ciliated cell.  
x 18750.

*Ductulus efferens.*

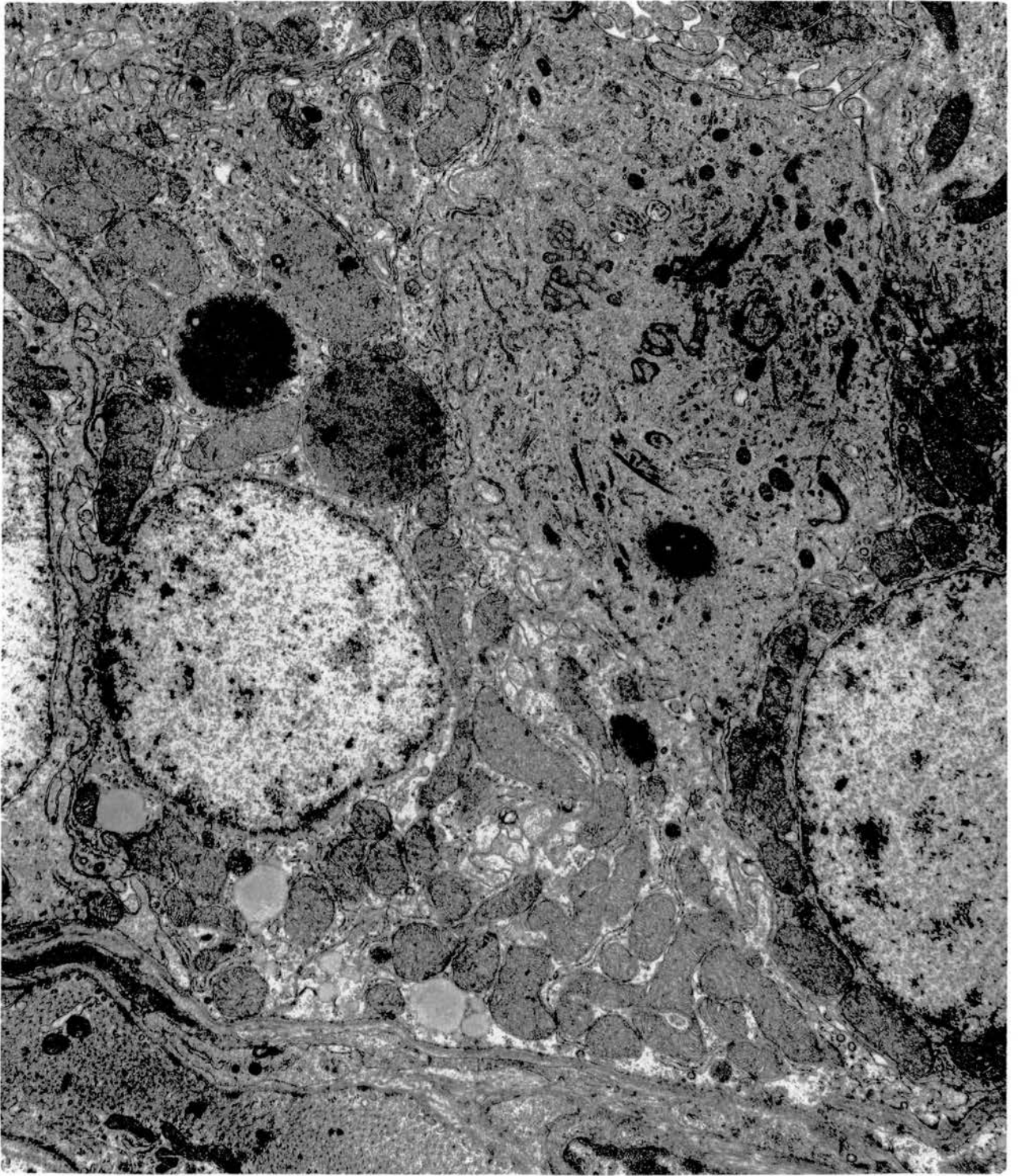


Fig. 125. Accumulation of lipid in the basal parts of non-ciliated type I cells together with the presence of large, irregular vacuolated bodies containing many dense granules. Non-vacuolated multi-granular or homogeneous bodies and free dense granules are also seen. x 7500.

Ductulus efferens.

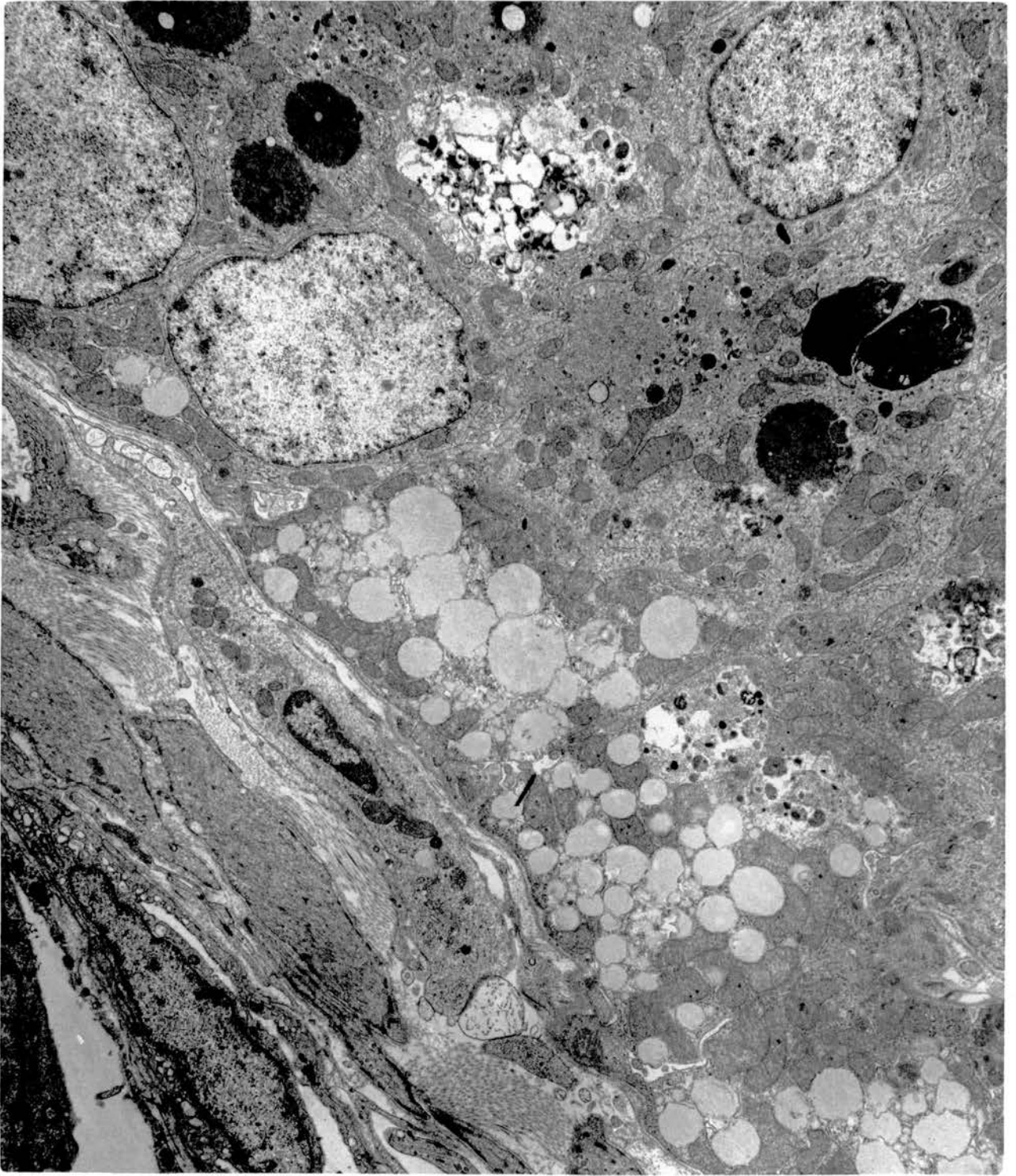
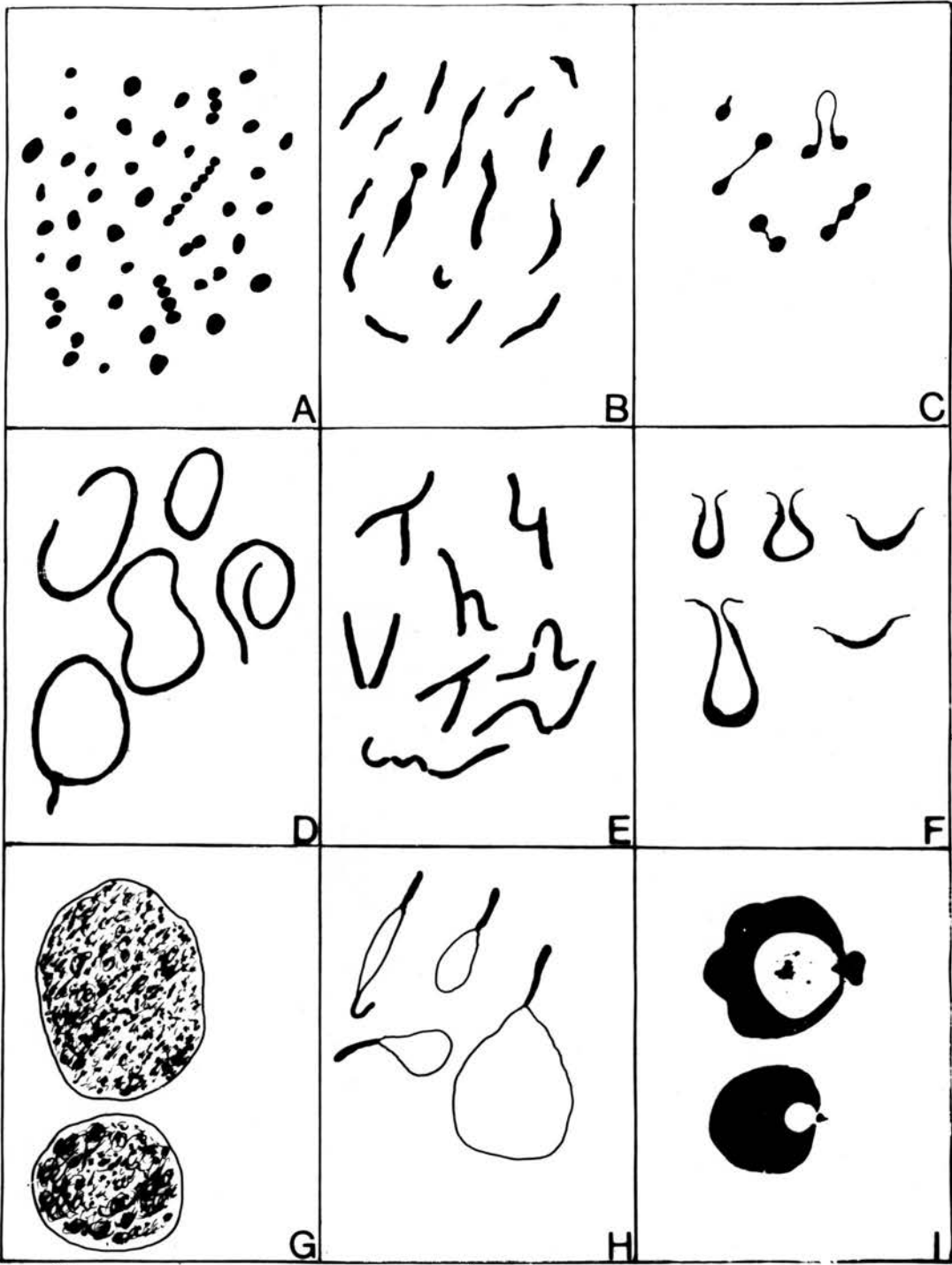


Fig. 126. Representations of the shapes of the worm-like structures in the apical cytoplasm of the non-ciliated type I cells. The relative proportions to the total population are as follows: A, 65%; B, 23%; C, 4%; D, 3%; E, 3%; F, 1%; G, 0.5%; H, 0.2%; I, 0.3%.





2µm

Fig. 127. Thin-walled electron-lucent vesicles seen among the worm-like structures of a non-ciliated type I cell. A flocculent material is contained in the lumen. x 18750.

Ductulus efferens.

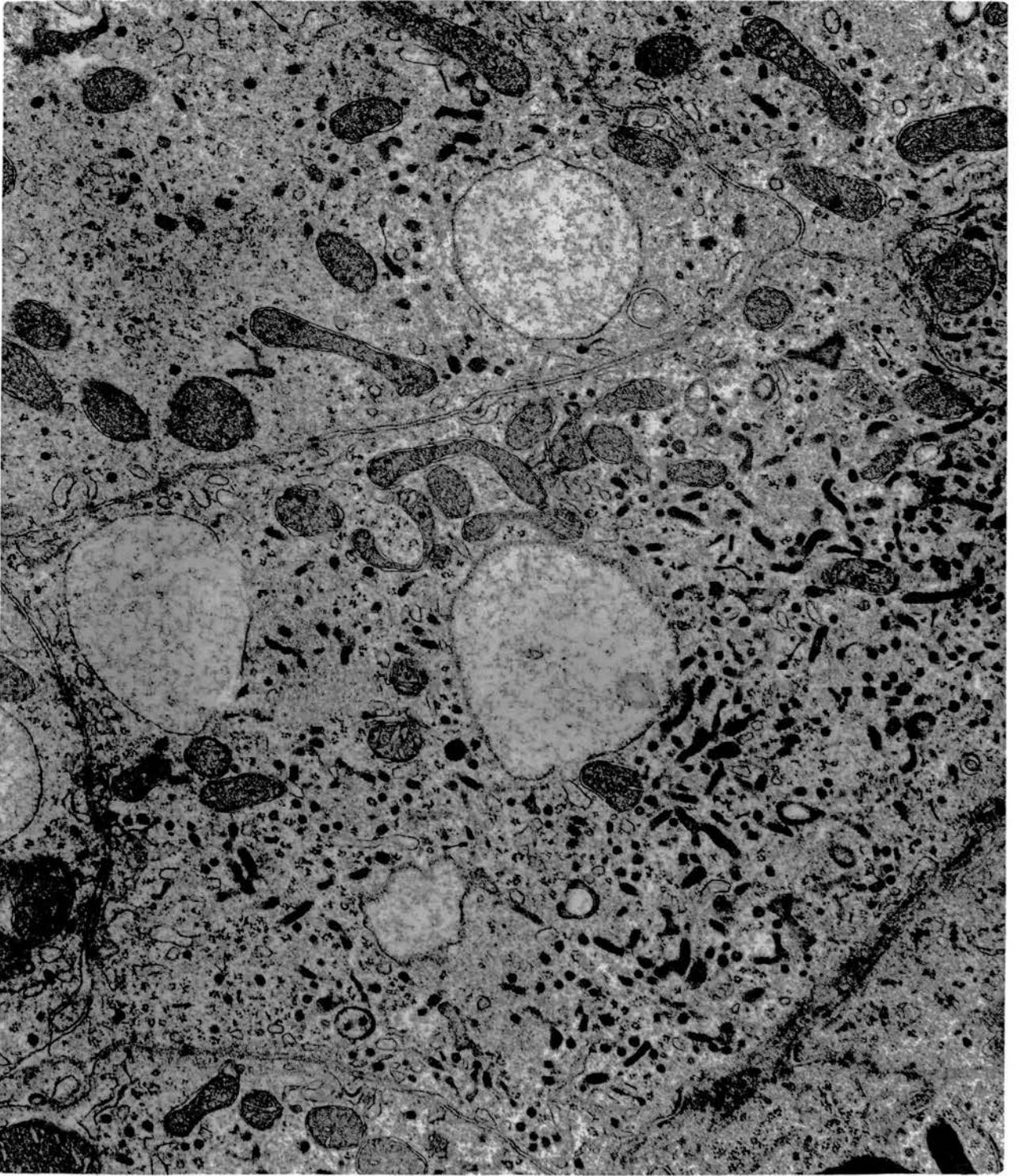


Fig. 128. A non-ciliated type I cell showing continuity of the cavity of a bilaminated thick-walled vesicle with that of an ill-defined, thin-walled one. A thin-walled vesicle containing flocculent material like that of figures 126G and 127, is also seen. x 37500.

Ductulus efferens of a ligated tract.

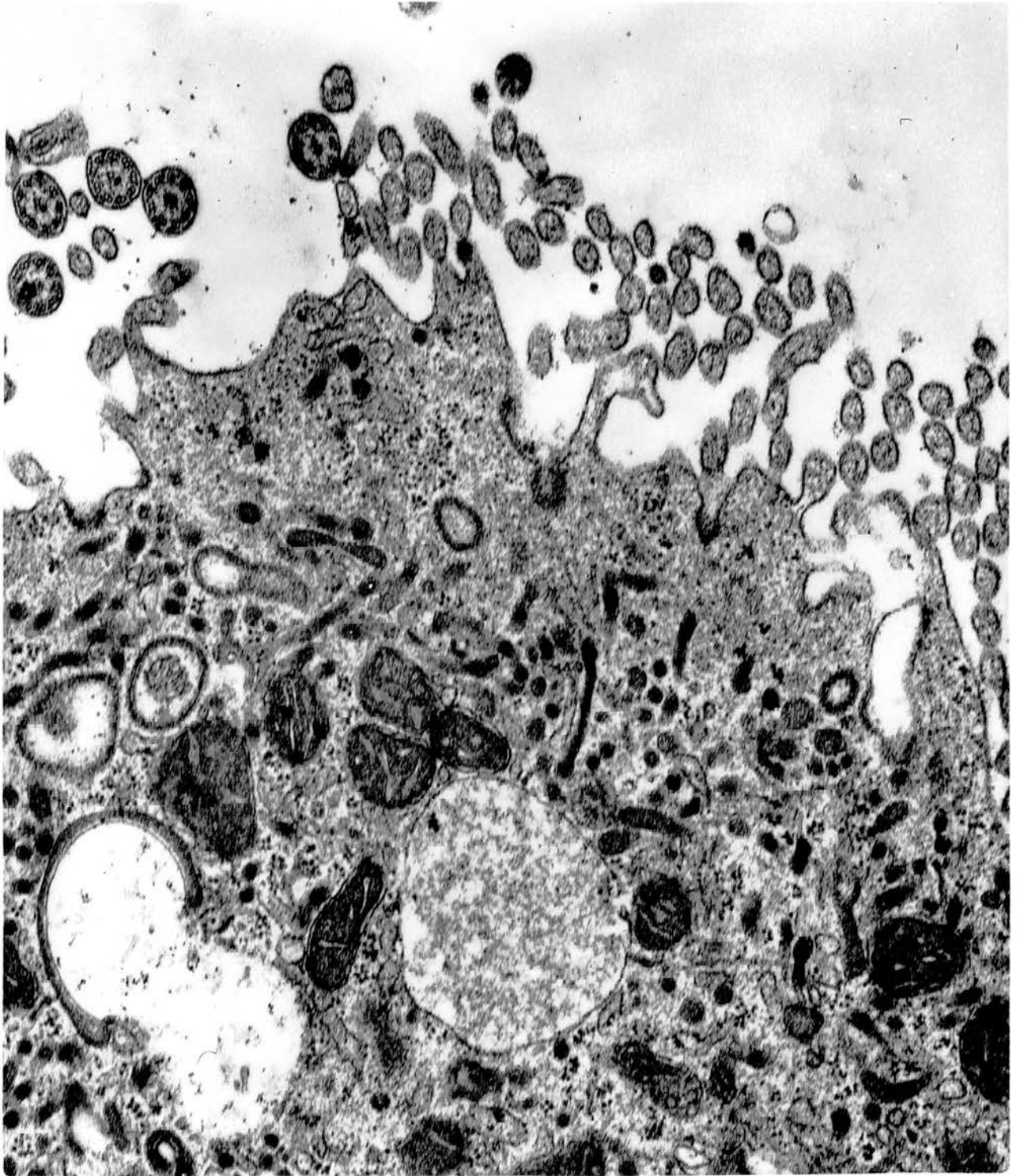


Fig. 129. A similar cell to that of figure 128 showing an abundance of thin-walled vesicles almost occluded with granular and floccular content and also incorporated multigranular bodies in their cavities. x 25000.

Ductulus efferens of a ligated tract.

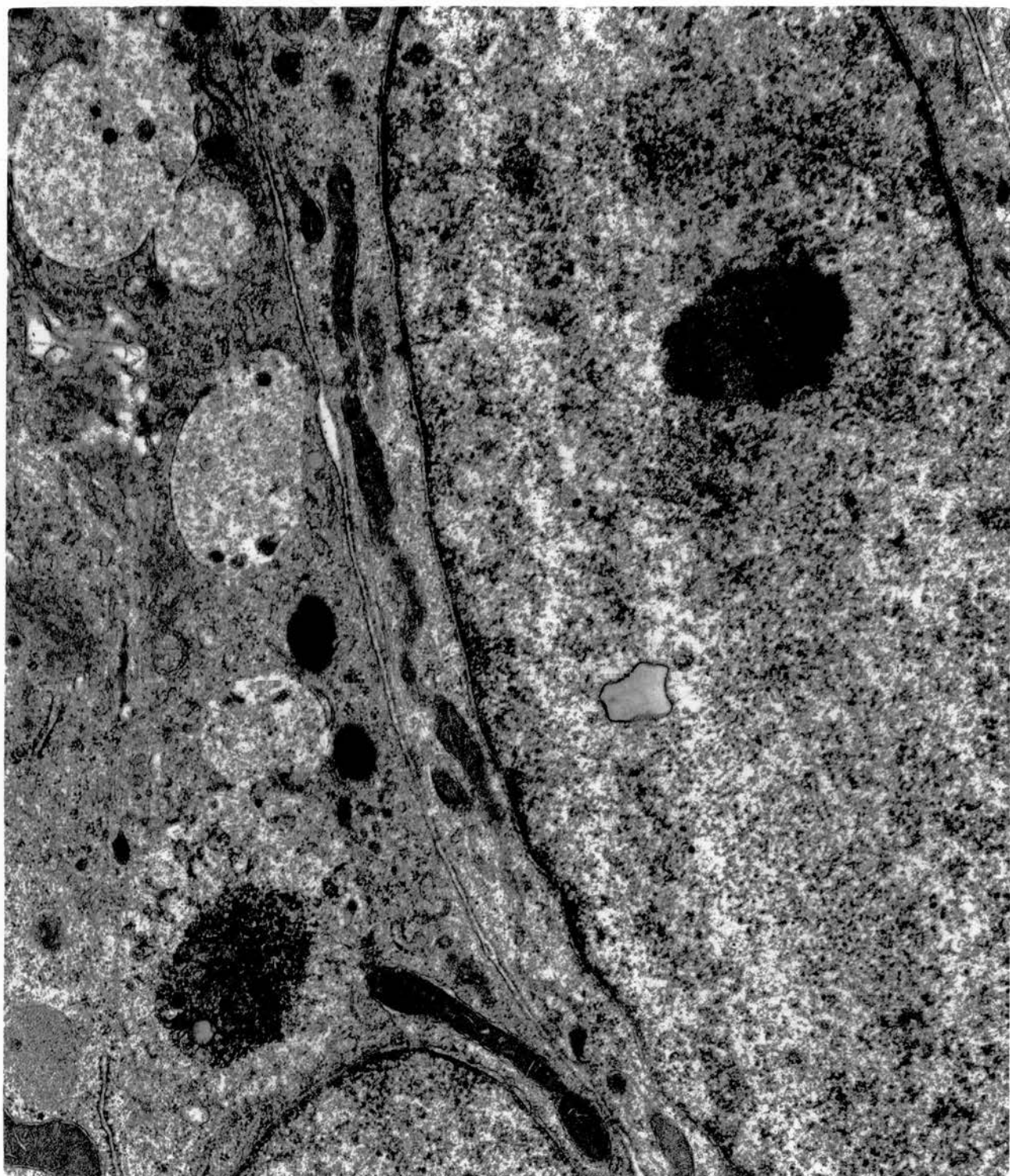


Fig. 130. Schematic representation of the fine structure of a non-ciliated type II cell. M, microvilli; BL, basal lamina; J, junctional complex; N, nucleus; G, Golgi complex; m, mitochondria; ER, rough and transitional endoplasmic reticulum; B, electron-dense bodies; L, lipid.



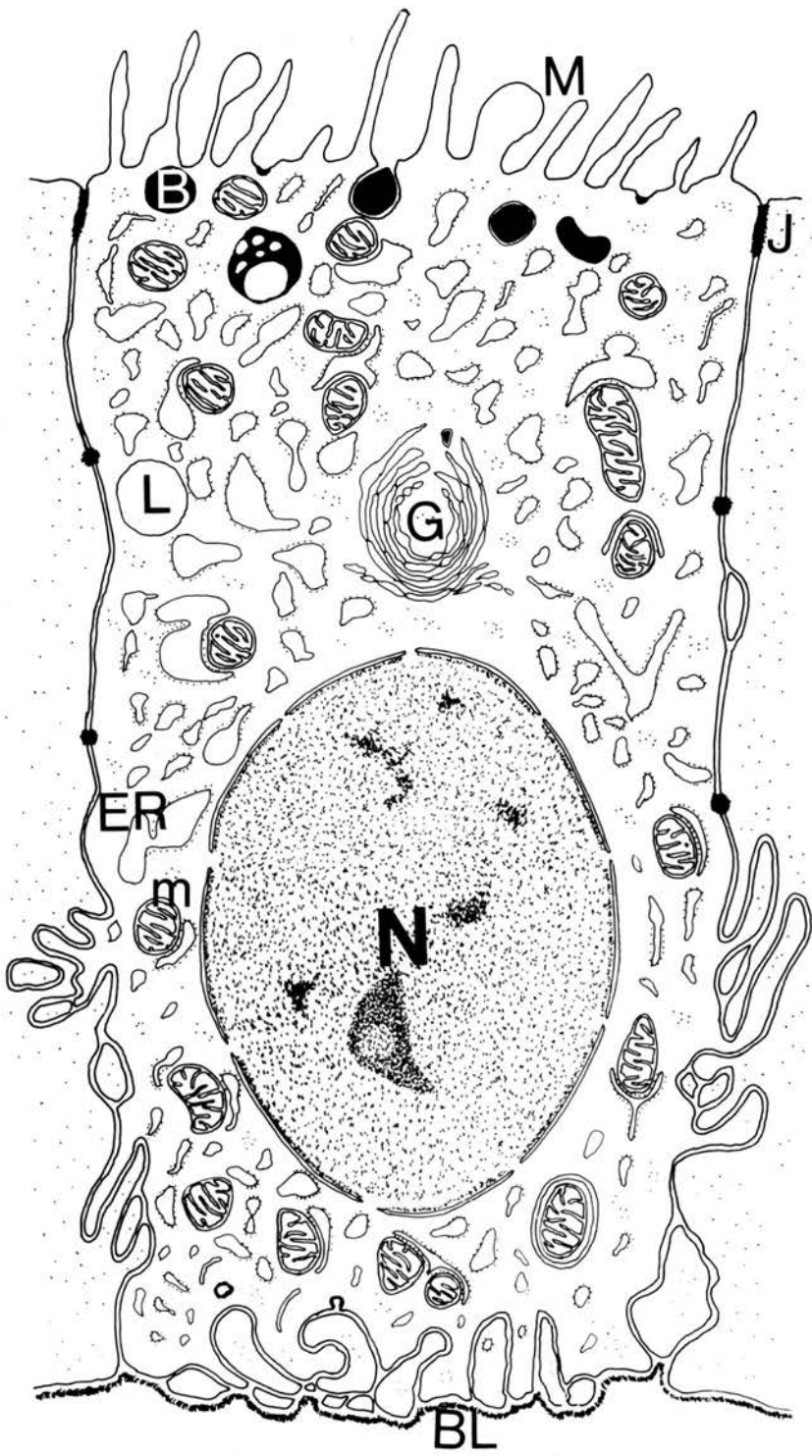


Fig. 131. Non-ciliated type II cell. The luminal border carries long and slender microvilli. The opposed lateral plasma membranes are attached by junctional complexes located towards the luminal tips. There are a number of membrane-limited dense granules in the apical cytoplasm; some are continuous with the surface membrane and others lie free in the lumen. Centrioles are seen in the apical cytoplasm of two of the cells. x 25000.

Middle segment of ductus deferens.

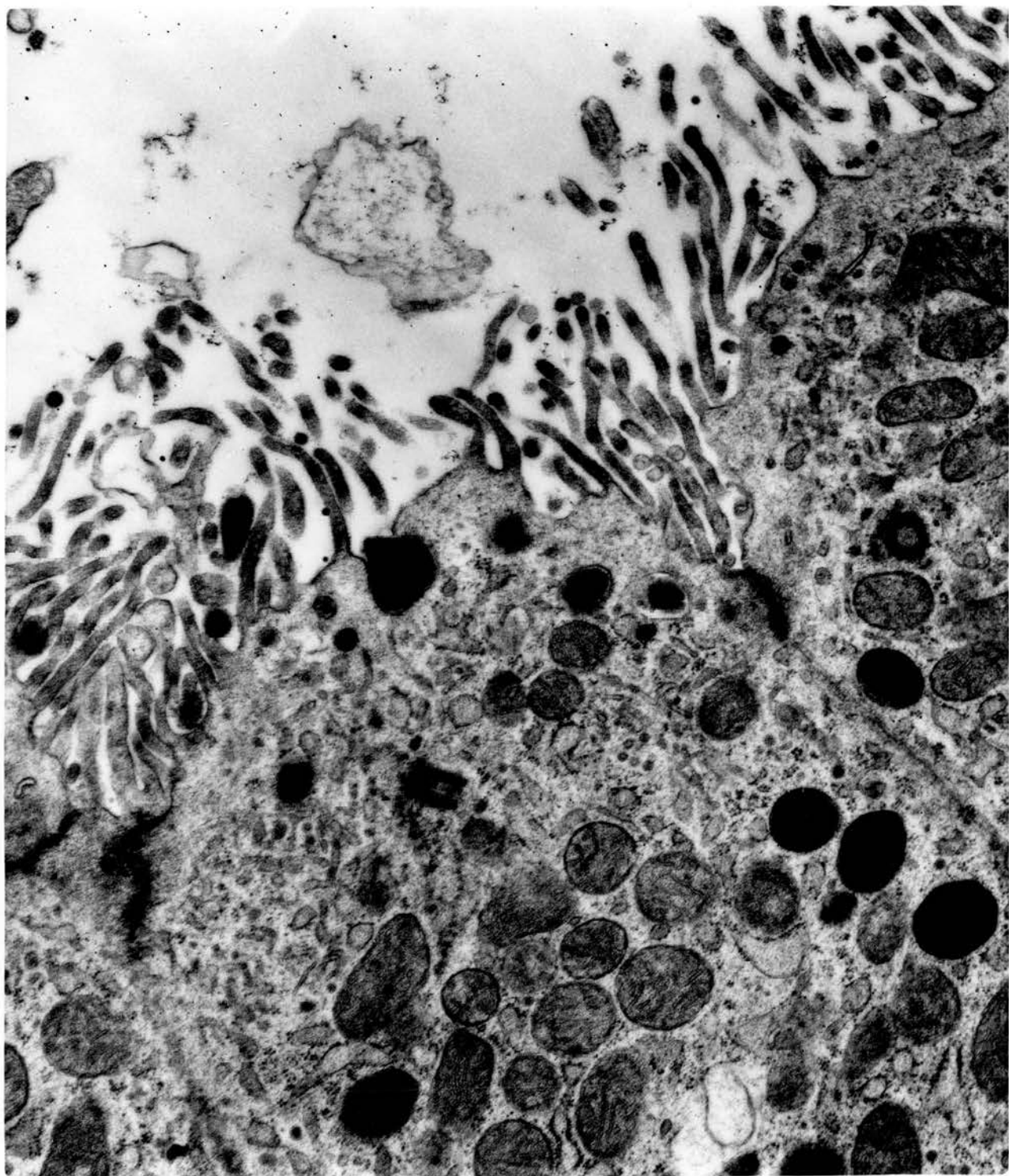


Fig. 132. Non-ciliated type II cells. The apical microvilli vary widely in shape and size. A rudimentary cilium is also seen on the border. The lateral plasma membranes run fairly straight for the luminal half of the cell; their attachment to those of adjacent cells by junctional complexes is demonstrable. Rough and transitional endoplasmic reticulum is a characteristic feature of this cell type; note the relation of these elements to the scattered mitochondria. x 12500.

Cranial segment of ductus deferens.

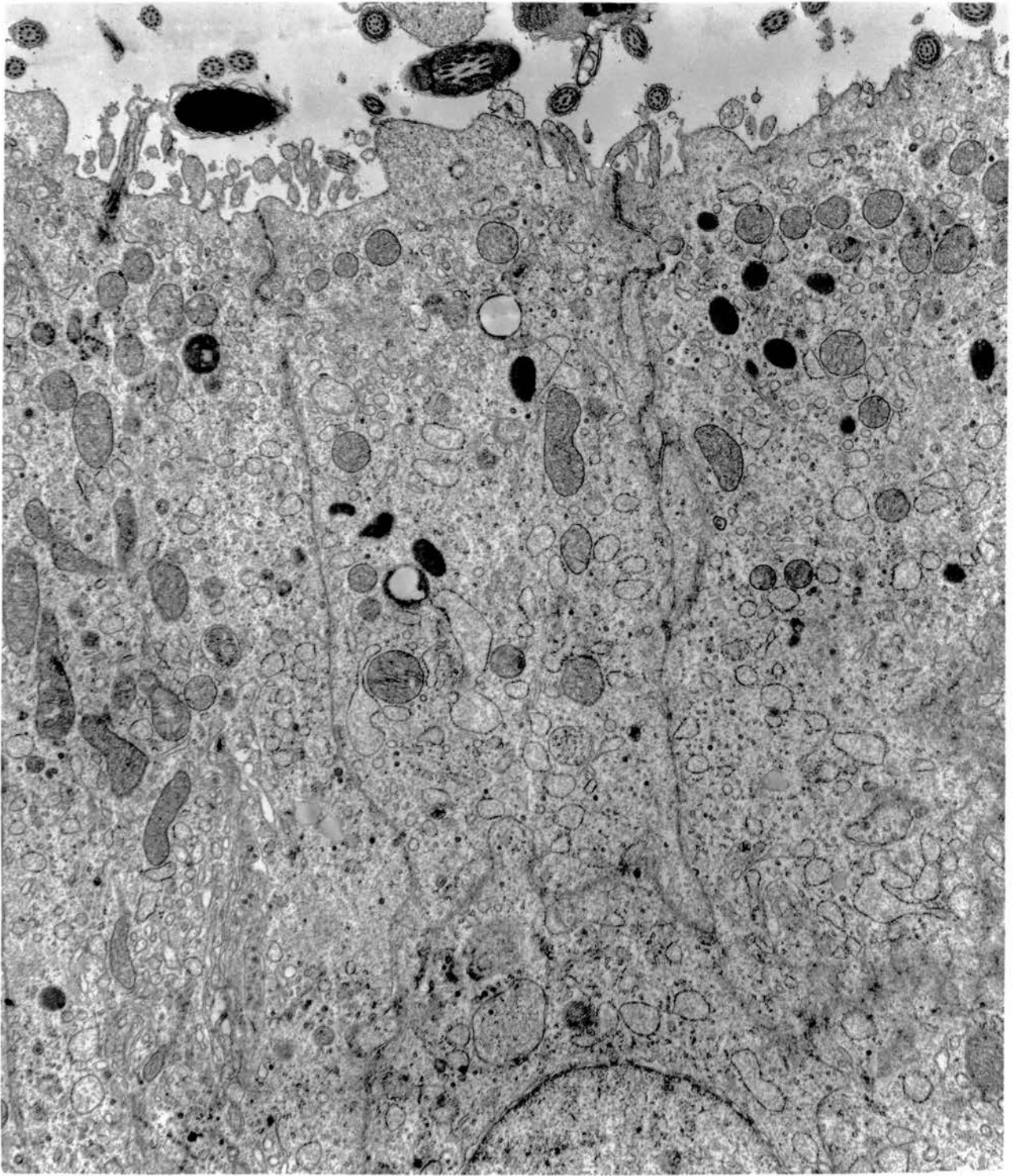


Fig. 133. There is an extensive folding of the basal plasma membrane in the basal parts of the lateral plasma membranes of the non-ciliated type II cells. x 25000.

Ductus epididymidis.

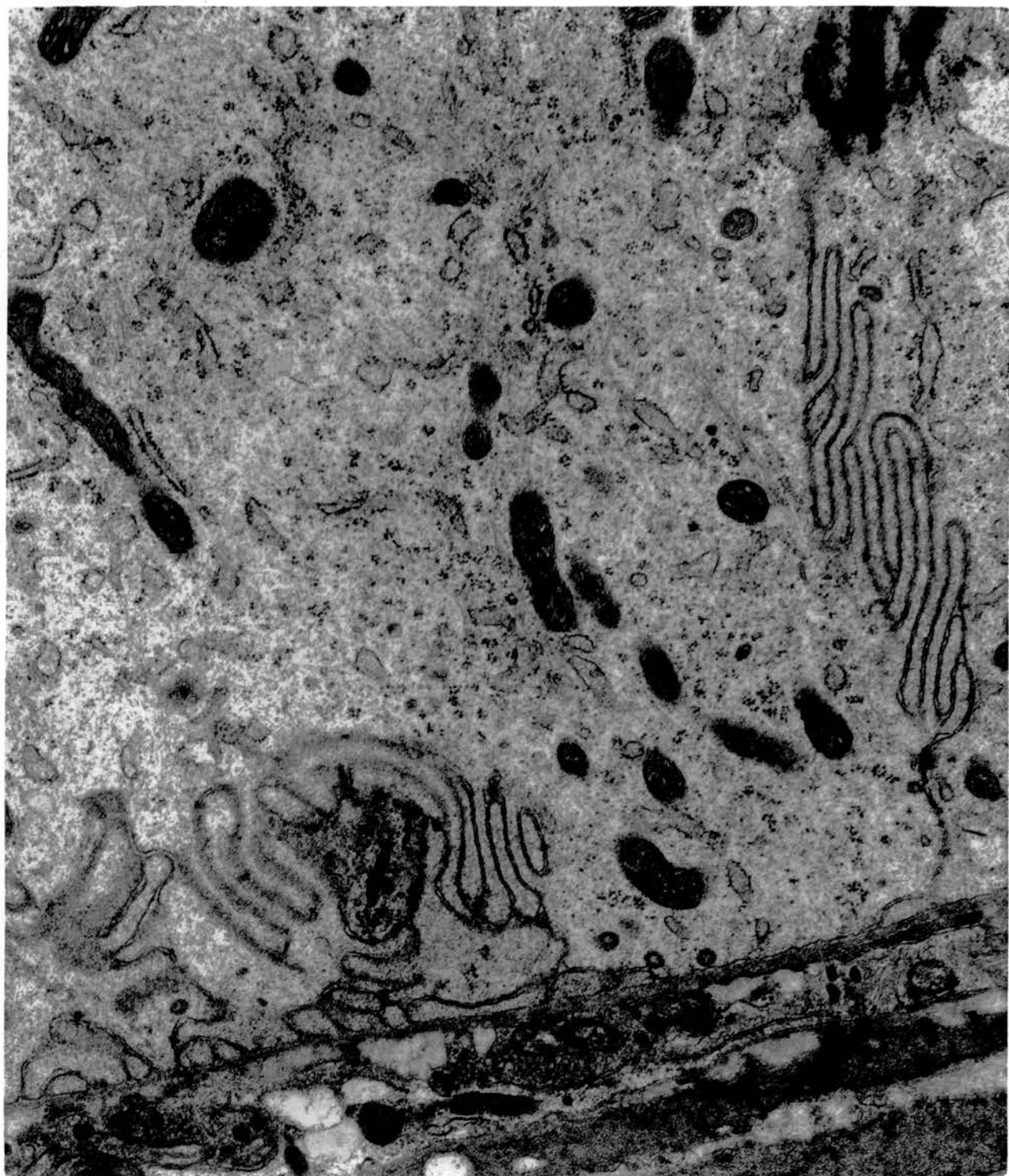


Fig. 134. Non-ciliated type II cell is distinguished from the adjacent basal cell (top) by lower density of its cytoplasm. Note the basal interdigitations of type II cells and the fuzzy vacuoles and caveoli associated with its membranes. x 25000.

Cranial segment of ductus deferens.



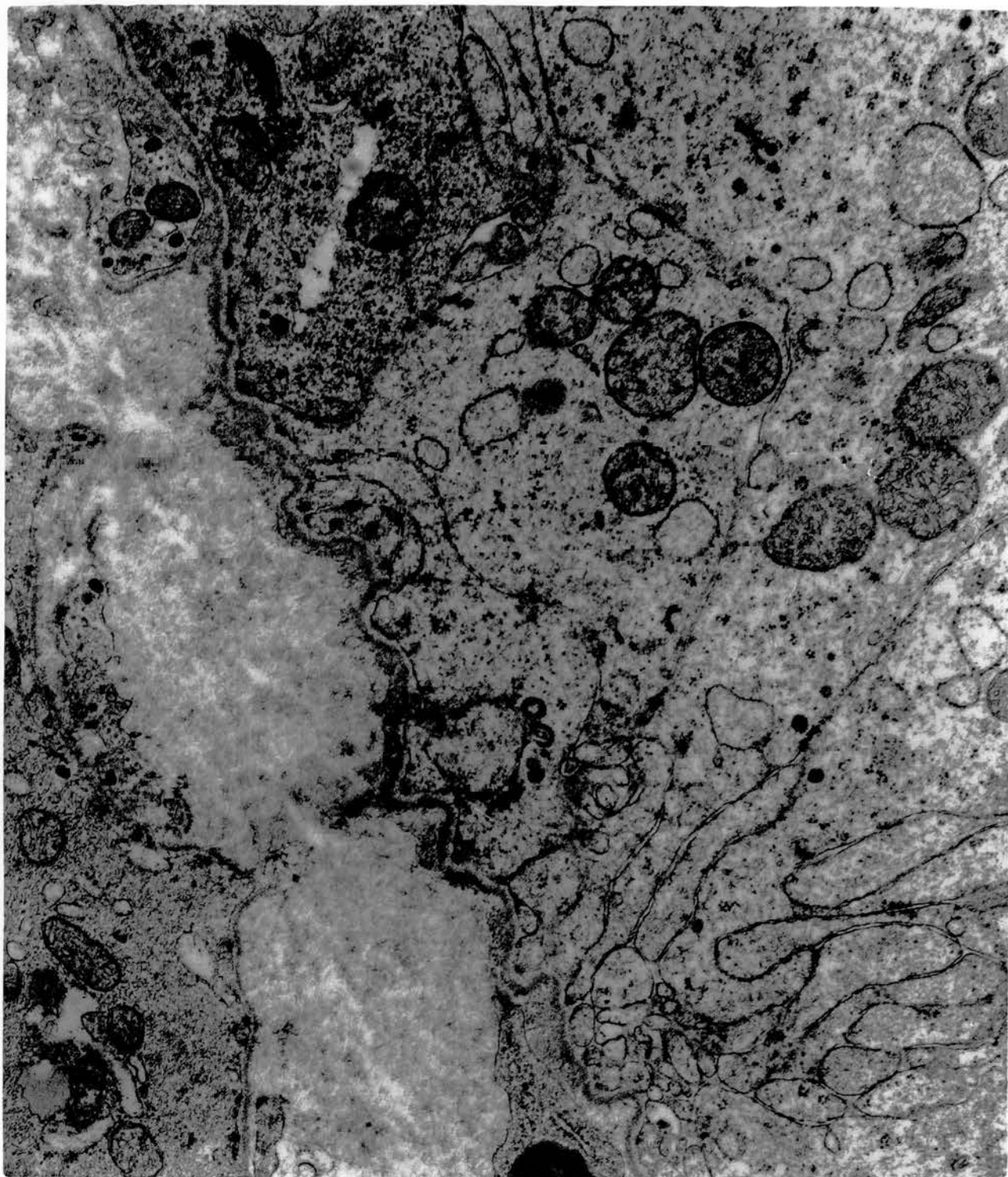


Fig. 135. A number of non-ciliated type II cells showing a partial section of the large nucleus and its contained nucleolus (left). Stacks of fine fibrils are loosely scattered in the cytoplasm (centre). x 25000.

Caudal segment of ductus deferens.

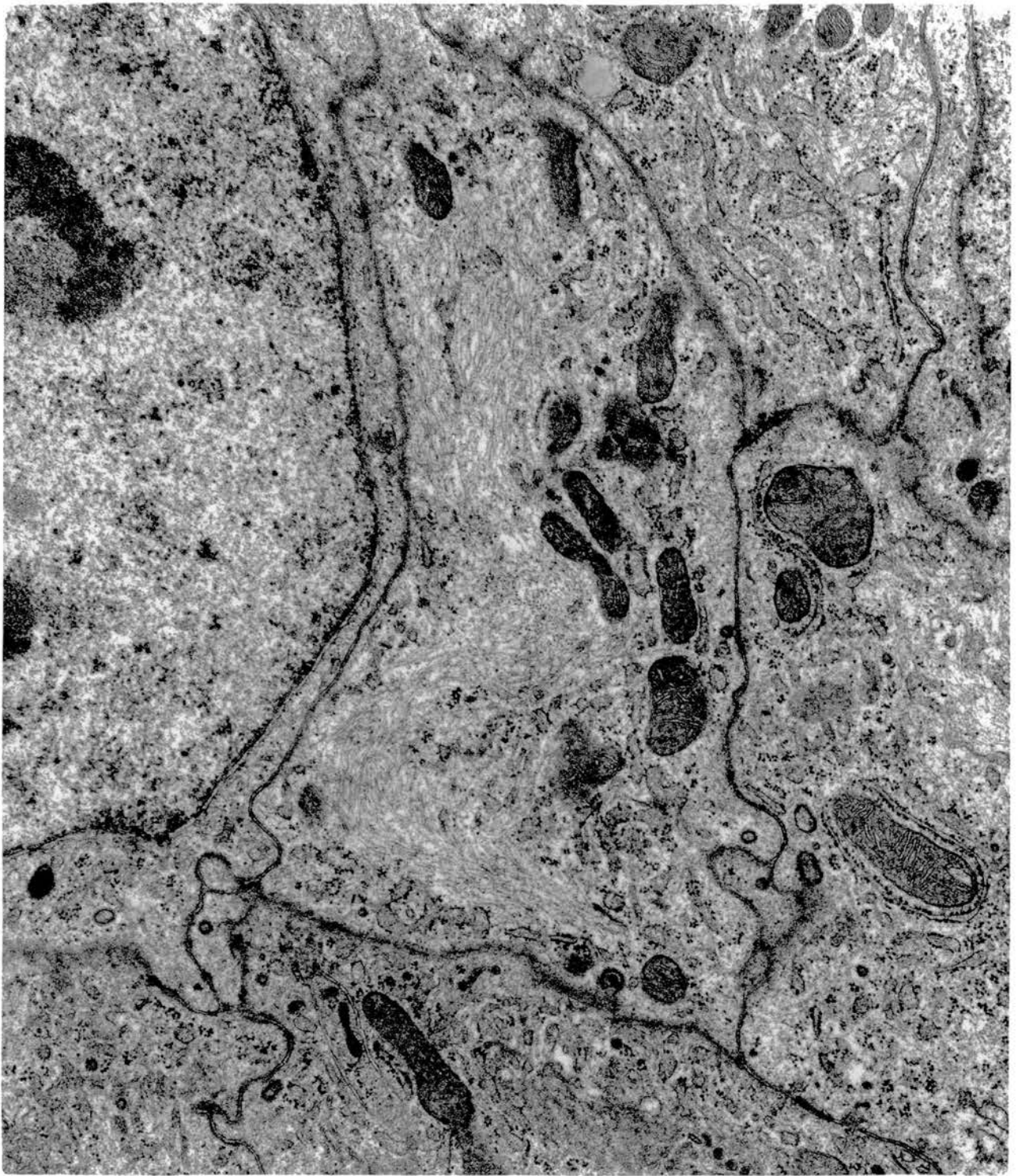


Fig. 136. Non-ciliated type II cells. The Golgi complex appearing in the form of whorled lamellae. An abundance of rough and transitional endoplasmic reticulum is seen. Note its relation to neighbouring mitochondria. x 25000.

Cranial segment of ductus deferens.

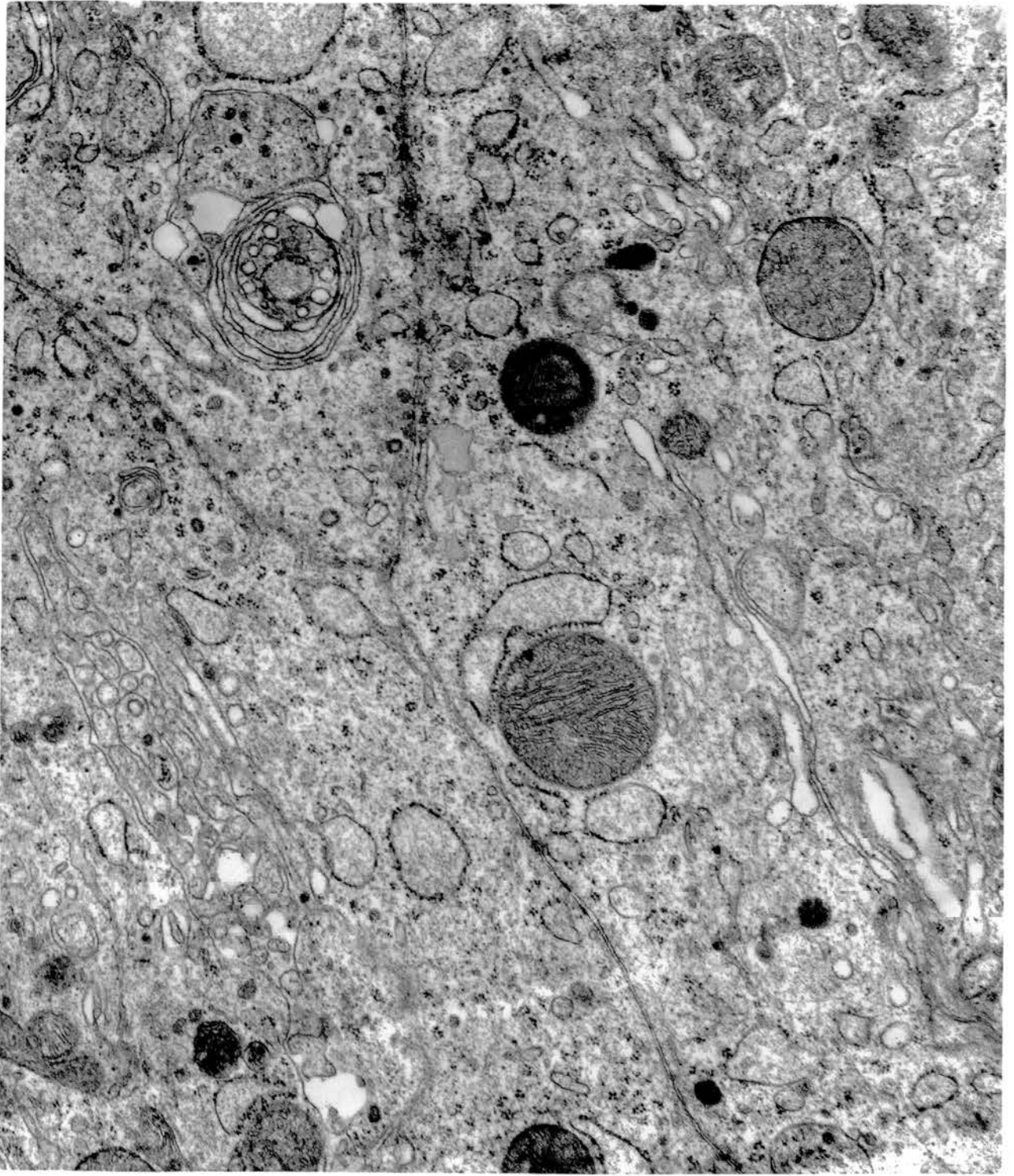


Fig. 137. Profiles of undistended RER in a non-ciliated type II cell closely associated with large mitochondria containing dense granules. x 37500.

Middle segment of ductus deferens.

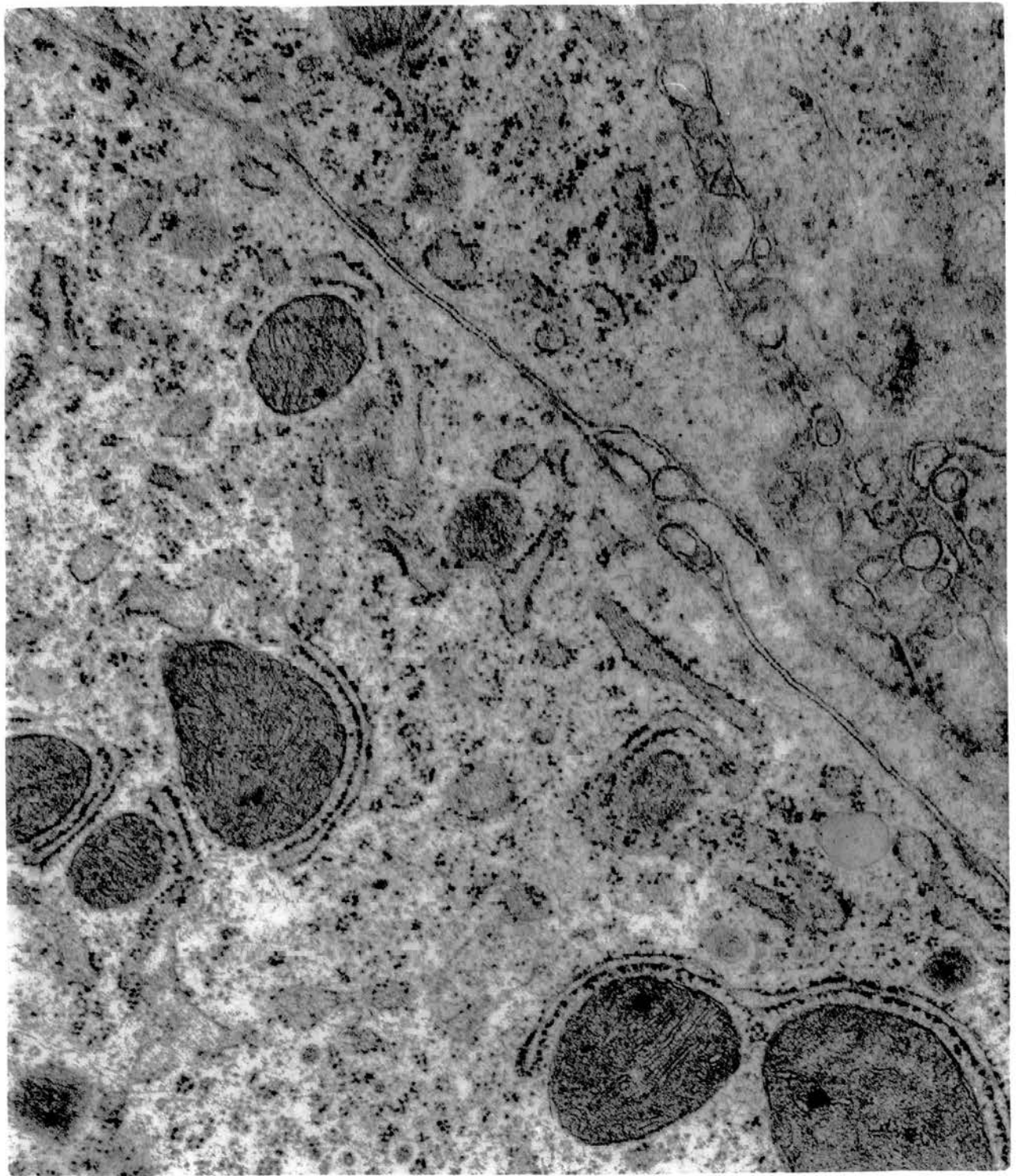


Fig. 138. Electron-dense bodies are commonly seen in the cytoplasm of a non-ciliated type II cell. Some of these appear vacuolated. They may lie close together, and some of the smallest forms appear to share a common limiting membrane (arrow). x 25000.

Cranial segment of ductus deferens.



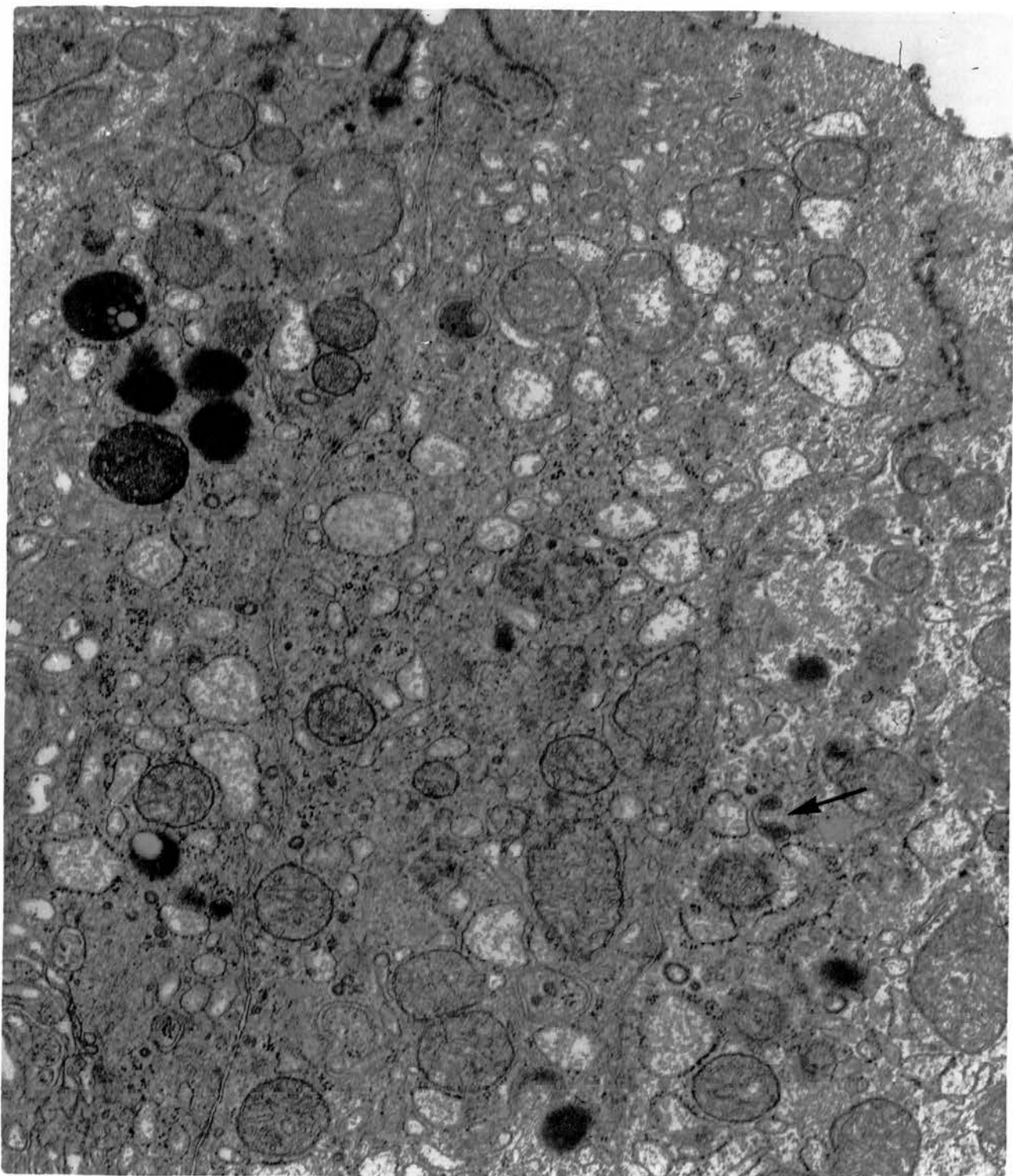


Fig. 139. Many of the electron-dense bodies seen in the cytoplasm of the non-ciliated type II cells contain clear areas; coalescence may have caused the margination of the dense material. Tiny granules which are more dense are scattered in the matrices of these bodies. A small dense granule arising within the Golgi cisternae is also seen (arrow). x 18750.

Cranial segment of ductus deferens.

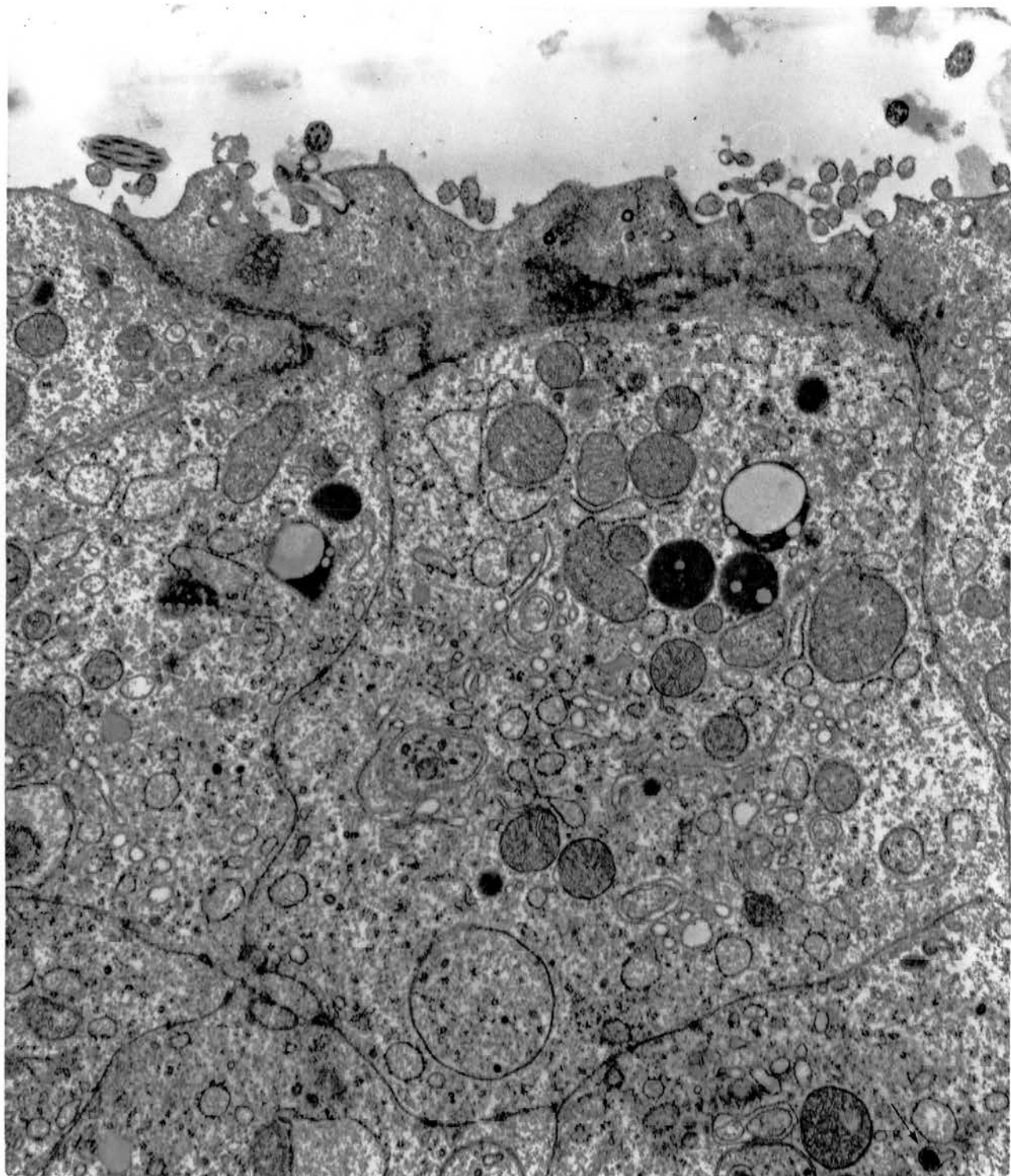


Fig. 140. Non-ciliated type II cell showing part of a nucleus, distended endoplasmic reticulum and homogeneous, dense granules, which lie within the Golgi cisternae and are seen independently in the cytoplasm. x 25000.

Cranial segment of ductus deferens.

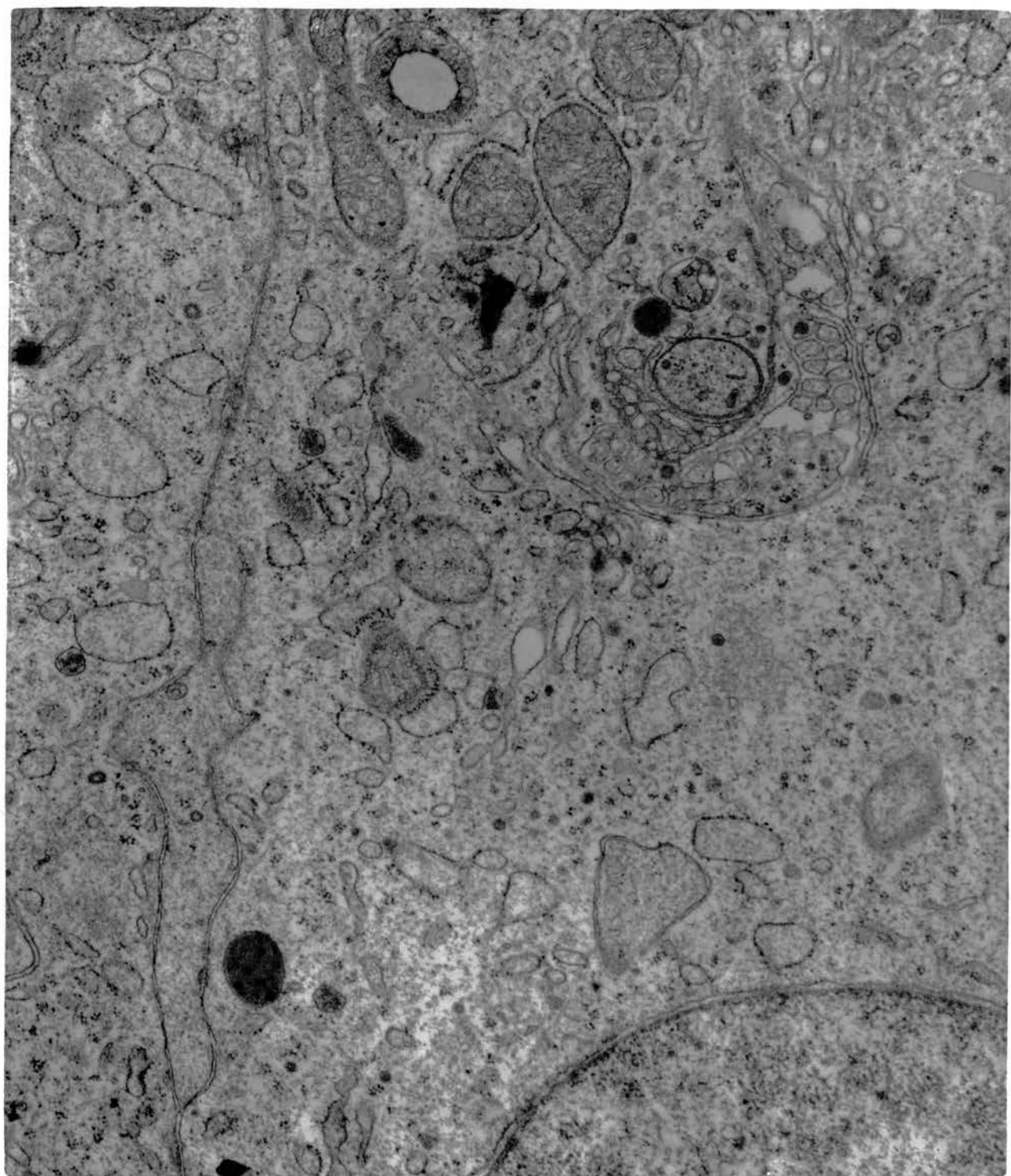


Fig. 141. Non-ciliated type II cells. A Golgi complex is seen to the left, and lying next to it is a small autophagic vacuole bound by double membrane. A large multiple form of autophagic vacuoles lies to the right. Note the abundance of distended cisternae of transitional and rough endoplasmic reticulum. x 25000.

Cranial segment of ductus deferens.

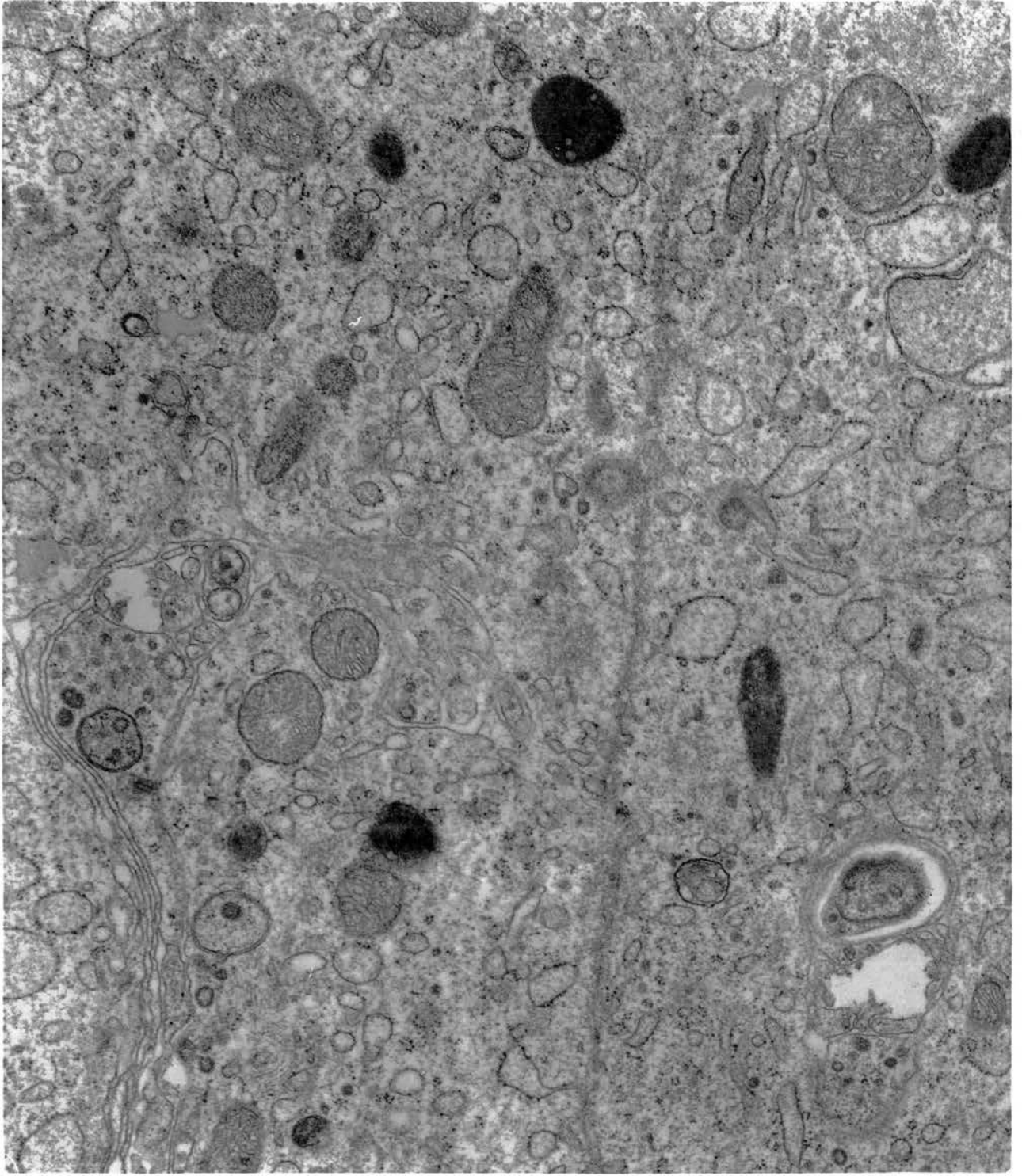


Fig. 142. Non-ciliated type II cells. Centrioles are present in the supra-nuclear region of the cytoplasm. Other structures seen are elements of rough and transitional endoplasmic reticulum, mitochondria, and membrane-bound dense granules which may or may not be vacuolated. Small dense granules are also present. x 37500.

Cranial segment of ductus deferens.



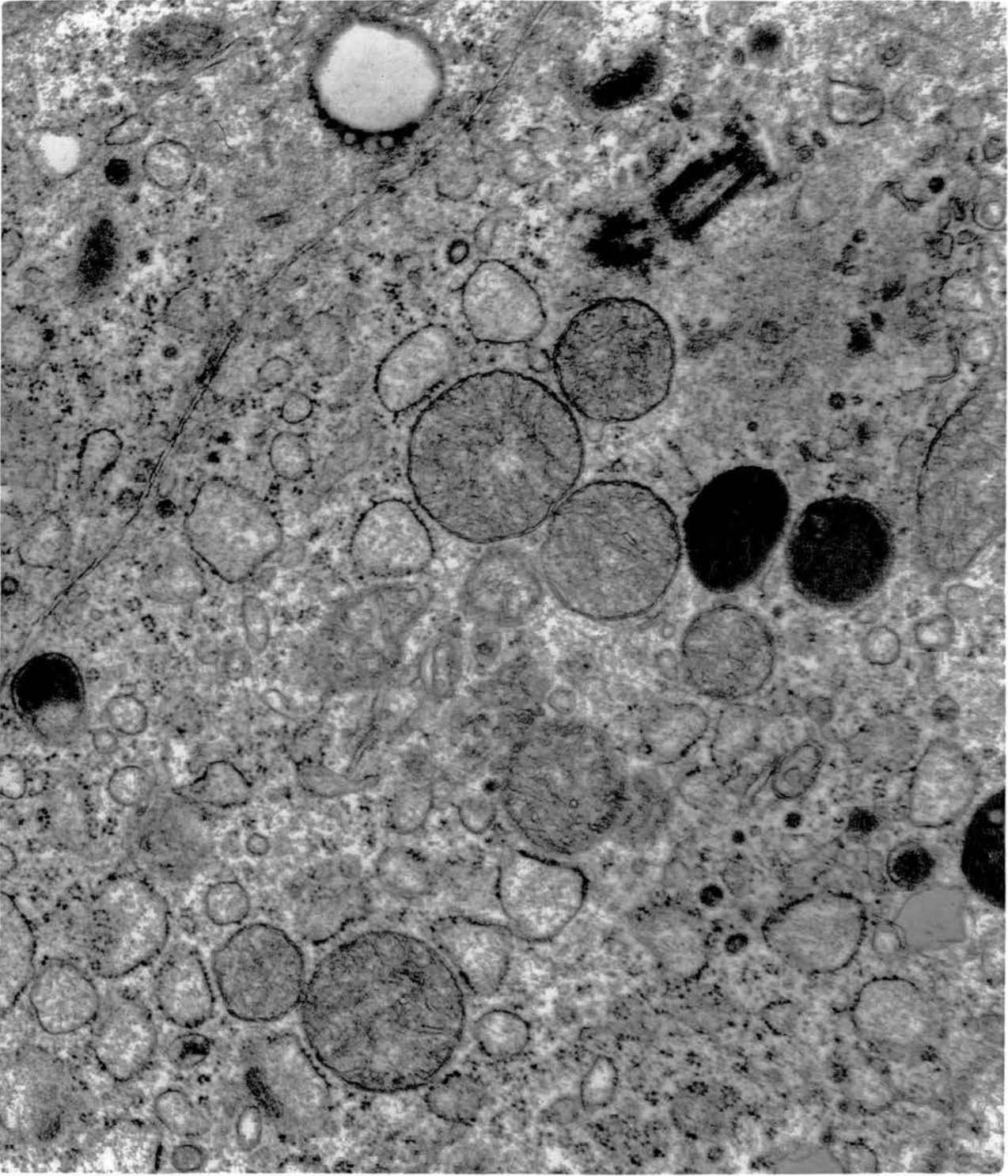


Fig. 143. Dark cells possessing the same structural features of the non-ciliated type II cells are occasionally observed. Compare the cell in the centre with its neighbours.  
x 12500.

Middle segment of ductus deferens.

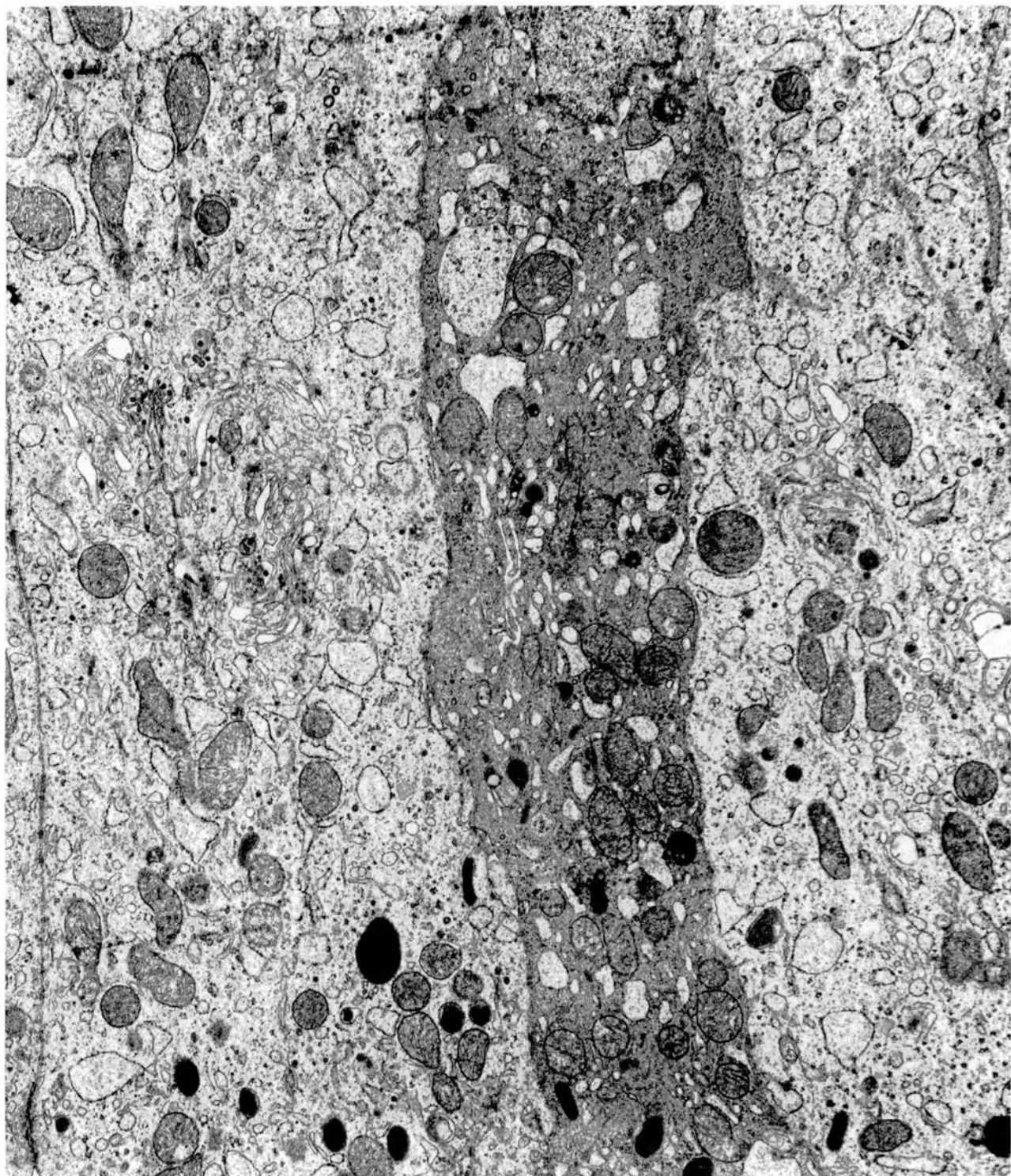


Fig. 144. Diagrammatic representation of the fine structure of a ciliated cell. M, microvilli; C, cilia; J, junctional complex; N, nucleus; G, Golgi complex; RE, rough endoplasmic reticulum; m, mitochondria; F, fibrils; V, vacuoles; B, electron-dense body; H, heterogeneous body; L, lipid.

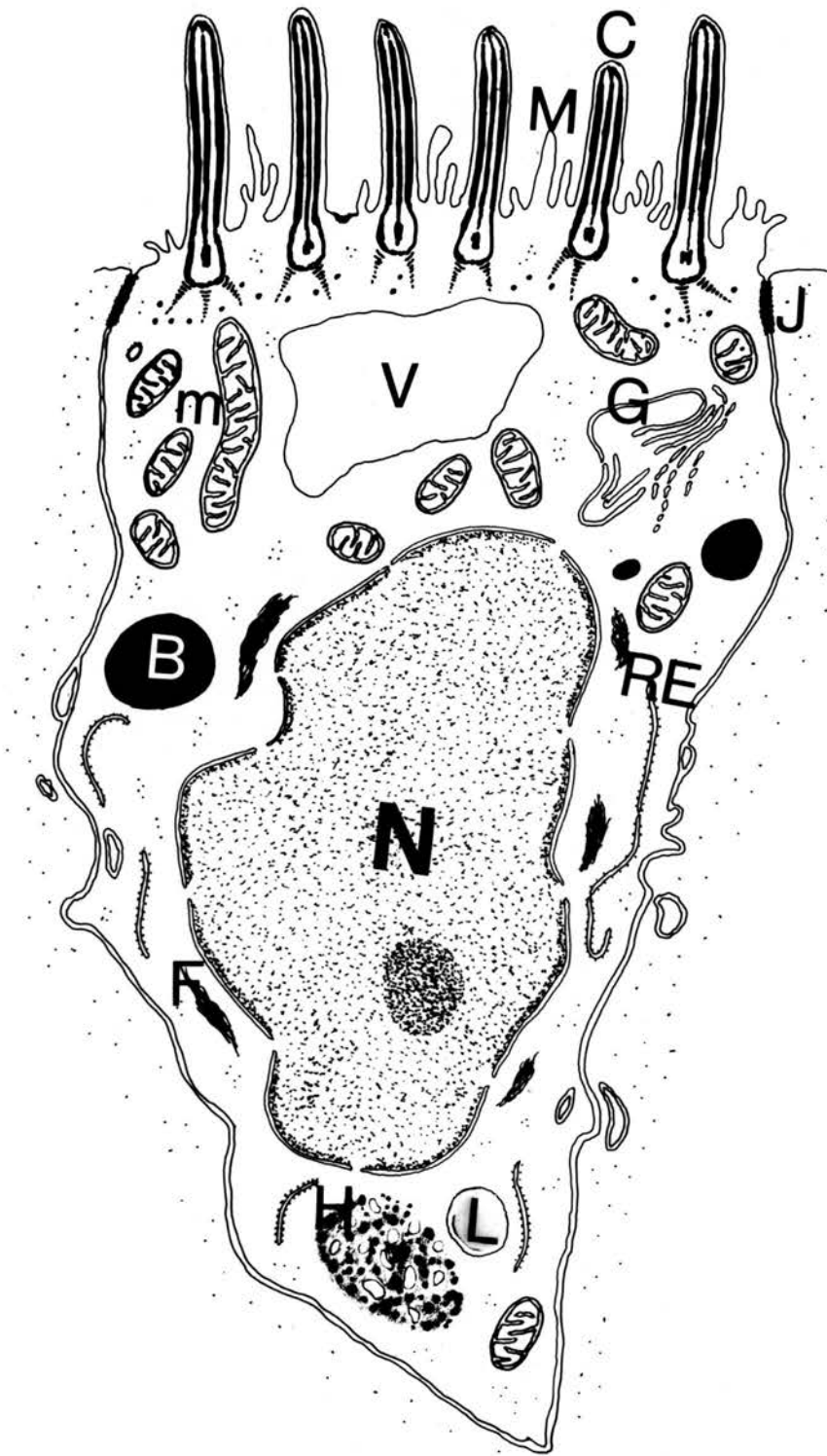


Fig. 145. A ciliated cell attached by junctional complexes to the adjacent non-ciliated type I cell. Its cytoplasmic matrix is comparatively denser than that of the type I cell and typical motile cilia are seen on the luminal border. Note the cross-striated rootlets and the dense granules scattered around them. x 25000.

Ductulus efferens.

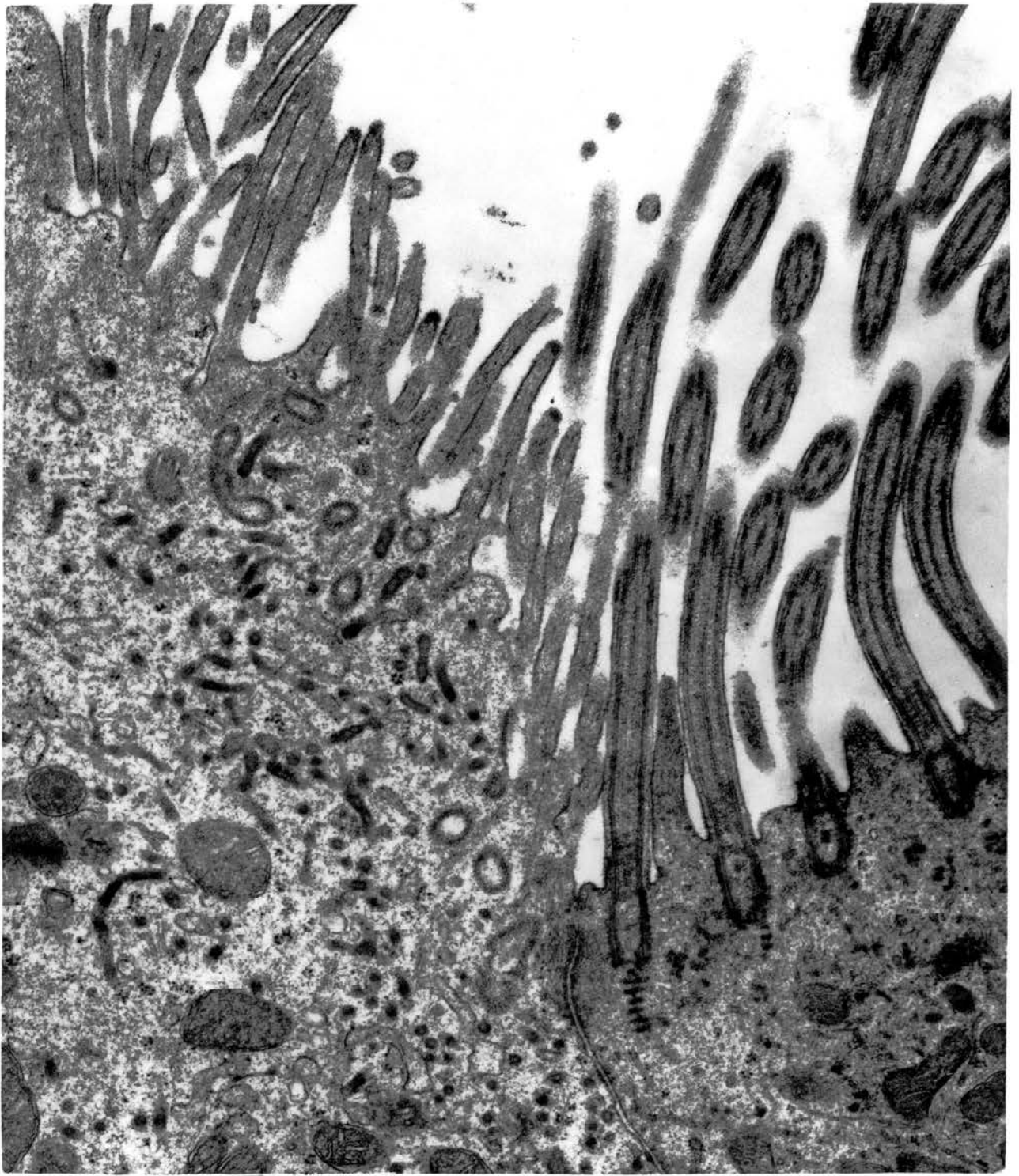


Fig. 146. Ciliated cells. The nuclei are slightly irregular and chromatin content evenly distributed. Mitochondria are usually concentrated in the supra-nuclear region where a small Golgi complex is also located. Bundles of fibrous material run close to the nuclear membrane. Part of a multigranular heterogeneous body is also present. x12500.

Narrow connecting ductule.



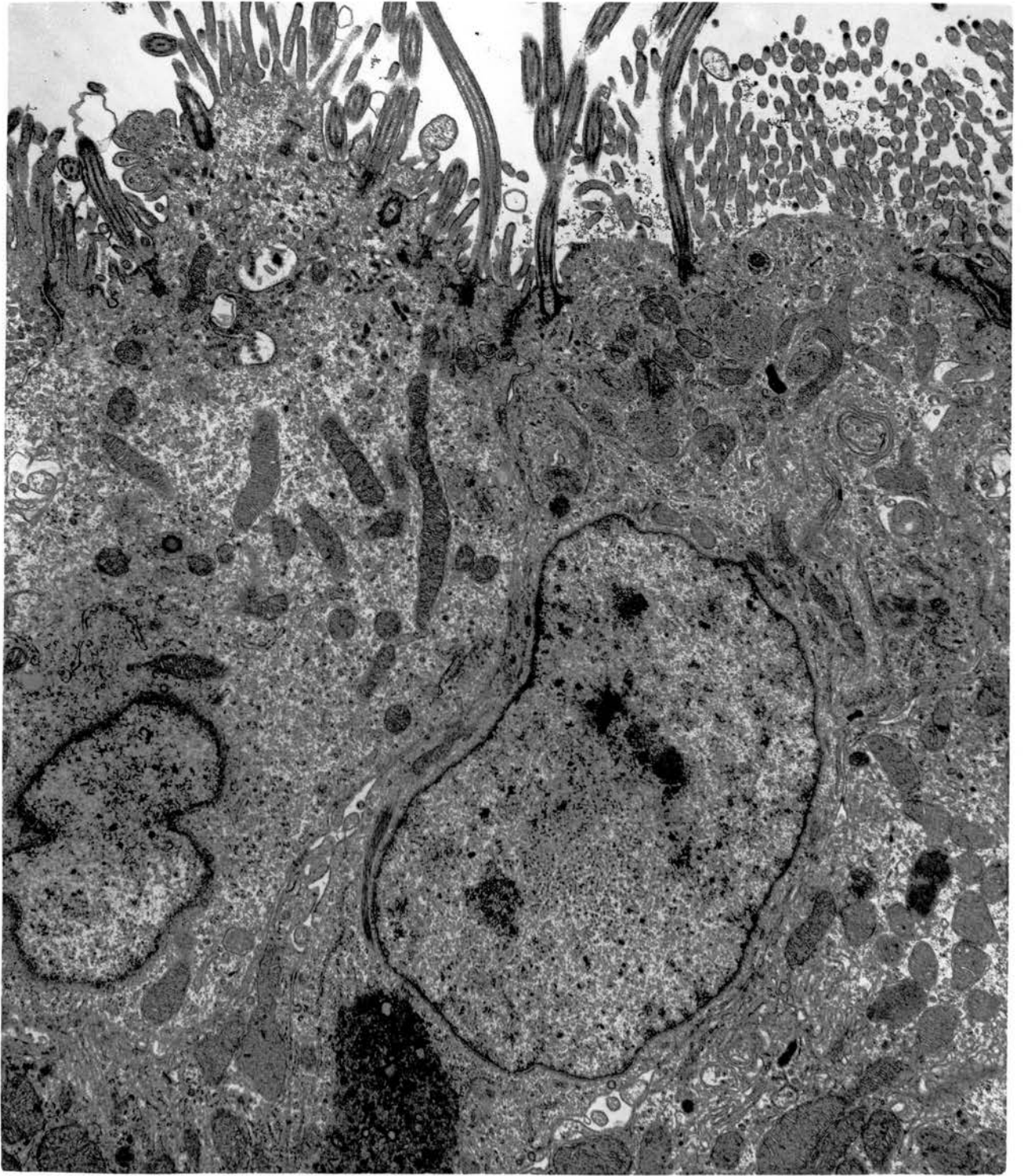


Fig. 147. Golgi complex of a ciliated cell (upper left) consists of closely packed cisternae in some form of a concentric arrangement. Adjacent parts of cytoplasm are of non-ciliated type I cells. Note the difference in size of mitochondria in the two types of cells. x 25000.

Ductulus efferens.

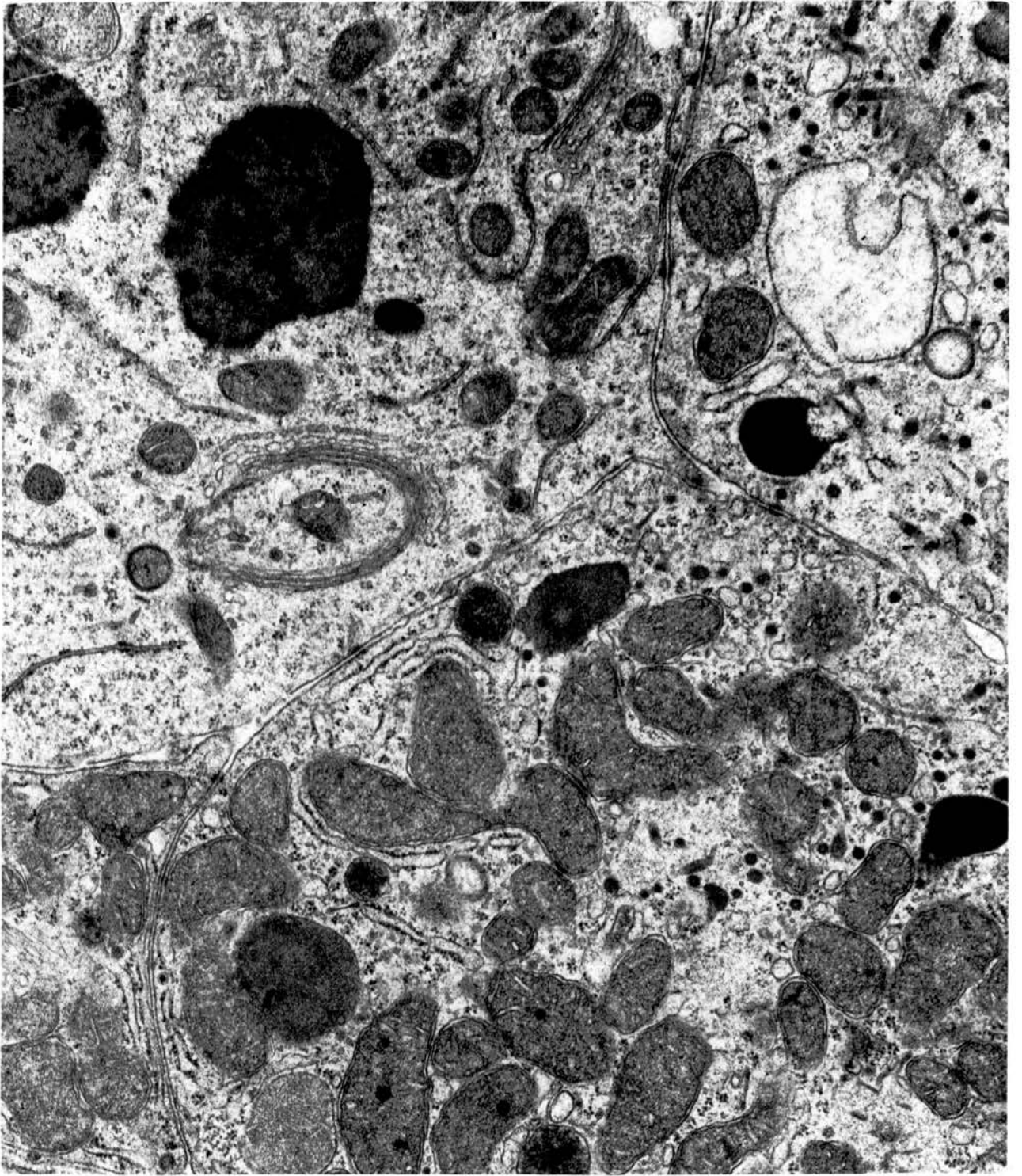


Fig. 148. Long twisting filaments of RER seen in the centre belong to a ciliated cell wedged between two non-ciliated type I cells. x 18750.

*Ductulus efferens.*

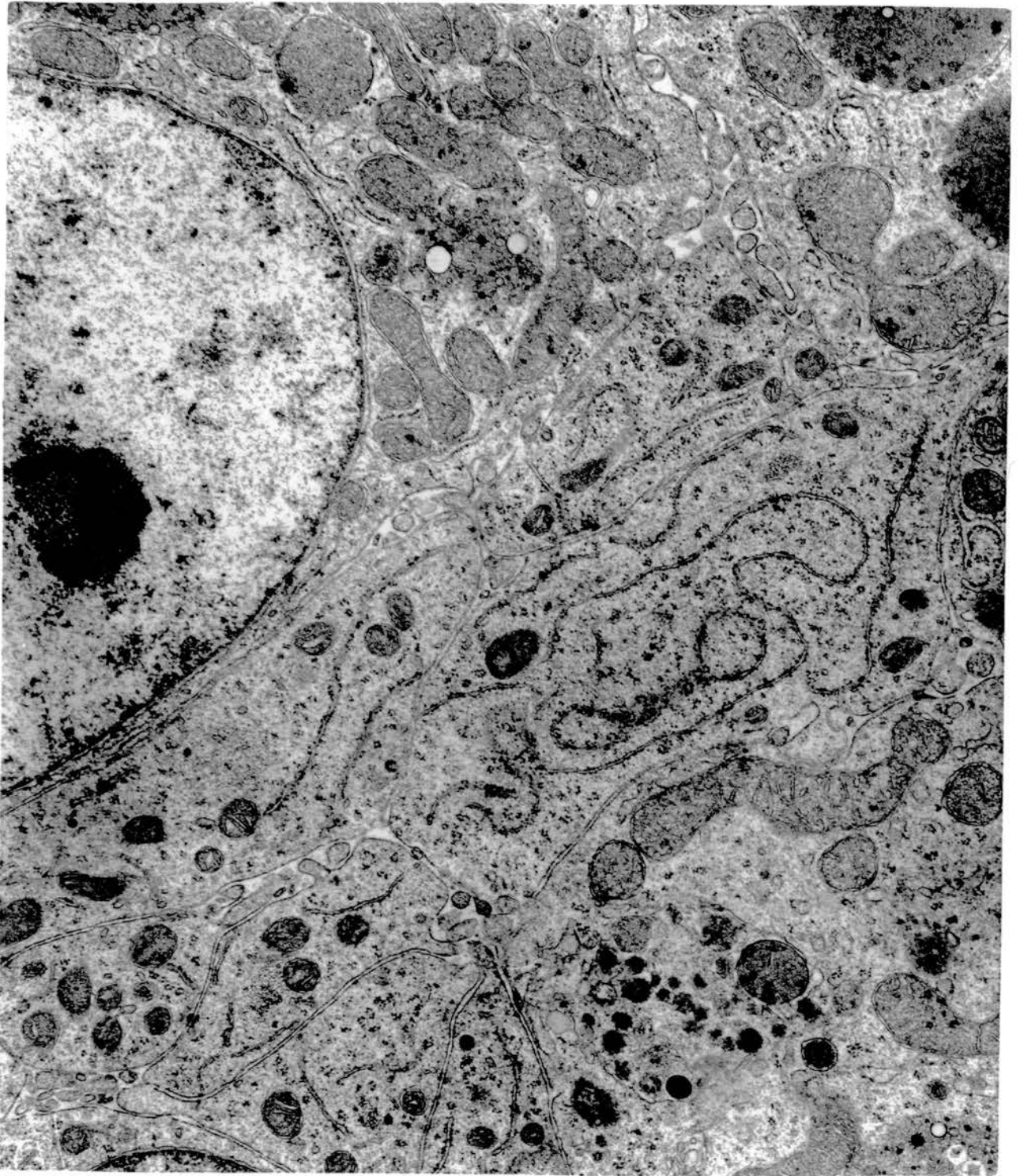


Fig. 149. Ciliated cells alternating with non-ciliated type I cells. Large vacuolar spaces containing an electron-lucent material are found in the apical cytoplasm of the former. Cytoplasmic buds protrude into the cavity of these vacuoles. Small dense granules and large electron-dense bodies consisting of fine granular material are seen in all cells.  
x 12500.

Ductulus efferens.

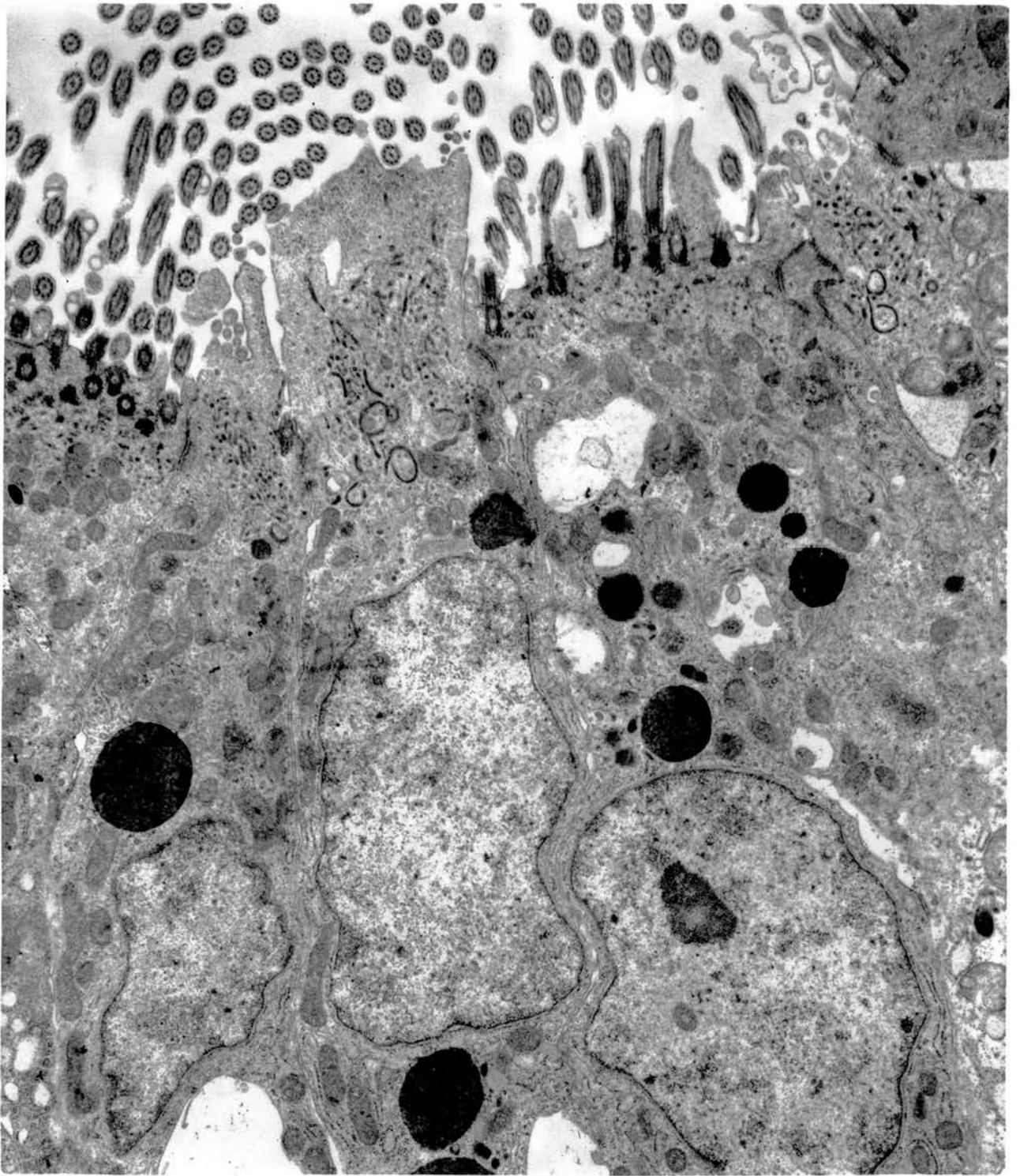


Fig. 150. Sections of spermatozoa located in an intact cytoplasmic vacuole of a ciliated cell as well as in deep invaginations of the plasma membranes related to the intercellular spaces.  
x 18750.

Ductulus efferens.



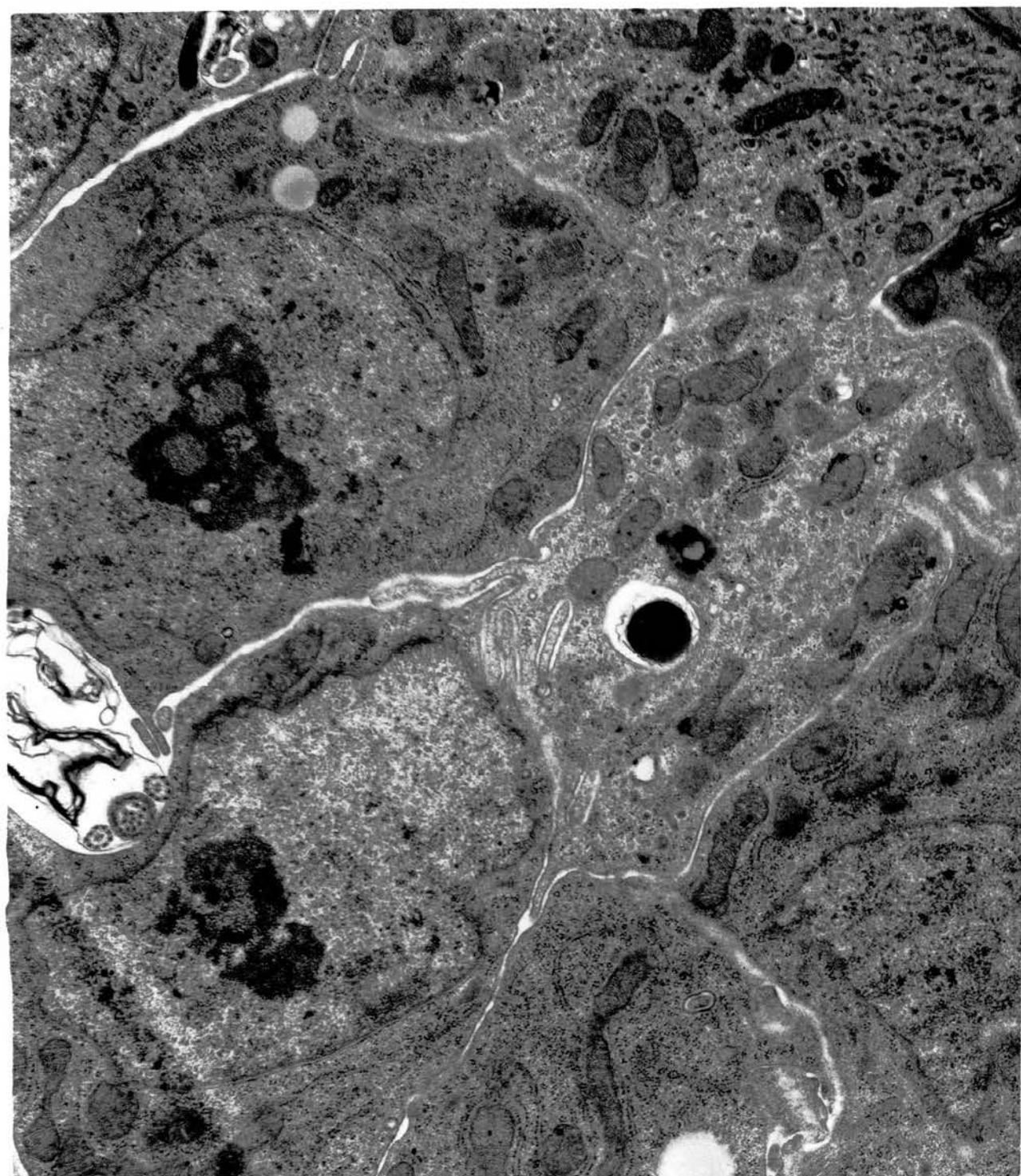


Fig. 151. A large nucleus of a ciliated cell seen at the bottom surrounded by bundles of fibrillar material in a broken concentric arrangement. A sectioned sperm tail is seen in the supranuclear region. x 18750.

Ductulus efferens.

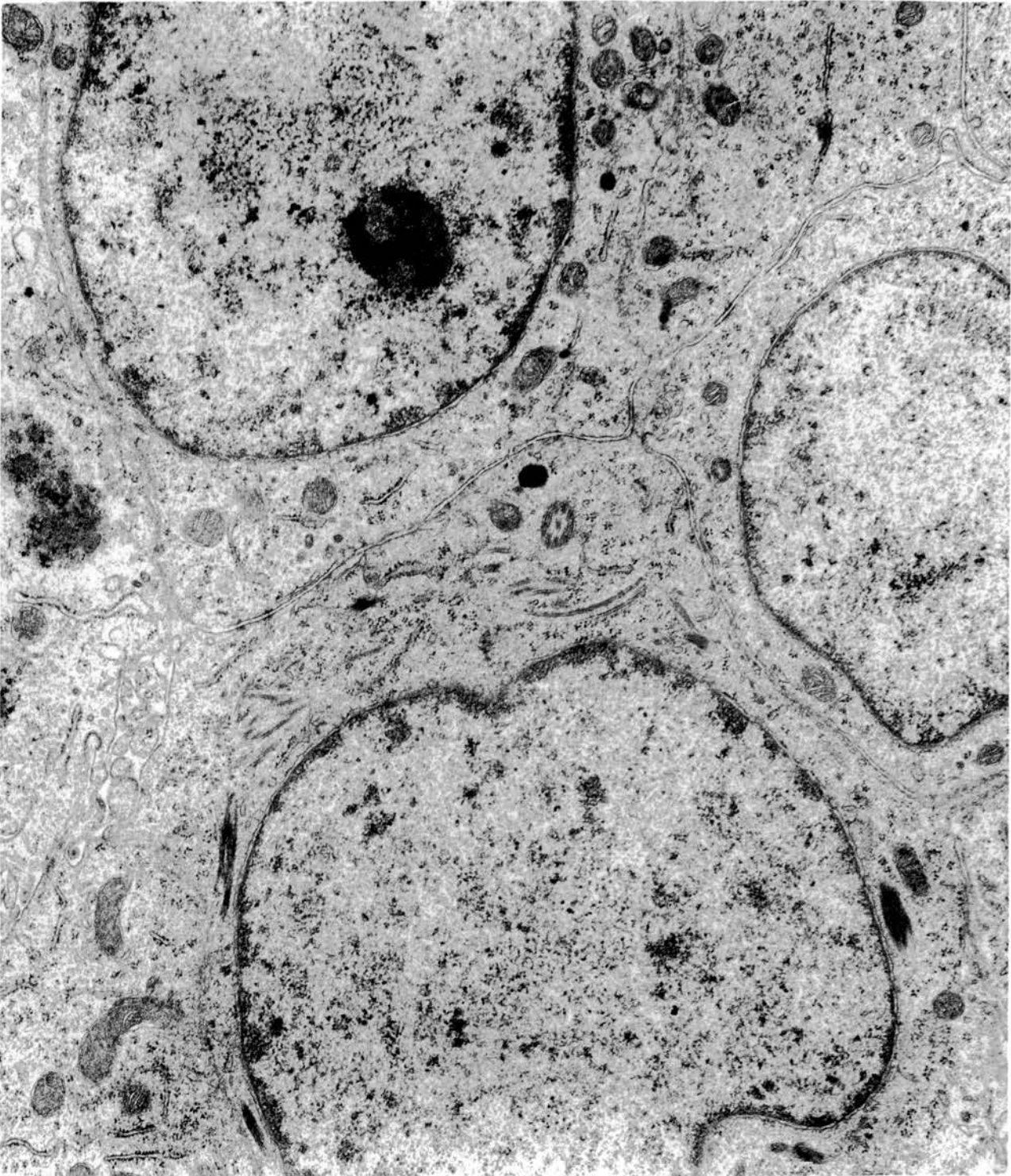

Fig. 152. Basal cells become more numerous in the caudal parts of the tract. In the ampullary portion of ductus deferens they form an almost complete basal layer. Four such cells are shown. x 12500.

Ampulla of ductus deferens.

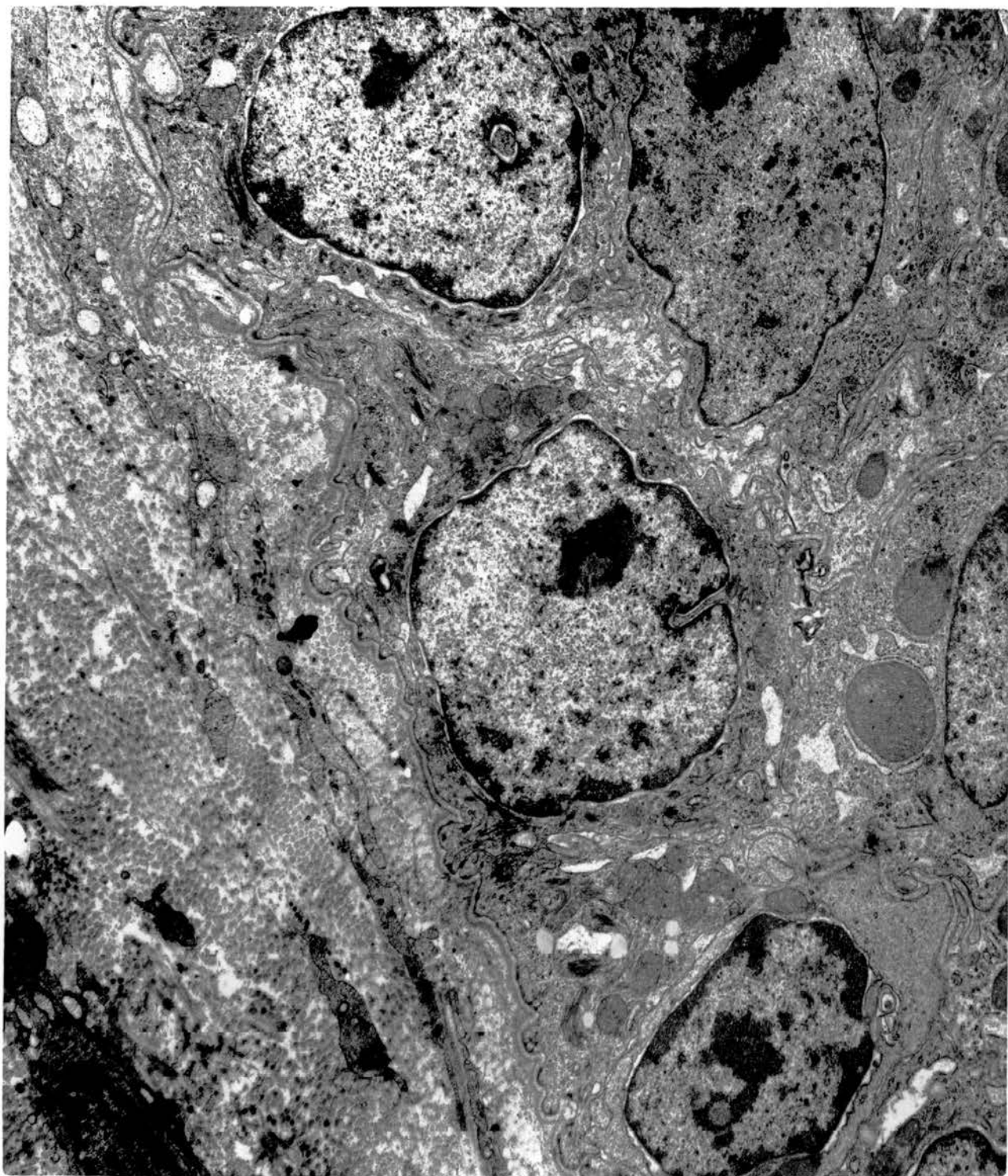


Fig. 153. Diagrammatic representation of the fine structure of a basal cell. BL, basal lamina; SE, surface epithelium; D, desmosomes; N, nucleus; F, fibrils; m, mitochondria; G, Golgi complex; C, centrioles; B, electron-dense bodies.

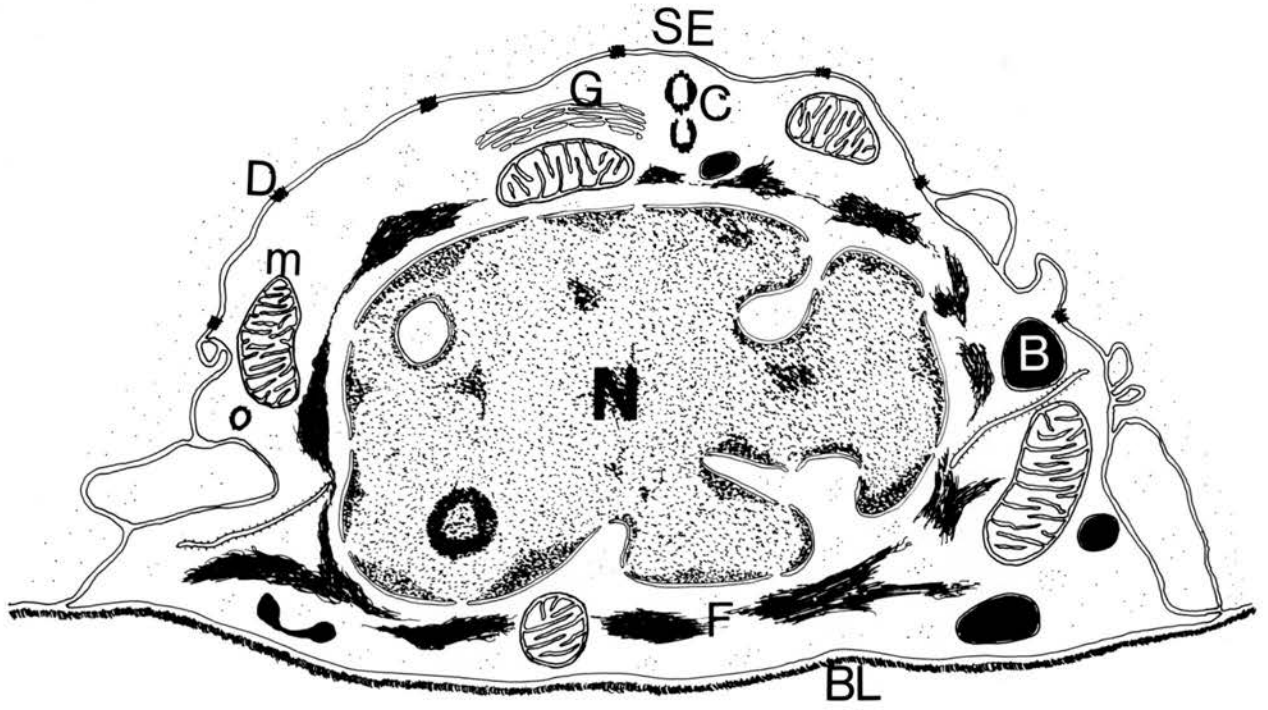


Fig.154. Basal cell. The nucleus is irregular and cytoplasm scanty. Note the fibrils around the nucleus and the desmosomal connections with the overlying surface epithelia. x 25000.

Basal cell from the cranial segment of ductus deferens.



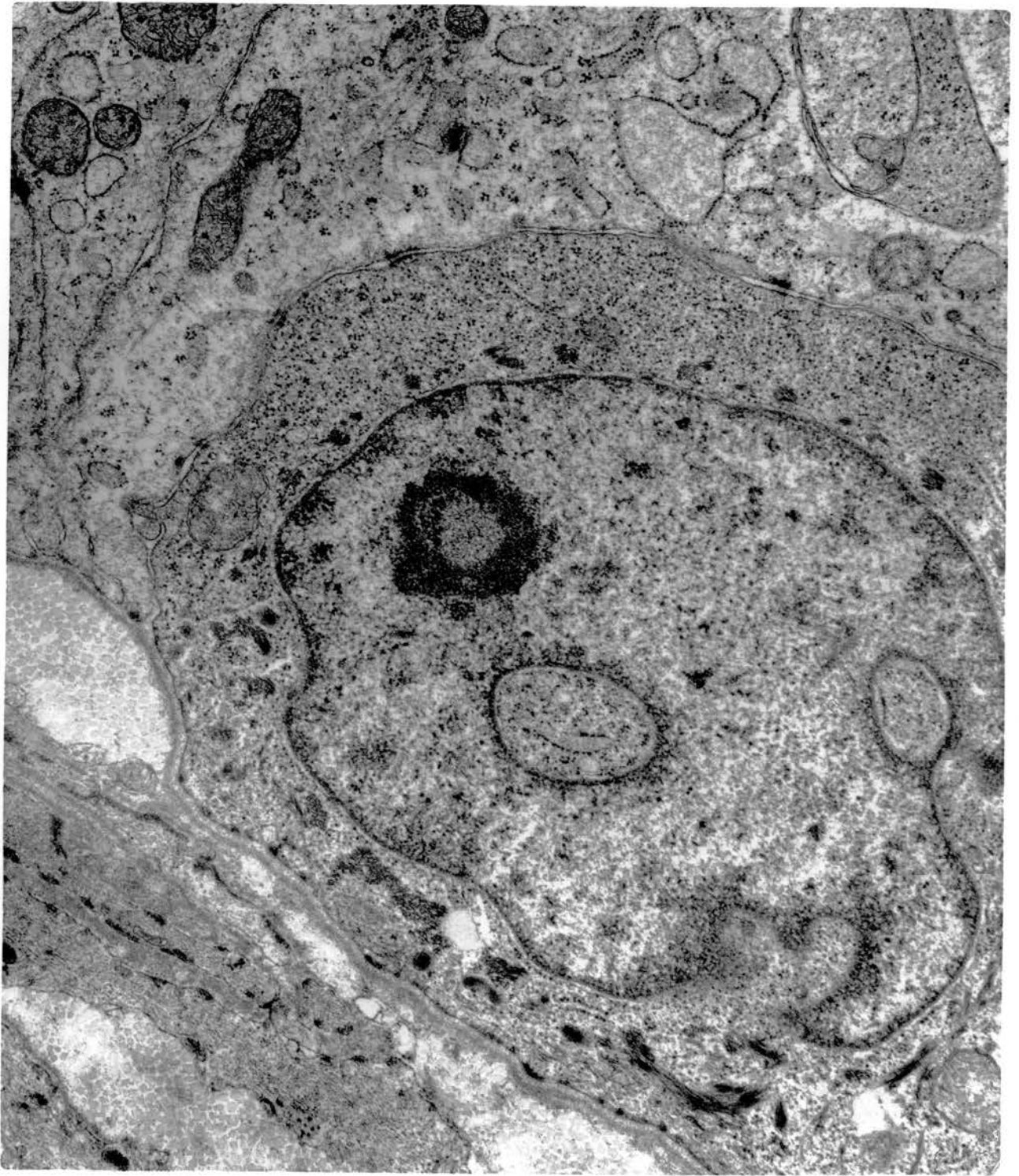


Fig. 155. Branching processes from a dark basal cell extending along the basal lamina. x 25000.

Basal cell from the middle segment of ductus deferens.

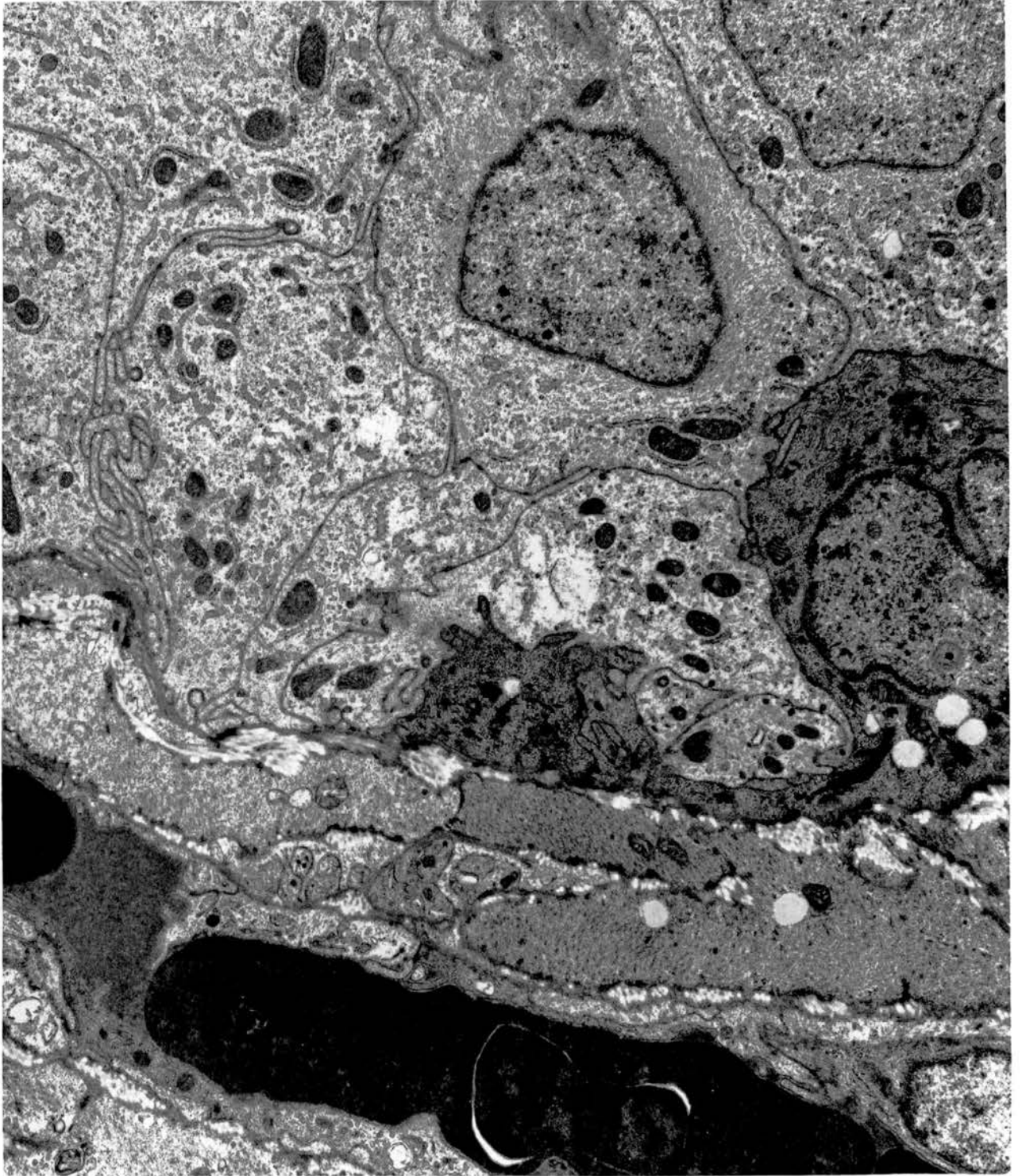


Fig. 156. Basal cell showing the concentric arrangement of cytoplasmic fibrils around the nucleus and the scanty organelles which also include electron-dense bodies. x 25000.

Basal cell from the caudal segment of ductus deferens.

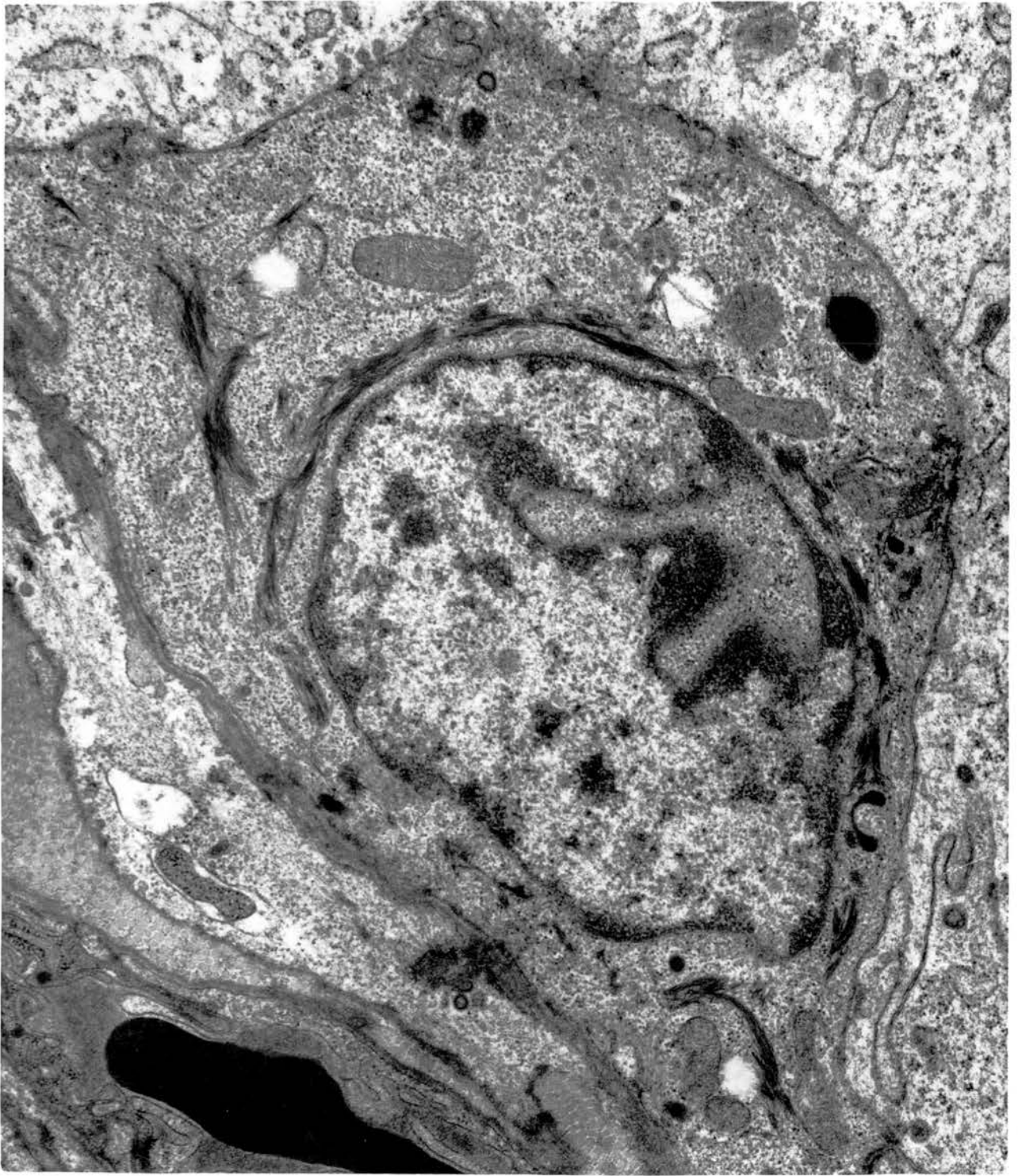


Fig. 157. A small Golgi complex and centrioles are located in the supranuclear region of a basal cell. x 18750.

Basal cell from the caudal part of ductus deferens.

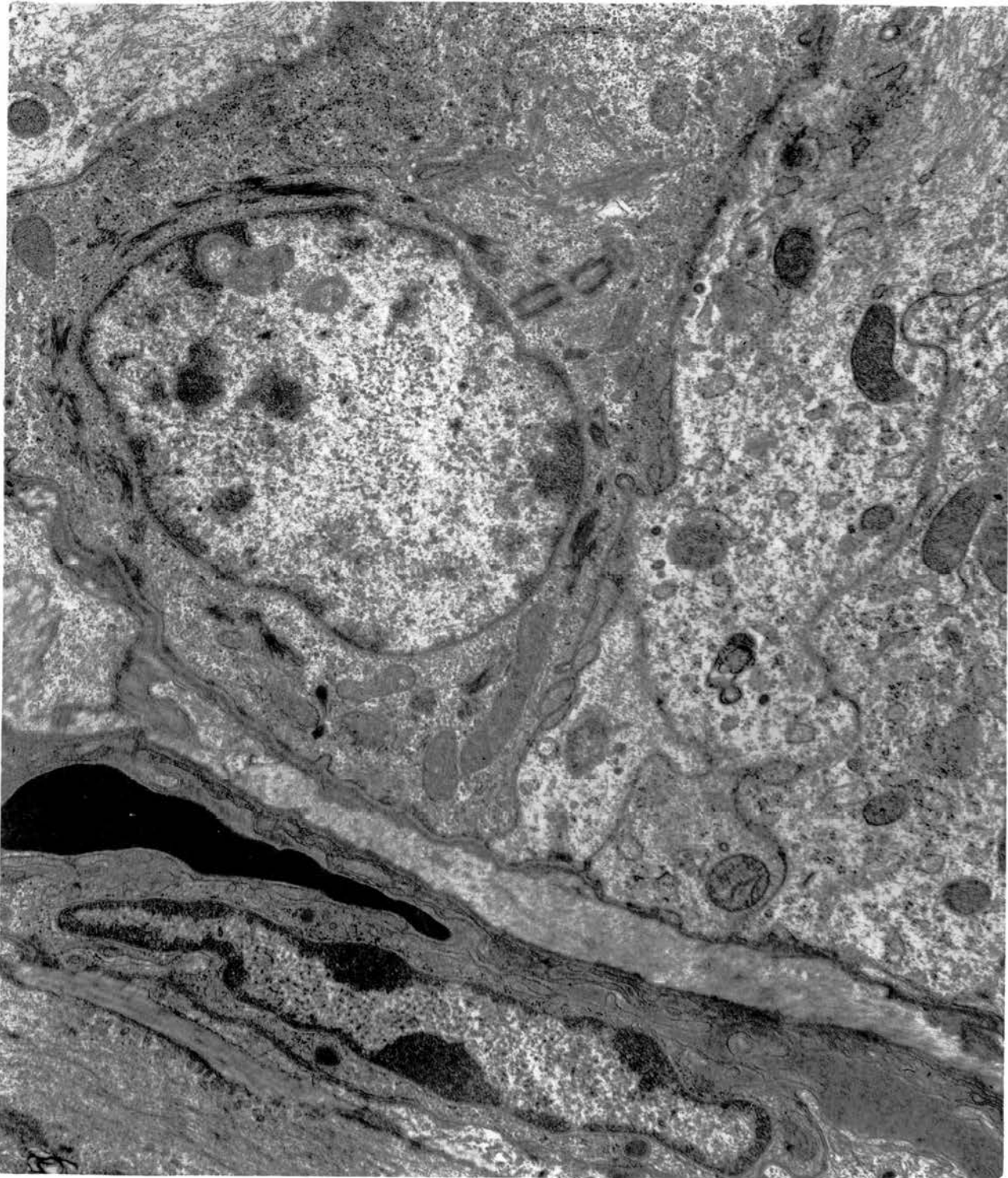


Fig. 158. Nerve axons are in contact with the basal lamina underlying a basal cell. The applied side of the axon is naked. x 25000.

Basal cell from the ductus epididymidis.



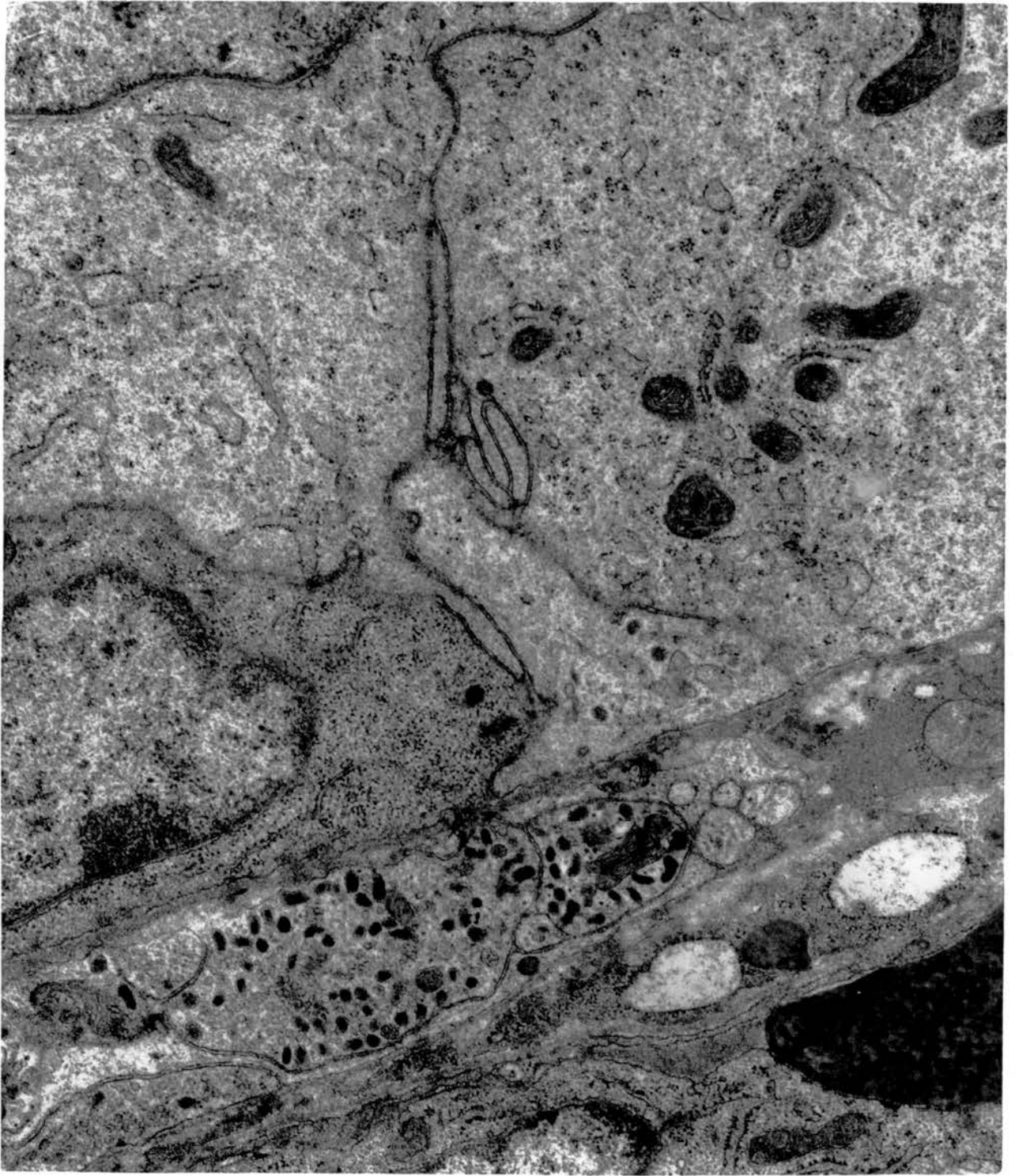


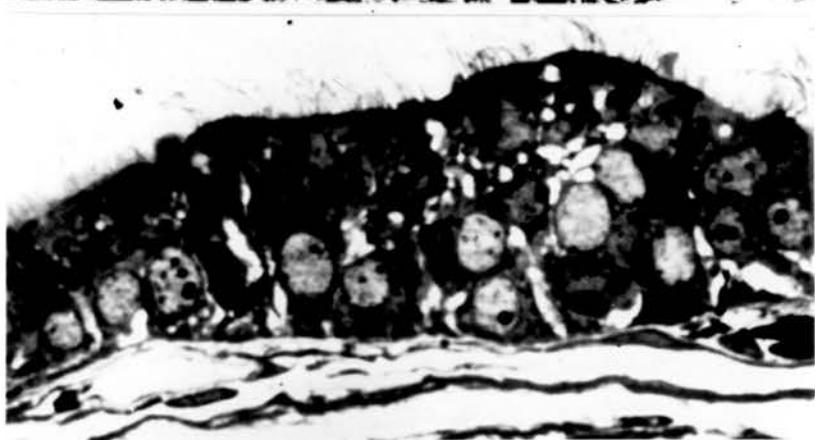Fig. 159. Rete testis 3 weeks after cranial ligation showing accumulation of spermatozoa together with cells possessing eosinophilic granules both in the lumen and within the epithelial lining (arrows). H & E. x 500.

Figs. 160, 161. An efferent (Fig. 160) and a connecting ductule (Fig. 161) showing intraepithelial vacuolation 3 weeks after cranial ligation. Toluidine blue. x 1400.

159



160



161

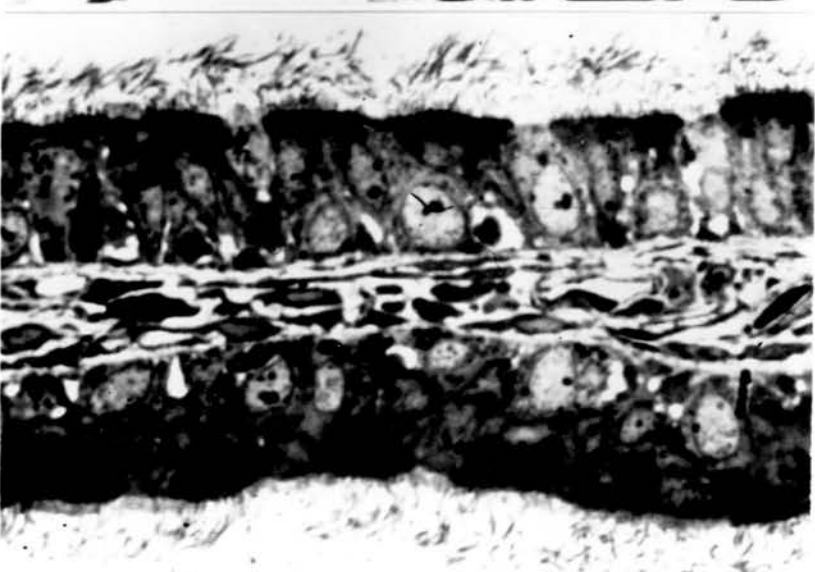


Fig. 162. An accumulation of seminal fluid and spermatozoa in the lumen of an efferent ductule 3 weeks after cranial ligation. Note the disruption of chromatin and the disappearance of most of the covering membranes.

x 12500.

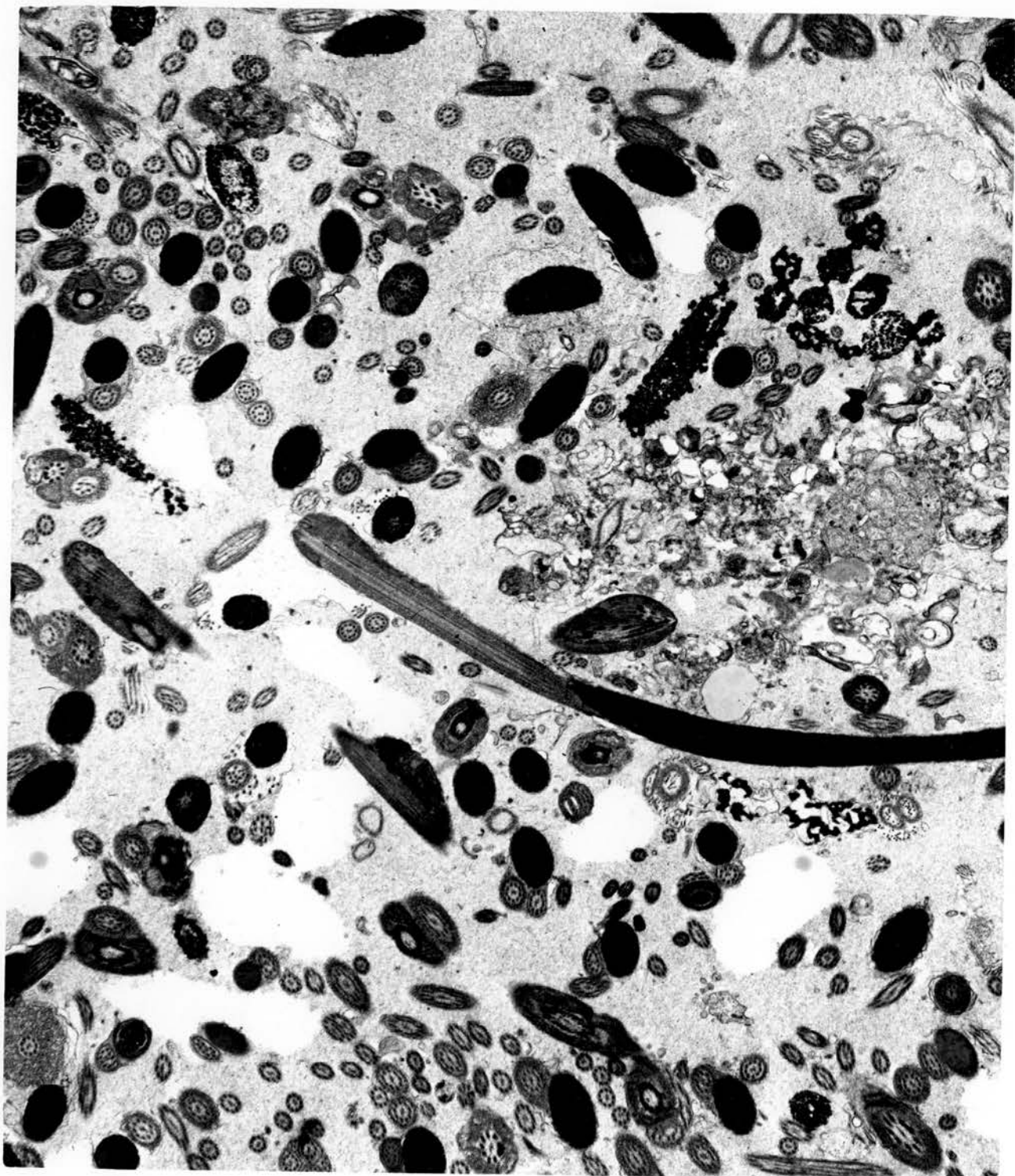


Fig. 163. Disintegrating spermatozoa in the lumen of an efferent ductule 3 weeks after caudal ligation. A large cell possesses many cytoplasmic vacuoles containing spermatozoa and products of sperm breakdown. x 12500.

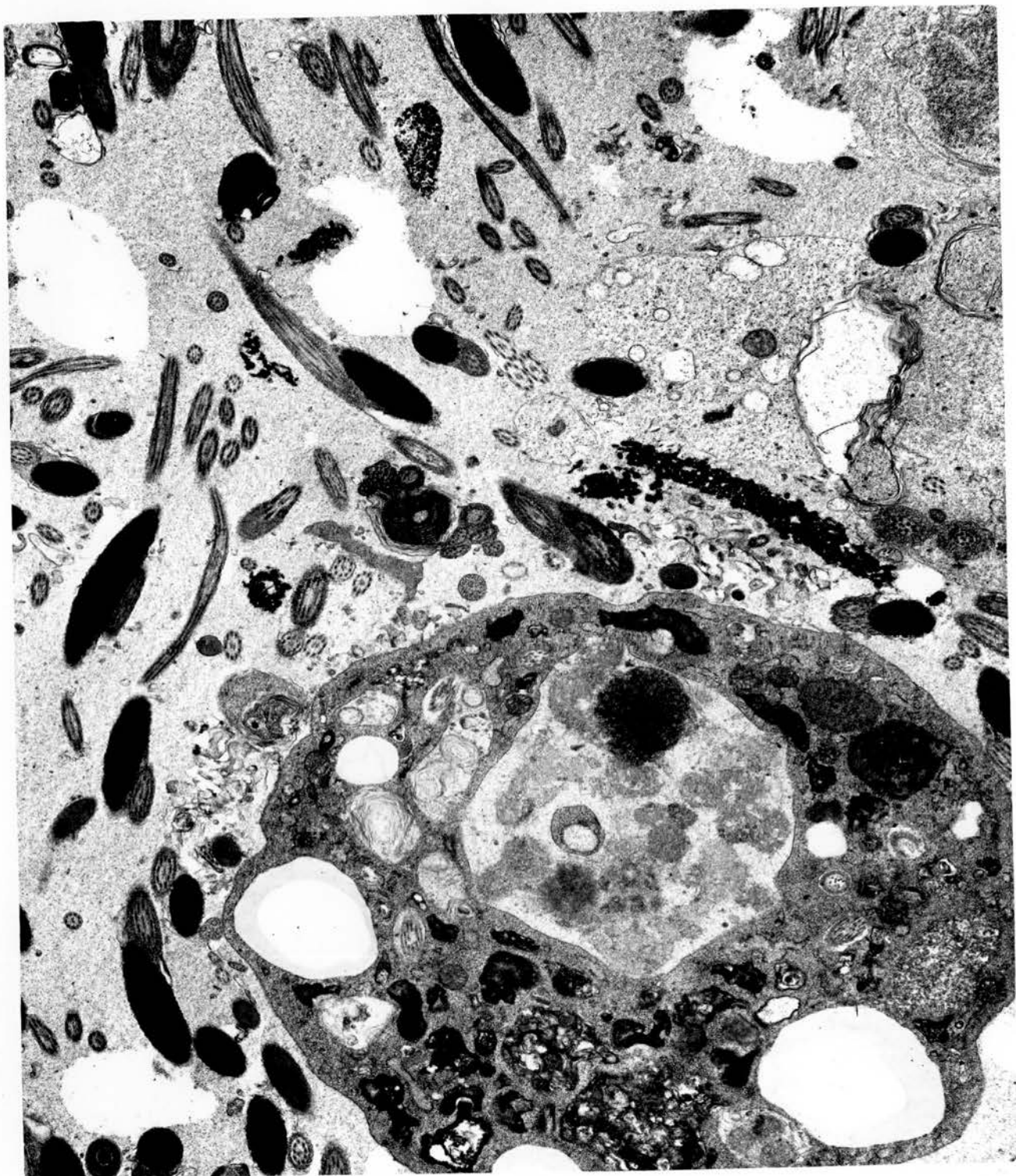


Fig. 164. Luminal macrophage in an efferent ductule 4 weeks after caudal ligation. Note the pseudopodial processes of the cell, its content of RER and sperm-containing vacuoles.  
x 18750.



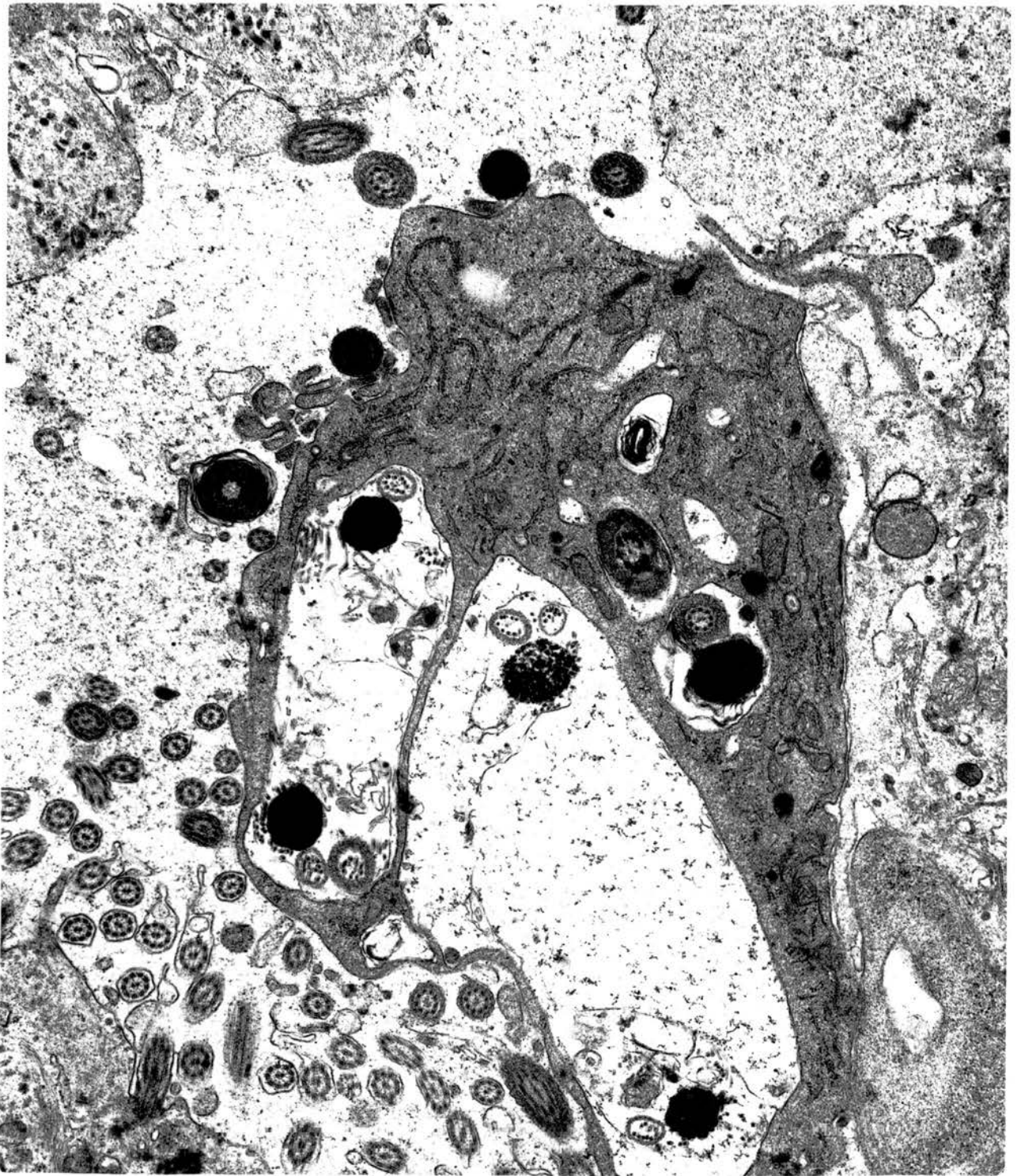


Fig. 165. Rete epithelium showing uptake of luminal spermatozoa 3 weeks after caudal ligation. x 25000.

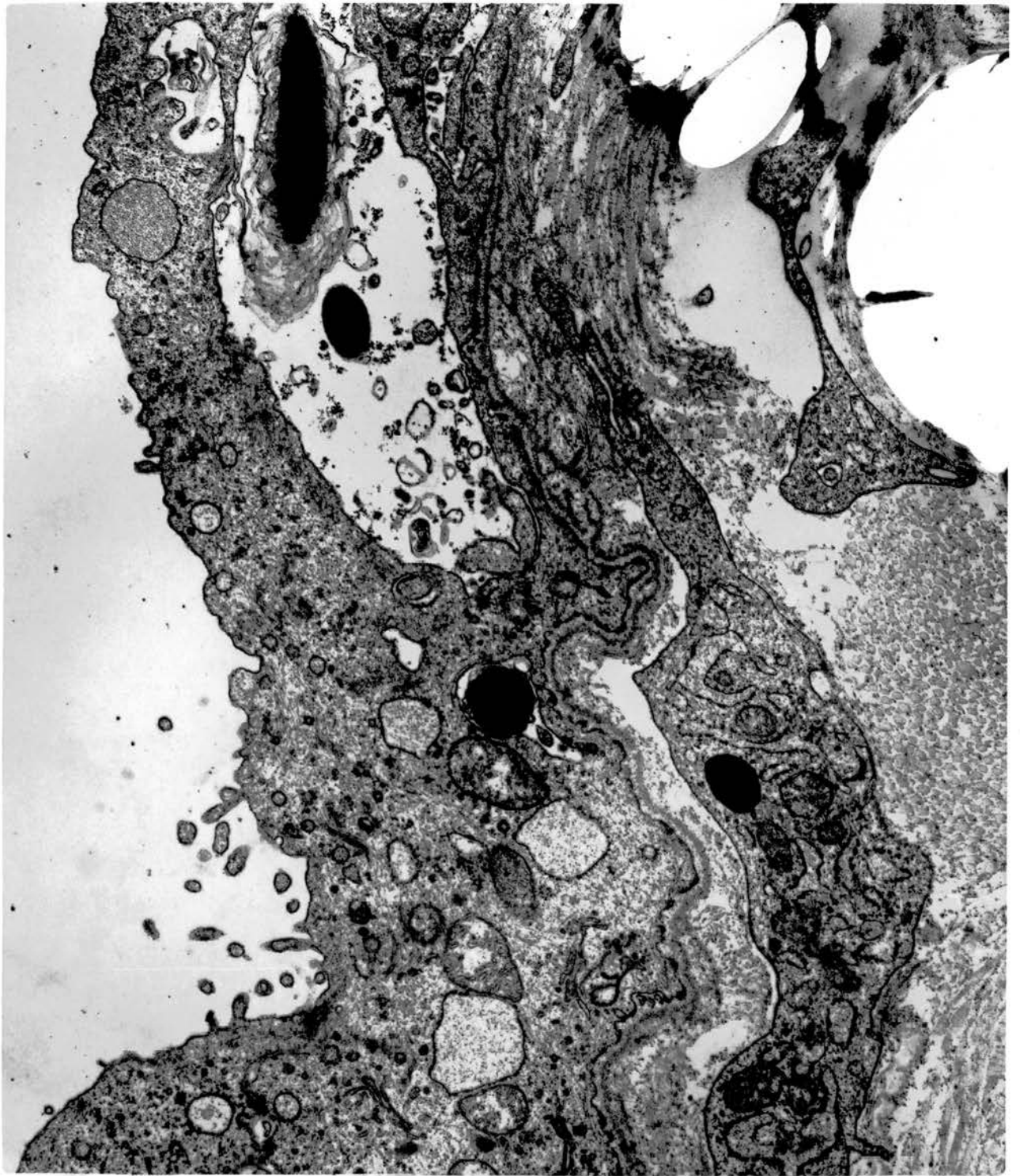


Fig. 166. Uptake of spermatozoa by ciliated cells. Note the intact junctional complexes. Ductulus efferens 3 weeks after caudal ligation. x 18750.

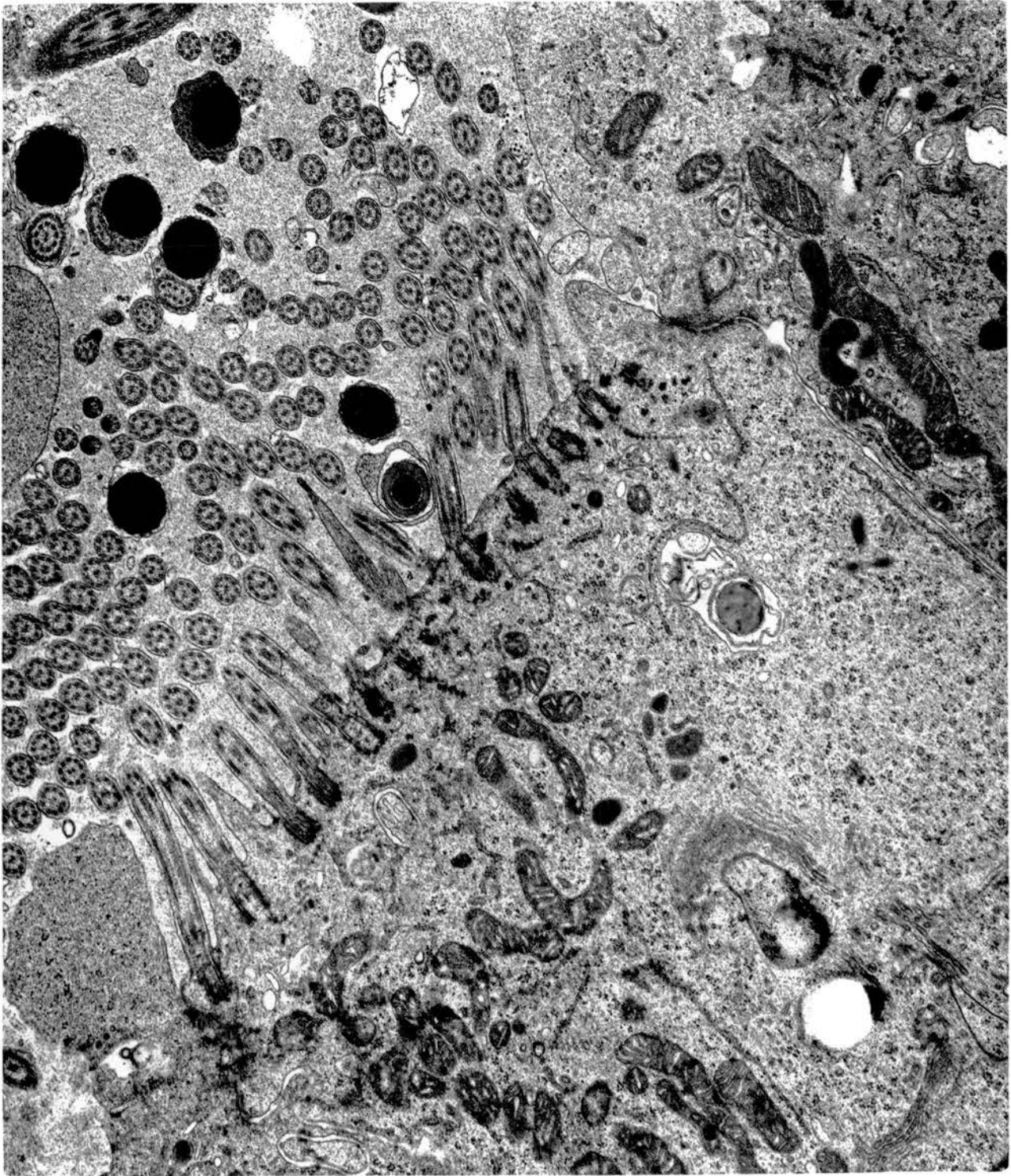


Fig. 167. Spermatozoa are contained in definite cytoplasmic vacuoles in a non-ciliated type I cell. Ductulus efferens 3 weeks after cranial ligation. x 18750.

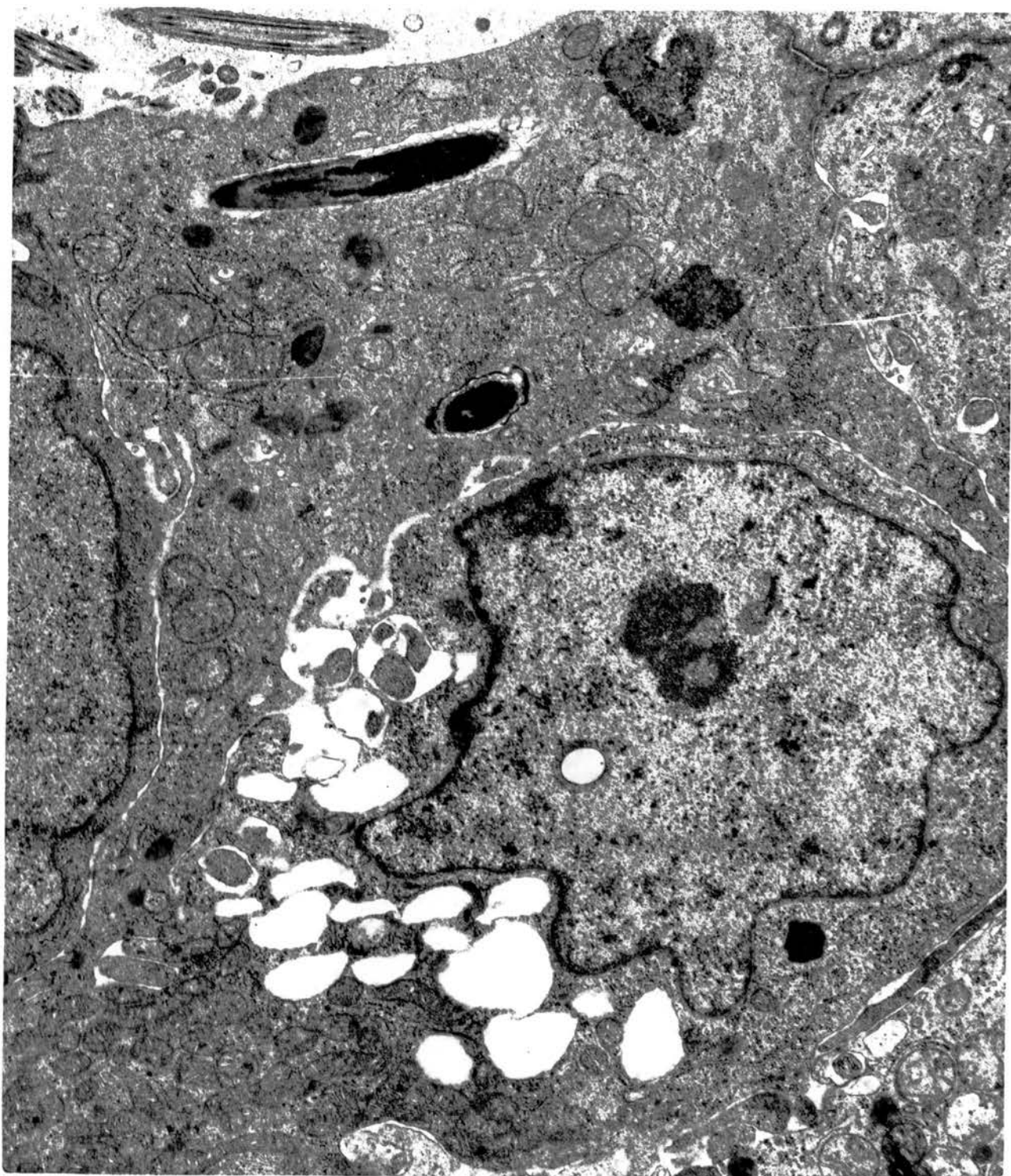


Fig. 168. Spermatozoa are occasionally seen in surface invaginations of the epithelium as illustrated here in a normal non-ciliated type I cell from a narrow connecting ductule.  
x 45000.



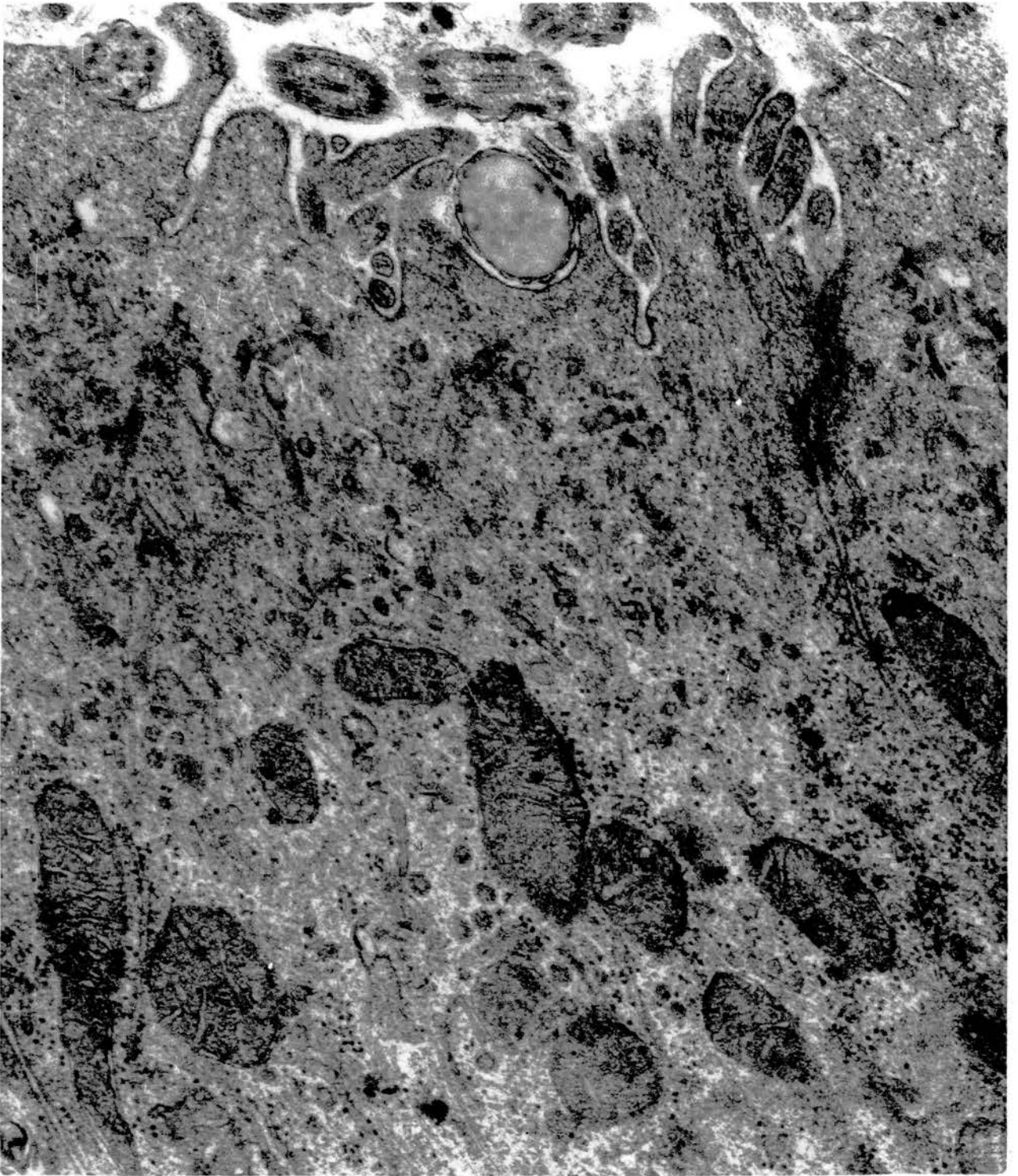


Fig. 169. Epithelial lining of a ductulus efferens 3 weeks after cranial ligation. Note the wide intercellular spaces and the contained spermatozoa. All cells are healthy and there are no signs of separation of junctional complexes. x 12500.

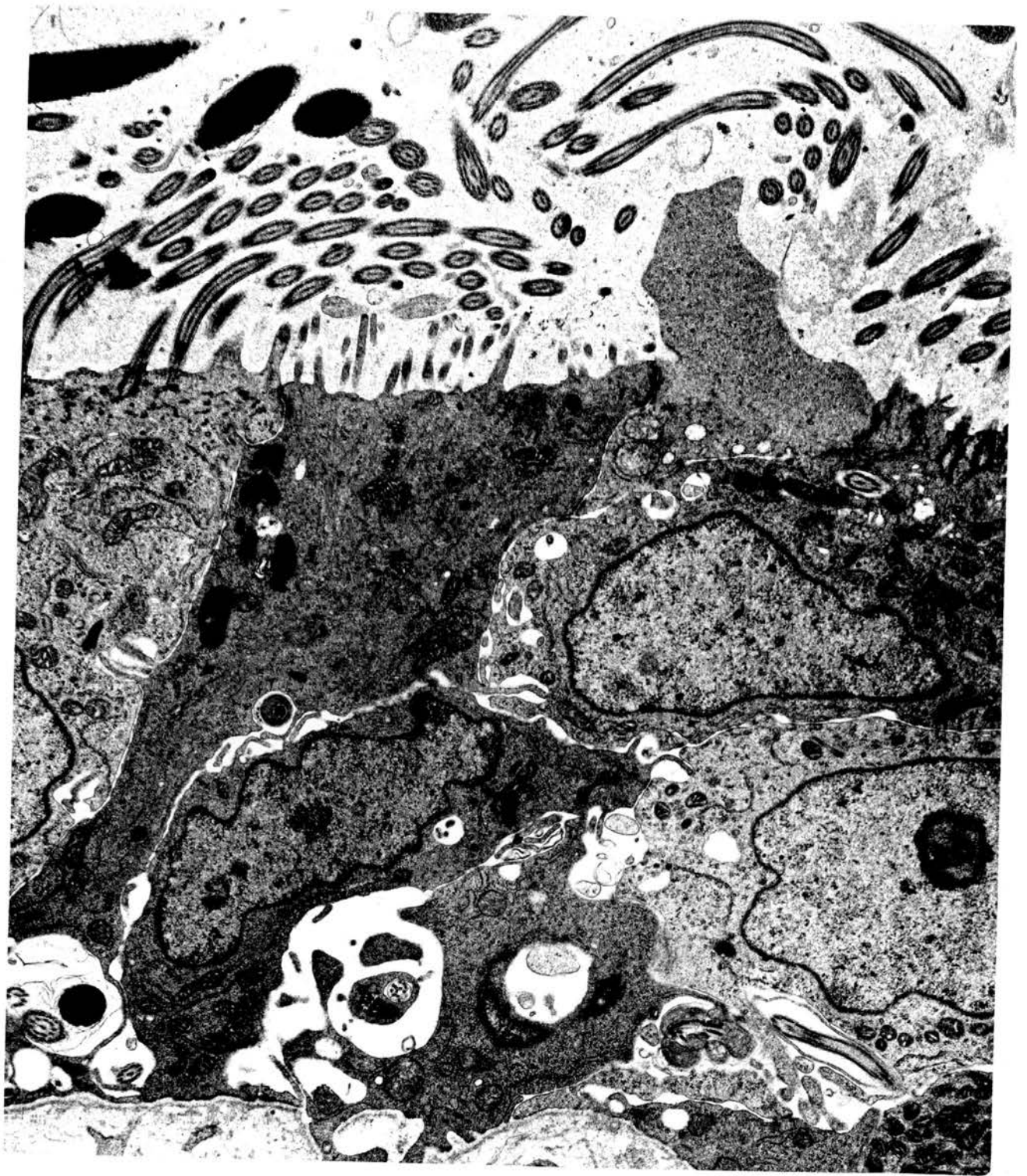


Fig. 170. Fluid-containing vacuoles in the apical cytoplasm of a ciliated cell of a ductulus efferens, 3 weeks after cranial ligation. Compare the consistency and electron density of the vacuolar fluid with the seminal fluid in the lumen. x 18750.

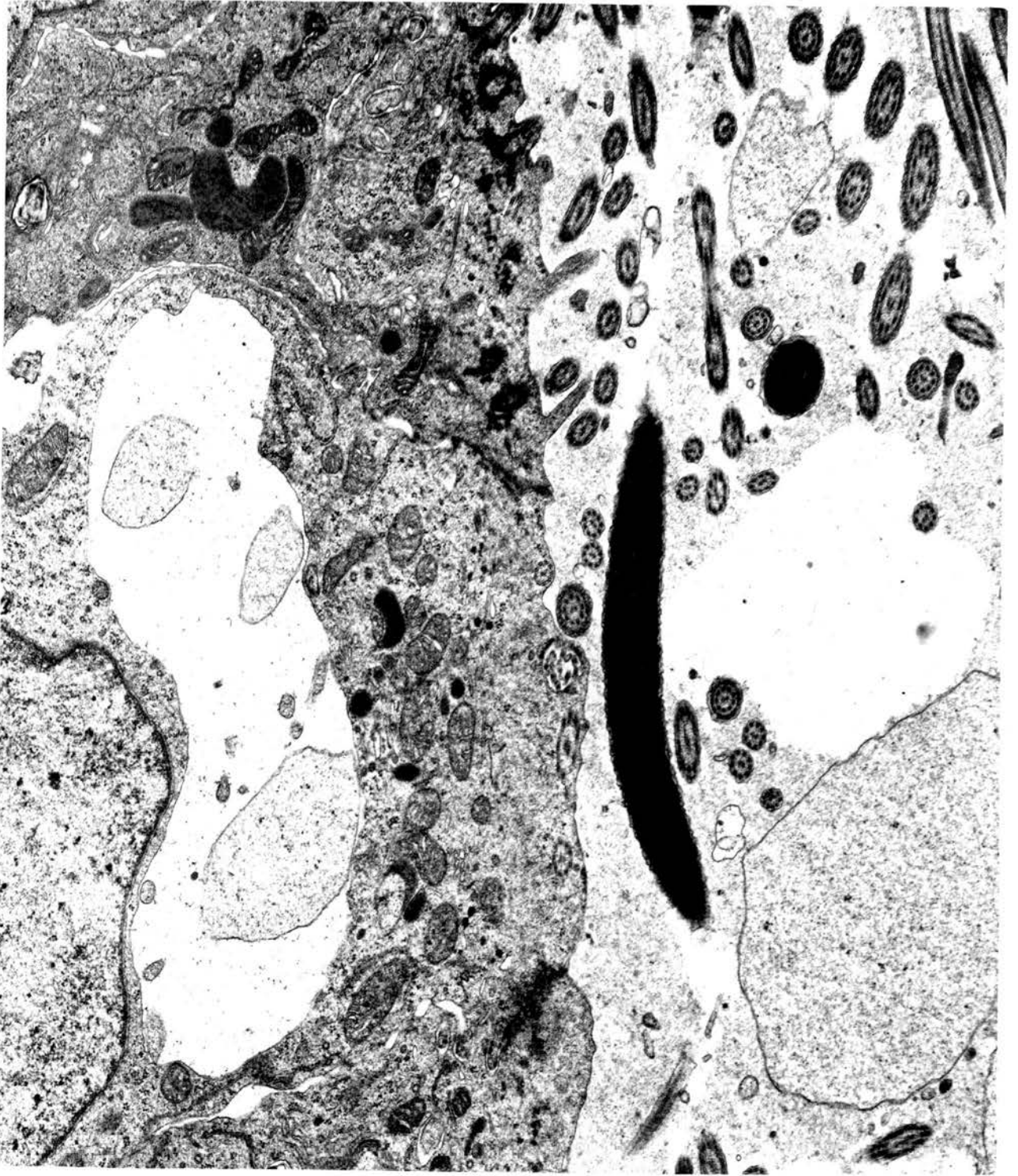


Fig. 171. Sperm-containing macrophage located between the basal lamina (right) and the surface epithelia (left) of a ductulus efferens 3 weeks after cranial ligation.

x 18750.

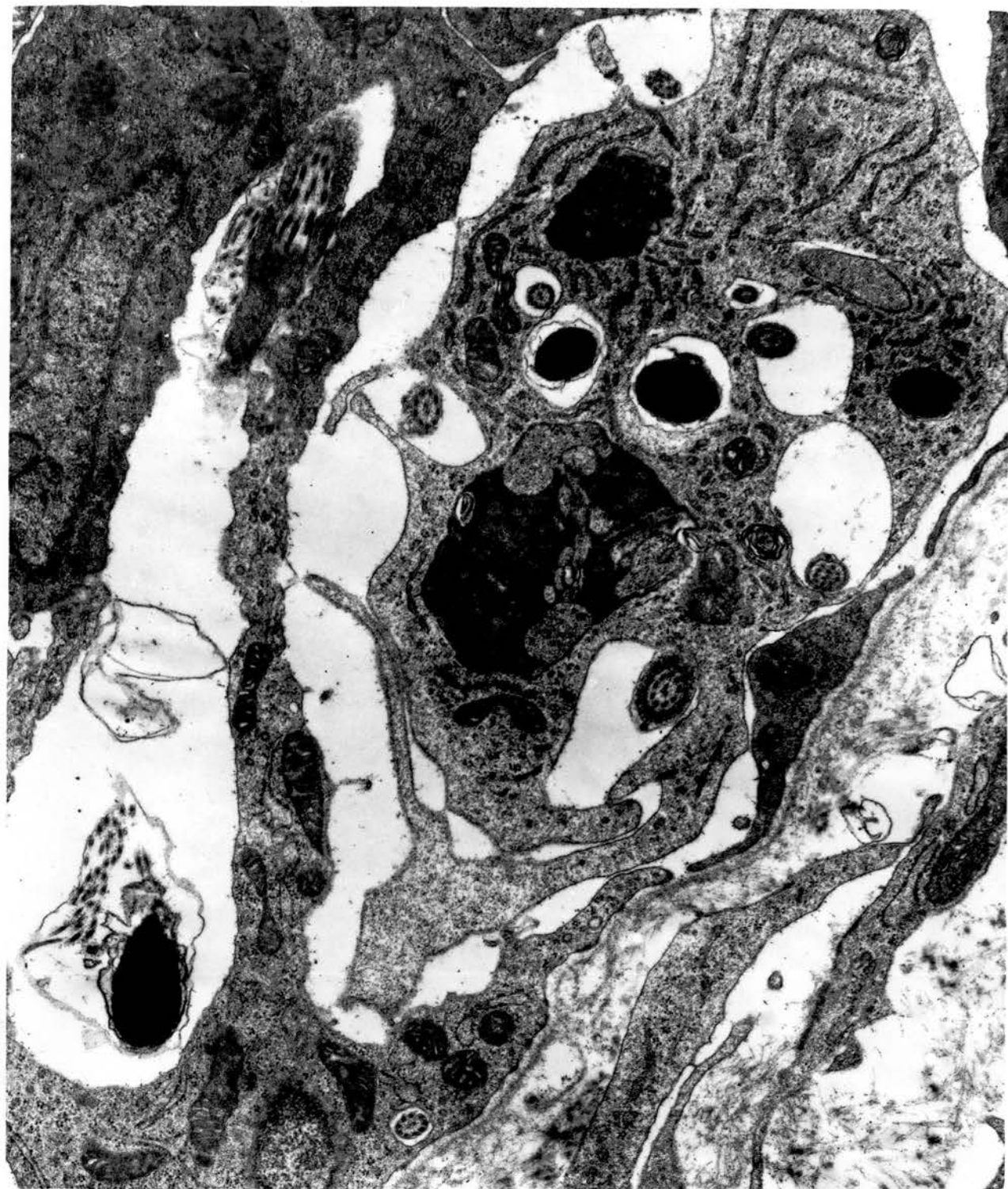

Fig. 172. Sperm-containing macrophage in the subepithelial tissue of a connecting ductule seen 3 weeks after cranial ligation. Note the undulating basal lamina (top) separating the epithelium from the macrophage. x 18750.



