



# THE UNIVERSITY *of* EDINBURGH

This thesis has been submitted in fulfilment of the requirements for a postgraduate degree (e.g. PhD, MPhil, DClInPsychol) at the University of Edinburgh. Please note the following terms and conditions of use:

This work is protected by copyright and other intellectual property rights, which are retained by the thesis author, unless otherwise stated.

A copy can be downloaded for personal non-commercial research or study, without prior permission or charge.

This thesis cannot be reproduced or quoted extensively from without first obtaining permission in writing from the author.

The content must not be changed in any way or sold commercially in any format or medium without the formal permission of the author.

When referring to this work, full bibliographic details including the author, title, awarding institution and date of the thesis must be given.

# **Investigation of the surgical endoscopic approaches used in the management of navicular bursa sepsis in the horse**

Justine Kane-Smyth BVM&S MRCVS

Resident in Equine Surgery

Master of Science by Research

University of Edinburgh

2016

# Abstract

## **Reasons for performing this study:**

Despite improvements in clinical outcome following treatment of synovial sepsis in horses, the prognosis for survival following septic navicular bursitis remains guarded, whilst the prognosis for athletic activity is considered poor. Surgical intervention is deemed essential for resolution. Two different surgical endoscopic approaches to the bursa have been described, however only the use of the direct approach has been reported in the management of clinical sepsis. The risk of inadvertent penetration of adjacent synovial structures with this approach is reported but has not been quantified. A transthecal approach, via the digital flexor tendon sheath, is considered to involve fewer complications than the direct approach but is typically reserved for elective examination of the aseptic bursa. The use of this approach in sepsis has not been evaluated. Intravenous regional limb perfusion with antimicrobials is an established adjunct in the management of synovial sepsis and is suggested to improve case outcome. The synovial concentrations of antimicrobial achieved following IVRP in case's of clinical sepsis have not been established.

**Objectives:**

- To quantify the risk of inadvertent synovial structure penetration when making a direct surgical endoscopic approach to the navicular bursa. To determine a safer direct approach, with reduced risk of inadvertent synovial penetration.
- To review the outcome of clinical case's of navicular bursa sepsis following surgical management via the transthecal endoscopic approach and post-operative management involving intravenous regional limb perfusion with amikacin. To compare these outcomes with those reported following management via the direct approach.
- To investigate the concentrations of amikacin achieved in synovial fluid following IVRP in clinical case's of synovial sepsis.

**Hypotheses:**

- There is significant risk of inadvertently penetrating the distal interphalangeal joint and/or digital flexor tendon sheath when making a direct surgical endoscopic approach to the navicular bursa, with attendant potential for contamination of these structures when managing septic bursitis. Making the approach as abaxial as possible and advancing the instrument in a sagittal trajectory will minimise the risk of inadvertent synovial penetration.
- The prognoses for survival and return to athletic function following surgical management of navicular bursa sepsis via the transthecal approach, in addition to post-operative intravenous regional perfusion with amikacin, are comparable with those reportedly managed via the

direct approach. The surgical technique permits simplified postoperative intrasynovial medication and monitoring of synovial fluid parameters by establishing communication between the bursa and tendon sheath

- Following regional intravenous limb perfusion, the levels of amikacin accumulated in contaminated synovial structures are greater than the minimum inhibitory concentration for commonly encountered bacteria, potentially validating the contribution of perfusion techniques as adjunct therapies in treating synovial sepsis.

#### **Methods:**

- Using 40 cadaver horse limbs, a conventional endoscopic approach, was made to the lateral aspect of the navicular bursa of each limb. Successful entry was confirmed endoscopically. Centesis and distension of the DFTS and DIPJ were performed to determine whether communication with the arthroscopic portal or bursa had occurred. Positive contrast radiographic navicular bursograms were performed to identify iatrogenic communication with the DFTS and/or DIPJ. A pilot study employing a modified approach was performed.
- The case records of 10 horses presented with navicular bursa contamination, which underwent therapeutic surgical endoscopy of the navicular bursa via a transthecal approach and received post-operative intravenous regional perfusion with amikacin were evaluated

retrospectively. Follow-up information was obtained by telephone questionnaire.

- Intravenous regional limb perfusion with amikacin was performed on clinical case's of synovial sepsis and synovial fluid was aspirated from the contaminated synovial cavity 30 minutes later. Synovial fluid amikacin concentration was then measured.

### **Results:**

- Using the direct surgical approach to the navicular bursa, inadvertent penetration of a synovial structure occurred in 45% of the limbs (digital flexor tendon sheath 37.5%, distal interphalangeal joint 17.5%, and both structures 10%). Incidence amongst the surgeons ranged 10-70%. Inadvertent penetration did not occur when using a modified approach.
- Of the 10 horses with septic navicular bursitis treated via transthecal endoscopic lavage and post-operative regional intravenous perfusion: 9 horses survived to long term follow up (>12 months). Eight returned to athletic function, 7 performed at their pre-injury level of athletic activity. One achieved a lower level of activity, 1 was retired, and 1 was euthanased.
- Synovial fluid concentration of amikacin achieved in excess of the minimum inhibitory concentration in 90% samples and 10-12 times minimum inhibitory concentration in 62.3% samples. The DFTS sample group recorded the highest individual sample concentration (391mg/L) as well as the highest group mean (175.1) and median (181). The

lowest individual result came from a TCJ, and proximal group had the lowest mean (43.3) and median (26.9) values.

### **Conclusions:**

- There is significant risk of inadvertent penetration of the digital flexor tendon sheath and/or distal interphalangeal joint when making a direct surgical endoscopic approach to the navicular bursa. Individual surgeon interpretation and application of the described technique appears to influence the incidence of inadvertent synovial penetration. Further investigation of the modified technique is necessary.
- Endoscopic lavage of the navicular bursa via a transthecal approach was a safe and effective surgical treatment. When combined with post-operative intravenous regional limb perfusion, the prognosis for survival and return to previous level of athletic function were comparable with the published outcomes using a direct endoscopic approach. Postoperative intrasynovial medication and monitoring of synovial fluid parameters is potentially simplified by establishment of communication between the bursa and tendon sheath, however further investigation is required to determine the duration of patency.
- Intravenous regional limb perfusion achieves therapeutic concentrations of amikacin within contaminated synovial cavities when using the described protocol.

**Potential Clinical Relevance:**

Use of the direct surgical endoscopic approach to the navicular bursa incurs the potential risk of inadvertent contamination of adjacent synovial structures. Whilst the transthecal approach intentionally involves an aseptic synovial structure, this is consequently thoroughly lavaged and the post-operative communication between synovial structures allows for convenient synovial medication and sampling. Use of intravenous perfusion with amikacin in clinical sepsis has the potential to improve case outcome.



# Declaration

I declare that the contents of this thesis are my own work and that they have not been presented to any University other than the University of Edinburgh.

Justine Kane-Smyth

July 2016

# Dedication

For my Mam and Nanny Kane

Both of whom have always had unwavering faith in me.

# Acknowledgements

I wish to express gracious thanks to my supervisor, Dr Richard Reardon, to whom I owe a great debt of gratitude for his encouragement, invaluable guidance and patient support.

I would like to sincerely thank Russell Parker and Dr Sarah Taylor, also for their supervisory assistance and participation in parts of this study. Thanks also to Eugenio Cillán García for his assistance and participation in part of this study.

Finally, I would like to express heartfelt thanks to Professor Paddy Dixon for his generosity, kindness and inspiration.

This study was partially funded by a generous contribution from the Roslin Institute

# Abbreviations

ADA – alternate direct approach  
CI - confidence interval  
CSL – collateral sesamoidean ligament  
DA – direct approach  
DDFT – deep digital flexor tendon  
DFTS – digital flexor tendon sheath  
DIPJ – distal interphalangeal joint  
DSIL - distal sesmoidean impar ligament  
EDTA - Ethylenediaminetetraacetic acid  
IP - Intraosseous perfusion  
IVRP – intravenous regional perfusion  
MCPJ – metacarpophalangeal joint  
MIC - minimum inhibitory concentration  
MRI – magnetic resonance imaging  
MTPJ – metatarsophalangeal joint  
NB – navicular bursa  
Nbone – navicular bone  
OR - odds ratio  
P2 – middle phalanx  
P3 – distal phalanx  
PIPJ – proximal interphalangeal joint  
PMMA – Polymethylmethacrylate  
RCJ – radiocarpal joint  
T-Lig - T-ligament  
TA – transthecal approach

TCJ – tarsocrural joint

TNCC – total nucleated cell count

TP – total protein

# Contents

Title Page	1
Abstract	2
Declaration	8
Dedication	9
Acknowledgements	10
Abbreviations	11
<b>Chapter 1: Literature Review</b>	<b>15</b>
1.1 Navicular Bursa	15
1.1.1 Anatomy	15
1.1.2 Clinical Conditions	19
1.2 Synovial Sepsis	21
1.2.1 Aetiopathogenesis	21
1.2.2 Treatment Options	23
1.2.3 Prognosis	29
1.3 Synovial Sepsis of the Navicular Bursa	33
1.3.1 Introduction	33
1.3.2 Aetiopathogenesis	33
1.3.3 Diagnosis	34
1.3.4 Treatment	36
1.3.4.1 Surgical treatment options	36
1.3.4.2 Adjunctive therapies	39
1.3.5 Prognosis	41
1.3.6 Differences in the studies	43
<b>Chapter 2: Navicular bursa surgical approach overview</b>	<b>45</b>
2.1 Comparison of the surgical endoscopic approaches to the navicular bursa	45
2.2 Rationale for using the transthecal approach for navicular bursa sepsis	47
2.3 Study objectives	49
<b>Chapter 3: Investigation of the frequency of inadvertent synovial penetration when using a direct surgical endoscopic approach to the navicular bursa</b>	<b>50</b>
3.1 Introduction	50
3.2 Hypotheses	51
3.3 Materials	51
3.4 Methods	52
3.4.1 Pilot Study	52
3.4.2 Test Procedure	52
3.4.3 Dissection	59
3.4.4 Statistical Analysis	60
3.5 Results	62
3.5.1 Pilot Results	62
3.5.2 Main Test Sample Results	62
3.6 Discussion	69
3.7 Conclusions	73

<b>Chapter 4: Use of a transthecal surgical endoscopic approach for the treatment of clinical navicular bursa contamination</b>	<b>74</b>
4.1 Introduction	74
4.2 Hypotheses	74
4.3 Material and Methods	75
4.3.1 Case Selection	75
4.3.2 Diagnosis	77
4.3.3 Surgical Technique	79
4.3.4 Clinical Pathology	82
4.3.5 Post-Operative Management	83
4.3.6 Follow-up	87
4.4 Results	88
4.5 Discussion	90
4.6 Conclusions	95
4.7 Potential Clinical Relevance	95
<b>Chapter 5: To determine the concentration of amikacin accumulated in synovial fluid following IVRP in case's of clinical synovial sepsis</b>	<b>97</b>
5.1 Introduction	97
5.2 Hypothesis	99
5.3 Materials and Methods	99
5.3.1 Case Selection	99
5.3.2 Control	100
5.3.3 IVRP Protocol	101
5.3.4 Amikacin concentration analysis	103
5.4 Results	104
5.5 Discussion	107
5.6 Conclusions and Potential Clinical Relevance	111
<b>Chapter 6: Areas of Future Study</b>	<b>112</b>
6.1 The repeatability and usefulness of the ADA	112
6.2 Duration of fenestration patency	113
6.3 The efficacy of IVRP in clinical NB	114
6.4 Determination of antimicrobial dose rates for use in IVRP	114
<b>References</b>	<b>115</b>

## Chapter 1.

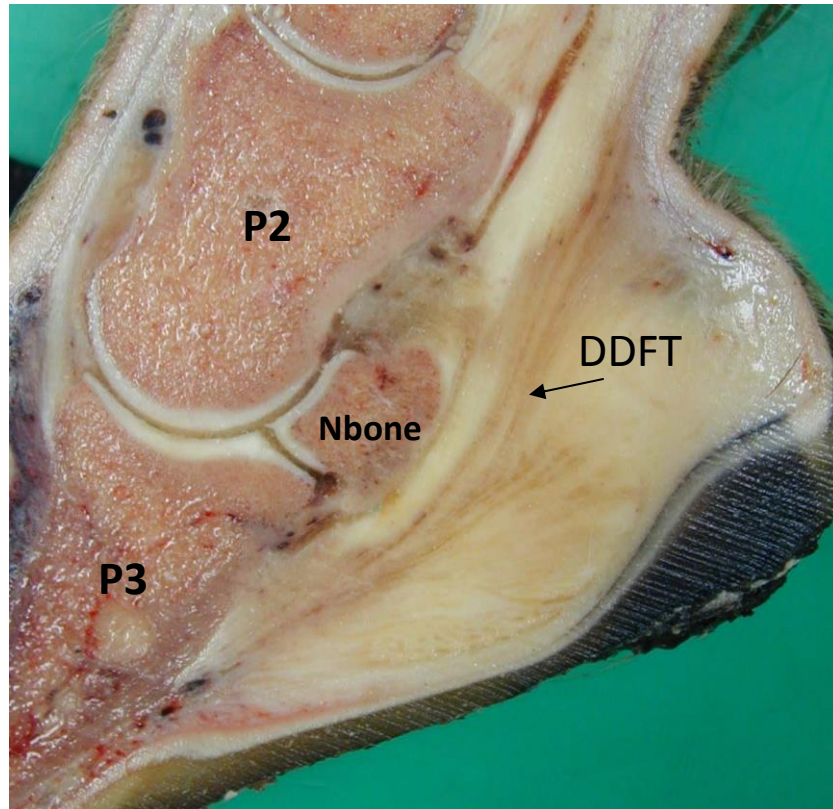
# Literature Review

## 1.1 Navicular Bursa

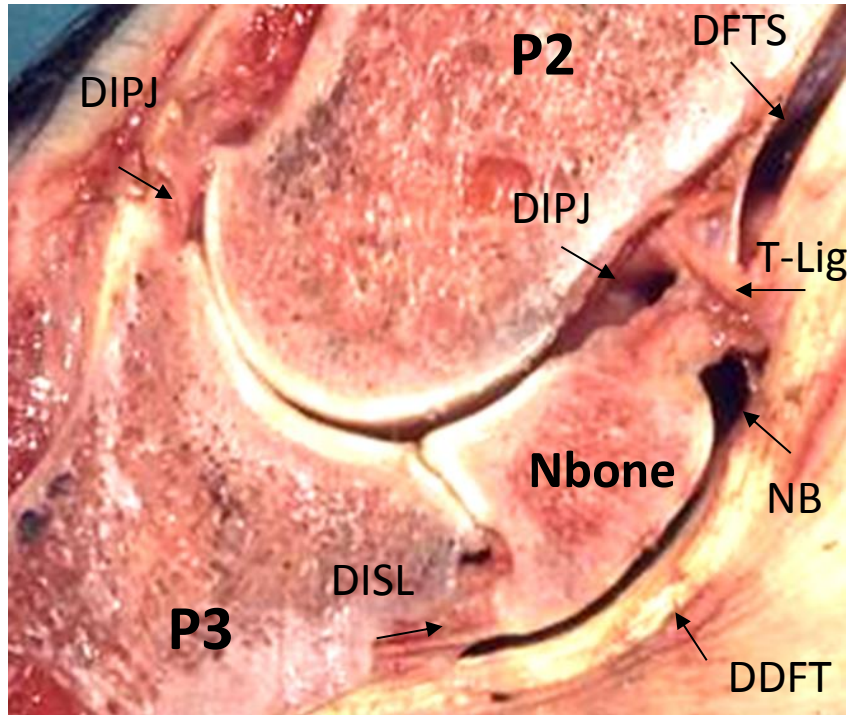
### 1.1.1 Anatomy

The horse's foot contains the podotrochlear apparatus, which is comprised of the navicular bone (or distal sesamoid) and its supporting ligaments, the navicular bursa (NB) deep digital flexor tendon (DDFT).<sup>7</sup> The NB (also referred to as the *bursa podotrochlearis manus*) is a closed, sac-like cavity interposed between the navicular bone and DDFT (Figures 1 and 3). Containing approximately 3ml of synovial fluid, it functions to allow low friction movement of the tendon as it changes direction and passes over the navicular bone.<sup>2,27</sup> The boundaries of the NB comprise the distal sesmoidean impar ligament (DSIL), forming the most distal border, the fibrocartilagenous *facies flexoria* on the palmar/plantar surface of the navicular bone forms the dorsal wall, the DDFT forms the palmar/ plantar wall, the collateral sesmoidean ligaments (CSL) contribute the abaxial and dorsal margins, and the dorsal margin is completed by the T-ligament (Figure 2).<sup>27</sup> The synovial capsules of the NB, digital flexor tendon sheath (DFTS) and distal interphalangeal joint (DIPJ) are located in very close proximity to each other, separated only by the T-ligament and collateral sesmoidean ligaments of the navicular bone. The T-ligament is a thin fibrous structure, composed of just a few fibres from each of the synovial capsules.<sup>9</sup>

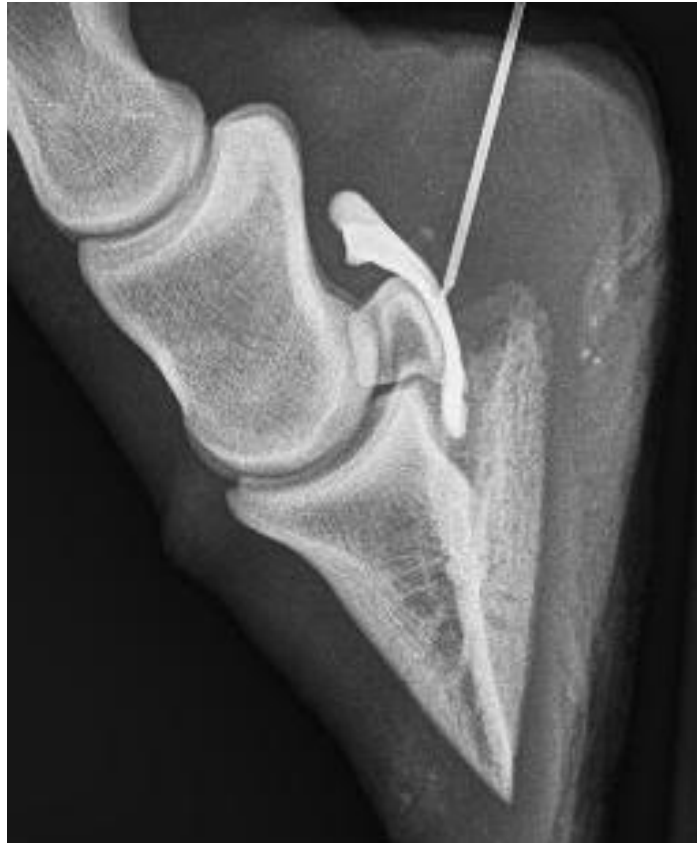



*Figure 1. Sagittal cadaveric section of the foot showing the anatomy of the digit. P2 = middle phalanx, P3 = distal phalanx, Nbone = navicular bone*



*Figure 2. Sagittal cadaveric section demonstrating the very close proximity between the NB, DFTS and DIPJ. DSIL = distal sesmoidean impar ligament, T-Lig = T-ligament, NBone = navicular bone.*



*Figure 3. Positive contrast radiographic navicular bursa gram (with a needle still in place) illustrating the location and shape of the NB.*

### 1.1.2 Clinical Conditions

Until recently, 'navicular syndrome' was one of the most commonly diagnosed causes of foot pain. A complex condition, involving chronic degenerative changes affecting the structures of the podotrochlear apparatus.<sup>27</sup> NB synovitis was logically assumed to be a contributing factor in such case's. Since the advent of magnetic resonance imaging (MRI) however, the term 'navicular syndrome' has become largely obsolete, as lesions within the hoof capsule are identified with greater precision and specificity. NB synovitis is recognised due to lesions of any of the anatomical structures contiguous with the NB, specifically: the DDFT, CSL, DSIL, and *facies flexoria* of the navicular bone. Longitudinal lesions or strain of the intra-bursal portion of the DDFT result in acute NB synovitis with or without disruption of the epitenon. Intra-bursal adhesions develop following epitenon injury, and the prolapsed tendon fibrils form firm fibrous attachments to adjacent intra-bursal structures, most often the CSL. Desmitis of the DSIL (with associated NB synovitis) is reported, either as a primary lesion or more commonly as part of a complex of lesions within the hoof capsule. Erosions of the navicular bone fibrocartilage are recognised, resulting in trauma of the opposing DDFT and in some case's also leading to adhesion formation.<sup>60</sup>

Septic navicular bursitis was historically the most commonly identified and treated condition affecting the NB. First described and reported at the turn of the 20<sup>th</sup> century in 1901 when it was usually the result of deep solar penetration with a nail foreign body, giving rise to the colloquial term 'street nail'.<sup>9,41</sup> Solar penetrating injuries often concurrently involve the DFTS and/or DIPJ, due to their close anatomical relationships with the NB. The condition occurs is

commonly the result of traumatic digital wounds or due to iatrogenic contamination during NB injection.<sup>58,70</sup>

## 1.2 Synovial Sepsis

### 1.2.1 Aetiopathogenesis

In adults, microorganism contamination of synovial structures occurs most commonly via communicating traumatic wounds or punctures (79-88% of case's), which may also allow introduction of foreign material, whilst it is more often the result of haematogenous spread in foals (34%).<sup>24,56,72</sup> Iatrogenic contamination (3% of case's) can occur during synoviocentesis or surgical intervention.<sup>72</sup> Occasionally, contamination occurs due to spread from an adjacent septic process, and rarely it occurs idiopathically.<sup>5</sup> Mixed populations of gram positive and gram negative bacteria are often involved when contamination occurs via a wound. With haematogenous aetiology, multiple synovial structures may be affected and gram negative bacterial species (e.g. *E. coli*, *Salmonella*, *Pseudomonas*, *Enterobacter* species) are most often isolated. Iatrogenic contamination typically involves *Staphylococcus* species.<sup>5</sup> Whether infection ensues is dependent upon several factors, principally the presence of foreign material and devitalised tissue, the size and virulence of the inoculant, as well as host immunocompetence.<sup>49</sup>

Synovial cavities are lined with a highly specialised mesenchymal membrane, which maintains homeostasis and tightly regulates the conditions within the synovial environment.<sup>12</sup> In the absence of additional compromising factors, the synovial defences can neutralise a considerable microbial inoculum and prevent infection. Colonisation and infection occurs when microorganisms overwhelm the host defences. Recognition of antigen (microorganism or foreign material) rapidly initiates a cascade of intense inflammatory responses.

Neutrophil influx predominates the immediate response, phagocytosing antigen and releasing destructive substances (collagenases, lysozymes, cytokines, etc.), which are not only harmful to microorganisms, but are also noxious to host tissues. This results in blood-synovial barrier disruption, allowing influx of additional inflammatory mediators and activation of other inflammatory pathways (coagulation, fibrinolytic, plasmin and kinin pathways). As a result, synoviocytes and chondrocytes (in joints only) are activated to release additional pro-inflammatory substances (e.g. matrix metalloproteinases) which further stimulate the inflammatory response, and an amplifying cycle of inflammation ensues. This results in the deposition of inflammatory debris as fibrinocellular conglomerate, which accumulates and inhibits synovial membrane perfusion and diffusion.<sup>5,38</sup> Normal synovium metabolism is further compromised by the physical distension of the cavity. The synovium then becomes ischaemic, compromising intrasynovial nutrition, further disrupting homeostasis and contributing to the escalating inflammatory cycle. Compromised blood flow hinders delivery of antimicrobial drugs, and intra-synovial debris provides a nidus for microbial persistence, and thus allows microorganism colonisation and proliferation. Whilst these processes primarily affect the synovium in the early phase, degradation of any intra-synovial cartilage ensues, and with eventual cartilage erosion, subchondral bone infection may be established.<sup>5,34</sup>

## **1.2.2 Treatment Options**

Successful treatment requires physical removal of any foreign material, debridement of devitalised tissues, clearance of microorganisms, inflammatory mediators and inflammatory debris. Completion of tissue healing and ultimately restoration of homeostasis within the synovial environment are essential for resolution.<sup>34</sup> Typically, this involves a multi-modal therapeutic approach, and regimens usually involve varying employment of the following treatment options to achieve these objectives:

### **I. Synovial Lavage**

Lavage of the synovial cavity with sterile fluids is used to remove much of the unwanted material and destructive substances, to decompress the cavity and thereby improve comfort. The simplest method involves through-and-through lavage with fluid ingress and egress via hypodermic needles.<sup>30</sup> The technique is limited by the inability to remove larger accumulations of debris or foreign material. Open surgery allows removal of a greater range of material, but is often associated with considerable post-operative morbidity and risk of poor functional recovery.<sup>51</sup> Both techniques are hindered by the inability to visually examine the internal structures and surfaces of the synovial cavity, foreign material may remain and concurrent structural injury may not be appreciated. Use of passive and closed suction drains following lavage has been described, but carry the risk of re-infection.<sup>18,55</sup> Case's of chronic sepsis have been managed by simply opening the cavity to allow passive drainage, and leaving the wound open to heal by second intention.<sup>5</sup> This approach is typically



employed as a salvage procedure and where there is no expectation of a return to athleticism

Surgical endoscopic lavage is considered the gold standard option, allowing superior access for debridement and removal of as much noxious material as possible.<sup>72</sup> The ability to thoroughly evaluate the internal environment permits identification of concurrent injury and therefore the ability to treat and/or offer a more precise prognosis. The technique facilitates high volume lavage via wide bore cannulas with minimal tissue trauma. Pre-operative prediction of the necessity for endoscopy is poor. In one report, only 49% of the endoscopically identified traumatic chondral lesions were predicted pre-operatively, synovial foreign material was accurately predicted in only 15% of the case's in which it was found endoscopically, further recommending this approach for complete lesion assessment and prognostication in every case of sepsis. The reported incidence of post-operative morbidity is low, the return to function more rapid and the prognosis for soundness is reportedly improved compared with alternative lavage techniques.<sup>18,72</sup>

## **II. Antimicrobial Therapy**

Immediate broad-spectrum systemic antimicrobial therapy is advised, with the choice of drugs is made empirically initially.<sup>72</sup> Combinations of drugs are often administered;  $\beta$ -lactam and aminoglycoside drugs are frequently chosen to provide synergetic activity against both gram positive and gram negative bacteria, respectively. Synovial fluid, intra-synovial debris or synovial membrane biopsies may be submitted for microbial culture to allow species identification and antimicrobial sensitivity testing. Even when growth medium

is used, microbial growth is achieved in only 70% of samples. Delivery of effective concentrations to the site of infection is hindered by poor synovial membrane perfusion, which may be compounded by local soft tissue inflammation and trauma, or indeed vascular injury.<sup>5,34</sup>

Alternative administration routes aimed to achieve higher local concentration have been described and used to complement systemic therapy. Some clinicians elect to use multiple alternative methods simultaneously.<sup>5,34</sup>

- i. Direct intra-synovial administration is a simple method of delivering very high concentrations of antimicrobials to the site of infection, and with less risk of systemic side effects. A single injection of 150mg gentamicin achieves synovial fluid concentrations 400 times greater than systemic intravenous administration of the drug at 6.6mg/kg once daily.<sup>73</sup> Spectrum of activity is obviously very important; however, preference is given to drugs with the minimum potential to generate synovitis. Concentration-dependent antimicrobial drugs lend themselves particularly well to this route of administration. The aminoglycosides, gentamicin and amikacin satisfy these criteria, as well as providing potent gram negative bactericidal activity, they are therefore commonly chosen empirically for this purpose. Time-dependent antimicrobials, such as cephalexin have been used and with reported success.<sup>5</sup>
- ii. Antimicrobial-impregnated delivery systems may be implanted within or in close proximity to the synovial cavity, usually in order to create depot and achieve high concentrations within the adjacent tissues.

Polymethylmethacrylate (PMMA) is a non-biodegradable, high density plastic, easily made by combining a liquid monomer and powder polymer, then moulded into beads. During mixing, an antimicrobial may be added, which then elutes from the implant in a biphasic pattern. Approximately 5% is released within the first 48 hours, and the remainder over a period of years.<sup>5</sup> With time the implant becomes encapsulated, but can reportedly maintain therapeutic drug levels with the surrounding 2-3mm of soft tissues despite this. Careful placement is important to avoid interference with function or structural injury. Removal is usually necessary, as paradoxically, the implant can become a nidus for persistent infection. Biodegradable substances, such as chitosin, hydroxyapatite and collagen may also be used, and offer the considerable advantage of avoiding an additional procedure for removal, and are generally more biocompatible than PMMA whilst *in situ*. Typically, they elute the drug more rapidly and maintain a more consistent concentration than PMMA. Bovine collagen sponges and membranes are commercially available, with or without gentamicin impregnated, and have been shown to produce drug concentrations 15 times greater than PMMA within the first 24 hours.<sup>32</sup> These may be used to pack tissue defects adjacent to synovial cavities where they can function to obliterate dead space, promote haemostasis, provide a local depot of antimicrobial drug and form a scaffold for tissue repair. Implantation within the synovial cavity has also been reported, with apparent success.<sup>64</sup> The rate of drug elution and collagen resorption is dependent on local blood flow.

iii. Regional perfusion techniques are used to deliver high concentrations of antimicrobials to areas in the distal limbs, with a tourniquet placed proximal to the site of interest. Intravenous regional perfusion (IVRP) involves administration via a peripheral vein, using slow delivery, the vascular tree is gradually distended and the tourniquet is then left in place for approximately 30 minutes (when performed under standing sedation).<sup>13,43,54,63</sup> The perfusate consists of the chosen antimicrobial and typically one third the systemic dose diluted in sterile saline. Addition of local anaesthetic drugs to the perfusate can improve patient tolerance of the procedure, however regional perineural anaesthesia is more effective.<sup>5,43,47</sup> Studies have shown that IVRP results in antimicrobial concentrations 12 times the MIC for the bacterial species most commonly isolated from orthopaedic infections, for at least 36 hours.<sup>43</sup> Alternatively, intraosseous perfusion (IP) delivers the drug directly to the highly vascular medullary cavity, via a drilled unicortical portal. Comparison of this technique with IVRP demonstrated accumulation of greater drug concentrations with the latter. Additionally, the incidence of serious complication with IP appears higher,<sup>8</sup> and osseous necrosis has been reported.<sup>46</sup> IVRP is generally preferred, however IP with in-dwelling catheters may be more feasible than repeated venepuncture or maintenance of intravenous catheters in foals.<sup>63</sup>

### **III. Bandaging**

Post-operative protection of the surgical sites with bandages, whether they are arthroscopic portals or open draining incisions, is considered mandatory to

encourage healing and prevent ascending infection.<sup>5,72</sup> Similarly, resolution of traumatic wounds is encouraged by maintaining an environment which promotes healing and limits movement. Counterpressure with bandaging is also suggested to reduce pain, and contribute to resolution of soft tissue infection and inflammation.<sup>45</sup>

#### **IV. Hyaluronan**

Post-lavage intra-synovial hyaluronan is reported to aid restoration of homeostasis. In an experimental study, it was found to improve clinical signs, synovial fluid cytological parameters and synovial membrane histological appearance.<sup>34</sup>

#### **V. Analgesia**

Comfort level is frequently used, though not completely reliably, as an indicator of response to therapy. Many clinicians elect to withhold analgesia beyond the immediate perioperative period to allow monitoring for recurrence or persistence of discomfort.<sup>72</sup> Pain can persist in the absence of sepsis in case's where other injury is concurrently involved. Uncontrolled orthopaedic pain is associated with life-threatening complications such as laminitis and caecal impaction. Provision of sufficient pain-relief is therefore considered important in contributing to successful case outcome but also in maintaining welfare. The most commonly administered analgesics are as follows:

- i. As well as effective analgesia, non-steroidal anti-inflammatory drugs (NSAID's) offer the additional (and in some instances the more relevant)

benefit of potent anti-inflammatory activity, mediated by cyclooxygenase (COX) inhibition. Experimental models have demonstrated reduced leucocyte and prostanoid synovial fluid levels following NSAID administration in horses. Positive effects on wound healing have also been reported.<sup>42</sup> The safety threshold for many of the NSAID drugs is low, and monitoring for signs of gastro-intestinal and renal toxicity, associated with COX inhibition is important in horses. The risk of side-effects is particularly higher in dehydrated animals.<sup>5</sup>

- ii. Opiate analgesia may be necessary in severely painful case's where the risk of contralateral limb complications must be considered. Continuous systemic administration, alone or in combination with other analgesics (e.g.  $\alpha$ -2 agonists, lidocaine), with infusion pumps can be used to maintain a constant plane of analgesia.<sup>5</sup> There is controversy regarding the potential for gastro-intestinal side-effects associated with systemic administration, with some studies suggesting a link with intestinal impaction.<sup>5</sup> Transdermal administration with potent opioid patches can be effective, however there are inconsistencies in absorption in animals with thicker skin. Epidural administration is effective for hindlimb pain, with the additional benefit of minimising the risk of systemic side effects.<sup>5</sup>

## **VI. Exercise and Physical Therapy**

Movement is essential for restoring synovial homeostasis.<sup>19,45</sup> Early movement is particularly advocated following tendon sheath or bursa synovial sepsis.<sup>39,45,59</sup> Where the inflammatory processes create an environment which

promotes fibrous adhesion formation, particularly in the presence of any intra-synovial soft tissue structural damage.<sup>45</sup> Passive exercises may be used in the immediate post-operative period when walking exercise may be contraindicated due to concurrent wound or injury.

## **VII. Arthrodesis**

There are several scenarios where arthrodesis is occasionally performed, as a salvage procedure. Firstly, in case's where sepsis has been successfully treated, but the septic processes have caused such advanced articular destruction that significant joint pain persists.<sup>5,34</sup> This is potentially more likely to arise in case's where there has been chronicity, or where the open arthrotomy has been performed. Secondly, when severe traumatic articular injury has been sustained and involves articular fracture or extensive cartilage damage. Alternatively, case's where the septic process remains refractory to conventional treatments, aggressive debridement of the articular tissues followed by arthrodesis has been used. Concurrent use of cancellous bone graft may be beneficial.<sup>6</sup>

### 1.2.3 Prognosis

Reported survival rates following endoscopic lavage treatment range from 89-100%, and rates of return to pre-injury levels of athletic activity range from 40-89%.<sup>3,18,54,72</sup> The prognosis for survival is poorer when multiple synovial structures are involved,<sup>18,54</sup> with sepsis of the navicular bursa reported as a particular negative prognostic indicator.<sup>18</sup> There are numerous case reviews and anecdotal reports documenting the negative effective of delaying treatment.<sup>3,14,15,16,18,31,37,71</sup> Reports published in the 1980's suggested that the prognosis was likely to be considerably poorer if treatment was delayed beyond 7 days.<sup>3,15,16</sup> Surprisingly however, the association with time has not been a consistent finding and some studies have failed to identify any statistical significance.<sup>19,54,59,63,72</sup> To avoid misinterpretation, careful analysis of these data sets is advised, a matter which has been advocated by some of the author's, as there are typically a considerable number of confounding variables.<sup>54</sup> Importantly, compared with the reports showing a significant association, these reports typically involve a shorter average delay in treatment, with a greater proportion of case's treated within 7 days. As these reports were all published within the past 13 years, this may be the result of greater clinician awareness of the generally accepted approach to treat synovial sepsis promptly. Despite the lack of statistical significance, most of the author groups maintain the dogma that early treatment is important and offers the optimum opportunity for a successful outcome.<sup>18,54,72</sup> Tendon sheath sepsis has been found to carry a better prognosis for survival than septic arthritis.<sup>56</sup> Cartilage injury as a consequence of sepsis may explain this difference. In severe case's subchondral bone infection can occur, which



allows persistence of the infection.<sup>72</sup> Synovial sepsis affecting forelimb structures is reportedly associated with a poorer prognosis for performance,<sup>54</sup> which has been suggested to be related to the greater weight borne by the forelimbs and therefore the consequence of any complications may be more severe.<sup>52</sup>

## **1.3 Synovial Sepsis of the Navicular Bursa**

### **1.3.1 Introduction**

First described and reported at the turn of the 20<sup>th</sup> century, the condition was very probably most common in the pre-industrial era.<sup>9,41</sup> Working horses in urban areas were at greatest risk and the condition became colloquially known as a 'street nail' because it was typically caused by solar penetration with nails literally found on the streets. The condition remains relevant however, and despite major advances in diagnostics and therapeutics, rates of recovery remain consistently poorer than those reported for sepsis of any other synovial structure.<sup>18,28,70,72</sup>

### **1.3.2 Aetiopathogenesis**

Sepsis of the NB is most often encountered following a deep solar penetrating injury with a foreign object, most commonly reported objects include nails, screw, glass and wood.<sup>31</sup> Less commonly it may be the result of a distal limb penetrating wound or rarely due to iatrogenic infection following bursa injection.<sup>26</sup> The site of all traumatic solar punctures is reasonably consistent, as they are most likely to occur through the more pliable frog tissue, typically at the central or collateral sulci of the frog.<sup>18,62,58,70</sup> Those occurring within the palmar/plantar region are reportedly more likely to involve NB entry. The direction and depth of penetration is highly variable however. Reports suggest that puncture of the central sulcus >2.6cm, in an adult horse, will involve DDFT penetration and >3.2cm will result in NB entry.<sup>62</sup> Depending on the trajectory, injury to the navicular bone and its supporting ligaments, P3, the DIPJ and

DFTS may also occur. Concavity of the palmar/plantar surface of P3 may encourage NB penetration, as the foreign body is directed proximally, toward the NB.<sup>23</sup> Due to the arrangement of structures within the foot, NB sepsis represents a uniquely complicated condition, which almost always involves multiple concurrent injuries. Penetration of the entire depth of both the digital cushion and DDFT is inevitable when NB contamination occurs. The most commonly reported complex of injuries involves DDFT penetration and DFTS contamination, with attendant risks of septic tendonitis and synovial sepsis respectively.<sup>72</sup>

### **1.3.3 Diagnosis**

Plain radiography may be diagnostic if the penetrating foreign body is metallic and remains *in situ*. The position of a penetrating solar body may be misleading however, as it is possible for multiple penetrating tracts of differing trajectory to be created, as the horse loads and off-loads the limb. The dense collagenous frog horn collapses on removal of the body, making tract identification difficult.<sup>58</sup>

Synoviocentesis followed by cytological analysis of aspirated fluid can provide definitive evidence of sepsis. Aspiration of fluid from the NB can be challenging and radiographic guidance may be required.<sup>57</sup> Fluid collection may not be possible in acute case's if the NB is open and draining or in chronic case's where the NB contains mostly inflammatory debris and/or adhesions. NB distension with fluid can demonstrate egress via any patent penetrating tracts. Positive contrast radiographic bursograms can reveal communicating tracts and/or any NB capsular disruption.

MRI allows identification of collapsed penetrating tracts, and offers the advantage of assessment of adjacent soft tissue structures, most notably the DDFT.<sup>66</sup>

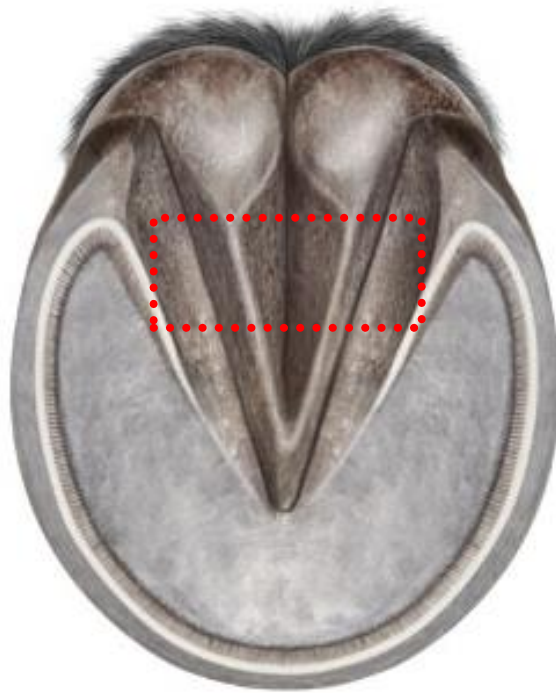### **1.3.4 Treatment**

Conservative management of NB sepsis is considered futile.<sup>40</sup> Antimicrobial therapy is an important, but generally considered an adjunct in the necessarily intensive treatment regimen. Surgery has long since been deemed essential in NB sepsis,<sup>22,31,50,62,70</sup> and various techniques have been described over time.

#### 1.3.4.1 Surgical treatment options

##### I. Surgical Bursotomy

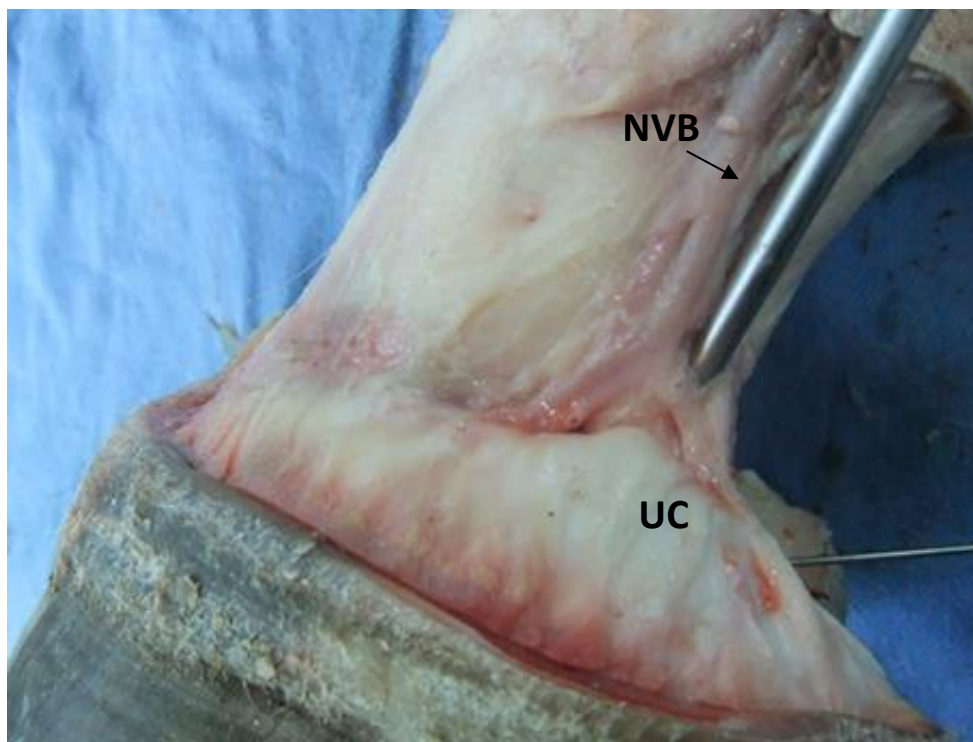Historically, solar penetration was managed via surgical bursotomy, colloquially known as a 'street-nail' procedure. This involved resection of up to two thirds of the central portion of the frog and digital cushion (Figure 4).<sup>40</sup> An open bursotomy was then performed by fenestrating the exposed DDFT, allowing debridement of any diseased tendon. This provided access for debridement and lavage of the NB, which was then left open to drain.<sup>40,50</sup> The period of convalescence was protracted and morbidity rate high. The procedure was typically employed for salvage, as the prognosis for soundness was very poor. Satisfactory postoperative outcome was reported in just 33-35%.<sup>5</sup>



*Figure 4. Resection of an approximately 7.5 x 2 cm area of frog and digital cushion (delineated by the dotted line), at the junction of the middle and palmar/plantar thirds of the frog was advised to adequately expose the DDFT.<sup>40</sup>*

## II. Surgical Endoscopy: Direct Approach

A minimally invasive endoscopic technique using a direct approach (DA) to the NB was first described in 1999.<sup>70</sup> The author's reported 16 case's of NB sepsis treated endoscopically, via a portal just proximal to the unguar cartilage (Figure 5). Postoperative morbidity was minimal and the horses required little analgesia. Compared with case's treated with open bursotomy, the duration of hospitalisation and rehabilitation were considerably reduced.<sup>70</sup> Most notably, case outcome was markedly improved, with 10 horses (62.5%) returning to pre-operative levels of activity. Endoscopic lavage via the DA is now the accepted treatment for horses with septic navicular bursitis.<sup>38</sup>



*Figure 5. Cadaver specimen demonstrating the position of the endoscope cannula relative to the neurovascular bundle (NVB) and unguar cartilage (UC), when placed via the direct approach (DA).*

### III. Surgical Endoscopy: Transthecal Approach

More recently, an indirect transthecal approach (TA) to the NB via the DFTS has been described.<sup>10,21,39,53,60,61</sup> A comparison of the TA with the DA has demonstrated superior visualisation within the NB (80% compared to 60%), particularly within the proximal portion, lower incidence of iatrogenic damage to the navicular bone fibrocartilage and DDFT, and reduced frequency of inadvertent penetration of the DIPJ.<sup>21</sup> As such, the TA has been accepted by many surgeons as the routine technique for elective exploration of the NB.<sup>39,60,61</sup> Because the TA involves an additional synovial structure, it has typically been reserved for non-septic bursae and avoided in case's of synovial sepsis.

#### 1.3.4.2 Adjunctive therapies

Farrriery can play an important role in the post-operative convalescence. Hospital plates are applied to protect the site of penetration and hold packing in place in case's with solar defects following penetrating injury. In all case's, heel elevation may improve horses comfort by reducing tension on the DDFT, which will in turn reduce compression of the inflamed NB.<sup>58,68</sup>

Intra-synovial medication with anti-inflammatory drugs may be used in the postoperative period.<sup>5</sup> Residual lameness, despite resolution of sepsis, may be attributable to ongoing aseptic bursitis. Resolution of the inflammatory processes may be expedited, and the associated pain may be ameliorated by direct injection of corticosteroid. Prior confirmation of asepsis by NB synovial fluid analysis is indicated if there is any suspicion of persistent sepsis.<sup>72</sup> Intra-



synovial hyaluronan is suggested to reduce the risk of adhesion formation, which may be of particular benefit where there is significant intra-bursal structural damage (i.e. DDFT, fibrocartilage).<sup>34</sup>

The location of the NB makes it very amenable to IVRP techniques. The author's of the original endoscopic technique (the DA) used IVRP for some of the reported case's and suggested that this may have made a positive contribution to the successful case outcome.<sup>70</sup> Packing the bursa with antimicrobial impregnated cancellous bone graft has been attempted as an adjunctive treatment, but with little success.<sup>22</sup>

### 1.3.5 Prognosis

Prior to the advent of any surgical endoscopic techniques for NB examination, Richard *et al.* reported 34 case's of NB sepsis treated with open bursotomy.<sup>50</sup> The author's recorded any horse servicably sound to perform a function such as breeding to have had a 'satisfactory outcome'. Of the 15 surviving case's, 12 were included in the 'satisfactory outcome' category. Author's of subsequent reports used similar categorisation to allow comparison of outcome measures.<sup>22,50,62,70</sup> Severe complications such as DDFT rupture and DIPJ subluxation were reported amongst these case's.<sup>50</sup>

Steckel *et al.* reviewed 19 case's which underwent bursotomy, they reported survival of 12 horses (63%), with only half of those resuming athletic activity (31.6% of the cohort).<sup>62</sup> Several years later, Honnas *et al.* reported 6 case's, also treated via bursotomy but with the addition of a cancellous bone graft used to pack the surgical site.<sup>22</sup> In this small study population, 4 survived but only 2 were considered to have a 'satisfactory outcome' (33.3%). Kilcoyne *et al.* reported the most successful outcome, with 4 of 10 case's treated with bursotomy returning to some level of athletic activity.<sup>31</sup> A meta-analysis for these published outcomes following surgical bursotomy indicates survival in 49%, and a return to athletic activity in just 19% (Table 1).

Markedly improved results were documented by Wright *et al.* in 1999,<sup>70</sup> and by Wright in 2004,<sup>69</sup> following treatment with endoscopic lavage via the DA. Survival was reported in 88% and 85% respectively, and 'satisfactory outcomes' in 75% and 79% respectively. Successful return to athletic activity was reported in 63% and 71% of the case's (respectively). Information of perhaps greater pertinence was provided by these author's, as they recorded

the horse's ability to resume pre-injury levels of athletic function, reportedly 63% and 59% in their respective cohorts.

In a recent larger multicentre study, Findlay *et al.* reported less successful results for horses with NB sepsis following endoscopic lavage.<sup>18</sup> Unfortunately details of the surgical approach were not specified however. Of the 86 horses with follow up data, only 45 survived long term, a considerably lower survival rate at 52%. Similarly, the number of horses returning to athletic activity was lower, with 45% of the total number capable of athletic activity, and only 34% resuming pre-injury level of activity.

The cause of the stark contrast in outcomes may be multifactorial. The more favourable outcomes reported by Wright *et al.* and Wright may be at least in part a reflection of the considerably smaller study populations (16 and 34 case's).<sup>69,70</sup> The greater population size in the Findlay *et al.* study may be a more reliable representation of the expected prognoses. As previously recognised, and identified once again in the Findlay *et al.* study, increasing time interval between injury and treatment was a negative prognostic indicator for survival and soundness in that cohort. Multivariable analysis identified an odds ratio of 1.2 for horses being unable to return to pre-injury activity, for each additional day treatment was delayed.<sup>18</sup> Despite this finding, the median time in the Findlay *et al.* study was notably shorter than that for the Wright *et al.* however.<sup>18,70</sup>

The author's of an MRI based study reported that solar penetrations in the central to palmar/plantar region of the frog were associated with poorer prognosis.<sup>66</sup> This was corroborated by Findlay *et al.* where this location was once again identified as a negative prognostic indicator.<sup>18</sup>

### **1.3.6 Differences in the studies**

Although, the overall prognoses for survival and functionality have considerably improved since the first reports, they remain notably poorer than the documented prognoses associated with synovial sepsis in other structures, as discussed earlier. The prognosis for survival in case's of NB sepsis is poorer when there is concurrent DIPJ sepsis.<sup>58</sup> With such an injury, the DSIL is frequently disrupted and it has been suggested that injury to this richly innervated structure results in persistent lameness.<sup>58,67</sup>

	<b>Survival</b>	<b>%</b>	<b>Satisfactory Outcome</b>	<b>%</b>	<b>Athletic Function</b>	<b>%</b>	<b>Pre-Injury Activity</b>	<b>%</b>	<b>Hospital (mean days)</b>	<b>Days</b>	<b>Authors</b>
<b>Bursotomy</b>											
	15/34	44	12/34	35	4/34	12	-	-	45	Mean 17	Richardson <i>et al</i> <sup>50</sup>
	10/19	53	10/19	53	6/19	32	-	-	-	Mean 44	Steckel <i>et al</i> <sup>62</sup>
	4/6	67	2/6	33	2/6	33	-	-	-	-	Honnas <i>et al</i> <sup>22</sup>
	-	-	-	-	4/10	40	-	-	-	-	Kilcoyne <i>et al</i> <sup>31</sup>
	29/59	49	24/59	41	11/59	19	-	-	-	-	Meta-Analysis
<b>Endoscopic Lavage</b>											
<b>DA</b>	14/16	88	12/16	75	10/16	63	10/16	63	17	Mean 13	Wright <i>et al</i> <sup>70</sup>
<b>DA</b>	29/34	85	27/34	79	24/34	71	20/34	59	20	-	Wright <sup>69</sup>
<b>Not reported</b>	-	-	-	-	2/3	67	-	-	-	-	Kilcoyne <i>et al</i> <sup>31</sup>
<b>Not reported</b>	45/86	52	-	-	39/86	45	29/86	34	11	Median 2	Findlay <i>et al</i> <sup>18</sup>

Table 1. Meta-analysis for the published outcomes following surgical treatment for NB sepsis.

## **Chapter 2.**

### **Navicular bursa surgical approach overview**

#### **2.1 Comparison of the surgical endoscopic approaches to the NB**

NB surgery has previously been well investigated, there are numerous publications reporting the use of the DA in cadaveric specimens, live research horses and clinical case's.<sup>10,21,39,53,60,61</sup> The literature also contains several reports detailing the use of the TA in horses with non-septic conditions affecting the NB.<sup>60,61</sup> Haupt and Caron conducted an excellent cadaveric study directly comparing the DA and TA, with the specific aims of comparing the visibility and the incidence of iatrogenic structural damage between the 2 techniques.<sup>21</sup> Whilst both iatrogenic damage to the navicular bone fibrocartilage and DDFT occurred during endoscope cannula placement with each of the techniques, the DA was found to pose considerably greater risk, with DDFT damage reported in almost every specimen (see Table 2). The TA afforded visualisation of a greater proportion of the proximal recess of the NB than the DA, though access to the distal portion was limited with the TA. This may influence the surgeon's technique choice depending on the known or anticipated location of the lesion. The section of DDFT within the proximal recess is a predilection site for dorsal border lesions and secondary adhesions,<sup>60</sup> therefore the TA may provide superior access for debridement of such lesions, which are likely to be identified on pre-operative MRI. Solar penetrating injuries can enter the bursa anywhere, but are reported to most

commonly enter distally,<sup>18,58,62</sup> and therefore access to debride the site of penetration may be optimised using the DA. In most case's, pre-operative imaging would assist in this decision making process. Haupt and Caron also reported inadvertent entry into the DIPJ with both techniques, the frequency was greater using the TA however, with which it occurred in almost half of the specimens.<sup>21</sup> Intentional entry into the DFTS is a pre-requisite of the TA, however inadvertent DFTS entry was reportedly 'quite common' using the DA. Whilst the frequency was not reported, the author's discussed the potential consequences were this to occur when treating NB sepsis.<sup>21</sup> These risks of inadvertent penetration of adjacent synovial structures had previously been documented by Rossignol.<sup>53</sup> As a result, some author's have recommended lavage of the DFTS when endoscopy has been performed in the management of navicular bursa sepsis.<sup>58</sup>

	<b>DDFT damage</b>	<b>Fibrocartilage damage</b>	<b>DIPJ entry</b>	<b>DFTS entry</b>	<b>Visualisation (mean)</b>	<b>Mean Time (min)</b>
<b>DA</b>	93.75%	75%	31%	Occurred	60%	1.21
<b>TA</b>	68.75%	18.75%	43%	-	80%	2.09

*Table 2. Summary of findings reported by Haupt and Caron following comparison of the DA and TA to the NB.<sup>21</sup>*

## **2.2 Rationale for using the transthecal approach (TA) for endoscopic treatment of NB sepsis**

Despite these reports, the DA has remained the accepted standard approach for treating NB sepsis.<sup>39</sup> To the author's knowledge, there are no reports in the literature of horses developing iatrogenic infection of the DFTS or DIPJ as a result of contamination during treatment of NB sepsis. Some author's have suggested that any communication created during cannula placement does not remain patent, preventing transference of microorganisms and infected material.<sup>39</sup> However, there are anecdotal reports of case's where post-operative DFTS and/or DIPJ infection were believed to have occurred as a result of iatrogenic contamination during endoscopic treatment of NB sepsis (including the author's personal experience). Typically, pre-operative analysis of synovial fluid from the relevant structure had confirmed asepsis, and antimicrobial drugs had been administered on synoviocentesis. Persistent post-operative lameness and progressive DFTS and /or DIPJ effusion had prompted repeat synoviocentesis, with analysis revealing evidence of sepsis. Whether NB sepsis had remained persistent, or not, varies amongst such anecdotal reports. The method of transference of sepsis was not determined in any instance. Logically it could be suggested that there is potential for contamination to occur either during initial placement of the cannula and obturator assembly, or during the repeated withdrawal and replacement of contaminated instruments through the penetrated synovial structures along the instrument tract, during the surgery. Alternatively, any instrument tracts



penetrating the DFTS or DIPJ could provide a route for extension of any persistent septic processes post-operatively, whether the tract is patent or not.

Concurrent sepsis of more than one synovial structure has been recognised as a negative prognostic indicator, and it is logical to strive toward avoiding contamination of healthy synovial structures during the management of established sepsis.<sup>18,72</sup> As such, there is understandable reluctance to use the TA in NB sepsis management when the DFTS is non-septic, and such a practice has not been reported. As discussed above, the DA may not be as safe as previously considered,<sup>10,21,53</sup> and the very reason for its use in sepsis could be questioned. Using the TA should carry lower risk of iatrogenic injury to the DDFT and fibrocartilage during any surgery. Specific to its application in sepsis management, it may offer other potential advantages. Assuming the fenestration between the NB and DFTS remains patent, postoperative synoviocentesis and intrasynovial antimicrobial medication of the NB could be performed via the DFTS. This has the potential to offer a simpler and safer method of post-operative monitoring and further treatment.

### 2.3 Study Objectives

1. To determine the frequency of inadvertent penetration of the DFTS and DIPJ when making a DA to the navicular bursa in cadaver limbs.
  - Secondary Objectives:
    - i. To determine the frequency of iatrogenic damage to the DDFT and fibrocartilage.
    - ii. To compare the frequencies of inadvertent synovial penetration and iatrogenic damage amongst different surgeons.
    - iii. To propose an alternative DA to the NB.
  
2. To report the management and post-operative outcome of clinical case's of NB sepsis treated using the TA for NB endoscopy and post-operative IVRP with amikacin.
  - Secondary Objective:
    - i. To compare case outcome with previously reported outcomes where the DA was employed.
  
3. To determine the concentration of amikacin accumulated in synovial fluid following IVRP in case's of clinical synovial sepsis.

## **Chapter 3.**

# **Investigation of the Frequency of Inadvertent Synovial Penetration When Using a Direct Endoscopic Approach to the Navicular Bursa**

## **3.1 Introduction**

As previously discussed, the described DA remains the standard technique for treatment of NB sepsis for many surgeons. Three previous studies have reported the potential for inadvertent synovial penetration of the DFTS and/or DIPJ during placement of the endoscope cannula using the DA.<sup>10,21,53</sup> Haupt and Caron were the only author's to quantify the frequency of DIPJ entry, which reportedly occurred in 5 of 16 cadaver limbs.<sup>21</sup> The frequency of inadvertent penetration of the DFTS has not been reported. The primary objective of this study was therefore, to record the frequency of DFTS and DIPJ penetration. Secondary objectives included recording the frequency of structural damage and comparison of these frequencies amongst a group of surgeons. During the study, an additional objective arose, which was to describe an alternate direct approach (ADA) to the NB.

### **3.2 Hypotheses**

It was hypothesised that the risk of inadvertent penetration of the DFTS or DIPJ would be greater than 10% and that this frequency would vary amongst surgeons.

It was subsequently hypothesised that the ADA would result in a lower frequency of inadvertent synovial structure penetration.

### **3.3 Materials**

Forty cadaver limbs were collected from horses at an abattoir, specific details of age, sex and breed were therefore not available. The cohort consisted of 8 limbs from ponies, 4 limbs from a draft-type horse and the remainder were of Thoroughbred-type. Forelimbs were removed at mid-radius level and hind limbs were removed mid-tibia. The limbs were frozen and stored at -20°C, then thawed at room temperature for 24 hours prior to use.

## **3.4 Methods**

### **3.4.1 Pilot Study**

Because the likely frequency of DFTS and/or DIPJ penetration was unknown, a pilot study was performed by 2 of the surgeons on 8 cadaver limbs. Each of the 2 surgeons performed the procedure, as described below, on 2 forelimbs and 2 hind limbs, with contralateral limb pairs divided between surgeon. The main test sample consisted of 20 paired forelimbs and 20 paired hind limbs, which were divided between the surgeons, such that each surgeon carried out the procedure on 5 forelimbs and 5 hind limbs. Different surgeons performed the procedure on contralateral limbs and there was an even spread of left and right limbs between surgeons. The surgeon group comprised 2 equine surgeons board-certified by the European College of Veterinary Surgeons (8 and 5 years certified), a residency-trained surgeon and a surgical resident, each of whom was experienced in equine endoscopic technique and had performed the DA in clinical case's.

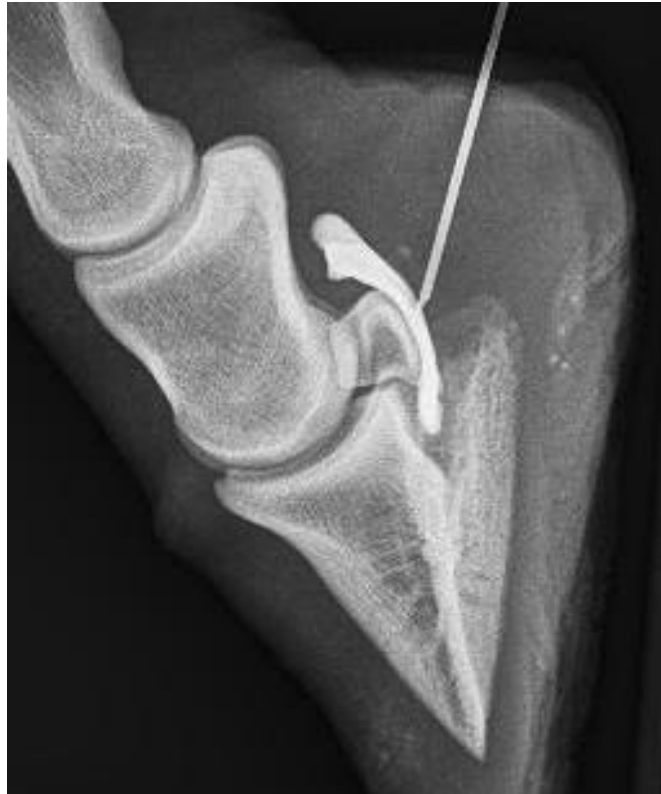### **3.4.2 Test Procedure**

The test procedure was divided into 5 distinct parts as follows:

#### **I. Pre-endoscopy positive contrast navicular bursogram**

A palmar/plantar approach to the "navicular position" was used to place a needle within the navicular bursa.<sup>57</sup> With the digit held in flexion, an 18g 90mm styletated spinal needle was introduced between the heel bulbs, just proximal to the coronary band, and advanced sagittally aiming for a point halfway

between the most dorsal and palmar/plantar aspects of the coronary band, and 0.5cm distal to the coronary band, until the needle contacted the navicular fibrocartilage. The navicular bursa was then maximally distended with a mixture of 2ml of tap water and 2ml of the iodine based, radiographic positive contrast material, iohexol (Omnipaque™ 300mg/ml, GE Healthcare AS, Oslo, Norway). This was performed by the same surgeon in every limb, using a 5ml syringe, until intra-bursal pressure prevented further fluid ingress. A closed 3-way tap was attached to the needle, and the needle left *in situ* for the rest of the procedure. A lateromedial radiograph was made to confirm correct needle placement and ensure there were no pre-existing communications with the DFTS and/or DIPJ (Figure 6). Limbs with pre-existing communications were excluded from the rest of the study.



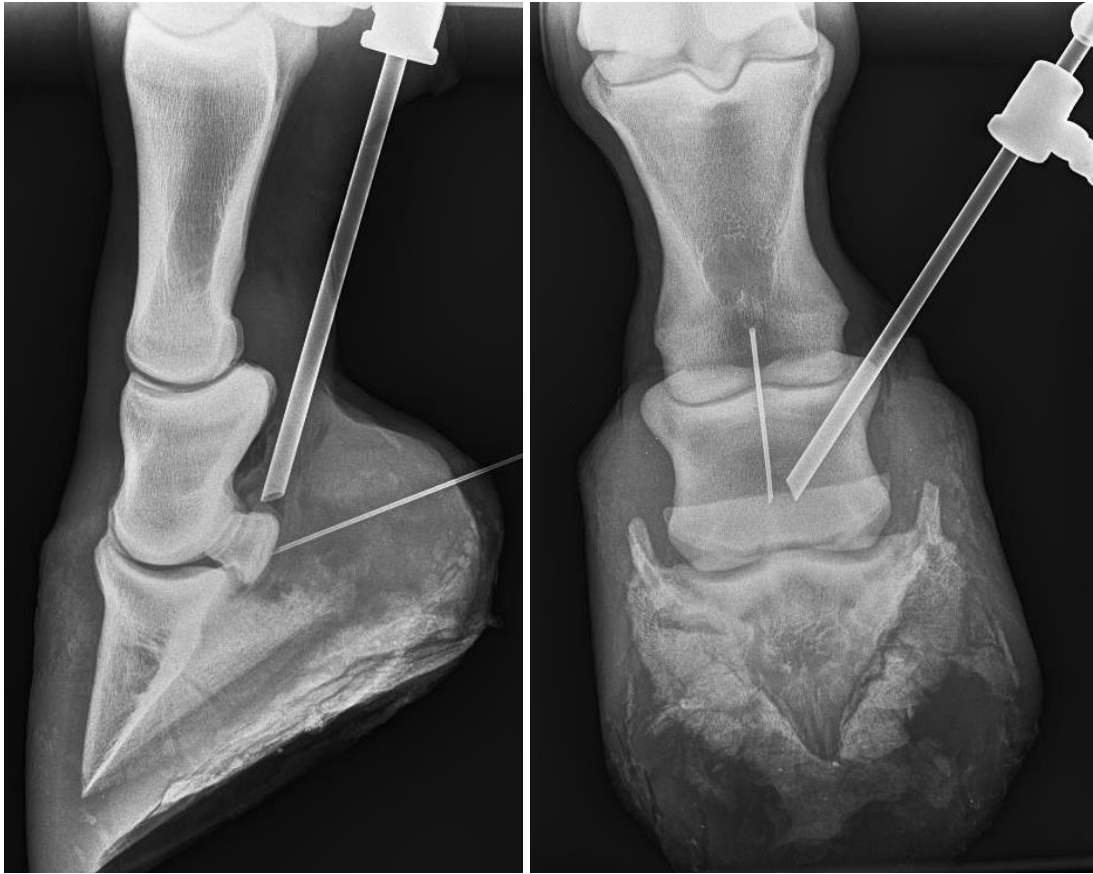*Figure 6. Pre-endoscopy positive contrast navicular bursogram confirming absence of communication between the NB and DIPJ and/or DFTS.*

## II. Endoscope placement using the DA

Limbs were placed with the lateral aspect uppermost and the distal limb positioned neutrally to allow manipulation. Using the description by Wright *et al* as a guide, a DA to the NB was made as follows: a 5 - 7.5mm skin incision was made using a No. 11 scalpel blade on the palmaro-/plantaro-lateral aspect of the limb, just proximal to the ungular cartilage, axial to the palmar/plantar digital neurovascular bundle and abaxial to the lateral margin of the DDFT.<sup>70</sup> An endoscope cannula and blunt obturator assembly (Karl Storz GmbH, Tuttlingen, Germany) were introduced and advanced distally and axially

toward the mid-sagittal aspect of the heel bulbs, aiming to enter the NB at the mid-point of the middle phalanx (P2). Care was taken to ensure the cannula was dorsal to the DDFT before advancement, at which point the distal limb was held in extension. Fluid distension of the NB was maintained with ingress of tap water with a 20ml syringe and the previously placed spinal needle. A sudden loss of resistance and egress of fluid from the cannula occurred on entry to the NB. The obturator was replaced with a 4mm 30° forward-oblique arthroscope (Karl Storz GmbH, Tuttlingen, Germany) and NB distension maintained with tap water ingress via the spinal needle to allow intra-bursal examination (Figures 7 and 8). Successful entry to the NB was confirmed by visualisation of the pre-placed spinal needle, the navicular bone fibrocartilage, dorsal surface of the DDFT and the characteristic intervening synovial plicae, which form the abaxial borders of the NB. The number of attempts required to gain successful entry was recorded, each re-direction and advancement of the cannula and obturator counted as an additional attempt. Any evidence of iatrogenic damage to the navicular bone fibrocartilage or the DDFT, identified on endoscopically, was also recorded.





*Figures 7 and 8. Lateromedial and dorsopalmar radiographs of one of the cadaver specimens, illustrating the position of the obturator and cannula assembly within the NB (included for illustrative purposes only).*

### III. Endoscope placement: Alternate direct endoscopic approach

The results of the testing indicated that one of the surgeons had inadvertently penetrated the DFTS and/or DIPJ significantly less frequently than any of the others (see Results). On review of that surgeon's technique, it was apparent that a modification of the described DA had been used. The endoscope cannula and obturator assembly was inserted from the described skin incision and advanced distally in a parasagittal plane, parallel to the DDFT, rather than directing it towards midline, as the published description dictates.<sup>70</sup>

To examine whether a lower frequency of DFTS and/or DIPJ penetration could be obtained with this modified technique, termed the ADA, using a different trajectory, 6 additional pairs of cadaver limbs were divided between 2 of the other surgeons, such that contralateral limbs were divided between them. The test procedure (steps 1-5), as described above, was repeated, except that the cannula and obturator assembly was advanced in a modified trajectory to aim distally along a straight parasagittal plane toward the lateral aspect of the NB.

### IV. Synovial distension to evaluate DFTS and/or DIPJ involvement

Following removal of the endoscope and cannula, the DFTS was distended with tap water, using an 18g 40mm needle, placed on the lateral aspect of the limb, just distal to the proximal sesamoid bone.<sup>1</sup> Distension of the DFTS was continued until intrathecal pressure prevented further ingress, or egress was observed from the endoscope portal skin incision or the spinal needle in the NB. Fluid was allowed to drain passively from the needle until pressure in the DFTS had subsided prior to needle removal.

The DIPJ was distended with tap water via an 18g 40mm needle placed in the dorsal pouch on dorsal midline 1cm proximal to the coronary band. Distension was continued until intra-articular pressure prevented further ingress, or egress was observed from either the endoscope portal skin incision or the needle in the NB. Fluid was then allowed to drain passively from the needle until pressure in the DIPJ had subsided prior to needle removal. All incidences of fluid egress confirming iatrogenic penetration of the DFTS or DIPJ were recorded.

V. Post-endoscopy positive contrast navicular bursogram

The skin incision was closed with a single cruciate nylon suture, apposing the skin edges under tension. The NB was injected via the pre-placed spinal needle with approximately 4ml iohexol and 4ml of tap water prior to making a lateromedial radiograph. Any egress from the skin incision was blotted with tissue paper and the incident recorded. The radiographs were reviewed and the location of contrast recorded. In case's where the dissemination of contrast material could not be clearly defined from the first radiograph, an additional 4ml of iohexol and 4ml of tap water were injected and another lateromedial radiograph obtained.

### **3.4.3 Dissection**

A superficial dissection was performed on each limb to examine the neurovascular bundle and ungular cartilage for evidence of iatrogenic trauma (e.g. transection) incurred when making the portal or during placement of the cannula and obturator.

### 3.4.4 Statistical Analysis

To simplify analysis and interpretation, penetration of the DFTS, DIPJ and/or both combined were categorised as “any inadvertent penetration” and all iatrogenic damage to any structure was categorised as “any iatrogenic damage”. Limb number in test sequence was used as a proxy for surgeon experience and termed “test experience”.

A power calculation was performed using the pilot inadvertent penetration frequencies (“any inadvertent penetration”) and a sample size calculator (Epi Info™ 7, Centres of Disease Control and Prevention, GA, USA) using a confidence level of 95% ( $\alpha=0.05$ ) and a power of 80% ( $\beta=0.2$ ). The results were used to determine the number of limbs required for each of the 4 surgeons in the main study.

Frequencies of “any inadvertent penetration”, “any iatrogenic damage” and “number of attempts” made for successful entry to the NB, were compared: between surgeons using Chi squared tests; between forelimb and hindlimb using Chi squared tests; and with “test experience” using regression analysis. In addition, logistic regression was used to examine the magnitude of difference in frequency of “any inadvertent penetration” between surgeons. Associations between frequency of “any inadvertent penetration” and “any iatrogenic damage” as well as “number of attempts” were assessed using Chi squared tests. The association between frequency of “any iatrogenic damage” and “number of attempts” was assessed using a Chi squared test. A Fisher’s exact test was performed to determine whether a significant change in frequency of “any inadvertent penetration” had occurred for the surgeons using

this ADA. Statistical analysis was carried out in Stata12™ (StataCorp LP, TX, USA). Significance was set at  $P < 0.05$ .

## 3.5 Results

### 3.5.1 Pilot

Inadvertent penetration of the DFTS occurred in 75% of limbs (6/8), whilst penetration of both the DFTS and DIPJ occurred in 25% of limbs (2/8) and no inadvertent penetration occurred in 25% of limbs (2/8). Based on an expected inadvertent penetration frequency of between 25% and 75%, using a population size of 40, confidence limits of 5%, with 4 clusters (surgeons), it was calculated that for a 95% confidence level, 9 limbs would be required per cluster and for a 99% confidence level 10 limbs would be required per cluster.

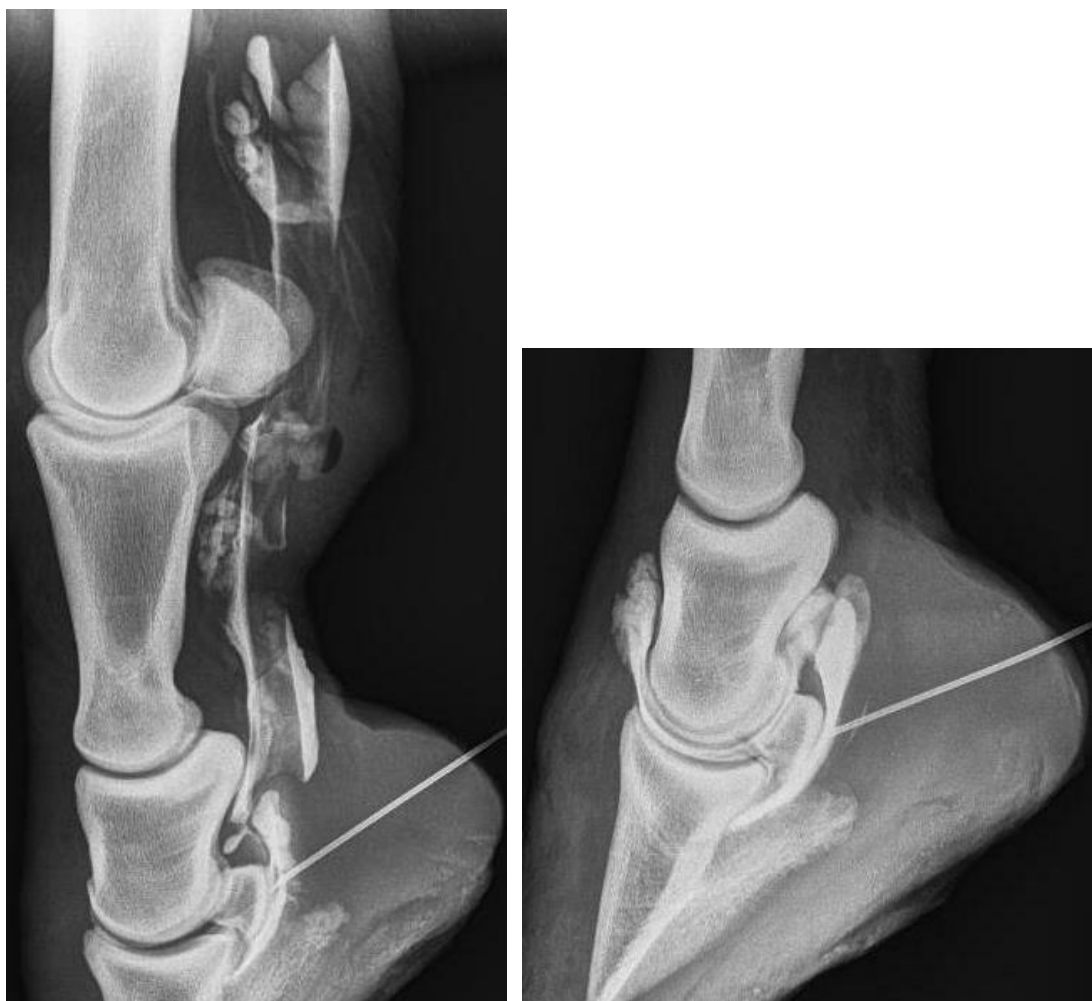### 3.5.2 Main Test Sample

#### DFTS and/or DIPJ Penetration

No pre-existing synovial communications between the navicular bursa and either the DFTS or DIPJ were identified on the bursograms performed prior to the test procedure. Following NB endoscopy, communication between the endoscope portal and the DFTS and/or the DIPJ occurred in 18/40 limbs (45%). Inadvertent synovial penetration was recognised as egress from the endoscopy portal in 16/18 limbs and on the positive contrast radiographs in all 18 limbs (Figures 9 and 10). Structures were penetrated with the following frequencies: the DFTS alone in 11 limbs (27.5%), (5 forelimbs and 6 hind limbs); the DIPJ alone in 3 limbs (7.5%), (1 forelimb and 2 hind limbs); both the DFTS and the DIPJ in 4 limbs (10%), (2 forelimbs and 2 hind limbs). Details of the frequencies of DFTS and/or DIPJ penetration and results of logistic regression analysis comparing frequency of “any inadvertent penetration”

between the surgeons are shown in Table 3. Frequency of “any inadvertent penetration” ranged from 10 to 80% and varied significantly between surgeons ( $P=0.008$ ), with surgeons C and D significantly ( $P=0.035$  and  $0.007$  respectively) more likely to penetrate the DFTS and/or the DIPJ than surgeon A (odds ratio 13.5, 95% C.I. 1.2-152 and odds ratio 36, 95% C.I. 2.7-476 respectively). Frequency of “any inadvertent penetration” did not vary significantly between forelimbs and hind limbs ( $P=1.0$ ); with “test experience” ( $P=0.659$ ); with “number of attempts” ( $P=0.060$ ); or with occurrence of “any iatrogenic damage” ( $P=0.949$ ).





*Figures 9 and 10. Post-endoscopy positive contrast navicular bursogram images illustrating evidence of prior inadvertent synovial penetration resulting in communication with the DFTS (left) and DIPJ (right).*

Surgeon	Synovial structure penetrated				Logistic regression comparison for penetration of the DFTS and/or DIPJ		
	DFTS	DIPJ	DFTS and DIPJ	Any	P-Value	OR	95% CI
<b>A</b>	1	0	0	1		1 (Ref)	
<b>B</b>	2	2	1	3	0.284	3.86	0.33-45.6
<b>C</b>	5	2	1	6	0.035	13.5	1.2-152
<b>D</b>	7	3	2	8	0.007	36	2.7-476

*Table 3. Frequency of DFTS and DIPJ penetration by the surgeons (who each performed the procedure on 10 legs), and results of logistic regression analysis comparing frequency of penetration of the DFTS and/or the DIPJ between the surgeons. OR = odds ratio; CI = confidence interval.*

#### Number of attempts made for successful entry to the NB

Successful entry into the NB was achieved on the first advancement of the cannula and obturator assembly in 18/40 (45%) of the limbs. Second and third attempts were necessary in 11 and 10 limbs respectively, whilst 5 attempts were required in 1 limb. The number of attempts required did not significantly vary between surgeons ( $P=0.728$ ) or between forelimbs and hind limbs ( $p=0.579$ ); or with “test experience” ( $P=0.056$ ).

#### Iatrogenic damage to adjacent structures

Iatrogenic damage to the navicular bone fibrocartilage and/or DDFT occurred in 22/40 (55%) limbs. Damage to the DDFT was identified in 16 (40%) limbs and varied from mild superficial epitenon disruption (12 limbs) to penetrating

lesions (2 limbs). Superficial navicular bone fibrocartilage lesions were observed alone in 12 (30%) limbs. Lesions of both the DDFT and the navicular bone fibrocartilage were observed in 6 (15%) limbs. Table 4 lists the details of the frequencies of iatrogenic damage sustained during endoscope placement between the surgeons. The details of the frequency of inadvertent synovial penetration and iatrogenic damage are shown in Table 5. Frequency of “any iatrogenic damage” differed significantly between the surgeons ( $P=0.008$ ), but did not significantly vary: between forelimbs and hind limbs ( $P=0.525$ ); with “test experience” ( $P=0.66$ ); with frequency of “any inadvertent penetration” ( $P=0.949$ ); or with “number of attempts” ( $P=0.68$ ). Dissections of the arthroscopic portal and proximal cannula tract did not identify evidence of iatrogenic damage to the ungular cartilage or digital neurovascular bundle in any of the limbs.

	Surgeon				Total (n=40)
	A	B	C	D	
No iatrogenic damage	0	7	5	6	18
Iatrogenic damage	10	3	5	4	22
DDFT lesion only	3	2	3	2	10
Fibrocartilage lesion only	2	1	1	2	6
DDFT and Fibrocartilage lesions	5	0	1	0	6

*Table 4. Frequency of iatrogenic damage sustained during endoscope placement between surgeons.*

	No iatrogenic damage	Iatrogenic damage	DDFT lesion	Fibrocartilage lesion	DDFT & Fibrocartilage lesions
No inadvertent penetration	10	12	10	7	5
Inadvertent penetration	8	10	6	5	1
DFTS penetration	7	8	5	4	1
DIPJ penetration	2	5	3	2	0
DFTS & DIPJ penetration	1	3	2	1	0

*Table 5. Frequency of inadvertent synovial penetration and iatrogenic damage. DFTS = digital flexor tendon sheath; DIPJ = distal interphalangeal joint; DDFT = deep digital flexor tendon.*

## ADA

The frequency of “any inadvertent penetration” was significantly lower ( $P=0.024$ ) using the ADA compared to the DA, with no evidence of either DFTS or DIPJ penetration identified in any of the 12 limbs when the ADA was used. There was no iatrogenic damage to the DDFT or navicular bone fibrocartilage apparent in any of the 12 limbs. However, both surgeons concluded that there was subjectively less manoeuvrability of the endoscope and a reduced field of view using this approach. In each limb the endoscope entered the NB laterally, allowing visualisation of this aspect from the proximal point of entry to the distal recess. Examination of the medial aspect of the bursa was limited, particularly proximally.

### 3.6 Discussion

To the author's knowledge this is the first study to quantify the risk of inadvertent penetration of the DFTS and/or DIPJ when using the DA approach to the NB. The study demonstrated considerable risk of inadvertent DFTS (37.5%) and DIPJ penetration (17.5%). The frequencies of inadvertent penetration (particularly of the DFTS) were surprisingly high. Considering the scarcity of anecdotal reports of horses treated for NB sepsis subsequently developing DFTS or DIPJ sepsis, the true incidence of this complication is expected to be very low. In the author's clinical experience, the complication has been observed in <5% of case's. As suggested previously, it is possible that inadvertent penetration does not result in patent communication.<sup>39</sup> Alternatively, the low incidence of complication may be explained by the NB lavage resulting in clearance of sepsis, preventing its spread into surrounding synovial structures. The study confirms that there is considerable risk of inadvertent synovial penetration and the creation of communication between adjacent synovial structures. One might suggest that this should be borne in mind when repeated withdrawal and replacement of contaminated instruments is necessary during NB sepsis treatment, as it may allow transference of sepsis from the navicular bursa.

The very close apposition between the DFTS and NB has previously been suggested to account for DFTS penetration with the DA.<sup>21</sup> The width of the distal extremity of the DFTS is reportedly highly variable, and in some instances located dorsal or abaxial to the neurovascular bundle,<sup>17</sup> suggesting that in some horses it may not be possible to avoid penetration, when using

the digital neurovascular bundle as a landmark. In the current study, more extensive dissection or DFTS endoscopy may have allowed identification of the sites of penetration in the current series.

When Haupt and Caron reported inadvertent DIPJ penetration in 31.2% of their specimens, they concluded that penetration was more likely when contact between the cannula and dorsal DDFT was not maintained during placement.<sup>21</sup> This recommendation was employed by the surgeons in the current study and may have contributed to the lower frequency (17.5%) observed. Differences in study design may also have influenced the outcome, as the DIPJ was distended prior to cannula insertion in the previous study, but not in the current study.<sup>21</sup> The NB was however distended prior to cannula placement in the current study, which potentially facilitating bursa entry. In another investigation, Rossignol and Perrin suggested that inadvertent DIPJ penetration occurred due to insufficient extension of the digit during advancement of the assembly.<sup>53</sup> The surgeons in the current study also observed this precaution, which potentially influenced the results.

The study was performed by 4 surgeons representing a range in level of experience, in order to replicate the clinical setting, where surgeons of variable experience may perform the surgical technique. A smaller group of surgeons performing the procedure a greater number of times may have allowed each surgeon to improve their skill during the study, possibly influencing the results. While “test experience” was not significantly associated with the number of attempts required to successfully enter the NB, an improving trend was observed, which may have reached significance if a greater number of limbs had been used per surgeon. Level of surgical experience was not well

correlated with frequency of inadvertent penetration, suggesting interpretation of the technique description was perhaps more important than experience. Subjectively, the board-certified surgeons caused less iatrogenic damage, which may relate to clinical experience.

It had been expected that repeated attempts to enter the NB would increase the likelihood of inadvertent penetration, but this was not observed. The overall low number of attempts required may have influenced this outcome. Previous reports have suggested that distension of the NB prior to cannula placement is not necessary.<sup>10</sup> However, the surgeons in the current study agreed that distension facilitated entry to the NB and allowed confirmation of successful entry. Considering use of this technique may therefore be recommended in clinical case's.

Haupt and Caron also reported a very high incidence of iatrogenic damage (DDFT 93.8% and navicular bone 75%) using the DA, and attributed this to trauma caused by the open end of the cannula. It was suggested that the incidence may be reduced by introducing the obturator alone, prior to placing the assembly.<sup>21</sup> Despite omission of this precaution, the incidence of trauma identified endoscopically in the current study was considerably lower (DDFT 40% and navicular bone 30%), although this may have been underestimated. Only superficial dissections were performed and iatrogenic trauma sustained to deeper structures may not have been apparent on endoscopic examination. The highest frequency of iatrogenic damage was incurred by the surgeon who achieved the lowest frequency of inadvertent penetration and was using the principles of the ADA to the NB. This might indicate that this approach increased the likelihood of iatrogenic trauma, although this was not



appreciated during the subsequent investigation by two other surgeons. The reason for this difference is unknown, but is potentially related to slight variation in the orientation of the cannula and obturator assembly during insertion.

Further investigation of the ADA would be beneficial before recommending it for clinical case's. The subjectively more limited endoscopic field of view and manoeuvrability encountered when using the ADA may be considered an acceptable compromise to limit the likelihood of inadvertent penetration when employing this technique in case's of NB sepsis. As the restriction in view appeared to be primarily proximo-medially within the NB, it is possible that the approach would still be useful for access to sites of NB penetration within the distal recess and particularly if combined with an equivalent portal from the medial side of the limb.

Performing the procedure on cadaveric limbs is not identical to the live animal, and the freeze-thaw process has been demonstrated to alter tissues.<sup>32</sup> However, multiple other studies have used cadaver material to evaluate surgical techniques and the procedure was considered sufficiently similar to performing it in clinical case's, to make valid comparisons.<sup>17,21,48</sup>

The variation in limb size and type is a limitation of the study and may explain some of the differences observed in the measured outcomes. However, this variation was considered acceptable, and it may reflect the potentially mixed population treated for NB sepsis. The variation was accounted for when comparing surgeons by ensuring that contralateral limbs were examined by different surgeons.

### **3.7 Conclusion**

There is considerable risk of inadvertent synovial penetration when using the DA to the NB. Although the consequences of such inadvertent penetration are unknown, examination of the DFTS and DIPJ at the end of NB lavage as treatment for sepsis, with a view to lavage of these structures may be advisable. For case's that do not respond as expected to NB lavage, consideration of DFTS and/or DIPJ sepsis is indicated. The examined, ADA may reduce the risk of inadvertent synovial penetration; however the field of view and manoeuvrability may be restricted. Further investigation of this technique is warranted.

## **Chapter 4:**

# **Use of a Transthecal Surgical Endoscopic Approach for the Treatment of Clinical Navicular Bursa Contamination**

## **4.1 Introduction**

The TA to the NB via the DFTS has become the technique of choice for elective examination of the NB.<sup>39,60,61</sup> Favoured for its superior visualisation within the proximal recess and lower incidence of iatrogenic trauma.<sup>21</sup> The approach involves fenestration of the T-ligament to intentionally create communication between the NB and DFTS, explaining the understandable reluctance regarding its use in the management of NB sepsis, when the DFTS is non-septic. Based on the results of the cadaver study in Chapter 3, suggesting considerable risk of complication with the DA, the approach routinely used for septic case's, employing this TA in such case's was proposed. Use of this approach to treat clinical NB sepsis has not been reported previously.

## **4.2 Hypotheses**

It was hypothesised that the TA would be a safe and efficacious technique for the treatment of clinical case's of NB contamination and sepsis. The long term prognosis for survival and return to athletic function following this treatment was hypothesised to be comparable to previously reported outcomes in case's where the DA was employed.

## **4.3 Materials and Methods**

### **4.3.1 Case Selection**

The clinical records for 10 horses presented to three equine hospitals with NB contamination or sepsis, which subsequently underwent therapeutic NB endoscopy via the TA, were reviewed (Table 6). Seven horses had sustained deep solar penetrating injuries (5 fore limb and 2 hind limb), 2 had traumatic coronary band wounds (both hind limb) and 1 horse (fore limb) had undergone intrabursal medication with triamcinolone acetonide with iatrogenic introduction of infection.

<b>Case</b>	<b>Age (yrs)</b>	<b>Breed</b>	<b>Use</b>	<b>Limb</b>	<b>Aetiology</b>	<b>Sepsis Duration (days)</b>	<b>Concurrent sepsis</b>
<b>1</b>	6	Cob	Riding club	Fore	Solar penetration	16	-
<b>2</b>	9	TB	Show jumping	Fore	Solar penetration	<0.5	-
<b>3</b>	2	Paint	Unbroken	Fore	Solar penetration	14	DIPJ
<b>4</b>	11	Trakhner	Riding Club	Fore	Iatrogenic	14	-
<b>5</b>	8	TB	Eventer	Fore	Solar penetration	<0.5	-
<b>6</b>	2	TB	Racing	Hind	Coronary band wound	5	DIPJ
<b>7</b>	12	TB	Hacking	Hind	Solar penetration	28	-
<b>8</b>	15	Connemara	Riding club	Hind	Coronary band wound	<0.5	-
<b>9</b>	18	Saddlebred	Hacking	Hind	Solar penetration	4	-
<b>10</b>	7	WB	Riding club	Fore	Solar penetration	2	-

*Table 6. Summarised details of case's treated for NB sepsis via the TA to the NB.*

### **4.3.2 Diagnosis**

Preoperative radiographs of the affected foot were made for each case, and no osseous abnormalities were identified. In 6 case's, the preoperative diagnosis was made on the basis of laboratory analysis of cellularity, total protein and differential leukocyte count of synovial fluid from the NB (Table 7). In 2 horses (Case's 3 and 6) concurrent DIPJ sepsis was recognised on arthrocentesis preoperatively. In 4 horses (Case's 5, 6, 7 and 9) where synoviocentesis was not performed or unsuccessful, diagnostic imaging findings suggestive of NB involvement, prompted surgical intervention (see Table 7 for specific details). Endoscopic findings were consistent with sepsis in each case.

Case	TNCC (cells x10 <sup>9</sup> /L)	TP (g/L)	Radiography	MRI
1	108	-	-	DDFT lesion
2	280	58	-	-
3	46	50	-	-
4	50	-	-	DDFT lesion Intra-bursal adhesions
5	-	-	In situ penetrating body contacting navicular bone	-
6	51	50	Contrast study: communication between NB and septic DIPJ	-
7	-	-	-	Penetrating tract to NB DDFT lesion
8	283	-	-	-
9	-	-	Contrast study: communication between NB and penetrating tract	-
10	6.4	38	Metallic probe demonstrated tract between NB and penetration site	-

*Table 7. Summary of pre-operative diagnostics.*

*TNCC = total nucleated cell count of NB synovial fluid preoperatively, TP = total protein of NB synovial fluid preoperatively.*

### 4.3.3 Surgical Technique

#### I. Preparation:

Each horse underwent preoperative preparation, including distal limb and foot decontamination, administration of systemic non-steroidal anti-inflammatory and broad-spectrum antimicrobial therapies. The choice of antimicrobial was made empirically, 8 horses received a combination of penicillin and gentamicin, whilst 2 case's were administered a combination of cefquinome and gentamicin. Surgery was performed under general anaesthesia with the horses positioned in either dorsal or lateral recumbency, according to surgeon preference. Where horses were placed in dorsal recumbency, affected fore limbs were positioned with the carpus flexed to 90° and the distal limb in a semi-flexed position, whilst affected hind limbs were positioned in extension. Where lateral recumbency was chosen, horses were positioned with the affected limb uppermost, supported at the mid-metacarpus/tarsus with the distal limb free. Provision was made for access to the sole in case's of solar penetration. An Esmarch's bandage and tourniquet were placed and the distal limb aseptically prepared.

#### II. Endoscopic approach:

In all case's, a TA was made to the NB as described by McIlwraith *et al* and Smith *et al*.<sup>39,61</sup> Briefly, the DFTS was distended with saline via a palmar/plantar pouch injection or injection at the base of the proximal sesamoid bones. A 1cm skin incision was made as distal and dorsal as possible, immediately proximal to the ungular cartilage, axial to the neurovascular bundle and abaxial to the border of the DDFT. An endoscope



cannula and conical obturator assembly were introduced, then advanced distally and axially to enter the DFTS. The obturator was then replaced with a 4mm, 30° forward oblique endoscope (Karl Storz GmBh, Tuttlingen, Germany).

An instrument portal was created on the medial side of the limb under needle guidance, also as distal as possible, and dorsal to the DDFT to facilitate instrument access to the distal synovial reflection of the DFTS. An incision was made in the distal synovial reflection (using a No. 15 scalpel blade on a No. 7 handle or a beaver blade) dissecting the tissues immediately dorsal to the DDFT, until an opening into the NB was created (Figure 11). The fenestration was then extended to the maximal width of the NB using a motorised synovial resector (Arthrex, Naples, Florida, USA,) and/or 5.2mm Suction Punch (Smith and Nephew-Dyonics, Andover, Massachusetts, USA). Any fibrin accumulations and/or hypertrophied synovia within the bursa were debrided using the resector or retrieved with the Suction Punch or Ferris-Smith arthroscopic rongeurs (Sontec Instruments, Colorado, USA). The sites of NB penetration were similarly debrided in Case's 5-9, however the penetration sites were not identifiable in Case's 1-3 and 10 (Case 4 involved only needle penetration). The endoscope and instrument portals were repeatedly reversed to ensure thorough exploration, lavage and debridement. In all case's involving solar penetration, the tracts was sharply debrided, curetted and lavaged using a solar approach.

### III. DIPJ arthroscopy:

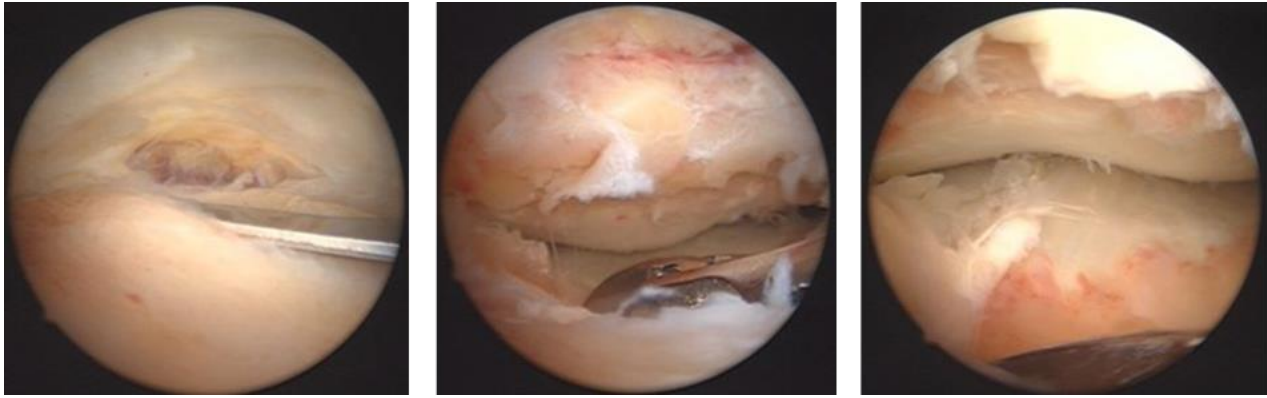
Once the communicating NB and DFTS were satisfactorily lavaged the palmar/plantar pouch of the DIPJ was explored arthroscopically in all case's, except Case's 7, 8 and 10, where preoperative arthrocentesis had confirmed absence of articular sepsis. The dorsal pouch of the DIPJ was examined via a standard dorsal arthroscopic approach in each of the 7 case's.<sup>39</sup> In 3 instances (Case's 1, 5 and 9), entry to the palmar/plantar pouch was gained via the DFTS, by blunt dissection through the remaining T-ligament dorsally, thus creating communication between the NB, DFTS and DIPJ. The palmar/plantar pouch of the DIPJ was examined via a standard arthroscopic approach in the other horses.<sup>39</sup>

### IV. Wound management:

Traumatic coronary band wounds (Case's 6 and 8) were sharply debrided and thoroughly lavaged. The wounds were left to heal by second intention.

### V. Closure:

In each case, the endoscopic portals were closed with monofilament polypropylene in a simple interrupted pattern. The DFTS and DIPJ (when examined) were then medicated with either amikacin or gentamicin (depending on surgeon preference, see Table 8). The surgical sites were protected with sterile dressings and modified Robert Jones bandages for anaesthetic recovery and in the postoperative period.



*Figure 11. Endoscopic images depicting fenestration of the T-ligament at the distal extremity of the DFTS and gaining entry into the NB.*

#### **4.3.4 Clinical pathology**

Microbiological culture and antimicrobial sensitivity testing were performed in 5 case's using either synovial fluid or fibrinocellular conglomerate retrieved from the NB. Microbial growth was obtained in just 3 instances (Case's 1, 2 and 4). Due to persistent synovial sepsis, as identified on cytological analysis of synovial fluid aspirated from the DFTS, Case 1 underwent repeat endoscopic surgery, 5 days after the initial surgery.

#### 4.3.5 Postoperative Management

##### I. Systemic antimicrobial therapy

The postoperative protocol was tailored to each individual case (Table 8). Outwith the exceptions noted below, all horses were administered gentamicin 6.6mg/kg intravenously (IV) once daily and either sodium penicillin G 20,000iu/kg IV every 8 hours or procaine penicillin 25,000iu/kg intramuscularly (IM) twice daily. Identification of a species of *Klebsiella* with penicillin resistance on microbial culture prior to referral prompted the choice of systemic cefquinome 1mg/kg IV twice daily in Case 4. Microbial culture of synovial fluid from Case's 1 and 2 grew *Staphylococcus aureus* and an undifferentiated species of *Pasteurella* respectively, both isolates showed in vitro resistance to penicillin. The initial empirical choice of systemic penicillin was therefore adjusted to cefquinome 1mg/kg IV twice daily in both instances.

##### II. IVRP

All of the horses received distal limb IVRP postoperatively. Under standing sedation, a tourniquet was applied at the mid-level of the third metacarpus/metatarsus just prior to catheterisation of the medial or lateral palmar/plantar digital vein at the level of the proximal sesamoid bone. This was followed by slow distension of the vasculature with 60ml of a solution consisting of the chosen antimicrobial and sterile saline, and in some case's a combination of saline and 10ml of mepivacaine 20mg/ml (Intra-Epicaine, Dechra, Staffordshire). The tourniquet remained in place for 20 minutes following delivery of the solution. All horses received 500mg of amikacin in each IVRP treatment with the exception of Case 4 where 1g was administered

on each occasion. Due to results of microbial sensitivity testing, the use of amikacin was discontinued in Case's 1 and 2 following the initial 2 treatments. These case's were then administered 3.2g of ticarcillin clavulanate (Timentin, GlaxoSmithKline, Middlesex) and 190mg of cefquinome respectively, during subsequent IVRP treatments.

### III. Synoviocentesis:

Postoperative synoviocentesis of the DFTS and/or DIPJ was performed in all case's to allow monitoring of synovial fluid parameters and facilitate intrasynovial antimicrobial medication. DFTS and DIPJ synoviocentesis were performed in Case's 3 and 6, where concurrent sepsis had been identified pre-operatively. Each synovial compartment was medicated with either amikacin or gentamicin following aspiration of a fluid sample (see Table 8 for details). Due to culture results, the protocol was altered to ticarcillin clavulanate for Case 1 and cefquinome for Case 2 on each occasion. The total number of times synoviocentesis and synovial medication was performed varied from 2 to 5 (Table 8), depending on clinical progress. A positive contrast radiographic study was performed via DFTS synoviocentesis in Case 9 and confirmed patent communication between the DFTS and NB 5 days post-operatively.

### IV. Analgesia:

Analgesia was not routinely administered in the immediate post-operative period and provided only when clinically necessary. Horses that showed

significant postoperative lameness were treated with oral phenylbutazone (4.4mg/kg *per os* [PO] twice daily) or suxibuzone (6.25 mg/kg PO twice daily), or flunixin (1.1mg/kg intravenously [IV] twice daily). In addition to oral suxibuzone, Case 7 was treated with extradural detomidine and morphine (1mg/kg every 4 hours), via an indwelling catheter, over a 48 hour period.

V. Exercise and Farriery:

The horses were walked in-hand twice daily and an ascending exercise programme commenced when comfort levels permitted, following bandage removal. Seven horses were shod with raised-heel shoes postoperatively. Those case's with solar penetrations were additionally managed with hospital plates to facilitate solar lesion management. The interval between surgery and farriery varied and was typically dictated by the condition of associated wounds and/or comfort level.

VI. Hospital Discharge:

Horses remained hospitalised until they had achieved a satisfactory level of comfort and had made sufficient clinical progress consistent with resolution of synovial sepsis, as subjectively assessed by the respective surgeon. A course of oral potentiated sulphonamides was prescribed at hospital discharge in each case. With the exception of Case 5, oral analgesia (phenylbutazone or suxibuzone) was administered to each horse following hospital discharge.

Case	IVRP drug	No.	Systemic drug	Days	Analgesia	Days	Intra-synovial drug	No.
1A	Amikacin 500mg	2	Penicillin Gentamicin Potentiated sulphonamides‡	4 4	Phenylbutazone Flunixin	4 1	Amikacin 100mg	3
1B	Ticarcillin clavulanate 3.2g	2	Cefquinome Gentamicin Potentiated sulphonamides‡	8 2	Flunixin Suxibuzone‡	8	Ticarcillin clavulanate 3.2g	3
2	Amikacin 500mg Cefquinome 190mg	2 5	Penicillin Gentamicin Cefquinome Potentiated sulphonamides‡	3 3 14	Phenylbutazone Phenylbutazone‡	10	Amikacin 100mg Cefquinome 90mg	1 3
3	Amikacin 500mg	3	Penicillin Gentamicin Potentiated sulphonamides‡	10 10	Phenylbutazone Phenylbutazone‡	8	Amikacin 100mg	2
4	Amikacin 1g	3	Cefquinome Gentamicin Potentiated sulphonamides‡	13 13	Phenylbutazone Phenylbutazone‡	4	Amikacin 100mg	5
5	Amikacin 500mg	2	Cefquinome Gentamicin Potentiated sulphonamides‡	8 8	Flunixin	2	Amikacin 100mg	2
6	Amikacin 500mg	2	Penicillin Gentamicin Potentiated sulphonamides‡	7 7	Phenylbutazone Phenylbutazone‡	4	Amikacin 100mg	2
7	Amikacin 500mg	4	Penicillin Gentamicin Potentiated sulphonamides‡	10 10	Suxibuzone Suxibuzone‡	9	Amikacin 100mg	2
8	Amikacin 500mg	1	Penicillin Gentamicin Potentiated sulphonamides‡	5 5	Phenylbutazone Phenylbutazone‡	1	Gentamicin 200mg	2
9	Amikacin 500mg	2	Penicillin Gentamicin Potentiated sulphonamides‡	5 5	Phenylbutazone Phenylbutazone‡	7	Amikacin 100mg	2
10	Gentamicin 10mg	2	Penicillin Gentamicin Enrofloxacin	2 2	Phenylbutazone	5	Amikacin 300mg	1

*Table 8. Details of the postoperative management for each case.*

*No. = Number of treatments, Days = number of days treatment administered, 1A = management of Case 1 following the first surgery, 1B = management of Case 1 following the second surgery, and ‡ indicates medication dispensed at discharge from the hospital.*

#### **4.3.6 Follow up**

Details of case outcome were obtained via telephone questionnaire with the horse owner, at least 12 months post-operatively. Owners were questioned regarding their horse's progress since hospital discharge, complications encountered, the current level of athletic performance achieved and cosmetic outcome.



#### 4.4 Results

Duration of hospitalisation ranged from 8 to 24 days. All horses survived to hospital discharge, the details of long term progress are shown in Table 9. Nine of the 10 horses (90%) survived to > 12 months follow up. Case 3 was euthanased 4 months postoperatively due to persistent lameness. Case 4 was retired from riding club activities due to persistent low grade lameness. Case 1 returned to a lower level of ridden work as the owner did not consider the horse fit for jumping at riding club level. Case's 6, 7, 8, 9 and 10 successfully returned to their previous levels of athletic activity, within their respective discipline (Table 9), whilst Case's 2 and 5 competed at an improved level. Overall 80% (8/10) of the horses returned to some level of athletic function and 70% (7/10) successfully returned to their previous or an improved level of athletic activity. NB intrasynovial medication with triamcinolone acetonide was performed in 4 case's (Case's 1, 3, 5 and 9) due to persistent lameness, within 1 month of hospital discharge. None of the owners reported any persistent palpable or cosmetic changes associated with the DFTS or surgical sites. The interval between injury and surgical treatment ranged from <12 hours to 28 days (median 4.5 days). Treatment of the 3 unsuccessful case's began 14-16 days after injury, however Case 7 was presented 28 days post-injury, and made a successful return to previous level of athletic activity. The median time from injury to treatment amongst the successful case's was 2 days.

<b>Case</b>	<b>Previous use</b>	<b>Current use</b>	<b>Follow up (months)</b>	<b>NB Medication</b>
<b>1</b>	Riding club	Hacking	32	Triamcinolone
<b>2</b>	Show jumping	Show jumping	12	-
<b>3</b>	Unbroken	Euthanased	14	Triamcinolone
<b>4</b>	Riding club	Retired	12	-
<b>5</b>	Eventing	Eventing	30	Triamcinolone
<b>6</b>	Racing	Racing	14	-
<b>7</b>	Hacking	Hacking	32	-
<b>8</b>	Riding club	Riding club	13	-
<b>9</b>	Hacking	Hacking	12	Triamcinolone
<b>10</b>	Riding Club	Riding Club	12	-

*Table 9. Details of case outcome at follow up (>12 months).*

## 4.5 Discussion

This is believed to be the first report of the use of the TA in clinical case's of NB contamination and sepsis. The results compare favourably with those reported using alternative techniques with survival in 90% and a return to pre-injury level of athletic activity in 70%. Table 11 lists a revision of the meta-analysis from Table 1, comparing the published outcomes following management of NB sepsis.

Various complicating factors may have influenced the outcome. Each of the 3 unsuccessful case's (Case's 1, 3 and 4) involved a forelimb, which has previously been suggested to carry a poorer prognosis than hind limb involvement.<sup>50</sup> The 2 surviving, unsuccessful case's (Case's 1 and 4) had DDFT lesions identified on MRI preoperatively which may have affected their outcome. This lesion was considered to pre-exist the onset of sepsis in Case 4, in which imaging had identified an insertional tear with associated intrabursal adhesions, findings that were confirmed on endoscopy. Recent literature suggests a guarded prognosis for return to ridden exercise for extensive distal DDFT tears.<sup>60</sup> Previous author's have suggested a poorer prognosis in case's with concurrent DIPJ sepsis,<sup>50</sup> whilst others have reported it to have no influence.<sup>70</sup> Of the 2 case's (Case's 3 and 6) in this series 1 was euthanased and 1 successfully returned to racing.

NB contamination and deep solar penetrations are generally regarded as surgical emergencies.<sup>18,23,58</sup> Previous studies have identified the interval between NB penetration and surgical treatment as one of the most influential factors in dictating case outcome. A delay in surgery of greater than 7 days

has consistently been reported to negatively impact case outcome.<sup>23,50,62</sup> In the current series, an interval from injury to treatment of 14-16 days was reported for the 3 unsuccessful case's, substantially longer than the median interval of 2.25 day amongst the successful case's. Interestingly however, a successful outcome was noted in 1 horse with an injury to treatment interval of 28 days.

Unlike the previous reports of endoscopic management, IVRP and intrasynovial antimicrobial medication were employed routinely in all case's postoperatively. This more aggressive approach to provision of antimicrobial therapy may have had a positive influence on case outcome, but with such small case numbers, particularly in conjunction with a new surgical technique, it is not possible to determine their significance.

Intra-operatively the TA should allow more thorough evaluation of the NB and particularly the proximal recess. The technique should pose less risk of iatrogenic injury or inadvertent synovial penetration. The DA has been demonstrated to carry the risk of inadvertent DFTS and/or DIPJ penetration, which could result in iatrogenic contamination of these structures.<sup>10,21,29,53</sup> Thus it cannot be assumed that the DA will prevent spread of infection. When the TA is employed, the DFTS may be simultaneously lavaged. Inadvertent entry to the DIPJ can occur with the TA if the dissection through the T-ligament is made too dorsal, however this incident should be immediately obvious and therefore allow lavage as necessary.

A potential benefit of using the TA was the ability to monitor the response to treatment by synoviocentesis of the DFTS, due to the common synovial

environment between the NB and DFTS. Postoperative monitoring of the NB can be problematic, given the risk of DDFT injury and practical difficulties associated with synoviocentesis. This has the potential to contribute to delayed identification of persistent infection with subsequent delay in treatment and possible influence on case outcome. Furthermore, intrasynovial antimicrobial medication may be similarly simplified and safer for both the horse and clinician. These advantages do however depend on the communication remaining patent postoperatively. Investigation for patency was performed in a single case on just one occasion in the current series. The confirmation of patency in that instance is encouraging but further investigation is required to determine the duration of patency and indeed even if patent, whether the synovial environment between the two compartments is uniform. Finally, the transthecal approach results in immediate NB decompression at the time of surgery, potentially minimising postoperative NB distension, and therefore possibly reducing synovial inflammation and pain.

The risk of potential extension of sepsis to other synovial compartments in the event of persistent NB sepsis must of course be acknowledged. Persistence of sepsis occurred in Case 1, as identified on DFTS synoviocentesis, and in this case a common communication had been created between the 3 synovial compartments (DFTS, DIPJ and NB). This persistence was attributed to the presence of *Staphylococcus aureus* with resistance to penicillin. Although the complication of DFTS and DIPJ sepsis was a failure of the initial treatment regimen, it may be argued that the persistent NB sepsis may have been detected and therefore dealt with more promptly as a result of communication between the synovial compartments. At follow up Case 1 had returned to

athletic activity, albeit at a lower level. Whether or not this was influenced by DFTS and/or DIPJ pathology associated with sepsis is unclear. Preoperative MRI had revealed a DDFT lesion presumably associated with the penetrating foreign body, which may have contributed to the reduced athletic potential of the horse. The owner of this horse did not report the presence of obvious DFTS distension, which would be suggestive of on-going pathology of clinical significance. Extension of the infection to the DFTS could be viewed to be of limited relevance. A horse with uncontrolled sepsis of its NB is unlikely to return to ridden exercise, and thus concurrent uncontrolled sepsis of the DFTS will have little practical bearing on the outcome.

Farriery was employed to improve comfort levels in 4 case's. By raising the heels, the moment of force exerted on the navicular bone by the DDFT at the DIPJ is reduced, and the angle between the DDFT and navicular bone is decreased. This results in decompression of the traumatised structures (NB and DDFT). This was associated with a subjective improvement in comfort in these horses.<sup>68</sup> Intrasynovial medication with triamcinolone acetonide was performed in 4 case's where persistent lameness was attributed to on-going active inflammation. It was elected to perform intrabursal medication as patency of the fenestration several weeks postoperatively could not be guaranteed.

	Survival	%	Satisfactory Outcome'	%	Athletic Function	%	Pre-Injury Activity	%	Hospital (mean days)	Days	Authors
<b>Bursotomy</b>											
	15/34	44	12/34	35	4/34	12	-	-	45	Mean 17	Richardson <i>et al</i> <sup>50</sup>
	10/19	53	10/19	53	6/19	32	-	-	-	Mean 44	Steckel <i>et al</i> <sup>62</sup>
	4/6	67	2/6	33	2/6	33	-	-	-	-	Honnas <i>et al</i> <sup>22</sup>
	-	-	-	-	4/10	40	-	-	-	-	Kilcoyne <i>et al</i> <sup>31</sup>
	29/59	49	24/59	41	11/59	19	-	-	-	-	Meta-Analysis
<b>Endoscopic Lavage</b>											
<b>DA</b>	14/16	88	12/16	75	10/16	63	10/16	63	17	Mean 13	Wright <i>et al</i> <sup>70</sup>
<b>DA</b>	29/34	85	27/34	79	24/34	71	20/34	59	20	-	Wright <sup>69</sup>
<b>Not reported</b>	-	-	-	-	2/3	67	-	-	-	-	Kilcoyne <i>et al</i> <sup>31</sup>
<b>Not reported</b>	45/86	52	-	-	39/86	45	29/86	34	11	Median 2	Findlay <i>et al</i> <sup>18</sup>
<b>TA</b>	<b>9/10</b>	<b>90</b>	<b>8/10</b>	<b>80</b>	<b>8/10</b>	<b>80</b>	<b>70</b>	<b>70</b>		<b>Mean 8.45 Median 4.5</b>	<b>Current study</b>

Table 10. Revised meta-analysis for the published outcomes following surgical treatment for NB sepsis

## **4.6 Conclusions**

Surgical endoscopic treatment for NB contamination via the TA was a viable treatment option with no significant long term adverse effects in this small case series. The prognosis for survival and return to athletic function were comparable, or improved to previously published data on the management of similar case's employing the DA. Investigation involving a larger number of case's is indicated to identify the optimal surgical approach. Determination of whether the synovial fistula between the NB and DFTS persists, as well as its physical and physiological effects also warrant further study.

## **4.7 Potential Clinical Relevance**

The TA may facilitate more thorough exploration and debridement of the NB, with reduced risk of iatrogenic injury, compared with the DA. Additionally, postoperative intrasynovial medication and monitoring of synovial fluid parameters is potentially simplified by establishing communication between the NB and DFTS, however further investigation is required to determine the duration of patency.

The inconsistency in achieving visualisation or access to sites of penetration into the bursa could present a limitation in the use of the transthecal technique. The approach results in more proximal positioning of the endoscope within the bursa, resulting in superior visualisation of this area. Perhaps a combined TA



and DA technique may represent the safest means of achieving maximal endoscopic access to the NB. Initially entering the NB via the TA to minimise the risk of iatrogenic structural damage and allow thorough examination of the proximal recess. With endoscopic guidance, a more distal portal could then be created using the DA, allowing more optimum access to the distal portion of the NB.

## **Chapter 5.**

# **Evaluation of the Concentration of Amikacin Accumulated in Synovial Fluid Following IVRP in Case's of Clinical Synovial Sepsis**

## **5.1 Introduction**

Regional limb perfusion with antimicrobials may be performed via intravenous (IVRP), intra-arterial or intraosseous routes, however IVRP is the generally the preferred technique.<sup>11</sup> Intra-arterial administration is associated with more frequent and more severe drug-induced toxic effects, and technical complications are often reported using the intraosseous route.<sup>54</sup>

Trials using clinically normal horses, with and without experimentally induced synovitis, have shown that IVRP can achieve high concentrations of antimicrobial drugs in synovial fluid, the synovial membrane, and local extra-synovial tissues.<sup>4,8,11,13,47</sup> It has been reported that the minimum inhibitory concentration (MIC) of antimicrobial drug in infected synovial fluid for the bacterial species (with specific drug sensitivity) commonly implicated in equine orthopaedic infections is 4mg/L.<sup>5</sup> Studies evaluating IVRP have repeatedly demonstrated accumulation of concentrations well in excess of this figure. Optimum concentration-dependent killing is achieved when antimicrobial concentrations are 10-12 times MIC. Extrapolating from this and recommendations from the human literature, the efficacy of IVRP may be optimised if these concentrations are achieved within synovial fluid and the

tissues. Again, many of the equine studies have reported such levels using experimental synovitis models. On this basis, IVRP has been adopted as an adjunctive therapy in the treatment of clinical synovial sepsis. However, there are no reports evaluating the concentrations of antimicrobial drugs achieved in synovial fluid in the presence of clinical synovial infection.

IVRP was employed as part of the protocol in the management of the 10 case's of navicular bursa sepsis described in Chapter 4. It was suggested that the improved case outcome in this cohort compared with previous published reports may have been influenced not just by the transthecal surgical technique (the TA to the NB) used, but also the routine use of IVRP. Despite favourable opinion regarding its use in clinical case's of sepsis,<sup>11</sup> a retrospective analysis of such use,<sup>54</sup> did not find it to greatly improve the prognosis for survival compared with other reports.<sup>18,56,72</sup> With the exception of that report, there is a scarcity of publications regarding its use in naturally occurring clinical synovial sepsis. The aim of this study was to investigate the concentrations of amikacin accumulated in synovial fluid in case's of naturally occurring synovial sepsis. The author's intention was to contribute clinically relevant information to the literature regarding the potential for this technique to be efficacious in clinical case's.

## **4.6 Hypothesis**

It was hypothesised that the concentration of amikacin accumulated in synovial fluid within a septic synovial structure following IVRP would be greater than the MIC for microorganisms commonly isolated in synovial infections.

## **5.3 Materials and Methods**

### **5.3.1 Case Selection**

Samples were collected from adult horses, with traumatically induced sepsis of synovial structures, including and distal to the carpus and tarsus, only. Any horses with known pre-existing orthopaedic disease of the affected limb were excluded. Samples from immature (<12 months) animals, ponies (<15hh) and heavy breeds were excluded. Horses were excluded if amikacin had been administered by any route in the preceding 60 days, administration of all other drugs, including intra-synovial medication of other aminoglycosides, was permitted. Samples were only collected from horses where the diagnosis was based on pre-operative analysis of the total protein content ( $\geq 30\text{g/L}$ ), total nucleated cell count ( $\geq 30 \times 10^9$  cells/L) and differential neutrophil content ( $\geq 90\%$ ) of undiluted synovial fluid.

### **5.3.2 Control**

Synovial fluid was aspirated from a metacarpophalangeal joint (MCPJ) and tarsocrural joint (TCJ) of one of the study horses during initial investigation of multiple limb injuries, and prior to IVRP. Subsequent analysis revealed TCJ sepsis, but the MCPJ was found to be aseptic. The left over MCPJ fluid sample was analysed for amikacin concentration and served as a control.

### 5.3.3 IVRP Protocol

- IVRP was performed under general anaesthesia, immediately prior to surgical endoscopic treatment for synovial sepsis in all cases. The horses were positioned in either dorsal or lateral recumbency, with this and the limb positioning (uppermost or dependant) dictated by the synovial structure of interest and accessibility for endoscopic surgery.
- The same perfusate composition was used in every case, irrespective of horse size, tourniquet location or structure involved. It consisted of 500mg amikacin (10ml volume) and 50ml sterile saline to create a total volume of 60ml.
- An elasticated Esmarch's tourniquet was applied as tightly as possible, without tearing the bandage, and wrapped around the limb at least 5 full circumferential turns, depending on limb circumference. The tourniquet was applied at mid-metacarpus/metatarsus level when infection involved the NB, DIPJ, proximal interphalangeal joint (PIPJ), MCPJ or metatarsophalangeal joint (MTPJ). It was applied at proximal metacarpal/metatarsal level when the DFTS was involved, ensuring the proximal recess of the sheath was not beneath the tourniquet. It was applied at the distal antebrachial level for carpal joint infection and at distal crus level for tarsal infection. To ensure optimum vessel compression, rolled gauze bandages were placed beneath the tourniquet medially and laterally on the metacarpus/metatarsus,

medially on the antebrachium and either side of the Achilles tendon bundle in the crus.

- The most easily palpable peripheral vein, closest to the injured synovial structure was selected. Vessels with evidence of overlying cellulitis or those involved with the inciting injury were avoided. Typically, this involved the palmar/plantar digital vein at proximal sesamoid bone level for distal limb structures, the cephalic vein and saphenous vein for more proximal forelimb and hindlimb structures respectively. The overlying hair was clipped and the skin aseptically prepared before a 23-gauge butterfly catheter was placed. The perfusate was administered by hand, delivered over a period of 1 minute, with digital pressure applied over the venepuncture site. The catheter was then removed and a pressure bandage applied to prevent leakage.
- The tourniquet remained in place for 20 minutes, during pre-surgical preparation, and was removed just prior to draping.
- Synoviocentesis and sample collection from the septic structure were performed 5 minutes after tourniquet removal. Synovial samples were mixed with EDTA and stored at -20°C.

#### **5.3.4 Amikacin Concentration Analysis**

The frozen synovial samples were submitted to the Antimicrobial Reference Laboratory at the Bristol Centre for Antimicrobial Research and Evaluation. Analysis was performed using a fluorescent polarisation assay, previously validated for equine synovial fluid.<sup>43,47</sup>



## 5.4 Results

Twenty five case's met the selection criteria, the cohort included horses of Thoroughbred and Warmblood type. Each had sustained traumatic injury involving contamination of a single synovial structure. All animals were free of known pre-existing orthopaedic disease affecting the injured limb. There was no detectable amikacin in the control sample of synovial fluid. With the exception of a sample from a radiocarpal joint (RCJ), concentrations greater than the control were measured in each of the case samples, ranging from 1.5 to 391mg/L. The results are summarised in Table 11, however the RCJ sample was considered to most likely represent a failure in the application of the tourniquet and it was removed from the data in Table 12. The results were reviewed according to synovial structure and then divided into 3 groups; the 'Distal Limb' group included results from the DIPJ, PIPJ and MCPJ/MTPJ, the 'Proximal Limb' group consisted of just TCJ's once the RCJ results had been removed from the analysis, and finally all of the results from DFTS's were collated in a third group. The DFTS sample group recorded the highest individual sample concentration (391mg/L) as well as the highest group mean (175.1 mg/L) and median (181 mg/L). The lowest individual result came from a TCJ, and proximal group had the lowest mean (43.3 mg/L) and median (26.9 mg/L) values (Table 12). When the group mean values were assessed for number of MIC multiples achieved, each group exceeded 10 times, with the DFTS mean concentration converting to 43.7 times the quoted MIC (4 mg/L)

	Structure	Amikacin (mg/L)
<b>Control</b>		
	MCPJ	0
<b>Distal Limb (n=7)</b>		
	DIPJ	143
	MTPJ	333
	PIPJ	24.3
	DIPJ	4.7
	MTPJ	192
	PIPJ	103.2
	NB	63.6
<b>Proximal Limb (n=9)</b>		
	TCJ	31.3
	TCJ	20.9
	TCJ	1.5
	TCJ	43.1
	TCJ	22.4
	TCJ	159
	TCJ	1.6
	TCJ	66.6
	RCJ	0
<b>DFTS (n=9)</b>		
	DFTS	391
	DFTS	196
	DFTS	88.4
	DFTS	16.2
	DFTS	243
	DFTS	262
	DFTS	147
	DFTS	181
	DFTS	51.3

*Table 11. Measured concentrations of amikacin from each sampled structure with confirmed clinical synovial sepsis.*

	Amikacin (mg/L)			times MIC
	Range	Mean	Median	Mean
<b>24 Case's</b>	1.5 - 391	116.1	77.5	29
<b>Distal Limb</b>	4.7 - 333	123.4	103.2	30
<b>Proximal Limb</b>	1.5 - 159	43.3	26.9	10.8
<b>DFTS</b>	16.2 - 391	175.1	181	43.7

*Table 12. Summary of data for sample groups, excluding the RCJ sample.*

## 5.5 Discussion

The results confirm that the particular IVRP protocol used in this study, can achieve detectable levels of amikacin in infected synovial fluid. Levels in excess of the published MIC for microorganisms commonly encountered in equine orthopaedic infections (4 mg/L) were measured in more than 90% of the samples, and levels consistent with optimum concentration-dependent killing (12 times MIC) were detected in 62.5% of the samples in this small cohort.

Various controlled studies investigating different indirect regional administration techniques have found that the synovial concentration of antimicrobial is altered by synovial inflammation, however the effect varies depending on administration route.<sup>13</sup> Lower synovial concentrations were reported following intraosseous perfusion of gentamicin in an induced septic synovitis study. Similarly, articular medication with amikacin resulted in lower synovial concentrations in a study examining the effects of induced aseptic synovitis.<sup>4</sup> Both author groups attributed the lower levels to increased blood flow resulting in faster clearance. Conversely, greater synovial levels of penicillin and kanamycin were measured after systemic administration in horses with induced synovitis.<sup>11</sup> This opposite effect may also be explained by the same mechanism, i.e. increased synovial perfusion and hence enhanced delivery of the drug. Another study using an induced synovitis model demonstrated significantly greater amikacin levels in synovial fluid after IVRP, compared with normal joints.<sup>43</sup> It was not known whether any local soft tissue trauma and inflammation, in addition to possible compromise to the

vasculature, as is common in case's of clinical synovial sepsis, would have influenced the accumulated amikacin in the current case series. On the basis of the results, any effect would appear to be negligible in this cohort. Logically, one would assume that the greater the severity of soft tissue and vascular compromise the greater the potential for failure of delivery of the drug to the synovial fluid. Further investigation of this area is warranted. Grading the severity of soft tissue compromise and performing Doppler evaluation of the vasculature to assess adequacy of perfusion may be beneficial.

There was no detectable amikacin in the only carpal joint sampled, previous experimental studies have attributed such occurrences to tourniquet failure, although this is not possible to confirm. The Esmarch's tourniquet was placed by the author in each case sampled, using the method routinely used in the hospital. Tourniquet efficacy is related to width and pressure applied. Wider tourniquets are reportedly more efficacious, and negate the need for excessive pressures.<sup>20,33</sup> In people, tourniquets wider than limb diameter are applied at subsystolic pressures and are still effective.<sup>20</sup> This was corroborated in an equine study comparing 3 different tourniquets in standing horses, where a narrow rubber tourniquet (1cm) consistently failed to achieve therapeutically useful amikacin concentrations in synovial fluid whilst 10 and 12.5 cm tourniquets were effective.<sup>33</sup> There are conflicting reports regarding the use of pneumatic tourniquets. One study advocated their use,<sup>33</sup> whilst further studies have shown that compared with pneumatic tourniquets applying up to 420mm Hg, greater drug levels were achieved using Esmarch's tourniquets. This is presumed to be the result of superior vessel occlusion preventing leakage into the systemic circulation.<sup>33</sup> Optimal pressures have not been investigated in

horses, data from canine studies report pressures in the order of 1000 mmHg using an Esmarch's tourniquet,<sup>36</sup> although this is expected to be even higher in horses. Despite the inability to control the pressure exerted, Esmarch's tourniquets are more commonly used, not least due to the ease of use and their relative inexpense.

The influence of tourniquet position on the limb is unknown and was not specifically investigated in the current study. However, it is interesting to note that the lowest measured concentrations (from the Proximal Limb group), and a presumed tourniquet failure (the RCJ sample) were recorded when the tourniquet was necessarily placed proximally. It is possible that the irregularity in limb shape and limb diameter at the distal antebrachium and crus may negatively influence the ability to achieve sufficient vessel occlusion. This complication has not previously been described, though it is anecdotally considered a possibility. As was used in this study, many clinicians use padding in these areas, in an attempt to enhance compression. The volume of perfusate used could also have been a contributing factor. Compared with the Distal Limb and DFTS groups, the infused volume of amikacin had a greater volume of tissue in which to distribute. If volume of perfusate compared with volume of tissue were the principle determinants in synovial concentration however, one would expect the highest concentrations to be achieved in the Distal Limb group where it was possible to most specifically isolate the region of interest. Interestingly, the highest overall concentrations were recorded in DFTS's. Similar to the Distal Limb group, this group possibly benefitted from placing the tourniquet on the comparatively narrow and regularly shaped metacarpus/metatarsus. However, compared with the Distal Limb group, the

structure of interest was less specifically isolated. It could be suggested that the DFTS benefits from a richer vascular network than the articular structures and therefore there is greater opportunity for amikacin delivery. Additionally, the relatively more extensive synovial membrane surface area associated with the DFTS may have contributed to the greater delivery of the drug. Further evaluation of these group differences is warranted to investigate whether it is possible to determine optimal tourniquet position and/or volume of perfusate to compensate for lower drug doses, thereby minimise expense and possible side effects.

The overall encouraging outcome of this study, with optimum levels of drug concentrations achieved in almost two thirds of samples, may have been influenced by the predominance of DFTS cases (9/25 or 36%) within the cohort. Although the sample size is small, very encouraging results were recorded from the DFTS group mean converting to an impressive 43.7 times MIC. Further investigation of this trend is justified to determine the factors which may contribute to the comparatively enhanced ability to concentrate amikacin in the DFTS.

The lack of specific case detail is a considerable limitation in the current study. To expand on this work, it would be useful to record the nature and extent of the inciting injury and the current soft tissue injury, the duration of sepsis, the synovial cytological parameters, as well as horse details such as weight and limb length/diameter.

It is not possible to conclude whether use of IVRP significantly influenced the outcome in the 10 cases of NB sepsis described in Chapter 4. A limiting factor

in this study is the absence of samples from septic NB in the cohort. Additionally, some of the case's were treated with antimicrobials other than amikacin. Repetition of this study with other drugs commonly used for IVRP as well as further investigation of their pharmacodynamics under the conditions of IVRP is justified. However, on the basis of this IVRP study, the author suggests that concentrations of amikacin exceeding the MIC were achieved within the NB synovial fluid in the majority of the 10 case's of NB sepsis.

### **5.6 Conclusions and Potential Clinical Relevance**

IVRP in clinical case's of synovial sepsis effectively results in levels of amikacin in excess of the literature recommended concentrations. The efficacy of such treatment was not investigated in this study, however the results provide both justification and a basis for further investigation of this technique.



## **Chapter 6.**

### **Areas of Future Study**

#### **6.1 The repeatability and usefulness of the ADA**

An alternative approach to the NB was proposed based on the results of the cadaver study, described in Chapter 3. The preliminary results suggest it to be a safer technique, possibly offering reduced risk of inadvertent synovial penetration and iatrogenic structural damage, than the routinely employed DA. However, the sample size was small, questioning the reliability of the data. Additionally, the field of view was subjectively considered comparatively limited. Further investigation of the repeatability of the findings in cadavers is proposed before attempting the approach in case's. Should the field of view prove sufficient, this technique may be considered in case's of sepsis where the surgeon is reluctant to employ the TA yet has concerns regarding the complications recognised with the DA.

## 6.2 Duration of fenestration patency

In Chapter 4, where the use of the TA to the NB was used in clinical sepsis. It was proposed that fenestrating the T-ligament would create a patent communication which could be useful post-operatively. The suggested benefits of persistent patency include:

- i. Simplified synovial fluid analysis, as fluid aspirated from the DFTS should be representative of that within the NB, making direct sampling from the NB unnecessary
- ii. Simplified medication of the NB with antimicrobials via DFTS centesis, affording the opportunity for more aggressive therapy
- iii. Reduced NB distension and synovitis resulting in improved horse comfort

The duration of patency in non-septic bursae, where the TA is more commonly employed, has similarly not been investigated in case's with sepsis. It is logical to assume that there is greater likelihood for the fenestration to lose patency in the very inflamed environment of the NB immediately following sepsis. However, the author has experience of a single case where a positive contrast navicular bursogram was performed 4 days following TA endoscopic surgery for NB sepsis, and the images confirmed persistent patency. Further investigation, involving post-operative contrast radiography would be of benefit to the surgeon in managing such case's.

### **6.3 The efficacy of IVRP in the presence of clinical synovial sepsis with soft tissue injury**

Despite the considerable body of experimental study evaluating various elements of IVRP, there remains a paucity of information regarding its use in the presence of soft tissue injury and/or vascular compromise. Correlation of the concentrations of antimicrobial drug achieved in tissues with the severity of tissue injury would provide useful information regarding its use. Limb diameter and wound area measurements could be employed. Ultrasonographic evaluation of the severity of oedema, in addition to Doppler assessment of the local blood flow may also provide interesting information.

### **6.4 Determination of antimicrobial dose rates for use in IVRP**

The published doses of antimicrobials used in IVRP were largely arbitrarily chosen. There are few specific experimental investigations assessing different drug concentrations, predominantly using small study cohorts of horses of similar proportions. Considerable further work in this area is required to allow safe and efficacious practice of the technique. The author proposes that horse factors may be influential, e.g. size/weight, limb length and diameter. Additionally, the potential for concurrent injury to influence the required dose is proposed as a further area of investigation.

## References

1. Bassage L, Ross M: Diagnostic Analgesia, in: Ross M, Dyson S (eds). *Diagnosis and Management of Lameness in the Horse* (ed 2). St Louis: Elsevier Saunders. pp100–34, (2011).
2. Baxter GM. Management of Bursitis. in: Auer J and Stick J (eds). *Equine Surgery* (ed 4). Chp 82. pp1148–1157. Elsevier Saunders, (2012).
3. Baxter GM. Retrospective study of lower limb wounds involving tendons, tendon sheaths or joints in horses. *Proc. Am. Ass. equine Practnrs.* **33**:715-728, (1987).
4. Beccar-Varela AM, Epstein KL and White CL. Effect of Experimentally Induced Synovitis on Amikacin Concentrations after Intravenous Regional Limb Perfusion. *Veterinary Surgery.* **40**(7): 891–897 (2011).
5. Bertone, A. L. Update on infectious arthritis in horses. *Equine Vet. Educ.* **11**, 143–152 (1999).
6. Bramlage L. Treatment of overwhelming joint infections by massive cancellous bone graft- ing. In: Lecture abstracts of the AOASIF Advanced Techniques in Equine Fracture Management (2005).
7. Budras K, Sack W and Röck S. in *Anatomy of the Horse* (Schülersche, 2008).
8. Butt TD, Bailey JV, Dowling PM, Fretz PB. Comparison of 2 techniques for regional antibiotic delivery to the equine forelimb: intraosseous perfusion vs. intravenous perfusion. *Can Vet J.* **42**(8):617-22 (2001).
9. Cadiot P and Dollar J. *Clinical Veterinary Medicine and Surgery.* Jenkins Veterinary Publisher and Bookseller, (1901).
10. Cruz AM, Pharr JW, Bailey JV, *et al*: Podotrochlear bursa endoscopy in the horse: A cadaver study. *Vet Surg.* **30**(6):539–45, (2001).
11. Cruz AM, Rubio-Martinez L, Dowling T. New antimicrobials, systemic distribution, and local methods of antimicrobial delivery in horses. *Vet Clin North Am Equine Pract.* **22**(2):297-322 (2006).
12. Dyce K, Sack W and Wensing C. *Textbook of Veterinary Anatomy.* WB Saunders, (2002).
13. Errico JA, Trumble TN, Bueno AC, Davis JL, Brown MP. Comparison of two indirect techniques for local delivery of a high dose of an

- antimicrobial in the distal portion of forelimbs of horses. *Am J Vet Res.* **69**(3):334-42 (2008).
14. Fraser BSL, Bladon BM. Tenoscopic surgery for treatment of lacerations of the digital flexor tendon sheath. *Equine Vet J.* **36**:528–531, (2004).
  15. Gaughan, E.M. Wounds of tendon sheaths and joints in horses. *Comp. cont. Educ. pract. Vet.* **16**:517-529, (1994).
  16. Gibson KT, McIlwraith CW, Turner AS et al. Open joint injuries in horses: 58 case's (1980–1986). *J AmVet Med Assoc.* **194**:398–404, (1989).
  17. Fowlie JG, O'Neill HD, Bladon BM, et al: Comparison of conventional and alternative arthroscopic approaches to the palmar/plantar pouch of the equine distal interphalangeal joint. *Equine Vet J.* **43**(3):265–9 (2011).
  18. Findley J. Pinchbeck GL, Milner PI, et al. Outcome of horses with synovial structure involvement following solar foot penetrations in four UK veterinary hospitals: 95 case's. *Equine Vet. J.* 1–6 (2013).
  19. Frees KE, Lillich JD, Gaughan EM, et al: Tenoscopic-assisted treatment of open digital flexor tendon sheath injuries in horses: 20 case's (1992–2001). *JAmVet Med Assoc.* **220**:1823–1827, (2002).
  20. Graham B, Breault MJ, McEwen JA, McGraw RW. Occlusion of arterial flow in the extremities at subsystolic pressures through the use of wide tourniquet cuffs. *Clin Orthop Relat Res.* **286**:257-61 (1993).
  21. Haupt JL, Caron JP. Navicular bursoscopy in the horse: a comparative study. *Vet Surg.* 2010;39(6):742–7.
  22. Honnas CM, Crabill MR, Mackie JT, et al. Use of autogenous cancellous bone grafting in the treatment of septic navicular bursitis and distal sesamoid osteomyelitis in horses. *J. Am. Vet. Med. Assoc.* **206**, 1191–4 (1995).
  23. Honnas CM, Meagher DM and Lindford RL. Surgical management of difficult foot problems in the horse: current concepts. *Proc. Am. Ass. Equine Practnrs.* **34**:249, (1988).
  24. Honnas CM, Schumacher J, Cohen ND, Watkins JP, et al. Septic tenosynovitis in horses: 25 case's (1983-1989). *J Am Vet Med Assoc.* **99**(11):1616-22 (1991).

25. Honnas CM, Schumacher J, Watkins J, *et al.* Diagnosis and treatment of septic tenosynovitis in horses. *Compend. Contin. Educ. Pract. Vet.* **13**:301–311 (1991).
26. Honnas CM, Welch RD, Ford TS, *et al.* Septic arthritis of the distal interphalangeal joint in 12 horses. *Vet. Surg.* **21**:261-268, (1992).
27. Kainer, R. Functional anatomy of the equine musculoskeletal system. In Baxter G (ed): *Adams' and Stashak's Lameness in Horses* (ed. 6) pp1–72 (Lippincott Williams and Wilkins, 2011).
28. Kane-Smyth J, Bladon BM, Parker R. Use of a transthecal bursoscopic approach for the treatment of navicular bursa sepsis. Proceedings of the 22nd European College of Veterinary Surgeons Annual Scientific Meeting. Rome; pp 26, (2013).
29. Kane-Smyth J, Taylor SE, García EC, Reardon RJ. Frequency of Penetration of the Digital Flexor Tendon Sheath and Distal Interphalangeal Joint Using a Direct Endoscopic Approach to the Navicular Bursa in Horses. *Vet Surg.* **45**(3):380-5 (2016).
30. Koch D. Management of infectious arthritis in the horse. *Compend. Contin. Educ. Pract. Vet.* **1**, 45–50 (1979).
31. Kilcoyne I, Dechant J, Kass P and Spier S. Penetrating injuries to the frog (cuneus unguulae) and collateral sulci of the foot in equids: 63 case's (1998–2008). *J. Am. Vet. Med. Assoc.* **239**, (2011).
32. Leitschuh PH, Doherty TJ, Taylor DC, *et al.* Effects of postmortem freezing on tensile failure properties of rabbit extensor digitorum longus muscle tendon complex. *J Orthop Res.* **14**(5):830–3, (1996).
33. Levine DG, Epstein KL, Ahern BJ, Richardson DW. Efficacy of three tourniquet types for intravenous antimicrobial regional limb perfusion in standing horses. *Vet Surg.* **39**(8):1021-4 (2010).
34. Lugo J and Gaughan EM. Septic arthritis, tenosynovitis, and infections of hoof structures. *Vet. Clin. North Am. Equine Pract.* **22**, 363–88 (2006).
35. Martins R, Auer A, Carter G. Equine pediatrics; septic arthritis and osteomyelitis. *J. Am. Vet. Med. Assoc.* **88**, 582–585 (1986).
36. McLaren AC, Rorabeck CH. The pressure distribution under tourniquets. *J Bone Joint Surg Am.* **67**(3):433-8 (1985).

37. McIlwraith CW. Treatment of infectious arthritis. *Vet. Clin. North Am. Equine Pract.* **5**, 363–379 (1983).
38. McIlwraith CW. Diseases of joints, tendons, ligaments and related structures. in *Adams' Lameness in Horses* (ed. Stashak, T.) pp459–644. Lippincott Williams and Wilkins, (2002).
39. McIlwraith CW, Nixon AJ, Wright IM, *et al*: Bursoscopy, in *Diagnostic and Surgical Arthroscopy in the Horse* (ed 3). Philadelphia: Mosby Elsevier. pp409–26, (2005).
40. McIlwraith CW and Turner AS. *Equine Surgery Advanced Techniques*. Lea and Febiger, Philadelphia. pp195-19, (1987).
41. Moller H and Dollar J. *Regional Veterinary Surgery*. (Jenkins Veterinary Publisher and Bookseller, 1904).
42. Morton AJ. Diagnosis and treatment of septic arthritis. *Vet Clin North Am Equine Pract.* **21**(3):627-49, (2005).
43. Murphey ED, Santschi EM, Papich MG. Regional intravenous perfusion of the distal limb of horses with amikacin sulfate. *J Vet Pharmacol Ther.* **22**:68–71 (1999).
44. Nixon. A.J. Endoscopy of the digital flexor tendon sheath in horses. *Vet. Surg.* **19**:266-27 (1990).
45. Nixon. A.J. Septic tenosynovitis In: *Current Practice of Equine Surgery*. Eds: N.A. White I1 and J.N. Moore. J.B. Lippincott Co., Philadelphia. pp 451-45, (1990).
46. Parker RA, Bladon BM, McGovern K, Smith KC. Osteomyelitis and osteonecrosis after intraosseous perfusion with gentamicin. *Vet Surg.* **39**(5):644-8, (2010).
47. Parra-Sanchez A, Lugo J, Boothe DM, Gaughan EM, Hanson RR, Duran S, Belknap JK. Pharmacokinetics and pharmacodynamics of enrofloxacin and a low dose of amikacin administered via regional intravenous limb perfusion in standing horses. *Am J Vet Res.* **10**:1687-95 (2006).
48. Reardon RJ, Bailey R, Walmsley JP, Heller J, Lischer C. An in vitro biomechanical comparison of a locking compression plate fixation and kerf cut cylinder fixation for ventral arthrodesis of the fourth and the fifth equine cervical vertebrae. *Vet Surg.* **39**(8):980-90 (2010).

49. Reginato A, Ferreiro JL, O'Connor CR, *et al.* Clinical and pathologic studies of twenty-six patients with penetrating foreign body injury to the joints, bursae and tendon sheaths. *Arthritis Rheumatol.* **33**, 1753–1762 (1990).
50. Richardson GL, O'Brien TR, Pascoe JR and Meagher DM. Puncture Wounds of the Navicular Bursa in 38 Horses A Retrospective Study. *Vet. Surg.* **15**, 156–160 (1986).
51. Rose R and Love D. Staphylococcal septic arthritis in three horses. *Equine Vet. J.* **2**, (1979).
52. Ross MW and McIlwraith CW. Conformation and Lameness. In: Ross MW, Dyson SJ (eds.) *Diagnosis and management of lameness in the horse*. St Louis: Saunders Elsevier, pp15–30, (2003).
53. Rossignol F, Perrin R. Tenoscopy of the Navicular Bursa : Endoscopic Approach and Anatomy. *J Equine Vet Sci.* **23**(6):258–65, (2003).
54. Rubio-Martínez LM, Elmas CR, Black B, Monteith G. Clinical use of antimicrobial regional limb perfusion in horses: 174 case's (1999-2009). *J. Am. Vet. Med. Assoc.* **241**(12):1650-8 (2012).
55. Santschi E, Adams S, Foster J, and Widmer B. Treatment of bacterial tarsal tenosynovitis and osteitis of the sustentaculum tali of the calcaneus in five horses. *Equine Vet. J.* **29**, (1997).
56. Schneider RK, Bramlage LR, Moore RM, *et al.* A retrospective study of 192 horses affected with septic art h r i t i s / tenosynovi t i s. **24**, 436–442 (1992).
57. Schramme MC, Boswell JC, Hamhougias K, *et al.* An in vitro study to compare 5 different techniques for injection of the navicular bursa in the horse. *Equine Vet J.* **32**(3):263–7 (2000).
58. Smith MRW. Penetrating injuries of the foot. *Equine Vet. Educ.* **25**, 422–431 (2013).
59. Smith LJ, Mellor DJ, Marr CM, *et al.* What is the likelihood that a horse treated for septic digital tenosynovitis will return to its previous level of athletic function? *Equine Vet J.* **38**:337–341, (2006).
60. Smith MR, Wright IM. Endoscopic evaluation of the navicular bursa: observations, treatment and outcome in 92 case's with identified pathology. *Equine Vet J.* **44**(3):339-45 (2012).



61. Smith MRW, Wright IM and Smith RKW. Endoscopic assessment and treatment of lesions of the deep digital flexor tendon in the navicular bursae of 20 lame horses. *Equine Vet. J.* **39**, 18–24 (2007).
62. Steckel R R, Fessler J F and Huston LC. Deep puncture wounds of the equine hoof: a review of 50 case's. in *35th Annual Convention of the American Association of Equine Practitioners* 35, 167–176 (1989).
63. Stewart AA, Goodrich LR, Byron CR, *et al*: Antimicrobial delivery by intrasynovial catheterisation with systemic administration for equine synovial trauma and sepsis. *Aust Vet J.* **88**:115–123, (2010).
64. Summerhays GE. Treatment of traumatically induced synovial sepsis in horses with gentamicin-impregnated collagen sponges. *Vet Rec.* **147**(7):184-8 (2000).
65. ter Braake F. Direct endoscopic approach improves prognosis of septic-synovitis in the horse. *Tijdschr Diergeneeskd.* **127**:444–9, (2002).
66. Urraca del Junco C, Mair TS, Powell SE, *et al*. Magnetic resonance imaging findings of equine solar Penetration wounds. *Vet. Radiol. ultrasound* **53**, 71–75 (2011).
67. Van Wulfen K and Bowker R. Microanatomic characteristics of the insertion of the distal sesamoidean impar ligament and deep digital flexor tendon on the distal phalanx in healthy feet obtained from horses. *Am. J. Vet. Res.* 215–221 (2002).
68. Willemen MA, Savelberg HH, Barneveld A. The effect of orthopaedic shoeing on the force exerted by the deep digital flexor tendon on the navicular bone in horses. *Equine Vet J.* **31**(1):25-30 (1999).
69. Wright, IM. Arthroscopy of the navicular bursa as an alternative to streetnail procedures. in *39th American College of Veterinary Surgeons Veterinary Symposium* 80–81 (2004).
70. Wright IM, Phillips TJ and Walmsley JP. General Articles Endoscopy of the navicular bursa : A new technique for the treatment of contaminated and septic bursae. *Equine Vet. J.* **31**, 5–11 (1999).
71. Wright IM and Scott M. Management of penetrating wounds in joints, tendon sheaths and bursae. *Equine Vet. Educ.* **1**:15-22, (1989).
72. Wright IM, Smith MRW, Humphrey DJ, Eaton-Evans TCJ, and Hillyer MH. Endoscopic surgery in the treatment of contaminated and infected synovial cavities. *Equine Vet. J.* **35**, 613–9 (2003).

73. Lloyd KCK, Stover SM, Pascoe JR, *et al.* Plasma and synovial fluid concentration of gentamicin in horses after intra-articular administration of buffered and unbuffered gentamicin. *Am J Vet Res.* **49**:644-649 (1988).