



# THE UNIVERSITY *of* EDINBURGH

This thesis has been submitted in fulfilment of the requirements for a postgraduate degree (e.g. PhD, MPhil, DClinPsychol) at the University of Edinburgh. Please note the following terms and conditions of use:

This work is protected by copyright and other intellectual property rights, which are retained by the thesis author, unless otherwise stated.

A copy can be downloaded for personal non-commercial research or study, without prior permission or charge.

This thesis cannot be reproduced or quoted extensively from without first obtaining permission in writing from the author.

The content must not be changed in any way or sold commercially in any format or medium without the formal permission of the author.

When referring to this work, full bibliographic details including the author, title, awarding institution and date of the thesis must be given.

**Retinopathy and Central Nervous System Microcirculatory  
Abnormalities in Adult Cerebral Malaria and Their Prediction of Outcome**

**Richard James Maude**



**Doctor of Medicine  
University of Edinburgh  
2015**

## DECLARATION

This thesis has been composed by the candidate, Dr Richard James Maude.

### Candidate's contribution to the work:

I analysed all the data presented in this thesis and wrote all the manuscripts contained herein.

For the studies in Bangladesh and India I was Principal Investigator and was responsible for overall study design, patient enrolment, collection and analysis of data and preparation of manuscripts. I enrolled and followed up the majority of the patients and took the majority of the retinal photographs at these two study sites and performed all of the fluorescein angiograms in Chittagong. Fluorescein angiograms in India were performed by the local ophthalmology team. I reported all the retinal photographs and angiograms taken in Bangladesh and India. Semiautomated retinal vessel tortuosity measurements were done on archived retinal photographs by the VAMPIRE team at the University of Edinburgh.

Ultrasound measurement of optic nerve sheath diameters and reading of the videos was done in equal part by both myself and my wife, Rapeephan Rattanawongnara whom I supervised and trained in the technique. Reading of the magnetic resonance imaging films was done by Professor Frederik Barkhof following which I analysed the results. For the study in Malaysia I was responsible for study design, data analysis and preparation of the manuscript. I took the first few sets of retinal photographs in Malaysia but most patients were enrolled and photographed by the local study team. Retinal photographs in Malaysia were reported by myself, Baljean Dhillon and Shyamanga Borooah.

The work has not been submitted for any other degree or professional qualification.

I have read and understood The University of Edinburgh guidelines on plagiarism and declare that this written dissertation is all my own work except where I indicate otherwise by proper use of quotes and references.

Dr Richard James Maude

20<sup>th</sup> February 2015

# ABSTRACT

## Introduction

Malaria retinopathy is a set of visible changes in the retina which are specific to falciparum malaria. Studies to date have been mostly limited to comatose African children. Retinal changes in adults with severe malaria and severely unwell patients without malaria have been less well studied and the specificity, pathogenesis, diagnostic and prognostic value of malarial retinopathy in adults are not known.

## Methods

A series of observational studies of retinopathy in Bangladesh, India and Malaysia were done from 2008-2012. The aims were to describe the spectrum of retinal changes in falciparum and knowlesi malaria in adults, determine their specificity for severe falciparum malaria, quantify the impact of malaria retinopathy on visual function, understand its pathogenesis and assess the potential contribution of retinopathy to confirming diagnosis of malarial coma, predicting prognosis and understanding pathogenesis of cerebral malaria.

## Results

495 patients were enrolled and underwent retinal photography (305 with *P. falciparum* malaria (112 cerebral, 68 noncerebral severe, 125 uncomplicated), 44 *P. knowlesi*, 43 sepsis, 41 encephalopathy and 62 healthy). Retinal whitening and white-centred haemorrhages were common and specific to severe falciparum malaria. Retinopathy was most common and severe in cerebral (88%) and fatal (91%) falciparum malaria. Moderate-severe retinopathy was 95% specific for cerebral malaria in comatose patients, and its severity correlated with depth of coma. Vessel whitening was not seen and papilloedema was rare. In noncerebral severe falciparum malaria, retinopathy predicted increased likelihood of later development of coma and death. Retinal findings in Bangladeshi children were similar to those in adults. Optic nerve sheath diameter was mildly increased and brain swelling minimal on MRI. Severity of retinopathy correlated with plasma lactate, serum bicarbonate, sequestered parasite load and red cell stiffness suggesting a central role for microvascular obstruction in the pathogenesis. Severity of retinal whitening correlated with decreased visual acuity.

## Conclusions

Retinal changes seen in severe *P. falciparum* malaria in Asian adults is similar, but not identical, to that seen in African children. They have potential to help with diagnosis and prognosis of Asian adults with severe falciparum malaria. Microvascular obstruction is prominent in the pathogenesis of retinopathy and coma in adults whereas raised intracranial pressure is not.



---

## ACKNOWLEDGEMENTS

I would like to thank the British Infection Society and the Wellcome Trust of Great Britain for funding the work described in this thesis.

Work such as this cannot be undertaken without the assistance of others. In particular I would like to thank my supervisors Arjen M Dondorp and Baljean Dhillon for easing my introduction to the world of research as well as for all their help, guidance, knowledge and friendship. Special thanks also go to Nicholas J White, Nicholas PJ Day, M Abul Faiz, Md Amir Hossain, Nicholas Beare and Shyamanga Borooah for all their expert advice and assistance. Particular thanks go to Nicholas Beare and Simon Glover who taught me the essential skills of retinal photography, fluorescein angiography and indirect ophthalmoscopy in Malawi and Shyamanga Borooah who taught me ultrasound measurement of optic nerve sheath diameter in Edinburgh.

I would like to thank all the staff of Mahidol-Oxford Tropical Medicine Research Unit for their assistance with the studies, especially the malaria team, in particular Kesinee Chotivanich, Kamolrat Silamut, Prakaykaew Charunwatthana, Katherine Plewes, Hugh Kingston, Trent Herdman and my wife, Rapeephan Maude, as well as numerous staff in the various support teams at MORU.

Large clinical studies such as those presented here necessarily involve contributions from large numbers of people. Although they are too numerous to name every one, I would also like to express my gratitude to my collaborators and co-authors, in particular the numerous doctors and hospital staff who assisted with the recruitment of patients and collection of data at Chittagong Medical College and Malaria Research Group, Chittagong, Bangladesh including Sanjib Kanti Pal, Sumon Sharma and Safiqul Mostafa Chy; Sanjib Mohanty and Saroj Mishra at Ispat General Hospital, Rourkela, India; Nick Anstey, Tsin Yeo and Bridget Barber at Menzies School of Health Research, Darwin, Australia; and Timothy Williams and Gayathri Govindasamy at Queen Elizabeth Hospital, Kota Kinabalu, Malaysia.

Finally, and most especially, I would like to thank my wife and family for their enduring support and encouragement without which I would not have completed this work.

---

## PUBLICATIONS ARISING FROM THIS THESIS

### Publication of material included in this thesis

- Govindasamy G, Barber BE, Ghani SA, William T, Grigg MJ, Borooah S, Dhillon B, Dondorp AM, Yeo TW, Anstey NM, **Maude RJ**. Retinal Changes in Uncomplicated and Severe Plasmodium knowlesi Malaria. *J Infect Dis*. 2016;213:1476-82.
- **Maude RJ**, Kingston H, Joshi S, Mishra S, Mohanty S, White NJ, Dondorp AM. Reversibility of retinal microvascular changes in severe malaria. *Am J Trop Med Hyg*. 2014;91:493-5.
- **Maude RJ**, Barkhof F, Hassan MU, Ghose A, Hossain A, Faiz MA, Choudhury E, Rashid R, Abu Sayeed A, Charunwatthana P, Plewes K, Kingston H, Maude RR, Silamut K, Day NPJ, White NJ, Dondorp AM. Magnetic resonance imaging of the brain in adults with severe falciparum malaria. *Malar J*. 2014;13:177.
- Maude RR, Hossain MA, Hassan MU, Osbourne S, Langan K, Sayeed MA, Karim MR, Samad R, Borooah S, Dhillon B, Day NPJ, Dondorp AM, **Maude RJ**. Transorbital sonographic evaluation of normal optic nerve sheath diameter in healthy volunteers in Bangladesh. *PLOS One*. 2013; 8:e81013.
- Vink JP, Laubscher M, Vlutters R, Silamut K, **Maude RJ**, Hasan MU, de Haan G. An automatic vision-based malaria diagnosis system. *J Microscopy*. 2013;250:166-78.
- **Maude RJ**, Plewes K, Dimock J, Dondorp AM. Low-cost portable fluorescein angiography. *Br J Ophthal*. 2011;95:1213-5.
- Glover S, **Maude RJ**, Beare NAV, Taylor TE, Molyneux M. Malarial retinopathy and fluorescein angiography findings in a Malawian child with cerebral malaria. *Lancet Infect Dis*. 2010;10:440.
- **Maude RJ**, Beare NAV, Abu Sayeed A, Chang CC, Charunwatthana P, Faiz MA, Hossain A, Bin Yunus E, Hoque MG, Hasan MU<sup>5</sup>, White NJ, Day NPJ, Dondorp AM. The spectrum of retinopathy in adults with *P. falciparum* malaria. *Trans R Soc Trop Med Hyg*. 2009;103:665-71.
- **Maude RJ**, Hasan MU, Beare NAV. Severe retinal whitening in an adult with cerebral malaria. *Am J Trop Med Hyg*. 2009;80:881.

- 
- **Maude RJ**, Dondorp AM, Abu Sayeed A, Day NPJ, White NJ, Beare NAV. The eye in cerebral malaria: what can it teach us? *Trans R Soc Trop Med Hyg.* 2009;103:661-4.

**Publications of material arising from work related to, but not included, in the thesis**

- Zaloumis S, Tarning J, Krishna S, Price R, White NJ, Davis T, McCaw J, Olliaro P, **Maude RJ**, Kremsner P, Dondorp AM, Gomes M, Barnes K, Simpson J. Population pharmacokinetics of intravenous artesunate: a pooled analysis of individual data from patients with severe malaria. *CPT Pharmacometrics Syst Pharmacol.* 2014;3:e145.
- **Maude RJ**, Ahmed BUMW, Rahman AHMW, Rahman R, Majumder MI, Braganza Menezes D, Abu Sayeed A, Hughes L, MacGillivray TJ, Borooah S, Dhillon B, Dondorp AM, Faiz MA. Retinal Changes in Visceral Leishmaniasis by Retinal Photography. *BMC Infect Dis.* 2014;14:527.
- Plewes K, Royackers AA, Hanson J, Hasan MM, Alam S, Ghose A, **Maude RJ**, Stassen PM, Charunwatthana P, Lee SJ, Turner GD, Dondorp AM, Schultz MJ. Correlation of biomarkers for parasite burden and immune activation with acute kidney injury in severe falciparum malaria. *Malar J.* 2014;13:91.
- Hanson J, Lee SJ, Mohanty S, Faiz MA, Anstey NM, Price RN, Charunwatthana P, Yunus EB, Mishra SK, Tjitra E, Rahman R, Nosten F, Htut Y, **Maude RJ**, Thi Hong Chau T, Phu NH, Hien TT, White NJ, Day NP, Dondorp AM. Rapid clinical assessment to facilitate the triage of adults with falciparum malaria, a retrospective analysis. *PLoS One.* 2014; 9:e87020.
- **Maude RJ**, Silamut K, Plewes K, Charunwatthana P, Ho M, Faiz MA, Rahman R, Hossain MA, Hassan MU, Yunus EB, Hoque G, Islam F Ghose A, Hanson J, Schlatter J, Lacey R, Eastaugh A, Tarning J, Lee SJ, White NJ, Chotivanich K, Day NPJ, Dondorp AM. Randomised controlled trial of levamisole hydrochloride as adjunctive therapy in severe falciparum malaria with high parasitaemia. *J Infect Dis.* 2014; 209:20-9.
- Kolyva C, Kingston H, Tachtsidis I, Mohanty S, Mishra S, Patnaik R, **Maude RJ**, Dondorp AM, Elwell CE. Oscillations in cerebral hemodynamics in patients with falciparum malaria. *Adv Exp Med Biol.* 2013;300:121.

- 
- Maude RR, Vaid N, Ghose A, Amin R, Samad R, Bin Yunus E, Rahman MR, Bengali AM, Hoque MG, Day NP, White NJ, White LJ, Dondorp AM, Faiz MA. Temporal trends in severe malaria in Chittagong, Bangladesh. *Malar J.* 2012;11:323.
  - Joshi VS, **Maude RJ**, Reinhardt JM, Tang L, Garvin MK, Sayeed AA, Ghose A, Hassan MU, Abramoff MD. Automated detection of malarial retinopathy-associated retinal hemorrhages. *Invest Ophthalmol Vis Sci.* 2012;53:6582-8.
  - Hanson J, Lam S, Mahanta KC, Pattnaik R, Alam S, Mohanty S, Hasan MU, Hossain A, Charunwatthana P, Chotivanich K, **Maude RJ**, Kingston H, Day NPJ, Mishra S, White NJ, Dondorp AM. Relative contributions of macrovascular and microvascular dysfunction to disease severity in falciparum malaria. *Malar J.* 2012;206:571-9.
  - **Maude RJ**, Hoque MG, Hasan MU, Abu Sayeed M, Akter S, Samad R, Alam B, Bin Yunus E, Rahman MR, Rahman MW, Chowdhury R, Seal T, Charunwatthana P, Chang CC, White NJ, Faiz MA, Day NPJ, Dondorp AM, Hossain MA. Timing of enteral feeding in cerebral malaria in resource-poor settings: a randomized trial. *PLOS One.* 2011;6:e27273.
  - Hanson J, Hasan MM, Royackers AA, Alam S, Charunwatthana P, **Maude RJ**, Douthwaite ST, Yunus EB, Mantha ML, Schultz MJ, Faiz MA, White NJ, Day NP, Dondorp AM. Laboratory prediction of the requirement for renal replacement in acute falciparum malaria. *Malar J.* 2011;10:217
  - Abu Sayeed A, **Maude RJ**, Uddin Hassan M, Mohammed N, Hoque M, Dondorp AM, Faiz MA. Malarial retinopathy in Bangladeshi adults. *Am J Trop Med Hyg.* 2011;84:141-7.
  - Löwenberg EC, Charunwatthana P, Cohen S, van den Born BJ, Meijers JC, Yunus EB, Hassan MU, Hoque G, **Maude RJ**, Nuchsongsin F, Levi M, Dondorp AM. Severe malaria is associated with a deficiency of von Willebrand factor cleaving protease, ADAMTS13. *Thromb Haemost.* 2010;103:181-7.
  - **Maude RJ**, Hasan MU, Douthwaite ST, Ghose A, Faiz MA, Dondorp AM. Studies on severe malaria are still possible and essential. *Clin Infect Dis.* 2010;50:281-2.
  - **Maude RJ**, Bin Yunus E, Hoque MG, Hassan MU, Hossain MA, Samad R, Rahman R, Ghose A, White NJ, Dondorp AM, Faiz MA. MORU and CMCH: a highly successful collaboration. *JCMCTA.* 2009;20:2-5.

- **Maude RJ**, Beare NAV. Fluorescein angiography findings strengthen the theoretical basis for trialling neuroprotective agents in cerebral malaria. *Trends Parasitol.* 2009;25:350-1.

---

## TABLE OF CONTENTS

DECLARATION .....	1
ABSTRACT.....	2
ACKNOWLEDGEMENTS .....	3
PUBLICATIONS ARISING FROM THIS THESIS .....	4
TABLE OF CONTENTS .....	8
LIST OF FIGURES AND TABLES.....	13
GLOSSARY.....	17
OUTLINE .....	19
Chapter 1 Introduction.....	20
1.1 Background .....	21
1.1.1 Clinical malaria .....	21
1.1.2 Pathogenesis of cerebral falciparum malaria.....	34
1.1.3 Retinal changes in malaria .....	48
1.2 Summary .....	61
1.3 Aims of this thesis .....	62
Research question:.....	62
Chapter 2 Retinopathy in <i>P. falciparum</i> malaria.....	63
2.1 Abstract.....	64
2.2 Introduction .....	64
2.3 Methods.....	67
2.3.1 Study site and patients.....	67
2.3.2 Clinical assessment.....	71
2.3.3 Investigations .....	71
2.3.4 Fundoscopy and retinal photography .....	73

---

2.3.5	Statistical analysis .....	75
<b>2.4</b>	<b>Results.....</b>	<b>76</b>
2.4.1	Patients recruited.....	76
2.4.2	Retinal photographs.....	83
2.4.3	Retinopathy as a diagnostic marker.....	85
2.4.4	Retinopathy as a prognostic marker .....	98
2.4.5	Retinopathy and visual function .....	101
2.4.6	Retinopathy and pathogenesis of severe malaria.....	103
	Lactate.....	103
	Bicarbonate.....	104
	Parasite count .....	105
	Parasite biomass .....	106
	Sequestered parasite biomass.....	107
	Haematocrit .....	108
	Platelets .....	109
	Red cell deformability .....	110
	Retinal Blood vessel tortuosity .....	117
<b>2.5</b>	<b>Discussion .....</b>	<b>120</b>
2.5.1	Summary of main findings and implications.....	120
2.5.2	Diagnosis .....	120
2.5.3	Prognosis .....	125
2.5.4	Visual function.....	127
2.5.5	Adults versus children .....	128
2.5.6	Pathogenesis .....	132
2.5.7	Limitations.....	136
<b>2.6</b>	<b>Conclusions .....</b>	<b>137</b>
<b>Chapter 3</b>	<b><i>P. falciparum</i> and optic nerve sheath diameter .....</b>	<b>139</b>
<b>3.1</b>	<b>Summary .....</b>	<b>140</b>

---

3.2	Normal range for ONSD in Bangladesh .....	141
3.2.1	Abstract .....	141
3.2.2	Introduction .....	141
3.2.3	Material and Methods .....	143
3.2.4	Results .....	144
3.2.5	Discussion.....	146
3.2.6	Conclusions .....	148
3.3	ONSD in severe falciparum malaria .....	149
3.3.1	Abstract .....	149
3.3.2	Introduction .....	149
3.3.3	Methods .....	151
3.3.4	Results .....	151
3.3.5	Discussion.....	154
3.3.6	Conclusions .....	155
Chapter 4	<i>P. falciparum</i> retinopathy and fluorescein angiography	156
4.1	Summary .....	157
4.2	Low cost fluorescein angiography .....	158
4.2.1	Abstract .....	158
4.2.2	Introduction .....	158
4.2.3	Method.....	160
4.2.4	Conclusions .....	162
4.3	Example fluorescein angiograms in severe malaria .....	163
4.4	Case report.....	168
4.4.1	Abstract .....	168
4.4.2	Introduction .....	168
4.4.3	Case description .....	168
4.4.4	Discussion.....	170
4.4.5	Conclusions .....	172



---

Chapter 5	<i>P. falciparum</i> retinopathy and magnetic resonance imaging of the brain .....	173
5.1	Abstract.....	174
5.2	Introduction .....	174
5.3	Methods.....	175
5.4	Results.....	178
5.5	Discussion .....	186
5.6	Conclusions .....	188
Chapter 6	Retinopathy in <i>P. knowlesi</i> malaria .....	189
6.1	Abstract.....	190
6.2	Introduction .....	190
6.3	Methods.....	191
6.4	Results.....	193
6.5	Discussion .....	200
6.6	Conclusions .....	202
Chapter 7	Summary of Results .....	204
7.1	Summary of results from each Chapter .....	205
Chapter 8	Discussion .....	207
8.1	General discussion .....	208
8.2	Critique .....	210
Chapter 9	Conclusions.....	216
9.1	Summary .....	217
9.2	Implications and impact .....	218
9.3	Future Directions.....	222
9.4	Conclusion.....	225

---

Chapter 10 APPENDIX.....	226
10.1 Grading of Malaria Retinopathy .....	227
10.2 Data collection forms .....	241
10.2.1 Enrolment .....	241
10.2.2 Eye history.....	242
10.2.3 Visual Function.....	243
10.2.4 Fundoscopy and Retinal Photography .....	244
10.2.5 Fluorescein angiography .....	245
10.3 Normal ranges for laboratory tests .....	246
BIBLIOGRAPHY .....	247

---

## LIST OF FIGURES AND TABLES

### FIGURES

Figure 1.1-1. The <i>Plasmodium falciparum</i> malaria parasite life cycle. ....	26
Figure 1.1-2. The <i>Plasmodium knowlesi</i> malaria parasite life cycle.....	27
Figure 1.1-3. Pathogenesis of cerebral falciparum malaria. ....	35
Figure 1.1-4. Examples of retinal changes seen in severe falciparum malaria.....	51
Figure 1.1-5. Areas of the retina used for classification of malaria retinopathy. ....	52
Figure 2.3-1. The 9 field retinal photography protocol. ....	74
Figure 2.4-1. Frequency and severity of retinopathy in patients of all ages with malaria, sepsis, encephalopathy and healthy controls.....	85
Figure 2.4-2. Frequency and severity of retinopathy in adults and children with malaria, sepsis, encephalopathy and healthy controls. ....	86
Figure 2.4-3. Frequency and severity of retinopathy excluding papilloedema and in those with bilateral changes only in patients of all ages with malaria, sepsis, encephalopathy and healthy controls.....	87
Figure 2.4-4. Papilloedema and severe white-centred retinal haemorrhages in Bangladeshi adult with cerebral malaria. ....	88
Figure 2.4-5. Papilloedema in Bangladeshi child with nonmalarial febrile encephalopathy. ....	89
Figure 2.4-6. Frequency and severity of retinal haemorrhages in each group.....	90
Figure 2.4-7. Numbers of retinal haemorrhages seen in individuals in each group.....	90
Figure 2.4-8. Proportion of individuals with white-centred haemorrhages. ....	91
Figure 2.4-9. Multiple white-centred retinal haemorrhages in Bangladeshi adult with cerebral malaria. ....	91
Figure 2.4-10. Severe white-centred retinal haemorrhages in Bangladeshi adult with noncerebral severe malaria. ....	92
Figure 2.4-11. Frequency and severity of retinal whitening in each group. ....	93
Figure 2.4-12. Severe macular and mild peripheral retinal whitening in Bangladeshi adult with cerebral malaria. ....	94
Figure 2.4-13. Severe macular and peripheral retinal whitening in Bangladeshi adult with cerebral malaria. ....	95
Figure 2.4-14. Retinal photograph of right eye from Bangladeshi adult with sepsis. ....	96

---

Figure 2.4-15. Retinal photographs of right and left eyes from Bangladeshi adult with nonmalarial febrile encephalopathy. ....	96
Figure 2.4-16. Severity of retinopathy and GCS in patients with severe .....	97
Figure 2.4-17. Frequency and severity of retinopathy in fatal and nonfatal severe malaria. ....	98
Figure 2.4-18. Frequency and severity of retinopathy in fatal and nonfatal cerebral and noncerebral severe malaria. ....	99
Figure 2.4-19. Mortality in noncerebral severe and cerebral malaria with different grades of overall retinopathy and retinal whitening. ....	99
Figure 2.4-20. Frequency and severity of retinopathy in patients with noncerebral severe malaria who did and did not develop coma during their admission. ....	100
Figure 2.4-21. Frequency and severity of retinopathy in fatal and nonfatal severe malaria in those who did and did not develop coma during admission. ....	101
Figure 2.4-22. Visual acuity in patients with falciparum malaria and different severities of macular whitening.....	101
Figure 2.4-23. Visual acuity in patients with severe and uncomplicated malaria, sepsis and healthy individuals. ....	102
Figure 2.4-24. Severity of macular whitening in patients with falciparum malaria with and without colour blindness on enrolment.....	102
Figure 2.4-25. Plasma lactate and severity of retinopathy in patients with severe malaria. ....	103
Figure 2.4-26. Venous plasma bicarbonate and severity of retinopathy in patients with severe malaria. ....	104
Figure 2.4-27. Log peripheral blood parasite count and severity of retinopathy in patients with severe malaria. ....	105
Figure 2.4-28. Log <i>Pf</i> HRP2-derived parasite biomass and severity of retinopathy in patients with severe malaria. ....	106
Figure 2.4-29. Log sequestered parasite biomass and severity of retinopathy in patients with severe malaria. ....	107
Figure 2.4-30. Haematocrit and severity of retinopathy in patients with severe malaria. .	108
Figure 2.4-31. Log (platelet count) and severity of retinal whitening in patients with severe malaria.....	109
Figure 2.4-32. Red cell deformability (elongation index) by study group. ....	111
Figure 2.4-33. Red cell deformability (elongation index) and severity of retinal whitening at different shear stresses (following 5 pages). ....	112

---

Figure 2.4-34. Tortuosity and vessel width in each group of study subjects.....	118
Figure 2.4-35. Tortuosity and vessel width in venules vs GCS.....	119
Figure 3.2-1. Distribution of mean optic nerve sheath diameter (ONSD) measurements. .	145
Figure 3.2-2. Optic nerve sheath diameter (ONSD) and age. ....	145
Figure 3.2-3. Optic nerve sheath diameter (ONSD) and head circumference.....	146
Figure 3.3-1. Optic nerve sheath diameter (ONSD) in malaria and sepsis compared to healthy controls.....	152
Figure 3.3-2. Optic nerve sheath diameter (ONSD) in fatal versus nonfatal severe falciparum malaria.....	153
Figure 3.3-3. Optic nerve sheath diameter (ONSD) in adults versus children with severe and uncomplicated falciparum malaria. ....	153
Figure 4.2-1. Fluorescein filter assembly. ....	161
Figure 4.3-1. Widespread retinal whitening and patchy hypoperfusion.....	163
Figure 4.3-2. Widespread punctate retinal whitening and hyperfluorescence.....	164
Figure 4.3-3. Macular and foveal retinal whitening, early hypoperfusion. ....	165
Figure 4.3-4. Macular and foveal retinal whitening and late hyperfluorescence.....	166
Figure 4.3-5. Macular and foveal retinal whitening with hypoperfusion. ....	167
Figure 4.4-1. Retinal photographs and fluorescein angiograms in severe falciparum malaria on admission and recovery. ....	169
Figure 5.4-1. Examples of MRIs from 4 patients with severe malaria. ....	181
Figure 5.4-2. Summary of retinal findings.....	184
Figure 5.4-3. Proportion of patients with and without coma with different grades of retinal whitening.....	184
Figure 5.4-4. Retinal photograph and MRI from patient with cerebral malaria (GCS=8 on enrollment), hyperlactaemia and 98% sequestered biomass.....	185
Figure 6.4-1. Common retinal lesions in patients with knowlesi malaria.....	197
Figure 6.4-2. Vessel whitening (left) with normal fluorescein angiogram (right) in a patient with non-severe knowlesi malaria. ....	199
Figure 6.4-3. Non-specific retinal whitening (left) with normal fluorescein angiogram (right) in a patient with non-severe knowlesi malaria. ....	199

---

**TABLES**

Table 1.1-1. World Health Organization criteria for severe <i>P. falciparum</i> malaria. <sup>13</sup> .....	22
Table 2.4-1. Summary of subjects recruited in Chittagong and Rourkela. ....	76
Table 2.4-2. Baseline characteristics of recruited patients in each group in Chittagong and Rourkela. ....	78
Table 2.4-3. Mortality, severity indicators and selected blood results present on enrolment in patients with severe malaria with and without retinopathy. ....	80
Table 2.4-4. History in recruited individuals .....	82
Table 2.4-5. Quality indicators for retinal photography. ....	83
Table 3.3-1. Severity features in patients with severe malaria on enrolment. ....	152
Table 5.4-1. Presenting severity signs of enrolled patients. ....	179
Table 5.4-2. MRI findings in 43 Bangladeshi patients with severe and cerebral malaria. ...	180
Table 6.4-1. Baseline features of patients with knowlesi malaria .....	194
Table 6.4-2. Visual assessment and eye examination findings outside the retina in patients with knowlesi malaria .....	195
Table 6.4-3. Retinal findings among patients with knowlesi malaria .....	196
Table 7.1-1. Summary of the main results for each Chapter .....	205

---

## GLOSSARY

ACT	artemisinin combination therapy
AC-PC	anterior-posterior commissure
AI	axonal injury
Ang	angiopoietin
APP	amyloid precursor protein
Tie-2	tyrosine kinase receptor
APP	amyloid precursor protein
BBB	blood brain barrier
BCS	Blantyre Coma Score
BG	basal ganglia
BRB	blood retinal barrier
CAM	coma acidosis malaria
CCI	intraclass correlation coefficient
CI	confidence interval
CM	cerebral malaria
CNS	central nervous system
CRVO	central retinal vein occlusion
CSF	cerebrospinal fluid
CT	computed tomography
DWI	diffusion weighted imaging
eGFR	estimated glomerular filtration rate
EI	elongation index
ELISA	enzyme-linked immunosorbent assay
FFA	fluorescein angiography
FLAIR	fluid attenuated inversion recovery
GCS	Glasgow Coma Scale
GRE	gradient echo
Hb	haemoglobin
Hct	haematocrit
HLA	human leukocyte antigen
HRP2	histidine rich protein 2
ICAM1	intercellular adhesion molecule 1 (CD54)
ICP	intracranial pressure
IFN	interferon
IL	interleukin
iNOS	inducible nitric oxide synthase
IQR	interquartile range

---

iRBC	infected red blood cells
LDH	lactate dehydrogenase
LORCA	Laser Optical Rotational Cell Analyser
MRI	magnetic resonance imaging
MRS	magnetic resonance spectroscopy
NIRS	near infrared spectroscopy
NA	not assessed
NAA	N-acetyl aspartate
NO	nitric oxide
NOS2	nitric oxide synthase 2
NPV	negative predictive value
OD	optic disc
ONSD	optic nerve sheath diameter
OPS	Orthogonal Polarising Spectroscopy
PCR	polymerase chain reaction
<i>P. falciparum</i>	<i>Plasmodium falciparum</i>
PF	posterior fossa
PfEMP1	<i>Plasmodium falciparum</i> erythrocyte membrane protein 1
<i>PfHRP2</i>	<i>Plasmodium falciparum</i> histidine rich protein 2
PIRW	patchy ischaemic retinal whitening
<i>P. knowlesi</i>	<i>Plasmodium knowlesi</i>
PPV	positive predictive value
RBC	red blood cell
RDT	rapid diagnostic test
RR	relative risk
SD	standard deviation
SEM	standard error of the mean
SP	sulfadoxine-pyrimethamine
ST	supratentorial region
STEAM	stimulated echo acquisition mode
T1-SE	T1 spin echo
TE	short echo time
TNF	tumour necrosis factor
VAMPIRE	Vessel Assessment and Measurement Platform for Images of the Retina
VCAM-1	vascular cell adhesion protein-1
vWF	von Willebrand factor
WHO	World Health Organisation



---

## OUTLINE

### Summary of Chapters

**Chapter 1** is the Introduction. It gives a background to the thesis introducing malaria, severe malaria pathogenesis and malaria retinopathy.

**Chapter 2** presents a series of studies on retinopathy in *P. falciparum* malaria in Bangladesh and India as compared to sepsis, nonmalarial encephalopathy and healthy individuals. These studies describe the spectrum of retinal findings in adult falciparum malaria, investigate the potential role of malarial retinopathy as a diagnostic and prognostic marker, assess its effect on visual function, and examine its pathogenesis in relation to known contributors to, and markers of, systemic microcirculatory blood flow obstruction.

**Chapter 3** presents two studies using optic nerve sheath diameter as a marker of intracranial pressure. The first study determines the normal range in Bangladesh and the second investigates intracranial pressure in severe and uncomplicated falciparum malaria and sepsis.

**Chapter 4** describes use of fluorescein angiography in severe falciparum malaria to study microvascular changes. It presents a novel, low cost method for doing bedside fluorescein angiography and shows some preliminary findings.

**Chapter 5** describes a study using magnetic resonance imaging of the brain in combination with retinal photography and optic nerve sheath diameter in adults with severe falciparum malaria. It investigates which MRI findings are specific to coma and to death in severe falciparum malaria, and explores how well retinopathy reflects changes in the brain.

**Chapter 6** describes a study of retinal findings in severe and uncomplicated *P. knowlesi* malaria in Sabah, Malaysia

**Chapter 7** is a summary of the Results.

**Chapter 8** is the general Discussion and Critique.

**Chapter 9** is the Conclusions.

**Chapter 10** is the Appendix.

## **Chapter 1 Introduction**

## 1.1 Background

### 1.1.1 Clinical malaria

#### Epidemiology

Malaria is a parasitic infection of red blood cells caused by protozoa of the genus *Plasmodium* which occurs across much of the tropics. Five species of *Plasmodia* infect humans. These are *P. falciparum*, *P. vivax*, *P. malariae*, *P. ovale* and *P. knowlesi*. By far the commonest are *P. vivax* and *P. falciparum* with the latter being the main cause of severe and fatal malaria. Estimates vary but it is thought that *P. falciparum* causes around half a million deaths and 200 million cases annually worldwide, and 90% of these deaths are in African children.<sup>1</sup> *P. vivax* causes a similar number of clinical cases to *P. falciparum* worldwide but the incidence of severe disease and death are much lower.<sup>2</sup> In Africa, most infections are due to *P. falciparum*, with *P. vivax* being rare, particularly in West Africa. This is thought to be largely due to the predominance of an inherited red cell phenotype, the Duffy negative trait, which prevents invasion of human red blood cells by the *P. vivax* parasite. Elsewhere in the tropics, including in South and Southeast Asia, *P. vivax* causes around half of the clinical cases of malaria. *P. knowlesi* is found principally in Malaysia where it is thought to cause over 50%<sup>3</sup> of cases and is the commonest cause of severe malaria in Sabah.<sup>4</sup> It has also been found in Indonesia<sup>5</sup> and occasionally in Myanmar,<sup>6</sup> Vietnam,<sup>7</sup> Thailand<sup>8</sup> and the Philippines.<sup>9</sup> Due partly to difficulties distinguishing *P. knowlesi* from other *Plasmodium* species on light microscopy its incidence is probably grossly under-reported.<sup>10</sup> It is also likely that the geographical extent of *P. knowlesi* endemicity is much greater than currently appreciated.<sup>11</sup>

#### Clinical features

In those who become symptomatic with malaria, infection most commonly causes uncomplicated disease. This is typically a non-specific illness similar to a systemic viral infection. Symptoms include fever, chills, perspiration, myalgia, fatigue, headache, anorexia, nausea and vomiting. Well-defined malaria paroxysms of periodic high fever, chills and rigors can occur, particularly in infections due to *P. vivax* or *P. ovale*.

In *P. falciparum* malaria, with early effective treatment and no evidence of vital organ dysfunction, recovery is rapid and mortality very low. In a minority, especially those who

receive late or no antimalarial treatment, the parasite burden increases further and results in severe malaria, the features of which can include coma (cerebral malaria), severe anaemia, metabolic acidosis, hypoglycaemia, renal failure, jaundice, pulmonary oedema and shock. The incidences of anaemia and convulsions decrease with age and the incidences of hyperparasitaemia, jaundice and renal failure increase with age. Multi-organ failure is commoner in adults than in children.<sup>12</sup> The World Health Organization (WHO) have a broad definition for severe falciparum malaria summarised in **Table 1.1-1**.<sup>13</sup>

**Table 1.1-1. World Health Organization criteria for severe *P. falciparum* malaria.**<sup>13</sup>

<i>P. falciparum</i> asexual parasitaemia plus no other obvious cause of symptoms plus one or more of:
<p>A. Clinical features:</p> <ol style="list-style-type: none"> <li>1) impaired consciousness or unrousable coma</li> <li>2) prostration, i.e. generalized weakness so that the patient is unable walk, or sit up without assistance</li> <li>3) failure to feed</li> <li>4) multiple convulsions (more than two episodes in 24 h)</li> <li>6) deep breathing, respiratory distress (acidotic breathing)</li> <li>7) circulatory collapse or shock (systolic blood pressure &lt; 70 mm Hg in adults and &lt; 50 mm Hg in children)</li> <li>8) clinical jaundice plus evidence of other vital organ dysfunction</li> <li>9) haemoglobinuria</li> <li>10) abnormal spontaneous bleeding</li> <li>11) pulmonary oedema (radiological)</li> </ol>
<p>B. Laboratory findings:</p> <ol style="list-style-type: none"> <li>1) hypoglycaemia (blood glucose &lt; 2.2 mmol/l or &lt; 40 mg/dl)</li> <li>2) metabolic acidosis (plasma bicarbonate &lt; 15 mmol/l)</li> <li>3) severe normocytic anaemia (Hb &lt; 5 g/dl, packed cell volume &lt; 15%)</li> <li>4) haemoglobinuria</li> <li>5) hyperparasitaemia (&gt; 2%/100,000/μl in areas of low transmission intensity or &gt; 5% or 250,000/μl in areas of high stable transmission intensity)</li> <li>6) hyperlactataemia (lactate &gt; 5 mmol/l)</li> <li>7) renal impairment (serum creatinine &gt; 265 μmol/l)</li> </ol>

As will be described later in this introduction, few of these criteria independently predict mortality and in clinical observational studies and treatment trials a stricter definition is usually used. One such commonly accepted definition is used throughout this thesis and is described in detail in **Section 2.3.1**.

Severe *P. knowlesi* and *P. vivax* malaria are less well defined than severe *P. falciparum* malaria. One reason for this is that they have only been described relatively recently, *P. vivax* having been thought to be benign and *P. knowlesi* only having been first reported to be commonly found in humans in 2004.<sup>14</sup> The WHO criteria for severe *P. falciparum* are often used to define severe vivax and knowlesi in the literature however there are differences in clinical presentation with, for example, coma being much less common than *P. falciparum*. Severe *P. vivax* malaria may present with severe anaemia, respiratory distress, acute renal failure, jaundice and/or shock and may result in splenic rupture.<sup>15</sup> Estimated mortality in patients hospitalised with *P. vivax* varies from 0.2 to 4%.<sup>15</sup> Severe *P. knowlesi* malaria commonly presents with acute respiratory distress, acute renal failure, shock, hyperbilirubinaemia and/or acidosis and mortality from severe disease was 27% in one series.<sup>16</sup> These differences in presentation and disease severity between the different Plasmodium species in humans are thought to be at least in part due to differences in virulence, red cell tropism, cytoadherence and dormant liver stages.

## Immunity

Although poorly understood, protective immunity to falciparum malaria is known to be related to the intensity of transmission and results in lower parasite densities (antiparasite immunity), fewer or no symptoms, protection from severe disease and lower mortality (antidisease immunity). In areas of high transmission intensity, such as sub-Saharan Africa, most symptomatic infections and most deaths occur in children, particularly less than 5 years of age. This is because frequent infections with *P. falciparum* induce gradual accumulation of protective immunity through childhood (premonition). By adulthood, most people infected with malaria in areas of high transmission intensity are asymptomatic, severe malaria is rare and there are few deaths. In areas of low transmission intensity, such as most endemic parts of Asia and Latin America, exposure to infection is less frequent and protective immunity does not accumulate. Thus symptomatic infection, severe and fatal malaria occur with similar frequency in all age groups and most adults infected with malaria

become symptomatic. In many low transmission settings, including Bangladesh,<sup>17</sup> India<sup>18</sup> and Malaysia,<sup>19</sup> infection is commonest in young adult males, at least partly because of age-specific occupational and risk behaviours such as forest exposure.

Immunity to falciparum malaria has been studied intensively with a particular focus on naturally acquired immunity as a model for development of potential vaccines and potential for loss of immunity during malaria control and elimination efforts. Of the two main types of naturally acquired immunity to *P. falciparum*, antidisease immunity appears to be acquired more quickly than antiparasite immunity. Sterilising immunity is not achieved and an asymptomatic carrier status occurs in many untreated individuals, particularly with ongoing exposure in high transmission areas. In the absence of ongoing exposure, immunity wanes and individuals previously protected from symptoms can become symptomatic with an increase in parasitaemia or upon reinfection.

Although the features of immunity to *P. falciparum* have been well described, the mechanism of immunity is not well understood. Children in the first 6 months of life experience antidisease immunity. This is thought to be either from maternal immunoglobulin G (IgG) antibodies acquired in utero or parasite growth inhibitors or IgA in breast milk. After these first 6 months, antimalarial immunity is thought to occur through a combination of humoral and cellular immunity. There is thought to be some immunity across different strains of *P. falciparum* from cross reacting antibodies and some immunity that is strain specific. In addition, there is antigenic variation within a particular strain. The relative importance of these different types has not been elucidated. Of note is that the risk of severe malaria increases in pregnancy and this is thought to be due to this being a state of relative immunosuppression through impaired cellular immunity through increased cytokine production and increase in certain hormones including cortisol.<sup>20</sup>

There has been much less research on immunity to the other Plasmodium species in humans. Non-sterilising immunity occurs to *P. vivax* and, similar to *P. falciparum*, this reduces parasite numbers and morbidity. Protection against *P. vivax* has been found to be associated with IgG responses to a range of antigens with considerable heterogeneity between studies.<sup>21</sup>

Certain haemoglobinopathies confer innate protection against malaria. Haemoglobin AS, CC and AC, as well as alpha thalassaemia protect against severe falciparum malaria, but less so against uncomplicated malaria and asymptomatic parasitaemia but not against.<sup>22</sup>

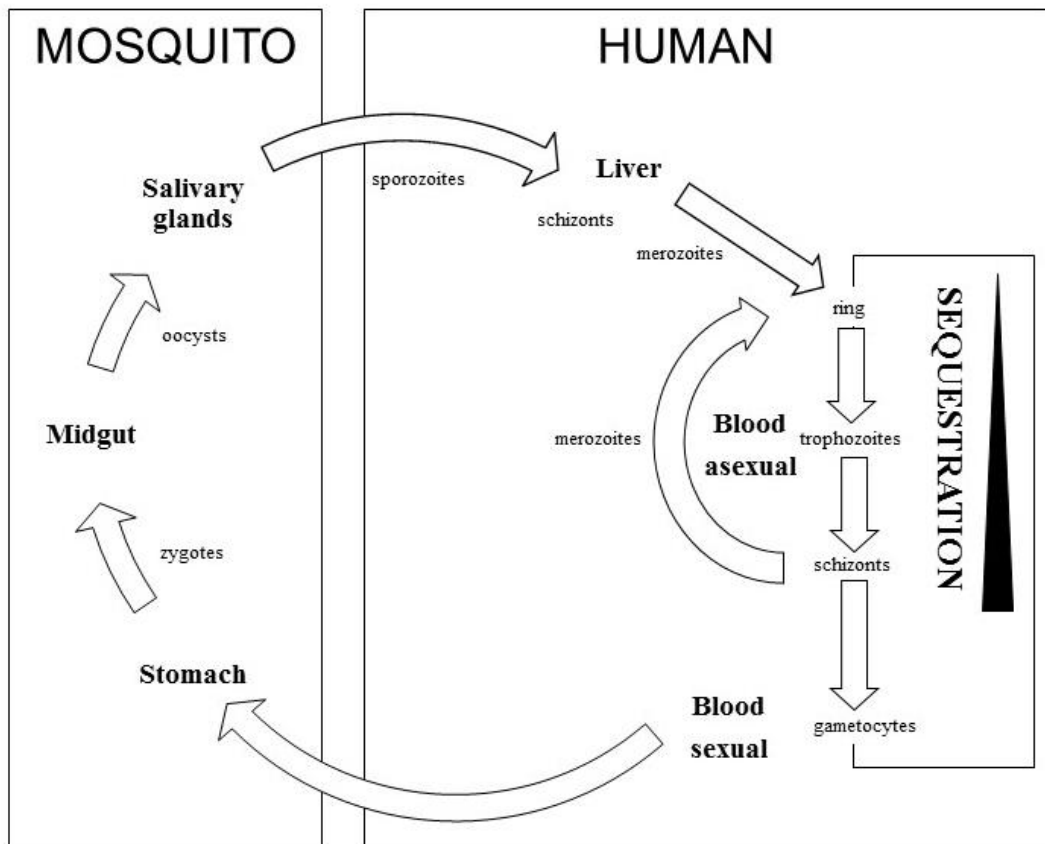
## Life Cycle

**Figure 1.1-1** shows the life cycle of the *Plasmodium falciparum* malaria parasite. On biting a human host, a female anopheline mosquito injects saliva containing *Plasmodium* sporozoites. These sporozoites then migrate to the liver of the human where they enter hepatocytes and multiply asexually to form hepatic schizonts. These schizonts rupture releasing thousands of merozoites into the blood. Following this, the merozoites invade erythrocytes and mature into ring forms and then trophozoites. Further asexual multiplication inside the erythrocyte occurs forming circulating schizonts. These intraerythrocytic schizonts rupture releasing more merozoites which invade new erythrocytes. Upon invasion, the merozoites either mature into ring forms, then trophozoites, and subsequently multiply asexually to form schizonts and merozoites; or switch to sexual reproduction forming either a male or female gametocyte. Upon taking a blood meal, a mosquito ingests these gametocytes in the peripheral blood following which male and female gametocytes combine in the mosquito stomach to form a zygote. These invade the wall of the mosquito midgut and form an oocyst which multiply asexually to produce sporozoites. These sporozoites migrate to the mosquito salivary gland to be injected when the mosquito next bites a human, thus completing the cycle.

Ring forms, trophozoites, schizonts and gametocytes are all present in the blood of the human host and are thus termed ‘blood stage’ parasites. All of these stages have a tendency to bind to the microvascular endothelium, and become sequestered in small vessels, particularly capillaries and postcapillary venules. Together with rosetting, agglutination and increased stiffness of infected and uninfected erythrocytes, this can cause obstruction of the microcirculation, a process thought to be central to the pathogenesis of severe disease. This process is thought to be much less prominent, or absent, in non-falciparum malaria and will be discussed in more detail in the next Section.

Other than sequestration, the life cycles of the other malaria species are similar to that of *P. falciparum*, with the following exceptions. In *P. vivax* and *P. ovale* infections, there is an additional quiescent stage in the human liver (hypnozoites) following injection of sporozoites. This results in recurrences of infection following the initial acute episode. Unlike the other human malarias, *P. knowlesi* is a zoonotic infection, the primary host being macaques in which it can cause symptomatic infection. Infection of humans is thought to occur mostly through human-macaque contact via anopheline mosquitoes, although there is

potential for it to be transmitted solely among humans. The life cycle is shown in **Figure 1.1-1**.



**Figure 1.1-1.** The *Plasmodium falciparum* malaria parasite life cycle.



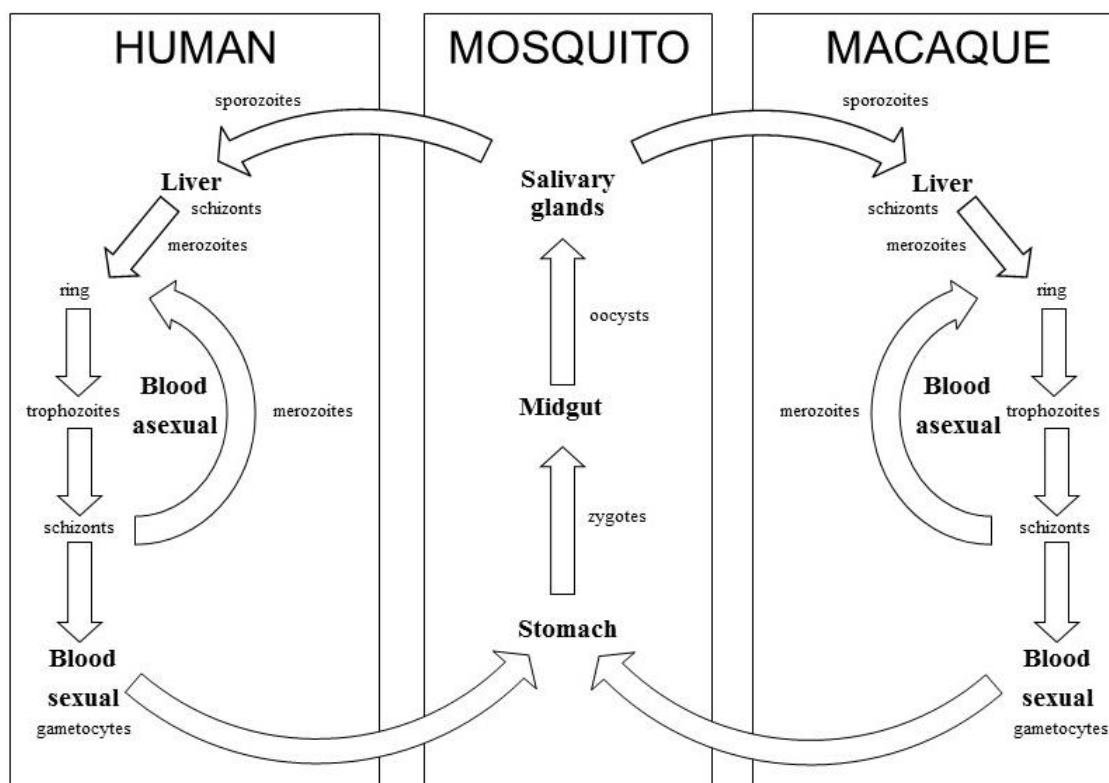


Figure 1.1-2. The *Plasmodium knowlesi* malaria parasite life cycle.

## Diagnosis

As outlined above, malaria cannot be reliably diagnosed from clinical features alone due to its non-specific presentation. Confirmation of a diagnosis of malaria requires detection of *Plasmodium* parasites in the peripheral blood. This is done either by direct detection of parasites in a blood smear by light microscopy or by detection of a malaria antigen in the blood by rapid diagnostic test. Both methods are widely used across the tropics, have high specificity for falciparum malaria infection but sensitivity and specificity for the other *Plasmodium* species is lower. A limitation of microscopy is that it requires sufficient parasites in the peripheral blood to be detected. In severe falciparum malaria where a high proportion of the parasites are sequestered, the peripheral parasitaemia can be very low although the total parasite burden is high. Occasionally, this can lead to a missed diagnosis, particularly where the microscopist is inexperienced. Another consequence is that the peripheral parasite count does not reliably predict the severity of malaria.<sup>23</sup> Although high parasitaemia (>2% or >100,000 parasites per microliter in low transmission areas and >5% or >250,000 parasites per microliter in high transmission areas) is one of the World Health

Organization criteria for severe malaria<sup>13</sup> peripheral parasite count is not an independent predictor of mortality.<sup>24</sup>

Diagnosis of *P. knowlesi* by microscopy can be challenging as its appearance is nearly identical to *P. malariae*. The distinction is important as *P. knowlesi* is a common cause of severe and fatal human malaria in Malaysian Borneo whereas *P. malariae* is relatively benign. This has led to underreporting of knowlesi malaria and delayed treatment of with intravenous artesunate.<sup>25</sup> The more sensitive and specific method of polymerase chain reaction (PCR) is now being increasingly used for diagnosis where resources permit.<sup>26</sup>

The cut-off for detection of parasites in the peripheral blood by microscopy is around 50 parasites per microliter. The most commonly used antigen for malaria rapid diagnostic tests (RDT) detect *P. falciparum* histidine rich protein II (*PfHRP2*). This is a protein produced by the parasite and released into the blood on rupture of a schizont to release merozoites (schizogony).<sup>27</sup> It is highly sensitive and specific for *P. falciparum* and as it is released by both sequestered and non-sequestered parasites it is a better marker of total parasite burden than peripheral parasitaemia. The *PfHRP2* concentration in the peripheral blood has also been shown to be a better predictor of mortality than peripheral parasitaemia.<sup>28</sup> For diagnosis, RDTs using *PfHRP2* have a similar sensitivity to microscopy but have the limitation that *PfHRP2* has a half-life of up to 4 weeks following release in the peripheral blood. Thus the test can remain positive following parasite clearance.<sup>29</sup> Some RDTs detect *Plasmodium* lactate dehydrogenase (LDH) and/or aldolase which have a much shorter half-life. Unlike *PfHRP2* these can detect non-falciparum malaria but their sensitivity is lower, they are more expensive and are less stable in storage.<sup>30</sup> Currently available rapid tests are particularly poor at detection *P. knowlesi* and there is a need for more sensitive and specific RDTs for settings where this infection predominates.<sup>31</sup>

In low transmission areas, detection of parasites in the peripheral blood plus symptoms consistent with severe malaria are sufficient for a diagnosis. However, in high transmission areas, frequent infections can lead to build up of antidiisease immunity which prevents the development of symptoms in most of those over 5 years of age. Thus a patient presenting with a febrile illness due to another cause may have detectable malaria parasites but another cause of their illness. In uncomplicated malaria, it is presumed that the patient has malaria and antimalarials are administered, often with antibiotics if another infection is suspected. In most cases, erroneously assuming the diagnosis is malaria and omitting these antibiotics does not have adverse consequences. In severe malaria, however, missing another serious

diagnosis, for example bacterial sepsis, meningitis, encephalitis or poisoning and treating only malaria can be fatal. Measuring the level of HRP2 by ELISA in the blood can help to identify those with a low parasite burden and thus high likelihood of an alternative diagnosis but it is currently only available as a research tool and there is no clear cut-off for severe disease.<sup>28</sup> There is an urgent need for a new tool to identify which severely unwell patients with malaria parasites in the peripheral blood are severely unwell because of malaria. As will be outlined later in this introduction, studies in Malawi suggest malaria retinopathy has potential to assist with this diagnostic challenge in comatose children with *P. falciparum* malaria. The specificity of malarial retinopathy for severe falciparum malaria compared to other severely unwell individuals with, for example sepsis and nonmalarial encephalopathy is not known. Determining the specificity for severe *P. falciparum* is one of the aims of this thesis and the study which includes this is presented in **Chapter 2**. There have been no studies of retinopathy in other types of malaria, including the other major causes of severe malaria, *P. knowlesi* and *P. vivax*, although the pathogenesis is thought to be somewhat different. Its role in diagnosis is thus not known. An additional aim of this thesis is to look for retinal changes in *P. knowlesi* malaria and compare them with those in *P. falciparum*. A study to examine retinal changes in *P. knowlesi* is presented in **Chapter 6**.

## Treatment

The primary aim of treatment of malaria is to rapidly eliminate malaria parasites from the body to abort symptoms and prevent the progression to severe disease and death. First-line antimalarial treatment worldwide for uncomplicated *P. falciparum* malaria is oral artemisinin combination therapy (ACT).<sup>13</sup> This consists of two antimalarials, an artemisinin derivative and a non-artemisinin partner drug, for example lumefantrine, mefloquine or piperaquine. Artemisinins are the most effective antimalarials known with rapid antiparasite action and minimal side effects. They are in the chemical class sesquiterpene lactones and these compounds contain a peroxide bridge thought to be responsible for the drug's rapid antiparasite action. Compounds in this class include artemisinin itself, originally derived from the plant *Artemisia annua*, and its semi synthetic derivatives artemether, artesunate and dihydroartemisinin.<sup>32</sup> In many areas, other antimalarials such as oral quinine or sulfadoxine-pyrimethamine (SP) are used although these are less effective than the ACTs, quinine commonly causes unpleasant side effects and resistance to SP is common through acquisition of point mutations in genes for target proteins in the folate pathway.

For uncomplicated *P. vivax* and *P. ovale* malaria, ACTs are also effective, although chloroquine is usually used. In addition, a 14 day course of primaquine is also given to clear hypnozoites from the liver. *P. malariae* malaria may also be treated with chloroquine or an ACT. *Plasmodium knowlesi* can be treated with chloroquine or quinine and has recently been shown to be sensitive to artesunate and ACT.<sup>16</sup> A randomized clinical trial of artesunate-mefloquine for *P. knowlesi* malaria is now underway.<sup>33</sup>

For those who develop severe disease, first-line antimalarial treatment for falciparum malaria is intravenous artesunate.<sup>13</sup> This has replaced the previous first choice treatment of intravenous quinine following two large trials, one in Asian adults<sup>34</sup> and one in African children,<sup>35</sup> showing patients treated with parenteral artesunate had lower (35% and 22% respectively) mortality than those treated with parenteral quinine. Artesunate is a water-soluble artemisinin antimalarial. Its rapid action and efficacy against all parasite stages in the blood, including early ring stage parasites, is thought to be contributory to its potency in treating severe malaria.<sup>35</sup> Intravenous artesunate also has the advantage of being administered as a bolus injection, unlike intravenous quinine which has to be given by infusion over several hours. The optimal treatment for severe malaria due to other *Plasmodium* species is not known but intravenous quinine and artesunate have each been used successfully.<sup>16</sup>

In addition to antimalarial treatment, there has been a series of trials of adjunctive therapies directly targeting disease pathogenesis in severe falciparum malaria. None of these have been effective in improving outcome in humans, including adrenaline,<sup>36</sup> anti-tumour necrosis factor antibody,<sup>37</sup> aspirin,<sup>38</sup> dexamethasone,<sup>39</sup> heparin,<sup>38</sup> human albumin,<sup>40</sup> intravenous immunoglobulin,<sup>41</sup> iron chelators,<sup>42,43</sup> low molecular weight dextran,<sup>44</sup> mannitol,<sup>45,46</sup> N-acetylcysteine,<sup>47</sup> phenobarbitone<sup>48</sup>, ursodeoxycholic acid<sup>49</sup> and levamisole.<sup>50</sup> One important limitation to these trials is that there is no satisfactory surrogate outcome marker for mortality in severe falciparum malaria. Mortality end-point trials in malaria require thousands of patients in the treatment and control groups. This is expensive and requires a multi-centre study to complete in a reasonable time frame and therefore very few such trials have been done. In order to identify promising candidates for further study trials have used surrogate endpoints, for example, blood lactate, measurement of blood flow in the systemic circulation or quantifying changes in parasite stages visible in the peripheral blood<sup>50</sup> but none of these markers are good predictors of death. These preliminary trials have only been done in small numbers of patients (usually <100) and are thus not powered to

detect small differences between the groups. Another limitation is that the pathogenesis of severe and cerebral malaria is incompletely understood. This will be discussed in more detail in the next Section of this introduction. Study of malarial retinopathy has potential to elucidate the microvascular pathogenesis of cerebral falciparum malaria and this is one of the aims of this thesis. This is discussed in detail in **Section 1.1.3** and **Chapter 2**

It may be that promising candidate adjunctive therapies with efficacy against mortality have been overlooked because of the limitations outlined above. Additionally there are several compounds with potential as adjunctive therapies for malaria now under development, and some that are currently being trialled, for example l-arginine, heparinoids and paracetamol, for which a more discriminative surrogate endpoint is needed. There is thus an urgent need for a simple bedside outcome measure that can be used as a surrogate marker for mortality in severe falciparum malaria in early stage trials of adjunctive therapies. By directly examining disease pathogenesis in the central nervous system, serial examination of the retina for malarial retinopathy has great potential to meet this need.

Discussion of the treatment of severe malaria must include mention of supportive care which is an essential contributor to reduction in mortality. Simple strategies include care of the unconscious patient with intubation and ventilation where necessary, haemodialysis for severe renal impairment and cautious administration of intravenous fluids with careful monitoring of fluid balance.<sup>51,52</sup> The latter is necessary as liberal fluid resuscitation confers an increased risk of pulmonary oedema but does not improve acid-base status or renal function.<sup>53</sup> For all patients with severe malaria, this is best done in an intensive care unit and such patients are often among the most unwell in the hospital. In most parts of the tropics facilities for intensive care, ventilation and haemodialysis are limited and much of the care of patients with severe malaria occurs on the general wards. An important part of management is early identification of those patients who are most in need of, and likely to benefit from, supportive care so the limited available resources can be used appropriately.

### **Prognosis**

Around 1 in 1000 patients with falciparum malaria go on to develop severe disease. This is commoner in those who receive late or no treatment. Of those who develop severe disease around 10-20% die despite antimalarial treatment and close to 100% die if

untreated.<sup>13</sup> Of those who recover, few have any significant long-term sequelae. Coma, in particular, is often rapidly reversible<sup>54,55</sup> and long-term neurological sequelae are uncommon in survivors.<sup>56,57</sup> In those who die with *P. falciparum* infection, around half of deaths in adults in low transmission settings occur in the first 48 hours after hospital admission<sup>58</sup> and around two thirds of deaths in children in high transmission settings occur in the first 24 hours.<sup>59</sup> Thus the time window for interventions aimed at reducing mortality is short.

The prognosis of treated severe falciparum malaria is challenging to predict. Comatose patients can rapidly recover and be conscious within a day of admission. Patients who appear relatively well on admission can deteriorate rapidly and develop multi-organ failure. The criteria for severe malaria are broad<sup>13</sup> and not all of the features are associated with increased mortality.<sup>12</sup> In large clinical trials and cohort studies, certain features have been identified which predict death better than others. Most consistent among these are age, coma and metabolic acidosis.<sup>12</sup> Mortality increases with age, being around 6% on those under 10 years and 37% in those over 50 years.<sup>12</sup> Scores have been developed which combine these features to give a probability of death in a particular patient but all have important limitations which mitigate against their application in routine clinical care. The simplest is the Coma Acidosis Malaria (CAM) score<sup>24</sup> which combines measurement of base deficit and Glasgow Coma Scale (GCS). When used correctly this reliably predicts survival for those who die early in their admission. However, it performs less well for those who die late with renal impairment, testing of base deficit is not available in many resource-limited settings and assessment of GCS is unreliable.<sup>60</sup>

The level of plasma *Pf*HRP2 in venous blood has also been studied as a possible marker to predict prognosis in severe malaria in African children<sup>28</sup>. It was found to be higher in fatal than non-fatal cases of severe malaria with a U-shaped relationship between HRP2 concentration and mortality suggesting those with lower concentrations of HRP2 and higher mortality have another cause of death. There was no clear cut-off for fatal disease in this study and quantitative measurement of HRP2 is currently available only as a research tool. Thus the clinical usefulness of this as a prognostic tool is limited.

There is a need for an additional discriminative marker which better predicts mortality in severe falciparum malaria. Being much commoner in severe malaria, and particularly cerebral malaria,<sup>61-63</sup> assessment of malaria retinopathy has potential as a bedside tool to help predict prognosis. This tool could be relatively low cost as ophthalmoscopes are widely available and most doctors have been trained to use them. In reality, however, the ability of

many general physicians to use an ophthalmoscope is poor and may be inadequate to derive useful information on severity of malaria retinopathy. Assessment of all patients with severe malaria by an ophthalmologist is another possible solution, although they may not be available to contribute to an admission assessment and awareness of malaria retinopathy among ophthalmologists is generally low. An alternative is automated quantification of malarial retinopathy. A range of low cost retinal cameras are currently under development and by the addition of software for automated image analysis it may be possible for a relatively unskilled operator to grade malaria retinopathy and derive prognostic information. A large multinational collaborative project, is currently underway to develop a low cost camera and software for this purpose (Richard Maude, co-investigator). The major limitation to the use of malaria retinopathy as a prognostic tool is that the sensitivity and specificity of malaria retinopathy for death in severe malaria are not known. Assessing this in adults is one of the aims of this thesis and is discussed in **Chapter 2**.

### 1.1.2 Pathogenesis of cerebral falciparum malaria

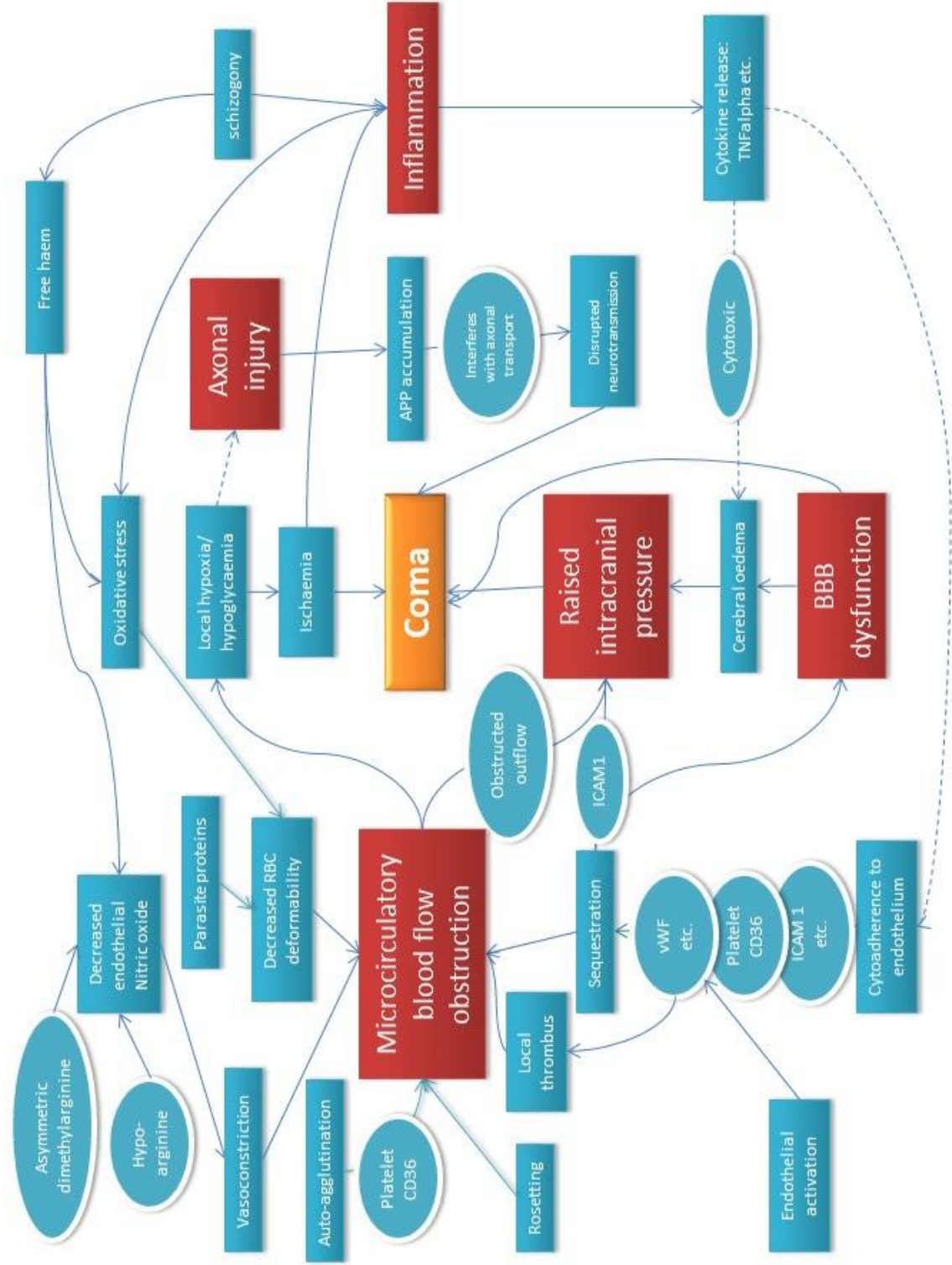
The direct cause of coma in malaria is not known, although there is an extensive literature describing multiple hypotheses for what is a complex pathophysiology. One area of particular controversy is whether the apparent differences between cerebral malaria in children and adults indicate two diverse pathological processes or whether they are one and the same. A second area of much discussion is to what degree animal models of cerebral malaria are useful to inform the study of human disease. This Section will review the current understanding of the pathophysiology of cerebral malaria paying particular attention to these areas of controversy and the limitations of currently available research techniques.

The most commonly held view is that the clinical disease of cerebral malaria is the culmination of a number of interrelated pathological processes. These can be summarised as several hypotheses, although the extent to which each contributes towards the final clinical picture is the subject of much debate. These processes are:

- 1) impaired microvascular function
- 2) inflammation
- 3) cerebral oedema
- 4) blood brain barrier dysfunction
- 5) axonal injury.

How these processes may combine to cause coma in severe malaria is illustrated in **Figure 1.1-3**.





**Figure 1.1-3.**  
**Pathogenesis of cerebral falciparum malaria.**

Hypothesis for how the major pathological processes in cerebral falciparum malaria may combine to cause coma.

APP = amyloid precursor protein,  
 BBB = blood brain barrier, ICAM1 = intercellular adhesion molecule 1 (CD54), RBC = red blood cell, vWF = von Willebrand factor.

*Note: this is an original figure created for this thesis.*

### Impaired microvascular function

A long-recognised pathological feature in post mortem studies of fatal cerebral malaria is sequestration of parasitized and non-parasitized erythrocytes in cerebral blood vessels, in particular capillaries and postcapillary venules.<sup>64,65</sup> This was originally proposed as a cause of coma by Laveran in 1884<sup>66</sup> and subsequently expanded as the *sequestration hypothesis* by Marchiafava and Bignami in 1894.<sup>67</sup> This sequestration is found preferentially in the white matter<sup>68</sup> with more in the cerebellum than the cortex<sup>69</sup> and more in the cortex than in the brainstem.<sup>70</sup> In adults the degree of microvascular congestion and sequestration in the brain correlates with coma depth and shorter time to death.<sup>65</sup> Sequestration also occurs in other organs in severe malaria, including heart, lungs, kidneys, liver, and small intestines, but significantly more of it occurs in the brain in cerebral malaria patients.<sup>71,72</sup> There is also much more intracerebral sequestration in cerebral malaria than in fatal non-cerebral malaria where it is also probably a universal finding.<sup>70,73-75</sup> This lesser degree of sequestration in those with non-cerebral severe malaria can suggest that sequestration alone is insufficient to cause coma, although it may simply be a matter of quantity.<sup>70,76</sup> Other than this quantitative difference in sequestration, there has been no difference found in other pathologic features such as endothelial cell changes between the brains of patients with fatal cerebral versus noncerebral severe malaria.<sup>64,73-75,77</sup>

Sequestration is thought to contribute to coma through the local reduction of microvascular blood flow. Cerebral blood vessels are differentially obstructed by sequestered erythrocytes, some being relatively free of obstruction whilst other adjacent vessels are totally occluded.<sup>70</sup> This may cause small areas of reduced supply of metabolic substrate to the brain for example oxygen and glucose, which would be especially problematic in the context of seizures, hypoglycaemia, hypoxia, fever or anaemia.<sup>78,79</sup> Because this obstructed flow occurs only in small patches, tissue necrosis is avoided thus explaining the rapid, and usually complete, reversibility of clinical symptoms in those who recover. Also, overall cerebral blood flow does not decrease in cerebral malaria,<sup>80</sup> although anaerobic glycolysis is increased<sup>81</sup> and net lactate in the cerebrospinal fluid (CSF), likely produced by the brain, is elevated and higher in those who died suggesting hypoxia contributes to the pathogenesis.<sup>82,83</sup>

Sequestration occurs through cytoadherence of parasitized and nonparasitized erythrocytes to vascular endothelium. Specifically, *P. falciparum* erythrocyte membrane protein 1 (PfEMP1),<sup>84</sup> and to a lesser extent rifin<sup>85</sup> and selectin,<sup>86</sup> on the surface of these erythrocytes binds to ICAM1,<sup>87</sup> and other less well characterized host receptors including VCAM1,<sup>72</sup> E-

selectin,<sup>72</sup> chondroitin sulphate and human leukocyte antigen (HLA) Class II on the endothelial cell membrane.<sup>64,88,89</sup> PfEMP1 is encoded by var genes of which there are 60 variants in 3 major groups, A, B and C. Antigenic variation by transcriptional switching between expressed var genes allows immune evasion by the parasite. Expression of particular var gene subgroups has been associated with severe disease, although a consistent pattern between studies has not been demonstrated.<sup>90,91</sup> This variation may account for the differences in degrees of sequestration between individuals and between different sites in the body. The binding of PfEMP1 to endothelium may be relatively non-specific due to attraction between opposite electrical charges<sup>92</sup> but ICAM1 is thought to be the most important of these receptors.<sup>72</sup> The expression of ICAM1 is enhanced by TNF $\alpha$  in humans<sup>93</sup> and is upregulated in cerebral vessels in cerebral malaria.<sup>64,94</sup> PfEMP1 expression is enhanced by fever and its adherence to endothelial receptors is especially strong in late stage parasites.<sup>95</sup> Thus in patients with extensive sequestration and thus late severe disease, few mature parasites are found in the peripheral blood.<sup>96</sup> PfEMP1 also binds to endothelial CD36 but this molecule is absent from brain microvasculature. It is possible that PfEMP1 in fact binds to platelet CD36 thus using platelets as a bridge between erythrocytes and endothelium,<sup>97</sup> although there is evidence that this alone is not sufficient.<sup>98</sup> Indeed, intravascular accumulation of platelets in African children with cerebral malaria has been found in autopsy studies<sup>99,100</sup> but is not prominent in adults.<sup>65</sup> Von Willebrand factor (vWF) mediates platelet adhesion and is a marker of endothelial activation. VWF is raised in cerebral malaria in children<sup>101</sup> and severe malaria in adults with decreased activity of vWF cleaving protease,<sup>102</sup> although it is equally raised in children without retinopathy of whom most are thought to have a disease other than malaria.<sup>101</sup>

Angiotensin 1 and 2 (Ang 1 and 2) are major regulators of endothelial activation and integrity and it has been proposed that they may contribute to sequestration and coma in cerebral malaria. In falciparum cerebral malaria, levels of ANG-1 are decreased and ANG-2 levels increased in the peripheral blood of both children<sup>103</sup> and adults<sup>104,105</sup> compared to uncomplicated malaria, and they predict fatal outcome.<sup>103,104</sup> In children Ang-2 and Tie-2 (the tyrosine kinase Ang receptor) levels are found in those with malaria retinopathy suggesting an association with cerebral microvascular obstruction.<sup>106</sup> In adults, however, immunohistochemistry of post-mortem brain tissue found no difference in expression of Ang-1, Ang-2 or Tie-2, on brain endothelium in cerebral compared to non-cerebral cases.<sup>107</sup> This suggests it is not specific to cerebral malaria and does not have a direct role in causing coma.

Sequestration in *P. falciparum* malaria may be enhanced by the binding of infected erythrocytes containing mature parasites to noninfected erythrocytes (rosetting)<sup>108</sup> and adherent infected erythrocytes binding other infected erythrocytes (autoagglutination). Rosetting has been demonstrated only *in vitro* and not all parasites display it.<sup>108,109</sup> It is, however, most commonly present in infected erythrocytes taken from children and adults with severe malaria,<sup>110,111</sup> although one study did not showing this association.<sup>112</sup> Rosetting has been associated with microcirculatory flow obstruction *in vitro* in an animal model<sup>113</sup> and rosettes are resistant to disruption by physiological shear forces suggesting they could persist long enough to contribute to microvascular obstruction.<sup>114,115</sup> Rosetting is mediated by binding of the *P. falciparum* variant iRBC surface antigens, the NTS-DBL1 $\alpha$ -domain of PfEMP1<sup>116</sup>, rifins<sup>117</sup> and stevor,<sup>118</sup> to uninfected red cells. Autoagglutination of infected erythrocytes is thought to occur via CD36 on platelets and is associated with disease severity.<sup>119,120</sup>

In addition to sequestration through cytoadherence, microcirculatory flow is also thought to be compromised by decreased red cell deformability which prevents erythrocytes with a mean diameter of 8 $\mu$ m deforming to squeeze through capillaries of as little as 5 $\mu$ m.<sup>121</sup> The deformability of parasitized and nonparasitized erythrocytes is reduced in severe malaria and this correlates strongly with poor outcome,<sup>122,123</sup> presumably by increasing the resistance to microvascular blood flow.<sup>124</sup> This is thought to be due to a combination of remodelling of the cell cytoskeleton by parasite proteins,<sup>125</sup> stiffness of the intracellular parasite itself and oxidative damage to the red cell membrane possibly by heme products.<sup>126</sup>

Nitric oxide (NO) produced by vascular endothelial cells causes vasodilation and is a major determinant of vascular function and regulation of vascular tone. Sequestration in falciparum malaria is associated with impaired endothelial NO bioavailability, endothelial activation and dysfunction which exacerbate impaired perfusion, hypoxia and tissue damage.<sup>127</sup> Low NO bioavailability is also associated with upregulation of ICAM-1.<sup>128</sup> This reduced bioavailability is due to multiple mechanisms, including reduced systemic and pulmonary NO production,<sup>127,129</sup> reduced L-arginine concentrations (a substrate for NO production),<sup>127,129</sup> reduced type 2 NO synthase (NOS2) expression,<sup>127,129</sup> and increased NO quenching.<sup>130,131</sup> In a trial of adjunctive L-arginine in severe falciparum malaria endothelial dysfunction was reversed and lactate levels reduced in the intervention group.<sup>127</sup> Inhaled nitric oxide in has also been shown to be of benefit in malaria in mice.<sup>132</sup> Further trials of L-arginine and inhaled nitric oxide in human severe falciparum malaria are underway.

Macrovascular haemodynamic failure is in general not a prominent contributor to microcirculatory failure in severe malaria. Low blood pressure is not a common feature of severe malaria and cerebral blood flow is not decreased in cerebral malaria.<sup>80</sup> In a prospective haemodynamic study of severe malaria in adults, hypovolaemia was common but not associated with increased severity of malaria or worse outcome, whereas microvascular obstruction was associated with both.<sup>133</sup>

In summary, reduced microcirculatory blood flow is thought to be a central process in the pathogenesis of coma in cerebral malaria.<sup>134</sup> As it directly visualises the microcirculation in the retina, which is a part of the central nervous system, malarial retinopathy is being used to study microvascular changes in cerebral malaria and has potential to give new insights. Study of cerebral falciparum malaria pathogenesis in adults using malaria retinopathy is an aim of this thesis and is discussed in more detail in **Section 1.1.3** and **Chapter 2**.

### **Inflammation**

Some investigators believe that malaria infection causes generalized vital organ dysfunction as a result of the release of systemic cytokines such as TNF $\alpha$ , or local release of mediators such as NO.<sup>76,135</sup> In Clark and Rockett's *cytokine hypothesis* it was proposed that in the brain this leads to an encephalopathy and coma.<sup>136</sup> A number of inflammatory mediators have been implicated but their role in the pathogenesis of cerebral malaria is unclear. This results partly from much of the information in this area coming from animal models which differ significantly from disease in humans.<sup>137</sup> Another complicating factor is the varying immune responses between hosts with different receptor polymorphisms and to different strains of parasite. Thirdly, overproduction of these cytokines may only be local thus their peripheral blood levels are not adequately representative of levels in the tissues.

The most consistently identified inflammatory mediators in cerebral malaria are TNF $\alpha$  and NO. In African children, concentrations of TNF $\alpha$  and its receptor were higher in those with cerebral malaria, particularly fatal disease, than in those with mild or uncomplicated malaria.<sup>138-142</sup> In addition, several polymorphisms in the TNF $\alpha$  promoter region have been associated with increased risk of cerebral malaria, death<sup>143</sup> and neurological sequelae.<sup>144</sup> In Vietnamese adults, the concentration of TNF $\alpha$  was higher in patients with severe multiorgan disease but lower in patients with cerebral malaria alone, suggesting its involvement in the

process leading to severe malaria but not specifically coma.<sup>145</sup> A study in India has suggested TNF $\alpha$  levels may be useful as a prognostic marker in falciparum malaria as they predicted length of hospital stay and were higher in those who later developed anaemia, hypoglycaemia or altered hepatic function. This study also found higher TNF $\alpha$  levels in those with cognitive dysfunction or coma.<sup>146</sup> However, levels of TNF $\alpha$  in peripheral blood in uncomplicated *Plasmodium vivax* malaria are just as high as in cerebral malaria<sup>147</sup> but this organism rarely causes severe disease.

These apparent contradictions may be because TNF $\alpha$  has multiple effects in malaria including induction of fever, upregulation of ICAM-1<sup>93</sup> and induction of NO production. TNF $\alpha$  also has beneficial effects in malaria. In animal models, TNF $\alpha$  has an antiparasitic effect at low levels but induces cerebral malaria when levels are high.<sup>148</sup> In Gabonese patients with severe malaria and high TNF $\alpha$  production capacities there was a more rapid clinical and parasitologic recovery.<sup>149</sup> Different strains of *P. falciparum* also vary in their abilities to stimulate TNF $\alpha$  production<sup>150</sup> and post mortem studies in Malawian children have shown production of TNF $\alpha$  increased locally in the brain.<sup>151</sup> The latter finding suggests plasma concentrations of TNF $\alpha$  may be imprecise indicators of TNF $\alpha$  effects in cerebral malaria with cerebral pathology maybe only occurring at the local tissue level where proinflammatory parasite products are released during schizogony. The varying effects of TNF $\alpha$  in malaria may also be because the differential effects of TNF $\alpha$  are modified by different levels of receptor expression in the host. In cerebral malaria circulating TNF receptors have been found to be in proportionately higher concentrations than TNF $\alpha$  itself.<sup>152-155</sup> Alternatively, there may be a contribution from different TNF $\alpha$  allelic types being expressed in different hosts, TNF $\alpha$ \*2 being the most strongly associated with severe disease.<sup>156</sup> The lack of clear role in the pathogenesis of malarial coma is highlighted by the finding that anti-TNF monoclonal antibody reduces fever but not severe disease<sup>157</sup> whereas pentoxifylline has contradictory effects on coma duration in different studies.<sup>158,159</sup>

TNF $\alpha$  stimulates the release of nitric oxide by inducible nitric oxide synthase (iNOS) in brain endothelial cells.<sup>160-162</sup> This NO is thought to diffuse into the brain parenchyma and may disrupt the regulation of formation of neural NO, altering neurotransmission and causing coma.<sup>161,163</sup> As NO is very short-lived this could explain the rapid reversibility of coma in recovering patients.<sup>161</sup> Increased iNOS expression in vessel walls has also been found to be associated with sequestration of parasites in cerebral malaria in post mortem brain specimens.<sup>164</sup>

However, the role of NO in cerebral malaria is probably more complex, due to its multiple physiological functions which as well as neurotransmission<sup>165</sup> include the killing of intracellular organisms and regulation of vascular tone, as discussed in the previous Section. The associations found between disease and nitric oxide activity, iNOS, or genetic polymorphisms in the iNOS promoter gene have not been consistent and results have varied with age, endemicity, and geographical location. Individuals also produce NO at different rates and a slow increase in some individuals may be insufficient to provide negative feedback against iNOS, thus allowing NO to build up locally to harmful levels.<sup>166</sup> Increased NO production is associated with protection from cerebral malaria in some studies in children<sup>129,167</sup> but no NO was found in CSF in another study with no difference in plasma levels between fatal and nonfatal disease.<sup>168</sup> As for TNF $\alpha$  it is likely that these contradictory studies reflect the fact that the relevant excess of nitric oxide production occurs locally in the brain and is not reflected in the peripheral blood. Detecting tissue expression of NO synthase immunohistochemically, or via *in situ* hybridization, may be more appropriate.

Other cytokines found to be increased in patients with cerebral malaria include interleukin (IL) 1,<sup>151</sup> IL 6,<sup>169</sup> and IL 10. Peripheral blood concentrations have, like TNF, also been shown to be higher in noncerebral severe malaria than in those with only cerebral disease.<sup>145</sup> The exact role of these cytokines in the pathogenesis is even less clear than that of TNF $\alpha$  or NO. A variety of other associations, for example specific HLA types, upregulation of CXCL4 and 10,<sup>170</sup> increased levels of immune regulatory Chitinase 3-like-1,<sup>171</sup> and toll-like receptor polymorphisms<sup>172,173</sup> have also recently been found to be associated with increased or decreased risk of coma in falciparum malaria.

In summary, the role of the immune system in the pathogenesis of human cerebral falciparum malaria remains unclear although an imbalanced inflammatory and cytokine response appears to be contributory.

### **Cerebral oedema and blood brain barrier dysfunction**

Cerebral oedema, increased intracranial pressure (ICP), and disruption of the blood brain barrier (BBB) have been implicated in the pathogenesis of malarial coma but their significance differs between children and adults.

In African children with cerebral malaria, cerebral oedema is more frequent and severe than in Asian adults, although not a universal finding.<sup>174</sup> Of 120 Malawian children with cerebral malaria who underwent brain magnetic resonance imaging (MRI), 77% had moderate to severe cerebral oedema which was diffuse in 79%.<sup>175</sup> A subsequent study of 168 Malawian children with cerebral malaria found severe brain swelling in 84% of those who died and 27% of those who survived suggesting brain swelling and raised ICP may contribute to a fatal outcome in children. Many of those who died had decreased CSF in the prepontine space suggesting brain stem herniation to be a likely cause of death.<sup>176</sup> Studies in African children with cerebral malaria show a subtle increase in BBB permeability with a disruption of endothelial intercellular tight junctions on autopsy<sup>177,178</sup> and opening pressures on lumbar puncture are elevated in over 80%.<sup>179,180</sup>

In contrast, opening pressures on lumbar puncture are usually normal in adult patients with cerebral malaria<sup>181</sup> and the BBB is functionally grossly intact.<sup>182,183</sup> Imaging studies reveal that most adults with cerebral malaria have no evidence of gross cerebral oedema.<sup>184-186</sup> A recent trial in India found 29% of adults with cerebral falciparum malaria to have moderate or severe cerebral swelling on Computed Tomography (CT) with 36% having mildly elevated CSF pressures on lumbar puncture. There was no association of cerebral oedema with mortality, or coma depth in this study and administration of mannitol to reduce the swelling had no effect on mortality and prolonged coma duration.<sup>46</sup> This may be due to a different mechanism of oedema from young African children although evidence for this is lacking.

There have been no published controlled trials evaluating the use of mannitol in cerebral malaria in children.<sup>187</sup> A small series in Kenyan children with cerebral malaria showed that mannitol lowered ICP, but there was no control group with which to compare the benefit of mannitol on case fatality or neurological outcome.<sup>188</sup> As discussed above, blood brain barrier leakage appears to play a part in the pathogenesis of malarial coma but its significance remains unclear and is greater in children than in adults. Rather than a primary cause for coma it is more likely a feature developing in the later stages of the disease.

There have been no systematic studies using MRI of the brain in adult cerebral malaria. Additionally, the specificity of cerebral oedema for coma is not known in adults or children as studies to date have included only patients with cerebral disease. Determination of the specificity of changes on brain MRI, including oedema, for cerebral malaria in adults and their specificity for a fatal outcome is one of the aims of this thesis and is presented in **Chapter 5**.



By examination of the optic nerve head for swelling, which occurs as a result of raised ICP, study of the retina by colour photography and ultrasound has been used to look for cerebral swelling in cerebral malaria in children. The timing of the onset of papilloedema in relation to stage of disease progression and death has not been studied due to difficulties performing serial examinations in very unwell children. Study of papilloedema in adult cerebral malaria forms a part of this thesis and is discussed extensively elsewhere. The colour photography findings are presented in **Chapter 2** and the ultrasound findings in **Chapter 3**.

### **Axonal Injury**

One major puzzle in cerebral malaria is since parasitized red blood cells do not leave the vascular space how do they cause coma? Possible mechanisms alluded to above are heterogeneous microcirculatory flow dysfunction causes deficiency of metabolic substrates to a degree insufficient to cause infarction but sufficient to cause transient neurological dysfunction. Another hypothesis is that of local intracerebral release of cytokines and nitric oxide which diffuse through a locally permeable blood brain barrier and interfere with neurotransmission. The third possible pathway, that of cerebral oedema compromising cerebral blood flow or leading to transtentorial herniation appears to be irrelevant in the majority of adults.

An additional postulated mechanism that could represent a final common pathway in cerebral malaria is axonal injury (AI). This is damage to axons which results in impaired axonal transport and consequently disrupted neurotransmission. It is also thought to be a common pathway of cerebral injury that occurs in other diseases such as multiple sclerosis<sup>189,190 191</sup> and stroke.<sup>192</sup> Axonal damage is a key predictor of outcome in a range of human CNS diseases, including malaria.<sup>193</sup> It may occur gradually, leaving a window for therapeutic intervention during the early stages<sup>194,195</sup> and if arrested early on is completely reversible. With large amounts of AI, disease becomes irreversible. The extent of AI distinguishes between groups of patients infected with *P. falciparum* with and without neurological complications during life.<sup>196,197</sup> Amyloid precursor protein (APP) is a protein that is normally transported along the axon, and accumulates at the sites of AI. APP staining has thus been used as a marker of axonal injury and has been found in post-mortem brain specimens of adults with cerebral malaria and more extensively than in those with no cerebral involvement, either diffusely or localized to the internal capsule or pons.<sup>196</sup> The

amount of APP correlated with plasma lactate, CSF protein, and GCS. It is thought to identify axons with reversible structural and biochemical changes.<sup>198</sup> Examining other proteins specific to axons (tau), neural cell bodies and astrocytes in CSF of patients with cerebral malaria has shown most of the brain parenchymal damage is in axons.<sup>199</sup> In addition, haemorrhage, myelin disruption,<sup>70</sup> glial reaction, and the presence of intravascular leukocytes were not associated with cerebral malaria in other studies.<sup>196</sup>

Hypoxia,<sup>200</sup> raised ICP,<sup>200-203</sup> and hypoglycaemia<sup>204</sup> can all contribute to AI. The heterogeneous microcirculatory dysfunction found in *P. falciparum* malaria sequestration could cause axons to suffer energy deprivation that is independent of neuron cell bodies. A recent neuropathological study of the brain in Malawian children with fatal cerebral malaria found axonal, myelin damage, disruption of the BBB, ring haemorrhages and vascular thrombosis in areas of prominent iRBC sequestration.<sup>205</sup> These findings were postulated to be supportive of a link between sequestration and intravascular and perivascular pathology in fatal paediatric cerebral malaria resulting in myelin damage, axonal injury and breakdown of the BBB. Similarly in adults, sequestration and consequent microvascular obstruction have been postulated to be central pathogenic processes in cerebral falciparum malaria although, as summarised above there are key differences which warrant further investigation.<sup>65</sup>

### **Pathogenesis of severe knowlesi malaria**

There have been few studies on the pathogenesis of severe knowlesi malaria and current understanding is derived mostly from small case series and case reports. It has long been known from studies in primates, the primary host, that *P. knowlesi* can obstruct cerebral capillaries and venules<sup>206</sup> and cause microcirculatory disturbance analogous to *P. falciparum*.<sup>207</sup> Also in primates, *P. knowlesi* has been shown to become trapped in the brain<sup>208</sup> and to cause reduced erythrocyte deformability.<sup>209</sup> A post mortem of one fatal case of severe human knowlesi malaria revealed similarities to *P. falciparum* including sequestration of parasitized erythrocytes in the brain but without evidence of associated inflammation.<sup>210</sup> There were also numerous petechial haemorrhages in the cerebrum and cerebellum. Despite this cerebral sequestration, the patient was not comatose and unlike in falciparum malaria there was no platelet clumping, no thrombi, no upregulation of ICAM-1 expression in endothelial cells and no cerebral oedema. There is *ex vivo* evidence that erythrocytes infected with mature forms of *P. knowlesi* bind to ICAM-1 and VCAM but not to CD36.<sup>211</sup> Levels of cytokines are

raised in knowlesi malaria, including TNF $\alpha$ , IL-6, IL-8, IL-1ra and IL-10, more so in severe disease but with a different profile than in *P. falciparum*. In severe knowlesi, TNF $\alpha$ , IL-8, MIP-1 $\beta$  and MCP-1 levels are increased compared to uncomplicated disease but are decreased in severe falciparum.<sup>212</sup>

It is not known if cytoadherence, reduced red cell deformability and parasite sequestration contribute to the pathogenesis of severe knowlesi malaria in humans. There is insufficient evidence to know how common sequestration is in severe *P. knowlesi* and whether it is only restricted to a subset of patients with marked inflammation. It is also not known what the pathological consequences are for the host. Further studies are clearly needed and direct study of microvascular changes in humans *in vivo* would be particularly informative. As for *P. falciparum* malaria, by direct visualization of the CNS microvasculature, study of the retina in severe knowlesi would help to clarify the frequency and contribution of microvascular obstruction to its pathogenesis and how this differs from *P. falciparum*. There have been no studies of malarial retinopathy in *P. knowlesi* malaria. The first such study in severe and uncomplicated human *P. knowlesi* infection is presented in **Chapter 6**.

### Limitations of Current Research Techniques

The primary strategies used to study pathogenesis in cerebral malaria have been *in vivo* clinical case series and case-control studies, post-mortem brain histopathology, *in vitro* studies and animal models. Because of the protected anatomical location of the brain, there has been very little *in vivo* work studying it directly. In particular, the lack of techniques to examine the brain microvasculature in living human patients has proven a major barrier to the advancement of our understanding. An alternative is the use of animal models, with both *P. coatneyi* and *P. fragile* in non-human primates and ANKA strains of *P. Berghei* in CBA or CB57BL/6 mice having been employed.<sup>213</sup> Unfortunately, *P. falciparum* malaria infection in humans behaves quite differently to both of these and the results have limited applicability.<sup>137</sup> In monkeys, severe malaria only commonly occurs in splenectomised animals and cerebral disease is not typical, although adherence of infected erythrocytes to cerebral endothelial cells similar to that seen in humans has been found.<sup>214,215</sup> This has contributed to our understanding of sequestration in malaria but monkeys do not typically develop coma. In mice, cerebral malaria does occur but sequestration appears not to be a feature. This is a significant and important difference from human disease where

sequestration is almost universally seen. Monocytes in cerebral vessels and cytokines appear to be essential in the pathogenesis in mice and much of the work so far has focussed on this area. Similar inflammatory processes only occasionally appear to be involved in humans.<sup>137,213</sup>

Post-mortem studies have provided a wealth of detailed information but they reflect, at best, pathology at a single point after death in the most severely ill patients. Specimens from these cases thus reflect only a subset of the most severely affected patients and do not demonstrate the evolution of disease over time. Information on the effects of *P. falciparum* on neuronal tissue outside of the brain is far more limited. A recent post mortem study in 18 African children with fatal falciparum malaria found sequestered parasites in retinal capillaries and venules and a positive correlation with the degree of sequestration in the brain and the severity of malarial retinopathy.<sup>216</sup> There have been no studies examining histopathology in the eye in adults with malaria.

Other *in vivo* human studies have looked at extracranial indicators of disease, usually in peripheral blood, including serum lactate and cytokine levels. A major concern here is that findings in the peripheral circulation may be quite different to what is occurring locally in the CNS as discussed earlier. Blood lactate has been found to increase with the severity of malaria,<sup>7</sup> indicating anaerobic glycolysis resulting from impairment of systemic tissue perfusion. Raised CSF lactate predicted death in cerebral malaria<sup>82</sup> and has been shown to vary independently of blood lactate.<sup>217</sup> Non-invasive bedside tools have been used to directly study impaired microvascular function and obstruction in severe falciparum malaria. Microvascular function using near infrared resonance spectroscopy (NIRS) have been measured in Indonesian adults with severe (n=36), and uncomplicated falciparum malaria (n=36), and healthy controls (n=36). This study found impaired microvascular function was significantly associated with worsening disease severity and increased venous lactate, a marker of impaired tissue perfusion. These were similar to findings in sepsis where microvascular reactivity was associated with both clinical severity and mortality.<sup>6</sup> Orthogonal polarising spectroscopy (OPS) directly visualises erythrocyte movement in the capillaries of the sublingual and rectal mucosa, and studies in Bangladeshi adults with falciparum malaria have shown obstructed capillaries proportional to disease severity.<sup>8</sup>

The two main techniques for examining changes in the central nervous system in living patients with malaria are imaging of the brain by CT and MRI, and imaging of the retina by photography, angiography and ultrasound. Technology in both fields is rapidly developing

and the potential of these techniques to contribute new understanding of the pathogenesis of cerebral malaria is huge.

Imaging of the retina in severe malaria is the main focus of this thesis and its contribution to date and potential for the future will be discussed in detail in the next Section.

### 1.1.3 Retinal changes in malaria

#### The eye in cerebral malaria: what can it teach us?

##### Abstract

The pathophysiology of coma in cerebral malaria is not well understood. Obstruction of microcirculatory flow is thought to play a central role, but other hypotheses include roles for parasite- and host-derived factors such as immune mediators, and for increased blood–brain barrier permeability leading to raised ICP. The retinal vasculature is a direct extension of the cerebral vasculature. It is the only vascular bed easily accessible for visualisation and provides a unique opportunity to observe vascular pathology and its effect on neurological tissue. A specific retinopathy has been well described in African children with cerebral malaria and its severity correlates with outcome. This retinopathy has been less well described in adults. The central mechanism causing malarial retinopathy appears to be microvascular obstruction, which has been demonstrated in affected retinas by fluorescein angiography. The presence in a central nervous system tissue of microvascular obstruction strongly supports the hypothesis that the sequestration of erythrocytes in small blood vessels and consequent obstruction of microcirculatory flow is an important mechanism causing coma and death in cerebral malaria. Retinopathy has potential as a diagnostic and prognostic marker in severe malaria but further work to examine its sensitivity and specificity for cerebral and fatal malaria is required. Despite advances in the antimalarial treatment of severe malaria, its mortality remains approximately 15–20%. Adjunctive treatment targeting sequestration is a promising strategy to further lower mortality and assessment of retinopathy may be a candidate surrogate outcome measure for clinical trials.

##### Introduction

The retinopathy of severe malaria has been well described in African children, and its prognostic and diagnostic value is established in these patients.<sup>63</sup> Its full assessment requires specialist techniques (e.g. indirect ophthalmoscopy, fundus photography) and training that will not be generally available in most tropical countries in the foreseeable future. It is also an important tool to further our understanding of how malaria causes morbidity and death. This role as a ‘window into the brain’ in severe malaria is one that is just beginning to be

realised, but already many pathophysiological insights have been gained. With the further application of established ocular imaging techniques to children and adults with severe malaria as well as the development of new methods of imaging this role is likely to expand.

### **Clinical utility**

The severity of malarial retinopathy correlates with mortality and duration of coma in African children with cerebral malaria, suggesting that the retinopathy is related to the pathophysiology of the disease and is not an epiphenomenon.<sup>63</sup> Approximately two-thirds of such patients have retinopathy that can be seen using an indirect ophthalmoscope,<sup>63</sup> and the mortality in this group is more than double that of comatose children with no retinopathy.<sup>218</sup> Approximately half of patients with severe malarial anaemia have retinopathy, with the full spectrum of changes being seen, but it is usually much milder than that seen in cerebral malaria.<sup>63</sup> Retinopathy is rarely seen in patients with uncomplicated malaria.<sup>219</sup>

The retinopathy of severe malaria has four main components: retinal whitening; vessel discolouration; haemorrhages; and papilloedema.<sup>220</sup> Cotton wool spots are also seen and are distinct from retinal whitening. Examples of these changes are shown in **Figure 1.1-4**. The vessel changes and pattern of retinal whitening appear to be unique to this disease.<sup>219,220</sup> Features of malaria retinopathy are normally classified according to the area of the retina in which they are seen. The areas of the retina used for this purpose are shown in **Figure 1.1-5**. They were defined as follows: fovea = area of retina in the centre of the macula 2.5 optic disc diameters from the temporal edge of the optic disc with diameter equal to that of the optic disc; macula = area of retina centred on the fovea and enclosed by the temporal arcade vessels, temporal border of the optic disc and extending to an arc 2.5 disc diameters temporally from the foveal centre; and peripheral retina = all of the retina outside of the macula.<sup>221</sup>

The first detailed descriptions of retinal whitening (opacification) in falciparum malaria were from studies using indirect ophthalmoscopy in African children.<sup>219,220,222</sup> Due to its appearance, topographic association with retinal capillary non-perfusion of fluorescein angiography<sup>223</sup> and paucity of histopathological changes in the choroid<sup>216</sup> malaria retinal whitening is thought to involve the inner retina. It does not obscure retinal vessels, is associated with a slight increase in retinal thickening, typically has a well demarcated,

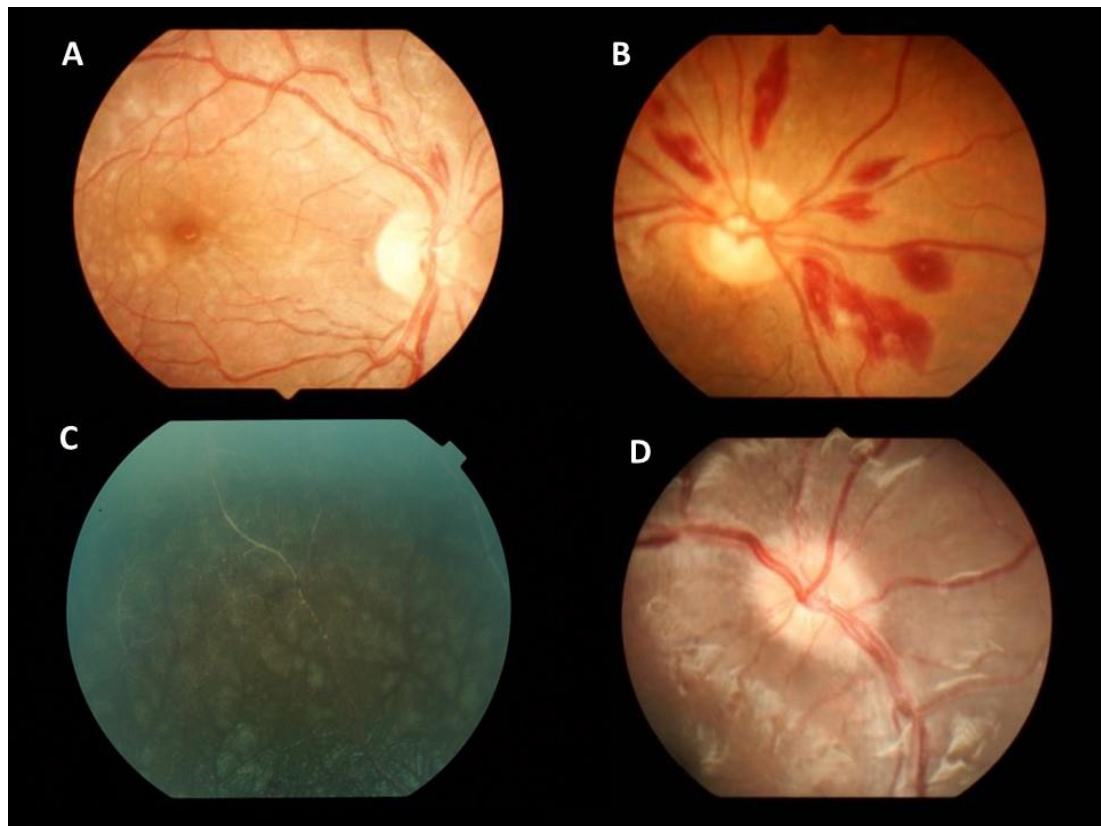
slightly elevated margin and occurs in several patterns that may coexist in the same patient. Individual lesions may be widely dispersed or clustered. When clustered they are usually separated from nearby vessels by a thin line of normal-appearing retina suggesting occurrence in the inner retina. Their colour varies from subtle cloudiness to intense white.<sup>219</sup> The typical size for lesions of malaria retinal whitening is estimated to be 200-500  $\mu\text{m}$  in diameter although they may merge together into larger confluent patches. Retinal whitening can be seen in the peripheral retina, the macula and the fovea. The lesions often cluster round the fovea but spare the central fovea and foveola and frequently extend temporally between the vessel arcades. In the peripheral retina, the lesions may be scattered or clustered in a mosaic pattern. Lesions are less well demarcated, less brightly white and more widely distributed than cotton wool spots.

Vessel discolouration in severe falciparum malaria is seen predominantly in capillaries and postcapillary venules. Affected vessels appear white, yellow or orange in discrete sections or peripheral capillary trees.<sup>220</sup> Fluorescein angiography has demonstrated some of these vessels to be devoid of blood flow suggesting obstruction.<sup>223</sup>

Retinal haemorrhages in severe falciparum malaria occur in all areas of the retina. They are typically round, oval (intraretinal) or flame-shaped (pre-retinal) with a white centre. Small dot haemorrhages (deep retina) are also seen but are less common, larger deep round haemorrhages occurring occasionally.<sup>220,222</sup>

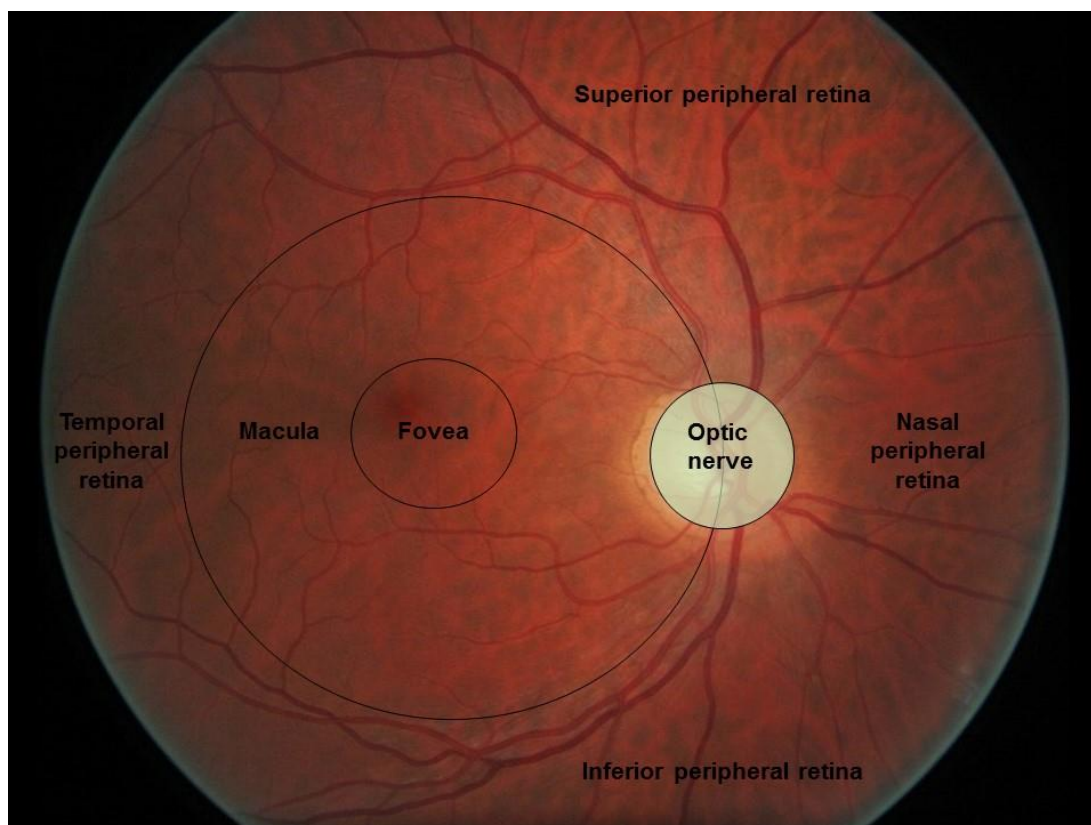
Whilst papilloedema and retinal haemorrhages can be visualised with an ordinary direct ophthalmoscope by a non-expert, the distinctive retinal whitening and vessel abnormalities are often found in the peripheral retina and thus require indirect ophthalmoscopy.<sup>220</sup> With training in indirect ophthalmoscopy, however, 95% of malaria-related retinal changes that are detected by an ophthalmologist may be observed by a non-ophthalmologist (T.E. Taylor, unpublished data). The interobserver concordance between ophthalmologists for grading the severity of malarial retinopathy has also proved satisfactory.<sup>224</sup>





**Figure 1.1-4. Examples of retinal changes seen in severe falciparum malaria.**

A. retinal whitening, B. retinal haemorrhages, C. retinal vessel discoloration and D. papilloedema. Images A, B and D are of Bangladeshi adults and were acquired with a portable retinal camera. Image C is of a Malawian child acquired by the author using a tabletop retinal camera. All photographs were taken by the author.



**Figure 1.1-5. Areas of the retina used for classification of malaria retinopathy.**

The image shown is a photograph of the author's right eye taken using a tabletop retinal camera.

Detection of retinopathy in severe falciparum malaria has been proposed as a bedside test to distinguish African children with cerebral malaria from those with coma due to other causes.<sup>220,225</sup> In particular, patchy retinal whitening and focal changes of vessel colour are highly specific for encephalopathy due to malaria in children and are therefore most important to identify.<sup>225</sup> This was supported by a large, prospective autopsy study of children with fatal cerebral malaria in Malawi where it was found that malarial retinopathy was better than any other clinical or laboratory feature in distinguishing malarial from non-malarial coma.<sup>100</sup> The clinical presentation of paediatric severe malaria with reduced consciousness is not specific. Up to one-third of comatose malaria film-positive patients in high transmission areas of the tropics have a non-malarial cause for their coma.<sup>226</sup> In high transmission areas, the high background prevalence of peripheral blood parasitaemia makes the diagnosis of cerebral malaria more difficult, whereas in low transmission settings the combination of coma and positive malaria blood film is more specific. There is a more marked seasonality in retinopathy positive than retinopathy negative cases of cerebral malaria in Malawi further supporting the hypothesis that the two groups have different aetiologies.<sup>227</sup> A review of

retinopathy negative children with cerebral malaria concluded that *P. falciparum* may still contribute to the coma but with variation in the phenotype due to different genetic susceptibility, partial immunity, coinfection with another infectious agent or a noninfectious comorbidity.<sup>228</sup> As a result, the presence or absence of malaria retinopathy is now being used in Malawi to confirm a clinical diagnosis of cerebral malaria in research studies.<sup>229,230</sup>

A potential limitation of the use of malaria retinopathy to distinguish patients with coma due to malaria from those with parasites but coma due to another cause is the lack of data on retinal findings in unconscious and severely ill febrile individuals in the tropics without malaria. There have been very few studies examining the retina in patients with, for example, sepsis, meningitis or encephalitis. Papilloedema is found in some patients with febrile encephalopathy and raised ICP and white centred haemorrhages are a recognized feature of bacteraemic sepsis. Both of these signs are part of the spectrum of changes comprising malaria retinopathy. It is not known whether retinal whitening or retinal vessel changes similar to those seen in malaria occur in these conditions, although it is plausible that the systemic ischaemia and prothrombotic state seen in sepsis could also involve the eye. In a study in Spain, 12% of bacteraemic patients and 5% with sepsis had retinal lesions comprising cotton wool spots, haemorrhages including white centred haemorrhages (Roth's spots), choroiditis and branch retinal artery occlusion. It was not recorded whether any of these patients were comatose.<sup>231</sup> Dengue virus infection is another common cause of severe febrile illness in the tropics, and an occasional cause of coma. It has long been known to cause a retinopathy which includes prominent BRB leakage,<sup>232</sup> haemorrhages, cotton wool spots, retinal artery occlusion, uveitis and/or maculopathy in around 10% of severe cases.<sup>233</sup> There are numerous other causes of severe febrile illness in which retinal changes have not been studied. There is a clear need for further studies of retinal signs in nonmalarial severe febrile illness in the tropics. One such study is presented in **Chapter 2**.

### **Pathophysiological mechanisms**

There is good evidence that the pathological mechanisms which produce the retinopathy seen in severe malaria are the same as those which cause coma in cerebral malaria. As well as correlating with disease severity, the retinal changes have histological correlates that match histological findings in the brain. Sequestration of infected erythrocytes occurs in retinal microvasculature in the same fashion as the cerebral microvasculature and is thought to cause the retinal vessel discolouration.<sup>234</sup> The number of retinal haemorrhages correlates

with the density of brain haemorrhages and, like cerebral haemorrhages, they have fibrin at their centre.<sup>235</sup> This is not surprising as the retina is embryologically derived from the same neuroectoderm as the brain and has the same type of vasculature within a structure of neurons and glial cells. There are marked similarities in anatomy and physiology of the microvasculature in parts of these two organs that are relevant to cerebral malaria. In particular in both organs there are similarities in vessel network architecture, abnormalities are seen in venous watersheds and there is high metabolic demand. These suggest both organs are similarly vulnerable to sequestration, venous congestion and a consequent deficit of delivery of metabolic substrate and ischaemia. The greatest similarity in vascular architecture is between cerebral white matter and the temporal peripheral retina where indeed the extent of retinal findings in African children correlates best with changes seen in the brain post-mortem.<sup>236 63</sup>

Reduced blood flow is the pathological sequel of microcirculatory obstruction. This is suggested by the histological appearance of cytoadherent erythrocytes containing mature forms of the parasite sequestered in the microvasculature, narrowing vessel lumens. The physical obstruction by these rigid cytoadherent parasitised erythrocytes is compounded by reduced red cell deformability and adhesive forces between infected erythrocytes (autoagglutination) and between infected and uninfected erythrocytes (rosetting).<sup>121</sup> Impaired perfusion has been demonstrated in vivo by fluorescein angiography of the retina in 28 of 34 children with cerebral malaria in a study in Malawi.<sup>223</sup> The majority of these had vessel obstruction at the capillary level and associated small zones of non-perfusion. The areas of non-perfusion matched areas of retinal whitening seen in malarial retinopathy, strongly supporting the hypothesis that microcirculatory obstruction and resulting hypoxia lead to retinal whitening. Approximately one-quarter of these patients also had larger occluded vessels (arterioles and venules) with larger associated zones of retinal non-perfusion.

If these patterns of non-perfusion, with extensive heterogeneity of microvascular obstruction, are mirrored in the brain then a model is suggested whereby there are multiple small zones of reduced perfusion resulting in gradients of tissue hypoxia. These may be partially or fully compensated by adjacent vasodilation and hyperperfusion. These multiple lacunae of hypoxia or ischaemia would be compatible with the absence of gross neurological deficits in most patients on recovery and also in keeping with the subtle neurocognitive deficits that are evident in African children years after an episode of cerebral malaria.<sup>237-239</sup>

In a later study of 18 Malawian children with cerebral malaria, 5 had little sequestration, no retinopathy and another cause of death post-mortem. The other 13 all had retinopathy, the severity of which correlated with the degree of sequestration in the retina and the brain. In this study, there was evidence of heterogeneous microvascular obstruction with blocked capillaries and venules being shown adjacent to patent ones. However, although the percentage of blocked capillaries was discussed in detail, the extent to which heterogeneity occurred and the scale at which was present were not reported.<sup>240</sup> As with all such studies, a major limitation is that only the most severe cases can be studied at a single time point.

The retina provides a unique opportunity to observe the central nervous system vasculature directly and over time during life and therefore to study cerebral vascular pathology and observe pathological changes as they evolve. A study using indirect ophthalmoscopy in Malawian children with cerebral malaria found retinopathy to be mostly present at the time of hospital admission, rarely appearing later. In around half of affected individuals, retinopathy worsened during the admission but other than an increase in the number of haemorrhages this was not associated with increased mortality. In 22 patients who were followed up, retinal whitening subsequently faded in one to two weeks and vascular changes disappeared over three weeks with some haemorrhages still present at 4 weeks.<sup>63</sup> There is a need for more detailed studies of the timecourse of retinopathy and its relation to outcome. The only other technique that currently allows detailed, direct, relatively non-invasive, serial observations of microcirculatory blood flow is OPS. OPS has been used to demonstrate reduced microcirculatory flow in the rectal mucosa in adult patients with cerebral malaria,<sup>124</sup> although this technique has yet to be employed in children. The severity of flow obstruction in this study correlated with the severity of disease. The proportion of adults with capillary obstruction demonstrated by OPS was similar (67%) to that demonstrated in children by fluorescein angiography (76%).<sup>223</sup>

The other major hypothesis to explain the pathophysiology of cerebral malaria is the local or systemic release of inflammatory mediators such as cytokines and nitric oxide.<sup>241</sup> The evidence from the eye goes against this. Retinal whitening is seen more in watershed zones and not along vessels, as would be expected if a causal substance was 'leaking' from the blood into the surrounding tissues, whereas the former points more towards a perfusion deficit.

Studies of the integrity of the blood–brain barrier (BBB) in cerebral malaria have relied on global measures of cerebral spinal fluid composition or on autopsy specimens in those that

have died. These have been equivocal, showing minor increases in BBB permeability, and have not demonstrated a breakdown in the BBB to a degree that would account for the degree of brain swelling. Magnetic resonance imaging in adults suggests the brain is congested with blood, and not full of water.<sup>185</sup> The retina has a blood–retinal barrier (BRB) that is structurally and functionally the same as the brain, and its integrity is tested by fluorescein angiography. Although BRB breakdown occurred in 44% of children with cerebral malaria, it only affected limited portions of a few vessels and to a minor degree. It was seen adjacent to ischaemic zones or in areas that had not been perfused but later recovered. It did not occur in discoloured vessels or vessels narrowed by sequestration.<sup>223</sup> A post mortem study in Vietnamese adults found evidence of blood brain barrier leakage, particularly in the brainstem, but there was no correlation with the degree of coma.<sup>242</sup> This suggests that breakdown of the blood–tissue barrier is a non-specific response to severe disease, possibly as a result of local hypoxia compounded by endothelial dysfunction.

Studies of malarial retinopathy show papilloedema, an indicator of raised ICP, to be commoner in children than in adults.<sup>61,63,243–245</sup> This is confirmed by an ongoing series of studies using MRI of the brain in Malawian children with cerebral malaria where moderate or severe cerebral oedema was found in 77%<sup>175</sup>, severe swelling was associated with death and confirmed on post mortem.<sup>176</sup> The few studies using brain imaging in adults have shown cerebral swelling to be much less marked and less frequent.<sup>181,246</sup> Post mortem studies in Vietnam found coma in fatal malaria in adults not to be associated with the degree of oedema.<sup>242</sup> To date there has been no formal study using brain imaging to examine the association of cerebral oedema with coma or death in adults. The first such study is presented in **Chapter 5**.

Raised ICP can also be detected through its effects on the optic nerve. Transmitted pressure from the cranial vault to the optic nerve causes oedema, swelling and protrusion of the optic disc and, when advanced, this is visible to clinicians as papilloedema. Milder forms of papilloedema are difficult to detect by clinical assessment. A highly sensitive method for identifying and quantifying swelling in the optic nerve is B scan ultrasound.<sup>247,248</sup> In Malawian children with cerebral malaria, 49% had evidence of raised ICP using this method and increased optic nerve sheath diameter (ONSD) was associated with neurological sequelae. Of the 24% who had papilloedema on fundocopy, 93% were detected on ultrasound.<sup>249</sup> Studies to date in adult malaria have not used this objective method, instead relying on subjective ophthalmoscopy which can have considerable inter-observer variability

for this sign and is frequently unable to detect it at all.<sup>250</sup> The first study examining ONSD in adult severe malaria is presented in **Section 3.3**.

### **Sequelae**

Although patients with cerebral malaria can have prolonged deep coma, neurological sequelae in adults are surprisingly rare, at approximately 1%.<sup>34</sup> This may be because of the redundancy of the cerebral microvasculature or redundancy in the cerebral cortex, which can accommodate small ‘silent’ infarcts. There is substantial heterogeneity of vascular obstruction, with patent capillaries adjacent to obstructed ones as shown by OPS.<sup>34</sup> In children, neurological sequelae are more frequent; approximately 12% at the time of discharge in one study<sup>57</sup> and 3% at 28 days in another,<sup>35</sup> although the majority resolve. In Malawian children, the presence of retinopathy on admission in patients with cerebral malaria does not appear to be a risk factor for epilepsy, developmental disabilities or behavioural abnormalities.<sup>251</sup> There have been no such studies in adults and there have been no follow up studies of retinal changes in cerebral malaria in any age group.

With frequent and often severe retinal changes in cerebral malaria, it would seem plausible that vision be in some way be affected. In a study of 162 children with severe malaria, 143 of whom had cerebral disease, visual acuity at 1 month in the half who attended follow-up showed no correlation with the severity of retinopathy seen during admission.<sup>252</sup>

Methodological difficulties, including the use of a variety of visual assessment tools to accommodate this heterogeneous group of children in terms of age and patient co-operation, language and culture, may well have reduced the robustness of their findings. In addition, acuity was not tested acutely; the first measurement was at 30 days, allowing any temporary effects on acuity to resolve before testing. It remains unanswered whether retinal whitening and non-perfusion in the macula affect vision acutely, and whether peripheral non-perfusion has an effect on visual fields.

### **Malarial retinopathy in adults**

In contrast to African children where there have been extensive systematic studies of malaria retinopathy for two decades, prior to the studies presented in this thesis there had been only three studies of retinopathy in severe malaria in adults<sup>182,243-245</sup> and no studies of malarial

retinopathy in Asian children. An Indian study included 214 adult patients with cerebral malaria of whom only 34.1% had retinopathy, with only disk pallor being significantly associated with increased mortality ( $P < 0.05$ ).<sup>243,244</sup> The relative frequencies of retinal changes reported in this study differed significantly from those reported elsewhere. The second study was done in a mixed group of adults and children in Thailand, of which 144 patients had cerebral malaria.<sup>245</sup> It focused on retinal haemorrhages, which were found in 14.6% of patients, there being very few other retinal abnormalities found. Both studies used predominantly direct ophthalmoscopy and did not state the degree of expertise of the examiner. A large proportion of retinal changes in malaria are in the peripheral retina<sup>220</sup> and the use of direct ophthalmoscopy by non-experts may account for the low incidences found. Neither study reported changes in retinopathy over time other than to say 'recovery was complete' in survivors. A more recent study of retinopathy in Bangladeshi adults with severe falciparum malaria was conducted in parallel to the studies presented in this thesis. This used nonexpert indirect and direct ophthalmoscopy and found retinopathy in 86% of fatal, 41% of cerebral and 25% of noncerebral severe malaria. Moderate-severe retinopathy was found to be an independent predictor of mortality. A small subset of patients underwent retinal photography which was found to be of similar sensitivity to nonexpert fundoscopy for detecting retinal haemorrhages but was much more sensitive in detecting retinal whitening.<sup>62</sup> A study using film-based retinal angiography in adults to investigate capillary permeability showed some areas of capillary non-perfusion in the retina, similar to the recent findings in children.<sup>182</sup> It is likely that the technology in this older study would not have been sufficient to demonstrate all the pathology demonstrated in children with digital angiography and a modern fundus camera.

Approximately one-third of patients with cerebral malaria die during the acute phase of the disease. In Sub-Saharan Africa the majority of these deaths occur in children under 5 years. In low transmission settings, including most of Asia, the majority of deaths are in adults. If current efforts across the tropics to eliminate malaria are even partially successful there will be decreasing transmission intensity and consequent loss of antidiarrhoeal immunity. In these areas it is highly likely that the burden of adult severe and fatal malaria will greatly increase.

There is ongoing debate whether the pathophysiological mechanisms leading to cerebral and severe malaria differ between adults and children although it appears likely to be the case. Pathology studies in adults show a clear correlation between the extent of sequestration in the brain vasculature and coma.<sup>253</sup> In adult cerebral malaria, platelets and white cells are



usually not seen in sequestered segments, whereas in children, in addition to sequestration there is some intravascular accumulation of mononuclear leukocytes and platelets as well as the presence of fibrin strands.<sup>100</sup> Finally, cerebral oedema appears to be much less marked and frequent in Asian adults than in African children. It has not been established whether retinal pathology differs between Asian adults and African children, and there have been no studies of malarial retinopathy in Asian children. The results of the first large study of falciparum malarial retinopathy using retinal photography in Asian adults and children is presented in **Chapter 2**.

### **Future research**

The ability to visualise sequestration and its effects on neurological tissue *in vivo* raises the possibility that malaria retinopathy could be used as a disease measure for investigative and interventional trials. Until now the only reliable indicators of efficacy of new agents have been an effect on death rates or neurological sequelae. These remain the ultimate measures, but it may be possible to study more upstream events and earlier effects. Malarial retinopathy may be a sensitive pharmacodynamic endpoint for the evaluation of such novel therapies. One such group of therapies may be novel anticoagulants such as heparin analogues, some of which have been shown to disrupt rosette formation and cytoadherence in *ex-vivo* human studies.<sup>254</sup>

### **Conclusion**

It is likely that the retinopathy seen in severe malaria and malarial coma are manifestations of the same pathophysiological mechanisms acting at related anatomical sites. To date, no technique has allowed direct examination of the small blood vessels of the brain, although examination of a number of surrogate markers has led to the conclusion that obstruction of microcirculatory flow is an important contributor to cerebral malaria. Retinal blood vessels are identical to those in the cerebrum and can be examined relatively easily. They provide a unique opportunity to increase our understanding of this still enigmatic disease. Recent clinical and pathological investigations suggest that multiple foci of capillary obstruction are important in the pathophysiology of severe malaria, and that breakdown of the BBB is a limited and secondary phenomenon. There is evidence of important differences in the

pathogenesis of cerebral malaria between children and adults and further study of this is urgently needed. Study of retinal changes in falciparum malaria could provide a platform for evaluation of better treatment strategies for cerebral malaria, as well as a potential tool for improving diagnosis and prognostication in cerebral malaria.

## 1.2 Summary

This thesis presents a series of studies on severe malaria in Asian adults using malarial retinopathy as a tool to study the pathogenesis of cerebral malaria and whether it differs from that seen in African children, to explore its potential role as a diagnostic and prognostic marker, to examine its effect on visual function and to explore its potential role as a diagnostic and prognostic marker and, it is hoped, as a possible surrogate endpoint for clinical trials of adjunctive therapy. They include simultaneous assessment by a range of other complementary tools such as MRI of the brain, ultrasound of the optic nerve head, automated image analysis of retinal vessel tortuosity, and known correlates and markers of systemic microvascular function in the peripheral blood: parasite biomass, lactate and red cell deformability. In this way it is hoped a more comprehensive picture of the complex pathogenesis of coma in malaria can be derived and greater understanding of the role of microvascular obstruction obtained.

Unlike previous studies on malaria retinopathy these studies also directly compare findings across the full spectrum of clinical *P. falciparum* malaria: cerebral versus noncerebral severe versus uncomplicated and fatal versus nonfatal disease; and with uncomplicated and severe *P. knowlesi* malaria, healthy individuals, sepsis and nonmalarial febrile encephalopathy. Additionally for the first time, direct comparison of retinal changes in falciparum malaria is made between adults and children in the same population. This range of subjects enrolled allows exploration of the potential role of malaria retinopathy in assisting diagnosis and predicting prognosis, as well as being able to assess its potential role as a surrogate marker for clinical trials of adjunctive therapies.

Alongside these studies, a series of fluorescein angiograms has been collected using a novel, low-cost method. This method is described in detail and preliminary results are presented. These angiograms are currently being graded and a new classification scheme for angiographic features in cerebral malaria is being developed. Once completed, this will allow further detailed study of the microvascular changes in adult cerebral falciparum malaria and comparison of the underlying pathogenic mechanisms with those seen in African children.

### 1.3 Aims of this thesis

**Research question:**

What is the potential contribution of malarial retinopathy to understanding the pathogenesis and improving the management of cerebral malaria in adults?

**Specific aims:**

1. Describe the spectrum of retinal changes in *P. falciparum* malaria in adults and its specificity compared to sepsis, non-malarial febrile encephalopathy and healthy individuals. Thus explore the utility of malarial retinopathy as a diagnostic marker for falciparum malaria.
2. Determine the relationship between retinal findings and disease severity and outcome in *P. falciparum* malaria. Thus explore the utility of malarial retinopathy as a prognostic marker for falciparum malaria.
3. Investigate the microvascular pathogenesis of malarial retinopathy and how this relates to cerebral *P. falciparum* malaria in adults.
4. Compare retinal findings in severe malaria in adults and children in the same population.
5. Investigate the role of raised intracranial pressure in the pathogenesis of cerebral malaria in adults.
6. Describe the spectrum of retinal changes in *P. knowlesi* malaria as compared to *P. falciparum* malaria.

## **Chapter 2 Retinopathy in *P. falciparum* malaria**

---

**Malarial retinopathy as a diagnostic, prognostic and pathogenic marker in *P. falciparum* malaria in Asian adults and children****2.1 Abstract**

Studies of malaria retinopathy in falciparum malaria have mainly focussed on comatose African children. Retinal changes in adults with severe malaria and severely unwell patients without malaria have been less well studied and the specificity, pathogenesis, diagnostic and prognostic value of malarial retinopathy in adults are not known. 451 patients of all ages with severe severe (112 cerebral, 68 noncerebral severe) and uncomplicated (125) falciparum malaria, sepsis (43), nonmalarial encephalopathy (41) and healthy individuals (62) were enrolled between 2008 and 2012 in Bangladesh and India. Patients underwent detailed clinical assessment including retinal photography using a portable camera. Malarial retinopathy was present in 91% and 88% respectively of patients with cerebral and fatal malaria, was highly specific for malarial coma, predicted development of coma in noncomatose patients with malaria and predicted mortality in severe malaria. The severity of macular whitening correlated with a decrease in visual acuity but it was not clear if this was a specific effect to malaria. The prevalence of retinal whitening and haemorrhages were similar to that described previously in African children but retinal vessel discolouration was absent and papilloedema rare. Contributors to, and markers of, microcirculatory obstruction were highly correlated with macular whitening suggesting microcirculatory obstruction by sequestered parasites has a central role in the pathogenesis of retinal whitening and coma. Malarial retinopathy can be used to study the CNS microvascular pathogenesis of cerebral malaria and has potential as a diagnostic and prognostic bedside marker in severe falciparum malaria.

**2.2 Introduction**

Retinopathy of severe *P. falciparum* malaria has been well described in African children and its severity correlates with mortality and duration of coma in patients with cerebral malaria<sup>20</sup>. Around two thirds of such patients have retinopathy that can be seen using an indirect ophthalmoscope,<sup>245</sup> whereas patients with non-severe falciparum malaria have mild or no

retinopathy.<sup>219</sup> The retinopathy of severe falciparum malaria has some features that are unique to this disease.<sup>219,220</sup> The pathological mechanism that produces the retinopathy seen in severe malaria is thought to be the same as that which causes coma in cerebral malaria. The retina has the same type of vasculature as the brain and microcirculatory flow dysfunction is thought to be important to severe malaria at both sites. This flow dysfunction is mainly caused by the phenomenon of cytoadherence of erythrocytes containing mature forms of the parasite leading to sequestration in the microvasculature. In addition, a reduction in red cell deformability and adhesive forces between infected erythrocytes (autoagglutination) and between infected and uninfected erythrocytes (rosetting) play a role.<sup>34,121</sup>

The retina provides a unique opportunity to directly observe CNS vasculature, thus allowing the possibility to study CNS vascular pathology directly. Post-mortem studies looking at the eye in African children who died of cerebral malaria found large numbers of sequestered parasites blocking small retinal blood vessels,<sup>234</sup> mirroring changes seen in post mortem studies in the brain in Asian adults.<sup>253</sup>

Despite these similarities, there are also differences in clinical features and pathological changes seen in cerebral malaria between African children and Asian adults. These include less prominent cerebral oedema, fewer neurological sequelae and higher mortality in adults. It is not clear how similar falciparum malarial retinopathy is to that seen in children. There have been no studies of retinopathy in Asian children.

There have been several previous studies of retinopathy in severe falciparum malaria in adults.<sup>61,223,243,244</sup> An Indian study included 214 patients with cerebral malaria of whom only 34.1% had retinopathy; with only disc pallor being significantly associated with increased mortality ( $p < 0.05$ ).<sup>223,243</sup> The relative frequencies of retinal changes reported in this study differed significantly from those reported elsewhere. Another study was done in a mixed group of adults and children in Thailand, of which 150 patients had cerebral malaria.<sup>244</sup> It found retinal haemorrhages in 14.6% of patients, there being very few other retinal abnormalities described. Both studies used predominantly direct ophthalmoscopy and did not state the degree of expertise of the examiner. More recently malarial retinopathy has been shown to be of prognostic value in Bangladeshi adults, even when assessed by non-expert examiners.<sup>255</sup>

Retinal examination by ophthalmoscopy is subjective thus a digital retinal camera was used in place of ophthalmoscopy in another study in Bangladeshi adults. This found much a higher prevalence of retinal findings (70% in cerebral malaria) and correlations between severity of

retinopathy and severity of malaria and blood lactate.<sup>219</sup> Acquisition and storage of images with digital photography enables result verification by a second masked observer and objective analysis to minimise bias. This is more objective than examination by indirect and direct ophthalmoscopy.

The first large study of *P. falciparum* malaria retinopathy using retinal photography in adults is presented. The aims were to establish the specificity of retinal changes for cerebral *P. falciparum* malaria in adults, compare findings in adults with those in children, quantify their prognostic value, investigate the microvascular pathogenesis of malaria retinopathy, and determine the effect of retinopathy on visual function.



## 2.3 Methods

### 2.3.1 Study site and patients

The studies presented in this Chapter were conducted in Chittagong Medical College Hospital, Chittagong, Chittagong Division, Bangladesh and Ispat General Hospital, Rourkela, Orissa, India. These are large tertiary referral hospitals with limited facilities for oxygen therapy, blood transfusion, intensive care and renal dialysis. Malaria transmission is seasonal and low intensity in these locations. Recruitment of subjects was from June 2008 to August 2012 in Bangladesh, October 2010 to December 2012 in India.

#### **Ethical approval**

Ethical approval for the studies was obtained from the University of Oxford Tropical Research Ethical Committee, the Bangladesh Medical Research Council Ethical Committee and the Ispat General Hospital Ethical Committee.

#### **Enrolment**

Consecutive patients of all ages admitted to the medical wards were screened for eligibility against the inclusion and exclusion criteria listed below. Eligible individuals were enrolled as soon as possible after admission.

#### **Inclusion and exclusion criteria**

##### *Inclusion Criteria*

1. The patient or attending relative is able and willing to give written, informed consent in the local language  
*Plus one of:*
2. Severe falciparum malaria as defined below
3. Uncomplicated malaria as defined below
4. Sepsis as defined in the below
5. Healthy volunteers. These were members of the research team or local hospital staff assisting with the study

##### *Exclusion Criteria*

1. Patient is unable or unwilling to cooperate with eye examination

2. Contraindications to tropicamide and/or phenylephrine eye drops, such as angle closure glaucoma or documented allergy
3. Patients having severe corneal scarring or cataracts in both eyes therefore precluding ophthalmoscopy and retinal photography
4. Known allergy to fluorescein (contraindication to angiography only)
5. Known allergy to anaesthetic eye drops (contraindication to orbital ultrasound only)

Note: if patients were excluded from the study they were immediately referred to the ward doctor along with the results of the initial investigations.

Note: pupillary dilatation in severely unwell individuals may cause concern for treating physicians who will then temporarily be unable to monitor pupil size and reactivity for around 2 to 4 hours. Although treating physicians should be notified when drops have been inserted and the time recorded, pupillary size and reactivity are likely to be of limited value in cerebral malaria as lateralised, expanding lesions causing uncal herniation and compression of the third cranial nerve have not been seen. Rather, as for other causes of medical coma, pupillary dilatation is likely to be a late event accompanied by other signs of brainstem dysfunction.<sup>220</sup>

#### *Criteria for cerebral malaria*<sup>256</sup>

1. Positive peripheral blood film with asexual forms of *Plasmodium falciparum*  
plus
2. GCS <11 (adults) or BCS<3 (preverbal children)

#### *Criteria for noncerebral severe malaria*<sup>256</sup>

1. Positive peripheral blood film with asexual forms of *Plasmodium falciparum*  
plus
2. GCS ≥11 (adults) or BCS≥3 (preverbal children)  
plus
3. Any of the following (modified World Health Organisation criteria):

- Haematocrit < 20 % with parasite count > 100,000/ mm<sup>3</sup>
- Jaundice with bilirubin > 2.5 mg/dl with parasite count > 100,000/ mm<sup>3</sup>
- Serum creatinine > 3 mg/dl with urine < 400 ml/24 hours
- Hypoglycaemia with venous glucose < 40 mg/dl
- Systolic blood pressure < 80 (adults) <70 (children) mmHg with cool extremities
- Peripheral asexual stage parasitaemia > 10 %
- Peripheral venous lactate > 4 mmol/l
- Peripheral venous bicarbonate < 15 mmol/l
- Respiratory insufficiency

*Criteria for uncomplicated malaria*<sup>256</sup>

Positive peripheral blood film with asexual forms of *Plasmodium falciparum* but not meeting criteria for cerebral or noncerebral severe malaria

*Criteria for non-malaria encephalopathy*

Negative peripheral blood film for Plasmodium species\* plus the following criteria:

- GCS of <11 or Blantyre Coma Scale of <3 (preverbal children)

*Criteria for bacterial sepsis*<sup>257</sup>

The presence of an infection other than malaria (negative peripheral blood film for Plasmodium species\*) or non-malaria encephalopathy (GCS >10) in combination with systemic inflammatory-response syndrome, as indicated by at least 3 of the following criteria:

- a core temperature of  $\geq 38^{\circ}\text{C}$  or  $\leq 36^{\circ}\text{C}$
- a heartbeat of 90 beats/min

- either a respiratory rate of  $\geq 20$  breaths/min, a PaCO<sub>2</sub> of  $\geq 32$  mmHg, or the use of mechanical ventilation for an acute respiratory process
- either a white-cell count of  $\geq 12 \times 10^9/L$  or  $\geq 4 \times 10^9/L$  or a differential count showing 10% immature neutrophils

As bacterial culture was not routinely available at the study sites, positivity of cultures was not required.

*Criteria for healthy individuals*

- No known acute illness.\*\*
- Reside within catchment area of study hospital.

\*Note a negative peripheral blood film is the standard clinical method for ruling out malaria. Although there is a possibility of a blood film appearing negative in patients with *falciparum* malaria and a high degree of parasite sequestration, this is extremely rare. I

\*\*Note it is possible for an asymptomatic individual with a very low parasitaemia to appear negative on a peripheral blood film but be positive on ultrasensitive PCR thus possibly being classed as a healthy control. The epidemiological and clinical significance of such cases is not clear, the infection possibly being transient, In the absence of any other clinical sequelae it would seem unlikely that such infections would incur significant retinal changes.

### 2.3.2 Clinical assessment

#### History and Examination

On enrolment a full history and physical examination were carried out. The history included recent symptoms, past medical history and medication history. In addition, specific questions were included on recent visual symptoms and history of conditions and medications that could affect the eye examination and retinal appearances. These are listed in the data collection form in **Section 10.2.2**.

Examination included a full physical examination and recording of vital signs. The recording form for visual function examination is provided in **Section 10.2.3**. Pupillary size and reaction to light were recorded. Visual acuity was assessed by Snellen chart (converted to logMAR<sup>258</sup> for analysis) where possible or the best of detection of light, hand or finger counting where not. Visual fields were assessed by confrontation. Colour vision was assessed using the Ishihara test and macular function using an Amsler grid. Many individuals with decreased consciousness were unable to complete a visual function exam on enrolment.

### 2.3.3 Investigations

#### Haematology and Biochemistry

Venous blood was obtained on enrolment for haemoglobin, haematocrit, platelet count, white cell count and biochemistry including urea and electrolytes, liver function tests,, plasma glucose, plasma lactate and serum bicarbonate.

#### Parasite counts and *Pf*HRP2-derived parasite biomass

In patients with *P. falciparum* malaria, a peripheral blood smear was taken to quantify the number of parasites per microliter, calculated from the number of parasites per red blood cell in thin smear or, where thin smears were negative, the number of parasites per white blood cell in thick smears using the following formulae:

*Thin smear:*

Parasites/ $\mu$ l = parasites per 1000 RBC \* haematocrit(%) \* 125.6

*Thick smear:*

Parasites/ $\mu\text{l}$  = parasites / number of white cells counted \* WBC(cells/ $\text{mm}^3$ ) \* 1000

In addition, *PfHRP2* was quantified on enrolment in venous blood using a quantitative antigen-capture enzyme-linked immunosorbent assay (ELISA). In brief, samples were tested with the malaria Ag Celisa kits (Cellabs, Sydney, Australia) using a sandwich ELISA. These kits detect *PfHRP2* protein produced by the parasite by a monoclonal antibody-based assay. This protein is specific to *P. falciparum*. Samples were added to microwells pre-coated with monoclonal capture antibody alongside serial dilutions of an HRP2 standard solution. These plates were incubated for 1 hour and read spectrophotometrically in a Bio-Tek ELX 808 TM plate reader (Bio-Tek Instruments, Winooski, Vermont, USA). The reading from the standard solution were used to construct a titration curve to convert titres to actual concentrations of *PfHRP2*. Parasite biomass per microliter was calculated using a method described previously.<sup>259</sup> The sequestered parasite biomass per microliter was calculated by subtracting the peripheral parasite count-derived biomass per microliter from the HRP2-derived biomass.

### **Red blood cell deformability**

Red blood cell deformability was measured on enrolment using a laser-assisted optical rotational cell analyser (LORCA; Mechatronics, Hoorn, The Netherlands).<sup>122</sup> This method applies a defined shear stress to a suspension of red blood cells in a highly viscous medium (5% polyvinylpyrrolidone in phosphate-buffered saline) at 37°C in a small space between two concentric rotating cylinders. Due to this shear stress, the cells deform into an elliptical shape to varying degrees depending on how stiff they are. A laser beam passed through these cells forms a diffraction pattern from which can be derived an Elongation Index (EI) which indicates the mean ellipticity of the red cells i.e. the mean amount that the red blood cells are deformed by the shear stress. EI is defined as the length of the long axis of the diffraction pattern minus the short axis divided by the length of the long axis plus the short axis. The EI is determined by computer analysis of the diffraction pattern using iso-intensity lines for curve fitting. In this study, red blood cell deformability was assessed at shear stresses of 0.30, 0.53, 0.95, 1.69, 3.00, 5.33, 9.49, 26.87 and 30.0 Pa. Shear stresses in vivo in

capillaries correspond approximately to 30.0 Pa, in arterioles to 9.49 Pa and in venules to 1.7 Pa.

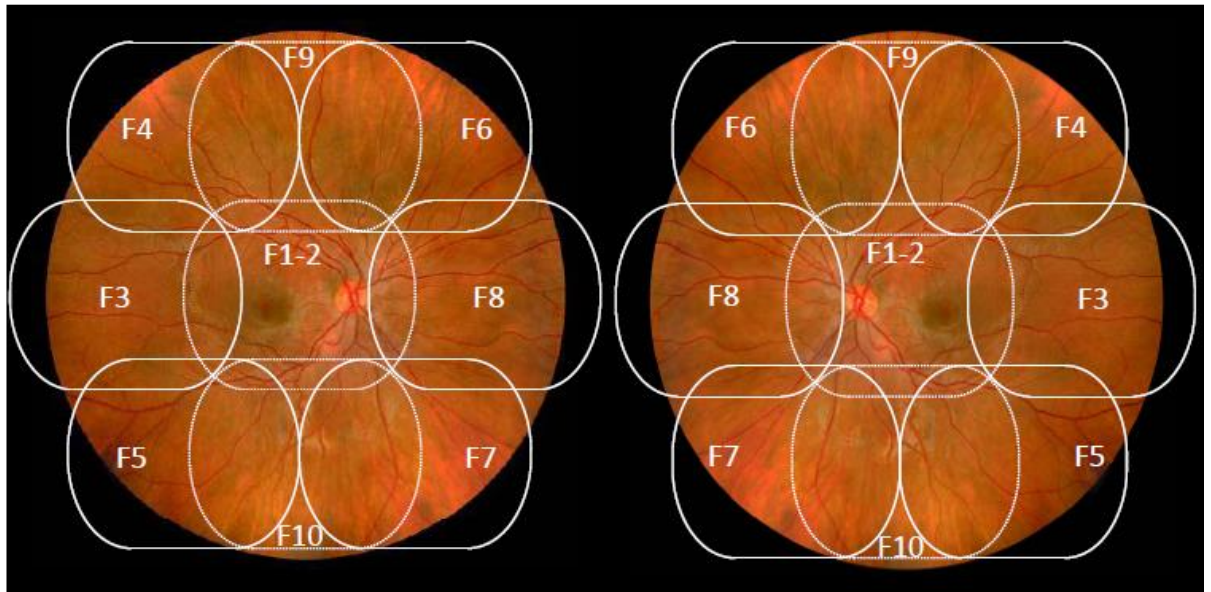
### **2.3.4 Fundoscopy and retinal photography**

#### **Fundoscopy**

As soon as possible after enrolment, all patients underwent dilated fundoscopy and retinal photography. First, external orbital and pupillary examination were performed. Patients were then given mydriatic eye drops consisting of phenylephrine plus tropicamide. Once mydriasis was achieved, indirect ophthalmoscopy was performed in both eyes to check for fundal visibility and for gross retinal changes.

#### **Retinal photography**

Next, digital photographs were taken of both retinas using a retinal camera. In Chittagong and in most patients in Rourkela, this was using a portable retinal camera (Kowa Genesis D, Kowa, Japan) following a 9 field protocol (**Figure 2.3-1**). This camera has a 50° field of view and resolution of 2 megapixels per image. The 9 field protocol captures a large part of the peripheral retina where many of the changes of malarial retinopathy are found. In Rourkela, a small number of patients underwent retinal photography with a tabletop retinal camera where portable retinal photography was unavailable due to operator absence. This used a 50° field of view and covered the same overall area as in **Figure 2.3-1**.



**Figure 2.3-1. The 9 field retinal photography protocol.**

Where possible, retinal photography was repeated daily until discharge and patients were invited to return for further retinal photography at weekly intervals until resolution of any visible retinopathy. *Note analysis of these follow-up photographs is not included in this thesis as the very large number of retinal photographs is still being analysed.*

In 2010-2011, a subset of patients in Bangladesh underwent fluorescein angiography using the method described in **Section 4.2**. A small number of patients in India underwent fluorescein angiography using a tabletop retinal camera. The selection of individuals for fluorescein angiography was determined by whether they tolerated colour photography sufficiently well and the availability of equipment. *Note analysis of these angiograms is not included in this thesis as the images are currently being analysed. Example images are shown in Section 4.3.*

Retinal images were stored digitally and anonymised. They were then examined at a later date by a single expert masked observer for grading of the severity of any retinal abnormalities present. All images were graded on 2 separate occasions by the same observer and the results compared to assess intra-observer agreement. In addition, a subset of images were re-graded by a second independent expert observer to assess inter-observer agreement. Retinal images were graded as mild, moderate or severe retinopathy according to a previously published classification of malarial retinopathy.<sup>260</sup> This classification includes retinal haemorrhages, retinal whitening, vessel discolouration and papilloedema as features of malarial retinopathy and is presented in full in **Appendix 10.1**. The form used is shown in **Section 10.2.4**. In addition



to this classification, numbers of retinal haemorrhages were recorded for each patient as a continuous measure.

### **Retinal vessel tortuosity**

Blood vessel width and tortuosity were measured from the retinal images as described previously<sup>261</sup>. Briefly, the Vessel Assessment and Measurement Platform for Images of the REtina (VAMPIRE; version 2.0, Universities of Edinburgh and Dundee, UK) applied a multi-scale, 2-D Gabor wavelet which transformed the fundus images to emphasize the appearance of vessels. Additionally a supervised pixel classification was guided to measure vessels by a Bayesian classifier. This is where the software builds a probabilistic model of the features consistent with a vessel and uses this model to predict the classification of a new area of the image as vessel or non-vessel. A trained user then manually identified regions of vessels for tortuosity or width measurements. For tortuosity, the algorithm integrated axis curvature and vessel width of chosen segments.<sup>262</sup> To measure vessel width the algorithm measured pixel widths perpendicular to an estimated vessel axis. Where images allowed the major saccadic vessels were sampled at one disc diameter from the disc, two disc diameters and three disc diameters from the disc edge. As normal ranges for the VAMPIRE parameters had not yet been established, data from 30 healthy individuals recruited in a separate study were used for comparison.

### **2.3.5 Statistical analysis**

Statistical analysis was performed using GraphPad Prism version 6.01 (GraphPad Software, Inc, La Jolla, USA). Intergroup differences were compared using unpaired t test with Welch's correction for normally distributed data or Mann-Whitney test for nonnormally distributed data. For non-normally distributed where possible it was log transformed and parametric tests applied. Distributions were compared using the Kolmogorov-Smirnov test. For comparison between multiple groups, one-way analysis of variance with Bonferroni's correction was used for nonpaired normally distributed data. For nonparametric data, the Kruskal Wallis test was used for multiple comparisons with Dunn's test to correct for multiple comparisons. Comparison of categorical variables was by Chi Square or Fisher's exact test. P for trend was used to assess correlation of variables with severity of malaria.

## 2.4 Results

### 2.4.1 Patients recruited

Subjects were recruited in Chittagong and Rourkela. Overall, 451 patients met eligibility criteria, were enrolled and successfully underwent retinal photography, as listed in Error! Reference source not found.. Most patients were adults (402/451 (89%)) and a small number of children were also recruited in each group.

**Table 2.4-1. Summary of subjects recruited in Chittagong and Rourkela.**

		Bangladesh	India	Age ≤16 years	Total
Malaria	<i>P. falciparum</i>	256	49	38	305
	Cerebral malaria	99	13	11	112
	Noncerebral severe malaria	51	17	5	68
	Uncomplicated malaria	106	19	22	125
Controls	Sepsis	43	0	5	43
	Encephalopathy	41	0	5	41
	Healthy	62	0	1	62
<b>Total</b>		<b>402</b>	<b>49</b>	<b>49</b>	<b>451</b>

Three subjects were excluded on screening due to having severe cataracts which precluded retinal photography. Cataracts were found in 121 patients but most were very mild and had no effect on retinal examination. Unilateral corneal scarring was found in 9 patients restricting fundal examination to one eye only. One patient had had unilateral enucleation of the eye. No patients gave a history of glaucoma and none were allergic to mydriatic eye drops.

The baseline characteristics of recruited patients with severe malaria, uncomplicated malaria, sepsis, encephalopathy and healthy subjects are summarised in Error! Reference source not found.. For reference, normal ranges for laboratory tests are provided in **Appendix 10.3**. Median age was similar between groups except those with uncomplicated malaria were younger than healthy individuals and those with encephalopathy. There were more males than females in those with malaria and healthy individuals but not the other groups. The

markers of severe malaria present on enrolment in the 180 patients with severe malaria are shown in **Table 2.4.3**.

**Table 2.4-2. Baseline characteristics of recruited patients in each group in Chittagong and Rourkela.**

Variable	Healthy	Sepsis	Encephalopathy	Uncomplicated malaria	Noncerebral severe malaria	Cerebral malaria
Age (years) <sup>a</sup>	34.5 (15-65)	28 (9-80)	35 (9-75)	25 (3-70)	33 (1.5-70)	30 (6-75)
Male/female	44/17	24/19	21/20	87/38	56/12	73/39
Glasgow Coma Scale <sup>a</sup>	15 (15-15)	15 (13-15)	8 (3-10)	15 (11-15)	14 (11-15)	8 (3-10)
Parasitaemia (/mm <sup>3</sup> )				12670 (7925-20277)	3946 (22030-470632)	24027 (14488-39811)
HRP2 (g/ $\mu$ L)				368.2 (291-466)	1162 (773-1746)	2714 (1671-2825)
Haematocrit (%) <sup>c</sup>	43.0 (41.8-44.3)	34.4 (31.8-36.9)	37.6 (34.-40.4)	32.1 (30.5-33.7)	29.3 (26.9-31.8)	28.2 (26.5-29.9)
Peripheral white blood cell count (*10 <sup>9</sup> /L) <sup>b</sup>	8.4 (7.1-9.3)	9.7 (6.8-17)	11.2 (8.0-15.9)	5.7 (4.2-7.9)	8.5 (6.3-12.4)	8.9 (6.5-13.4)
Platelet count (*10 <sup>9</sup> /L) <sup>b</sup>	245 (197-282)	195 (136-262)	233 (150-275)	60 (32-88)	30 (16-56)	33 (23-49)
Serum sodium (mmol/L)	139 (138-140)	135 (132-137)	134 (131-138)	134 (133-134)	134 (132-135)	137 (135-138)
Serum potassium (mmol/L)	3.7 (3.6-3.8)	3.6 (3.4-3.8)	3.6 (3.3-3.8)	3.6 (3.5-3.7)	3.9 (3.7-4.1)	3.8 (3.7-4.0)

Variable	Healthy	Sepsis	Encephalopathy	Uncomplicated malaria	Noncerebral severe malaria	Cerebral malaria
Total serum bilirubin (mg/dL) <sup>b</sup>		0.6 (0.4-1.3)	0.3 (0.2-0.7)	1.0 (0.6-2.0)	2.6 (1.1-8.3)	2.3 (1.1-5.8)
Serum alanine aminotransferase (U/L)		19 (13-28)	21 (14-31)	23 (20-27)	30 (23-38)	23 (20-27)
Serum alkaline phosphatase (U/L)		95 (73-124)	77 (59-101)	78 (69-88)	97 (85-111)	83 (75-92)
Serum albumin (g/100ml)		3.1 (2.9-3.4)	3.3 (3.1-3.6)	2.9 (2.8-3.0)	2.6 (2.5-2.8)	2.7 (2.6-2.9)
Serum creatinine (mg/dL) <sup>b</sup>	0.7 (0.7-0.9)	1.0 (0.8-1.3)	1.0 (0.7-1.6)	0.9 (0.8-1.1)	1.6 (1.0-3.4)	1.3 (0.9-1.9)
Blood urea nitrogen (mg/dL)	7.4 (6.4-8.5)	12.6 (9.5-16.7)	17.1 (11.5-25.4)	13.7 (12.2-15.4)	30.1 (24.4-37.2)	34.5 (30.2-39.4)
Plasma lactate (mmol/L) <sup>b</sup>	1.5 (1.2-1.8)	1.9 (1.6-2.3)	1.8 (1.4-2.3)	1.9 (1.8-2.1)	3.3 (2.8-3.8)	3.9 (3.5-4.4)
Venous bicarbonate (mmol/L) <sup>c</sup>	25.9 (25.3-26.6)	22.3 (20.8-23.9)	22.6 (20.1-25.2)	23 (22.4-23.5)	19.7 (18.4-20.9)	17.8 (16.8-18.8)
Serum base excess (mmol/L) <sup>b</sup>	1.5 (0 - 3)	-1 (-5 - -1)	-1 (-4 - -2)	-1 (-3 - -1)	-4 (-9 - -1)	-5 (-10 - -2)

Values are geometric mean (95% confidence interval) unless stated otherwise; a median (range); b median (range); c mean (interquartile range); d mean (95% confidence interval).

In those with severe malaria, coma, hyperlactataemia and acidosis were commoner and *Pf*HRP2 higher in those with retinopathy than those without. There were no differences in other severity markers or baseline blood results.

**Table 2.4-3. Mortality, severity indicators and selected blood results present on enrolment in patients with severe malaria with and without retinopathy.**

\* = geometric mean (95% CI)

	Retinopathy n = 146	No retinopathy n = 34	p
Died	49 (34%)	5 (15%)	<b>0.04</b>
Cerebral malaria (GCS < 11)	98 (67%)	14 (41%)	<b>0.005</b>
Venous lactate >4 mmol/l	72 (49%)	9 (26%)	<b>0.02</b>
Generalized convulsions (≥2 in 24 hours)	40 (27%)	9 (26%)	0.9
Acidosis (venous bicarbonate <15 mmol/l)	40 (27%)	3 (9%)	<b>0.02</b>
Renal failure (creatinine >3g/dL or anuria)	28 (19%)	6 (18%)	0.9
Jaundice (bilirubin >2.5 mg/dl + parasites >100,000/mm <sup>3</sup> )	24 (16%)	6 (18%)	0.9
Hyperparasitaemia (>10%)	25 (17%)	3 (9%)	0.3
Severe anaemia (Hct < 20% + parasites > 100,000/mm <sup>3</sup> )	13 (9%)	2 (6%)	0.7
Spontaneous bleeding	5 (3%)	1 (3%)	1
Shock (systolic BP<80 + cool peripheries)	3 (2%)	0 (0%)	1
Hypoglycaemia (blood glucose <40 mg/dl)	1 (1%)	1 (3%)	0.3
Pulmonary oedema	2 (1%)	0 (0%)	1
Parasitaemia (cells/mm <sup>3</sup> )*	27698 (18436 - 41612)	21556 (8351 - 55644)	0.6
<i>Pf</i> HRP2 (g/μL)*	2194 (1778 - 2708)	643 (321 - 1288)	<b>&lt;0.0001</b>
Peripheral white blood cell count (cells/mm <sup>3</sup> )*	9.2 (8.4 - 10.1)	7.8 (6.6 - 9.1)	0.1
Platelet count (cells/mm <sup>3</sup> )*	32 (29 - 36)	36 (23 - 55)	0.5

Mortality was higher in those with retinopathy. The median (interquartile range) of time to death for those with cerebral malaria was 48.5 (24.3-86.5) hours and those with noncerebral severe malaria 72.5 (31.4-138.0) hours.

The history of premorbid conditions, recent symptoms and consumption of medications which can cause changes in visual function or retinal appearance are listed in **Table 2.4-4**. Note that for patients who were too unwell to provide answers themselves, the history was provided by their attendants. Comorbid conditions and medications were unlikely to have significantly influenced the prevalence of retinopathy in each group. Comorbidities were present in a small minority of each group and cumulative doses of medications were low. Of note, 84 individuals had previously had malaria, 45 of whom had retinal changes (0 healthy, 2 sepsis, 3 encephalopathy and 40 malaria). None of those with sepsis, encephalopathy or healthy individuals who had retinal changes had had malaria within the past year. Premorbid diabetes mellitus was present in 10 individuals, 6 of whom had mild retinal changes (1 healthy, 1 sepsis and 4 malaria; 5 had haemorrhages and 4 whitening). Thirty individuals had a past history of hypertension (5 sepsis, 5 encephalopathy, 9 healthy and 11 malaria), 8 of whom had mild retinal changes and 3 had moderate retinal changes (6 had haemorrhages and 11 whitening). Although a high proportion of individuals with malaria had had quinine, this was of duration 7 days or less and a total amount insufficient to cause retinal changes.

Table 2.4-4. History in recruited individuals

	Cerebral	Noncerebral	Uncomplicated	Sepsis	Encephalopathy	Healthy	Total
<b>Comorbidities</b>							
Diabetes	0 (0.0%)	1 (1.5%)	4 (3.2%)	2 (4.7%)	0 (0.0%)	3 (4.8%)	10 (2.2%)
Hypertension	4 (3.6%)	2 (2.9%)	5 (4.0%)	6 (14.0%)	4 (9.8%)	9 (14.5%)	30 (6.7%)
Anaemia	2 (1.8%)	0 (0.0%)	0 (0.0%)	1 (2.3%)	0 (0.0%)	0 (0.0%)	3 (0.7%)
Stroke	10 (8.9%)	7 (10.3%)	8 (6.4%)	3 (7.0%)	2 (4.9%)	0 (0.0%)	30 (6.7%)
Other neurological condition	0 (0.0%)	0 (0.0%)	3 (2.4%)	1 (2.3%)	2 (4.9%)	0 (0.0%)	6 (1.3%)
Previous malaria	24 (21.4%)	16 (23.5%)	30 (24.0%)	2 (4.7%)	4 (9.8%)	8 (12.9%)	84 (18.6%)
<b>Symptoms in previous 2 weeks</b>							
Loss of vision	0 (0.0%)	1 (1.5%)	0 (0.0%)	2 (4.7%)	0 (0.0%)	2 (3.2%)	5 (1.1%)
Blurred vision	11 (9.8%)	7 (10.3%)	17 (13.6%)	7 (16.3%)	2 (4.9%)	6 (9.7%)	50 (11.1%)
Scotoma	0 (0.0%)	0 (0.0%)	0 (0.0%)	0 (0.0%)	0 (0.0%)	1 (1.6%)	1 (0.2%)
Photophobia	3 (2.7%)	5 (7.4%)	9 (7.2%)	1 (2.3%)	1 (2.4%)	1 (1.6%)	20 (4.4%)
Double vision	0 (0.0%)	1 (1.5%)	1 (0.8%)	0 (0.0%)	1 (2.4%)	0 (0.0%)	3 (0.7%)
Visual field deficit	1 (0.9%)	2 (2.9%)	2 (1.6%)	1 (2.3%)	1 (2.4%)	3 (4.8%)	10 (2.2%)
Colour blindness	1 (0.9%)	2 (2.9%)	2 (1.6%)	0 (0.0%)	0 (0.0%)	0 (0.0%)	5 (1.1%)
Seizure	34 (30.4%)	14 (20.6%)	4 (3.2%)	2 (4.7%)	5 (12.2%)	1 (1.6%)	60 (13.3%)
Headache	67 (59.8%)	50 (73.5%)	70 (56.0%)	29 (67.4%)	11 (26.8%)	13 (21.0%)	240 (53.2%)
Weakness	9 (8.0%)	15 (22.1%)	14 (11.2%)	5 (11.6%)	8 (19.5%)	1 (1.6%)	52 (11.5%)
<b>Medications</b>							
Chloroquine	6 (5.4%)	3 (4.4%)	6 (4.8%)	1 (2.3%)	1 (2.4%)	2 (3.2%)	19 (4.2%)
Hydroxychloroquine	0 (0.0%)	0 (0.0%)	0 (0.0%)	0 (0.0%)	0 (0.0%)	1 (1.6%)	1 (0.2%)
Primaquine	1 (0.9%)	2 (2.9%)	2 (1.6%)	0 (0.0%)	0 (0.0%)	2 (3.2%)	7 (1.6%)
Quinine	61 (54.5%)	24 (35.3%)	43 (34.4%)	1 (2.3%)	6 (14.6%)	1 (1.6%)	136 (30.2%)
Ethambutol	0 (0.0%)	2 (2.9%)	1 (0.8%)	1 (2.3%)	0 (0.0%)	1 (1.6%)	5 (1.1%)
Ciprofloxacin	14 (12.5%)	8 (11.8%)	14 (11.2%)	7 (16.3%)	2 (4.9%)	5 (8.1%)	50 (11.1%)
Other quinolone	4 (3.6%)	0 (0.0%)	5 (4.0%)	1 (2.3%)	0 (0.0%)	1 (1.6%)	11 (2.4%)
Chlorpromazine	0 (0.0%)	0 (0.0%)	1 (0.8%)	1 (2.3%)	1 (2.4%)	0 (0.0%)	3 (0.7%)



## 2.4.2 Retinal photographs

Most patients underwent retinal photography with a portable retinal camera. In India, some individuals with malaria (2 cerebral, 4 noncerebral and 10 uncomplicated) were photographed with a wide field tabletop retinal camera when the portable retinal camera was not available. Indicators of the quality of retinal photography are shown in **Table 2.4.-5**.

**Table 2.4-5. Quality indicators for retinal photography.**

	Cerebral	Noncerebral	Uncomplicated	Sepsis	Encephalopathy	Healthy
<b>Image clarity</b>						
Ungradable	2.7%	1.5%	4.8%	2.3%	4.9%	0.0%
Marked blurring	16.1%	14.7%	9.7%	9.3%	22.0%	9.7%
Mild blurring	79.5%	75.0%	72.6%	60.5%	51.2%	72.6%
No blurring	1.8%	8.8%	12.9%	27.9%	22.0%	17.7%
<b>Number of photographs</b>						
≥9 photos both eyes	78.3%	77.4%	72.2%	69.0%	64.1%	51.6%
≥9 photos ≥1 eye	92.5%	87.1%	89.8%	88.1%	92.3%	79.0%
Median (IQR) photos/person	41 (23-54)	30 (17.5-51)	24 (16-39)	28 (16.5-42.5)	24 (17-34)	21 (10-30)
<b>Coverage</b>						
Macula	97.2%	100.0%	96.6%	100.0%	100.0%	98.4%
Temporal	86.1%	83.3%	86.4%	95.2%	87.2%	88.7%
Superior	94.4%	92.4%	94.9%	100.0%	97.4%	95.2%
Nasal	95.4%	89.4%	88.1%	97.6%	97.4%	90.3%
Inferior	94.4%	97.0%	95.8%	95.2%	100.0%	96.8%
Any peripheral	97.2%	100.0%	97.5%	100.0%	100.0%	98.4%

Image clarity was defined as follows: ungradeable = none of the images contained identifiable retinal vessels or fovea; marked blurring = all areas of the retina were blurred; mild blurring = some retinal areas were blurred and some clear but retinal vessels and fovea were easily identifiable in all areas; no blurring = all retinal areas were clear. Coverage was defined as follows: for peripheral retina: at least 1 gradable image with  $\geq 2/3$  covering the relevant area; for macula: at least 1 gradable image centred on the fovea.

In all groups, the majority of individuals tolerated retinal photography well and  $\geq 9$  gradable photographs were obtained. The median (IQR) number of retinal photographs taken per eye was 14 (10-23.75). Blurring of retinal photographs was commonly encountered and was due

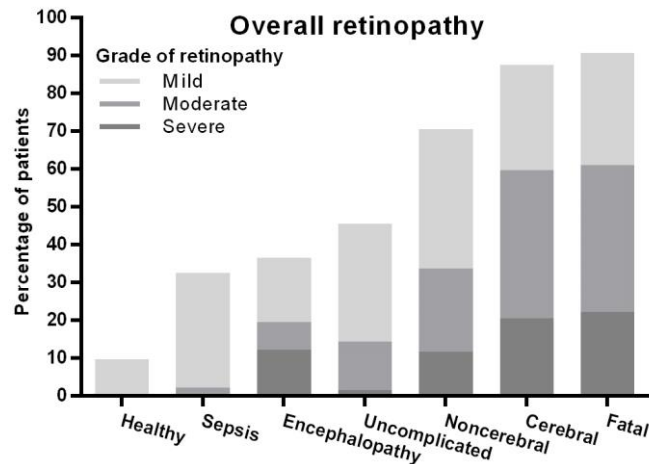
to a variety of factors including dessication of the cornea, roving eye movements, nystagmus, occult seizure activity and voluntary eye movements. In the few individuals in whom retinal photographs were unreadable, examination was completed by indirect ophthalmoscopy.

Intra-observer and interobserver agreement for grading of retinal photographs were high. Overall grading of retinopathy (none, mild, moderate or severe as defined in **Appendix 10.1**) on two separate masked readings of retinal photographs from each eye by the same observer matched in 96% of cases. A second independent observer graded photos from 10 patients and the overall grading of retinal findings matched that of the first observer in 100% of cases.

### 2.4.3 Retinopathy as a diagnostic marker

#### Overall retinopathy

Overall retinal findings in each group are summarised in **Figure 2.4-1**.



**Figure 2.4-1. Frequency and severity of retinopathy in patients of all ages with malaria, sepsis, encephalopathy and healthy controls.**

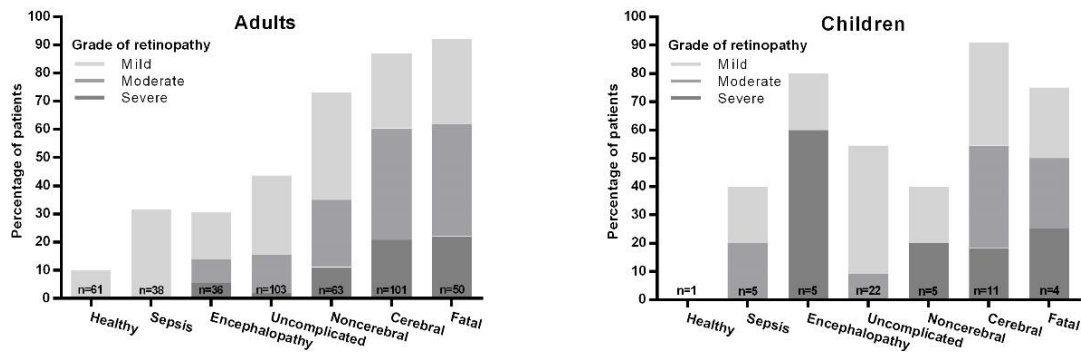
Severity is defined in **Appendix 10.1**.

Retinopathy was commonest and most severe in fatal (49/54 (91%)) and cerebral (98/112 (88%)) malaria. In those with noncerebral severe malaria retinopathy was less common (48/68 (71%)) than in those with cerebral malaria ( $p=0.005$ ). This difference was more marked for moderate-severe retinopathy (33/54 (61%) fatal; 67/112 (60%) cerebral versus 23/68 (34%) of noncerebral severe,  $p=0.0006$ ). In those with uncomplicated malaria, retinopathy and moderate-severe retinopathy were much less frequent than in noncerebral severe malaria (57/125 (46%),  $p=0.0007$  and 18/125 (14%),  $p=0.0018$  respectively).

When using the presence or absence of retinopathy to distinguish between severe and uncomplicated malaria in conscious individuals the sensitivity and specificity for severe malaria were 78% and 46% with positive predictive value (PPV) 54% and negative predictive value (NPV) 71%. The associated relative risk (RR) (95% CI) of severe malaria in those with retinopathy was 1.9 (1.2-2.8).

The differences between groups appeared to be more marked in adults than in children (**Figure 2.4-2**) but inferences were limited by the small number of children recruited. In

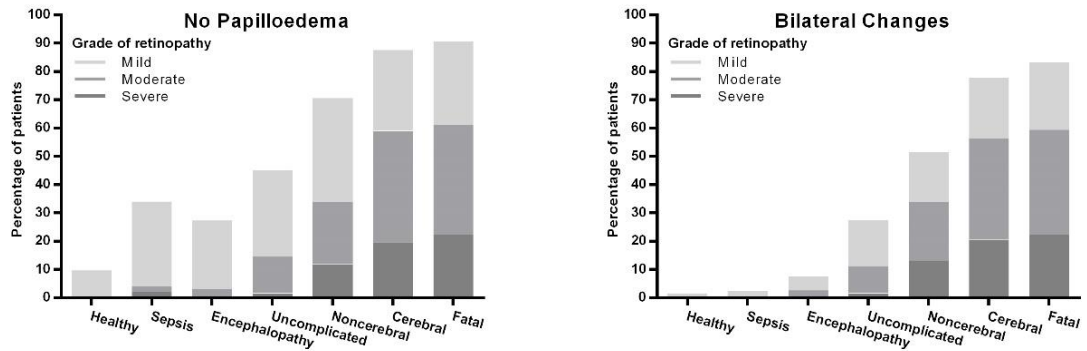
adults, 92% with fatal, 87% with cerebral, 73% with noncerebral severe and 44% with uncomplicated falciparum malaria had retinopathy, as compared to 75%, 91%, 40% and 55% in children. There were no significant differences in the frequency of retinopathy between adults and children for those with fatal, cerebral or noncerebral severe malaria, sepsis or healthy individuals. Retinopathy was commoner in children with encephalopathy than in adults ( $p=0.05$ ), due to 3/5 children having papilloedema, a feature not seen in the children with cerebral malaria.



**Figure 2.4-2. Frequency and severity of retinopathy in adults and children with malaria, sepsis, encephalopathy and healthy controls.**

Severity is defined in **Appendix 10.1**.

Although less common than in severe malaria, retinal changes were also found in 33% of patients with sepsis, 37% of those with encephalopathy and 10% of healthy individuals. Other than papilloedema in 4/41 (10%) patients with encephalopathy, retinal changes in these control groups were mostly mild and unilateral whereas changes seen in those with malaria were more often moderate-severe and were mostly bilateral (**Figure 2.4-3**). Of those with moderate-severe retinal changes, these were bilateral in 0% of healthy individuals, 0% of sepsis, 25% of encephalopathy, 89% with uncomplicated malaria, 97% of cerebral malaria and 97% of fatal malaria. On questioning, out of those with retinal signs, 16% of those with sepsis, 15% of those with encephalopathy and 2% of healthy individuals, had had previous malaria, or had underlying diabetes, hypertension or anaemia. Medications which can affect the retina had been taken by 33%, 40% and 0% of those with retinal changes, respectively, although most were only short courses of  $\leq 7$  days therefore unlikely to cause visible retinal damage. Thus most of the mild changes seen in these groups were unexplained.



**Figure 2.4-3. Frequency and severity of retinopathy excluding papilloedema and in those with bilateral changes only in patients of all ages with malaria, sepsis, encephalopathy and healthy controls.**

Severity is defined in **Appendix 10.1**.

In patients with coma, 98/112 (88%) patients with cerebral malaria and 15/41 (37%) patients with non-malarial encephalopathy had retinal changes ( $p < 0.0001$ ). This translates to a RR of cerebral malaria in those with coma and retinal changes of 2.5 with sensitivity of 88% and specificity of 63%. The PPV was 87% and NPV 65%. When papilloedema was excluded, the RR increased to 2.7 with sensitivity 88% and specificity 71%. For moderate-severe retinopathy and excluding papilloedema, RR was 1.8 (1.5-2.2) with sensitivity 59% and specificity 95%.

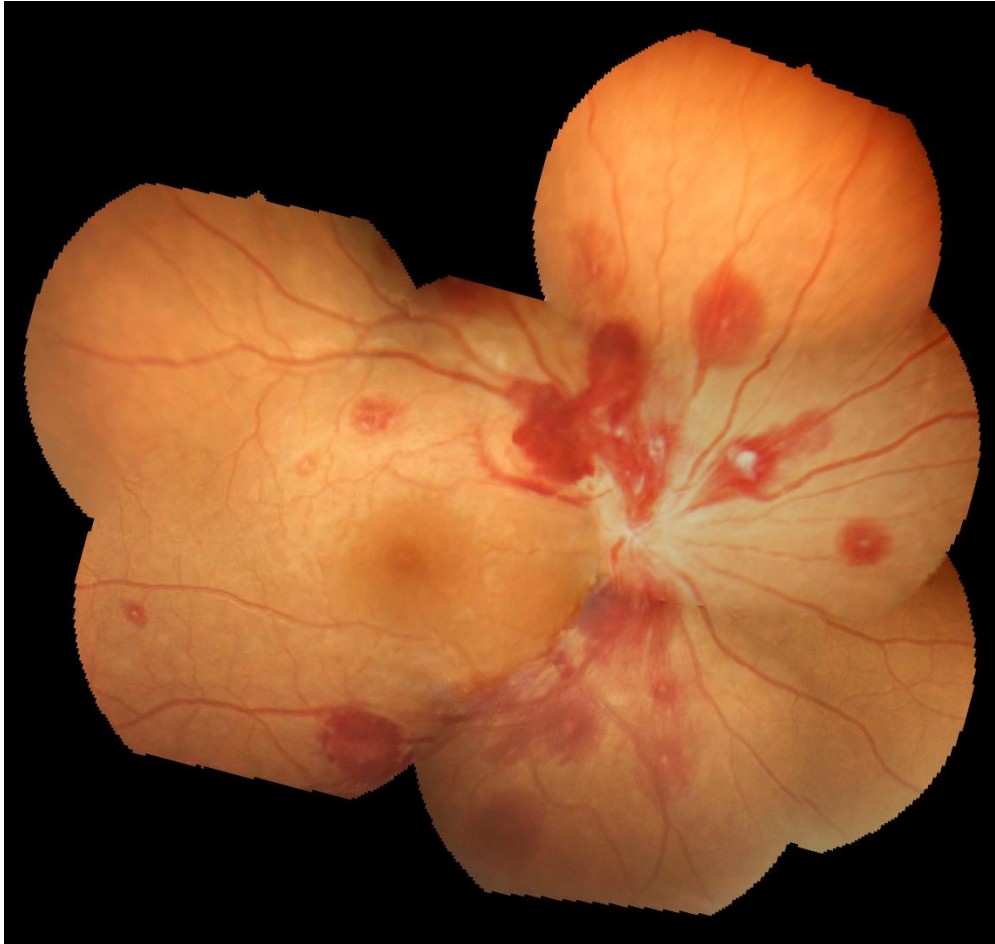Despite the differences in prevalence and severity of retinopathy between groups, it was not possible to define clear cut-offs. This was in part due to the heterogeneous nature of the lesions which varied in size and location and clarity and in some cases overlapped.

### Papilloedema

Unilateral swelling of the optic disc consistent with papilloedema was seen in 2 patients with severe malaria, 1/112 (1%) with coma who survived and 1/68 (1%) without coma who died (**Figure 2.4-4**). Both were adults. Neurological examination was otherwise normal and the patients had no neurological symptoms. Neither underwent brain imaging, the first because of lack of scanner availability and the second because they died 12 hours after admission before imaging could be done. One possibility is that this swelling of the optic disc was due to unilateral optic neuropathy for example due to anterior ischaemic optic neuropathy

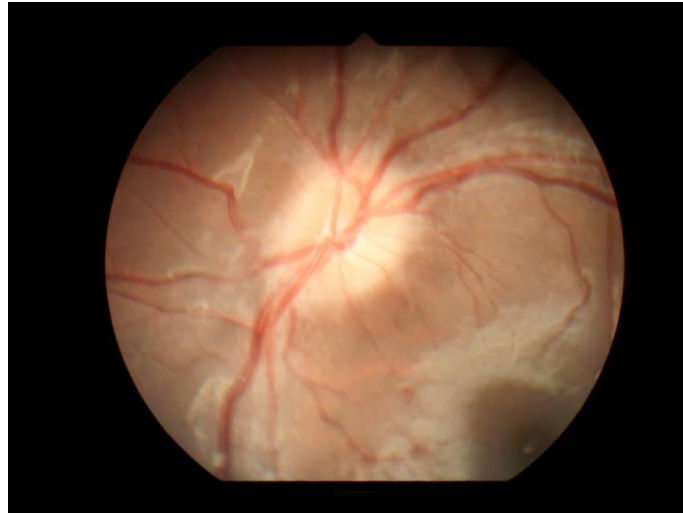
(AION) although it was not possible to confirm with available diagnostic tools.

Papilloedema was seen in 6/41 (15%) of those with encephalopathy (3 children, 3 adults (**Figure 2.4-5**)) and none with sepsis or healthy individuals.



**Figure 2.4-4. Papilloedema and severe white-centred retinal haemorrhages in Bangladeshi adult with cerebral malaria.**

Composite retinal photograph of right eye. Papilloedema in this patient was unilateral and confirmed on indirect ophthalmoscopy. There were also multiple severe peripapillary flame-shaped haemorrhages. One possible cause of the papilloedema is unilateral optic neuropathy although it was not possible to confirm this with available diagnostic tools.



**Figure 2.4-5. Papilloedema in Bangladeshi child with nonmalarial febrile encephalopathy.**

Single retinal photograph of left eye. Papilloedema was bilateral in this patient.

#### **Retinal haemorrhages**

Retinal haemorrhages were present in all groups but were commonest in fatal (54%) and cerebral (52%) malaria (**Figure 2.4-6**). Most individuals in all groups had mild haemorrhages (1-5 total in both eyes). The median number of haemorrhages was greater than in healthy individuals in all groups other than encephalopathy ( $p < 0.0001$ , **Figure 2.4-7**). More patients with cerebral malaria than noncerebral severe malaria had haemorrhages (50% vs 34%,  $p = 0.03$ ) but there was no difference in the median number of haemorrhages. The median number of haemorrhages was greater in those with cerebral malaria (median (IQR) 1 (3-7)) than in those with encephalopathy (0 (0-0),  $p < 0.0001$ ). The presence of haemorrhages on retinal examination in an individual with coma conferred a RR of cerebral malaria of 1.8 (1.4-2.2). Sensitivity and specificity of haemorrhages for cerebral malaria in comatose patients were 39% and 91% respectively.

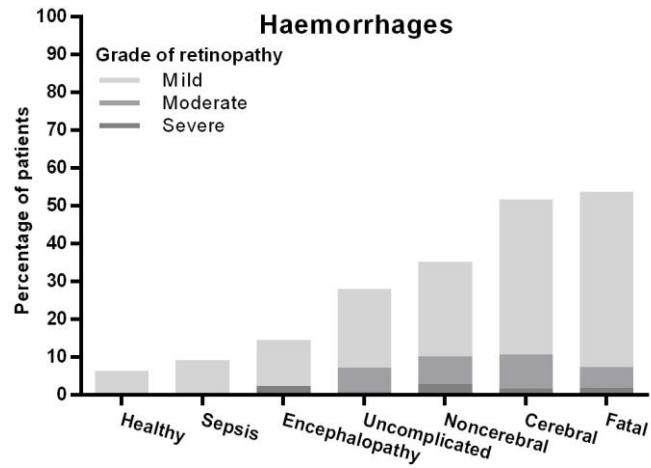


Figure 2.4-6. Frequency and severity of retinal haemorrhages in each group.

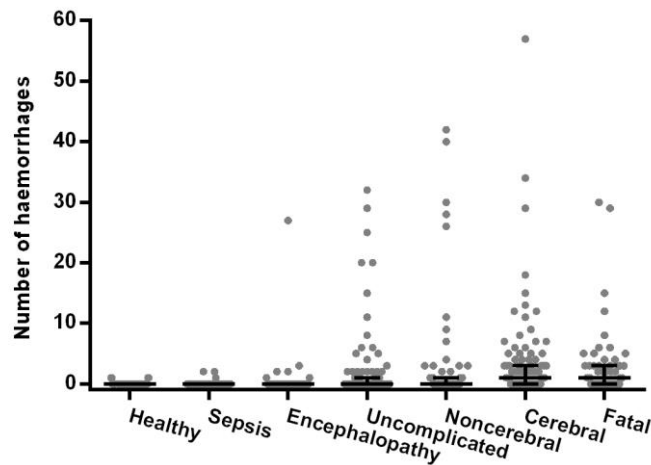


Figure 2.4-7. Numbers of retinal haemorrhages seen in individuals in each group.

In patients with severe malaria, dot, blot and white-centred haemorrhages were all common. Around half of haemorrhages seen were white centred haemorrhages in those with malaria and sepsis but were rare in those with encephalopathy and healthy individuals (**Figure 2.4-8**). The proportion of haemorrhages which were white-centred was unrelated to the severity of malaria. Examples of white-centred haemorrhages in a patient with cerebral malaria are shown in **Figure 2.4-9** and noncerebral malaria in **Figure 2.4-10**.



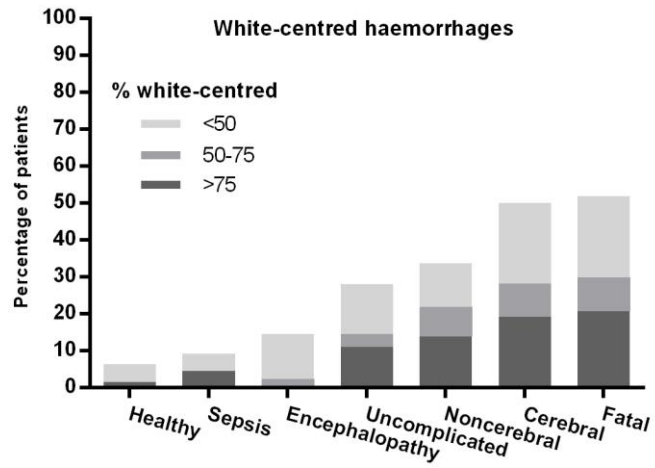


Figure 2.4-8. Proportion of individuals with white-centred haemorrhages.

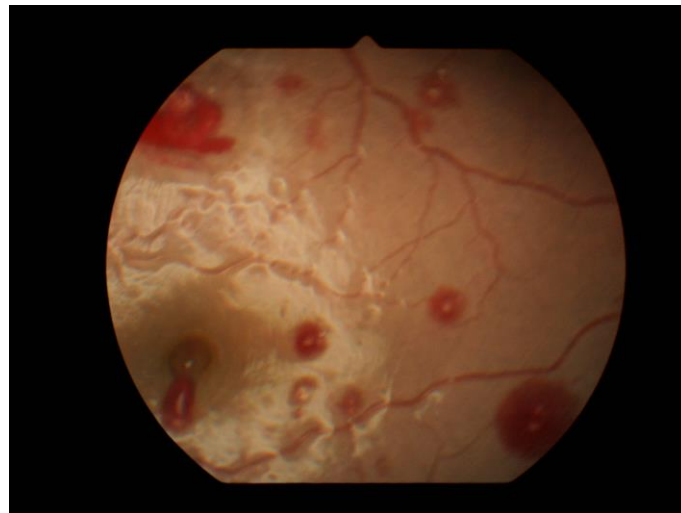
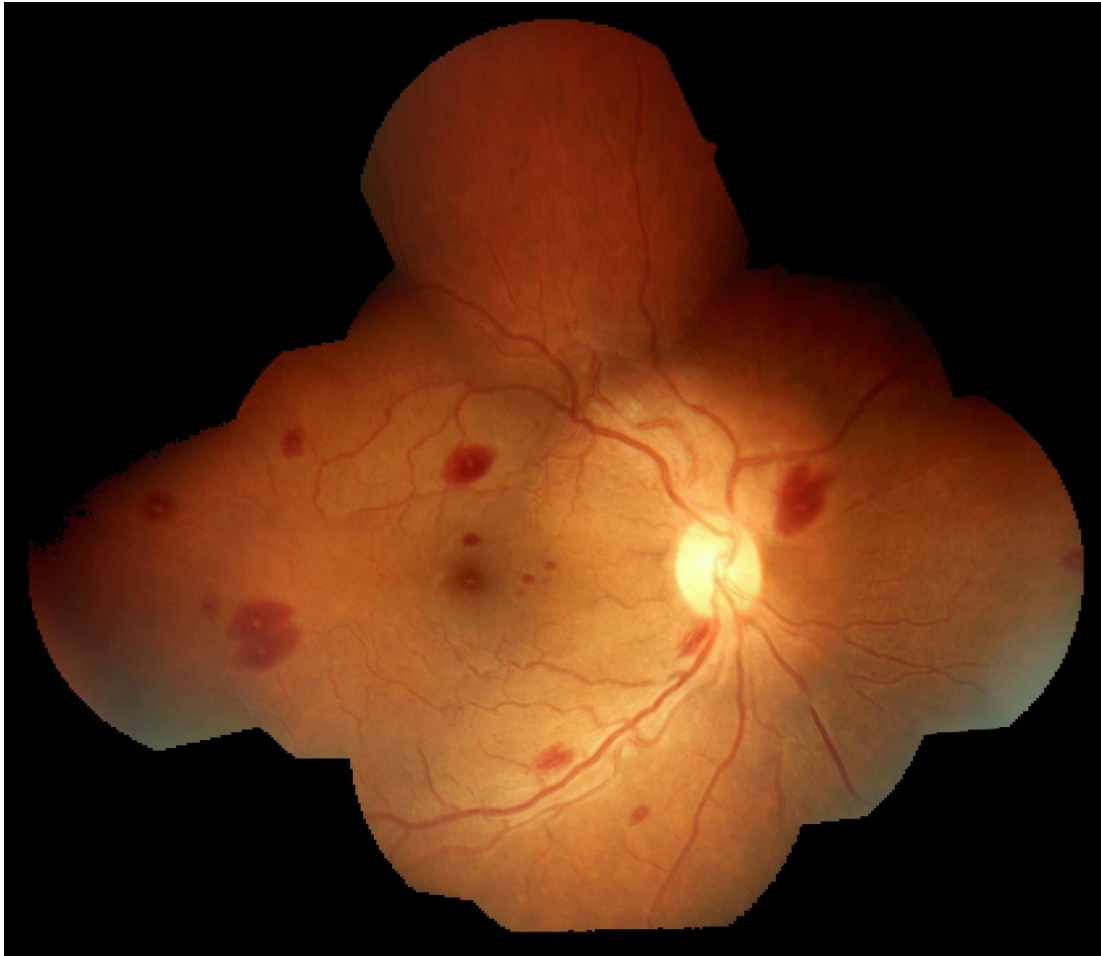

Figure 2.4-9. Multiple white-centred retinal haemorrhages in Bangladeshi adult with cerebral malaria.

Single retinal photograph of left eye.



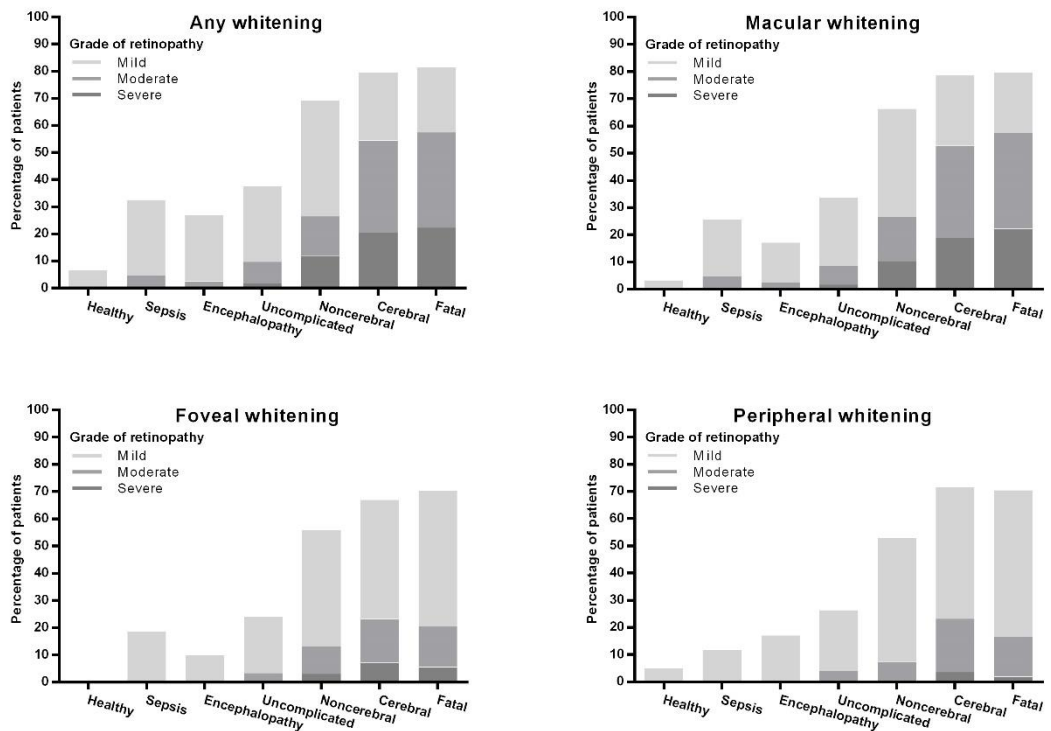
**Figure 2.4-10. Severe white-centred retinal haemorrhages in Bangladeshi adult with noncerebral severe malaria.**

Composite retinal photograph of right eye showing multiple severe flame-shaped and dot haemorrhages.

### **Retinal whitening**

Retinal whitening was the predominant determinant of overall grade of retinopathy in all patient groups. It was present in 81% of fatal, 79% of cerebral, 69% of noncerebral severe and 38% of uncomplicated malaria; as well as 33% of sepsis, 27% of encephalopathy and 6% of healthy individuals in whom changes were mostly unilateral and mild. Macular, foveal and peripheral whitening were all commonest and most severe in those with fatal and cerebral malaria (**Figure 2.4-11**). In those with severe malaria, macular changes were the most prominent with multiple small patches of whitening clustered around and temporal to

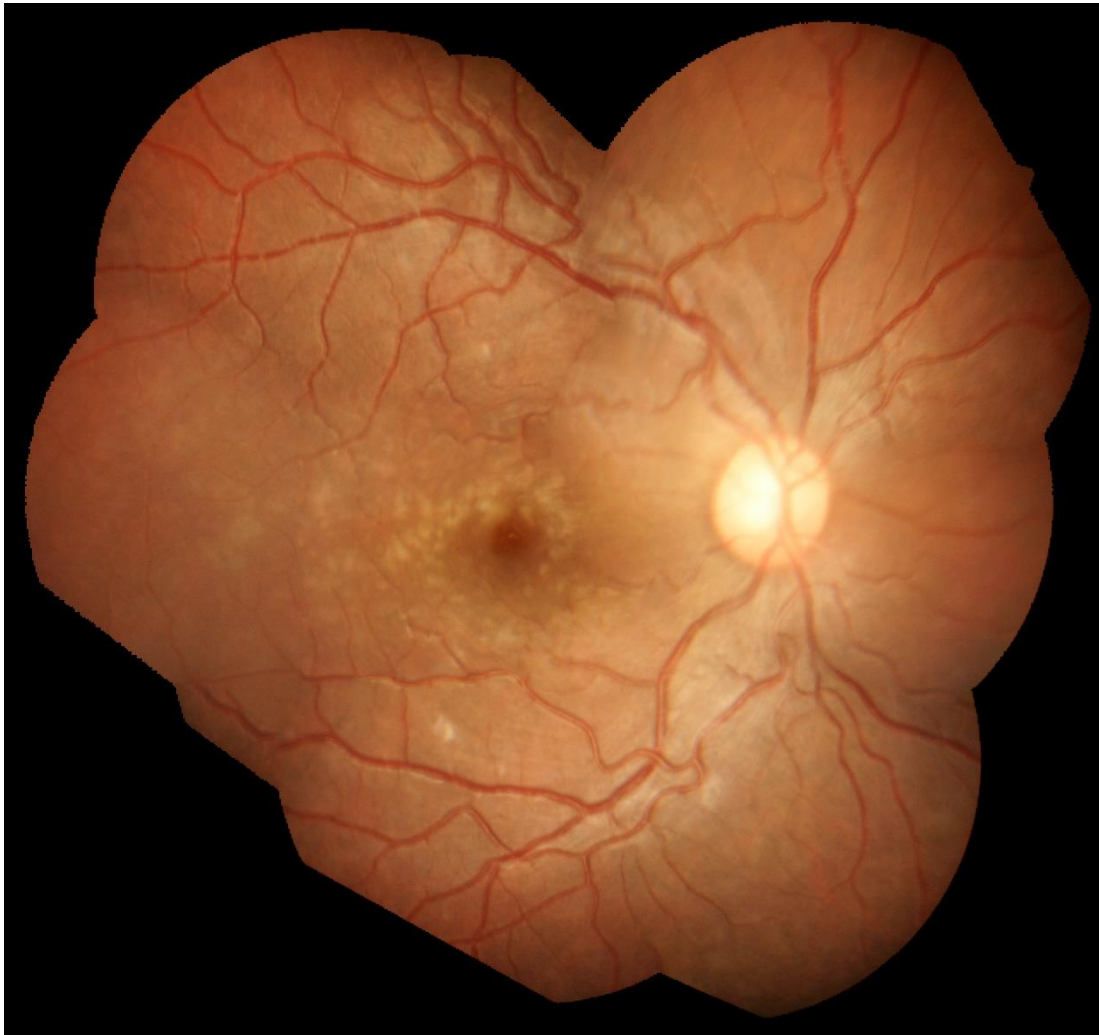the fovea being highly specific for malaria (**Figure 2.4-12**). Macular and foveal whitening were frequently also associated with peripheral whitening (example shown in **Figure 2.4-13**).



**Figure 2.4-11. Frequency and severity of retinal whitening in each group.**

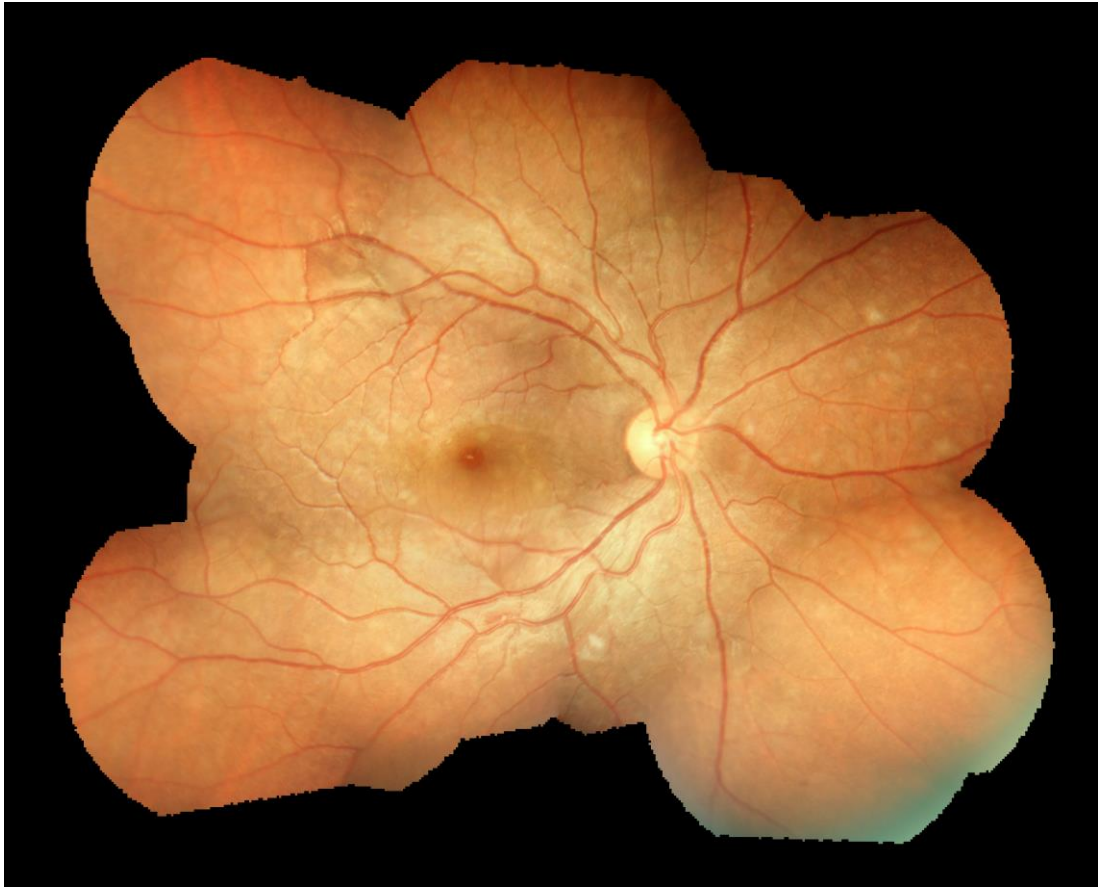Severity is defined in **Appendix 10.1**.

Figures are shown for each of any whitening, macular, foveal and peripheral whitening.



**Figure 2.4-12. Severe macular and mild peripheral retinal whitening in Bangladeshi adult with cerebral malaria.**

Composite retinal photograph of right eye showing mosaic severe retinal whitening around the fovea and along the temporal watershed and mild peripheral whitening. The lesions are typically situated between small retinal vessels and appear slightly raised on indirect ophthalmoscopy indicating their retinal location. This appearance is highly specific for *falciparum* malaria.

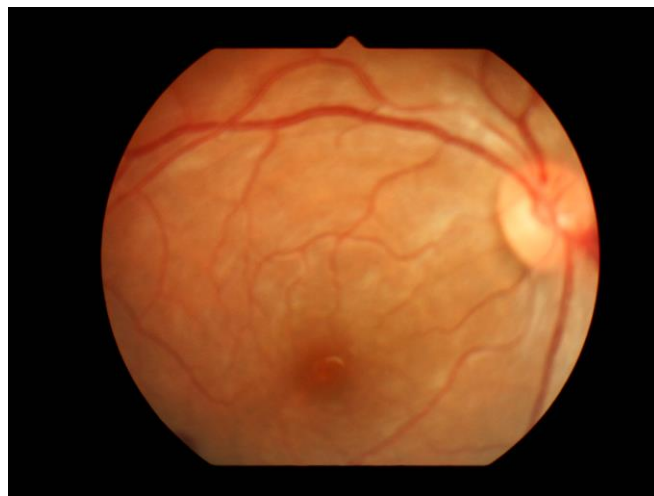

**Figure 2.4-13. Severe macular and peripheral retinal whitening in Bangladeshi adult with cerebral malaria.**

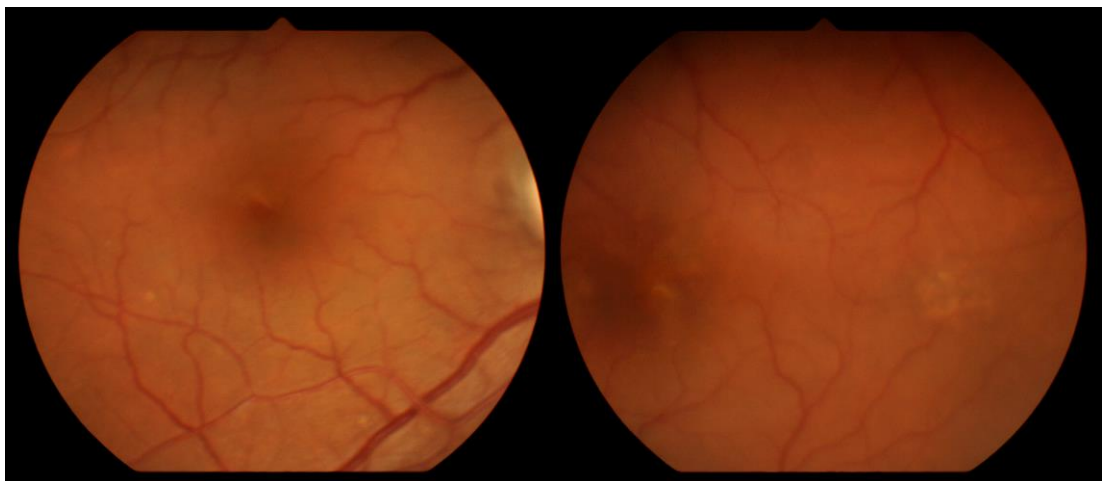
Composite retinal photograph of right eye.

Retinal whitening was seen in some individuals without malaria but, other than one adult with sepsis and one adult with fatal encephalopathy and moderate whitening in Bangladesh, this was all mild with occasional single white spots in the macula or periphery. The individual with sepsis and moderate retinal whitening was unusual in having moderate macular and mild foveal whitening with several pale spots similar in appearance to those seen in malaria (**Figure 2.4-14**) and 2 white-centred haemorrhages. They did not have peripheral whitening or whitening temporal to the fovea, as commonly seen in severe malaria. They presented with anaemia, hyperlactaemia, renal failure, raised bilirubin, AST and ALT. As they were fully conscious it was only possible to photograph one eye. The individual with encephalopathy had a patch of mosaic temporal whitening and a few pale

spots in and around the fovea in one eye and occasional single white spots in the other eye (**Figure 2.4-15**). The mosaic whitening was clustered and appeared more focal than that typically seen in patients with malaria. In addition, the lesions were not raised and they were crossed by large and small retinal blood vessels suggesting a location deeper in the retina or choroid than the whitening typical of malaria. Both patients were negative for malaria on a peripheral blood film but neither were tested for *PfHRP2* and in neither was an underlying diagnosis confirmed. The patient with sepsis denied previous malaria or any other past medical history but the patient with encephalopathy died before this could be asked. It was not possible for an ophthalmologist to examine the patient with encephalopathy prior to death.



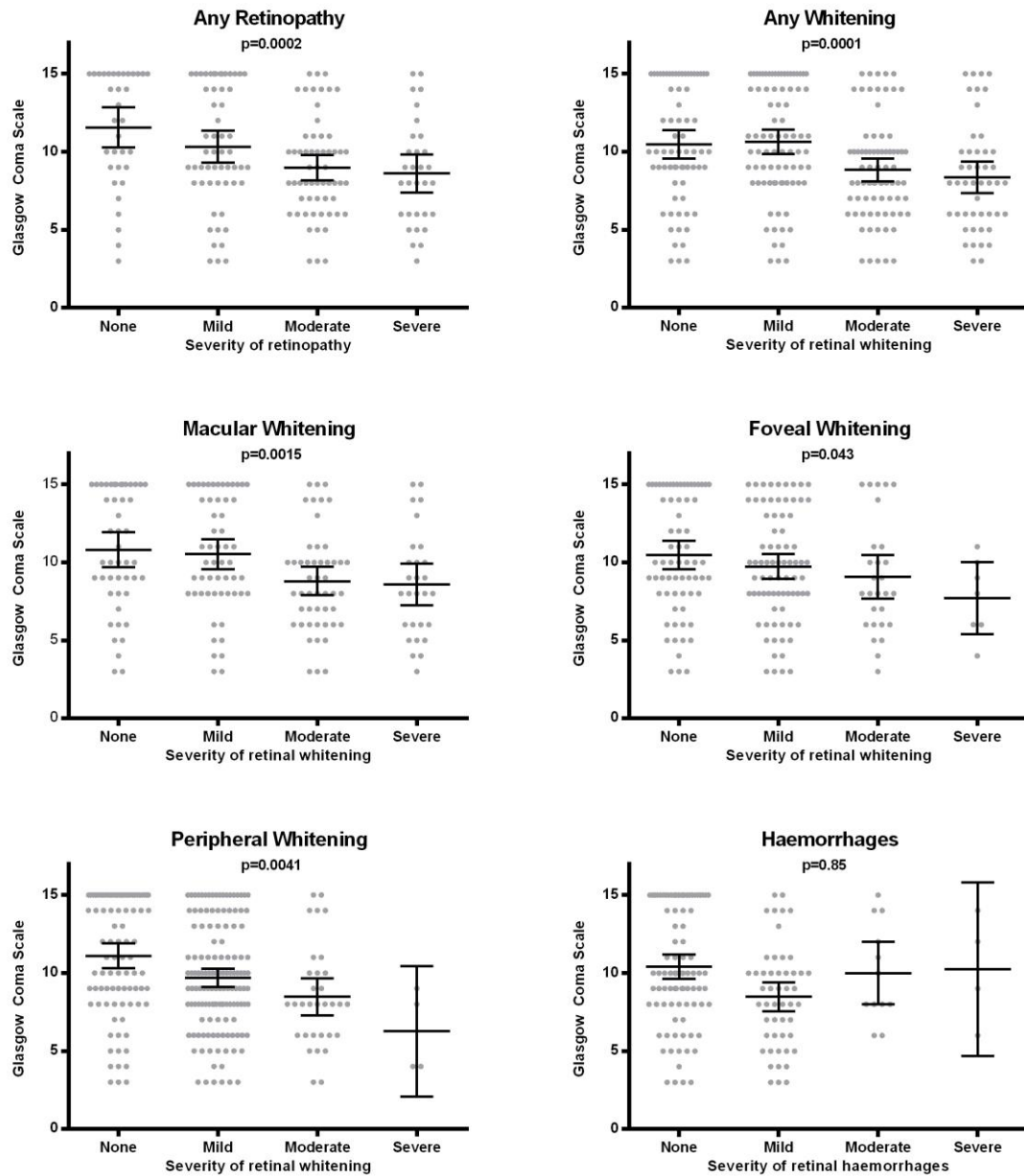
**Figure 2.4-14.** Retinal photograph of right eye from Bangladeshi adult with sepsis.



**Figure 2.4-15.** Retinal photographs of right and left eyes from Bangladeshi adult with nonmalarial febrile encephalopathy.



In patients with severe malaria, the severity of retinal whitening correlated with GCS (Figure 2.4-16). This relationship was strongest for macular whitening.

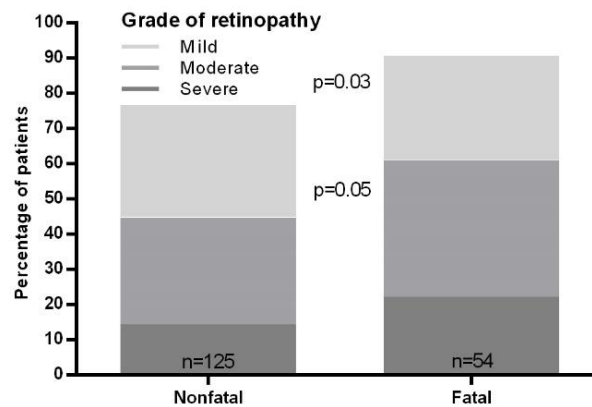


**Figure 2.4-16. Severity of retinopathy and GCS in patients with severe**  
Severity is defined in **Appendix 10.1**.

### 2.4.4 Retinopathy as a prognostic marker

#### Death

Retinopathy was commoner in those with fatal than in nonfatal falciparum malaria (49/54 (91%) versus 96/125 (77%),  $p=0.03$ , **Figure 2.4-17**). This was also true for moderate-severe retinopathy (33/54 (61%) versus 56/125 (45%) respectively,  $p=0.05$ ). Mortality in patients with severe malaria and retinopathy was higher than those without retinopathy (Error! Reference source not found., 34% versus 15%,  $p=0.04$ ). The sensitivity of retinopathy for predicting death in severe malaria was 91% with specificity 23%, PPV 34%, NPV 85% and RR of death 2.3.

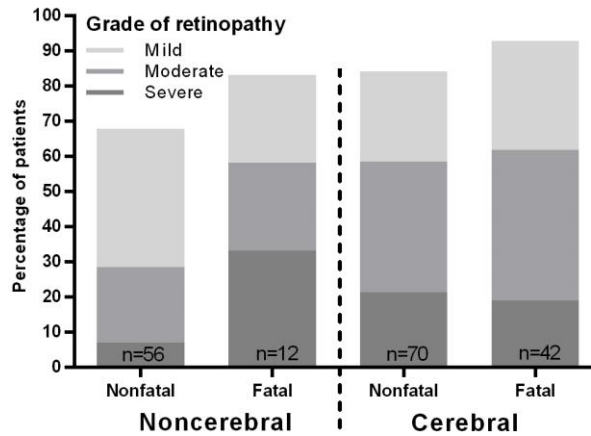


**Figure 2.4-17. Frequency and severity of retinopathy in fatal and nonfatal severe malaria.**

Severity is defined in **Appendix 10.1**.

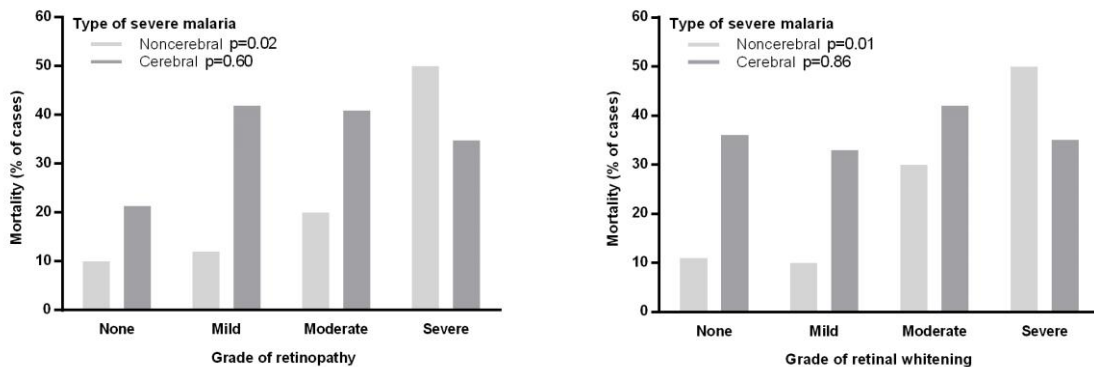
There was no difference in the overall prevalence of retinopathy between those with fatal and nonfatal malaria for the subgroups with and without coma (**Figure 2.4-18**). However, for those with noncerebral severe malaria, mortality was higher with moderate-severe retinopathy (30%) than none-mild retinopathy (11%,  $p=0.05$ ) and moderate-severe whitening (39%) versus none-mild whitening (10%,  $p=0.01$ ). There was a significant trend in those with noncerebral severe malaria of increasing mortality with increasing severity of overall retinopathy ( $p=0.02$ ) and also retinal whitening ( $p=0.01$ , **Figure 2.4-19**). There was no such trend for cerebral malaria.





**Figure 2.4-18. Frequency and severity of retinopathy in fatal and nonfatal cerebral and noncerebral severe malaria.**

Severity is defined in **Appendix 10.1**.



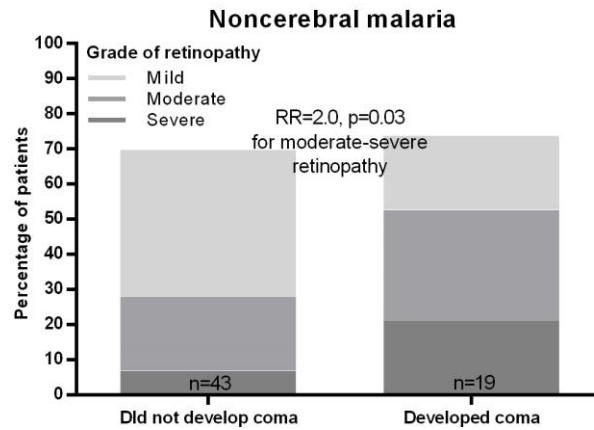
**Figure 2.4-19. Mortality in noncerebral severe and cerebral malaria with different grades of overall retinopathy and retinal whitening.**

Severity is defined in **Appendix 10.1**.

**Coma**

Of the 68 individuals with non-cerebral severe malaria, 62 were followed up (4 died early, 1 was transferred to another facility and 1 was lost to follow-up) and 19 subsequently developed coma during their admission. Those who developed coma were more likely to have moderate-severe retinopathy (RR 2.0,  $p=0.03$ ,

Figure 2.4-20).

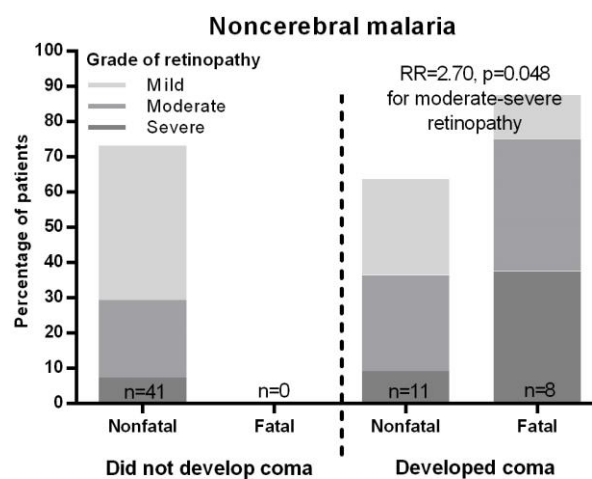


**Figure 2.4-20. Frequency and severity of retinopathy in patients with noncerebral severe malaria who did and did not develop coma during their admission.**

Severity is defined in **Appendix 10.1**.

In those with noncerebral severe malaria who later developed coma, those with moderate-severe retinopathy were also more likely to die (RR 2.7, p=0.048,

**Figure 2.4-21).** In patients with retinopathy who developed coma after enrolment and subsequently died

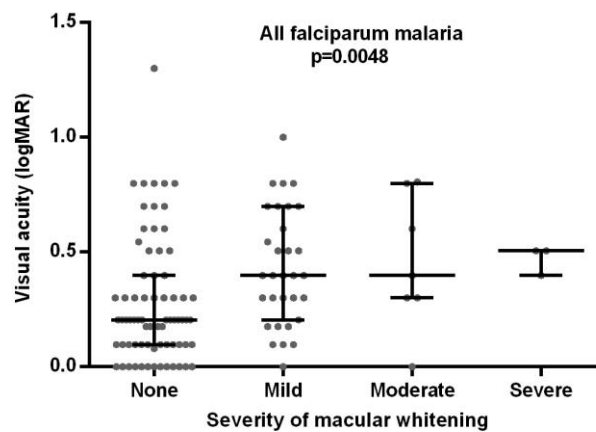


**Figure 2.4-21. Frequency and severity of retinopathy in fatal and nonfatal severe malaria in those who did and did not develop coma during admission.**

Severity is defined in **Appendix 10.1**.

### 2.4.5 Retinopathy and visual function

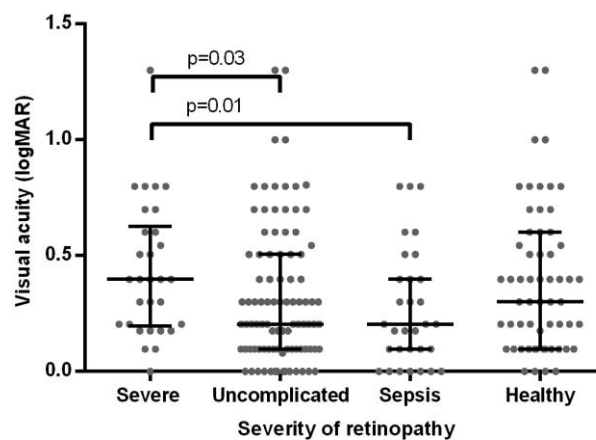
In patients with falciparum malaria, worse visual acuity was associated with more severe macular whitening (**Figure 2.4-22**).



**Figure 2.4-22. Visual acuity in patients with falciparum malaria and different severities of macular whitening.**

Severity is defined in **Appendix 10.1**.

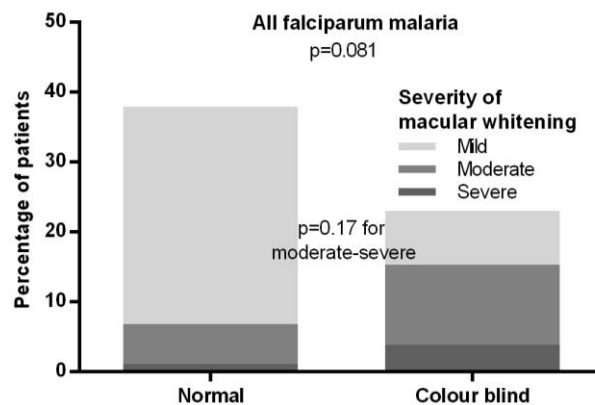
Median acuity in those with severe malaria was worse than those with uncomplicated malaria ( $p=0.03$ ) and sepsis ( $p=0.01$ ) but no different to healthy individuals **Figure 2.4-23**.



**Figure 2.4-23. Visual acuity in patients with severe and uncomplicated malaria, sepsis and healthy individuals.**

Severity is defined in **Appendix 10.1**.

Overall, of those who were conscious, well enough to be assessed, and could do the test 10/29 (34%) of those with severe malaria, 16/84 (19%) of patients with uncomplicated malaria, 5/25 (13%) with sepsis and 8/57 (14%) healthy individuals were colour blind on enrolment. Colour blindness was commoner in severe malaria than in healthy individuals ( $p=0.029$ ) but not uncomplicated malaria ( $p=0.09$ ) or sepsis ( $p=0.10$ ). The severity of macular whitening was not associated with presence of colour blindness in patients with malaria (**Figure 2.4-24**).



**Figure 2.4-24. Severity of macular whitening in patients with falciparum malaria with and without colour blindness on enrolment.**

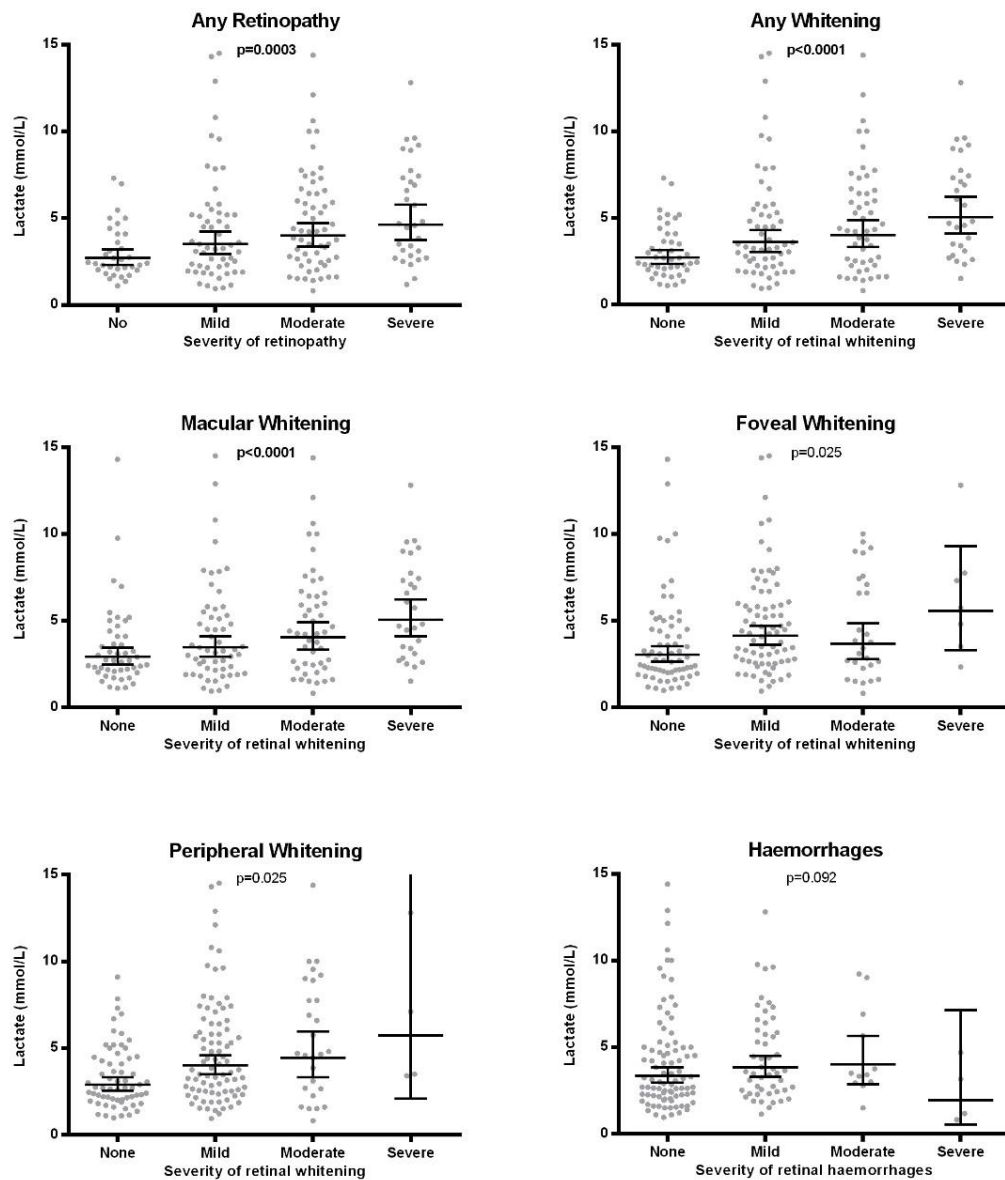
Severity is defined in **Appendix 10.1**.

## 2.4.6 Retinopathy and pathogenesis of severe malaria

### Lactate

In patients with severe malaria, the severity of retinopathy and retinal whitening correlated with plasma lactate (

Figure 2.4-25). This correlation was stronger for macular whitening than for foveal or

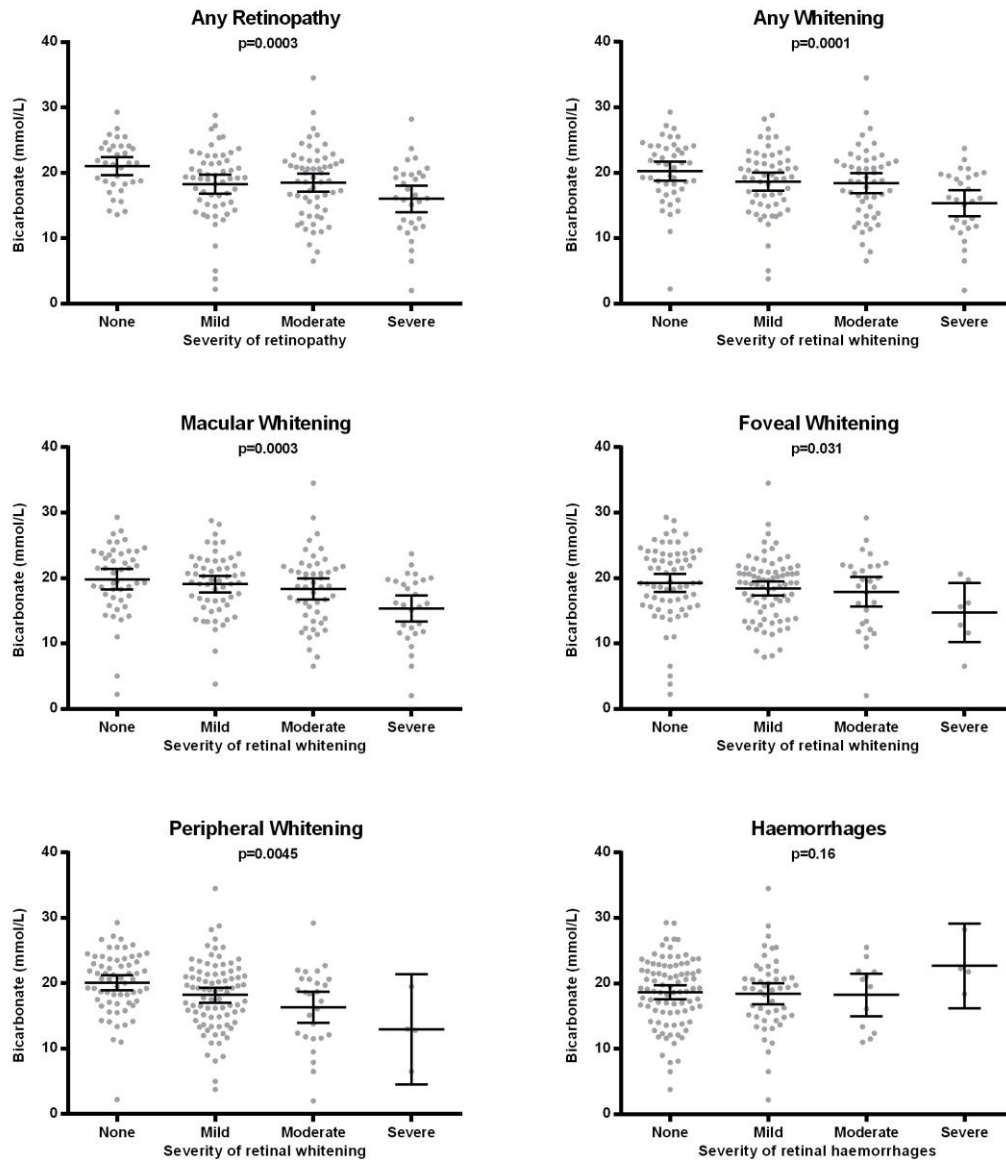


**Figure 2.4-25. Plasma lactate and severity of retinopathy in patients with severe malaria.**

Severity is defined in **Appendix 10.1**. Bars represent geometric mean and 95% confidence interval.

## Bicarbonate

In patients with severe malaria, the severity of retinopathy and retinal whitening correlated negatively with venous plasma bicarbonate (**Figure 2.4-26**). This correlation was strongest for macular whitening.

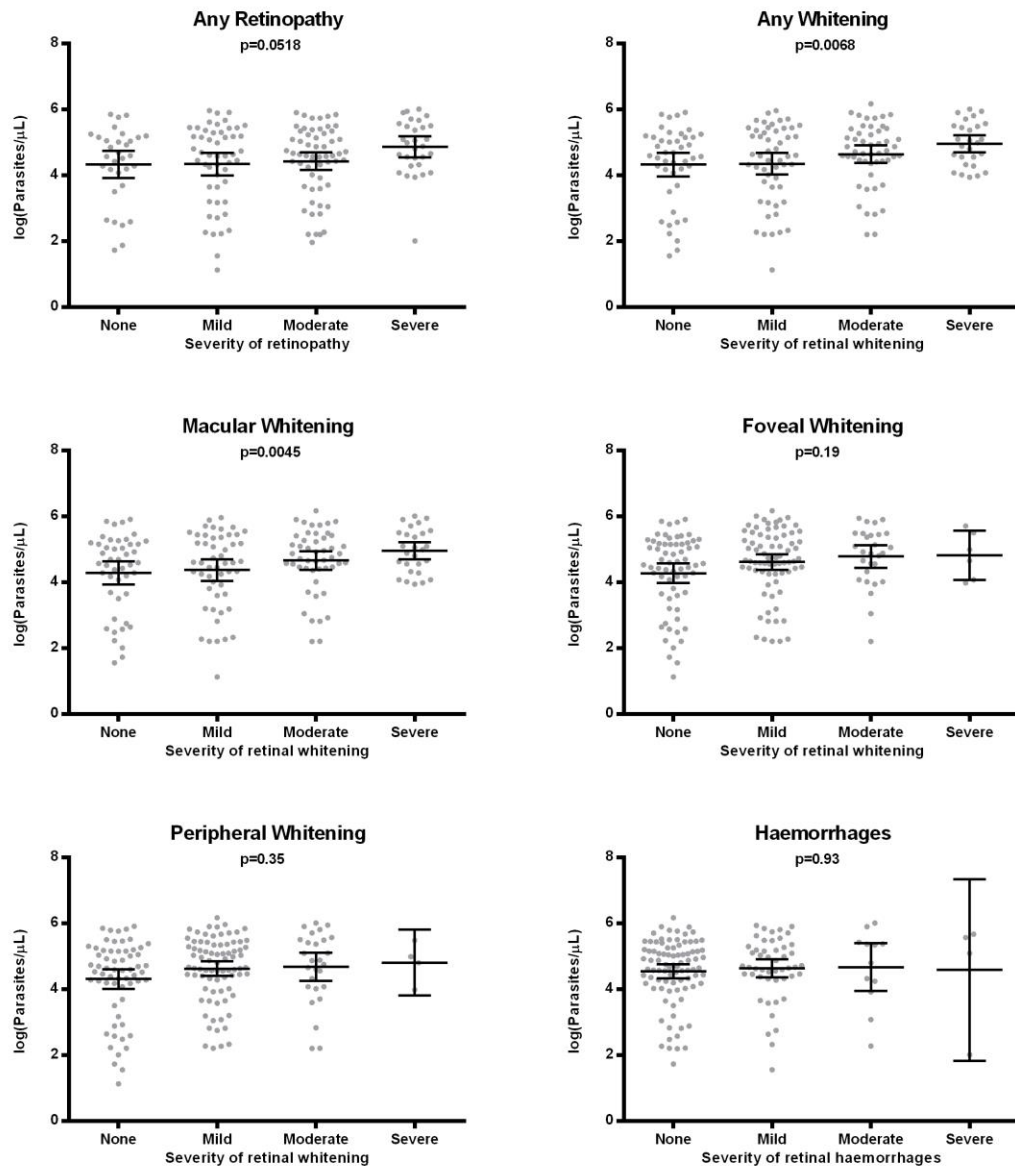


**Figure 2.4-26. Venous plasma bicarbonate and severity of retinopathy in patients with severe malaria.**

Severity is defined in **Appendix 10.1**. Bars represent mean and 95% confidence interval.

### Parasite count

In patients with severe malaria, the severity of retinal whitening correlated with peripheral blood parasite count (**Figure 2.4-27**). This correlation was strongest for macular whitening.

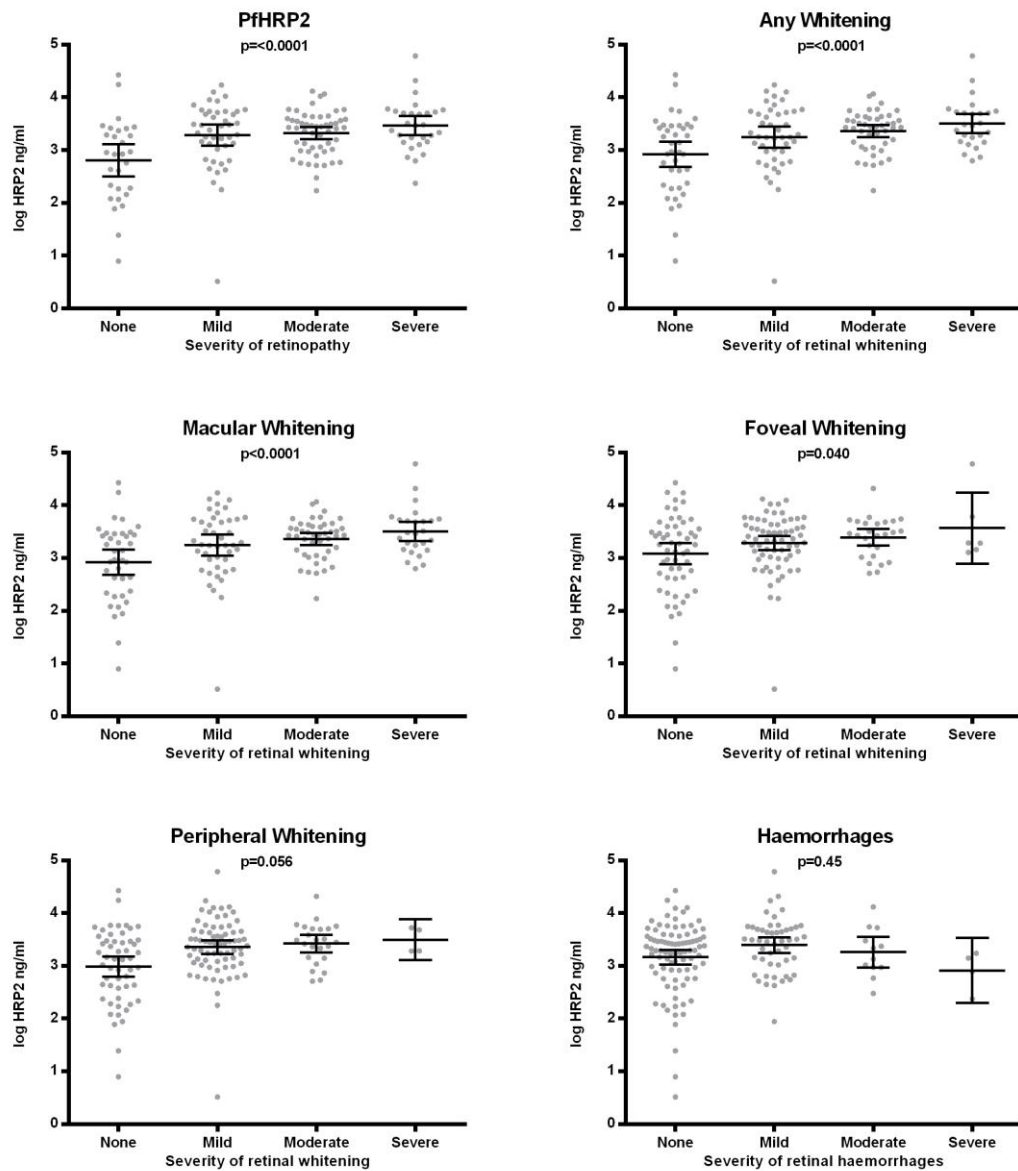


**Figure 2.4-27. Log peripheral blood parasite count and severity of retinopathy in patients with severe malaria.**

Severity is defined in **Appendix 10.1**. Bars represent mean and 95% confidence interval.

### Parasite biomass

In patients with severe malaria, the severity of retinopathy and retinal whitening correlated with  $\log(PfHRP2)$ , a surrogate for parasite biomass (**Figure 2.4-28**). This correlation was strongest for macular whitening.



**Figure 2.4-28. Log *PfHRP2*-derived parasite biomass and severity of retinopathy in patients with severe malaria.**

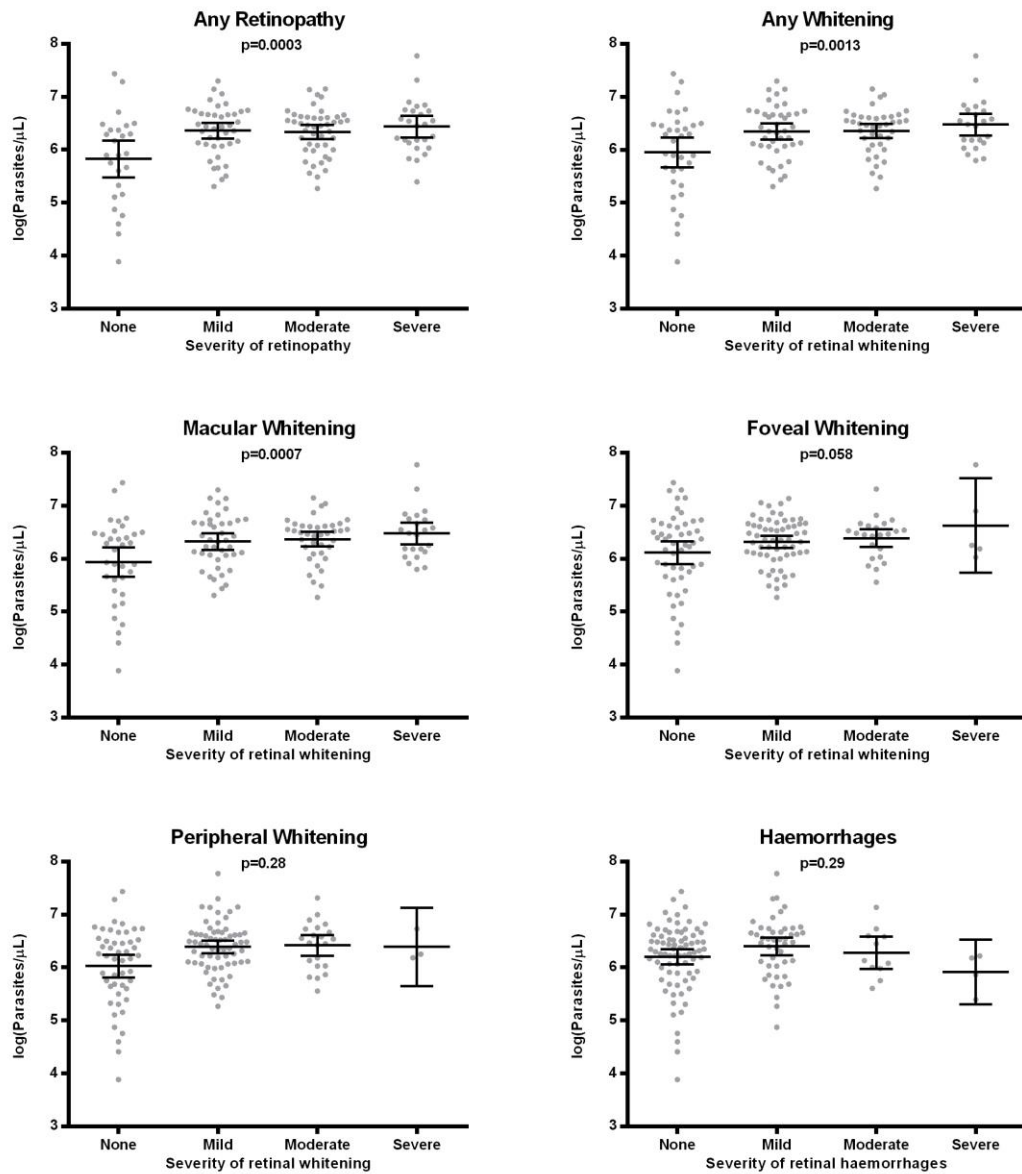
Severity is defined in **Appendix 10.1**. Bars represent mean and 95% confidence interval.

HRP2 = *Plasmodium falciparum* histidine-rich protein 2.



### Sequestered parasite biomass

In patients with severe malaria, the severity of retinopathy and retinal whitening correlated with log (sequestered parasite biomass) (**Figure 2.4-29**). This correlation was strongest for macular whitening.

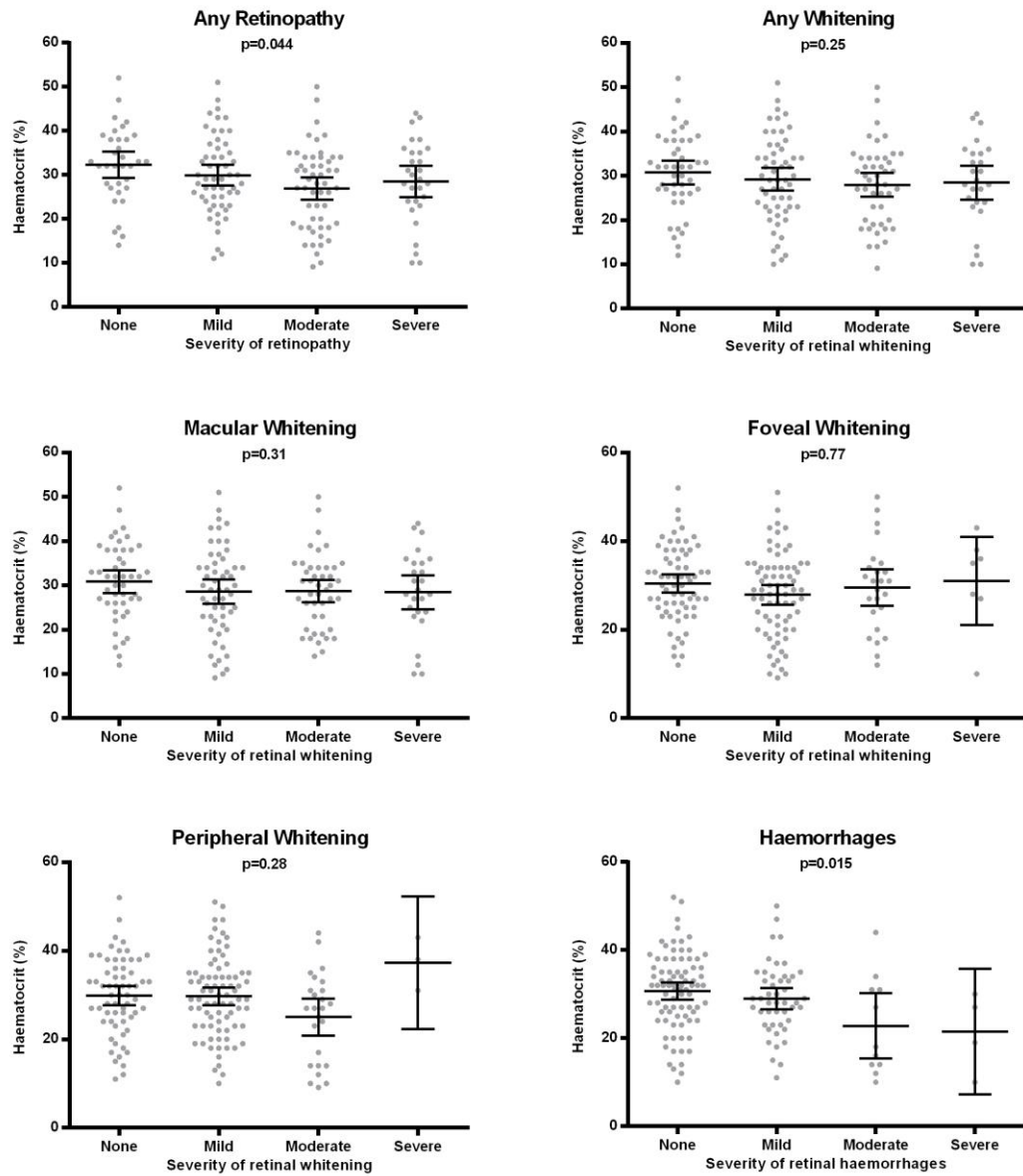


**Figure 2.4-29. Log sequestered parasite biomass and severity of retinopathy in patients with severe malaria.**

Severity is defined in **Appendix 10.1**. Bars represent mean and 95% confidence interval.

## Haematocrit

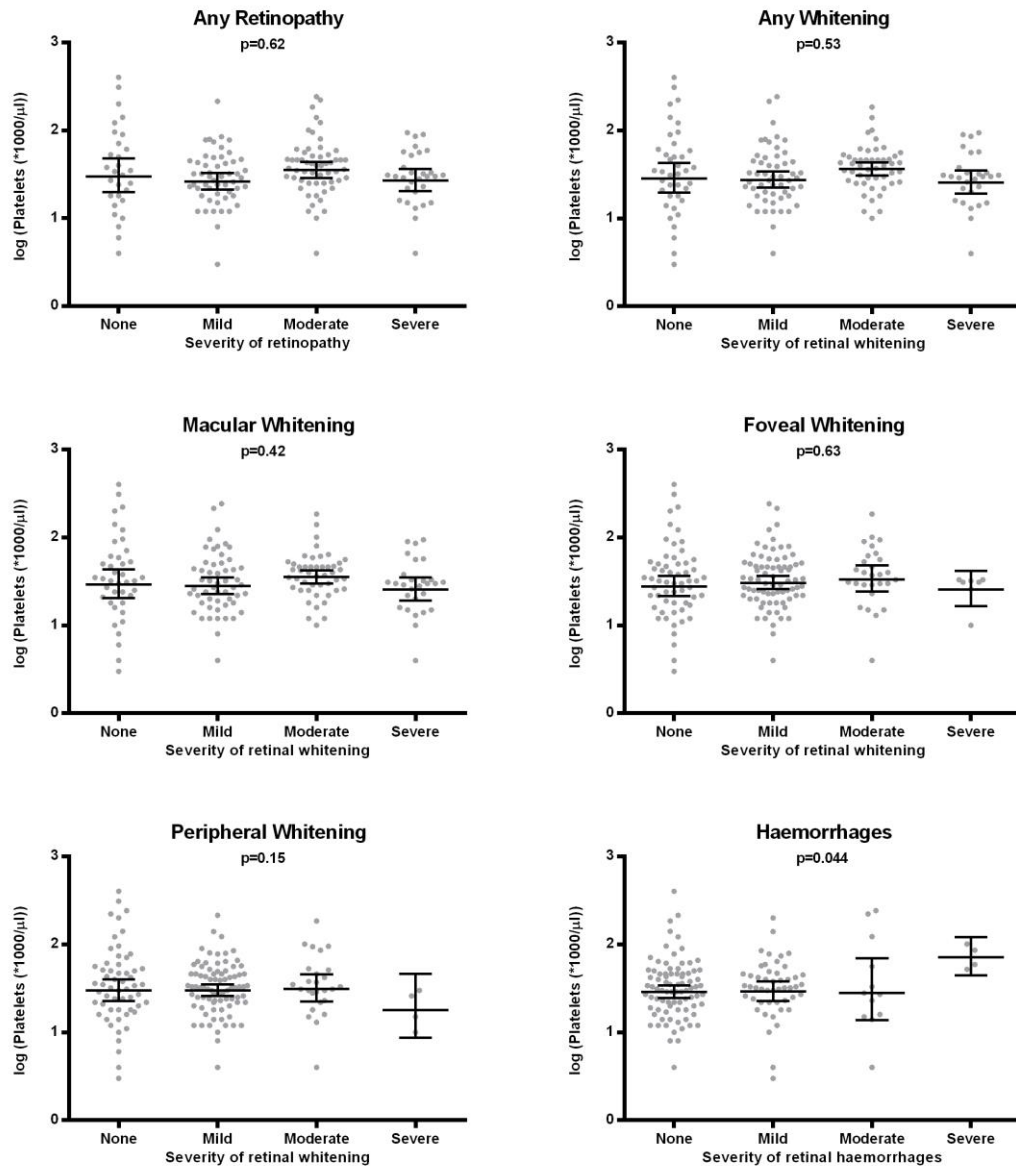
In patients with severe malaria, the severity of retinopathy and retinal haemorrhages correlated negatively with haematocrit (**Figure 2.4-30**). There was no correlation for retinal whitening.



**Figure 2.4-30. Haematocrit and severity of retinopathy in patients with severe malaria.** Severity is defined in **Appendix 10.1**. Bars represent mean and 95% confidence interval.

## Platelets

In patients with severe malaria, there was a weak correlation between the severity of retinal haemorrhages and log(platelet count) (**Figure 2.4-31**). There was no correlation for retinal whitening.



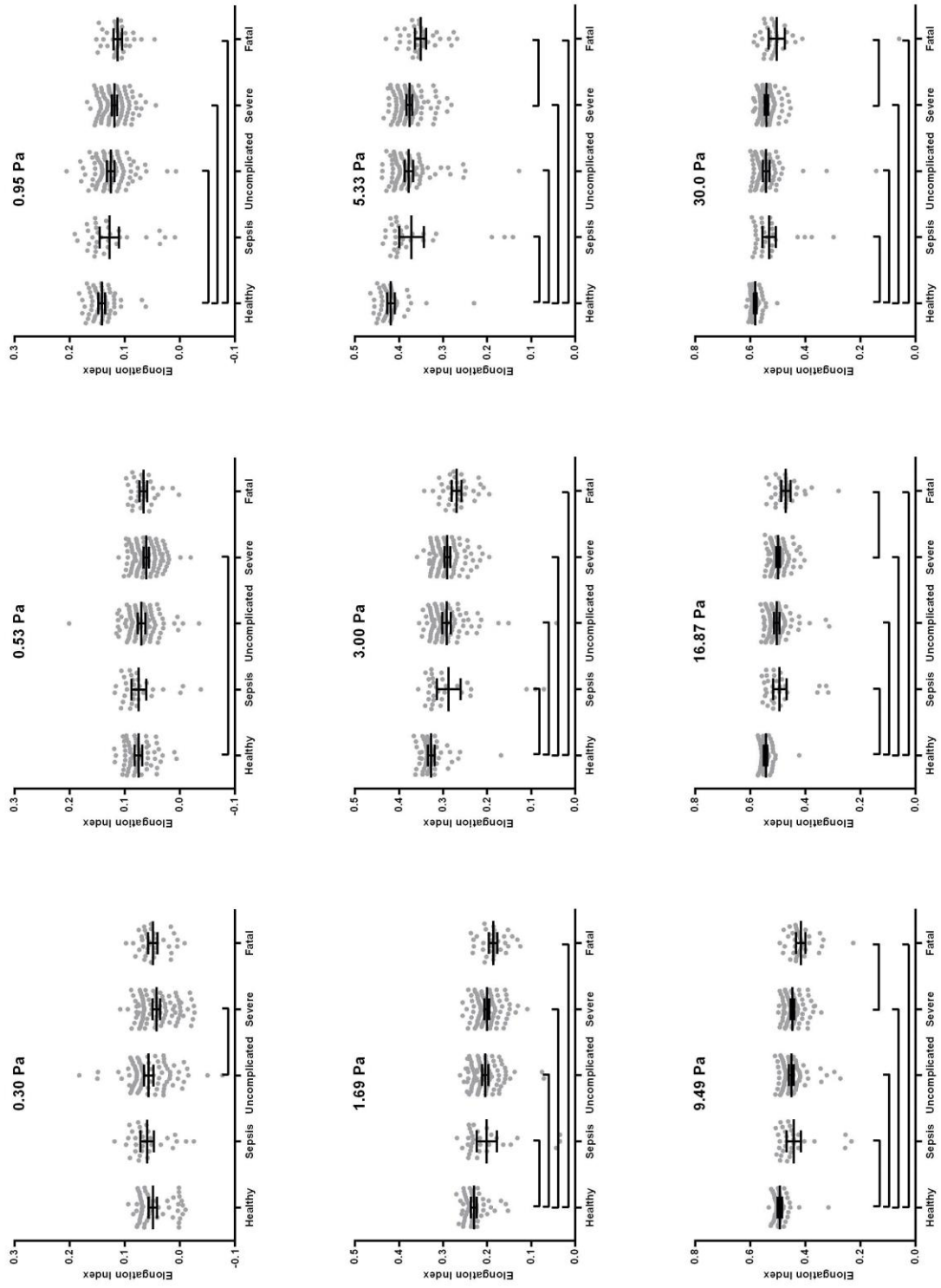
**Figure 2.4-31. Log (platelet count) and severity of retinal whitening in patients with severe malaria.**

Severity is defined in **Appendix 10.1**. Bars represent mean and 95% confidence interval.

**Red cell deformability**

As found in previous studies, red cell deformability decreased with increasing severity of malaria at physiological shear stresses (1.69-30.0 Pa) (**Figure 2.4-32**). The highest deformability was in healthy individuals. Red cell deformability was also decreased in sepsis but to a lesser degree than in severe malaria.

Red cell deformability correlated negatively with severity of retinal whitening at physiological shear stresses. This correlation was strongest for macular whitening and at shear stresses of 3.00 to 30.0 Pa which are equivalent to shear stresses encountered in the human microcirculation in vivo. The results are shown in **Figure 2.4-33**.



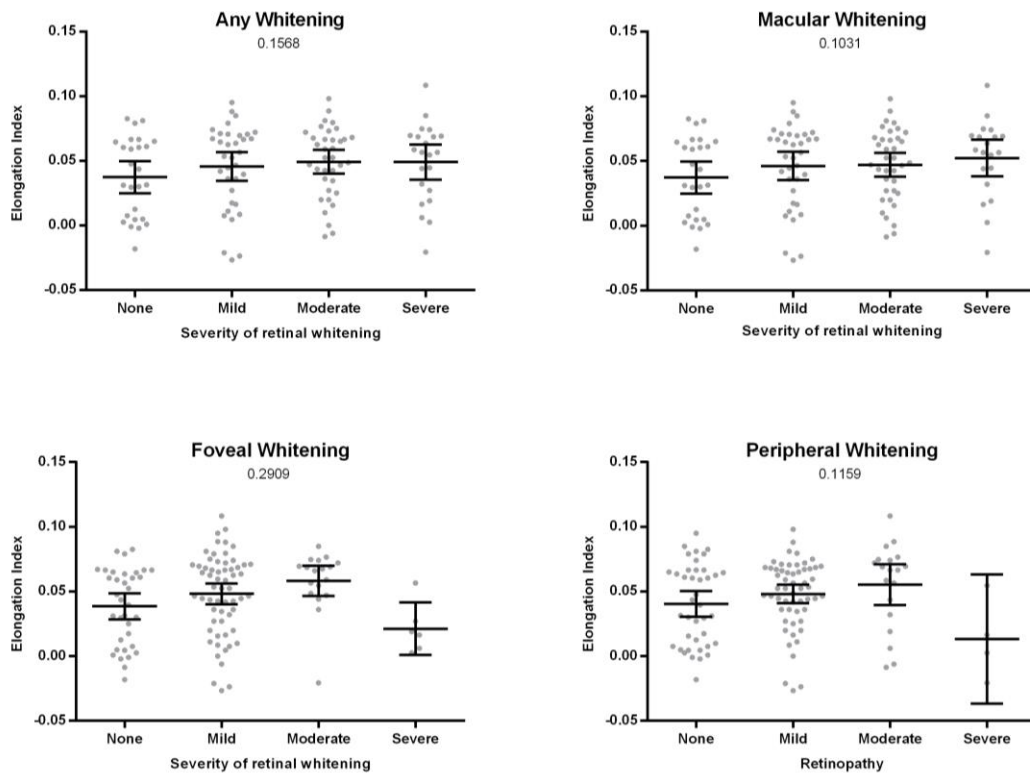
**Figure 2.4-32.**  
**Red cell**  
**deformability**  
**(elongation**  
**index) by**  
**study group.**

Significant differences ( $p < 0.05$ ) between groups are shown as horizontal bars.

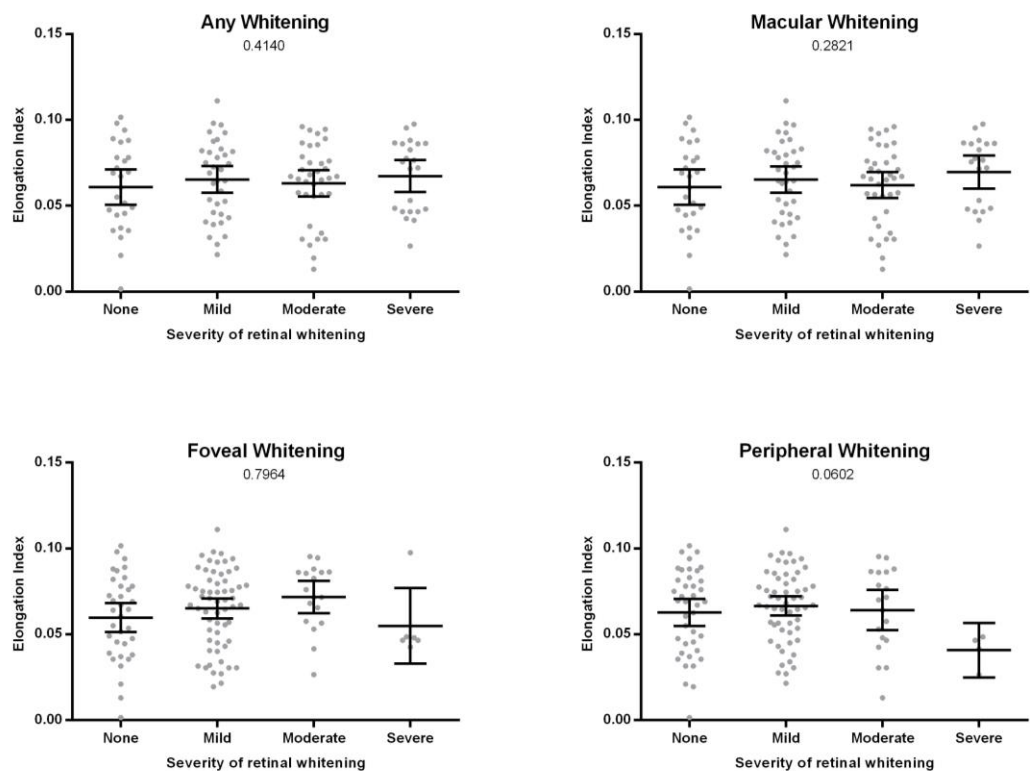
**Figure 2.4-33. Red cell deformability (elongation index) and severity of retinal whitening at different shear stresses (following 5 pages).**

Severity is defined in **Appendix 10.1**.

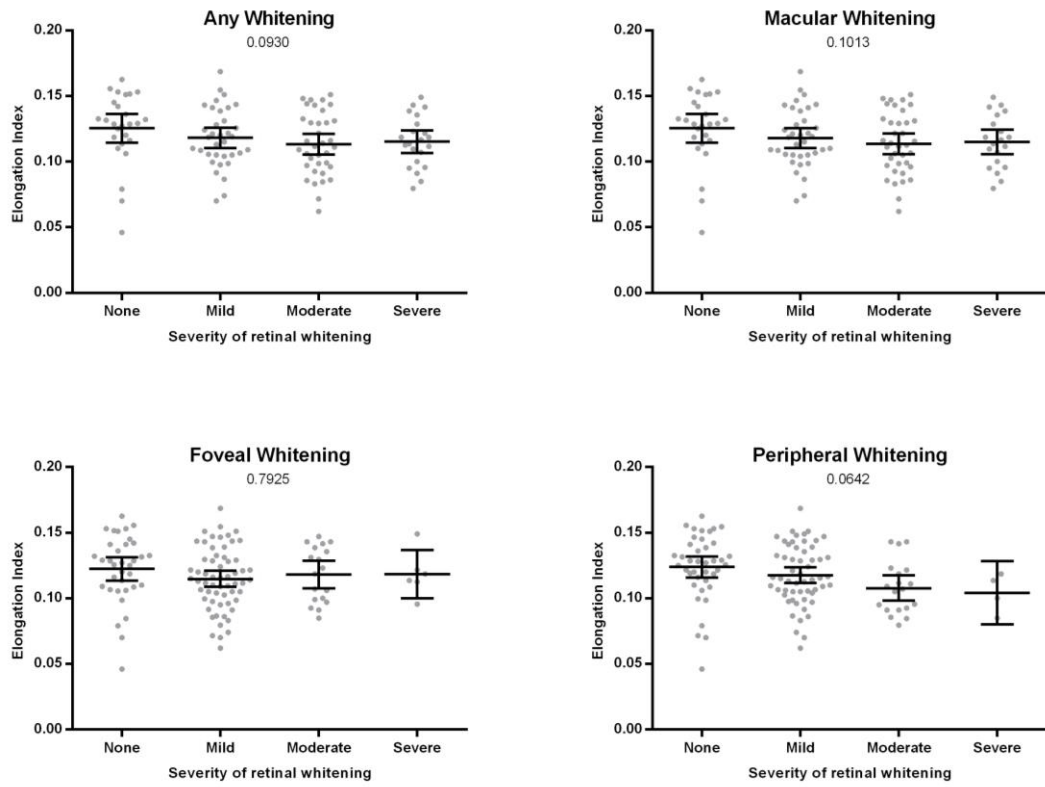
**Shear stress 0.3 Pa**



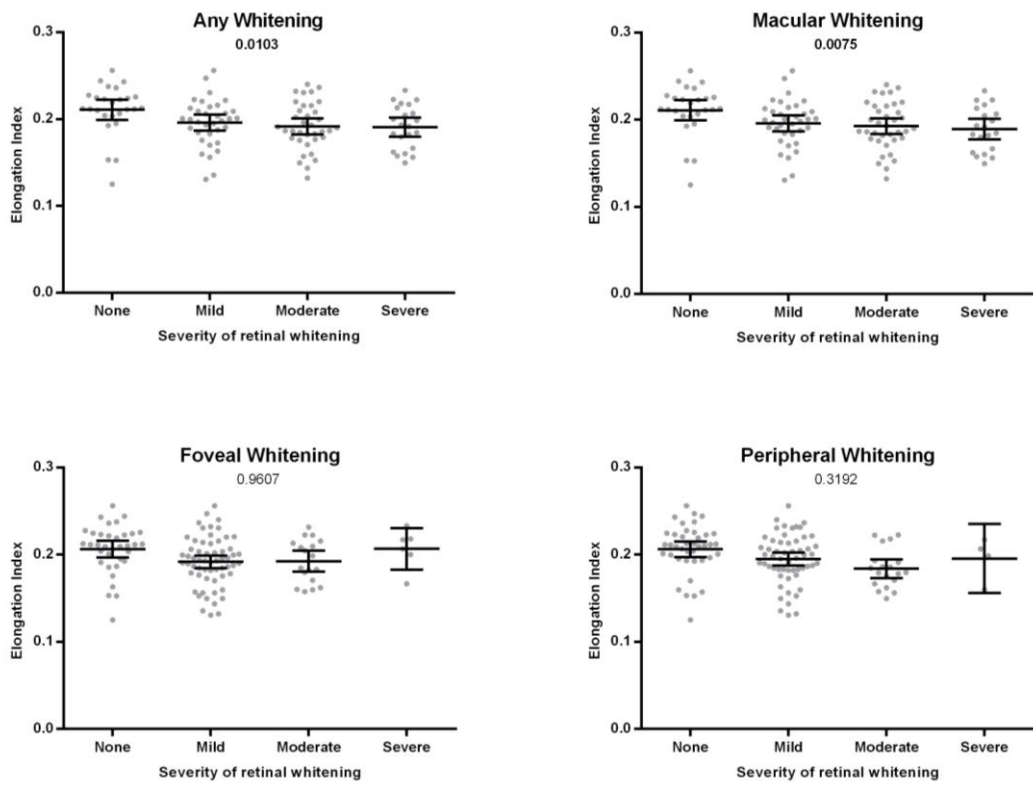
**Shear stress 0.53 Pa**



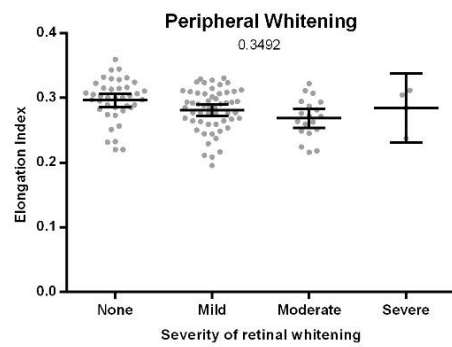
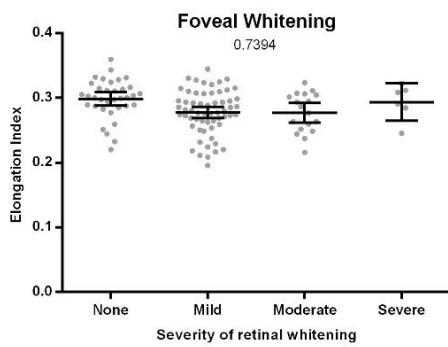
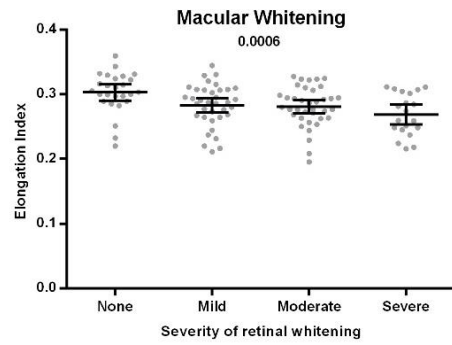
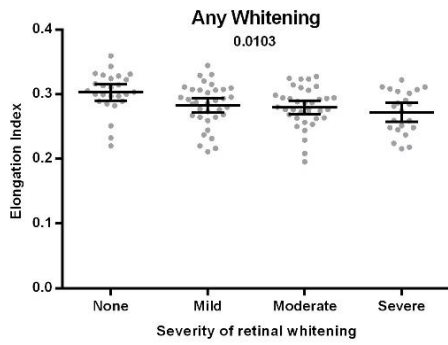
**Shear stress 0.95 Pa**



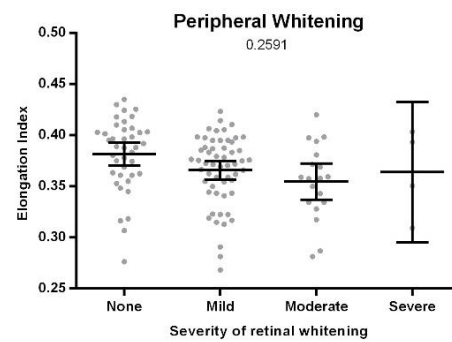
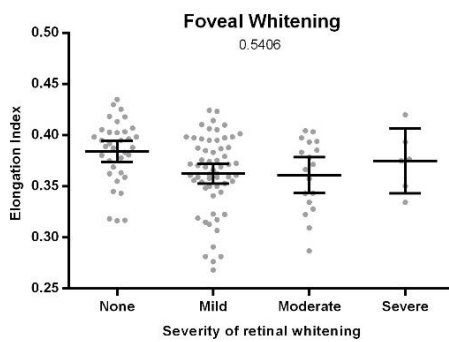
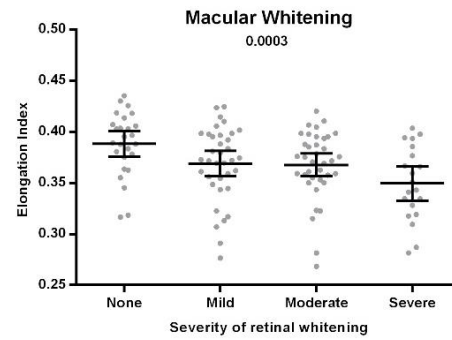
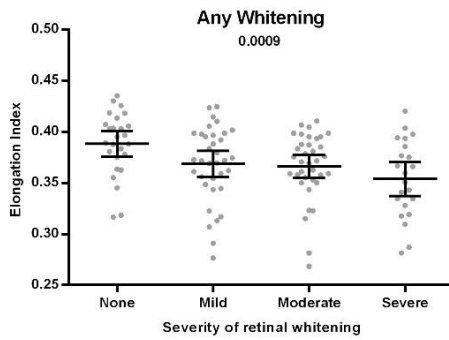
**Shear stress 1.69 Pa**



**Shear stress 3.00 Pa**

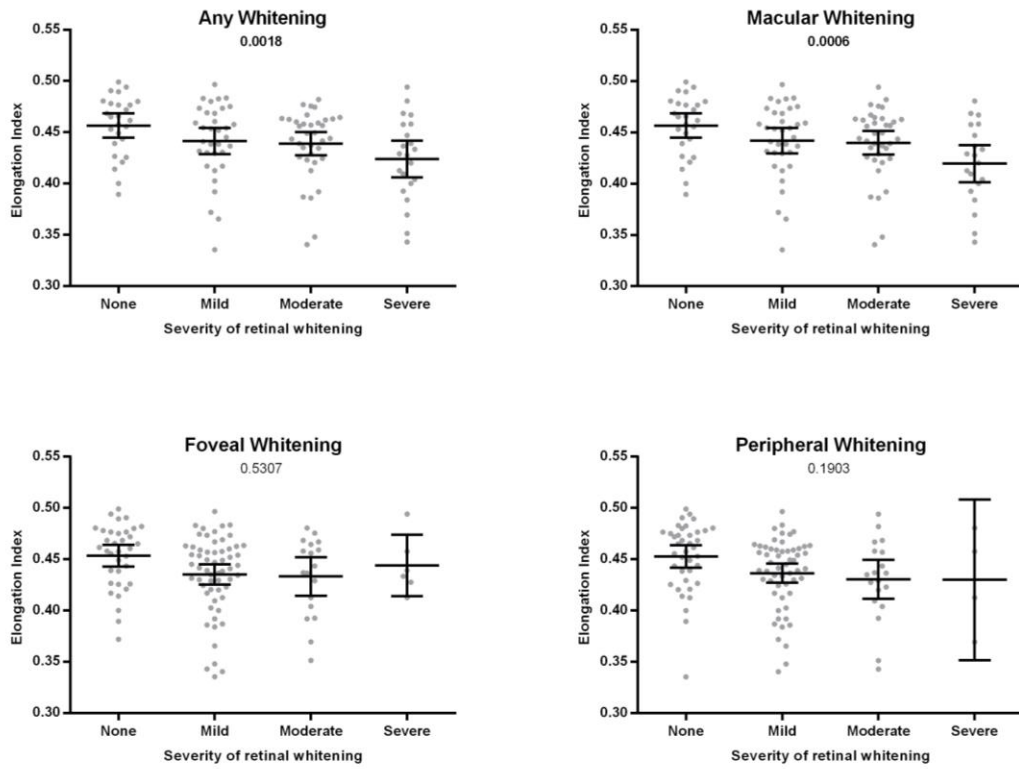


**Shear stress 5.33 Pa**

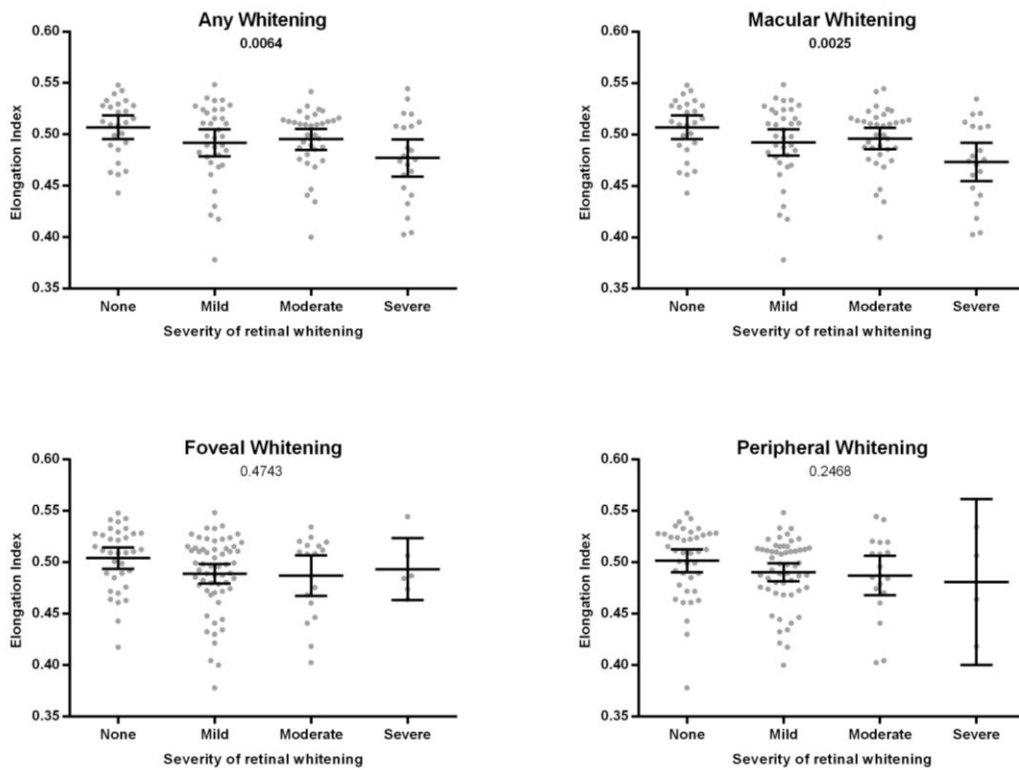




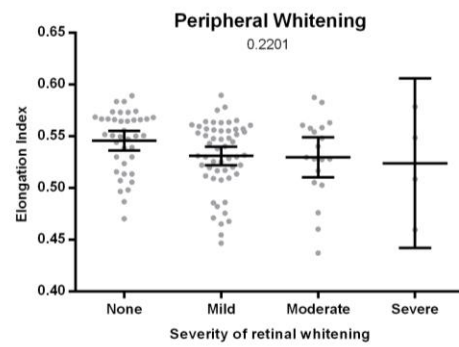
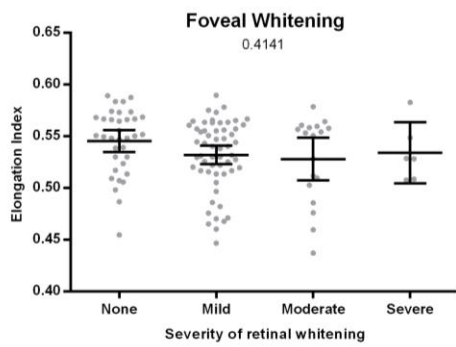
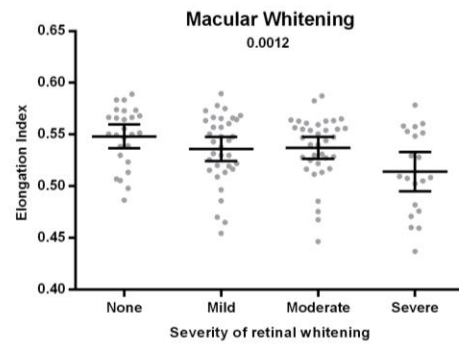
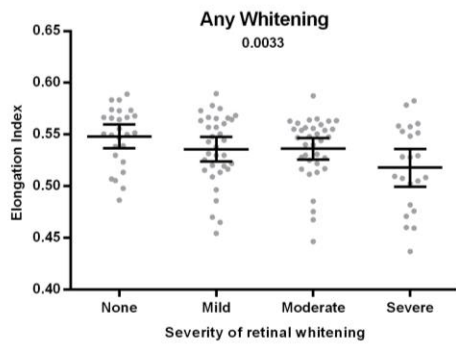
Shear stress 9.49 Pa



Shear stress 16.87 Pa



Shear stress 30.0 Pa

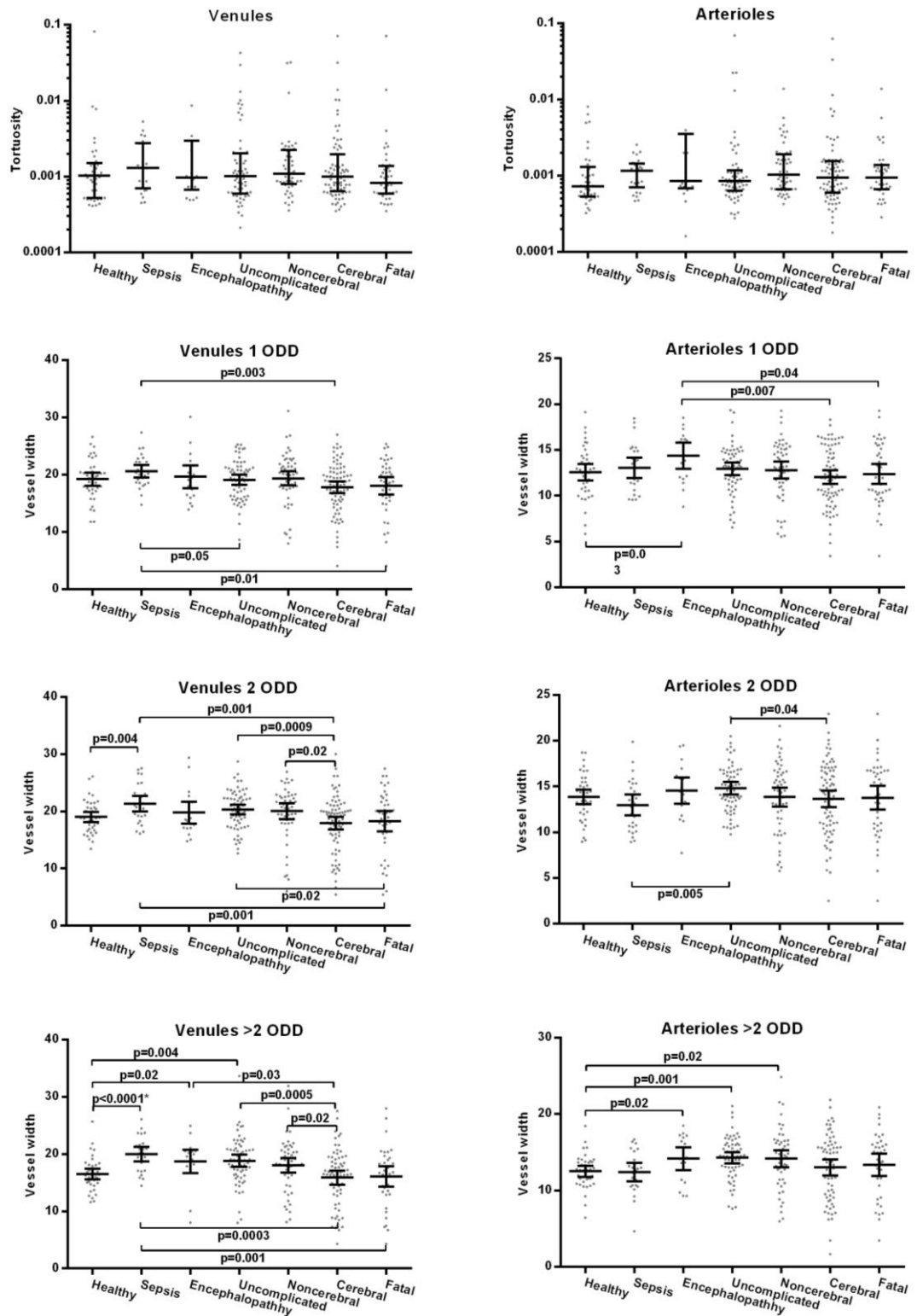


**Retinal Blood vessel tortuosity**

Retinal vessel tortuosity was measured in 283 patients. These comprised 42 with fatal malaria, 79 with cerebral malaria, 55 with noncerebral severe malaria, 64 uncomplicated malaria, 27 sepsis, 19 encephalopathy and 39 healthy. The results are presented in

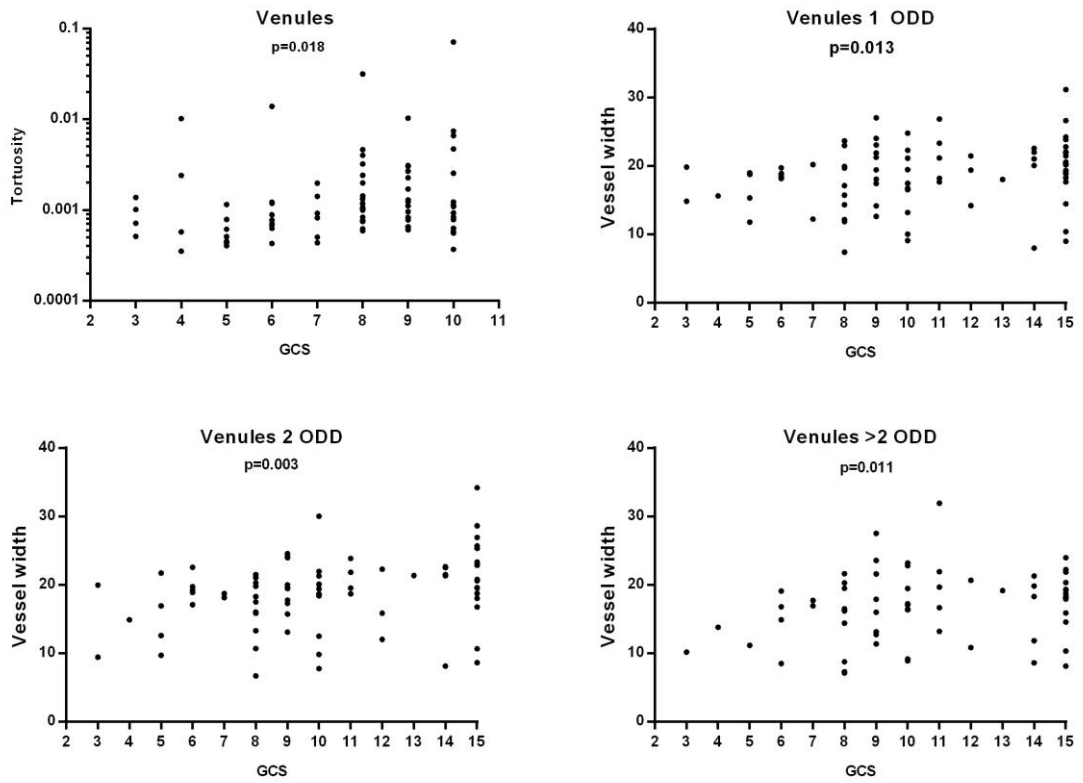
**Figure 2.4-34.** In those with malaria, mean venule widths  $\geq 2$  optic disc diameters (ODD) from the disc decreased with increasing severity of malaria ( $p=0.006$  at 2 ODD and  $p=0.001$  at  $>2$  ODD). There was no such trend for arteriolar width. There was no trend in tortuosity. Mean venule width was lowest in cerebral and fatal malaria but not significantly different from healthy individuals. Venule width was highest in sepsis at all ODDs but arteriolar width was not increased in sepsis. At 2 and  $>2$  disc diameters from the disc, the variances of vessel widths in both venules and arterioles was greater in severe malaria than the other groups. Variance in tortuosity was also greater in malaria than the other groups. There were no differences in vessel width and tortuosity between fatal and nonfatal severe malaria.

In nonfatal severe malaria, mean vessel width correlated positively with enrolment GCS in venules 1, 2 and  $>2$  optic disc diameters from the disc. Tortuosity of venules also correlated positively with GCS (**Figure 2.4-35**).



**Figure 2.4-34. Tortuosity and vessel width in each group of study subjects.**

Median (IQR) is shown by black bars and significant differences between medians are shown as horizontal black lines. \* = difference significant when corrected for multiple comparisons. ODD = optic disc diameter.



**Figure 2.4-35. Tortuosity and vessel width in venules vs GCS.**

OD = optic disc diameter.

## 2.5 Discussion

### 2.5.1 Summary of main findings and implications

This study found that malaria retinopathy in Asian adults and children with *P. falciparum* malaria was commoner and more severe in cerebral (88%) and fatal (91%) disease than in noncerebral severe (71%) or uncomplicated disease (46%). These differences were even more pronounced for moderate-severe retinopathy and retinal whitening. Retinopathy was less common, less severe and of a different pattern in those with sepsis, nonmalarial encephalopathy and healthy individuals. Findings were similar in Asian children and adults, although there were some differences to findings in previous studies of African children. The high prevalence and specificity of retinal changes for *P. falciparum* malaria may give it some utility as a diagnostic marker in severe disease. Although, not an absolute marker, retinal whitening predicted development of coma and death and may have potential utility to help predict prognosis in clinical situations. Correlation with contributors to, and markers of, microcirculatory blood flow obstruction and association of retinal whitening with coma are additional supporting evidence for a central role for microcirculatory obstruction in the pathogenesis of malarial retinopathy and malaria coma. All of these areas will be discussed in detail in the following Sections.

### 2.5.2 Diagnosis

Almost 90% of patients with cerebral malaria in this study had malarial retinopathy. This is a higher proportion that has been shown in previous studies of malaria retinopathy in Indian adults (34%),<sup>244</sup> Bangladeshi adults (41%)<sup>255</sup>, Thai adults and children (14.6%)<sup>245</sup> and African children (Malawi 61%<sup>63</sup>, Ghana 73%<sup>263</sup> and Kenya(77%)<sup>222</sup>). In noncerebral severe malaria, 71% had retinopathy, as compared to 53% in Malawian children<sup>63</sup> and 53% in Ghanaian children.<sup>263</sup> A major factor in the different prevalences found is probably the variation in method used to examine the retina. The present study used retinal photography whereas previous studies used mostly direct and/or indirect ophthalmoscopy. It has been shown previously in a concomitant study in the same population in Bangladesh that retinal photography is more sensitive for detecting retinal changes than direct and indirect ophthalmoscopy. This is particularly true for retinal whitening, the commonest and most specific finding in the present study.<sup>255</sup> Retinal haemorrhages are easier to identify than

retinal whitening<sup>62,224</sup> and retinal vessel changes as they are often in the peripheral retina.<sup>224</sup> Probably for this reason, early studies of malarial retinopathy found low prevalences of retinopathy and focussed mainly on haemorrhages.<sup>245,264,265</sup>

Indirect ophthalmoscopy is more sensitive than direct ophthalmoscopy as it provides a wider field of view and better visualisation of the peripheral retina. However, the equipment is more expensive and it requires more training. When used by an experienced ophthalmologist the sensitivity of direct compared to indirect ophthalmoscopy for malarial retinopathy in the Gambia was 73%, and 37% in those with less training through undilated pupils.<sup>266</sup> In the previous study in Bangladesh,<sup>62</sup> the observers had limited experience of fundoscopy and this may have resulted in the low prevalences of retinopathy found. Direct ophthalmoscopy was less sensitive than indirect. The studies in India<sup>244</sup> used primarily direct ophthalmoscopy but did not state the level of expertise of the examiners. In Malawi<sup>63</sup> and Ghana<sup>263</sup> where higher prevalences of retinopathy were found fundoscopic examination was done by both direct and indirect ophthalmoscopy by experienced ophthalmologists. The studies in Malawi have also found more retinal whitening and vessel changes than those done elsewhere. Inter-observer concordance by expert observers using ophthalmoscopy was high.<sup>224</sup>

There have been no direct comparisons of retinal photography and ophthalmoscopy for detecting malarial retinopathy. A small study in Kenya using portable retinal photography found 77% of those with cerebral malaria to have retinopathy. This study described retinal opacification in 60% of children with severe malaria. This opacification has since been called retinal whitening. In the present study in Asia, retinal whitening was the commonest finding and the sign with the strongest association with cerebral malaria. Of those with cerebral malaria, 52% had retinal haemorrhages whereas 79% had retinal whitening. For malarial retinopathy to have maximum utility as a diagnostic tool it is essential therefore that sufficiently sensitive methods are used to detect it. From the results presented here, portable retinal photography appears to be the best technique for doing so.

Although it has previously been stated that malaria retinopathy is specific for *P. falciparum* malaria<sup>225</sup> it had not been possible to confirm this due to a lack of studies examining the eyes in severely unwell individuals in the tropics without malaria. Although autopsy series in Malawian children have found retinopathy to be 90% sensitive and 85% specific for the typical pathological features of cerebral malaria,<sup>100</sup> it has only been possible to study individuals with fatal disease. The present study took a different approach in recruiting patients with the whole clinical spectrum of falciparum malaria and directly comparing

findings in other severely unwell patients with a similar clinical presentation to malaria in the same population. This reproduced the diagnostic dilemma encountered in clinical settings across the tropics and gives a true indication of the utility of retinopathy as a bedside marker.

In this study, retinal whitening and white-centred haemorrhages were the best discriminators between severe malaria and the other groups, although there was overlap in retinal findings between all the groups and malarial retinopathy was not an absolute marker for malaria.

Moderate-severe retinal whitening, however, was highly specific for malaria with high sensitivity for malaria in patients with coma. White centred haemorrhages were found only in malaria and sepsis and were much commoner in malaria. When both eyes were examined malarial retinopathy as a whole was a much better discriminator between patients with severe malaria and severely unwell patients without malaria. Almost all patients with severe malaria had bilateral changes whereas most of those without malaria did not. This has potential to assist with diagnosis in resource-limited clinical settings in that if a patient has malarial retinopathy (retinal whitening and/or white-centred haemorrhages, particularly with bilateral changes) and coma then their coma is highly likely to be due to malaria. Conversely if a patient with coma does not have malarial retinopathy it is *unlikely* their coma is due to malaria. Papilloedema was a poor discriminator between cerebral malaria and nonmalarial encephalopathy, being present in both but more frequent in encephalopathy.

These findings are in broad agreement with post mortem studies in African children which found that 23% of children with clinical cerebral malaria had another diagnosis, based on a lack of cerebral histopathological features on post mortem, and the presence of malarial retinopathy on indirect ophthalmoscopy was the only clinical feature which distinguished between these two groups.<sup>100</sup> In high transmission settings, incidental parasitaemia is common due to accumulated antidisease immunity and diagnosis of severe malaria requires exclusion of other potential causes of disease. This can be challenging in resource-poor settings where the capacity for diagnostic tests is limited and expensive investigations, for example CT and MRI, are often unavailable. In these settings, the presence or absence of retinopathy has a potential role in the diagnosis of cerebral malaria.<sup>225</sup> In Malawian children, patchy retinal whitening and focal changes of vessel colour were the most specific for cerebral malaria, more so than white-centred retinal haemorrhages which were also common.<sup>267</sup> It has been argued that these components of malaria retinopathy should be used as a diagnostic test as their presence increases the likelihood of a correct diagnosis of cerebral malaria.<sup>225</sup> It has also been proposed as a marker with which to divide patients into groups with different underlying pathophysiology for research studies on cerebral malaria.<sup>268</sup>



In low transmission settings including India and Bangladesh it has generally been assumed that the presence of *P. falciparum* parasites in the peripheral blood plus symptoms consistent with severe malaria is sufficient for a diagnosis. This is because there is very little antidiisease immunity in the population. If this were true, the contribution of retinopathy to diagnosis would be limited in low transmission settings in places where malaria microscopy or rapid tests can be performed rapidly and with sufficient quality. If a patient were negative for malaria in the peripheral blood, then it would be assumed that they have an alternative diagnosis which would prompt further investigation and treatment. However misdiagnosis of malaria is common and retinopathy may still be of assistance in these cases. There are a variety of contributors to misdiagnosis of malaria. Clinicians frequently make diagnoses without arranging confirmatory diagnostic tests<sup>269</sup> and where tests do occur, false positive and false negative results can occur by either microscopy<sup>226</sup> or RDT<sup>270</sup> leading to clinicians distrusting and ignoring the results.<sup>226,271</sup> This is exacerbated by previous guidelines for management of malaria having included syndromic management and, although now frowned upon, this practice remains widespread.<sup>272</sup> Additionally, *Plasmodium* species are frequently incorrectly identified on microscopy sometimes leading to the wrong treatment.<sup>25,273</sup> The malaria microscopy in the present study was performed in idealised research settings by expert microscopists thus misdiagnosis should have been avoided. This is very different to the everyday situation in many hospitals across the tropics where the workload is high, conditions are often not ideal and misdiagnoses common. The results of this study indicate that finding malarial retinopathy in a severely unwell patient increases the likelihood that they have falciparum malaria. Also finding moderate-severe retinopathy in patients with confirmed falciparum infection suggests an increased risk of severe disease and death. This may be of assistance in the early management and triage of severely unwell patients in resource-limited settings. However, there remains considerable uncertainty due to the overlap in retinal findings with patients with sepsis and encephalopathy and the results here do not justify the use of retinopathy in isolation to guide patient management.

Where blood tests for malaria are not readily available or the results delayed, this study also suggests detection of moderate-severe retinal whitening and/or white-centred haemorrhages in a comatose adult patient could help as part of a package of assessment tools to guide initial patient management. Although any patient with suspected severe malaria should receive intravenous artesunate urgently,<sup>13</sup> detection of malaria retinopathy should reduce any doubt about its necessity. Comatose patients with malaria retinopathy could also be prioritised for management in intensive care and should be promptly investigated for the

other features of severe malaria, particularly treatable features including severe anaemia (requiring blood transfusion) and acute renal failure (requiring prompt dialysis) to optimise outcome.<sup>13</sup> Additionally, finding malaria retinopathy in a comatose patient may assist with difficult decisions of how to spend limited resources. For example, a patient's relatives could be reassured that a CT scan, MRI scan or lumbar puncture are unlikely to alter management in a patient with moderate-severe malaria retinopathy and this expense may be avoided.

An observational study of 32 Malawian children with suspected cerebral malaria but no retinopathy, found a stereotypical pattern of short illness with rapid deterioration in mental state, mostly normal laboratory tests, rapid recovery and low mortality.<sup>228</sup> Two main explanations were postulated: incidental parasitaemia and another cause of illness or a modulated host response due to different genetic susceptibility, altered immune response or coinfection. In Asian patients in the present study, patients with retinopathy had a higher mortality, were more likely to have coma, hyperlactaemia and/or acidosis and had a higher parasite biomass than those without retinopathy. White cell count was mostly normal in this group suggesting sepsis was not a major contributor to their illness. There were no differences in the other features of severe malaria. The same explanations as postulated in Malawi may apply. An alternative explanation is that the retinopathy reflects a spectrum of degrees of sequestration in the central nervous system vasculature and the amount or pattern of sequestration in individuals with coma but no retinopathy differs between the retina and the brain sufficient to cause coma in the brain but not retinopathy in the eye. Further studies are needed to explore this.

The traditional view that parasites in the peripheral blood plus an appropriate clinical picture equals severe malaria in low transmission settings is being challenged by recent evidence. A growing set of studies have shown asymptomatic parasitaemia to be common in low transmission settings including Bangladesh.<sup>274,275</sup> The implication of this is that some individuals with parasitaemia and symptoms will have asymptomatic parasitaemia and another cause for their symptoms other than malaria. Most of these asymptomatic infections are not detectable by routine microscopy or rapid diagnostic tests<sup>276</sup> and the traditional view still applies to the majority of parasitaemic patients. In this study, around 10% of adult patients with fatal or cerebral malaria did not have retinopathy. Further studies will be needed to establish if these patients have asymptomatic parasitaemia and another diagnosis, similar to the 23% of African children described above.<sup>100</sup> If this were the case, malarial retinopathy would have a more important role in confirming the diagnosis of cerebral malaria in low transmission settings.

A postulate limitation to the routine use of malarial retinopathy as a bedside tool to aid diagnosis is the need to dilate pupils for fundal examination and photography. As discussed in the **Methods** section, this temporarily prevents the monitoring of pupil size and reactivity which are commonly used in comatose patients to detect early false localising signs of raised intracranial pressure. However, this is likely to be of limited value in cerebral malaria where uncal herniation is not seen and, as for other causes of medical coma, pupillary dilatation is likely to be a late event accompanied by other signs of brainstem dysfunction.<sup>220</sup>

### 2.5.3 Prognosis

In this study, the presence of malarial retinopathy on enrolment predicted death in patients with severe malaria with a RR of 2.3. This predictive capacity was confined to those with noncerebral severe malaria in whom retinopathy on enrolment also predicted later development of coma. Additionally, retinopathy predicted death in the group who later developed coma with a RR of 2.7. In those with cerebral malaria, severity of retinopathy and mortality were not associated. From these findings, malaria retinopathy has potential prognostic utility in predicting death and development of coma in noncerebral severe malaria but not in cerebral malaria. However, as above, there was overlap with findings in patients with non-cerebral severe and uncomplicated disease thus retinopathy should not be used in isolation to determine patient management. One possibility is that retinopathy could form part of a predictive scoring system with other prognostic factors. Further analyses would be required to investigate this.

In Malawian children, in contrast, retinopathy predicted death in cerebral falciparum malaria, specifically papilloedema and the number of haemorrhages were independent predictors of death.<sup>63</sup> In the present study, retinal whitening predicted death and development of coma whereas papilloedema and haemorrhages were not associated. Median time to death in fatal infections who developed coma after enrolment was almost 5 days, thus giving a potential therapeutic time window for a putative future adjunctive therapy to take effect. However, many of those with nonfatal infections also had retinopathy indicating that a trial of such interventions would need to be large to detect a therapeutic effect. This overlap in findings between groups also resulted in relatively small relative risks, probably indicating a spectrum of disease, retinal changes and cerebral sequestration.

There have been no previous studies on retinopathy as a predictor of death or development of coma in noncerebral severe malaria. There are few data of any kind on retinopathy in African children with noncerebral severe falciparum malaria, partly due to the difficulty of eye examination and retinal photography in conscious patients.<sup>277</sup> In Malawi, one study included 47 patients with severe malarial anaemia, the primary manifestation of noncerebral severe falciparum malaria. Only two of these died thus preventing assessment of the prognostic value of retinopathy in this group.<sup>63</sup> Fourteen Kenyan children with noncerebral severe falciparum malaria were included in another study but it was not reported if they died.<sup>222</sup> In Ghana, 32 children with noncerebral severe malaria were examined for retinopathy but none died.<sup>263</sup> In adult cerebral malaria in India, optic disc pallor has previously been shown to be commoner in those who died.<sup>243</sup> Moderate to severe retinopathy on direct and indirect ophthalmoscopy were independently predictive of death in our previous study in Bangladeshi adults where most of the changes seen were retinal haemorrhages.<sup>62</sup> In that study, the proportion of patients with fatal disease which had retinal haemorrhages (86%) was much higher than has been seen elsewhere, including the present study (52%).

The findings in the present study thus differed significantly from previous studies which found retinopathy to be predictive of mortality in cerebral malaria. In Nigerian children with cerebral malaria, retinal haemorrhages predicted mortality whereas papilloedema did not;<sup>278</sup> in Mali exudates, papilloedema and cotton wool spots were associated with death;<sup>279</sup> and in Malawi, papilloedema conferred the highest risk of death and haemorrhages were also independently associated.<sup>63</sup> There are several possible reasons for this difference with the current study. One is that the retinal photographs in this study were read at a later date, thus the reporting was masked as to the clinical status of the patient. This blinding was not complete as the same person who took the photographs also reported them thus may have been able to remember some retinal appearances. Previous studies have used ophthalmoscopy with the disadvantage that the examiner can see how unwell the patient at the time they perform the examination and this may bias the assessment of severity of retinal findings. Another possible explanation is that there could be different pathogenic processes predominating in fatal malaria in African children and Asian adults and children. In African children, brain swelling appears to be more prominent than in adults and is associated with death,<sup>176</sup> unlike in adults.<sup>242</sup> This would explain papilloedema being predictive of death in African children but not in Asian adults. Retinal whitening was the predominant sign found in the present study and, as in African children, this was not independently predictive of

death.<sup>63</sup> It may be that retinal whitening is a result of the same pathogenic process which causes coma but additional factors are required for death to occur. Why retinal haemorrhages are predictive of death in African children but not in the present study is unclear. It has been shown in Malawi that an increase in the number of haemorrhages on serial examination is associated with increased mortality<sup>63</sup> and the number of retinal haemorrhages correlates with the number of brain haemorrhages in fatal cerebral malaria.<sup>235</sup> This phenomenon of increasing retinal haemorrhages was not observed in the present study (results currently being analysed) and although brain haemorrhages occur in adults,<sup>68,280</sup> it is not known how these relate to retinal haemorrhages. It may be that in African children haemorrhages are reflective of a different final common pathway from that in adults that includes papilloedema.

#### **2.5.4 Visual function**

Visual acuity in *falciparum* malaria was worse in those with more severe macular whitening. Mechanistically, this makes sense in that macular whitening was centred on and in most cases involved the fovea, the part of the retina primarily responsible for acuity. It is not clear from these results if worse visual function in severe malaria was a non-specific effect of severe illness or whether it was a consequence of the specific changes in the retina found in malaria. Median acuity was worse in severe malaria than uncomplicated malaria or sepsis, however median acuity in severe malaria was not different to healthy controls. Acuity in healthy controls was also not different from those with uncomplicated malaria or sepsis. In healthy controls, the range of visual acuities was broad and consistent with underlying eye disease in the general population. The similarity of median visual acuity between healthy individuals and all the other groups suggests that the differences for those with severe malaria may be of marginal clinical significance. Colour blindness was commoner in severe malaria than in healthy individuals but was not different from uncomplicated malaria or sepsis. There was no association between macular whitening and colour vision loss. Assessing visual function in severe malaria is not straightforward and it is difficult to assess the impact of retinopathy in visual function in a study of this type. The tests used were relatively crude which may introduce errors into the measurement. Another challenge is that visual function cannot be assessed on enrolment in comatose patients who tend to have the worst retinopathy. Instead it can only be first assessed once a patient reawakens on follow-

up. No data from comatose patients were included in the analyses presented here although many were later followed up and reassessed frequently along with follow-up retinal photographs. These data are yet to be analysed. In addition, patients were asked about visual symptoms in the two weeks prior to admission and relatively few reported any. This suggests perhaps that any associated retinal changes may have occurred late or very acutely. The only other study assessing the effect of retinopathy on visual function was a 1-month follow-up study of Malawian children with severe malaria. In this, there was no evidence of malarial retinopathy affecting visual acuity and no association of visual acuity with whitening.<sup>252</sup> Visual acuity on admission and other components of visual function were not assessed in that study.

### 2.5.5 Adults versus children

This study recruited patients of all ages and thus allowed direct comparison of findings in adults and children. Although the number of children was smaller, overall findings in patients of all ages were very similar with roughly the same proportions of those with fatal, cerebral and noncerebral severe malaria having retinopathy and the retinopathy comprising the same set of features. The small number of children precluded correlation of retinal changes with outcome. There has previously been much discussion about differences in the pathogenesis and presentation of severe malaria between children and adults. Many of these differences have been alluded to elsewhere in this thesis including more frequent multi-organ failure and higher mortality in adults and more frequent and severe cerebral oedema in children. These comparisons have been hampered by a lack of data from children in low transmission settings and adults from high transmission settings relying predominantly on comparing Asian adults with African children. The findings of the present study suggest the differences may be between Africa and Asia rather than between age groups although further studies in Asian children and African adults will be required to confirm this.

There has been a single publication describing African adults with malaria retinopathy. Of three patients with cerebral malaria, one had macular whitening, another macular and peripheral whitening with two blot haemorrhages and the third papilloedema plus a flame-shaped haemorrhage. Two adult patients with noncerebral severe malaria had only retinal haemorrhages. None had retinal vessel discolouration.<sup>281</sup>

Overall, the prevalence and spectrum of ocular fundus findings in Asian adults and children in this study was similar to those found previously in African children but there were some notable differences. As discussed above, the prevalences of retinopathy seen in the present study were higher than those seen elsewhere and this is probably due to retinal photography being more sensitive than ophthalmoscopy for these changes. In common with Malawian children, retinopathy was commonest in cerebral and fatal malaria with retinal whitening being the commonest and most specific finding. Of all the retinal changes seen, moderate-severe macular retinal whitening was most strongly associated with coma and death in the present study. In African children, macular whitening was similarly associated with coma but haemorrhages and papilloedema were the most strongly associated with death.<sup>63</sup>

Unlike in African children, papilloedema was rare in the present study and retinal vessel discolouration was not seen in adults or in children. As discussed above, the difference in prevalence of papilloedema probably reflects a difference in the frequency and severity of brain swelling in Malawian children compared to Asian adults. The prevalence of brain swelling in Asian children is not known. Papilloedema was seen in only two (1%) patients with severe malaria in this study and neither were children. In African children, 24% had papilloedema on indirect ophthalmoscopy.<sup>249</sup> Retinal photography can under-estimate the severity and miss mild papilloedema compared to indirect ophthalmoscopy because it visualises the retina in two dimensions whereas indirect ophthalmoscopy allows visualisation of a protruding optic nerve head. Many patients also underwent indirect ophthalmoscopy in this study but no additional papilloedema was seen. Previous studies have shown swelling of the brain to be commoner and more severe in cerebral malaria in African children than in Asian adults. **Chapter 3** of this thesis presents additional evidence for this from ultrasonographic measurement of the optic nerve sheath diameter. In **Chapter 5**, using MRI of the brain it is demonstrated that there is a lower frequency and severity of brain swelling in adults with severe malaria than seen in similar studies in African children and where brain swelling is present in adults, this is not associated with coma or death, as shown previously on histopathology and CT.<sup>181,242</sup>

By capturing the peripheral retina and allowing prolonged and repeated examination of retinal images, retinal photography should be highly sensitive for detecting retinal vessel changes. Indeed this was found to be the case in Malawian children and multiple example retinal photographs have been published.<sup>63,219,220,234</sup> Although the sensitivity of retinal photography for malarial retinopathy has not been formally examined, in Malawi, retinal

vessel colour changes have been reported as clearly visible on retinal photographs including in images captures by the author of this thesis.<sup>282</sup> As in the present study, vessel discolouration has not been reported in the other studies of malarial retinopathy in Asia,<sup>62,182,244</sup> although use of ophthalmoscopy may have limited the sensitivity of these studies as these changes are often in the peripheral retina and can be difficult to see.<sup>224,277</sup> The quality of retinal photographs in the current thesis was mostly very high, included the peripheral retina and the absence of retinal vessel colour changes therefore is likely to be real.

The lack of blood vessel discolouration in patients of any age in the present study warrants further exploration. Retinal vessel whitening (sometimes yellow/orange) is a common finding in African children with cerebral malaria (32% in one study<sup>63</sup>) and is thought to be due to obstructed capillaries and venules filled with sequestered parasitized red cells in which much of the haemoglobin has been metabolised by the parasite. On post-mortem studies, vessels packed with dehaemoglobinised red cells have been demonstrated histopathologically although discoloured vessels have not been specifically examined.<sup>234</sup> In African children, retinal blood vessel discolouration can take on the appearance of a ‘frosted tree’ where entire capillary beds are affected.<sup>220,277,282</sup> This lack of vessel discolouration in patients in Bangladesh and India is perhaps surprising as the same process of small vessel obstruction is thought to be responsible for the patches of retinal whitening that are common in African and Asian patient with cerebral malaria. In studies using fluorescein angiography, including preliminary work presented in **Chapter 4** of this thesis, these white patches have been found to correspond to areas of nonperfusion.<sup>223,282</sup> Additionally, the same process of sequestration and blood vessel obstruction has been demonstrated on brain histopathology in Asian adults<sup>253</sup> as in African children.<sup>71</sup> It is thus remarkable that most of those with cerebral malaria in the present study had moderate to severe retinal whitening but no vessel discolouration. There are several possible explanations for this difference:

1) There may be a different degree of dehaemoglobinization in obstructed capillaries of Asian adults and children with severe malaria versus African children. In *falciparum* malaria, mature intraerythrocytic parasites consume 60-80% of the haemoglobin in a red cell.<sup>283</sup> Thus the maximum typical decrease in haemoglobin content in a column of sequestered erythrocytes would be 80%, assuming all cells in the column contain mature parasites. In adults, many of the sequestered parasites in the brain are immature ring forms<sup>253</sup> which consume much less haemoglobin<sup>234</sup> and many erythrocytes in obstructed cerebral microvessels are uninfected.<sup>65,74,75</sup> Thus very few capillaries, if any, would have lost



sufficient haemoglobin to change from red to white or yellow. Vessel discolouration of this type has also not been described in other diseases with low haemoglobin concentrations.<sup>284,285</sup> Sequestration of uninfected erythrocytes has not been shown in African children with cerebral malaria, the studies to date having focussed instead on the proportions of obstructed capillaries, but it would seem unlikely that this aspect of the underlying pathophysiology would be very different from Asian adults and children. This dehaemoglobinisation may be more pronounced in those with pre-existing anaemia and this warrants further investigation as anaemia is commoner in children than in adults in Africa and tropical parts of Asia.<sup>286</sup>

2) Vessel discolouration may represent an entirely different process from dehaemoglobinisation. It is known that perivascular inflammatory changes and accumulation of platelets are more prominent in severe malaria in African children than in Asian adults<sup>99,205</sup> but this has not been seen in the few patients whose retina has been examined histologically.<sup>234,287</sup> Vessel pallor occurs due to vascular sheathing in retinal vasculitides due to the perivascular accumulation of inflammatory infiltrate. This predominantly affects large vessels but can result in appearances similar to the frosted tree seen in African children with *falciparum* malaria. Causes include systemic lupus erythematosus, Crohn's disease, leukemia, toxoplasma and HIV.<sup>288</sup> As the inflammatory infiltrate seen in paediatric malaria is much less than seen in these conditions this seems unlikely to be the cause but further histopathological studies of the eye are needed. Other uncommon causes of pale vessels such as lipaemia retinalis have been described but these appear different on fundoscopic examination and are pathogenically unrelated.<sup>289</sup>

3) The lack of vessel discolouration in the present study could be due to a difference in the retinal background pigmentation. Retinas in Malawian children have a dark brown background, compared to the orange background typically seen in patients in India and Bangladesh. It may be that the difference in contrast masks vessel discolouration and makes it more difficult to see these changes in patients with paler retinas. However, in the five African adults with retinopathy seen in Malawi, no vessel discolouration was seen. Also, a small number of patients in Bangladesh had dark retinal background pigmentation but no vessel discolouration. This suggests differences in pigmentation may not be the explanation, although further data are needed.

### 2.5.6 Pathogenesis

In the introduction it was postulated that malaria retinopathy has great potential as a tool with which to study the pathogenesis of cerebral malaria. The retinal and brain are both part of the central nervous system and there are many similarities in the anatomy and physiology of the microvasculature in both organs.<sup>236</sup> In this study, retinal whitening was present in 79% of patients with cerebral malaria and the severity of whitening correlated with admission GCS. These associations were strongest for macular whitening. It has been postulated that macular whitening is due to hypoxic oedema of ischaemic patches of retina secondary to heterogeneous obstruction of the microvasculature by sequestered parasitized erythrocytes, similar to that seen in Patchy Ischaemic Retinal Whitening (PIRW).<sup>290,291</sup> The macula has a higher metabolic demand than the peripheral retina and is the site of multiple watershed zones of arterial blood supply and thus may be more susceptible to ischaemia.<sup>292</sup> This would explain why peripheral retinal whitening is less strongly associated with severity and outcome from severe malaria than macular or foveal whitening in the present study.

In Malawian children, fluorescein angiograms have shown obstruction of retinal perfusion coinciding with patches of whitening which would support this hypothesis.<sup>223,282</sup> In **Chapter 4** of this thesis, similar preliminary findings are presented for Bangladeshi and Indian adults and children indicating a common mechanism with African children. Retinal histology has shown sequestration in the retinal microvasculature<sup>234,287</sup> very similar to that seen in the brain in Asian adults<sup>65,253</sup> and Malawian children.<sup>71,205</sup> In a recent small case series in Malawi the severity of retinopathy correlated with the degree of sequestration in the retina and in the brain.<sup>240</sup>

Taken together, these findings support the existence of a common pathogenic mechanism between Asian adults and children and African children of microvascular obstruction due to sequestration of parasitised erythrocytes in the retina leading to retinal whitening, and in the brain as a central process leading to coma. Understanding the shared processes that contribute to this microvascular obstruction in the retina and brain is important when considering use of retinopathy as a surrogate marker of cerebral sequestration in severe falciparum malaria. As discussed above, being much easier to visualize *in vivo* than the brain, the retina has potential as a source of surrogate outcome measures in studies of cerebral malaria pathogenesis and in intervention studies with adjunctive therapies targeting this pathogenesis.

The processes known to contribute to systemic microcirculatory obstruction in severe malaria are cytoadherence of parasitized erythrocytes, autoagglutination, rosetting and decreased red cell deformability. As outlined in detail in the introduction to this Chapter, there has been detailed study of cytoadherence in the brain of Asian adults and African children, and the mechanisms and receptors involved appear to be the identical. In the retina, although sequestration of parasitized erythrocytes has been demonstrated,<sup>287</sup> it is not known if the mechanism is shared with that in the brain. There have been no histological studies of the retina in Asian children or adults. The present study found a strong correlation between red cell stiffness and severity of retinal whitening, in particular macular whitening at shear stresses equivalent to the human microcirculation *in vivo*. This suggests that red cell stiffness may contribute to sequestration and microvascular obstruction in the retina in severe falciparum malaria. Previously red cell stiffness had been shown to have prognostic significance in severe malaria in Asian adults and African children as a postulated contributor to systemic microcirculatory obstruction<sup>122,123</sup> and this was thought to be partly due to oxidative damage to the erythrocyte membrane.<sup>293</sup> The present study also showed red cell stiffness to be increased in sepsis, something that has not been demonstrated previously, although to a lesser degree than severe malaria.

The degree of correlation of retinal changes with known measurable indicators of systemic microvascular obstruction has not been well explored. A pilot study for the work presented in **Chapter 2** of this thesis showed that the severity of retinopathy correlated with plasma lactate,<sup>61</sup> a marker of tissue ischaemia produced by anaerobic glycolysis. The present study confirmed this and found the association to be strongest for macular whitening, consistent with the hypothesis that this is due to the same process in the retina causing retinal ischaemia. Previous studies have found raised lactate in the blood to be an independent predictor of mortality in both African children<sup>294</sup> and Asian adults.<sup>257</sup> CSF lactate was also raised in almost all adults with cerebral malaria in whom it was predictive of mortality,<sup>82</sup> adding further to the evidence that cerebral vascular obstruction is an important process in coma and death in cerebral malaria. These results suggest that malaria retinopathy could be a surrogate marker for this process.

In the present study the severity of retinopathy, particularly macular whitening, was correlated with serum bicarbonate. This is a marker of metabolic acidosis. Acidosis in the peripheral blood has been shown to be predictive of mortality in severe malaria independently of lactate in Vietnamese adults,<sup>257</sup> and high anion gap acidosis other than lactate acidosis was also common in Kenyan children with severe malaria.<sup>295</sup> An unidentified

acid other than lactic acid and independent of renal failure is thought to be an important contributor to metabolic acidosis in severe malaria.<sup>296</sup> The nature of this acid and the pathogenic process that produces it remain to be identified. Further analysis is required to assess the degree of correlation of retinopathy in the present study with acidosis independently of lactate. This is important to investigate as the unidentified pathogenic process may also contribute to the pathogenesis of malaria retinopathy and cerebral malaria.

The severity of retinopathy in the present study correlated with peripheral parasite count, total parasite biomass and sequestered parasite biomass. Again these correlations were strongest for macular whitening. As expected from previous studies, the correlations were weaker for peripheral parasite count than for biomass or sequestered biomass. This is because in severe malaria much of the parasite burden is sequestered in the microvasculature and does not circulate in the peripheral blood.<sup>96,253</sup> The peripheral parasitaemia may therefore be low when the total parasite load is high and vice versa. The peripheral blood *Pf*HRP2 level was used as a marker of total parasite biomass and from this, the sequestered biomass was estimated. This derivation uses an equation that relies on several assumptions and is thus not a precise indicator of sequestered biomass. Despite this, the correlation of sequestered biomass with severity of macular whitening was strong. These results are compatible with parasite sequestration causing microvascular obstruction including in the retina where it determines the severity of retinal whitening.

The severity of retinal haemorrhages in the present study was less strongly associated with coma than retinal whitening and did not predict mortality. Haemorrhages were commoner in cerebral malaria than in encephalopathy suggesting they may be related to a pathogenic mechanism that is more associated with malaria. The predominant type of retinal haemorrhages seen in severe malaria was white-centred. The number of retinal haemorrhages in African children with fatal cerebral malaria has been shown to correlate with the number in the brain<sup>235</sup> and they are predictive of mortality.<sup>63</sup> Histopathology of the brain in African children has shown ring haemorrhages associated with vascular thrombosis to be common.<sup>205</sup> In Vietnamese adults with severe malaria, brain haemorrhages were also found at post mortem but there was no difference in their number or prevalence between cerebral and noncerebral severe malaria.<sup>242</sup> The histopathology of *retinal* haemorrhages in severe malaria has not been explored. These findings suggest the significance of brain and retinal haemorrhages to be different between African children and Asian adults. In the present study, the number of retinal haemorrhages correlated inversely with haematocrit and platelets whereas there were no correlations between these and retinal whitening. These hint

at some clues to the pathogenesis of retinal haemorrhages in Asian adults with severe malaria. Retinal haemorrhages, including white-centred haemorrhages, commonly occur in patients with severe anaemia due to other causes. The pathogenesis is uncertain but it has been postulated that low oxygen carrying capacity causes local hypoxia may cause damage to the vessel wall resulting in leakage.<sup>297</sup> This may be potentiated by local thrombosis and/or platelet accumulation resulting in a visible white spot at the centre. Any bleeding tendency due to, for example, low platelets would increase the likelihood of haemorrhage. In severe malaria, anaemia and thrombocytopaenia are common and their association with haemorrhages in the present study suggest this to be a plausible mechanism. On fluorescein angiography in African children, haemorrhages did not coincide with occluded blood vessels supporting embolism or local endothelial cell damage as possible mechanisms.<sup>223</sup> Further studies of retinal histopathology in children and adults are required to clarify this.

Increased tortuosity and engorgement of retinal venules has been shown previously in Ghanaian children with cerebral malaria.<sup>263</sup> Although shown to be reversible, the method used to define these abnormal vessels was not described, assessment appeared to be subjective and no quantitative results were presented. In the present study, retinal vessel tortuosity was quantified in all groups including healthy individuals using a semiautomated method. This reduced subjectivity in the measurement of tortuosity and provided the first quantitative measure of vessel tortuosity in cerebral and noncerebral severe malaria. It was found that there was larger variation in width and tortuosity of retinal venules and arterioles in those with severe malaria than uncomplicated malaria or healthy subjects. This is consistent with the heterogeneous microcirculatory obstruction seen in severe malaria on brain histopathology,<sup>65</sup> on direct visualization of the systemic (rectal) microcirculation using OPS<sup>298</sup> and in the retina on fluorescein angiography.<sup>223</sup> There was a positive correlation of venule width and tortuosity with GCS and decreasing mean venule width with increasing severity of malaria. One possible explanation for this is that obstructed capillary beds containing sequestered parasites reduce the blood volume returning to the venules which they drain into. This would reduce the intravascular pressure and thus width of these vessels whilst adjacent perfused capillary beds would have normal or possibly increased compensatory venous return. If this were the case, it could be speculated that there could be back-pressure in some arterioles feeding into the obstructed capillaries and this might lead to increased arteriolar width and tortuosity. This was not seen, although there was an increase in the variance of arteriolar width and tortuosity in severe malaria. Another speculation worth considering is if this lack of increased tortuosity were related to disordered local

autoregulation of microvascular blood flow. This is known to occur in severe malaria and is thought to be related to impaired nitric oxide response impairing the ability of arterioles to vasodilate.<sup>127</sup>

### 2.5.7 Limitations

The studies in this Chapter had several limitations. Retinal photography was used as the primary tool to assess patients for retinopathy. These retinal photographs were mostly read by a single observer (RJM) with only a small number being read by a second observer (NAVB). Inter-observer concordance was high but a higher number of double-read photographs would have been preferable with comparison of findings for individual features of retinopathy to fully verify reproducibility of the findings. The main reason for this limitation was the difficulty of finding a suitably expert second observer with the available time to read the large number of retinal photographs. As a substitute the author double-read all retinal photographs masked to the clinical status of the patients wherever possible. For the occasional case with particularly memorable retinal changes, the author could recall some clinical details thus blinding was not complete. An alternative unbiased method would be automated slide reading by a software algorithm and the author has begun exploring possible means of doing this.<sup>291</sup>

This study examined the potential of retinopathy to contribute to diagnosis and prognosis in patients with severe malaria. However, as with indirect ophthalmoscopy, retinal photography is expensive, requires extensive training and is not widely available in resource-poor settings. The results presented here reflect an idealised situation in the sense that bedside examination using direct ophthalmoscopy will always find a subset of the findings captured by photography. It was shown in this study that moderate-severe retinopathy, in particular macular whitening, was the best diagnostic and prognostic indicator, being 95% specific for malaria in comatose patients. In previous studies of malarial retinopathy, moderate-severe retinopathy was the easiest to identify by ophthalmoscopy and, although whitening can be more challenging to identify than haemorrhages,<sup>62,224</sup> macular changes are technically the easiest to visualise. If an examiner was only able to detect haemorrhages due to lack of skill or experience, this study has shown that they are present in half of cerebral and fatal malaria and are commoner in cerebral malaria than in encephalopathy, being 91% specific for malaria in comatose patients. Specificity was even higher for white-centred haemorrhages.

Many clinicians do not even attempt fundoscopy for a variety of reasons. They may lack training, experience and confidence; ophthalmoscopes may be unavailable as even simple ophthalmoscopes can be expensive, although low cost models are beginning to appear on the market; and good quality fundal examination is time consuming and thus often not a priority in busy hospitals in clinics. Recently, adapted smartphones have begun to be trialled as possible low-cost platforms for retinal photography,<sup>299</sup> but are not yet ready for widescale use. For the potential contribution of retinopathy to diagnosis and management of severe malaria shown in the present study to be realised, these barriers must be overcome.

Another limitation of this study is that the number of children enrolled was relatively small. Thus only a cursory comparison of findings in Asian adults and children was possible. This was a reflection of the caseload that presented to the hospitals during the study period. How retinopathy in African children might differ from Asian children is a crucial question in studies of the pathogenesis and treatment of cerebral malaria and much more data will be needed to fully address this. As a follow-on to the studies presented in this Chapter, it is planned to recruit a larger cohort of children with which these questions can be answered.

## 2.6 Conclusions

Malarial retinopathy in Asian adults and children was present in 90% of patients with cerebral and fatal *falciparum* malaria, was highly specific for malarial coma in unconscious patients, predicted increased likelihood of development of coma in noncomatose patients with *falciparum* malaria and predicted increased mortality in severe malaria. Malarial retinopathy may thus have potential to aid with diagnosis and prognosis in severe *falciparum* malaria but further analyses combining it with other prognostic factors and further studies on its performance using standard ophthalmoscopic examination techniques are needed. The severity of macular whitening correlated with a decrease in visual acuity but it was not clear if this was a specific effect to malaria. The prevalence of retinal whitening and haemorrhages were similar to that described previously in African children but retinal vessel discolouration was absent and papilloedema rare. Contributors to, and markers of, microcirculatory obstruction were highly correlated with macular whitening consistent with the hypothesis that microcirculatory obstruction by sequestered parasites has a central role in the pathogenesis of both retinal whitening and coma. Additional longitudinal data collected as an extension to these studies are currently being analysed. These will help to determine the rate

of recovery from retinopathy, clarify its effect on visual function and further explore its potential role as a surrogate marker for intervention studies. Further data from Asian children and African adults are needed to clarify the similarities and differences in retinal findings between Asia and Africa.



### **Chapter 3 *P. falciparum* and optic nerve sheath diameter**

### 3.1 Summary

This Chapter summarises two studies. The first was a necessary pre-requisite for the second as it established the normal range for ONSD in Bangladesh. This was not known prior to this study and was necessary to assess whether ONSD in other conditions was raised. The second study measured ONSD in severe and uncomplicated *P. falciparum* malaria and sepsis and compared this to the normal range found in the first study.

## 3.2 Normal range for ONSD in Bangladesh

### Transorbital sonographic evaluation of normal optic nerve sheath diameter in healthy volunteers in Bangladesh

#### 3.2.1 Abstract

Measurement of ONSD by ultrasound is increasingly used as a marker to detect raised ICP. ONSD varies with age and there is no clear consensus between studies for an upper limit of normal. Knowledge of normal ONSD in a healthy population is essential to interpret this measurement. In a prospective observational study, ONSD was measured using a 15 MHz ultrasound probe in healthy volunteers in Chittagong, Bangladesh. The aims were to determine the normal range of ONSD in healthy Bangladeshi adults and children, compare measurements in males and females, horizontal and vertical beam orientations and left and right eyes in the same individual and to determine whether ONSD varies with head circumference independent of age. 136 subjects were enrolled, 12.5% of whom were age 16 or under. Median ONSD was 4.41 mm with 95% of subjects in the range 4.25-4.75mm. ONSD was bimodally distributed. There was no relationship between ONSD and age ( $\geq 4$  years), gender, head circumference, and no difference in left vs right eye or horizontal vs vertical beam. Ultrasonographic ONSD in Bangladeshi healthy volunteers has a narrow bimodal distribution independent of age ( $\geq 4$  years), gender and head circumference. ONSD  $>4.75$  mm in this population should be considered abnormal.

#### 3.2.2 Introduction

Identification of elevated ICP is important in the assessment of a range of neurological diseases. It is a predictor of poor prognosis including risk of death from brainstem herniation. ICP is commonly measured by opening pressure on lumbar puncture but this is invasive, unpleasant for the patient, and contraindicated in many cases. Non-invasive detection of raised ICP can be achieved by detection of specific signs e.g. papilloedema on fundoscopy. This requires an experienced examiner with an ophthalmoscope and the changes can appear late requiring a sustained increase in ICP.<sup>300,301</sup> CT and MRI of the head can be used to infer ICP and determine the safety or otherwise of lumbar puncture. These require the patient to be moved, are frequently not available in resource-poor settings and can be normal early in the presence of raised ICP.<sup>302,303</sup>

Ultrasound measurement of the ONSD is a quick, non-invasive method of detecting raised ICP. It is increasingly being used in emergency departments and intensive care units.<sup>304-306</sup>

The optic nerve sheath is a membrane covering the optic nerve behind the eye and is continuous with the dura mater over the brain. It distends when ICP is high due to expansion of the underlying subarachnoid space and its' diameter can be reliably measured at its point of maximal distension 3mm posterior to the globe.

ONSD has been used as a clinical and research tool for a variety of conditions to detect raised ICP. Its sensitivity for detecting raised ICP is high<sup>304,307</sup> and ONSD varies almost concurrently with ICP.<sup>308</sup> It is cheap and easy to train operators. Ultrasound is known to be operator dependent. However, ONSD ultrasound has been well evaluated and found to have low intra and inter-operator variability.<sup>309,310</sup> ONSD can be measured with the ultrasound beam in the vertical or horizontal orientation and this varies between studies. The degree of normal intra-individual variation in ONSD between left and right eyes is thought to be minimal.<sup>301,302,311</sup>

There is no consensus as to the cut-off for an abnormal ONSD indicating raised ICP and a lack of large studies evaluating its performance as part of care pathways and insufficient evidence for a cut-off in adolescents and non-Caucasian populations have limited its use. There is considerable interindividual variation in ONSD<sup>308</sup> but no difference between male and female children.<sup>311</sup> Although 5mm is most commonly used for adults, different studies have used values up to 5.9mm.<sup>308</sup> In children, ONSD has been shown to increase with age with most of the increase in the first year of life. Threshold values of 4.0mm under 1 year and 4.5mm in those 1 to 16 years of age<sup>308,311</sup> or 4mm under 4 years and 5mm in older children and adults<sup>301</sup> have been proposed. It is not known whether ONSD increases beyond childhood<sup>311</sup> or how ONSD varies with ethnicity or head circumference.

Knowledge of the normal range of ONSD in a healthy population is essential to interpret this measurement as a marker of ICP in clinical practice<sup>304,312</sup> and research. Studies are currently underway in Bangladesh using ONSD to detect raised ICP in adult severe malaria. To date, however, there has been no evaluation of ONSD in a healthy Bangladeshi population.

An observational study was performed to determine the normal range of ONSD in healthy Bangladeshi adults and children, compare measurements in males and females, horizontal and vertical beam orientations and left and right eyes in the same individual and to determine whether ONSD correlates with head circumference independent of age.

### 3.2.3 Material and Methods

The study was conducted in Chittagong Medical College Hospital, Chittagong, Bangladesh. Chittagong Medical College Ethical Committee and OXTREC, the University of Oxford Tropical Research Ethics Committee provided ethical approval for this study. Healthy relatives of patients and hospital staff of all ages and both genders were recruited if they provided written, informed consent. Written informed consent was obtained from the next of kin, caretakers, or guardians on behalf of children participating in the study. Individuals were excluded if they had any chronic diseases, any acute illnesses in the preceding 4 weeks or had taken any medications in the preceding 4 weeks. Upon enrollment, basic demographic data were collected and the head circumference measured by a single observer using a purpose-designed non-stretchable tape around the widest possible occipitofrontal circumference.

ONSD was measured 3 mm behind the retina. A single investigator used a 15 MHz linear ultrasound probe (Accutome B-Scan Plus, Accutome Inc., USA) oriented perpendicularly in the vertical plane and at around 30 degrees in the horizontal plane on the closed eyelids of both eyes of supine subjects. Ultrasound gel was applied to the outside of each eyelid and recordings made in the axial and longitudinal planes of the widest diameter visible. Video of every ultrasound was recorded for later analysis by a single masked investigator. To determine ONSD, electronic calipers were used to mark 3 mm perpendicularly behind the retina. The ONSD was measured at the depth marker at right angles to the optic nerve. This method has been described and illustrated diagrammatically in detail elsewhere.<sup>313</sup> Each video was played three times and a single measurement made each time from a randomly selected frame, giving 6 measurements of each eye and 12 measurements in total per subject.

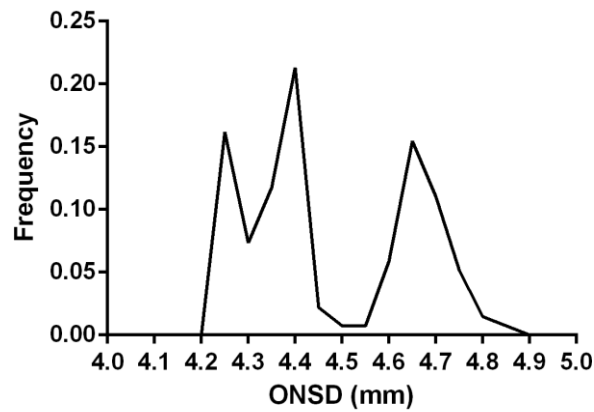
The study aimed to include 100 healthy Bangladeshi people. Previous studies in healthy children found ranges of ONSD of 2.5-4.1mm in 31 people in Africa<sup>312</sup> and 2.1-4.3mm in 102 people in the UK with correlation with age.<sup>311</sup> As it was not known to what degree ONSD varies in Bangladeshi people, or how this changes with age or skull size, it was not possible to perform a precise sample size calculation. The UK study was used as a guide to the approximate sample size required. With this sample size, assuming an alpha of 0.05, two groups of equal size and a total population of 158,000,000, a 10% difference in mean ONSD between adults and children can be detected. Results from a second smaller group of different healthy individuals recruited concurrently from the same population for a separate

study were also included for comparison. In this group, videos were recorded by a different investigator from the first group using the same methodology except head circumference was not measured and ONSD was recorded only in the horizontal plane. Results of this study will be published separately. The same investigator measured all ONSDs from the videos for both groups.

Statistical analysis was performed using GraphPad Prism 6 (GraphPad Software, Inc., USA). Mann Whitney U test was used to compare unpaired ONSD between genders and observers, Wilcoxon matched pairs signed rank test to compare left and right eyes and horizontal and vertical measurements. Linear regression was used to assess for correlations with age and head circumference. One way analysis of variance and intraclass correlation coefficient (CCI) were used to test for differences between the repeated measures of ONSD within individuals. Mean values of repeated measures were used for correlations and comparison between groups.

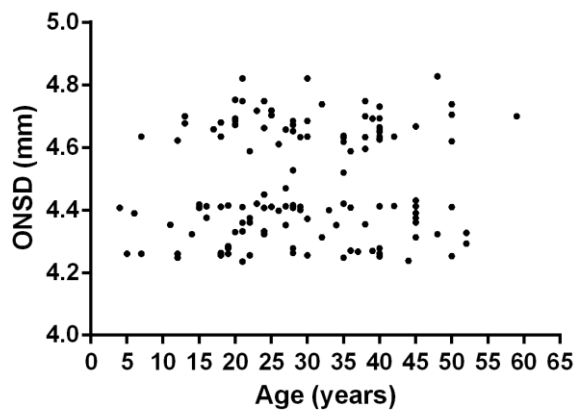
### 3.2.4 Results

ONSD was measured in 106 healthy volunteers by the first observer, and an additional 30 by the second observer. All those asked agreed to participate in the study. 17/136 (12.5%) subjects were age 16 or under and 49.3% were male. All patients were of Bangladeshi origin. The median (range) ONSD was 4.41 (4.24-4.83) mm and 95% of individuals had mean ONSD in the range 4.25-4.75 mm (**Figure 3.2-1**). The distribution of ONSD in this study was bimodal (**Figure 3.2-1**). There was no difference in the measurements in the two groups [median (range) 4.41 (4.24-4.83) vs 4.33 (4.24-4.75) mm,  $p=0.52$ ]. There was no difference between the 6 repeated measures of ONSD in each eye (right eye CCI=0.897,  $F(4.432, 465.3) = 1.331$ ,  $p=0.254$  and left eye CCI=0.897,  $F(4.595, 482.4) = 1.351$ ,  $p=0.2451$ ).

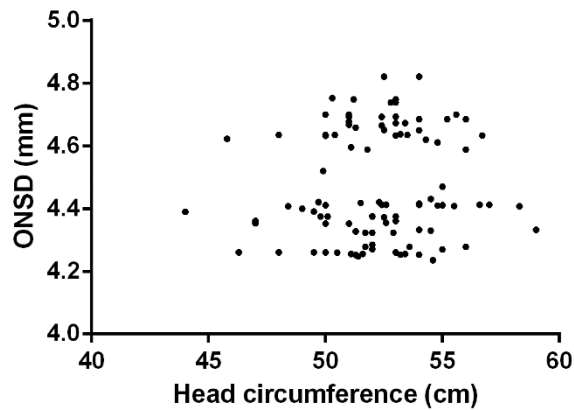


**Figure 3.2-1. Distribution of mean optic nerve sheath diameter (ONSD) measurements.**

There was no relationship between ONSD and age ( $R^2=0.0093$ ,  $p=0.27$ , **Figure 3.2-2**) or ONSD and head circumference ( $R^2=0.011$ ,  $p=0.31$ , **Figure 3.2-3**), and no difference in ONSD between males and females ( $p=0.47$ ). There were also no differences in individual's mean measurements taken in the horizontal or vertical planes ( $p=0.99$ ), or between left and right eyes ( $p=0.12$ ). The maximum difference between mean measurements in horizontal and vertical planes was 0.093mm and between left and right eyes 0.13mm.



**Figure 3.2-2. Optic nerve sheath diameter (ONSD) and age.**



**Figure 3.2-3. Optic nerve sheath diameter (ONSD) and head circumference.**

The mean (95% CI) difference in individual ONSD measurements from the overall mean for each subject was 0.19 (0.17-0.20) mm. Repeating each measurement three times gave a mean difference of 0.07 (0.06-0.08) mm from the overall mean for each subject. The mean (95%) coefficient of variation of the multiple ONSD readings for each individual was 1.19 (1.09-1.29) % and the typical error of measurement 0.054 (0.049-0.59) mm.

### 3.2.5 Discussion

This study indicates the cut-off for the upper limit of normal ONSD in Bangladeshi people  $\geq 4$  years old is 4.75mm. The normal range of ONSD was independent of age, gender, ultrasound beam orientation, head circumference and observer.

The range of ONSD in this study (4.24-4.83 mm) was higher and narrower than has usually been found previously. Examples from previous studies include 2.5-4.1mm in 50 UK adults,<sup>310</sup> 2.1-4.3mm in 102 UK children,<sup>311</sup> 2.5-4.1mm in 31 African children,<sup>312</sup> 2.9-4.3mm in 20 German adults<sup>314</sup> and 2.2-4.9 mm in 26 Greek adults.<sup>306</sup> A study in Iran found similar values to the present study with a mean of 4.6mm in normal subjects.<sup>315</sup> The differences in normal range between studies may be due to differences between ethnicities, although it is not possible to exclude subtle differences in methodology as a contributing factor. Examples might include variation in the angle or positioning of the probe or differences in resolution. The precision of measurement increases with increasing frequency of the ultrasound probe



used.<sup>316</sup> This study used a relatively high frequency 15MHz probe which may have partially accounted for the relatively narrow normal range found.

The distribution of ONSDs in this population was bimodal with a cut-off between the two groups of 4.5mm. This could not be explained by differences between investigators, genders or ethnic origin and warrants further investigation. Previous similar studies have not found a bimodal distribution. Possible explanations might include two genetically distinct subpopulations (e.g. Bengali vs tribal) or two groups with different nutrition in childhood (for example malnutrition causing growth retardation and a smaller ONSD in those living in rural areas). As information on e.g. ethnic origin, place of residence and economic status were not collected these cannot be determined. Another possibility is that the bimodal distribution was an artefact of the measuring technique used, e.g. the electronic calipers, although the technique was highly standardised between measurements and no specific problems were identified during operation. A consequence of this is that in those with  $ONSD < 4.5\text{mm}$ , an increase in ICP could produce an ONSD within the normal distribution of the second peak between 4.5 and 4.75mm.

This study had several limitations. A direct measure of ICP was not included thus it is not known how well ONSD above the derived normal range predicts ICP. Previous studies have shown a reliable linear relationship.<sup>317</sup> The present study did not include any volunteers under 4 years of age. Previously it has been shown that ONSD increases with age under 4 years and most within the first year of life.<sup>301</sup> Previous studies have also suggested a much smaller increase in ONSD to the end of childhood, although this was not corroborated by the present study. Each measurement was made three times from the same video by the same observer. This observer was not masked to the other results from the same video and this may have reduced the variability in these measurements due to observer bias. As the two investigators measuring ONSD did so in different patients, it was not possible to determine interobserver variability in this study. However, there was no difference in the median or range of observations by the two investigators and previous studies have shown inter-observer agreement to be high.<sup>309,310</sup>

### **3.2.6 Conclusions**

Ultrasonographic measurements of ONSD in Bangladeshi healthy volunteers have a narrow bimodal distribution. ONSD is independent of age ( $\geq 4$  years), gender and head circumference. ONSD  $>4.75$  mm in this population should be considered abnormal.

### 3.3 ONSD in severe falciparum malaria

#### 3.3.1 Abstract

Raised ICP and cerebral oedema are found in most African children with cerebral malaria and are associated with a worse outcome. In adults with cerebral malaria, raised ICP and cerebral oedema are thought to be less frequent and severe than in children but available evidence is limited and there have been no studies in Asian children. ONSD is a non-invasive marker of ICP which is more sensitive than fundoscopy. ONSD was measured in 28 patients with cerebral, 18 with noncerebral and 32 with uncomplicated *P. falciparum* malaria, as well as 21 people with sepsis. Median ONSD was higher in all groups than in healthy controls and highest in those with uncomplicated malaria. There was no difference in median ONSD between those with cerebral and noncerebral severe malaria or between those with fatal and nonfatal severe malaria. There was also no difference in ONSD between adults and children with severe malaria. Raised ICP is not seen in most Asian adults and children with cerebral *P. falciparum* malaria, it is not specific to cerebral malaria and not associated with mortality. This suggests cerebral oedema is not an important contributor to coma or death in adults or children with falciparum malaria in Asia.

#### 3.3.2 Introduction

Cerebral oedema and consequent raised ICP are common in cerebral malaria in African children. In a recent study using magnetic resonance imaging of the brain in Malawi, 77% of 120 children with cerebral malaria had moderate to severe cerebral oedema.<sup>175</sup> When measured by lumbar puncture, raised ICP was found in 95% of 46 Malawian children with cerebral malaria<sup>249</sup>, 100% of 26 Kenyan children with cerebral malaria<sup>179</sup> and 80% of 40 Gambian children.<sup>318</sup> In 23 Kenyan children with cerebral malaria who underwent direct ICP monitoring, all had evidence of ICP elevation, in 4 of whom it was severely elevated.<sup>188</sup>

Although sensitive, these techniques have limitations in severe malaria. CT and MRI studies generally require patients to be well enough to be moved to the scan room, the scanners are frequently not available in resource limited settings and can be normal early in the course of increasing ICP.<sup>302,303</sup> Lumbar puncture is invasive and can precipitate potentially fatal brain

herniation. Direct ICP monitoring requires insertion of an intracranial device which carries significant risks and is generally only available in well-resourced settings.

Fundoscopy is widely available and non-invasive. However, its sensitivity for raised ICP is poor as papilloedema is a relatively insensitive, subjective and late marker of raised ICP.<sup>300,301</sup> Of 45 children with severe, mostly cerebral, malaria in Malawi only 24% had clinically evident papilloedema on dilated fundoscopy,<sup>319</sup> although the majority have raised ICP.<sup>179,249,318</sup> Optic nerve sheath diameter is increasingly used as a non-invasive surrogate marker of ICP in a range of conditions and it has the advantages of being more sensitive to changes in ICP and less subjective than fundoscopy. ONSD was found to be increased in 49% of 101 Malawian children with cerebral malaria and 45% of 11 with noncerebral severe malaria.<sup>249</sup> Median CSF pressure was higher in those with increased ONSD. There was no difference in mortality but neurological sequelae were commoner in those with increased ONSD. Raised ICP has been associated with a poor outcome in some studies of paediatric cerebral malaria<sup>179,188</sup> but not in others.<sup>249,318</sup> However, administration of mannitol to lower of ICP in paediatric cerebral malaria had no clear effect on outcome.<sup>188,320</sup>

In adults with severe malaria, cerebral oedema and raised ICP are less prominent than in African children, although this has been much less studied than in children. Of 120 Indian adults with cerebral malaria who underwent lumbar puncture, 36% had raised CSF pressure of whom only 2% had severely raised pressure. In the same study, 63% of 126 patients with cerebral malaria had evidence of cerebral swelling and 29% moderate to severe swelling on CT brain. CSF pressures correlated with CT findings but the extent of swelling did not correlate with coma depth or mortality and mannitol had no effect on outcome.

There has been no study using measurement of ONSD in adults with cerebral malaria and there are very few published data on ICP in adults or children with noncerebral severe malaria, uncomplicated malaria or sepsis. The specificity of raised ICP for cerebral malaria is not known.

We undertook a study using ONSD as a surrogate marker for ICP in patients with cerebral, severe noncerebral and uncomplicated malaria, sepsis and healthy controls. The aims were to determine the frequency of raised ICP in these groups and to assess the specificity of raised ICP for cerebral malaria.

### 3.3.3 Methods

This study was conducted in Chittagong Medical College Hospital from June to August 2011. Ethical approval was obtained from the Bangladesh Medical Research Council Ethical Committee and OXTREC, the University of Oxford Tropical Research Ethics Committee. Consecutive adult patients with severe malaria, uncomplicated malaria and sepsis were enrolled according to inclusion and exclusion criteria outlined in **Section 2.3.1** providing they or their relatives gave written, informed consent.

All patients underwent a full clinical assessment including history taking and physical examination, and blood was taken for parasite count, haematology and biochemistry including lactate and bicarbonate. Measurement of ONSD was done by two investigators using the methods described in **Section 3.2.3**. Mean ONSD measurements for each patient were compared to the normal range for this population determined in **Section 3.2**. In addition, median ONSD for each group was compared to the median ONSD found in 106 healthy subjects in the separate study described in **Section 3.2**.

Statistical analysis was performed using GraphPad Prism 6.01 (GraphPad Software, Inc., USA). Kruskal Wallis test with Dunn's test for multiple comparisons was used to compare ONSD between multiple groups. Mann Whitney U test was used to compare unpaired ONSD between two groups. Mean values of repeated measures were used for correlations and comparison between groups.

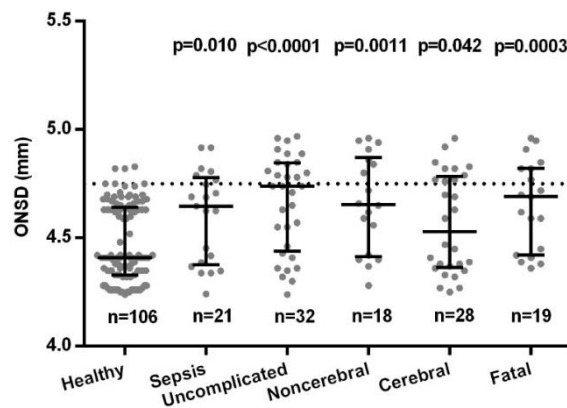
### 3.3.4 Results

In total, 46 patients with severe falciparum malaria were recruited, 28 with cerebral and 18 with noncerebral severe malaria. Median (IQR) GCS in those with cerebral malaria was 8 (6-9). Features of severe malaria on enrolment are listed in table **Table 3.3-1**. In addition, 32 patients with uncomplicated falciparum malaria and 21 with sepsis were recruited for comparison. Median ONSD was higher in all groups than in healthy controls and highest in those with uncomplicated malaria (median (IQR) of 4.74 (4.44-4.85) mm) (**Figure 3.3-1**). Of those with cerebral malaria, 10/28 (36%) had raised ONSD, 7/18 (39%) with noncerebral severe malaria, 7/19 (37%) of those with fatal malaria and 10/27 (37%) with nonfatal

malaria. No patients in this study had ONSD above 5mm, a commonly cited generic conservative cut-off for significantly raised ICP.<sup>307</sup>

**Table 3.3-1. Severity features in patients with severe malaria on enrolment.**

	Number of patients (%)	
	n=46	
Glasgow Coma Scale <11	28	(61%)
Venous lactate > 4 mmol/l	22	(48%)
Venous bicarbonate < 15 mmol/l	13	(28%)
Serum creatinine > 3.0 mg/dl	11	(24%)
Generalised convulsions (>2 in 24 hours)	10	(22%)
Haematocrit < 20 % with parasite count > 100,000/mm <sup>3</sup>	9	(20%)
Bilirubin > 3.0 mg/dl with parasite count > 100,000/mm <sup>3</sup>	9	(20%)
Peripheral asexual stage parasitaemia > 5 %	8	(17%)
Blood glucose <40 mg/dL	1	(2%)
Systolic blood pressure < 80 mm Hg with cool extremities	0	(0%)
Pulmonary oedema	0	(0%)
Spontaneous bleeding	0	(0%)



**Figure 3.3-1. Optic nerve sheath diameter (ONSD) in malaria and sepsis compared to healthy controls.**

ONSD in sepsis, uncomplicated falciparum malaria, noncerebral severe falciparum malaria, cerebral falciparum malaria and fatal falciparum malaria compared to healthy subjects.

There was no difference in median ONSD in fatal versus nonfatal severe falciparum malaria (Figure 3.3-2).

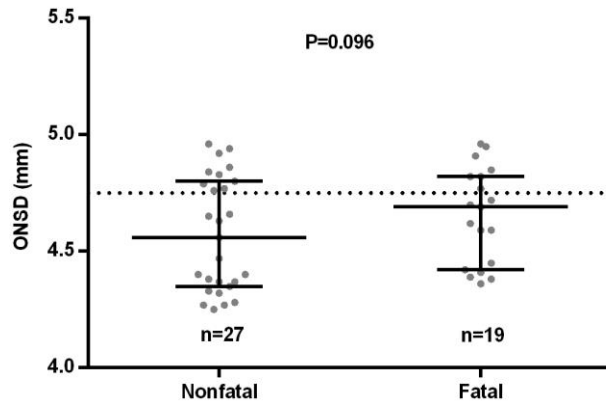


Figure 3.3-2. Optic nerve sheath diameter (ONSD) in fatal versus nonfatal severe falciparum malaria.

Six patients with severe malaria (4 cerebral) and 7 with uncomplicated malaria were children ( $\leq 16$  years old). The median (IQR) age of the children was 10 (4.75-14.5) years and none of the children died. There was no difference in median ONSD between adults and children with cerebral, severe or uncomplicated malaria (Figure 3.3-3).

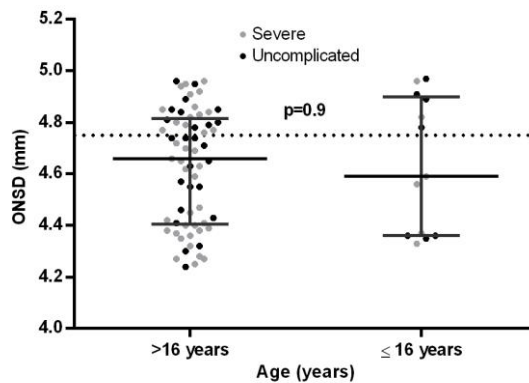


Figure 3.3-3. Optic nerve sheath diameter (ONSD) in adults versus children with severe and uncomplicated falciparum malaria.

### 3.3.5 Discussion

Raised ICP is absent in the majority of children and adults with severe falciparum malaria in Asia, and is not associated with coma or death. This is in agreement with a study using CT in Indian adults with cerebral malaria of whom 29% had moderate-severe brain swelling and swelling was not related to coma or death.<sup>46</sup> This differs markedly from African children with cerebral malaria in whom the majority of fatal cases had severely swollen brains on MRI and raised ICP on LP whereas most nonfatal cases did not.<sup>176</sup> In another study in Malawian children, 77% with cerebral malaria had moderate-severe cerebral oedema on MRI.<sup>175</sup> Also in Malawian children with cerebral malaria, 95% had raised CSF pressure on LP, 49% had increased ONSD and CSF pressure on LP was higher than in those with normal ONSD.<sup>249</sup>

The reason for this difference in prominence and frequency of raised ICP between African children and Asian adults and children is not clear. In studies in both locations, it has been postulated that cerebral oedema occurs partly as the result of accumulation of sequestered parasites in the cerebral vasculature<sup>176,181</sup> in addition to cytotoxic and vasogenic oedema.<sup>181</sup> It is not clear to what degree each process contributes in each group and further studies are needed.

It has been postulated that the pathogenesis of cerebral malaria in children and adults may be different on the basis of differences in findings between studies in African children and Asian adults. The difference in cerebral oedema is one of the major discrepancies cited. In addition to adults, this study recruited children and there was no difference in ONSD between the two age groups in those with cerebral, noncerebral severe or uncomplicated malaria. Admittedly the numbers of children were small, but these findings suggest that raised ICP is not contributory to coma in Asian children, unlike African children. A future study with a larger cohort of Asian children would help to clarify this.

If this difference between Asian and African children with cerebral malaria is confirmed, there are several possible explanations. One is that the differences seen in cerebral malaria between Africa and Asia are not due to differences in age of the patient, but rather because of a difference in the parasites in the two locations. Another possibility is that there is some innate difference in the genetic makeup of the human host in Africa versus Asia that contributes to disease pathogenesis. Further studies of cerebral malaria pathogenesis in Asian children and African adults would be required to answer this.



That ONSD was higher in patients with uncomplicated malaria and similar in sepsis strongly suggests that raised ICP does not have an important role in causing coma in Asian patients with falciparum malaria.

### **3.3.6 Conclusions**

Raised ICP as measured by ONSD does not play a role in causing coma or death in Asian adults or children with cerebral malaria.

**Chapter 4 *P. falciparum* retinopathy and fluorescein angiography**

## 4.1 Summary

Fluorescein angiography was performed in a subset of patients with *P. falciparum* who underwent retinal photography. Availability of tabletop cameras to photograph the study patients was extremely limited and therefore few angiograms could be performed using this method. Instead, a novel low cost method was devised and tested in Chittagong and successfully used to perform angiograms in most patients with severe malaria in 2010 and 2011. This method is described in detail in this Chapter.

Analysis of fluorescein angiograms requires expert observers and is very time-consuming. Towards the end of this work for this thesis, I was part of an expert working group which devised a new classification scheme for analysing fluorescein angiograms in falciparum malaria. The angiograms performed for this thesis are currently being analysed by expert observers using this new scheme and thus the full results are not yet available to include in this thesis. In lieu of this, some examples of the angiograms performed are presented including a published case report which demonstrates for the first time reversibility of retinal whitening and associated angiographic changes.

## 4.2 Low cost fluorescein angiography

### 4.2.1 Abstract

Fundus fluorescein angiography has great potential as a unique tool to investigate *in vivo* the microvascular pathogenesis of a wide variety of diseases affecting the central nervous system. However, because it requires a bulky and expensive tabletop retinal camera, it is normally limited to cooperative and alert seated patients in well-resourced settings. Recent and ongoing studies of the pathogenesis of severe malaria are employing fluorescein angiography to examine in detail the postulated central role of microvascular obstruction. We describe a novel method of fluorescein angiography with which a portable retinal camera can be adapted at very low cost for use in sick patients at the bedside. This method greatly expands the scope of potential studies utilising fluorescein angiography.

### 4.2.2 Introduction

Fundus fluorescein angiography (FFA) was first formally described in humans in 1961.<sup>321</sup> Although the underlying principals are relatively simple,<sup>322</sup> the equipment has become increasingly complex and expensive and, with improved optics and high resolution digital imaging, developed into a valuable clinical tool used by ophthalmologists worldwide.

The basic components of FFA have remained unchanged since its inception. Sodium fluorescein injected into a peripheral vein circulates to the retina. Incident white light is passed through an 'excitation' optical filter (blue, wavelength around 465nm), absorbed by the fluorescein and then emitted at a different wavelength (around 525nm) as fluorescence.<sup>323</sup> A 'barrier' (yellow/green) optical filter is used to block all but this emitted light which is captured by a camera. This produces a map of the intraretinal fluorescein and thus retinal blood perfusion and blood retinal barrier (BRB) integrity. Because it requires a bulky tabletop retinal camera, FFA has been mostly limited to relatively fit, mobile and cooperative subjects in well-resourced settings.

FFA has been used to diagnose, assess and investigate the pathogenesis of a variety of conditions which affect the retina including diabetic retinopathy, central retinal vein occlusion, retinal vasculitis,<sup>324,325</sup> and infectious diseases such as malaria,<sup>223</sup> dengue,<sup>326</sup> syphilis,<sup>327</sup> tuberculosis,<sup>328</sup> bartonellosis,<sup>329</sup> toxoplasmosis,<sup>330</sup> West Nile Virus<sup>331</sup> and murine typhus.<sup>332</sup>

Of these infections, malaria has been of particular ophthalmological interest. Malarial retinopathy is a unique set of retinal changes including retinal haemorrhages (particularly white-centred), retinal whitening, vessel discolouration (orange/white) and papilloedema. It is present in the majority of patients with cerebral and severe malaria and its severity correlates with disease severity and outcome.<sup>61,63</sup> A central pathogenic feature of severe malaria is thought to be obstruction of the microcirculation by sequestered parasitized erythrocytes, particularly in the brain in cerebral malaria.<sup>333</sup> Indirect evidence for this includes: large numbers of sequestered parasites in the brain on autopsy,<sup>253</sup> decreased flow in the rectal microcirculation,<sup>298</sup> decreased erythrocyte deformability,<sup>122</sup> raised blood lactate<sup>257</sup> and high HRP2-derived sequestered parasite biomass.<sup>259</sup> However, it has not been possible to visualise the microcirculation in the brain in living subjects.

The retinal microcirculation is uniquely identical to that in the brain and the same pathogenetic processes occurring at both sites in cerebral malaria are thought to cause retinopathy and coma.<sup>291</sup> The retina is the only vascular bed that can be easily visualized in living subjects. FFA is thus now being employed in studies to investigate the pathogenesis of cerebral malaria.<sup>223,282</sup> In Malawian children with cerebral malaria, FFA reveals abnormalities in the majority, including impaired perfusion, vessel occlusion, filling defects, leakage and vessel mottling.<sup>223</sup> The weight and immobility of tabletop cameras makes it very difficult to capture clear images in conscious patients with severe malaria as they generally have limited tolerance and are unable to sit up, thus restricting it to deeply comatose patients lying on their side on a raised bed. This same problem has severely limited studies using FFA on acutely ill patients with a range of other diseases.

To overcome these difficulties, we developed a simple method of modifying a portable retinal camera to undertake FFA at the bedside on supine patients. This is being used successfully in ongoing studies of severe malaria in Bangladesh. We have found this technique to be well-tolerated, regardless of conscious level, and minimally disruptive to patient care. The modifications to the fundus camera required for FFA are relatively cheap (under 100 USD) and an experienced retinal photographer requires minimal additional

training (use of the Kowa Genesis D camera and familiarity with the normal procedure for fluorescein angiography). To date, we have used the technique on 32 patients with severe malaria (both adults and children) with clinically useful pictures being obtained in 29 (91%).

### 4.2.3 Method

#### *Apparatus required:*

Kowa Genesis D portable fundus camera

Kodak 3x3" #15 Deep Yellow and 3x3" #47A Light Blue Wratten 2 optical filters. *Tip:* the outer layer of these filters can become cloudy after several weeks in very hot and humid environments. This can be prevented by storing them in a fridge or air-conditioned room. If necessary, the opaque outer layer can be removed by gentle rubbing with a cotton bud soaked in water.

Velcro®

Strong glue

Old 35mm photographic slides with plastic frame

Stopwatch

#### *Method: (Figure 4.2-1)*

##### Filter assembly

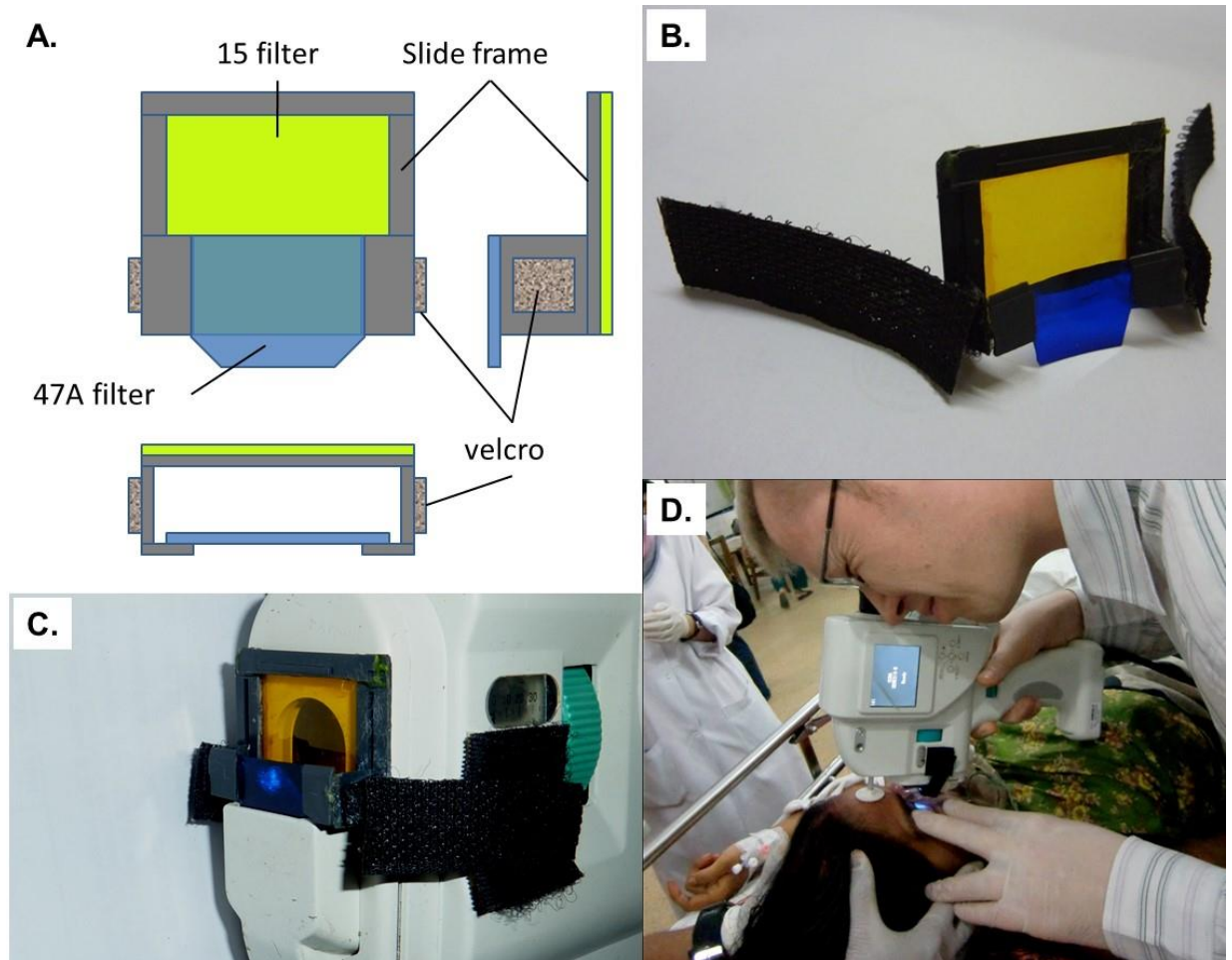
Cut a 20 by 20 mm square out of each of the #15 and #47A filters. Trim the bottom corners off the 47A filter from about 2/3 of the way down.

Cut three 20mm long and four 10mm long strips of plastic from the frame of the photographic slide.

Construct a 3-sided frame from the 20mm pieces and glue on the #15 filter.

The 10mm pieces should then be glued perpendicular to the frame in an 'L' shape to support the #47A filter, and a small piece of Velcro® (loop side) glued onto each side.

Glue 20 by 20mm velcro (loop side) patches to the sides of the camera.



**Figure 4.2-1. Fluorescein filter assembly.**

A. Schematic of the filter assembly. Left-hand image is as viewed from the front, right hand image from the side and bottom image from the top. B. Photograph of filter assembly with attached velcro strips. C. Kowa Genesis D retinal camera with added velcro patches and attached FFA filter. D. Camera in use.

### *Photography*

Focus the camera and check by taking a colour fundus picture of the eye to be examined.

*Tip:* it is important not to change the focus after this step as the fundus is not visible once the filters are in place and it is very difficult to refocus quickly enough during the initial phase of the angiogram.

Place the filter assembly on the front of the camera and secure with two strips of Velcro (loop side).

Turn the camera's brightness and flash up to maximum.

Get in position ready to take the photographs.

Have an assistant simultaneously inject fluorescein and start the stopwatch. Begin photographing immediately. The assistant should record the time of each photograph from the stopwatch. Continue for 10 minutes to capture all phases of the angiogram. *Tip:* good communication between the photographer and assistant is essential.

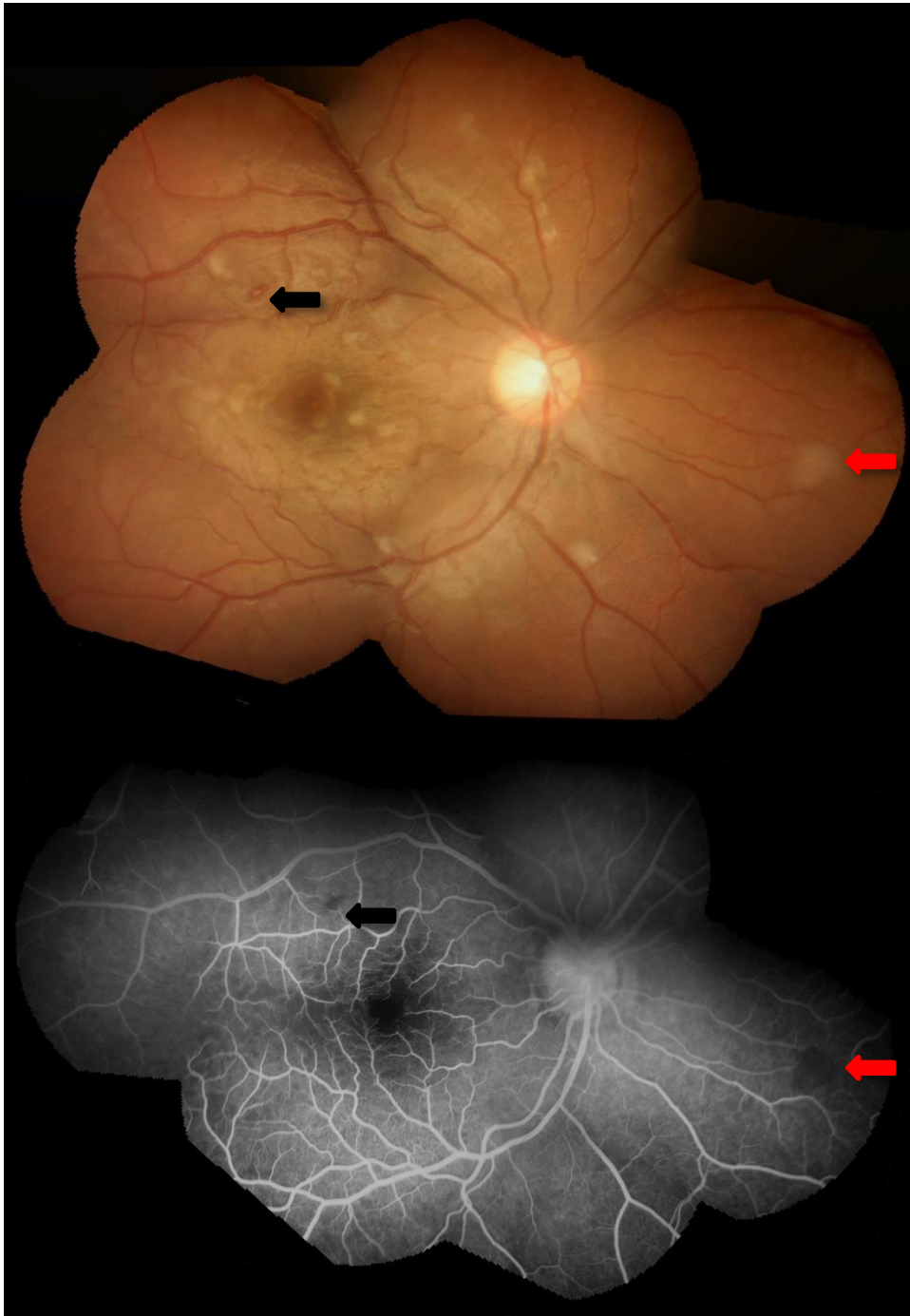
The pictures can then be merged using software such as Adobe Photoshop®<sup>334</sup> to give composite images of the entire fundus. For examples, see **Section 4.3, Figures 4.3-1, 4.3-2, 4.3-3 and 4.3-4.**

#### **4.2.4 Conclusions**

This simple and cheap adaptation of a portable fundus camera greatly expands the scope of studies utilising FFA. We have used it in a wide range of patients, both comatose and awake, adults and children. It has the advantage that the camera is taken to the patient rather than the other way around. As the patient does not need to be moved it can be undertaken in a variety of settings, minimising inconvenience and avoiding interference with patient care. In addition, the photographer can travel to remote locations and undertake the technique in the field.



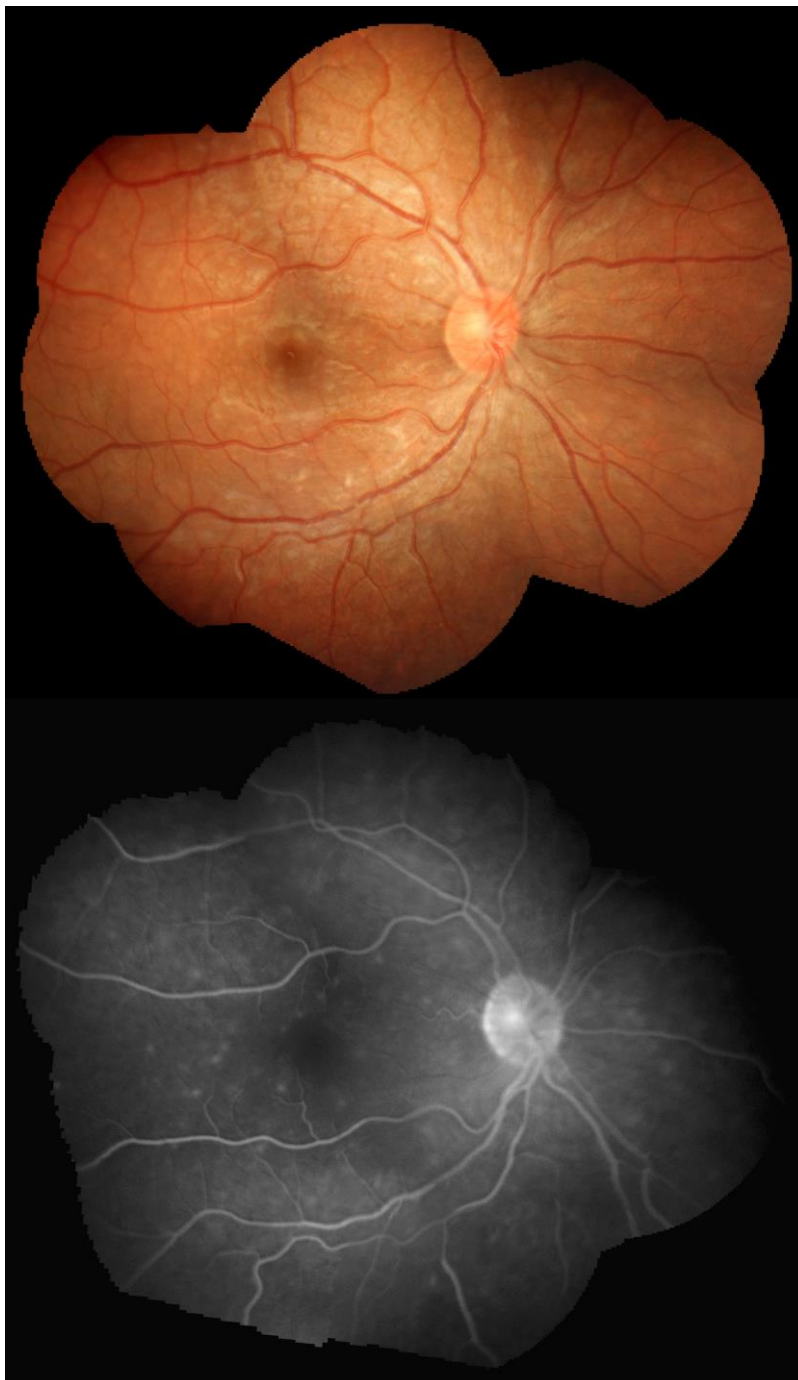### 4.3 Example fluorescein angiograms in severe malaria



**Figure 4.3-1. Widespread retinal whitening and patchy hypoperfusion.**

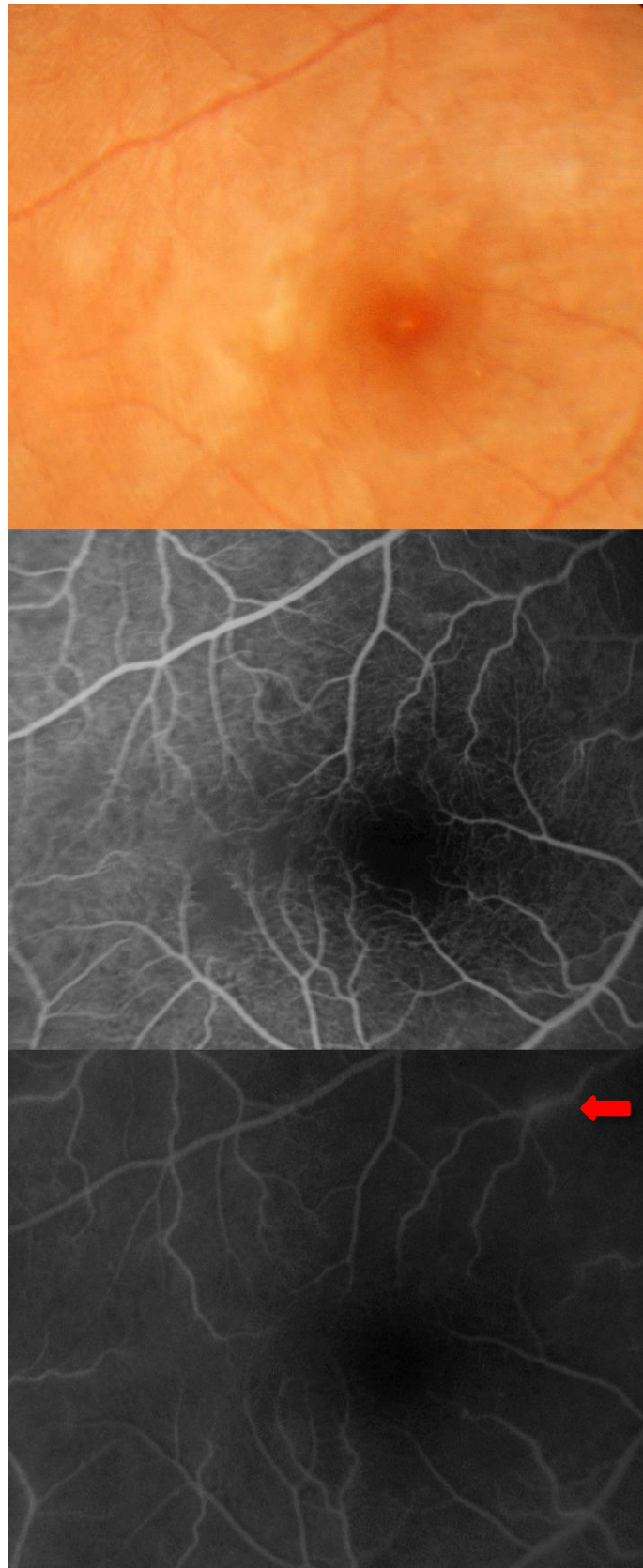
Composite fundus photograph (top) and fluorescein angiogram (bottom) of Bangladeshi child with cerebral malaria showing widespread moderate retinal whitening in macula, fovea and periphery and corresponding patchy hypoperfusion (e.g. red arrow). Single white-centred retinal haemorrhage with masking of fluorescein (black arrow).

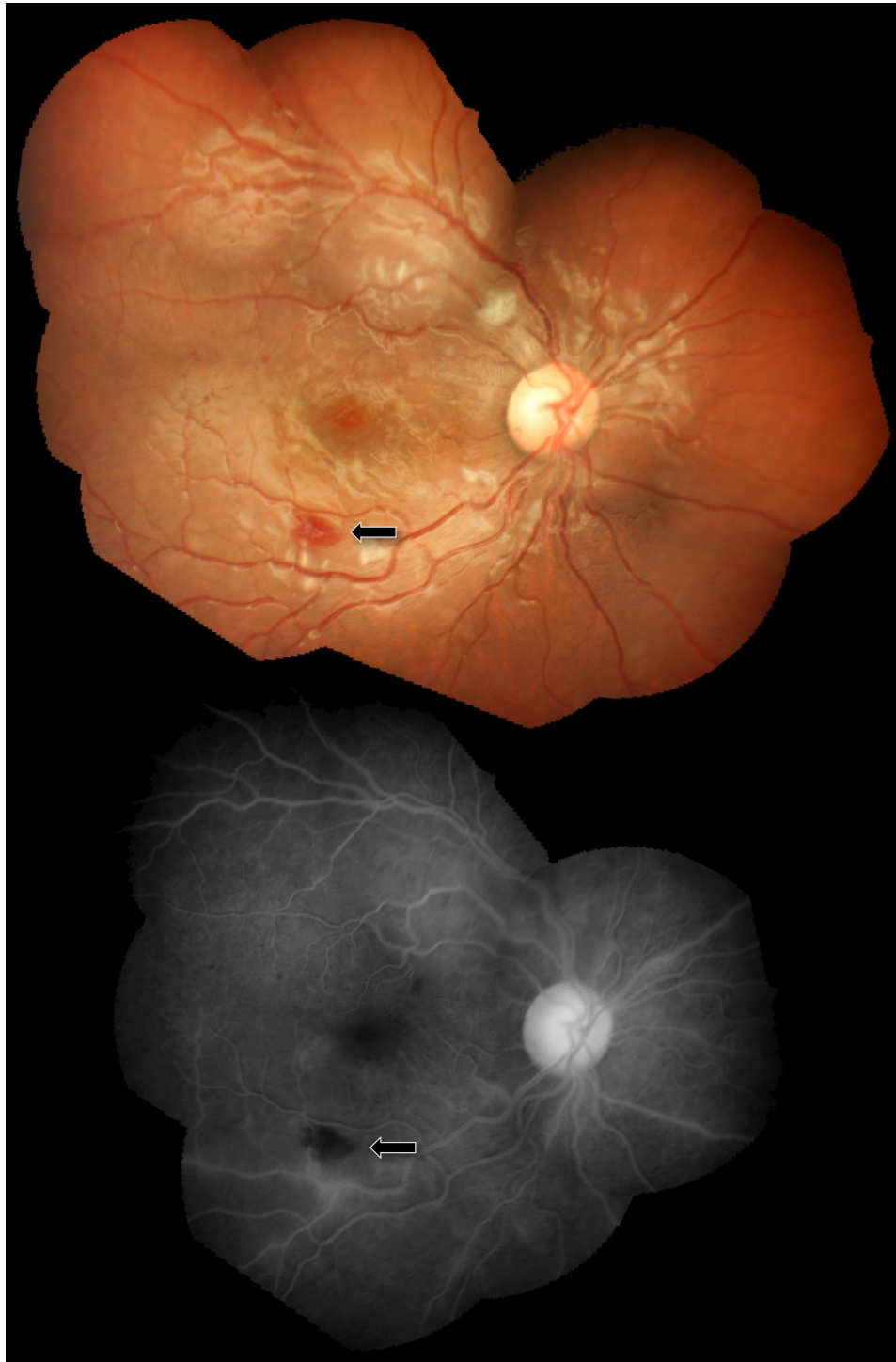
**Figure 4.3-2.**  
**Widespread punctate retinal whitening and hyperfluorescence.**  
Composite fundus photograph (top) and fluorescein angiogram (bottom) of Bangladeshi adult with cerebral malaria showing widespread severe punctate retinal whitening and corresponding hyperfluorescence on angiogram. The cause is unclear but it may represent fluorescein leakage. Staining or transmission defects are less likely as it appeared early in the angiogram and persisted through arterial and venous phases. Images were acquired with a portable retinal camera.



**Figure 4.3-3. Macular and foveal retinal whitening, early hypoperfusion.**

Colour fundus photograph (top), early phase fluorescein angiogram (middle) and late phase (bottom) of Bangladeshi adult with cerebral malaria showing severe macular and foveal whitening with perifoveal hypoperfusion (early) and subtle vessel leakage (late) (e.g. red arrow). Images were acquired with a portable retinal camera.





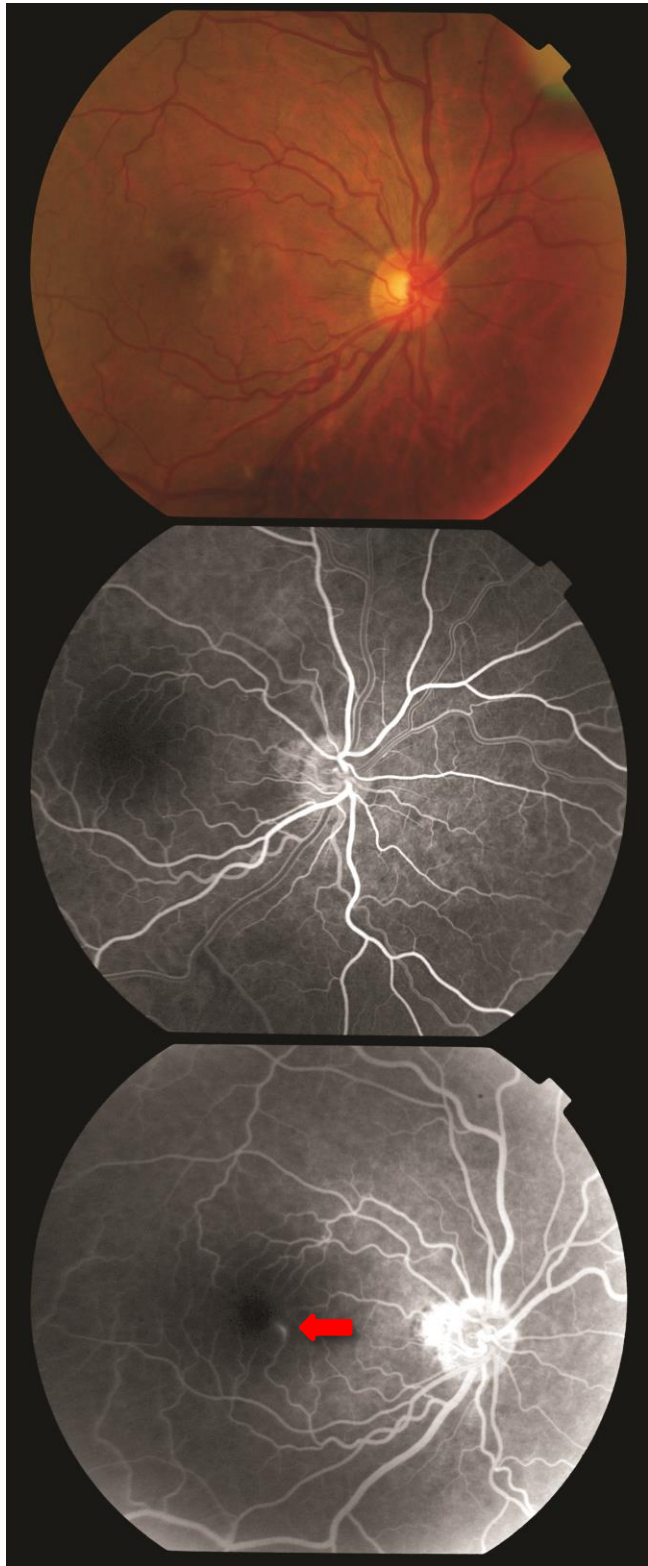
**Figure 4.3-4. Macular and foveal retinal whitening and late hyperfluorescence.**

Composite fundus photograph (top) and late phase fluorescein angiogram (bottom) of Bangladeshi adult with cerebral malaria showing moderate macular and foveal whitening with widespread hyperfluorescence indicating fluorescein leakage from vessels and a single white-centred flame haemorrhage with fluorescein masking (black arrows). Images were acquired with a portable retinal camera.



**Figure 4.3-5. Macular and foveal retinal whitening with hypoperfusion.**

Colour fundus photograph (top), early arterial phase fluorescein angiogram (middle) and middle phase fluorescein angiogram (bottom) of Indian adult with cerebral malaria showing macular and foveal whitening with perifoveal hypoperfusion in early phase angiogram and focal hyperfluorescence in late phase (e.g. red arrow). Images were acquired with a tabletop retinal camera.



## 4.4 Case report

### Reversibility of retinal microvascular changes in severe falciparum malaria

#### 4.4.1 Abstract

Malarial retinopathy allows detailed study of central nervous system vascular pathology in living patients with severe malaria. An adult with cerebral malaria is described who had prominent retinal whitening with corresponding retinal microvascular obstruction, vessel dilatation and increased vascular tortuosity and blood retinal barrier leakage with decreased visual acuity, all of which resolved on recovery. Further study of these features and their potential role in the pathogenesis of cerebral malaria are warranted.

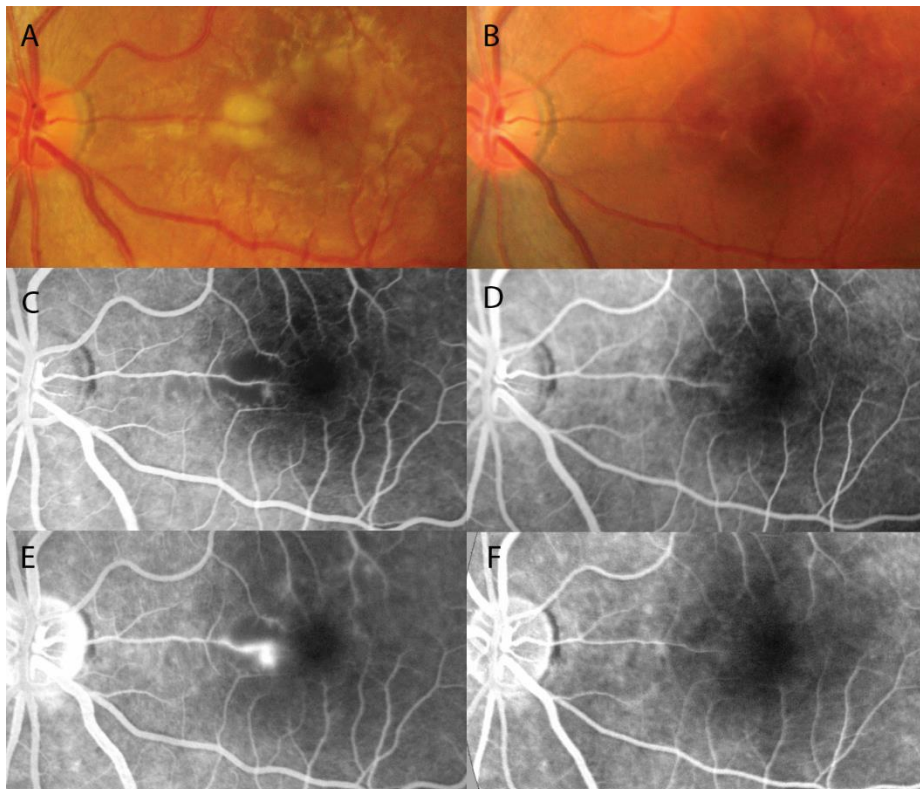
#### 4.4.2 Introduction

The pathogenesis of coma in falciparum malaria and its rapid reversibility are potential targets for adjunctive therapies but are not well understood. Microvascular obstruction is probably an important contributor. The brain microvasculature is relatively inaccessible so it can be studied in detail only at post mortem. Similarly, microvascular obstruction in the retina is thought to be a major contributor to the unique retinopathy of severe falciparum malaria and as it is easily visualised in living subjects, in depth study is providing new and valuable insights. We describe an adult patient with cerebral malaria who had prominent retinal changes with some previously unrecognised features which resolved on recovery.

#### 4.4.3 Case description

A 24-year-old male truck driver from Orissa, India was admitted with severe *P. falciparum* malaria (parasitemia 0.3%) with coma, generalized convulsions, hyperlactatemia, renal failure and black urine. He had no prior medical history. Retinal photography showed bilateral patchy macular whitening with corresponding capillary non-perfusion and leakage of fluorescein due to blood retinal barrier breakdown on fluorescein angiography (**Figure 4.4-1**). He was treated with intravenous artesunate and from recovery of

consciousness on day 3 until discharge, his visual acuity was markedly reduced (counting digits only) with loss of red green colour vision. Repeat examination on day 55 showed the retinal changes, angiogram abnormalities and visual deficits had resolved (acuity 6/9 bilaterally and normal colour vision). Blood vessel tortuosity was measured as the ratio of blood vessel path length to chord length in three arterioles and three venules in matched pairs of retinal photographs by a single masked observer. To measure blood vessel path length, the centre line of vessels was traced between branch points using Adobe Photoshop CS4 (Adobe Systems, CA, USA). Chord length was measured as a straight line along the same vessels.<sup>335</sup> Tortuosity was greater on day 0 than day 55 (mean ratios of vessel widths measured at 10 points in each vessel 1.226 in arterioles and 1.172 in venules, and vessel lengths 1.043 and 1.035). These differences are similar to those found previously in diabetic macular oedema.<sup>335</sup> Serum bicarbonate was normal and plasma lactate was raised at 4.8 mmol/l.



**Figure 4.4-1. Retinal photographs and fluorescein angiograms in severe falciparum malaria on admission and recovery.**

Retinal photographs (A and B) and fluorescein angiograms (arterial phase: C and D and late phase: E and F) of left eye. Day 3: increased vessel thickness and tortuosity plus patchy macular whitening (A) with corresponding areas of reduced perfusion (C) and fluorescein

leakage (**E**). Day 55: normal vessels, no whitening (**B**) and normal perfusion around the fovea (**D**) with no leakage of fluorescein (**F**).

#### 4.4.4 Discussion

Malarial retinal whitening is thought to be due to hypoxic opacification of the retina following obstruction of small blood vessels (predominantly capillaries and venules) by sequestered parasites.<sup>290,291</sup> It is similar to patchy ischaemic retinal whitening (PIRW), a transient early sign of central retinal vein occlusion (CRVO)<sup>290</sup> thought to represent intracellular oedema of overlying retinal intermediary neurones.<sup>336</sup> The degree of retinal whitening in adults and children correlates with severity of malaria and peripheral blood lactate.<sup>61,218</sup> Hyperlactemia is common in severe malaria at least partly due to obstruction of the systemic microcirculation by sequestered parasites. Cerebrospinal fluid lactate concentrations are also raised in cerebral malaria in which it is predictive of mortality.<sup>83</sup>

The appearance and distribution of retinal whitening are unique to severe falciparum malaria. Typically, there are multiple small lesions most prominent in the macula, particularly temporal to the fovea. This area is a watershed between the superior and inferior retinal vascular arcades and particularly vulnerable to ischaemic insults. Mid-peripheral involvement in malaria distinguishes it from PIRW, Purtscher's retinopathy and cotton wool spots (sometimes also seen in malaria), which are distributed particularly around the optic disk and are typically more opaque. Malarial retinopathy is considered reversible<sup>63,263</sup> but this case is the first published photographic evidence of reversibility.

The angiogram in this patient showed that the whitening corresponds closely to capillary non-perfusion. This has not been described previously in adults but is common in Malawian children with cerebral malaria.<sup>223</sup> Post-mortem studies in Malawi have found retinal blood vessels in cerebral malaria to be packed with sequestered parasites,<sup>234</sup> similar to findings in the brain in adults.<sup>64</sup> As retinal whitening<sup>63</sup> and CNS sequestration<sup>65,71</sup> are particularly prominent in patients with malarial coma (cerebral malaria) this suggests small blood vessel central nervous system (CNS) ischemia plays a major role in pathogenesis. This is supported by the finding of a raised plasma lactate. In addition, tissue infarcts and necrosis are rarely seen in post mortem studies of severe malaria suggesting either only small vessels are affected or large vessels are only transiently occluded. In survivors, malarial coma is rapidly



reversible and, as seen in the retina in this case, reversal of blood vessel obstruction is a plausible contributor.

This patient had mildly increased tortuosity of retinal blood vessels which decreased on recovery. Although increased vascular tortuosity has not been well-described in malaria, it is a recognized feature of other vascular-occlusive diseases of the retina. Vessel tortuosity is due to a combination of vessel dilation from radial stretching and the vessel taking a more serpentine path due to longitudinal stretching.<sup>337</sup> Several pathogenic mechanisms have been proposed for increased retinal vascular tortuosity including: in anaemia 1) increased blood flow; in diabetic retinopathy 2) impairment of autoregulation of vessel tone by some combination of disturbed blood flow, tissue hypoxia, endothelial dysfunction and increased vascular endothelial growth factor<sup>338</sup>; and in CRVO and raised ICP resulting in CRV compression 3) venous congestion causing elevated vascular pressure and dilatation of blocked vessels. In malaria, anaemia is common, uninfected red blood cells have reduced deformability, and sequestered parasites cause microvascular and venular obstruction. Angiogenesis is probably unimportant over the short timescale.<sup>335</sup>

Increased vascular tortuosity has not been well described previously in severe falciparum malaria possibly because the normal appearance of retinal vessels varies significantly between individuals and subtle changes are difficult to identify. Ophthalmoscopy revealed engorgement and tortuosity of retinal venules in 26% of children with cerebral malaria in Ghana which mostly resolved by one week.<sup>263</sup> In our patient comparison of retinal photographs provided a more objective measure. Means of quantifying vessel tortuosity using computer-aided image processing are under development. In **Chapter 2**, an analysis of retinal vessel tortuosity in *P. falciparum* malaria using one such computer-aided method is presented. This method was not applied in this case as it was only available for a subset of patients.

The angiogram in this patient showed focal leakage of fluorescein across the blood retinal barrier (BRB) in areas of nonperfusion suggesting a common etiology. The BRB is analogous to the blood brain barrier which is also mildly disrupted in cerebral malaria. Leakage from larger retinal vessels crossing ischaemic areas is a well-known phenomenon in retinal ischaemia. The significance of this as a contributor to the pathogenesis of malarial coma is not known. More angiographic studies are needed.

This case had decreased visual acuity which had resolved at follow-up. Although it is not possible to give a cause for this, it is the first report of an association between macular retinal whitening and decreased visual acuity with subsequent recovery.

#### **4.4.5 Conclusions**

Further studies of malarial retinopathy have potential to enhance our understanding of vascular changes in severe malaria. To maximise their impact, studies should use retinal photography where possible to allow detailed examination of the full range of fundus signs by multiple masked observers. This should be done both acutely and at follow-up. Fluorescein angiography provides a detailed map of CNS retinal perfusion. There is a need for further detailed studies to include assessment of vascular tortuosity to investigate its' role as a potential early and sensitive marker in studies of severe malaria. The rate of reversibility of malarial retinopathy has potential as an endpoint in intervention studies of severe malaria, particularly for adjunctive therapies which directly target the pathogenesis. Further information on the speed of reversibility of the various components of malarial retinopathy is needed and studies are underway to investigate this.

**Chapter 5 *P. falciparum* retinopathy and magnetic resonance  
imaging of the brain**

## Magnetic Resonance Imaging of the brain in adults with severe falciparum malaria

### 5.1 Abstract

MRI allows detailed study of structural and functional changes in the brain in patients with cerebral malaria. In a prospective observational study in adult Bangladeshi patients with severe falciparum malaria, MRI findings in the brain were correlated with clinical and laboratory parameters, retinal photography and ONSD) ultrasound (a marker of ICP). Of 43 enrolled patients, 31 (72%) had coma and 12 (28%) died. MRI abnormalities were present in 79% overall with mostly mild changes in a wide range of anatomical sites. There were no differences in MRI findings between patients with cerebral and non-cerebral or fatal and non-fatal disease. Subtle diffuse cerebral swelling was common (n=22/43) but mostly without vasogenic oedema or raised ICP (ONSD). Also seen were focal extracellular oedema (n=11/43), cytotoxic oedema (n=8/23) and mildly raised brain lactate on magnetic resonance spectroscopy (n=5/14). Abnormalities were much less prominent than previously described in Malawian children. Retinal whitening was present in 36/43 (84%) patients and was more common and severe in patients with coma. Cerebral swelling is mild and not specific to coma or death in adult severe falciparum malaria. This differs markedly from African children. Retinal whitening, reflecting heterogeneous obstruction of the central nervous system microcirculation by sequestered parasites resulting in small patches of ischemia, is associated with coma and this process is likely important in the pathogenesis

### 5.2 Introduction

Severe falciparum malaria is a multi-organ disease with a treated mortality of 10 to 30%. There are differences in clinical presentation<sup>12</sup> and pathological findings<sup>339</sup> between adults and children. Coma (defining cerebral malaria) is one of the commonest features and is an independent risk factor for mortality in all age groups.<sup>12</sup>

The pathogenesis of coma in malaria is not well understood. This has hampered efforts to develop adjunctive therapies to reduce mortality. Much of our knowledge comes from autopsy studies which only provide information on fatal cases.<sup>339</sup> Due to inaccessibility of the brain, studies in living subjects with cerebral malaria have been mostly limited to measurement of indirect markers.<sup>340</sup> Several processes are thought to be important including

microvascular obstruction by sequestered erythrocytes, inflammation, endothelial dysfunction with increased BBB permeability, and cerebral oedema. The relative contribution of these processes is unclear.

Brain imaging by CT and MRI allow direct observation of the brain in living subjects. As malaria occurs predominantly in resource-limited settings, imaging studies have been limited to mostly single cases and small case series. Larger studies and more advanced MRI techniques might allow for more in-depth study of not only structural but also functional changes in the brain, including assessment of oedema, haemorrhage, ischaemia, and brain metabolism. Systematic study of cerebral malaria using advanced MRI could provide fundamental additional insights into our understanding of this disease.<sup>340</sup>

A recent study using MRI compared findings in unconscious African children with and without malarial retinopathy.<sup>175</sup> In this context, absence of malarial retinopathy is thought to indicate an alternative non-malarial cause of coma. Findings of markedly increased brain volume, abnormal T2 signal intensity, and diffusion weighted imaging (DWI) abnormalities in cortical, deep gray and white matter structures were much commoner in patients with retinopathy suggesting these MRI findings are specific to malaria. In this study insights into pathogenesis were limited by lack of a control group of severe but non-comatose patients, so that the specificity of the changes could not be determined.

We here report a prospective observational study using a variety of MRI techniques aiming to determine the structural and functional changes in the brain in adult patients with severe falciparum malaria.

## 5.3 Methods

### Study Site and Patients

The study was carried out in Chittagong Medical College Hospital, Chittagong, Bangladesh, from June 2009 to August 2011. Ethical approval was obtained from the Bangladesh Medical Research Council Ethical Committee and OXTREC, the University of Oxford Tropical Research Ethics Committee.

Consecutive adult ( $\geq 16$  years) patients with slide-confirmed severe falciparum malaria, according to modified WHO criteria,<sup>54</sup> were eligible for inclusion. Cerebral malaria was defined as GCS (GCS)  $< 11$  out of 15 in the absence of hypoglycaemia ( $< 2.2$  mmol/L). Severe but non-cerebral malaria was defined as GCS  $\geq 11$  plus one or more of the other severity criteria listed in **Table 5.4-1** (Results).

Patients were excluded if they died before imaging could be done or if MRI was deemed unsafe (due to shock (systolic blood pressure  $< 80$  mm Hg with cool extremities), hypoglycaemia (blood glucose  $< 2.2$  mmol/L), or signs of respiratory insufficiency (respiratory rate  $> 32$ /min, nailbed oxygen-saturation  $< 90\%$  by pulse oximetry, signs of pulmonary oedema on physical exam or chest x-ray)) or the presence of metallic devices or pregnancy. Those with documented allergy to MRI contrast media or acute renal failure (serum creatinine  $> 1.4$  mg/dL and estimated glomerular filtration rate (eGFR)  $< 30$  mL/min<sup>341</sup>) did not receive contrast media.

### **Study procedures**

On admission a full history and examination were carried out. Blood samples were taken for haemoglobin, haematocrit, parasite count, platelet count, white cell count, glucose, plasma lactate, full biochemistry and *Pf*HRP2 (as a marker of parasite biomass<sup>28</sup>). All patients underwent retinal photography (using a Kowa Genesis D retinal camera, Kowa Company Ltd., Tokyo, Japan) through dilated pupils on admission with 'masked' analysis by a single observer (RJM) grading severity findings according to published classification criteria.<sup>277</sup> From 2011 onwards patients also underwent orbital ultrasound (Accutome B-scan Plus, Accutome Inc., Malvern, PA, USA) to determine optic nerve sheath diameter as a marker of ICP. Each ultrasound was recorded on video and later scored by two masked observers (RJM and RRM) according to previously described methods.<sup>342</sup>

### **MRI scanning**

Imaging of the brain was performed using either a 1.5T (Magnetom Avanto, Siemens AG, Erlangen, Germany) or a 0.3T (Airis II, Hitachi Medical Corporation, Tokyo, Japan) MRI scanner. The 1.5T scanner was available from 2010 onwards. Availability of gadolinium contrast medium was limited throughout the study. Scanning was done on the 1st day of admission when possible (up to a maximum 48 hours after admission).

The MRI sequences performed were as follows: for both 0.3 and 1.5 T scans: 1. Sagittal T1-weighted images to identify midline and Anterior-Posterior Commissure (AC-PC) line for slice positioning and evaluate swelling and major venous sinus patency; 2. Axial T2-weighted and Fluid Attenuated Inversion Recovery (FLAIR) turbo spin echo for lesion identification; 3. Axial T1-Spin Echo (T1-SE) after contrast (dimeglumine gadopentetate, 4690mg in 10ml, Bayer Schering Pharma AG, Berlin, Germany), in stable patients with normal renal function on enrollment repeated after 10 minutes; 4. Gradient Echo (GRE) for micro-haemorrhages. For 1.5 T scans: 5. Axial trace-diffusion weighted imaging (DWI) (b-values 0, 500, 1000 s/mm<sup>2</sup>); and 6. Single-voxel Magnetic Resonance Spectroscopy (MRS) of the parietal grey matter (2x2x2 cm) using Short Echo Time (TE)-Stimulated Echo Acquisition Mode (STEAM).

Image analysis consisted of: 1. Visual rating of infarcts and white matter lesions on FLAIR/T2; 2. Determination of cytotoxic edema from DWI with confirmation by ADC maps; 3. Assessment of cerebral swelling from sagittal T1 and axial FLAIR/T2 as none, mild, severe; 4. Detection of haemorrhage and venous patency; 5. Calculation of metabolite ratios (Choline/creatinine, N-acetyl aspartate (NAA)/Creatinine and Lactate/Creatinine) using MRS on a 2cm<sup>3</sup> cube of parietal cortex; and 6. Determination of blood brain barrier (BBB) leakage from T1-SE scans. Image analysis was done by a single expert (FB) masked to all demographic and clinical information.

### **Drug and supportive treatments**

Antimalarial treatment was with intravenous artesunate followed by artemether-lumefantrine when the patient was recovering, with supportive treatment in accordance with 2006 and 2010 WHO guidelines<sup>13,343</sup> and local hospital guidelines, although access to mechanical ventilation and renal replacement therapy was limited.

### **Statistical Analysis**

Numbers of patients were compared using Chi-square with Yate's correction or Fisher's exact tests as appropriate. When appropriate, data were log transformed to obtain a normal distribution. Normally distributed data were compared using Student's t test. The Mann-

Whitney U test was used for unpaired nonparametric data. The level of significance was  $p < 0.05$ .

## 5.4 Results

During the study period, 97 adults were admitted with severe falciparum malaria. No scanner was available for 35 patients, and 12 died before having MRI. MRI was contraindicated in 5 with respiratory insufficiency and 2 with hypoglycaemia. The remaining 43 patients had MRI scans. In 9/43 (21%) image quality was reduced due to movement of the patient during the scan.

The 1.5T scanner was used on 26/43 (60%) patients (17 cerebral, 9 non-cerebral) and 0.3T on 17/43 (40%) patients (14 cerebral and 3 non-cerebral). The median (interquartile range (IQR)) time from enrollment to MRI scan was 22.6 (3.7-29.5) hours. 17/43 (40%) scans (13 with the 1.5T scanner) were done within the first 10 hours of admission.

Of those enrolled, 31/43 (72%) had cerebral and 12/43 (28%) non-cerebral but severe disease. Infections were fatal in 12/43 (28%). Median (range) age was 30 (16-75) years; 35/43 (81%) were male. Severity criteria on enrollment are listed in **Table 5.4-1**.



**Table 5.4-1. Presenting severity signs of enrolled patients.**

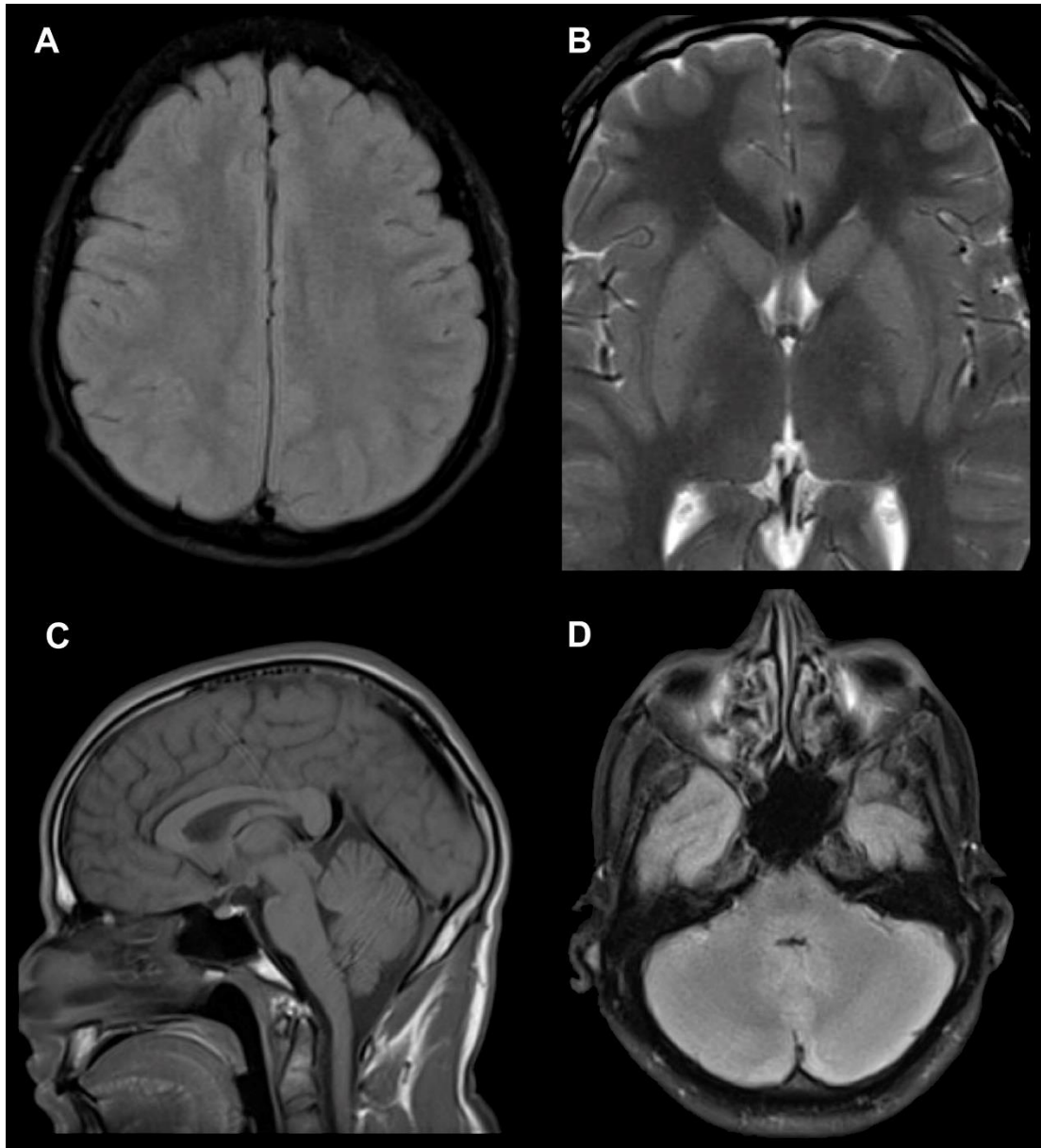
	Number (%) (n=43)
Cerebral malaria (GCS < 11)	31 (72%)
Venous lactate >4 mmol/l	20 (47%)
Jaundice (bilirubin >2.5 mg/dl + parasites >100,000/mm <sup>3</sup> )	9 (21%)
Hyperparasitaemia (>10%)	8 (19%)
Generalized convulsions (≥2 in 24 hours)	7 (16%)
Acidosis (venous bicarbonate <15 mmol/l)	6 (14%)
Renal failure (creatinine >3g/dL or anuria)	5 (12%)
Severe anaemia (Hct < 20% + parasites > 100,000/mm <sup>3</sup> )	3 (7%)
Spontaneous bleeding	1 (2%)
Hypoglycaemia (blood glucose <40 mg/dl)	1 (2%)
Pulmonary oedema	0 (0%)
Shock (systolic BP<80 + cool peripheries)	0 (0%)

**MRI**

MRI findings are summarized in **Table 5.4-2**. Examples of MRI findings are shown in **Figure 5.4-1**. Overall, 34/43 (79%) patients had abnormalities on MRI; 12/17 (71%) by 0.3T and 22/26 (85%) by 1.5T scan ( $p=0.44$ ). These abnormalities were found in a variety of anatomical sites: in the supratentorial region (ST) in 22/43 (44%) (including basal ganglia (BG) in 9/43 [21%]), and posterior fossa (PF) in 16/43 (37%). There were no differences in MRI findings between individuals with cerebral and non-cerebral malaria and no differences between fatal and nonfatal infections. This was true for all MRI sequences and at all anatomical locations.

Table 5.4-2. MRI findings in 43 Bangladeshi patients with severe and cerebral malaria.

MRI abnormality	Location/type	Overall (n=43)	Cerebral (n=31)	Non-cerebral (n=12)	P	Died (n=12)	Survived (n=31)	P
All	All	34 (79%)	24 (77%)	10 (83%)	1	9 (75%)	25 (81%)	0.69
High signal on T2/FLAIR	All	11 (26%)	8 (26%)	3 (25%)	1	2 (17%)	9 (29%)	0.7
Swelling	All	23 (53%)	17 (55%)	6 (50%)	1	7 (58%)	16 (52%)	0.74
	Supratentorial	17 (40%)	13 (42%)	4 (33%)	0.73	5 (42%)	12 (39%)	1
	Posterior fossa	18 (42%)	12 (39%)	6 (50%)	0.52	7 (58%)	11 (35%)	0.3
	ST and PF	11 (26%)	7 (23%)	4 (33%)	0.47	5 (42%)	7 (23%)	
	Basal ganglia	2 (5%)	2 (6%)	0 (0%)	1	0 (0%)	2 (6%)	1
Atrophy	All	3 (7%)	1 (3%)	2 (17%)	0.18	0 (0%)	3 (10%)	0.55
Haemorrhage	All	0 (0%)	0 (0%)	0 (0%)	1	0 (0%)	0 (0%)	1
High signal on DWI	Total done	23	15	8		7	16	
	Abnormal	8 (35%)	7 (47%)	1 (13%)	0.18	3 (43%)	5 (31%)	0.66
MRS high ratio	Total done	14	9	5		7	7	
	Choline/creatinine	5 (36%)	2 (22%)	3 (60%)	0.27	3 (43%)	2 (29%)	1
	NAA/creatinine	0 (0%)	0 (0%)	0 (0%)	1	0 (0%)	0 (0%)	1
	Lactate/creatinine	5 (36%)	4 (44%)	1 (20%)	0.58	2 (29%)	3 (43%)	1
Gadolinium enhanced	Total done	5	4	1		2	3	
	Venous congestion	2 (40%)	2 (50%)	0 (0%)	1	1 (50%)	1 (33%)	1



**Figure 5.4-1. Examples of MRIs from 4 patients with severe malaria.**

**A** diffuse moderate supratentorial swelling on FLAIR with obliteration of sulcal pattern, **B** bilateral swollen striatum on T2 with mildly increased signal intensity and blurred borders, **C** diffuse mild supratentorial and marked posterior fossa swelling on T1 and **D** marked posterior fossa swelling and mild signal increase on FLAIR.

The commonest abnormalities were mild degrees of diffuse swelling in the supratentorial region and/or posterior fossa. In 19/22 (86%), this swelling was mild, 2/22 moderate (1 PF and 1 ST) and 1/22 marked (PF). Diffuse swelling was present in both ST and PF in 12/22 (55%), 5/22 only in the PF and 5/22 only in the ST including 2/5 only in the BG. There was

no supra- or infratentorial brain herniation visible in any of the patients. On T2 weighted and fluid attenuated inversion recovery (FLAIR) imaging the swollen areas showed a normal signal in 16/22 (73%) indicating the swelling is not due to extracellular (vasogenic) oedema. Of the other 6 cases, 4 had a high signal only in the basal ganglia whereas swelling of the brain was diffuse in both the ST and PF in 2 of these cases. In addition 7/13 (54%) patients had normal DWI in the swollen areas indicating that most of the swelling was not due to cytotoxic oedema. Gadolinium contrast was given to 4 patients with swelling and 1 without. Two of those with swelling had venous congestion, both of these had coma, one of whom died. Of those with swelling but no venous congestion one had coma and one did not. The patient without swelling or venous congestion was comatose on enrollment.

Overall, high signal on T2/FLAIR was present in 11/43 (26%) patients with most having focal lesions; 4 of these had lesions only in the basal ganglia (2 diffuse and 2 in striatum only), 2 only in the globus pallidus, 1 in globus pallidus and pons, 1 in corpus callosum, 1 widespread in cerebral cortex, 1 in parietal cortex and 1 in the cerebellum.

On DWI, 8/23 (31%) were abnormal. 7/8 (88%) of these had coma (1/8 versus 7/8  $p=0.18$ ) and 3/8 (38%) were fatal (3/8 versus 5/8  $p=0.66$ ). High signal was present diffusely in the cerebral cortex in 3/23 (13%) patients (throughout the cortex and basal ganglia ( $n=1$ ), throughout the cortex and around the superior colliculus ( $n=1$ ) or only subtle changes in the parieto-occipital cortex and the putamen ( $n=1$ ). 2/3 of those with diffuse high cortical signal on DWI had coma. Another patient had subtle high signal throughout the cerebellum. Isolated focal high signal was also seen on DWI in the globus pallidus (1 patient), putamen (1 patient) and splenium (2 patients). Abnormal areas on DWI corresponded to high signal on T2/FLAIR in 5 patients (1 diffuse cerebral cortex and superior colliculus, 1 splenium of corpus callosum, 1 globus pallidus, 1 striate and 1 cerebellum).

On magnetic resonance spectroscopy (MRS), 10/14 (71%) had abnormalities: 5 mildly raised choline/creatinine ratios, 5 mildly raised lactate/creatinine ratios and none had raised N-acetylaspartic acid/creatinine ratios. Raised lactate was not associated with diffuse changes on DWI. There was no difference in mean (95%CI) peripheral blood lactate in those with (4.48 [3.26-5.70] mmol/L) and without (5.16 [3.4-6.92] mmol/L,  $p=0.61$ ) a raised lactate/creatinine ratio on MRS.

None of the patients had haemorrhages or microhaemorrhages on gradient echo (GRE) and no incidences of cerebral venous thrombosis were detected.

### **ONSD**

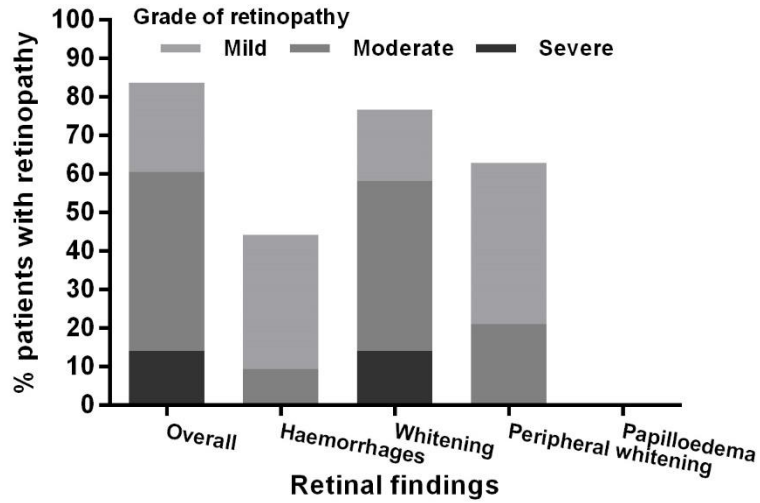
Measurement of ONSD was done in 14 patients. Median (range) ONSD was 4.77 (4.32-4.96) mm. In those with swelling on MRI (n=10), ONSD was 4.77 (4.38-4.96) mm vs 4.62 (4.32-4.94) mm in those without swelling (n=4, P=0.67). Using a cut-off of 4.75 mm for this population,<sup>342</sup> 8/14 patients had abnormally enlarged ONSD, 6/10 (60%) with swelling and 2/4 (50%) without (P=0.61). There was no difference in ONSD between those with and without coma (p=0.60) and those with fatal and nonfatal infections (p=0.69).

### **Retinopathy**

Retinal photography was performed in all patients (**Figure 5.4-2**). The results presented here are a subset of those presented in **Chapter 2**, hence the percentages are different because of this. 36/43 (84%) had malarial retinopathy; 26/43 (60%) had moderate to severe retinal changes which were more common in those with coma (22/31 (71%)) than those without coma (3/12 (25%)), p=0.014, **Figure 5.4-3**). None had papilloedema. Moderate-severe peripheral retinal whitening was only present in those with coma (9/31 (29%)) and not in those without (0/12 (0%)), p=0.044). An example of this is shown in figure 4. Moderate-severe retinal whitening was not associated with raised lactate on MRS (4/5 (20%) with raised lactate vs 5/10 (50%) without, p=0.58).

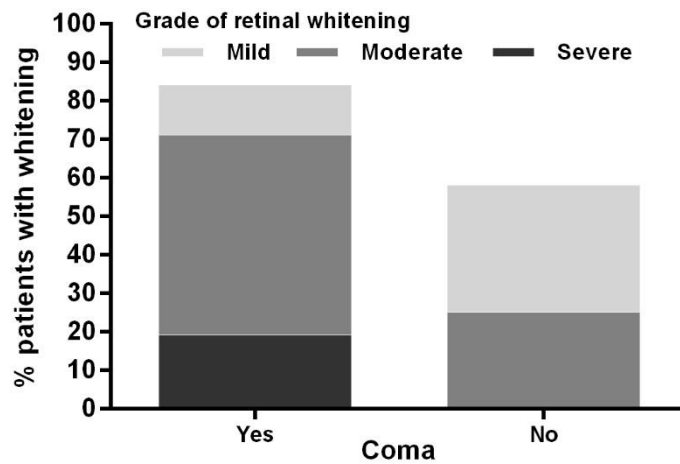
### **Sequestered biomass**

There was no difference in median (range) plasma *Pf*/HRP2 concentration, total calculated parasite burden<sup>28</sup> or calculated proportion of sequestered biomass between those with swelling on MRI and those without (p=0.27, 0.11 and 0.14). Those with venous congestion after contrast and moderate to severe cortical swelling did not have a higher sequestered biomass than the rest of the cohort.



**Figure 5.4-2. Summary of retinal findings.**

Severity is defined in **Appendix 10.1**.



**Figure 5.4-3. Proportion of patients with and without coma with different grades of retinal whitening.**

Severity is defined in **Appendix 10.1**.

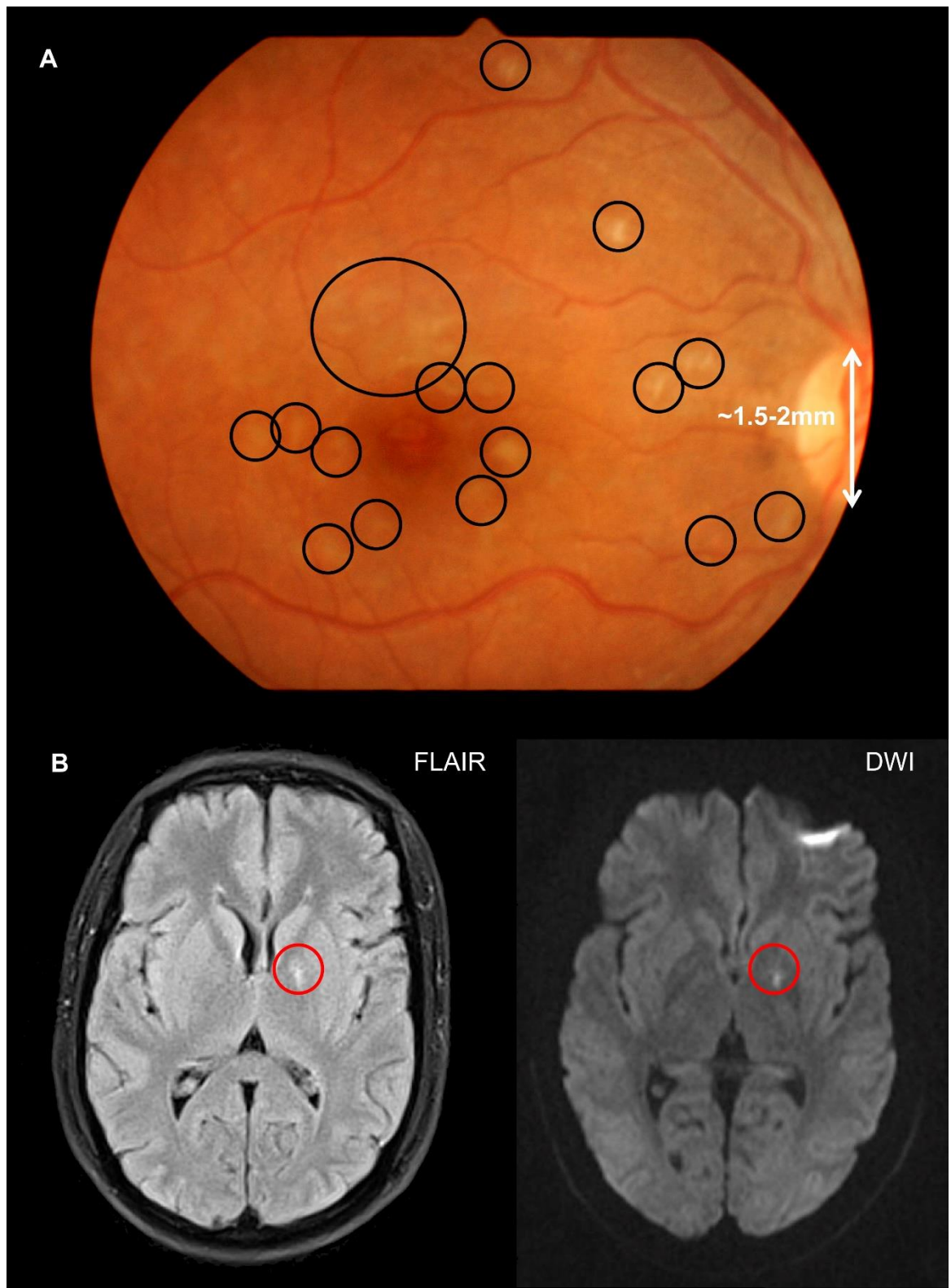


Figure 5.4-4. Retinal photograph and MRI from patient with cerebral malaria (GCS=8 on enrollment), hyperlactaemia and 98% sequestered biomass.

A. the retina has typical lesions of retinal whitening (black circles) in the macula and fovea. Using the vertical optic disc diameter (white) as reference<sup>344</sup>, each lesion of whitening is estimated at around 0.2-0.5mm diameter. B on MRI the only abnormality was high signal in the globus pallidus on T2/FLAIR (left) and DWI (right).

## 5.5 Discussion

This study describes a wide variety of mostly subtle changes on brain MRI in adults with severe falciparum malaria. None of the changes were more frequent in those with coma compared to severe disease without coma, or in patients with fatal disease compared to survivors. Diffuse mild brain swelling was present in the majority without evidence of diffuse cerebral oedema, either cytotoxic (on DWI) or vasogenic (T2 and FLAIR). This swelling was probably at least partly due to venous congestion of the sequestered parasitized red cell mass causing increased cerebral blood volume, whereas no venous thrombosis was detected. This lack of thrombosis is consistent with previous post mortem studies in adults with severe malaria,<sup>253</sup> despite activation of the coagulation cascade in severe malaria. In contrast, in paediatric cerebral malaria in addition to red cell sequestration, intravascular accumulation of mononuclear cells, platelets and fibrin strands are more commonly observed.<sup>100</sup> The reason for this difference is not understood. The observed brain swelling was considered insufficient to cause coma and was in addition not specific to coma or fatal disease in this series and not correlated to ONSD. The MRI changes thus appear not to be in a causal relationship with observed neurological symptoms.

In this study, most patients had retinal whitening which was mostly diffuse small patches and commoner and more severe in those with coma. The retina is part of the central nervous system (CNS) and whitening is thought to be due to ischaemia as a result of heterogeneous obstruction of the microvasculature by sequestered parasites.<sup>291</sup> As the retinal vasculature is very similar to that in the brain, it strongly suggests that ischaemia would also occur in the brain. In autopsy studies the amount of sequestration and microvascular congestion in the brain has been shown to correlate with coma in malaria.<sup>65</sup> On brain MRI in the present study there was a lack of diffuse ischaemic changes on DWI and complete absence of haemorrhages on GRE. This may be because MRI is insufficiently sensitive to detect small lesions of very focal ischaemia. Retinal lesions seen in this study were typically 0.2-0.5mm



in diameter and brain haemorrhages on post-mortem studies of fatal malaria are typically microhaemorrhages.<sup>345</sup> 1.5T MRI is limited to 1mm for T1 and T2 and 2mm or more for DWI.<sup>346</sup> Ultrahigh-field MRI at 7 or 8T would be required to show lesions of this magnitude on T2/FLAIR imaging<sup>347</sup> and 1mm on DWI.<sup>348</sup> Such scanners are generally not available in the resource poor areas where malaria is common.

A minority of patients had raised lactate on MRS, although raised CSF lactate in cerebral malaria is common.<sup>82</sup> MRS in this study was limited to a single voxel in the parietal cortex but ischaemic lesions were predominant in the brainstem and basal ganglia. Systemic markers of ischaemia (blood lactate) and sequestered biomass did not correlate with the findings on MRI. This may reflect the heterogeneous distribution of parasite sequestration in different organs in the body as shown in autopsy studies.<sup>73</sup> Explanations for this include differences in endothelial cell surface receptors in different tissues,<sup>72</sup> and between individuals.

The MRI and retinal findings in this study contrast to those seen in previous studies in African children.<sup>175</sup> In both populations, lesions in the brain in severe malaria were found in a broad range of anatomical locations. However, the type and severity of abnormalities seen was markedly different. The most common abnormality in Malawi was basal ganglia lesions, present in >80% compared to 23% in the present study. Brain swelling was much less severe in the present study than in African children<sup>174,175</sup>. In previous imaging studies most adults with cerebral malaria had little evidence of cerebral oedema<sup>184,349</sup>, or showed mostly moderate brain swelling not correlating with coma depth.<sup>46</sup> High signal on T2 associated with thickening of the supratentorial cortex was present in the majority of Malawian children.<sup>175</sup> In contrast to Bangladeshi adults, this suggests the swelling in Malawian children was at least partly due to oedema. In many of these children, the T2 changes were confluent and in some associated with diffuse abnormalities on DWI. These larger lesions than found in adults mirror those seen in the retina; confluent patches of retinal whitening being common in African children with cerebral malaria but absent in Bangladeshi adults.<sup>61,220</sup>

In adults, a slight increase in brain volume has been attributed to increased intracranial blood volume probably as a consequence of sequestration of parasitized erythrocytes.<sup>349</sup> The present study appears to confirm this by finding brain swelling and venous congestion without signs of increased ICP. Raised ICP in children<sup>180</sup> and the extent of brain swelling on CT in adults<sup>46,186</sup> are unrelated to mortality and depth of coma. Mannitol to reduce ICP in cerebral malaria did not improve outcome in adults<sup>46</sup> or children.<sup>350</sup> The exact role of raised

ICP in the pathogenesis of cerebral malaria is unclear, but seems to play only a minor role in adults. Rather than a primary cause for coma it is more likely a feature developing in the later stages of the disease.

This study had several limitations. It was not possible to perform all MRI sequences in all patients due to limited availability of scanners and patients being too unwell or restless. MRI was not performed in half of the fatal cases who died shortly after admission, which could have confounded the selection of patients. However, as most MRIs were done on the day of admission, and all within 48 hours, it seems unlikely that this will have had a major effect on our findings.

The mechanisms of coma and death in malaria are probably multifactorial and individual factors might contribute to different degrees between individuals. Subtle variations in the amount and location of sequestration and swelling may lead to coma in some individuals but not be apparent on MRI. Sequestration could target neurotoxic substances produced by the parasite. Changes in areas that do not determine consciousness could be obvious on MRI but not result in coma. In addition, metabolic disturbance outside the brain, e.g. toxic substances in the blood, may cause coma and death with a normal MRI appearance.

MRI has great potential to further elucidate the pathogenesis of coma and death in malaria. Future studies should use MRS to study metabolic disturbance in different parts of the brain and gadolinium contrast to quantify cerebral perfusion and map venous congestion. The availability of increasingly sophisticated scanning software and more powerful scanners should greatly assist in these efforts.

## 5.6 Conclusions

A variety of abnormalities were identified with different MRI techniques in adult patients with severe falciparum malaria. Mild brain swelling likely caused by venous congestion was common but much less severe than previously seen in Malawian children. MRI findings in non-comatose individuals with severe malaria have not previously been examined. None of the observed changes on MRI were specific to patients with coma or fatal disease suggesting the processes they represent are not central to their pathogenesis.

## **Chapter 6 Retinopathy in *P. knowlesi* malaria**

---

**Retinal changes in uncomplicated and severe *Plasmodium knowlesi* malaria****6.1 Abstract**

*Plasmodium knowlesi* is now the commonest cause of malaria in Malaysian Borneo and three times more likely to cause severe malaria than *P. falciparum*, however little is known about its pathogenesis. A specific retinopathy has been well described in severe falciparum malaria and provides insights into the pathophysiology of malarial coma. Retinal changes in *knowlesi* malaria have not been studied. An observational study of retinopathy in 44 hospitalised Malaysian adult patients with PCR-confirmed *P. knowlesi* malaria (20 severe, 24 non-severe), was conducted using indirect ophthalmoscopy (all patients) and fundus photography (29 patients). Median age of patients was 44 years (range 18 – 74 years). No coma or deaths occurred. Photography was more sensitive than indirect ophthalmoscopy for detecting retinal lesions. On photography, retinal changes other than drusen were present in 5/12 (42%) patients with severe *knowlesi* and 8/17 (47%) patients with non-severe *knowlesi* malaria. Retinal whitening occurred in 3 (35%) and 5 (29%) patients with severe and non-severe *knowlesi* malaria, respectively, and was mild in all; haemorrhages occurred in 2 (17%) and 3 (18%), respectively; and loss of retinal pigment epithelium in 1 (8%) and 4 (24%). Drusen were present in 9 (71%) and 12 (75%). All changes were mild, with no differences between patients with severe and non-severe disease. Patients with retinal haemorrhages had a lower median (IQR) platelet count than those without haemorrhages (22 [13.5-38.5] x10<sup>9</sup>/L vs 43 [27.5-72] x10<sup>9</sup>/L, p=0.039). The paucity of specific retinal findings and lack of correlation with disease severity in *Plasmodium knowlesi* malaria contrast with the retinal findings reported in falciparum malaria and suggests that pathophysiological mechanisms differ. Microvascular obstruction in the central nervous system does not appear to be an important contributor to the pathophysiology of severe *knowlesi* malaria.

**6.2 Introduction**

The simian parasite, *Plasmodium knowlesi* is increasingly recognized as a cause of uncomplicated and severe human malaria in South East Asia<sup>351-358</sup> and is now the commonest cause of malaria in Malaysian Borneo.<sup>351-353</sup> Although three times more likely to cause severe disease than *P. falciparum*,<sup>359</sup> little is known about its pathogenesis. In

falciparum malaria, a unique retinopathy has been described that has provided insights into the pathogenesis of severe and fatal falciparum malaria in both children<sup>223,234,360</sup> and adults.<sup>361,362,363</sup> This consists of retinal whitening (macular or peripheral), vessel discoloration (white or orange), retinal haemorrhages (particularly with white centres) and/or papilloedema.<sup>363</sup>

Falciparum retinopathy is thought to be largely due to cytoadhesion and sequestration of parasitized erythrocytes in the retinal microvasculature.<sup>267</sup> As the retinal microvasculature is similar to the cerebral microvasculature, these changes reflect the cytoadhesion and sequestration that cause coma in cerebral falciparum malaria.<sup>364</sup> In knowlesi malaria, coma, with the exclusion of other causes, has not been reported to date and in the single human autopsy report of fatal knowlesi malaria cytoadherence to endothelial cells was not clearly apparent despite the accumulation of parasitized erythrocytes within cerebral vessels.<sup>365</sup> Early studies in rhesus monkeys suggested red cell clumping and sludging may underlie microvascular obstruction in knowlesi malaria.<sup>366-368</sup> Pathogenesis of disease in severe knowlesi malaria may therefore differ from that of severe falciparum malaria. Retinal findings in knowlesi malaria have not been described, and may provide insights into these different mechanisms of disease.

A prospective observational study was undertaken to determine the spectrum of retinal findings in severe and non-severe knowlesi malaria, as compared to those previously reported in patients with severe and non-severe falciparum malaria.

## 6.3 Methods

### Study site and patients

This study was conducted from December 2010 – September 2011 alongside a prospective clinical and epidemiological study of all malaria patients admitted to Queen Elizabeth Hospital, an adult tertiary referral hospital in Kota Kinabalu, Sabah, Malaysia.<sup>359</sup>

Consecutive patients with PCR-confirmed *P. knowlesi* mono-infection underwent retinal examination if they were non-pregnant,  $\geq 12$  years old, had no major comorbidities or concurrent illness, were within 96 hours of commencing antimalarial treatment, had not been previously enrolled in the study, were willing and able to cooperate with eye examination, had no contraindications to tropicamide or phenylephrine eye drops, and did not have severe

bilateral corneal scarring or cataracts precluding funduscopy. Clinical details of these patients have been previously reported.<sup>359</sup> Severe malaria was defined as the presence of  $\geq 1$  of: unrousable coma (GCS  $< 11$ ); multiple ( $> 2$ ) convulsions; respiratory distress (respiratory rate  $> 30$  breaths per minute and oxygen saturation  $< 94\%$ ); hypotension (systolic blood pressure  $\leq 80$  mm Hg); jaundice (bilirubin  $> 43$   $\mu\text{mol/L}$  plus parasitemia  $> 20\,000/\mu\text{L}$  and/or creatinine  $> 132$   $\mu\text{mol/L}$ ); significant abnormal bleeding; hypoglycaemia (blood glucose  $< 2.2$  mmol/L); metabolic acidosis (bicarbonate  $< 15$  mmol/L or lactate  $> 4$  mmol/L); severe anaemia (haemoglobin  $< 7.0$  g/dL); acute kidney injury (AKI; creatinine  $> 265$   $\mu\text{mol/L}$ ); hyperparasitemia ( $> 100,000$  parasites/ $\mu\text{L}$ ). Informed consent was provided by study participants or their guardian. The study was approved by the Ethics Committees of the Malaysian Ministry of Health and Menzies School of Health Research.

### Study procedures

Standardized history and physical examination were documented. Haematology, biochemistry, acid-base parameters, and lactate (by bedside blood analysis; iSTAT system) were obtained on admission. Parasite counts were determined by microscopy, and parasite species were identified by PCR.<sup>369,370</sup> Patients were treated according to hospital guidelines, as previously described.<sup>359</sup>

Assessment of visual function and detailed eye examination were performed by one of five experienced ophthalmologists. Visual function assessment included testing of visual acuity using a 6 meter Snellen chart (converted to logMAR<sup>258</sup> for analysis), colour vision using a D15 chart, and visual fields using automated perimetry as compared to normative data (Humphrey Field Analyzer, Carl Zeiss Meditec, Dublin, CA). Detailed eye examination included pupillary light reaction, anterior segment slit lamp examination, intraocular pressure measurement (Slit Lamp Mounted Goldmann Applanation Tonometer, Carl Zeiss Model: SL115 Classic with AT 020) and fundus examination by indirect ophthalmoscopy 30 minutes after administration of tropicamide and/or phenylephrine eye drops for mydriasis. Fundus photography was performed using a 9 field protocol on patients able to be transported to the fundus camera (TopCon Medical Systems). Fundus fluorescein angiography (Heidelberg Retina Angiograph 2, Heidelberg Engineering, Germany) was performed in one patient with abnormal retinal findings. Retinal photographs were reread masked and findings agreed by consensus between four observers (RJM, SB, BD and GG). Where appropriate, retinal findings were classified as mild, moderate or severe according to a previously published classification for *P. falciparum* malarial retinopathy.<sup>260</sup>

**Statistical analysis**

Statistical analysis was performed using GraphPad Prism version 6.01 (GraphPad Software, Inc, La Jolla, USA). Intergroup differences were compared using Mann-Whitney test for continuous variables or Chi Square/Fisher's exact test for categorical variables.

**6.4 Results**

A total of 44 patients were enrolled, including 20 with severe and 24 with non-severe *knowlesi* malaria. Baseline demographics are shown in **Table 6.4-1**. Patients with severe *knowlesi* malaria were older than those with non-severe *knowlesi* malaria (median [IQR] age 51.5 [40 – 55] vs. 40.5 [24 – 48.5] years,  $p=0.018$ ). Eight patients had a history of hypertension (3 with severe *knowlesi* malaria and 5 with non-severe *knowlesi* malaria). No patient had diabetes, and no patient reported having had malaria in the previous 2 months. Among the 20 patients with severe *knowlesi* malaria, severity criteria included jaundice ( $n=11$ , 55%), hyperparasitemia ( $n=11$ , 55%), respiratory distress ( $n=8$ , 40%), hypotension ( $n=6$ , 30%), acute kidney injury ( $n=3$ , 15%), metabolic acidosis ( $n=2$ , 10%), and abnormal bleeding ( $n=1$ , 5%). Seven patients (35%) had one severity criterion, 7 (35%) had 2 criteria, 3 (15%) had 3 criteria, and 3 (15%) had 4 severity criteria. No patient had coma, and no deaths occurred. Epidemiological and clinical features of these patients have been previously reported.<sup>359</sup>

**Table 6.4-1. Baseline features of patients with knowlesi malaria**

	Severe malaria (n=20)	Non-severe malaria (n=24)	P value
Age (years), median (IQR)	51.5 (20-74)	40.5 (18-71)	0.018
Male sex	15 (75%)	17 (71%)	0.757
Hypertension	3 (15%)	5 (21%)	0.710
Diabetes mellitus	0 (0%)	0 (0%)	NA
Previous malaria (self-reported)	7 (35%)	8 (33%)	0.579
Previous malaria in past 2 months (self-reported)	0 (0%)	(0%)	NA

**Visual assessment and Eye Examination**

Visual assessment and eye examination results are shown in **Table 6.4-2**. There were no differences in visual acuity, visual fields or colour vision between patients with severe and non-severe knowlesi malaria. Cataracts were common, occurring in 12/20 (60%) patients with severe knowlesi malaria and 9/24 (38%) with non-severe malaria ( $p=0.14$ ). One patient with non-severe malaria had asteroid hyalosis, a degenerative condition of the eye causing small white opacities in the vitreous, and two had old corneal lesions.



**Table 6.4-2. Visual assessment and eye examination findings outside the retina in patients with knowlesi malaria**

	Severe malaria (n=20)	Non-severe malaria (n=24)	P value
Corneal scarring, n (%)	0 (0%)	2 (8%)	0.498
Cataract, n (%)	12 (60%)	9 (38%)	0.137
Acuity (logMAR), median (IQR)	0.076 (0.0-0.21)	0.0 (0.0-0.054)	0.094
Abnormal visual fields, n (%)*	1 (5%)	6 (25%)	0.106
Abnormal colour vision, n (%)**	4 (20%)	1 (4%)	0.161
Intraocular pressure (mmHg), mean (95% CI)	13.4 (11.7-15.1)	13.3 (11.9-14.7)	0.94

\*, \*\* Definitions are provided in the Methods section.

\* In all but one patient the abnormal visual fields were attributed to excessive fixation losses that precluded definitive interpretation. No distinct field loss patterns were seen. One patient had a peripheral field constriction with fundus features of retinitis pigmentosa.

\*\* Colour defects detected included 3 tritane, 1 deutan, and 1 protan.

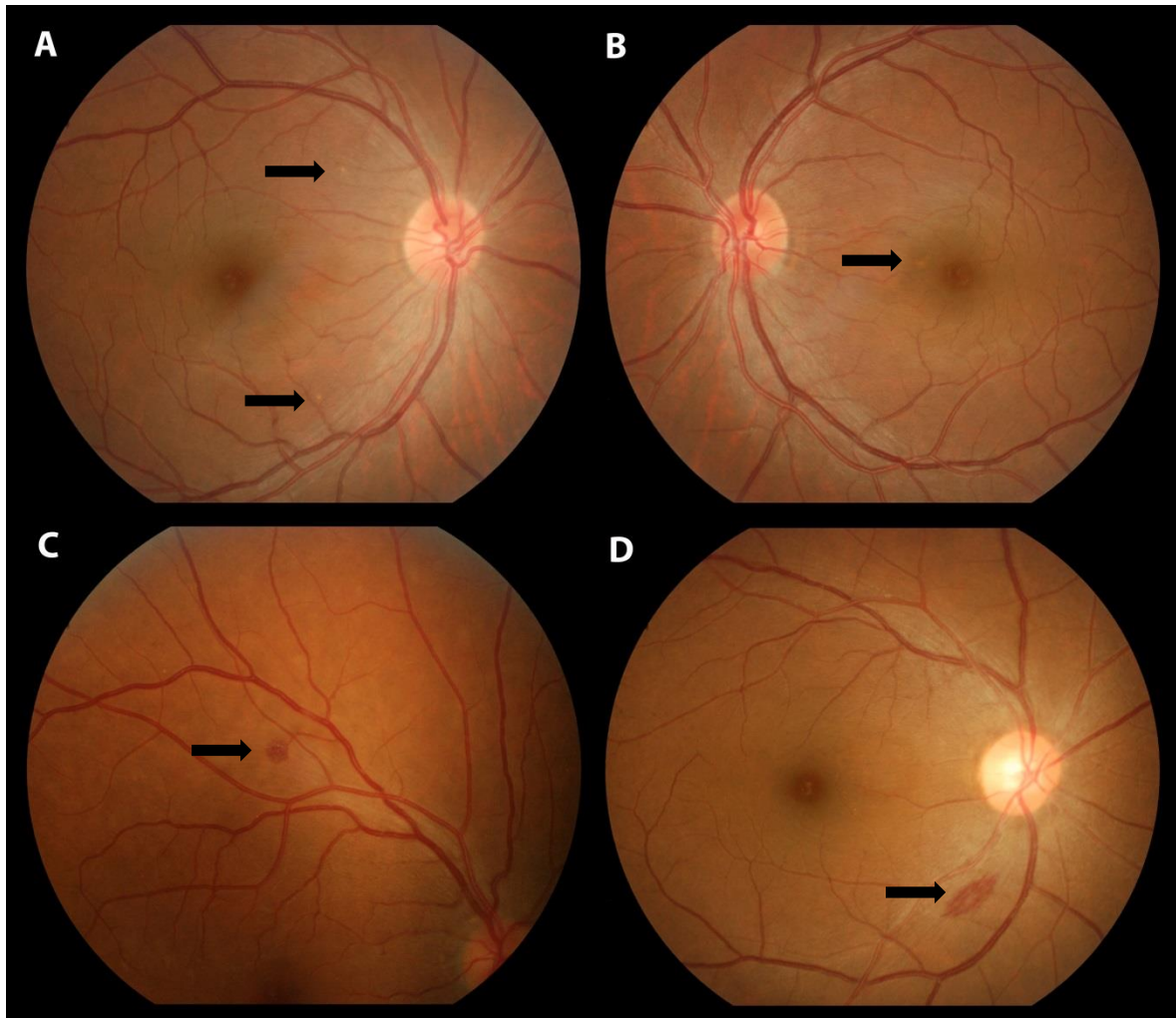
### Retinal findings

All patients underwent indirect ophthalmoscopy. Retinal photographs were taken in 12/20 (60%) patients with severe knowlesi and 17/24 (71%) patients with non-severe knowlesi malaria. Retinal findings are shown in **Table 6.4.3**. Retinal changes were common in both groups, but were mild, and were equally common in severe and non-severe disease. Examples of common lesions seen on retinal photography are shown in **Figure 6.4-1**.

**Table 6.4-3. Retinal findings among patients with knowlesi malaria**

	Photography			Indirect ophthalmoscopy		
	Severe (n=12)	Non-severe (n=17)	P value	Severe (n=20)	Non-severe (n=24)	P value
Any retinal lesion	11 (92)	14 (82)	0.62	6 (30)	7 (29)	0.952
Haemorrhages	2 (17)	3 (18)	1.00	0 (0)	2 (8)	0.493
Retinal whitening	3 (25)	5 (29)	1.00	2 (10)	1 (4)	0.583
Cotton wool spot	1 (8)	1 (6)	1.00	0 (0)	0 (0)	NA
Vessel whitening	0 (0)	1 (6)	1.00	0 (0)	1 (4)	1.00
Papilloedema	0 (0)	0 (0)	1.00	0 (0)	0 (0)	NA
Retinal pigment epithelium depigmentation	1 (8)	4 (24)	0.35	0 (0)	1 (4)	1.00
Drusen	9 (75)	12 (71)	1.00	4 (20)	4 (17)	1.00

Numbers are n (%); NA: not assessed



**Figure 6.4-1. Common retinal lesions in patients with knowlesi malaria.**

A non-severe malaria with 2 small spots of non-specific retinal whitening in the macula, B non-severe malaria with minor area of loss of retinal pigment epithelium, C severe malaria with blot retinal haemorrhage and D non-severe malaria with white-centered haemorrhage.

*Comparison between indirect ophthalmoscopy and retinal photography*

Almost all lesions seen on indirect ophthalmoscopy were confirmed on retinal photography. In one patient a single retinal haemorrhage was seen on indirect ophthalmoscopy but not on the photographs, and in another, a small area of retinal whitening on photography was thought to be drusen on indirect ophthalmoscopy. Photography was more sensitive than indirect ophthalmoscopy at detecting patients with retinal changes, with changes noted in 25/29 [86%] patients using photography compared to 13/44 [30%] using indirect

ophthalmoscopy ( $p < 0.0001$ ). In 8/29 (28%) patients who had retinal photography performed, retinal changes were seen on photography but not on indirect ophthalmoscopy; these changes included 6 non-specific whitening, 6 drusen, and one haemorrhage.

#### *Retinal haemorrhages*

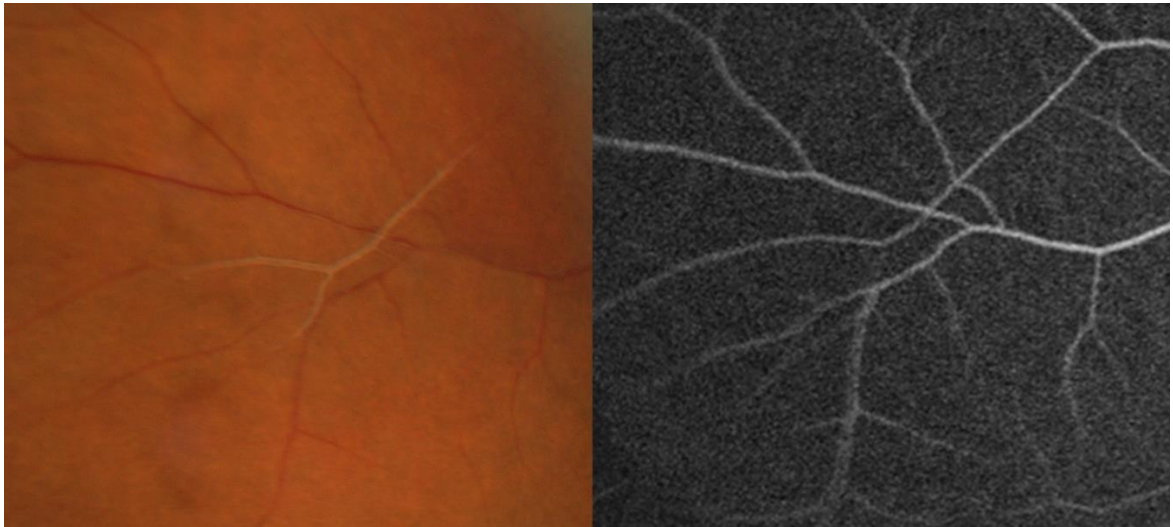
Five patients were noted to have retinal haemorrhages on photography, including 2/12 (17%) with severe disease, and 3/17 (18%) with non-severe disease. All were classified as mild (1 – 5 per eye) according to criteria developed for falciparum malarial retinopathy.<sup>260</sup> Three patients had single dot or blot haemorrhages in one eye. Two patients had multiple haemorrhages: one with non-severe knowlesi malaria who had a white-centered haemorrhage in one eye and a white-centered haemorrhage and a dot haemorrhage in the other; and another patient with severe knowlesi malaria who had three dots and one blot in one eye and two blots in the other. Both these patients had severe thrombocytopenia (platelet count  $19 \times 10^3/\mu\text{l}$  and  $8 \times 10^3/\mu\text{l}$  respectively). The median (IQR) admission platelet count among the 5 patients with retinal haemorrhages on photography was lower than that of patients without retinal haemorrhages ( $22 [13.5 - 38.5] \times 10^3/\text{L}$  versus  $43 [27.5-72] \times 10^3/\text{L}$ ,  $p=0.039$ ), although there were no differences in prothrombin time, activated partial thromboplastin time or haemoglobin.

#### *Retinal whitening and vessel discoloration*

Eight of 29 patients (28%) with knowlesi malaria had non-specific retinal whitening on photography, including 3/12 (25%) with severe disease, and 5/17 (29%) with non-severe disease. In all these patients the retinal whitening appeared as occasional scattered spots in the peripheral or macular retina. In three patients, there was also loss of the retinal pigment epithelium (**Figure 6.4-1B**), although it could not be determined if this was acute or chronic. No patient had the moderate-severe whitening typical of severe falciparum malaria.

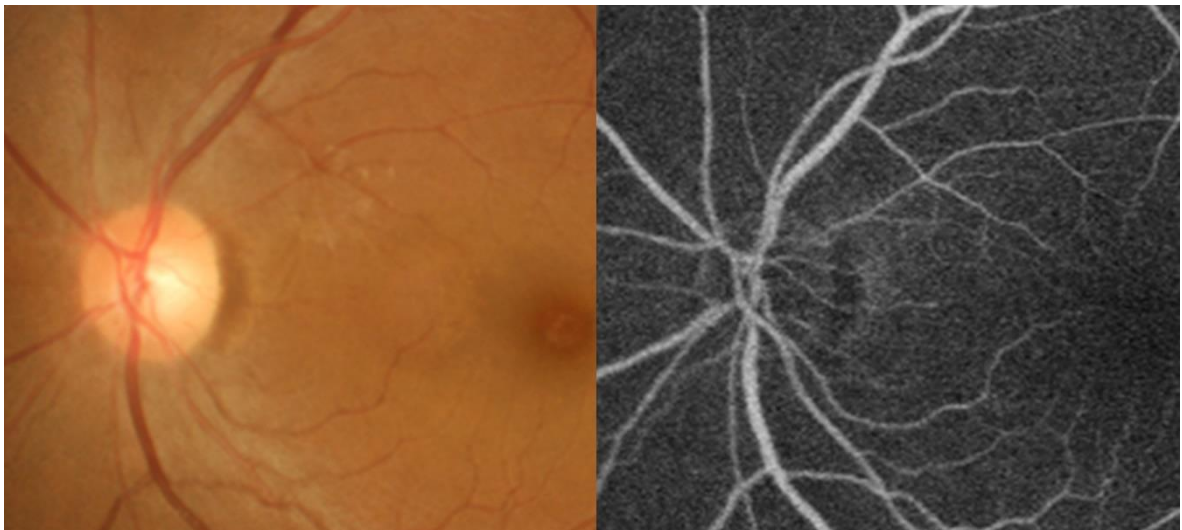
One case of vessel whitening was seen, in a patient with non-severe knowlesi malaria. The whitening involved an arteriole, with sheathing of the vessel wall and a thin patent lumen observed on fundus photography. There were no inflammatory changes noted, and a fluorescein angiogram, done at the same time, indicated a patent vessel with no surrounding retinal ischaemia (**Figure 6.4-2**). The same patient had some temporal and macular retinal whitening with a window defect on the angiogram at the site of the temporal whitening, consistent with a retinal pigment epithelial lesion and an abnormality in the choriocapillaries

rather than the retinal vessels. At the site of the macular whitening the angiogram was normal, indicating normal retinal perfusion (**Figure 6.4-3**).



**Figure 6.4-2. Vessel whitening (left) with normal fluorescein angiogram (right) in a patient with non-severe knowlesi malaria.**

Fundus photography demonstrated whitening of an arteriole, with sheathing of the vessel wall. No inflammatory changes noted. The fluorescein angiogram was performed at the same time as the fundus photography, and demonstrates some minor attenuation of blood flow with a patent vessel, and no surrounding ischaemia.



**Figure 6.4-3. Non-specific retinal whitening (left) with normal fluorescein angiogram (right) in a patient with non-severe knowlesi malaria.**

*Drusen and other incidental findings*

Around half (13/29) of patients with retinal lesions on fundus photography had small numbers of hard drusen but no other lesions. Drusen are commonly regarded as a normal variant which appear with increasing age,<sup>371</sup> and increase in prevalence and number with age. On indirect ophthalmoscopy, the median (IQR) age of patients with drusen was higher than that of patients without drusen (52 [48.5 – 67]) versus 38 (25.5 – 50.5) years,  $p=0.005$ , although this difference was not significant among those who had retinal photography performed (43 [30-51] versus 39 [20-55] years,  $p=0.78$ ). Similarly, retinal pigment epithelium changes are also frequently incidental and age-related, although they can also be pathological. In this study, 3 out of 5 patients with retinal pigment epithelial changes also had whitening suggesting a possible pathological association.

One 71 year old patient with non-severe malaria had a Weiss ring in one eye, a common finding in people over 65 years of age, and caused by vitreous shrinkage. Another had retinitis pigmentosa. Two patients with severe malaria and one with non-severe malaria had increased cup to optic disc ratio. One patient with untreated hypertension had subtle macular whitening.

## 6.5 Discussion

Retinal changes in *knowlesi* malaria in this study were common, but were mild and occurred equally in severe and non-severe disease, suggesting that the lesions observed are not directly related to the pathological processes leading to severe *knowlesi* malaria. This is different to severe *falciparum* malaria, which is associated with specific retinal changes including moderate-severe retinal whitening, vessel discolouration, multiple white-centered haemorrhages, and papilloedema.<sup>363</sup> In *falciparum* malaria these changes are of potential use diagnostically and are proving of utility in elucidating microvascular pathogenesis of disease.<sup>333</sup> Although most prominent in fatal or cerebral *falciparum* malaria, occurring in 91% (49/54) of fatal cases and 88% (98/112) with cerebral malaria on retinal photography in adult patients in a large observational study in Bangladesh and India (**Chapter 2**), malarial retinopathy was also seen in 71% (48/68) of these patients with severe but non-cerebral *falciparum* malaria. The lack of these specific retinal changes among patients with severe

*knowlesi* malaria suggests differences in disease pathogenesis between the two *Plasmodium* species.

Non-specific retinal whitening, although common among the *knowlesi* malaria patients in this study, was scant and far less prominent than typically seen in patients with cerebral *falciparum* malaria. In the study referred to above, 54% (61/112) with cerebral and 29% (18/68) with severe non-cerebral *falciparum* malaria had moderate-severe retinal whitening. In *falciparum* malaria, whitening is thought to be due to obstruction of blood vessels by endothelial cytoadherence and sequestration of parasitized red cells within the retinal microvasculature. These changes mirror the sequestration and microvascular obstruction that occur in the brain and lead to coma.<sup>333</sup> Importantly, retinal whitening is also present, although less prominent, in non-comatose patients with severe *falciparum* malaria.<sup>372</sup> In *falciparum* malaria, sequestration in the central nervous system is due primarily to binding of parasitized erythrocytes to upregulated endothelial intercellular adhesion molecule (ICAM-1).<sup>373</sup> In a single autopsy report of severe *knowlesi* malaria without coma, accumulation of parasitized erythrocytes within cerebral vessels was described, although ICAM-1 was not detected<sup>210</sup> consistent with an *in vitro* study demonstrating variable binding of *P. knowlesi* to ICAM-1.<sup>211</sup> Furthermore, in *P. knowlesi* infection late-stage parasites are observed in peripheral blood<sup>374</sup>, suggesting sequestration does not occur to the same degree as in *falciparum* malaria. A paucity of central nervous system endothelial cytoadhesion of *P. knowlesi*-infected red blood cells might explain the lack of severe retinal whitening and absence of coma in severe *knowlesi* malaria. While microvascular accumulation of parasitized red cells does occur in fatal *knowlesi* malaria, it is possible that clumping of *P. knowlesi* infected- and uninfected-red cells, and microvascular sludging, as reported in severe and fatal *knowlesi* malaria in rhesus monkeys<sup>366-368</sup> may be a more important mechanism of impaired microvascular perfusion in severe *knowlesi* malaria. It is possible that the high parasitemias associated with *P. knowlesi* may contribute to this microvascular sludging.

In the present study, some of the retinal changes that did occur among patients with *knowlesi* malaria appeared to relate to defects in the retinal pigment epithelium (RPE). Hard drusen were present in most patients with *knowlesi* malaria, as found in previous population studies using retinal photography.<sup>375</sup> Commonly regarded as a normal variant increasing with age, drusen are accumulations of waste products in the RPE, which if sufficiently large, can cause death of the RPE cells and overlying retina resulting in age-related macular degeneration. It

is likely that the frequency of drusen and RPE defects among the *knowlesi* malaria patients in our study is related to the age of the patients.

Retinal haemorrhages were relatively common in patients with severe and non-severe *knowlesi* malaria, however were all classified as mild (1 – 5 in  $\geq 1$  eye) according to criteria developed to describe *falciparum* malarial retinopathy,<sup>260</sup> and were white-centered in only one patient, with non-severe *knowlesi* malaria. In adults with severe cerebral *falciparum* malaria, in one series 30%<sup>372</sup> and another 39%<sup>255</sup> had white-centered haemorrhages (Roth's spots) thought to result from intraluminal fibrin deposition. Thrombocytopenia is near-universal in *knowlesi* malaria<sup>354-356,359</sup> and a lower platelet count was associated with presence of haemorrhages. The two patients with multiple haemorrhages in the present study had severe thrombocytopenia, which may have been contributory.

Retinal vessel whitening was seen in only one patient in our study, with non-severe *knowlesi* malaria, and the normal fluorescein angiography and lack of acute inflammatory changes suggested it was related to an old event. In *falciparum* malaria retinal vessel whitening is prominent in African children<sup>223</sup> but absent in Bangladeshi adults.<sup>61</sup> It is thought to be due to obstruction of the vessel segment by dehaemoglobinized parasitized erythrocytes.<sup>234</sup>

A limitation of this study was that neither healthy controls nor patients with *falciparum* or *vivax* malaria were included. This limited our ability to assess the specificity of findings for *knowlesi* malaria, and it was also not possible to determine the background rate of retinal lesions in the population.

## 6.6 Conclusions

Retinal lesions in patients with *knowlesi* malaria are common but are mild, non-specific, and unrelated to disease severity. The paucity of retinal lesions in severe *knowlesi* malaria contrasts with the greater frequency, severity and specificity reported in severe *falciparum* malaria including in adults without coma. In conjunction with the apparent absence of coma definitively associated with severe *knowlesi* malaria, this suggests that pathophysiological mechanisms differ between these two species. While central nervous system microvascular accumulation has been reported in fatal *knowlesi* malaria, the mechanisms and/or consequences likely differ from the endothelial cytoadherence-mediated sequestration



characteristic of *P. falciparum*. Microvascular obstruction in the central nervous system does not appear to be an important contributor to the pathophysiology of severe *knowlesi* malaria.

## **Chapter 7 Summary of Results**

## 7.1 Summary of results from each Chapter

The main results are summarised in **Table 7.1-1**.

**Table 7.1-1. Summary of the main results for each Chapter.**

<p><b>Chapter 2: Retinopathy in <i>P. falciparum</i> malaria</b></p> <ol style="list-style-type: none"> <li>1. Malarial retinopathy was specific to falciparum malaria as compared to sepsis, encephalopathy and healthy individuals in Bangladesh and India</li> <li>2. The spectrum of retinal findings in Asian adults was similar to Asian children but there were differences compared to previous studies in African children: retinal vessel discolouration was absent and papilloedema was rare</li> <li>3. Retinopathy was present in around 90% of patients with cerebral and fatal malaria</li> <li>4. The frequency and severity of retinopathy correlated with severity of falciparum malaria</li> <li>5. Retinal whitening and white-centred haemorrhages were highly specific in this population for cerebral malaria in comatose patients</li> <li>6. The severity of retinal whitening predicted mortality and development of coma</li> <li>7. Visual acuity was decreased in severe malaria and correlated with severity of retinopathy</li> <li>8. The severity of retinal whitening in severe malaria correlated with plasma lactate, serum bicarbonate, parasite biomass, sequestered biomass and red cell stiffness</li> <li>9. Retinal venular tortuosity decreased with increasing severity of malaria, vessel width and tortuosity correlated with GCS and variance of vessel width was increased in severe malaria</li> </ol>
<p><b>Chapter 3: <i>P. falciparum</i> retinopathy and optic nerve sheath diameter</b></p> <ol style="list-style-type: none"> <li>1. The normal range for ONSD was &lt;4.75mm</li> <li>2. ONSD was normal in most patients with severe malaria and there was no association of ONSD with severity of malaria, coma or death</li> </ol>
<p><b>Chapter 4: <i>P. falciparum</i> retinopathy and fluorescein angiography</b></p> <ol style="list-style-type: none"> <li>1. A novel method for low cost fluorescein angiography was described</li> </ol>

2. Example retinal photographs showed non-perfusion at sites of retinal whitening and mild focal vessel leakage
3. A case report was presented in which retinal whitening, blood vessel obstruction and vessel leakage, as well as associated visual impairment, were completely reversible

**Chapter 5 *P. falciparum* retinopathy and magnetic resonance imaging of the brain**

1. Cerebral oedema in adult severe malaria was mostly mild and not associated with coma or death
2. Mild brain swelling in adults with severe malaria was likely caused by venous congestion
3. A variety of abnormalities other than oedema were identified
4. None of the observed changes on MRI were specific to patients with coma or fatal disease suggesting the processes they represented are not central to their pathogenesis

**Chapter 6 Retinopathy in *P. knowlesi* malaria**

1. Retinal findings in severe and uncomplicated *P. knowlesi* malaria were less common and had a different pattern to those seen in severe and uncomplicated *P. falciparum* malaria

## **Chapter 8 Discussion**

## 8.1 General discussion

This thesis presented a series of studies aimed at determining the potential contribution of malarial retinopathy to understanding the pathogenesis and improving the management of cerebral malaria in adults. Unlike previous studies of malaria retinopathy, these studies directly compared retinal findings in patients with the full spectrum of clinical disease in hospitalized patients with *P. falciparum* malaria to severely unwell patients from the same population with sepsis and nonmalarial encephalopathy, as well as healthy individuals. This allowed determination of the sensitivity and specificity for *P. falciparum* in the full range of clinical scenarios faced by attending clinicians in Bangladesh and India and thus investigation of the potential role of malarial retinopathy as a tool in assisting diagnosis and predicting prognosis in severe malaria in adults.

In **Chapter 2**, it was established that retinal whitening is present in most patients with cerebral falciparum malaria and predicts the development of coma in noncerebral severe falciparum malaria. This whitening correlated with known contributors to and markers of systemic microvascular obstruction in severe malaria. In addition, preliminary results of fluorescein angiography in **Chapter 3** showed that nonperfused areas of retina coincide with retinal whitening on colour photography. Taken together these strongly suggest that microcirculatory flow obstruction is causing retinal whitening and is an important process in causing coma. All of this is very similar to previous findings in African children with falciparum malaria indicating a shared pathogenesis of heterogeneous microvascular obstruction in the retina and brain.<sup>236</sup> However there were several major difference in findings between studies of falciparum malaria in this thesis and previous work in African children.

In Asian adults, and also in the small number of Asian children enrolled, no retinal vessel discolouration was seen. In African children, white, orange or yellow retinal vessels are seen by indirect ophthalmoscopy in around 1 in 3 with cerebral malaria and this is thought to represent obstructed retinal vessels containing sequestered dehaemoglobinised parasitized erythrocytes.<sup>234</sup> As this is the same process that appears to cause retinal whitening in both adults and children its absence in Asian patients is puzzling. In **Chapter 2** several possible explanations for this are proposed.

These studies also confirmed that retinopathy has prognostic value in severe falciparum malaria in adults. As in African children, the severity of retinopathy predicted mortality,

however in Asian adults it is retinal whitening that was predictive, as compared to retinal haemorrhages and papilloedema in African children.<sup>63</sup> Unlike African children these studies also showed that retinal whitening is predictive of the later development of coma in adults with noncerebral severe falciparum malaria. This has potential to help guide patient management and allocation of limited resources, as explored in detail in **Chapter 2**.

In those with cerebral malaria, papilloedema was seen in 1% of adults and was not seen in children. Ultrasonographic measurements of ONSD as a marker of ICP in this thesis (**Chapter 3**) confirmed this by showed ICP is mildly raised in a minority of patients of all ages with uncomplicated, noncerebral severe, cerebral and fatal falciparum malaria and that there was no difference in median ONSD between these groups and no association with GCS or mortality. In the study presented in **Chapter 5**, MRI of the brain found swelling was mostly mild and not specific to coma or fatal malaria.<sup>175,176</sup> Again this is very different to African children with cerebral malaria in whom papilloedema was present in 15% and was the strongest predictor of mortality,<sup>63</sup> MRI of the brain and post mortem studies showed moderate to severe swelling to be common,<sup>176</sup> and ONSD was raised in 49%.<sup>249</sup> In **Chapter 4**, preliminary results of fluorescein angiography in Bangladeshi and Indian adults showed BRB leakage to be very mild as compared the more prominent BRB leakage seen in African children.<sup>223</sup> A previous small study in Thailand found similar fluorescein leakage and systemic capillary permeability in mostly adult patients with severe malaria but these were not specific to coma.<sup>182</sup> Taken together these findings suggest that raised ICP does not play a role in causing coma or death in Asian adults or children with cerebral malaria. This is in stark contrast to recent literature on African children with cerebral malaria in whom brain swelling is thought to be an important contributor to death.<sup>176</sup>

In **Chapter 2** it was shown that mean venule width decreased with increasing severity of malaria and there was no difference in mean venule width in severe malaria compared to healthy individuals. There was also no correlation of blood vessel tortuosity with severity of malaria although venule tortuosity and width did correlate with GCS. In **Chapter 4**, a case of cerebral malaria was described where arteriole and venule width and tortuosity measured manually were higher at baseline than on recovery. Although at first glance, these results may appear to be contradictory, they highlight the inadequacy of mean vessel width as a summary measure in severe malaria. In **Chapter 2**, it was also found that the variance in vessel width was increased in severe malaria. This was probably due to the heterogeneous microvascular obstruction and disordered regulation of microvascular tone seen in severe

malaria causing dilatation of some vessels and narrowing of others. The mean width would thus have been determined by which of these processes predominated in an individual.

*P. knowlesi* is a common cause of severe malaria in parts of Southeast Asia and can be difficult to distinguish from *P. falciparum*. Being relatively recently discovered to cause severe malaria in humans, the pathogenesis of *P. knowlesi* malaria is poorly understood and retinal findings in *P. knowlesi* malaria have not been studied previously. In **Chapter 6** it was shown that retinal findings in severe and uncomplicated *P. knowlesi* malaria in Malaysian adults differed markedly from those in *P. falciparum* in Bangladesh and India described in **Chapters 2, 4 and 5**. Retinal whitening was much less prominent with haemorrhages and drusen also being seen. There were no differences between severe and uncomplicated disease. The findings strongly suggest that the pathophysiology of *P. knowlesi* and *P. falciparum* are different and that microvascular obstruction in the central nervous system is not important in the pathogenesis of severe *P. knowlesi*. Further comparison of findings in **Chapters 2 and 6** confirms the specificity of malarial retinopathy for severe falciparum malaria in that finding moderate-severe retinopathy, in particular whitening, in a parasitaemic patient strongly suggests they have *P. falciparum*. No patient with *P. knowlesi* malaria had moderate-severe retinopathy. The presence of mild retinopathy would not, however assist clinicians in identifying *P. knowlesi* infection as while there were similarities to mild retinopathy in *P. falciparum* no findings were specific to *P. knowlesi*. There is some evidence that there is accumulation of parasitized erythrocytes in cerebral vessels in *P. knowlesi*<sup>210</sup> and this may account for the overlap with falciparum. Fluorescein angiography was done in one patient with knowlesi malaria and no vessel obstruction was seen. In future studies of knowlesi malaria, additional fluorescein angiograms may be particularly informative. *P. knowlesi* has been suggested as an animal model for human falciparum malaria.<sup>376</sup> The findings in this thesis that retinopathy in knowlesi is mild and different to falciparum indicate that the usefulness of such a model would be limited.

## 8.2 Critique

There are many important limitations to the work presented in this thesis. The first is that the use of portable retinal photography as the principal method of detecting retinopathy probably gave an over-optimistic picture of the current diagnostic and prognostic value of malarial retinopathy in most settings. Retinal photography has the advantages of capturing most



retinal signs and permitting blinding of the assessor to the clinical status of the patient as images can be examined at a later date. It also allows multiple observers to examine the same retina and permits prolonged examination of images which is a big advantage in uncooperative and confused patients. Use of this technique allowed imaging of a wide range of patients of all ages and all conscious levels in a way that has not been possible in previous studies. This is ideal for research studies of pathogenesis and when using malarial retinopathy as an outcome marker for intervention studies. However, it does not reflect the reality of how malarial retinopathy would be used currently as a bedside tool to aid diagnosis and prognosis. In many settings, retinal photography is not available, current portable retinal cameras are difficult to use and relatively expensive (around 5-10,000 USD), although much cheaper than standard tabletop retinal cameras (>50,000 USD). Several systems are currently being developed and trialled using smartphones with attached lenses to take retinal photographs. These systems will be much cheaper than dedicated retinal cameras and the image quality of some is now comparable to portable retinal cameras.<sup>299</sup> However field testing is ongoing and none are yet widely commercially available.

The main technique used in other studies of malarial retinopathy to date has been direct and/or indirect ophthalmoscopy. These are both highly user-dependent. Studies in Malawi have also used tabletop retinal cameras in subgroups of patients but, as with ophthalmoscopy, these are poorly tolerated by agitated and confused patients and this has greatly limited the number of conscious individuals with severe malaria who have been studied. Indirect ophthalmoscopy has a much better field of view than direct ophthalmoscopy and is more sensitive for detecting retinal changes but requires considerably more skill to use. Indirect ophthalmoscopes are also prohibitively expensive (around 4-5000 USD) compared to direct ophthalmoscopes (around 300-600 USD). Thus indirect ophthalmoscopy is mainly restricted to use by ophthalmologists who are not available to assist with acute medical cases in many resource-poor settings. Direct ophthalmoscopy is widely available but many general physicians lack experience, confidence and training in its use and thus the sensitivity is often poor.

To definitively establish the role of malarial retinopathy in diagnosis and prognosis in non-research clinical settings will require an assessment of the sensitivity of techniques that are used widely by non-specialist clinicians. This will require either: 1) large studies comparing retinal findings detected by direct ophthalmoscopy used by physicians with findings on retinal photography, ideally supplemented by specific training on detection of the specific changes seen in malarial retinopathy and/or 2) development of low cost but high quality

retinal cameras that can be used by non-specialists. Efforts to develop the second option have already begun with a range of lower cost retinal cameras now being developed. To complement this, there has also been preliminary work to develop software which will automatically detect malarial retinopathy thus obviating the need for specialist training to read retinal photographs<sup>377</sup> and further development of this software is ongoing.

If these hurdles were overcome and retinal cameras became much cheaper, another major barrier to their widespread use is that few physicians have experience in retinal photography which is widely seen as the preserve of ophthalmologists and retinal photography technicians. The author of this thesis carried out most of the retinal photography and fluorescein angiography for **Chapters 2, 4 and 5**, and trained and supervised a team of assistants who took the remainder. Despite not being an ophthalmologist, with relatively little training it was possible to acquire high quality images covering most of the visible retina from early in the study period. By using a portable retinal camera, patients could be photographed lying in bed in most clinical settings and the severity of illness was rarely a barrier to acquiring high quality images. It was also possible to work round clinical teams engaged in complex patient management and it was found that judicious use of the portable retinal camera did not interfere with clinical care as use of a tabletop camera might. Most patients could be photographed in around 10-20 minutes with 1 assistant present.

Fluorescein angiography will be an essential component of studies of falciparum malaria pathogenesis going forwards. Preliminary results presented in this thesis demonstrate the wealth of detail that can be seen using this technique. Similar to retinal photography, fluorescein angiography is a highly specialist technique used almost exclusively by ophthalmological technicians and ophthalmologists. Major barriers to its widespread use include the high cost of retinal cameras and additional skills level required to acquire the images. In **Section 4.2** a novel low cost method for performing fluorescein angiograms is described. As it was time-consuming and took longer to learn sufficient to acquire analysable images, it was only used in a subset of patients. Although the image quality was not comparable to a tabletop camera, analysable images were still acquired from most patients using this relatively simple technique and relatively little additional skill was needed to acquire the images. It was also relatively straightforward to do angiography in unconscious and severely unwell patients. Another limitation was the lack of a built-in timer required to log the time of each photograph but this was replicated by use of an assistant recording timings manually. With further development, low cost adaptations such as this would be

invaluable in facilitating further study of disease pathogenesis in the retina in resource poor settings.

Only a small number of patients underwent high quality fluorescein angiography with a tabletop camera in these studies. A major limitation of tabletop cameras is that patients had to be moved to another site for the photography to be done and thus had to be conscious and cooperative. It was thus not possible to do high quality fluorescein angiography in unconscious or severely unwell adults and most of these angiograms were done once the patients had begun to recover. When studying disease pathogenesis, this is not ideal and angiograms acquired on enrolment would be more informative. Although the angiograms acquired in **Chapter 2** are still being analysed, it has been noted that the quality of the images is not comparable to those acquired with a high quality tabletop camera. In Malawi, unconscious children are photographed lying on their side, the bed being raised to the level of the tabletop retinal camera. If this study were repeated, it would be preferable to acquire a tabletop retinal camera for use in the acute medical and intensive care wards and a similar method to that developed in Malawi would be trialled in Bangladesh and India. Although this was originally intended, it was not possible due to budget limitations.

In Malaysia, retinal photography was done using a tabletop camera as this was available at the study site. In severe *P. knowlesi* malaria patients do not become comatose and are more able to sit up for retinal photography than in *P. falciparum*. In addition, use of a portable camera would have required separate additional training as it is not a technique in routine use, hence the choice of tabletop cameras here. In this study, only around two thirds of patients underwent photography thus limiting later expert analysis of retinal findings to this subset. All patients had retinal examination by expert indirect ophthalmoscopy but in 28% who also had retinal photography, retinal changes were missed on indirect ophthalmoscopy. In retrospect it may have been better to use portable retinal photography in this study of *P. knowlesi* malaria as a record of retinal findings could be acquired in a higher proportion of patients.

Another limitation is that assessment of retinal changes on the large number of retinal photographs acquired in these studies was done mostly by a single individual with only 10 sets of photographs being double-read by a second observer. This limited the assessment of inter-observer reproducibility of retinal findings. To minimise bias, the single observer was masked to the patients' diagnosis and clinical status and examined all retinal photographs on two separate occasions. Using this method, intra-individual reproducibility was high. The

main reason for choosing this method is that it was not possible to find a second observer with sufficient expertise in reading retinal photographs who had the time to read them within the period of the study. There was insufficient budget available to send the large number of images to a dedicated retinal photograph reading centre. It would have been preferable to double-read a larger number of sets of photographs and to compare findings between the two observers for each feature of malarial retinopathy.

In contrast to the patients with *P. knowlesi* infection in Malaysia, assessment of visual function in patients with *P. falciparum* malaria in Bangladesh and India was relatively crude due to the tools available for the study and limited attention span of severely unwell patients. Results for visual acuity were highly variable even in healthy subjects and many patients were assessed as having abnormal colour vision. Visual function assessments were carried out by general physicians and this may have decreased the sensitivity. Many patients were also unwell with systemic symptoms which may have decreased the reliability of the results. In particular visual field assessments were done in patients with falciparum malaria by confrontation which has been shown to be inferior to perimetry. Amsler grid did not detect any abnormalities but many patients found it difficult to understand what they were being asked to do. The Snellen and Ishihara tests were also problematic. For the Snellen chart, many patients were illiterate and unable to identify letters thus a chart with pictures had to be adopted part-way through the study. An abbreviated Ishihara test was used as the full test was found to be too difficult for unwell patients to complete. Many patients were also unable to read the Arabic numerals thus diagrams of the numerals had to be used for reference. These adaptations were found to be effective. If this study were to be repeated it would be better to use tools developed for illiterate subjects from the start and to seek additional funding for the assistance of a clinician or technician with experience in visual function assessment to apply more sophisticated methodologies. Serial assessments of visual acuity would also help to clarify which abnormalities are short-term and which long-term.

The number of children recruited in the studies in this thesis was relatively small. This greatly limited comparison of findings with those in adults. It was not possible to conclusively answer whether malarial retinopathy is different in Asian children and African children or whether the differences observed between Asia and Africa are due to differences between children and adults. The number of children was limited by the range of patients admitted to the hospitals where patients were recruited. If these studies were to be repeated, inclusion of additional study sites would help to recruit more children. Ideally the number of children with severe malaria should be similar to the number of adults to provide maximal

---

statistical power for these comparisons. Studies of the epidemiology of severe malaria by the author of this thesis indicate that children with severe malaria comprise around a quarter of the total in Bangladesh.<sup>17</sup> To recruit a comparable number of children to the adults enrolled in this study would thus require two additional hospitals with similar numbers of severe malaria cases. Similarly MRI of the brain was not done in Asian children in **Chapter 5**.

Future studies are required to show whether the same lack of association between brain MRI findings and coma and mortality exists in Asian children as was found in Asian adults. They should also conclusively demonstrate whether marked cerebral oedema conveying a high risk of death is specific to African children with cerebral malaria.

In **Section 4.4**, a single interesting case of severe falciparum malaria is described. This patient was followed up after they had recovered from cerebral malaria and malarial retinopathy and they had retinal photography and angiography at both time points. Despite being only one patient, detailed analysis was highly informative and demonstrated the complete reversibility of clinical disease, retinal findings and compromised visual function. A proportion of other patients with severe malaria and retinopathy in Bangladesh were also followed up and photographed repeatedly during their admission and in many cases at multiple timepoints post-discharge. The retinal photographs and angiographies from these follow-up assessments are still being analysed. This is a crucial analysis to determine the rate of reversibility of malarial retinopathy, an essential requirement to assess the potential of malarial retinopathy as an endpoint for intervention studies for adjunctive therapies targeting the microvascular pathogenesis of severe malaria. Although it was relatively quick to record the follow-up images, the limiting factor for this analysis was the time take to process and examine the large number of retinal photographs acquired. In retrospect, it would have been preferable to recruit additional research assistants to help with the analysis of the retinal photographs, or to send the images to dedicated fundus photograph reading centres, but funding was not available for this. Further information on the speed of reversibility of the various components of malarial retinopathy is needed and retrospective analyses are now underway to investigate this from the archived retinal photographs acquired for this thesis.

## **Chapter 9 Conclusions**

## 9.1 Summary

This thesis presented a series of studies of malarial retinopathy in *P. falciparum* and *P. knowlesi* malaria in Asian adults and children. It used the highly sensitive technique of retinal photography to determine the full range of retinal changes in uncomplicated, noncerebral severe and cerebral falciparum malaria to findings in sepsis, nonmalarial febrile encephalopathy and healthy individuals. It showed that in comparison to previous studies in African children, the prevalences of retinal whitening and retinal haemorrhages were similar but papilloedema much less common and retinal vessel discolouration was absent. Malarial retinopathy was present in around 90% of patients with cerebral and fatal malaria, and was predictive of mortality and development of coma. Retinal whitening was highly specific for cerebral malaria in comatose patients. Correlation with blood lactate, bicarbonate, parasite count, parasite biomass and sequestered biomass, as well as preliminary results from fluorescein angiograms provided additional support for the hypothesis that microvascular obstruction by sequestered parasites is a central pathogenic process in causing retinal whitening and coma in cerebral falciparum malaria. Study of optic nerve sheath diameter and MRI of the brain provided further evidence of raised ICP and brain swelling being unrelated to coma and death in Asian adults with severe malaria. Study of retinopathy in severe and uncomplicated *P. knowlesi* malaria revealed retinal changes to be different to and less prominent than in *P. falciparum* and that microvascular obstruction is not a prominent process in its pathogenesis.

---

## 9.2 Implications and impact

Being a Physician in Tropical Medicine and General Medicine and not formally trained as an ophthalmologist I have approached this thesis from the perspective of the broad context of clinical malaria research and the clinical management of severe malaria. In this Section I will outline how I think the malarial retinopathy research presented in this thesis has contributed to these two areas.

This research has potential implications for clinical practice as it has shown that in Asian adults with falciparum malarial retinopathy can be used to help with studying the pathogenesis of cerebral malaria, that it may be able to aid with diagnosis of cerebral malaria in comatose patients, it may help to predict the prognosis of severe malaria and that it has potential as an outcome measure for clinical trials of adjunctive therapies. This is important as much of the research evidence for malarial retinopathy prior to the work for this thesis was from studies in African children and it was not known how applicable they were to adults in whom the disease spectrum and pathogenesis are thought to differ. By use of retinal photography, these studies have established a gold standard for detection of malarial retinopathy in Asian adults against which the performance of other methods can be compared. Further research will be needed before the findings could be adopted into clinical practice. This further research will need to test how well available eye examination techniques (direct and indirect ophthalmoscopy) perform against retinal photography and test whether they are sufficiently sensitive to contribute to diagnosis and prognosis in the hands of clinicians with a range of abilities. If they are, then there is potential for malarial retinopathy to be included in prognostic scoring systems for severe falciparum malaria.<sup>24</sup> The additional prognostic value of malaria retinopathy on top of other factors will need to be assessed. Further analyses of the data presented here could help with this but additional studies will be needed. In the longer term, if sufficiently sensitive low cost retinal camera systems become available for use by general clinicians then the results of this thesis may be reproducible in routine clinical practice. Preliminary studies have begun to develop such a camera. This will be discussed in more detail in the next Section.

The findings of this research also have implications for future research on the microvascular pathogenesis of cerebral falciparum malaria. The studies add to the evidence that microvascular obstruction in the retina and brain are closely related and that there is visible evidence of it in the retina in almost 90% of patients with cerebral disease. By allowing



serial direct visualisation of dynamic microvascular pathogenesis in the central nervous system, malarial retinopathy provides the unique opportunity to study these processes in detail in living patients. No other previous technique has afforded this opportunity. On the basis of the results presented here, in addition to previous published studies, there is a case for including malarial retinopathy as a routine part of studies of severe malaria pathogenesis in humans as it appears to outperform other markers of cerebral and fatal malaria.

Similarly, the results of this thesis strongly support malarial retinopathy being further investigated as a potential surrogate outcome measure for clinical trials in cerebral malaria. It was found in these studies that retinal photography is a relatively low cost, non-invasive, easy to learn, bedside tool that can be used in almost all patients with cerebral malaria. Using this method, CNS microvascular changes resulting from the same pathogenic processes as in cerebral malaria can be recorded and examined in detail on multiple occasions in living patients to monitor the rate of development and reversal of microvascular obstruction. These signs are also visible in almost all patients. Further studies are ongoing to determine the rate of recovery from each feature of malarial retinopathy, as the next essential step in this process. For it to be used as an outcome measure, it will be necessary to demonstrate that retinopathy improves quickly enough for this improvement to be detected during an admission.

This research has raised awareness of malarial retinopathy as a means of studying the microvascular pathogenesis of cerebral malaria, its potential role as a diagnostic and prognostic tool in severe malaria and as an outcome marker for clinical trials of adjunctive therapies. Carrying out the clinical studies involved collaboration with and assistance from clinicians and scientists from Australia, Bangladesh, Canada, India, Malaysia, the Netherlands, Thailand, the USA and the UK, many of whom had not previously encountered malarial retinopathy.

Although I have always had a strong interest in ophthalmology, through the work in this thesis I have been able to greatly develop my expertise in retinal diagnostics. I have also demonstrated to the wider clinical research community that with the appropriate training, specialist skills such as this are not inaccessible to non-specialists. Many of the clinicians with whom I worked were training in general medicine, infectious diseases or intensive care and many had limited skills in eye examination. Through exposure to and involvement in this research they were stimulated to practice their skills in fundus examination and particularly to examine patients with malaria for signs of malarial retinopathy. During the

course of the research I arranged training sessions for these physicians in direct and indirect ophthalmoscopy, retinal photography and visual function examination. A personal highlight was providing bedside teaching sessions with an ophthalmologist in direct ophthalmoscopy for physicians in Bangladesh where examination findings were compared with retinal photographs from the same patient. Most participants had lacked confidence in this essential technique prior to the teaching due to limited exposure during their medical training. Following the teaching sessions, direct ophthalmoscopy and visual function examination were being used much more widely on the medical wards and in intensive care and contributed to the management of a broad variety of patients both with and without malaria. In addition, I taught some general physicians indirect ophthalmoscopy and by the end of the studies some were reasonably proficient and keen to practice further including wishing to pursue their own research using this technique. Many of the ophthalmologists with whom I collaborated in Bangladesh, India and Malaysia had never seen malarial retinopathy prior to involvement in these studies but without exception all were fascinated, keen to learn more about it and interested to examine patients with malaria on the medical wards.

Outwith the research team and study sites, this research has had impact in raising awareness of malarial retinopathy in the malaria research community and its potential importance in contributing to the study and management of severe malaria. This occurred both through the peer-reviewed publications listed at the beginning of this thesis and through the opportunity I had to present this work at a range of meetings and conferences. These presentations included:

1. Reducing deaths from malaria. Invited speaker, Global Health Network and Nuffield Department of Medicine, Oxford University, Oxford, UK. 13/8/14.
2. Reducing deaths from malaria. Invited speaker, National Institutes of Health, Bethesda, MD, USA. 25-26/6/14.
3. MRI of the brain in adults with severe falciparum malaria. MRI of the brain in adults with severe falciparum malaria. Oral. American Society of Tropical Medicine and Hygiene meeting 2013, Washington D.C., USA. 13-17/11/2013.
4. Observational studies of malaria retinopathy in adults: its potential role in diagnosis, prognosis and intervention studies and insights into the pathogenesis of cerebral malaria. Oral. American Society of Tropical Medicine and Hygiene meeting 2013, Washington D.C., USA. 13-17/11/2013.

5. MRI of the brain in adult patients with cerebral and severe malaria. Poster. American Society of Tropical Medicine and Hygiene meeting 2012, Atlanta, USA. 11-15/11/2012.
6. The Contribution of Malaria Retinopathy to Reducing Mortality from *P. falciparum* Malaria in Asia. Oral. American Society of Tropical Medicine and Hygiene meeting 2011, Philadelphia, USA. 4-8/12/2011.
7. Malarial retinopathy in adults. Oral. Bangladesh Society of Medicine Conference 2011, Dhaka, Bangladesh. 15-16/3/2011.
8. Malarial retinopathy in adults. Oral. Federation of Infection Societies conference 2010, Edinburgh, UK. 17-19/11/2010.
9. In-vivo evidence that microcirculatory obstruction is a central pathological process in severe falciparum malaria. Oral. American Society of Tropical Medicine and Hygiene meeting 2010, Atlanta, USA. 3-7/11/2010.
10. Malarial retinopathy and microcirculation in adults. Invited talk. Parasite to Prevention: advances in the understanding of malaria conference, Edinburgh, UK. 20-22/10/2010.
11. Malarial retinopathy in adults. Oral. Joint International Tropical Medicine Meeting 2009, Bangkok, Thailand. 3-4/12/2009.
12. Malarial retinopathy and microcirculation in adults with cerebral malaria. Oral and poster. American Society of Tropical Medicine and Hygiene meeting 2009, Washington DC, USA. 17-22/11/2009.

---

### 9.3 Future Directions

Alongside the studies presented in this thesis, a series of enrolment and follow-up fluorescein angiograms has been collected using both the portable retinal camera and tabletop retinal cameras. Preliminary results of some of these angiograms were presented in **Chapter 4** and full analysis is ongoing. I have been part of a multinational collaborative team developing a new classification scheme for angiographic features in cerebral falciparum malaria and this new classification has recently been submitted for publication. The fluorescein angiograms I have taken are currently being graded using this new classification. Once completed, this will allow further detailed study of the microvascular changes in adult cerebral falciparum malaria and comparison of the underlying pathogenic mechanisms with those seen in African children. It will also give an indication of the rate of recovery of microvascular obstruction.

Many of the patients recruited for the study described in **Chapter 2** underwent serial retinal photography. For many patients this was done every 24-48 hours until discharge and then at intervals following discharge until resolution of retinal changes. At each time point, each patient also underwent examination of visual function. This very large set of retinal photographs is currently being graded. The results of the grading will be analysed to determine the time course of resolution of retinal whitening and retinal haemorrhages. The time course of recovery of visual function will also be quantified and correlated with the time to resolution of retinopathy to examine causation.

The retinal photographs collected on enrolment are being regraded by two ophthalmologists to provide further evidence on the inter-observer variability of grading. Inter-observer agreement will be determined for each feature of malarial retinopathy and any areas of disagreement studied in more detail.

Additionally, I am also helping to develop a new classification scheme for changes seen on colour retinal photographs in falciparum malaria. Once completed, this will allow a finer and more objective grading of the various features. This is particularly important for retinal whitening which is the most specific feature in adults and the most strongly associated with outcome. This new grading of retinal whitening will be used for a variety of purposes, as outlined below.

In future it is planned to match serial retinal photographs to serial visual function assessments to better understand how retinopathy affects visual function.

In parallel to the collection of retinal photographs, many of the patients recruited for the study in **Chapter 2** also underwent video recording of capillary blood flow in the rectal mucosa by OPS. This is a validated measure of systemic microcirculatory blood flow that has previously been shown to be deranged in severe malaria.<sup>298</sup> The videos are currently being analysed. Once completed, the various derived metrics of microcirculatory blood flow will be compared to the severity of retinal whitening to further examine the association between systemic and CNS microvascular obstruction.

Once the OPS results are available, a multivariable statistical model will be built for severe falciparum malaria including malarial retinopathy, and correlates and markers of systemic microvascular obstruction comprising parasite biomass, plasma lactate, serum bicarbonate, base excess, red cell deformability and systemic microvascular blood flow to determine which are most strongly associated with, and which are independent predictors of coma and mortality.

Retinopathy will be combined with coma, acidosis, lactate, renal failure, HRP2 level and other known correlates of severity and death in a multivariable statistical model to assess whether retinopathy improves the prediction of mortality as compared to the CAM score.<sup>24</sup> This will be used to develop a new clinical scoring system for severe malaria, with versions developed for use in resource-poor and resource-rich settings.

There is an ongoing collaborative multinational study developing automated methods for grading retinal images using a portable retinal camera with a smartphone platform.

Following an initial project to detect retinal haemorrhages in images acquired for this thesis from Bangladeshi adults,<sup>377</sup> the system is now being trialled on paediatric images from Malawi. It is planned to analyse images from Bangladesh and India acquire for this thesis later in 2015.

Further studies are planned using retinal photography in patients with nonsevere cerebral and cerebral falciparum malaria in the study sites in India and Bangladesh. The first of these will start in June 2015 and will collect additional serial retinal photographs using the portable camera. These will be used to supplement those already collected as an evidence base for use of malarial retinopathy as an outcome measure for clinical trials.

In addition, I am developing a protocol to do more detailed MRI of the brain in parallel to malaria retinopathy. These studies will investigate the metabolic and circulatory changes identified in this thesis in more detail including more MR angiography and additional voxels of MRS and how they relate to clinical phenotype and malarial retinopathy.

In addition to the studies of retinopathy in *P. falciparum* and *P. knowlesi* malaria, I have completed a study of retinopathy in severe *P. vivax* malaria in Rajasthan, India. *P. vivax* has been said to be an occasional cause of cerebral malaria but the pathogenesis of severe and cerebral vivax malaria is not known.<sup>378,379</sup> The results of this study are currently being analysed and the findings compared with those in falciparum and knowlesi.

I am currently engaged in a small study of malaria retinopathy in *P. coatneyi* malaria in macaques in collaboration with the Armed Forces Research Institute of Medical Sciences in Bangkok, Thailand. This animal model is the most similar to human *P. falciparum* malaria displaying similar sequestration in the brain<sup>380,381</sup> and has the advantage that detailed post mortem can be undertaken in all subjects including detailed examination of the brain and retina in the same individual. Such details studies including fatal and nonfatal falciparum malaria have not been possible in humans.

Lastly, I am planning to apply for further funding to apply additional techniques to study of malarial retinopathy in falciparum, vivax and knowlesi malaria. These include optical coherence tomography (OCT) to examine retinal thickness, look for macular oedema and examine the retinal nerve fibre layer changes seen and further study of retinal vasculature and blood flow using OCT angiography. I would also like to study visual function in more detail through collaboration with specialist technicians.

## 9.4 Conclusion

Malarial retinopathy is commonest in cerebral and fatal *P. falciparum* malaria in Asian adults and children. The constellation of retinal changes seen in severe *P. falciparum* malaria in Asian adults is similar, but not identical, to that seen in African children. Retinal whitening is probably a consequence of obstruction of blood vessels by sequestered parasites and is an almost universal finding in cerebral and fatal falciparum malaria in which the same process is central to causing coma. Raised ICP is rare in severe malaria in Asian adults and children and does not appear to be a central process in causing coma or mortality. Retinal changes in severe falciparum malaria are commoner and more prominent than those in sepsis, nonmalarial febrile encephalopathy and severe *P. knowlesi* malaria. As it is specific to malarial coma and helps to predict mortality and development of coma, malarial retinopathy has potential to contribute to diagnosis and prognosis of Asian adults with severe falciparum malaria and as a candidate outcome marker for intervention studies of adjunctive therapies.

**Chapter 10      APPENDIX**



## 10.1 Grading of Malaria Retinopathy

The retinal findings in this thesis were classified according to a predefined scheme as: “none” (0), “mild” (1), “moderate” (2) or “severe” (3). This classification was developed by Simon Harding and Nicholas AV Beare of the University of Liverpool, UK, from an earlier published schema for indirect and direct ophthalmoscopy.<sup>277</sup> Findings were recorded using a Grading Form (**Appendix 10.2**) and scored as present only if the grader was  $\geq 50\%$  certain of its presence. “NS”, meaning “not seen”, was recorded where the image was not adequate and does not indicate that the sign was absent. “0” was used to indicate the absence of a sign if the image examination was adequate.

In summary, the classification scheme used was as follows for each eye:

### 1. Whitening

- a. Foveal: circle of  $\leq 500$   $\mu\text{m}$  radius from centre of fovea
  - Mild:  $< 1/3$  optic disc area
  - Moderate:  $1/3$ - $2/3$  optic disc area
  - Severe:  $\geq 2/3$  optic disc area
- b. Macular:  $\leq 2.5$  disc diameters from centre of fovea, excluding fovea
  - Mild:  $< 1/3$  optic disc area
  - Moderate:  $1/3$ - $1$  optic disc area
  - Severe:  $\geq 1$  optic disc area
- c. Peripheral: defined as the area outside of the macula and divided into superior, inferior, nasal and temporal quadrants
  - Mild: occasional spots
  - Moderate: more than occasional spots/patches of definite mosaic
  - Severe: widespread mosaic/large areas of confluence

Peripheral whitening score =  $\frac{\text{sum of scores for each quadrant}}{\text{number of quadrants seen}}$

### 2. Haemorrhages

- a. Number of haemorrhages
  - Mild: 1-5
  - Moderate: 6-19
  - Severe:  $> 20$
- b. % white centred: none / 25-50% / 50-75% /  $> 75\%$

### 3. Papilloedema

- Mild: 1-3 quadrants of abnormal elevation of the disc with blurring of the margin, no disc haemorrhages
- Moderate: any of: a. 4 quadrants of abnormal elevation of the disc with blurring of the margin, b. any abnormal elevation of the disc with: disc haemorrhages (less than 5) or dilated pre-papillary capillaries
- Severe: any of: a. marked elevation of the disc with blurred margin with loss of the optic disc cup, b. any elevation of the disc with 5 or more disc haemorrhages

### 4. Vessel changes

- Superior/inferior/nasal/temporal; arteries/veins/capillaries; orange/white
- Graded as mild/moderate/severe subjectively according to area of capillary involvement, number of branches of vessel change, length of involvement overall variety and extent of vessel changes
- Vessel changes score =  $\frac{\text{number of affected quadrants}}{\text{number of quadrants seen}}$

The published classification scheme on which this was based is reproduced in full below.



## Classifying and grading retinal signs in severe malaria

S P Harding FRCOphth   S Lewallen MD   N A V Beare FRCOphth  
A Smith FRCOphth   T E Taylor DO MTropMed   M E Molyneux FRCP MD

St Paul's Eye Unit, Royal Liverpool University Hospital, Prescot Street, Liverpool L7 8XP, UK

Correspondence to: S P Harding  
Email: SimonPHarding@aol.com

TROPICAL DOCTOR 2006; 36 (Suppl 1): 1-13

### Introduction

Severe malaria is a common cause of coma and death in areas of the world where infection with *Plasmodium falciparum* is endemic. Over 1 million children die each year in sub-Saharan Africa.<sup>1,2</sup> Significant numbers of adults are affected throughout the world in endemic areas of South America, Africa and Southern Asia. In addition, malaria is a significant risk for travellers from non-endemic areas.

Studies of childhood severe malaria in Africa over the last 15-20 years have focused on improving understanding of the disease, translating into better diagnosis and treatment. As part of this effort, studies of the eye have yielded new information on disease classification and prognosis, as well as giving insights into underlying pathophysiological mechanisms. A unique cluster of clinical signs termed malarial retinopathy has been described<sup>3-5</sup> with components shown to be useful prognostic indicators for death.<sup>6-8</sup> A classification system has been developed and tested.<sup>9</sup>

The diagnosis of cerebral malaria is made on the clinical grounds of coma in the presence of *P. falciparum* parasites in the peripheral blood and in the absence of other causes of coma. Coma in children is assessed using the Blantyre coma score (BCS), which ranges from 0-5. At the deepest levels of coma (BCS 0-2) a diagnosis of cerebral malaria is made. A recent paper from a postmortem study of children dying with malaria parasitaemia showed that 23% of cases with this clinical diagnosis did not have pathological features usually associated with cerebral malaria, and had another identifiable cause of death.<sup>10</sup> There was a strong correlation between the presence/absence of malarial retinopathy and the pathological features of cerebral malaria.

The importance of malarial retinopathy in the diagnosis of severe malaria is becoming increasingly apparent. As a result, there is a need for the introduction of standardized examination of the fundus of the eye. We have used our experience in studying the features of the retinopathy to develop this field guide for the use of other malaria research teams and for clinicians caring for patients with coma. We conducted a series of consensus sessions to refine our previous classification protocols and develop a set of standard images against which grading can be performed (see p. 6). A set of examples is also included (see p. 10).

### Principles of ophthalmic examination

When examining the eye of a patient in whom malaria is suspected it is essential to dilate the pupil. In patients with heavily pigmented irides tropicamide (0.5% or 1.0%) and phenylephrine (2.5%) eye drops are required. Tropicamide alone is usually sufficient in patients with lighter coloured irides. One drop of each drug, repeated after 5 min, is usually sufficient. Wait 30-45 min for adequate dilatation and confirm with a pen torch before attempting fundus examination. Cyclopentolate 1% is an alternative; however, it takes longer to work and its effects can last up to 24 h.

A combination of direct and indirect ophthalmoscopy is recommended. For indirect ophthalmoscopy a +20 dioptre aspheric condensing lens is ideal. The +28 dioptre lens can help in cases with suboptimal dilation. The +15 dioptre lens gives better magnification for assessment of the macula and the disc, as does a direct ophthalmoscope. However, the grading scheme was developed using a +20 dioptre lens and it alone is sufficient. Grading is based on involvement of the disc, the macula and the periphery. Examination of the periphery is the most difficult. Levels of coma and agitation vary between patients and fluctuate within a single patient; so systematic examination of the fundus can be difficult. One sequence that can be followed comprises starting with the optic disc, moving to the macula and then observing each quadrant of the retina.

### Principles of grading

The macula is defined as the zone of retina roughly within a circle centred on the centre of the fovea. The temporal arcade vessels define the superior, inferior, and most of the nasal borders. The temporal border of the macula is defined as an imaginary arc extending from the centre of the fovea and whose radius is 2.5 disc diameters (see schematic in Figures 1 and 2). The fovea is defined as a circle with a diameter equal to that of the optic disc.

Peripheral retina is defined as all retina lying outside the macula. It is divided into quadrants: temporal, superior, inferior and nasal (see Figures 1 and 2). Because of the clinical condition of an individual child it is not always possible to complete a satisfactory examination of all peripheral quadrants. Agitation, seizures, tonic ocular deviation, inadequate dilatation and the position of infusion lines can all interfere with clinical assessment.

Retinal signs in severe malaria

**RETINAL STUDIES IN SEVERE MALARIA**

Name :

ID No :

**Right eye**

**Left eye**

**Haemorrhages :** 0 1-5 5-20 20-50 50+  
% white centred : none 25-50 50-75 >75

0 1-5 5-20 20-50 50+  
none 25-50 50-75 >75

**Papilloedema :** Y/N If Yes: mild/mod/severe

Y/N If Yes: mild/mod/severe

**Macular whitening :**  
( $\leq 2.5$  DD centre of fovea) 0 <1/3 1/3-1  $\geq 1$  DA

0 <1/3 1/3-1  $\geq 1$  DA

**Peripheral whitening** (by quadrant):

temp	0	1+	2+	3+	NS
sup	0	1+	2+	3+	NS
inf	0	1+	2+	3+	NS
nasal	0	1+	2+	3+	NS

0	1+	2+	3+	NS
0	1+	2+	3+	NS
0	1+	2+	3+	NS
0	1+	2+	3+	NS

sum of quadrantscores \_\_\_\_\_  
number of quadrants seen \_\_\_\_\_

**Vessel changes** (by quadrant) :

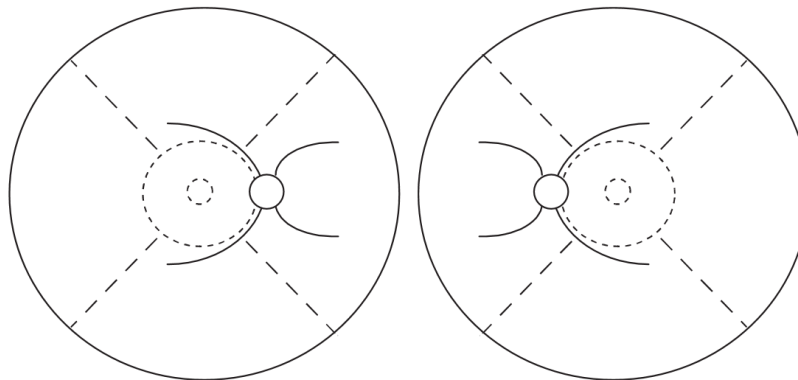
	arteries /veins			capillaries		
temp	0	Or	W	0	W	NS
sup	0	Or	W	0	W	NS
inf	0	Or	W	0	W	NS
nasal	0	Or	W	0	W	NS

	arteries /veins			capillaries		
0	Or	W	0	W	NS	
0	Or	W	0	W	NS	
0	Or	W	0	W	NS	
0	Or	W	0	W	NS	

number of quadrants vascular change \_\_\_\_\_  
number of quadrants seen \_\_\_\_\_

subjective overall severity score 1+ 2+ 3+

1+ 2+ 3+



**Examined by:**

**Date:**

*Insert version No. and date*

**Figure 1** Form for the full standardized grading of malarial retinopathy. Temp, temporal; sup, superior; inf, inferior

**RETINAL STUDIES IN SEVERE MALARIA**

Name :

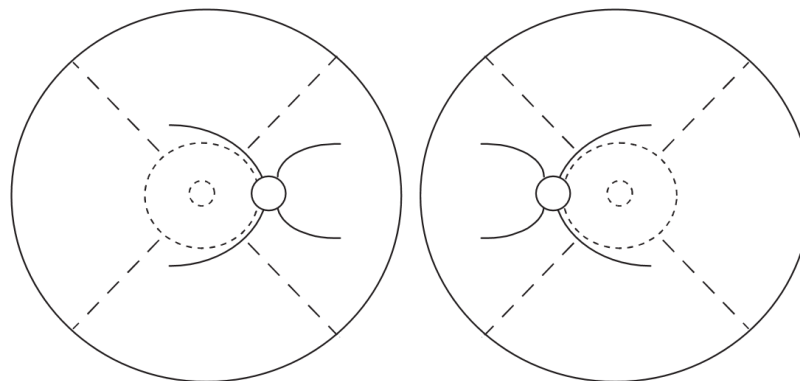
ID No :

**Right eye**

**Left eye**

<b>Haemorrhages :</b>	0 1-5 5-20 20-50 50+	0 1-5 5-20 20-50 50+
% white centred :	none 25-50 50-75 >75	none 25-50 50-75 >75
<b>Papilloedema :</b>	Y/N If Yes: mild/mod/severe	Y/N If Yes: mild/mod/severe
<b>Macular whitening :</b> ( $\leq 2.5$ DD centre of fovea)	0 <1/3 1/3-1 $\geq 1$ DA	0 <1/3 1/3-1 $\geq 1$ DA
<b>Peripheral whitening (by quadrant):</b>		
temp	0 1+ 2+ 3+ NS	0 1+ 2+ 3+ NS
sup	0 1+ 2+ 3+ NS	0 1+ 2+ 3+ NS
inf	0 1+ 2+ 3+ NS	0 1+ 2+ 3+ NS
nasal	0 1+ 2+ 3+ NS	0 1+ 2+ 3+ NS
<b>Vessel changes (by quadrant):</b>		
temp	0 malarial NS	0 malarial NS
sup	0 malarial NS	0 malarial NS
inf	0 malarial NS	0 malarial NS
nasal	0 malarial NS	0 malarial NS

Comment on other vessel changes seen:



Examined by :

Date:

*Insert version No. and date*

**Figure 2** Form for the simplified standardized grading of malarial retinopathy. See Figure 1 for key to abbreviations

*Retinal signs in severe malaria*

During grading, findings are recorded on a standard form, which has been developed over several malaria seasons and is shown in Figure 1. Where there is doubt, when assigning a grade for a particular lesion, the grader should score it as present if he/she is 50% certain of its presence/extent. 'NS' means 'not seen', and this is recorded when the examination is not adequate owing to factors listed above; it does not mean that the sign is absent. Absence of a sign after satisfactory examination is recorded as '0, none, or no'.

**Description and definition of specific lesions***Retinal whitening*

Retinal whitening may occur in the macula or in the periphery. The features of retinal whitening are:

- colour (opacification of the normally clear retina) ranging from subtle greying through white or cream
- zones of involvement are usually well demarcated and range in size from 100 to 1000  $\mu\text{m}$  (the disc is about 1500  $\mu\text{m}$ ) but may involve a greater extent by developing confluence
- often in a mosaic pattern in the periphery
- preferentially affects retinal vascular watershed zones: fovea, temporal horizontal raphe, pre-equatorial, temporal > nasal
- sparing of the perivascular retina in peripheral whitening
- the centre of the fovea is spared (roughly equivalent to the anatomical foveola).

*Macular whitening (Standards 1-3, Examples A-D)*

Macular whitening is graded into mild (1+), moderate (2+) or severe (3+) depending on extent of involvement. Standards 1 and 2 illustrate the maximum extent of mild (<1/3 disc area [DA]) and moderate ( $\geq 1/3-1$  DA), respectively. When assessing the extent of involvement, you should mentally compact the zones of involvement into a notional circle using the optic disc as the nominal equivalent of a DA. When assessing whitening, consider its location and extent, but not colour or density.

Extension temporally along the horizontal raphe is illustrated in Standard 1 and Examples B-D. Confluence is illustrated in Example D; confluence is not a determinant of grade in the macula.

Peripheral (or extramacular) whitening (Standards 4-6): Grading peripheral whitening is more difficult – inter-observer variability, particularly with new observers, is not good for this sign.<sup>9</sup> It is graded as mild (1+), moderate (2+) or severe (3+) (widespread mosaic or patches of confluence) for each quadrant with a summation score to allow for the possibility of one or more quadrants being unobservable.

$$\text{Peripheral whitening score} = \frac{\text{Sum of scores for each quadrant}}{\text{Number of quadrants seen}}$$

*Vessel changes*

In severe malaria, changes, which can vary markedly, are visible in the arterioles and venules and also in the capillaries (Standards 8-10, Examples G-K).

*Arterioles/venules* Signs seen in larger vessels include:

- orange or white colour at the margin of the blood column referred to as tram-lining (Standards 7 and 8)

- the luminal margin of this tram-lining may be smooth or irregular (Standard 8)
- arterioles and venules may be orange or white across their full width (Standards 7 and 8).

These vessel changes can be confused with an optical illusion caused by reflected light when using the indirect ophthalmoscope. Take care to differentiate from true tram-lining (Example G).

*Capillaries* Signs in capillaries include:

- whitening of the capillary network, which may look like patches of frosting or lace (Standards 8 and 9, Example H and I)
- capillary whitening can occur within patches of peripheral whitening (Example F – distinct white lines can be seen within patches of retinal whitening).

As with peripheral whitening, the problem of not being able to examine one or more quadrants for vessel changes is handled by recording the number of quadrants affected and the number of quadrants examined. A vessel score is then calculated:

$$\text{Vessel changes score} = \frac{\text{Number of affected quadrants}}{\text{Number of quadrants seen}}$$

To date, there is no satisfactory system with reasonable interobserver agreement for grading the severity of vessel changes. We consider the presence of 'malaria vessel changes' of any severity to be a pathognomonic sign of cerebral malaria and suggest that effort put into studying questionable vessels to determine if they are abnormal is more important than grading overall severity of vessel changes. Nonetheless, experienced examiners may make a subjective assessment (mild (1+), moderate (2+), severe (3+)) of the overall severity of vessel changes for the eye, taking into consideration the following factors:

- area of capillary involvement
- number of branches of vessel change
- length of involvement
- overall variety and extent of vessel changes.

Children with severe malarial retinopathy usually show more than one of the signs described above as illustrated in Example J.

*Haemorrhages*

Haemorrhages are frequently present and are most often round; the majority will have white centres. Occasionally, the haemorrhages may be very large, lie on top of the retina as large blots, or extend into the vitreous cavity. Flame-shaped haemorrhages are not typical but may accompany papilloedema.

In scoring haemorrhages the total number in the entire retina is assessed followed by the proportion that are white centred. Increasing frequency of haemorrhages is a risk factor for death. Because of the difficulty in examining the entire retina in many children, the number of haemorrhages in each eye can be underestimated.

*Optic disc*

The significance of papilloedema in cerebral malaria is not clear. It is the strongest risk factor for poor outcome among comatose children with clinical cerebral malaria.<sup>6,7</sup> It accompanies other retinal features of cerebral malaria in a proportion

**Box 1** Acute papilloedema in severe malaria

<p>Mild papilloedema (Standard 10)</p> <ul style="list-style-type: none"> <li>● One to three quadrants of abnormal elevation of the disc with blurring of the margin, no disc haemorrhages.</li> </ul> <p>Moderate papilloedema (Standard 11) any of:</p> <ul style="list-style-type: none"> <li>● Four quadrants of abnormal elevation of the disc with blurring of the margin</li> <li>● Any abnormal elevation of the disc with: <ul style="list-style-type: none"> <li>○ Disc haemorrhages (less than five)</li> <li>○ Dilated pre-papillary capillaries.</li> </ul> </li> </ul> <p>Severe papilloedema (Standard 12) any of:</p> <ul style="list-style-type: none"> <li>● Marked elevation of the disc with blurred margin with loss of the optic disc cup</li> <li>● Any elevation of the disc with five or more disc haemorrhages.</li> </ul>
--

of cases and increases the risk of poor outcome. However, it is not specific to cerebral malaria and can occur in many other conditions that cause coma. Thus, papilloedema in the absence of retinal whitening, vessel changes, or the round, white-centred haemorrhages of cerebral malaria should prompt the examiner to consider other causes of coma.

Features of papilloedema include elevation of the disc, blurring of the disc margin, opacification of the peripapillary nerve fibre layer, dilatation of the pre-papillary capillary plexus, hyperaemia, dilatation of the large veins, loss of cupping, splinter haemorrhages, cotton wool spots, loss of spontaneous pulsation. The exact relationship and significance of each of these features remains uncertain in many diseases. This especially applies to the hyperaemia that occurs frequently in children with severe malaria.

In order to classify the severity of disc changes in severe malaria a classification was developed over three malaria seasons (Blantyre, 1999, 2000; Kilifi, 2001) and is shown in Box 1. The optic disc in children with severe malaria may appear erythematous or hyperaemic in the absence of other disc signs. Spontaneous venous pulsation (SVP) and venous dilatation may be present in these cases. The significance of this sign remains unclear. It separates hyperaemia from other changes of papilloedema allowing for the possibilities of it being a precursor of clinically definite papilloedema or being an indicator of other unrelated metabolic factors. SVP cannot be present if the disc is to be graded as papilloedema. Splinter haemorrhages indicate moderate or severe.

**Hyperaemia:**

- increased dilatation of optic disc capillaries producing erythema
- dilated retinal veins
- no other signs of papilloedema.

Haemorrhages must be no greater than one disc diameter away from the disc margin to be considered to be associated with papilloedema.

**Discussion**

The classification described above has been developed over several years in Blantyre, Malawi, and Kilifi, Kenya, and provides a useful predictor of death.<sup>6-8</sup> The risk of death has been shown to increase with the increasing severity of retinopathy. The increased risk of death ranged in these two studies as follows: presence of malarial retinopathy 1.4-2.4; macular whitening 1.5-2.3; vessel changes 1.8-2.8; presence of haemorrhages 1.5-1.9; 5 or more haemorrhages 2.6-3.0; papilloedema 3.8-7.1.

An interobserver study in 1999 showed a good agreement between two ophthalmologists using a combination

of direct and indirect ophthalmoscopy through dilated pupils (weighted kappa ( $k_w$ ): haemorrhages 0.85, macular whitening 0.68, vessel changes 0.63).<sup>9</sup> This should be the standard for fundus examination using the full grading and classification system. However, we recognize that clinical conditions and the requirements for grading vary widely. We have therefore produced a simplified version of the full grading system in Figure 2 with removal of the assessment for hyperaemia, and the severity grading of vessel changes.

The standard photographs and the additional examples that we have included in this guide are intended for display in emergency and critical care wards where patients are being managed. They will be of value in the training of clinicians in the routine management of patients and for reference in future clinical studies. Although the protocols have been developed and tested in a paediatric population, we believe that they will be equally relevant to adults.

We believe that dilated fundoscopy should be part of the clinical assessment of any patient suspected of having severe or cerebral malaria. The use of our standard images and definitions should improve diagnostic accuracy in this important disease.

**Acknowledgements**

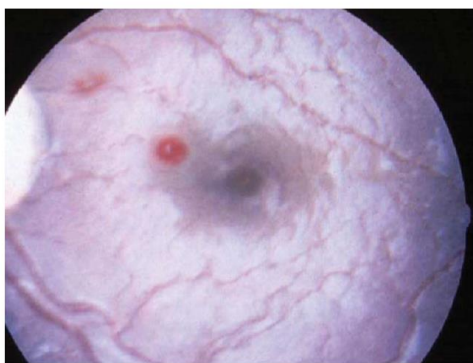We wish to record the contribution of the following colleagues in the development of the clinical description of malarial retinopathy: B Hoar, J Gardiner, S Glover, J Lochhead, A Movafaghly and C Southern. We also wish to acknowledge the financial support of the following: The Wellcome Trust, The National Institutes of Health, The Beit Trust, The Foundation for the Prevention of Blindness.

**References**

- 1 World Health Organization. Communicable diseases cluster. Severe falciparum malaria. *Trans R Soc Trop Med Hyg* 2000;**94**(Suppl. 1): S1-90
- 2 Molyneux ME, Taylor TE, Wirima JJ, Borgstein A. Clinical features and prognostic indicators in paediatric cerebral malaria: a study of 131 comatose children. *Q J Med* 1989;**265**:441-9
- 3 Lewallen S, Taylor TE, Molyneux ME, Wills BA, Courtwright P. Ocular fundus findings in Malawian children with cerebral malaria. *Ophthalmology* 1993;**100**:857-61
- 4 Hero M, Harding SP, Riva C, Winstanley PA, Marsh K. Photographic and angiographic characterisation of retinal appearances in severe malaria in Kenyan children. *Arch Ophthalmol* 1997;**115**:997-1003
- 5 Lewallen S, Harding SP, Ajewole J, et al. A review of the spectrum of clinical fundus findings in *P. falciparum* malaria in African children with a proposed classification and grading system. *Trans R Soc Trop Med Hyg* 1999;**93**:619-22
- 6 Lewallen S, Bakker H, Taylor TE, Wills BA, Courtwright P, Molyneux ME. Retinal findings predictive of outcome in cerebral malaria. *Trans R Soc Trop Med Hyg* 1996;**90**:144-6
- 7 Beare NA, Southern C, Chalira C, Taylor TE, Molyneux ME, Harding SP. Prognostic significance and course of retinopathy in children with severe malaria. *Arch Ophthalmol* 2004;**122**:1141-7
- 8 Lewallen S, Beare N, Molyneux ME, et al. Case fatality rates vary in children with CM depending on ocular findings [Abstract]. *Dubai: International Society for Geographical and Epidemiological Ophthalmology*. Vancouver: ISGEO, 2004
- 9 Beare NA, Southern C, Lochhead J, Molyneux ME, Lewallen S, Harding SP. Inter-observer concordance in grading retinopathy in cerebral malaria. *Ann Trop Med Parasitol* 2002;**96**:105-8
- 10 Taylor TE, Fu WJ, Carr RA, et al. Differentiating the pathologies of cerebral malaria by post mortem parasite counts. *Nature Med* 2004;**10**:143-5

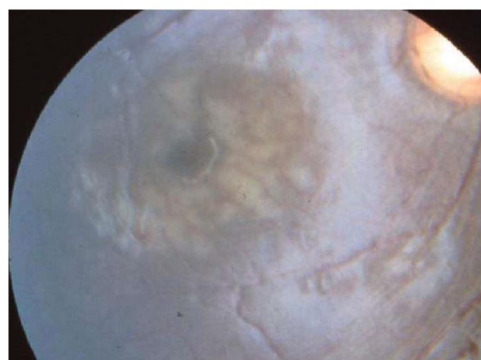
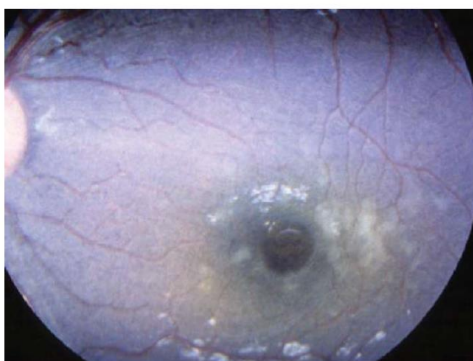*Retinal signs in severe malaria***Standard Photographs:**

The 12 standard photographs are used during the process of grading malarial retinopathy



**Standard 1** Mild macular whitening  $< 1/3$  disc area (DA) (maximum extent for  $< 1/3$  DA). Note small foci of whitening around foveola extending into temporal macula along horizontal raphe. Also visible are a single white centred haemorrhage and a nerve fibre layer haemorrhage near the disc

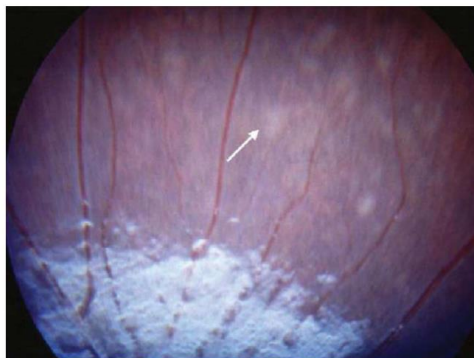
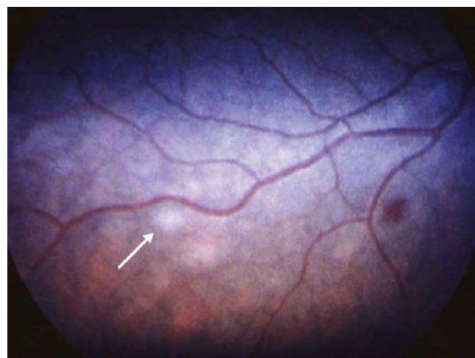
**Standard 2** Moderate macular whitening  $1/3-1$  DA (maximum extent for  $1/3-1$  DA). Whitening is more extensive; foveola is dark in this image, a feature that is not unusual in this population



**Standard 3** Severe macular whitening  $> 1DA$ . Extensive patchy whitening

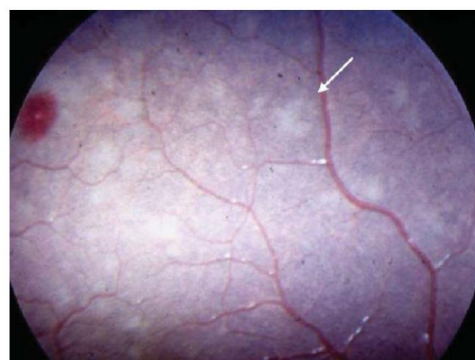*Retinal signs in severe malaria*

**Standard 4** Mild peripheral whitening (1+). Note two foci of whitening (one arrowed) seen against a background of normal choroidal pigment variation

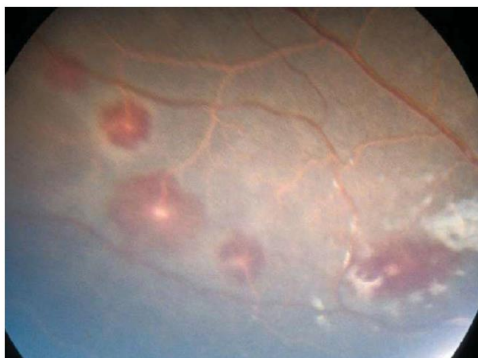

**Standard 5** Moderate peripheral whitening (2+) (the minimum for standard 2+). The bright area seen inferiorly in this image is reflection artefact. One focus of whitening arrowed

**Standard 6** Severe peripheral whitening (3+) (the minimum for standard 3+). One focus of whitening arrowed

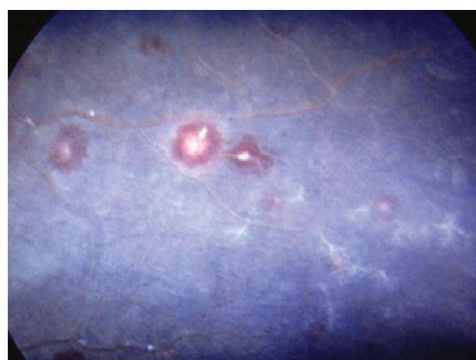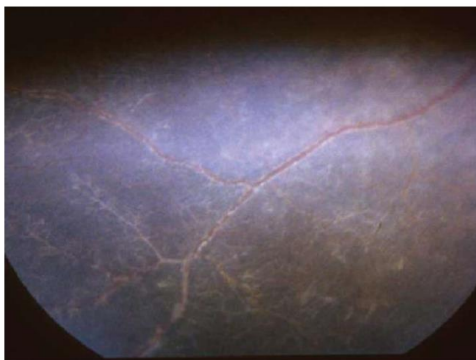




*Retinal signs in severe malaria*

**Standard 7** Orange vessel and orange tram-lining. Smaller branches show complete orange colouration while larger vessels running from 12 o'clock to 3 o'clock show orange tram-lining

**Standard 8** White tram-lining, white vessel and extensive capillary whitening. The luminal edge of the white tram-lining is irregular along the length of the larger venule in this image

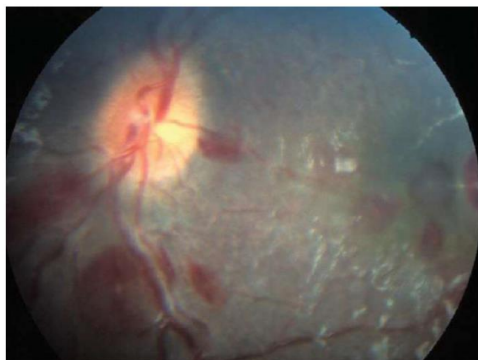
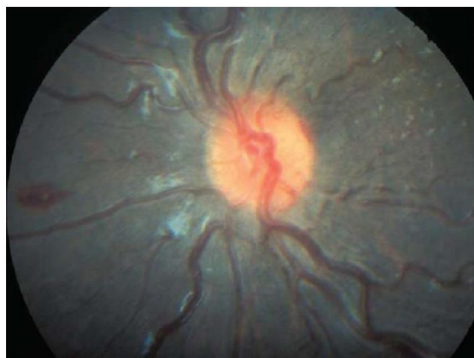


**Standard 9** Capillary whitening. Zones of capillary whitening are visible with some orange tram-lining within the retinal vessels. Several white-centred haemorrhages are seen

---

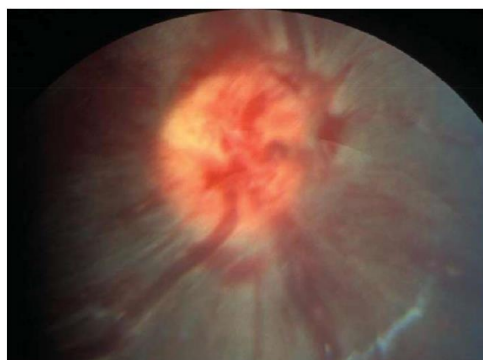
*Retinal signs in severe malaria*

**Standard 10** Mild papilloedema. Note elevation and blurring of superior and inferior quadrants of optic disc and absence of haemorrhages



**Standard 11** Moderate papilloedema. Four quadrants elevation and blurring with a single haemorrhage at the temporal disc margin

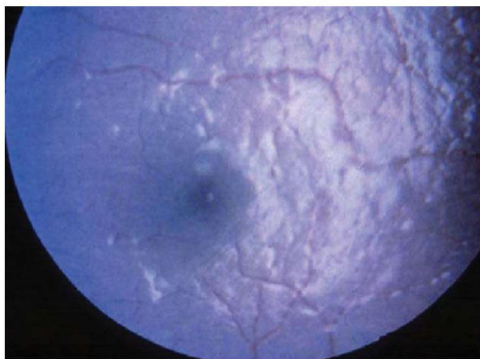
**Standard 12** Severe papilloedema. Four quadrants of elevation and blurring with marked elevation and absent central cup. Five or more haemorrhages



*Retinal signs in severe malaria*

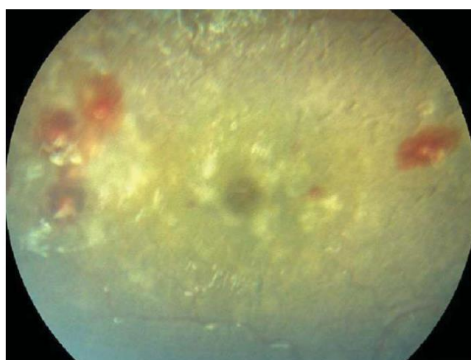
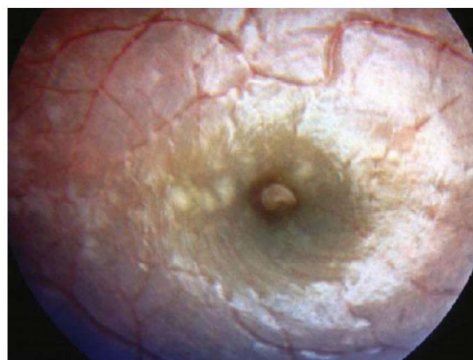---

**Examples:** These examples are included to show further variation in clinical features



**Example A** Mild macular whitening [ $<1/3$  disc area (DA)]. Two small foci of whitening adjacent to the foveola (arrows) to be distinguished from reflections elsewhere within the macula

**Example B** Moderate macular whitening ( $1/3-1$  DA). Extension of whitening into temporal macula along the horizontal raphe is shown

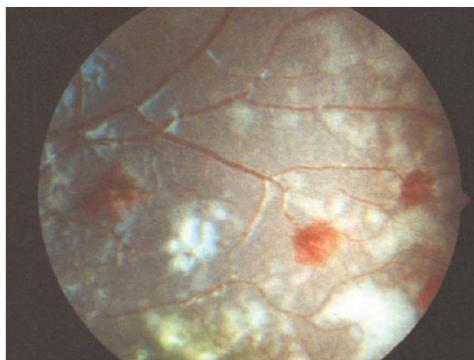
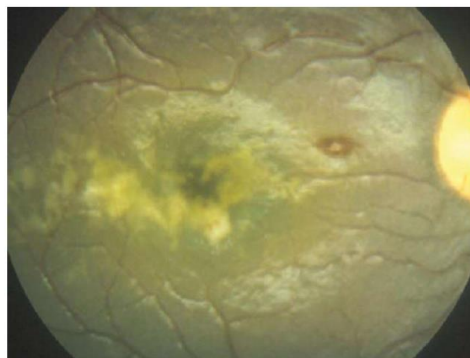


**Example C** Severe macular whitening ( $>1$  DA). Extensive whitening in temporal macula with several haemorrhages

---

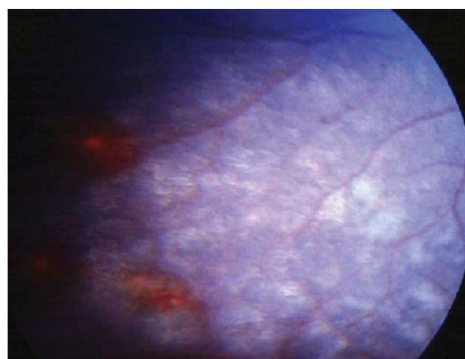
*Retinal signs in severe malaria*

**Example D** Severe macular whitening with confluence within fovea. A single white-centred haemorrhage is also present



**Example E** Severe peripheral whitening (3+). Confluence of whitening and perivascular sparing is well shown in periphery between 10 o'clock and 12 o'clock. Note fovea is visible at extreme edge of image at 1 o'clock with severe macular whitening

**Example F** Severe peripheral whitening (3+). Note subtle whitening of capillary tree within patches of retinal whitening and sparing of perivascular retina

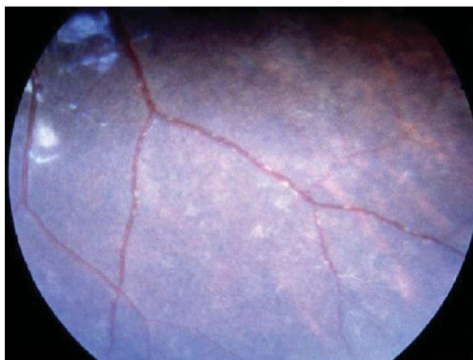
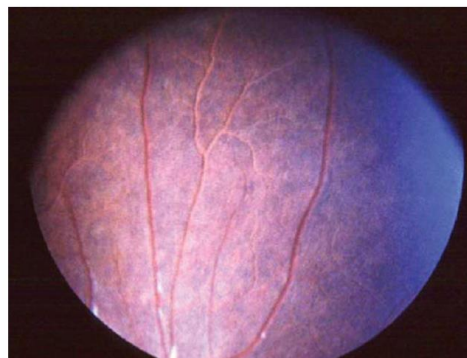


---

*Retinal signs in severe malaria*

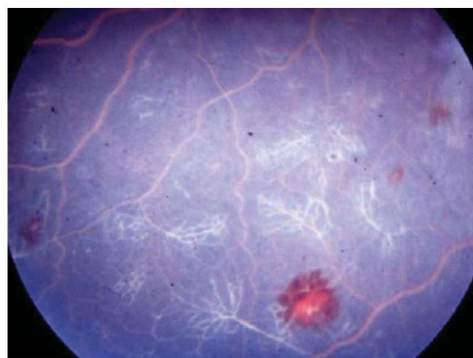
---

**Example G** Orange tram-lining of vessel. A margin of depigmented retinal pigment epithelium is seen alongside vessels, a feature often seen in African children and not to be confused with orange tram-lining

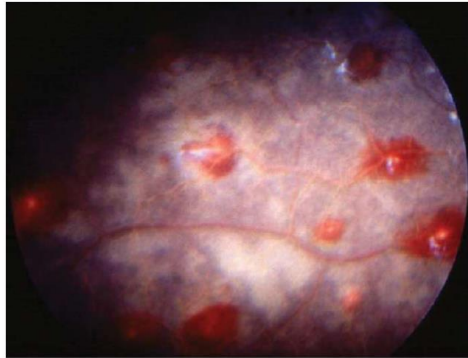


**Example H** Subtle capillary whitening. Whitening is visible within groups of capillaries plus some focal changes within the vein adjacent

**Example I** Marked capillary whitening. Whitening is seen widely in the capillary tree with white and orange pre- and post-capillary vessels and orange discolouration of larger vessels



---

*Retinal signs in severe malaria*

**Example J** White centred haemorrhages, peripheral retinal whitening (3+) with confluence, perivascular sparing and subtle capillary whitening, orange discolouration of vessels



## 10.2 Data collection forms

### 10.2.1 Enrolment

#### Eye Enrolment

Patient code: \_\_\_\_\_ Initials: \_\_\_\_\_ Age: \_\_\_\_\_ Hospital: \_\_\_\_\_

Examination: Date: \_\_\_\_ / \_\_\_\_ / \_\_\_\_ Time: \_\_\_\_ : \_\_\_\_ Day of study: 0

#### Eligibility Screening

##### Diagnosis

Severe malaria  Uncomplicated malaria  Healthy

##### History

<b>Glaucoma*</b>	Yes		No
<b>Tropicamide allergy*</b>	Yes		No
<b>False eye</b>	Left	Right	No

##### Examination

<b>ANTERIOR</b>	<b>Right Eye</b>					<b>Left Eye</b>				
False/missing eye	Yes		No		NS	Yes		No		NS
Corneal scarring	No	Mild	Mod	Severe	NS	No	Mild	Mod	Severe	NS
Cataract	No	Mild	Mod	Severe	NS	No	Mild	Mod	Severe	NS
Fundus visible?*	Yes			No		Yes			No	
If 'Severe' is marked for any of the above then this precludes retinoscopy										

**\*If patient has: Glaucoma, tropicamide allergy or both fundi not visible then they are excluded from the study**

**Excluded**

**Included**

**If included, complete Eye History and Daily Eye Examination Record for day 0**

Doctor signature.....

Date...../...../.....

Name.....

1/1

## 10.2.2 Eye history

## Eye Enrolment

Patient code: \_\_\_\_\_ Initials: \_\_\_\_\_ Age: \_\_\_\_\_ Hospital: \_\_\_\_\_

## History

Eye History:	Comorbidities:	Symptoms in the past 2 weeks:
Literate: Y / N	<b>Glaucoma*:</b> Y / N	Loss of vision: Y / N
Highest Schooling: Nil / 1° / 2° / Uni	Diabetes Mellitus: Y / N	Blurred vision: Y / N
Wears glasses Y / N	Hypertension: Y / N	Scotomata: Y / N
Short-sighted Y / N	Stroke: Y / N	Photophobia: Y / N
Long-sighted Y / N	Anaemia: Y / N	Diplopia: Y / N
Previous eye problem Y / N	Other neurological: Y / N	↓Visual Field: Y / N
Previous eye review Y / N (when: _____ what: _____)	(specify: _____)	Loss of colour vision: Y / N
Previous eye Surgery Y / N (when: _____ what: _____)	Previous malaria: Y / N (date: _____)	Seizure: Y / N
		Headache: Y / N
		Limb weakness: Y / N

**\*If the patient has glaucoma they are excluded from the study**

Medications	Taken?	Route (IV/oral)	Dose per day (mg)	Duration	Last Taken
Chloroquine	Y / N				
Hydroxychloroquine	Y / N				
Primaquine	Y / N				
Quinine	Y / N				
Ethambutol	Y / N				
Ciprofloxacin	Y / N				
O/ Levo/ Moxi/Nor - floxacin	Y / N				
Chlpropromazine	Y / N				
Other _____					

Doctor signature.....

Date...../...../.....

Name.....

2/1



### 10.2.3 Visual Function

Serial retinal photography for malarial retinopathy in patients with severe malaria

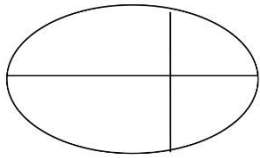
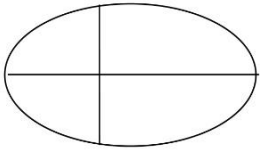
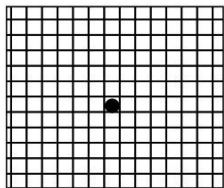
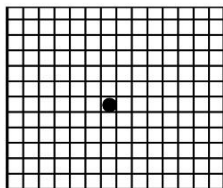


#### Eye Examination Record

Patient code \_\_\_\_\_ Initials: \_\_\_\_\_ Age: \_\_\_\_\_ Hospital: **CMCH**

If unable to do eye examination, please state reason: \_\_\_\_\_

Examination: Date: \_\_\_\_ / \_\_\_\_ / \_\_\_\_ Time: \_\_\_\_ : \_\_\_\_ Day of study: \_\_\_\_\_

#### Functional Examination

VISION	Right Eye					Left Eye						
<b>Pupils</b>												
Size (mm)												
React to light	Yes	No	Slow	NS		Yes	No	Slow	NS			
<b>Acuity</b>												
Gross	Threat	Light	Hand	Digits	NS	Threat	Light	Hand	Digits	NS		
Snellen E	20 /				NS	20 /				NS		
<b>Colour vision</b>												
Ishihara	Right	Wrong	Can't do	NS		Right	Wrong	Can't do	NS			
<b>Visual Fields (by quadrant)</b>												
					Normal	NS					Normal	NS
Shade field deficit on diagram						Nose						
<b>Macula</b>												
					Normal	NS					Normal	NS
Amsler grid												
Mark area:												
Distorted 												
Missing 												
<b>KEY</b> Threat = blinks in response to threat      Light = sees light and dark Hand = sees hand movements      Digits = counts fingers NS = not adequately examined												

Doctor's signature.....

Date...../...../.....

Name.....

### 10.2.4 Fundoscopy and Retinal Photography

Serial retinal photography for malarial retinopathy in patients with severe malaria

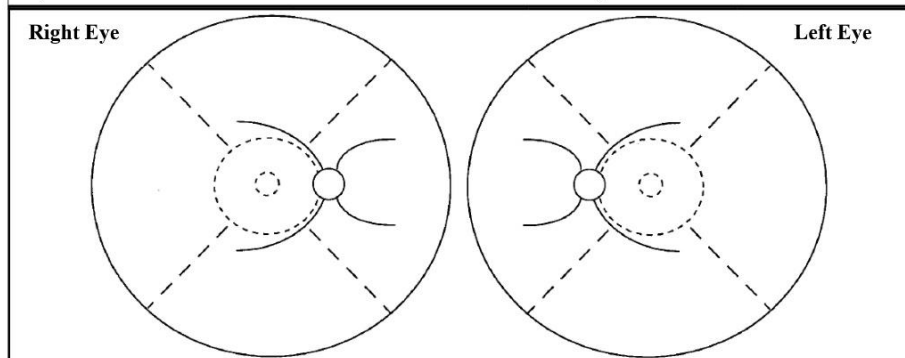
#### Eye Examination Record

Patient code \_\_\_\_\_ Initials: \_\_\_\_\_ Age: \_\_\_\_\_ Hospital: **CMCH**

Direct Ophthalmoscopy:  Indirect Ophthalmoscopy:  Camera:

Examination: Date: \_\_\_\_ / \_\_\_\_ / \_\_\_\_ Time: \_\_\_\_ : \_\_\_\_ Day of study: \_\_\_\_\_

FUNDOSCOPY	Right Eye					Left Eye								
<b>Haemorrhages</b>														
Number	0	1-5	6-20	21-50	>50	0	1-5	6-20	21-50	>50				
% white centred	<50		50-75		>75	<50		50-75		>75				
<b>Papilloedema</b>	Yes		No			Yes		No						
<b>Macular Whitening</b> (total coalesced area, optic disc areas)														
Macula <sup>1</sup>	0	<1/3	1/3-1	>1		0	<1/3	1/3-1	>1					
Central foveal area <sup>2</sup>	0	<1/3	1/3-2/3	>2/3		0	<1/3	1/3-2/3	>2/3					
<b>Extramacular/peripheral whitening</b> (by quadrant)														
Temporal	0	1	2	3	NS	0	1	2	3	NS				
Superior	0	1	2	3	NS	0	1	2	3	NS				
Nasal	0	1	2	3	NS	0	1	2	3	NS				
Inferior	0	1	2	3	NS	0	1	2	3	NS				
<b>KEY</b> 0 = no whitening      1 = occasional spots      2 = more than occasional spots / patches of definite mosaic 3 = widespread mosaic / large areas of confluence      NS = cannot be adequately examined (e.g. eyes deviated)														
<b>Vessel delineation/whitening</b> (by quadrant)														
	Arterioles/ Venules			Capillaries				Arterioles/ venules			Capillaries			
Temporal	0	Or	W	0	Or	W	NS	0	Or	W	0	Or	W	NS
Superior	0	Or	W	0	Or	W	NS	0	Or	W	0	Or	W	NS
Nasal	0	Or	W	0	Or	W	NS	0	Or	W	0	Or	W	NS
Inferior	0	Or	W	0	Or	W	NS	0	Or	W	0	Or	W	NS
<b>KEY</b> <sup>1</sup> Macula = extends ≤2.5 disc diameters from centre of fovea, area enclosed by ≤500µm radius from centre of fovea <sup>2</sup> Central foveal area = circle DD = Disc diameter      W = vessel whitening DA = disc area      0 = none      NS = not adequately examined Or = orange discoloration														



Doctor's signature.....

Date...../...../.....

Name.....

### 10.2.5 Fluorescein angiography

**Serial retinal photography for malarial retinopathy in patients with severe malaria**  
**Fluorescein Angiography Record**

Patient Code: \_\_\_\_\_ Initials: \_\_\_\_\_ Age: \_\_\_\_\_ Hospital: **CMCH**

File name: **Right:** \_\_\_\_\_ **Left:** \_\_\_\_\_

(ABCDE A: 1=right, 2=left B: 0=severe, 1=uncomp, 2=healthy, 3=sepsis, 4=enkeph CDE: pt code)

#	Date (dd/mm/yy)	Time (seconds)	Side		Area of focus					
			Right	Left	Inferior	Macula	Disc	Tempo- poral	Nasal	Super- ior
1										
2										
3										
4										
5										
6										
7										
8										
9										
10										
11										
12										
13										
14										
15										
16										
17										
18										
19										
20										
21										
22										
23										
24										
25										
26										
27										
28										
29										
30										
31										
32										
33										
34										
35										
36										
37										
38										
39										
40										
41										
42										
43										
44										
45										

Doctor's signature \_\_\_\_\_ Name \_\_\_\_\_ Date \_\_\_\_/\_\_\_\_/\_\_\_\_

Doctor's signature \_\_\_\_\_ Name \_\_\_\_\_ Date \_\_\_\_/\_\_\_\_/\_\_\_\_

---

### 10.3 Normal ranges for laboratory tests

Variable	Range	Units
Haematocrit males	40 – 54	%
Haematocrit females	37 – 47	%
Peripheral white blood cell count	4.0 – 11.0	*10 <sup>9</sup> /L
Platelet count	150 – 400	*10 <sup>9</sup> /L
Serum sodium	135 – 145	mmol/L
Serum potassium	3.5 – 5.0	mmol/L
Total serum bilirubin	0.2 – 1.2	mg/dL
Serum alanine aminotransferase	5 – 35	U/L
Serum alkaline phosphatase	30 - 150	U/L
Serum albumin	3.5 - 5.0	g/100ml
Serum creatinine	0.8 – 1.7	mg/dL
Blood urea	7.0 – 19.0	mg/dL
Plasma lactate	0.6 – 2.4	mmol/L
Venous bicarbonate	24 - 30	mmol/L
Serum base excess	±2	mmol/L

---

**BIBLIOGRAPHY**

1. Organization WH. Malaria Factsheet No 94. 2012. <http://www.who.int/mediacentre/factsheets/fs094/en/index.html> (accessed 8th October 2012).
2. Baird JK. Evidence and implications of mortality associated with acute *Plasmodium vivax* malaria. *Clin Microbiol Rev* 2013; **26**(1): 36-57.
3. Yusof R, Lau YL, Mahmud R, et al. High proportion of knowlesi malaria in recent malaria cases in Malaysia. *Malar J* 2014; **13**: 168.
4. Barber BE, William T, Grigg MJ, et al. A prospective comparative study of knowlesi, falciparum, and vivax malaria in Sabah, Malaysia: high proportion with severe disease from *Plasmodium knowlesi* and *Plasmodium vivax* but no mortality with early referral and artesunate therapy. *Clin Infect Dis* 2013; **56**(3): 383-97.
5. Sulistyaningsih E, Fitri LE, Loscher T, Berens-Riha N. Diagnostic difficulties with *Plasmodium knowlesi* infection in humans. *Emerg Infect Dis* 2010; **16**(6): 1033-4.
6. Jiang N, Chang Q, Sun X, et al. Co-infections with *Plasmodium knowlesi* and other malaria parasites, Myanmar. *Emerg Infect Dis* 2010; **16**(9): 1476-8.
7. Van den Eede P, Van HN, Van Overmeir C, et al. Human *Plasmodium knowlesi* infections in young children in central Vietnam. *Malar J* 2009; **8**: 249.
8. Sermwittayawong N, Singh B, Nishibuchi M, Sawangjaroen N, Vuddhakul V. Human *Plasmodium knowlesi* infection in Ranong province, southwestern border of Thailand. *Malar J* 2012; **11**: 36.
9. Luchavez J, Espino F, Curameng P, et al. Human Infections with *Plasmodium knowlesi*, the Philippines. *Emerg Infect Dis* 2008; **14**(5): 811-3.
10. Barber BE, William T, Grigg MJ, Yeo TW, Anstey NM. Limitations of microscopy to differentiate *Plasmodium* species in a region co-endemic for *Plasmodium falciparum*, *Plasmodium vivax* and *Plasmodium knowlesi*. *Malar J* 2013; **12**: 8.
11. Moyes CL, Henry AJ, Golding N, et al. Defining the geographical range of the *Plasmodium knowlesi* reservoir. *PLoS Negl Trop Dis* 2014; **8**(3): e2780.
12. Dondorp AM, Lee SJ, Faiz MA, et al. The relationship between age and the manifestations of and mortality associated with severe malaria. *Clin Infect Dis* 2008; **47**(2): 151-7.
13. World Health Organization. Guidelines for the treatment of malaria. 2nd ed. Geneva: World Health Organization; 2010.
14. Singh B, Kim Sung L, Matusop A, et al. A large focus of naturally acquired *Plasmodium knowlesi* infections in human beings. *Lancet* 2004; **363**(9414): 1017-24.
15. Anstey NM, Douglas NM, Poespoprodjo JR, Price RN. *Plasmodium vivax*: clinical spectrum, risk factors and pathogenesis. *Adv Parasitol* 2012; **80**: 151-201.
16. William T, Menon J, Rajahram G, et al. Severe *Plasmodium knowlesi* malaria in a tertiary care hospital, Sabah, Malaysia. *Emerg Infect Dis* 2011; **17**(7): 1248-55.
17. Maude RJ, Hasan MU, Hossain MA, et al. Temporal trends in severe malaria in Chittagong, Bangladesh. *Malar J* 2012; **11**: 323.
18. Mishra SK, Mohanty S, Satpathy SK, Mohapatra DN. Cerebral malaria in adults -- a description of 526 cases admitted to Ispat General Hospital in Rourkela, India. *Ann Trop Med Parasitol* 2007; **101**(3): 187-93.

19. William T, Jelip J, Menon J, et al. Changing epidemiology of malaria in Sabah, Malaysia: increasing incidence of *Plasmodium knowlesi*. *Malar J* 2014; **13**: 390.
20. Doolan DL, Dobano C, Baird JK. Acquired immunity to malaria. *Clin Microbiol Rev* 2009; **22**(1): 13-36, Table of Contents.
21. Cutts JC, Powell R, Agius PA, Beeson JG, Simpson JA, Fowkes FJ. Immunological markers of *Plasmodium vivax* exposure and immunity: a systematic review and meta-analysis. *BMC Med* 2014; **12**: 150.
22. Taylor SM, Parobek CM, Fairhurst RM. Haemoglobinopathies and the clinical epidemiology of malaria: a systematic review and meta-analysis. *Lancet Infect Dis* 2012; **12**(6): 457-68.
23. Imwong M, Woodrow CJ, Hendriksen IC, et al. Plasma concentration of parasite DNA as a measure of disease severity in falciparum malaria. *J Infect Dis* 2015; **211**(7): 1128-33.
24. Hanson J, Lee SJ, Mohanty S, et al. A simple score to predict the outcome of severe malaria in adults. *Clin Infect Dis* 2010; **50**(5): 679-85.
25. Rajahram GS, Barber BE, William T, Menon J, Anstey NM, Yeo TW. Deaths due to *Plasmodium knowlesi* malaria in Sabah, Malaysia: association with reporting as *Plasmodium malariae* and delayed parenteral artesunate. *Malar J* 2012; **11**: 284.
26. Singh B, Daneshvar C. Human infections and detection of *Plasmodium knowlesi*. *Clin Microbiol Rev* 2013; **26**(2): 165-84.
27. Desakorn V, Dondorp AM, Silamut K, et al. Stage-dependent production and release of histidine-rich protein 2 by *Plasmodium falciparum*. *Trans R Soc Trop Med Hyg* 2005; **99**(7): 517-24.
28. Hendriksen IC, Mwangi-Amumpaire J, von Seidlein L, et al. Diagnosing severe falciparum malaria in parasitaemic African children: a prospective evaluation of plasma PfHRP2 measurement. *PLoS medicine* 2012; **9**(8): e1001297.
29. Houze S, Boly MD, Le Bras J, Deloron P, Faucher JF. PfHRP2 and PfLDH antigen detection for monitoring the efficacy of artemisinin-based combination therapy (ACT) in the treatment of uncomplicated falciparum malaria. *Malar J* 2009; **8**: 211.
30. UNICEF/UNDP/World Bank/WHO Special Programme for Research and Training in Tropical Diseases., Centers for Disease Control (U.S.), Foundation for Innovative New Diagnostics. Malaria rapid diagnostic test performance : summary results of WHO malaria RDTs product testing: rounds 1-3 [2008-2011]. Geneva: World Health Organization; 2011.
31. Foster D, Cox-Singh J, Mohamad DS, Krishna S, Chin PP, Singh B. Evaluation of three rapid diagnostic tests for the detection of human infections with *Plasmodium knowlesi*. *Malar J* 2014; **13**: 60.
32. Maude RJ, Woodrow CJ, White LJ. Artemisinin Antimalarials: Preserving the "Magic Bullet". *Drug Dev Res* 2010; **71**(1): 12-9.
33. Grigg MJ, William T, Dhanaraj P, et al. A study protocol for a randomised open-label clinical trial of artesunate-mefloquine versus chloroquine in patients with non-severe *Plasmodium knowlesi* malaria in Sabah, Malaysia (ACT KNOW trial). *BMJ Open* 2014; **4**(8): e006005.

34. Dondorp A, Nosten F, Stepniewska K, Day N, White N, South East Asian Quinine Artesunate Malaria Trial g. Artesunate versus quinine for treatment of severe falciparum malaria: a randomised trial. *Lancet* 2005; **366**(9487): 717-25.
35. Dondorp AM, Fanello CI, Hendriksen IC, et al. Artesunate versus quinine in the treatment of severe falciparum malaria in African children (AQUAMAT): an open-label, randomised trial. *Lancet* 2010; **376**(9753): 1647-57.
36. Day NP, Phu NH, Bethell DP, et al. The effects of dopamine and adrenaline infusions on acid-base balance and systemic haemodynamics in severe infection. *Lancet* 1996; **348**(9022): 219-23.
37. van Hensbroek MB, Palmer A, Onyiorah E, et al. The effect of a monoclonal antibody to tumor necrosis factor on survival from childhood cerebral malaria. *The Journal of infectious diseases* 1996; **174**(5): 1091-7.
38. Hemmer CJ, Kern P, Holst FG, Nawroth PP, Dietrich M. Neither heparin nor acetylsalicylic acid influence the clinical course in human Plasmodium falciparum malaria: a prospective randomized study. *The American journal of tropical medicine and hygiene* 1991; **45**(5): 608-12.
39. Hoffman SL, Rustama D, Punjabi NH, et al. High-dose dexamethasone in quinine-treated patients with cerebral malaria: a double-blind, placebo-controlled trial. *The Journal of infectious diseases* 1988; **158**(2): 325-31.
40. Maitland K, Babiker A, Kiguli S, Molyneux E. The FEAST trial of fluid bolus in African children with severe infection. *Lancet* 2012; **379**(9816): 613; author reply -4.
41. Taylor TE, Molyneux ME, Wirima JJ, Borgstein A, Goldring JD, Hommel M. Intravenous immunoglobulin in the treatment of paediatric cerebral malaria. *Clin Exp Immunol* 1992; **90**(3): 357-62.
42. Mohanty D, Ghosh K, Pathare AV, Karnad D. Deferiprone (L1) as an adjuvant therapy for Plasmodium falciparum malaria. *Indian J Med Res* 2002; **115**: 17-21.
43. Smith HJ, Meremikwu M. Iron chelating agents for treating malaria. *Cochrane Database Syst Rev* 2003; (2): CD001474.
44. Akech SO, Jemutai J, Timbwa M, et al. Phase II trial on the use of Dextran 70 or starch for supportive therapy in Kenyan children with severe malaria. *Crit Care Med* 2010; **38**(8): 1630-6.
45. Okoromah CA, Afolabi BB, Wall EC. Mannitol and other osmotic diuretics as adjuncts for treating cerebral malaria. *Cochrane Database Syst Rev* 2011; (4): CD004615.
46. Mohanty S, Mishra SK, Patnaik R, et al. Brain swelling and mannitol therapy in adult cerebral malaria: a randomized trial. *Clinical infectious diseases : an official publication of the Infectious Diseases Society of America* 2011; **53**(4): 349-55.
47. Charunwatthana P, Abul Faiz M, Ruangveerayut R, et al. N-acetylcysteine as adjunctive treatment in severe malaria: a randomized, double-blinded placebo-controlled clinical trial. *Critical care medicine* 2009; **37**(2): 516-22.
48. Meremikwu M, Marson AG. Routine anticonvulsants for treating cerebral malaria. *Cochrane Database Syst Rev* 2002; (2): CD002152.
49. Treeprasertsuk S, Silachamroon U, Krudsood S, et al. Ursodeoxycholic acid and artesunate in the treatment of severe falciparum malaria patients with jaundice. *J Gastroenterol Hepatol* 2010; **25**(2): 362-8.

50. Maude RJ, Silamut K, Plewes K, et al. Randomized controlled trial of levamisole hydrochloride as adjunctive therapy in severe falciparum malaria with high parasitemia. *J Infect Dis* 2014; **209**(1): 120-9.
51. Hanson J, Anstey NM, Bihari D, White NJ, Day NP, Dondorp AM. The fluid management of adults with severe malaria. *Crit Care* 2014; **18**(6): 642.
52. Maitland K, Kiguli S, Opoka RO, et al. Mortality after fluid bolus in African children with severe infection. *N Engl J Med* 2011; **364**(26): 2483-95.
53. Hanson JP, Lam SW, Mohanty S, et al. Fluid resuscitation of adults with severe falciparum malaria: effects on Acid-base status, renal function, and extravascular lung water. *Crit Care Med* 2013; **41**(4): 972-81.
54. Tran TH, Day NP, Nguyen HP, et al. A controlled trial of artemether or quinine in Vietnamese adults with severe falciparum malaria. *N Engl J Med* 1996; **335**(2): 76-83.
55. Taylor TE, Wills BA, Kazembe P, et al. Rapid coma resolution with artemether in Malawian children with cerebral malaria. *Lancet* 1993; **341**(8846): 661-2.
56. Bajiya HN, Kochar DK. Incidence and outcome of neurological sequelae in survivors of cerebral malaria. *J Assoc Physicians India* 1996; **44**(10): 679-81.
57. Brewster DR, Kwiatkowski D, White NJ. Neurological sequelae of cerebral malaria in children. *Lancet* 1990; **336**(8722): 1039-43.
58. Dondorp A, Nosten F, Stepniewska K, Day N, White N. Artesunate versus quinine for treatment of severe falciparum malaria: a randomised trial. *Lancet* 2005; **366**(9487): 717-25.
59. Dondorp AM, Fanello CI, Hendriksen IC, et al. Artesunate versus quinine in the treatment of severe falciparum malaria in African children (AQUAMAT): an open-label, randomised trial. *Lancet* 2010; **376**(9753): 1647-57.
60. Gill MR, Reiley DG, Green SM. Interrater reliability of Glasgow Coma Scale scores in the emergency department. *Ann Emerg Med* 2004; **43**(2): 215-23.
61. Maude RJ, Beare NA, Abu Sayeed A, et al. The spectrum of retinopathy in adults with Plasmodium falciparum malaria. *Trans R Soc Trop Med Hyg* 2009; **103**(7): 665-71.
62. Abu Sayeed A, Maude RJ, Hasan MU, et al. Malarial retinopathy in Bangladeshi adults. *Am J Trop Med Hyg* 2011; **84**(1): 141-7.
63. Beare NA, Southern C, Chalira C, Taylor TE, Molyneux ME, Harding SP. Prognostic significance and course of retinopathy in children with severe malaria. *Arch Ophthalmol* 2004; **122**(8): 1141-7.
64. Silamut K, Phu NH, Whitty C, et al. A quantitative analysis of the microvascular sequestration of malaria parasites in the human brain. *The American journal of pathology* 1999; **155**(2): 395-410.
65. Ponsford MJ, Medana IM, Prapansilp P, et al. Sequestration and microvascular congestion are associated with coma in human cerebral malaria. *J Infect Dis* 2012; **205**(4): 663-71.
66. A. L. Traité Des Fièvres Palustres Avec La Description Des Microbes Du Paludisme. Paris: Octave Doin; 1884.
67. E. M, A B. On summer-autumn malarial fevers, in Two Monographs on Malaria and the Parasites of Malarial Fevers (translated from the first Italian edition by J. H. Thompson). London: The New Sydenham Society; 1894.



68. Nagatake T, Hoang VT, Tegoshi T, Rabbege J, Ann TK, Aikawa M. Pathology of falciparum malaria in Vietnam. *Am J Trop Med Hyg* 1992; **47**(2): 259-64.
69. Sein KK, Maeno Y, Thuc HV, Anh TK, Aikawa M. Differential sequestration of parasitized erythrocytes in the cerebrum and cerebellum in human cerebral malaria. *Am J Trop Med Hyg* 1993; **48**(4): 504-11.
70. Pongponratn E, Turner GD, Day NP, et al. An ultrastructural study of the brain in fatal Plasmodium falciparum malaria. *Am J Trop Med Hyg* 2003; **69**(4): 345-59.
71. Seydel KB, Milner DA, Jr., Kamiza SB, Molyneux ME, Taylor TE. The distribution and intensity of parasite sequestration in comatose Malawian children. *J Infect Dis* 2006; **194**(2): 208-5.
72. Turner GDH, Morrison H, Jones M, et al. An immunohistochemical study of the pathology of fatal malaria. Evidence for widespread endothelial activation and a potential role for intercellular adhesion molecule-1 in cerebral sequestration. *Am J Pathol* 1994; **145**(5): 1057-69.
73. Pongponratn E, Riganti M, Punpoowong B, Aikawa M. Microvascular sequestration of parasitized erythrocytes in human falciparum malaria: a pathological study. *Am J Trop Med Hyg* 1991; **44**(2): 168-75.
74. MacPherson GG, Warrell MJ, White NJ, Looareesuwan S, Warrell DA. Human cerebral malaria. A quantitative ultrastructural analysis of parasitized erythrocyte sequestration. *Am J Pathol* 1985; **119**(3): 385-401.
75. Riganti M, Pongponratn E, Tegoshi T, Looareesuwan S, Punpoowong B, Aikawa M. Human cerebral malaria in Thailand: a clinico-pathological correlation. *Immunol Lett* 1990; **25**(1-3): 199-205.
76. Turner G. Cerebral malaria. *Brain Pathol* 1997; **7**(1): 569-82.
77. Aikawa M, Iseki M, Barnwell JW, Taylor D, Oo MM, Howard RJ. The pathology of human cerebral malaria. *Am J Trop Med Hyg* 1990; **43**(2 Pt 2): 30-7.
78. Idro R, Karamagi C, Tumwine J. Immediate outcome and prognostic factors for cerebral malaria among children admitted to Mulago Hospital, Uganda. *Ann Trop Paediatr* 2004; **24**(1): 17-24.
79. Idro R. Severe anaemia in childhood cerebral malaria is associated with profound coma. *Afr Health Sci* 2003; **3**(1): 15-8.
80. Clavier N, Rahimy C, Falanga P, Ayivi B, Payen D. No evidence for cerebral hypoperfusion during cerebral malaria. *Crit Care Med* 1999; **27**(3): 628-32.
81. Warrell DA, White NJ, Veall N, et al. Cerebral anaerobic glycolysis and reduced cerebral oxygen transport in human cerebral malaria. *Lancet* 1988; **2**(8610): 534-8.
82. White NJ, Warrell DA, Looareesuwan S, Chanthavanich P, Phillips RE, Pongpaew P. Pathophysiological and prognostic significance of cerebrospinal-fluid lactate in cerebral malaria. *Lancet* 1985; **1**(8432): 776-8.
83. White NJ, Miller KD, Brown J, Marsh K, Greenwood B. Prognostic value of CSF lactate in cerebral malaria. *Lancet* 1987; **1**(8544): 1261.
84. Magowan C, Wollish W, Anderson L, Leech J. Cytoadherence by Plasmodium falciparum-infected erythrocytes is correlated with the expression of a family of variable proteins on infected erythrocytes. *J Exp Med* 1988; **168**(4): 1307-20.

85. Kyes SA, Rowe JA, Kriek N, Newbold CI. Rifins: a second family of clonally variant proteins expressed on the surface of red cells infected with *Plasmodium falciparum*. *Proc Natl Acad Sci U S A* 1999; **96**(16): 9333-8.
86. Ockenhouse CF, Klotz FW, Tandon NN, Jamieson GA. Sequestrin, a CD36 recognition protein on *Plasmodium falciparum* malaria-infected erythrocytes identified by anti-idiotypic antibodies. *Proc Natl Acad Sci U S A* 1991; **88**(8): 3175-9.
87. Turner GD, Morrison H, Jones M, et al. An immunohistochemical study of the pathology of fatal malaria. Evidence for widespread endothelial activation and a potential role for intercellular adhesion molecule-1 in cerebral sequestration. *Am J Pathol* 1994; **145**(5): 1057-69.
88. Ockenhouse CF, Ho M, Tandon NN, et al. Molecular basis of sequestration in severe and uncomplicated *Plasmodium falciparum* malaria: differential adhesion of infected erythrocytes to CD36 and ICAM-1. *J Infect Dis* 1991; **164**(1): 163-9.
89. Ockenhouse CF, Tegoshi T, Maeno Y, et al. Human vascular endothelial cell adhesion receptors for *Plasmodium falciparum*-infected erythrocytes: roles for endothelial leukocyte adhesion molecule 1 and vascular cell adhesion molecule 1. *J Exp Med* 1992; **176**(4): 1183-9.
90. Avril M, Tripathi AK, Brazier AJ, et al. A restricted subset of var genes mediates adherence of *Plasmodium falciparum*-infected erythrocytes to brain endothelial cells. *Proc Natl Acad Sci U S A* 2012; **109**(26): E1782-90.
91. Warimwe GM, Fegan G, Musyoki JN, et al. Prognostic indicators of life-threatening malaria are associated with distinct parasite variant antigen profiles. *Sci Transl Med* 2012; **4**(129): 129ra45.
92. Aikawa M, Kamanura K, Shiraishi S, et al. Membrane knobs of unfixed *Plasmodium falciparum* infected erythrocytes: new findings as revealed by atomic force microscopy and surface potential spectroscopy. *Exp Parasitol* 1996; **84**(3): 339-43.
93. Dobbie MS, Hurst RD, Klein NJ, Surtees RA. Upregulation of intercellular adhesion molecule-1 expression on human endothelial cells by tumour necrosis factor-alpha in an in vitro model of the blood-brain barrier. *Brain Res* 1999; **830**(2): 330-6.
94. SenGupta SK, Naraqi S. The brain in cerebral malaria: a pathological study of 24 fatal cases in Papua New Guinea. *P N G Med J* 1992; **35**(4): 270-4.
95. Udomsangpetch R, Pipitaporn B, Silamut K, et al. Febrile temperatures induce cytoadherence of ring-stage *Plasmodium falciparum*-infected erythrocytes. *Proc Natl Acad Sci U S A* 2002; **99**(18): 11825-9.
96. Silamut K, White NJ. Relation of the stage of parasite development in the peripheral blood to prognosis in severe falciparum malaria. *Trans R Soc Trop Med Hyg* 1993; **87**(4): 436-43.
97. Wassmer SC, Lepolard C, Traore B, Pouvelle B, Gysin J, Grau GE. Platelets reorient *Plasmodium falciparum*-infected erythrocyte cytoadhesion to activated endothelial cells. *J Infect Dis* 2004; **189**(2): 180-9.
98. Arman M, Adams Y, Lindergard G, Rowe JA. A method for positive and negative selection of *Plasmodium falciparum* platelet-mediated clumping parasites and investigation of the role of CD36. *PLoS One* 2013; **8**(2): e55453.
99. Grau GE, Mackenzie CD, Carr RA, et al. Platelet accumulation in brain microvessels in fatal pediatric cerebral malaria. *J Infect Dis* 2003; **187**(3): 461-6.

100. Taylor TE, Fu WJ, Carr RA, et al. Differentiating the pathologies of cerebral malaria by postmortem parasite counts. *Nat Med* 2004; **10**(2): 143-5.
101. Phiri HT, Bridges DJ, Glover SJ, et al. Elevated plasma von Willebrand factor and propeptide levels in Malawian children with malaria. *PLoS One* 2011; **6**(11): e25626.
102. Lowenberg EC, Charunwatthana P, Cohen S, et al. Severe malaria is associated with a deficiency of von Willebrand factor cleaving protease, ADAMTS13. *Thromb Haemost* 2010; **103**(1): 181-7.
103. Conroy AL, Phiri H, Hawkes M, et al. Endothelium-based biomarkers are associated with cerebral malaria in Malawian children: a retrospective case-control study. *PLoS One* 2010; **5**(12): e15291.
104. Jain V, Lucchi NW, Wilson NO, et al. Plasma levels of angiopoietin-1 and -2 predict cerebral malaria outcome in Central India. *Malar J* 2011; **10**: 383.
105. Conroy AL, Lafferty EI, Lovegrove FE, et al. Whole blood angiopoietin-1 and -2 levels discriminate cerebral and severe (non-cerebral) malaria from uncomplicated malaria. *Malar J* 2009; **8**: 295.
106. Conroy AL, Glover SJ, Hawkes M, et al. Angiopoietin-2 levels are associated with retinopathy and predict mortality in Malawian children with cerebral malaria: a retrospective case-control study\*. *Crit Care Med* 2012; **40**(3): 952-9.
107. Prapansilp P, Medana I, Mai NT, et al. A clinicopathological correlation of the expression of the angiopoietin-Tie-2 receptor pathway in the brain of adults with Plasmodium falciparum malaria. *Malar J* 2013; **12**: 50.
108. David PH, Handunnetti SM, Leech JH, Gamage P, Mendis KN. Rosetting: a new cytoadherence property of malaria-infected erythrocytes. *Am J Trop Med Hyg* 1988; **38**(2): 289-97.
109. Udomsangpetch R, Wahlin B, Carlson J, et al. Plasmodium falciparum-infected erythrocytes form spontaneous erythrocyte rosettes. *J Exp Med* 1989; **169**(5): 1835-40.
110. Carlson J, Helmby H, Hill AV, Brewster D, Greenwood BM, Wahlgren M. Human cerebral malaria: association with erythrocyte rosetting and lack of anti-rosetting antibodies. *Lancet* 1990; **336**(8729): 1457-60.
111. Ringwald P, Peyron F, Lepers JP, et al. Parasite virulence factors during falciparum malaria: rosetting, cytoadherence, and modulation of cytoadherence by cytokines. *Infect Immun* 1993; **61**(12): 5198-204.
112. al-Yaman F, Genton B, Mokela D, et al. Human cerebral malaria: lack of significant association between erythrocyte rosetting and disease severity. *Trans R Soc Trop Med Hyg* 1995; **89**(1): 55-8.
113. Kaul DK, Roth EF, Jr., Nagel RL, Howard RJ, Handunnetti SM. Rosetting of Plasmodium falciparum-infected red blood cells with uninfected red blood cells enhances microvascular obstruction under flow conditions. *Blood* 1991; **78**(3): 812-9.
114. Chotivanich KT, Dondorp AM, White NJ, et al. The resistance to physiological shear stresses of the erythrocytic rosettes formed by cells infected with Plasmodium falciparum. *Ann Trop Med Parasitol* 2000; **94**(3): 219-26.
115. Nash GB, Cooke BM, Carlson J, Wahlgren M. Rheological properties of rosettes formed by red blood cells parasitized by Plasmodium falciparum. *Br J Haematol* 1992; **82**(4): 757-63.

116. Rowe JA, Moulds JM, Newbold CI, Miller LH. P. falciparum rosetting mediated by a parasite-variant erythrocyte membrane protein and complement-receptor 1. *Nature* 1997; **388**(6639): 292-5.
117. Goel S, Palmkvist M, Moll K, et al. RIFINs are adhesins implicated in severe Plasmodium falciparum malaria. *Nat Med* 2015.
118. Niang M, Bei AK, Madnani KG, et al. STEVOR is a Plasmodium falciparum erythrocyte binding protein that mediates merozoite invasion and rosetting. *Cell Host Microbe* 2014; **16**(1): 81-93.
119. Chotivanich K, Sritabal J, Udomsangpetch R, et al. Platelet-induced autoagglutination of Plasmodium falciparum-infected red blood cells and disease severity in Thailand. *J Infect Dis* 2004; **189**(6): 1052-5.
120. Pain A, Ferguson DJ, Kai O, et al. Platelet-mediated clumping of Plasmodium falciparum-infected erythrocytes is a common adhesive phenotype and is associated with severe malaria. *Proc Natl Acad Sci U S A* 2001; **98**(4): 1805-10.
121. Dondorp AM, Kager PA, Vreeken J, White NJ. Abnormal blood flow and red blood cell deformability in severe malaria. *Parasitol Today* 2000; **16**(6): 228-32.
122. Dondorp AM, Angus BJ, Hardeman MR, et al. Prognostic significance of reduced red blood cell deformability in severe falciparum malaria. *Am J Trop Med Hyg* 1997; **57**(5): 507-11.
123. Dondorp AM, Nyanoti M, Kager PA, Mithwani S, Vreeken J, Marsh K. The role of reduced red cell deformability in the pathogenesis of severe falciparum malaria and its restoration by blood transfusion. *Trans R Soc Trop Med Hyg* 2002; **96**(3): 282-6.
124. Dondorp AM, Pongponratn E, White NJ. Reduced microcirculatory flow in severe falciparum malaria: pathophysiology and electron-microscopic pathology. *Acta Trop* 2004; **89**(3): 309-17.
125. Hosseini SM, Feng JJ. How malaria parasites reduce the deformability of infected red blood cells. *Biophys J* 2012; **103**(1): 1-10.
126. Nuchsongsin F, Chotivanich K, Charunwatthana P, et al. Effects of malaria heme products on red blood cell deformability. *Am J Trop Med Hyg* 2007; **77**(4): 617-22.
127. Yeo TW, Lampah DA, Gitawati R, et al. Impaired nitric oxide bioavailability and L-arginine reversible endothelial dysfunction in adults with falciparum malaria. *J Exp Med* 2007; **204**(11): 2693-704.
128. Deanfield JE, Halcox JP, Rabelink TJ. Endothelial function and dysfunction: testing and clinical relevance. *Circulation* 2007; **115**(10): 1285-95.
129. Anstey NM, Weinberg JB, Hassanali MY, et al. Nitric oxide in Tanzanian children with malaria: inverse relationship between malaria severity and nitric oxide production/nitric oxide synthase type 2 expression. *J Exp Med* 1996; **184**(2): 557-67.
130. Yeo TW, Lampah DA, Tjitra E, et al. Relationship of cell-free hemoglobin to impaired endothelial nitric oxide bioavailability and perfusion in severe falciparum malaria. *J Infect Dis* 2009; **200**(10): 1522-9.
131. Janka JJ, Koita OA, Traore B, et al. Increased pulmonary pressures and myocardial wall stress in children with severe malaria. *J Infect Dis* 2010; **202**(5): 791-800.

132. Serghides L, Kim H, Lu Z, et al. Inhaled nitric oxide reduces endothelial activation and parasite accumulation in the brain, and enhances survival in experimental cerebral malaria. *PLoS One* 2011; **6**(11): e27714.
133. Hanson J, Lam SW, Mahanta KC, et al. Relative contributions of macrovascular and microvascular dysfunction to disease severity in falciparum malaria. *J Infect Dis* 2012; **206**(4): 571-9.
134. Dondorp AM. Clinical significance of sequestration in adults with severe malaria. *Transfus Clin Biol* 2008; **15**(1-2): 56-7.
135. Newton CR, Taylor TE, Whitten RO. Pathophysiology of fatal falciparum malaria in African children. *Am J Trop Med Hyg* 1998; **58**(5): 673-83.
136. Clark IA, Rockett KA. The cytokine theory of human cerebral malaria. *Parasitol Today* 1994; **10**(10): 410-2.
137. White NJ, Turner GD, Medana IM, Dondorp AM, Day NP. The murine cerebral malaria phenomenon. *Trends Parasitol* 2010; **26**(1): 11-5.
138. Kwiatkowski D. Tumour necrosis factor, fever and fatality in falciparum malaria. *Immunol Lett* 1990; **25**(1-3): 213-6.
139. Akanmori BD, Kurtzhals JA, Goka BQ, et al. Distinct patterns of cytokine regulation in discrete clinical forms of Plasmodium falciparum malaria. *Eur Cytokine Netw* 2000; **11**(1): 113-8.
140. Kwiatkowski D, Hill AV, Sambou I, et al. TNF concentration in fatal cerebral, non-fatal cerebral, and uncomplicated Plasmodium falciparum malaria. *Lancet* 1990; **336**(8725): 1201-4.
141. Kern P, Hemmer CJ, Van Damme J, Gruss HJ, Dietrich M. Elevated tumor necrosis factor alpha and interleukin-6 serum levels as markers for complicated Plasmodium falciparum malaria. *Am J Med* 1989; **87**(2): 139-43.
142. Grau GE, Taylor TE, Molyneux ME, et al. Tumor necrosis factor and disease severity in children with falciparum malaria. *N Engl J Med* 1989; **320**(24): 1586-91.
143. Gimenez F, Barraud de Lagerie S, Fernandez C, Pino P, Mazier D. Tumor necrosis factor alpha in the pathogenesis of cerebral malaria. *Cell Mol Life Sci* 2003; **60**(8): 1623-35.
144. McGuire W, Hill AV, Allsopp CE, Greenwood BM, Kwiatkowski D. Variation in the TNF-alpha promoter region associated with susceptibility to cerebral malaria. *Nature* 1994; **371**(6497): 508-10.
145. Day NP, Hien TT, Schollaardt T, et al. The prognostic and pathophysiologic role of pro- and antiinflammatory cytokines in severe malaria. *J Infect Dis* 1999; **180**(4): 1288-97.
146. Kinra P, Dutta V. Serum TNF alpha levels: a prognostic marker for assessment of severity of malaria. *Trop Biomed* 2013; **30**(4): 645-53.
147. Karunaweera ND, Grau GE, Gamage P, Carter R, Mendis KN. Dynamics of fever and serum levels of tumor necrosis factor are closely associated during clinical paroxysms in Plasmodium vivax malaria. *Proc Natl Acad Sci U S A* 1992; **89**(8): 3200-3.
148. Clark IA, Cowden WB, Butcher GA, Hunt NH. Possible roles of tumor necrosis factor in the pathology of malaria. *Am J Pathol* 1987; **129**(1): 192-9.
149. Kremsner PG, Winkler S, Brandts C, et al. Prediction of accelerated cure in Plasmodium falciparum malaria by the elevated capacity of tumor necrosis factor production. *Am J Trop Med Hyg* 1995; **53**(5): 532-8.

150. Allan RJ, Rowe A, Kwiatkowski D. Plasmodium falciparum varies in its ability to induce tumor necrosis factor. *Infect Immun* 1993; **61**(11): 4772-6.
151. Brown H, Turner G, Rogerson S, et al. Cytokine expression in the brain in human cerebral malaria. *J Infect Dis* 1999; **180**(5): 1742-6.
152. Kern P, Hemmer CJ, Gallati H, et al. Soluble tumor necrosis factor receptors correlate with parasitemia and disease severity in human malaria. *J Infect Dis* 1992; **166**(4): 930-4.
153. Molyneux ME, Engelmann H, Taylor TE, et al. Circulating plasma receptors for tumour necrosis factor in Malawian children with severe falciparum malaria. *Cytokine* 1993; **5**(6): 604-9.
154. Deloron P, Roux Lombard P, Ringwald P, et al. Plasma levels of TNF-alpha soluble receptors correlate with outcome in human falciparum malaria. *Eur Cytokine Netw* 1994; **5**(3): 331-6.
155. Wenisch C, Varijanonta S, Looareesuwan S, Graninger W, Pichler R, Wernsdorfer W. Soluble intercellular adhesion molecule-1 (ICAM-1), endothelial leukocyte adhesion molecule-1 (ELAM-1), and tumor necrosis factor receptor (55 kDa TNF-R) in patients with acute Plasmodium falciparum malaria. *Clin Immunol Immunopathol* 1994; **71**(3): 344-8.
156. Wattavidanage J, Carter R, Perera KL, et al. TNFalpha\*2 marks high risk of severe disease during Plasmodium falciparum malaria and other infections in Sri Lankans. *Clin Exp Immunol* 1999; **115**(2): 350-5.
157. Kwiatkowski D, Molyneux ME, Stephens S, et al. Anti-TNF therapy inhibits fever in cerebral malaria. *Q J Med* 1993; **86**(2): 91-8.
158. Looareesuwan S, Wilairatana P, Vannaphan S, et al. Pentoxifylline as an ancillary treatment for severe falciparum malaria in Thailand. *Am J Trop Med Hyg* 1998; **58**(3): 348-53.
159. Das BK, Mishra S, Padhi PK, et al. Pentoxifylline adjunct improves prognosis of human cerebral malaria in adults. *Trop Med Int Health* 2003; **8**(8): 680-4.
160. Clark IA, Rockett KA, Cowden WB. Proposed link between cytokines, nitric oxide and human cerebral malaria. *Parasitol Today* 1991; **7**(8): 205-7.
161. Clark IA, Rockett KA, Cowden WB. Possible central role of nitric oxide in conditions clinically similar to cerebral malaria. *Lancet* 1992; **340**(8824): 894-6.
162. Maneerat Y, Viriyavejakul P, Punpoowong B, et al. Inducible nitric oxide synthase expression is increased in the brain in fatal cerebral malaria. *Histopathology* 2000; **37**(3): 269-77.
163. Clark IA, Rockett KA. Nitric oxide and parasitic disease. *Adv Parasitol* 1996; **37**: 1-56.
164. Clark IA, Awburn MM, Whitten RO, et al. Tissue distribution of migration inhibitory factor and inducible nitric oxide synthase in falciparum malaria and sepsis in African children. *Malar J* 2003; **2**: 6.
165. Bredt DS, Snyder SH. Nitric oxide, a novel neuronal messenger. *Neuron* 1992; **8**(1): 3-11.
166. Clark IA, Alleva LM, Mills AC, Cowden WB. Pathogenesis of malaria and clinically similar conditions. *Clin Microbiol Rev* 2004; **17**(3): 509-39, table of contents.

167. Cramer JP, Nussler AK, Ehrhardt S, et al. Age-dependent effect of plasma nitric oxide on parasite density in Ghanaian children with severe malaria. *Trop Med Int Health* 2005; **10**(7): 672-80.
168. Agbenyega T, Angus B, Bedu-Addo G, et al. Plasma nitrogen oxides and blood lactate concentrations in Ghanaian children with malaria. *Trans R Soc Trop Med Hyg* 1997; **91**(3): 298-302.
169. Lyke KE, Burges R, Cissoko Y, et al. Serum levels of the proinflammatory cytokines interleukin-1 beta (IL-1beta), IL-6, IL-8, IL-10, tumor necrosis factor alpha, and IL-12(p70) in Malian children with severe *Plasmodium falciparum* malaria and matched uncomplicated malaria or healthy controls. *Infect Immun* 2004; **72**(10): 5630-7.
170. Wilson NO, Jain V, Roberts CE, et al. CXCL4 and CXCL10 predict risk of fatal cerebral malaria. *Dis Markers* 2011; **30**(1): 39-49.
171. Erdman LK, Petes C, Lu Z, et al. Chitinase 3-like 1 is induced by *Plasmodium falciparum* malaria and predicts outcome of cerebral malaria and severe malarial anaemia in a case-control study of African children. *Malar J* 2014; **13**: 279.
172. Greene JA, Sam-Agudu N, John CC, Opoka RO, Zimmerman PA, Kazura JW. Toll-like receptor polymorphisms and cerebral malaria: TLR2 Delta22 polymorphism is associated with protection from cerebral malaria in a case control study. *Malar J* 2012; **11**: 47.
173. Apinjoh TO, Anchang-Kimbi JK, Njua-Yafi C, et al. Association of cytokine and Toll-like receptor gene polymorphisms with severe malaria in three regions of Cameroon. *PLoS One* 2013; **8**(11): e81071.
174. Newton CR, Peshu N, Kendall B, et al. Brain swelling and ischaemia in Kenyans with cerebral malaria. *Arch Dis Child* 1994; **70**(4): 281-7.
175. Potchen MJ, Kampondeni SD, Seydel KB, et al. Acute brain MRI findings in 120 Malawian children with cerebral malaria: new insights into an ancient disease. *AJNR Am J Neuroradiol* 2012; **33**(9): 1740-6.
176. Seydel KB, Kampondeni SD, Valim C, et al. Brain swelling and death in children with cerebral malaria. *N Engl J Med* 2015; **372**(12): 1126-37.
177. Brown H, Rogerson S, Taylor T, et al. Blood-brain barrier function in cerebral malaria in Malawian children. *Am J Trop Med Hyg* 2001; **64**(3-4): 207-13.
178. Adams S, Brown H, Turner G. Breaking down the blood-brain barrier: signaling a path to cerebral malaria? *Trends Parasitol* 2002; **18**(8): 360-6.
179. Newton CR, Kirkham FJ, Winstanley PA, et al. Intracranial pressure in African children with cerebral malaria. *Lancet* 1991; **337**(8741): 573-6.
180. White NJ. Lumbar puncture in cerebral malaria. *Lancet* 1991; **338**(8767): 640-1.
181. Mohanty S, Mishra SK, Patnaik R, et al. Brain swelling and mannitol therapy in adult cerebral malaria: a randomized trial. *Clin Infect Dis* 2011; **53**(4): 349-55.
182. Davis TM, Suputtamongkol Y, Spencer JL, et al. Measures of capillary permeability in acute falciparum malaria: relation to severity of infection and treatment. *Clin Infect Dis* 1992; **15**(2): 256-66.
183. Warrell DA, Looareesuwan S, Phillips RE, et al. Function of the blood-cerebrospinal fluid barrier in human cerebral malaria: rejection of the permeability hypothesis. *Am J Trop Med Hyg* 1986; **35**(5): 882-9.

184. Looareesuwan S, Warrell DA, White NJ, et al. Do patients with cerebral malaria have cerebral oedema? A computed tomography study. *Lancet* 1983; **1**(8322): 434-7.
185. Looareesuwan S, Wilairatana P, Krishna S, et al. Magnetic resonance imaging of the brain in patients with cerebral malaria. *Clin Infect Dis* 1995; **21**(2): 300-9.
186. Patankar TF, Karnad DR, Shetty PG, Desai AP, Prasad SR. Adult cerebral malaria: prognostic importance of imaging findings and correlation with postmortem findings. *Radiology* 2002; **224**(3): 811-6.
187. Okoromah CA, Afolabi BB. Mannitol and other osmotic diuretics as adjuncts for treating cerebral malaria. *Cochrane Database Syst Rev* 2004; (4): CD004615.
188. Newton CR, Crawley J, Sowumni A, et al. Intracranial hypertension in Africans with cerebral malaria. *Arch Dis Child* 1997; **76**(3): 219-26.
189. Ferguson B, Matyszak MK, Esiri MM, Perry VH. Axonal damage in acute multiple sclerosis lesions. *Brain* 1997; **120** ( Pt 3): 393-9.
190. Pfeifenbring S, Bunyan RF, Metz I, et al. Extensive acute axonal damage in pediatric multiple sclerosis lesions. *Ann Neurol* 2015.
191. Neifer S, Kremsner PG, Bienzle U. Application of anti-TNF to Plasmodium vinckei-infected mice is followed by an increase of parasitaemia. *Acta Trop* 1989; **46**(4): 273-5.
192. Pendlebury ST, Blamire AM, Lee MA, Styles P, Matthews PM. Axonal injury in the internal capsule correlates with motor impairment after stroke. *Stroke* 1999; **30**(5): 956-62.
193. Medana IM, Esiri MM. Axonal damage: a key predictor of outcome in human CNS diseases. *Brain* 2003; **126**(Pt 3): 515-30.
194. Povlishock JT. Traumatically induced axonal injury: pathogenesis and pathobiological implications. *Brain Pathol* 1992; **2**(1): 1-12.
195. Povlishock JT, Becker DP, Cheng CL, Vaughan GW. Axonal change in minor head injury. *J Neuropathol Exp Neurol* 1983; **42**(3): 225-42.
196. Medana IM, Day NP, Hien TT, et al. Axonal injury in cerebral malaria. *Am J Pathol* 2002; **160**(2): 655-66.
197. Gentleman SM, Nash MJ, Sweeting CJ, Graham DI, Roberts GW. Beta-amyloid precursor protein (beta APP) as a marker for axonal injury after head injury. *Neurosci Lett* 1993; **160**(2): 139-44.
198. Umehara F, Abe M, Koreeda Y, Izumo S, Osame M. Axonal damage revealed by accumulation of beta-amyloid precursor protein in HTLV-I-associated myelopathy. *J Neurol Sci* 2000; **176**(2): 95-101.
199. Medana IM, Lindert RB, Wurster U, et al. Cerebrospinal fluid levels of markers of brain parenchymal damage in Vietnamese adults with severe malaria. *Trans R Soc Trop Med Hyg* 2005; **99**(8): 610-7.
200. Kaur B, Ruddy GN, Timperley WR. The possible role of hypoxia in the formation of axonal bulbs. *J Clin Pathol* 1999; **52**(3): 203-9.
201. Adams JH, Graham DI, Jennett B. The neuropathology of the vegetative state after an acute brain insult. *Brain* 2000; **123** ( Pt 7): 1327-38.
202. Graham DI, Lawrence AE, Adams JH, Doyle D, McLellan DR. Brain damage in non-missile head injury secondary to high intracranial pressure. *Neuropathol Appl Neurobiol* 1987; **13**(3): 209-17.



203. Dolinak D, Smith C, Graham DI. Global hypoxia per se is an unusual cause of axonal injury. *Acta Neuropathol* 2000; **100**(5): 553-60.
204. Dolinak D, Smith C, Graham DI. Hypoglycaemia is a cause of axonal injury. *Neuropathol Appl Neurobiol* 2000; **26**(5): 448-53.
205. Dorovini-Zis K, Schmidt K, Huynh H, et al. The neuropathology of fatal cerebral malaria in malawian children. *Am J Pathol* 2011; **178**(5): 2146-58.
206. Rigdon RH, Fletcher DE. Lesions in the brain associated with malaria. Pathologic study on man and on experimental animals. *Arch Neurol Psychiat* 1947; **53**: 191.
207. Knisely MH, Stratman-Thomas WK, Elitio TS, Black EH. Knowlesi malaria in monkeys: I. Microscopic pathological circulatory physiology. *J Nat Malar Soc* 1954; **4**: 285.
208. Areekul S, Chantachum Y, Cheeramakara C. Evidence of trapped red cells in the brain of rhesus monkey infected with Plasmodium knowlesi. *Southeast Asian J Trop Med Public Health* 1983; **14**(4): 531-5.
209. Miller LH, Usami S, Chien S. Alteration in the rheologic properties of Plasmodium knowlesi--infected red cells. A possible mechanism for capillary obstruction. *J Clin Invest* 1971; **50**(7): 1451-5.
210. Cox-Singh J, Hiu J, Lucas SB, et al. Severe malaria - a case of fatal Plasmodium knowlesi infection with post-mortem findings: a case report. *Malar J* 2010; **9**: 10.
211. Fatih FA, Siner A, Ahmed A, et al. Cytoadherence and virulence - the case of Plasmodium knowlesi malaria. *Malar J* 2012; **11**: 33.
212. Cox-Singh J, Singh B, Daneshvar C, Planche T, Parker-Williams J, Krishna S. Anti-inflammatory cytokines predominate in acute human Plasmodium knowlesi infections. *PLoS One* 2011; **6**(6): e20541.
213. Craig AG, Grau GE, Janse C, et al. The role of animal models for research on severe malaria. *PLoS Pathog* 2012; **8**(2): e1002401.
214. Kawai S, Aikawa M, Kano S, Suzuki M. A primate model for severe human malaria with cerebral involvement: Plasmodium coatneyi-infected Macaca fuscata. *Am J Trop Med Hyg* 1993; **48**(5): 630-6.
215. Aikawa M, Brown A, Smith CD, et al. A primate model for human cerebral malaria: Plasmodium coatneyi-infected rhesus monkeys. *Am J Trop Med Hyg* 1992; **46**(4): 391-7.
216. Barrera V, Hiscott PS, Craig AG, et al. Severity of retinopathy parallels the degree of parasite sequestration in the eyes and brains of malawian children with fatal cerebral malaria. *J Infect Dis* 2015; **211**(12): 1977-86.
217. Posner JB, Plum F. Independence of blood and cerebrospinal fluid lactate. *Arch Neurol* 1967; **16**(5): 492-6.
218. Lewallen S, Bronzan RN, Beare NA, Harding SP, Molyneux ME, Taylor TE. Using malarial retinopathy to improve the classification of children with cerebral malaria. *Transactions of the Royal Society of Tropical Medicine and Hygiene* 2008; **102**(11): 1089-94.
219. Lewallen S, Harding SP, Ajewole J, et al. A review of the spectrum of clinical ocular fundus findings in P. falciparum malaria in African children with a proposed classification and grading system. *Trans R Soc Trop Med Hyg* 1999; **93**(6): 619-22.

220. Beare NA, Taylor TE, Harding SP, Lewallen S, Molyneux ME. Malarial retinopathy: a newly established diagnostic sign in severe malaria. *Am J Trop Med Hyg* 2006; **75**(5): 790-7.
221. Photocoagulation for diabetic macular edema. Early Treatment Diabetic Retinopathy Study report number 1. Early Treatment Diabetic Retinopathy Study research group. *Arch Ophthalmol* 1985; **103**(12): 1796-806.
222. Hero M, Harding SP, Riva CE, Winstanley PA, Peshu N, Marsh K. Photographic and angiographic characterization of the retina of Kenyan children with severe malaria. *Arch Ophthalmol* 1997; **115**(8): 997-1003.
223. Beare NA, Harding SP, Taylor TE, Lewallen S, Molyneux ME. Perfusion abnormalities in children with cerebral malaria and malarial retinopathy. *J Infect Dis* 2009; **199**(2): 263-71.
224. Beare NA, Southern C, Lochhead J, Molyneux ME, Lewallen S, Harding SP. Inter-observer concordance in grading retinopathy in cerebral malaria. *Ann Trop Med Parasitol* 2002; **96**(1): 105-8.
225. Beare NA, Lewallen S, Taylor TE, Molyneux ME. Redefining cerebral malaria by including malaria retinopathy. *Future Microbiol* 2011; **6**(3): 349-55.
226. Keyburn H, Mbatia R, Drakeley C, et al. Overdiagnosis of malaria in patients with severe febrile illness in Tanzania: a prospective study. *BMJ* 2004; **329**(7476): 1212.
227. Postels DG, Birbeck GL, Valim C, Mannor KM, Taylor TE. Seasonal differences in retinopathy-negative versus retinopathy-positive cerebral malaria. *Am J Trop Med Hyg* 2013; **88**(2): 315-8.
228. Postels DG, Birbeck GL. Children with retinopathy-negative cerebral malaria: a pathophysiologic puzzle. *Pediatr Infect Dis J* 2011; **30**(11): 953-6.
229. Potchen MJ, Birbeck GL, Demarco JK, et al. Neuroimaging findings in children with retinopathy-confirmed cerebral malaria. *Eur J Radiol* 2010; **74**(1): 262-8.
230. Kariuki SM, Gitau E, Gwer S, et al. Value of Plasmodium falciparum histidine-rich protein 2 level and malaria retinopathy in distinguishing cerebral malaria from other acute encephalopathies in Kenyan children. *J Infect Dis* 2014; **209**(4): 600-9.
231. Bouza E, Cobo-Soriano R, Rodriguez-Creixems M, Munoz P, Suarez-Leoz M, Cortes C. A prospective search for ocular lesions in hospitalized patients with significant bacteremia. *Clin Infect Dis* 2000; **30**(2): 306-12.
232. Lim WK, Mathur R, Koh A, Yeoh R, Chee SP. Ocular manifestations of dengue fever. *Ophthalmology* 2004; **111**(11): 2057-64.
233. Su DH, Bacsal K, Chee SP, et al. Prevalence of dengue maculopathy in patients hospitalized for dengue fever. *Ophthalmology* 2007; **114**(9): 1743-7.
234. Lewallen S, White VA, Whitten RO, et al. Clinical-histopathological correlation of the abnormal retinal vessels in cerebral malaria. *Arch Ophthalmol* 2000; **118**(7): 924-8.
235. White VA, Lewallen S, Beare N, Kayira K, Carr RA, Taylor TE. Correlation of retinal haemorrhages with brain haemorrhages in children dying of cerebral malaria in Malawi. *Trans R Soc Trop Med Hyg* 2001; **95**(6): 618-21.
236. MacCormick IJ, Beare NA, Taylor TE, et al. Cerebral malaria in children: using the retina to study the brain. *Brain* 2014; **137**: 2119-42.

237. Boivin MJ. Effects of early cerebral malaria on cognitive ability in Senegalese children. *J Dev Behav Pediatr* 2002; **23**(5): 353-64.
238. Carter JA, Ross AJ, Neville BG, et al. Developmental impairments following severe falciparum malaria in children. *Trop Med Int Health* 2005; **10**(1): 3-10.
239. Kihara M, Carter JA, Newton CR. The effect of Plasmodium falciparum on cognition: a systematic review. *Trop Med Int Health* 2006; **11**(4): 386-97.
240. Barrera V, Hiscott PS, Craig AG, et al. Severity of Retinopathy Parallels the Degree of Parasite Sequestration in the Eyes and Brains of Malawian Children With Fatal Cerebral Malaria. *J Infect Dis* 2014.
241. Clark IA, Schofield L. Pathogenesis of malaria. *Parasitol Today* 2000; **16**(10): 451-4.
242. Medana IM, Day NP, Sachanonta N, et al. Coma in fatal adult human malaria is not caused by cerebral oedema. *Malar J* 2011; **10**: 267.
243. Kochar DK, Shubhakaran, Kumawat BL, Vyas SP. Prognostic significance of eye changes in cerebral malaria. *J Assoc Physicians India* 2000; **48**(5): 473-7.
244. Kochar DK, Shubhakaran, Kumawat BL, Thanvi I, Joshi A, Vyas SP. Ophthalmoscopic abnormalities in adults with falciparum malaria. *QJM* 1998; **91**(12): 845-52.
245. Looareesuwan S, Warrell DA, White NJ, et al. Retinal hemorrhage, a common sign of prognostic significance in cerebral malaria. *Am J Trop Med Hyg* 1983; **32**(5): 911-5.
246. Rasalkar DD, Paunipagar BK, Sanghvi D, Sonawane BD, Loniker P. Magnetic resonance imaging in cerebral malaria: a report of four cases. *Br J Radiol* 2011; **84**(1000): 380-5.
247. Fledelius HC. Ultrasound in ophthalmology. *Ultrasound Med Biol* 1997; **23**(3): 365-75.
248. Newman WD, Hollman AS, Dutton GN, Carachi R. Measurement of optic nerve sheath diameter by ultrasound: a means of detecting acute raised intracranial pressure in hydrocephalus. *Br J Ophthalmol* 2002; **86**(10): 1109-13.
249. Beare NA, Glover SJ, Lewallen S, Taylor TE, Harding SP, Molyneux ME. Prevalence of raised intracranial pressure in cerebral malaria detected by optic nerve sheath ultrasound. *Am J Trop Med Hyg* 2012; **87**(6): 985-8.
250. Johnson LN, Hepler RS, Bartholomew MJ. Accuracy of papilledema and pseudopapilledema detection: a multispecialty study. *J Fam Pract* 1991; **33**(4): 381-6.
251. Postels DG, Taylor TE, Molyneux M, et al. Neurologic outcomes in retinopathy-negative cerebral malaria survivors. *Neurology* 2012; **79**(12): 1268-72.
252. Beare NA, Southern C, Kayira K, Taylor TE, Harding SP. Visual outcomes in children in Malawi following retinopathy of severe malaria. *Br J Ophthalmol* 2004; **88**(3): 321-4.
253. Silamut K, Phu NH, Whitty C, et al. A quantitative analysis of the microvascular sequestration of malaria parasites in the human brain. *Am J Pathol* 1999; **155**(2): 395-410.
254. Leitgeb AM, Blomqvist K, Cho-Ngwa F, et al. Low anticoagulant heparin disrupts Plasmodium falciparum rosettes in fresh clinical isolates. *Am J Trop Med Hyg* 2011; **84**(3): 390-6.

255. Abu Sayeed, A, Maude R, Hasan M, et al. Malarial retinopathy in Bangladeshi adults. *American Journal of Tropical Medicine and Hygiene* 2011; **84**: 141-7.
256. Tran TH, Day NP, Nguyen HP, et al. A controlled trial of artemether or quinine in Vietnamese adults with severe falciparum malaria. *N Engl J Med* 1996; **335**(2): 76-83.
257. Day NP, Phu NH, Mai NT, et al. The pathophysiologic and prognostic significance of acidosis in severe adult malaria. *Crit Care Med* 2000; **28**(6): 1833-40.
258. Bailey IL, Lovie JE. New design principles for visual acuity letter charts. *Am J Optom Physiol Opt* 1976; **53**(11): 740-5.
259. Dondorp AM, Desakorn V, Pongtavornpinyo W, et al. Estimation of the total parasite biomass in acute falciparum malaria from plasma PfHRP2. *PLoS Med* 2005; **2**(8): e204.
260. Harding SP, Lewallen S, Beare NAV, Smith A, Taylor TE, Molyneux ME. Classifying and grading retinal signs in severe malaria. *Trop Doct* 2006; **36**(suppl 1): 1-13.
261. Perez-Rovira A, MacGillivray T, Trucco E, et al. VAMPIRE: Vessel assessment and measurement platform for images of the REtina. *Conf Proc IEEE Eng Med Biol Soc* 2011; **2011**: 3391-4.
262. Trucco E, Azegrouz H, Dhillon B. Modeling the tortuosity of retinal vessels: does caliber play a role? *IEEE Trans Biomed Eng* 2010; **57**(9): 2239-47.
263. Essuman VA, Ntim-Amponsah CT, Astrup BS, et al. Retinopathy in severe malaria in Ghanaian children--overlap between fundus changes in cerebral and non-cerebral malaria. *Malar J* 2010; **9**: 232.
264. Haslett P. Retinal haemorrhages in Zambian children with cerebral malaria. *J Trop Pediatr* 1991; **37**(2): 86-7.
265. Newton CR, Winstanley PA, Marsh K. Retinal haemorrhages in falciparum malaria. *Arch Dis Child* 1991; **66**(6): 753.
266. Burton M, Nyong'o O, Burton K, et al. Retinopathy in Gambian children admitted to hospital with malaria. *Trop Doct* 2004; **34**(4): 214-8.
267. Beare NA, Lewallen S, Taylor TE, Molyneux ME. Redefining cerebral malaria by including malaria retinopathy. *Future Microbiology* 2011; **6**(3): 349-55.
268. Lewallen S, Bronzan RN, Beare NA, Harding SP, Molyneux ME, Taylor TE. Using malarial retinopathy to improve the classification of children with cerebral malaria. *Trans R Soc Trop Med Hyg* 2008; **102**(11): 1089-94.
269. Ughasoro MD, Okoli CC, Uzochukwu BS. Qualitative study of presumptive treatment of childhood malaria in third tier tertiary hospitals in southeast Nigeria: a focus group and in-depth study. *Malar J* 2013; **12**: 436.
270. Mukadi P, Gillet P, Barbe B, et al. SMS photograph-based external quality assessment of reading and interpretation of malaria rapid diagnostic tests in the Democratic Republic of the Congo. *Malar J* 2015; **14**(1): 26.
271. Leslie T, Mikhail A, Mayan I, et al. Overdiagnosis and mistreatment of malaria among febrile patients at primary healthcare level in Afghanistan: observational study. *BMJ* 2012; **345**: e4389.
272. Baiden F, Malm K, Bart-Plange C, et al. Shifting from presumptive to test-based management of malaria - technical basis and implications for malaria control in Ghana. *Ghana Med J* 2014; **48**(2): 112-22.

273. Obare P, Ogutu B, Adams M, et al. Misclassification of Plasmodium infections by conventional microscopy and the impact of remedial training on the proficiency of laboratory technicians in species identification. *Malar J* 2013; **12**: 113.
274. Starzengruber P, Fuehrer HP, Ley B, et al. High prevalence of asymptomatic malaria in south-eastern Bangladesh. *Malar J* 2014; **13**: 16.
275. Incardona S, Vong S, Chiv L, et al. Large-scale malaria survey in Cambodia: novel insights on species distribution and risk factors. *Malar J* 2007; **6**: 37.
276. Wang B, Han SS, Cho C, et al. Comparison of microscopy, nested-PCR, and Real-Time-PCR assays using high-throughput screening of pooled samples for diagnosis of malaria in asymptomatic carriers from areas of endemicity in Myanmar. *J Clin Microbiol* 2014; **52**(6): 1838-45.
277. Harding SP, Lewallen S, Beare NA, Smith A, Taylor TE, Molyneux ME. Classifying and grading retinal signs in severe malaria. *Trop Doct* 2006; **36 Suppl 1**: 1-13.
278. Oluwayemi OI, Brown BJ, Oyediji OA, Adegoke SA, Adebami OJ, Oyediji GA. Clinical and laboratory predictors of outcome in cerebral malaria in suburban Nigeria. *J Infect Dev Ctries* 2013; **7**(8): 600-7.
279. Schemann JF, Doumbo O, Malvy D, et al. Ocular lesions associated with malaria in children in Mali. *Am J Trop Med Hyg* 2002; **67**(1): 61-3.
280. Oo MM, Aikawa M, Than T, et al. Human cerebral malaria: a pathological study. *J Neuropathol Exp Neurol* 1987; **46**(2): 223-31.
281. Beare NA, Lewis DK, Kublin JG, Harding SP, Zijlstra EE, Molyneux ME. Retinal changes in adults with cerebral malaria. *Ann Trop Med Parasitol* 2003; **97**(3): 313-5.
282. Glover SJ, Maude RJ, Taylor TE, Molyneux ME, Beare NA. Malarial retinopathy and fluorescein angiography findings in a Malawian child with cerebral malaria. *Lancet Infect Dis* 2010; **10**(6): 440.
283. Francis SE, Sullivan DJ, Jr., Goldberg DE. Hemoglobin metabolism in the malaria parasite Plasmodium falciparum. *Annu Rev Microbiol* 1997; **51**: 97-123.
284. Aisen ML, Bacon BR, Goodman AM, Chester EM. Retinal abnormalities associated with anemia. *Arch Ophthalmol* 1983; **101**(7): 1049-52.
285. Holt JM, Gordon-Smith EC. Retinal abnormalities in diseases of the blood. *Br J Ophthalmol* 1969; **53**(3): 145-60.
286. McLean E, Cogswell M, Egli I, Wojdyla D, de Benoist B. Worldwide prevalence of anaemia, WHO Vitamin and Mineral Nutrition Information System, 1993-2005. *Public Health Nutr* 2009; **12**(4): 444-54.
287. White VA, Lewallen S, Beare NA, Molyneux ME, Taylor TE. Retinal pathology of pediatric cerebral malaria in Malawi. *PLoS One* 2009; **4**(1): e4317.
288. Abu El-Asrar AM, Herbort CP, Tabbara KF. Differential diagnosis of retinal vasculitis. *Middle East Afr J Ophthalmol* 2009; **16**(4): 202-18.
289. Zahavi A, Snir M, Kella YR. Lipemia retinalis: case report and review of the literature. *J AAPOS* 2013; **17**(1): 110-1.
290. Browning DJ. Patchy ischemic retinal whitening. *Ophthalmology* 2004; **111**(3): 606-7; author reply 7.
291. Maude RJ, Dondorp AM, Abu Sayeed A, Day NPJ, White NJ, Beare NAV. The eye in cerebral malaria: what can it teach us? *Trans R Soc Trop Med Hyg* 2009; **103**(7): 661-4.

292. Ocular Blood Flow. Heidelberg, Germany: Springer-Verlag; 2012.
293. Dondorp AM, Omodeo-Sale F, Chotivanich K, Taramelli D, White NJ. Oxidative stress and rheology in severe malaria. *Redox Rep* 2003; **8**(5): 292-4.
294. Planche T, Agbenyega T, Bedu-Addo G, et al. A prospective comparison of malaria with other severe diseases in African children: prognosis and optimization of management. *Clin Infect Dis* 2003; **37**(7): 890-7.
295. Clark IA, Jacobson LS, Rockett KA. Acidosis in severe childhood malaria. *QJM* 1997; **90**(9): 601-4.
296. Dondorp AM, Chau TT, Phu NH, et al. Unidentified acids of strong prognostic significance in severe malaria. *Crit Care Med* 2004; **32**(8): 1683-8.
297. Loewenstien J. Retinopathy associated with blood anomalies. In: Albert D, Jakobiec F, eds. Principles and Practice of Ophthalmology. Philadelphia, USA: W.B. Saunders; 1999.
298. Dondorp AM, Ince C, Charunwatthana P, et al. Direct in vivo assessment of microcirculatory dysfunction in severe falciparum malaria. *J Infect Dis* 2008; **197**(1): 79-84.
299. Sharma A, Subramaniam SD, Ramachandran KI, Lakshmikanthan C, Krishna S, Sundaramoorthy SK. Smartphone-based fundus camera device (MII Ret Cam) and technique with ability to image peripheral retina. *Eur J Ophthalmol* 2016; **26**(2): 142-4.
300. Stocchetti N. Could intracranial pressure in traumatic brain injury be measured or predicted noninvasively? Almost. *Intensive Care Med* 2007; **33**(10): 1682-3.
301. Helmke K, Hansen HC. Fundamentals of transorbital sonographic evaluation of optic nerve sheath expansion under intracranial hypertension II. Patient study. *Pediatr Radiol* 1996; **26**(10): 706-10.
302. Tasker RC, Matthew DJ, Kendall B. Computed tomography in the assessment of raised intracranial pressure in non-traumatic coma. *Neuropediatrics* 1990; **21**(2): 91-4.
303. Holliday PO, 3rd, Kelly DL, Jr., Ball M. Normal computed tomograms in acute head injury: correlation of intracranial pressure, ventricular size, and outcome. *Neurosurgery* 1982; **10**(1): 25-8.
304. Blaivas M, Theodoro D, Sierzenski PR. Elevated intracranial pressure detected by bedside emergency ultrasonography of the optic nerve sheath. *Acad Emerg Med* 2003; **10**(4): 376-81.
305. Jang T, Aubin C. The use of serial ocular ultrasonography in the care of patients with head injury. *Ann Emerg Med* 2005; **45**(3): 336-7.
306. Soldatos T, Karakitsos D, Chatzimichail K, Papatheanasiou M, Gouliamos A, Karabinis A. Optic nerve sonography in the diagnostic evaluation of adult brain injury. *Crit Care* 2008; **12**(3): R67.
307. Major R, Girling S, Boyle A. Ultrasound measurement of optic nerve sheath diameter in patients with a clinical suspicion of raised intracranial pressure. *Emerg Med J* 2011; **28**(8): 679-81.
308. Moretti R, Pizzi B. Ultrasonography of the optic nerve in neurocritically ill patients. *Acta Anaesthesiol Scand* 2011; **55**(6): 644-52.

309. Bauerle J, Lochner P, Kaps M, Nedelmann M. Intra- and interobserver reliability of sonographic assessment of the optic nerve sheath diameter in healthy adults. *J Neuroimaging* 2012; **22**(1): 42-5.
310. Ballantyne SA, O'Neill G, Hamilton R, Hollman AS. Observer variation in the sonographic measurement of optic nerve sheath diameter in normal adults. *Eur J Ultrasound* 2002; **15**(3): 145-9.
311. Ballantyne J, Hollman AS, Hamilton R, et al. Transorbital optic nerve sheath ultrasonography in normal children. *Clin Radiol* 1999; **54**(11): 740-2.
312. Beare NA, Kampondeni S, Glover SJ, et al. Detection of raised intracranial pressure by ultrasound measurement of optic nerve sheath diameter in African children. *Trop Med Int Health* 2008; **13**(11): 1400-4.
313. Tayal VS, Neulander M, Norton HJ, Foster T, Saunders T, Blaiwas M. Emergency department sonographic measurement of optic nerve sheath diameter to detect findings of increased intracranial pressure in adult head injury patients. *Ann Emerg Med* 2007; **49**(4): 508-14.
314. Hansen HC, Helmke K, Kunze K. Optic Nerve Sheath Enlargement in Acute Intracranial Hypertension. *Neuro-Ophthalmology* 1994; **14**: 345-54.
315. Amini A, Kariman H, Arhami Dolatabadi A, et al. Use of the sonographic diameter of optic nerve sheath to estimate intracranial pressure. *Am J Emerg Med* 2013; **31**(1): 236-9.
316. Hewick SA, Fairhead AC, Culy JC, Atta HR. A comparison of 10 MHz and 20 MHz ultrasound probes in imaging the eye and orbit. *Br J Ophthalmol* 2004; **88**(4): 551-5.
317. Rosenberg JB, Shiloh AL, Savel RH, Eisen LA. Non-invasive methods of estimating intracranial pressure. *Neurocrit Care* 2011; **15**(3): 599-608.
318. Waller D, Crawley J, Nosten F, et al. Intracranial pressure in childhood cerebral malaria. *Trans R Soc Trop Med Hyg* 1991; **85**(3): 362-4.
319. Smith A, Beare NA, Musumba CO, Lochhead J, Newton CR, Harding SP. New classification of acute papilledema in children with severe malaria. *J Pediatr Neurol* 2009; **7**(4): 381-8.
320. Okoromah CA, Afolabi BB, Wall EC. Mannitol and other osmotic diuretics as adjuncts for treating cerebral malaria. *Cochrane Database Syst Rev* 2011; (4): CD004615.
321. Novotny HR, Alvis DL. A method of photographing fluorescence in circulating blood in the human retina. *Circulation* 1961; **24**: 82-6.
322. Alvis MD, Julian KG. The story surrounding fluorescein angiography. 1982; **5**: 6-8.
323. Hurley BR, Regillo CD. Retinal Angiography and Optical Coherence Tomography. New York: Springer; 2009.
324. Wykes WN, Livesey SJ. Review of fluorescein angiograms performed in one year. *Br J Ophthalmol* 1991; **75**(7): 398-400.
325. Warner JE. Vasculopathies affecting the eye. *J Neuroophthalmol* 2004; **24**(2): 164-9.
326. Bacsal KE, Chee SP, Cheng CL, Flores JV. Dengue-associated maculopathy. *Arch Ophthalmol* 2007; **125**(4): 501-10.
327. Yoo C, Kim SK, Huh K, Oh J. Atypical acute syphilitic posterior placoid chorioretinitis. *Korean J Ophthalmol* 2009; **23**(2): 108-11.

328. Bansal R, Gupta V, Gupta A. Current approach in the diagnosis and management of panuveitis. *Indian J Ophthalmol* 2010; **58**(1): 45-54.
329. Cunningham ET, Koehler JE. Ocular bartonellosis. *Am J Ophthalmol* 2000; **130**(3): 340-9.
330. Atmaca LS, Simsek T, Atmaca Sonmez P, Sonmez K. Fluorescein and indocyanine green angiography in ocular toxoplasmosis. *Graefes Arch Clin Exp Ophthalmol* 2006; **244**(12): 1688-91.
331. Anninger WV, Lomeo MD, Dingle J, Epstein AD, Lubow M. West Nile virus-associated optic neuritis and chorioretinitis. *Am J Ophthalmol* 2003; **136**(6): 1183-5.
332. Khairallah M, Ben Yahia S, Toumi A, et al. Ocular manifestations associated with murine typhus. *Br J Ophthalmol* 2009; **93**(7): 938-42.
333. Maude RJ, Dondorp AM, Abu Sayeed A, Day NP, White NJ, Beare NA. The eye in cerebral malaria: what can it teach us? *Trans R Soc Trop Med Hyg* 2009; **103**(7): 661-4.
334. Hackel RE SP. Creating retinal fundus maps. *J Ophth Photography* 2005; **27**: 10-8.
335. Kristinsson JK, Gottfredsdottir MS, Stefansson E. Retinal vessel dilatation and elongation precedes diabetic macular oedema. *Br J Ophthalmol* 1997; **81**(4): 274-8.
336. Sarda V, Nakashima K, Wolff B, Sahel JA, Paques M. Topography of patchy retinal whitening during acute perfused retinal vein occlusion by optical coherence tomography and adaptive optics fundus imaging. *Eur J Ophthalmol* 2011; **21**(5): 653-6.
337. Hart WE, Goldbaum M, Cote B, Kube P, Nelson MR. Measurement and classification of retinal vascular tortuosity. *Int J Med Inform* 1999; **53**(2-3): 239-52.
338. Sasongko MB, Wong TY, Donaghue KC, et al. Retinal arteriolar tortuosity is associated with retinopathy and early kidney dysfunction in type 1 diabetes. *Am J Ophthalmol* 2012; **153**(1): 176-83 e1.
339. Haldar K, Murphy SC, Milner DA, Taylor TE. Malaria: mechanisms of erythrocytic infection and pathological correlates of severe disease. *Annual review of pathology* 2007; **2**: 217-49.
340. Looareesuwan S, Laothamatas J, Brown TR, Brittenham GM. Cerebral malaria: a new way forward with magnetic resonance imaging (MRI). *Am J Trop Med Hyg* 2009; **81**(4): 545-7.
341. Levey AS, Bosch JP, Lewis JB, Greene T, Rogers N, Roth D. A more accurate method to estimate glomerular filtration rate from serum creatinine: a new prediction equation. Modification of Diet in Renal Disease Study Group. *Annals of internal medicine* 1999; **130**(6): 461-70.
342. Maude RR, Amir Hossain M, Hassan MU, et al. Transorbital sonographic evaluation of normal optic nerve sheath diameter in healthy volunteers in bangladesh. *PLoS One* 2013; **8**(12): e81013.
343. World Health Organization. Roll Back Malaria Dept. Guidelines for the treatment of malaria. Geneva: World Health Organization; 2006.
344. Society EG. Terminology and guidelines for glaucoma 3rd edition. Savona, Italy: Dogma; 2008.



345. White VA, Lewallen S, Beare N, Kayira K, Carr RA, Taylor TE. Correlation of retinal haemorrhages with brain haemorrhages in children dying of cerebral malaria in Malawi. *Transactions of the Royal Society of Tropical Medicine and Hygiene* 2001; **95**(6): 618-21.
346. Duyn JH, Koretsky AP. Novel frontiers in ultra-structural and molecular MRI of the brain. *Current opinion in neurology* 2011; **24**(4): 386-93.
347. Novak V, Abduljalil AM, Novak P, Robitaille PM. High-resolution ultrahigh-field MRI of stroke. *Magnetic resonance imaging* 2005; **23**(4): 539-48.
348. Heidemann RM, Porter DA, Anwander A, et al. Whole-Brain, Multi-Shot, Diffusion-Weighted Imaging in Humans at 7T with 1 mm Isotropic Resolution. *Proc Int Soc Magnetic Resonance Med* 2011; **19**: 417.
349. Looareesuwan S, Wilairatana P, Krishna S, et al. Magnetic resonance imaging of the brain in patients with cerebral malaria. *Clinical infectious diseases : an official publication of the Infectious Diseases Society of America* 1995; **21**(2): 300-9.
350. Namutangula B, Ndeezi G, Byarugaba JS, Tumwine JK. Mannitol as adjunct therapy for childhood cerebral malaria in Uganda: a randomized clinical trial. *Malar J* 2007; **6**: 138.
351. William T, Rahman HA, Jelip J, et al. Increasing incidence of *Plasmodium knowlesi* malaria following control of *P. falciparum* and *P. vivax* malaria in Sabah, Malaysia. *PLoS Neglected Tropical Diseases* 2013; **7**(1): e2026.
352. Cox-Singh J, Davis TM, Lee KS, et al. *Plasmodium knowlesi* malaria in humans is widely distributed and potentially life threatening. *Clin Infect Dis* 2008; **46**(2): 165-71.
353. Singh B, Sung LK, Matusop A, et al. A large focus of naturally acquired *Plasmodium knowlesi* infections in human beings. *Lancet* 2004; **363**(9414): 1017-24.
354. Daneshvar C, Davis TM, Cox-Singh J, et al. Clinical and laboratory features of human *Plasmodium knowlesi* infection. *Clin Infect Dis* 2009; **49**(6): 852-60.
355. Barber BE, William T, Jikal M, et al. *Plasmodium knowlesi* malaria in children. *Emerg Infect Dis* 2011; **17**(5): 814-20.
356. William T, Menon J, Rajahram G, et al. Severe *Plasmodium knowlesi* malaria in a tertiary hospital, Sabah, Malaysia. *Emerg Infect Dis* 2011; **17**(7): 1248-55.
357. Singh B, Daneshvar C. Human infections and detection of *Plasmodium knowlesi*. *Clinical Microbiology Reviews* 2013; **26**(2): 165-84.
358. Rajahram G, Barber BE, William T, Menon J, Anstey NM, Yeo TW. Deaths due to *Plasmodium knowlesi* malaria in Sabah, Malaysia: association with reporting as *P. malariae* and delayed parenteral artesunate. *Malar J* 2012; **11**(1): 284.
359. Barber BE, William T, Grigg MJ, et al. A prospective comparative study of knowlesi, falciparum and vivax malaria in Sabah, Malaysia: high proportion with severe disease from *Plasmodium knowlesi* and *P. vivax* but no mortality with early referral and artesunate therapy. *Clin Infect Dis* 2013; **56**(3): 383-97.
360. Beare NA, Taylor TE, Harding SP, Lewallen S, Molyneux ME. Malarial retinopathy: a newly established diagnostic sign in severe malaria. *Am J Trop Med Hyg* 2006; **75**(5): 790.
361. White LJ, Maude RJ, Pongtavornpinyo W, et al. The role of simple mathematical models in malaria elimination strategy design. *Malaria journal* 2009; **8**: 212.

362. Maude RJ. Retinopathy and Systemic Microcirculatory Flow Abnormalities in Adult Cerebral Malaria. Edinburgh: University of Edinburgh, *In Press*; 2015.
363. Beare NA, Taylor TE, Harding SP, Lewallen S, Molyneux ME. Malarial retinopathy: a newly established diagnostic sign in severe malaria. *The American Journal of Tropical Medicine and Hygiene* 2006; **75**(5): 790.
364. Maude RJ, Dondorp AM, Sayeed AA, Day NP, White NJ, Beare NA. The eye in cerebral malaria: what can it teach us? *Transactions of the Royal Society of Tropical Medicine and Hygiene* 2009; **103**(7): 661-4.
365. Cox-Singh J, Hiu J, Lucas SB, et al. Severe malaria-a case of fatal *Plasmodium knowlesi* infection with post-mortem findings. *Malar J* 2010; **9**: 10.
366. Knisely MH, Strathman-Thomas WK, Eliot TS, Bloch EH. Knowlesi malaria in monkeys IIA: a first step in the separation of the mechanical pathologic circulatory factors of one slide disease from possible specific toxic factors of that disease. *Angiology* 1964; **15**(9): 411-6.
367. Knisely MH, Stratman-Thomas WK. Knowlesi malaria in monkeys; microscopic pathological circulatory physiology of rhesus monkeys during acute *Plasmodium knowlesi* malaria. *J Natural Malaria Soc* 1945; **4**: 285.
368. Knisely MH, Stratman-Thomas WK. Microscopic observations of intravascular agglutination of red cells and consequent sludging of blood in rhesus monkeys infected with knowlesi malaria. *Anatomical Record* 1948; **101**(4): 701.
369. Padley D, Moody A, Chiodini P, Saldanha J. Use of a rapid, single-round, multiplex PCR to detect malarial parasites and identify the species present. *Ann Trop Med Parasitol* 2003; **97**(2): 131-7.
370. Imwong M, Tanomsing N, Pukrittayakamee S, Day NPJ, White NJ, Snounou G. Spurious amplification of a *Plasmodium vivax* small-subunit RNA gene by use of primers currently used to detect *P. knowlesi*. *J Clin Microbiol* 2009; **47**(12): 4173.
371. Sarks SH, Arnold JJ, Killingsworth MC, Sarks JP. Early drusen formation in the normal and aging eye and their relation to age related maculopathy: a clinicopathological study. *Br J Ophthalmol* 1999; **83**(3): 358-68.
372. White LJ, Maude RJ, Pongtavornpinyo W, et al. The role of simple mathematical models in malaria elimination strategy design. *Malar J* 2009; **8**: 212.
373. Turner GDH, Morrison H, Jones M, et al. An immunohistochemical study of the pathology of fatal malaria: evidence for widespread endothelial activation and a potential role for intercellular adhesion molecule-1 in cerebral sequestration. *American Journal of Pathology* 1994; **145**(5): 1057.
374. Lee K-S, Cox-Singh J, Singh B. Morphological features and differential counts of *Plasmodium knowlesi* parasites in naturally acquired human infections. *Malar J* 2009; **8**: 73.
375. Silvestri G, Williams MA, McAuley C, et al. Drusen prevalence and pigmentary changes in Caucasians aged 18-54 years. *Eye (Lond)* 2012; **26**(10): 1357-62.
376. Cox-Singh J, Culleton R. Plasmodium knowlesi: from severe zoonosis to animal model. *Trends Parasitol* 2015.
377. Joshi VS, Maude RJ, Reinhardt JM, et al. Automated detection of malarial retinopathy-associated retinal hemorrhages. *Invest Ophthalmol Vis Sci* 2012; **53**(10): 6582-8.

378. Kochar DK, Das A, Kochar SK, et al. Severe Plasmodium vivax malaria: a report on serial cases from Bikaner in northwestern India. *Am J Trop Med Hyg* 2009; **80**(2): 194-8.
379. Naing C, Whittaker MA, Nyunt Wai V, Mak JW. Is Plasmodium vivax malaria a severe malaria?: a systematic review and meta-analysis. *PLoS Negl Trop Dis* 2014; **8**(8): e3071.
380. Kawai S, Sugiyama M. Imaging analysis of the brain in a primate model of cerebral malaria. *Acta Trop* 2010; **114**(3): 152-6.
381. Sein KK, Brown AE, Maeno Y, et al. Sequestration pattern of parasitized erythrocytes in cerebrum, mid-brain, and cerebellum of Plasmodium coatneyi-infected rhesus monkeys (Macaca mulatta). *Am J Trop Med Hyg* 1993; **49**(4): 513-9.