



THE UNIVERSITY *of* EDINBURGH

Title	Internal derangement of the knee joint: a pathological and clinical study
Author	Turner, Arthut Logan
Qualification	MD
Year	1894

Thesis scanned from best copy available: may contain faint or blurred text, and/or cropped or missing pages.

Digitisation notes:

- P.70-71, 79-80 in inverted order in original numeration. Left as in original.

INTERNAL DERANGEMENT OF THE KNEE JOINT.

A Pathological and Clinical Study.

by

A. LOGAN TURNER. M.B. C.M. F.R.C.S.E.

1894.



TABLE of CONTENTS. (General Summary).

INTERNAL DERANGEMENT of the KNEE JOINT.

Conditions resulting from

INJURY.

- a. Displacements of the Semi-lunar Cartilages.
- b. Traumatic Loose Bodies.

DISEASES, which may give rise to Derangement.

- a. Tubercle.
- b. Arthritis Deformans.
- c. Syphilis.
- d. Spinal Arthropathy.
- e. Tumours.

PART I is devoted to Displacements of the Semi-lunar
Cartilages.

PART II to the remaining Conditions;

TABLE in DETAIL.

INJURY. Introductory Remarks. Outline of Thesis-----p.p.1-5.

PART I. AFFECTIONS of SEMI-LUNAR CARTILAGES.

1. Historical Sketch-----p.p.6-12.
2. Anatomical & Physiological Considerations-p.p.13-24.
(The Mechanism of the Displacement).
3. Causes of Displacement-----p.p.25-32.
4. Lesions Observed on Opening the Joint----p.p.33-40.
(Table of Cases).
5. Pathological Remarks-----p.p.40-45.
6. Symptoms and Diagnosis-----p.p.46-56.
7. Treatment and Prognosis-----p.p.56-87.

PART II. LOOSE BODIES, HYPERTROPHIED SYNOVIAL FRINGES, and
other MORBID CONDITIONS as TUMOURS.

- b. Traumatic Loose Bodies-----p.p.69-85.
 1. The Nature of the Injury-----p.p.70-74.
 2. The Bone injured-----p.75.
 3. The Nature of the Body-----p.76.
 4. The Number of Bodies-----p.77.
 5. Appearance & Structure of the Bodies-----p.77.

DISEASE.

a. Tubercle-----p. p. 86-121.

Loose Bodies.

1. Melon Seed-like Bodies & Masses of Coagulated Fibrin-----p. 87.
2. Loose Bodies derived from Synovial Membrane, consisting of the Synovial Tissues, or containing Fibro-cartilage, or Bone and Cartilage---p-93.
3. Loose Bodies derived from the Articular Surfaces of Bones consisting of the Cartilage and subjacent Bone separating by quiet Necrosis-----p.103.

b. Arthritis Deformans-----p. p. 122-144.

Loose Bodies.

1. Melon Seed-like Bodies & Masses of Coagulated Fibrin-----p. 123.
2. Loose Bodies derived from the Synovial Membrane, consisting of fully formed Tissues as Cartilage & Bone or both-----p. 124.
3. Loose Bodies derived from the Articular Ends of Bones being detached Ecchondroses or Osteo-phytes-----p. 131.

Hypertrophied Synovial Fringes-----p. 140.

Symptoms & Diagnosis of Loose Bodies in general---p. p.145-146.

Treatment of Loose Bodies in general-----p. p.147-151.

c. Syphilis-----p. p.151-153.

Loose Bodies and Synovial Fringes.

d. Spinal Arthropathy-----p. p.153-156.

Charcot's Disease, (with Loose Bodies).

e. Tumours-----p. p.157-169.

1. Fatty Tumours-----p.157.

Hypertrophied Ligamenta Alaria.

2. Sarcomata-----p.167.

LIPOMA ARBORESCENS-----p. p.169-173.

The term "Internal Derangement" which is employed as the title of this Thesis has become classical, and was first used by that distinguished surgeon, Mr Hey of Leeds in the year 1803 in a paper forming the subject of Chapter 8 in the first Edition of his "Practical Observations in Surgery". It has been thought advisable therefore, to retain this term which however has now a wider signification than that given to it by Mr Hey. The term sufficiently explains itself, implying that there is some disturbance of the internal component parts of the joint, producing certain symptoms to be afterwards enumerated, and leading one to suspect the existence of some internal lesion in the joint. A very brief summary from Hey's paper enables us to appreciate his definition of the title.

"This joint is not unfrequently affected with an "internal derangement of its component parts, and that "sometimes in consequence of trifling accidents. The disease is, indeed, now and then removed, as suddenly as it "is produced, by the natural motions of the joint without "surgical assistance, but it may remain for weeks or months "and will then become a serious misfortune, as it causes "a considerable degree of lameness.

"This disorder may happen with or without contusion.

"In the former, the symptoms are equivocal till the ef-
 "fects of the contusion are removed. When no contusion
 "has happened, or the effects of it are removed, the joint
 "with respect to its shape appears to be uninjured. If
 "there is any difference from its usual appearance, it is
 "that the ligament of the patella appears more relaxed
 "than in the sound limb. The leg is readily bent or ex-
 "tended by the hands of the surgeon, and without pain to
 "the patient__at most, the degree of uneasiness caused by
 "this flexion or extension is trifling. But the patient
 "himself cannot freely bend or perfectly extend the limb
 "in walking; he is compelled to walk with an invariable
 "and small degree of flexion.

"The complaint which I have described may be brought
 "on, I apprehend, by any such alteration in the state of
 "the joint as will prevent the condyles of the os femo-
 "ris from moving truly in the hollow formed by the semi-
 "lunar cartilages and articular depressions of the tibia.
 "An unequal tension of the lateral or cross ligaments of
 "the joint, or some slight derangement of the semi-lunar
 "cartilages may probably be sufficient to bring on the
 "complaint".

It is evident then that Hey regarded the complaint

as one due to some interference with the proper movement of the femoral condyles upon the tibial articular surfaces, and that such interference might be due, inter alia, to some derangement of the semi-lunar cartilages and he was unquestionably right, though he had no opportunity of examining the interior of joints so affected.

Symptoms closely resembling those produced by derangement of one or other semi-lunar cartilage may be dependent upon entirely different lesions, so much so, that it becomes often very difficult to diagnose the exact condition before the joint is opened for the purpose of treatment. Consequently I have preferred to give a wider bearing to the title "Internal Derangement" than that indicated by Hey and for purposes of description have divided this essay into two parts from the pathological side, thus grouping all the morbid conditions which may give rise to symptoms more or less similar and which should be associated with this term "Internal Derangement."

I. A lesion of one or other Semi-lunar Cartilage.

II. Loose and pedunculated bodies, hypertrophied synovial fringes, new growths etc.

The subject cannot be so divided clinically because one lesion in some of its symptoms so frequently corresponds

with another, rendering an exact diagnosis sometimes very difficult. This is not a matter of very much importance so far as immediate treatment is concerned, though the prognosis may be affected by what is found. If any attempt be made to divide the subject clinically, a division into traumatic and non-traumatic lesions would be of considerable value to the clinician, because with the exception of certain loose bodies which might be traumatic, but whose origin from injury is disputed, the morbid conditions in group I are produced by traumatism, those in group II are not. Undoubtedly, the condition is one of very considerable surgical importance, as a person may become more or less permanently disabled, he may require to give up his occupation altogether or only be able to work for short periods, and in the young it may be necessary to withhold from all active exercise in the shape of football, cricket, cycling, and other forms of athletics.

An attempt will be made to give a succinct account of the various pathological conditions that may occur, to define as clearly as possible the symptoms, endeavouring to differentiate by them the lesion that exists, to discuss the different methods of treatment, and to show what benefit may be derived therefrom.

Such results have been arrived at by a study of the literature of the subject, by the examination of pathological material which has been put at my disposal, and by the study of a series of cases which have come under my own observation, and I would take this opportunity of acknowledging my indebtedness to Professor Annandale for the kind way in which he has allowed me to make use of the patients under his care, and for the valuable assistance I have thus obtained, and at the same time to thank Professor Sir William Turner for leave to examine the material bearing upon this subject in the Anatomical Museum of the University of Edinburgh.

The work has been carried on in the University Clinical Surgery department of the Royal Infirmary, and part I in a less extended form has already been the subject matter of a short paper in the Edinburgh Hospital Reports, vol. II, 1894.

PART 1. AFFECTIONS OF THE SEMI-LUNAR CARTILAGES.

HISTORICAL SKETCH.

The Affections of the Semi-lunar Cartilages of the knee Joint that will be here considered, are displacements of these bodies either in whole or in part through tearing or stretching of their attachments, so that they occupy an abnormal position in the joint, or become too freely movable in it and thus interfere with the natural movements of the femoral condyles upon the tibia. In order to avoid confusion, it may be pointed out that other terms have been employed to designate what is really the same pathological condition, namely, "Partial Luxation of the thigh bone from the Semi-lunar Cartilages" used by Sir Astley Cooper, and the title "Subluxation of the Knee" in Erichsen's Principles and Practice of Surgery.

As already indicated, the earliest description of this condition is usually assigned to William Hey¹, a Leeds surgeon, with whom the term Internal Derangement originated: he himself states that he is not acquainted with any author who has described either the disease or the

1. op.cit.

remedy, but in a paper recently written by Professor
Bruns¹ of Tübingen I find two earlier references quoted.

In 1731 H. Bassius³ reports two cases of the kind under the title "Cartilago tibiae semilunaris elongata locoque sua paulum emota". In one of these which occurred in a woman, who had injured her knee from a fall, he found the external semi-lunar cartilage so swollen and softened, that it protruded a thumb's breadth; by pressure of the finger he was able to reduce it, but it immediately reappeared.

In 1773 William Bromfield⁴ a surgeon at St. Georges Hospital, reported a case, and as it appears to be the first case of the kind in English literature, showing a recognition of the condition before Hey's time, his own words are worth quoting:—"I have seen a temporary lameness "happen from one of the semi-lunar cartilages within the "joint of the knee having slipped out of its situation; "the knee immediately became swelled and very painful.

2. Beiträge zur klinischen Chirurgie. IX Band. Tübingen 1892.

3. H. Bassii observationes anat: Chirurg: Med: Halle Magdeburg 1731. Dec I. Observ: V. pag: 155.

4. W. Bromfield. Chirurg: observat: and cases.

"This case I first discovered by accident; for the assistant having hold of the leg, and sometimes lightly extending, at other times gently bending it, while I was examining the joint of the knee, the cartilage slipped into its place, and the patient soon became easy".

A few years after the publication of Hey's Observations, Sir Astley Cooper¹ in Part II of his Surgical Essays published in 1819, describes the condition briefly, leaning to the view, that an increased secretion into a joint may so stretch and lengthen the ligaments as to allow of the cartilages gliding too freely upon the tibial surfaces, and thus interfering with the proper movements of the femoral condyles; and he further explains how the fault may be rectified by flexion and extension.

Sir Benjamin Brodie², on the other hand, in his well known work on the Diseases of the Joints, shortly dismisses the subject, as he knows of no joint liable to these affections, in which such an examination has been made as to afford any certain evidence as to the peculiar condition existing, and he considers it difficult to understand

1. Astley Cooper. Surgical Essays. Part II. 1819.

2. Benjamin Brodie. Diseases of the Joints. 5th Edit: 1850.

how there should be any actual displacement of parts so fixed by their attachments as the semi-lunar cartilages. Writing about the same time, Samuel Smith of Leeds, in a Clinical Lecture on Internal Derangement of the Knee Joint, quotes a graphic account given by a patient, herself evidently a sufferer from this complaint, as one is led to understand by the nature of her symptoms. This case is of special interest as showing a recognition of the importance of the movement of rotation at the knee joint, not only in the production of the lesion, but also in the method of treatment.

In 1855, Mr Syme² describes the case of a young man, who suffered from repeated attacks of pain and stiffness in one knee joint, of short duration, and when seen by him on one occasion when the condition was of five days standing, he removed the stiffness by flexion and extension under chloroform, but as he states that there was a loose body in this joint, one would be guarded in one's diagnosis without further enquiry.

In thus tracing the history of this form of Derange-

1. Samuel Smith. Lancet. Sept. 20th 1851.

2. J. Syme. Lancet. May 5th 1855.

ment one must quote a case reported by White, as he appears to be the first to draw attention to pain over the site of the semi-lunar cartilage, in this case the internal, as a diagnostic point of considerable value.

Prior to 1867, no descriptive anatomico-pathological account of this supposed lesion had been given, writers upon the subject dealing with it in a more or less speculative way, but in that year Mr Brodhurst¹ details an instance in which he opened the knee joint to remove a loose body, and then found that the offending structure was the anterior portion of the left internal semi-lunar cartilage, detached, but held in situ by a small band of ligament, and then a year or two later Sir William Ferguson³ described a dissecting room specimen, without unfortunately specifying which cartilage, but where one of them had been torn from its connection with the tibia, throughout its whole length, with the exception of its extremities, so that during flexion and extension it must have occasionally slipped, and thus we find after the lapse

1. W. T. White. Lancet. Jan. 1856.

2. B. Brodhurst. St. George's Hosp. Rep. vol. II. 1867.

3. Sir Wm. Ferguson. A system of Practical Surgery. 5th Edit. 1870.

of a century an actual demonstration of what must previously have existed. Other authors might have been quoted but enough has been said to show from the writings of prominent surgeons how some internal lesion of the joint was long recognised, and that a displacement of one or other semi-lunar cartilage was the suspected cause.

During recent years our knowledge of this subject has been very materially increased, due largely to the introduction of the Listerian Methods of operating, enabling surgeons to open the knee joint with greater confidence and safety, so that much that was previously obscure has been made clear.

An admirable paper has been written by Dr. Scott Lang¹ generally acknowledged to be a lucid explanation of the subject both from an Anatomico-physiological and a clinical point of view and no account of this condition would now be complete without some reference to the work done by him.

He demonstrated that there must be some degree of flexion at the knee to admit of displacement of a semi-lunar cartilage taking place, because the movement of

1. W. Scott Lang. Ed. Med. Journal, vol. XXXII. 1886.

rotation, during which the attachments of the cartilages may be stretched or torn, is only possible when the knee is flexed. With a thorough appreciation of the mechanism of these derangements, manipulative treatment for the reduction of them was put upon a sounder basis.

A new departure in the methods of treatment was introduced by Professor Annandale, who, in 1883, opened the knee joint and stitched the displaced semi-lunar cartilage in its place, a complete cure following; thus placing to the credit of the Edinburgh School another advance in surgical treatment.

ANATOMICAL AND PHYSIOLOGICAL CONSIDERATIONS.

Mechanism of the Displacement.

In order to elucidate the various points that will be brought forward in considering this form of Internal Derangement, a certain knowledge of the Anatomy and Mechanism of the knee joint is essential.

The capsule of the joint is strengthened superficially by fibrous covering derived from the muscular tendons and aponeuroses, and in addition there are certain strong parts which have received special names. In front, there is the ligamentum patellae, and behind, the posterior ligament of Winslow. On the sides are the internal and external lateral ligaments; these are nothing more than portions of the capsule specially developed, and without detailing the exact attachments of these fibres, it will suffice for our purpose to say that the capsule, including all these special structures, with the exception of the ligamentum patellae, has a firm attachment to the femur above its articular surfaces, and to the tibia, below its corresponding surfaces.

Within the capsule of the joint these two bones are still further held together by the crucial ligaments, anterior and posterior. The two ligamenta alaria, and

ligamentum mucosum, are merely folds of synovial membrane and need not be discussed any further in this part of the paper, though they must be taken into consideration when dealing hereafter with other morbid conditions; but there are other intra-articular structures which require more careful examination.

The Interarticular or Semi-lunar fibro cartilages or menisci are two crescentic plates interposed between the femoral articular surfaces and those of the tibia; their upper surfaces are somewhat concave, and serve to deepen the articular facets of the tibia; their lower surfaces are flattened. The outer circumferential border of each is convex, thick and attached, the inner border is concave, thin and free, and within certain limits both are movable upon the tibial surfaces. According to Morris they serve a threefold purpose, first, to interrupt shocks or jarring vibrations, secondly, to fill the angular intervals between the articular surfaces of the tibia and femur, and thirdly, they deepen the facets of the tibia for the femur.

The convex outer margin of the internal semi-lunar cartilage can be felt in the interval between the bones

in the healthy knee about at one and a half inches from the ligamentum patellae. The margin of the external cartilage cannot be so felt, because it lies more within the interior of the joint.

The Internal Semi-lunar Cartilage is oval in shape and forms nearly a semicircle: its anterior horn is inserted into an impression at the fore and outer part of the internal articular surface of the tibia, and is also connected with the transverse ligament. Its posterior horn is attached to the inner edge of the hollow behind the spine, and it has also an attachment to the posterior crucial ligament: hence its terminal points of attachment are considerably separated; between these horns the circumference of the cartilage is attached to the deep surface of the capsule, of the joint, and by means of the capsule to the tuberosity of the femur on the one hand, and to the head of the tibia on the other: the capsular fibres between the semi-lunar cartilage and the tibia are called the coronary ligaments, and are shorter and firmer bands than the capsular fibres between it and the femur. It has further, a strong fibrous union with the internal lateral ligament of the joint, a point of considerable importance when we come to consider the possibility of a complete

detachment of this cartilage.

The External Semi-lunar Cartilage is nearly circular in shape: its anterior horn is fixed just in front of the spine of the tibia, its posterior horn behind and between the two osseous points of the same spine, consequently its terminal points of attachment, which are interposed between those of the internal semi-lunar cartilage, are closely approximated. Its convex border anteriorly is attached to the transverse ligament, and it has similar connections with the deep surface of the joint capsule, and through it to the femur and tibia, but here the union is less firm, because the anterior part of the cartilage is more in the centre of the joint and the tendon of the popliteus muscle separates it behind from the Capsule: it has no union with the external lateral ligament, but some fibres connect it with the posterior cruciate ligament.

while on the other hand in rotation outwards when the internal cartilage requires support, this ligament is slack.

The nearer the points of attachment, the greater the range of movement, and the less the fixation, the less the liability to feel the effects of strain, consequently the external semi-lunar cartilage with greater range of movement and less fixation should escape strain and therefore

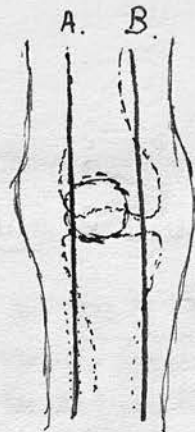
The Transverse ligament is a fibrous cord which lies immediately beneath the synovial membrane at the anterior part of the joint and it connects the anterior extremities of the two semi-lunar cartilages. At its outer end it is attached to the convex border of the external cartilage, and at its inner end it is fixed to the anterior part of the internal cartilage, the exact insertion being subject to some variation. Its thickness and strength vary much in different joints, it is sometimes altogether absent. Its function is probably to keep the two cartilages in their relative positions to one another and to act as an additional means of fixture and restraint to the external semi-lunar cartilage, because in rotation inwards of the leg at the knee, during which movement this cartilage has a tendency to slip, the transverse ligament becomes tense, while on the other hand in rotation outwards when the internal cartilage requires support, this ligament is slack.

The nearer the points of attachment, the greater the range of movement, and the less the fixation, the less the liability to feel the effects of strain, consequently the external semi-lunar cartilage with greater range of movement and less fixation should escape strain and therefore

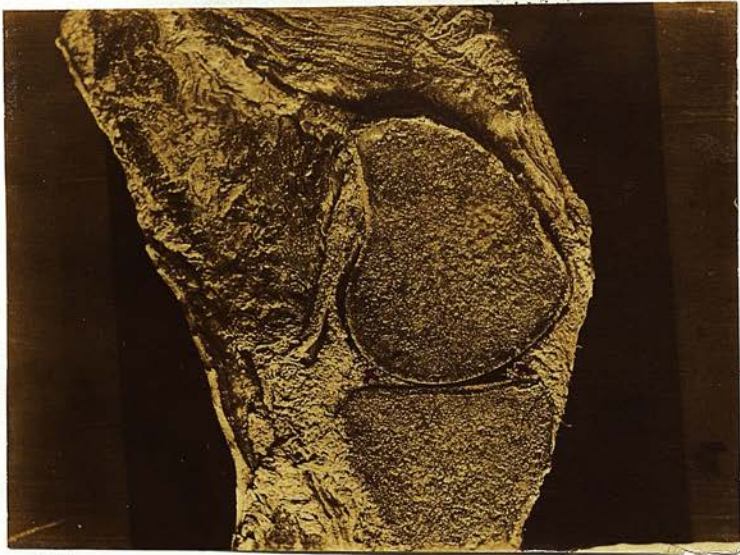Photographs made from vertical antero-posterior sections of the frozen knee joint in the extended & flexed positions kindly put at my disposal by Professor Cunningham of Dublin.

I have made these photographs in order to bring out the greater mobility of the external semilunar cartilage as compared with the internal.

The accompanying diagram shows the plane through which these sections were made in the extended & flexed positions.



- A. Section showing external semilunar cartilage. (tibial surface)
- B. Section showing internal semilunar cartilage. (fibular surface)



A.Z.P.

... X Anterior & Posterior Arthritis.

Anterior & Posterior Arthritis of Internal Semilunar Cartilage seen in section & showing relation to upper surface of head of tibia in the extended position.

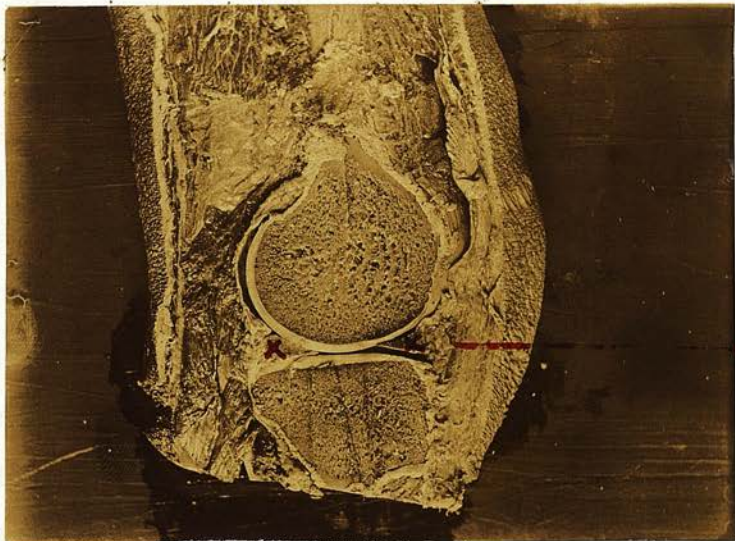

A.Z.P.

... X Anterior & Posterior Arthritis.

infrapatellar X
pad of fat -
(inner ligamentum
alarium)

The same seen in acute flexion of the joint.



A.C.T.

X Anterior & Posterior Extremities -

Anterior & Posterior extremities of External Semilunar Cartilage seen in section & showing relation to upper surface of head of tibia in extended position -



X
intra-patellar
pad of fat following
Cartilage -
(outer liposynovium
alarium)

A.C.T.

X Anterior & Posterior Extremities -

The same seen in acute flexion of the joint - the greater recession of the external cartilage can be seen & consequently its greater mobility requires

be less frequently displaced. It might be argued that these two factors are in favour of more frequent displacement, because the cartilage might more readily, upon occasions, slip too far in towards the inner part of the external femoral condyle and thus become displaced: such a view has already been advanced by Mr Godlee in his description of a dislocated external semi-lunar cartilage.

Clinical experience shows that the internal semi-lunar cartilage is the one that is most often displaced, and the cases that I will presently deal with, serve to strengthen the experience of others. With its lesser range of movement and greater fixation, it is more exposed to strain and consequently to the risk of separation of its attachments. Without doubt, I think it is the fixation of the cartilage that renders it more liable to displacement, and a study of the physiology of the knee joint will go far to explain this.

The movements at the knee joint are those of flexion and extension, associated with a certain degree of rotation, a rotation inwards inseparable with the commencement of flexion, outwards inseparable with the completion of extension: but when the knee is in the flexed position, a considerable additional rotation can be effected.

In extension the semi-lunar cartilages are interlocked between the femoral condyles and the articular surfaces of the tibia, so that they are thus fixed and no strain is put upon their ligamentous attachments, in that position of the limb.

During flexion of the leg the semi-lunar cartilages glide backwards on the head of the tibia, and may be felt receding when the finger is placed upon their anterior convex margin, again to glide forwards as the leg is extended; this is a movement of very considerable practical importance, because during it the anterior coronary attachments are stretched; further reference to it will be made hereafter.

The greater range of rotation which is only possible when the knee is bent, may be either rotation of the tibia upon the femur when the latter is fixed, or of the femur upon the tibia when the tibia is fixed, and during those movements the coronary ligaments are stretched owing to a certain fixation of the cartilages. Suppose then that the femur is fixed and the tibia rotated outwards, the attachments of the internal semi-lunar cartilage are put upon the stretch, and owing to its form, and connections already described considerable strain is brought to bear upon them,

and the greater the fixation in any knee joint, the greater will be this strain. A similar condition may be noted if the tibia be fixed and the femur rotated inwards upon it. The same remarks hold good in regard to the external semi-lunar cartilage, but in this case the movements of rotation must be reversed, an inward rotation of the tibia upon the femur, or an outward rotation of the femur upon the tibia causing a strain upon its attachments. On account however, of the greater mobility of this cartilage it is evident that so great a strain cannot be brought to bear upon these attachments.

In relation to this a point of very considerable interest may be noted: it is impossible to rotate the tibia inwards to such a degree as to put so severe a strain upon the coronary ligaments of the external semi-lunar cartilage as upon those of the internal. Both the lateral ligaments are tense in extension of the joint. In flexion of the joint, the external lateral ligament is greatly relaxed and offers no obstruction to rotation of the joint either outwards or inwards when bent. The internal lateral ligament does not offer any resistance to external rotation up to a certain point, when tension of its fibres is produced and further rotation is prevented. The anatomical explanation of this check action of the internal lateral

ligament is to be found in the study of its attachments and direction of its fibres, for its upper end is connected to the femoral tuberosity in a vertical plane, posterior to its lower attachment to the shaft of the tibia; the direction of its fibres is oblique downwards and forwards, so that when more outward rotation is attempted, the anterior part of the ligament becomes tense and impedes further movement. The range of inward rotation of the knee joint is more limited than that of outward rotation both in the flexed and semiflexed position. The ligament which acts as a check to this movement is the anterior crucial, which passes obliquely from the upper end of the tibia to the intercondylar surface of the outer condyle of the femur, and soon becomes tense when inward rotation is made. If one examines the external semi-lunar cartilage when this check takes place, one finds that the strain upon its coronary ligaments is not great and the possibility of increased strain is prevented by the tense anterior crucial ligament.

In addition to these facts we find that the ordinary position of the leg in walking and running lends itself to more frequent strain upon the coronary attachments of the internal semi-lunar cartilage; this position

which is commonly assumed is one in which the toes and foot are naturally turned somewhat outwards, so that any force applied will in consequence be more readily received upon the inner aspect of the foot, so that a sudden and forcible rotation outwards of the tibia at the knee might be produced, causing an abnormal strain upon the attachments of this cartilage, resulting either in their stretching or in an actual tearing of them, depending upon the degree of force applied, or upon the condition of the ligaments themselves. To sum up then, we are led to conclude that a more frequent displacement of the internal semi-lunar cartilage is dependent upon these three factors acting together:—

- 1st. That it is more firmly fixed than the external.
- 2nd. That a greater degree of rotation outwards is possible and consequently greater strain can be brought to bear upon its attachments.
- 3rd. That the ordinary position of the foot and leg lends itself to a greater liability to the production of outward rotation.

The majority of the cases recorded of Internal Derangement due to a displaced meniscus, are those in which the Internal Cartilage is affected: in the paper by Prof. Bruns already quoted, there is a table containing 43 cases:

this is compiled from various sources and shows a preponderance of lesion of this cartilage: in 27, the Internal semi-lunar cartilage is displaced, in 13, the external, and in 3, the cartilage is not specified. During the last decade, 35 cases have been under Professor Annandale's care. As only 30 of this total have been proved conclusively by operation to have been cases where the symptoms depended upon some affection of one or other semi-lunar cartilage, deductions will be drawn in this paper from these thirty cases only; it is necessary to limit the analysis to operative cases, as other morbid conditions may give rise to symptoms closely resembling those of displaced semi-lunar cartilage, so that a precise diagnosis cannot always be made with certainty from the history and external examination of the joint. In 25 of these the internal semi-lunar cartilage was displaced, in 2 the external, in 3 the cartilage was not specified. Sixteen of these cases have been observed by myself.

If this series be analysed still further, one finds that as regards sex, 28 occurred in men, 2 in women. The relative frequency of the lesion in the right or left knee owing to imperfect notes in the Ward Journals, cannot be absolutely stated, a point however of comparatively little

importance, but where the affected knee is specified 13 are Right Internal Semi-lunars, 5 are Left, while of the two External, 1 is Right and 1 is Left, thus leaving 10 cases unrecorded.

of these displacements, but that it must be applied when the joint is somewhat flexed, so as to permit of rotation or twisting of the leg at the knee joint. Consequently the lesion usually results from indirect violence. The nature of the excitation varies greatly, both in the manner of its application and in its degree, but there is usually very considerable difficulty in ascertaining from the patient exactly how the accident occurred, not necessarily from dulness of intellect or want of observation, but probably the suddenness of the accident and the acuteness of the pain render him unable to remember the details. The amount of force producing the twist, necessary to stretch or tear the ligamentous attachments must vary in different knees.

A careful study of the thirty cases just brought under notice goes far to prove that a knee joint may become "predisposed" to the lesion; that is to say that the attachments of the semi-lunar cartilage may become gradually stretched and weakened so that the cartilage becomes too freely movable, or that an injury, by no means severe

CAUSES OF DISPLACEMENT.

What has been already said in the foregoing section has served to indicate not only that violence is an exciting cause of these displacements, but that it must be applied when the joint is somewhat flexed, so as to permit of rotation or twisting of the leg at the knee joint. Consequently the lesion usually results from indirect violence. The nature of the traumatism varies greatly, both in the manner of its application and in its degree, but there is usually very considerable difficulty in ascertaining from the patient exactly how the accident occurred, not necessarily from dulness of intellect or want of observation, but probably the suddenness of the accident and the acuteness of the pain render him unable to remember the details. The amount of force producing the twist, necessary to stretch or tear the ligamentous attachments must vary in different knees.

A careful study of the thirty cases just brought under notice goes far to prove that a knee joint may become "predisposed" to the lesion: that is to say that the attachments of the semi-lunar cartilages may become gradually stretched and weakened so that the cartilage becomes too freely movable, or that an injury, by no means severe

enough to cause their rupture in a normal healthy joint may readily produce it in one in which this process of stretching has been going on. Thirteen of those patients have followed the occupation of coal miners, who worked for a varying number of years more or less continuously in the kneeling posture: there is certain variation in that posture, but whatever that variation may be, the position is one requiring more or less acute flexion at the knee joint, sometimes it is one of actual kneeling on the ground, at other times it is squatting with the leg or legs bent under the thighs.

We have seen that in flexion the semi-lunar cartilages recede into the joint, and as they do so they render tense the anterior portion of their coronary ligaments; prolonged flexion of the knee strains the anterior part of the coronary ligaments so that a gradual stretching and weakening of them may thus be produced. In such an occupation however something more must be considered than the mere position of flexion because in order to carry out the necessary work of digging, there is constant movement and modification in the degree of flexion of the joint, now more, now less, according to the circumstances of the work, so that the strain upon the coronary ligaments is

constantly altering. In the majority of these cases symptoms followed the history of a definite injury, thus to cite out of many, two examples, in one merely the catching of the foot against a stone while walking, in another, an injury of greater severity received while playing football, on the other hand, in one or two no information of the kind could be obtained. While of necessity admitting that an injury may cause detachment of a semi-lunar cartilage in a previously healthy joint, it is conceivable that such injuries in the above mentioned cases might have failed to cause the results they did, had the knees not been subjected to the previous long continued strain from kneeling, and were the fact proved that in one or two cases no such injury has been received it would lend greater support to the argument.

The occupation of coal miner is not the only one from which the same deductions may be drawn, because we find in more than one instance these symptoms arising in those whose business is that of marine engineer where from the confined space much kneeling and squatting is necessary and in one of Professor Annandales' early cases the man was a gardener, a trade necessitating a like position.

In women the condition is rare, doubtless due to the fact that they are seldom exposed to such violence as

would lead to the tearing of the attachments of their semi-lunar cartilages, but it is interesting to note as bearing upon this point of predisposition that the occupation of one of the two women in this series of cases who suffered from this form of internal derangement, was that of domestic servant, and that two other patients similarly affected, an account of whose condition I have obtained information upon, are also domestic servants. Are there not grounds here for supporting the argument of previous weakening by strain, seeing the constant necessity for kneeling such an occupation entails? In reference to this question of predisposition, there is still another point which calls for some remark and that is whether it is possible for Chronic synovitis or repeated attacks of synovitis to so relax the ligamentous attachments of the cartilages as to make them more movable. Sir Astley Cooper¹ inclined to this idea, because he states that in cases where there has been increased secretion into a joint, the ligaments become so much lengthened as to allow the cartilages to glide upon the surface of the tibia. In Holmes'² System of Surgery it

1. Astley Cooper. op. cit.

2. Holmes. System of Surgery.

is stated that the attachments of the cartilage must have been previously stretched by inflammation of the joint and their own substance enlarged so as to increase their prominence, this we cannot accept, as it stands, as there is a large number of cases in which the joint is known to have been previously quite healthy before the injury was received which caused the displacement.

In order to prove or disprove these statements satisfactorily, experiments would have to be made for the purpose. Clinical experience does not support the contention, and is it not more probable that the trauma which produced the effusion, caused at the same time displacement of the cartilage, which latter was not recognised until repeated attacks of synovitis led the patient to seek for further advice, when the true state of affairs was discovered.

I have attempted to show then, that undoubtedly the semi-lunar cartilages may become predisposed to luxation, so that the same injury may produce in one joint, what it will fail to do in another. The displacement may occur in playing football, cricket, golf, tennis, or in other forms of athletics, or it may occur under everyday circumstances, and an enumeration of the actions or postures at the moment will only help to support what has been already said in

a blow directly applied to the joint appears to have been the initial cause of detachment; undoubtedly in some the

regard to the mechanism of these displacements. Severe twists of the knee, as in catching the foot and screwing the leg suddenly inwards or outwards; forcible turning of the toes outwards, as described in Samuel Smith's case, where a girl was ordered by her dancing master as a punishment to stand against the wall and turn her toes out to an extreme degree, when something gave way in her left knee. The knee must have been somewhat flexed at the same time. Turning sharply and pushing off with the foot, a movement so frequently carried out in playing football, violence applied to the inner side of the foot, prolonged kneeling, squatting, when engaged in active work such are some of the examples of exciting causes, which patients are able to describe.

Once the lesion has occurred, very little may again put the cartilage into an abnormal position if repair of the torn attachments has not taken place after the original separation. Crossing one leg over the other, the mere catching of the toe against a stone or upon some uneven ground while walking, turning round in bed if the foot be caught in the bedclothes, rising from kneeling and other slight movements of a similar kind may be the causes of such displacements recurring. In more than one recorded instance a blow directly applied to the joint appears to have been the initial cause of detachment; undoubtedly in some the

leg may have been twisted in the fall resulting from the blow and in this way displacement of the cartilage been produced, but in one case observed by myself and operated upon by Mr Annandale seventeen months after the injury, the history given was that the patient while jumping over a fence struck the inner side of his left knee on the top rail as he rose to the jump; no fall resulted, but swelling and stiffness of the knee followed necessitating rest: on the subsidence of the swelling a few days later, he found he could not straighten his leg and the doctor who then saw him carried out some manipulations and straightened the leg. Without any further injury he had repeated attacks of locking of the joint, and when the joint was opened a considerable portion of the internal semi-lunar cartilage was found detached. The patient was a miner and therefore comes into the class of knees that are predisposed.

There is yet another question of some considerable importance and that is, can displacement occur without any previous injury to the joint? and upon this point I think we require more information. In two only of the 30 cases is no history of violence to be obtained, one was that of a miner who from the nature of his work might

have received a strain sufficient to tear his already relaxed ligament, without having his attention drawn to it: if every case which could not give the history of an injury belonged to a class where the joint was predisposed, there would thus be strong proof given in favour of predisposition, but in the same series we find a printer, who suffered from displacement and could not recollect having received any injury. He was in the habit of playing Association football. A medical man in Edinburgh who experienced all the symptoms of displaced cartilage tells me he had never injured his knee in anyway likely to produce this, but that the cartilage had slipped for the first time while rising from kneeling.

Notwithstanding these exceptions we must I think consider this form of derangement as traumatic in origin thus supporting our clinical division as indicated in the introductory remarks.

LESIONS observed on opening the JOINT.

An intelligent appreciation of the Clinical symptoms of a morbid condition cannot be had without understanding what pathological changes may take place.

A good deal has been written about displacements of the semi-lunar cartilages but nothing definite appears to have been stated as to what actually occurs, and why certain symptoms should or should not be present. It seems to me that the conditions may reasonably be divided under four heads.--

1st. That owing to stretching or tearing of the coronary ligaments, the cartilage which normally recedes slightly into the joint during flexion, may slip too far back and in upon the tibial surface, so that when extension occurs it is unable to come sufficiently forward again, with the result that it is caught between the joint surface and acting as a wedge locks the joint.

2nd. In some cases, the cartilage owing to its increased mobility may be pushed too far forwards and outwards on extension of the joint, so that it may be seen and felt outside the joint.

3rd. In rare cases, the cartilage may pass into the intercondyloid notch; this requires a complete separation

of the whole of the circumferential attachments.

4th. The cartilage may be thickened and structurally altered giving rise to symptoms without any detachment. In order to simplify descriptive detail I have photographed the majority of the cartilages removed from the cases which have been observed by myself; in no case was it possible to obtain a picture of the semi-lunar cartilage as it lay in situ, but its position in the joint when opened is described. It is necessary to divide this detailed account into two main groups.

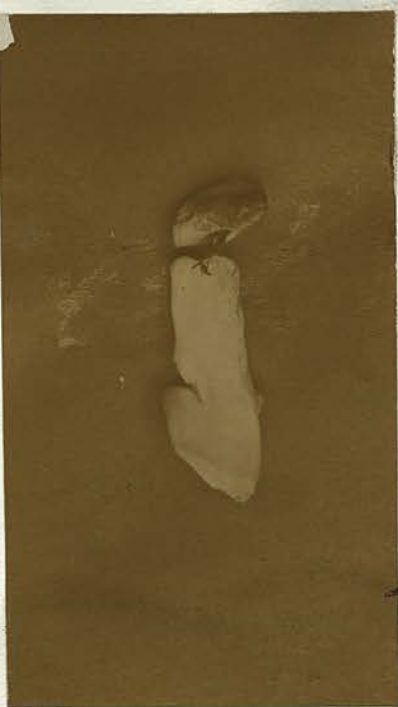1st. Where there is no tearing or rupture of any of the attachments of the semi-lunar cartilage, but where they have a preternatural range of movement in the joint owing to relaxation or stretching of these attachments.

2nd. Where the attachments of the semi-lunar cartilage are torn through either in whole or in part, so that from this cause there is too great mobility of the whole cartilage, or of the detached portion.

A detailed account will be given of the morbid appearances in all but 12 of Professor Annandale's series of 30 cases, there being no notes to hand of these 12 cases, and then reference will be made to certain conditions described by other writers.

These photographs illustrate the portions of the Semilunar Cartilages removed at operation. I have photographed them natural size.

A. 1. G.D.

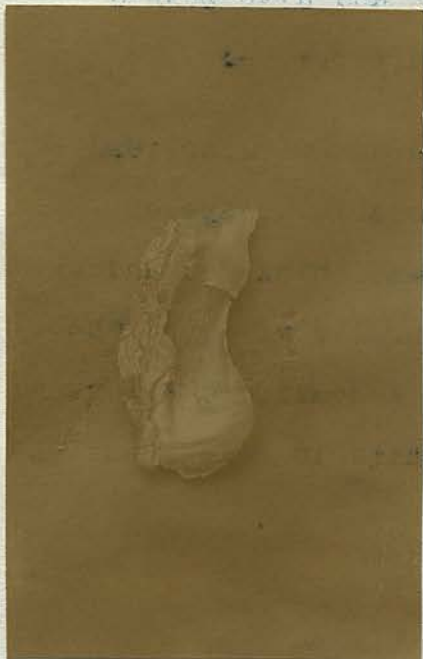

A.Z.T.



A. 2. Res. Mr. W.

A.Z.T.



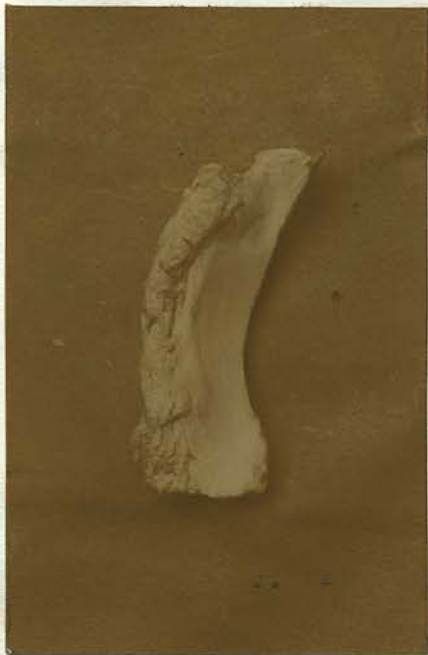A. 3. W.W.

A.Z.T.

GROUP I. Where there is no tearing or rupture of attachments, but preternatural mobility from their relaxation or stretching.

A. INTERNAL SEMI-LUNAR CARTILAGE.

1. G.D. 34 years, a miner. Operation, October 1890. Left Knee. The cartilage was found too freely movable owing to stretching of the coronary ligaments. The greater portion of the structure was removed.
2. Revd. Mr. W. May 1893. Operation, Right Knee. The middle portion of the cartilage was too freely movable and was consequently removed.
3. W.W. 25 years, an engineer. Operation, October 1893. Right Knee. There was no tearing of the ligaments, but the cartilage could be pulled to a considerable extent out of the joint and also pushed into it more than normally. Large part removed.
4. J.H. 24 years, a carter. Operation, June 1893. Left Knee. There was a considerable escape of synovial fluid: the cartilage was thickened and of a yellowish colour and preternaturally movable. The larger part of it was removed. A small but elongated, fibrinous like body, flat and white in colour was



A. 5. T. M.

A. 5. T. M.



A. 5. T. M.

Group II
A. i. J. T.

detected and removed. The presence of lipping at the articular margins of the femur indicated a chronic rheumatic affection.

5. T.M. 42 years, a labourer, Operation, December 1893.

Right Knee. The cartilage was found too freely movable and was excised.

6. J.E. 52 years, a miner. Operation, May 1893.

Right Knee. The cartilage was too freely movable and its outer convex border was thickened. It was removed.

B. EXTERNAL SEMI-LUNAR CARTILAGE. None in this division.

GROUP II. Where the attachments of the Semilunarcartilage are torn through either in whole or in part.

A. INTERNAL SEMI-LUNAR CARTILAGE.

1. J.F. 21 years, a miner. Operation, August 1893.

Right Knee. The cartilage lay in the intercondyloid fossa arching backwards with its convexity upwards: the whole of the circumferential attachments had been torn, so that it was fixed by its anterior and posterior horns only, the whole surface of the inner facet on the tibia being thus exposed. The cartilage itself



ALT.

A. 2. W. MacD.
(much altered by spirit)



ALT.

A. 3. W. J.

did not appear to have undergone any structural change, but its inner concave margin was marked by two indentations, one near the anterior extremity in the form of a small nick, and a larger one near the posterior end, appearing as if portions of the cartilage had been nipped out.

2. W. MacD. 38 years, a miner. Operation, January 1893.

Right Knee. On the joint being opened a portion of the cartilage was found protruding. This was the posterior end free from its attachments in front of the posterior horn, somewhat frayed and thinned, and folded outwards upon itself, and capable of flail like movement. The anterior horn and anterior portion of the body were attached. The greater part of the cartilage was removed.

3. W. I. 40 years. Operation, December 1892. Right Knee.

The central portion of the cartilage was free from its coronary attachments, but fixed in front and behind. The detached part was removed.

4. J. F. 41 years, a miner. Operation, March 1893.

Right Knee. The condition was similar to the preceding one. Detached part removed. In addition, there was a distinct process of fat in the region of the inner ligamentum mucosum. This also was removed.

6. W. 30 Years a Soldier - Operation November 1888

Right knee. The cartilage was completely separated

from the anterior attachment and was displaced

backward. It was drawn forward and attached to the anterior

published

7. W. 32 Years a Soldier - Operation November 1888

Right knee. The cartilage had been almost entirely

rent away from the anterior attachment and was displaced

back upon itself, lying towards the mesocondylar

space. It was attached. Published in same paper.

8. U. 32 Years a Soldier - Operation July 1888

Right knee. The cartilage was partially separated

from the anterior attachment and was attached

Published in same paper.

9. R. 32 Years a Soldier - Operation

Left knee. The body of the cartilage

was undergoing a form of fatty degeneration

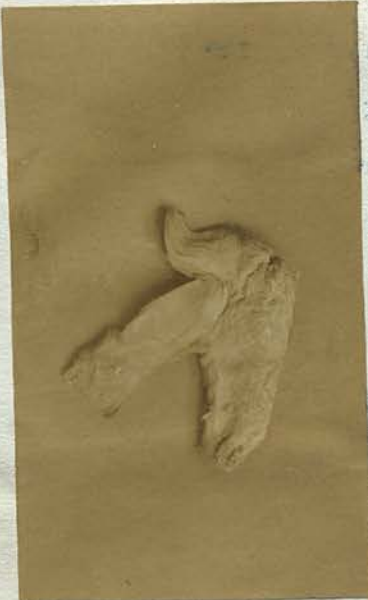and a portion had been torn from

Published

A. 8. R.W.

1. A. 32 Years a Soldier - Operation

Right knee. The cartilage was



5. T.W. 30 years, a miner. Operation, November 1883.
Right Knee. The cartilage was completely separated from its anterior attachments and was displaced backwards. It was drawn forward and stitched. Case already published.¹

6. W.B. 32 years, a gardener. Operation, November 1885.
Right Knee. The cartilage had been almost entirely torn away from its anterior attachments and was folded back upon itself, lying towards the intercondyloid notch. It was stitched. Published in same paper.

7. J.G. 35 years, a miner. Operation, July 1886.
Right Knee. The cartilage was partially separated from its anterior attachments and was stitched. Published in same paper.

8. R.W. 38 years, a miner. Operation, July 1888.
Left Knee. The body of the cartilage was thickened and undergoing a form of fatty degeneration. There was a tongue like process split from its upper surface. Published.²

1. Annandale. Med. Chir. Soc. Trans. Edin. vol. VI. 1886-87.

2. Annandale. Brit. Med. Journal. Feb. 1889.



A. 9.

A. 9. J. T.

... the two hands were ...
... attached to front of the ...
... by the hair which ...
... the whole ...



A. 10.

A. 10. H. J.

... the ...
... The ...
... the ...
... the ...
... the ...
... the ...
... the ...



A. 11.

A. 11. W. H.

... the ...
... the ...
... the ...
... the ...
... the ...
... the ...

9. J.T. 32 years, a miner. Operation, July 1893.

Left Knee. The larger part of the circumferential attachments was torn; anteriorly, it was only attached by its horn, while a portion of the body was still attached in front of the posterior horn. The free portion was very movable: the whole cartilage between the two horns was excised.

10. M.F. 57 years, a gas maker. Operation, August 1893.

Left Knee. The cartilage was torn away from its anterior attachments, the stump of the anterior horn being left. The free portion was flattened out and irregularly frayed, with a tongue like process split from its superior surface: this process, along with the frayed end, was freely movable. The whole movable portion was divided from its attachment behind.

11. W.N. 19 years, a printer. Operation, February 1893.

Left Knee. The middle portion of the cartilage was detached from the tibia for at least a quarter inch and appeared thickened; its inner concave margin was frayed. It was removed.



677.

B. I. T. S.

INTERNAL ORBITAL LIGAMENT
The internal orbital ligament is a
1905. It is a thin, white, fibrous
band which is attached to the
internal orbital foramen and
extends to the lesser orbital
foramen. It is situated in the
orbital canal and is situated
between the two foramina.

Special reference may be made to the condition
in number I of Group II where the internal orbital
ligament was completely detached from the internal
orbital foramen and lay in the lesser orbital
foramen. It has been only once previously described
by Dr. G. H. R. Jones, who considered that from its greater size and
position it was the internal lateral ligament and
not the internal orbital ligament. In almost all
specimens the position is almost an upper orbital
foramen. The same relationship is seen in the
internal ligament which is usually attached and
is situated in the lesser orbital foramen. Dr. W. H. Ferguson
has also referred to this ligament as being
situated in the lesser orbital foramen from the connection with the

B. EXTERNAL SEMI-LUNAR CARTILAGE.

1. T.S. 20 years, an iron dresser. Operation, April 1893. Right Knee. A quantity of bloody fluid escaped: the cartilage was completely torn from its circumferential attachments, being fixed by its horns only. Two loose bodies consisting of cartilage and bone were also found. All were removed.

Special reference must be made to the condition found in number I of Group II where the internal semi-lunar cartilage was completely detached from its circumferential attachments and lay in the intercondyloid fossa, a condition which appears to have been only once previously described.*

Dr Scott Lang considers that from its greater size, and from ^{its} attachment to the internal lateral ligament such a complete luxation is almost an impossibility, without at the same time involving a serious rupture of the internal lateral ligament, to which it is firmly attached, and Erichsen states that it never happens. Sir Wm Ferguson whose dissecting room specimen has already been referred to, describes a cartilage as being torn from its connection with the

* Croft. Brit. Med. Journal. March 1888.

tibia throughout its whole length, with the exception of its extremities, but unfortunately the cartilage is not specified.

In the case described in group II, the patient was a miner and had been following this occupation for twelve years having commenced as a lad of nine years of age. The accident which produced the condition, two years before the operation was a somewhat severe one, occurring while playing Association football, when he collided with an opponent and had his leg jammed between those of his adversary: he felt a crack which he likened to a small pistol shot: he fell and was unable to rise for a few minutes. The exact amount of violence necessary to produce this lesion cannot be estimated, but in this case it occurred in a "predisposed" joint, and consequently less force would be required.

Complete detachment of all the coronary attachments of the external semi-lunar cartilage is not so infrequent, as in the case of T.S. described above, but the cartilage lay upon the external articular surface of the tibia and not in the intercondylar fossa when the joint was opened. Other cases of the kind are recorded, notably that of a dissecting room specimen described by Mr Godlee in the *Pathological Society's Transactions*, vol. XXXI, where the circumference

of the cartilage was torn away from its attachment to the capsule of the joint and occupied a vertical position in the intercondyloid fossa. Though displacement of this cartilage is rarer than that of the internal, the possibility of a complete luxation occurring is readily enough understood when we remember how its attachments are weakened.

Splitting of the cartilage may take place, so that a portion or portions of it may form processes which are movable in the joint cavity. Mr Davies-Colley in the British Medical Journal, vol I. 1888 reports a case in which the internal semi-lunar cartilage was split into three ribbons by two fissures running from before backwards. One can understand how a process so formed might become broken off by repeated pinches in the joint and thus give rise to a loose body, and in studying the origin of loose bodies in the knee joint, this fact must not be lost sight of. Dr Maxter of Boston in the last volume of the Trans. of the American Surgical Ass. 1893 describes a case in which he found pieces of the internal semi-lunar cartilage broken off and forming loose bodies, thus supporting an origin of loose bodies from this source. In a case described by Mr Brodhurst only a small band of ligament prevented the cartilage from becoming a perfectly free structure in the

joint. Nowhere is any account to be found of detachment of one or other horn of a cartilage. In many, the cartilage is said to be detached from its "anterior attachment", and in one or two it is described as torn from its "posterior attachment," but we cannot infer from these terms that there has been tearing of the horns from the bone; such a condition would have been noted in a more precise way and experience is quite against such a form of injury taking place.

Dr. Borck of Rostock describes a case in which he found the Internal Semi-lunar Cartilage completely torn across its middle so that the anterior half was separated from the posterior, the anterior portion again being free from its circumferential attachments, fixed only by its anterior extremity, evidently resembling number 2 in group II.

The naked eye appearance of some of the cartilages removed indicated that a structural change has taken place in them, occurring in an otherwise perfectly healthy joint and not to be associated with a tubercular or rheumatic condition. Such changes may be of a twofold nature, on the

1. Borck. Verhandlungen der deutschen Gesellschaft für Chirurgie. XXII Kongress 1892.

one hand towards thinning and loss of substance, on the other hand thickening of the cartilage and consequent increase in size. Illustrations of both these conditions are to be found from a study of these cases, and a glance at the tables given above will show that where the lesion is one of complete detachment from tearing through of the coronary ligaments with flail like portions in these the free portion may become frayed and thinned and a part of the cartilage be nipped out. The manner in which this is brought about may be readily understood when we consider how the constant movements of the bones of the joint against these flail like pieces of cartilage may cause by attrition, thinning of them, on the other hand, in the group of lesions where there is preternatural mobility from stretching only there the change in the cartilage that can be noted is one of thickening. This too can be easily understood, because, the increased mobility, to a limited extent, will set up sufficient irritation to produce a chronic inflammatory thickening. Such flail like processes of the semi-lunar cartilages may affect the articular surfaces of the bones. In one case there was found on opening the joint, in addition to the detached cartilage, a distinct indentation; without any loss of the cartilage substance, upon one of

the femoral condyles suggesting a pinch of very considerable force.

Lastly, there is a condition of the semi-lunar cartilages described by Kocher, which must be referred to here; though not resulting from injury, symptoms of internal derangement due to isolated disease in one or other cartilage are recorded by him in four cases. He describes the condition as that of circumscribed fungous disease of a meniscus or meniscitis fungosa, and indicates how isolated deposits of disease may originate in one of these structures just as it does in bone. Diagnosis is somewhat difficult as the most marked swelling and tenderness were by no means circumscribed in correspondence with the margin of the affected cartilage. In three cases the internal, and in one, the external cartilage was the site of the disease. In three of them (two internal and one external) excision of the cartilage resulted in recovery and free movement of the affected knee.

SYMPTOMS and Diagnosis.

It is necessary to distinguish between cases in which the lesion has been produced for the first time, and those old-standing cases, in which, once the cartilage has become detached, there is a frequent recurrence of the symptoms due to its again assuming an abnormal position probably from some trivial injury, or perhaps only during some natural movement of the joint. The former have been called acute cases, the latter chronic. These terms are extremely misleading and should not be employed. The terms "recent" and "old-standing" may be substituted as expressing the two conditions in a much clearer way.

As no recent cases have come under my notice, a knowledge of their symptoms is largely derived from the account given by patients with the old-standing condition. With some few exceptions, as already indicated, there is the history of an injury varying in its nature and degree, the exact details of which, as regards the position of the limb, one has considerable difficulty in obtaining, owing to the suddenness of the accident and the acuteness of the pain.

There must, however, be some degree of flexion at the knee, making rotation of one bone upon the other possible, and at the same time either the tibia or the femur is fixed.

There is sudden and intense pain in the knee, often of a sickening character. The patient falls to the ground, and will sometimes state that he felt a crack or click in the joint. On examination, the knee is found locked in a semi-flexed position, it cannot be completely extended, and on attempting to do so there is the sensation of something being caught between the joint surfaces of the femur and tibia. On the other hand, flexion is quite possible. There is pain on pressure over the site of the semi-lunar cartilage in the line of the joint, and this is increased on attempting to extend the limb. It may be on the inner or outer side of the joint, depending upon which cartilage has been injured. A prominence may be formed or a depression may be felt in the position of the cartilage, depending upon whether it has been displaced outwards or inwards, but as there is usually considerable effusion into the joint, sometimes at once, it becomes difficult, if not impossible, to differentiate such a condition.

Probably no better idea can be got of the symptoms which arise in old-standing cases, than by the study of a few illustrative examples selected for the purpose of showing how such symptoms may vary.

The case of **J.F.**, 21 years of age, a miner, may be

quoted in some detail as presenting well-marked signs of cartilage detachment. In obtaining a history it is most important to avoid putting leading questions, endeavouring rather to hear the patient's own statement about himself. For ten years he had followed the occupation of a miner, almost constantly assuming the miner's squatting position. In August 1891, that is, two years before admission, he received an injury to his right knee while playing football, but he was unable to give a clear account of the nature of the accident. He felt a crack likened by him to a small pistol shot, he fell, and for a few minutes was unable to rise. On doing so he found the joint swollen and stiff with pain, especially marked on the inner side and at the same time he thought he felt "something" in the same locality. After two or three days' rest, he consulted a bonesetter, who by rubbing and manipulation jerked this "something" into place, enabling him then to walk with greater ease. The swelling subsided, and he returned to work, being able to bend his knee easily in the required position, though he continued to feel pain on attempting to completely straighten the leg.

Since that time, on fifteen or sixteen occasions, locking and swelling of the joint have occurred, with pain

localised to the inner side, necessitating manipulation by himself or a friend, in order to again bring about extension of the leg. He was often able to avoid such occurrences by care during his work, but when forgetful in running or other active exercise it would occur, incapacitating him from all such enjoyment, and causing him at last to apply for surgical advice.

On examination of the joint itself, there was found some swelling, especially a fulness on the inner side. There was pain on pressure over the site of the internal semi-lunar cartilage in the line of the joint, and about one and a half inches from the inner border of the ligamentum patellae. I would here emphasise the necessity of localising with care the exact position of the pain, in order to distinguish it from that due to a strain of the internal lateral ligament, a not unfrequent result of an injury to the joint, setting up a local periostitis, and causing sometimes very considerable pain, but in this case it is elicited by pressure on the bone, on the tibia or femur below or above the line of the joint, and not in the interval between the bones. The internal semi-lunar cartilage could be felt, receding on flexion, and coming forward in extension, just as in the left healthy joint, and

semi-lunar cartilage.

All the cases do not present such well-marked fea-

apparently similar to it in outline and movement.

Such is a good example of a typical old-standing case, strongly suggesting displacement of the internal semi-lunar cartilage. The joint was opened by Mr Alexis Thomson and a condition of very considerable interest was found. The internal semi-lunar cartilage lay in the intercondyloid fossa arching backwards with its convexity upwards. Its circumferential attachments had been torn, so that it was fixed by its anterior and posterior horns only, the whole surface of the inner facet on the head of the tibia being thus exposed. The cartilage did not appear to have undergone any structural change, but its inner free margin was marked by two indentations, a small one near the anterior extremity in the form of a nick, a larger one near the posterior end in the shape of a gap, suggesting that a part of the cartilage had been nipped out. This is a pathological condition of extreme interest as only one similar detachment of this cartilage is recorded in the literature of the subject. Mr Erichsen states that such a condition probably never occurs, while Dr Scott Lang is of opinion that it would be almost impossible without rupture of the internal lateral ligament. Mr Godlee describes and figures a like condition of the external semi-lunar cartilage.

All the cases do not present such well-marked fea-

tures. M.F., 57 years of age, a gas maker, injured his left knee twelve years before admission. Swelling of the joint followed, but after rest this subsided, the knee improving but always remaining weak. This weakness has been his chief complaint, though he describes an occasional "jerking" of the knee, but nothing could be elicited of a more definite nature as regards this symptoms. The joint never became locked, though sometimes he felt as if there was "something" on the inner side, which did not however interfere with his work.

Six weeks before admission a second accident occurred, causing swelling and pain and interference with walking. Local examination revealed nothing. There was pain on the inner side over the cartilage.

When the joint was opened, the internal semi-lunar cartilage was found torn from its anterior attachment, merely a stump being left in front, and a portion of the body was separated from its circumferential attachments, but evidently posteriorly retaining its normal position. The free portion was flattened out and irregularly frayed, with a distinct tongue-like process, split from its superior surface, and freely moveable. The whole of the detached portion was removed. This is a case, then, where, from the



pathological condition, a well-marked train of symptoms might have been expected, but such a history was not obtainable.

On the other hand, another example illustrates well how a marked train of symptoms may occur with apparently very little to cause them.

W.W., 25 years of age, an engineer, appears to have injured his right knee eleven years before the operation while playing cricket. For a lengthened period of time he complained of nothing definite, save some pain and stiffness. Later, however, he perceived that when catching his foot upon a stone or when walking upon uneven ground, his knee would become locked, and he would be unable to straighten his leg, requiring to move it gently and press upon the joint with his hand, when he was at once able to resume walking. This would occur again and again necessitating his giving up all active exercise, the wearing of a bandage failing to give him relief. On examination of the joint the same signs as those described in the first case could be made out, the internal semi-lunar cartilage being felt with greater readiness than in the healthy joint.

On opening the joint, no tearing of ligaments or detachment of the cartilage was found to exist, but its range of

movement was preternatural, as it could be freely pulled forwards and pushed backwards into the joint, probably from its coronary ligaments having become relaxed. The larger portion of the cartilage was removed.

While such typical symptoms may result from little disturbance of the parts, poorly marked symptoms may follow a lesion of a similar nature, though it hardly appears necessary to quote a case in support of this statement.

Lastly, one case must be cited, where a diagnosis of some affection of the semi-lunar cartilages was made, and on opening the joint nothing abnormal was found in connection with either one or other of them, nor did any of the other joint structures appear to be at fault.

The patient P.M.G. was a miner, and about three months before admission he slipped and twisted his left leg. Swelling and stiffness followed, a jerking or click was constantly felt on the outer side of the knee, but no pain, nor at any time was there locking. A second accident was followed by swelling and pain on pressure over the site of the internal semi-lunar cartilage, and always when the joint was acutely flexed. The symptoms, therefore, vary considerably and do not altogether depend upon the amount of displacement of the cartilage.

Are we always able to make a diagnosis of the exact nature of the lesion enabling us to state whether we are dealing with a displaced semi-lunar cartilage, or a loose body, or a pedunculated body, either of the synovial membrane or subsynovial tissues? It is not always an easy matter to say that the case is one of displaced semi-lunar cartilage. There are two signs, however, upon which much reliance may be placed; first, in connection with the displaced cartilage, the pain experienced by the patient in movement, especially when the leg is rotated outwards or inwards at the knee, depending upon whether the internal or external cartilage is affected, is always localised to one part of the joint, namely over the site of the cartilage in the interval between the bones, and pressure made over it elicits pain there also. This was well brought out in a case which was sent into hospital as one of displaced internal semi-lunar cartilage; there was the history of a blow upon the inner side of the knee, a few weeks before, with swelling, stiffness and pain on that side following. When examined on admission, the leg could be forcibly rotated outwards without occasioning pain, and pressure over the cartilage caused no inconvenience, but when it was made above the interval, upon the internal femoral condyle

then pain was very considerable. The case was in all probability one of periostitis and osteitis, the result of the blow, and it was relieved by simple treatment.

Second, if there is any symptom of something moving in the joint, a sign which is not always present, it is located to the region of the cartilage only. On the other hand, when a loose body is present, the site of the pain varies, and the body is felt sometimes at one spot, sometimes at another. It is in the case of the pedunculated body that the difficulty in differential diagnosis arises, especially if such be in the neighbourhood of one of the semi-lunar cartilages, because its attachment prevents any range of movement and also localises the pain.

Granted that the case be one of affection of a semi-lunar cartilage, are we in a position to state the variety of the displacement, that the cartilage is freely movable at its injured part and may therefore occupy some abnormal position in the joint, or that its detachment is limited, and it is only movable within a restricted area, or that its anterior attachment is free, and the cartilage can be folded back upon itself? Other writers have endeavoured to show that this is possible in any given case, by a careful examination of the joint and a comparison

of the two knees in these patients, the conclusion arrived at was that a comparison of the two joints is no criterion, as, even under normal conditions, variation in the definition and movements of these cartilages on the two sides can be recognised.

TREATMENT.

Treatment falls under three heads; 1st, the immediate replacement of the cartilage in the recent case or on recurrence in an old standing case; 2nd, palliative means whereby an attempt may be made to affect re-union of the torn ligaments, or if that fail, to adopt measures by which the cartilage will slip as seldom as possible; and 3rd, operative interference. As regards the first of these, granted that an exact diagnosis has been made as to the nature of the injury, the method of freeing the "locking of the joint" is one of manipulation, based upon a knowledge of the movements causing the displacement, such as have already been indicated. If there should be much pain and muscular spasm, chloroform may be given, otherwise reduction may be attempted without it. In the old standing cases it is usually an easy matter, and many patients learn to unlock their own joints by carrying out certain movements.

Flex the knee fully, then rotate the leg firmly inwards

if it is the internal semi-lunar cartilage that is displaced, outwards, if it is the external, and then extend somewhat suddenly, while still maintaining the rotation, at the same time pressing the rim of the cartilage into the joint with the thumb should it protrude over the inner or outer tuberosity of the tibia. If this should fail at the first trial more than one attempt should be made. After reduction, complete rest of the joint should be maintained, not only to get rid of the effusion, but to seek if possible to obtain re-union between the torn ligaments. Elastic pressure may be employed for the former, with cotton wool and a flannel bandage, but if any success in the latter be looked for, the most perfect rest of the joint is necessary for several weeks. The movements of flexion and extension must be prevented by a posterior splint or plaster of Paris bandage extending for a considerable distance above and below the joint, so as to maintain complete extension, for any movement of flexion is associated with rotation, which it is most desirable to prevent; lateral leather splints, elastic knee caps, and bandages will not suffice at this time and for this purpose; preferably, the patient should be kept in the recumbent position so that there should be no

jarring of the joint surfaces. But as a rule such rigorous treatment for what appears so trivial an injury is not carried out, and in the majority of cases displacement recurs on future occasions. In such a case the patient may wear some form of knee cap in order to partially restrain the movements of the joint, and he should be instructed how to keep the toes turned inwards, if the internal semi-lunar cartilage is at fault, outwards, if the external, thus lessening the risk of reproducing the luxation.

Operative interference is eminently satisfactory, and as a rule, results support this method of treatment.

Unfortunately in two of this series of cases, suppuration in the joint followed the operation, causing in the one a permanent ankylosis; in the other case where there was a considerable quantity of bloody fluid and two traumatic loose bodies, the movements are now fairly good, flexion to a right angle being possible with further gradual improvement taking place.

In advising operation the surgeon should be to some extent guided by the frequency of the occurrence of displacement, and by the occupation of the patient. The latter is of considerable importance, as in certain occupations, danger to life may arise from sudden locking of the joint, causing the individual to fall in places where there might

be a risk of further injury, as for example in the case of an engine driver or mason. In such cases one would be more inclined to urge operative treatment, if a fair trial be made with a knee-cap and by the turning of the toes inwards or outwards as the case may be, and yet displacement be frequent and a source of annoyance to the patient, then the question of operation should be considered. The operation may be either of stitching the detached portion to the capsule and other fibrous structures covering the head of the tibia, or of removal of that portion. Professor Annandale was the first to carry out the operation of stitching, ten years ago, on November 16th 1883 and the result was a complete success. The choice of operation must depend upon the nature of the lesion found when the joint has been opened into. If the cartilage presents no detachment, but is too freely movable, or if it is detached over a limited area, or even if it be entirely torn away from its anterior attachments, as was the condition in one of Professor Annandale's early cases, replacement by stitching may be carried out.

The operation may be briefly described as follows :-

1. Brit. Med. Journ. Apr. 13th 1885.

An incision about three inches long from the border of the ligamentum patellae and over the line of the joint, divides the skin and fascia superficial to the capsule. All bleeding is arrested and then the capsule is opened by an incision similar in direction, but of less extent, care being taken that this is done above the cartilage, otherwise the attachments of that body to the tibia will be divided, and a wrong impression of the exact state of the joint may be obtained. This incision through the capsule is between the ligamentum patellae and the internal lateral ligament on the inner side, and between the same structure and the external lateral ligament and biceps tendon on the outer side, if the external semi-lunar cartilage is being dealt with, consequently no structure of any importance is divided, the joint is not subsequently weakened, and a good view of the cartilage is obtained. Mr Allingham¹ advocates a vertical incision on the grounds that there is less weakening of the joint and that a better view can be got of its interior. As regards this latter point, experiment does not support his view, and it appears more reasonable to incise in the long axis of the cartilage to be dealt with, than

1. op. cit.

across it; certainly no weakening has followed the transverse incision. The patellar branch of the internal saphenous nerve, is divided by the transverse incision and a feeling of numbness, is complained of by the patient in its distribution, but after a time, improvement takes place. Some small branches of the long saphena vein, may be divided in the posterior part of the incision, but this gives rise to no difficulty. Professor Chiene has kindly informed me of the method adopted by himself, in operating upon the knee joint in such conditions, by a curved incision through the skin and fascia turning a flap backwards, as the limb lies extended on its posterior aspect, and then with transverse incision the capsule is opened in the interval between the bones. The principle which has guided him, is the same as that which has been introduced in opening the skull, namely, to turn back a door of skin tissue before opening into a cavity, so that sound tissue is replaced over the deeper wound.

The detached portion is then held in position by blunt hooks, catgut sutures are passed through it and the fibrous tissues and capsule upon the head of the tibia, their number depending upon the extent of the detachment. Before closing the joint, it is very necessary that in all

cases a thorough exploration should be made so as to eliminate any other source of derangement, which might at the same time be present. In two of these cases loose bodies were also present. The capsule is then stitched with catgut, no drainage being required and the external wound is closed. A posterior splint is applied and the joint kept at rest for six weeks, the patient remaining in bed until the wound is healed, and afterwards, with the limb in plaster, moving about on crutches. At the end of this time passive and active movements are commenced, the possibility of an early return to work being greatly influenced by the attention the patient pays to this, as some of them after leaving the surgeon's hands fail to carry out the steps required, thus unnecessarily protracting the period of stiffness.

In the series of cases under review, nine were dealt with by stitching. This total does not imply that they were the only cases deemed suitable for this method of treatment, many others might have been similarly treated with success, but in the last one, operated upon in 1890, symptoms returned, necessitating a further operation for removal. From consideration of this fact, and seeing that equally good results are got after removal, and further,

*This Page out of
place - should follow
b4*

account of herself; "My knee is quite well, there is no pain or stiffness and I never feel any of the old trouble".

Similar statements are made by the others rendering repetition unnecessary.

Turning next to those cases in which the semi-lunar cartilage is removed, we find that this operation is indicated when that body is almost completely torn from its attachments, being more or less freely movable, and presenting an area of detachment too large to justify the selection of the previous operation, though in this series of 20 cases so treated, these points were not taken into consideration for the reasons above given.

The operation is similar in all its details to that just described, save as regards dealing with the cartilage itself. This is first fixed by means of a blunt hook passed underneath should it be detached from its circumference only, or grasped with forceps if it presents a free extremity, and then with a curved probe-pointed bistoury passed beneath it, the attachments of the detached portion are divided. The operation is completed as before, and the limb is fixed in the extended position upon a posterior splint.

Without doubt, in many of these cases, the period of fixation has been unduly protracted, thus delaying very

that the patient should be able to resume his occupation at an earlier date, excision has been employed exclusively by Professor Annandale during the last three years. With the exception of the above mentioned failure, all the cases of stitching have been most successful. The affected knee has become as strong as the sound one, all the old trouble has disappeared, and the patient's occupation has been resumed without any discomfort being experienced, or any necessity arising for stopping work on account of knee trouble.

C. H. a miner, whose cartilage was stitched in the summer of 1885 writes at this date, June 1893, "My knee never gives me any trouble. I am able to work every day and have no pain."

G. K. a fireman, writing four years after a similar operation says, "I feel neither pain or stiffness, and can bend and work my knee about as well as the other one, and am able for my employment." I had the opportunity of examining this knee a few months ago and could detect no difference between it and the other one. He cycles, and at times, plays football.

C. L. a domestic servant, whose cartilage was stitched six and a half years ago, gives as favourable an

considerably resumption of work. The nature of the operation does not necessitate so long a period of rest as in the former instances. After the wound is healed, usually in a fortnight, the splint may be removed, and an elastic bandage applied to the knee, the patient being then allowed a certain amount of movement in bed, so that at the end of the three weeks he may get up, and endeavour, by rubbing and movement, to regain the perfect use of the limb.

Sufficient time has hardly yet elapsed since the operation in the last four cases to justify any conclusion being drawn as to the final result, but they continue to make satisfactory progress towards the recovery of a useful limb.

Here also, an equally satisfactory prognosis can be given. The old feeling of weakness, and the fear that used to be experienced that the joint might at any moment become "locked", is no longer complained of, and after a time there is nothing to hinder a resumption of the former employment.

G.D. A miner, operated upon three years ago, writes that his knee is quite well and that he is working again as a miner.

M.C. a retortman, an occupation which entails a considerable amount of strain upon the lower limbs, whose

internal semi-lunar cartilage was removed four years before, tells a similar story. He is as able for his work as ever he was, and has complete power of flexion and extension without at any time experiencing pain.

J. C. a cabinetmaker, on whom a similar operation was performed in 1890, writes, "I work without the least difficulty. I play cricket, and golf, and sometimes go long runs on a bicycle without feeling any bad effects."

In order to gain some idea as to how soon after operation a man may return to his work, one or two instances of patients treated more recently may be cited, but here the nature of the occupation must be taken into account, the length of time during which splints have been worn, and the amount of care which the patient gives to massage and movement.

J. P. a miner, operated on in July last was able to resume work two and a half months after the operation and W. M. similarly engaged, after three months, but in both of these men splints were worn for an unnecessarily long period of time and their occupation is essentially one which requires free movement of flexion at the knee; so that one would be entitled to give a more favourable opinion on this point than these two cases indicate.

The results of the two forms of operation are more or less equally balanced, but one would decide in favour of the more radical method of removal, being influenced by the fact of an occasional failure after stitching, and an earlier recovery of the use of the limb after excision.

PART II. LOOSE BODIES, HYPERTROPHIED SYNOVIAL FRINGES,
AND OTHER MORBID CONDITIONS AS TUMOURS.

So far we have studied **Internal Derangement** of the knee joint caused by displacement of the **Semi-lunar Cartilages**, which, with one or two exceptions resulted from injury. They have been classed by themselves, because they form a lesion distinct from any other. If their displacement was the only lesion that could follow injury, a division of the causes producing **Internal Derangement** might be made into **Traumatic** and **Non-traumatic**, i. e. the result of disease, including displacements of the **Semi-lunar Cartilages** under the first, and all other conditions such as are indicated by the title of **Part II** under the second. But without doubt certain **Loose Bodies** may result from injury alone, consequently, while maintaining the classification of the causes of derangement as **traumatic** and **non-traumatic**, which is certainly the best method that can be adopted, the subdivisions would be as follows:--

- I. INJURY. a. Detachment of Semi-lunar cartilages.
 b. Traumatic Loose Bodies.
- II. DISEASE. a. Tubercle.
 b. Arthritis Deformans.
 c. Syphilis.
 d. Spinal Anthropathies, e.g. Charcot's Disease.
 e. Tumours of Synovial Membrane.

Following this classification, the nature of traumatic loose bodies will be first discussed, because owing to their origin from injury they must be considered next to the Semi-lunar Cartilages.

Papers have been written and discussions have been held for and against the traumatic origin of such bodies. That such an origin is possible in a perfectly healthy joint, I shall be able to prove, and to do so shall consider it under certain heads. At the outset it may be stated that that able opponent of traumatic loose bodies, Sir George Humphry, considers that there is already sufficient explanation of the formation of loose bodies from the

that would produce such detachment without at the same-time doing serious damage to the joint itself. As an additional support to Humphry's view I would record a case under the care of Mr Cotterill, where the injury received was of such a nature as to produce a compound fracture of the leg necessitating amputation through the thigh.

On the other hand there is sufficient proof that such a result may be obtained without "serious damage" to the joint, as reported in Sir John Simon's case, where only some "inconsiderable synovitis" supervened upon the injury, and in a case recorded by Mr Teale we read that the joint was much swollen immediately and excessively painful, but that is nothing more than would be expected after a severe wrench of the knee. In reference to this question of visible damage following an injury to the knee, I have seen a case of simple fracture into the joint accompanying other injuries which necessitated amputation through the thigh: there was no swelling or bruising of the joint to indicate any lesion in it, and yet on opening it after the operation, a fracture of the nature of a split between the femoral condyles was found.

I. Simon. Path. Soc. Trans. vol. XV.

processes of synovial membrane which grow into the joint without searching for other and highly improbable modes of origin, but surely such an argument is not conclusive and because there is more frequent origin from that source, it does not exclude the possibility of a less common mode of origin.

I. The Nature of the Injury. It has been argued by Humphry¹ that one can scarcely conceive such an occurrence as a detachment of a piece of bone and cartilage taking place without greater damage to the joint than appears to have been recorded in any case of loose body so formed in the synovial cavity, and that such an accident would be attended with severe shock and contusion of soft parts, ecchymosis, and immediately consecutive pain, inflammation and other trouble, which the sufferer would not quickly recover from, nor easily forget. There is undoubtedly evidence to show that it is difficult to detach a portion of articular cartilage and bone without causing very considerable damage to the adjacent parts as seen from certain experiments made by Burghard² upon the cadaver, where he found it extremely difficult to deliver a blow

1. G.M. Humphry. Journ. Anat. & Phys. vol XXIII.

2. Burghard. Brit. Med. Journal. May. 1892.

Riedel¹ of Jena in a paper on loose cartilages in joints brings forwards evidence to show that separation of articular cartilage and bone directly from injury is not so uncommon, and that such may be caused by an injury of a relatively slight character. At the same time the very fact of a loose body being found after considerable damage and bruising of the joint would be in favour of its origin from that injury which Professor Humphry seeks to deny. Soon after the injury the loose body is detected not as a rule at once, because the effusion into the joint and neglect of careful examination renders this impossible, unless under such circumstances as existed in Tarnier's case where the patient died at once from the effects of his fall. In other cases the bodies were detected at varying, but short periods, from a few days to three weeks and a month. This early detection is of great importance as tending to support detachment directly due to the injury. Previous to that time the patients went about ignorant one may say of the fact that they possessed knee joints, an injury is received there is synovitis and soon a movable body is detected, it is removed and during the

1. Riedel. Centralblatt für Chirurgie. No. 12, 1891.

operation nothing is found to suggest any disease in the joint indicating that the body might have been slowly forming as a pedunculated body or separating by necrosis and had then become detached by the blow; Surely such facts must be given the weight they merit in discussing this question of traumatic origin. Humphry argues and quotes several cases in support of his argument, that some local irritation in the form of a sprain or wrench, occurring frequently in young men and boys of active habits in whom perhaps such an injury is soon forgotten causes the villous outgrowths from the synovial membrane to form in a perfectly healthy joint; they become cartilaginous and perhaps osseous and may remain pedunculated or become detached, and becoming hidden in some recess give little or no trouble and no indication of their presence, until some particular movement or strain or perhaps a blow dislodges the body and it produces the symptoms characteristic of it. The presence of the body is set down to the recent injury, which in reality has done nothing more than bring into evidence what has for long existed. That such undoubtedly occurs will be shewn, when the origin of loose bodies from the synovial membrane is discussed and where the initial cause is disease but it in no way

weakens the argument in favour of direct detachment from trauma.

An important factor in the production of such a lesion distinct from the severity of the injury is the manner in which such blows are administered. In relation to this fact experiment showed that by striking the articular edges obliquely a loose body could be produced, or if the blow was localized and struck with a sharp object.

These points are well demonstrated clinically: in a case of a young lad described by Poulet² and Vaillard the knee³ struck against a heap of sharp flints, and in Mr Jacobson's³ description of a case of traumatic loose body, the blow was produced by a cask weighing 2 cwt. striking the inner side of the knee. In this case, as well as in one recorded by Mr Burghard⁴ the leg was in the position of flexion, at the moment, a matter of some considerable importance, as tending to expose to violence the articular surface of the femur by opening out the joint.

1. Burghard. op. cit.

2. Poulet et Vaillard. Archiv. de Physiologie. vol I. 1885.

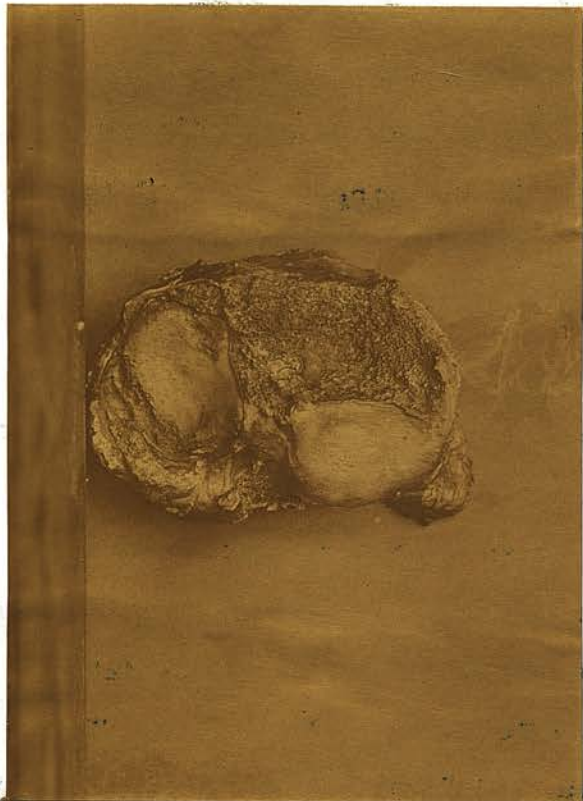
3. Jacobson. Lancet. Aug. 24. 1889.

4. Burghard. op. cit.

2. The bone injured. The bone which is most frequently injured in such an accident is the femur, and this can be readily understood from its size and prominence in the joint, presenting the largest area of cartilage and bone and being consequently more exposed to blows. In 10 authentic cases of traumatic loose bodies in healthy joints which I have been able to collect,⁷ are shown to be derived from the femur; as reported by Tarnier,¹ Simon,² Claudot,³ Jacobson,⁴ Poulet⁵ and Vaillard, Richet,⁶ and Burghard.⁷

In every case the exact area which has been chipped is not stated, but where details are at hand it is evident that the prominent anterior part of the internal condyle is most liable to suffer as would be expected. In Mr Jacobson's case the depressed roughened patch from which the body had evidently come, was situated upon the anterior and

1. Tarnier. Bulletin de la Soc Anat. 1855 p.193.
2. Simon. Path. Soc. Trans. vol.XV.p.206.
3. Claudot. Archiv. de Med.mil.1889.
4. Jacobson. Lancet. Aug.24.1889.
5. Poulet et Vaillard. Archiv,de Physiol.vol I 1885.
6. Richet. Traite pratique d'Anatomie Med. Chir.p 130.
7. Burghard. op.cit.



A.G.T.

Head of Tibia

illustrating Mr. Otterill's case of
traumatic pore body -

encroaching slightly upon the inferior aspect of the convexity of the internal condyle, while Mr Burghard found that the loose body had been chipped off from the extreme inner edge of the articular end of the femur.

In 1, already referred to as under Mr Cotterill's charge the anterior half of the external articular facet of the tibia was denuded of its cartilage, with loss of part of the subjacent bone.

Mr Pridgin Teale¹ found upon the posterior surface of the patella a shallow cavity which exactly corresponded in size and shape with the piece of cartilage and bone removed from the joint, and^{if} we are to look upon a piece of cartilage chipped off from one of the fragments of a fractured patella wired by Mr Watson Cheyne, as a loose body, then, in 2 of the eleven cases, the patella was the bone injured.

3. The nature of the Body. As a rule, the loose body consists of articular cartilage along with a portion of the subjacent bone, but this is not always the case; Tarnier found a portion of the articular cartilage stripped quite cleanly off from the bone beneath, which latter

1. Teale. Brit. Med. Journ. May 26. 1888.

was quite sound ,and reference has already been made to the piece of patellar cartilage in Mr Cheyne's case.

In no instance has a piece of bone only been knocked off, but Mr Burghard found that a piece of the adjacent non-articular bone had been removed along with the articular cartilage.

4. The number of Bodies. In all the cases recorded only one loose body was found and this is just what would be expected. Humphry states that the presence of two loose bodies negatives the possibility of their having been separated from the articular surface, but we are inclined to think that one such body might ,in a wrench of the joint, knock off a portion of articular cartilage and bone and so form a second; but in such a case one must admit some previous disease in the joint, and thus bring another element into the case; on the other hand the first body may be traumatic and if the joint sustain a second injury, it may chip off another portion.

5. The appearance and structure of the bodies. It is upon this question that much of the argument against traumatic loose bodies is based, and it cannot be thoroughly discussed without considering at the same time an equally important point, namely, the condition of the joint surfaces.

a. In favour of trauma: Appearances and structure of the loose body and condition of the joint. In Simon's case, the body is distinctly stated to be a broken off bit of the articular end of the femur, covered on one side with its natural cartilage, and Mr Shattock's report upon its microscopic structure supports this conclusion because he says that the specimen has every character of healthy articular cartilage in the arrangement of its cell groups and matrix, and that there can be no doubt about its being detached from an articular surface.

Mr Jacobson's account is very instructive, because in addition to a loose body covered on one aspect with smooth yellowish white articular cartilage and on the other presenting a bony surface, dotted with minute pits, there was a smaller body still attached but slightly movable and easily separated with the finger nail; this second smaller body did not correspond to the whole of the rough bony surface denuded of cartilage, but when taken along with the first and larger one, the whole deficiency was filled up; the character of the patch upon the internal condyle is in favour of the loss of bone and cartilage from off it, because it is described as being distinctly depressed and roughened and contrasting sharply with the surrounding,

and cartilage detached from the articular surface, so that such an appearance need not necessarily be diagnostic: the cells near the surface are flattened out and lying parallel with it, whereas those in the deeper layers are more spherical and arranged more or less in vertical columns just as they are in articular cartilage.

I have examined a loose body in no way resembling in its naked eye appearance a piece of articular cartilage and bone in order to verify this point. The body was slightly larger than a bean, somewhat flattened and consisted of cartilage completely surrounding an osseous nucleus, the surface of the body being smooth but tuberculated. Unfortunately there is no history attached to it to indicate its origin save that it was removed from a knee joint by Professor Annandale, but it is just such a body as that described by Humphry¹ in which he says the cartilage presents the features of normal articular cartilage. Under the microscope the body is seen to be surrounded by a distinct fibrous covering, here and there sending processes into the deeper parts, and this is covered by a layer of endothelium as determined by the haematoxylin stain.

1. G.M. Humphry. op.cit. p. 494.

smooth cartilage covered surface.

Very similar conditions are described by Mr Teale and Mr Burghard. Mr Cotterill's case already cited, and of which a photograph is shewn, is conclusive. The left knee joint was opened after amputation had been performed through the thigh, and a loose portion of bone covered on one side with articular cartilage escaped. Upon the external articular facet of the tibia and in its posterior half and extending across the non-articular area of the bone in the same region, there was a rough patch excavated to the depth of a quarter of an inch at its deepest part.

It was devoid of cartilage and corresponded to the loose fragment above mentioned.

b. Against trauma. Appearance and structure of the loose body and condition of the joint.

It has already been indicated that Humphry considers the formation of loose bodies from synovial membrane as by far the most frequent mode of origin: that during the time in which they remain unnoticed in the joint either as pedunculated or as loose bodies they may calcify or ossify in the centre, surrounding such a centre there being a layer of cartilage. In structure he says they may present closely the appearance of a portion of bone

The greater mass of the body appears to be composed of cartilage; in this mass the cell spaces in the matrix are very numerous giving a fibrous network appearance to these areas. Here and there are portions of fully formed hyaline cartilage with fewer cell spaces, containing cells dividing in the ordinary way and showing the normal homogeneity of the matrix. There is no arrangement of cells in vertical columns in the deeper parts and in flattened parallel lines superficially as seen in the articular cartilage from the end of a long bone, but the cells are all more or less globular and follow no definite order.

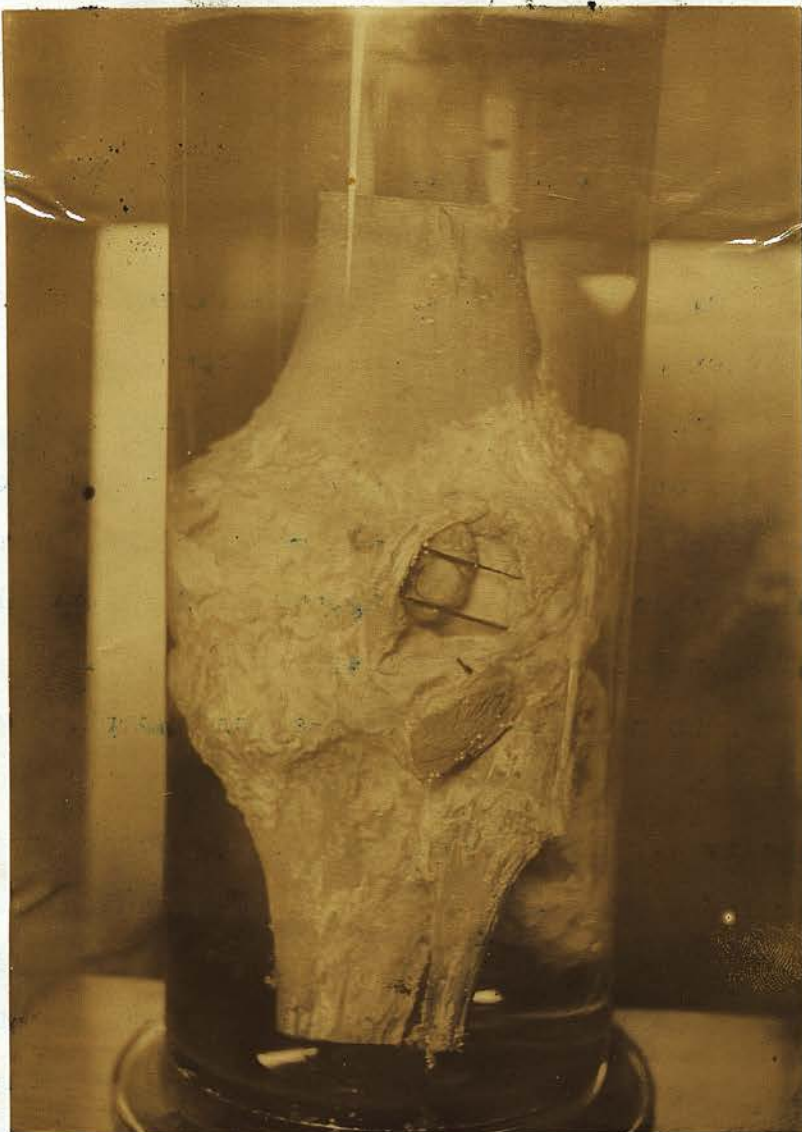It was impossible to say whether the central portion of the body was made up of bone or was merely calcified as it had fallen out in the process of cutting.

In order to explain the presence of cartilage upon one side and bone upon the other, he states that during the long period of repose, one side becomes deprived of cartilage and the bony nucleus laid bare, through contact with and perhaps attrition upon the femur or tibia, and in support of this he describes a specimen in the Pathological Museum at Cambridge, where a subspheroidal or flattened osseous body with cartilaginous margin hangs by a broad peduncle from the synovial membrane into the space between

the patella and femur; the cartilage on both surfaces of this body has disappeared and the osseous centre exposed by attrition against these bones. In another case described and figured by Klein, where there are two bodies each composed of a layer of cartilage and of bone, the cartilaginous covering extends over the smooth edges of the bodies on to their surfaces which are applied to the internal femoral condyle: this extension of the cartilaginous covering in a smooth manner over the edge of the loose body on to its applied surface is due to imperfect denudation of the bone, and he considers that it may be taken as a proof that in any case the loose body has not been separated from the articular surface by direct force nor yet by necrosis.

The presence of a depression or fossa upon the articular surfaces of one of the bones is similarly explained: just as the applied surface of the body becomes rubbed away, so does the articular surface against which it rubs, and the body he says is greater than the cavity in the bone. That loose bodies may become lodged in the knee joint and give rise to no symptoms, all will admit, and a specimen in the Anatomical Museum of the University affords an excellent

1. Klein. Virchow's Archiv. XXIX, 190.



A.L.T.

Os. E. g. 35.

Capule of knee: opened behind showing
bone body caught between it & external
condyle of femur.

illustration of how a loose body may be lodged. Os. E. g. 35. The joint shows signs of arthritis deformans and "the thickened joint capsule opened behind shows a large cartilaginous loose body caught between the posterior aspect of the external condyle and the capsule: The body is about the size and shape of a bean but considerably thicker & nodulated". In such a position it would not have given rise to symptoms. A photograph of this specimen is appended. How long the body had lain there one is unable to state, but there is no evidence of that rubbing away of surfaces that Humphry has described.

I cordially agree with all that he says concerning the formation of loose bodies from synovial membrane and the changes they undergo in the joint, but I do not think he in the least degree disproves the contention that such may be formed by direct detachment from injury in a perfectly healthy joint. Because loose bodies are most frequently formed from synovial membrane is not a sufficient reason that they may not form elsewhere. The specimen of a body consisting of a central bony nucleus and an envelope of cartilage, such a one as those described by him whose side or sides get rubbed down, does not show the arrangement of cells as similar to that in articular cartilage, and he fails to

explain away the sudden appearance of a distinct body almost immediately after an injury, its structure of bone and cartilage, the bony surface rough with no shelving of the cartilage over the edge on to the surface of separation and with an area upon one of the bones of the joint deprived of its articular cartilage, rough and somewhat excavated and corresponding in size exactly to the loose portion. In all probability both conditions may occur and so apparent discrepancies can be explained. Professor Humphry is now less sceptical than he was on this subject and readily admits that such a lesion may occur.

In order to make this subject as complete as possible, a few words must be added in consideration of the possibility of traumatic loose bodies being formed from other sources than bone and cartilage. No case of the kind has come under my own notice, but such have been recorded.

Mr Bowlby describes a specimen of a loose body formed by blood extravasation in the synovial membrane, preserved in St. Bartholomew's Hospital Museum: The patient was a healthy man of 24 years who had severely wrenched his knee while playing football: he described the sensation as of

1. Bowlby. Path. Soc. Trans. vol. XXXIX p. 282.

something being torn in the joint. The injury was followed by acute synovitis and then by chronic effusion in the joint, and on the subsidence of this, four months after the accident, a loose body was distinctly felt. On incision of the joint there was found attached by a pedicle to the synovial membrane a body consisting of two folds of synovial membrane enclosing between them some partially decolorised blood clot. In this description there is nothing to gainsay the probability of such a traumatic origin, but it must be borne in mind that an inflammation accompanying the injury might cause an overgrowth of the synovial fringes and so lead to their separation and formation as loose bodies, and in this way trauma would be the initial cause of such bodies.

II. DERANGEMENT RESULTING FROM DISEASE.

a. Tubercle.

Conditions arising from the presence of tubercle in the joint, apart from the common variety of the disease, the gelatinous degeneration, may give rise to symptoms of internal Derangement. The condition most frequently found is the "loose body", but in addition, pendulous growths or pedunculated bodies from the synovial membrane are formed, giving rise to symptoms, though they may eventually become detached.

The Loose Bodies are formed from different sources and will be considered as follows:--

I. Melon Seed-like Bodies and Masses of Fibrin, these occur along with tubercle of the synovial membrane.

II. Loose Bodies derived from the Synovial Membrane, consisting of the synovial tissues, or formed of fibro cartilage, cartilage or bone and cartilage.

These two groups represent the condition of **Hydrops Articulari Tuberculosum.**

III. Loose Bodies derived from the Articular Surfaces of the bones, consisting of the cartilage and subjacent bone, and separating by quiet necrosis.

I. Melon Seed-like Bodies. These bodies resemble in form as their name indicates, the seeds of a melon and are similar to what are sometimes found in the Sheaths of tendons and bursae. They are white or brownish in colour, usually flat, but may be slightly biconvex, thin and wafer like, and either circular in outline or somewhat tailed. They are usually present in large numbers and most commonly found in the knee. As a rule they are associated with chronic tubercular disease as pointed out by Riedel and it is in relation to this that they are now being studied, but as will be seen presently they are also found in non-tubercular conditions. Their microscopic structure shows them to be made up of masses of clotted fibrin formed from a fibrinous condition from the synovial membrane. The joint usually contains a quantity of fluid. The synovial membrane may be thickened, and in more than one situation these may be distinct fringing with pendulous bodies projecting from it into the cavity of the joint. A good opportunity of studying such a condition was afforded me in the case of R. N. 32 years of age, a miner, who was admitted under

1. Riedel. "Zur Aetiologie der fibrinozen Frem^mund Körper im Knie". Deut. Zeitsch für Chir-, Bd X.

Professor Annandale's care in December 1892. The patient was a strong healthy man, who two years before admission received a severe blow upon the outer side of his right knee, but notwithstanding considerable pain and some lameness, he continued his work. Six months later he again injured the same knee from a fall: the joint became swollen and painful, but he still continued to work until a third injury compelled him to lie up for some days. During the last nine months the joint has remained more or less swollen and has been repeatedly blistered, but the treatment has never been very thorough as he has always remained at his work. On several occasions he had symptoms of loose body.

On admission, the knee joint was found to be uniformly enlarged, there was no discoloration of the skin or any elevation in the temperature of the parts. There was distinct fluctuation. The joint could be moved without pain, and when the hand was laid upon it during movement, a distinct soft creaking was felt and heard, and occasionally there was a louder click. No loose body was felt.

The joint was opened by a curved transverse incision dividing the ligamentum patellae; there was at once a rush of small, white, flat bodies along with some clear synovial fluid from the joint: the different pouches were filled

with these bodies, presenting the appearances of those melon seeds already described. The synovial membrane was thickened throughout and lined here and there in patches with opaque white fibrinous material; pendulous pedunculated bodies of all sizes were attached to the membrane being translucent in character when held up to the light. The synovial membrane on section had the translucent gelatinous appearance of tubercle.

Some of the pendulous bodies were prepared for microscopic examination, being stained as in all the succeeding specimens with double stain, Haematoxylin and Rubine and Orange, and cut in paraffin blocks. The sections showed a core of tubercular tissue with well formed giant cell systems lying in a vascular fibrous tissue matrix, while investing the fringe was a layer of coagulated fibrin.

The loose bodies which were the melon seeds already described, consisted of fibrin entangling in its meshes a large number of leucocytes and some red blood corpuscles, but, in addition to this, definite capillaries containing blood could be demonstrated.

In order to test the similarity in structure between these and similar bodies found in tendon sheaths, microscopic sections were made of some found in a case of

compound palmar ganglion in a man 45 years of age who had suffered from the condition for nearly fifteen months; these bodies also consisted of coagulated fibrin, but they possessed in addition some definite structure in the form of a covering consisting of a layer of cells, while in the substance of the body, here and there were clusters of cells: these bodies are also looked upon as being usually tubercular in origin.

Masses of Coagulated Fibrin are found however as loose bodies in tubercular joints in no way resembling in their naked eye appearance the melon seeds just described, and yet from their microscopic character they must be classed in this group. Their appearance and structure are well brought out in two cases of tubercular disease of the knee recently under Mr Annandale's care.

Caroline Ross. The first was that of a girl, 5 years of age, who first came under treatment with an Enlarged bursa patellae, which was opened and scraped. The caseous debris removed revealed the presence of tubercle. Nearly a month later the knee joint was excised for marked synovial degeneration, a vertical section of the patella showing a caseating focus in its centre, but towards its superficial aspect. A smooth irregular

shaped body about the size of a walnut slipped out of the joint during the operation. It was somewhat fatty in appearance and consistence, thicker at one end than the other and somewhat constricted at parts. Under the microscope nothing of any definite structure was visible, the whole consisting of a mass of fibrin entangling in its meshes, red blood corpuscles.

The second case was that of a man G.S. 33 years of age, who had suffered from swelling and pain in the right knee following an injury seven months previous to his admission on March 2nd 1894. The joint presented the characters of a white swelling as it was proved to be when opened for the purpose of excision and a loose body, similar in appearance and consistence to the previous one, escaped. It had the same smooth surface of a similar fatty consistence and white in colour, but considerably smaller and thinner. On section it was found to be of similar structure to the one just described, but it was more fibrinous and less cellular, that is, there were fewer red blood corpuscles entangled in it and consequently it appeared of a firmer consistence. The haematoxylin stain

indicated a layer of cells upon the surface of the body, which was torn away in part: here and there were scattered leucocytes especially towards the periphery.

Such masses of coagulated fibrin are similar to those which are found in tubercular pleurisy, and appear to be associated in the joint with that form of tubercle which is characterised by the fringed and folded appearance of the synovial membrane, that form which sometimes closely simulates arthritis deformans: they are rarely found where the tubercle takes the form of the gelatinous or pulpy degeneration. It is probable I think, that the melon seed character of so many of these bodies is due to the movements of the joint: the fibrin gets as it were churned up and the bodies are rubbed into the shapes that they assume. So also in the tendon sheaths, movement is an all important factor. The masses do not take the melon seed shape in the pleura, because that necessary movement is absent. A study of the history of the cases just recorded supports this view. R.N. was able to move his joint more or less freely up to the date of his admission, whereas C.R. and G.S., in whom the fibrin was found as a mass, were unable to do so.

II. Loose bodies derived from the synovial membrane consisting of the synovial tissues, or containing fibro cartilage or bone and cartilage.

In addition to the Melon seed bodies, other loose bodies associated with the presence of tubercle in joints have been found. Several of them may be present in one joint and they may attain a considerable size; they consist of fully developed tissue and are formed from the synovial membrane becoming detached either in the normal movements of the joint, or from some slight twist or wrench. Before they become so separated they may give rise to symptoms of derangement so that they will first be discussed as pedunculated bodies, and then as loose bodies. This is necessary as the clinical aspects differ, while pathologically the former is merely an earlier stage of the second.

I have had no opportunity of studying the gradual formation of these bodies, but owe my description of the same to the writings of Kölliker,¹ Rokitansky² and Alexis Thomson³.

1. Kölliker, Human Histology vol. I. Syd. Soc.

2. Rokitansky, Path. Anat. vol. III. Syd. Soc.

3. Thomson, Tuberculosis of Bones and Joints. Lab. Rep. Roy. Coll. Phys. Edin. vol. II.

The first named describes a series of vascular processes, or folds of the synovial membranes (*plicae synoviales*) which exist in almost every joint and are placed close to the junction of the synovial membrane with the cartilage. In addition to the blood vessels, fibrous connective tissue and the usual epithelium of the synovial membrane, these processes he says, contain sometimes fat cells and isolated cartilage cells. I have examined the synovial membrane from two specimens of the healthy human knee joint, and one from the ox, but I have failed to find these cartilage cells, but do not wish to give this negative fact undue prominence owing to the small number of specimens examined: further, these cells must be looked upon as being merely "potential", connective tissue cells, requiring an irritant to render them active. At the edge of these vascular processes are found minute, conical, membranous processes often resembling the stems of a cactus, which frequently contain vessels, but mostly consist merely of an axis of indistinct fibrous connective tissue, with occasional cartilage cells. From these non-vascular processes Kólliker considers the loose bodies are formed.

When the tubercular poison has entered the synovial tissues, inflammation ensues with a consequent proliferation of the various elements that exist there, the so-called

cartilage cells taking their share, so that these processes become thickened and form outgrowths in the cavity of the joint, becoming in the course of time detached, the stalk giving way in the movements of the joint.

On the other hand, the process of their formation may be as follows:--the inflammation of the synovial membrane which results from the introduction of the tubercle bacillus is followed by an effusion into the joint, and a deposit of fibrinous lymph on the surface of the membrane: organisation follows so that the superficial layer of the membrane and the lymph become converted into a very vascular granulation tissue containing many tubercular granulations. As a result of these changes the synovial membrane becomes thickened in parts and processes are thus formed; further development may take place in them, the connective tissue cells forming cartilage or bone. These may become detached in the movements of the joint.

An excellent illustration of the condition before detachment came under treatment in Dr P. H. MacLaren's wards in the summer of 1893, and I am indebted to him for the privilege of examining the patient and the bodies removed from the joint.

J.S. 34 years of age, a shoemaker, and a native of Orkney, had been troubled with his right knee for 12 years: he had an attack of pain in it not started by any injury, but following "influenza": this lasted for some days, and was especially severe when starting to walk after resting. Since that time he has been liable to attacks of pain, when his foot slips or when his toes knock against a stone: the pain is sudden and severe necessitating his sitting down, and he cannot always extend the limb fully: after this the knee swells and remains swollen for a few days. This condition would come on once a month, but sometimes oftener, and during the last few months the swelling of the joint has never altogether disappeared. The patient has complained of rheumatic pains in different parts of the body and has suffered both from bronchitis and pleurisy. An examination of the lungs and kidneys revealed nothing abnormal.

At the time of admission, the joint was swollen and fluid could be readily detected, there was no discoloration of the skin and the appearance of the joint in no way suggested white swelling. There was pain in the joint, worse on movement and also upon pressure

over the outer part. A distinct creaking sensation was felt on laying the hand upon the knee during movement and upon its inner aspect, but above the position of the internal semi-lunar cartilage there could be felt a small body movable, and at times disappearing from the touch, it was of firm consistence and about the size of an almond; the patient was able to find this himself on moving the joint about, and sometimes he could feel a second body. The movements of the knee were limited probably owing to the swelling.

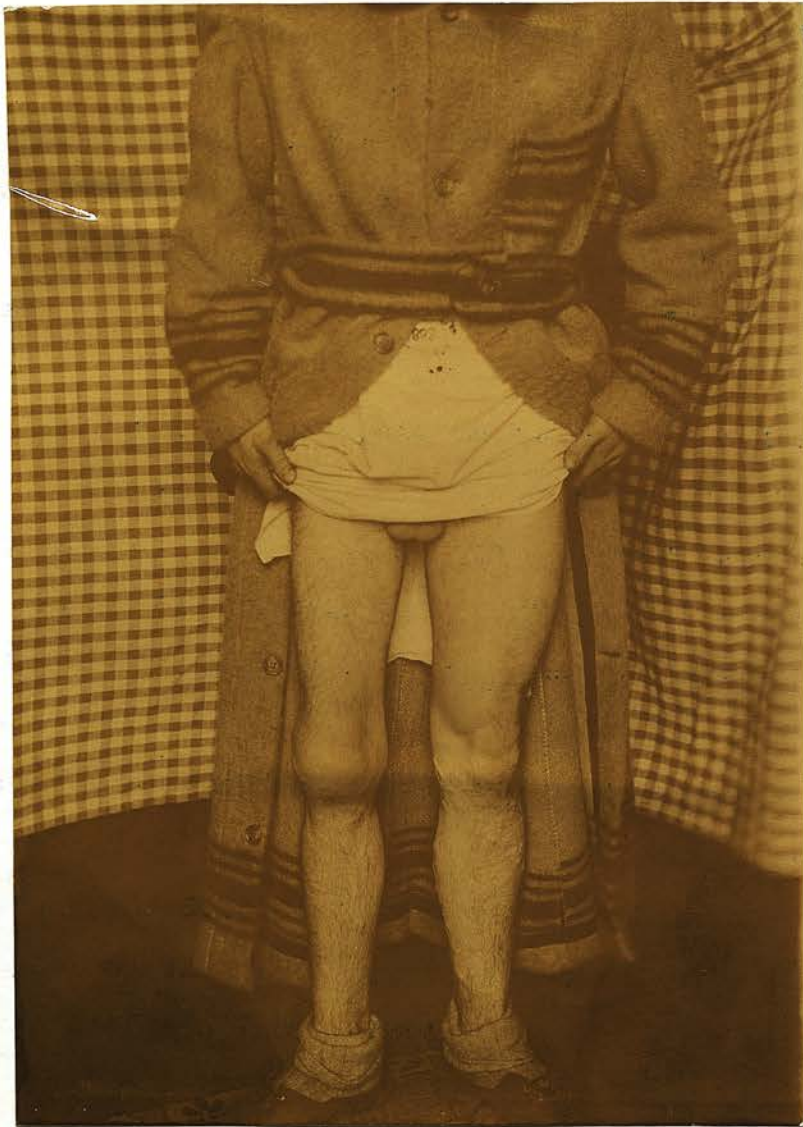After the swelling had subsided under rest, the joint was opened by a transverse incision upon its inner aspect. The large body above mentioned and five smaller ones were removed from the synovial membrane to a limited area of which they were attached on the inner side of the joint; they were pedunculated bodies varying in size from a pea to an almond. Microscopic examination reveals upon the free surface of the bodies a layer of fibrin similar to that found in the melon seeds with leucocytes scattered throughout it. The body itself is made up of the elements of synovial membrane, fibrous tissue cells, and numerous blood vessels, while scattered throughout it are a number of giant cell systems indicating the presence of tubercle.

There is no evidence of cartilage or osseous tissue, The joint was closed, the wound healed without complication and the patient left hospital six weeks later.

The symptoms here resembled somewhat those associated with loose bodies, but the fact that the body was always felt at one spot and did not appear at different parts of the joint, suggested its being fixed to some extent. The absence of any injury, and the detection of the body above the position of the internal semi-lunar cartilage served to exclude that structure as the one at fault.

Another case of a similar nature admitted under Mr Annandale's care strongly suggests a tubercular origin, though the microscope has failed to give any positive information upon this point.

R.G. 24 years of age, a plumber by trade, complained of a chronic swelling of the right knee joint. He has had no other affection, nor has any other joint given him trouble. His father died of Bright's disease, and one brother, patient states suffers from bronchitis. His employment necessitates a considerable amount of kneeling. Four years ago, in December 1889, the right knee became a little stiff and painful, especially upon the inner side, and soon began to swell slightly: but these symptoms were not marked and for



A.C.T.

R.P.
Hydrops Articularis of Right Knee & wasting
of Thigh & leg.

twelve months he was able to continue his work: at first the joint was always stiffer in the morning, but towards the end of that time it was more painful at night. These symptoms now became more aggravated forcing him to discontinue his work, when he was treated with blisters and a splint, so that some improvement followed, and he again worked, undertaking a light job.

One and a half years ago, he fell and twisted his right knee. After this accident he noticed a small body about the size of the end of his little finger, on the outer side of the joint in the interval between the bones: this would move out and in: when walking it would sometimes lock the joint causing him to stop and push it in before he could resume his walk: on these occasions the joint became more swollen: this body always seems to have appeared in the same place. He was now in hospital for four months with the joint strapped with sticking plaster and upon a splint. Since that time, one year ago, it has never locked, but since then he has taken no active exercise and done very little work.

When admitted on December 29, 1893 the right thigh and leg were found considerably wasted; the right knee was more or less uniformly swollen: complete extension

was possible, but not full flexion, and on movement distinct creaking could be felt and heard suggesting fringing. The joint could be handled without pain, but where the body was said to have appeared, there was pain on pressure, and an edge which appeared to be a prominent external semi-lunar cartilage could be felt. Much of the swelling having disappeared under rest, a transverse incision was made over the outer aspect of the joint. A small quantity of fluid escaped. The external semi-lunar cartilage was normally placed but on introducing the finger, some fringed processes were detected upon the synovial membrane in the outer part of the joint; these were removed; they were less developed than in the previous case. Under the microscope, the portion of fringe which was cut and stained showed nothing but blood clot, some of it recent, some of it old. There was no evidence of tubercle.

The wound healed by 1st Intention and the patient was discharged to the Convalescent Home with an elastic bandage upon the knee. On March 23rd almost two months after the operation the joint is still very much swollen and the membrane distinctly thickened

and does not appear to have benefited from the operation. He was ordered a Thomas' knee splint. In this case the absence of signs of tubercle in the fringes does not warrant the exclusion of this disease.

The chronic character of the complaint, the absence of inflammation and the slow development of the effusion subsiding under rest, only again to recur, are in favour of the tubercular origin of these bodies giving rise to Internal Derangement, just as in the case already detailed. They both serve to bring out a similarity between the symptoms they occasion, and those which are produced by actually detached bodies: pain, often sudden in its character, inability at the same-time to fully extend the limb, followed by effusion into the joint: they differ in the fact that when a body is felt, it is usually in a limited area and in that area only, though there may be exception to this latter point if these bodies are numerous, but they do not appear at different parts of the joint and cannot be worked round the knee by manipulation as in the case of a loose body.

I am indebted to Mr Thomson for the examination of a detached body derived in this way from the synovial membrane in a case of tubercular disease of the knee.

The patient was a woman, forty two years of age, who had slowly developed symptoms in connection with her right knee accompanied latterly by the presence of loose bodies. The joint was incised and a number of loose bodies varying in size from a pea to a hazel nut escaped: these bodies were tough and fibrous in consistence and of irregular shape; under the microscope one recognises a vascular connective tissue forming the basis of the body, while lying in this, here and there, are nodules of hyaline cartilage and bone. Owing to the death of the patient a few weeks later an opportunity was afforded of examining the synovial membrane and bones both of which presented all the appearances of a gross tubercular lesion.

III. Loose Bodies derived from the articular surfaces of bones consisting of the cartilage and subjacent bone separating by quiet necrosis.

The term "quiet necrosis" was employed by Sir James Paget to describe a condition of necrosis in which the dead bone exfoliated without the usual attendant suppuration and other signs of destructive inflammation. His attention was drawn to this point in a case of necrosis of a portion of the shaft of the femur where the sequestrum lay under perfectly healthy soft parts, in a small hollow in the wall of the femur and covered by thickened periosteum: there had been no severer inflammation than that which produced the thickened periosteum. In 1870 he instances the formation of a loose body in the knee by a similar process.

The patient was a lad of 16, athletic and thoroughly healthy and had had many blows and sprains of the knee, but could not refer to any as a cause of special injury. For a year he had nearly all the signs of a loose body. This was excised. It resembled a piece of articular cartilage and bone from one of the

1. Paget. St. Bart's. Hosp. Rep. vol. VI. 1870.

femoral condyles, one surface being smooth and convex, the other concave and rough with a small piece of prominent bone upon it: its borders were smoothly rounded off. Microscopically, it presented all these characters of articular cartilage already described. It did not resemble those fragments of condyle which are sometimes broken off in violent fractures of the femur, and there was no history of any special injury.

Sir James Paget explains the origin of this body by this process of quiet necrosis following some slight sprain previously complained of, and he considers that cartilage is a tissue in which such a process might be most expected, because it is without blood vessels: further, the loose body so formed is detected some weeks after the injury and a corresponding bare area is found upon the femur. Before the publication of this case by Paget, the late Mr Teale¹ of Leeds had already suggested such an origin of certain loose bodies, and his prior claim is courteously acknowledged by Sir James Paget, who had not seen his paper upon this subject before writing his own. In Teale's case, the patient, a brewer, accidentally let a cask fall against

1. Teale. Med. Chir. Trans. vol. XXXIX.

his right knee: pain followed and he was unable to work for 3 weeks, but was subsequently able to continue his employment for twelve months, when he became suddenly lame, and for the first time felt a loose body in the joint. This was removed and presented the appearance of a piece of articular cartilage and bone. The patient died soon after the operation, and on the under surface of the inner condyle of the femur, a depression was found with a rough surface of bone at its base, into which the loose body accurately fitted and the continuity of the articular surface was perfectly restored. This he suggested as an example of slow exfoliation extending through a period of about 12 months.

Other examples bearing upon this mode of origin are cited by Mr Howard Marsh¹ but it is unnecessary to multiply them here.

That it is quite possible for bone to separate without much structural trace of its having done so has been amply proved by the case of necrosis of the femur which first directed Paget's attention to the condition and which has just been referred to, and also by the case

1. Howard Marsh. Brit. Med. Jour. Ap. 14th. 1888.

described by Mr Marrant Baker where the whole shaft of the femur necrosed without any further indication of the process than was shown by the presence of the thickened periosteum, and further, a central necrosis of the radius occurring without suppuration in a boy of 15 years of age was shown by Mr Watson Cheyne to the Pathological Society of London in April 1890.

Whether such a process ever takes place in a perfectly healthy joint is a matter of considerable doubt. Sir James Paget's case certainly supports the view that it may do so as far as the history goes. Mr Cheyne is of opinion that some of the cases described as quiet necrosis, were, in all probability, instances of tubercular necrosis, and the following case which I have had an opportunity of studying, may serve to throw some light upon this question, and will in consequence be given in some detail.

T.S. 20 years of age, an iron dresser in a foundry, was admitted into Ward IX of the Royal Infirmary under the care of Mr Alexis Thomson. The patient was thin and unhealthy looking, but an examination of his internal organs revealed nothing abnormal. His family history indicated no tubercular predisposition so far as questioning was able to elicit information.

A week before his admission, while running and jostling down a road, he fell, and in doing so twisted his right leg. On rising he found the leg bent so that he could not straighten it: he limped home, considerable swelling of the knee joint and pain supervened, necessitating his resting. On the following day he saw a doctor, who straightened the limb. Two days after the accident he attempted walking, but on commencing to do so he felt something crack and could both see and feel a small round swelling on the outer side of the joint, which he was himself able to shove in again. On admission a week later on April 14th 1893, there was found to be considerable swelling of the right knee joint and fluctuation was distinct: there was pain on movement of the joint and upon pressure over the head of the tibia externally in the interval between the bones and a distinct ridge lying horizontally in this position felt to the touch like the outer margin of a semi-lunar cartilage: nothing else could be felt. The diagnosis made was that of displaced external semi-lunar cartilage and upon opening the joint such was found to be the case as already described in Group II, Section B in the chapter upon semi-

lunar cartilages. A considerable quantity of bloody fluid escaped from the joint, and on exploring the cavity with the finger a loose body was detected and removed: this consisted of cartilage and bone, to all appearances resembling a piece of detached articular cartilage with the subjacent bone. One surface entirely composed of cartilage was convex and traversed by a series of small cracks, which gave the appearance as if the body had been forcibly bent during some movements of the joint: these cracks lay more or less parallel to each other across the long axis of the body, and extended through half the thickness of the cartilage: upon the other aspect was a small piece of bone, the surface of which was rough. The rest of this attached surface consisted of cartilage indicating a larger area of cartilage separation than of bone. The edges of the body were vertical, there was no beveling as described in Mr Teale's case.

A second larger body was also found of a similar nature to the first, but this was not bent in the same way nor was the cartilaginous surface fissured, though at one end there was some slight attempt at cracking. On the deep surface of the patella the finger could

feel an area of bare bone. No other abnormal condition was detected. These bodies were looked upon at this time as pieces of bone and cartilage detached directly by the injury a week previously. The joint was closed and the external wound sutured.

A section of the bodies showed the cartilage to be of the thickness of normal articular cartilage upon a patella. A section of a healthy patella was made and the thickest part of it was 3 mms, while upon the loose body it measured three and a half ms, at a similar spot; in fact while allowing for some variation in every patella the thickness of the cartilage emphasised the probability of its being articular.

The wound became septic requiring reopening and drainage of the joint. Improvement was slow but gradual and the patient left hospital on June 29th, with a small sinus on the outer aspect of the joint, and some movement.

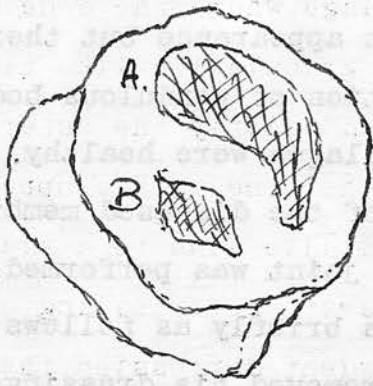
On communicating with the patient in October I learnt that movement was better, but there was some pain in the joint and the sinus had not yet closed.

On January 2nd 1894, the patient was readmitted: the whole joint was swollen and somewhat globular in

outline, and in appearance resembled a white swelling: the sinus was discharging a thin watery, yellowish fluid, and the sore had an unhealthy tubercular appearance. The leg could be bent to about a right angle without pain; there was no starting pain at night: the joint had a soft, doughy, yet fluctuating feel, and some soft creaking could be felt on moving it: there was some pain experienced on firm pressure: on January 12th, the joint was opened by a transverse incision through the ligamentum patellae, the patella was turned up and removed: the whole synovial membrane was thickened and gelatinous in appearance but there was no evidence of the formation of pendulous bodies from it, the articular cartilages were healthy. In order to get rid of the whole of the diseased membrane a complete excision of the joint was performed. The after history of the case is briefly as follows: the patient became delirious and removed his dressings and splints: the wound again became septic so that amputation through the thigh was deemed necessary, the patient at this time being distinctly maniacal and remaining so until his death upon February 12th.

Post-mortem examination revealed absolutely

outline and its appearance resembled a white swelling.
 the sinus was discharging a thin watery yellowish
 fluid and the sore had an unhealthy character ap-
 pearance. The leg could be bent to about a right angle
 without pain; there was no starting pain at night;
 the joint had a soft, boggy feel, the knee-joint and
 some soft creaking could be felt on moving it; there
 was some pain experienced on firm pressure on January
 18th, the joint was opened by a transverse incision
 through the ligamentum patellae, the patella was turned
 up and removed; the whole synovial membrane was thick-



Under surface of Patella
 showing areas devoid of
 Cartilage.

ened and gelatinous in appearance. In order to
 evidence of the formation of the articular cartilage from
 it, the articular cartilage was removed. The articular
 get rid of the whole piece excision of the
 history of the case is given as follows: The patient
 became delirious and removed his dressings and splints;
 the wound was exposed and the patient
 through the joint. The patient
 at this time being distressed and remaining
 so until his death upon February 17th.
 Post-mortem examination revealed absolutely

nothing to account for death, there being no signs of a general tuberculosis or indeed of tubercle in any part of the body, nor was there any evidence of septicaemia or pyaemia. The cause of death was probably acute mania.

The Patella. The articular surface of this bone was almost completely hidden by the overhanging synovial membrane, but after dissection, the following appearances were observed. The articular cartilage that existed was quite healthy, but there were two areas devoid of cartilage, where the bone was exposed and covered by a soft granulation like tissue. The larger area A. occupied chiefly the outer part of the articular surface of the bone at its upper part but extending across the middle line to a small extent; this surface was broadest above, tailing at the lower part; there was no evident depression, the bare surface being almost level with that of the surrounding cartilaginous surface: the inflammatory process which had ensued in the joint was sufficient to alter its condition leading to its partial repair. This was the area felt with the finger at the first operation, and in size corresponded to both the loose bodies removed.

A second smaller area B. occupied the lower part of the inner articular surface. This appeared more recent in origin and was distinctly excavated, its surface being rough and pitted, with a well marked raised edge, especially upon the inner side. The portion of bone and cartilage, which in all probability had exfoliated from this surface, must have been overlooked, in size it did not correspond to either of the two bodies above mentioned.

A series of vertical sections made through the thickness of the bone, revealed a large area of sclerosis below the floor of the bare patches sufficient in itself to indicate the presence of a slow inflammatory process. Microscopic examination of decalcified portions of the larger of the two bodies establishes beyond question the origin of the bodies by necrosis, the arrangement of the various elements being similar to that found in articular cartilage and bone, whilst the changes from the normal arrangement are evidences of chronic inflammatory process having existed. The cartilage cells towards the free surface are flattened, lie in rows close together and are more or less parallel with the surface. In its deeper parts on the

other hand, the cells are most elongated with their longer diameters at right angles to the surface, and lying in nearly vertical parallel lines. The bone trabeculae beneath are thicker than they are in the healthy patella and their outlines present a rugged appearance: owing to the absence of the soft tissues in the bone substance the presence of tubercular elements cannot be observed.

The Synovial Membrane showed large numbers of well formed giant cell systems proving that the condition was a tubercular one.

The etiology of the case is probably as follows: the patella had become the seat of tubercle and as a result of this, slow exfoliation of one or more portions of bone had commenced by the process of tubercular quiet necrosis. The injury which tore the attachments of the external semi-lunar cartilage, was sufficient to cause detachment of the sequestrum or sequestra so that they formed the loose bodies found at the operation a week later. Owing to the septic condition then set up, the disease became more rapid, the whole of the synovial membrane soon becoming infected. The naked eye and microscopic appearance of the bodies

prove them to be pieces of articular cartilage and the subjacent bone, and the bare area upon the patella with the sclerosis beneath demonstrates their origin from that bone in which a chronic inflammatory process must have existed for some considerable time. Whether the patella was injured at an earlier date and in this way the disease was started, there is no evidence to show.

At the first operation, when the bodies were removed, they were looked upon as purely traumatic in origin, that the same injury which had torn the attachments of the external semi-lunar cartilage had also directly separated these fragments from the patella, and as there was no visible or palpable evidence of disease present, they were regarded as traumatic loose bodies. But owing to the rapid development of tubercle which followed, an opportunity has been given within a year of disproving this idea and substantiating the slow formation of sequestra, tubercular in their origin and only becoming detached as loose bodies from the severity of the injury applied to the joint. Doubtless on more than one occasion a wrong impression has been obtained in regard to this matter, and a body

matter is complicated; some of the cases of loose

which was considered to be traumatic in origin and in a healthy joint has in reality become loose perhaps from some strain or blow, or natural movement merely completing a process of exfoliation which has been in progress prior to the date of the injury. This point is of very considerable practical importance, as influencing the prognosis: if a body consisting of bone and cartilage presenting all the characters already described, be removed from the joint after an injury more or less severe and with a roughened patch to correspond upon one of the articular surfaces, then prognosis would be favourable, the injury alone accounting for the condition. On the other hand if a similar body is found with no such injury to account for its origin appearing, perhaps after a slight wrench or only after a natural movement of the joint, then the probability of its origin by the process of tubercular quiet necrosis must not be lost sight of and the subsequent course of that case should be carefully watched: the case next to be described is probably one of this kind, that just detailed above however, showed that the severe injury followed by a loose body does not exclude disease, and hence the matter is complicated: some of the cases of loose

bodies regarded as cases due to direct trauma in a healthy joint may not have been such after all.

The second case at the present time under Professor Annandale's care in Ward VIII, of the Royal Infirmary appears to be another example of the formation of a loose body in a similar way, but here the facts are not so complete, as sufficient time has not yet elapsed to enable one to note its future progress either towards cure or to more evident manifestation of the disease that is present.

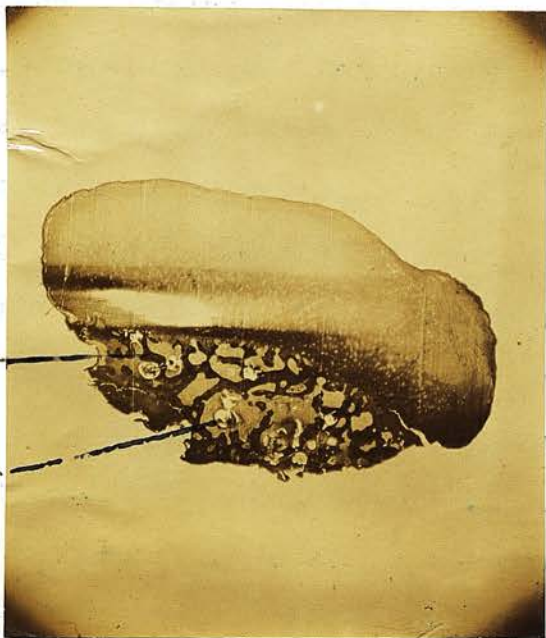B.B. 22 years of age, a domestic servant was admitted upon February 25th, 1884, Her family history so far as can be ascertained is good and the patient herself has always enjoyed good health, and there are no signs of tubercle or rheumatism. She came complaining of a loose body in the left knee joint, previous to the appearance of which she had never had any trouble in either knee. Nine weeks before admission while stooping down to the ground for the purpose of lifting something from it, she felt a crack in the left knee joint and during the act of rising she felt a similar crack accompanied by intense pain in the joint and within a few minutes considerable swelling came on: she was unable to straighten her leg partly from pain,

partly from a feeling of something in the joint preventing it being done. Three weeks after this, while bending her knee, she suddenly discovered a small body in the joint which slipped very easily away from under the fingers which she has several times since felt in different parts of the joint and which has on more than one occasion caused locking. No history of an injury was to be obtained.

On admission there was some slight effusion into the joint and on one occasion the body was detected upon the inner side of the patella, but it rapidly slipped away. The joint was opened by a small vertical incision beyond the outer border of the patella, the finger introduced and after a little search the body was caught and extracted. No second body could be detected, the joint appeared otherwise healthy and as through so small an incision a complete examination of the articular surfaces could not be made, it was impossible to say whether any area devoid of cartilage existed. No synovial fringing was felt.

The loose body presented the following characters:--about the size of a bean somewhat triangular in shape, broader at one end and tapering towards the

other, it measured 1 and 7 tenths m.m. in length, 1 m.m. in breadth at its broad extremity, and one half m.m. in thickness. It consisted of bone and cartilage; the cartilaginous surface was smooth and somewhat convex with a fine groove running along it, as if the result of nipping during some movement of the joint. All round the body the cartilage was continuous on to the sides, while at the broad extremity and upon one of the sides, it passed round on to the other surface for a short distance with a somewhat bevelled appearance: the narrow extremity consisted entirely of cartilage. The other surface with the exceptions above stated, consisted of bone: this was not pitted but smooth, appearing as if covered with a layer of fibrous tissue: the bony surface measured 1 m.m. in length and 4 fifths m.m. in breadth. The cartilaginous tapering extremity tended to peel easily off from the bone, and there was a slight indication of fraying. On section through the middle of the body, the naked eye appearance was identical with that seen on making a section of a normal patella or the end of a femur: the articular cartilage covering one aspect of the bone and directly continuous with it.



Trabecula eaten through,
granular debris beside
it -
debris -

B.B
Micro-Photograph of bone body
Consisting of articular cartilage
and bone -

Microscopic examination corroborates one's opinion of the origin of this body, as in the previous case from the articular end of one of the bones, and it is a very pretty illustration of such as the accompanying micro-photograph shows. The cartilage is hyaline cartilage and does not exceed in thickness that of normal articular cartilage, and on its surface there is a thickish layer of fibrous tissue. The bone trabeculae are thick: at one spot there can be seen a trabecula which appears to have been eaten through: the gap between the ends is filled up with a broken down granular looking substance, which extends into the spaces on either side: no evidence of tubercle can be detected in this material, but it presents a very different appearance to what exists in the other cavities. In two other situations in the same section the bony trabeculae are also broken down and the same debris lies in their neighbourhood. Such appearances are evidences of the presence of disease.

In discussing the possibility of the separation of articular cartilage and bone by quiet necrosis, Humphry lays some stress upon the extension of the cartilage over the rounded edge of the body upon the circumference of

the bony surface, that surface which he calls the applied surface, or one that has been in contact with one of the bones of the joint. He considers that such a fracture renders a derivation from the articular surface very improbable: the cause of it is the imperfect denudation of the bone by attrition. The microscope proves both these specimens just described to be pieces of articular cartilage and bone, the second one has the condition of the edges that is described by Humphry. This condition I believe to be due to less bone being separated than cartilage. The smooth appearance of the bony surface can be accounted for by the movements of the sequestrum in the joint after its separation in this case, nine weeks before its removal, thus contrasting with that of the previous case, where the bony surface was rough, but which had only existed as a loose body for a week.

Sir George Humphry considers that it requires rather more evidence than is yet to hand to prove that, in an otherwise healthy joint, a portion of bone and cartilage presenting to the naked eye and under the microscope quite a natural appearance, has been the seat of necrosis, and has in consequence been separated: surely he says the necrosis however quiet must leave some structural traces of the

process by which that death was brought about, and which attended upon it. After studying the case of T.S. and regarding it as a proof of the assertion that quiet necrosis may be a tubercular process I am inclined to agree with Humphry when he states that evidence is necessary to prove the occurrence of this process in an otherwise healthy joint. In the case of T.S. the joint was not healthy, and there was structural evidence of the death in the sclerosed patella, and the thickened trabeculae, and in the cases of this kind where quiet necrosis has been suggested as the origin of these bodies, the description is deficient on account of the absence of a thorough examination of all the parts involved. The after history of all such cases should be closely followed, as a careful note of what results would make a valuable addition to our knowledge of this subject.

b. Arthritis Deformans.

The pathological condition now to be described is perhaps best known as arthritis deformans: other terms are employed when the same condition is referred to and in order to avoid confusion they may be mentioned, rheumatoid arthritis, arthritis, chronic rheumatic arthritis and rheumatic gout.

It is not the purpose of this Thesis to enter into the etiology of this disease any more than it was in the case of tubercle, but as by far the larger number of the cases of loose body appears to occur where arthritis deformans is present, as other symptoms indicate, the condition will be studied as it bears upon the production of internal derangement. Here also, as in tubercle, we find that a similar grouping of the different lesions can be made, these lesions being loose bodies and hypertrophied synovial fringes.

The **Loose Bodies** are divided into three groups:--

- I. Melon seed-like Bodies and Masses of Coagulated Fibrin. These are associated with hypertrophy of the synovial membrane.
- II. Loose Bodies derived from the Synovial Membrane consisting of fully formed tissues as cartilage and bone or both.

III. Loose Bodies derived from the articular ends of the bones, being detached ecchondroses and osteophytes.

I. Melon Seed-like Bodies. I have not been able to find any account of these melon seeds filling a joint in the way that they have been described in tubercle, indeed any reference to them as actual loose bodies has not been obtained. Dr Robert Adams¹ quotes from Mr Herbert Mayo² and Rokitansky³ upon this subject, both of whom found the synovial membrane covered with innumerable little processes, something like melon seeds, pendulous into the cavity of the joint; they resembled those seeds, in shape and colour, some larger others smaller. It is quite conceivable that many of these may become detached in the movements of the joint. They are described by Rokitansky as having a fibrous of fibroid texture, but nothing of a more definite nature is stated. That masses of coagulated fibrin may occur in this disease as loose bodies is shown to be the case from

-
1. Adams. On Rheumatic Gout. second edition.
 2. Herbert Mayo. Outlines of Pathology. 1836. p.105.
 3. Rokitansky. Path. Anat. Syd. Soc. Trans. vol. III. p.289.

Allan

the examination of a body removed from a knee joint by Mr Alexis Thomson in April 1893. The condition of the knee joint will be referred to presently as an example of the hypertrophied synovial fringes. The body which was removed at the operation was a soft yellowish green mass, disc shaped and about an inch in diameter, resembling closely a piece of nummular sputum with a smooth, shining surface. Microscopic examination revealed a mass of fibrin entangling in it a large number of cells resembling leucocytes to a far greater extent than what was seen in similar bodies in the tubercular joints, in parts indeed it was packed with them. It was probably detached from the fringes as the same material was to be found upon their surface. From the absence of information in the literature consulted upon this subject, it is evident that this variety of loose body in arthritis deformans is rare.

II. Loose Bodies derived from the Synovial Membrane consisting of fully formed tissues as cartilage and bone or both.

In studying the origin of loose bodies from the synovial membrane in connection with tubercle we saw that the inflammatory process thus set up produced an increase in the various elements forming that membrane, amongst



ART.

7. 163.

Fringing of synovial membrane in
Arthritis deformans.

which were the so-called cartilage cells already referred to, and from these the cartilaginous and osseous portions of the pedunculated and loose bodies were formed. A similar explanation may be given to account for the formation of many such bodies in arthritis deformans, but with this difference that the inflammatory process is started by some other agency than the tubercle bacillus. Owing to the rarity of these cartilage cells, too much importance must not be placed upon the part that they play in this process, it being more probable that here also as in tubercle the morbid inflammatory process causes the connective tissue cells of the synovial membrane to undergo further development into cartilage and bone, in fact, that they must not be looked upon as cartilage cells in any other light than that they are only so potentially. M.M. Cornil and Ranvier attribute the formation of cartilage in the **synovial fringes** to the replacement of the fat which they contain **by Embryonic cells**, from some of which cartilage is formed, from others, fibrous tissue. An excellent illustration of this **condition** of the synovial membrane is seen in a specimen **in the** Museum of the Royal College of Surgeons of Edinburgh. **7.163**. The lower end of a left femur with **the adjacent synovial membrane**. This is covered with a

remarkable outgrowth of fringed processes.

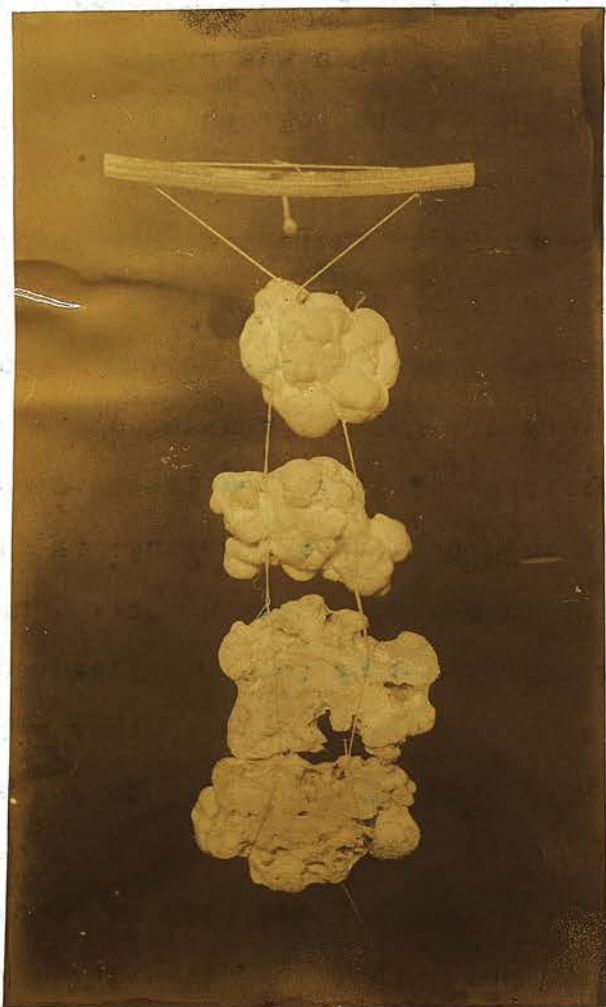
Another specimen is a good example of the various stages which these bodies pass through. Os.E. j.2. (Univ. Mus.). Portions of the synovial membrane of the right knee joint, a dissecting room specimen. In some places the bodies are sessile, one is pedunculated, while there are several which are lying free in the joint; the pedunculated body hangs by a thin, string like stalk half an inch long.

Such a stalked body as that just described gives an accurate idea of how those symptoms already described in connection with pedunculated bodies are produced: granted that the body be attached to the membrane in a position that will allow it to pass between the articular surfaces, locking will occur; the body if felt, will always be so at one part of the joint, and its range of movement will be a limited one.

Microscopic examination of one of the detached bodies at the bottom of the jar shows it to consist of a thin crust of bone forming a complete ring round the body: this encloses an area of fat cells, containing a few blood vessels, and scattered throughout it are also to be seen some trabeculae of bone. The fat is probably the bone marrow.

By far the largest number of loose bodies in joints are formed in connection with arthritis deformans and this appears to be the general consensus of opinion: some of them are ^{derived} ~~derived~~ from the synovial membrane, some of them from the cartilaginous and bony ridges formed at the articular margins, as will be seen when the next group of loose bodies is considered.

In the Anatomical Museum of the University, in addition to the specimen already referred to as showing the various stages in the formation of these bodies, there are others evidently examples of loose bodies occurring in knee joints affected with this disease. Os, E. j. 3. is a loose body removed from the left knee joint, oval, in shape, convex on one surface and flattened upon the other and somewhat curved upon itself; it measures 5 c.m.s. in length, 3.5.c.m.s. in breadth and 1.c.m. in thickness. The convex surface is studded over with irregular nodules of cartilage, presenting in consequence a tuberculated appearance, while the flattened, though somewhat concave surface, is quite smooth. On section the body is seen to consist of a central plate of bone with a thick layer of mixed hyaline and fibrocartilage on either aspect. It was removed by operation from a man 41, years of age, who had suffered from his knee



A.F.T.

Os. E. j. i.

Three larva bodies from Rues.

The lowest is section showing body nucleus -

for 10 years, during the last 4 of which, there were symptoms of loose body. Other signs of disease were present in the shape of "lipping" of the articular margins of the femoral condyles. There is no statement made as to whether it was considered at the time of operation to have been derived from the synovial membrane: now, there is no evidence of a pedicle, but seeing that the body had been loose for four years a trace of such was hardly to be expected.

Os. E. j. i. of which a photograph is added is a very pretty specimen of loose bodies with this tuberculated appearance of the surface. There are three bodies, each larger than the other; the smallest the size of a walnut, and the largest nearly as big as a medium sized hen's egg. The surface is very irregularly nodulated and consists of opaque, white, fibro-cartilaginous tissue, dense in parts and wrapped in a smooth fibrous covering: the largest body which is cut in section shows a central nodule of bone, completely surrounded by this cartilaginous tissue, in which there are a number of spaces. They were removed from the right knee joint of a man T.M. 68 years of age. Twenty years before his admission under Mr Annandale's care, he had suffered from a loose body which had been fixed at that time under the superficial tissues by Mr

Syme. Soon after that, a second body was felt, but it gave no trouble till 1877, when pain and swelling came on.

In March 1878, Mr Annandale made a free incision into the joint and removed three loose bodies. Unfortunately the notes obtained are far from complete and do not state facts which might have converted ones views of the case from an hypothesis into reality. But the information that is to hand suggests their origin in arthritis deformans; the slow and insidious nature of the joint complaint, with little else that is symptomatic; the presence of more than one body, in this case three, originating at different times, and the nodular appearance of their surfaces: this appears to be a striking feature of these bodies and is highly suggestive of their origin from this cause. Some are markedly tuberculated, others less so, but if one notes the description of loose bodies which are said to be removed from osteo-arthritic joints, in the majority of them this term is applied to the appearance of their surfaces. It is seen in the case just described, in the body lying behind the external condyle, Os. E. G. 35, in Os E. g. 3, in the case of W. A. which follows, and in some of the specimens described by Mr Howard Marsh, in St. Bartholomew's Hospital Reports, volume IV.

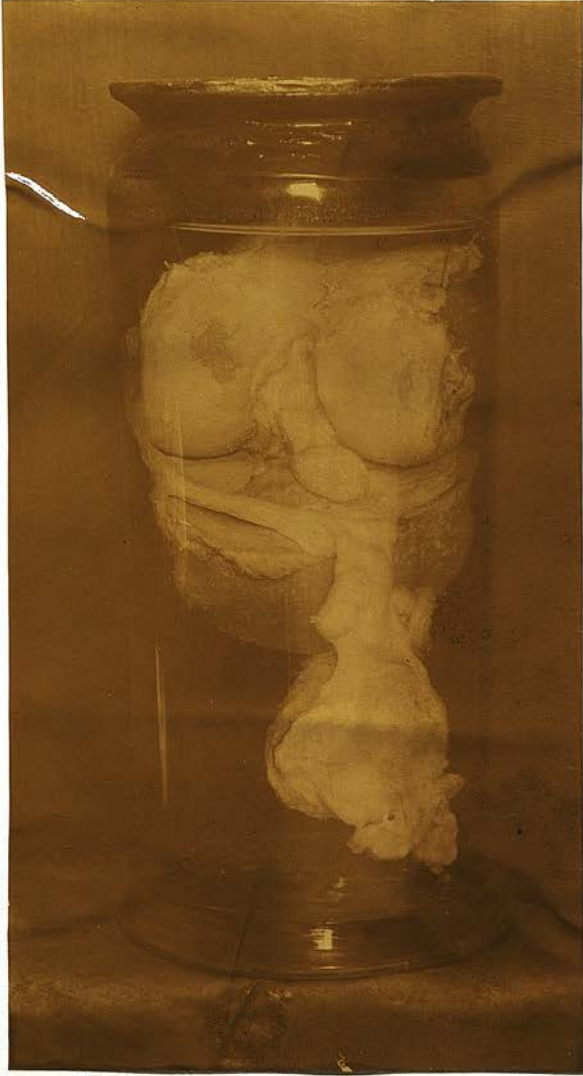The reason for this appearance is to be found I think in the development of the body from separate foci of cartilage lying in the synovial membrane some increasing more rapidly than others, and thus giving an irregular outline. Such a body strongly suggests an origin from the synovial membrane, and from a joint affected with arthritis deformans.

W.A. 40 years of age, had a loose body removed from his left knee in 1890. Twelve years before he had received a severe blow upon it, but while no bad result followed immediately, later he began to suffer pain in it and he would be suddenly pulled up while walking and be unable to move until he had put his hand upon the joint and moved it. At that time he felt a small body "like a marble" which he could push round in his knee, and then recover the use of his limb. This body, he thought had grown larger since he first noticed it. When removed it presented a spherical appearance about the size of a shilling but very much thicker and with a rough nodular surface. It consisted of cartilage with a hard strong centre. Microscopically it was found that the body consisted chiefly of hyaline cartilage, but many of

the cell spaces contained several cells as many as nine being found in some, and in one or two the process of division was apparent. The general arrangement was not suggestive of articular cartilage. At the present time there is no swelling in the joint, it is stiff in the morning, and there is marked creaking to be felt; and there is well marked lipping especially upon the tibia.

III. Loose Bodies derived from the articular ends of bones being detached ecchondroses or osteophytes.

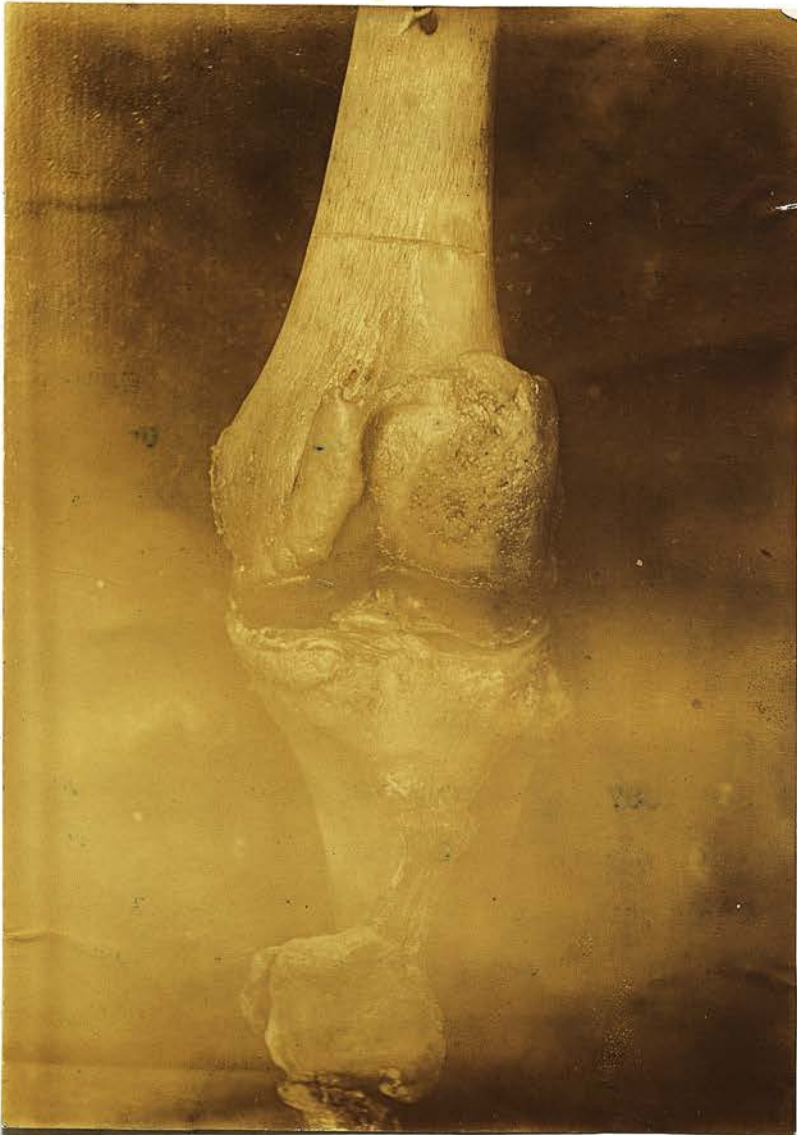In Arthrititis deformans certain formative changes, leading to the production of cartilage and bone, take place at the margin of the articular cartilage. The cells at this margin are proliferating, so that nodular outgrowths of cartilage are formed, which have been termed "ecchondroses". By the deposition in them of lime salts, or by ossification, they become wholly or in part calcified or transformed into bone, and to these the term "osteophyte" is applied. This heaping up is believed to be due to the fact that the articular cartilages at their edges are covered by synovial membrane, and consequently the proliferating cell elements cannot escape as they do



A.T.T.

7. 161. R.C.S. Mus. Ed.

Knee joint showing how bone is
front of anterior crucial ligament -
"Addimentary Bone" of Adams.



A.G.T.

Os. E.g. 36.

showing "liping" round articular
surface of femur & margin of
patella.

on the general surface of the cartilage. The term "lipping" is applied to the ridges formed in this way.

No one who has examined specimens of joints affected with this disease will deny the fact that ecchondroses or osteophytes might very readily become detached by a blow applied to the joint and so form a loose body, or indeed that such might separate spontaneously. An illustration of lipping is given in the accompanying photograph taken from the specimen labelled Os.E.G.36 in the University Museum. It is a dried macerated knee, with lipping in the form somewhat of projections of new bone upon the femur, and along the margin of the patella there are also nodules of bone. One can conceive how a blow might readily knock off a piece of this lip and give rise to a loose body.

On May 3rd 1887, there was admitted into Mr Annandale's Wards, a dairyman, A.C. 43 years of age who stated that a fortnight before, he had been kicked on the outside of his left knee by a cow: the joint became stiff, swollen and painful. Under rest and soothing applications the swelling subsided, but any attempt to move the limb caused pain. On admission there was found in addition to some synovitis, a small body about the size of a bean upon the inner side of the joint close to the patella.

A vertical incision was made along the inner side of this bone and over the body: it was removed and was found to measure half an inch in its longest diameter: it was firm, osseous and irregular upon the surface. There could be felt upon the inner condyle of the femur just below the body a rough spot, and there were signs of lipping indicating the condition that existed. In all probability then, the kick from the cow had knocked the inner edge of the patella against this osteophyte.

Sir Benjamin Brodie alludes to two cases in which this growth of bone had taken place, and in consequence of the movements of the joint, portions had been broken off and lay loose.

It is of interest to note that symptoms may be developed in connection with these osteophytes before any detachment of them has taken place.

In a case which came under Mr Annandale's care in 1885, that of a lady, 55 years of age, a small hard body could be felt upon the outer edge of the patella of the right knee, and in the movements of the joint,

1. Brodie. Diseases of Joint. 1850. p.255.

the edge of the patella would come in contact with this body, causing her great pain. The joint was opened, and the outgrowth which was attached to the articular surface of the femur, was removed: she had symptoms of arthritis deformans, and though some pain and stiffness attacked the joint at times, she was able to use the joint and limb usefully.

J. C. 50 years of age, a fisherman was operated upon by Mr Annandale on December 3d 1890, for somewhat obscure symptoms of loose body in his right knee. Three months before he stated that he had strained his knee and had felt "something go in it". He was then only able to walk with great pain: there was considerable swelling of the joint which subsided under rest and counter-irritation, but as soon as he began to use it again the condition got worse. The knee never locked when walking, but he was sometimes brought abruptly to a standstill with great pain. Nothing could be felt in the joint. A vertical incision was made over its inner aspect, the finger introduced and a nodule of bone was felt along the articular edge of the internal condyle of the femur. This was removed with the chisel. Another ridge was

felt close to the intercondyloid notch, but could not be reached for removal. The whole joint was explored, but nothing further was detected. The piece of bone removed was three quarters of an inch in length, and a quarter of an inch broad at its base, tapering towards the other extremity. The patient left hospital without any marked improvement, but he writes at this date April 1st 1894, three and a quarter years after the operation that he is able to work with no stiffness of the joint, but there is occasional pain. It is evident from the following case that these ecchondroses, perhaps also the osteophytes, may become detached without any recognisable cause. **J.H.** 24 years of age, a carter came under treatment for symptoms of loose body in May 1893. Two years before while walking to his work one morning he suddenly felt pain on the inner side of his left knee joint, causing him to walk lame. He knew of no strain nor had he in any way twisted the leg. This pain which he described as "jerking" in character continued to come and go, making the joint weak. During the last eight months, the pain increased, and some swelling showed itself, so that there was

stiffness in the joint: the pain was chiefly on the inner side of the knee. About two months ago, he began to think there was something loose in the joint because he felt a bean like body moving in it which sometimes could be felt on the inner side, sometimes on the outer, and which could be pushed away with a jerk. He found it necessary to carefully guard his movements while walking, as any freedom in this brought on pain.

On admission, the joint was found considerably swollen, with distinct fluctuation present. There was no loose body felt. On June 7th the joint was opened on the inner side: there was a considerable escape of fluid: the internal semi-lunar cartilage appeared unduly movable and was thickened and as already stated a portion was removed. On introducing the finger a loose body was felt and removed. It was an elongated, flat, white body, thin and somewhat flaky and indented at one extremity. There was evidence of lipping at the articular margin of the femur.

The body consisted of ^{hyaline} cartilage, many of the cell spaces containing as many as five cells. Ossification had commenced because there can be seen in the section

the lacunae and branching canaliculi of bone. The patient was re-admitted in January 1894, complaining of pain and stiffness in the left knee operated upon, and latterly of pain in the right knee: he had never been able to return to his work. In the left knee complete flexion was not possible, there was pain generally in the joint, and weakness in the morning, wearing off considerably during the day. Distinct creaking could be felt and heard. In the right knee there was some pain, and sensation of jerking and the same feeling of creaking. He was ordered Iodine douching, massage to the joints, and tonic treatment.

This patient's condition had become worse and as it illustrates certain points in this disease, it will serve as a test for referring to them. It is not necessarily a condition arising in middle life, but cases are reported in which it has shewn itself in young adults, and Dr A.E. Garrod records two cases occurring in children of nine and ten years. This patient was 24 years of age, another, the notes of whose case I have, was the same age, and one of the patients, to whom reference will be made presently in connection with hypertrophied synovial

fringes, was also 24. with these facts therefore, one must be careful not to put aside the possibility of arthritis deformans because the patient is young. In this case there is no history of an injury which is so often the exciting cause; the fact that only the left knee was affected for a period of nearly three years illustrates the non-articular variety of the condition, and the subsequent affection of the opposite joint is not inconsistent with this variety, though symmetry is usually absent. Further, the slow and insidious nature of the complaint is well brought out with the absence of any previous symptoms. Some pain and weakness in the joint, followed later by swelling and some rigidity extending over a period of months and even years.

It opens up also the question of prognosis after operative interference upon loose bodies. The question as to whether trauma alone is the cause of the body or whether there is also disease present must be taken into consideration. This can hardly be better brought out than by comparing the results obtained after opening the knee joint in cases where the semi-lunar cartilage was detached, and those in

which loose bodies have been dealt with. The former I have already fully referred to in Part I. I have been able to obtain information from some of the patients who have been thus treated, and though their loose bodies were removed and the disagreeable symptoms which they gave rise to disappeared, a very important result, the disease from which they suffered forbade the recovery to a perfect joint. I have examined W.A. whose case has already been quoted three and a half years after operation, and save for stiffness of the joint in the morning and some pain when the weather changes, he has no inconvenience.

Another patient writes after the same period of time, that his knee is worse since the operation, there being great stiffness and pain in it, and we have already seen how J.H. has not yet been able to return to his work one year after the operation. In all these cases there were evidences of arthritis deformans and they all illustrate the slow character of the disease.

HYPERTROPHIED SYNOVIAL FRINGES.

By this term I wish rather to refer to the condition described by Robert Adams as consisting of "vascular excrescences" of the synovial membrane, though undoubtedly some hypertrophy of the membrane also exists, nevertheless the condition is I think to be found with but very little thickening and certainly prior to the formation of pendulous bodies from the synovial membrane. These excrescences consist in an increased vascularity of the fimbriae normally existing at the margins of the articular cartilages and also in an abnormal vascularity throughout the membrane generally.

The two cases which I have examined appear to be examples of this condition. They presented symptoms of internal derangement which could not be assigned to any special lesion of the joint; they occurred in patients without any other signs of this disease and therefore they go to prove that this condition is an early manifestation, a remark which was made by Adams, though Cruveilhier found them in the knee joint of an individual who had also other signs in the same joint.

Though the history in both cases is somewhat similar it will save confusion to shortly study each separately.

J, M'W. 24 years, (another example of arthritis deformans in a young adult), a compositor, found his right knwe joint swollen and painful in 1884, without any history of injury: this recovered under rest and blisters and was probably a simple synovitis from another cause. In February 1892, eight years later, he received a blow on the inner side of the same knee causing swelling and pain. A year later he had sudden pain in the joint and inability to bear his weight through it, complete flexion and extension became impossible, and pain was most marked on the inner side of the joint. These symptoms continued till his admission in April 1893, when the leg was found slightly flexed and great pain was caused in attempting to straighten it: there was swelling and tenderness upon the inner side, but nothing could be felt.

As ordinary treatment had failed to relieve this now chronic condition, the joint was opened by Mr Alexis Thomson by a transverse incision over the internal semi-lunar cartilage, which was found to have its normal attachments. The synovial membrane was red in colour appearing highly vascular, resembling the mucous membrane of the small intestine. It had a soft,

velvet like feel. A small piece of it was cut away for further examination. On squeezing the joint, the fibrinous loose body, already described at the commencement of this section, escaped. Nothing else was detected. The microscopic sections of the synovial membrane showed here and there upon the surface of the fringe a fibrinous deposit. There was a proliferation of the synovial elements, but the most marked feature was its great vascularity. Large numbers of blood vessels were scattered throughout the fringes, some filled with blood, others empty, while round many of them, especially at the free margin, was a very considerable small cell infiltration. There was no evidence of tubercle.

The patient made an excellent recovery, being allowed the free use of his joint, a month after the operation. I had an opportunity of examining him at the present time, a year after operation, and found him in good health and doing his daily work. The knee was freely movable with entire absence of pain and swelling. On placing the hand upon the joint during movement some little roughening is felt upon the outer aspect, but not appreciable by the patient.

The second case was that of J.A. 39 years, a labourer, with a good family history. In 1889 his left knee began to swell after some extra exertion which he had to undergo and it has troubled him more or less since. Leeching, blisters and rest have failed to relieve him. In 1892, the joint became more swollen and painful and he was put under antirheumatic treatment. He tended to fall when weight was borne upon it, and when going down hill there was a tendency for the joint to lock. On admission in April 1893, the knee was painful, swollen and tender over the articular margins. An exact diagnosis was not made, but profiting by the experience of the previous case Mr Thomson opened the joint: there was no loose body and no lipping of the bones, but there was a quantity of bloody fluid, and a dirty, dark red fringed condition of the synovial membrane, a part of it protruding through the wound in the capsule. A portion was removed and found generally similar to the previous one, but there were evidences of many old haemorrhages into the tissues as demonstrated by the green colouring that the extravasated blood had taken up from the haematoxylin stain. There was a marked dividing up of the

fringes into small processes.

The patient made an excellent recovery and he also was examined quite recently, a year after operation. The knee was swollen and there was not such free movement as in the previous case. Both these cases are of value: the chronic history of pain, weakness, and effusion into the joint without any further signs of disease, the highly vascular condition of the synovial membrane with entire absence of the signs of tubercle lead one to conclude the condition to be one of early arthritis deformans, insidious in its course and puzzling in its symptoms. Operative interference has been proved justifiable, not only because simpler means had failed, and because a diagnosis was arrived at by so doing, but because in the case of the first patient, an excellent result has been obtained, and in the case of the second, though not so successful, the previous disagreeable symptoms have disappeared. It will be interesting to see if any new development should arise in the future.

SYMPTOMS AND DIAGNOSIS OF LOOSE BODIES.

A very brief account of the symptoms and diagnosis of loose bodies will be given here once and for all. These symptoms vary and the presence of a loose body is not always readily detected, because they are modified by the disease which may exist in the joint.

The body may or may not be first detected after an injury: its detection is usually sudden, perhaps while walking, the patient is seized with acute pain, causing him to stop and even to fall to the ground, and he may be unable to straighten his leg, the joint having become locked with the sensation of there being something between the opposed bony surfaces. This locking is usually only temporary freeing itself, consequently differing from that which is produced by a dislocated semi-lunar cartilage, where manipulation is necessary to reduce it. This can be readily understood when we consider that the locking is due in the first case to an unattached body getting between the femur and the tibia as the joint is being extended: it thus acts as a wedge, but being free, as the movement of extension is continued, it is pushed out in front and complete extension then becomes possible, on the other hand the semi-lunar cartilage is still attached and

cannot get free. In some cases locking never occurs, because the body may be too large to get between the joint surfaces, or too small to cause opposition to the movement. The frequency with which such a symptom recurs varies in different cases. Effusion into the joint usually follows and very repeated locking may produce a chronic effusion.

The body or bodies may be accidentally felt or even seen projecting under the skin where the capsule is superficial: the slightest touch may cause it to slip away from under the finger making its exact size and consistence difficult of detection. It may be felt now at one part, now at another part of the joint and it may be worked across the joint, with the fingers. There are periods varying in length in which the body is no longer felt nor does it give rise to any trouble, becoming hidden in one of the pouches and in some cases as for instance, where melon seeds are present, the ordinary symptoms of loose body are not complained of: here as with fringing, the soft creaking on movement is suggestive of their presence.

Treatment.

The treatment of loose bodies resolves itself into the palliative and operative. Immediate reduction when the joint is locked is not so often necessary in the case of the loose body the reason already given in considering the symptoms: when it is necessary, flexion of the joint will assist in disengaging it, accompanied by some manipulation which the patient usually learns for himself. Synovitis is treated on the principles already laid down in dealing with the detachment of Semi-lunar Cartilages.

Palliative treatment or the employment of means to prevent the body getting between the joint surfaces and so diminishing the attacks of pain and locking, must to a large extent depend upon the frequency of these attacks. Where the inconvenience derived from its presence is slight, where the vocation of the patient is not of the kind to render him liable to further risk of injury should locking occur and where the wearing of a pad or knee cap is found beneficial, then operative interference need not be pressed, though the safety with which the joint can be now opened should be impressed upon the patient for the purpose of restricting the movements of the body, the wearing of an elastic bandage or knee cap is advised, or some form of

knee cap with a pad so arranged as to fix the body by its pressure at a spot where the patient has learnt to know that it becomes most readily fixed has been suggested.

The question how far such palliation may be the means of permanently fixing the body may be conveniently enquired into at this stage. Mr Hey of Leeds records two cases treated by knee caps, in one of which after it had been worn twelve months, the patient no longer recognised the presence of a loose body even when he walked without his bandage while in the second, after a trial of ten years the patient found this treatment to answer every purpose he desired.

Poulet and Vaillard² experimented upon dogs: they opened joints and detached portions of bone and cartilage and then closed them. Several weeks afterwards, the animals were killed and it was then found that the bodies had taken fresh attachments to the synovial membrane and become partially vascularised, so that such a re-attachment is possible.

It must also be borne in mind that loose bodies as

1. Hey. op.cit. p.345.

2. Poulet and Vaillard. Archives de Physiologie. vol.V.1885.

such will increase in size deriving their nutriment from the synovial fluid as some of the cases I have seen and those of other surgeons go to prove, so that in the course of time if left, they may cause considerable inconvenience from their size.

In advising operation, one would take into consideration the frequent occurrence of suffering and interference with the usefulness of the limb and the uselessness of any appliance, and further, if the body were single and from its size incommoding the patient, one would advocate the relief to be obtained by its extraction. At the same time the probable cause of the loose body must be taken into consideration, as prognosis will be greatly influenced according as to whether the body has originated solely from trauma or whether there is also disease in the joint as already indicated.

When the joint is free from all acute inflammation, it may be opened, and the body or bodies, sometimes more than one is detected during the operation if not before, are removed. The open method by direct incision is the one now employed, though a word must be said of the subcutaneous section. By this latter method, a long narrow tenotome was introduced under the skin at the lower part of the knee

joint and carried up in the subcutaneous tissue, till the body which had been first fixed on the inner side of the patella was reached; the capsule was there divided, the body pressed through the opening thus made into the subcutaneous tissue, where it was fixed with a firm pad and sticking plaster. At the end of a week, it was then excised from its new situation. In this way the danger of inducing inflammation in the joint was reduced to a minimum.

By the open method an incision is made through the skin and fasciae down to the capsule, all bleeding being then arrested. This incision is usually a vertical one, an inch and a half or two inches long. If the body has been fixed or made apparent immediately before the operation then it is cut down upon in that situation and pressed out; this is not always possible, and in these cases the site chosen may depend upon where the body most frequently shows itself. In either case it is made upon the inner or outer side of the patella. The capsule is then incised in the same direction and if the body does not lie immediately beneath it, the finger is introduced and the joint explored. After the body is removed the joint must be examined to ascertain if other loose bodies are present: the condition of the synovial membrane should be investi-

gated and also the articular ends of the bones, so that if possible an indication may be got of the probable site of origin of the body, or of the presence or absence of disease. The capsule is stitched with catgut sutures and the external wound closed: no drainage is necessary. A posterior splint is applied, and the joint kept at rest for a fortnight when passive and then active movements may be commenced.

c. Syphilis.

Syphilis may give rise to several forms of arthritis, and may affect a joint either in its secondary or tertiary stages. It is in this latter stage that loose bodies and hypertrophied fringes may exist; during the secondary period, an effusion of a subacute or chronic nature is the lesion, of which practically nothing further is known, the condition clearing up under treatment, so that no evidence is forthcoming as to the pathological changes that may be present.

Loose bodies may be produced by gummata breaking into the joint. At a meeting of the Medical Society of London on February 27th 1888. Mr Sheild showed a man with loose bodies in one of his knee joints. He had a

history of syphilis two years previously, and at this meeting it was suggested that they might be ossified gummata, but no prior history of synovial inflammation could be obtained from the patient.

In a valuable paper by Mr J. Hutchinson junior on Syphilitic Joint Diseases,¹ various specimens of the disease in the tertiary stage are described: it is there stated that gummata occasionally break into the joint. In a knee joint described by Mr Hutchinson and preserved in the Museum of the Royal College of Surgeons of England, there is a gummatus mass in the fatty tissue just outside the ligamentum mucosum thus illustrating how from its position rupture into the joint cavity might occur.

There is also to be seen in St Bartholomew's Hospital Museum an example of the disease affecting the knee, elbow and shoulder joints in one patient and it illustrates the development of numerous fringes, in connection with the synovial membrane. The joints in some respects resemble in their appearance what is found in arthritis deformans, but there is no eburnation of the exposed bone, no osteo-phytic growths or lipping. In some of the specimens, a scar

1. Hutchinson. Brit. Med. Journ. Apr. 16th. 1892.

of fibrous tissue replaces the lost cartilage at the site of erosion.

d. Spinal Arthropathy. e.g. Charcot's Disease.

Certain pathological features were recognised by the late Professor Charcot, as existing in the joints of some of those who were affected with locomotor ataxia, and as some of the conditions found are of the nature of loose bodies, pedunculated bodies and new bony formations, reference must be made to this disease in the study of the subject with which we are dealing. The case which I have described is a good example of what may be found in these joints. In the valuable Report¹ of a Committee of the Clinical Society of London, nominated to investigate this form of joint disease, there is to be found much interesting matter. In a table of 42 cases, the condition of the joint or joints is briefly described: in four of them loose or pedunculated bodies were recognised, in one they are stated to be partly bony, partly cartilaginous, but in none have I been able to find any mention of the melon seed like bodies, nor is there any microscopic descrip-

1. Clin. Soc Trans. vol. XX. 1887.

tion appended to the cases.

I am indebted to Mr Caird for leave to make use of a case of Charcot's disease recently under his care and thank him for furnishing me with some of the loose bodies which I have prepared for the microscope. Without detailing in full all the symptoms that the patient shewed, it will suffice to say that the diagnosis of locomotor ataxy was made and confirmed on post-mortem examination.

The patient R.K. a carter, 36 years of age, unmarried, was admitted into Ward 13 on December 10th 1893, and the condition of his knee joints was as follows. Right Knee. Swelling first noticed 8 years ago: there was no injury at that time. The swelling gradually increased for eight months, when he was compelled to lie up for three months, but rest and blistering failed to effect much improvement. But in the course of time the condition improved thus allowing him to use his leg fairly well, though the swelling never entirely disappeared. During the last year it has again got worse, though he has always been able to go about.

On admission; the circumference of the knee measured 19 inches, there was no discoloration or

inflammatory signs: the swelling was most marked on the inner side: the patella was enormously hypertrophied and the internal femoral condyle could with difficulty be made out. The joint was full of fluid, there was cracking felt under the fingers on movement and a loose body could be detected on the inner side of the joint. There was free lateral movement and abnormal antero-posterior movement of the joint.

Left Knee: swelling commenced two years ago, but the joint has never been so large as the other, and during the last twelve months has somewhat decreased.

On admission, the circumference also measured 19 inches, but there was a partial dislocation of the tibia backwards and outwards. Fluid was present, but there was not such marked cracking; one large loose body was felt on the inner side and several smaller ones on the outer. There was marked lateral movement.

On December 22nd, the right knee joint was excised and a large quantity of translucent, sticky, yellowish fluid escaped, along with many small melon seed bodies. The end of the femur was rounded off and devoid of cartilage: the bone was sclerosed: the head of the

tibia was expanded and cup shaped, the walls of the cup being made up of large pieces of bone embedded in fibrous tissue. The patient died on December 27th. The melon seed bodies resembled in their naked eye appearances those previously described, but microscopically they differed. Covering their surface was a layer of fibrine, free from leucocyte infiltration in its outer parts, but containing these cells in its deeper parts, while the mass of the body was made up of wavy bands of fibrous tissue. It has thus been seen that melon seed like bodies may be found in tubercle, in arthritis deformans and in Charcot's disease of joints. It might be argued that these two last conditions were identical with each other and consequently the presence of such bodies in both can be readily understood, but the conclusion arrived at by the Committee already referred to was that certain differences existed which amply warranted the separation of tabic arthropathy from the group of joint diseases known as arthritis deformans.

e. Tumours.

In assigning to tumours a place in the varieties of lesions that may cause internal derangement of the knee joint, it is not my intention to include either the exostoses or the sarcomata of the bone, developed most frequently in this region in connection with the femur. My reason for so doing is because they do not give rise to those symptoms which we have already seen to be so suggestive of derangement. The tumours to be discussed are found in connection with the synovial membrane and the fatty tissue immediately subjacent to it, so that they are thus growths in the joint proper.

The two varieties which have been described are the fatty and the sarcomatous, the former being the more common: these lipomata are quite distinct from the condition of lipoma arborescens ^{to be} ~~already~~ described.

Fatty Growths. In order to understand the relation which the fatty tissue bears to the synovial membrane of the knee joint, and at the same time properly to appreciate what is presently to be said in regard to the origin of these growths, a very brief resume must first be given of the arrangement of the fat. This is an extra-articular structure subjacent to the synovial membrane, where it forms

a useful medium for filling up space. It is especially developed in certain situations: it lies in the processes or fringes of the membrane, it exists as a large pad below the ligamentum patellae, the infra-patellar pad of Goodsir in relation to which certain folds of the synovial membrane receive special names. One the ligamentum mucosum is the central portion of the synovial membrane which lies against the infra-patellar pad of fat, extending from it upwards and backwards to the intercondyloid notch of the femur, where it is attached in front of the anterior crucial ligament. Between the layers of this fold some of the fat of the pad passes. The lateral margins of this central portion of the membrane are called the alar ligaments, two in number, external and internal in relation to middle plane of the joint being folds of synovial membrane containing fat, passing downwards from each side of the patella to be continuous with the ligamentum mucosum below. It appears to be from the infra-patellar pad and from the fat contained in these folds that these fatty growths are developed.

In 1875. Volkmann¹ reports a case in a man, 63 years

1. Volkmann. Beitrage f. Chirurgie. S.183. 1875.

of age, who had suffered from symptoms of internal derangement in one knee for a year and a half. They were found to be due to a fatty growth which was removed.

König¹ and Barwell² also record cases, in that of the latter, two pedunculated fatty masses being removed from the same joint.

In 1886, Dr. Weir³ of New York published an interesting paper on joint tumours: He describes a case in which he removed from the knee of a young man a mass made up of very vascular connective tissue, rich in fat and connective tissue cells. This was felt before operation as a mass of considerable firmness on the inner side of the patella and was evidently pedunculated: it was found to stretch under the ligamentum patellae and across the joint, so that one may look upon it as originating in the infra-patellar pad of fat.

Sir Benjamin Brodie⁴ reports two cases of what he calls fleshy tumours growing from the inner surface of the synovial membrane and removed by operation: there is no minute

-
1. König. Lehrbuch der Chirurgie. Bd. III. S. 476.
 2. Barwell. Internal. Cyclop. of Surgery. vol. IV p. 339.
 3. Weir. New York Medical Record. June 26th. 1886.
 4. Brodie. op. cit. 1850.

account of their structure.given. In both cases a swelling in the joint was recognised,one on the outer,and one on the inner side of the patella,and they were diagnosed as loose cartilages before operation. In the first case,a second tumour appeared in the same situation.

In the session of 1886-87 Professor Annandale read before the Medico-Chirurgical Society of Edinburgh,a paper on Internal Derangement of the Knee Joint,in which he described two cases of fatty growths in the joint: an account of them will be found in the Transactions of the Society for that date,so that no detailed description of them need be again given,but I wish to refer to the position in which they were found. In both,the symptoms pointed to a condition on the inner side of the joint,and the growth in each case was found "lying over the inner and anterior margin of the internal semi-lunar cartilage",that is to say in the position of the internal ligamentum alarium.

Since that date,three other cases,probably of a similar nature,have been treated by him,and as I have had an opportunity of examining them both clinically and microscopically,they will be detailed in greater fulness,and their description will serve to bring out the symptoms with which they are associated.

CASE I. D.G. 41 years, a miner, was admitted in February 1893. Two and a half years before, while riding a bicycle, he fell off and struck his right knee upon the road metal, making a superficial cut over the joint. He lay up for a fortnight, but at that time he had no trouble with the knee joint. He returned to his work and it was not until nearly a year and a half later that he began to have pain in the joint on movement, with swelling and stiffness at times causing him to rest. This would recur at different times, rest and blisters failing to give permanent relief. There was never any locking of the joint, nor was a loose body ever felt. There was some fulness of the joint on admission, but nothing to indicate any lesion of one or other semi-lunar cartilage. As ordinary treatment had failed, operation was decided upon, and because the patient complained of pain on the inner side, the incision was made there. The internal semi-lunar cartilage was found normal both as regards its appearance and mobility, but in front of it and in the region of the internal ligamentum alarium, there was a fulness, a distinct bulging forwards of the synovial membrane into the joint cavity. A ligature was passed round it,

and it was removed. There was no evidence of disease in the joint.

On examining the portion removed, under the microscope one found it to consist chiefly of fat: there was the ordinary arrangement of fat cells, containing a number of blood vessels, and with an endothelial covering: in fact it appeared to be an overgrowth of the normally existing synovial membrane.

The wound healed without any complication and when the patient was seen five weeks after the removal of the splints, movement was good, though he still complained of some pain on the inner side of the joint. Writing a year after the operation; he still complained of some pain, though he was able to work as a miner.

CASE II. J.F. 41 years, a miner, was admitted in March 1893. He was a healthy active man with a good family history. Nine months before admission he injured his right knee by a fall. He could only with difficulty rise owing to the pain and stiffness in the joint, and he was unable to straighten the leg: the joint became swollen and he remained in bed for a few days after which he saw a bone setter who told him a bone was

"out", which he at once put in. At the end of a fortnight, while at work upon his knees, the joint locked, requiring the bone setter to reduce it: this has occurred repeatedly.

On admission there was found to be effusion in the joint, and pain over the inner side though not located to the semi-lunar cartilage. No swelling could be felt. On opening the joint over the internal semi-lunar cartilage there was found in the position of the inner ligamentum alarium a distinct process of fat, which appeared unusually developed and which might readily enough have got in between the joint surfaces. It was ligatured and removed. As the internal semi-lunar cartilage appeared somewhat too freely movable, the larger part of it was also removed.

The microscope showed the mass to resemble the specimen described in the previous case.

I had an opportunity of examining the patient seven months after the operation and found the movements of the knee to be perfect: there was no pain or locking and he was carrying on his work as a miner without inconvenience: writing a year after the operation he gives a similar report.

CASE III. Miss E.J. a lady's companion, was admitted in May 1893. Two years previously she had fallen and twisted her right knee causing her very great pain. She was ordered to rest, but being obliged to discharge certain duties, it was very insufficiently maintained, causing the swelling and pain to remain and at times she was suddenly pulled up when walking: the diagnosis then made was that of "loose cartilage". At the end of two months Scott's dressing and splints were applied. The condition then improved. On resuming work, notwithstanding the wearing of bandages, effusion into the joint would repeatedly recur during a period of ten months. For a year before operation, occasional attacks of pain, difficulty in walking uphill or upstairs, with swelling of the joint and pain and an appearance of thickening upon the inner side of the knee were the chief things complained of.

No diagnosis was made before incision, which was carried out over the internal semi-lunar cartilage, the chief symptoms being in that region. This cartilage appeared perfectly normal nor was any loose body to be detected, but in the position of the internal ligamentum alarium there was a prominence covered

by the synovial membrane projecting into the joint cavity: it was removed, and like the other two, to the naked eye it appeared to consist of fat, though unfortunately it was not preserved for future examination.

When I saw her four months after operation, movement was fairly good and she had been walking 10 miles a day without experiencing pain, and there was no swelling of the joint. Eight months after the operation she writes that she is perfectly well, save for a slight jerking pain in the joint when she catches her foot against a stone.

A study of three cases taken in conjunction with the two earlier ones of Mr. Annandale's and with the others recorded, leads one to look upon this condition with very considerable interest; that all the cases of this kind are instances of subsynovial fatty tumour, or new growth one cannot admit. Lanenstein of Hamburg describes a case in which from an injury received upon the knee joint, the subpatellar pad of fat had been forced through the overlying ligamentum mucosum and lay in the lower and anterior part of the joint.

1. Lanenstein. Centralblatt f. Chirurgie. No. 49. 1884.

Allingham¹ records two cases of derangement associated with a lesion of one ligamentum alarium: in the first, it had been wrenched away from its femoral attachment by an injury so that it could be pinched between the femur and tibia, while in the second from the thickening of the subpatellar pad from chronic inflammation resulting from injury, the ligamenta alaria were pushed into the joint and so gave rise to symptoms. In the three cases just detailed, there was distinct history of an injury, but the appearance of the joint in none of them suggested a condition similar to Lauenstein's case and the endothelial covering in the two masses examined is against it, ⁿ Nor did a condition like that found in either of Allingham's cases exist.

Microscopically there is no evidence of old haemorrhage as the result of injury causing enlargement. Consequently one is inclined to the belief that we have here to deal with an hypertrophy of the fat normally existing outside the synovial membrane in the region of the ligamentum patellae, this hypertrophy resulting from injury. In two of the cases the men were miners, but while suggesting kneeling as a cause of chronic irritation I think the rarity of the condition contra-indicates such being the

1. Allingham. op.cit.

cause. Though these three cases are not looked upon as tumours, they are included in this group of lesions, because of their microscopic appearances.

Notwithstanding the complication of an abnormally movable semi-lunar cartilage in the knee of J.F. the subjective symptoms in the various cases described tend to indicate a lesion of a semi-lunar cartilage, and the fact that the ligamenta alaria lie normally in such close relation with these cartilages renders the difficulty in diagnosis greater. One does not find locking such a very decided symptom in them, but too much importance must not be attached to this, as it has already been shewn that locking does not always occur where a semi-lunar cartilage is detached. If a distinct mass be felt, then there is no longer any doubt that something abnormal exists. When a history is obtained like that given in case III. an exploratory incision is justifiable, and the termination justifies the action, because such excellent results have been obtained.

Sarcomata.

Another variety of tumour that has been described in connection with the synovial membrane is the sarcoma. In the Transactions already referred to Mr Annandale

reported the case of a woman aged 33 from whose right knee he removed a small tumour, the size of a horse bean, attached to the synovial membrane. It was ligatured and removed and pronounced by Dr Sims Woodhead to be an example of myeloid sarcoma. I had the opportunity of seeing this patient on April 10th 1894, eight years after operation, and found her perfectly well and experiencing no trouble whatever from her knee.

Weir¹ of New York describes two cases, one in a woman, 24 years of age, another in a man of 39: both had slender pedicles attaching them to the synovial membrane, and both were found to be sarcomatous in nature. In the first, there were small round and spindle cells and many giant cells, and the second was looked upon as a fibro-sarcoma.

Yet another case is recorded by Simon in Langenbeck's² Archiv, and was described by him as an hypertrophied, sarcomatous, synovial fringe.

In Annandale's and Weir's cases a movable body could be detected, so that the presence of something in the joint was recognised, though its nature was not known.

1. Weir. op.cit.

2. Langenbeck. Archiv.f.Klin.Chirurg.Bd.VI.S 573. 1865.

The duration of the bodies in the three cases was 18 months, "over a year", and five years.

Lipoma Arborescens.

Before concluding this subject, it is necessary that some reference be made to the condition termed Lipoma Arborescens, first described by Johannes Müller in 1838. As the name implies, the condition is one consisting of a series of pendulous fatty processes hanging from the synovial membrane of joints. In some cases it is said to be associated with Tubercle, in others with Arthritis Deformans and in others again no disease is reported to have been present, and another theory presently to be referred to, is given for their production, consequently I have preferred to refer to this somewhat rare appearance in joints under a heading by itself, distinct from those diseases already described.

An accurate idea of what actually exists, quite apart from its cause may be obtained by perusal of the two specimens described by Mr. Bland Sutton² and figured by him in

-
1. Müller. "Ueber den feinern Bau und die Formen der Kraukhaften Geschwülste. Berlin. 1838.
 2. Bland Sutton. Path. Soc. Trans. vol. XXXIX. 1888.

the Transactions of the Pathological Society of London. The one is the shoulder joint of a woman in which may be seen sprouting from the synovial membrane, especially near the margins of the glenoid fossa, a number of pedunculated processes, some of the size of a millet seed, others equaling in size a cherry stone: in fact there can be traced every gradation from the simple villous fringe to the pedunculated mass of fat: the bulk of these processes are made up of fat, though many of them are composed of fibrous tissue.

The second specimen in the Museum of the Royal College of Surgeons of England is the knee joint, and is described as showing round the articular margin of the femur a crowd of small oval and branched growths of fibrous and fatty structures, each covered by a shining membrane, like a reflection of synovial membrane, and all attached by long slender pedicles: their shapes and sizes are various: some are like branching threads, others are nearly cylindrical, and others are flattened and lanceolate.

The cause of such growths is stated to be a chronic inflammatory irritation, set up in some cases by tubercle, in others where arthritis deformans is present, and again in syphilis, and seldom in rheumatism.

They are looked upon as rare in association with Tubercle.

A case is reported by Schmolck in a man, 23 years of age, with no tubercular history, and no history of an injury. He had been treated for effusion into the right knee joint, when three years later after active gymnastic exercise, he had severe pain in the same joint, and two small, rather movable soft bodies were detected in it. The joint was opened on the inner side and there was prolapse of a large number of fringe like processes, some of them the size of the end of the thumb. A number were removed, and from the outer side of the joint, three large polypoid masses were also cut away.

Microscopically, the smaller fringes were found to contain spindle, round and star-shaped cells, with little fatty tissue, but in the larger masses, fat was the main constituent. Over the surface of the tumours were many miliary deposits of tubercle, seen also over the portions of synovial membrane removed, which did not present these masses.

-
1. Schmolck. Deutsche Zeitschr. f. Chirurg. Bd. XXIII. Heft. 3 u. 4. 1886.

They are much more frequent, however, in association with Arthritis Deformans. In the woman from whose shoulder joint Mr. Sutton's specimen is figured, every joint showed evidence of osteo-arthritis, and Schneller, who looks upon chronic inflammatory irritation as the cause of their origin holds this view. To the naked eye it would be difficult at all times to say positively from the appearance of the growths whether they were fatty bodies or not.

An interesting paper upon this subject has recently been written by Sokoloff,¹ who attempts to show that such irritation is not the sole cause of the development of these tumours. He says they may be produced in that part of a joint which is subject to negative pressure, in other words they grow from a part of the synovial membrane which has ceased to functionate, and he describes two cases to prove his point.

In the one, the shoulder joint of a woman who suffered from syringo-myelia, there was a dislocation and from the part of the capsule which was at the time without function, there was a mass of these fatty growths. The rest of the joint which was still

1. Sokoloff. Sammlung Klinische Vortrage No. 81. Sept. 1893.

functional was free from anything of this nature. The second case was that of a man, 65 years of age, who had 15 years before his death dislocated his shoulder. It was reduced, but dislocation recurred, and was left unreduced. Slight movement was always possible. On his death, the head of the humerus was found in a new groove, and in the posterior corner of the capsule behind and outward from the newly formed groove, there was a large conglomerate mass of polypi: he looked upon them as existing in a functionless part of the joint, where the pressure was negative.

It may be stated in regard to this second case that the cause of death was put down to rheumatic lesions, that there were some of these polypi scattered through the joint, and that the amount of fat in them was insignificant, consequently one is inclined to doubt this case as proving Sokoloff's theory, and one would prefer to look upon it as one of those cases of fringed and pedunculated processes, such as have already been described in arthritis deformans.