

**AN EVALUATION OF THE PLACE OF Nd:YAG LASER IRIDOTOMY  
IN THE TREATMENT OF ANGLE CLOSURE GLAUCOMA**

**BRIAN WILLIAM FLECK**

**DOCTOR OF MEDICINE DEGREE  
UNIVERSITY OF EDINBURGH  
1992**



## **CONTENTS**

Contents	i
Declaration of originality	xii
Acknowledgements	xiii
Ethical approval	xv
List of Tables	xvi
List of Figures	xx

<b>ABSTRACT</b>	<b>1</b>
-----------------	----------

## **CHAPTER 1**

<b>INTRODUCTION AND LITERATURE REVIEW</b>	<b>3</b>
1.1 Introduction	3
1.2 History of the use of light energy to produce iris openings	4
1.3 History of surgical operations for angle closure glaucoma	
1.4 Pathogenesis of angle closure glaucoma in relation to surgical management	5
1.5 Forms of angle closure glaucoma in relation to surgical management	8
1.5.1 Acute angle closure glaucoma	8
1.5.1.1 Cornea	9
1.5.1.2 Iris	9
1.5.1.3 Lens	10
1.5.1.4 Trabecular meshwork	10
1.5.1.5 Optic disc	10
1.5.2 Intermittent (subacute) angle closure glaucoma	11

1.5.3 Chronic angle closure glaucoma	11
1.6 Racial differences	12
1.7 Outcome of treatment	12
1.7.1 Operative and early postoperative complications	13
1.7.2 Operative and early postoperative complications of drainage surgery	23
1.7.3 Prevention of acute angle closure glaucoma	24
1.7.4 Long term glaucoma outcome	24
1.7.5 Long term visual acuity outcome	26
1.7.6 Treatment of chronic angle closure glaucoma	28
1.8 Laser treatment of angle closure glaucoma - Q switched Nd:YAG laser iridotomy	31
1.9 The physics of laser energy	31
1.10 Characteristics of the Q-Switched Nd:YAG laser	32
1.11 Laser interactions with tissues	33
1.12 Ophthalmic uses of the Q-switched Nd:YAG laser	35
1.13 Histopathological changes in the iris following Q-switched Nd:YAG laser iridotomy	36
1.14 Indirect tissue damage due to Q-switched Nd:YAG laser iridotomy	36
1.14.1 Cornea	36
1.14.2 Transient intraocular pressure elevation	37
1.14.3 Lens damage	38
1.14.4 Vitreous and retina	38
1.15 Contact lenses used in Nd:YAG laser iridotomy	38
1.16 Other forms of laser iridotomy	39
1.16.1 Argon laser iridotomy	39
1.16.2 Ruby laser iridotomy	40

1.16.3 Dye laser iridotomy	40
1.16.4 Fibreoptic delivery	41
1.17 Areas of understanding of laser iridotomy which require further work	41
<b>CHAPTER 2</b>	
<b>MATERIALS AND METHODS</b>	44
2.1 Patients	44
2.2 Methods	45
2.2.1 Ethical approval	46
2.2.2 Randomisation	46
2.2.3 Treatment techniques	46
2.2.3.1 Operative peripheral iridectomy	46
2.2.3.2 Nd:YAG laser iridotomy	47
2.2.4 Examination methods and definitions	48
2.2.4.1 Laser induced corneal damage	48
2.2.4.2 Iritis	49
2.2.4.3 Indentation gonioscopy	49
2.2.4.4 Optic disc appearances and visual field examination	49
2.2.4.5 Provocation tests	50
2.2.4.6 Posterior synechiae	50
2.2.5 Endothelial cell density measurement	50
2.2.6 Corneal pachymetry	51
2.2.7 Iridotomy area measurement	52
2.2.7.1 Calibration of iris measurements	52
2.2.8 Effect of pupil dilation on iridotomy position, shape and area	54

2.3 Statistical analysis	58
<b>CHAPTER 3.</b>	
<b>A RETROSPECTIVE ANALYSIS OF THE OUTCOME OF OPERATIVE SURGERY PROCEDURES FOR ANGLE CLOSURE GLAUCOMA</b>	<b>59</b>
3.1 Summary	59
3.2 Introduction	60
3.3 Materials and methods	61
3.4 Statistical analysis	62
3.5 Results	62
3.5.1 Fellow eye	63
3.5.1.1 Operation	64
3.5.1.2 Operative complications	64
3.5.1.3 2-5 year outcome	65
3.5.1.3.1 Glaucoma outcome	65
3.5.1.3.2 Visual acuity outcome	65
3.5.2 Acute angle closure glaucoma	66
3.5.2.1 2-5 year outcome	70
3.5.2.1.1 Glaucoma outcome	70
3.5.2.1.2 Visual acuity outcome	71
3.5.3 Chronic angle closure glaucoma	72
3.5.4 Intermittent angle closure glaucoma	73
3.6 Discussion	73
3.6.1 Fellow eyes	74
3.6.2 Acute angle closure glaucoma eyes	75
3.6.3 Summary of results	77

## **CHAPTER 4.**

### **Nd:YAG LASER IRIDOTOMY IN FELLOW EYES.**

#### **A RANDOMISED, PROSPECTIVE COMPARISON OF ND:YAG LASER IRIDOTOMY AND OPERATIVE PERIPHERAL IRIDECTOMY IN THE FELLOW EYE OF PATIENTS WITH ACUTE ANGLE CLOSURE**

<b>GLAUCOMA</b>	78
4.1 Summary	78
4.2 Introduction	78
4.3 Materials and method	79
4.3.1 Operative Surgery	80
4.3.2 Laser treatment	80
4.3.3 Post treatment assessment	81
4.3.4 Follow up	82
4.3.5 Specular microscopy analysis	82
4.3.6 Statistical analysis	83
4.4 Results	83
4.4.1 Immediate post treatment assessment	85
4.4.2 Assessment 24 hours post treatment	86
4.4.3 1 month follow up	87
4.4.4 6 month follow up	88
4.4.5 Final follow up	90
4.5 Discussion	90
4.5.1 Acute angle closure glaucoma following prophylactic iridotomy or iridectomy	90
4.5.2 Early post-treatment complications	91
4.5.3 Long term glaucoma outcome	94
4.5.4 Long term visual acuity outcome	95

4.6 Conclusion	95
<b>CHAPTER 5</b>	
<b>Nd:YAG LASER IRIDOTOMY IN ACUTE ANGLE CLOSURE GLAUCOMA</b>	
5.1 Summary	96
<b>CHAPTER 5a</b>	
<b>A PROSPECTIVE COMPARISON OF Nd:YAG LASER IRIDOTOMY, PERIPHERAL IRIDECTOMY AND TRABECULECTOMY IN THE TREATMENT OF ACUTE ANGLE CLOSURE GLAUCOMA</b>	
5a.1 Introduction	97
5a.2 Materials and methods	98
5a.2.1 Initial examination	98
5a.2.2 Peripheral iridectomy	99
5a.2.3 Trabeculectomy	100
5a.2.4 Nd:YAG laser iridotomy	100
5a.2.5 Post treatment assessment	101
5a.2.6 Follow up	101
5a.3 Results	102
5a.3.1 Corneal pachymetry results	105
5a.3.2 Duration of inpatient treatment	108
5a.3.3 Nd:YAG laser iridotomy	108
5a.3.4 Peripheral iridectomy	111
5a.3.5 Trabeculectomy	111
5a.3.6 Acute angle closure glaucoma	112
5a.3.7 Glaucoma outcome	113
5a.3.7.1 Gonioscopy	114

5a.3.7.2 Provocation tests	114
5a.3.7.3 Iridotomy area	115
5a.3.8 Visual acuity outcome	115
5a.3.9 Posterior synechiae	116
5.4 Discussion	117
5a.4.1 Corneal pachymetry	117
5a.4.2 Operative and early postoperative complications	118
5a.4.3 Acute angle closure glaucoma	118
5a.4.4 Glaucoma outcome	120
5a.4.5 Visual acuity outcome	121
<b>CHAPTER 5b</b>	
<b>COMPARISON OF ACUTE ANGLE CLOSURE</b>	
<b>GLAUCOMA EYES AND FELLOW EYES</b>	125
5b.1 Materials and methods	125
5b.2 Results	125
5b.2.1 Operative complications	126
5b.2.1.1 Nd:YAG laser iridotomy	126
5b.2.1.2 Operative peripheral iridectomy	126
5b.2.2 Follow up	126
5b.2.2.1 Glaucoma outcome	127
5b.2.2.2 Visual acuity outcome	127
5b.3 Discussion	127
<b>CHAPTER 6</b>	
<b>HOW LARGE MUST AN IRIDOTOMY BE?</b>	129
6.1 Summary	129
6.2 Introduction	129



6.3 Materials and methods	130
6.3.1 Case reports of acute angle closure glaucoma in the presence of a small patent Nd:YAG laser iridotomy.	130
6.3.2 Mathematical model of minimum effective iridotomy area	131
6.3.3 Photometric analysis of the effect of pupil dilation on iridotomy area	131
6.4 Results	132
Case reports	132
Mathematical model	137
Effect of pupil dilation on iridotomy area	140
6.5 Discussion	145
<b>CHAPTER 7</b>	
<b>CHRONIC ANGLE CLOSURE GLAUCOMA AND NARROW ANGLE GLAUCOMA</b>	151
<b>CHAPTER 7a</b>	
<b>CHRONIC ANGLE CLOSURE GLAUCOMA</b>	151
7a.1 Summary	151
7a.2 Introduction	151
7a.3 Materials and methods	152
7a.4 Results	153
7a.4.1 Nd:YAG laser iridotomy treatment parameters	154
7a.4.2 Follow up	154
7a.4.2.1 Glaucoma outcome	154
7a.4.2.1.1 Visual fields and optic discs	154

7a.4.2.1.2 Medication	155
7a.4.2.1.3 Intraocular pressure	155
7a.4.2.1.4 Glaucoma control	155
7a.4.2.1.5 Gonioscopy	156
7a.4.2.2 Visual acuity outcome	156
7a.5 Discussion	157
7a.5.1 Glaucoma outcome	157
7a.5.2 Visual acuity outcome	159
<b>CHAPTER 7b</b>	
<b>NARROW ANGLE GLAUCOMA</b>	160
7b.1 Summary	160
7b.2 Introduction	160
7b.3 Materials and methods	161
7b.4 Results	162
7b.4.1 Glaucoma outcome	163
7b.4.2 Visual acuity outcome	163
7b.5 Discussion	164
<b>CHAPTER 8</b>	
<b>ARGON LASER PRETREATMENT PRIOR TO Nd:YAG</b>	
<b>LASER IRIDOTOMY</b>	165
8.1 Summary	165
8.2 Introduction	165
8.3 Materials and Methods	166
8.3.1 Argon laser pretreatment	167
8.3.2 Nd:YAG laser iridotomy	167
8.3.3 Follow up	168

8.4 Results	169
8.4.1 Initial examination	169
8.4.2 Treatment	171
8.4.3 Iris appearance following argon laser pretreatment	171
8.4.4 Nd:YAG laser iridotomy in the argon laser pretreatment site	175
8.4.5 Treatment parameters	178
8.4.6 Operative complications	178
8.4.7 Glaucoma outcome	179
8.4.8 Visual acuity outcome	181
8.5 Discussion	181

## **CHAPTER 9**

### **ND:YAG LASER IRIDOTOMY IN CHINESE PATIENTS.**

<b>A COMPARISON OF Nd:YAG AND ARGON LASER IRIDOTOMY IN CAUCASIAN AND CHINESE EYES</b>	185
9.1 Summary	185
9.2 Introduction	186
9.3 Materials and methods	187
9.3.1 Argon laser treatment	188
9.3.2 Nd:YAG laser treatment	188
9.4 Results	189
9.4.1 Argon laser iridotomy treatment results	191
9.4.2 Nd:YAG laser iridotomy treatment results	193
9.5 Discussion	195

<b>CHAPTER 10</b>	
<b>DISCUSSION AND CONCLUSIONS</b>	197
10.1 Is Nd:YAG laser iridotomy as effective as operative peripheral iridectomy ?	197
10.1.1 Acute angle closure glaucoma	197
10.1.2 Fellow eyes	198
10.1.3 Chronic angle closure glaucoma	199
10.2 Is Nd:YAG laser iridotomy as safe as operative peripheral iridectomy ?	199
10.2.1 Long term visual acuity outcome	199
10.2.2 Operative and early post operative complications	200
10.2.2.1 Cornea	200
10.2.2.2 Hyphaema	201
10.2.2.3 Early post treatment intraocular pressure elevation	201
10.2.2.4 Focal lens opacities	202
10.2.2.5 Iritis	203
10.2.2.6 Posterior synechiae	203
10.3 What is the optimal method of producing a Nd:YAG laser iridotomy ?	204
<b>PROJECTS CURRENTLY IN PROGRESS</b>	207
<b>RECENT DEVELOPMENTS IN THE LITERATURE</b>	208
<b>REFERENCES</b>	210
<b>COMMUNICATIONS FROM THESE STUDIES</b>	233

## DECLARATION OF ORIGINALITY

The studies reported in this thesis were conceived and carried out entirely by myself, with the help of several colleagues working under my direction as acknowledged below. This thesis is entirely my own work.



B W FLECK

10.4.92

## ACKNOWLEDGEMENTS

### FUNDING

Purchase of a Zeiss visulas Nd:YAG laser and Mackintosh Plus microcomputer used in this project was made possible using a grant from the Edinburgh Royal Infirmary Eye Research Endowment Fund. Dr A D Adams, Consultant Ophthalmologist, provided helpful advice in making this purchase.

A grant from the W H Ross Foundation provided salaries for a research technician and two clinical assistants, who staff a weekly iridotomy research clinic. The W H Ross Foundation also funded secretarial and photographic expenses incurred during the course of the project.

### PERSONNEL

The following colleagues took part in various stages of the project, and their contribution is gratefully acknowledged:

**Research technician and administrator :** Mrs C McGlynn.

**Research clinical assistants :** Dr E Fairley  
Dr E Wright

**Junior medical staff (Edinburgh) :** Dr B Dhillon  
Dr V Khanna  
Dr G McIntosh  
Dr P Koay  
Dr JMS McConnell

**(Singapore) :** Dr C Chaing  
Dr G Min  
Dr PK Wong  
Dr P Cheong

**Consultant supervision :**

Equipment purchase and iridotomy clinic	Dr A Adams
M D project	Dr JF Cullen
Singapore project	Dr ASM Lim

**Statistical advice** Ms Celia McIntyre, Dept. of Medical Statistics and Computing, University of Edinburgh.

**Mathematical modelling (chapter 6)**

**Photographs**

**Secretarial help**

Mr G Wetherill,  
Edinburgh  
Statistical Consultancy  
Service

Dr N A Fleck,  
Dept. Engineering  
Cambridge University

Mr S Thompson  
Mr S Gairns  
Mrs M Brannon

Mrs P Fleck  
Mrs M Marshall

## **ETHICAL APPROVAL**

Approval of each clinical study was obtained from the unit ethical committee. Approval to perform a randomised prospective comparison of Nd:YAG laser iridotomy and surgical peripheral iridectomy was obtained from the regional surgical subspecialties ethical committee. Informed patient consent was obtained prior to inclusion in any part of the study.



## LIST OF TABLES

TABLE	PAGE
<b>CHAPTER 1 : Introduction and literature review</b>	
1.1 Incidence of focal corneal opacities following argon laser iridotomy and Nd:YAG laser iridotomy.	14
1.2 Endothelial cell density change following operative or laser treatment of angle closure glaucoma.	16
1.3 Incidence of iris bleeding following argon and Nd:YAG laser iridotomy.	17
1.4 Incidence of iritis following operative or laser treatment of angle closure glaucoma.	18
1.5 Prevalence of posterior synechiae following laser or operative treatment of angle closure glaucoma.	19
1.6 Incidence of iridotomy reclosure.	20
1.7 Early post treatment intraocular pressure elevation.	21
1.8 Incidence of focal lens opacities following argon and Nd:YAG laser iridotomy.	22
1.9 Posterior segment complications following operative or laser treatment for angle closure glaucoma.	23
1.10 Long term glaucoma outcome following acute angle closure glaucoma.	25
1.11 Long term glaucoma outcome in fellow eyes.	26
1.12 Long term visual acuity outcome following acute angle closure glaucoma.	27
1.13 Long term visual acuity outcome in fellow eyes.	28
1.14 Glaucoma outcome following operative or laser treatment of chronic angle closure glaucoma.	30
1.15 Visual acuity outcome following operative or laser treatment of chronic angle closure glaucoma.	31
1.16 Wavelengths of laser energy produced by commonly used laser media.	32
1.17 Characteristics of an ophthalmic Q-switched Nd:YAG laser.	33
1.18 Less common indications for the use of the Q-switched Nd:YAG laser.	35
<b>CHAPTER 2 : Material and methods</b>	
2.1 Calibration of measurements of iridotomy diameter.	53

**CHAPTER 3 : A Retrospective analysis of the outcome of operative surgery procedures for angle closure glaucoma.**

3.1	Retrospective study of angle closure glaucoma. Diagnostic categories.	63
3.2	Retrospective study of angle closure glaucoma. Patients undergoing peripheral iridectomy in the fellow eye - initial findings.	64
3.3	Retrospective study of angle closure glaucoma. Assessment at presentation. Acute angle closure glaucoma.	67
3.4	Retrospective study of angle closure glaucoma. Assessment after initial medical control. Acute angle closure glaucoma.	68
3.5	Retrospective study of angle closure glaucoma. Operative complications. Acute angle closure glaucoma.	69
3.6	Retrospective study of angle closure glaucoma. Complications during the first week following operation. Acute angle closure glaucoma.	69
3.7	Retrospective study of angle closure glaucoma. Glaucoma outcome 2-5 years following treatment. Acute angle closure glaucoma.	70
3.8	Retrospective study of angle closure glaucoma. Causes of reduced visual acuity 2-5 years following treatment of acute angle closure glaucoma.	71
3.9	Retrospective study of angle closure glaucoma. Causes of loss of 2 or more lines of visual acuity after 2-5 years follow up. Acute angle closure glaucoma.	72

**CHAPTER 4 : A randomised, prospective comparison of Nd:YAG laser iridotomy and operative peripheral iridectomy in the fellow eye of patients with acute angle closure glaucoma.**

4.1	Prospective comparison of operative peripheral iridectomy and Nd:YAG laser iridotomy in fellow eyes. Patient groups.	84
4.2	Prospective comparison of operative peripheral iridectomy and Nd:YAG laser iridotomy in fellow eyes. Initial assessment.	84
4.3	Prospective comparison of operative peripheral iridectomy and Nd:YAG laser iridotomy in fellow eyes. Examination 24 hours following treatment.	86
4.4	Prospective comparison of operative peripheral iridectomy and Nd:YAG laser iridotomy in fellow eyes. Examination 6 months following treatment.	88

4.5	Prospective comparison of operative peripheral iridectomy and Nd:YAG laser iridotomy in fellow eyes. Corneal endothelium cell density.	89
<b>CHAPTER 5 : Nd:YAG laser iridotomy in acute angle closure glaucoma.</b>		
5.1	Prospective study of the treatment of acute angle closure glaucoma. Patient groups.	103
5.2	Prospective study of the treatment of acute angle closure glaucoma. Initial examination.	103
5.3	Prospective study of the treatment of acute angle closure glaucoma. Examination after initial medical control.	104
5.4	Prospective study of the treatment of acute angle closure glaucoma. Serial intraocular pressure and pachymetry measurements following acute angle closure glaucoma.	106
5.5	Prospective study of the treatment of acute angle closure glaucoma. Comparison of acute and fellow eyes - initial characteristics.	125
<b>CHAPTER 6 : How large must an iridotomy be ?</b>		
6.1	Photometric analysis of change in iridotomy area on dilating the pupil.	142
6.2	Changes in iridotomy shape on dilating the pupil.	144
6.3	Distance of iridotomies from the limbus before and after dilating the pupil.	145
<b>CHAPTER 7 : Chronic angle closure glaucoma &amp; narrow angle glaucoma.</b>		
7.1	Chronic angle closure glaucoma. Examination at presentation.	153
7.2	Chronic angle closure glaucoma. Nd:YAG laser iridotomy treatment parameters and early complications.	154
7.3	A comparison of Nd:YAG laser treatment parameters and complication rates in fellow eyes and chronic angle closure glaucoma eyes.	157
7.4	Narrow angle glaucoma - initial assessment.	162
<b>CHAPTER 8 : Argon laser pretreatment prior to Nd:YAG laser iridotomy.</b>		
8.1	Argon laser pretreatment prior to Nd:YAG laser iridotomy. Patients age/sex distribution and diagnosis.	169

8.2	Argon laser pretreatment prior to Nd:YAG laser iridotomy. Glaucoma examination prior to iridotomy and glaucoma outcome	170
8.3	Argon laser pretreatment prior to Nd:YAG laser iridotomy. Number of laser pulses and total energy used in treatment.	178
8.4	Argon laser pretreatment prior to Nd:YAG laser iridotomy. Inferior trabecular meshwork pigmentation 6 months following treatment.	180
8.5	Argon laser pretreatment prior to Nd:YAG laser iridotomy. Iridotomy area, and the area of the surrounding pigment epithelium defect	180

**CHAPTER 9 : Nd:YAG laser iridotomy in Chinese patients – a comparison of Nd:YAG and argon laser iridotomy in Caucasian and Chinese eyes.**

9.1	Argon and Nd:YAG laser iridotomy in Chinese and Caucasian eyes. Patient groups.	189
9.2	Argon and Nd:YAG laser iridotomy in Chinese and Caucasian eyes. Indications for laser iridotomy.	190
9.3	Argon and Nd:YAG laser iridotomy in Chinese and Caucasian eyes. Iris colour.	190
9.4	Argon laser iridotomy in Chinese and Caucasian eyes. Treatment parameters.	191
9.5	Argon iridotomy in Chinese and Caucasian eyes. Patency and reclosure rates.	191
9.6	Argon laser iridotomy in Chinese and Caucasian eyes. Number of laser pulses and total energy used.	192
9.7	Nd:YAG laser iridotomy in Chinese and Caucasian eyes. Patency and reclosure rates.	193
9.8	Nd:YAG laser iridotomy in Chinese and Caucasian eyes. Number of laser pulses and total energy used.	194

## LIST OF FIGURES

FIGURE	PAGE
<b>CHAPTER 1 : Introduction and literature review</b>	
1.1 Tissue damage produced by shock waves and acoustic waves following Nd:YAG laser iridotomy.	7
1.2 Optimum position for Nd:YAG laser iridotomy.	7
1.3 Nd:YAG laser iridotomy position too central - lens damage.	8
1.4 Nd:YAG laser iridotomy position too peripheral - corneal damage	8
<b>CHAPTER 2 : Materials and methods</b>	
2.1 Nd:YAG laser iridotomy. Grade ++ corneal damage.	48
2.2 Specular micrograph of the corneal endothelium 6 months following Nd:YAG laser iridotomy.	51
2.3 Calculation of the surface area of an ellipse.	52
2.4 Photometric analysis of the effect of pupil dilation on iridotomy area.	56-57
<b>CHAPTER 3 : A Retrospective analysis of the outcome of operative surgery procedures for angle closure glaucoma.</b>	
3.1 Retrospective study of operative peripheral iridectomy in the fellow eye. Distribution of visual acuity change between initial presentation and 2-5 year follow up.	66
<b>CHAPTER 4 : A randomised, prospective comparison of Nd:YAG laser iridotomy and operative peripheral iridectomy in the fellow eye of patients with acute angle closure glaucoma.</b>	
4.1 Early post-treatment intraocular pressure changes in fellow eyes following operative peripheral iridectomy and Nd:YAG laser iridotomy.	85
<b>CHAPTER 5 : Nd:YAG laser iridotomy in acute angle closure glaucoma.</b>	
5.1 Prospective study of the treatment of acute angle closure glaucoma. Intraocular pressure following initial medical control, corneal pachymetry study.	107

5.2	Prospective study of the treatment of acute angle closure glaucoma. Central corneal thickness following initial medical control of acute angle closure glaucoma.	108
5.3	Hyphaema following Nd:YAG laser iridotomy in an eye with controlled acute angle closure glaucoma.	110

**CHAPTER 6 : How large must an iridotomy be ?**

6.1	How large must an iridotomy be to prevent acute angle closure glaucoma? Case 2. Initial iridotomy size too small.	134
6.2	How large must an iridotomy be to prevent acute angle closure glaucoma? Case 2. Iridotomy of adequate size.	136
6.3	Pressure difference across the iris as a function of iridotomy area.	140
6.4	Change in iridotomy area as a function of change in iris area on dilating the pupil.	143

**CHAPTER 8 : Argon laser pretreatment prior to Nd:YAG laser iridotomy.**

8.1	Argon laser pretreatment site in a grey iris immediately following treatment.	171
8.2	Argon laser pretreatment site in a grey iris 28 days after treatment.	172
8.3	Argon laser pretreatment site in a brown iris 42 days following treatment.	173
8.4	Nd:YAG laser iridotomy in an argon laser pretreatment site 9 months after treatment.	174
8.5	Primary Nd:YAG laser iridotomy 3 months after treatment.	174
8.6	Nd:YAG laser iridotomy in an argon laser pretreatment site 3 months after argon laser treatment.	175
8.7	Nd:YAG laser iridotomy in an argon laser pretreatment site 4 months after argon laser treatment.	176
8.8	Argon laser pretreatment site in a grey iris 56 days after treatment.	177

## **ABSTRACT**

A series of clinical studies evaluating the role of Nd:YAG laser iridotomy in the management of angle closure glaucoma were undertaken.

Baseline data on the outcome of peripheral iridectomy or drainage surgery in 137 consecutive patients presenting with acute angle closure glaucoma during the period 1980 to 1985 was obtained.

A prospective, randomised comparison of Nd:YAG laser iridotomy and peripheral iridectomy was performed in 52 fellow eyes, with a mean follow up period of 11.8 months. There was no significant change in endothelial cell count 6 months after treatment in either group. There were no significant differences in the visual acuity or glaucoma outcome of the two groups. One laser patient developed acute angle closure glaucoma.

A non randomised prospective comparison of Nd:YAG laser iridotomy, peripheral iridectomy and trabeculectomy was performed in 54 eyes with acute angle closure glaucoma. The mean total Nd:YAG laser energy needed to create an iridotomy was greater in acute angle closure glaucoma eyes than in fellow eyes. Serial ultrasound pachymetry was used to measure the resolution of corneal oedema in 4 patients, in order to assess the optimal timing of Nd:YAG laser iridotomy. Two patients with a small patent Nd:YAG laser iridotomy developed acute angle closure glaucoma during the follow up period and this problem was investigated further. A mathematical model of the minimum area of iris opening needed to prevent angle closure glaucoma was developed. Photometric measurements of Nd:YAG laser iridotomy size before and after pupil

dilation were made in 16 eyes. Pilocarpine/phenylephrine provocation tests were performed in 47 eyes with a laser iridotomy, and 36 eyes with a peripheral iridectomy. These investigations suggested that the minimum "safe" iridotomy size is 150-200 $\mu$  diameter.

A prospective study of Nd:YAG laser iridotomy in 16 patients with chronic angle closure glaucoma showed improved glaucoma control in 7 patients.

The technique of argon laser pretreatment followed by Nd:YAG laser iridotomy 4-6 weeks later was assessed in 10 patients. Argon laser pretreatment was performed in the right eye, and primary Nd:YAG laser iridotomy in the left eye. The mean total Nd:YAG laser energy needed to produce a patent iridotomy was significantly greater in pretreated eyes, and considerable pigment dispersion occurred at the time of Nd:YAG laser iridotomy in pretreated eyes.

A comparison of argon laser iridotomy and Nd:YAG laser iridotomy was made in a group of 33 Chinese patients in Singapore and 25 Caucasian patients in Edinburgh. Qualitative differences in iris tissue responses to laser energy were noted.



## CHAPTER 1

### INTRODUCTION AND LITERATURE REVIEW

#### 1.1 INTRODUCTION

Argon<sup>1</sup> and Nd:YAG<sup>2</sup> laser iridotomy have already largely superseded surgical peripheral iridectomy<sup>3</sup> in the treatment of angle closure glaucoma<sup>4</sup>. Laser surgery is more convenient and less costly than conventional surgery<sup>5</sup>. Rare but serious operative complications such as endophthalmitis, flat anterior chamber and malignant glaucoma are completely eliminated. However laser surgery should not be regarded as non invasive<sup>6</sup>. Corneal endothelium damage<sup>7-9</sup>, iris bleeding<sup>10-13</sup>, post-laser intraocular pressure elevation<sup>10,11,12,14</sup>, and focal lens damage<sup>14-17</sup> have been reported following Nd:YAG laser iridotomy. Laser iridotomy represents a return to small iris openings, such as those produced by surgical iridotomy<sup>18-20</sup>. Very small iris openings may not be as effective as larger openings in preventing iris bombé and angle closure glaucoma<sup>20,21</sup>.

Several studies have compared argon laser and Nd:YAG laser iridotomy<sup>10,13,22,23</sup>. Nd:YAG laser iridotomy requires less laser energy, produces fewer short term complications, and has a much lower rate of delayed iridotomy closure than argon laser iridotomy<sup>10,13,22,23</sup>. Late corneal decompensation has been reported following argon laser iridotomy<sup>24</sup>, but not following Nd:YAG laser iridotomy.

Nd:YAG laser iridotomy has not been compared with surgical peripheral iridectomy in a prospective study. Peripheral iridectomy is a remarkably "safe" operation, with few short or long term complications<sup>25</sup>. A series of studies comparing Q-switched Nd:YAG laser iridotomy and

operative peripheral iridectomy are reported in this thesis.

## **1.2 HISTORY OF THE USE OF LIGHT ENERGY TO PRODUCE IRIS OPENINGS**

Meyer-Schwickerath attempted to use xenon arc white light to produce iridotomies in 1956<sup>26</sup>. Zweng used a ruby laser to produce iris burns in rabbits in 1964<sup>27</sup>, and Perkins reported the results of ruby laser iridotomy in humans in 1971<sup>28</sup>. Argon laser iridotomy was introduced by Abraham in 1975<sup>1</sup>. Argon lasers were already widely available in ophthalmic departments for the treatment of retinal diseases, and argon laser iridotomy rapidly became a popular alternative to surgical peripheral iridectomy<sup>1,29,30-33</sup>. Dye laser iridotomy was reported by Bass in 1979<sup>34</sup>.

These forms of light energy produce thermal destruction of tissue<sup>35</sup>. However high energy laser pulses of very short duration produce mechanical disruption of tissue –“photodisruption”<sup>35,36</sup>. Krasnov described Q switched ruby laser iridotomy in 1977<sup>37</sup>, and Frankhauser described Q switched Nd:YAG laser iridotomy in 1981<sup>2</sup>.

Q switched Nd:YAG laser iridotomy was found to produce a lower incidence of focal lens opacities and iridotomy re closure than argon laser iridotomy<sup>10,11,13,22,23</sup> and is now preferred to argon laser iridotomy<sup>13</sup>.

## **1.3 HISTORY OF SURGICAL OPERATIONS FOR ANGLE CLOSURE GLAUCOMA**

Empirical surgical management of angle closure glaucoma by broad iridectomy, introduced by Von Graefe in 1857<sup>38</sup>, pre dated an understanding of the mechanism of action of surgery by many years.

In fact the pathogenesis of angle closure glaucoma was in part elucidated by observing the effects of surgery. Curran noted deepening of the anterior chamber following surgical iridotomy, and suggested that some forms of glaucoma are due to obstruction of aqueous flow through the pupil by the iris "hugging the lens over too great an extent" <sup>18</sup>. Barkan emphasised a gonioscopic classification of glaucoma, and described widening of the drainage angle following broad iridectomy <sup>39</sup>. The action of iridectomy was to "short circuit relative pupillary block, with ensuing collapse of iris bombé" <sup>40</sup>.

Following Von Graefe's description of the broad iridectomy in 1857 <sup>38</sup> Pfluger described a more conservative form of surgery, the peripheral iridectomy, in 1893 <sup>41</sup> but the operation did not come into common use. Surgical iridotomy was introduced by Curran in 1920 <sup>18,19, 20</sup>, and it is interesting to note that the size and shape of iris openings produced by this operation were very similar to those obtained by Nd:YAG laser iridotomy <sup>21</sup>.

Chandler popularised the peripheral iridectomy during the 1950's<sup>3</sup>, and this operation became the preferred treatment of both acute <sup>25,42 - 46</sup> and chronic <sup>47 - 52</sup> forms of angle closure glaucoma.

#### **1.4 PATHOGENESIS OF ANGLE CLOSURE GLAUCOMA IN RELATION TO SURGICAL MANAGEMENT**

Chandler <sup>3</sup> and Barkan <sup>40</sup> recognised the role of pupil block in the pathogenesis of angle closure glaucoma. Increased resistance to aqueous flow through the pupil leads to iris bombé <sup>3,40</sup>. Iris bombé leads to iridocorneal contact <sup>53 - 55</sup> which initially occurs superiorly <sup>56</sup>. Peripheral Iridectomy <sup>57</sup>, or argon laser iridotomy <sup>58</sup> lead to an increase in peripheral anterior chamber depth, with no change in central anterior

chamber depth<sup>53,57,58</sup>. Iris bombé is relieved, with no change in the position of the lens. The rapid gush of aqueous into the anterior chamber which occurs at the moment of iris penetration during Nd:YAG laser iridotomy confirms the concept that a therapeutic iris opening bypasses relative pupil block. The minimum size of iris opening needed to equilibrate anterior and posterior chamber pressures has not been defined.

Pupil block forces are primarily dependent on the position of the anterior lens surface in relation to the iris - central anterior chamber depth, and on the tone of the dilator and sphincter muscles of the iris. Patients with a central anterior chamber depth of less than 2.5 mm are at risk of developing angle closure glaucoma<sup>59</sup>. Shallow anterior chambers are found in : hypermetropes<sup>60</sup>; the elderly, due to continued increase in lens thickness throughout life<sup>60-63</sup>; and females, who have a 4% shallower anterior chamber than males<sup>60</sup>.

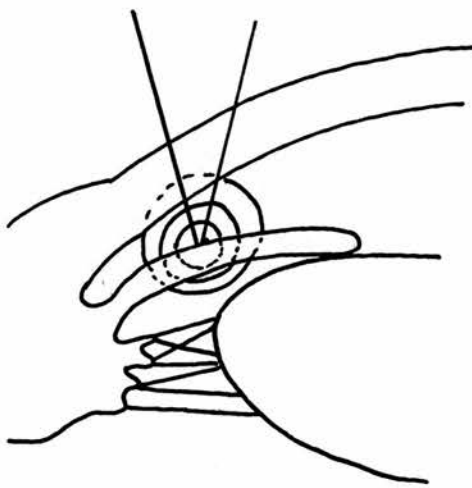
The effect of iris muscle tone on pupil block forces has been extensively investigated by Mapstone using pharmacological methods<sup>64-72</sup>. However abnormalities of iris muscle tone in naturally occurring angle closure glaucoma have not been defined. Mapstone found an increased prevalence of diabetes mellitus among angle closure glaucoma patients<sup>73</sup>.

The degree of iris bombé, and therefore peripheral anterior chamber depth and narrowness of the angle, is dependent on the pupil block force, and iris tone. Peripheral anterior chamber depth shows a diurnal variation, and is shallowest in the evenings<sup>74</sup>.


The relative positions of the cornea, iris and lens are important in choosing a safe site at which to perform a laser iridotomy. Mechanical shock waves produced at the point of laser focus radiate outwards and

may damage nearby tissues, notably the lens and corneal endothelium (Figure 1.1). Eyes with angle closure glaucoma have a shallow central anterior chamber depth<sup>59,61</sup> increasing the risk of lens damage, and a shallow peripheral anterior chamber depth<sup>57,58,61</sup>, increasing the risk of corneal endothelium damage.


An iridotomy is best performed approximately 2/3 way from the edge of the pupil to the iris base<sup>11</sup> (Figure 1.2). An iridotomy performed too close to the pupil edge may result in lens damage (Figure 1.3). An iridotomy performed too peripherally may result in corneal endothelium damage (Figure 1.4).




**Figure 1.1**  
Tissue damage produced  
by shock waves and acoustic  
waves following Nd:YAG laser  
iridotomy



**Figure 1.2**  
Optimum position for  
Nd:YAG laser iridotomy



**Figure 1.3**  
**Nd:YAG laser iridotomy**  
**position too central -**  
**lens damage**



**Figure 1.4**  
**Nd:YAG laser iridotomy**  
**position too peripheral -**  
**corneal damage**

Figures 1.1-1.4 modified from Schwartz et al <sup>11</sup>.

## **1.5 FORMS OF ANGLE CLOSURE GLAUCOMA IN RELATION TO SURGICAL MANAGEMENT**

The distribution of clinical presentations of angle closure glaucoma in Britain has been documented by Leighton <sup>75</sup>. 50.6% of cases were acute or subacute, 31.2% chronic, 7.8% intermittent, 6.5% associated with central retinal vein occlusion, thrombotic glaucoma or absolute closed-angle glaucoma, and 3.9% induced by mydriatic eye drops <sup>75</sup>.

The term "angle closure glaucoma" encompasses a spectrum of diseases which vary in clinical presentation and response to medical and surgical treatment.

### **1.5.1 ACUTE ANGLE CLOSURE GLAUCOMA**

The acute rise in intraocular pressure which occurs in acute angle

closure glaucoma causes oedema and ischaemia of a number of ocular structures. Surprisingly the duration of acute attack prior to medical control has not been demonstrated to affect the eventual glaucoma outcome following peripheral iridectomy<sup>25</sup>. However, prompt medical control may be expected to minimise ischaemic damage of the corneal endothelium<sup>76,77,78</sup> iris, lens and optic nerve head, and limit goniosynechiae formation. Acutely raised intraocular pressure leads to iris sphincter ischaemia, mydriasis, and a poor response to miotics<sup>78</sup>. Oral or intravenous acetazolamide, followed by one drop of Pilocarpine 2% three hours later will control most episodes of acute angle closure glaucoma<sup>79</sup>. Strong miotics may in fact precipitate acute angle closure glaucoma<sup>42,80</sup>.

#### **1.5.1.1 CORNEA**

Corneal oedema normally clears within 2-12 days of initial medical control of acute angle closure glaucoma<sup>76</sup>. However, permanent structural damage occurs during an acute attack, the severity of which is related to the duration of the attack<sup>76,77,81</sup>. Corneal sensation is reduced<sup>77</sup> and endothelial cell density is reduced<sup>76,81,82,83</sup>. Measurements of endothelial cell density made in acute angle closure glaucoma eyes following medical control of intraocular pressure, but prior to surgery, have shown a cell density 33%<sup>76</sup> and 9.7%<sup>81</sup> lower than that in the fellow eye. Surgical<sup>81,82</sup> and argon laser<sup>10</sup> treatment can further reduce endothelial cell density, and bullous keratopathy has been reported following argon laser iridotomy<sup>24</sup>.

#### **1.5.1.2 IRIS**

Sector iris atrophy may occur due to ischaemic damage during an

episode of acute angle closure glaucoma<sup>84</sup>. Oedema of the iris stroma is often seen for several days following an acute attack.

### **1.5.1.3 LENS**

A variety of lens changes may be seen following an episode of acute angle closure glaucoma<sup>85</sup>. Glaukomflecken are typical, in addition to anterior capsular, cortical and nuclear cataract. Following surgical treatment it may be difficult to differentiate cataract caused by acute angle closure glaucoma from cataract caused by surgery. However in studies of patients in which both the acute and fellow eye have been treated by peripheral iridectomy, cataract has been found more frequently in the acute eye on follow up<sup>25,43,46,86,87</sup>. Acute angle closure glaucoma per se causes cataract.

### **1.5.1.4 TRABECULAR MESHWORK**

Indentation gonioscopy has been used to differentiate appositional angle closure from goniosynechiae prior to surgery<sup>88,89,90</sup>. Normal intraocular pressure without medication is much less likely to occur following peripheral iridectomy if extensive goniosynechiae are present<sup>51,88,89</sup>. However even in the absence of goniosynechiae, eyes which have had acute angle closure glaucoma have a higher intraocular pressure and lower outflow facility than contralateral fellow eyes<sup>91</sup>. Primary trabecular meshwork damage occurs during acute angle closure glaucoma, in addition to goniosynechiae development.

### **1.5.1.5 OPTIC DISC**

Ischaemic damage of the optic disc may occur rapidly during an episode of acute angle closure glaucoma<sup>92</sup>. Optic disc pallor is seen



more frequently than glaucomatous cupping following acute angle closure glaucoma, and may be associated with profound visual loss<sup>92</sup>. Visual field loss and colour vision defects following acute angle closure glaucoma are more in keeping with ischaemic optic neuropathy than glaucomatous damage<sup>93</sup>. The visual evoked potential is abnormal following acute angle closure glaucoma<sup>94</sup>.

Ischaemic optic disc damage during acute angle closure glaucoma appears to increase susceptibility to subsequent glaucomatous damage due to raised intraocular pressure. Optic disc cupping and visual field loss can develop very rapidly following peripheral iridectomy if the intraocular pressure remains elevated<sup>25</sup>.

### **1.5.2 INTERMITTENT (SUBACUTE) ANGLE CLOSURE GLAUCOMA**

The term "intermittent" and "subacute" angle closure glaucoma have generally been used to describe mild, self limiting episodes of acute angle closure glaucoma. Patients report episodes of pain, blurred vision or haloes. Between episodes gonioscopy may show the angle partly closed by apposition, or open but very narrow. However optic disc cupping or visual field loss occurs in less than 10% of cases<sup>49</sup>. The success of surgical treatment must be measured by resolution of symptoms, as these eyes usually have a normal intraocular pressure, optic disc appearance and visual field prior to operation.

### **1.5.3 CHRONIC ANGLE CLOSURE GLAUCOMA**

Mild degrees of pupil block may fail to precipitate acute angle closure glaucoma. Gradual closure of the angle by iridocorneal apposition<sup>47</sup> beginning superiorly<sup>56</sup> may lead to chronically raised intraocular

pressure, with optic disc cupping and glaucomatous visual field loss <sup>47</sup>.

Prior to iridectomy appositional angle closure may be differentiated from synechial closure by the response to miotics <sup>47,54</sup>, or by indentation gonioscopy <sup>88,89</sup>. Iridectomy eliminates appositional closure, but synechial closure will persist <sup>51</sup>. There has been some debate as to whether synechiae develop by anterior spread onto the trabecular meshwork - "creeping" angle closure glaucoma <sup>48</sup>, or following initial iridocorneal apposition, beginning superiorly <sup>53</sup>. Synechial closure of more than 80% of the circumference of the trabecular meshwork is frequently associated with advanced glaucomatous visual field loss <sup>89</sup>.

The presence of extensive goniosynechiae <sup>49,51,89,95</sup>, optic disc cupping <sup>49,95</sup> or visual field loss <sup>49,52,89,95</sup> reduce the likelihood of successful glaucoma control by peripheral iridectomy alone. The intraocular pressure with medication, and the presence or absence of visual field loss prior to operation, have a greater predictive value than optic disc cupping or the extent of goniosynechiae <sup>95</sup>.

Chronic angle closure glaucoma is often an asymmetrical disease, and one eye may show no glaucomatous changes at the time of presentation <sup>48,75</sup>.

## **1.6 RACIAL DIFFERENCES**

Race has a marked effect on both the prevalence of angle closure glaucoma in a community, and the behaviour of angle closure glaucoma when it does occur.

Angle closure glaucoma is more common than open angle glaucoma in Chinese <sup>96,97</sup> and Eskimo <sup>98,99</sup> populations. While acute angle closure glaucoma is more common than chronic angle closure glaucoma in Caucasians <sup>75</sup>, the converse is found in Negro populations <sup>100</sup>.

## **1.7 OUTCOME OF TREATMENT**

The outcome of a laser or operative surgery procedure for angle closure glaucoma may be measured in four ways:

1. Operative and early postoperative complications
2. Prevention of acute angle closure glaucoma
3. Long term glaucoma outcome
4. Long term visual acuity outcome

Various types of angle closure glaucoma have been included together in assessing the outcome of a treatment in some studies<sup>9,11 15,22,23,30,95,101-109</sup>. This approach is not entirely valid. Acute angle closure glaucoma eyes might be expected to have more operative complications and a less satisfactory visual acuity and glaucoma outcome than fellow eyes. The glaucoma outcome of chronic angle closure glaucoma eyes might be expected to be less satisfactory than that of fellow eyes. In assessing a treatment the nature of the disease under study must be carefully defined, in this case the form of angle closure glaucoma present.

### **1.7.1 OPERATIVE AND EARLY POSTOPERATIVE COMPLICATIONS**

Complications following operative surgery or laser treatment for angle closure glaucoma may or may not influence the visual acuity or glaucoma outcome. While the overall incidence of complications related to a procedure is of interest, only those complications which cause significant morbidity or alter the long term outcome need influence the choice of preferred procedure for routine clinical use.

The most serious complications of surgical iridectomy are malignant (ciliary block) glaucoma, and endophthalmitis. While these complications do not occur following laser iridotomy, they are extremely rare following peripheral iridectomy performed using modern microsurgical techniques.

The most frequently reported operative and early postoperative complications following peripheral iridectomy, argon laser iridotomy and Nd:YAG laser iridotomy are shown in Tables 1.1-1.9. The majority of reports refer to findings in chronic angle closure glaucoma eyes, and fellow eyes.

Table 1.1 shows the reported incidence of focal corneal opacities following argon and Nd:YAG laser iridotomy.

Author	Incidence of corneal opacities
<b>Argon Laser Iridotomy</b>	
Robin <sup>10</sup>	5/20 (5%)
McAllister <sup>22</sup>	2/25 (8%)
Del Priore <sup>13</sup>	11/43 (26%)
Podos <sup>30</sup>	4/45 (9%)
Quigley <sup>33</sup>	"almost all"
Pollock <sup>110</sup>	5/21 (24%)
<b>Nd:YAG Laser Iridotomy</b>	
Robin <sup>10</sup>	7/20 (35%)
McAllister <sup>22</sup>	2/25 (8%)
Del Priore <sup>13</sup>	13/43 (30%)
Robin <sup>111</sup>	11/44 (25%)
Schwartz <sup>11</sup>	7/182 (4%)
Naveh <sup>14</sup>	3/40 (7.5%)
Gray <sup>80</sup>	5/40 (12.5%)

**TABLE 1.1**  
**Incidence of focal corneal opacities following argon laser iridotomy and Nd:YAG laser iridotomy**

Short duration burn argon laser iridotomy has been found to cause fewer corneal opacities than long duration burn iridotomy. <sup>103,112</sup>.

A persisting corneal opacity has been reported in one eye following argon laser iridotomy <sup>1</sup>, and in one eye following Nd:YAG laser iridotomy <sup>14</sup>. Iridocorneal adhesions overlying the treatment site have been reported in three eyes following Nd:YAG laser iridotomy <sup>14</sup>.

Localised stripping of Descemet's membrane has been reported in 3/110 (3%) eyes following operative peripheral iridectomy <sup>101</sup>, but focal corneal opacities have not been reported.

Table 1.2 shows reported endothelial cell density change following operative peripheral iridectomy, argon laser iridotomy and Nd:YAG laser iridotomy. Most studies have found no significant change in endothelial cell density following treatment. However the number of eyes included in these studies has been small, ranging from 4 - 28 eyes (Table 1.2). Borderline reduction in cell density following argon laser iridotomy was reported by Robin and Pollack <sup>10</sup>, and following peripheral iridectomy by Setälä <sup>81</sup>. Bullous Keratopathy has been described following argon laser iridotomy <sup>24</sup> but not following peripheral iridectomy or Nd:YAG laser iridotomy.

Author	Percentage decrease in endothelial cell density	Number of eyes
<b>Peripheral iridectomy</b>		
Korey <sup>113</sup>	NS	8
Markowitz <sup>82</sup>	NS	24
Setala <sup>81</sup>	4.8±3.8%	25
Wishart <sup>8</sup>	NS	4
<b>Argon Laser Iridotomy</b>		
Robin <sup>10</sup>	8±7%	17
Smith <sup>114</sup>	NS	28
<b>Nd:YAG Laser Iridotomy</b>		
Robin <sup>10</sup>	NS	17
Wishart <sup>8</sup>	NS	6
Schrems <sup>115</sup>	NS	18

**TABLE 1.2**  
**Endothelial cell density change following operative or laser treatment of angle closure glaucoma**

NS = Not Significant

Table 1.3 shows the reported incidence of microscopic iris bleeding following argon laser iridotomy and Nd:YAG laser iridotomy. Iris bleeding is very unusual following argon laser iridotomy, but has been reported in 15-90% of eyes following Nd:YAG laser iridotomy. Macroscopic hyphaema has been reported in four cases following Nd:YAG laser iridotomy <sup>12,15,116</sup>. Macroscopic hyphaema following peripheral iridectomy has been reported in 5/103 (5%) cases by Douglas <sup>117</sup> and 8/110 (7%) cases by Luke <sup>101</sup>.

Author	Iris bleeding
<b>Argon Laser Iridotomy</b>	
Hodes <sup>118</sup>	1 patient
Mishima <sup>112</sup>	1 patient
<b>Nd:YAG Laser Iridotomy</b>	
Haut <sup>107</sup>	90/100 (90%)
Wise <sup>12</sup>	19/30 (63%)
Del Priore <sup>13</sup>	19/43 (44%)
Gray <sup>80</sup>	6/40 (15%)
Robin <sup>111</sup>	23/44 (52%)
McAllister <sup>22</sup>	7/25 (28%)
Moster <sup>23</sup>	13/38 (34%)
Naveh <sup>14</sup>	8/40 (20%)
Robin <sup>10</sup>	9/20 (45%)
Schwartz <sup>11</sup>	36/182 (20%)
Pollock <sup>110</sup>	10/21 (48%)

**TABLE 1.3**  
**Incidence of iris bleeding following argon and Nd:YAG laser iridotomy**

Table 1.4 shows the incidence of iritis following argon laser iridotomy, Nd:YAG laser iridotomy and operative peripheral iridectomy. While definitions of significant iritis vary, the comparative studies of Moster <sup>23</sup> and McAllister <sup>22</sup> both found a lower incidence of iritis following Nd:YAG laser iridotomy than argon laser iridotomy.

Author	Definition of iritis	Incidence
<b>Argon Laser Iridotomy</b>		
Moster <sup>23</sup>	Flare or cells	4/38 (11%)
McAllister <sup>22</sup>	-	3/25 (12%)
<b>YAG Laser Iridotomy</b>		
Moster <sup>23</sup>	Flare or cells >1 week	1/38 (3%)
McAllister <sup>22</sup>	-	1/25 (4%)
Schwartz <sup>11</sup>	-	21/182 (12%)
<b>Peripheral Iridectomy</b>		
Luke <sup>101</sup>	Flare or cells >2 weeks	2/28 (7%)

**TABLE 1.4**  
**Incidence of iritis following operative or laser treatment of angle closure glaucoma**

Table 1.5 shows the reported prevalence of posterior synechiae following argon laser iridotomy, Nd:YAG laser iridotomy and operative peripheral iridectomy. Posterior synechiae may have been under-reported in some studies <sup>23,30</sup> as synechiae may only be reliably detected if the pupil is dilated. Laser iridotomy appears to cause fewer posterior synechiae than peripheral iridectomy. Posterior synechiae are particularly likely to develop when miotics are used in the presence of a patent iridectomy <sup>119</sup>. Cataracts are more prevalent in eyes with posterior synechiae <sup>87</sup>.



Author	Incidence
<b>Argon Laser Iridotomy</b>	
Moster <sup>23</sup>	2/38 (5.2%)
Podos <sup>30</sup>	2/45 (4%)
Abraham <sup>1</sup>	3/22 (14%)
<b>Nd:YAG Laser Iridotomy</b>	
Moster <sup>23</sup>	1/38 (2.7%)
<b>Peripheral Iridectomy</b>	
Phillips <sup>120</sup> (acute ACG)	21/63 (33%)
Floman <sup>87</sup> (acute ACG)	40/70 (57%)
Floman <sup>87</sup> (fellow eye)	60/155 (39%)
Phillips <sup>119</sup> (mixed diagnoses)	20/63 (32%)

**TABLE 1.5**  
**Prevalence of posterior synechiae following laser or operative treatment of angle closure glaucoma**

Table 1.6 shows the incidence of iridotomy closure following a period of initial patency. While closure occurs in 15-20% of cases following argon laser iridotomy, it is very unusual following Nd:YAG laser iridotomy.

Author	Incidence iridotomy reclosure
<b>Argon Laser Iridotomy</b>	
McAllister <sup>22</sup>	5/25 (20%)
Moster <sup>23</sup>	6/38 (10%)
Wise <sup>12</sup>	1/30 (3%)
Del Priore <sup>13</sup>	9/43 (21%)
Harrad <sup>105</sup>	2/47 (4%)
Podos <sup>30</sup>	10/45 (22%)
<b>Nd:YAG Laser Iridotomy</b>	
McAllister <sup>22</sup>	1/25 (4%)
Moster <sup>23</sup>	0/38
Wise <sup>12</sup>	0/30
Del Priore <sup>13</sup>	0/43
Schwartz <sup>11</sup>	0/200
Gray <sup>80</sup>	1/40 (2.5%)
Naveh <sup>14</sup>	4/40 (10%)
Brazier <sup>106</sup>	1/27 (4%)
Wishart <sup>15</sup>	6/100 (6%)
<b>Peripheral Iridectomy</b>	
None	

**TABLE 1.6**  
**Incidence of iridotomy reclosure**

Table 1.7 shows the incidence of early post treatment intraocular pressure elevation following argon laser iridotomy and Nd:YAG laser iridotomy. A transient rise in intraocular pressure occurs in approximately 30% of patients with either form of treatment.

Author	Definition of elevation	Incidence of elevated IOP
<b>Argon Laser Iridotomy</b>		
McAllister <sup>22</sup>	>6 mm Hg rise	5/25 (20%)
Moster <sup>23</sup>	>8 mm Hg rise	13/38 (34%)
Robin <sup>10</sup>	>10 mm Hg rise	7/20 (35%)
Wise <sup>12</sup>	Mean elevation	8.6 mm Hg rise
Pollock <sup>110</sup>	>10 mm Hg rise	8/21 (38%)
<b>Nd:YAG Laser Iridotomy</b>		
McAllister <sup>22</sup>	>6 mm Hg rise	7/25 (28%)
Moster <sup>23</sup>	>8 mm Hg rise	12/38 (32%)
Robin <sup>10</sup>	>10 mm Hg rise	6/20 (30%)
Wise <sup>12</sup>	Mean elevation	7.3 mm Hg rise
Pollock <sup>110</sup>	>10 mm Hg rise	6/21 (29%)
Naveh <sup>14</sup>	>10 mm Hg rise	17/40 (42%)
Robin <sup>111</sup>	>6 mm Hg rise	9/44 (20%)
Schwartz <sup>11</sup>	>10 mm Hg rise	54/182 (30%)
Haut <sup>107</sup>	IOP >25 mm Hg	7/100 (7%)
Brazier <sup>106</sup>	>8 mm Hg rise	9/27 (33%)
<b>Peripheral Iridectomy</b>		
No reports		

**TABLE 1.7**

**Early post treatment intraocular pressure elevation**

Table 1.8 shows the reported incidence of focal lens opacities underlying argon and Nd:YAG laser iridotomy treatment sites. While focal lens opacities occur in up to 50% of cases following argon laser iridotomy, they are very rare following Nd:YAG laser iridotomy. Focal lens opacities have been reported to occur less frequently following short duration burn argon laser iridotomy than following long duration burn treatment <sup>103,105,112</sup>. Focal opacities involve the anterior capsule or anterior subcapsular area, and have not been reported to progress, or to influence visual acuity outcome. Focal lens opacities have not been reported following peripheral iridectomy.

Author	Focal lens opacities
<b>Argon Laser Iridotomy</b>	
Harrad <sup>105</sup>	21/47 (45%)
McAllister <sup>22</sup>	1/25 (4%)
Moster <sup>23</sup>	1/38 (3%)
Pollock <sup>110</sup>	9/21 (43%)
Del Priore <sup>13</sup>	23/43 (53%)
Podos <sup>30</sup>	2/45 (3%)
Robin <sup>10</sup>	7/20 (35%)
Wise <sup>12</sup>	9/30 (30%)
Yassur <sup>121</sup>	25/53 (47%)
Pollock <sup>31</sup>	11/33 (30%)
Abraham <sup>1</sup>	7/22 (32%)
Yamamoto <sup>103</sup> (Long Burn)	53/98(54%)
Yamamoto <sup>103</sup> (Short burn)	1/36(3%)
<b>Nd:YAG Laser Iridotomy</b>	
Berger <sup>17</sup>	1 case reported
Welch <sup>122</sup>	" " " "
Montgomery <sup>16</sup>	" " " "
Naveh <sup>14</sup>	" " " "
Wishart <sup>15</sup>	1 case
Haut <sup>107</sup>	2 cases
<b>Peripheral Iridectomy</b>	
None	

**TABLE 1.8**  
**Incidence of focal lens opacities following Argon and Nd:YAG laser iridotomy**

Table 1.9 shows posterior segment complications which have been reported following surgical or laser treatment for angle closure glaucoma. Several authors have advocated the use of an Abraham +66 dioptre contact lens to focus laser light on the iris and minimise retinal exposure during argon laser iridotomy <sup>123,124,125</sup>. "Plasma shielding" during Nd:YAG laser iridotomy minimises posterior segment irradiation <sup>37</sup> (see page 34). Nd:YAG laser optical breakdown in the vitreous produces

no measurable changes in vitreous structure <sup>126</sup>.

Author	Complication
<b>Argon laser iridotomy</b>	
Berger <sup>127</sup>	Foveal burn
Karmon <sup>128</sup>	Peripheral retinal burn
Pollock <sup>31</sup>	Peripheral retinal burn
<b>ND:YAG Laser Iridotomy</b>	
Karjalainen <sup>129</sup>	Serous retinal detachment
<b>Peripheral Iridectomy</b>	
None	

**TABLE 1.9**  
**Posterior segment complications following operative or laser treatment for angle closure glaucoma**

### **1.7.2 OPERATIVE AND EARLY POSTOPERATIVE COMPLICATIONS OF DRAINAGE SURGERY**

There have been few reports of primary drainage surgery for angle closure glaucoma. Wilson reported that 24/112 (21%) of chronic angle closure glaucoma eyes, 8/71 (11%) of acute angle closure glaucoma eyes and 22/126 (17%) of open angle glaucoma eyes undergoing trabeculectomy developed a shallow or flat anterior chamber during the early postoperative period <sup>130</sup>. 3/71 (4%) of eyes undergoing trabeculectomy for acute angle closure glaucoma developed a hyphaema <sup>130</sup>.

Watson reported that 13/424 (3%) of eyes undergoing trabeculectomy for a variety of indications developed a flat anterior chamber during the early postoperative period <sup>131</sup>.

### **1.7.3 PREVENTION OF ACUTE ANGLE CLOSURE GLAUCOMA**

Acute angle closure glaucoma following prophylactic peripheral iridectomy in fellow eyes, or therapeutic peripheral iridectomy in acutely affected eyes is very rare <sup>25,42,43,117</sup>. However a number of cases have been reported following argon laser iridotomy <sup>132,133</sup> and Q-switched Nd:YAG laser iridotomy <sup>15,80,106</sup>. Acute angle closure glaucoma has not been reported following primary drainage surgery.

### **1.7.4 LONG TERM GLAUCOMA OUTCOME**

The reported long term glaucoma outcome following treatment for acute angle closure glaucoma is shown in Table 1.10. Peripheral iridectomy results in normal intraocular pressure without additional topical medication in approximately 70% of cases. Primary drainage surgery appears to give a better glaucoma outcome <sup>130,134</sup>. The results following Nd:YAG laser iridotomy have been disappointing - 50% of cases were controlled by iridotomy alone in the study reported by Gray <sup>80</sup>.

Author	Follow up period	Glaucoma outcome - Normal IOP without medication
<b>Peripheral Iridectomy</b>		
Playfair <sup>25</sup>	1-12 years	58/81 (72%)
Krupin <sup>86</sup>	52 months (mean)	37/49 (76%)
Floman <sup>87</sup>	4.2 years (mean)	108/155 (70%)
Lowe <sup>43</sup>	at 5 years	12/17 (70%)
Williams <sup>46</sup>	0.5-16 years	83/120 (69.2%)
Ghoshal <sup>135</sup>	> 3 years	24/26 (92%)
Godel <sup>136</sup>	1-4 years	89/100 (89%)
Murphy <sup>44</sup>	21 months	28/46 (60.8%)
<b>Iridencleisis</b>		
Mackie <sup>134</sup>	0.5-8 years	106/110 (96.4%)
<b>Trabeculectomy</b>		
Wilson <sup>130</sup>	1-7 years	65/71 (93%)
<b>Nd:YAG Laser Iridotomy</b>		
Gray <sup>80</sup>	0.5-3 years	19/38 (50%)

**TABLE 1.10**  
**Long term glaucoma outcome following acute angle closure**  
**glaucoma**

Approximately 10% of fellow eyes develop raised intraocular pressure during long term follow up, as shown in table 1.11.

Author	Follow up period	Glaucoma outcome - IOP > 21mm Hg, or medication needed
<b>Peripheral Iridectomy</b>		
Playfair <sup>25</sup>	1-12 years	0/81 (0%)
Krupin <sup>86</sup>	52 months (mean)	5/40 (12%)
Floman <sup>87</sup>	4.2 years (mean)	24/70 (35%)
Lowe <sup>43</sup>	at 5 years	5/26 (19%)
Williams <sup>46</sup>	0.5-16 years	0/45 (0%)
Ghoshal <sup>135</sup>	> 3 years	1/29 (3%)
<b>Nd:YAG Laser Iridotomy</b>		
Tomey <sup>137</sup>	0.5-15 years	6/81 (7%) ("occludable angle" eyes)

**TABLE 1.11**  
**Long term glaucoma outcome in fellow eyes**

### 1.7.5 LONG TERM VISUAL ACUITY OUTCOME

Table 1.12 shows the reported long term visual acuity outcome following treatment for acute angle closure glaucoma. Approximately 20-30% of eyes develop significantly reduced visual acuity due to cataract development 2-5 years after peripheral iridectomy. The incidence may be higher following primary drainage surgery<sup>45</sup>. The cause of reduced visual acuity may be unclear in some eyes. While most authors attribute visual acuity loss primarily to cataract development<sup>25,43,45,46,86,87</sup>, others give greater significance to ischaemic damage sustained by the optic nerve head<sup>92</sup>.



Author	Follow up Period	Visual acuity outcome
<b>Peripheral Iridectomy</b>		
Playfair <sup>25</sup>	at 5 years	8/68 (12%) needed cataract operation (7 acute eyes, 1 fellow eye)
Krupin <sup>86</sup>	52 months (mean)	19/49 (39%) VA reduced $\geq$ 3 lines
Floman <sup>87</sup>	4.2 years (mean)	34/70 (51%) VA reduced $\geq$ 2 lines
Lowe <sup>43</sup>	at 5 years	5/26 (19%) had dense cataract
Sugar <sup>45</sup>	6.6 years	24/78 (30.7%) VA $\leq$ 6/18 due to cataract (acute and fellow eyes)
Williams <sup>46</sup>	0.5-16 years	6/86 (7%) VA reduced $\geq$ 3 lines
Luke <sup>101</sup>	4.4 years (mean)	8/36 (22%) had cataract
<b>Primary Drainage (Iridencleisis)</b>		
Mackie <sup>134</sup>	0.5-8 years	1/60 (2%) lost more than one line of visual acuity due to cataract progression
Sugar <sup>45</sup>	7.8 years (mean)	7/17 (41%) developed cataract
<b>Nd:YAG Laser Iridotomy</b>		
Tomey <sup>137</sup>	0.5-1.5 years	1/27 (4%) VA reduced by $\geq$ 2 lines

**TABLE 1.12**  
**Long term visual acuity outcome following acute angle closure glaucoma**

The visual acuity outcome following prophylactic treatment of fellow eyes may be more easily analysed (Table 1.13). 15-20% of fellow eyes develop some reduction in visual acuity due to cataract development 2-5 years after peripheral iridectomy. The figure may be slightly less for argon laser iridotomy <sup>102</sup>. Long term results following Nd:YAG laser iridotomy are not yet available.

Author	Follow up period	Visual acuity outcome
<b>Peripheral Iridectomy</b>		
Krupin <sup>86</sup>	52 months (mean)	6/40 (15%) VA reduced $\geq$ 3 lines
Floman <sup>87</sup>	4.2 years (mean)	51/155 (33%) VA reduced $\geq$ 2 lines
Lowe <sup>43</sup>	at 5 years	2/26 (8%) VA , 6/18 due to cataract
Sugar <sup>45</sup>	7.8 years (mean)	4/17 (23%) had cataract
Williams <sup>46</sup>	0.5-16 years	1/45 (2%) VA reduced $\geq$ 3 lines
Luke <sup>101</sup>	4.4 years (mean)	no cataract
Ghoshal <sup>135</sup>	> 3 years	1/29 (3%) VA reduced $\geq$ 1 line
Douglas <sup>117</sup>	0.5 - 2 years	1/103 (1%) VA reduced $\geq$ 1 line
<b>Argon Laser Iridotomy</b>		
Quigley <sup>33</sup>	> 1 year	13/88 (15%) VA reduced $\geq$ 2 lines (fellow + "occludable angle" eyes)
Robin <sup>102</sup>	5 years	6/98 (6%) VA reduced $\geq$ 2 lines (chronic angle closure glaucoma)
<b>Nd:YAG Laser Iridotomy</b>		
Tomey <sup>137</sup>	0.5-1.5 years	8/61 (10%) VA reduced $\geq$ 2 lines (“occludable angle” eyes)
Schwartz <sup>11</sup>	0.5-2.5 years	5/182 (3%) VA reduced $\geq$ 2 lines (chronic angle closure glaucoma)

**TABLE 1.13**  
**Long term visual acuity outcome in fellow eyes**

### **1.7.6 TREATMENT OF CHRONIC ANGLE CLOSURE GLAUCOMA**

The outcome of surgical treatment of chronic angle closure glaucoma may be measured in terms of glaucoma control (medication requirement, intraocular pressure, optic disc cupping, visual field), and

visual acuity outcome.

In measuring the glaucoma outcome, careful definition of the pre operative glaucoma status is necessary. Preoperative intraocular pressure with medication, visual field, outflow facility, cup : disc ratio, and the extent of goniosynechia influence the glaucoma outcome following surgery <sup>95</sup>.

The reported glaucoma outcome following surgical or laser treatment for chronic angle closure glaucoma is summarised in Table 1.14. Following peripheral iridectomy, argon laser iridotomy or Nd:YAG laser iridotomy 70 - 90% of eyes with no visual field loss are normotensive, although a proportion of these need additional glaucoma medication, most frequently a  $\beta$  blocker <sup>138</sup>. The results in eyes with visual field loss prior to surgery are less good. 45-65% of eyes are normotensive, with additional medication if required, following peripheral iridectomy <sup>49,52</sup>. Primary drainage surgery results in normal intraocular pressure with or without additional medication in more than 90% of cases <sup>52,89</sup>.

Author	Preoperative glaucoma status	Operation	Glaucoma outcome (Normal IOP, with medication if necessary)
Playfair <sup>49</sup>	Full Field	P.I.	73/96 (76%)
	Field Loss	P.I.	28/62 (45%)
Gelber <sup>52</sup>	Full Field	P.I.	28/29 (96%)
	Field Loss	P.I.	7/11 (64%)
	Field Loss	Trabeculectomy	14/15 (93%)
Horie <sup>89</sup>	Angle closed <80% and IOP normal on medication	P.I.	135/135 (100%)
	angle closed >80% or elevated IOP on medication	Scheie's operation	47/49 (96%)
Go <sup>95</sup>	Angle closed <80% and IOP normal on medication	P.I.	84/110 (76%)
		Argon Iridotomy	64/85 (75%)
Geiser <sup>139</sup>	Full field	Argon Iridotomy	5/8 (63%)
	Field loss	Argon Iridotomy	7/9 (78%)
Quigley <sup>33</sup>		Argon Iridotomy	69/75 (92%)
Tomey <sup>137</sup>		Nd:YAG Iridotomy	169/187 (90%)

**TABLE 1.14**  
**Glaucoma outcome following operative or laser treatment of chronic angle closure glaucoma**

The visual acuity outcome following surgical or laser treatment of chronic angle closure glaucoma has been less well documented than the glaucoma outcome. Table 1.15 summarises the reported results. Surgical peripheral iridectomy, argon laser iridotomy and Nd:YAG laser iridotomy appear to have a similar outcome, but cataract development is more frequent following drainage surgery.

Author	Follow up	Operation	Outcome (Rate of cataract development)
Gelber <sup>52</sup>	12 months (mean)	P.I. Trabeculectomy	5/40 (12.4%) 5/17 (29%)
Quigley <sup>33</sup>	1.8 years (mean)	Argon laser iridotomy	13/88 (15%) *
Tomey <sup>137</sup>	6-18 months	Nd:YAG laser iridotomy	14/187 (7%)

**TABLE 1.15**

**Visual acuity outcome following operative or laser treatment  
of chronic angle closure glaucoma**

\*Includes a number of acute angle closure glaucoma patients

**1.8 LASER TREATMENT OF ANGLE CLOSURE GLAUCOMA.**

**Q-SWITCHED Nd:YAG LASER IRIDOTOMY**

The possibility of creating a hole in the iris using light energy was first raised by Meyer-Schwickerath in 1956<sup>26</sup>. Since then a variety of laser energy sources have been used to produce iridotomies<sup>1,2,27,28,37</sup>. Q switched Nd:YAG laser iridotomy is currently the preferred technique<sup>13</sup>.

**1.9 THE PHYSICS OF LASER ENERGY**

Laser (Light Amplification by Stimulated Emission of Radiation) energy is produced by "pumping" electrons of atoms in the laser medium to an excited state, using an external energy source<sup>35,36,140</sup>. Decay of electrons to a low energy state releases photons, which stimulate the release of further photons. A chain reaction of photon release occurs within the laser cavity. Photons are contained within the laser cavity by optical mirrors, and may be released continuously or in pulses<sup>140</sup>.

The wavelength of the laser energy is determined by the nature of the lasing medium <sup>36</sup>. Examples are shown in Table 1.16.

Laser medium	Wavelength (nm)	Colour
Argon	488	blue
	514	green
Krypton	568	yellow
	647	red
Dye	590	orange
Helium-Neon	633	red
Ruby	694	red
Nd:YAG	1,064	infrared
CO <sub>2</sub>	10,600	infrared

**TABLE 1.16**  
**Wavelengths of laser energy produced by commonly used laser media**

### 1.10 CHARACTERISTICS OF THE Q-SWITCHED Nd:YAG LASER

Short pulses of laser light may be produced by placing an optical switch in the laser cavity <sup>140</sup>. An electrically driven electro-optical crystal (Pockels cell) is the most commonly used optical switch in pulsed Nd:YAG lasers. The Pockels cell deflects light within the laser cavity, reducing the "quality" of resonance in the cavity. When the Pockels cell is turned off the quality of the resonator increases, and a pulse of laser energy is rapidly generated. The term "Q switch" refers to the quality switch effect produced by a Pockels cell <sup>140</sup>.

The characteristics of the Zeiss "Visulas" ophthalmic Q-switched Nd:YAG laser are shown in Table 1.17. As Nd:YAG laser light is infrared and lies outwith the visible spectrum, a Helium-Neon aiming laser, which produces visible red light is used for focusing. The objective lens of the Zeiss Q switched Nd:YAG laser has a diameter of 40mm and a focal length

of 125 mm, producing a cone of laser light which subtends an angle of 18°.

Laser medium :	Neodymium doped yttrium aluminium garnet crystal
Pump :	Xenon flash, duration 20 ms
Cavity :	Elliptical reflecting cavity with laser rod and xenon flash lamp aligned in parallel
Switch :	Pockel cell Q switch
Wavelength of laser :	1064 nm
Duration of pulse :	7 ns
Diameter of focussed spot :	30µm
Energy per pulse :	5 - 10 mJ
Peak power :	1.4 K Watts
Peak irradiance :	$2 \times 10^{12}$ watts $m^{-2}$

**TABLE 1.17**  
**Characteristics of an ophthalmic Q switched Nd:YAG laser**

During the period 1982 -1983 I was involved in the development of an ophthalmic Q switched Nd:YAG laser using an attenuated continuous wave Nd:YAG laser produced by Ferranti PLC. The prototype did not reach the stage of clinical trials due to commercial factors.

### **1.11 LASER INTERACTIONS WITH TISSUES**

Both the wavelength and time duration of laser pulses determine their effects on various tissues <sup>35,36</sup>.

Absorbtion of argon, krypton, ruby or dye laser energy by iris pigment results in thermal damage at the treatment site <sup>35</sup>. Argon laser energy is poorly absorbed by lightly pigmented irises, resulting in difficulties when performing an iridotomy <sup>12,23,30,105,121,141-144</sup>. The use of shorter duration pulses, of 0.02 and 0.05 second duration, reduces

thermal conduction within the treated tissue<sup>35,112,145</sup>, localising tissue damage.

Very short duration laser pulses of pico and nanosecond duration produce mechanical rather than thermal effects at the tissue treatment site<sup>35,146</sup>. Very high irradiance results in "optical breakdown" at the point of focus. This process is not dependent on absorption of laser energy by pigment, and may occur in transparent media including air and water<sup>140</sup>. Photon absorption at the point of focus results in ionisation and release of free electrons - "plasma" formation. The plasma absorbs incident light, with the result that structures distal to the plasma are not irradiated - "plasma shielding"<sup>37</sup>. The characteristics of optical breakdown of Q switched Nd:YAG laser pulses have been studied by hydrophone analysis<sup>147,148,149</sup>, thermocouple measurements<sup>37</sup>, and high speed photography<sup>147,150</sup>.

The very high temperature of the plasma results in rapid expansion, producing a supersonic shock wave<sup>140,147,148</sup>, which decays to an acoustic wave after travelling approximately 100-200 $\mu$ <sup>140,147,148</sup>. The energy of the acoustic wave decays as an inverse function of the distance from its origin, and produces pressure transients of 9-16 bar at 18mm<sup>147</sup>.

As the plasma cools the surrounding liquid is vapourised and a bubble of 1.5 - 2.3 mm diameter is produced<sup>147</sup>. Bubble expansion propels debris 8 - 10 mm from the treatment site<sup>148,150</sup>, at speeds of greater than 20 km/hr<sup>150</sup>. While the predominant tissue effects are mechanical, the plasma has a very high temperature. Krasnov has measured increases in tissue temperature using a thermocouple<sup>37</sup>, and analysis of energy changes following Q switched Nd:YAG laser pulses shows that thermal effects contribute to photodisruption<sup>147</sup>.



The mechanical effects of optical breakdown produced by Q-switched Nd:YAG laser pulses delivered to the iris stroma and pigment epithelium may be used to cut a full thickness hole in the iris.

## 1.12 OPHTHALMIC USES OF THE Q-SWITCHED Nd:YAG LASER

The Q-switched Nd:YAG laser has primarily been used for performing posterior capsulotomy following extracapsular cataract surgery<sup>9,151,152,153</sup> and iridotomy in the management of angle closure glaucoma<sup>2,13</sup>. However a variety of less common indications for its use have been described. These are summarised in Table 1.18.

Indication	Author
1. "Malignant " glaucoma - ciliary block glaucoma in phakic, aphakic and pseudophakic eyes	Brown <sup>154</sup> Epstein <sup>155</sup> Weinberger <sup>156</sup> Rockwood <sup>157</sup> Shrader <sup>158</sup>
2. Opening failed trabeculectomy site Trabeculotomy	Klapper <sup>159</sup> Dutton <sup>160</sup> Krasnov <sup>37</sup>
3. Puncture of miotic cysts	Schrems <sup>161</sup>
4. Removal of persistent pupillary membrane	Vega <sup>162</sup>
5. Division of vitreous traction bands	Frankhauser <sup>163</sup>
6. Relief of vitreoretinal traction in pneumatic retinopexy	Fleck <sup>164</sup>
7. Lens nucleus disruption in experimental cataract surgery	Fleck <sup>165</sup>

**TABLE 1.18**  
**Less common indications for the use of the Q-switched Nd:YAG laser**

### **1.13 HISTOPATHOLOGICAL CHANGES IN THE IRIS FOLLOWING Q SWITCHED Nd:YAG LASER IRIDOTOMY**

Histopathological examination of iris specimens following Q switched Nd:YAG laser iridotomy shows changes of mechanical rather than thermal origin <sup>166</sup>.

Operative iridectomy specimens containing a Nd:YAG laser iridotomy site have been studied using light and electron microscopy <sup>166,167</sup>. Immediately following iridotomy stromal necrosis and blood vessel disruption occur in a very localised area around the iridotomy <sup>166</sup>. The area of pigment epithelium disruption is slightly greater than the area of stromal disruption <sup>166</sup>.

Q switched Nd:YAG laser iridotomy in cynomolgus monkeys produces a wide area of pigment epithelium disruption, and iridotomy closure due to pigment proliferation commonly occurs <sup>110,168</sup>. In rabbits pigment epithelium disruption is minimal and no inflammatory or fibrotic reaction or stromal atrophy develops following Nd:YAG laser iridotomy <sup>169,170</sup>.

### **1.14 INDIRECT TISSUE DAMAGE DUE TO Q-SWITCHED Nd:YAG LASER IRIDOTOMY**

Q switched Nd:YAG laser pulses delivered to the iris not only disrupt iris tissue, but also damage adjacent ocular tissues.

#### **1.14.1 CORNEA**

Nd:YAG laser energy is not significantly absorbed by the cornea <sup>171</sup>. However Q switched Nd:YAG laser pulses create a transient thermal divergent lens effect within the corneal stroma, which could alter focussing during rapidly delivered trains of laser pulses <sup>172</sup>.

The effects of Nd:YAG laser pulses on the corneal endothelium have been studied using specular microscopy and electron microscopy in animals <sup>7,173,174</sup>, and by specular microscopy in humans <sup>7,8,9</sup>. Endothelial damage can be produced by acoustic transients if optical breakdown is produced in the aqueous within 1 mm of the corneal endothelium <sup>175</sup>. However endothelial damage produced during Q switched Nd:YAG laser iridotomy appears to be mainly due to high velocity debris from the iris <sup>7,8,9</sup>. Punched out areas of bare Descemet's membrane are produced. These are most frequent in the endothelium overlying the treatment site <sup>7</sup>. Similar lesions are seen following posterior capsulotomy in aphakic eyes. They are less frequent in pseudophakic eyes, and it is possible that a lens implant shields the cornea from dispersed debris <sup>7</sup>. The lesions resolve over a 3-4 day period by spread of surrounding healthy endothelial cells<sup>7</sup>.

#### **1.14.2 TRANSIENT INTRAOCULAR PRESSURE ELEVATION**

Measurements of aqueous prostaglandin E<sub>2</sub> levels in rabbits following Q switched Nd:YAG laser iridotomy have shown high levels 30 minutes after treatment, returning to normal after 6 hours <sup>176</sup>. It has been postulated that prostaglandins mediate the intraocular pressure elevation which occurs following iridotomy. However other workers have found only a small rise in PG F<sub>1a</sub> and thromboxane B<sub>2</sub> levels following iridotomy in rabbits <sup>177</sup>. While pre-treatment with indomethacin 1% blocks the rise in PG F<sub>1a</sub> and TB B<sub>2</sub> levels which normally occur in rabbits following anterior capsulotomy, it does not prevent intraocular pressure elevation <sup>177</sup>.

Particulate debris and elevated aqueous protein levels following iridotomy <sup>177</sup> probably cause increased intraocular pressure by

transiently reducing outflow facility at the trabecular meshwork <sup>178</sup>.

### **1.14.3 LENS DAMAGE**

Focal <sup>170</sup> and diffuse <sup>179</sup> lens damage has been found to be minimal following Q switched Nd:YAG laser iridotomy in rabbits. Latina detected small areas of anterior capsule opacification and pigment deposition following Q switched Nd:YAG laser iridotomy in rabbits, but the anterior capsule remained intact <sup>169</sup>. A similar pattern of injury has been found in humans <sup>122</sup>. In contrast focal lens opacities and anterior capsule rupture frequently occurs following Q-switched Nd:YAG laser iridotomy in cynomolgus monkeys <sup>168</sup>.

### **1.14.4 VITREOUS AND RETINA**

Q switched Nd:YAG laser pulses do not produce detectable physicochemical changes in the vitreous <sup>126</sup>. Retinal damage has only been described when Nd:YAG laser pulses are delivered within 3mm of the retina <sup>180</sup>.

## **1.15 CONTACT LENSES USED IN Nd:YAG LASER IRIDOTOMY**

A contact lens may be used to eliminate corneal refraction, eliminate reflection from the surface of the tear film, and reduce eye movements during treatment. A convex contact lens converges light rays and increases the cone angle of laser energy entering the eye. More laser energy may then be focussed onto a smaller treatment spot <sup>181,182,183</sup>. A convex contact lens also magnifies the surgeon's image of the iris.

The Zeiss anterior segment YAG contact lens produces no increase in laser cone angle, or magnification of the treatment area. While orientation is facilitated by a wide field of view, critical focussing is

difficult.

In contrast, the Wise 103 dioptre iridotomy-sphincterotomy lens increases laser cone angle, resulting in an irradiance at the iris plane 7.8 times greater than that obtained using a plano contact lens <sup>183</sup>. The diameter of the laser beam at the cornea is increased, reducing thermal effects within the corneal stroma. The iris is magnified by a factor of approximately x4, allowing more critical focussing of laser energy onto iris structures. Increased irradiance at the iris allows lower energy Nd:YAG laser pulses to be used without loss of optical breakdown. Individual radial strands of the iris may be cut, resulting in better control of iridotomy shape <sup>108</sup>. Corneal endothelium damage is proportional to the amount of laser energy used in treatment <sup>7</sup>. The use of lower energy pulses in conjunction with a Wise 103 dioptre contact lens may therefore produce less damage to the corneal endothelium.

## **1.16 OTHER FORMS OF LASER IRIDOTOMY**

### **1.16.1 ARGON LASER IRIDOTOMY**

Argon laser iridotomy was introduced into clinical use by Abraham in 1975 <sup>1</sup>, and remained very popular until a series of comparative studies showed that Q-switched Nd:YAG laser iridotomy produced more satisfactory results <sup>10,13,22,23</sup>.

Argon laser energy is absorbed by pigmented tissues, and acts by producing thermal damage <sup>35,36</sup>. The main disadvantages of argon laser iridotomy have proved to be:

1. A high iridotomy reclosure rate <sup>13,22,23,30</sup>. This may be related to migration and proliferation of pigment epithelium cells, which occurs several weeks following argon laser iridotomy <sup>184</sup>, but does not occur following Q-switched Nd:YAG laser iridotomy <sup>166</sup>.

2. A high incidence of focal lens opacities underlying the treatment site <sup>1,10,12,13,22,23,30,31,103,105,110,121</sup>.

3. Poor response of lightly pigmented irises to argon laser energy. While heavily pigmented irises readily absorb argon laser energy <sup>12,105,112,132</sup>, lightly pigmented irises fail to do so <sup>12,23,30,105,121,141-144</sup>. Racial differences in iris pigmentation and structure may therefore produce differing responses to argon laser energy.

### **1.16.2 RUBY LASER IRIDOTOMY**

Zweng reported the use of a pulsed ruby laser used to produce retinal burns and iridotomies in rabbits in 1964 <sup>27</sup>. The pulsed ruby laser was later used by Perkins to produce iridotomies in humans <sup>28,185</sup>. While the pigment epithelium was disrupted by this form of treatment, the stroma proved resistant to ruby laser pulses, and multiple treatment sessions were needed <sup>185</sup>. Beckman found that the ruby laser could produce a patent iridotomy in brown irises, but not in blue irises <sup>144</sup>.

The Q switched ruby laser was later used to produce iridotomies in monkeys <sup>186,187</sup> and in humans <sup>37,146,188</sup>. However iris bleeding and pigment dispersion is very marked following Q switched ruby laser iridotomy <sup>188</sup>. Higher energy pulses are needed to create a Q switched ruby laser iridotomy than a Q switched Nd:YAG laser iridotomy <sup>10,188</sup>.

### **1.16.3 DYE LASER IRIDOTOMY**

The first dye laser iridotomies were produced by Bass who found that short duration pulses (1µs) using rhodamine 6G dye (wavelength 590nm), were most effective <sup>34</sup>. However a prospective randomised comparison of Nd:YAG laser iridotomy and dye laser iridotomy showed a greater incidence of complications following dye laser iridotomy <sup>15</sup>.

#### **1.16.4 FIBREOPTIC DELIVERY**

Continuous wave Nd:YAG laser iridotomy uses much higher energy levels than Q switched Nd:YAG laser iridotomy<sup>189</sup>. Less energy is needed if the laser energy is delivered through a fiberoptic probe in contact with the sclera<sup>190, 191</sup>. Erbium:YAG laser energy delivered through a fiberoptic probe<sup>192</sup> has also been used to produce an experimental iridotomy.

#### **1.17 AREAS OF UNDERSTANDING OF LASER IRIDOTOMY WHICH REQUIRE FURTHER WORK**

The widespread clinical use of Nd:YAG laser iridotomy has come about relatively quickly, and its place in the management of angle closure glaucoma has not yet been fully evaluated. In our research programme we have attempted to answer some outstanding questions.

1. How safe is Nd:YAG laser iridotomy? Is it as safe as operative peripheral iridectomy? While comparisons of argon laser iridotomy and Nd:YAG laser iridotomy have been made<sup>10,13,22,23</sup>, no prospective comparison of operative peripheral iridectomy and Nd:YAG laser iridotomy has been carried out. We have performed such a study, using the fellow eye of patients with acute angle closure glaucoma as a model (chapter 4). Questions addressed by this study include :

Is Nd:YAG laser iridotomy more or less damaging to the corneal endothelium than operative peripheral iridectomy?

What are the comparative risks of early post-treatment intraocular pressure elevation, iris bleeding, iritis, posterior synechiae formation and focal lens damage?

In the longer term is Nd:YAG laser iridotomy associated with a higher or lower incidence of cataract development than operative

peripheral iridectomy?

2. Is Nd:YAG laser iridotomy as effective as operative peripheral iridectomy in preventing the development of acute angle closure glaucoma? This question is addressed in chapter 4 (fellow eyes), and chapter 5 (acute angle closure glaucoma eyes). An analysis of factors which may be responsible for the failure of very small iridotomies to prevent acute angle closure glaucoma is given in chapter 6.

3. What is the place of Nd:YAG laser iridotomy in the management of chronic angle closure glaucoma and narrow angle glaucoma? A preliminary study of the outcome of Nd:YAG laser iridotomy in chronic angle closure glaucoma and in narrow angle glaucoma is presented in chapter 7.

4. Might the combined use of argon laser and Nd:YAG laser energy to produce an iridotomy offer any advantages over the use of Nd:YAG laser energy alone? Controlled studies of combination treatment have not been performed. An evaluation of argon laser pretreatment 4-6 weeks prior to Nd:YAG laser iridotomy is presented in chapter 8.

5. Are racial differences in iris pigmentation and structure significant in performing Nd:YAG laser iridotomy or argon laser iridotomy? A comparison of clinical experience in performing Nd:YAG and argon laser iridotomies in caucasian patients in Edinburgh, and chinese patients in Singapore, is presented in chapter 9.

6. Are there any differences in the long term visual acuity or



glaucoma outcomes following operative peripheral iridectomy or Nd:YAG laser iridotomy used in a variety of forms of angle closure glaucoma?

We are currently undertaking a long term prospective comparison of operative peripheral iridectomy and Nd:YAG laser iridotomy in the treatment of acute angle closure glaucoma. The results of this study will be available in 7-8 years and will give more complete information on the long term visual acuity and glaucoma outcome of Nd:YAG laser iridotomy in eyes with acute angle closure glaucoma and in fellow eyes.

## CHAPTER 2

### MATERIALS AND METHODS

#### 2.1 PATIENTS

A series of studies were designed with the aim of answering the question "Is Nd:YAG laser iridotomy a satisfactory alternative form of treatment to operative peripheral iridectomy in the management of angle closure glaucoma?"

The component studies consisted of:

1. A retrospective analysis of the outcome of treatment of angle closure glaucoma in Edinburgh during the years 1980 - 1985. The glaucoma and visual acuity outcome 5 years after treatment were assessed using information obtained from the case records of 137 patients treated during the study period. Details of this study are given in chapter 3.

2. A prospective comparison of Nd:YAG laser iridotomy and operative peripheral iridectomy in the treatment of acute angle closure glaucoma. A series of 70 consecutive patients presenting with acute angle closure glaucoma during the period January 1987 - June 1989 were studied prospectively. The acute eye was treated by Nd:YAG laser iridotomy, operative peripheral or sector iridectomy, or drainage surgery as judged appropriate by the consultant in charge of the case (details of this study are given in chapter 5). Consent was obtained from 52 patients to enter the fellow eye into a randomised prospective comparison of Nd:YAG laser iridotomy and operative peripheral iridectomy (details of this study are given in chapter 4). The occurrence of acute angle closure

glaucoma in 3 eyes with small patent iridotomies prompted an investigation of factors responsible for this (details of this analysis are given in chapter 6).

3. A group of 16 patients with a diagnosis of chronic angle closure glaucoma, and 22 patients with a diagnosis of "narrow angle glaucoma", who underwent Nd:YAG laser iridotomy during the period June 1986 to March 1989 were recalled for a detailed follow up examination in order to measure the glaucoma and visual acuity outcome of laser treatment (details of this study are given in chapter 7).

4. The effect of argon laser treatment of the iris stroma 4-6 weeks prior to performing Nd:YAG laser iridotomy was assessed in the right eye of 10 patients with chronic or intermittent angle closure glaucoma. The left eyes were treated with primary Nd:YAG laser iridotomy (details of this study are given in chapter 8).

5. A comparison of Nd:YAG laser iridotomy and argon laser iridotomy was made in a retrospective study of 31 Chinese patients treated in Singapore, and 25 Caucasian patients treated in Edinburgh. Differences in the effects of laser energy on the irises of these two groups were assessed (details of this study are given in chapter 9).

## **2.2 METHODS**

The detailed methods of the component studies are described in each chapter of this thesis.

In addition to clinical examination techniques, specialised investigations were used where appropriate - endothelial cell density measurement by specular microscopy, ultrasound pachymetry measurement of corneal thickness following acute angle closure glaucoma, and photometric measurement of iridotomy area.

### **2.2.1 ETHICAL APPROVAL**

Approval of each clinical study was obtained from the unit ethical committee. Approval to perform a randomised prospective comparison of Nd:YAG laser iridotomy and operative peripheral iridectomy was obtained from the regional surgical subspecialties ethical committee.

### **2.2.2 RANDOMISATION**

Informed patient consent to inclusion in the randomised comparison of Nd:YAG laser iridotomy and operative peripheral iridectomy in the treatment of fellow eyes was obtained prior to randomisation. Randomisation was stratified into a group aged more than 70 years, and a group aged less than 70 years. Randomisation was carried out by opening the top envelope in a container containing consecutively numbered sealed envelopes. Each envelope contained a card marked "surgery" or "laser", and the number of the envelope. The allocation of "surgery" or "laser" to each number had been performed using a random number generator computer programme prior to commencement of the trial, and the cards were placed in the envelopes by a person not involved in the study.

### **2.2.3 TREATMENT TECHNIQUES**

#### **2.2.3.1 OPERATIVE PERIPHERAL IRIDECTOMY**

Surgery was performed under local or general anaesthetic. BWF personally performed all operative peripheral iridectomies in the prospective comparison of Nd:YAG laser iridotomy and operative peripheral iridectomy described in chapter 4. A corneal incision was used. The peripheral iris was grasped with grooved forceps, and a peripheral iridectomy was performed with scissors. No sutures were

used. This technique minimised postoperative discomfort and therefore facilitated very early measurement of intraocular pressure.

Operative peripheral iridectomies were performed on acute angle closure glaucoma eyes (chapter 5) by several experienced surgeons. In most cases a corneoscleral incision was used. A fornix based conjunctival flap was made, followed by a corneoscleral incision into the anterior chamber. The peripheral iris was prolapsed using gentle pressure to the posterior edge of the wound, and a peripheral iridectomy was made with scissors. The corneoscleral and conjunctival wounds were closed using 8/0 polyglactin ("vicryl") suture material.

#### **2.2.3.2 Nd:YAG LASER IRIDOTOMY**

A Zeiss "Visulas" Nd:YAG laser and Zeiss anterior segment YAG contact lens were used. A treatment site was chosen in the superior iris, between 10 and 2 o'clock, approximately 2/3 distance from the pupil margin to the base of the iris. An iris crypt was used when present. A single 5-10 mJ pulse was delivered to the treatment site. If this pulse did not penetrate the iris, further single pulses were delivered to the same site until penetration was achieved. A gush of aqueous fluid from the posterior chamber could be seen at the moment of penetration. Patency was assessed by direct visualisation of the posterior chamber, or anterior lens capsule.

BWF personally performed all Nd:YAG laser iridotomies in the prospective comparison of Nd:YAG laser iridotomy and operative peripheral iridectomy described in chapter 4. Nd:YAG laser iridotomies were performed on acute angle closure glaucoma eyes (chapter 5) and chronic and narrow angle closure glaucoma eyes (chapter 7) by several experienced surgeons. BWF personally performed all argon laser and

Nd:YAG laser treatments described in chapter 8.

Several surgeons performed the argon and Nd:YAG laser iridotomies described in the comparative study of laser techniques in Edinburgh and Singapore described in chapter 9.

## 2.2.4 EXAMINATION METHODS AND DEFINITIONS

### 2.2.4.1 LASER INDUCED CORNEAL DAMAGE

Corneal damage evident on slit lamp examination 2 and 24 hours following laser treatment was scored as:

- 0 = no damage evident
- + = focal granularity of the endothelium
- ++ = focal full thickness corneal oedema.

Figure 2.1 shows an example of grade ++ corneal damage.

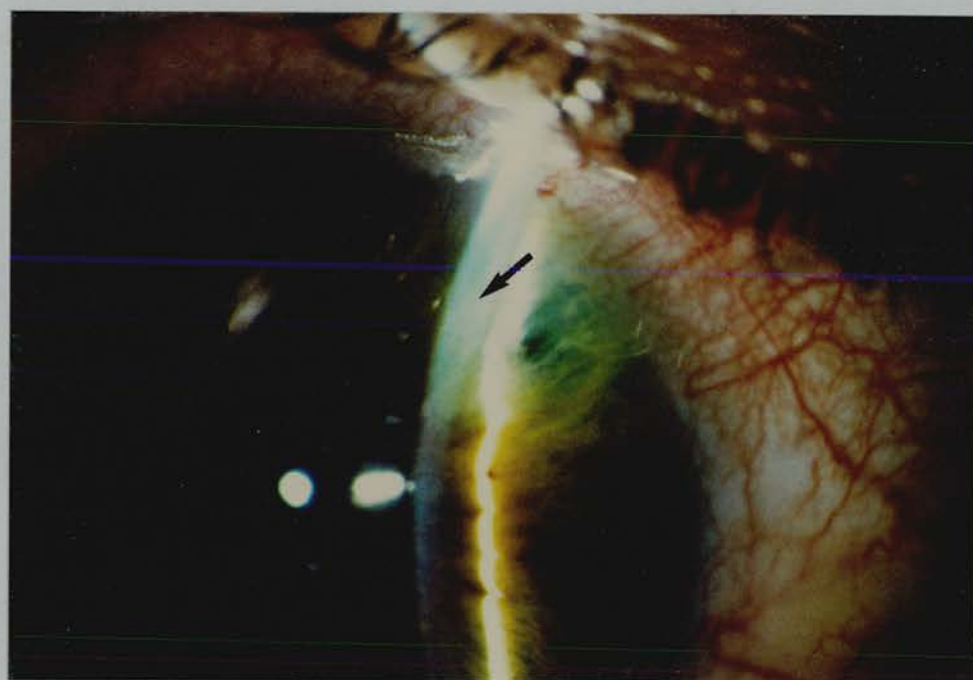


Figure 2.1. Nd:YAG laser iridotomy. Grade ++ corneal damage. Focal full thickness corneal oedema overlying the iridotomy treatment site is indicated by the arrow.

#### **2.2.4.2 IRITIS**

Iritis was judged to be present if there were more than 5 white cells per field using a 3mm long x 0.2mm wide slit beam focussed in the central part of the anterior chamber. The presence of dispersed pigment particles in the aqueous was not judged to be indicative of iritis.

#### **2.2.4.3 INDENTATION GONIOSCOPY**

Goldman indirect gonioscopy was performed in order to detect iridocorneal contact. If any part of the angle appeared to be closed Posner four mirror indentation gonioscopy was performed in order to differentiate iridocorneal contact from iridotrabecular adhesion (goniosynechiae). In the prospective studies described in chapters 4,5,6 and 8 all pre treatment gonioscopy examinations were performed by BWF. Follow up gonioscopy was performed by BWF, or by one of two experienced research assistants (EW or EF). If there was any uncertainty about the gonioscopy findings, the examination was repeated by BWF. A variety of examiners performed gonioscopy examinations on the patients with chronic and narrow angle closure glaucoma described in chapter 7.

#### **2.2.4.4 OPTIC DISC APPEARANCES AND VISUAL FIELD EXAMINATION**

The observers who performed gonioscopy (see section 2.2.4.3) also examined the optic discs. The vertical cup:disc ratio was recorded, expressed as a decimal ratio.

Visual field examinations using a tangent screen or Friedman Visual Field Analyser were performed where clinically indicated, but were not an integral part of the studies.

#### **2.2.4.5 PROVOCATION TESTS**

Pilocarpine/phenylephrine provocation tests as described by Mapstone<sup>68</sup>, and modified by Harrad<sup>105</sup> were used. The intraocular pressure was measured, one drop of G. Phenylephrine 10% and one drop of G. Pilocarpine 2% were instilled, and the intraocular pressure was measured again one hour later. An intraocular pressure rise of more than 8 mm Hg, with angle closure on gonioscopy, was regarded as a positive result. At the end of the test G. Thymoxamine 0.5% was instilled and the patient was observed until the pupil became small.

#### **2.2.4.6 POSTERIOR SYNECHIAE**

The pupil was dilated using G. Phenylephrine 10% in order to detect posterior synechiae, and allow examination of the lens and fundus. G. Thymoxamine 0.5% was used to reverse pupil dilation.

#### **2.2.5 ENDOTHELIAL CELL DENSITY MEASUREMENT**

Specular microscopy was performed using a Keeler-Konan Pocklington specular microscope before operative or laser treatment, and six months after treatment. Several central fields were photographed and stored for later analysis.

Patients were coded by number, and endothelial cell counts were performed by an observer unaware of the coding system. Using standardised print magnification and a transparent grid, three representative fields of 0.05 mm<sup>2</sup> were chosen for each patient, and the cells within these fields were counted. The mean value for the three areas was then calculated, and the result multiplied by a factor of 20 in order to express the result in cells per mm<sup>2</sup>.



Figure 2.2 shows an example of a specular micrograph taken 6 months following laser treatment. A representative  $0.05 \text{ mm}^2$  square is marked for counting. The endothelial cell density in this case was 2240 cells per  $\text{mm}^2$ .

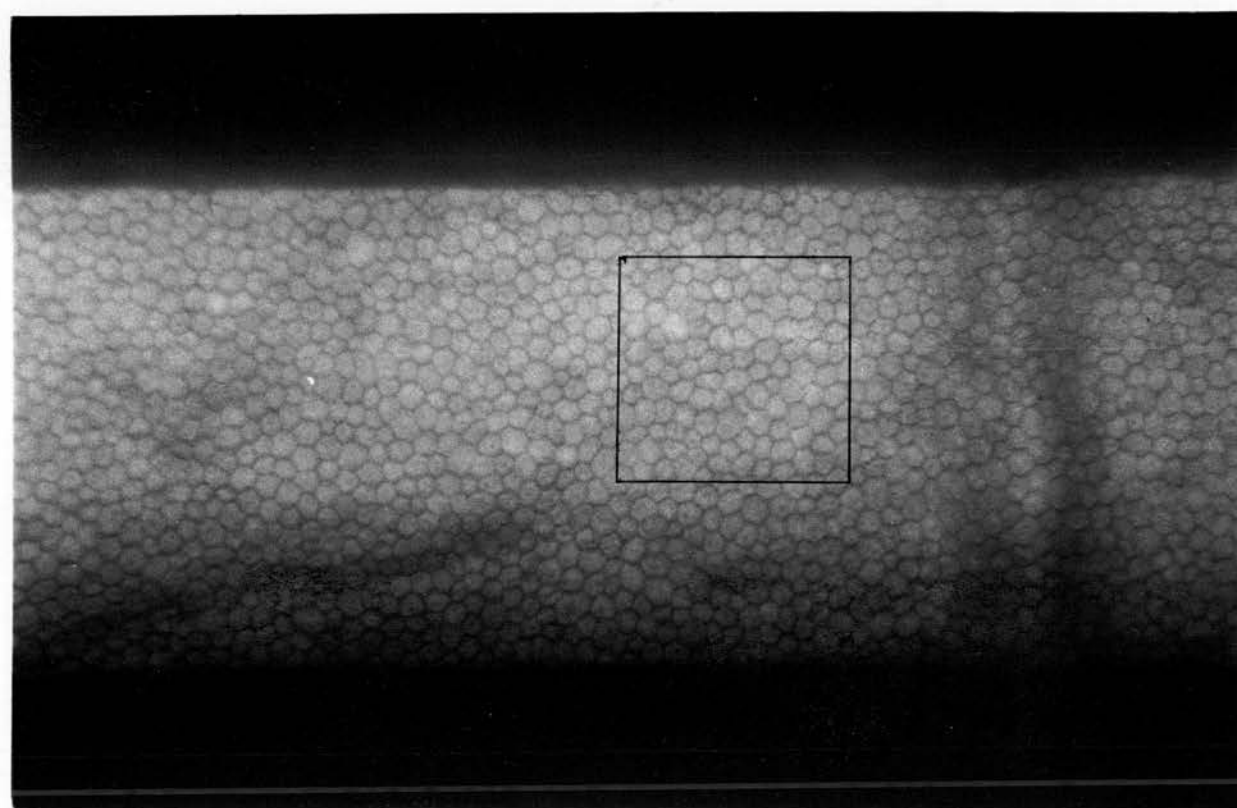


Figure 2.2. Specular micrograph of the corneal endothelium 6 months following Nd:YAG laser iridotomy. A representative area of  $0.05 \text{ mm}^2$  is marked for counting. The endothelial cell density in this case was 2240 cells per  $\text{mm}^2$ .

### 2.2.6 CORNEAL PACHYMETRY

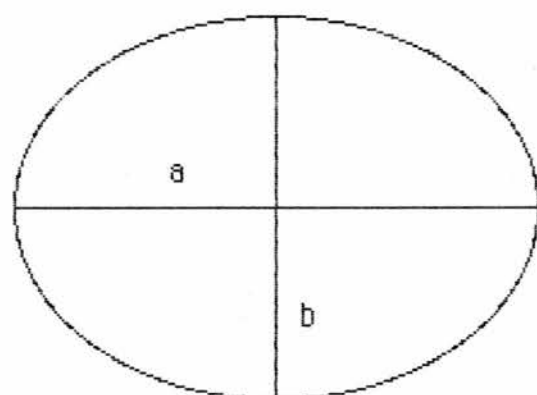
Serial measurements of corneal thickness and intraocular pressure were made following initial medical control of acute angle closure



glaucoma. Central corneal tissue thickness was measured using an "Ophthasonic" ultrasound pachymeter (Teknar Inc). Three readings were taken at the time of each measurement, and the average result recorded. Intraocular pressure was measured using a Goldman applanation tonometer.

### 2.2.7 IRIDOTOMY AREA MEASUREMENT

A simple clinical measurement of iridotomy area was used in the studies described in chapters 4,5,6,7 and 8. The area of the iridotomy or iridectomy was measured using a Haag-Streit slit lamp. The 200 $\mu$  spot size was focussed on the iris plane adjacent to the iridotomy. The maximum diameter of the iridotomy in two axes was then estimated. Most iridotomies approximated to an ellipse, and the area of iris patency was calculated using the formula  $\pi/4 \times \text{Diameter a} \times \text{Diameter b}$  (Fig 2.3.)



The surface area of this ellipse is  $\pi/4ab$ , where a and b are the two diameters of the ellipse

**Figure 2.3. Calculation of the surface area of an ellipse.**

#### 2.2.7.1 CALIBRATION OF IRIS MEASUREMENTS

In order to calibrate measurements made in this way photometric measurements of iridotomy area were made in 16 eyes of 11 patients.

The horizontal corneal diameter was measured using a Haag-Streit eyepiece graticule, which is marked in 100 $\mu$  divisions. The cornea and iris were then photographed using a Zeiss anterior segment camera. Colour transparency photographs were projected onto a white screen. The projected corneal diameter was measured in millimetres and compared with the measurement obtained using the slit lamp measuring eyepiece. A magnification factor for the projected image was derived for each eye. The magnification factor was approximately x80 in every case. The diameter of the iridotomy in two axes was measured on the screen, and the actual iridotomy diameters were calculated using the magnification factor. Table 2.1 shows the results of iridotomy measurements made using slit lamp measurements and photometry.

Eye	Slit Lamp Spot (mm)	Photometric (mm)
1	0.05x0.05	0.38x0.08
2	0.10x0.05	0.29x0.16
3	0.20x0.20	0.59x0.17
4	0.10x0.10	0.30x0.17
5	0.50x0.30	0.54x0.20
6	0.3x0.1	0.46x0.21
7	0.3x0.1	0.46x0.21
8	0.3x0.3	0.92x0.29
9	0.2x0.1	0.43x0.12
10	0.2x0.1	0.43x0.24
11	0.2x0.1	0.21x0.17
12	0.2x0.1	0.27x0.18
13	0.2x0.1	0.23x0.12
14	0.2x0.1	0.43x0.13
15	0.5x0.4	0.65x0.41
16	0.5x0.2	0.53x0.26

**Table 2.1**  
**Calibration of measurements of iridotomy diameters**

There was only moderately good correlation between iridotomy diameter measurements using the slit lamp spot and photometric measurements (correlation coefficient  $r = 0.6252$ ,  $t = 4.3872$ ,  $p < 0.001$ ). Iridotomy area measurements quoted in chapters 4-8 must therefore be regarded as approximate measurements only. However these measurements were adequate to detect whether an iridotomy was of very small diameter - less than  $100\mu$ , or whether it was moderately large - greater than  $200\mu$  in diameter, and were therefore taken as adequate for clinical assessment purposes.

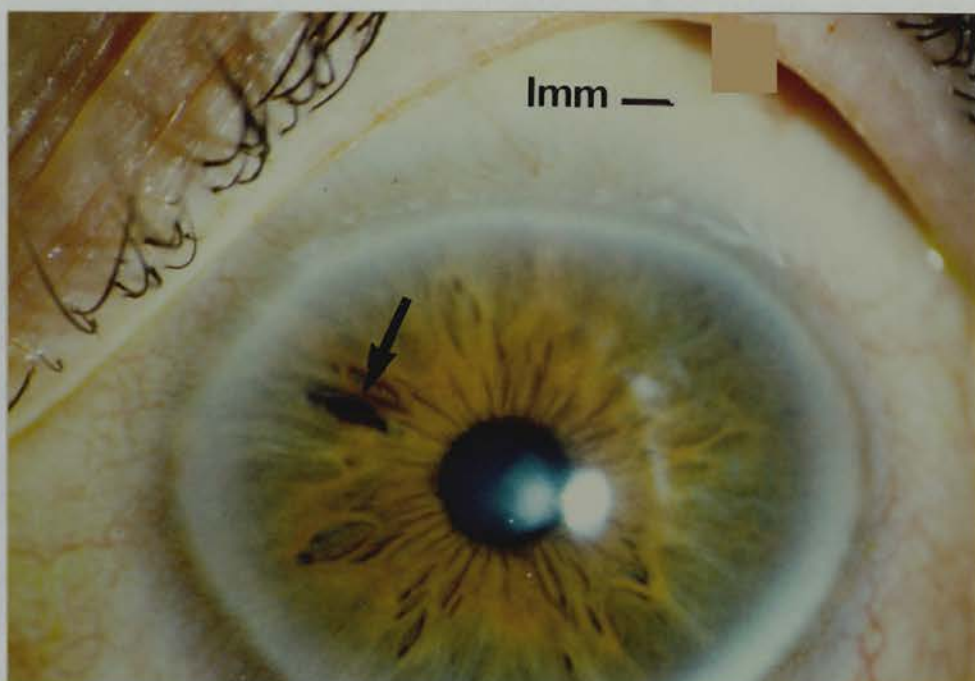
### **2.2.8 EFFECTS OF PUPIL DILATION ON IRIDOTOMY SHAPE, POSITION AND AREA.**

The effects of pupil dilation on iridotomy position, shape and area were also measured using the photometric technique described above. 16 eyes of 11 patients were used. The horizontal corneal diameter was measured using a Haag-Streit slit lamp eyepiece graticule. Photographs of the cornea and iris were taken before and after dilating the pupil with Tropicamide 1%. Measurements of corneal diameter, pupil diameter, iridotomy position in relation to the limbus, iridotomy shape and iridotomy area were made from the projected images of these photographs. Linear measurements were made using a millimetre rule, and iridotomy area was measured by projecting the image onto millimetre graph paper. These measurements were then converted to "real" size using a magnification factor derived from the known corneal diameter.

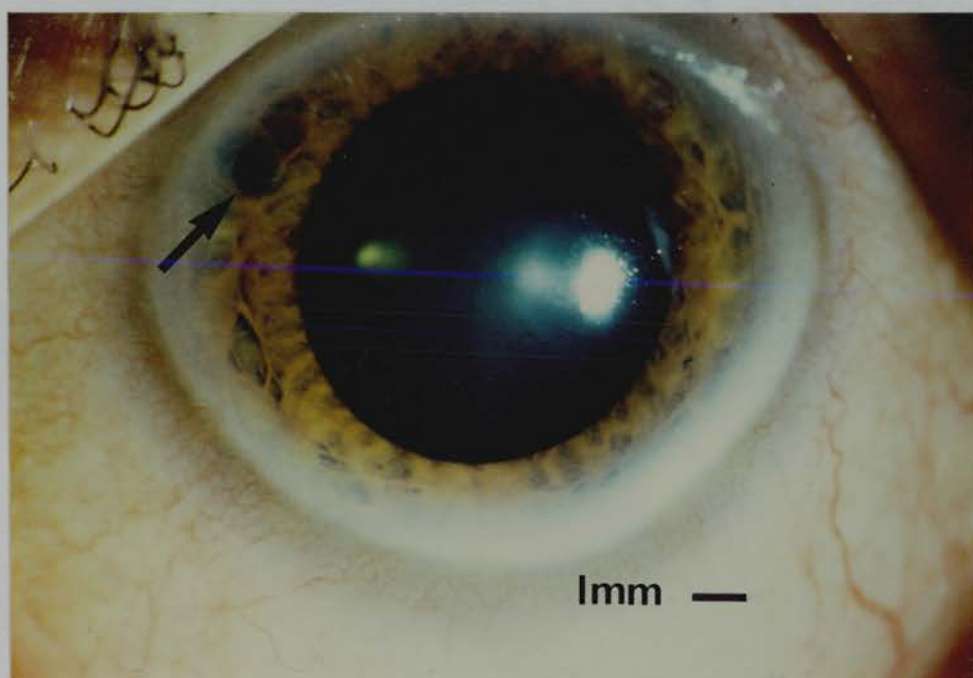
The cornea acts as a convex lens, resulting in a magnified image of the pupil. While this magnification effect is less in the iris periphery, at the site of an iridotomy, some error persists in measuring the absolute

area of an iridotomy. Relative comparison of iridotomy areas may be made between eyes, but these measurements probably deviate slightly from the area which would be measured if the cornea were not present.

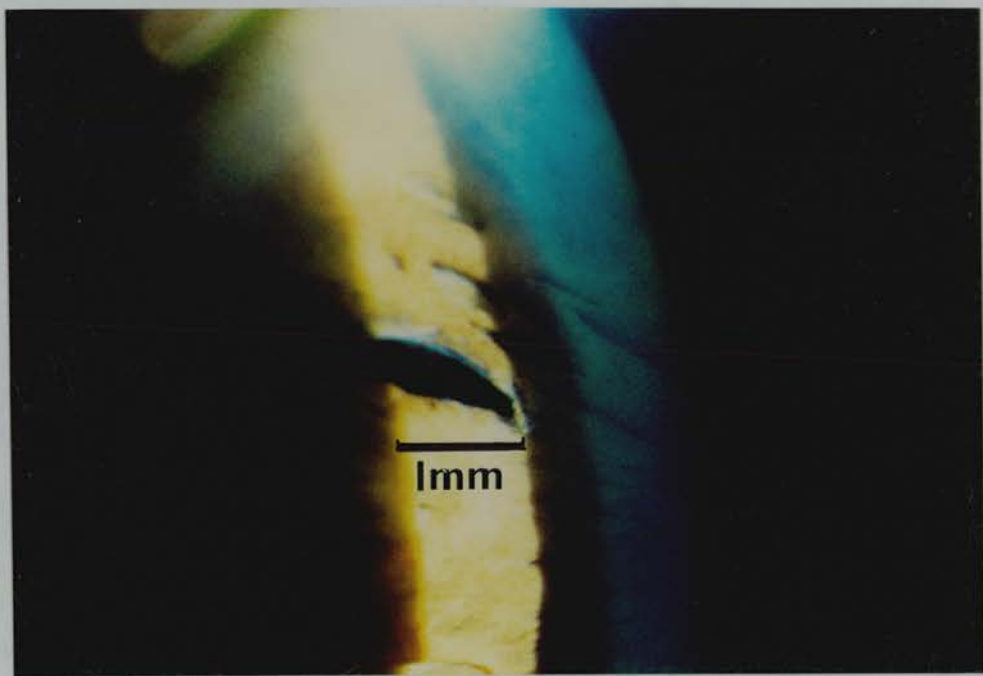
Figures 2.4 a-d shows an example of photometric analysis of the effect of pupil dilation on iridotomy area.



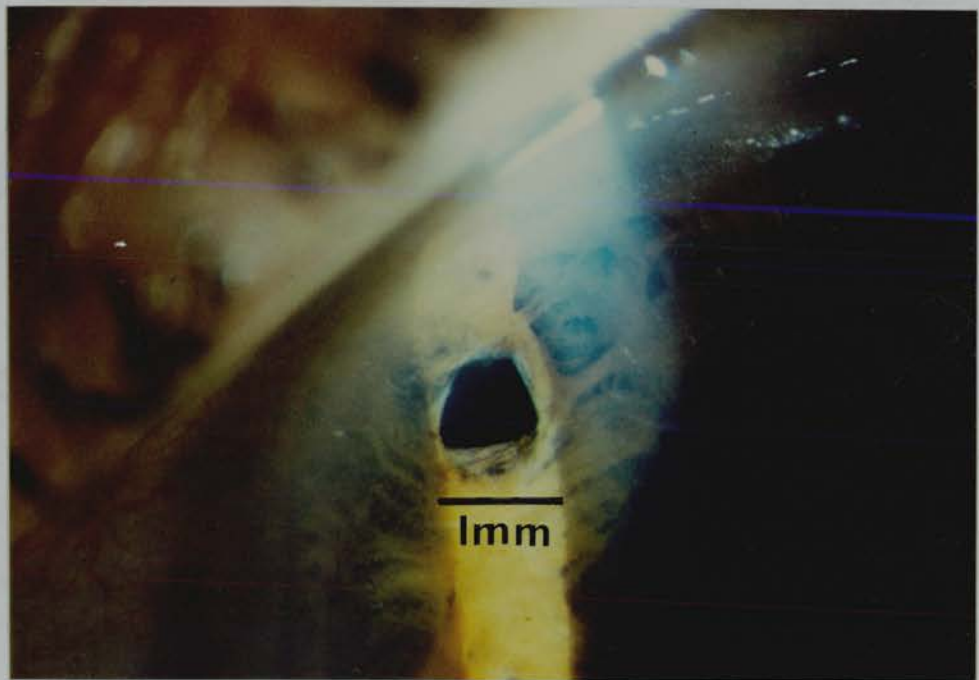
**Figure 2.4a.** Photometric analysis of the effect of pupil dilation on iridotomy area. x7.6 magnification. Undilated pupil. Corneal diameter 11.8 mm. Pupil diameter 2.1 mm.



**Figure 2.4b.** Photometric analysis of the effect of pupil dilation on iridotomy area. x7.6 magnification. Dilated pupil. Pupil diameter 6.3 mm.



**Figure 2.4c.** Photometric analysis of the effect of pupil dilation on iridotomy area.  $\times 17.5$  magnification. Undilated pupil. Iridotomy diameters  $0.92 \times 0.29$  mm.



**Figure 2.4d.** Photometric analysis of the effect of pupil dilation on iridotomy area.  $\times 17.5$  magnification. Dilated pupil. Iridotomy diameters  $0.61 \times 0.53$  mm.

### 2.3 STATISTICAL ANALYSIS

Statistical advice was sought prior to commencement of the studies, and during data analysis.

The unpaired Student t test was used to test the significance of differences between two groups in the mean value of a continuous variable. The Wilcoxon rank sum test was also applied to confirm significant findings in some analyses, although data approximated to a normal distribution in most circumstances.

The  $\chi^2$  test was used to test the significance of differences between two groups in the distribution of discrete variables. Yate's correction was applied to the  $\chi^2$  test when numbers were small - a total of less than 100, or less than 10 items in any cell<sup>193,194</sup>.

Linear regression analysis was used to quantify correlation between continuous variables. For example regression analysis of photometric measurements was used to detect factors which influence changes in iridotomy area on dilating the pupil.

Statistical analyses were performed using a Texas instruments TI 30 STAT calculator, and Cricket software "Statworks" software with a Mackintosh Plus microcomputer.

Statistical results are presented as a p value where a significant difference was found, and "NS" where there was no significant difference between groups.

In our studies of chronic angle closure glaucoma and narrow angle glaucoma (chapter 7), only one eye from each patient was used for statistical analysis, as the two eyes could not be considered to be independent variables.



## CHAPTER 3.

### A RETROSPECTIVE ANALYSIS OF THE OUTCOME OF OPERATIVE SURGERY PROCEDURES FOR ANGLE CLOSURE GLAUCOMA

#### 3.1 SUMMARY

A retrospective analysis of the 2-5 year outcome of surgery for angle closure glaucoma was performed using the case records of 137 patients treated in Edinburgh during the period 1980-1985. 20/71(28%) of operations for acute angle closure glaucoma were accompanied by operative or early postoperative complications. There were no significant operative or early postoperative complications among 59 fellow eyes. One eye treated by peripheral iridectomy for acute angle closure glaucoma developed a recurrence of acute angle closure glaucoma due to an imperforate iridectomy.

9/59 (15%) of fellow eyes required medication or had raised intraocular pressure 2-5 years following peripheral iridectomy.

14/59 (24%) of fellow eyes lost 2 or more lines of visual acuity due to cataract development 2-5 years following peripheral iridectomy.

9/15 (60%) of acute angle closure glaucoma eyes were normotensive without medication 2-5 years following peripheral iridectomy. 24/27 (89%) of acute angle closure glaucoma eyes were normotensive without medication 2-5 years following iridencleisis or trabeculectomy.

3/15 (20%) of acute angle closure glaucoma eyes lost 2 or more lines of visual acuity 2-5 years following peripheral iridectomy. 3/27 (11%) of acute angle closure glaucoma eyes lost 2 or more lines of visual acuity 2-5 years following iridencleisis or trabeculectomy. However

analysis of visual acuity results following acute angle closure glaucoma may have been unreliable for a variety of reasons.

All the potential limitations of a retrospective study were encountered, and the need for prospective evaluations of treatments for acute angle closure glaucoma was recognised.

### **3.2 INTRODUCTION**

The outcome of prophylactic peripheral iridectomy in the fellow eye of acute angle closure glaucoma patients has been well documented. Acute angle closure glaucoma following prophylactic peripheral iridectomy is very rare<sup>25,42,43,117</sup>. The reported long term incidence of raised intraocular pressure following iridectomy in the fellow eye ranges from 0 - 19%<sup>25,43,46,86,135</sup>. In the long term 2 - 41% of fellow eyes lose 2 or more lines of visual acuity due to cataract development following peripheral iridectomy<sup>43,45,46,86,87,135</sup>.

However, for a variety of reasons the outcome in eyes with acute angle closure glaucoma is less well understood. It may be difficult to differentiate tissue damage due to acute angle closure glaucoma from the long term complications of surgery used in its treatment.

Peripheral iridectomy almost completely prevents recurrence of acute angle closure glaucoma<sup>25,43</sup>. Peripheral iridectomy following acute angle closure glaucoma results in long term normal intraocular pressure without medication in 70 - 76% of eyes<sup>25,43,46,86,87,95</sup>. Approximately 40% of eyes with acute angle closure glaucoma treated by peripheral iridectomy lose two or more lines of visual acuity after 1 - 5 years<sup>86,87</sup>.

No cases of recurrence of acute angle closure glaucoma have been reported following primary drainage surgery<sup>130,134</sup>. Primary iridencleisis<sup>134</sup> or trabeculectomy<sup>130</sup> for acute angle closure glaucoma

results in long term normal intraocular pressure without medication in more than 90% of eyes. Visual acuity loss due to cataract formation has been reported in 41% of eyes undergoing iridencleisis for acute angle closure glaucoma, after a mean follow up period of 7 years<sup>45</sup>.

In order to obtain further information on the outcome of conventional surgery for angle closure glaucoma in our department, and assess whether our results are consistent with published studies, a retrospective study of the five year outcome of surgery performed during the period 1980 - 1985 was performed.

### **3.3 MATERIALS AND METHODS**

The Ophthalmology department of Edinburgh Royal Infirmary was the only department performing ophthalmic surgery in a region with a population of approximately 900,000 during the study period. Each consultant in the department adhered to a policy of performing prophylactic peripheral iridectomy in the fellow eye. Treatment of the acutely affected eye varied. Acute attacks of less than 48 hours duration which responded promptly to medical treatment were treated by peripheral or sector iridectomy. Acute attacks of more than 48 hours duration, or attacks which responded poorly to initial medical treatment, were treated by primary drainage surgery, in the form of iridencleisis, sector iris inclusion, or trabeculectomy operation. Intermittent and chronic angle closure glaucoma were treated by peripheral iridectomy.

The names and hospital numbers of all patients who had had a peripheral iridectomy or sector iridectomy operation between January 1980 and December 1985, inclusive, were obtained from the operating theatre records. As almost all patients with acute angle closure glaucoma would have had a peripheral iridectomy performed in the fellow eye, most cases would be detected in this way. This method of detecting

cases was believed to be more reliable than use of the Lothian Health Board diagnostic index, which has been found to be inaccurate in as many as 40% of cases <sup>195</sup>.

Patients' age, sex and general health, the results of assessment at presentation, assessment following initial medical treatment, operation details, postoperative complications and the results of assessment five years following surgery were recorded. If the patient had been followed up for less than five years, the assessment at the last clinic visit was recorded.

### **3.4 STATISTICAL ANALYSIS**

Differences between groups were tested using the Unpaired Student t test. When a significant difference was found the Wilcoxon signed rank test was also applied. However in most instances the distribution of variables approximated to normality.

Differences between groups in the distribution of discrete variables were tested using the  $\chi^2$  test. Yates correction was applied as numbers were relatively small <sup>193</sup>.

### **3.5 RESULTS**

182 patients underwent peripheral or sector iridectomy in at least one eye during the study period. The case records of 45 patients (25%) could not be traced. The case records of 137 patients were obtained. The distribution of diagnoses of these patients is shown in Table 3.1.

Diagnosis	Number of patients
Unilateral acute ACG	79
Bilateral acute ACG	5
Unilateral chronic ACG	14
Bilateral chronic ACG	18
Unilateral intermittent ACG	4
Bilateral intermittent ACG	7
Others, e.g. pupil seclusion	10
Total	137

**Table 3.1 Retrospective study of Angle Closure Glaucoma.**  
**Diagnostic categories**  
 "ACG"=Angle Closure Glaucoma

### 3.5.1 FELLOW EYE.

97 patients had one eye which could be identified as a "fellow" eye. These consisted of:

79 patients with unilateral acute angle closure glaucoma with an asymptomatic "fellow" eye.

4 patients with unilateral symptoms of intermittent angle closure glaucoma and an asymptomatic "fellow" eye.

14 patients with chronic angle closure glaucoma and a "fellow" eye with no symptoms or signs of glaucoma.

69 of these patients had been followed up for at least 2 years, and 41 for 5 years. Of the remaining 28 patients, 9 had been discharged from follow up within 6 months of presentation, and 2 between 6 months and 2 years of presentation. 3 had been transferred to another health district, and 14 were lost to follow up, and could not be traced.

Of the 69 patients with a 2 - 5 years follow up, 59 had had a peripheral iridectomy performed in the fellow eye, 9 were treated conservatively and one had had an iridencleisis operation.

The results of initial assessment of the 59 patients who

underwent prophylactic peripheral iridectomy in the fellow eye and were available for follow up 2-5 years later are shown in Table 3.2.

Age, years	66.9±10.4
Male : Female ratio	19 : 40
Mean Intraocular Pressure, mm Hg	18.1±6.2
Number with partly closed angle on gonioscopy	12
Optic disc cupping	0
Field loss	0

**TABLE 3.2**  
**Retrospective study of patients undergoing peripheral iridectomy in the fellow eye: initial findings**

The intraocular pressure was greater than 21 mm Hg in 13 eyes - 7 eyes had an intraocular pressure of 22 - 25 mm Hg, 4 of 26 - 29 mm Hg, and 2 eyes had an intraocular pressure greater than 30 mm Hg.

Following initial medical treatment the mean intraocular pressure was 15.2±3.7 mm Hg, and 3 eyes had an intraocular pressure between 22 and 25 mm Hg.

### **3.5.1.1 OPERATION**

Surgery was performed under local anaesthetic in 28 patients, and general anaesthetic in 31 patients.

### **3.5.1.2 OPERATIVE COMPLICATIONS**

One of the patients followed for less than 2 years developed an aqueous leak from the wound postoperatively, which sealed spontaneously. None of the 59 patients followed for 2 - 5 years had significant operative or early post operative complications.

### **3.5.1.3 2 – 5 YEAR FOLLOW UP**

No patient developed acute angle closure glaucoma following peripheral iridectomy.

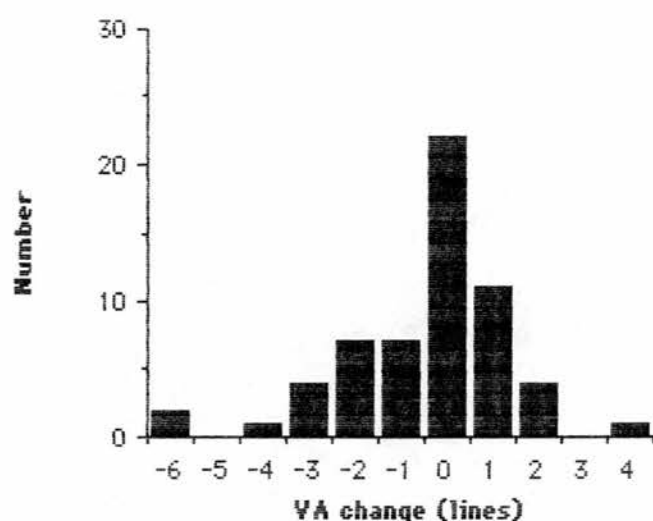
#### **3.5.1.3.1 GLAUCOMA OUTCOME**

9 (15%) patients were using topical medication or had an intraocular pressure greater than 21 mm Hg in the fellow eye at follow up. One of these patients had developed pathological optic disc cupping and glaucomatous visual field loss during the follow up period. A second patient, a 73 year old male with a history of ischaemic heart disease, developed pathological optic disc cupping and glaucomatous visual field loss despite apparently normal intraocular pressure readings.

However only 3 of these 9 patients had had acute unilateral angle closure glaucoma with a normotensive fellow eye at presentation. 3 had had unilateral angle closure glaucoma with raised intraocular pressure in the fellow eye, 2 had had unilateral intermittent angle closure glaucoma with a normotensive fellow eye, and one had had unilateral chronic angle closure glaucoma with a normotensive fellow eye.

#### **3.5.1.3.2 VISUAL ACUITY OUTCOME**

The distribution of visual acuity change between presentation and follow up is shown in Figure 3.1.



**Figure 3.1. Retrospective study of operative peripheral iridectomy in the fellow eye. Distribution of visual acuity change between initial presentation and 2-5 year follow up.**

14/59 (24%) patients lost 2 or more lines of visual acuity, in 9 cases due to cataract development in previously clear lenses, and in 5 cases due to progression of pre existing cataract.

Two patients underwent cataract surgery during the follow up period. One had had a clear lens prior to peripheral iridectomy, and one had had nuclear cataract.

### **3.5.2 ACUTE ANGLE CLOSURE GLAUCOMA**

Of the 84 patients with acute angle closure glaucoma, 71 were treated with either peripheral iridectomy, iridencleisis, trabeculectomy or sector iridectomy. Sector iris inclusion operations were included in the iridencleisis group. Only one eye was used for statistical analysis in bilateral cases, chosen by tossing a coin.



The results of initial assessment of these 71 patients is shown in Table 3.3. There was no significant difference between any pair of groups in mean age or mean intraocular pressure, using the unpaired Student t test. More patients in the peripheral iridectomy group had a visual acuity of 6/12 or better, but the differences were not significant using the  $\chi^2$  test with Yate's correction. There was insufficient information in the case notes to allow comparison of the duration of acute attack.

	Peripheral Iridectomy	Iridencleisis	Trabeculectomy	Sector Iridectomy
Number of patients	21	23	13	14
Mean age	65.2±10.3	68.1±11.3	64.7±11.1	68.3±8.6
Male : Female	6 : 15	7 : 16	5 : 8	8 : 6
Mean IOP	49.8±15.9	53.4±11.9	53.6±11.7	49.5±19.9
No. patients with vision worse than 6/12	15 (32%)	22 (96%)	13 (100%)	11 (79%)

**TABLE 3.3**  
**Retrospective study. Assessment at presentation.**  
**Acute angle closure glaucoma**

Table 3.4 shows the results of assessment following initial medical control. The mean intraocular pressure of the peripheral iridectomy group was significantly lower than that of the iridencleisis group ( $p < 0.05$ ), or trabeculectomy group ( $p < 0.05$ ), using the unpaired student t test. However differences between the groups fell just short of significance at the  $p = 0.05$  level using the Wilcoxon signed rank test. The proportion of patients with miosed pupils following initial medical treatment was significantly higher in the peripheral iridectomy group than the iridencleisis group ( $p < 0.01$ ) or the trabeculectomy group ( $p < 0.05$ ), using the  $\chi^2$  test with Yate's correction. These findings confirm that patients treated with peripheral iridectomy had a less severe form of acute angle closure glaucoma than patients treated with iridencleisis or trabeculectomy.

	Peripheral Iridectomy	Iridencleisis	Trabeculectomy	Sector Iridectomy
Number patients	21	23	13	14
Mean IOP, mm Hg	16.0±3.9	19.4±8.4	22.8±15.2	18.9±9.3
IOP > 21 mm Hg	1 (5%)	7 (30%)	3 (23%)	3 (21%)
Pupil large	2 (10%)	14 (61%)	6 (46%)	2 (14%)
Corneal oedema	0	8 (35%)	6 (46%)	2 (14%)

**TABLE 3.4**  
**Retrospective Study. Assessment following initial**  
**medical control. Acute angle closure glaucoma**

Operative complications are shown in Table 3.5. There were no significant differences between the groups. One peripheral iridectomy operation did not result in a full thickness iris opening. This was not recognised, and the patient developed acute angle closure glaucoma three days later.

	Peripheral Iridectomy	Iridencleisis	Trabeculectomy	Sector Iridectomy
Iridectomy not patent	1	0	0	0
Hyphaema	1	3	0	2

**TABLE 3.5**  
**Retrospective Study. Operative Complications.**  
**Acute angle closure glaucoma**

Table 3.6 shows the complications which occurred during the first week after operation. There were no statistically significant differences between the groups, however numbers were small.

	Peripheral Iridectomy	Iridencleisis	Trabeculectomy	Sector Iridectomy
Number patients	21	23	13	14
Acute ACG	1	0	0	0
IOP>21mm Hg	3	1	2	0
Shallow AC	0	4	2	0
Flat AC	0	1		0
Hyphaema	1	2	1	2
Total	5 (24%)	8 (35%)	5 (38%)	2 (14%)

**TABLE 3.6**  
**Retrospective Study. Complications during the first week following operation. Acute angle closure glaucoma.**

### 3.5.2.1 2-5 YEAR FOLLOW UP

49 patients completed 2-5 years of follow up. 7 patients were discharged after less than 2 years of follow up, 3 were transferred to a different health district, and 12 were lost to follow up and could not be traced.

#### 3.5.2.1.1 GLAUCOMA OUTCOME

Table 3.7 shows the glaucoma outcome 2-5 years following treatment. There was no significant difference between any pair of groups in the mean intraocular pressure at follow up, using the unpaired Student t test. 6/15 (40%) of peripheral iridectomy patients required some form of additional glaucoma treatment. 9/15 (60%) remained normotensive without medication. While the glaucoma outcome appeared to be better than this in each of the other groups the differences did not reach statistical significance using the  $\chi^2$  test with Yate's correction.

Pathological optic disc cupping and glaucomatous visual field loss occurred in two peripheral iridectomy patients and one sector iridectomy patient, but did not occur following drainage surgery.

	Peripheral Iridectomy	Iridencleisis	Trabeculectomy	Sector Iridectomy
Number patients	15	17	10	7
Mean IOP mm Hg	15.5±4.0	15.0±3.5	15.4±2.5	17.2±2.1
IOP > 21 mm Hg	1	0	0	0
Cupped disc	2	0	0	1
Field loss	2	0	0	1
"Pale" disc	0	2	1	0
Drainage op.	3	0	0	0
Medical Rx	4	2	1	0
Any glaucoma treatment	6 (40%)	2 (12%)	1 (10%)	0

TABLE 3.7

**Retrospective Study. Glaucoma outcome 2-5 years following treatment. Acute angle closure glaucoma.**

### 3.5.2.1.2 VISUAL ACUITY OUTCOME

Table 3.8 shows the visual acuity outcome 2-5 years following treatment.

A lower proportion of peripheral iridectomy patients than iridencleisis patients, trabeculectomy patients or sector iridectomy patients had a visual acuity worse than 6/12. This difference was not statistically significant using the  $\chi^2$  test with Yate's correction. However as visual acuity at initial presentation was better in the peripheral iridectomy group differences in visual outcome cannot be attributed to the effects of surgery, using this form of analysis.

	Peripheral Iridectomy	Iridencleisis	Trabeculectomy	Sector Iridectomy
Number patients	15	17	10	7
VA < 6/12	6 (40%)	13 (76%)	6 (60%)	5 (71%)
Causes VA <6/12:				
Newly developed cataract:	3	2	0	2
Pre existing cataract:	1	11	2	3
Other:	2	0	4	0

**TABLE 3.8**

**Retrospective Study. Causes of reduced visual acuity 2-5 years following treatment of acute angle closure glaucoma**

"Other" includes age related macular degeneration, amblyopia, and ischaemic optic neuropathy.

A more useful measure of visual acuity outcome is visual acuity loss during the follow up period. The causes of visual acuity loss by two or more lines of visual acuity are shown in Table 3.9. There were no significant differences between the groups. An increased rate of cataract development following drainage surgery compared to peripheral or sector iridectomy was not demonstrated.

	Peripheral Iridectomy	Iridencleisis	Trabeculectomy	Sector Iridectomy
Number patients	15	17	10	7
Visual loss $\geq 2$ lines	3	2	1	4
Causes visual loss:				
Newly developed cataract:	3	2	0	2
Pre existing cataract:	0	0	0	2
BRVO:	0	0	1	0

**TABLE 3.9**

**Retrospective Study. Causes of loss of two or more lines of visual acuity after 2-5 years follow up. Acute angle closure glaucoma**

BRVO = Branch retinal vein occlusion

### **3.5.3 CHRONIC ANGLE CLOSURE GLAUCOMA**

Information in the case records was inadequate to make an analysis of the outcome of peripheral iridectomy in chronic angle closure glaucoma. While 32 patients had a diagnosis of chronic angle closure glaucoma written in the case records, only 6 eyes of 4 patients had documented raised intraocular pressure and a partly closed angle prior to operation, underwent peripheral iridectomy, and were followed up for more than 2 years.

### **3.5.4 INTERMITTENT ANGLE CLOSURE GLAUCOMA**

A 1-5 year follow up was available for 13 eyes of 8 patients treated by peripheral iridectomy for symptoms of intermittent angle closure glaucoma. At follow up one eye required medication to maintain normal intraocular pressure. All other eyes were normotensive without medication. The visual acuity was 6/12 or better in every eye, all optic discs were normal, all visual fields were full and all patients were asymptomatic.

### **3.6 DISCUSSION**

In common with many retrospective studies the reliability of conclusions derived from this analysis is limited by several potential sources of bias.

1. Case record retrieval was incomplete. 25% of case records could not be obtained. Our case records are shared with other departments in the hospital. It is possible that a proportion of unobtainable case records had been lost following a patient's visit to a clinic in another department. A higher proportion of unobtainable case records could have belonged to patients in poor general health.

2. Recording of information in case records was incomplete. There was considerable variation in the completeness of clinical examination findings recorded.

3. Variation in indications for operations. There was no protocol by which a particular operation was chosen for a particular clinical situation. There was bias towards the use of peripheral iridectomy in milder attacks of acute angle closure glaucoma, as indicated by a lower mean intraocular pressure and a higher rate of miosis following initial medical treatment in these cases. The results of the four types of

operation used to treat acute angle closure glaucoma were therefore not directly comparable.

4. Inadequate follow up. The number of patients followed up for 2 - 5 years was inadequate. Patients discharged within two years of surgery may have had better vision and better glaucoma control than patients who were kept under review. Lowe attempted to carry out a five year follow up of 52 patients who had had surgery for angle closure glaucoma<sup>43</sup>. Only 26 (50%) were available for review. Of the 26 who did not attend, 18 probably had died and 8 had been discharged from follow up and could not be traced.

### **3.6.1 FELLOW EYES**

Peripheral iridectomy completely prevented acute angle closure glaucoma in our study, confirming the results of previous studies<sup>25,43,86,87</sup>.

9/59 (15%) of patients in our study were using topical medication or had an intraocular pressure greater than 21mm Hg in the fellow eye 2-5 years following peripheral iridectomy. Previous studies have found 0<sup>25,42,46</sup>, 3%<sup>135</sup>, 12%<sup>86</sup>, 19%<sup>43</sup> and 35%<sup>87</sup> of fellow eyes needed medication to maintain normal intraocular pressure 1 - 12 years after peripheral iridectomy (see Table 1.11).

14/59 (24%) of patients in our study lost 2 or more lines of visual acuity in the fellow eye due to cataract development 2-5 years following peripheral iridectomy. Floman found that 33% of fellow eyes lost 2 or more lines of visual acuity due to cataract development after a follow up period of 2-4 years<sup>87</sup>. Krupin found that 15% of fellow eyes lost 3 or more lines of visual acuity due to cataract development after a mean follow up period of 52 months<sup>86</sup>. Godel found that 40% of fellow eyes developed cataracts 1 - 4 years after peripheral iridectomy, compared to



8% in a control group treated conservatively <sup>196</sup> (see Table 1.12).

Our long term results of operative peripheral iridectomy in fellow eyes are therefore comparable to previously published studies.

### **3.6.2 ACUTE ANGLE CLOSURE GLAUCOMA EYES**

One case of recurrent angle closure glaucoma, due to an imperforate peripheral iridectomy, occurred in our study. Acute angle closure glaucoma in the presence of a patent peripheral iridectomy is very unusual, and has not occurred in several large series <sup>25,43,86,87</sup>.

We found that 60 % of acute angle closure glaucoma eyes treated with peripheral iridectomy were normotensive without medication 2-5 years after surgery. In contrast 89% of eyes treated with primary drainage surgery, in the form of either trabeculectomy or iridencleisis, were normotensive without medication. There was no significant difference between these outcomes using the  $\chi^2$  test with Yate's correction.

Previous studies have found that 60 - 90% of acute angle closure glaucoma eyes treated with peripheral iridectomy remain normotensive without medication in the long term <sup>25,43,44,46,86,87,135</sup> (see table 1.10). Most workers have reported a rate of 70 - 75% <sup>25,43,46,86,87</sup> (see table 1.10).

Primary drainage surgery for acute angle closure glaucoma has been reported to result in normal intraocular pressure without medication in more than 90% of eyes at follow up <sup>130,134</sup> (see table 1.10). Our finding of 89% of eyes normotensive without medication is comparable to the results of these studies.

Assessment of visual outcome following acute angle closure glaucoma is difficult. The visual acuity prior to the acute attack is often unknown, and vision is reduced for several days following the acute

attack. Visual acuity normally improves during the first four weeks following the acute attack, due to resolution of corneal oedema, stabilisation of intraocular pressure, resolution of intraocular inflammation, and recovery of neuroretinal and optic nerve head function. Residual visual acuity loss due to cataract could be attributed to either the effects of acute angle closure glaucoma, or to the deleterious effects of surgery.

We found that 70% of patients treated with primary drainage surgery in the form of either iridencleisis or trabeculectomy, had a visual acuity worse than 6/12 two to five years following surgery, compared to 40% of patients treated with peripheral iridectomy. This difference was not statistically significant, and in any case eyes treated with primary drainage surgery had worse visual acuity before surgery than eyes treated with peripheral iridectomy.

It is difficult to assess the state of the lens and measure visual acuity during the interval between medical treatment of an acute attack and definitive surgical treatment. Our figures for visual loss due to cataract progression following surgery are probably unreliable. We found that 3/15 (20%) of peripheral iridectomy patients, and 3/27 (11%) of primary drainage patients appeared to lose 2 or more lines of visual acuity between the time of assessment following initial medical control, and the 2 - 5 year follow up assessment. Reports of visual loss due to cataract following acute angle closure glaucoma treated by peripheral iridectomy vary. Floman found that 51% of eyes lost 2 or more lines of visual acuity after a mean follow up period of 4.2 years<sup>87</sup>. Krupin found that 39% of eyes lost 3 or more lines of visual acuity after a mean follow up period of 52 months<sup>86</sup>. Playfair found that 12% of eyes had needed cataract surgery during a 5 year follow up period<sup>25</sup>. Lowe found that 19% of eyes had developed a dense cataract after 5 years<sup>43</sup> (see

Table 1.12). Visual acuity outcome has been found to be consistently worse in the acute eye than in the fellow eye <sup>25,43,46,86,87,101</sup>.

The long term visual acuity outcome following primary drainage surgery for acute angle closure glaucoma has not been adequately documented. Sugar found that 7 of 17 eyes with acute angle closure glaucoma treated with iridencleisis developed cataract after a mean follow up period of 7.8 years <sup>45</sup>.

### **3.6.3 SUMMARY OF RESULTS**

Peripheral iridectomy reliably prevents further episodes of acute angle closure glaucoma in acutely affected and fellow eyes. 85% of fellow eyes were normotensive without medication 2-5 years after peripheral iridectomy. 24% of fellow eyes treated with peripheral iridectomy lost two or more lines of visual acuity due to cataract 2-5 years after surgery. 60% of acute angle closure glaucoma eyes treated with peripheral iridectomy were normotensive without medication 2 - 5 years after surgery, and 89% of eyes treated with primary drainage surgery were normotensive, although this difference was not statistically significant. 20% of acute angle closure glaucoma eyes treated with peripheral iridectomy lost 2 or more lines of visual acuity due to cataract 2-5 years after surgery. However, assessment of visual acuity loss following acute angle closure glaucoma is unreliable.

While the limitations of a retrospective study have reduced the reliability of these results, they indicate that the outcome of surgical treatment of angle closure glaucoma in Edinburgh during the period 1980-1985 was similar to previously published results.

## **CHAPTER 4.**

### **Nd:YAG LASER IRIDOTOMY IN FELLOW EYES.**

#### **A RANDOMISED, PROSPECTIVE COMPARISON OF ND:YAG LASER IRIDOTOMY AND OPERATIVE PERIPHERAL IRIDECTOMY IN THE FELLOW EYE OF PATIENTS WITH ACUTE ANGLE CLOSURE GLAUCOMA**

##### **4.1 SUMMARY**

A prospective, randomised comparison of Nd:YAG laser iridotomy and operative peripheral iridectomy in the fellow eye of 52 patients presenting with acute angle closure glaucoma has been undertaken. Nd:YAG laser iridotomy resulted in a significantly higher incidence of iris bleeding at the time of treatment ( $p < 0.05$ ), higher intraocular pressure one hour ( $p < 0.02$ ) and three hours ( $p < 0.02$ ) following treatment, and a higher incidence of focal corneal oedema 24 hours following treatment ( $p < 0.001$ ). One laser treated patient developed acute angle closure glaucoma two weeks following treatment despite the presence of a small patent iridotomy. After a mean follow up period of 11.8 months there was no significant difference between the two groups in visual acuity or intraocular pressure.

##### **4.2 INTRODUCTION**

While several studies have compared argon laser iridotomy and Q switched Nd:YAG laser iridotomy <sup>10,11,13,22,23</sup>, and one study has compared argon laser iridotomy and operative peripheral iridectomy <sup>95</sup>, formal comparison of Nd:YAG laser iridotomy and operative peripheral iridectomy has not been undertaken. We have performed a randomised,

prospective comparison of the early post-treatment complications, glaucoma outcome and visual acuity outcome of Nd:YAG laser iridotomy and operative peripheral iridectomy in the fellow eyes of a group of patients presenting with acute angle closure glaucoma.

Fellow eyes are a particularly satisfactory "model" with which to compare these two forms of treatment. Fellow eyes have, in general, no preexisting disease, but are at risk of developing acute angle closure glaucoma without prophylactic treatment<sup>42</sup>. Unlike eyes which have sustained an attack of acute angle closure glaucoma it may be assumed that corneal endothelium changes<sup>76,81,82</sup>, or cataract development<sup>25,43,86,87</sup> following prophylactic treatment will be due to the treatment rather than the preexisting disease, allowing for normal ageing changes.

### **4.3 MATERIALS AND METHODS**

Approval to perform a randomised prospective comparison of Nd:YAG laser iridotomy and operative peripheral iridectomy was obtained from the regional surgical subspecialties ethical committee. Consecutive patients presenting with acute angle closure glaucoma in one eye during the period January 1987 to June 1989 were referred to the study if the consultant in charge of the case believed the patient was suitable for either Nd:YAG laser iridotomy or surgical peripheral iridectomy in the fellow eye. If the fellow eye had an intraocular pressure greater than 21 mm Hg or a cup:disc ratio greater than 0.6 the patient was excluded from the study. Informed patient consent to inclusion in the study was obtained before randomisation. Randomisation was stratified into a group aged more than 70 years, and a group aged less than 70 years. Randomisation was carried out by opening the top envelope in a container of consecutively numbered sealed envelopes. The envelope contained a card marked "surgery" or "laser", and the number of the envelope. The

allocation of "surgery" or "laser" to each number had been performed using a random number generator computer programme prior to commencement of the trial, and the cards were placed in the envelopes by a person not involved in the trial.

Initial examinations were performed by one observer (BWF), and included assessment of corrected visual acuity, intraocular pressure, Goldman gonioscopy, slit lamp examination of the lens, and fundal examination. Specular microscopy was performed using a Keeler-Konan Pocklington specular microscope. Several central fields were photographed and stored for later analysis.

48 hours prior to operative or laser treatment all systemic and topical intraocular pressure lowering agents, other than G Pilocarpine 2%, were discontinued. One drop of G Pilocarpine 2% was instilled one hour before treatment.

#### **4.3.1 OPERATIVE SURGERY**

Operative peripheral iridectomy was performed under general anaesthetic, or subconjunctival local anaesthetic. Retrobulbar local anaesthetic was not used, in order to avoid possible changes in intraocular pressure induced by this procedure during the early postoperative period. A corneal incision was performed, the peripheral iris was grasped with grooved forceps, and a peripheral iridectomy was made using scissors. The incision was not sutured, in order to minimise postoperative irritation, and facilitate early measurement of intraocular pressure.

#### **4.3.2 LASER TREATMENT**

Nd:Yag laser iridotomy was performed by one surgeon (BWF). A Zeiss "Visulas" Nd:YAG laser and Zeiss anterior segment YAG contact lens

were used in all treatments. A treatment site was chosen in the superior iris, between 10 and 2 o'clock, approximately 2/3 distance from the pupil margin to the base of the iris. An iris crypt was used when present. A single 5-10 mJ pulse was delivered to the treatment site. If this pulse did not penetrate the iris, further single pulses were delivered to the same site until penetration was achieved. A gush of aqueous fluid from the posterior chamber could be seen at the moment of penetration. Patency was assessed by direct observation of the posterior chamber, or anterior lens capsule.

### **4.3.3 POST TREATMENT ASSESSMENT**

Goldman applanation tonometry was performed 1, 2, 3, 6 and 24 hours following treatment. A Perkins hand held applanation tonometer was used to measure the early postoperative intraocular pressure in some surgical patients who had had a general anaesthetic. Systemic and topical intraocular pressure lowering agents were withheld unless the pressure rose above 40 mm Hg.

Twenty four hours after treatment the cornea was examined and focal oedema scored as 0 = no abnormality, + = focal granular changes in the corneal endothelium overlying the treatment site, or ++ = focal full thickness corneal oedema. Iritis was judged to be present if there were more than 5 white cells per field using a 3 mm long, 0.2 mm wide slit beam focussed in the central anterior chamber. The presence of dispersed pigment particles in the aqueous was not judged to be indicative of iritis. Intraocular pressure was measured, the iridotomy or iridectomy inspected for patency, and the lens examined. No topical treatment was given unless significant iritis was present, in which case G. Betamethasone 0.1% four times daily for one week was prescribed. Mydriatics were not used.

#### **4.3.4 FOLLOW UP**

Patients were assessed 1 week, 1 month, 6 months, 12 months and then annually following treatment. Examinations were performed by one of three observers (BWF, EW, or EF) in the iridotomy research clinic. Corrected visual acuity, intraocular pressure, examination of the lens and examination of the optic disc were carried out at every visit. The vertical cup:disc ratio was recorded in decimal form. The pupil was dilated using G. Phenylephrine 10% one month following treatment in order to detect posterior synechiae, and examine the lens and fundus.

Six months following treatment specular microscopy, gonioscopy and provocation testing were performed. Goldman gonioscopy was performed on all patients by BWF, EW or EF, followed by Posner 4 mirror indentation gonioscopy by BWF if any part of the angle appeared to be closed. Pilocarpine/phenylephrine provocation testing as described by Mapstone<sup>68</sup> and modified by Harrad<sup>105</sup> was used. One drop of G. Phenylephrine 10% and one drop of G. Pilocarpine 2% were instilled. The intraocular pressure was measured one hour later. Visual field examinations were performed when clinically indicated, but did not form an integral part of the study. A Friedman visual field analyser was used.

#### **4.3.5 SPECULAR MICROSCOPY ANALYSIS**

Patients were coded by number, and endothelial cell counts were performed by an observer unaware of the coding system. Using standardised print magnification and a transparent grid, three representative fields of 0.05 mm<sup>2</sup> were chosen for each patient, and the cells within these fields were counted. The mean value for the three areas was then calculated.



#### 4.3.6 STATISTICAL ANALYSIS

Where appropriate the unpaired Student t test or the  $\chi^2$  test with Yate's correction were used to test the significance of differences between the two groups. Statistical results are presented as a "p" value where a significant differences exists, and "NS" where there is no significant difference.

#### 4.4 RESULTS

70 patients presented with acute or subacute angle closure glaucoma during the study period. Two patients had bilateral acute angle closure glaucoma. Thirteen patients were not thought to be equally suitable for Nd:YAG laser iridotomy or operative peripheral iridectomy by the consultant in charge of the case, or declined inclusion in the trial. Three patients had an intraocular pressure greater than 21 mm Hg, or pathological optic disc cupping in the fellow eye and were excluded from the study.

52 patients were included in the study, 26 treated by Nd:YAG laser iridotomy and 26 treated by operative peripheral iridectomy. The minimum follow up period was 6 months. Thirteen patients from the surgical group and sixteen patients from the laser treated group had completed one year of follow up at the time of analysis. The mean follow up time for the surgical group was  $11.7 \pm 8.7$  months, and that of the laser treated group  $16.1 \pm 11.0$  months (unpaired Student t test NS). Two patients in the laser treated group died due to ischaemic heart disease, in each case approximately nine months following treatment. No patients were lost to follow up.

Details of initial assessment of the two groups are given in Tables 4.1 and 4.2. The two groups were very similar in composition.

	Surgery	Laser	P
Number	26	26	
Male : Female	9:17	7:19	
Age (years)	67.5±13.1	68.3±12.6	NS
Age range	41 - 88	40 - 88	
Right : Left	10:6	11:15	

**TABLE 4.1**

**Prospective comparison of operative peripheral iridectomy and Nd:YAG laser iridotomies in fellow eyes. Patient Groups.**

Figures are presented as mean ± one standard deviation. P = statistical p value, NS = Not statistically significant.

	Surgery	Laser	P
Corrected visual acuity worse than 6/9 due to cataract	3	4	
Intraocular pressure (mm Hg)	15.0±3.6	15.5±3.4	NS
Intraocular pressure, range	6-20	8-21	
Gonioscopy (Goldman)			
partly closed	6	6	
Iris colour Brown:Grey	10:16	10:16	

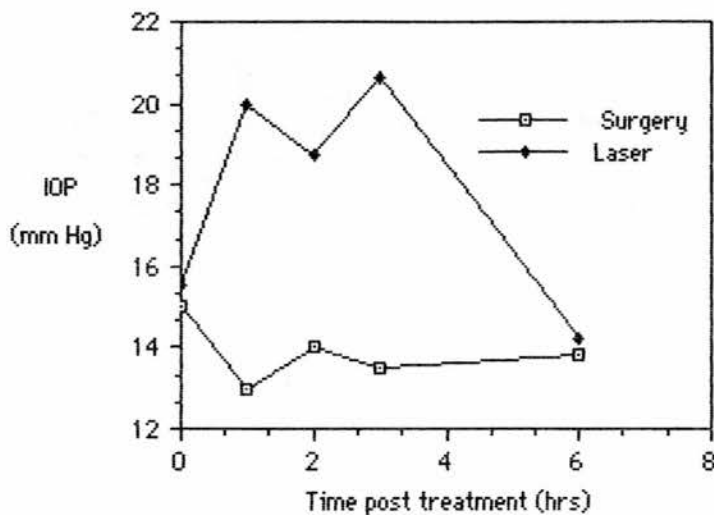
**TABLE 4.2**

**Prospective comparison of operative peripheral iridectomy and Nd:YAG laser iridotomies in fellow eyes. Initial Assessment.**

A patent laser iridotomy was obtained at the initial treatment session in 25 patients. Treatment sessions on three consecutive days were needed to obtain a patent iridotomy in one patient. A patent iridectomy was produced in all surgical patients. A mean of  $3.1 \pm 2.6$  pulses (range 1-10) with a mean total energy of  $25.8 \pm 21.4$  mJ (range 4.9-72.9 mJ) was used in laser treatment. One pulse was sufficient to create an adequate iridotomy in 11 patients, and less than 10 mJ total energy was used in 10 patients. Slight iris bleeding occurred at the time of treatment in 15 laser patients and 7 surgical patients ( $\chi^2$  test with Yate's correction  $p < 0.05$ ). There were no other operative complications.

#### 4.4.1 IMMEDIATE POST-TREATMENT ASSESSMENT

The mean intraocular pressure before treatment and 1,2,3 and 6 hours following treatment is shown in Figure 4.1.



**Figure 4.1. Early post treatment intraocular pressure changes in fellow eyes following operative peripheral iridectomy and Nd:YAG laser iridotomy.**

Complete data was available in 9 surgically treated patients and 15 laser treated patients. The groups were significantly different 1 hour and 3 hours following treatment using the unpaired Student t test ( $p < 0.02$  in each case). Two surgically treated patients (8%) developed an intraocular pressure rise to between 20 and 25 mm Hg within 3 hours of surgery. Seven laser treated patients (27%) developed an intraocular pressure rise to greater than 21 mm Hg. The intraocular pressure rose to 30-40 mm Hg in two patients, and above 40 mm Hg in two patients.

Of the 15 laser treated patients with complete intraocular pressure data, the peak pressure occurred one hour following treatment in 7, at two hours in 4, and at three hours in 4. In all but two cases the intraocular pressure had returned to normal six hours following treatment.

#### 4.4.2 ASSESSMENT 24 HOURS POST TREATMENT

The results of examination 24 hours following treatment are shown in Table 4.3.

	Surgery	Laser	P
Focal corneal oedema	0	15	<0.001
Grade: +		11	
++		4	
Intraocular pressure, mm Hg	11.1±3.1	12.2±4.0	NS
Iritis	11	6	NS
Patent	26	26	
Focal lens opacities	6	2	

**TABLE 4.3**

**Prospective comparison of operative peripheral iridectomy and Nd:YAG laser iridotomy in fellow eyes. Examination 24 hours following treatment.**

P = statistical p value, NS = Not statistically significant.

Focal corneal damage was evident in 15/26 (58%) of laser treated patients, and in no surgical patients ( $\chi^2$  test with Yate's correction  $p < 0.001$ ). In mild cases the appearance was of slight granularity of the endothelium overlying the treatment site. However in grade ++ cases focal full thickness corneal oedema was present. Focal corneal oedema was most marked 24 hours following laser treatment, and had fully resolved after one week in all cases. Corneal changes were not seen following operative peripheral iridectomy.

The total laser energy used to treat the 15 patients who subsequently developed focal corneal oedema was  $30.95 \pm 21.6$  mJ, compared with  $18.2 \pm 19.7$  mJ in those who did not. This difference was not statistically significant, using the unpaired Student t test.

The total laser energy used to treat the six patients who

subsequently developed iritis was  $39.75 \pm 26.2$  mJ, compared with  $20.7 \pm 18.2$  mJ in those who did not. Again this difference was not statistically significant using the unpaired Student t test.

Six surgical patients were found to have minimal focal lens opacities at the iridectomy site due to mild operative trauma affecting the anterior lens capsule. These opacities were not progressive and did not lead to visual loss during the follow up period. Two laser treated patients developed focal lens opacities underlying the treatment site. In one case a faint haze was present deep to the anterior capsule, which did not progress and was not associated with reduced visual acuity. The second case developed polychromatic crystals in the anterior lens cortex underlying the treatment site, and subsequently developed a nuclear cataract with loss of one line of visual acuity, from 6/9 to 6/12.

#### **4.4.3 1 MONTH FOLLOW UP**

One laser treated patient developed acute angle closure glaucoma three weeks following treatment. The patient had been using cyclopentolate 1% drops to the acutely affected eye following trabeculectomy, and may have inadvertently contaminated the fellow eye. Following treatment with pilocarpine 2% the intraocular pressure returned to normal. The iridotomy was small ( $50\mu \times 50\mu$ ) but patent. Further laser treatment was performed in order to enlarge the opening, resulting in no further symptoms. Subsequent pilocarpine/phenylephrine and cyclopentolate provocation tests were negative. Further details of this case are given in chapter 6, pages 133-136 (case 2).

One patient was found to have developed iridotomy closure two weeks following treatment and further laser treatment to re open the iridotomy was performed.

Posterior synechiae developed in three surgical patients, and three

laser treated patients. Two of the surgical patients and one of the laser treated patients had had iritis at the 24 hours post-treatment examination. The adhesions were of minimal extent in all cases, did not progress, and were not associated with subsequent cataract development or loss of visual acuity.

#### 4.4.4 SIX MONTH FOLLOW UP

Table 4.4 summarises findings in the two groups six months following treatment.

	Surgery	Laser	P
Visual acuity loss of two or more lines.	0	2	NS
Posterior synechiae	3	3	NS
Intraocular pressure, mm Hg	14.5±2.7	15.0±3.2	NS
Gonioscopy -angle partly closed	0	2	NS
Provocation test positive	0	0	NS

**TABLE 4.4**  
**Prospective comparison of operative peripheral iridectomy and Nd:YAG laser iridotomy in fellow eyes.**  
**Examination 6 months following treatment.**

When compared with pretreatment measurements visual acuity was unchanged, or changed by only one line in all surgical patients. However in the laser treated group visual acuity deteriorated by two or more lines in two patients. These patients had developed nuclear cataract - one in a previously clear lens, and one in a lens with pre existing nuclear cataract.

The mean intraocular pressure was 14.5±2.7 mm Hg in the surgical group and 15.0±3.2 mm Hg in the laser treated group (unpaired Student t test NS). One laser treated patient had an intraocular pressure of 25 mm

Hg. All other patients had an intraocular pressure of less than or equal to 21 mm Hg, and no patient required topical medication.

All iridotomies and iridectomies were patent. Gonioscopy revealed an open angle in all surgical patients, with focal goniosynechia adjacent to the iridectomy in two patients.

Two laser treated patients had partly closed angles on Goldman gonioscopy, but the angles were open on indentation. One of these patients had focal areas of goniosynechia adjacent to the iridotomy site. The iridotomy size in these patients was not excessively small, one measured 100 $\mu$ x200 $\mu$  and the other 100 $\mu$ x500 $\mu$ .

No patient developed more than a 10% change in the cup:disc ratio during the follow up period. Pilocarpine/phenylephrine provocation tests were performed on 14 surgical patients and 23 laser treated patients. All tests were negative.

Satisfactory pretreatment and 6 month post-treatment specular micrographs were obtained in 7 surgical patients and 9 laser treated patients. The endothelial cell counts derived from the photographs are shown in Table 4.5.

	Surgery	Laser	P
Pre treatment density, mm <sup>-2</sup>	2470.3 $\pm$ 522.7	2531.7 $\pm$ 649.1	NS
Post treatment density, mm <sup>-2</sup>	2442.0 $\pm$ 557.1	2188.0 $\pm$ 560.7	NS
Percentage change	-3.6 $\pm$ 3.95	-7.2 $\pm$ 10.6	NS

**TABLE 4.5**  
**Prospective comparison of operative peripheral iridectomy**  
**and Nd:YAG laser iridotomy in fellow eyes.**  
**Corneal Endothelium cell density.**

P = statistical p value, NS = Not statistically significant.

The two groups did not significantly differ in mean endothelial cell count either before or 6 months following treatment. There was no

significant percentage change in endothelial cell count following treatment in either group, and no difference between the two groups.

#### **4.4.5 FINAL FOLLOW UP**

At the final follow up examination an additional two laser treated patients with initially clear lenses were found to have developed nuclear cataract sufficient to cause two or more lines of visual acuity loss. A total of four laser treated patients lost two or more lines of visual acuity due to cataract. Lens changes sufficient to cause two or more lines of visual acuity loss did not occur in any surgical patient ( $X^2$  NS). The intraocular pressure at final follow up was  $14.9 \pm 2.4$  mm Hg in the surgical group, and  $14.3 \pm 2.4$  mm Hg in the laser treated group (unpaired Student t test NS). No patient had an intraocular pressure greater than 21 mm Hg, but one laser treated patient was using topical  $\beta$  blocker medication to maintain normal intraocular pressure.

### **4.5 DISCUSSION**

#### **4.5.1 ACUTE ANGLE CLOSURE GLAUCOMA FOLLOWING PROPHYLACTIC IRIDOTOMY OR IRIDECTOMY**

One laser treated patient developed acute angle closure glaucoma despite the presence of a small, patent iridotomy. Enlargement of the iridotomy led to resolution of symptoms. Subsequent pilocarpine/phenylephrine and cyclopentolate provocation tests were negative.

Lowe found that conservative treatment of the fellow eye resulted in a 50% incidence of subsequent acute angle closure glaucoma<sup>42</sup>. However, acute angle closure glaucoma following prophylactic surgical peripheral iridectomy is extremely rare<sup>25,42,43,117</sup>. Small argon<sup>132, 133</sup> or Nd:YAG<sup>15,21,80,106</sup> laser iridotomies may, however, fail to prevent



acute angle closure glaucoma. The size of the iridotomy appears to be crucial, as acute angle closure glaucoma has only been reported in iridotomies less than 150 $\mu$  in diameter<sup>15,21,80,106,132,133</sup>. The problem of acute angle closure glaucoma in eyes with a small, patent iridotomy is discussed further in chapter 6.

One case developed closure of a previously patent iridotomy, two weeks following treatment. This patient had not had significant iritis following treatment. Nd:YAG laser iridotomy closure is uncommon<sup>11,14,15,22,80,106</sup>. Late iridotomy closure, or partial closure, has been reported in 10-20% of cases following argon laser iridotomy<sup>13,22,23,30,105</sup>.

#### **4.5.2 EARLY POST-TREATMENT COMPLICATIONS**

Focal corneal endothelium damage, iris bleeding, iritis, transient intraocular pressure elevation, and focal lens opacity have been reported following Nd:YAG laser iridotomy<sup>10-17,22,23,80,106,107,111,122</sup>.

Focal corneal endothelium damage was evident in 58% of our laser treated patients. More marked focal oedema occurred in 17% of patients. Other workers have reported that 4-30% of eyes develop focal endothelial changes following Nd:YAG laser iridotomy<sup>10,11,13,14,22,80</sup> (see Table 1.1).

Punctate areas of endothelial loss overlying treatment sites have been attributed to damage caused by the dispersion of high velocity particulate debris<sup>7,9</sup>. The endothelial granularity which we observed on slit lamp examination would be compatible with this hypothesis.

Reduced endothelial cell count has been described by some workers following argon laser iridotomy<sup>10</sup>, but others have found no change<sup>114</sup> (see Table 1.2). We found no significant change in endothelial cell count following Nd:YAG laser iridotomy, confirming previous studies<sup>8,10,115</sup>.

No significant change in endothelial cell count following surgical peripheral iridectomy was found in our study, again confirming the results of other workers<sup>8,82,197</sup>. One previous study found a 5% reduction in endothelial cell count<sup>81</sup> (see Table 1.2). On the basis of existing data Nd:YAG laser iridotomy would appear to be as safe as operative peripheral iridectomy in the treatment of angle closure glaucoma patients with co existing Fuch's endothelial dystrophy. However a much larger study would be needed to detect a small difference in endothelial cell loss produced by these two forms of treatment, if such a difference does exist.

58% of laser treated patients developed iris bleeding at the time of treatment, compared to 27% following operative surgery ( $\chi^2$  test with Yate's correction  $p < 0.05$ ). Other workers have reported an incidence of 20–80% microhyphaema following Nd:YAG laser iridotomy<sup>10,11,12,13, 14,22,23,80,111</sup> (see Table 1.3). Macrohyphaema did not occur in our series, bleeding was transitory and did not appear to result in any adverse effect.

The incidence of iritis was similar following Nd:YAG laser iridotomy or operative peripheral iridectomy. Posterior synechiae developed in three patients from each group. While synechiae were not associated with cataract development and visual loss in our study, posterior synechiae have previously been found to be associated with cataract development following operative peripheral iridectomy<sup>87</sup>. Post treatment topical steroid treatment is therefore indicated in all cases. Mydriasis using G. Phenylephrine 10% has been found to carry minimal risk of provoking acute angle closure glaucoma<sup>198</sup>.

Our finding of transitory, but very marked, intraocular pressure elevation during the first three hours following treatment in a proportion of patients confirms the findings of previous studies

10,11,12,14,22,23,106 (see Table 1.7). We now give acetazolamide 500 mg orally one hour before treatment, and have had no further instances of intraocular pressure rise above 21 mm Hg while treating 12 fellow eyes since July 1989. Pilocarpine <sup>199</sup>, Timolol <sup>200</sup> and apraclonidine <sup>201</sup> have been found to prevent the development of post-treatment intraocular pressure elevation.

Studies in rabbits suggest that post iridotomy intraocular pressure elevation is caused by mechanical blockage of the trabecular meshwork by particulate debris and plasma proteins released from the iris <sup>177,178</sup>. While raised aqueous prostaglandin levels have been found following iridotomy <sup>176</sup>, indomethacin does not prevent post iridotomy intraocular pressure elevation <sup>177</sup>. Our own findings following Nd:YAG laser phacolysis in rabbits also suggests that elevated intraocular pressure following anterior segment laser surgery is caused by mechanical blockage of the trabecular meshwork by proteins <sup>165</sup>. Nd:YAG laser disruption of the lens nucleus did not cause raised intraocular pressure unless the lens capsule was disrupted. Capsule damage was associated with escape of semi-liquid lens proteins into the aqueous, and rapid elevation of intraocular pressure. While it was possible that prostaglandins or other mediators were responsible for intraocular pressure elevation, the time course suggested direct mechanical blockage of the trabecular meshwork <sup>165</sup>.

Iris tissue is physically removed from the eye during operative peripheral iridectomy, but this does not occur during Nd:YAG laser iridotomy. Aqueous leakage from peripheral iridectomy wounds was not evident, and the absence of intraocular pressure elevation following operative peripheral iridectomy was probably due to the absence of debris in the aqueous.

Focal lens opacities were found underlying the laser treatment

site in two patients. Focal opacities induced by Nd:YAG laser photodisruption are rare <sup>14-17,107,122</sup>, in contrast to a much higher incidence found following argon laser iridotomy <sup>1,10,13,22,23,105,112</sup> (see Table 1.8). We found six cases of small focal lens opacities at the site of operative peripheral iridectomy. Focal opacities, whether caused by argon laser iridotomy, Nd:YAG laser iridotomy or operative peripheral iridectomy have previously been found to be non-progressive, and not associated with visual loss. However one of our laser treated patients lost one line of visual acuity due to nuclear cataract development, having sustained a focal opacity at the time of treatment.

#### **4.5.3 LONG TERM GLAUCOMA OUTCOME**

There was no significant difference in the mean intraocular pressure of the two groups six months following treatment ( $14.5 \pm 2.7$  mm Hg in surgical patients,  $15.0 \pm 3.2$  mm Hg in laser treated patients, unpaired Student t test NS), or at the time of most recent follow up ( $14.9 \pm 2.4$  mm Hg in surgical patients,  $14.3 \pm 2.4$  mm Hg in laser treated patients, unpaired Student t test NS). Only one patient needed treatment to maintain an intraocular pressure of less than 21 mm Hg. However patients presenting with elevated intraocular pressure or pathological optic disc cupping in the fellow eye were excluded from the study. The reported long term incidence of raised intraocular pressure following peripheral iridectomy in fellow eyes ranges from zero to 19% <sup>25,43,46,86,135</sup> (see Table 1.11). Our own retrospective study of the outcome of peripheral iridectomy in fellow eyes found that 15% of patients required medication or had elevated intraocular pressure in the fellow eye 2-5 years following treatment (see page 65).

The appearance of optic discs remained unchanged in all eyes, and gonioscopic appearances six months following treatment were similar in

the two groups. Two laser treated eyes had areas of angle closure which could be opened on indentation. While the area of the iridotomy was not excessively small in these cases, it was smaller than that normally obtained by peripheral iridectomy. Wishart has reported progressive angle narrowing in four eyes following Nd:YAG laser iridotomy, with widening of the angle on performing a further laser iridotomy<sup>15</sup>. It is possible that small iridotomies do not fully overcome iris bombé.

#### **4.5.4 LONG TERM VISUAL ACUITY OUTCOME**

There was no significant difference in the visual acuity outcome of the two groups six months following treatment, or at the final follow up visit. While four laser treated patients lost two or more lines of visual acuity due to cataract development and no surgical patients lost vision, this difference was not statistically significant. Del Priore reported progression of cataract following Nd:YAG laser iridotomy in 2/43 patients<sup>13</sup>. On long term follow up 2-23% of fellow eyes subjected to peripheral iridectomy were found to develop cataract sufficient to reduce visual acuity by two or more lines<sup>43,45,46,86,135</sup> (see Table 1.13). Floman reported an incidence of 41% among an Israeli population<sup>87</sup>. These figures compare with a prevalence of 8% among fellow eyes treated conservatively<sup>196</sup>.

#### **4.6 CONCLUSION**

Outpatient Nd:YAG laser iridotomy is more convenient and may be cheaper than operative peripheral iridectomy<sup>5</sup>. Our study shows that the two treatments have a similar short term outcome in terms of efficacy and complication rates. However the occurrence of acute angle closure glaucoma in an eye which had a small but patent prophylactic Nd:YAG laser iridotomy is disturbing.

## CHAPTER 5.

### **Nd:YAG LASER IRIDOTOMY IN ACUTE ANGLE CLOSURE GLAUCOMA**

#### **5.1 SUMMARY**

A non randomised prospective comparison of Nd:YAG laser iridotomy, peripheral iridectomy, and trabeculectomy has been undertaken in 54 patients with acute angle closure glaucoma.

Iris bleeding occurred more frequently following Nd:YAG laser iridotomy than operative peripheral iridectomy ( $p < 0.02$ ). Focal corneal oedema occurred in 4/19 (22%) eyes following Nd:YAG laser iridotomy, but did not occur following operative peripheral iridectomy or trabeculectomy.

Acute angle closure glaucoma occurred in two laser treated patients despite the presence of a patent iridotomy. The area of iris opening was significantly greater following peripheral iridectomy than following Nd:YAG laser iridotomy ( $p < 0.001$ ).

84% of Nd:YAG laser iridotomy patients, 80% of peripheral iridectomy patients, and 90% of trabeculectomy patients were normotensive without medication at follow up. Trabeculectomy produced a significant lowering of intraocular pressure ( $p < 0.05$ ), but this did not occur following Nd:YAG laser iridotomy or peripheral iridectomy.

There was no statistically significant difference in the visual acuity outcome of the three groups, although there was a trend towards a higher incidence of cataract development following trabeculectomy.

## CHAPTER 5a

### A PROSPECTIVE COMPARISON OF ND:YAG LASER IRIDOTOMY, PERIPHERAL IRIDECTOMY AND TRABECULECTOMY IN THE TREATMENT OF ACUTE ANGLE CLOSURE GLAUCOMA.

#### 5a.1 INTRODUCTION

Several reports describe the use of Nd:YAG Laser iridotomy in a variety of forms of angle closure glaucoma<sup>4,11,14,104,137</sup>. However relatively little attention has been given to the special problems involved in treating acute angle closure glaucoma<sup>80</sup>. These eyes are often hyperaemic, with some degree of corneal and iris oedema. Marked pupil block effects are present.

The operative treatment of acute angle closure glaucoma remains controversial. While many workers advocate peripheral iridectomy in all cases<sup>25</sup>, in the long term only 70-75% of eyes remain normotensive without medication following this form of treatment<sup>25,43,86,87</sup>. Accurate prediction of which eyes will need further glaucoma treatment following peripheral iridectomy is not possible<sup>25</sup>, and some workers have advocated primary drainage surgery<sup>130,134</sup>. The policy of our department has been to perform peripheral or sector iridectomy on eyes which have had an acute attack of less than 48 hours duration, have responded well to initial miotic treatment, and have not had extensive goniosynechiae on gonioscopy. Eyes which have not met these criteria have been treated by primary drainage surgery, in the form of trabeculectomy, iridencleisis or sector iris inclusion operation.

In order to assess the safety and effectiveness of Nd:YAG laser iridotomy in the treatment of acute angle closure glaucoma we have undertaken a non randomised prospective comparison of Nd:YAG laser

iridotomy, operative peripheral iridectomy and trabeculectomy in a group of 54 patients presenting to our department with acute angle closure glaucoma between January 1987 and June 1989. The study was an open pilot study designed to evaluate the feasibility of performing a larger randomised comparison of Nd:YAG laser iridotomy and operative peripheral iridectomy in the treatment of acute angle closure glaucoma.

## **5a.2 MATERIALS AND METHODS**

70 patients presented to the ophthalmology department of Edinburgh Royal Infirmary with acute or subacute angle closure glaucoma during the period January 1987 to June 1989. 54 of these patients underwent Nd:YAG laser iridotomy, operative peripheral iridectomy or trabeculectomy for acute angle closure glaucoma and were observed prospectively. The remaining patients either had subacute glaucoma and were excluded (7 patients), or were treated by an alternative operation, such as iridencleisis or sector iris inclusion (9 patients).

Treatment of the acutely affected eye was not randomised. Patients with acute angle closure glaucoma of more than approximately 48 hours duration or who responded less promptly to initial medical control underwent primary trabeculectomy. Patients with marked breathlessness due to cardiac or respiratory disease and the very elderly were treated by Nd:YAG laser iridotomy. Some patients expressed a preference for either laser treatment or conventional surgery, and were treated accordingly.

### **5a.2.1 INITIAL EXAMINATION**

Initial examination was performed by a number of experienced observers and included assessment of corrected visual acuity, the degree



of corneal oedema present, scored as 0, + or ++, intraocular pressure measured by Goldman applanation tonometry, pupil size measured in millimetres, and Goldman gonioscopy.

Patients were then treated with acetazolamide 500 mg intravenously, one drop of G. Timolol 0.5%, and G. Pilocarpine 2% hourly. The intraocular pressure was measured every 1-2 hours, until it had fallen below 21 mm Hg.

Serial measurements of corneal thickness and intraocular pressure were made in four patients following initial medical treatment. Central corneal thickness was measured using an "Ophthasonic" ultrasound pachymeter (Teknar Inc). Three readings were taken at the time of each measurement, and the average result recorded. Intraocular pressure was measured using a Goldman applanation tonometer. Measurements were made at the time of initial medical treatment, and approximately 1 hour, 2 hours, 4 hours, 6 hours, 24 hours, 48 hours and 72 hours later.

Examination of all patients 24 hours after presentation was performed by BWF, and included assessment of visual acuity, corneal oedema, intraocular pressure, pupil size, Goldman gonioscopy, lens and fundus appearances. The vertical cup:disc ratio was recorded in decimal form.

Operative peripheral iridectomy, trabeculectomy or Nd:YAG laser iridotomy was performed 3-4 days later, by one of several experienced surgeons.

### **5a.2.2 PERIPHERAL IRIDECTOMY**

Operative peripheral iridectomy was performed under general or local anaesthetic. A 2-3mm clear cornea incision was used in 5 patients. The peripheral iris was grasped with grooved forceps, and an iridectomy performed with scissors. The incision was not sutured. In the remaining

10 patients a corneoscleral incision was used. The peripheral iris was prolapsed, and a peripheral iridectomy was performed with scissors. The incision was closed with one 8/0 polyglactin ("Vicryl") suture.

Postoperatively patients were treated with G. Betamethasone 0.1% four times daily and G. Tropicamide 1% once daily, for one week.

### **5a.2.3 TRABECULECTOMY**

Trabeculectomy was performed under general anaesthetic or local anaesthetic. A limbal or fornix based conjunctival flap was used. A 4 mm x 2 mm rectangular partial thickness scleral flap was fashioned, and a 1mm x 2mm trabeculectomy block was excised. A small peripheral iridectomy was made. The sclera and conjunctiva were sutured using 8/0 virgin silk.

### **5a.2.4 Nd:YAG LASER IRIDOTOMY**

All patients were given acetazolamide 500mg orally one hour before treatment. One drop of G. Pilocarpine 2% was instilled 30 minutes before treatment. A Zeiss visulas Nd:YAG laser and Zeiss anterior segment YAG contact lens were used in all treatments.

A treatment site was chosen in the superior iris, between 10 and 2 o'clock, approximately 2/3 way from the pupil margin to the iris base. An iris crypt was used where present. A single 5-10 mJ pulse was delivered to the treatment site. If this pulse did not penetrate the iris further single pulses were delivered to the same site until penetration was achieved. Patency was assessed by direct visualisation of the posterior chamber, or anterior lens capsule.

### 5a.2.5 POST TREATMENT ASSESSMENT

The intraocular pressure was measured and the cornea, anterior chamber and iris were examined 2 hours and 24 hours after treatment.

### 5a.2.6 FOLLOW UP

Patients were examined 1 week, 1 month, 3 months, 6 months and then 6 monthly after treatment. Visual acuity, intraocular pressure, lens appearance and optic disc appearance were noted at every visit. Visual fields were assessed using a Friedman visual field analyser if the intraocular pressure was raised or the optic disc appearance was abnormal.

Six months following treatment Goldman gonioscopy was performed on laser iridotomy and peripheral iridectomy patients by one of three experienced observers (BW, EW or EF). Posner 4 mirror indentation gonioscopy was performed by BWF if any part of the angle appeared to be closed. Pilocarpine/phenylephrine provocation testing as described by Mapstone<sup>68</sup>, and modified by Harrad<sup>105</sup> was then performed. The intraocular pressure was measured, one drop of G. Phenylephrine 10% and one drop of G. Pilocarpine 2% were instilled, and the intraocular pressure was measured again one hour later. An intraocular pressure rise of more than 8 mm Hg, with angle closure on gonioscopy, was regarded as a positive result.

At the final follow up visit the size of the iridotomy or iridectomy was measured by comparison with the 200 $\mu$  spot size produced by a Haag-Streit slit lamp. The area of the iridotomy or iridectomy was then calculated using the formula Diameter a x Diameter b x  $\pi/4$  (see Fig 2.3, page 52). The pupil was dilated using G. Phenylephrine 10% in all patients, to detect posterior synechiae and allow examination of the lens and fundus.

### 5a.3 RESULTS

70 patients presented with acute or subacute angle closure glaucoma during the study period. 7 cases had subacute angle closure glaucoma, with an intraocular pressure of less than 21 mm Hg at presentation. These cases were excluded. The remaining 63 patients presented with acute angle closure glaucoma.

Nine patients underwent iridencleisis or sector iris inclusion surgery. The remaining 54 patients were included in the study. 19 underwent Nd:YAG laser iridotomy, 15 underwent operative peripheral iridectomy, and 20 underwent trabeculectomy. One patient from the peripheral iridectomy group and one patient from the laser treated group had bilateral acute angle closure glaucoma. One eye was randomly chosen for analysis by tossing a coin.

Details of the three patient groups are shown in Table 5.1. Patients in the peripheral iridectomy group were younger than those in the laser treated group ( $p < 0.02$ , unpaired Student t test), but there was no significant difference in the mean age of the trabeculectomy group and the laser treated group. The duration of the acute attack prior to treatment was longer in the trabeculectomy group than in either the peripheral iridectomy ( $p < 0.05$ ), or laser treated group ( $p < 0.05$ , unpaired Student t test). The duration of follow up was similar in the three groups (unpaired Student t test NS). The minimum follow up period was 6 months.

	Nd:YAG Laser Iridotomy	Peripheral Iridectomy	Trabeculectomy
Number of patients	19	15	20
Age, years	73.3 ±10.6	63.6 ±11.1	65.5±14.7
Male : Female	2 : 17	6 : 9	7:14
Duration acute attack, hours	33.1±17.9	33.5±41.5	78.7±81.5
Follow up, months	15.8±10.2	12.9±16.6	18.9±11.3

**TABLE 5.1**  
**Prospective study of the treatment of acute angle closure glaucoma. Patient groups.**

Table 5.2 gives the results of the initial examination.

	Nd:YAG Laser Iridotomy	Peripheral Iridectomy	Trabeculectomy
Number patients	19	15	20
Intraocular pressure, mm Hg	46.1±15.1	53.3±10.5	50.1±18.0
Visual acuity 6/12 or better	5(26%)	6 (40%)	2 (10%)

**TABLE 5.2**  
**Prospective study of the treatment of acute angle closure glaucoma. Initial examination.**

There were no significant differences between the three groups in the mean intraocular pressure or proportion of patients with a visual acuity of 6/12 or better at presentation.

Table 5.3 gives the results of the examination performed after initial medical control.

	Nd:YAG Laser Iridotomy	Peripheral Iridectomy	Trabeculectomy
Number patients	19	15	20
Intraocular pressure, mm Hg	10.8±4.2	11.8±3.1	23.1±14.0
No. patients with IOP ≤ 21mm Hg	19 (100%)	14 (93%)	10 (50%)
Pupil ≤ 3mm	17 (89%)	14 (93%)	5 (25%)
Corneal oedema present.	3 (15%)	3 (20%)	12 (60%)
Visual acuity 6/12 or better	7/15 (47%)	11 (73%)	2/9 (22%)
Lens opacities present	10 (52%)	2 (13%)	12 (60%)

**TABLE 5.3**  
**Prospective study of the treatment of acute angle closure**  
**glaucoma. Examination after initial medical control.**

The mean intraocular pressure following initial medical control was higher in the trabeculectomy group than in the peripheral iridectomy group (unpaired Student t test  $p < 0.01$ ), or laser treated group ( $p < 0.001$ ). A significantly greater proportion of trabeculectomy patients (10/20) than laser iridotomy patients (1/19) had an intraocular pressure greater than 21 mm Hg after initial medical control ( $p < 0.01$ ,  $\chi^2$  test with Yate's correction). The pupil became miosed following initial medical treatment in a significantly smaller proportion of trabeculectomy patients (5/20) than peripheral iridectomy patients (14/15,  $\chi^2$  with Yate's correction  $p < 0.001$ ) or laser iridotomy patients (17/19,  $\chi^2$  test with Yate's correction  $p < 0.001$ ). No patient had pathological optic disc cupping.

Residual corneal oedema was present in a higher proportion of trabeculectomy patients than peripheral iridectomy or laser iridotomy

patients, but the differences were not statistically significant. Significantly more peripheral iridectomy patients had a visual acuity of 6/12 or better (11/15), compared to trabeculectomy patients (2/9,  $\chi^2$  test with Yate's correction  $p < 0.02$ ). Fewer peripheral iridectomy patients had cataract (2/15), compared to trabeculectomy patients (12/20,  $\chi^2$  test with Yate's correction  $p < 0.02$ ), or laser iridotomy patients (10/19,  $\chi^2$  test with Yate's correction  $p < 0.05$ ).

In summary patients in the trabeculectomy group had a more severe form of glaucoma at presentation, with less complete intraocular pressure control, less pupil miosis, and greater residual corneal oedema following initial medical control. While the peripheral iridectomy and laser iridotomy groups had a similar severity of glaucoma, the prevalence of cataract was lower in the peripheral iridectomy group. This difference may have been related to the lower mean age of the peripheral iridectomy group.

### **5a.3.1 CORNEAL PACHYMETRY RESULTS**

Serial central corneal thickness and intraocular pressure measurements were performed in four patients. The results of these measurements are shown in Table 5.4.

Patient	Time (Hours)	Acute eye		Fellow eye	
		IOP	Pachymetry	IOP	Pachymetry
Patient 1 Age 81	0	45	-	14	-
	1	20	-	-	-
	2	11	746	13	552
	4	-	799	-	-
	6	-	753	-	-
	18	10	749	11	548
	48	10	668	-	-
	72	8	588	-	-
Patient 2 age 46	0	66	-	18	-
	1	16	548	14	536
	18	12	545	12	535
Patient 3 Age 67	0	52	-	19	-
	1	12	552	12	517
	40	8	510	11	470
Patient 4 Age 71	0	45	-	15	-
	17	11	526	9	513

**TABLE 5.4**

**Serial intraocular pressure and pachymetry measurements following acute angle closure glaucoma.**

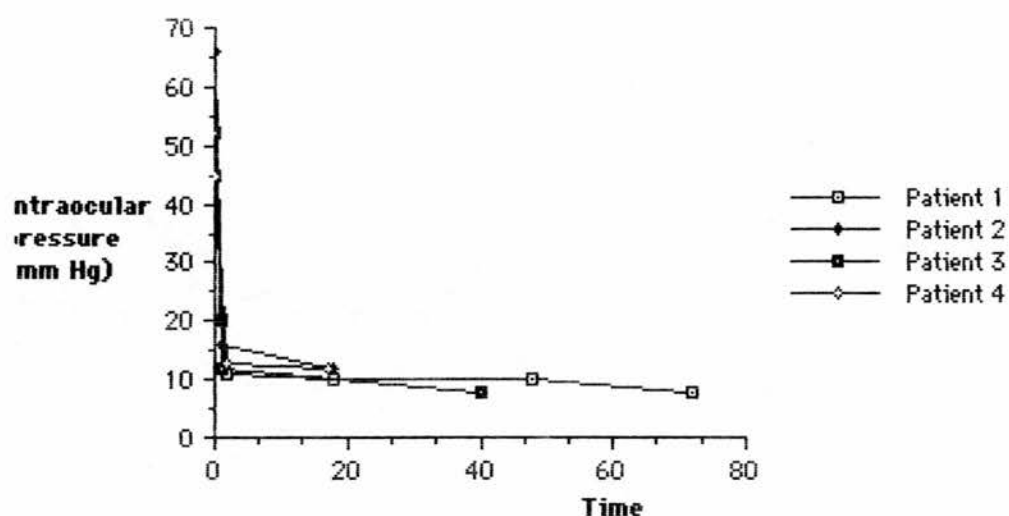
Time = time in hours from initial medical treatment

IOP = intraocular pressure

Pachymetry = ultrasound pachymetry readings of central cornea, in micrometers.

Figure 5.1 shows changes in intraocular pressure following initial medical control of acute angle closure glaucoma in the four patients included in the study. The intraocular pressure fell to below 21 mm Hg within one hour in every case.

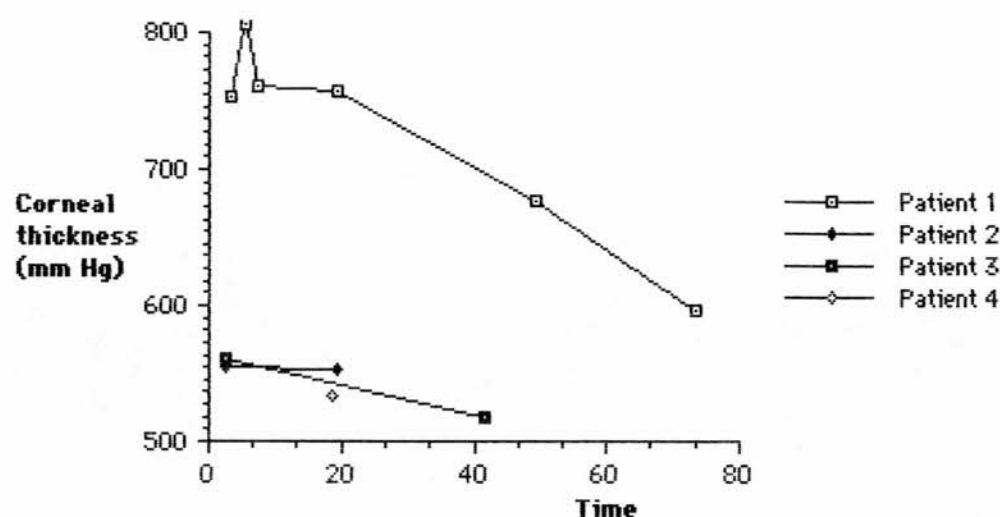




**Figure 5.1**  
**Prospective study of the treatment of acute angle closure glaucoma. Intraocular pressure following initial medical control, corneal pachymetry study**

Figure 5.2 shows central corneal thickness following initial medical control of acute angle closure glaucoma.

Central corneal thickness fell to within 10% of the thickness of the fellow cornea within 24 hours in 3 patients. However resolution of corneal oedema progressed much more slowly in one patient (Patient 1), who was aged 81 years.



**Figure 5.2**  
**Prospective study of the treatment of acute angle closure glaucoma. Central corneal thickness following initial medical control.**

### 5a.3.2 DURATION OF INPATIENT TREATMENT

The duration of in patient stay, treating both the acutely affected eye and the fellow eye, was  $5.9 \pm 3.8$  days for laser treated patients,  $7.9 \pm 2.8$  days for peripheral iridectomy patients, and  $7.9 \pm 3.5$  days for trabeculectomy patients. Differences were not significant using the unpaired Student t test.

### 5a.3.3 Nd:YAG LASER IRIDOTOMY

8 patients in the laser iridotomy group had grey irises, and 11 had brown irises.

Primary failure to achieve a patent iridotomy occurred in one patient. This failure was not recognised and the patient developed acute angle closure glaucoma three days later. Nd:YAG laser iridotomy was performed, resulting in a satisfactory opening in the iris.

The mean number of laser pulses required to create a patent

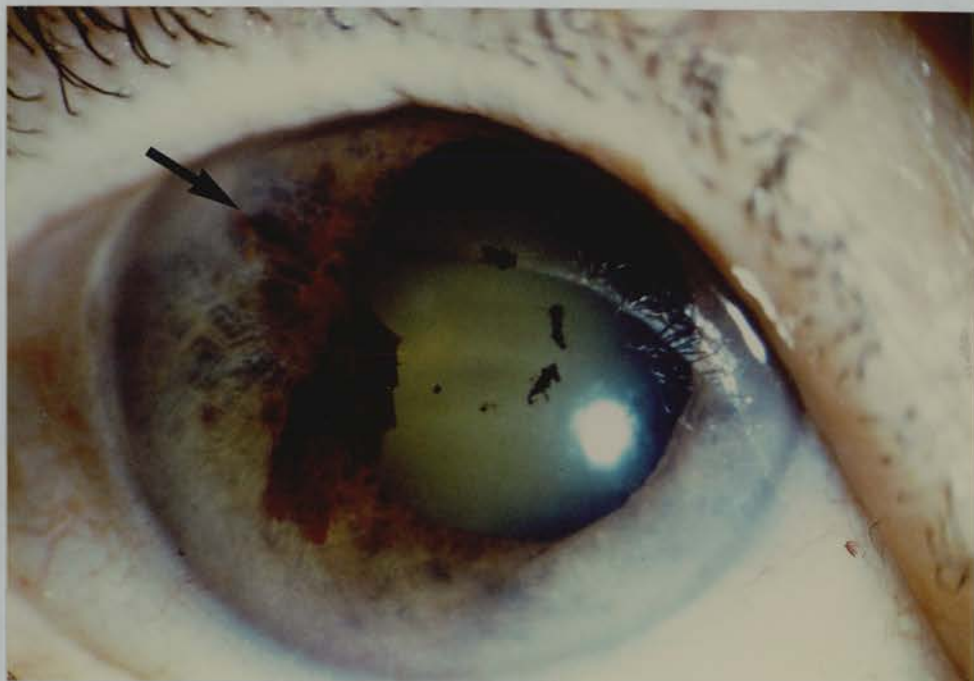
iridotomy was  $4.6 \pm 5.8$ . Six patients required only one pulse. There was no significant difference in the number of pulses required to perforate brown and grey irises ( $5.0 \pm 5.8$  and  $4.4 \pm 6.0$  respectively).

The mean power required to create a patent iridotomy was  $35.6 \pm 40.6$  mJ (range 5 - 136 mJ). Brown irises did not differ from grey irises, with levels of  $40.5 \pm 44.7$  mJ and  $31.7 \pm 36.9$  mJ respectively. In six patients less than 10 mJ energy was needed to create a patent iridotomy.

In three patients treatment was performed at more than one site before perforation of the iris was achieved.

Three patients had residual corneal oedema at the time of laser treatment. However the mean number of pulses (1.3) and total power (7.1 mJ) required to create an iridotomy in these patients was not significantly different from that of the group as a whole.

Slight oozing of blood at the treatment site occurred in 8 patients, compared to zero patients in the peripheral iridectomy group ( $\chi^2$  test with Yate's correction  $p < 0.02$ ) A larger flow of blood, resulting in a blood clot on the iris surface, occurred in one patient (Figure 5.3).



**Figure 5.3. Hyphaema following Nd:YAG laser iridotomy in an eye with controlled acute angle closure glaucoma.** The arrow indicates the iridotomy site.

Transient elevation of intraocular pressure following treatment did not occur, probably due to pretreatment with acetazolamide 500 mg orally.

A significant degree of iritis occurred in one patient 24 hours following treatment, but was readily controlled using topical steroid medication.

Full thickness focal corneal oedema overlying the treatment site was evident in four patients 24 hours after treatment. The mean total energy used in treatment of these patients ( $75.6 \pm 69.2$  mJ) was greater than that used in treating patients who did not develop focal corneal oedema ( $24.7 \pm 19.7$  mJ, unpaired Student t test  $p < 0.02$ ).

Focal lens opacities at the treatment site were not evident in any patient.

#### **5a.3.4 PERIPHERAL IRIDECTOMY**

The pigment epithelium of the iris was incompletely excised in 4 patients. This complication occurred in 3 of the 5 patients in whom a corneal incision had been used. It is likely that iris oedema resulted in separation of the iris stroma from the pigment epithelium when grasped with grooved forceps. In one patient the pigment epithelium remained intact following surgery. This was not recognised and the patient developed acute angle closure glaucoma five weeks later. The imperforate pigment layer was opened using the Nd:YAG laser. No other operative or early postoperative complications occurred in the peripheral iridectomy group.

#### **5a.3.5 TRABECULECTOMY**

Three patients developed small operative hyphaemas, which cleared spontaneously during the first postoperative week. Seven patients developed clinically significant iritis during the first postoperative week, which was readily controlled using topical steroid medication. This incidence was higher than that seen in either of the other two groups, but the differences were not statistically significant. Three patients had a shallow anterior chamber during the first 48 hours following surgery, but in each case the chamber reformed to near normal depth spontaneously. Three patients developed raised intraocular pressure during the first week following surgery. In two cases the pressure returned to normal using ocular massage, and remained normal thereafter. Revision of the trabeculectomy was needed in the third patient.

One patient had persisting corneal oedema despite normal intraocular pressure control following surgery. This patient was

diabetic, and had a family history of Fuchs' endothelial dystrophy. The fellow eye showed endothelial changes typical of early Fuchs' dystrophy, with no overt oedema.

## **FOLLOW UP**

### **5a.3.6 ACUTE ANGLE CLOSURE GLAUCOMA**

One laser treated patient and one peripheral iridectomy patient developed acute angle closure glaucoma in the early post treatment period due to primary failure to produce an iris opening.

Two laser treated patients developed acute angle closure glaucoma despite the presence of a patent iridotomy.

Case 1. A 75 year old man underwent Nd:YAG laser iridotomy for acute closed angle glaucoma. The iridotomy was small ( $100\mu\times 50\mu$ ), but patent. One month after treatment he complained of painless blurring of vision. At that time he was using no topical eye medication. Intraocular pressure was 68 mm Hg, and gonioscopy revealed 300 degrees of angle closure. Medical treatment with topical pilocarpine and timolol restored normal intraocular pressure, with an open angle on gonioscopy. The iridotomy was small but patent. Trabeculectomy was performed, leading to normal intraocular pressure without medication.

Case 2. An 83 year old female presented with acute angle closure glaucoma. Initial examination revealed a deep anterior chamber, and the angle configuration on gonioscopy suggested plateau iris syndrome. Nd:YAG laser iridotomy was performed, creating a moderately large, patent iridotomy. Fourteen days later the patient returned with painful loss of vision in the eye. G. Betamethasone QID and G. Cyclopentolate 1% had been prescribed following laser iridotomy, and the patient was using these drops at the time of developing recurrent symptoms. The intraocular pressure was 50 mm Hg. Following topical pilocarpine and

timolol treatment the intraocular pressure fell to 7 mm Hg. The iridotomy was patent and moderately large (200 $\mu$ x400 $\mu$ ). Indentation gonioscopy showed the angle was closed by goniosynechiae over 150 degrees. A sector iridectomy was performed. On further follow up the intraocular pressure was found to be 28 mm Hg with no medication, and fell to 21 mm Hg on adding G. Timolol 0.5% B.D.

These patients are discussed in greater detail in chapter 6, pages 132,133,136,137 (cases 1 and 3).

### **5a.3.7 GLAUCOMA OUTCOME**

16/19 (84%) of laser iridotomy patients maintained normal intraocular pressure without further glaucoma treatment during the follow up period. Three patients required topical medication or had an intraocular pressure greater than 21 mm Hg at follow up.

12/15 (80%) of peripheral iridectomy patients maintained normal intraocular pressure without further glaucoma treatment during the follow up period. Three patients required topical medication or had an intraocular pressure greater than 21 mm Hg at follow up.

18/20 (90%) of trabeculectomy patients maintained normal intraocular pressure without further glaucoma treatment during the follow up period. One patient required topical medication to maintain normal intraocular pressure, and one patient underwent repeat trabeculectomy.

The mean intraocular pressure at follow up was 17.3 $\pm$ 8.4 mm Hg in the laser treated group, 16.0 $\pm$ 3.7 mm Hg in the peripheral iridectomy group, and 15.2 $\pm$ 3.5 mm Hg in the trabeculectomy group. These differences were not statistically significant. However within the trabeculectomy group the mean intraocular pressure at follow up, 15.2 $\pm$ 3.5mm Hg, was significantly lower than the mean preoperative

intraocular pressure,  $23.1 \pm 14.0$  mm Hg ( $p < 0.05$ , paired Student t test). Within the peripheral iridectomy group the mean intraocular pressure at follow up,  $16.0 \pm 3.7$  mm Hg, was significantly higher than the mean preoperative intraocular pressure,  $11.8 \pm 3.1$  mm Hg ( $p < 0.01$ , paired Student t test). This was also the case within the Nd:YAG laser iridotomy group, with a mean intraocular pressure at follow up of  $17.3 \pm 8.4$  mm Hg, compared to  $10.8 \pm 4.2$  mm Hg before treatment ( $p < 0.05$ , paired Student t test).

No patient developed pathological optic disc cupping during the follow up period.

#### **5a.3.7.1 GONIOSCOPY**

Goldman indirect gonioscopy was performed 6 months following treatment, and, if any part of the angle was found to be closed Posner 4 mirror indentation gonioscopy was performed by BWF. Three peripheral iridectomy patients were found to have areas of goniosynechiae on indentation, and one of these patients required medication to maintain normal intraocular pressure. Three laser treated patients had areas of goniosynechiae, and one of these needed topical medication to maintain normal intraocular pressure. A further two laser treated patients had small areas of focal goniosynechiae.

Five laser treated patients showed marked pigmentation of the trabecular meshwork inferiorly, a finding not seen in peripheral iridectomy patients. One of these patients required topical medication to maintain normal intraocular pressure.

#### **5a.3.7.2 PROVOCATION TESTS**

Pilocarpine/phenylephrine provocation tests were performed on all laser treated patients and peripheral iridectomy patients 6 months



following treatment. All tests were negative. However a total of 4 patients had sustained a second episode of acute angle closure glaucoma prior to provocation testing, two because of primary failure to obtain an iris opening, and two despite the presence of a patent iridotomy, as discussed above.

### **5a.3.7.3 IRIDOTOMY AREA**

The mean surface area of iris patency following laser iridotomy was  $0.086 \pm 0.12 \text{ mm}^2$ . The mean surface area of operative iridectomies was  $1.22 \pm 0.95 \text{ mm}^2$  ( $p < 0.001$ , unpaired Student t test).

### **5a.3.8 VISUAL ACUITY OUTCOME**

In many cases accurate assessment of corrected visual acuity following initial medical treatment, prior to laser treatment or operative surgery, was difficult. Residual corneal oedema, miosis due to pilocarpine, and possible residual optic nerve head dysfunction lead to poor vision. It was therefore impossible to distinguish visual loss due to acute angle closure glaucoma from visual loss as a complication of laser treatment or surgery. Visual acuity one week after laser treatment or surgery was consistently better than visual acuity immediately prior to laser treatment or operative surgery. Only one laser treated patient, and two peripheral iridectomy patients, lost one or more line of visual acuity during this interval. In each case this was due to cataract progression. Assessment of reduced visual acuity at the final follow up visit was therefore based on a comparison with the visual acuity one week after laser treatment or surgery, rather than with preoperative visual acuity.

At the final follow up examination one laser iridotomy patient was found to have lost 2 lines of visual acuity due to the development of cataract in a previously clear lens. Three peripheral iridectomy patients

lost two or more lines of visual acuity. In two cases this was due to cataract development in a previously clear lens, and in one case was due to progression of pre existing cataract.

Six trabeculectomy patients lost two or more lines of visual acuity during the follow up period. This was due to cataract development in a previously clear lens in one case, progression of pre existing cataract in four cases, and cystoid macular oedema following cataract surgery in one case.

Differences between the groups in the incidence of visual acuity loss by two or more lines during the follow up period were not statistically significant.

#### **5a.3.9 POSTERIOR SYNECHIAE**

8/19 (42%) laser treated patients, 4/15 (27%) peripheral iridectomy patients, and 8/20 (40%) trabeculectomy patients had posterior synechiae at the time of the final follow up visit. The differences between pairs of groups were not statistically significant. A total of 20/54 (37%) of acute angle closure glaucoma eyes treated by Nd:YAG laser iridotomy, operative peripheral iridectomy or trabeculectomy developed posterior synechiae. 4/10 (40%) of acute angle closure glaucoma eyes treated by Nd:YAG laser iridotomy, operative peripheral iridectomy or trabeculectomy who lost two or more lines of visual acuity during follow up developed posterior synechiae.

7/19 (37%) laser treated patients received a mydriatic following treatment, compared to 10/15 (67%) peripheral iridectomy patients ( $\chi^2$  with Yate's correction NS), and 20/20 (100%) trabeculectomy patients ( $\chi^2$  with Yate's correction  $p < 0.001$ ). This difference arose from concern that a further attack of acute angle closure glaucoma might be provoked by mydriasis in patients treated by Nd:YAG laser iridotomy.

## **5a.4 DISCUSSION**

This was not a randomised study, and the results are biased by differences between the groups. The trabeculectomy group had a longer mean duration of acute attack prior to treatment, and responded less well to initial medical treatment than either the peripheral iridectomy or Nd:YAG laser iridotomy group. One might therefore expect the visual acuity and glaucoma outcome to be less good in this group.

Patients in the Nd:YAG laser iridotomy group were older than those in the peripheral iridectomy group, and cataract was commoner in the Nd:YAG laser iridotomy group. However the duration of acute attack prior to treatment, and the response to initial medical treatment were very similar in the peripheral iridectomy and Nd:YAG laser iridotomy groups, allowing a valid comparison of the glaucoma outcome in these two groups.

### **5a.4.1 CORNEAL PACHYMETRY**

Resolution of corneal oedema occurred rapidly in 3 of the 4 patients in whom serial measurements were made. Slow resolution of oedema in one patient aged 81 years may have been related to low endothelial cell density. Endothelial cell counts were not performed in these patients. Corneal endothelial cell density becomes reduced with increased age<sup>202,203</sup>.

Residual corneal oedema at the time of performing Nd:YAG laser iridotomy reduces visualisation of the iris. We have observed no adverse corneal effects or higher laser energy requirements when performing Nd:YAG laser iridotomy in the presence of corneal oedema. However it is probably preferable to wait until corneal oedema has resolved before proceeding with iridotomy.

#### **5a.4.2 OPERATIVE AND EARLY POSTOPERATIVE COMPLICATIONS**

Full thickness focal corneal oedema occurred in 4/19 (22%) of patients following Nd:YAG laser iridotomy. This incidence is similar to that reported previously (see Table 1.1), and to our own findings in fellow eyes (15% of cases - see page 86). A higher mean total laser energy ( $75.6 \pm 69.2$  mJ) was used to treat eyes which developed focal corneal oedema than in eyes which did not develop corneal oedema ( $24.7 \pm 19.7$  mJ, unpaired Student t test  $p < 0.02$ ).

Iris bleeding occurred more frequently following Nd:YAG laser iridotomy (9/19, 47% eyes) than peripheral iridectomy (0/15 eyes,  $\chi^2$  test with Yate's correction  $p < 0.02$ ). Operative hyphaema occurred in 3 trabeculectomy patients. Iris bleeding did not cause clinically apparent adverse effects. The incidence of iris bleeding following Nd:YAG laser iridotomy was similar to that reported previously (see Table 1.3), and to our own findings in fellow eyes (57% of cases - see page 84).

Iritis occurred in 7/20 (35%) trabeculectomy patients, 1/19 (5%) Nd:YAG laser iridotomy patients, and in 0/15 peripheral iridectomy patients. A low incidence of iritis following peripheral iridectomy and Nd:YAG laser iridotomy has been reported previously (see Table 1.5).

Transient intraocular pressure elevation following Nd:YAG laser iridotomy did not occur, demonstrating the effectiveness of pretreatment with acetazolamide 500 mg orally.

#### **5a.4.3 ACUTE ANGLE CLOSURE GLAUCOMA**

Acute angle closure glaucoma is rare following peripheral iridectomy<sup>25,42,43,117</sup>, and has generally been attributed to plateau iris syndrome<sup>204,205</sup>. An anteriorly placed iris root results in peripheral iris

bunching on pupil dilation, with occlusion of the trabecular meshwork. One of our patients (case 2) probably had plateau iris syndrome, and developed acute angle closure glaucoma despite the presence of a relatively large, patent iridotomy.

The mechanism of failure of very small iridotomies may be different. The mean surface area of laser iridotomies in our study was fourteen times less than that of peripheral iridectomies. Acute angle closure glaucoma has been described following argon laser iridotomy<sup>132,133</sup> and Nd:YAG laser iridotomy<sup>15,80,106</sup> when the iridotomy was very small. One of our patients (case 1) developed acute angle closure glaucoma in the presence of a small, patent iridotomy (100 $\mu$  x 50 $\mu$ ). The mechanisms by which acute angle closure glaucoma may arise in the presence of a small, patent iridotomy are discussed in chapter 6.

Pilocarpine/phenylephrine provocation tests six months following treatment were negative in all cases. However two cases of acute angle closure glaucoma following successful Nd:YAG laser iridotomy occurred less than one month after treatment. One further Nd:YAG laser iridotomy patient, and one peripheral iridectomy patient developed acute angle closure glaucoma due to primary failure to produce an iris opening. Other workers have reported negative pilocarpine/phenylephrine provocation tests 2-6 months after treatment<sup>15,80</sup>, but with a small number of spontaneous episodes of acute angle closure glaucoma 2-4 weeks after production of a patent Nd:YAG laser iridotomy.

Combined administration of pilocarpine and phenylephrine in theory produces maximal pupil block forces<sup>64</sup>. Pilocarpine/phenylephrine tests performed very soon after iridotomy should detect cases in which the iridotomy size is inadequate. The iridotomy might then be enlarged to a more effective size. However a more satisfactory approach would

probably be to produce an iridotomy of adequate size at the initial treatment session.

#### **5a.4.4 GLAUCOMA OUTCOME**

There were no significant differences in the glaucoma outcomes of the three groups. 84% of Nd:YAG laser iridotomy patients, 80% of peripheral iridectomy patients, and 90% of trabeculectomy patients had normal intraocular pressure without medication at follow up. There were no significant differences between the mean intraocular pressures of the three groups at follow up:  $17.3 \pm 8.4$  mm Hg in the Nd:YAG laser iridotomy group,  $16.0 \pm 3.7$  mm Hg in the peripheral iridectomy group, and  $15.2 \pm 3.5$  mm Hg in the trabeculectomy group.

However the mean intraocular pressure after initial medical control was significantly higher in the trabeculectomy group ( $23.0 \pm 14.0$  mm Hg) than in the peripheral iridectomy ( $11.8 \pm 3.1$  mm Hg) or Nd:YAG laser iridotomy ( $10.8 \pm 4.2$  mm Hg) group. Within the trabeculectomy group the mean intraocular pressure at follow up ( $15.2 \pm 3.5$  mm Hg) was significantly lower than the mean preoperative intraocular pressure ( $23.1 \pm 14.0$  mm Hg,  $P < 0.05$ , unpaired Student t test). Trabeculectomy therefore had a measureable intraocular pressure lowering effect. This was in contrast to the peripheral iridectomy and Nd:YAG laser iridotomy groups, within which the mean intraocular pressure at follow up ( $16.0 \pm 3.7$  and  $15.2 \pm 3.5$  mm Hg respectively) was significantly higher than the mean preoperative intraocular pressure ( $11.8 \pm 3.1$  and  $10.8 \pm 4.2$  mm Hg respectively,  $p < 0.01$  and  $P < 0.05$  respectively, unpaired Student t test). Miotics were being administered at the time of measurement of preoperative intraocular pressure.

Previous studies of peripheral iridectomy in acute angle closure glaucoma have found that 70-76% of eyes remain normotensive without

medication <sup>25,43,46,86,87,95</sup> (see Table 1.10). Gray found 50% of eyes remained normotensive without medication following Nd:YAG laser iridotomy <sup>80</sup>. Primary drainage surgery in the form of iridencleisis <sup>134</sup> or trabeculectomy <sup>130</sup> has been reported to result in normal intraocular pressure without medication in 90-95% of cases.

Five laser treated patients had marked pigmentation of the inferior part of the trabecular meshwork six months following treatment, but this had no effect on intraocular pressure control. Argon laser iridotomy in cynomolgus monkeys resulted in pigment deposition in the inferior part of the trabecular meshwork, which was cleared by bulk aqueous flow and phagocytosis <sup>178</sup>. Pigment deposition does not appear to produce clinically significant effects.

Apart from these changes gonioscopic appearances were similar in the peripheral iridectomy and Nd:YAG laser iridotomy groups. Nd:YAG laser iridotomy appears to be as effective as peripheral iridectomy in maintaining an open drainage angle following acute angle closure glaucoma.

#### **5a.4.5 VISUAL ACUITY OUTCOME**

Six trabeculectomy patients, three peripheral iridectomy patients and one laser iridotomy patient lost two or more lines of visual acuity due to cataract progression during the follow up period. These differences were not statistically significant. It is difficult to differentiate visual loss due to surgical or laser treatment from visual loss due to the effects of acute angle closure glaucoma. Patients in the trabeculectomy group had uncontrolled intraocular pressure for a longer period prior to initial medical treatment, and might therefore have been expected to have a worse visual acuity outcome. Patients in the peripheral iridectomy group were younger than patients in the

trabeculectomy or Nd:YAG laser iridotomy groups, and might therefore have been expected to have a better visual acuity outcome. The numbers of patients in our study groups were too few to detect trends in visual acuity outcome.

Floman found two or more lines of visual acuity loss due to cataract in 38% of eyes 1-3 years following operative peripheral iridectomy for acute angle closure glaucoma<sup>87</sup>. Krupin found three or more lines of visual acuity loss due to cataract in 39% of patients after a mean follow up period of 52 months<sup>86</sup>. Williams found two or more lines of visual acuity loss in 19% of eyes six months to 16 years following operative peripheral iridectomy for acute angle closure glaucoma and in 6.9% of cases the visual loss was attributed to cataract<sup>46</sup>. Lowe found that 19% of eyes had a dense cataract five years after peripheral iridectomy for acute angle closure glaucoma<sup>43</sup>. Luke found that 22% of eyes developed cataract following peripheral iridectomy for acute angle closure glaucoma, after a mean follow up period of 4.4 years<sup>101</sup> (see Table 1.12).

Sugar found a higher prevalence of cataract among eyes treated by iridencleisis for acute angle closure glaucoma (41%), than among the fellow eyes of the same patients treated by peripheral iridectomy (23%)<sup>45</sup>. 38% of eyes developed cataract 6-22 years after a trephine or iridencleisis operation for open angle glaucoma, compared with 8% of unoperated control patients<sup>206</sup>. 20% of cataracts developed soon after surgery, and 80% at a later stage<sup>206</sup>. Watson found that cataract progression following trabeculectomy for open angle glaucoma occurred in 23% of cases treated with an "anterior" opening into the anterior chamber, and 6% of cases with a "posterior" opening<sup>131</sup>.

No studies of the long term visual acuity results of Nd:YAG laser iridotomy for acute angle closure glaucoma have been published to date.



Del Priore found a loss of two or more lines of visual acuity due to cataract in 2/43 eyes undergoing Nd:YAG laser iridotomy for chronic angle closure glaucoma, after a mean follow up period of 27 months<sup>13</sup>.

Focal lens opacities underlying the treatment site were not detected in any of our patients. Focal lens opacities following Nd:YAG laser iridotomy are very unusual<sup>10,13,14,15,22,23,107</sup>. Focal opacities are much more commonly seen following argon laser iridotomy<sup>1,10,13,22,23,105,112</sup>.

Posterior synechiae developed in 20/54 (37%) of acute angle closure glaucoma eyes, treated by Nd:YAG laser iridotomy, peripheral iridectomy, or trabeculectomy, compared to 6/52 (12%) of eyes in our fellow eye study (see Table 4.4).

Among acute angle closure glaucoma eyes posterior synechiae occurred more commonly following Nd:YAG laser iridotomy(42%) than peripheral iridectomy (27%), possibly due to our reluctance to use post treatment mydriatics. The iridotomy provides an alternative channel through which aqueous may by-pass the pupil, allowing adhesions to readily develop between the iris and lens<sup>119,120</sup>. Posterior synechiae are particularly frequent following the administration of miotics<sup>119</sup>.

Posterior synechiae were more frequently seen following trabeculectomy (40%) than peripheral iridectomy (27%). This finding may have been related to the higher incidence of iritis seen among trabeculectomy patients.

Previous studies<sup>87,119</sup> have reported a similar prevalence of posterior synechiae following peripheral iridectomy for acute angle closure glaucoma, and have also found a higher prevalence of posterior synechiae among acute angle closure glaucoma eyes than among fellow eyes<sup>87</sup>. We found a higher prevalence of posterior synechiae following Nd:YAG laser iridotomy than has previously been reported<sup>23</sup>. However, in

our study pupil dilation was carried out in order to detect posterior synechiae. Previous studies in which this was not done may have under-reported the true incidence of posterior synechiae <sup>23</sup>.

Floman found two or more lines of visual acuity loss due to cataract in 56% of acute angle closure glaucoma eyes treated by operative peripheral iridectomy with posterior synechiae, compared to 27% of eyes without posterior synechiae <sup>87</sup>. However it is difficult to ascertain whether posterior synechiae cause cataract per se, or whether they are merely associated with other potentially cataractogenic factors such as operative or laser induced lens trauma, or iritis.

We found that 20/54 (37%) of acute angle closure glaucoma eyes treated by Nd:YAG laser iridotomy, operative peripheral iridectomy or trabeculectomy developed posterior synechiae. 4/10 (40%) of acute angle closure glaucoma eyes treated by Nd:YAG laser iridotomy, operative peripheral iridectomy or trabeculectomy who lost two or more lines of visual acuity during follow up developed posterior synechiae, a proportion almost identical to the prevalence of posterior synechiae among the whole group. While our numbers are relatively low, these findings do not support the concept that posterior synechiae cause progressive cataract development.

**CHAPTER 5b**  
**COMPARISON OF ACUTE ANGLE CLOSURE GLAUCOMA EYES**  
**AND FELLOW EYES**

**5b.1 MATERIALS AND METHODS**

52 of the 70 patients presenting with acute angle closure glaucoma during the period January 1987 to June 1989 were randomly allocated to Nd:YAG laser iridotomy or operative peripheral iridectomy in the fellow eye. The choice of procedure in the acutely affected eye was made using a variety of clinical factors. 36 patients were treated with the same procedure in each eye and were observed prospectively in order to compare the outcome in the acutely affected eye and the fellow eye.

**5.b.2 RESULTS**

21 patients underwent bilateral Nd:YAG laser iridotomy and 15 patients underwent bilateral operative peripheral iridectomy during the study period. One laser treated patient had bilateral acute angle closure glaucoma and was excluded from the study.

The characteristics of the 35 patients included in the study are shown in Table 5.6.

Number of patients	35
Age, years	65±11.6
Male : female ratio	10 : 25
Duration acute attack, hours	31.0±17.2
Mean IOP acute eyes, mm Hg	47.5±14.2
Mean IOP fellow eyes, mm Hg	17.8±6.7

**TABLE 5.5**  
**Prospective study of the treatment of acute angle**  
**closure glaucoma. Comparison of acute and**  
**fellow eyes - initial characteristics.**

Intraocular pressure was significantly higher in acute eyes at presentation (paired Student t test  $p < 0.001$ ).

29/35 (83%) of fellow eyes and 20/35 (57%) of acutely affected eyes had a visual acuity of 6/12 or better following initial medical control, but prior to surgical or laser treatment,  $\chi^2$  test with Yate's correction  $p < 0.05$ .

## **5b.2.1 OPERATIVE COMPLICATIONS**

### **5b.2.1.1 OPERATIVE COMPLICATIONS: Nd:YAG LASER**

#### **IRIDOTOMY**

The mean total laser energy used to produce an iridotomy in acute eyes was  $35.6 \pm 33.0$  mJ, compared to  $20.0 \pm 17.6$  mJ in fellow eyes. This difference did not reach statistical significance using the paired Student t test.

Iris bleeding occurred in 9 acute eyes and 10 fellow eyes. Focal corneal oedema overlying the treatment site was seen in 6 acute eyes and 5 fellow eyes ( $\chi^2$  test with Yate's correction NS).

### **5b.2.1.2 OPERATIVE COMPLICATIONS: OPERATIVE**

#### **PERIPHERAL IRIDECTOMY**

Operative hyphaema occurred in one acute eye and three fellow eyes. A patent iridectomy was not produced in one acute eye due to separation of the iris stroma from the pigment epithelium.

## **5b.2.2 FOLLOW UP**

Patients were followed up for a mean period of  $12.9 \pm 11.8$  months (range 6-36 months).

### **5b.2.2.1 GLAUCOMA OUTCOME**

The mean intraocular pressure at follow up was  $15.6 \pm 3.6$  mm Hg in acutely affected eyes and  $14.8 \pm 3.3$  mm Hg in fellow eyes (paired Student t test NS).

26/35 (74%) of acute eyes had normal intraocular pressure without medication following Nd:YAG laser iridotomy or operative peripheral iridectomy. 5 eyes had normal intraocular pressure at follow up following additional medical (3 eyes) or surgical (2 eyes) treatment. 4 eyes which had received no additional medical or surgical treatment had an intraocular pressure greater than 21 mm Hg at follow up.

31/35 (89%) of fellow eyes had normal intraocular pressure with no medication at follow up. 4 eyes were being treated with topical medication at the time of follow up. The difference in glaucoma outcome between acutely affected eyes and fellow eyes was not statistically significant, using  $\chi^2$  test with Yate's correction.

### **5b.2.2.2 VISUAL ACUITY OUTCOME**

6/35 (17%) acutely affected eyes lost 2 or more lines of visual acuity due to cataract during the follow up period - 3 due to cataract development in previously clear lenses and 3 due to progression of pre existing cataract. 1/35 (3%) fellow eye lost 2 or more lines of visual acuity due to cataract development in a previously clear lens. This difference was not significant using the  $\chi^2$  test with Yate's correction.

## **5b.3 DISCUSSION**

The mean total laser energy needed to produce a Nd:YAG laser iridotomy in acute eyes and in fellow eyes was not significantly different. Complications such as iris bleeding and focal corneal oedema were seen equally frequently in acute eyes and fellow eyes. Resolving

corneal and iris oedema, and ocular hyperaemia following acute angle closure glaucoma did not significantly affect Nd:YAG laser iridotomy procedures.

75% of the acute eyes were normotensive without medication at follow up, a figure which is comparable to the results of previous studies<sup>25,43,46,86,87</sup> (see Table 1.10). 89% of fellow eyes were normotensive without medication, a result which is also similar to previously published results (see Table 1.11). The number of patients in our study was relatively small, and differences in the glaucoma outcome of acute eyes and fellow eyes were not statistically significant.

6/35 (17%) of acutely affected eyes and 1/35 (3%) of fellow eyes lost 2 or more lines of visual acuity due to cataract progression during the follow up period. These figures are comparable with previously reported results (see Tables 1.12 and 1.13). Again the number of patients in our study was relatively small, and no statistically significant difference in the visual acuity outcome of acute eyes and fellow eyes was obtained.

Patients with acute angle closure glaucoma of prolonged duration or which responded poorly to initial medical control were treated by primary trabeculectomy during the study period, and cases with less severe glaucoma were treated by operative peripheral iridectomy or Nd:YAG laser iridotomy. To this extent differences in outcome between acutely affected eyes and fellow eyes treated by operative peripheral iridectomy or Nd:YAG laser iridotomy were probably less than if no case selection had occurred.

## CHAPTER 6

### HOW LARGE MUST AN IRIDOTOMY BE?

#### 6.1 SUMMARY

3 cases of acute angle closure glaucoma in eyes with a small, but patent, Nd:YAG laser iridotomy are presented, and similar cases in the literature are reviewed. Theoretically a 15 $\mu$  diameter iridotomy should be large enough to prevent angle closure glaucoma due to pupil block. Mechanisms by which larger iridotomies fail to prevent angle closure glaucoma, and the role of provocation tests following iridotomy, are discussed. An iridotomy should be at least 150-200 $\mu$  in diameter if acute angle closure glaucoma is to be reliably prevented.

#### 6.2 INTRODUCTION

Various forms of iris surgery have been used to treat angle closure glaucoma since Von Graefe's original description of the broad iridectomy in 1857<sup>38</sup>. Surgical iridotomy was introduced by Curran in 1920<sup>18,19,20</sup>. Peripheral iridectomy was described by Chandler in 1952<sup>3</sup>. Argon laser iridotomy<sup>1</sup>, and more recently Nd:YAG laser iridotomy<sup>2</sup> have already largely superseded surgical iridectomy. While laser surgery has many advantages over conventional surgery, it must not be forgotten that laser iridotomy represents a return to the use of smaller iris openings than those obtained by surgical peripheral iridectomy<sup>21</sup>. Gifford noted in 1921 that very small surgical iridotomies were not as effective in controlling intraocular pressure as larger iridotomies<sup>20</sup>.

Reports are now emerging of acute angle closure glaucoma developing in the presence of a small but patent argon<sup>132,133</sup> or Nd:YAG<sup>80,106</sup> laser iridotomy. While cases of acute angle closure glaucoma

following surgical peripheral iridectomy have generally been attributed to plateau iris syndrome <sup>117, 204, 205</sup>, not all cases of acute angle closure glaucoma following a small laser iridotomy can be placed in this category <sup>80,103,106,132</sup>.

The mechanism of failure of very small iridotomies may be obstruction of aqueous flow at very small iridotomy size. Below a critical surface area significant iris bombé may occur at normal aqueous flow rates. When iris bombé is sufficient to cause iridocorneal contact throughout a critical extent of the angle, beginning superiorly, acute angle closure glaucoma occurs <sup>53,56</sup>. The minimum "safe" area of iridotomy has not been defined, but an approximate value may be calculated using a simple mathematical model.

### **6.3 MATERIALS AND METHODS**

#### **6.3.1. Case reports of acute angle closure glaucoma in the presence of a small patent Nd:YAG laser iridotomy.**

We have treated 3 patients who developed acute angle closure glaucoma despite the presence of a patent Nd:YAG laser iridotomy.

A Zeiss "Visulas" Nd:YAG laser and Zeiss anterior segment YAG contact lens were used in all treatments. Patients were given acetazolamide 500 mg orally one hour before treatment, and one drop of G. Pilocarpine 2% 30 minutes before treatment. A treatment site was chosen in the superior iris between 10 and 2 o'clock, approximately 2/3 distance from the pupil margin to the base of the iris. An iris crypt was used, where present. A single 5-10 mJ pulse was delivered to the treatment site. If this pulse did not penetrate the iris, further single pulses were delivered to the same site until penetration was achieved. Patency was assessed by direct observation of the posterior chamber, or



anterior lens capsule.

The size of iridotomies was measured by comparison with the 0.2mm spot produced by a Haag-Streit slit lamp focussed on the iris plane.

### **6.3.2. Mathematical model of minimum effective iridotomy area.**

A mathematical model of aqueous flow through an iridotomy has been developed in order to determine the minimum size of iridotomy needed to prevent iris bombé and acute angle closure glaucoma.

### **6.3.3. Photometric analysis of the effect of pupil dilation on iridotomy area.**

A photometric technique was devised to analyse changes in iridotomy area following pupil dilation. 16 eyes of 11 patients treated by Nd:YAG laser iridotomy were used.

The horizontal corneal diameter was measured using a Haag-Streit slit lamp measuring eyepiece, which incorporates a graticule with 0.1 mm divisions. The cornea and iris were then photographed using a Zeiss anterior segment camera.

The pupil was dilated using one drop of Tropicamide 1% and the eye was again photographed, using identical camera settings.

Colour transparency photographs were prepared, and projected onto a white screen. The projected horizontal corneal diameter was measured in millimetres, and compared with the measurement obtained using the slit lamp measuring eyepiece. A magnification factor for the projected image was derived from these measurements for each eye. The magnification factor was approximately x80 in every case.

The following measurements were then made from the projected

image, and converted to unmagnified values using the magnification factor :

- undilated horizontal pupil diameter
- dilated horizontal pupil diameter
- iridotomy diameter in the radial and circumferential axis, pupil undilated
- iridotomy diameter in the radial and circumferential axis, pupil dilated
- distance from limbus to nearest point of iridotomy, pupil undilated
- distance from limbus to nearest point of iridotomy, pupil dilated

The area of the iridotomy before and after pupil dilation was measured by placing millimetre graph paper on the white screen and counting the number of squares covered by the image of the iridotomy.

Linear regression analysis was used to detect significant correlations between changes in iridotomy area on dilating the pupil and a variety of parameters which could potentially influence this.

## **6.4 RESULTS**

### **6.4.1 CASE REPORTS.**

Case 1. A 75 year old hypermetropic male presented with right acute angle closure glaucoma of 48 hours' duration. The intraocular pressure was 78 mm Hg, the anterior chamber was shallow, and the angle was closed throughout 360 degrees. The left eye had a very narrow, open angle. Treatment with acetazolamide 500 mg intravenously and 6. Pilocarpine 2% hourly resulted in a fall in intraocular pressure to 12 mm Hg, with an open angle throughout 360 degrees. Nd:YAG laser iridotomy was performed three days later. A treatment site 1 mm from the limbus

at 10 o'clock was chosen. The iris was a light grey colour, with no crypts. Three 9.0 mJ pulses resulted in a small (200 $\mu$ x100 $\mu$ ), patent iridotomy. Minimal iris bleeding occurred at the time of treatment, but there were no other complications. One week following treatment the iridotomy was patent, though small. The intraocular pressure was 10 mm Hg. No further eye medication was prescribed.

Two weeks following treatment the patient complained of blurred vision in the right eye. The intraocular pressure was 68mm Hg, and gonioscopy revealed 300 degrees of angle closure superiorly. Medical treatment with topical pilocarpine 2% and timolol 0.5% reduced the intraocular pressure to 13 mm Hg, with an open angle. The iridotomy was small (50 $\mu$ x100 $\mu$ ), but patent. Trabeculectomy with peripheral iridectomy was performed, leading to an intraocular pressure of 10 mm Hg, and a visual acuity of 6/5.

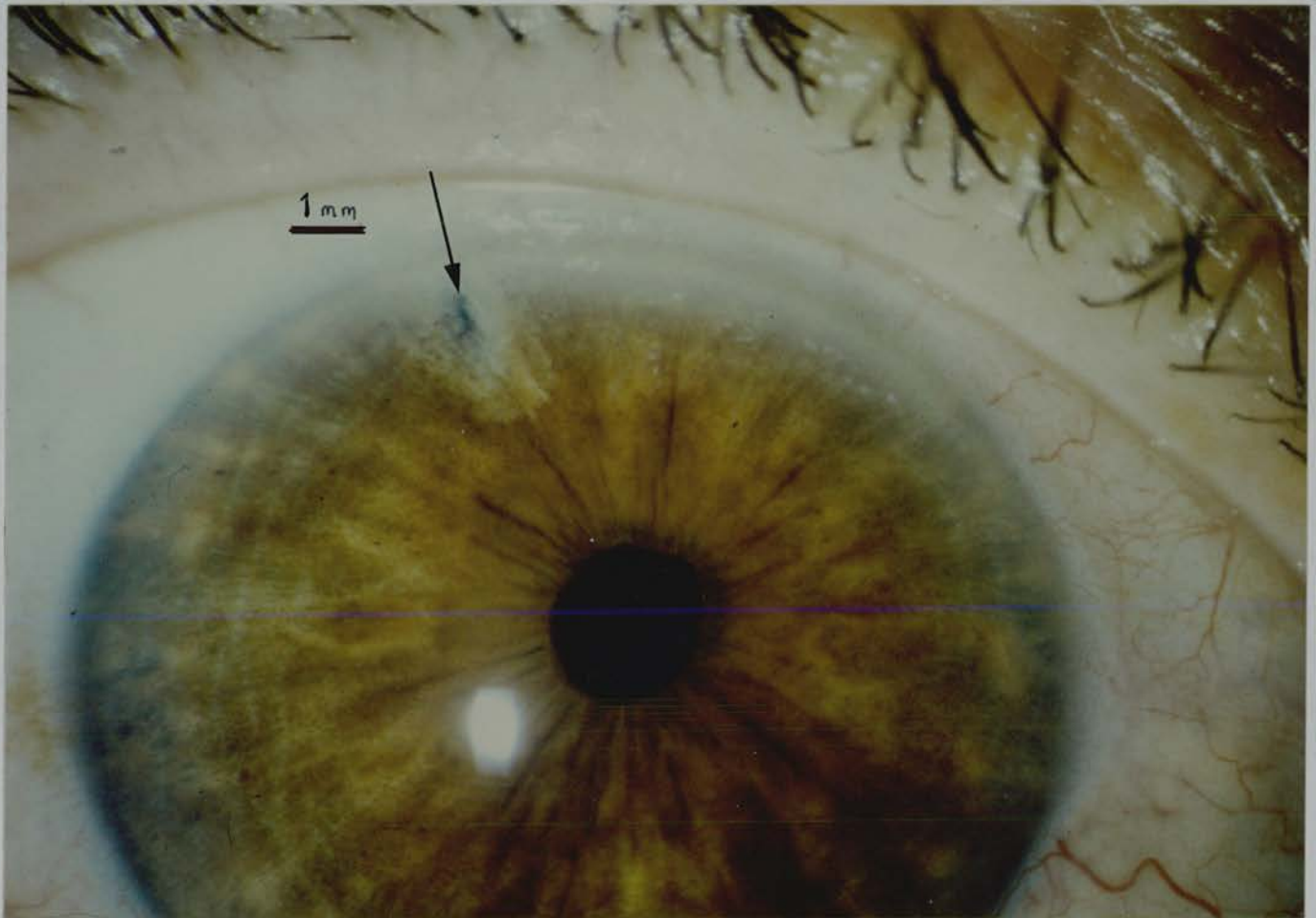
Case 2. A 65 year old female presented with left acute angle closure glaucoma of 24 hours' duration. The intraocular pressure was 58 mm Hg, the anterior chamber was shallow, and the angle was closed throughout 360 degrees. The right anterior chamber was shallow with 120 degrees of angle closure superiorly, and the intraocular pressure was 15 mm Hg.

Following initial medical control, left trabeculectomy was performed.

Further examination of the right eye following treatment with G. Pilocarpine 2% revealed an open angle throughout 360 degrees. Right Nd:YAG laser iridotomy was performed. The treatment site was 1 mm from the limbus, at 10 o'clock. The iris was brown, with no crypts. Four 9.7 mJ pulses were used to produce a patent iridotomy, and one further 9.7 mJ pulse was used to enlarge the opening.

One week later the iridotomy was patent, though small. The

intraocular pressure was 14 mm Hg. At review three weeks later the right intraocular pressure was found to be 41mm Hg, and the pupil was dilated. Gonioscopy was not performed. The patient had been using cyclopentolate 1% drops to the left eye, and may have inadvertently contaminated the right eye. Following treatment with pilocarpine 2% the intraocular pressure returned to 16 mm Hg. The iridotomy was patent, but small -  $50\mu\times 50\mu$  (Figure 6.1).



**Figure 6.1**

**How large must an iridotomy be in order to prevent acute angle closure glaucoma? Case 2. Initial iridotomy size too small.**

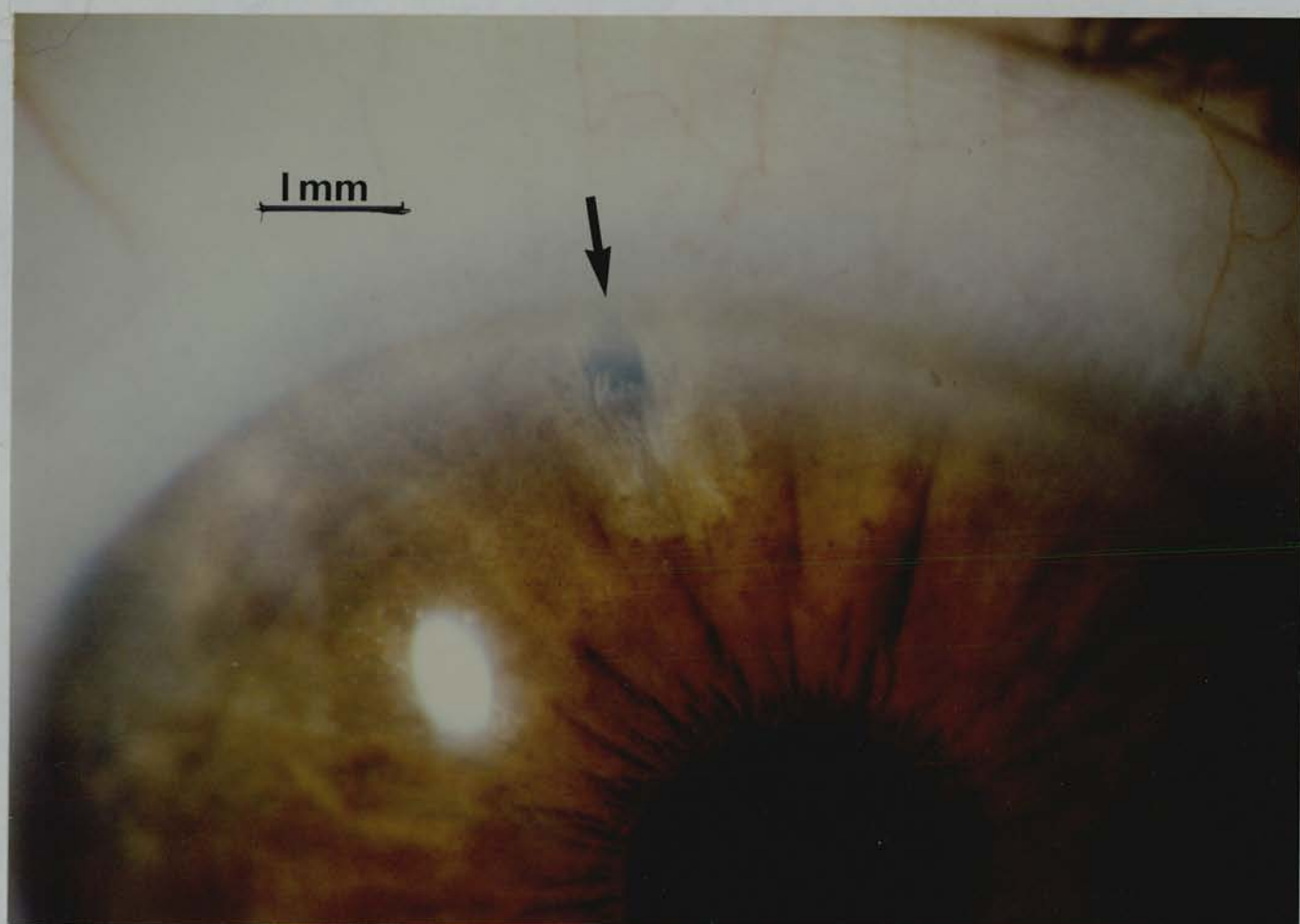
Acute angle closure glaucoma developed. Iridotomy diameter  $50\mu$ . The arrow indicates the very small area of full thickness iris opening at the centre of the treatment site.

Further laser treatment was performed in order to enlarge the opening. Five 2.0 mJ Nd:YAG pulses were delivered to the sides of the existing iridotomy, enlarging the opening to 100 $\mu$ x100 $\mu$ . Following treatment G Betamethasone 0.1% QID and G Tropicamide 1% once daily were prescribed. The patient returned four days later complaining of pain and reduced vision in the right eye. The intraocular pressure was 50 mm Hg, and the pupil was mid-dilated and unreactive. The iridotomy was now situated very peripherally, with iris strands running forwards to the cornea, but appeared to be patent. Gonioscopy was not performed. The intraocular pressure returned to normal following treatment with acetazolamide 500 mg intravenously, and G. pilocarpine 2% hourly. The iridotomy was patent, but small (100 $\mu$ x100 $\mu$ ). The angle was open on gonioscopy. Treatment with G. Pilocarpine 2% QID was prescribed.

A pilocarpine/phenylephrine provocation test as described by Mapstone<sup>68</sup> performed on the right eye one week later was negative.

Intermittent aching pain above the right eye continued, and further Nd:YAG laser enlargement of the iridotomy was performed 6 weeks later. Twenty one 1.1 mJ pulses were delivered using a Wise 103 dioptre contact lens, resulting in some oozing of blood. A further ten 1.0 mJ pulses were delivered 30 minutes later. The resulting iridotomy measured 200 $\mu$ x200 $\mu$ .

One week later all symptoms had resolved, and the iridotomy measured 100 $\mu$ x200 $\mu$ . Pilocarpine/phenylephrine testing was again negative. However provocation using G. Tropicamide 1% produced a 9 mm Hg rise in IOP, with folds of iris blocking the trabecular meshwork over 270 degrees on gonioscopy. At follow up three weeks later the intraocular pressure was 17 mm Hg, with no medication (Figure 6.2). Subsequent cyclopentolate 1% provocation testing produced no rise in intraocular pressure.



**Figure 6.2**

**How large must an iridotomy be in order to prevent acute angle closure glaucoma? Case 2 . Iridotomy of adequate size.**

Following laser enlargement all symptoms resolved and provocation testing was negative. Iridotomy diameter 200 $\mu$

Case 3. An 83 year old female presented with intermittent pain in the left eye. The intraocular pressure was 44 mm Hg, the anterior chamber was deep, and Goldman gonioscopy revealed 90 degrees of angle closure superotemporally. The plane of the iris was flat, with an anteriorly placed iris insertion. The right eye had a similar angle

configuration, with normal intraocular pressure. Plateau iris configuration was diagnosed. The intraocular pressure in the left eye quickly returned to normal following treatment with acetazolamide 500 mg orally and G. pilocarpine 2% hourly. Gonioscopy revealed 180 degrees of angle closure superiorly. Nd:YAG laser iridotomy was performed three days later. The iris was light grey, with no crypts. A treatment site 1mm from the limbus at 2 o'clock was selected. Four 10.9 mJ pulses produced a moderately large ( $200\mu\times 400\mu$ ), patent iridotomy. There was minimal iris bleeding at the time of treatment.

Following treatment G. Timolol 0.5% twice daily, G. Cyclopentolate 1% twice daily, and G. Betamethasone 0.1% four hourly were prescribed. Fourteen days later the patient returned with pain and reduced vision of 24 hours duration in the left eye. The intraocular pressure was 50 mm Hg. Following treatment with G. Pilocarpine 2% and G. Timolol 0.5% the intraocular pressure fell to 7 mm Hg. The iridotomy was patent and moderately large ( $200\mu\times 400\mu$ ). Indentation gonioscopy revealed goniosynechiae over 150 degrees superiorly, with plateau iris configuration. A sector iridectomy was performed. On further follow up intraocular pressure in the left eye was found to be 28 mm Hg on no treatment, falling to 21 mm Hg on addition of G. Timolol 0.5% twice daily. Gonioscopy revealed an open angle throughout 360 degrees.

#### **6.4.2 RESULTS - MATHEMATICAL MODEL**

A very small iridotomy may be of inadequate physical size to by-pass pupil block adequately. Given a constant rate of aqueous flow and complete pupil block, the pressure difference across an iridotomy increases as the size of the iridotomy decreases. Increased posterior chamber pressure relative to anterior chamber pressure will result in iris bombé. The degree of bombé is dependent on the rigidity of the iris,

and the pressure difference across the iris. At a critical level, dependent on peripheral anterior chamber depth, iris bombé may become sufficient to cause iridocorneal contact over a large enough extent of the angle to precipitate acute angle closure glaucoma<sup>53-56</sup>.

The minimum "safe" area of an iridotomy may be calculated using a simple mathematical model. Several assumptions are necessary, each of which must be qualified.

1. Aqueous production is constant. However aqueous production in fact declines at high intraocular pressure.

2. Pupil block is complete. While pupil block forces in eyes with acute angle closure glaucoma are substantial, pupil block is likely to be relative rather than complete during development of an angle closure glaucoma episode.

3. All aqueous passes through the iridotomy. In addition to some aqueous passing through the pupil, some aqueous leaves the eye via uveoscleral outflow.

4. Iridotomy area is unchanged by iris bombé. Iris bombé, and increased flow through a small iridotomy, could conceivably stretch open an iridotomy, increasing its area.

The limitations of each of these assumptions would tend to result in reduced iris bombé for a given iridotomy area. Estimation of minimum effective iridotomy area based on these assumptions will therefore be conservative.

In order to calculate the minimum iridotomy area needed to prevent development of iris bombé an assessment is first made as to whether aqueous flow is laminar or turbulent through small iridotomies. Assuming the iridotomy aperture is  $10\mu$ , aqueous viscosity equals the viscosity of water ( $\eta = 10^{-3}$  Newton seconds per square metre),



aqueous density equals the density of water ( $\rho = 1000$  kilograms per cubic metre), and aqueous flow,  $Q$ , is approximately two microlitres per minute ( $3.3 \times 10^{-11}$  cubic metres per second), as measured by Bloom et al.<sup>207</sup>, then Reynolds number for the system may be calculated.

If the iridotomy size ( $d$ ) is  $10\mu$  diameter, then the aqueous velocity

$$v = \text{flow} / \pi r^2 = 4.2 \times 10^{-1} \text{ms}^{-1},$$

Reynolds number for the system

$$R = \rho v d / \eta, \quad R = 42.$$

If  $R$  is considerably less than 1000, flow is laminar. Aqueous flow through an iridotomy of diameter  $10\mu$ , or larger, will be laminar.

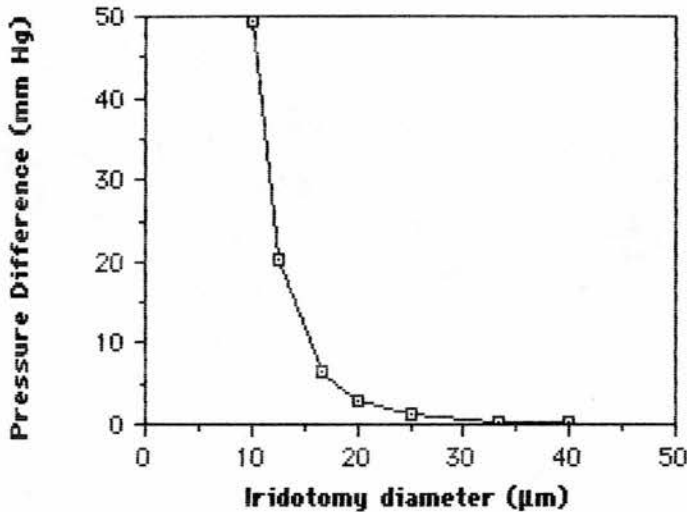
Secondly the iridotomy channel may be considered to be a pipe of length  $50\mu$ , assuming the peripheral iris thickness is  $50\mu$ . The pressure drop (p.d.) along a pipe of length  $l = 50\mu$ , diameter  $d = 100\mu$ , at flow rate  $Q$  is expressed by the formula :

$$\begin{aligned} \text{p.d.} &= 128 \eta l Q / \pi d^4 \\ &= 128 \times 10^{-3} \times 5 \times 10^{-5} \times 3.3 \times 10^{-11} / 3.142 \times 10^{-16} \\ &= 0.672 \text{Nm}^{-2}. \\ &= 0.00494 \text{ mm Hg, as } 1 \text{ mm Hg} = 136 \text{ Nm}^{-2}. \end{aligned}$$

An iridotomy of  $100\mu$  diameter will have a pressure drop of  $0.00494$  mm Hg across it, assuming total pupil block.

However, as p.d. is proportional to  $1/d^4$ , if the diameter of the iridotomy were  $50\mu$ , p.d. would be  $.079$  mm Hg, under the same conditions. If the iridotomy were  $25\mu$ , the p.d. would be  $1.27$  mm Hg. If the iridotomy were  $12.5\mu$ , the p.d. would be  $20.2$  mm Hg, and if the iridotomy were  $10\mu$  the p.d. would be  $49.4$  mm Hg. It is not difficult to conceive that a pressure difference of  $10$ - $20$  mm Hg across the iris could result in significant iris bombé, with iridocorneal contact and angle closure.

Such a pressure difference could develop if the size of the iridotomy was between 10 and 15 $\mu$  in diameter (Figure 3).



**FIGURE 6.3**  
**Pressure difference across the iris as a function of iridotomy area**

#### **6.4.3 EFFECT OF PUPIL DILATION ON IRIDOTOMY AREA**

Photographs of 16 eyes of 11 patients taken before and after pupil dilatation were analysed. The following derived values were then obtained :

##### **1. Change in iris area by pupil dilation.**

The cornea and pupil approximated to a circle in every case. The area of the iris before and after pupil dilation could be obtained from the difference between the area of the cornea and the area of the pupil.

Iris area, undilated pupil

$$= (\text{corneal diameter})^2 \times \pi/4 - (\text{undilated pupil diameter})^2 \times \pi/4$$

Iris area, pupil dilated

$$= (\text{corneal diameter})^2 \times \pi/4 - (\text{dilated pupil diameter})^2 \times \pi/4$$

The change in iris area on dilating the pupil was expressed by the ratio : (iris area, dilated pupil) / (iris area, undilated pupil)

## **2. Change in iridotomy area by pupil dilation.**

The change in the iridotomy area on dilating the pupil was expressed by the ratio :

$$(\text{iridotomy area, dilated pupil}) / (\text{iridotomy area, undilated pupil})$$

## **3. Change in iridotomy shape by pupil dilation.**

With the pupil undilated every iridotomy was elliptical, with the longest axis radial to the limbus, and the shortest axis circumferential to the limbus. A derived "elliptical factor" was calculated from the ratio:

$$(\text{radial axis diameter}) / (\text{circumferential axis diameter}).$$

On dilating the pupil the iridotomy shape changed, with the radial axis becoming shorter and the circumferential axis becoming longer. In 13 eyes the circumferential axis became longer than the radial axis, and the "ellipse factor" then had a value less than 1. In 3 eyes the iridotomy became circular.

The change in iridotomy shape on dilating the pupil was expressed as the ratio :

$$(\text{ellipse factor, undilated pupil}) / (\text{ellipse factor, dilated pupil})$$

The value of this ratio was termed the "shape change ratio"

#### 4. Change in position of the iridotomy in relation to the limbus.

The difference between the distance of the nearest point of the iridotomy to the limbus before and after dilating the pupil was calculated, and the value obtained was termed "position change".

Table 6.1 gives the results of photometric analysis of changes in iridotomy area on dilating the pupil.

Change in iris area, 100% = no change	73.0±8.9%
Mean area iridotomies, undilated pupil, mm <sup>2</sup>	0.072±0.058
Mean area iridotomies, dilated pupil, mm <sup>2</sup>	0.076±0.083
Mean change in iridotomy area on dilating the pupil (100% = no change)	99.3±0.68%
Number of iridotomies which became larger	7
Number of iridotomies which became smaller	9
Change in iridotomy area of iridotomies which became larger (100% = no change)	170.1±19.8%
Change in iridotomy area of iridotomies which became smaller (100% = no change)	44.3±22.3%

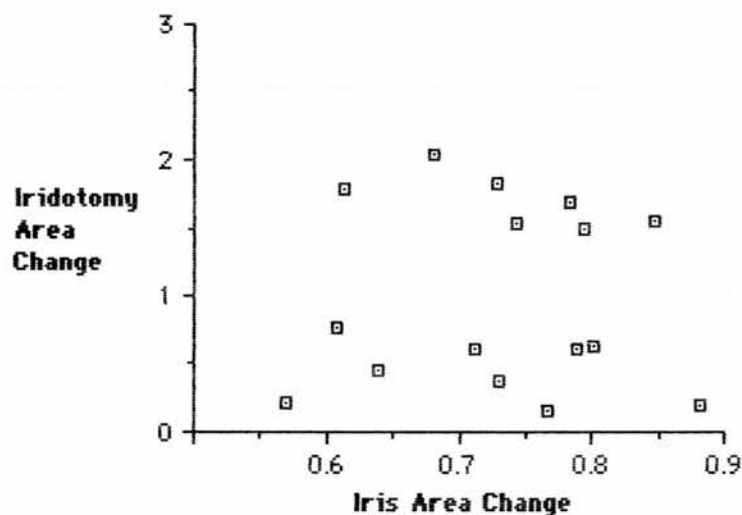
**TABLE 6.1**  
**Photometric analysis of changes in iridotomy area on dilating the pupil**

Dilating the pupil reduced the mean area of the iris by 73%. The iridotomy area became larger in 7 patients and smaller in 9 patients on dilating the pupil. The mean iridotomy area with the pupil dilated was 99.3% of the mean iridotomy area with the pupil undilated. No mean change in iridotomy area occurred on dilating the pupil. Eyes in which the iridotomy became larger, and eyes in which the iridotomy became smaller were then separated into two groups. The mean change in iridotomy area among those iridotomies which became larger was 170%, and the mean change among those which became smaller was 44.3%. No statistically significant differences were found between these two groups in : iris area change; initial iridotomy area; ellipse factor with

pupil undilated; shape change ratio; the distance of the iridotomy from the limbus with the pupil undilated (unpaired Student t test NS). The maximum change occurred in two eyes in which the iridotomy area with the pupil dilated was 19% and 21% of the iridotomy area with the pupil undilated. In these eyes the iridotomy was small prior to pupil dilation ( $0.031$  and  $0.033 \text{ mm}^{-2}$ ). No other factors were present which might have predicted marked reduction in iridotomy area on pupil dilation.

The iridotomy area following pupil dilation correlated with iridotomy area prior to pupil dilation ( $r=0.66$ ,  $p=0.005$ ), but did not correlate with the ellipse factor prior to pupil dilation or the distance of the iridotomy from the limbus prior to pupil dilation. The only factor which could predict small iridotomy area following pupil dilation was small iridotomy area prior to pupil dilation.

The change in iridotomy area was independent of change in iris area (correlation coefficient  $r=0.002$ ,  $t=0.007$ ,  $p=0.99$ ), as shown in Figure 6.4.



**Figure 6.4**

**Change in iridotomy area as a function of change in iris area on dilating the pupil**

Every iridotomy was elliptical with a longer radial axis prior to pupil dilation. 13/16 iridotomies became elliptical with a longer circumferential axis on dilating the pupil, and three iridotomies became circular. Values for the degree of elliptical shape of iridotomies before and after dilating the pupil are shown in Table 6.2.

Ellipse factor, pupil undilated (ratio) (radial / circumferential axis diameter )	243.8±94.0%
Ellipse factor, pupil dilated (ratio) (radial / circumferential axis diameter )	69.9±20.3%
Shape change ratio (Ellipse factor, pupil undilated/ Ellipse factor, pupil dilated)	369.9±166.8%

**TABLE 6.2**  
**Changes in iridotomy shape on dilating the pupil**

The mean change in elliptical shape was by a factor of 369.9%. The mean change in elliptical shape correlated with the ellipse factor present prior to pupil dilation ( correlation coefficient  $r=0.62$ ,  $t=2.9936$ ,  $p=0.01$ ). The shape of iridotomies which were very elliptical prior to pupil dilation changed more when the pupil was dilated than iridotomies which were more circular in shape.

The change in iridotomy area on dilating the pupil was independent of the shape change ratio ( correlation coefficient  $r=0.123$ , NS).

Table 6.3 shows the mean distance of iridotomies from the limbus before and after dilating the pupil.

Distance from limbus, mm, pupil undilated	1.106±0.511
Distance from limbus, mm, pupil dilated	0.496±0.431
Position change, mm	0.609±0.498

**TABLE 6.3**  
**Distance of iridotomies from the limbus before and after dilating the pupil**

There was no significant correlation between the distance of the iridotomy from the limbus with the pupil undilated and the change in its area on dilating the pupil (correlation coefficient  $r=0.17$ , NS), or the change in iridotomy position and the change in area on dilating the pupil (correlation coefficient  $r=0.244$ , NS).

## 6.5 DISCUSSION

Curran observed in 1920 that in some patients with glaucoma the passage of aqueous through the pupil appeared to be impeded by the iris "hugging the lens over too great a surface extent"<sup>18</sup>. Surgical iridotomy allowed free drainage of fluid from the posterior chamber to the anterior chamber, with posterior movement of the iris and a reduction in intraocular pressure. Barkan elaborated the concept of pupil block as the causative mechanism of iris bombé, with resulting angle closure<sup>40</sup>. A peripheral iridectomy causes "collapse" of iris bombé, resulting in widening of the "entrance to" the angle<sup>40</sup>. Peripheral anterior chamber depth, but not central anterior chamber depth, increases following peripheral iridectomy<sup>53,57,58</sup>, due to resolution of iris bombé.

Failure of surgical peripheral iridectomy, or laser iridotomy, as evidenced by development of acute angle closure glaucoma, may occur by one of two mechanisms. A small number of angle closure glaucoma cases are related to "plateau iris configuration" - an anteriorly placed iris

root, flat iris plane, and a normal or near normal central anterior chamber depth. Pupil dilation results in peripheral iris bunching, with occlusion of the trabecular meshwork <sup>109,208</sup>. As pupil block is not causative, operative peripheral iridectomy or laser iridotomy are relatively ineffective in preventing further attacks of acute angle closure glaucoma. One of our patients (case 3) probably had plateau iris syndrome, and developed acute angle closure glaucoma following mydriasis despite the presence of a relatively large, patent, iridotomy.

Perhaps the term "angle crowding" angle closure glaucoma would be a more appropriate term to use for eyes which develop acute angle closure glaucoma following mydriasis in the presence of a patent peripheral iridectomy. Two other cases with moderately large peripheral iridectomies who developed acute angle closure glaucoma while using mydriatic drops have been reported <sup>117,204</sup>.

Mydriatic or dark room provocation tests following peripheral iridectomy have been found to be positive in 3-19% of cases <sup>208-211</sup>. Gonioscopy at the end of a positive provocation test in eyes with a patent peripheral iridectomy has revealed angle closure in some cases, due to angle crowding <sup>136,208</sup>. However in other eyes the angle has been open <sup>208,209,211</sup>. Raised intraocular pressure in these eyes may be explained by the outflow facility lowering effect of anticholinergic drugs <sup>212</sup>. Operative peripheral iridectomy appears to entirely overcome pupil block. No cases of acute angle closure glaucoma due to iris bombé have been reported in the presence of a patent surgical iridectomy.

Mydriatic provocation tests following argon laser iridotomy <sup>121,213</sup>, and Nd:YAG laser iridotomy <sup>15</sup>, have given similar results to those performed following operative peripheral iridectomy. However pilocarpine/phenylephrine tests have been negative in all eyes tested following argon laser iridotomy <sup>105</sup>, or Nd:YAG laser iridotomy <sup>21,80</sup>. The



test produces only moderate mydriasis, and increased tone in both the sphincter and dilator muscles of the iris may prevent angle crowding. The test induces maximal pupil block<sup>64</sup>, and failure to obtain any positive results suggests that pupil block was fully overcome in all cases tested.

Acute angle closure glaucoma in the presence of a small, patent argon laser iridotomy has previously been reported in two patients<sup>132,133</sup>. Mandelkorn reported a case of acute angle closure glaucoma following a 50 $\mu$  diameter argon laser iridotomy<sup>132</sup>. Further argon laser treatment was applied to the site, resulting in satisfactory long term pressure control. Brainard reported a similar case, in an eye with a 75 $\mu$  diameter argon laser iridotomy<sup>133</sup>. Further argon laser treatment to enlarge the iridotomy to 125 $\mu$  resulted in satisfactory long term intraocular pressure control, suggesting inadequate iridotomy size was responsible for initial failure.

Acute angle closure glaucoma has also been reported in the presence of a small, but patent Nd:YAG laser iridotomy<sup>15, 80, 106</sup>. Brazier reported two cases. One was treated by surgical peripheral iridectomy, with no further complications. The second was treated with miotics<sup>106</sup>. Wishart reported two cases of acute angle closure glaucoma and two cases of subacute angle closure glaucoma in the presence of patent Nd:YAG laser iridotomies<sup>15</sup>. In three cases the iridotomy was 100 $\mu$  diameter, and in the fourth 150 $\mu$ . Gray reported two cases of acute angle closure glaucoma in the presence of a small, patent iridotomy<sup>80</sup>. One developed acute angle closure glaucoma while using 6 Pilocarpine 4%, and was treated by trabeculectomy. The second was treated by a further iridotomy. Intraocular pressure subsequently remained normal in both cases. Two of our cases (cases 1 and 2) developed acute angle closure glaucoma despite the presence of a small patent iridotomy. Case 1

responded to trabeculectomy, and case 2 responded to laser enlargement of the iridotomy.

The occurrence of acute angle closure glaucoma in the presence of a small, but patent, iridotomy, which responds to surgical peripheral iridectomy or laser enlargement, suggests the size of the initial iridotomy was inadequate.

Wishart studied iris bombé using slit lamp photograph assessment of peripheral anterior chamber depth. In four eyes with very small iridotomies and progressive narrowing of the angle, repeat laser iridotomy resulted in deepening of the peripheral anterior chamber<sup>15</sup>. This study provides further evidence that very small iridotomies may not fully relieve iris bombé.

We have calculated that the minimum functional iridotomy diameter should be approximately  $15\mu$ , as previously suggested by Wheeler<sup>214</sup>. However our clinical experience, and that of others<sup>15,80,106,132,133</sup>, shows that iridotomies in the range of 50-150 $\mu$  diameter may fail to prevent acute angle closure glaucoma.

Several factors may contribute to the reduction in area of an iridotomy of theoretically "safe" area below that needed to prevent acute angle closure glaucoma. Most cases of acute angle closure glaucoma following Nd:YAG laser iridotomy have occurred within one month of treatment. Naveh has observed rapid reduction of Nd:YAG laser iridotomy area within an hour of treatment in six eyes<sup>14</sup>. In each case a return to the original iridotomy area occurred within two weeks. Localised iris oedema around the treatment site may have been responsible.

Reclosure of Nd:YAG laser iridotomies due to iris pigment epithelium proliferation is unusual, and tends to occur 1-4 months following treatment<sup>14, 15, 22, 80, 106</sup>. Reclosure resulted in acute angle closure glaucoma in two eyes reported by Wishart<sup>15</sup>, and one eye reported

by Gray<sup>80</sup>.

Case 2 in our study developed acute angle closure glaucoma following mydriasis. Pupil dilation might reduce the area of an iridotomy, and folds of iris tissue might functionally block an iridotomy when the pupil is dilated. Mydriatics might therefore produce acute angle closure glaucoma in the presence of a patent iridotomy by two mechanisms - pupil block due to reduction of iridotomy area, and angle crowding.

In a photometric study of iridotomy area following pupil dilation we observed two eyes in which the iridotomy area became reduced to 20% of undilated area on dilating the pupil. However the factors responsible for some iridotomies becoming smaller on dilating the pupil, and some becoming larger, were not identified. Iridotomy area following pupil dilation correlated with iridotomy area prior to pupil dilation, but did not correlate with any other measured factor. If the theoretical minimum effective iridotomy diameter is  $15\mu$ , iridotomies must be at least  $33.5\mu$  in diameter in order to allow for a potential fivefold reduction in iridotomy area when the pupil is dilated.

In order to answer the question "How large must an iridotomy be in order to prevent acute angle closure glaucoma?" several factors must be considered. In forms of angle crowding angle closure glaucoma, such as plateau iris syndrome, a large iridotomy will not prevent the development of acute angle closure glaucoma following mydriasis, as pupil block is not causative.

Theoretical modelling suggests an iridotomy of 10-15 $\mu$  diameter will prevent angle closure glaucoma due to pupil block. However an iridotomy of greater size may fall below this critical level due to early post treatment oedema, late pigment epithelium proliferation, or pupil dilation. Wishart reported subacute angle closure glaucoma in an eye

with a 150 $\mu$  diameter iridotomy<sup>15</sup>. All other cases of acute angle closure glaucoma in the presence of a patent iridotomy have occurred in eyes with an iridotomy of less than 100 $\mu$  in diameter. The smallest potentially safe iridotomy diameter would therefore appear to be 100 $\mu$ . However, in order to incorporate a safety margin, we would recommend that iridotomies should be at least 150-200 $\mu$  in diameter.

Provocation tests have not been helpful in identifying eyes at risk, as eyes developing acute angle closure glaucoma following Nd:YAG laser iridotomy have done so before a provocation test had been performed<sup>15,21,80</sup>. If provocation tests are to be employed, we suggest the use of G. Tropicamide 1% soon after the iridotomy has been performed, in order to detect cases at risk of developing acute angle closure glaucoma. Routine pupil dilation to prevent posterior synechiae formation following laser iridotomy may be more safely achieved using G. Phenylephrine 10%, with measurement of intraocular pressure following dilation. Lowe has shown that phenylephrine very rarely results in acutely raised intraocular pressure following peripheral iridectomy<sup>204</sup>, and the effect may be quickly reversed using G. Thymoxamine 0.5% if a pressure rise does occur.

## **CHAPTER 7**

### **CHRONIC ANGLE CLOSURE GLAUCOMA AND NARROW ANGLE GLAUCOMA**

#### **CHAPTER 7a**

#### **CHRONIC ANGLE CLOSURE GLAUCOMA**

##### **7a.1 SUMMARY**

Nd:YAG laser iridotomy was performed in 16 patients with chronic angle closure glaucoma. Glaucoma control improved in 7 patients, and did not worsen in any patient. Two patients underwent trabeculectomy during the follow up period because of failure of Nd:YAG laser iridotomy to adequately improve intraocular pressure control. 4/14 (29%) of eyes lost two or more lines of visual acuity during the follow up period due to progression of preexisting cataract.

##### **7a.2 INTRODUCTION**

Mild degrees of pupil block may result in slowly progressive angle closure, beginning superiorly<sup>53</sup>. Closure may be appositional or synechial<sup>47,49,51,56,95</sup> and the response to miotics<sup>47,54</sup>, or the angle appearance on indentation gonioscopy<sup>88,89</sup>, may be used to differentiate these processes prior to iridectomy. When more than 80% of the angle circumference is closed, raised intraocular pressure with optic disc cupping and glaucomatous visual field loss are likely to develop<sup>89</sup>.

Prior to the advent of laser iridotomy, operative peripheral iridectomy was the treatment of choice for most cases of chronic angle closure glaucoma<sup>44,48,49,52,89,95</sup>. However some workers have argued that cases with extensive goniosynechiae, optic disc cupping or visual

field loss should be treated with primary drainage surgery <sup>49,52,95</sup>.

The advent of argon laser iridotomy, and the belief that this was a non invasive technique <sup>215</sup>, led to recommendations that all cases of chronic angle closure glaucoma should be treated with argon laser iridotomy <sup>215,139</sup>. However laser surgery cannot be regarded as non invasive <sup>6</sup>. While chronic angle closure glaucoma cases have been included in studies of argon <sup>33</sup> and Nd:YAG <sup>137</sup> laser iridotomy techniques, no study has reported the long term outcome of Nd:YAG laser iridotomy for chronic angle closure glaucoma.

### **7a.3 MATERIALS AND METHODS**

16 patients with a diagnosis of chronic angle closure glaucoma who underwent Nd:YAG laser iridotomy between June 1986 and March 1989 were recalled for a detailed follow up examination. The diagnosis was based on the following features:

- Intraocular pressure greater than 21 mm Hg prior to medical treatment, with or without pathological optic disc cupping or glaucomatous visual field loss.

- Part or all of the angle closed on Goldman gonioscopy.

Information on the results of examination prior to Nd:YAG laser iridotomy, and medical and laser glaucoma treatment, were obtained from the case records. At the follow up examination measurement of corrected visual acuity, Friedman analyser visual field charting, and Goldman applanation tonometry were performed. The area of the iridotomy was measured by comparison with the 0.2 mm spot produced by a Haag-Streit slit lamp, and the position of the iridotomy was noted. Goldman gonioscopy was performed by one observer (BWF), followed by Posner 4 mirror indentation gonioscopy if any part of the angle appeared to be closed. The pupil was dilated with G. phenylephrine 10% to detect

posterior synechiae, and examine the lens and fundus.

#### 7a.4 RESULTS

16 patients with chronic angle closure glaucoma in one or both eyes attended for follow up examination. 8 were female, and the mean age of the group was  $66.0 \pm 8.4$  years. 10 patients had bilateral angle closure glaucoma, and 6 unilateral angle closure glaucoma. In bilateral cases one eye was randomly selected for analysis by tossing a coin. The results of examination at presentation of these eyes is shown in Table 7.1.

Number patients	16
Visual acuity less than 6/12	3
cause - cataract	2
- amblyopia	1
Mean intraocular pressure, mm Hg	$35.2 \pm 9.5$
Cup : disc ratio $\geq 0.7$	4
Visual field loss	7
Gonioscopy $> 210^\circ$ angle closure	12

**TABLE 7.1**  
**Chronic angle closure glaucoma. Examination at presentation.**

Initial medical treatment consisted of G. Pilocarpine 2% four times daily in 14 patients. In 2 patients, with initial intraocular pressure greater than 40 mm Hg, G. Timolol 0.5% twice daily was also prescribed at the initial visit. Two further patients were found to have an intraocular pressure greater than 25 mm Hg while using G. Pilocarpine 2% four times daily, and G. Timolol 0.5% twice daily was added to their regimen.

Prior to Nd:YAG laser iridotomy 8 eyes had an intraocular pressure greater than 21 mm Hg, and the mean intraocular pressure of the group was  $22.9 \pm 6.3$  mm Hg.

#### **7a.4.1 Nd:YAG LASER IRIDOTOMY TREATMENT PARAMETERS.**

The laser treatment parameters, operative complications and immediate postoperative complications recorded in the case records are shown in Table 7.2.

Number patients	16
Mean number laser pulses	2.5±1.9
Mean total energy (mJ)	20.1±13.5
Primary patency	16
Iris bleeding	1
Focal corneal oedema ++	2
Intraocular pressure rise ≥ 6 mm Hg	2

**TABLE 7.2**

**Chronic angle closure glaucoma. Nd:YAG laser iridotomy treatment parameters and early complications.**

#### **7a.4.2 FOLLOW UP**

The mean follow up period was 21.3±9.7 months. Two of the eyes analysed had undergone a trabeculectomy operation during the follow up period because of failure of Nd:YAG laser iridotomy to adequately improve intraocular pressure control.

##### **7a.4.2.1 GLAUCOMA OUTCOME**

###### **7a.4.2.1.1 VISUAL FIELDS AND OPTIC DISCS**

Slight progression of visual field loss was noted in 2 eyes, but the eyes had developed cataract and the visual field changes may have been secondary to this. The cup : disc ratio did not enlarge by more than 20% in any eye.



#### **7a.4.2.1.2 MEDICATION**

11 patients were being treated with glaucoma medication at the time of the follow up examination including 2 eyes which had undergone trabeculectomy. After excluding these 2 eyes, 5 eyes needed fewer medications than prior to laser treatment, 6 the same number of medications, and 3 needed more medications than prior to laser treatment. In 3 eyes needing the same number of medications miotics had been withdrawn, which may be considered advantageous. A total of 8/16 (50%) of eyes therefore benefited from laser iridotomy in terms of medication requirement.

#### **7a.4.2.1.3 INTRAOCULAR PRESSURE**

14/16 (88%) eyes, including the 2 eyes which underwent trabeculectomy, had an intraocular pressure less than or equal to 21 mm Hg. The mean intraocular pressure of the group was  $18.7 \pm 3.2$  mm Hg, which was not significantly less than the mean intraocular pressure on medication prior to laser iridotomy ( $22.9 \pm 6.3$  mm Hg).

After excluding the 2 eyes which underwent trabeculectomy, the intraocular pressure was within 2 mm Hg of the pretreatment level in 3 eyes, lower in 9 eyes, and higher in 2 eyes.

#### **7a.4.2.1.4 GLAUCOMA CONTROL**

Nd:YAG laser iridotomy could be regarded as having improved glaucoma control if:

1. The same number or fewer medications resulted in reduced intraocular pressure, or
2. Fewer medications resulted in the same or lowered intraocular pressure.

Using these criteria 7/16 (44%) of patients benefited from Nd:YAG laser iridotomy.

Conversely Nd:YAG laser iridotomy could be regarded as having worsened glaucoma control if:

1. The same number or more medications resulted in increased intraocular pressure, or
2. More medications resulted in the same or increased intraocular pressure. Using these criteria no patient had worse glaucoma control following Nd:YAG laser iridotomy.

#### **7a.4.2.1.5 GONIOSCOPY**

After excluding the 2 eyes which underwent trabeculectomy during the follow up period, 7/14 eyes had partly closed angles on Goldman gonioscopy at follow up. Indentation gonioscopy showed that residual angle closure was due to goniosynechiae in all but one eye. This eye had 60° of angle closure on Goldman gonioscopy at follow up, but the angle was entirely open on indentation. The iridotomy area was rather small in this eye (100µx200µ), and it is possible that some degree of residual iris bombé was present.

Gonioscopy examinations prior to iridotomy were performed by a variety of observers, and comparison with the follow up examinations were therefore not valid.

#### **7a.4.2.2 VISUAL ACUITY OUTCOME**

Five eyes lost two or more lines of visual acuity following Nd:YAG laser iridotomy. In four cases this was due to progression of pre existing cataract, and in one case due to development of cataract in a previously clear lens following trabeculectomy.

Three eyes had posterior synechiae, and in two of these eyes two

or more lines of visual acuity was lost due to progression of preexisting cataract.

## 7a.5 DISCUSSION

The Nd:YAG laser treatment parameters and complication rates in chronic angle closure glaucoma eyes were similar to those found when treating the fellow eye of patients with acute angle closure glaucoma, as shown in Table 7.3. (see Tables 4.3 and 7.2 )

	Fellow eye	Chronic ACG eye
Number eyes	26	16
Mean number pulses	3.1±2.6	2.5±1.9
Mean total energy (mJ)	25.8±21.4	20.1±13.5
Primary patency	25 (96%)	16 (100%)
Iris bleeding	15	1
Focal corneal oedema ++	4	2
Intraocular pressure rise $\geq$ 6mm Hg, to a final IOP > 21mm Hg	6	2

TABLE 7.3

**A comparison of Nd:YAG laser treatment parameters and complication rates in fellow eyes and chronic angle closure glaucoma eyes**

Slight iris bleeding was probably under-reported in the chronic angle closure glaucoma group. Post treatment intraocular pressure rise was probably less frequent in the chronic angle closure glaucoma group because of the use of topical  $\beta$  blockers or oral acetazolamide prior to treatment.

### 7a.5.1 GLAUCOMA OUTCOME

Measurement of glaucoma outcome is complex, as changes in glaucoma medication following iridotomy alter intraocular pressure control. We found that 12 of the 14 eyes (86%) which did not undergo

trabeculectomy during the follow up period had an intraocular pressure of less than 21 mm Hg at follow up, compared to 8/16 (50%) eyes prior to laser iridotomy. This finding is similar to that obtained following peripheral iridectomy<sup>49,52,89,95</sup>, argon laser iridotomy<sup>33,95,139</sup> and Nd:YAG laser iridotomy<sup>137</sup> for chronic angle closure glaucoma (see Table 1.14)

The mean intraocular pressure at follow up,  $18.7 \pm 3.2$  mm Hg, was not significantly lower than that prior to laser iridotomy,  $22.9 \pm 6.3$  mm Hg. When the intraocular pressure results and medication requirement results were combined it was evident that 7/14 patients had improved glaucoma control following Nd:YAG laser iridotomy. After excluding two patients who underwent trabeculectomy because of failure of Nd:YAG laser iridotomy to adequately improve glaucoma control, no patient had worse glaucoma control following Nd:YAG laser iridotomy.

The number of patients in our study was too few to assess whether patients with visual field loss at presentation responded less well to iridotomy than patients with a full visual field. Previous studies have found this to be the case following operative peripheral iridectomy<sup>49,52,89,95</sup>.

At follow up 7/14 eyes had partly closed angles on Goldman gonioscopy. Indentation gonioscopy showed that closure was entirely due to goniosynechia in 6 of these eyes. In one eye closure was appositional, suggesting that part of the closure was due to residual iris bombé. This eye had a rather small iridotomy. Wishart described four eyes with small iridotomies in which repeat laser iridotomy resulted in deepening of the peripheral anterior chamber<sup>15</sup>. Very small iridotomies may fail to prevent acute angle closure glaucoma<sup>21,80</sup>, and it is conceivable that very small iridotomies may inadequately overcome iris bombé in chronic angle closure glaucoma.

### **7a.5.2 VISUAL ACUITY OUTCOME**

We found loss of two or more lines of visual acuity in 4 of the 14 (29%) eyes which did not undergo trabeculectomy during the follow up period. This figure is slightly higher than that found for fellow eyes in our study (2/26 (8%), see table 4.4) and for chronic angle closure glaucoma eyes treated by peripheral iridectomy, argon laser iridotomy, or Nd:YAG laser iridotomy in previous studies (7-15%, see Table 1.15). However our numbers were small.

As Nd:YAG laser iridotomy has not been demonstrated to be safer than operative peripheral iridectomy the indications for Nd:YAG laser iridotomy should in general remain the same as those for operative peripheral iridectomy. However, unlike peripheral iridectomy, Nd:YAG laser iridotomy does not result in a surgical wound, and therefore does not make subsequent drainage surgery more difficult. Medical treatment of chronic angle closure glaucoma is unsatisfactory<sup>48</sup>. A reasonable approach would be to perform Nd:YAG laser iridotomy at the time of diagnosis in all chronic angle closure glaucoma patients, and resort to drainage surgery if additional medical treatment fails to adequately control glaucoma on follow up.

## CHAPTER 7b

### NARROW ANGLE GLAUCOMA

#### 7b.1 SUMMARY

Nd:YAG laser iridotomy was performed in 22 patients who fulfilled our diagnostic criteria of narrow angle glaucoma. Glaucoma control improved in 3 patients and deteriorated in 6 patients following iridotomy. Two patients underwent trabeculectomy during the follow up period due to failure of Nd:YAG laser iridotomy to adequately improve intraocular pressure control. 2/22 (9%) of eyes lost two or more lines of visual acuity due to progression of preexisting cataract during the follow up period. One eye developed a dense cataract in a previously clear lens, having sustained a focal lens opacity at the iridotomy site during treatment.

#### 7b.2 INTRODUCTION

Several workers have used the term "narrow angle glaucoma" to describe eyes with the following features <sup>15,216-218</sup>.

Anterior chamber depth  $\leq$  2.5 mm

Intraocular pressure  $>$  21 mm Hg

A narrow or slit-like angle

When glaucomatous optic disc cupping and visual field loss are present the term "narrow angle glaucoma" has been used <sup>15,216,218</sup> and when these features are absent the term "ocular hypertension with a narrow angle" has been used <sup>217</sup>. However the gonioscopic appearances which differentiate chronic angle closure glaucoma from narrow angle

glaucoma are subjective. No clear distinction may be made between narrow angle glaucoma and open angle glaucoma. The existence of narrow angle glaucoma as a disease entity must therefore be questioned.

The results of laser or surgical treatments of narrow angle glaucoma have been disappointing<sup>15,216,217</sup>. Romano found Nd:YAG laser iridotomy resulted in a reduction of medication requirement in 33% of cases, but increased medication was needed in 6 of the 7 eyes which had goniosynechia prior to iridotomy<sup>217</sup>. Wishart found Nd:YAG laser iridotomy, dye laser iridotomy or argon laser trabeculoplasty combined with peripheral iridectomy adequately controlled glaucoma in only 24% of eyes<sup>216</sup>.

We have examined a group of 22 patients fulfilling the gonioscopic and intraocular pressure criteria of narrow angle glaucoma or narrow angle ocular hypertension, treated by Nd:YAG laser iridotomy.

### **7b.3 MATERIALS AND METHODS**

22 patients with a diagnosis of narrow angle glaucoma who underwent Nd:YAG laser iridotomy between June 1986 and March 1989 were recalled for a detailed follow up examination. The diagnosis was based on the following criteria:

- Intraocular pressure greater than 21 mm Hg prior to medical treatment, with or without pathological optic disc cupping or glaucomatous visual field loss.

- Very narrow but open angle on Goldman gonioscopy. Gonioscopy prior to Nd:YAG laser iridotomy was performed by a number of experienced observers, and some degree of subjective variation in descriptions of angle appearances was likely. Descriptions of optic disc appearances were also subject to observer variation.

## 7b.4 RESULTS

22 patients fulfilled our diagnostic criteria of narrow angle glaucoma in one or both eyes. 15 of these patients were female and the mean age of the group was  $69.1 \pm 6.1$  years. 9 of the cases were bilateral, and in these cases one eye was chosen at random for analysis, by tossing a coin.

Details of the initial glaucoma examination of these eyes is shown in Table 7.4.

Number patients	22
Mean intraocular pressure, mm Hg, untreated	$31.5 \pm 6.4$
visual field loss	5
cup : disc ratio $\geq 0.7$	8

**TABLE 7.4**  
**Narrow angle glaucoma. Initial assessment.**

18 patients were initially treated with G. Pilocarpine 2% four times daily, and 2 patients were initially treated with G. Timolol 0.5% twice daily. Two patients with presenting intraocular pressures greater than 30 mm Hg, and with advanced visual field loss, were treated with both G Timolol 0.5% twice daily and G Pilocarpine 2% four times daily.

The mean intraocular pressure after initial medical control was  $21.5 \pm 7.0$  mm Hg. 4/22 eyes had an intraocular pressure greater than 21 mm Hg. Three eyes developed partly closed angles on gonioscopy while using miotics.

The mean follow up period of the group was  $15.2 \pm 6.7$  months. During this time two eyes underwent trabeculectomy, and required no medication following operation.



#### **7b.4.1 GLAUCOMA OUTCOME**

No progression of visual field loss was documented during the follow up period. One optic disc developed a 30% increase in the cup : disc ratio during the follow up period.

After excluding the 2 eyes which underwent trabeculectomy, 4 /20 (20%) eyes had an intraocular pressure greater than 21 mm Hg at follow up. The mean intraocular pressure at follow up was  $20.0 \pm 3.5$  mm Hg, compared to  $21.5 \pm 7.0$  prior to laser iridotomy (unpaired Student t test NS).

After excluding the 2 eyes which underwent trabeculectomy, 3/20 (15%) of eyes had lower intraocular pressure with the same number or fewer medications, or unchanged intraocular pressure with fewer medications.

In 6/20 (30%) of eyes the intraocular pressure was higher, with the same or more medications, or the intraocular pressure was unaltered, with more medications. Measured in this way glaucoma control improved in 15% of eyes and deteriorated in 30% of eyes following iridotomy.

#### **7b.4.2 VISUAL ACUITY OUTCOME**

3 eyes lost 2 or more lines of visual acuity during the follow up period. Two of these eyes had preexisting cataract which progressed. The remaining eye had a clear lens prior to treatment and developed a focal lens opacity at the laser treatment site due to treatment too close to the pupil margin . A dense nuclear cataract developed during the follow up period, reducing visual acuity from 6/9 to perception of light.

## 7b.5 DISCUSSION

The mean intraocular pressure with medication following iridotomy,  $20.0 \pm 3.5$  mm Hg, was not significantly lower than that prior to iridotomy,  $21.5 \pm 7.0$  mm Hg. Glaucoma control was improved in 15% of eyes and deteriorated in 30% of eyes following Nd:YAG laser iridotomy. Romano found deterioration of glaucoma control was particularly likely to occur in patients with goniosynechiae prior to iridotomy<sup>217</sup>.

Cataract development was similar to that seen following Nd:YAG laser iridotomy for chronic angle closure glaucoma. 3/20 (19%) eyes lost 2 or more lines of visual acuity due to cataract development. Operative peripheral iridectomy, argon laser iridotomy and Nd:YAG laser iridotomy for chronic angle closure glaucoma have been reported to result in visual acuity loss of 2 or more lines in 7-15% of eyes, due to cataract progression (see Table 1.15).

One eye sustained focal lens damage due to treatment close to the pupil margin. A dense nuclear cataract developed during the following six months. While focal lens opacity has been described following Nd:YAG laser iridotomy in humans<sup>14-17,107,122</sup> progression to clinically significant visual loss has not been reported previously.

The management of narrow angle glaucoma remains difficult, and Nd:YAG laser iridotomy appears to be of limited value in treatment. Not only does glaucoma control deteriorate in some patients following Nd:YAG laser iridotomy, but should miotics be required there is a high risk of posterior synechiae development<sup>119</sup>.

## CHAPTER 8

### ARGON LASER PRETREATMENT PRIOR TO ND:YAG LASER IRIDOTOMY

#### 8.1 SUMMARY

Argon laser pretreatment followed by Nd:YAG laser iridotomy 4-6 weeks later was performed in the right eye of 10 patients. Primary Nd:YAG laser iridotomy was performed in the left eye. Significantly more Nd:YAG laser energy was needed to produce an iridotomy in pretreated eyes ( $p < 0.001$ ). A patent Nd:YAG laser iridotomy was not obtained at the pretreatment site in 2 eyes. After a mean follow up period of 9.4 months there was no difference in the visual acuity or glaucoma outcome of the two groups. Pretreated eyes developed a significantly larger pigment epithelium defect around the iridotomy site, and a greater degree of pigmentation of the inferior part of the trabecular meshwork 6 months following treatment.

Argon laser pretreatment followed by Nd:YAG laser iridotomy 4-6 weeks later offers no advantages over primary Nd:YAG laser iridotomy.

#### 8.2 INTRODUCTION

Argon laser iridotomy<sup>1</sup>, and more recently Nd:YAG laser iridotomy<sup>2</sup> have already largely superseded operative peripheral iridectomy<sup>3</sup> in the treatment of angle closure glaucoma. Argon laser energy is absorbed by pigmented tissue, leading to thermal tissue destruction<sup>35,36</sup>. Q-switched Nd:YAG laser pulses create a focus of very high irradiation at the treatment site, resulting in formation of a "plasma". Rapid expansion of the plasma produces a shock wave, with mechanical tearing of adjacent tissues<sup>35,36,140,147,148</sup>.

Argon laser iridotomy is associated with a higher incidence of focal lens opacities and iridotomy reclosure than Nd:YAG laser iridotomy<sup>10,11,13,22,23</sup>. Iris bleeding occurs more frequently following Nd:YAG laser iridotomy<sup>10,11,13,22,23</sup>. Attempts have been made to combine the two forms of treatment in order to reduce these complications<sup>37,157,169,219-221</sup>.

Krasnov used argon laser burns to coagulate the iris stroma prior to performing Q-switched ruby laser iridotomy two weeks later<sup>37</sup>. Zborwski used argon laser burns to coagulate the iris stroma immediately prior to performing Nd:YAG laser iridotomy<sup>221</sup>. Several workers have commented on the relative ease with which a Nd:YAG laser iridotomy may be performed at the site of a failed argon laser iridotomy<sup>157,219,220</sup>. This has also been our experience. However controlled trials of these techniques have not been undertaken.

Histologically, an argon laser burn results in atrophy of the iris stroma approximately 2 weeks later<sup>32,222</sup>. Nd:YAG laser iridotomy might be more easily performed in an area of stromal atrophy. We have undertaken a prospective study in which ten patients underwent argon laser pretreatment in the right eye, followed by Nd:YAG laser iridotomy 4 - 6 weeks later. Primary Nd:YAG laser iridotomy was performed in the left eye.

### **8.3 MATERIALS AND METHODS**

The study was approved by the unit ethical committee, and informed patient consent was obtained prior to entry into the trial. Ten consecutive patients referred for laser iridotomy were recruited. Patients with acute angle closure glaucoma were excluded.

Initial assessment included a review of the patients' case records and current glaucoma control. Goldman gonioscopy was performed by one

observer (BWF), followed by Posner 4 mirror indentation gonioscopy if any part of the angle appeared to be closed. The iris colour, and presence or absence of iris crypts, was noted.

Argon laser pretreatment was performed in the right eye and Nd:YAG laser iridotomy in the left eye at the first treatment session. Nd:YAG laser iridotomy was performed in the pretreated area of the right eye at the second treatment session.

Acetazolamide 500 mg was given orally, and one drop of G. Pilocarpine 2% topically, 30 minutes before treatment.

### **8.3.1 ARGON LASER PRETREATMENT**

A Coherent 9900 Argon blue-green laser and Abraham 66 dioptre iridotomy contact lens were used. A treatment site was chosen in the superior iris between 10 and 2 o'clock, 2/3 way from the pupil to the iris base. An iris crypt was used where present. A series of superficial burns of the iris stroma were made, using 2-5 pulses of 0.5-0.7 mW power, 0.2 second duration, and 200-500 $\mu$  diameter spot size.

### **8.3.2 ND:YAG LASER IRIDOTOMY**

A Zeiss "Visulas" Nd:YAG laser and Zeiss anterior segment YAG contact lens were used. A treatment site was chosen in the left eye as symmetrical as possible to the argon laser pretreatment site in the right eye. An iris crypt was used where present. A single 5-10 mJ pulse was delivered to the treatment site. If this pulse did not penetrate the iris, further single pulses were delivered to the same site until penetration was achieved. Patency was assessed by direct observation of the posterior chamber, or anterior lens capsule. The iridotomy was inspected, and the intraocular pressure measured 2 hours following treatment. Patients were reviewed 24 hours, 1 week, and 1 month

following treatment.

Four to six weeks following argon laser pretreatment Nd:YAG laser iridotomy was performed in the pretreated area of the right eye. The treatment procedure was identical to that used for primary Nd:YAG laser iridotomy. The iridotomy was inspected, and the intraocular pressure measured 2 hours following treatment, and patients were reviewed 24 hours, 1 week, and 1 month following treatment.

### **6.3.3 FOLLOW UP**

Patients were reviewed monthly for three months, and then at three monthly intervals. Glaucoma medication was withdrawn in a stepwise fashion in patients with good glaucoma control. Medication was reintroduced if the intraocular pressure rose above 21 mm Hg.

Six months after treatment Goldman gonioscopy was performed by one observer (BWF), followed by Posner 4 mirror indentation gonioscopy if any part of the angle appeared to be closed. Special attention was given to the degree of pigmentation of the inferior part of the trabecular meshwork. The size of the iridotomy was measured by comparison with the 0.2 mm spot produced by a Haag-Streit slit lamp. The area of the iridotomy was then calculated using the formula  $\text{Diameter } a \times \text{Diameter } b \times \pi/4$  (see Figure 2.3, page 48). Transillumination of the iris revealed the extent of pigment epithelium disruption around the iridotomy, and this area was also measured. Pilocarpine/phenylephrine provocation testing as described by Mapstone<sup>68</sup> and modified by Harrad<sup>105</sup> was performed. One drop of G. Phenylephrine 10% and one drop of G. Pilocarpine 2% were instilled. The intraocular pressure was measured one hour later. A rise in intraocular pressure by more than 6 mm Hg was considered positive.

## 8.4 RESULTS

Details of the patients' age, sex and diagnosis are given in table 8.1.

Age, years	64.7 ± 8.7
Sex Male : Female	5 : 5
Diagnosis:	
Chronic ACG	5
Intermittent ACG	3
Subacute ACG	1
Open angle glaucoma with narrow angle	1

**TABLE 8.1**  
**Argon laser pretreatment prior to Nd:YAG laser iridotomy.**  
**Patients age/sex distribution and diagnosis.**

"ACG" = Angle Closure Glaucoma.

### 8.4.1 INITIAL EXAMINATION

Corrected visual acuity was 6/9 or better in 17 eyes. One patient had nuclear cataracts reducing visual acuity to 6/18 in each eye, and one patient had a unilateral nuclear cataract reducing visual acuity to 6/60. Five patients had light brown irises and five patients had grey irises. Three patients had prominent iris crypts - two had brown irises and one had grey irises.

Table 8.2 shows the glaucoma features of each patient immediately prior to laser iridotomy, and at the follow up examination.

## PRE IRIDOTOMY

## POST IRIDOTOMY

Patient	Diagnosis	Symptoms	IOP R	IOP L	Rx R	Rx L	Symptoms	IOP R	IOP L	Rx R	Rx L	CHANGE
1	Intermittent	+	20	21	-	-	-	25	25	-	-	Resolution symptoms. Slight increase IOP.
2	Intermittent	+	12	12	-	-	-	15	15	-	-	Resolution symptoms. Slight increase IOP.
3	Intermittent	+	17	17	-	-	-	16	16	-	-	Resolution symptoms. Slight increase IOP.
4	Subacute	+	28	22	T	T	-	18	18	-	-	Resolution symptoms. Withdrawal medication. Normalised IOP.
5	OAG with narrow angle	-	20	20	T	T	-	23	23	T	T	No benefit
6	Chronic ACG	-	17	17	P+T	P+T	-	20	20	T	T	Reduced medication. Normalised IOP.
7	Chronic ACG	-	28	18	P	-	-	15	16	P+T	-	Normalised IOP R eye, additional medication. Reduced medication. Normalised IOP.
8	Chronic ACG	-	27	29	P	P	-	19	21	Propine	-	Withdrawal medication. Normalised IOP.
9	Chronic ACG	-	35	15	P	P	-	21	20	-	-	Reduced medication. Normalised IOP.
10	Chronic ACG	-	18	23	P+Betoptic	-	-	10	21	Betoptic	-	Reduced medication.

TABLE 8.2

**Argon laser pre treatment prior to Nd:YAG laser iridotomy. Glaucoma examination prior to iridotomy, and glaucoma outcome.**

"ACG" = Angle Closure Glaucoma, "OAG" = Open Angle Glaucoma,

"P" = Pilocarpine, "T" = Timolol.

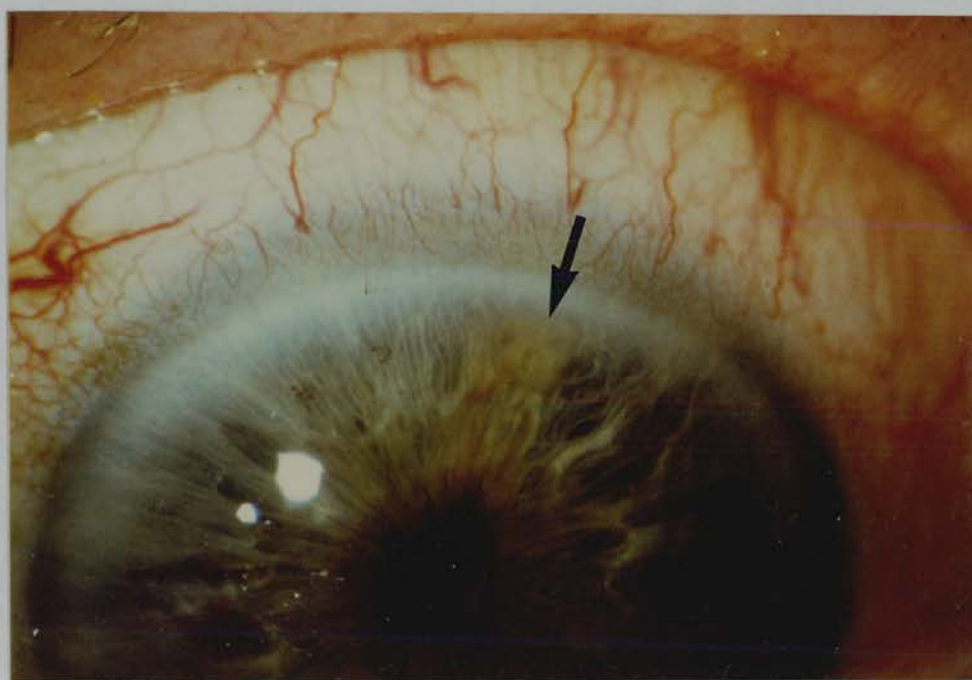


#### 8.4.2 TREATMENT

All patients had argon laser pretreatment followed by Nd:YAG laser iridotomy in the right eye. The mean period between argon laser pretreatment and Nd:YAG laser iridotomy was  $36.6 \pm 16$  days (range 14-62 days). Nine patients underwent Nd:YAG laser iridotomy in the left eye. One patient with unilateral chronic angle closure glaucoma affecting the right eye declined prophylactic treatment in the left eye.

#### 8.4.3 IRIS APPEARANCE FOLLOWING ARGON LASER PRE-TREATMENT

The immediate effect of argon laser burns was contracture of the iris stroma. Following treatment an elevated area of bunched up iris stroma was seen (Figure 8.1).

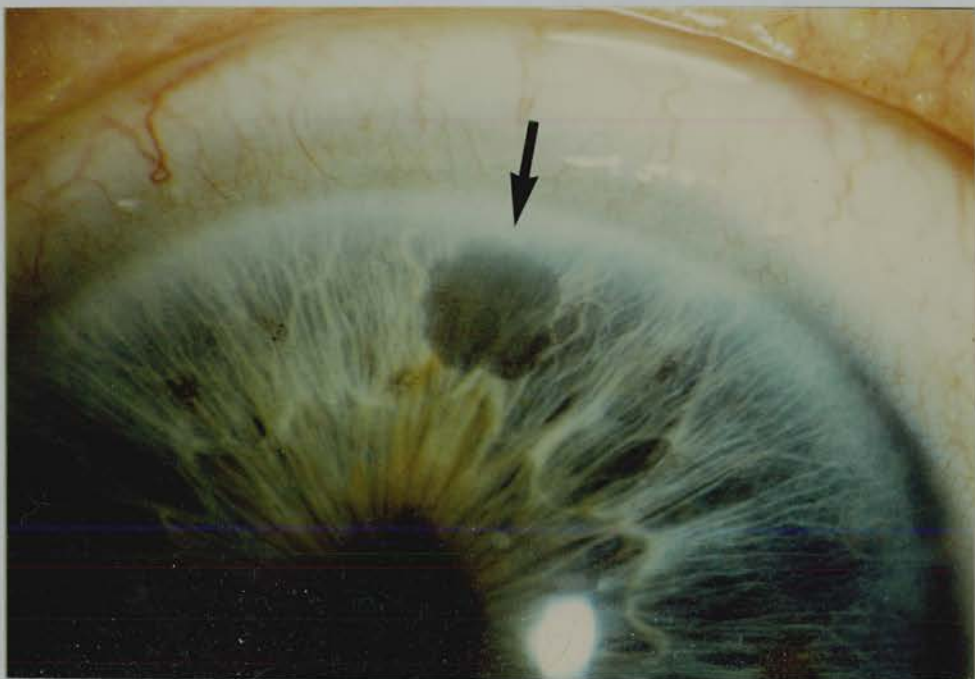


**Figure 8.1. Argon laser pretreatment site in a grey iris immediately following treatment. A pale brown elevated, bunched up area of iris is seen at the treatment site (indicated by arrow).**

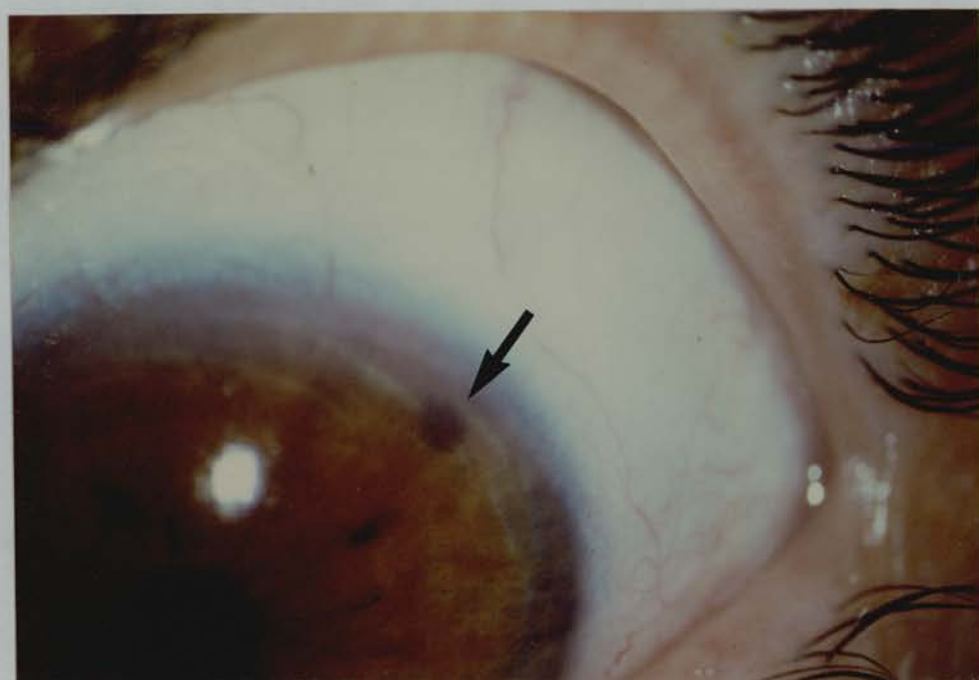
The treated area was a light brown colour in grey irises, and dark brown in brown irises.

One week later the treated area remained elevated, with scattered pigment in the stroma.

After four to six weeks the treated area was less elevated, but significant atrophy was not evident. Grey irises appeared to have a dense granular membrane on the surface of the treated area (Figure 8.2). The treated area was densely pigmented in brown irises (Figure 8.3).

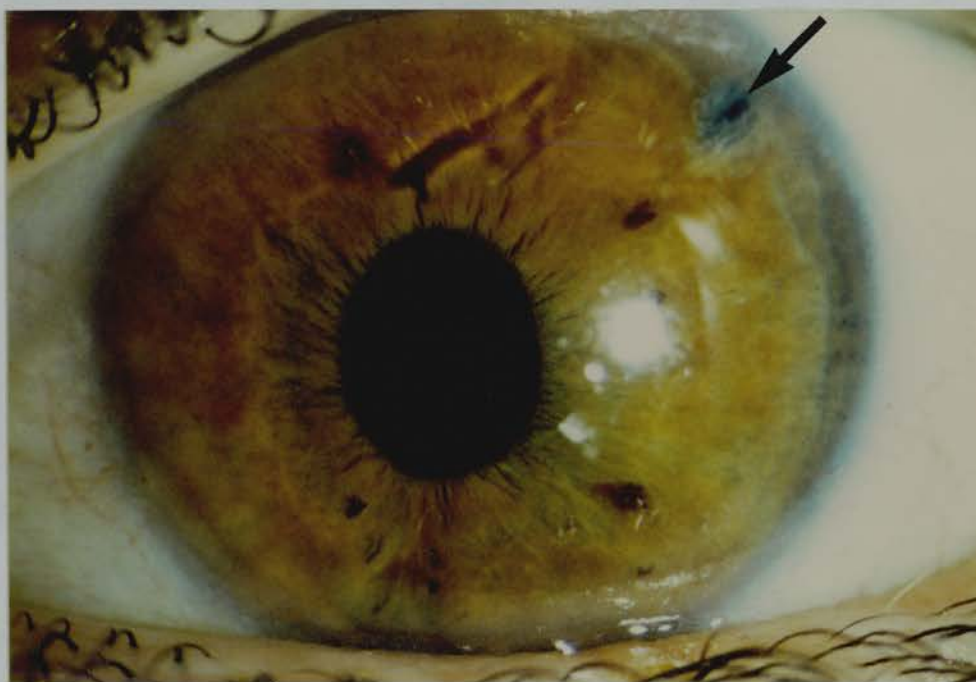


**Figure 8.2. Argon laser pretreatment site in a grey iris 28 days after treatment** (the same eye as that shown in Figure 8.1). A thick granular membrane appears to be present at the treatment site.

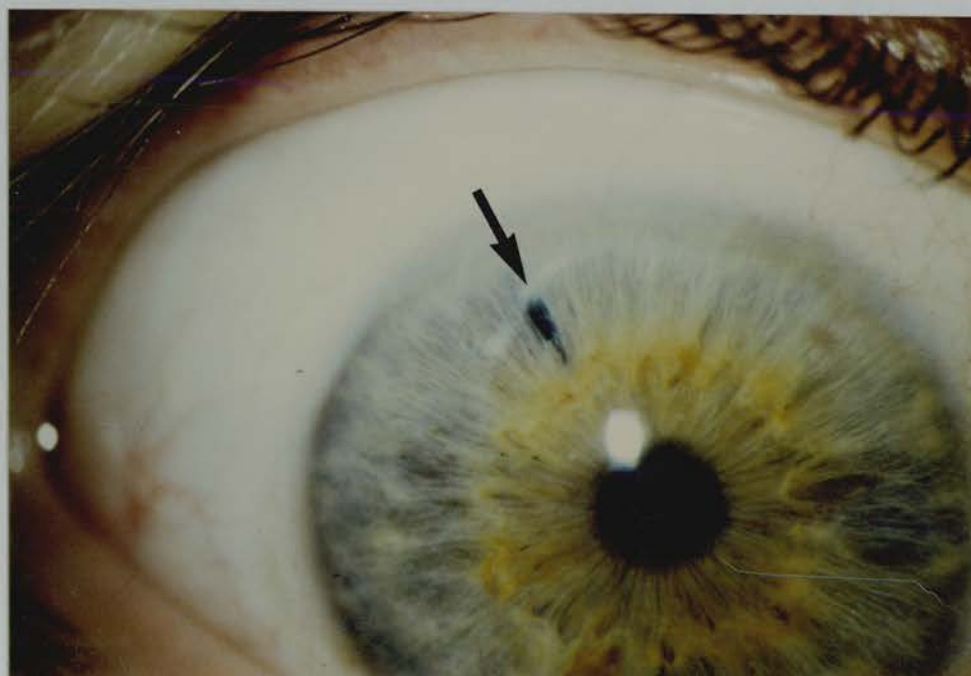


**Figure 8.3. Argon laser pretreatment site in a brown iris 42 days following treatment.** The treatment site is densely pigmented.

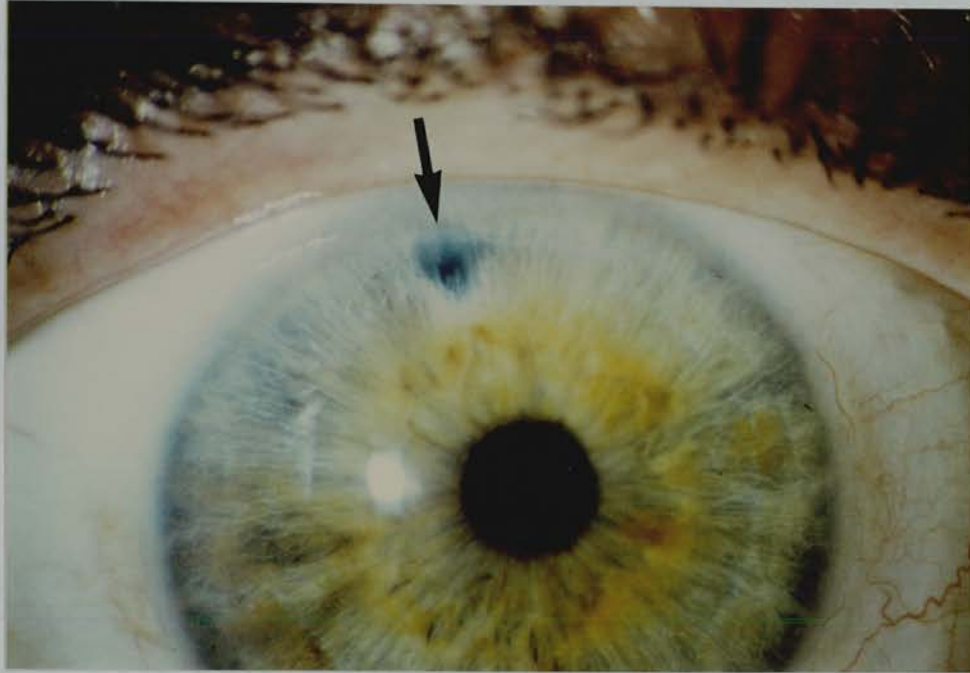
After four months the stroma in the treated area had become atrophic. Nd:YAG laser iridotomy had been performed in the argon laser pretreated area prior to this stage (Figures 8.4, 8.5, 8.6).



**Figure 8.4. Nd:YAG laser iridotomy in an argon laser pretreatment site 9 months after treatment (same eye as shown in Figure 8.3). The argon laser treated stroma around the Nd:YAG laser iridotomy has become atrophic.**



**Figure 8.5. Primary Nd:YAG laser iridotomy 3 months after treatment.**



**Figure 8.6. Nd:YAG laser iridotomy in an argon laser pretreatment site 3 months after argon laser treatment** (fellow eye of that shown in Figure 8.5). Note stromal atrophy in the argon laser pretreated area around the Nd:YAG laser iridotomy.

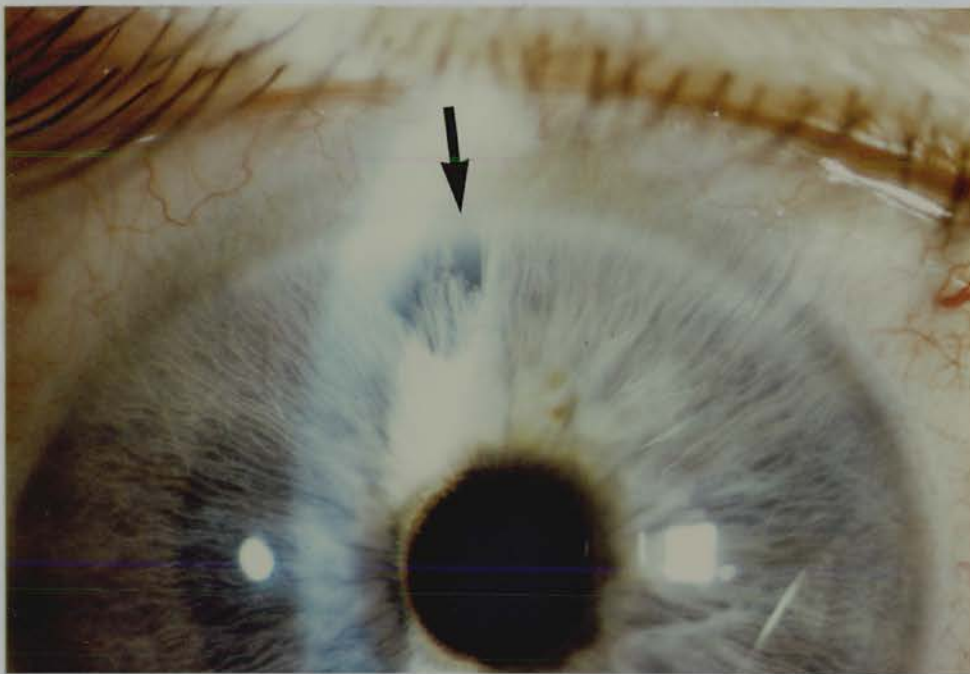
Transillumination of the iris 6 months after treatment revealed defects in the pigment epithelium at the argon laser pretreated site. However these changes may have been related to Nd:YAG laser iridotomy performed in the argon laser pretreated area.

#### **8.4.4 Nd:YAG LASER IRIDOTOMY IN THE ARGON LASER PRE-TREATMENT SITE**

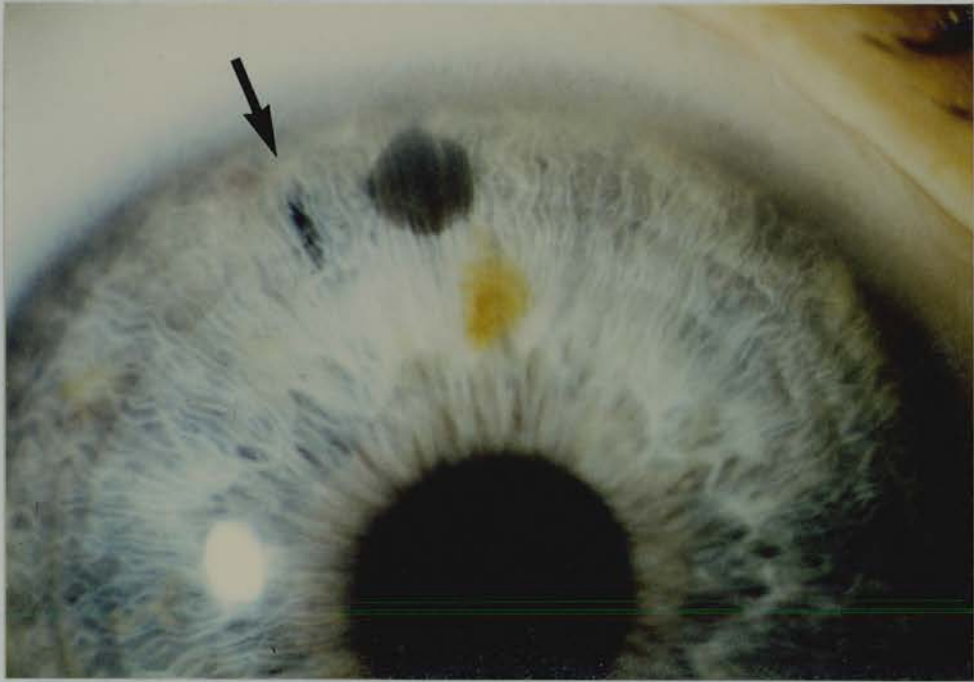
The iris stroma in the argon laser pretreated area proved difficult to cut using the Nd:YAG laser.

One patient underwent Nd:YAG laser iridotomy 2 weeks after argon laser pretreatment. Considerable fragmentation of the surrounding iris

stroma developed (Figure 8.7). Seven cases underwent Nd:YAG laser iridotomy 4-6 weeks after argon laser pretreatment. In these cases the iris stroma appeared to be "tough", and relatively resistant to Nd:YAG laser photodisruption (Figure 8.8). Two cases underwent Nd:YAG laser iridotomy 8 weeks following argon laser pretreatment. In these cases the iris stroma had become atrophic, and penetration of the iris was easily achieved.



**Figure 8.7. Nd:YAG laser iridotomy in an argon laser pretreatment site 4 months after argon laser treatment. The Nd:YAG laser iridotomy was performed 2 weeks after argon laser pretreatment, and considerable fragmentation of the iris stroma occurred.**



**Figure 8.8. Argon laser pretreatment site in a grey iris 56 days after treatment.** A dark grey granular membrane was present on the surface of the pretreatment site. Nd:YAG laser iridotomy at this site failed. Nd:YAG laser iridotomy was then performed at a new site (indicated by arrow).

In every case marked pigment dispersion from the pigment epithelium at the argon laser pretreatment site occurred at the time of Nd:YAG laser iridotomy.

#### 8.4.5 TREATMENT PARAMETERS

The number of pulses, and the total energy used in treatment are shown in Table 8.3.

	Argon laser pretreatment	Nd:YAG after Argon pre Rx	1° Nd:YAG iridotomy
Number of pulses	5.6±4.4	5.4±7.3	2.9±2.0
Total energy (mj)	496±44.1	31.8±29.0	19.4±13.3

**TABLE 8.3**

**Argon laser pretreatment prior to Nd:YAG laser iridotomy. Number of laser pulses, and total energy used in treatment**

Nd:YAG laser iridotomy performed following argon laser pretreatment required significantly more total Nd:YAG laser energy than primary Nd:YAG laser iridotomy ( $p < 0.001$  unpaired student t test). There was no significant difference in the number of Nd:YAG laser pulses used in each form of treatment.

A patent iris opening was obtained in all primary Nd:YAG laser iridotomies. However Nd:YAG iridotomy at an argon laser pretreated site failed in three eyes. In two of these eyes a Nd:YAG laser iridotomy was performed at a fresh site, and in one eye a patent Nd:YAG iridotomy was obtained at the argon laser pretreated area during a second treatment session one week later.

In two cases the size of the primary Nd:YAG laser iridotomy was thought to be inadequate, and subsequent Nd:YAG laser enlargement of the iridotomy was performed.

#### 8.4.6 OPERATIVE COMPLICATIONS

Slight iris bleeding occurred at the time of treatment in 5 primary Nd:YAG iridotomies and one argon laser pretreated Nd:YAG iridotomy ( $\chi^2$  test NS).



Post treatment intraocular pressure elevation to above 21 mm Hg did not occur following primary Nd:YAG laser iridotomy. Intraocular pressure elevation to 24 mm Hg and 34 mm Hg respectively occurred two hours after argon laser pretreated Nd:YAG iridotomy in two patients. Both of these patients had chronic angle closure glaucoma.

Clinically significant iritis or focal corneal oedema did not occur.

#### **FOLLOW UP**

The mean duration of follow up was  $9.4 \pm 3.1$  months, with a range of 5-14 months.

#### **8.4.7 GLAUCOMA OUTCOME**

Progression of visual field loss or optic disc cupping did not occur.

Glaucoma control improved in a measurable way in eight patients. (Table 8.2). In one patient with chronic angle closure glaucoma (patient 7) there was no measurable improvement in glaucoma control. The patient with open angle glaucoma with narrow angles had slightly worse glaucoma control following treatment (patient 5). There was no difference in the outcome of eyes treated with a primary Nd:YAG laser iridotomy and those treated with argon laser pretreated Nd:YAG laser iridotomy.

Goldman gonioscopy revealed open angles in 9 patients. One chronic angle closure glaucoma patient had angle closure throughout 300 degrees superiorly in both eyes (patient 9). On indentation small areas of goniosynechiae were present superiorly in the right eye, but not in the left eye.

Pigmentation of the inferior part of the trabecular meshwork was a prominent feature in eyes with an argon laser pretreated Nd:YAG laser iridotomy (Table 8.4).

	Primary Nd:YAG	Argon/Nd:YAG
Number of eyes:		
Grade 0 pigment	6	4
Grade + pigment	4	3
Grade ++ pigment	0	3

**TABLE 8.4**  
**Argon laser pretreatment prior to Nd:YAG laser iridotomy.**  
**Inferior trabecular meshwork pigmentation 6 months**  
**following treatment**

In five patients the inferior part of the trabecular meshwork was more pigmented in the eye with an argon laser pretreated Nd:YAG laser iridotomy, and in five patients there was no difference in the degree of trabecular meshwork pigmentation in the two eyes. This difference was not statistically significant, using the  $\chi^2$  test with Yate's correction.

Pilocarpine/phenylephrine provocation tests were performed in both eyes of 8 patients. All tests were negative.

The areas of full thickness iris patency, and of surrounding iris transillumination defect are shown in Table 8.5.

	1 <sup>0</sup> Nd:YAG	Argon/YAG
Iridotomy area (mm <sup>2</sup> )	0.034±0.038	0.0836±0.1578
Surrounding transillumination defect	0.036±0.038	0.456±0.6404
Ratio transillumination defect: iridotomy size	1.1±0.316	15.86±21.9

**TABLE 8.5**  
**Argon laser pretreatment prior to Nd:YAG laser iridotomy.**  
**Iridotomy area, and the area of the surrounding pigment epithelium**  
**defect. "Argon/YAG" refers to argon laser pretreated Nd:YAG laser iridotomy**

There was no significant difference in the mean iridotomy area of the two groups using the unpaired Student t test. However the area of transillumination defect was significantly greater in the argon laser pretreated Nd:YAG laser iridotomy group ( $p < 0.05$ ).

#### **8.4.8 VISUAL ACUITY OUTCOME**

No eye lost more than one line of visual acuity during the follow up period, and there was no progression of preexisting lens opacities or development of new lens opacities. No focal lens opacities were seen.

### **8.5 DISCUSSION**

While claims have been made that combined argon and Nd:YAG laser iridotomy is more easily performed than primary Nd:YAG laser iridotomy<sup>221</sup>, our study is the first controlled study of argon laser pretreated Nd:YAG laser iridotomy. We found that Nd:YAG laser iridotomy performed 4-6 weeks after argon laser pretreatment required significantly more Nd:YAG laser energy than primary Nd:YAG laser iridotomy. In two cases a Nd:YAG laser iridotomy was not obtained at the argon laser pretreated site.

The timing of Nd:YAG laser iridotomy following argon laser pretreatment appears to be of some importance. In our cases maximal stromal atrophy did not occur until approximately 4 months after argon laser pretreatment.

Histological studies of human tissue have shown stromal oedema around argon laser iridotomy sites 4-24 hours after treatment, with tissue necrosis and pigment dispersion<sup>32,222</sup>. During the next few days necrotic cells were seen among surviving collagen trabeculae, but inflammatory cell infiltration was minimal. Stromal thinning occurred as early as 17 days following treatment<sup>32</sup>, and this progressed over the

next 3-4 months. The observation of progressive stromal thinning may explain why some argon laser iridotomies progressively enlarge over a period of months<sup>223</sup>. The pigment epithelium was relatively spared in areas of partial thickness iris burns<sup>32</sup>. By 5 months - 2 years following treatment some degree of reparative fibrosis was seen<sup>32,222</sup>.

Animal studies of argon laser iridotomy produced similar results. Iridotomies in rabbits and cynomolgus monkeys showed stromal oedema and necrosis during the first few weeks after treatment, followed by stromal atrophy 3 months after treatment<sup>184</sup>.

The 4-6 week delay period used in our study to allow stromal atrophy to occur was probably insufficient. After initial resolution of stromal oedema, atrophy of collagen trabeculae proceeded more slowly. A delay period of 4 months might have been more satisfactory. However undue delay in creating a patent iridotomy increases the risk of goniosynechiae formation, or the occurrence of acute angle closure glaucoma. We have therefore chosen not to repeat the study using a longer delay period.

Considerable pigment dispersion occurred at the argon laser pretreatment site during Nd:YAG laser iridotomy. Migration and proliferation of pigment epithelium occurs several weeks following argon laser iridotomy<sup>184</sup>. It is likely that the pigment epithelium was loosely adherent to the overlying atrophic stroma at pretreated sites. The shock wave produced by Nd:YAG laser photodisruption may have dislodged loosely attached pigment cells.

Histological studies of Nd:YAG laser iridotomies in humans have shown minimal disruption of surrounding tissues<sup>166,167</sup>. Immediately following Nd:YAG laser iridotomy a very localised area of stromal necrosis and blood vessel disruption was seen. Pigment epithelium disruption occurred over a slightly larger area<sup>166</sup>.

The findings in Dutch-belted pigmented rabbits were similar, although a wider area of pigment epithelium loss occurred at the time of treatment <sup>169</sup>. The iridotomies remained patent, with no inflammatory or fibrotic reaction <sup>169</sup>. Among groups of pigmented and albino rabbits Nd:YAG laser iridotomy resulted in localised stromal and pigment epithelium disruption soon after treatment. Virtually no stromal oedema or inflammation developed, and there was no subsequent stromal atrophy or fibrosis <sup>170</sup>. However in cynomolgus monkeys large areas of pigment epithelium were disrupted by Nd:YAG laser iridotomy, and iridotomy closure occurred 3-4 weeks later, by migration and proliferation of pigment cells <sup>110,168</sup>.

We found no significant pigment epithelium loss beyond the iridotomy site following primary Nd:YAG laser iridotomy. It would appear that in humans the pigment epithelium is normally tightly bound to the overlying stroma, and disruption is very localised during Nd:YAG laser iridotomy. The pigment dispersion which occurred at the time of Nd:YAG laser iridotomy in argon laser pretreated sites was probably due to the loose attachment of unhealthy pigment epithelium to the overlying stroma at this site, rather than a primary effect of Nd:YAG laser photodisruption.

The inferior part of the trabecular meshwork was more heavily pigmented in argon laser pretreated eyes than primary Nd:YAG laser iridotomy eyes 6 months following treatment. However increased trabecular meshwork pigmentation did not appear to affect glaucoma control. Argon laser iridotomy in the cynomolgus monkey has been found to cause increased pigmentation of the inferior part of the trabecular meshwork soon after treatment <sup>178</sup>. Histologically, the pigment was present both extracellularly, and within giant vacuoles in the juxtacanalicular endothelial cells of the trabecular meshwork. One year

after iridotomy pigmentation was minimal, and no permanent structural trabecular meshwork damage was detected<sup>178</sup>. It would appear that pigment released from the iris at the time of iridotomy is efficiently cleared by bulk aqueous flow, and phagocytosis at the trabecular meshwork<sup>178</sup>. While there has been concern that pigment deposition in an already compromised glaucomatous trabecular meshwork might further reduce outflow facility, Pollack found that outflow facility increased following argon laser iridotomy in a group of chronic angle closure glaucoma patients<sup>184</sup>.

We found that iris bleeding occurred less frequently at the time of argon laser pretreated Nd:YAG laser iridotomies than primary Nd:YAG laser iridotomies. However the difference was not statistically significant, and iris bleeding produced no demonstrable adverse effects when it did occur. Previous studies have produced conflicting results. Zborskwi found no iris bleeding in 16 eyes treated with argon laser immediately prior to Nd:YAG laser iridotomy<sup>221</sup>. However Robin and Pollack reported iris bleeding following Nd:YAG laser iridotomy at failed argon laser iridotomy sites in 11 of 33 eyes<sup>219</sup>, and Drake reported one case of profuse iris bleeding when a Nd:YAG laser iridotomy was performed immediately following argon laser pretreatment<sup>224</sup>.

Our study has failed to demonstrate any beneficial effect of argon laser pretreatment 4-6 weeks prior to Nd:YAG laser iridotomy. Argon laser pretreatment resulted in a significant increase in the total amount of Nd:YAG laser energy required to produce an iridotomy. Considerable pigment dispersion occurred at the time of argon laser pretreated Nd:YAG laser iridotomy. Argon laser pretreatment had no effect on visual acuity or glaucoma outcome, after a mean follow up period of 9.4 months.

## CHAPTER 9

### **Nd:YAG LASER IRIDOTOMY IN CHINESE PATIENTS: A COMPARISON OF Nd:YAG AND ARGON LASER IRIDOTOMY IN CAUCASIAN AND CHINESE EYES**

#### **9.1 SUMMARY**

A retrospective assessment of clinical experience with argon laser iridotomy and Nd:YAG laser iridotomy in Singapore and in Edinburgh was performed.

The case records of:

16 Chinese patients treated by argon laser iridotomy

11 Caucasian patients treated by argon laser iridotomy

15 Chinese patients treated by Nd:YAG laser iridotomy

14 Caucasian patients treated by Nd:YAG laser iridotomy

were reviewed.

Argon laser iridotomy appeared to be more satisfactory in Chinese patients than in Caucasian patients. Conversely Nd:YAG laser iridotomy appeared to be more satisfactory in Caucasian patients than in Chinese patients. Quantification of the laser energy used in these treatments was not possible due to differences in iridotomy technique in Singapore and in Edinburgh. However qualitative differences in tissue responses to argon and Q-switched Nd:YAG laser energy which appeared to be dependent on racial differences in iris structure were observed. Further controlled studies of iridotomy techniques in Chinese patients are warranted.

## 9.2 INTRODUCTION

Light energy has been used to produce iridotomies in two ways - thermal damage due to tissue absorption of light energy, and mechanical disruption due to the rapid expansion of plasmas produced by very short duration laser pulses<sup>35,36,140,147,148</sup>. Thermal destruction has been produced using xenon arc light<sup>26</sup>, ruby laser<sup>27,28,185</sup>, argon laser<sup>1</sup>, dye laser<sup>15,34,218</sup>, krypton laser<sup>225</sup> and free running Nd:YAG laser energy<sup>189,191</sup>. Thermal absorption is dependent on tissue pigmentation<sup>35,36</sup>. Laser energy within the visible spectrum, such as argon blue-green, is absorbed by melanin. The more heavily pigmented a tissue, the greater the energy uptake. Irises in pigmented races may therefore be expected to absorb laser energy readily, whereas lightly pigmented irises in Caucasians may absorb laser energy less well. Several workers have commented that lightly pigmented irises are particularly difficult to treat using the argon laser<sup>12,23,30,105,121,141-144</sup>.

Very short duration laser pulses focussed over a small area produce a very high irradiation, resulting in the stripping of electrons from atoms and "plasma" formation. Rapid expansion of the plasma results in a mechanical shock wave, producing mechanical disruption of adjacent tissue<sup>35,36,140,147,148</sup>. Photodisruption has been produced using the Q-switched ruby laser<sup>37,188</sup>, and Nd:YAG laser<sup>2</sup>. Photodisruption is independent of tissue absorption and therefore of tissue pigmentation<sup>35,36</sup>. The effects of photodisruptive energy are dependent on the mechanical properties of the tissue being treated rather than its colour. The relatively delicate irises found of Caucasians may be readily penetrated using photodisruption<sup>10,11,13,22,23,224</sup>. However clinical experience in Singapore has indicated that the thicker, tougher irises of Chinese patients may be more difficult to penetrate using photodisruptive laser energy.



In order to evaluate the relative merits of thermal iridotomy and photodisruptive iridotomy in Chinese and Caucasian eyes a retrospective assessment of clinical experience with argon laser iridotomy and Q-switched Nd:YAG laser iridotomy in Singapore and in Edinburgh was performed.

### **9.3 MATERIALS AND METHODS**

In November 1987 the case records of the 56 patients most recently treated by Nd:YAG laser iridotomy or argon laser iridotomy in Edinburgh and in Singapore were reviewed. A relatively small number of cases was available as a Nd:YAG laser had only recently been purchased in Edinburgh and in Singapore. In addition few cases of argon laser iridotomy had been performed in Edinburgh. Iridotomies performed in eyes with acute angle closure glaucoma were excluded. In patients who had had bilateral iridotomies only one eye, chosen by tossing a coin, was used for statistical analysis.

The following information was obtained from the records of each patient :

Patient data : race, age, sex, diagnosis and indication for iridotomy, iris colour.

Treatment parameters : type of laser used, power setting, spot size, pulse duration, number of pulses used, qualitative assessment of iris tissue reaction to laser energy.

Treatment result : production of a patent iridotomy at the first or subsequent treatment sessions, and the occurrence or absence of late iridotomy closure.

### **9.3.1 ARGON LASER TREATMENT**

All argon laser treatments were performed using a Coherent 900 blue-green argon laser, and Abraham 66 dioptre iridotomy contact lens. A series of burns were used to "chip" through the iris until penetration was achieved. Further enlarging burns were applied as necessary until an iridotomy of 200 - 300 $\mu$  diameter was obtained.

All treatments in Singapore were performed by one surgeon (ASML). A "short" duration (0.05 or 0.1 second), small diameter (50 $\mu$ ) burn technique was used. One iridotomy was produced in each eye.

Argon laser iridotomies were performed by a variety of operators in Edinburgh. A "long" duration ( $\geq$  0.1 second), large diameter (50-200 $\mu$ ) burn technique was used. Two iridotomies were produced in each eye, in order to reduce the risk of acute angle closure glaucoma if one iridotomy reclosed.

The total energy, in Joules, used in a treatment was calculated by multiplying the power setting, in watts, for each pulse by the time duration, in seconds, of that pulse, and summing these values. When more than one spot size or time duration were used in a treatment, the most frequently used spot size and time duration were recorded.

The argon laser in Edinburgh was calibrated and found to be 84% efficient at the 1 watt setting. It was not possible to arrange calibration of the argon laser used in Singapore.

### **9.3.2 Nd:YAG LASER TREATMENT**

A Zeiss Visulas Nd:YAG laser and Zeiss anterior segment contact lens were used to treat patients in Edinburgh. A Coherent 7970 Nd:YAG laser and Abraham Nd:YAG iridotomy contact lens were used to treat patients in Singapore. Both laser systems produced a pulse duration of 7 nanoseconds, and a spot diameter of 30 $\mu$ m. All treatments in Singapore

were performed by one surgeon (ASML), and all treatments in Edinburgh were performed by one surgeon (BWF). The lasers were self calibrating and had recently undergone factory testing.

Single 5 -7 mJ pulses were delivered to the treatment site until penetration was achieved. An iris crypt was used where available. Further pulses were used to enlarge the iridotomy to 200 - 300 $\mu$  diameter when necessary. One iridotomy was produced in each eye. The total energy used in treatment was obtained by summing the energy value of each pulse.

#### 9.4 RESULTS

The number of patients in each group and the age and sex distribution are given in Table 9.1. The groups were similar in composition.

	Argon laser		Nd:YAG Laser	
	Chinese	Caucasian	Chinese	Caucasian
Number patients	16	11	15	14
Age	62.6 $\pm$ 7.9	65.8 $\pm$ 15.8	61.9 $\pm$ 9.1	69.5 $\pm$ 11.4
Male : female	7 : 9	4 : 7	8 : 7	8 : 6

**TABLE 9.1**  
**Argon and Nd:YAG laser iridotomy in Chinese and**  
**Caucasian eyes: Patient groups**

The indications for laser iridotomy in each group are shown in Table 9.2.

	Argon laser		Nd:YAG Laser	
	Chinese	Caucasian	Chinese	Caucasian
Number patients	16	11	15	14
Fellow eye or narrow angle	13	5	4	14
Chronic ACG	5	8	0	0
Other	0	1	3	0

**TABLE 9.2**

**Argon and Nd:YAG laser iridotomy in Chinese and Caucasian eyes: Indications for laser iridotomy in each group.**

"Other" refers to patients with iris bombé due to extensive posterior synechiae formation.

All Nd:YAG laser iridotomies performed in Caucasians were in the fellow eye of acute angle closure glaucoma patients.

The distribution of iris colour for each group is shown in Table 9.3.

	Argon laser		Nd:YAG laser	
	Chinese	Caucasian	Chinese	Caucasian
Number patients	16	11	15	14
Dark brown	16	0	15	0
Light brown	0	5	0	5
Grey	0	6	0	9

**TABLE 9.3**

**Argon and Nd:YAG laser iridotomy in Chinese and Caucasian eyes : Iris colour**

Chinese irises are heavily pigmented, and are thicker than Caucasian irises.

#### 9.4.1 ARGON LASER IRIDOTOMY TREATMENT RESULTS.

The argon laser treatment parameters used are shown in Table 9.4.

	Chinese	Caucasian
Number patients	16	11
Spot size $\leq 50\mu$	16 (100%)	6 (55%)
Burn duration $\leq 0.05s$	11 (69%)	0
$\geq 0.1s$	5 (31%)	11 (100%)
More than one site attempted	0	8 (73%)
Mean max power used, watts	1.3 $\pm$ 0.2	1.5 $\pm$ 0.9

**TABLE 9.4**  
**Argon laser iridotomy in Chinese and Caucasian eyes:**  
**treatment parameters**

A smaller spot size and shorter duration burn technique was used in Chinese eyes. In 8 of the 11 Caucasian eyes treated, more than one treatment site was used. The unit's policy during this period was to perform 2 argon laser iridotomies in each eye, as the reported incidence of argon laser iridotomy reclosure was high<sup>22,23,30</sup>.

The failure rate for producing a patent iridotomy at the first and at subsequent treatment sessions, and the reclosure rate, are shown in Table 9.5.

	Chinese	Caucasian
Number patients	16	11
Failure to produce patency at 1st session	3 (19%)	5 (45%)
Failure to produce patency at subsequent sessions	2 (12.5%)	4 (36%)
Reclosure	0	0

**TABLE 9.5**  
**Argon laser iridotomy in Chinese and Caucasian eyes :**  
**patency and reclosure rates**

Among Caucasians patency was obtained at the first treatment session in only 6 of 11 eyes, compared to 13 of 15 Chinese eyes. In Caucasians long duration, large diameter burns resulted in superficial iris damage. Laser absorption was probably reduced due to light iris pigmentation. Iris penetration was difficult to achieve in these circumstances.

In Chinese eyes each short duration, small diameter burn produced a well defined "punched out" area of iris damage. Repeated burns easily penetrated the iris, and subsequent burns were then used to enlarge the iris opening. Significant iris charring did not occur in any eye. Pigment dispersion occurred at the moment of full thickness iris penetration, but was otherwise minimal.

There were no cases of iridotomy reclosure during the follow up period of the study.

The number of laser pulses and total laser energy used in the treatment of each group are shown in Table 9.6.

	Chinese	Caucasian
Number pulses (range)	64.6±45.3 (11-160)	178.5±174.2 (5-540)
Total energy, Joules (Range)	5.4±4.5 (1.65-18.9)	55.7±88.3 (3.1-272.2)

**TABLE 9.6**  
**Argon laser iridotomy in Chinese and Caucasian eyes:**  
**Number of laser pulses and total energy used**

The number of argon laser pulses used in treatment was fewer in Chinese eyes than in Caucasian eyes (unpaired Student t test  $p < 0.02$ ). The total argon laser energy used in treatment was less in Chinese eyes than in Caucasian eyes (unpaired Student t test  $p < 0.05$ ). However different techniques were used in the two groups. Two iridotomies were performed

in 8 of the 11 Caucasian patients, increasing the total laser energy used. The long duration, large diameter burns used in Caucasians were probably less efficient in penetrating the iris than the short duration small diameter burns used in Chinese patients. Quantitative comparison of argon laser iridotomy in Chinese and Caucasian patients was therefore not valid.

#### 9.4.2 Nd:YAG LASER IRIDOTOMY TREATMENT RESULTS.

The treatment parameters used for Nd:YAG laser iridotomy were identical in Chinese and Caucasian eyes : 30 $\mu$  spot diameter, 7 ns pulse duration, 5 -7 mJ energy per pulse. Only one site was treated in each eye.

The failure rate for producing a patent iridotomy at the first and at subsequent treatment sessions, and the reclosure rate, are shown in Table 9.7.

	Chinese	Caucasian
Number patients	15	14
Failure to produce patency at 1st session	2 (13%)	0
Failure to subsequently produce patency	-	0
Reclosure	0	0

**TABLE 9.7**  
**Nd:YAG laser iridotomy in Chinese and Caucasian eyes:**  
**patency and reclosure rates**

Among Caucasians patency was obtained at the first treatment session in every eye. The iris was readily penetrated, especially if treatment was applied in an iris crypt. The iris tissue appeared to be very delicate, and was easily "cut" by Nd:YAG laser pulses. In contrast patency was not obtained at the initial treatment session in two Chinese eyes, and these were subsequently treated using the argon laser. Chinese

irises were difficult to penetrate. The stroma was thick and heavily pigmented. Initial laser pulses caused profuse pigment dispersion from the stroma which impaired subsequent visualisation of the iris, and may have interfered with the delivery of laser energy to the iris plane. While the Chinese cases included in this study were treated by ASML, the subsequent clinical experience of BWF in treating Chinese patients has been similar.

There were no cases of iridotomy reclosure during the follow up period of the study.

The number of laser pulses and total laser energy used in the treatment of each group are shown in Table 9.8.

	Chinese	Caucasian
Number pulses (range)	15.4±28.7 (1-104)	3.4±2.4 (1-9)
Total energy, Joules (Range)	0.0588±0.0537 0.015-0.196	0.0293±0.0219 0.0049-0.0729

**TABLE 9.8**  
**Nd:YAG laser iridotomy in Chinese and Caucasian eyes:**  
**Number of laser pulses and total energy used**

The number of Nd:YAG laser pulses used in treatment was not significantly different in Chinese and Caucasian eyes. The total Nd:YAG laser energy used in treatment was greater in Chinese eyes than in Caucasian eyes, but the difference was not statistically significant (unpaired Student t test  $p=0.069$ ).



## 9.5 DISCUSSION

Several reports describe special difficulties in performing argon laser iridotomies in blue irises<sup>12,23,105,121,132,141-144,213</sup>. Variations in technique have been suggested to overcome these difficulties, such as the use of a thermally induced bubble on the surface of the iris to focus laser energy<sup>141</sup>, the use of green filtered argon laser light<sup>143</sup>, and the use of an initial "contraction" burn<sup>142</sup>.

Our study suggests that argon laser iridotomy may be more difficult to perform in Caucasian eyes than Chinese eyes, although variation in iridotomy technique made quantitative analysis unreliable. Laser treatment parameters have been found to be critical when performing argon laser iridotomies in heavily pigmented irises. Initial experience using relatively long duration (0.1 seconds) laser burns seemed to indicate that these irises were particularly difficult to treat<sup>213</sup>. However several workers then found that high power, short duration (0.02-0.05 seconds) laser burns easily penetrated heavily pigmented irises<sup>12,105,112,132,226</sup>. In Singapore the transition from a "long burn" to a "short burn" technique led to a marked reduction in the total laser energy needed in treatment<sup>227</sup>.

Q switched Nd:YAG laser iridotomy is independent of iris pigmentation, but is dependent on the mechanical properties of the iris. Nd:YAG laser iridotomies have been found to be more easily produced in lightly pigmented irises than in heavily pigmented irises<sup>11,224</sup>. Reported Nd:YAG laser energy levels used in Saudi Arabia<sup>137</sup>, Israel<sup>14</sup>, Alaska<sup>111</sup> and China<sup>228</sup> have in general been higher than those used in North America<sup>10,11,22,23</sup>.

We observed that Nd:YAG laser iridotomy appeared to be more difficult to perform in Chinese eyes than in Caucasian eyes, although no statistically significant difference in the mean total laser energy used

in treatment was found. While patency was easily achieved at the first treatment session in every Caucasian, patency was not achieved in two Chinese patients.

Racial differences in the structure of the iris are significant, and the findings of studies carried out in one race do not necessarily apply to other races. The iris in Chinese eyes is more heavily pigmented and thicker than in Caucasian eyes, and appears to be more difficult to cut using the Q-switched Nd:YAG laser. While comparative studies of Q-switched Nd:YAG laser iridotomy and argon laser iridotomy in Caucasians have favoured Nd:YAG laser iridotomy <sup>10,13,22,23</sup>, controlled studies of laser iridotomy techniques in non-caucasian races are needed.

## CHAPTER 10

### DISCUSSION AND CONCLUSION

What is the place of Nd:YAG laser iridotomy in the management of angle closure glaucoma? Does Nd:YAG laser iridotomy compare favourably with operative peripheral iridectomy, a well established, safe and effective form of treatment <sup>25,43,44,86</sup> ?

#### 10.1 IS Nd:YAG LASER IRIDOTOMY AS EFFECTIVE AS OPERATIVE PERIPHERAL IRIDECTOMY ?

##### 10.1.1 ACUTE ANGLE CLOSURE GLAUCOMA

We have observed two patients who developed a recurrence of acute angle closure glaucoma despite the presence of a small patent iridotomy. Subsequent trabeculectomy or peripheral iridectomy prevented further attacks. Similar cases have been reported previously <sup>15,80,106</sup>. In every case the diameter of the iridotomy has been less than 150 $\mu$ . Theoretically an iridotomy of diameter 15 $\mu$  ought to prevent iris bombé <sup>21,214</sup>. However dilating the pupil may reduce the area of an iridotomy by a factor of 5 (see page 143). In clinical practice a diameter of 150–200 $\mu$  has been found to be necessary to prevent acute angle closure glaucoma <sup>21</sup>. Provocation tests have not proved to be helpful in detecting eyes at risk of acute angle closure glaucoma following iridotomy <sup>15,21,80</sup>.

In a non-randomised study of Nd:YAG laser iridotomy for acute angle closure glaucoma we found 89% of eyes remained normotensive without medication on follow up. However, selection of cases was biased towards milder forms of glaucoma. Gray has reported that 50%

of eyes remained normotensive without medication following Nd:YAG laser iridotomy for acute angle closure glaucoma<sup>80</sup>. Previous studies have shown that approximately 70% of eyes remain normotensive without medication following peripheral iridectomy for acute angle closure glaucoma<sup>25,43,46,86,87</sup>. We are currently performing a prospective randomised comparison of Nd:YAG laser iridotomy and operative peripheral iridectomy in a consecutive series of 250 cases presenting with acute angle closure glaucoma.

### **10.1.2 FELLOW EYES**

Operative peripheral iridectomy is a very effective means of preventing acute angle closure glaucoma in fellow eyes<sup>25,42,46,86,87</sup>. We have observed acute angle closure glaucoma in a fellow eye despite the presence of a small patent Nd:YAG laser iridotomy<sup>21</sup>. To our knowledge acute angle closure glaucoma in a fellow eye with a patent Nd:YAG laser iridotomy has not been described previously. Following enlargement of the iridotomy a pilocarpine/phenylephrine provocation test and a cyclopentolate 1% provocation test were negative, and the eye has remained normotensive during a follow up period of 8 months. Again, it would appear that an iridotomy must have a diameter of at least 150-200 $\mu$  in order to prevent iris bombé and subsequent acute angle closure glaucoma.

In a randomised prospective comparison of Nd:YAG laser iridotomy and operative peripheral iridectomy in the fellow eyes of 52 patients we found no difference in intraocular pressure control between the two groups after a mean follow up period of 11.8 months.

### **10.1.3 CHRONIC ANGLE CLOSURE GLAUCOMA**

Is Nd:YAG laser iridotomy as effective as operative peripheral iridectomy in the treatment of chronic angle closure glaucoma? We found that 83% of eyes with chronic angle closure glaucoma had normal intraocular pressure, with topical medication if necessary, following Nd:YAG laser iridotomy. This compared with figures of 76-100% reported following operative peripheral iridectomy<sup>49,52,89,95</sup>, 63-92% following argon laser iridotomy<sup>33,95,139</sup> and 90% following Nd:YAG laser iridotomy<sup>137</sup> (see Table 1.14). We found that improved intraocular pressure control and gonioscopic widening of the angle failed to occur in two eyes with a very small iridotomy. Our observations confirm those of Wishart, who found that repeat iridotomy resulted in a widening of the angle in four eyes with a small iridotomy<sup>15</sup>.

Nd:YAG laser iridotomy appears to be as effective as operative peripheral iridectomy in the treatment of chronic angle closure glaucoma, provided the iridotomy is at least 150-200 $\mu$  in diameter. However the number of patients in our study was small and a controlled comparison of Nd:YAG laser iridotomy and operative peripheral iridectomy has not been undertaken.

## **10.2 IS Nd:YAG LASER IRIDOTOMY AS SAFE AS OPERATIVE PERIPHERAL IRIDECTOMY?**

### **10.2.1 LONG TERM VISUAL ACUITY OUTCOME**

We found that 4/26 (15%) of fellow eyes treated with Nd:YAG laser iridotomy lost two or more lines of visual acuity due to cataract development during a mean follow up period of 11.8 months, compared to 0/26 (0%) of eyes treated by operative peripheral iridectomy. These

findings suggest that Nd:YAG laser iridotomy does not result in a lower incidence of visual acuity loss due to cataract development than operative peripheral iridectomy. Previous studies have reported a 3-10% incidence of visual acuity loss due to cataract development following Nd:YAG laser iridotomy in fellow eyes <sup>11,137</sup>, compared to a 1-33% incidence following peripheral iridectomy (see Table 1.11).

Acute angle closure glaucoma eyes developed cataract more frequently than fellow eyes. We found 1/19 (5%) of eyes treated by Nd:YAG laser iridotomy, 3/15 (20%) of eyes treated by operative peripheral iridectomy, and 6/20 (30%) of eyes treated by trabeculectomy lost two or more lines of visual acuity due to cataract development or progression. The number of patients in our study was too small to reliably assess whether Nd:YAG laser iridotomy results in a lower incidence of cataract development than operative peripheral iridectomy. A larger randomised comparison of Nd:YAG laser iridotomy and operative peripheral iridectomy in the treatment of acute angle closure glaucoma is now in progress. Our finding of a high rate of cataract development following drainage surgery confirm the results of previous studies <sup>45</sup> (see Table 1.10).

## **10.2.2 OPERATIVE AND EARLY POSTOPERATIVE COMPLICATIONS**

### **10.2.2.1 CORNEA**

Corneal endothelium damage following Nd:YAG laser iridotomy is thought to be caused by high velocity particles projected from the treatment site by plasma rapid expansion <sup>7</sup>. Our findings support this hypothesis. In 42% of fellow eyes treated by Nd:YAG laser iridotomy focal granularity of the corneal endothelium was evident by slit lamp

examination 24 hours following treatment. In a further 15% of eyes these changes were more pronounced, and accompanied by overlying corneal oedema. The mean total laser energy used in treatment was higher in patients who developed corneal changes ( $30.95 \pm 21.6$  mJ), compared to those who did not ( $18.2 \pm 19.7$  mJ), although the difference was not statistically significant.

We did not find a significant decrease in central corneal endothelial cell density following Nd:YAG laser iridotomy or operative peripheral iridectomy. Other studies have also failed to demonstrate central corneal endothelial cell density reduction following Nd:YAG laser iridotomy<sup>8,10,115</sup> or operative peripheral iridectomy<sup>8,82,197</sup>. In contrast one study found a small, but significant, decrease in central corneal endothelial cell density following argon laser iridotomy<sup>10</sup>.

While bullous keratopathy has been reported following argon laser iridotomy<sup>24</sup>, this has not occurred following Nd:YAG laser iridotomy. Focal corneal endothelium changes following Nd:YAG laser iridotomy do not appear to be of long term significance.

#### **10.2.2.2 HYPHAEMA**

We found 58% of fellow eyes developed slight iris bleeding during Nd:YAG laser iridotomy, compared to 27% of eyes during operative peripheral iridectomy ( $\chi^2$  test with Yate's correction  $p < 0.05$ ). Other workers have reported an incidence of 15–90% iris bleeding following Nd:YAG laser iridotomy (see Table 1.5) Iris bleeding was transitory and produced no detectable adverse effects.

#### **10.2.2.3 EARLY POST TREATMENT INTRAOCULAR PRESSURE ELEVATION**

A transient elevation of intraocular pressure occurred in fellow

eyes during the first three hours after treatment in 27% of cases treated by Nd:YAG laser iridotomy and 8% of cases treated by operative peripheral iridectomy. The mean intraocular pressure of the laser treated group was significantly higher than that of the surgical group one hour and three hours following treatment. Early post treatment intraocular pressure elevation has been reported in 20-40% of eyes following argon laser iridotomy or Nd:YAG laser iridotomy (see Table 1.6)

It has been postulated that raised aqueous prostaglandin levels following iridotomy may mediate raised intraocular pressure<sup>176</sup>. However, indomethacin does not prevent post iridotomy intraocular pressure elevation in rabbits<sup>177</sup>. It is more likely that particulate debris and plasma proteins released at the time of iridotomy result in transient mechanical blockage of trabecular meshwork outflow<sup>177,178</sup>. The absence of intraocular pressure elevation following operative peripheral iridectomy may be due to the relative absence of particulate debris in the aqueous following the procedure. Iris tissue is physically removed from the eye during operative peripheral iridectomy, but not during Nd:YAG laser iridotomy.

Our findings, and those of others (see Table 1.6) indicate that raised intraocular pressure commonly occurs following Nd:YAG laser iridotomy unless preventive treatment is given. Pretreatment with pilocarpine<sup>199</sup>, timolol<sup>200</sup>, or apraclonidine<sup>201</sup> lowers the incidence of post laser intraocular pressure elevation.

#### **10.2.2.4 FOCAL LENS OPACITIES**

While focal lens opacities have been reported following Nd:YAG laser iridotomy<sup>14-17,107,122</sup>, these opacities have not progressed, and have not resulted in reduced visual acuity.



We have observed nuclear cataract development with loss of visual acuity in two eyes with focal lens opacities at the Nd:YAG laser iridotomy site. The first was a fellow eye in which visual acuity fell from 6/9 to 6/12 due to nuclear cataract development. The second was an eye treated by Nd:YAG laser iridotomy following a diagnosis of "narrow angle glaucoma". The treatment site was placed too close to the pupil and a focal lens opacity developed. Visual acuity fell from 6/9 to perception of light during a 10 month follow up period, due to the development of a very dense nuclear cataract. It is likely that cataract development in this case was caused by the Nd:YAG laser iridotomy procedure.

We also found focal lens opacities at operative peripheral iridectomy sites. However these opacities did not progress and did not result in reduced visual acuity.

#### **10.2.2.5 IRITIS**

We found iritis in 42% of fellow eyes following operative peripheral iridectomy, and 23% of fellow eyes following Nd:YAG laser iridotomy ( $\chi^2$  test with Yate's correction, no significant difference, (see Table 4.3, page 81). Other workers have reported a 3-12% incidence of iritis following Nd:YAG laser iridotomy, and a 7% incidence following operative peripheral iridectomy (see Table 1.8). Definitions of significant iritis vary. While iritis tends to be of mild severity following Nd:YAG laser iridotomy and operative peripheral iridectomy, and of little significance per se, its presence may contribute to posterior synechiae development.

#### **10.2.2.6 POSTERIOR SYNECHIAE**

We found posterior synechiae in 3/26 (12%) of fellow eyes

following either Nd:YAG laser iridotomy or operative peripheral iridectomy (see page 87,88). The prevalence of posterior synechiae was higher among acute angle closure glaucoma eyes: 42% of eyes treated by Nd:YAG laser iridotomy, 27% of eyes treated by operative peripheral iridectomy, and 40% of eyes treated by trabeculectomy (see page 116).

Previous studies have reported a similar prevalence of posterior synechiae following peripheral iridectomy for acute angle closure glaucoma<sup>87,119</sup>, and have also found a higher prevalence of posterior synechiae among acute angle closure glaucoma eyes than fellow eyes<sup>87</sup>. We found a higher prevalence of posterior synechiae following Nd:YAG laser iridotomy than has been reported previously<sup>23</sup>. However, in our study pupil dilation was carried out in order to detect posterior synechiae. Previous studies in which this was not done may have under-reported the true prevalence of posterior synechiae<sup>23</sup>.

### **10.3 WHAT IS THE OPTIMAL METHOD OF PRODUCING A Nd:YAG LASER IRIDOTOMY ?**

We have found that argon laser pre treatment of the iris stroma does not facilitate Nd:YAG laser iridotomy (see chapter 8). Significantly more Nd:YAG laser energy was needed to produce an iridotomy in an argon laser pre treated site than in a previously untreated iris (see Table 8.2). Pigment dispersion from the pigment epithelium layer of the iris was more marked following Nd:YAG laser iridotomy in an argon laser pre treated site, than following primary Nd:YAG laser iridotomy (see page 177).

We have found that an iridotomy must be at least 150–200 $\mu$  in diameter in order to reliably prevent the development of acute angle closure glaucoma (see chapter 6).

The production of larger iridotomies requires more laser energy than the production of small iridotomies. We have found that high laser energy levels are more likely to produce focal corneal endothelium damage than low levels in both acute angle closure glaucoma eyes (see page 110), and fellow eyes (see page 86). Our initial experience with the "linear incision" technique devised by Wise using a 103 dioptre contact lens<sup>12</sup> indicates that multiple low energy laser pulses may cause less endothelial damage than a small number of higher energy pulses. The production of an iridotomy of defined size is also more readily achieved using the "linear incision" technique. A randomised comparison of this treatment with operative peripheral iridectomy is currently in progress.

Without preventive treatment approximately 30% of fellow eyes develop transient intraocular pressure elevation following Nd:YAG laser iridotomy (see page 85). Pretreatment with acetazolamide (see page 93), Pilocarpine<sup>199</sup>, Timolol<sup>200</sup>, or apraclonidine<sup>201</sup>, greatly reduces the incidence of this complication.

We found the incidence of iritis and posterior synechiae was similar following Nd:YAG laser iridotomy and operative peripheral iridectomy in fellow eyes (see Tables 4.3 and 4.4). Topical steroid treatment should therefore be used following Nd:YAG laser iridotomy. A mydriatic may be used providing an iridotomy of adequate size has been produced. G. Phenylephrine 10% has been found to carry minimal risk of provoking acute angle closure glaucoma when used following operative peripheral iridectomy<sup>198</sup>, and might therefore be appropriate following Nd:YAG laser iridotomy.

Racial differences in the structure of the iris influence the ease with which Nd:YAG laser iridotomy may be performed. We found that higher mean energy levels were used to produce Nd:YAG laser

iridotomies in Chinese eyes than in Caucasian eyes, although the difference was not statistically significant (see Table 9.6). While Nd:YAG laser iridotomy has been shown to be more satisfactory than argon laser iridotomy in Caucasians <sup>10,13,22,23</sup>, this may not be the case in other races.

Nd:YAG laser iridotomy technique continues to improve. Our studies suggest that Nd:YAG laser iridotomy is as safe as operative peripheral iridectomy, and as effective provided a large enough iris opening is produced. However, Nd:YAG laser iridotomy has not been demonstrated to be safer than operative peripheral iridectomy and must be regarded as an invasive technique <sup>6</sup>, only undertaken when a well defined benefit from treatment may be anticipated.

## **PROJECTS CURRENTLY IN PROGRESS**

The following related projects are currently in progress.

1. A randomised prospective comparison of Nd:YAG laser iridotomy and operative peripheral iridectomy in the treatment of acute angle closure glaucoma.

A randomised prospective study comparing the long term visual acuity and glaucoma outcome of Nd:YAG laser iridotomy and operative peripheral iridectomy in acute angle closure glaucoma and fellow eyes began in July 1989. "Linear incision" low energy laser treatment is being used, with a Wise 103 dioptre contact lens. To date, 93 patients have been entered into the study. We plan to recruit a total of 200 patients and follow them for 5 years. We anticipate that this study will further define the long term visual acuity and glaucoma outcome following Nd:YAG laser iridotomy.

2. Corneal thickness and endothelial cell density

A study is in progress in which a group of 20 patients presenting with acute angle closure glaucoma have hourly intraocular pressure and corneal thickness measurements made during the period of initial medical control of the acute attack. Frequent measurements continue until the rate of change of corneal thickness has become low, and then 12 hourly, followed by daily readings are obtained.

We plan to enrol 20 patients into the study, and correlate the rate of resolution of corneal oedema with factors such as the duration of the acute attack of angle closure glaucoma, patient age and central endothelial cell density.

## DEVELOPMENTS IN THE LITERATURE

Several groups of workers are studying Nd:YAG laser iridotomy techniques and three recently published papers are of special interest in the context of our research.

Panek et al. have studied changes in the endothelial cell density of both the central cornea and the cornea overlying the Nd:YAG laser iridotomy treatment site of 18 patients<sup>230</sup>. While there was no significant change in central endothelial cell density, a small, but significant decrease (3.8% decrease,  $p=0.04$ ) of endothelial cell density overlying the iridotomy site was found 1-8 weeks after treatment. These findings are consistent with our own studies (Table 4.5) and those of other workers<sup>8,10,115</sup>. Nd:YAG laser iridotomy may result in some focal corneal endothelial cell damage overlying the treatment site, but does not cause a significant decrease in central corneal endothelial cell density.

Prum et al. have made videographic studies of argon and Nd:YAG laser iridotomy techniques in cadaver eyes<sup>231</sup>. Argon laser burns caused mounding up of the iris pigment layer prior to iris penetration, an effect which was not seen during Nd:YAG laser iridotomy<sup>231</sup>. This observation is consistent with the iris pigment epithelium effects we have observed following argon laser pretreatment of the iris (see Tables 8.4 and 8.5). Argon laser burns appear to loosen the adherence of the iris pigment epithelium to the overlying iris stroma.

McGalliard and Wishart have reported the results of Nd:YAG laser iridotomy for chronic angle closure glaucoma in 73 eyes of 43 patients<sup>232</sup>. 69% of eyes with peripheral anterior synechiae had reduced intraocular pressure following iridotomy. There was no reduction of intraocular pressure in eyes without peripheral anterior synechiae. This study confirms our preliminary finding of a beneficial effect of

Nd:YAG laser iridotomy in some patients with chronic angle closure glaucoma (see chapter 7).

Several components of our research work have been reported recently. Background animal work in rabbits has confirmed that the Q-switched Nd:YAG laser produces only very localised effects on the retina and vitreous <sup>233</sup>. Data contained in chapters four <sup>234</sup>, five <sup>21</sup>, six <sup>235</sup>, and eight <sup>236</sup> of this thesis has been published. A further paper discussing the effect of pupil dilation on iridotomy area is in press.

## REFERENCES

1. Abraham RK, Miller GL: Outpatient argon laser iridectomy for angle closure glaucoma: a two year study.  
Trans Am Acad Ophthalmol Otolaryng 1975,**79**:529-538.
2. Frankhauser F, Roussel P, Steffen J, Van Der Zyphen E, Chrenkova A: Clinical studies on the efficiency of high power laser radiation upon some structures of the anterior segment of the eye. First experience of the treatment of some pathological conditions of the anterior segment of the human eye by means of a Q-switched laser system.  
Int Ophthalmol 1981,**3**:129-139.
3. Chandler PA: Narrow Angle Glaucoma  
A.M.A. Arch Ophthalmol 1952,**47**:695-716
4. Rivera AH, Brown RH, Anderson DR.  
Laser Iridotomy vs Surgical Iridectomy - Have the Indications Changed?  
Arch Ophthalmology 1985,**103**:1350-1354
5. Rich W.The economics of Nd-YAG laser treatment.  
Dev Ophthalmol 1987,**14**: 93-96
6. Spaeth GL. Laser Treatment is Invasive Surgery  
Ophthalmic Surgery 1988,**19**(7):463-464
7. Kerr-Muir MG, Sherrard ES.  
Damage to the corneal endothelium during Nd/YAG photodisruption.  
Brit J Ophthalmol 1985,**69**:77-85
8. Wishart PK, Sherrard ES, Nagasubramanian S, Kerr Muir MG, Hitchings RA. Corneal endothelial changes following short pulsed laser iridotomy and surgical iridectomy.  
Trans Ophthalmol Soc UK 1986,**105**:541-548
9. Canning CR, Capon MR, Sherrard ES, Kerr-Muir MG, Pearson R, Cooling R:  
Neodymium: YAG laser iridotomies short-term comparison with capsulotomies and long-term follow-up.  
Graefes Arch Clin Exp Ophthalmol 1988,**226**:49-54



10. Robin AL, Pollack IP. A comparison of neodymium: YAG and argon laser iridotomies.  
Ophthalmology 1984,**91**:1011-1016
11. Schwartz LW, Mosier MR, Spaeth GL, Wilson RP, Poryzees E. Neodymium-YAG laser iridotomies associated with closed or occludable angles.  
Am J Ophthalmol 1986,**102**:41-44
12. Wise JB. Low-energy linear-incision neodymium: YAG laser iridotomy versus linear-incision argon laser iridotomy. A prospective clinical investigation.  
Ophthalmology 1987,**94**:1531-1537
13. Del Priore LV, Robin AL, Pollack IP: Neodymium: YAG and argon laser iridotomy. Long-term follow-up in a prospective, randomized clinical trial.  
Ophthalmology 1988,**95**:1207-1211.
14. Naveh N, Zborwsky-Gutman L, Blumenthal M. Neodymium-YAG laser iridotomy in angle closure glaucoma: preliminary study.  
Brit J Ophthalmol 1987,**71**:257-261,
15. Wishart PK, Hitchings RA. Neodymium YAG and dye laser iridotomy—a comparative study.  
Trans Ophthalmol Soc UK 1986,**105**:521-540
16. Montgomery DMI, Dutton GN. Correspondence: Intralenticular haemorrhage complicating pulsed laser iridotomy.  
Brit J Ophthalmol 1987,**71**:484
17. Berger CM, Lee DA , Christensen RE: Anterior lens capsule perforation and zonular rupture after Nd:YAG laser iridotomy  
Am J Ophthalmol 1989,**107**:674-675
18. Curran EJ: A New Operation for Glaucoma Involving A New Principle In The Aetiology And Treatment of Chronic Primary Glaucoma.  
Archives Ophthalmol 1920,**49**:131-155
19. Curran EJ: Peripheral Iridotomy in Acute And Chronic Glaucoma: some results after 10 years duration. Anatomical classification of glaucoma.  
Transactions Ophthalmol Soc UK 1931,**51**:520-538

20. Gifford H: Peripheral Iridotomy (Curran) In The Treatment Of Glaucoma.  
Am J Ophthalmol 1921,**4**:889-894
21. Fleck BW, Fairley E, McGlynn C : A prospective comparison of Nd:YAG laser iridotomy and surgical peripheral iridectomy in the treatment of acute closed-angle. In Khoo CY et al eds. Proceedings of the XXVI International Congress of Ophthalmology, Amsterdam: Elsevier Science Publishers B.V.1991:852-858.
22. McAllister JA, Schwartz LW, Moster M, Spaeth GL: Laser peripheral iridectomy comparing Q-switched neodymium YAG with argon.  
Trans Ophthalmol Soc UK 1985,**104**: 67-69
23. Moster MR, Schwartz LW, Spaeth GL, Wilson RP, McAllister JA, Poryzees EM. Laser iridectomy. A controlled study comparing argon and neodymium:YAG.  
Ophthalmology 1986,**93**:20-24
24. Schwartz AL, Martin NF, Weber PA.  
Corneal Decompensation after Argon Laser Iridectomy.  
Arch Ophthalmol. 1988,**106**:1572-1574.
25. Playfair TJ, Watson PG. Management of Acute Primary Angle-Closure Glaucoma : A long term follow-up of the results of peripheral iridectomy used as an initial procedure.  
Brit J Ophthalmol 1979,**63**:17-22
26. Meyer-Schwickerath C. Erfahrungen mit der Lichtkoagulation der Netzhaut und der Iris  
Doc Ophthalmol 1956,**10**:119-131
27. Zweng HC, Flocks M, Kapney NS et al.  
Experimental laser photocoagulation.  
Am J Ophthalmol. 1964,**58**:353-362.
28. Perkins ES. Laser iridotomy for secondary glaucoma.  
Trans Ophthalmol Soc UK 1971,**91**:777-780.
29. Abraham RK, Munnerly C: Laser iridotomy- improved methodology with a new iridotomy lens.  
Ophthalmology 1979,**86**(Suppl):126.

30. Podos SM, Kels BD, Ritch R et al. Continuous wave argon laser iridectomy in angle-closure glaucoma. *Am J Ophthalmol.* 1979,**88**: 836-842.
31. Pollack IP, Patz A. Argon laser iridotomy: an experimental and clinical study. *Ophthalmic Surg* 1976,**7**(1):22-30.
32. Schwartz LW, Rodrigues MM, Spaeth GL et al. Argon laser iridotomy in the treatment of patients with primary angle-closure glaucoma or pupillary block glaucoma: A clinicopathologic study. *Ophthalmology* 1978,**85**:294-309.
33. Quigley HA. Long term follow up of laser iridotomy. *Ophthalmology* 1981,**88**:218-224.
34. Bass MS, Cleary CV, Perkins ES, Wheeler CB. Single treatment laser iridotomy *Brit J Ophthalmol* 1979,**63**:29-30
35. Marshall J. Lasers in ophthalmology: The basic principles. *Eye* 1988,**2**:S98-S112
36. Peyman GA, Raichand M, Zeimer RC. Ocular effects of various laser wavelengths. *Survey of Ophthalmology* 1984,**28**:391-404
37. Krasnov MM: Q-switched laser iridectomy and Q-switched laser goniopuncture. *Adv Ophthalmol* 1977,**34**:192-196.
38. Von Graefe A. Über die Iridectomie bei Glaucoma und Über den glaucomatösen Process. *Albrecht von Graefe Arch Ophthalmol* 1857,**3**:456-555.
39. Barkan O: Glaucoma : Classification, causes and surgical control (Results of gonioscopic research). *Am J Ophthalmol* 1938,**21**:1099
40. Barkan O : Iridectomy in narrow angle glaucoma. *Am J Ophthalmol* 1954 ;504-519.

41. Pflüger E. Operazioni moderne del glaucoma.  
Arch d'ophtal. 1893-94,1:321.
42. Lowe RF: Acute Angle Closure Glaucoma The Second Eye: An Analysis Of 200 Cases.  
Brit J Ophthalmol 1962,46:641-650
43. Lowe RF: Primary Angle Closure Glaucoma - A Review 5 years after bilateral surgery.  
Brit J Ophthalmol 1973,57:457-463
44. Murphy MB, Spaeth GL. Iridectomy in primary angle-closure glaucoma. Classification and differential diagnosis of glaucoma associated with narrowness of the angle.  
Arch Ophthalmol 1974,92:114-122.
45. Sugar HS. Cataract formation and refractive changes after surgery for angle closure glaucoma.  
Am J Ophthalmol 1970,69:747-749
46. Williams DJ, Gills JP Jr, Hall GA.  
Results of 233 peripheral iridectomies for narrow-angle glaucoma.  
Am J Ophthalmol. 1968,65: 548.
47. Foulds WS, Phillips CJ: Some observations on chronic closed-angle glaucoma.  
Brit J Ophthalmol 1957,41:208-213
48. Lowe RF: Primary creeping angle-closure glaucoma.  
Brit J Ophthalmol 1964,48:544-550
49. Playfair TJ, Watson PG. Management of chronic or intermittent primary angle-closure glaucoma. A long term follow up of the results of peripheral iridectomy used as an initial procedure.  
Brit J Ophthalmol 1979,63:23.
50. Pollack IP. Chronic angle-closure glaucoma. Diagnosis and treatment in patients with angles that appear open.  
Arch Ophthalmol 1971,85:676-689
51. Forbes M, Becker B. Iridectomy in advanced angle-closure glaucoma.  
Am J Ophthalmol. 1964,57:57.

52. Gelber EC, Anderson DR. Surgical decisions in chronic angle closure glaucoma.  
Arch Ophthalmol. 1976,**94**:1481.
53. Phillips CI. Closed-angle glaucoma: Significance of sectoral variations in angle depth.  
Brit J Ophthalmol 1956,**40**:136-143
54. Bhargava SK, Leighton DA, Philips CI: Early angle-closure glaucoma. Distribution of iridotrabecular contact and response to pilocarpine.  
Arch Ophthalmol 1973,**89**:369-372
55. Mapstone R. One Gonioscopic Fallacy  
Brit J Ophthalmol 1979,**63**:221-224
56. Phillips CI. Sectoral Distribution of Goniosynechia  
Brit J Ophthalmol 1956,**40**:129-135
57. Lee DA, Brubaker RF, Ilstrup DM. Anterior chamber dimensions in patients with narrow angles and angle-closure glaucoma.  
Arch Ophthalmology 1984,**102**:46-50
58. Jacobs IH, Krohn DL. Central anterior chamber depth after laser iridectomy.  
Am J Ophthalmol 1980,**89**: 865-867.
59. Lowe RF. Primary angle closure glaucoma: inheritance and environment.  
Brit J Ophthalmol 1972,**56**:13-20.
60. Fontana ST, Brubaker RF.  
Volume and depth of the anterior chamber in the normal ageing eye.  
Arch Ophthalmol 1980,**98**:1803-1808
61. Phillips CI: Aetiology of angle-closure glaucoma.  
Brit J Ophthalmol 1972,**56**:248-254
62. Johnson SB, Coakes RL, Brubaker RF. A simple photogrammetric method of measuring anterior chamber volume.  
Am J Ophthalmol 1978,**85**:469-474

63. Morkowitz SN, Morin JD. The ratio of lens thickness to axial length for biometric standardization in angle-closure glaucoma. *Am J Ophthalmol* 1985,**99**:400-402
64. Mapstone R. Mechanics of pupil block. *Brit J Ophthalmol* 1968,**52**:19-25
65. Mapstone R. Forces determining pupil size. *Exptl Eye Res* 1970,**10**:47-52
66. Mapstone R. Closed angle glaucoma. Experimental results. *Brit J Ophthalmol* 1974,**58**:41-45
67. Mapstone R. Precipitation of angle closure. *Brit J Ophthalmol* 1974,**58**:46-54
68. Mapstone R. Provocative tests in closed-angle glaucoma. *Brit J Ophthalmol* 1976,**60**:115-119
69. Mapstone R. Normal response to pilocarpine and phenylephrine. *Brit J Ophthalmol* 1977,**61**:510-511
70. Mapstone R. Dilating dangerous pupils. *Brit J Ophthalmol* 1977,**61**:517-524
71. Mapstone R. Outflow changes in positive provocative tests. *Brit J Ophthalmol* 1977,**61**:634-636
72. Mapstone R. The Fellow Eye. *Brit J Ophthalmol* 1981,**65**:410-413
73. Mapstone R, Clark CV. Prevalence of diabetes in glaucoma. *Brit J Ophthalmol* 1985,**69**:93-95
74. Mapstone R, Clark CV. Diurnal variation in the dimensions of the anterior chamber. *Arch Ophthalmol* 1985,**103**:1485-1487
75. Leighton DA, Phillips CI, Tsukahara S. Profile of presenting states of eyes in angle closure glaucoma. *Brit J Ophthalmol* 1971,**55**:577-584

76. Bigar F, Witmer R. Corneal endothelial changes in primary acute angle-closure glaucoma.  
*Ophthalmology*;1982,**89**:596-599
77. Patel BCK, Tullo AB. Corneal sensation in acute-angle closure glaucoma.  
*Acta Ophthalmologica* 1988,**66**:44-46
78. Rutkowski PC, Thompson HS. Mydriasis and increased intraocular pressure. Iris fluorescein studies.  
*Arch Ophthalmol* 1972,**87**:25-29
79. Airaksinen PJ, Saari KM, Tiainen TJ, Jaanio ET. Management of acute closed angle glaucoma with miotics and timolol.  
*Brit J Ophthalmol* 1979,**63**:822-825.
80. Gray RH, Hoare Nairn J, Ayliffe WHR.  
Efficacy of Nd-YAG Laser iridotomies in acute angle-closure glaucoma.  
*Brit J Ophthalmol* 1989,**73**:182-185
81. Setälä K. Corneal endothelial cell density after an attack of acute glaucoma.  
*Acta Ophthalmol* 1979,**57**:1004.
82. Markowitz SN, Morin JD. The endothelium in primary angle-closure glaucoma.  
*Am J Ophthalmol*. 1984,**98**:103-104.
83. Olsen T. The endothelial cell damage in acute glaucoma. On the corneal thickness response to intraocular pressure.  
*Acta Ophthalmol* 1980,**58**:257.
84. Winstanley J. Iris atrophy in primary glaucoma.  
*Trans Ophthalmol Soc UK* 1961,**81**:23-35
85. Lowe RF. Primary angle closure glaucoma : damage to cornea and lens. *Brit J Ophthalmol* 1965;**49**:460-465.
86. Krupin T, Mitchell KB, Johnson MF, Becker B. The long term effects of iridectomy for primary acute angle-closure glaucoma.  
*Am J Ophthalmol* 1978,**86**:506-509

87. Floman N, Berson D, Landau L. Peripheral iridectomy in closed angle glaucoma - late complications.  
Brit J Ophthalmol 1977,**61**:101-104
88. Forbes M. Indentation gonioscopy and efficacy of iridectomy in angle-closure glaucoma.  
Trans Am Ophthalmol Soc. 1974,**72**:488.
89. Horie T, Kitazawa Y, Nose H. Visual field changes in primary angle closure glaucoma.  
Jap J Ophthalmol 1975,**19**:108-115.
90. Campbell DGA. Comparison of diagnostic techniques in angle-closure glaucoma.  
Am J Ophthalmol 1979,**88**:197-204.
91. Mapstone R. Outflow changes in normal eyes after closed-angle glaucoma.  
Brit J Ophthalmol 1977,**61**:637-640
92. Hillman JS. Acute closed-angle glaucoma: an investigation into the effect of delay in treatment.  
Brit J Ophthalmol 1979,**63**:817-821.
93. McNaught EI, Rennie A, McClure E, Chisholm IA.  
Pattern of visual damage after acute angle-closure glaucoma.  
Trans Ophthalmol Soc UK 1974,**94**:406-415.
94. Mitchell KW, Wood CM, Howe JW et al. The visual evoked potential in acute primary angle closure glaucoma.  
Brit J Ophthalmol 1989,**73**:448-456.
95. Go FJ, Yamamoto T, Kitazawa Y. Argon laser iridotomy and surgical iridectomy in the treatment of primary angle-closure glaucoma. Jpn J Ophthalmol 1984,**28**:36-46.
96. Loh RCK. The problem of glaucoma in Singapore.  
Singapore Med J. 1968,**9**:76-80.
97. Lim ASM. The pattern of ocular disease in Singapore.  
Transactions of the Australian College of Ophthalmologists 1971,  
**3**:122-125.



98. Arkill SM , Lightman DA , Sommer A, Taylor HR, Korshin DM, Tielsch M.  
The prevalence of glaucoma among Eskimos of Northwest Alaska  
Arch Ophthalmol 1987, **105**:482-485
99. Alsbirk PH. Early detection of primary angle-closure glaucoma. Limbal and axial chamber depth screening in a high risk population (Greenland Eskimos).  
Acta Ophthalmol 1988, **66**: 556-564
100. Alper MG, Laubach JL. Primary angle-closure glaucoma in the American negro.  
Arch Ophthalmol 1968, **79**:663-668.
101. Luke S. Complications of peripheral iridectomy.  
Can J Ophthalmol 1969, **4** :346-351.
102. Robin AL, Pollack IP. Argon Laser peripheral iridotomies in the treatment of primary angle closure glaucoma; long-term follow-up.  
Arch Ophthalmol. 1982, **100**:919.
103. Yamamoto T, Shirato S, Kitazawa Y.  
Argon laser iridotomy in angle-closure glaucoma: a comparison of two methods.  
Jpn J Ophthalmol 1982, **26**:387-396.
104. Klapper RM. Q-switched neodymium:YAG laser iridotomy.  
Ophthalmology 1984, **91**:1017-1021
105. Harrad RA, Stannard KP, Shilling JS. Argon Laser iridotomy.  
Brit J Ophthalmol. 1985, **69**:368-372.
106. Brazier DJ. Neodymium-YAG laser iridotomy.  
J R Soc Med 1989, **79**:658-660
107. Haut J, Gaven I, Moulin F, Larricart P, Marre JM, Van Effenterre G.  
Study of the first hundred phakic eyes treated by peripheral iridotomy using the Nd:YAG laser.  
Int Ophthalmol 1986, **9**:227-235

108. Wise JB. Large iridotomies by the linear incision technique using the neodymium:YAG laser at low energy levels. A study using cynomolgus monkeys.  
Ophthalmology 1987,**94**:82-86
109. Wand M, Clark JA, Hill DA. Nd: YAG laser iridectomies: 100 consecutive cases.  
Ophthalmic Surg 1988,**19**:399-402
110. Pollack IP, Robin AL, Dragon DM, Green WR, Quigley HA, Murray TG, Hotchkiss ML. Use of the neodymium:YAG laser to create iridotomies in monkeys and humans.  
Trans Am Ophthalmol Soc 1984,**82**:307-328
111. Robin AL, Arkell S, Gilbert SM, Goossens AA, Werner RP, Korshin DM.  
Q-switched neodymium-YAG laser iridotomy. A field trial with a portable laser system.  
Arch Ophthalmol 1986,**104**:526-530
112. Mishima S, Kitazawa Y, Shirato S. Laser therapy for glaucoma.  
Aust NZ J Ophthalmol 1985,**13**:225-235
113. Korey M, Gieser D, Kass MA, Waltman SR, Gordon M, Becker B. Central corneal endothelial cell density and central corneal thickness in ocular hypertension and primary open angle glaucoma.  
Am J Ophthalmol 1982,**94**:610-616
114. Smith J, Whitted P. Corneal endothelial changes after argon laser iridotomy.  
Am J Ophthalmol. 1984,**98**:153-156.
115. Schrems W, Belcher CD III, Tomlinson CP. Changes in the human central corneal endothelium after neodymium:YAG laser surgery.  
Ophthalmic Laser Ther 1986,**1**:143-152
116. Gilbert CM, Robin AL, Pollack IP.  
Hyphaema complicating neodymium:YAG iridotomy.  
Ophthalmology 1984,**91**:1123.

117. Douglas WHG, Strachan IM. Surgical safety of prophylactic peripheral iridectomy. *Brit J Ophthalmol.* 1967,**51**:459-462.
118. Hodes BL, Bentivegna JF, Weyer NJ. Hyphema complicating laser iridotomy. *Arch Ophthalmol.* 1982,**100**:924-925.
119. Phillips CI, Clark CV, Levy AM. Posterior synechiae after glaucoma operations: aggravation by shallow anterior chamber and pilocarpine. *Brit J Ophthalmol* 1987,**71**:428-432.
120. Phillips CI, Snow JT. Peripheral iridectomy in angle closure glaucoma - a common complication  
*Brit J Ophthalmol* 1967,**51**:733-738
121. Yassur Y, Melamed S, Cohen S, Ben-Sira I. Laser Iridotomy in closed angle glaucoma. *Arch Ophthalmol.* 1979,**97**:1920-1921.
122. Welch DB, Apple DJ, Mendelsohn AD, Reidy JJ, Chalkley TH, Wilensky JT. Lens injury following iridotomy with a Q-switched neodymium-YAG laser. *Arch Ophthalmol* 1986,**104**:123-125
123. Bongard B, Pederson JE. Retinal burns from experimental laser iridotomy. *Ophthalmic Surgery* 1985,**16**:42-44.
124. Mainster MA, Sliney DH, Belcher CD, Buzney SM. Laser photodisruptors; damage mechanisms, instrument design and safety. *Ophthalmology* 1983,**90**:973-991.
125. Puliafito CA, Steinert RF. Laser surgery of the lens; experimental studies. *Ophthalmology* 1983,**90**:1007-1012.
126. Krauss JM, Puliafito CA, Miglior S, Steinert RF, Cheng HM. Vitreous Changes After Neodymium-YAG Laser Photodisruption. *Arch Ophthalmology* 1986,**104**:592-597
127. Berger BB. Foveal photocoagulation from laser iridotomy. *Ophthalmology* 1984,**91**:1029-1033

128. Karmon G, Savir H. Retinal damage after argon laser iridotomy.  
Am J Ophthalmol 1986,**101**:554-560
129. Karjalainen K, Laatikainen L, Raitta C. Bilateral nonrhegmatogenous retinal detachment following neodymium-YAG laser iridotomies (letter).  
Arch Ophthalmol 1986,**104**:1134
130. Wilson P. Trabeculectomy : Long term follow up.  
Brit J Ophthalmol 1977,**61**:535-538
131. Watson PG, Grierson I. The place of trabeculectomy in the treatment of glaucoma.  
Ophthalmology 1981,**88**:175-196
132. Mandelkorn R, Mendelsohn A, Olander K et al. Short exposure times in argon laser iridotomy.  
Ophthalmic Surg 1981,**12**:805-809.
133. Brainard JD, Landers JH, Shock JP. Recurrent angle closure glaucoma following a patent 75-micron laser iridotomy: a case report.  
Ophthalmic Surg 1982,**13**:1030-1032.
134. Mackie EG, Rubinstein K. Iridencleisis in congestive glaucoma.  
Brit J Ophthalmol. 1954,**38**:641-652.
135. Ghoshal TK, Blaxter PL. Results of peripheral iridectomy in closed-angle glaucoma.  
Brit J Ophthalmol. 1969,**53**:110-115.
136. Godel V, Stein R, Feiler-Ofrey V. Angle-closure glaucoma following peripheral iridectomy and mydriasis.  
Am J Ophthalmol, 1968,**65**:555-560
137. Tomey KF, Traverso CE, Shamma IV. Neodymium-YAG laser iridotomy in the treatment and prevention of angle closure glaucoma. A review of 373 eyes.  
Arch Ophthalmol 1987,**105**:476-481

138. Phillips CI. Timolol in operated closed angle glaucoma.  
Brit J Ophthalmol 1980,**64**:240 -246
139. Gieser DK, Wilensky JT.  
Laser iridectomy in the management of chronic angle-closure glaucoma.  
Am J Ophthalmol 1984,**98**:446-450
140. Loertscher H, Rol P. Basic physics of Neodymium:YAG laser.  
Int Ophthalmol Clin 1985,**25**:1-14.
141. Hoskins HD, Migliazzo CV. Laser Iridectomy - a technique for blue irises.  
Ophthalmic Surg 1984,**15**:488-490.
142. Stetz D, Smith H, Ritch R.  
A simplified Technique for Laser Iridectomy in Blue Irides.  
Am J Ophthalmol 1983,**96**:249-251
143. Minning CA.  
The use of green only argon laser for iridotomy in blue eyed patients.  
Am J Ophthalmol. 1983,**96**:114-115.
144. Beckman H, Sugar HS. Laser iridectomy therapy of glaucoma.  
Arch Ophthalmol 1973,**90**:453-455.
145. Wheeler CB. Laser Iridectomy.  
Phy Med Biol 1977,**6**:1115-1135
146. Krasnov MM. Q-switched ("cool") lasers in ophthalmology.  
Int. Ophthalmol Clin 1976,**16** : 29-44.
147. Vogel A, Hentschel W, Holzfuss J, Lauterborn W. Cavitation bubble dynamics and acoustic transient generation in ocular surgery with pulsed neodymium:YAG lasers.  
Ophthalmology 1986,**93**:1259-1269.
148. Capon MRC, Mellerio J. Nd:YAG lasers: plasma characteristics and damage mechanisms.  
Lasers Ophthalmol 1986,**1**:95-106.

149. Wilmanns I, Stodtmeister R, Pillunat LE. Nd:YAG laser shock waves in artificial eyes.  
*Ophthalmologica* 1988,**196**:210-215
150. Vernon SA, Cheng H. Freeze frame analysis on high speed cinematography of Nd/YAG laser explosions in ocular tissues.  
*Brit J Ophthalmol* 1986,**70**:321-325
151. Aron-Rosa D, Aron JJ, Grieseman M. Use of the Neodymium laser to open the posterior capsule after lens implant surgery. *Am Intra-ocular Implant Soc J* 1980, **6**: 352.
152. Greenridge KC.  
Nd:YAG capsulotomy - energy requirements and visual outcome.  
*Cataract* 1984: 31-33
153. Stark WJ, Worthen DM, Holloday JT, et al. Neodymium : YAG lasers. An FDA Report.  
*Ophthalmology* 1985,**92**:209-212.
154. Brown RH , Lynch MG, Tearse JE, Nunn RD. Neodymium-YAG vitreous surgery for phakic and pseudophakic malignant glaucoma.  
*Arch Ophthalmol* 1988,**104**:1464-1466
155. Epstein DL, Steinert RF, Puliafito CA. Neodymium-YAG laser therapy to the anterior hyaloid in aphakic malignant (ciliovitreal block) glaucoma.  
*Am J Ophthalmol* 1984,**98**:137-143
156. Weinberger D, Lusky M, Debbi S, Ben Sira I.  
Pseudophakic and aphakic pupillary block.  
*Ann Ophthalmol* 1988,**20**:403-405
157. Rockwood EJ, Meyers SM, Meisler DM, Zakov ZN, Langston RH. Treatment of selected cases of pupillary block with YAG laser iridotomies (letter).  
*Ophthalmic Surg* 1984,**15**:968
158. Shrader CE, Belcher CD, Thomas JV, Simmons RJ, Murphy EB. Pupillary and iridovitreal block in pseudophakic eyes.  
*Ophthalmology* 1984,**91**:831-837

159. Klapper RM.  
The role of neodymium:YAG laser in microsurgery of the glaucomas.  
Int Ophthalmol Clin 1985,**25**:101-117
160. Dutton GN, Allan D, Cameron SA. Pulsed Neodymium-YAG laser trabeculotomy: energy requirements and replicability.  
Brit J Ophthalmol 1989,**73**:177-181
161. Schrems W, Tomlinson CP, Belcher CD. Visual field improvement after neodymium:YAG laser puncture of miotic cysts.  
Ophthalmic Surgery 1987,**18**:342-343
162. Vega LF, Sabates R.  
Neodymium:YAG laser treatment of persistent pupillary membrane.  
Ophthalmic Surgery 1987,**18**:452-454
163. Frankhauser F, Lortscher H, Van Der Zypen E.  
Clinical studies on high and low power laser radiation upon some structures of the anterior and posterior segments of the eye. Experiences in the treatment of some pathological conditions of the anterior and posterior segments of the human eye by means of a Nd:YAG laser, driven at various power levels.  
Int Ophthalmol 1982,**5**:15-32.
164. Fleck BW, Dhillon BJ, Khanna V, McConnell, Chawla HB. Nd:YAG Laser Augmented Pneumatic Retinopexy. Ophthalmol. Surg. 1988, **19**:855-858.
165. Fleck BW, Chew PTK, Lim ASM, Tock EDC.  
Nd:YAG laser disruption of rabbit lens nucleus.  
Lasers and Light in Ophthalmology 1990,**3**:227-232.
166. Goldberg MF, Tso MO, Mirolovich T. Histopathological characteristics of neodymium-YAG laser iridotomy in the human eye.  
Brit J Ophthalmol 1987,**71**:623-625.
167. Rodrigues MM, Spaeth GL, Moster M, Thomas G, Hackett J.  
Histopathology of neodymium: YAG laser iridectomy in humans.  
Ophthalmology 1985,**92**:1696-1700

168. Dragon DM, Robin AL, Pollack IP, Quigley HA, Green WR, Murray TG, Hotchkiss ML, D'Anna S.  
Neodymium:YAG laser iridotomy in the cynomolgus monkey.  
*Invest Ophthalmol Vis Sci* 1985,**26**:789-796
169. Latina MA, Puliafito CA, Steinert RR, Epstein DL.  
Experimental iridotomy with the Q-switched neodymium-YAG laser.  
*Arch Ophthalmol* 1984,**102**:1211-1213
170. Seedor JA, Greenidge KC, Dunn MW. Neodymium:YAG laser iridectomy and acute cataract formation in the rabbit.  
*Ophthalmic Surg* 1986,**17**:478-482
171. Krauss JM, Puliafito CA, Steinert RF. Laser interactions with the cornea.  
*Survey of Ophthalmology* 1986,**31**:37-53
172. Venkatesh S, Guthrie S, Cruikshank FR, Bailey RT, Foulds WS, Lee WR.  
Thermal lens measurements in the cornea.  
*Brit J Ophthalmol* 1985,**69**:92-95
173. Schubert HD. Endothelial repair following Nd:YAG laser injury.  
*Invest Ophthalmol and Vis Sci* 1984,**25**:971-976
174. Khodadoust AA, Arkfeld DF, Caprioli J, Sears M.  
Ocular effect of Neodymium-Yag laser.  
*Am J Ophthalmol* 1984,**98**:144-152
175. Meyer KT, Petitt TH, Straasma BR.  
Cornea Endothelial Damage With Neodymium:YAG Laser.  
*Ophthalmology* 1984,**91**:1022-1029
176. Gailitis R, Peyman GA, Pulido J, Mitchell MD, Weinreb RM.  
Prostaglandin release following Nd:YAG iridotomy in rabbits.  
*Ophthalmic Surg* 1986,**17**:467-469
177. Liu SJ, Hunter DM, Dei T, Lin T, Lam KW. Study of prostaglandins and intraocular pressure in rabbits after Nd:YAG laser anterior segment procedures.  
*Ophthalmic Surg* 1988,**19**:112-115



178. Robin AL, Pollack IP, Quigley HA, D'Anna S, Addicks EM. Histological studies of angle structures after laser iridotomy in primates. *Arch Ophthalmol* 1982, **100**:1665-1670
179. Higginbotham EJ, Ogura Y. Lens clarity after argon and neodymium-YAG laser iridotomy in the rabbit. *Arch Ophthalmol* 1987, **105**:540-541
180. Jampol LM, Goldberg MF, Jednock N. Retinal damage from a Q-switched YAG laser. *Am J Ophthalmol*. 1983, **96**:326-329.
181. Frankhauser F, Rol P. Microsurgery with the neodymium:YAG laser: an overview. *Int Ophthalmol Clin* 1985, **25**:55-84
182. Schirmer KE. Argon laser surgery of the iris, optimised by contact lenses. *Arch Ophthalmology* 1983, **101**:1130-1132
183. Wise JB, Munnerlyn CR, Erickson PJ. A high-efficiency laser iridotomy-sphincterotomy lens. *Am J Ophthalmol* 1986, **101**:546-553
184. Pollack IP. Use of argon laser energy to produce iridotomies. *Trans Am Ophthalmol Soc* 1979, **77**:674-706.
185. Perkins ES, Brown NAP. Iridotomy with a ruby laser. *Brit J Ophthalmol* 1973, **57**:487-498
186. Bonney CH, Gaasterland DE. Low-energy, Q-switched ruby laser iridotomies in *Macaca mulatta*. *Invest Ophthalmol Vis Sci*. 1979, **18**:278-287.
187. Pollack IP, Robin AL. Iridotomies in cynomolgus monkeys using a Q-switched ruby laser. *Trans Am Ophthalmol Soc* 1980, **78**:88-106.
188. Robin AL, Pollack IP. The Q-switched ruby laser in glaucoma. *Ophthalmology* 1984, **91**:366-371.
189. Peyman GA, Larson B. Effects of the CW YAG laser on the human iris and retina. *Ophthalmology* 1984, **91**:1034-1039

190. Rol P, Kwasniewska S, van der Zypen E, Fankhauser F. Transscleral iridotomy using a neodymium: YAG laser operated both with standard equipment and an optical fiber system - a preliminary report: Part I-Optical system and biomicroscopic results. *Ophthalmic Surg* 1987, **18**:176-182
191. Van der Zypen E, Fankhauser F, Kwasniewska S. Transscleral iridotomy using a neodymium: YAG laser operated both with standard equipment and an optical fiber system - a preliminary report: Part II-Light and electron microscopic findings. *Ophthalmic Surg* 1987, **18**:337-341
192. Peyman GA, Katoh N. Effects of an erbium: YAG laser on ocular structures. *Int Ophthalmol* 1987, **10**:245-252
193. Yates F: *J Royal Statistical Soc* 1934, **1**:217
194. Swinscow TDV. *Statistics at square one*. Chapter 8. The  $\chi^2$  tests. Page 49. British Medical Association Publications 1983.
195. Foubister G, Hughes SPF: Fractures of the femoral neck: a retrospective and prospective study. *J R Coll Surg Edinb* 1989, **34**:249-252.
196. Godel V, Regenbogen L. Cataractogenic factors in patients with primary angle-closure glaucoma after peripheral iridectomy. *Am J Ophthalmol* 1977, **83**:180-184.
197. Korey M, Gieser D, Kass MA, Waltman SR, Gordon M, Becker B. Central corneal endothelial cell density and central corneal thickness in ocular hypertension and primary open angle glaucoma. *Am J Ophthalmol* 1982, **94**:610-616.
198. Lowe RF. Angle-closure, pupil dilatation and pupil block. *Brit J Ophthalmol* 1966, **50**:385-389
199. Schrems W, Eichelbronner O, Kriegelstein GK. The immediate IOP response of Nd-YAG-laser iridotomy and its prophylactic treatability. *Acta Ophthalmol* 1984, **62**:673-680

200. Stilma JS, Boen Tan TN. Timolol and intra-ocular pressure elevation following neodymium: YAG laser surgery.  
Doc Ophthalmol 1986,**61**:233-239
201. Kitazawa Y, Taniguchi T, Sugiyama K. Use of apraclonidine to reduce acute intraocular pressure rise following Q-switched Nd:YAG laser iridotomy.  
Ophthalmic Surgery 1989,**20**:49-52
202. Mishima S. Clinical investigations on the corneal endothelium.  
Ophthalmology 1982,**89**:525-530
203. Waring GO, Bourne WM, Edelhauser HF, Kenyon KR. The corneal endothelium.  
Ophthalmology 1982,**89**:531-591
204. Lowe RF. Primary angle-closure glaucoma : postoperative acute glaucoma after phenylephedrine eyedrops.  
Am J Ophthalmol 1968;**65**:552-554
205. Wand M, Grant WM, Simmons RJ, Hutchinson BT. Plateau iris syndrome. Trans Am Acad Ophthalmol Otolaryngol.  
1977,**83**:122-130.
206. Sugar HS. Postoperative cataract in successfully filtering glaucomatous eyes.  
Am J Ophthalmol 1970,**69**:740
207. Bloom JN, Levene RZ, Thomas G, Kimura R. Fluorophotometry and the rate of aqueous flow in man.  
Arch Ophthalmol 1976,**94**:435-443.
208. Lowe RF. Primary angle closure glaucoma - investigations after surgery for pupil block.  
Am J Ophthalmol 1964,**57**:931-938
209. Harris LS, Galin MA. Cycloplegic provocative testing.  
Arch Ophthalmol 1969,**81**:356-358
210. Hung PT, Chou LH. Provocation and mechanism of angle-closure glaucoma after iridectomy.  
Arch Ophthalmol 1979,**97**:1862-1864.

211. Friedman Z, Neumann E. Comparison of prone position, dark room, and mydriatic tests for angle closure glaucoma before and after peripheral iridectomy.  
Am J Ophthalmol 1972,**74**: 24-27
212. Harris LS. Cycloplegic-induced intraocular pressure elevations.  
Arch Ophthalmol 1968,**79**:242-246.
213. Karmon G, Vender T, Savir H. Evaluation of laser iridectomy in angle-closure glaucoma: provocative tests.  
Brit J Ophthalmol 1982,**66**:471-473
214. Wheeler CB. Laser Iridectomy.  
Phys Med Biol 1977,**22** :1115-1135.
215. Ritch R. The treatment of chronic angle-closure glaucoma.  
Ann Ophthalmol. 1981,**13**:21.
216. Wishart PK, Nagasubramanian S, Hitchings RA.  
Argon laser trabeculoplasty in narrow angle glaucoma.  
Eye 1987,**1**:567-576
217. Romano JH, Hitchings RA, Pooinasawmy D. Role of Nd:YAG peripheral iridectomy in the management of ocular hypertension with a narrow angle.  
Ophthalmic Surg 1988,**19**:814-816
218. Hitchings RA. Combined dye and argon laser treatment for narrow angle glaucoma.  
Trans Ophthalmol Soc 1984,**104**:52-54
219. Robin AL, Pollack IP. Q-switched neodymium-YAG laser iridotomy in patients in whom the argon laser fails.  
Arch Ophthalmol 1986,**104**:531-535,
220. Naveh-Floman N, Blumenthal M. A modified technique for serial use of argon and neodymium:YAG lasers in laser iridotomy.  
Am J Ophthalmol 1985,**100**:485-486.
221. Zborwiski-Gutman L, Rosner M, Blumenthal M, Naveh N. Sequential Use of Argon and ND:YAG Lasers to produce an iridotomy- a pilot study.  
Metabolic, Pediatric and Systemic Ophthalmology. 1988,**11**:58-60.

222. Rodrigues MM, Streeten B, Spaeth GL, Schwartz LW. Argon laser iridotomy on primary angle-closure or pupillary block glaucoma. Arch Ophthalmol 1978,**96**:2222-2231
223. Sachs SW, Schwartz B. Enlargement of laser iridotomies over time. Brit J Ophthalmol 1984,**68**:570-573
224. Drake MV. Neodymium:YAG laser iridotomy. Surv Ophthalmol 1987,**32**:171-177
225. Yassur Y, David R, Rosenblatt I, Marmour U. Iridotomy with red krypton laser. Brit J Ophthalmol 1986,**70**:295-297
226. Ritch R, Palmberg P. Argon laser iridectomy in densely pigmented irides. Am J Ophthalmol 1982,**93**:800-801.
227. Chiang C, Lim ASM, Ang BC, Min G, Fleck BW. Laser iridotomy as an alternative to surgical iridectomy. Proceedings of the 21st Annual Combined Surgical Meeting, Singapore Academy of Medicine, November 1987.
228. Ye T, Ge J, Zhuan W. A preliminary study of short-term efficacy of Nd:YAG laser peripheral iridotomy in patients with primary angle closure glaucoma. Eye Science (China). 1987,**3**:1.
229. Lim ASM. Peripheral Iridectomy- surgical: Argon: YAG. 1989. PG Publishing, Singapore.
230. Panek WC, Lee DA, Christensen RE. The effects of Nd:YAG laser iridotomy on the corneal endothelium. Am J Ophthalmol 1991, **111**: 505-507.
231. Prum BE, Shields SR, Shields MB, Hickingbotham D, Chandler DB. In vitro videographic comparison of argon and Nd:YAG laser iridotomy. Am J Ophthalmol 1991, **111**: 589-594.
232. McGalliard JN, Wishart PK. The effect of Nd:YAG iridotomy on intraocular pressure in hypertensive eyes with shallow anterior chamber. Eye 1990, **4**:823-829.

233. Fleck BW, Chew PTK, Lim ASM, Tock EDC.  
Effects of pulsed Nd:YAG laser on the surface of rabbit retina.  
*Ophthalmic Surgery* 1991;**22**:168-171.
234. Fleck BW, Dhillon B, Khanna V, Fairley E, McGlynn C.  
A randomised, prospective comparison of Nd:YAG laser iridotomy  
and operative peripheral iridectomy in fellow eyes.  
*Eye* 1991;**5**:315-321.
235. Fleck BW. How large must an iridotomy be?  
*Br J Ophthalmol* 1990;**74**:583-588.
236. Fleck BW, Wright E, McGlynn C.  
Argon laser pretreatment 4-6 weeks before Nd:YAG laser  
iridotomy. *Ophthalmic Surgery* 1991;**22**:644-649.

## COMMUNICATIONS FROM THESE STUDIES

### PAPERS PUBLISHED

1. Fleck BW, Dhillon B, Khanna V, Fairley E, McGlynn C.  
A randomised, prospective comparison of Nd:YAG laser iridotomy and operative peripheral iridectomy in fellow eyes.  
*Eye* 1991;5:315-321.
2. Fleck BW, Fairley E, McGlynn C : A prospective comparison of Nd:YAG laser iridotomy and surgical peripheral iridectomy in the treatment of acute closed-angle. In Khoo CY et al eds. Proceedings of the XXVI International Congress of Ophthalmology, Amsterdam: Elsevier Science Publishers B.V.1991:852-858.
3. Fleck BW. How large must an iridotomy be?  
*Brit J Ophthalmol* 1990;74:583-588.
4. Fleck BW, Wright E, McGlynn C.  
Argon laser pretreatment 4-6 weeks before Nd:YAG laser iridotomy. *Ophthalmic Surgery* 1991;22:644-649.
5. Fleck BW, Wright E, Fairley E. The effect of pupil dilation on Nd:YAG iridotomy area. *Brit J Ophthalmol* 1992 (in press).

### VERBAL COMMUNICATIONS

1. Prospective randomised controlled trial of Neodymium-YAG laser iridotomy and surgical peripheral iridectomy in the treatment of acute angle closure glaucoma. A preliminary report. Fleck BW, Dhillon BJ, Khanna V, McConnell JMS. 5th Annual Conference of the British Medical Laser association. January 1987.
2. Laser Iridotomy as an alternative to Surgical Iridectomy. Chiang C, Lim ASM, Ang BC, Min G, Fleck BW. 21st Annual Combined Surgical Meeting, Singapore Academy of Medicine. November 1987.
3. A Comparison of Argon with Nd YAG Laser Iridotomy in S.E. Asian and Caucasian Eyes. Fleck BW, Wong PK, Cheong P, Chiang C, Dhillon B, Khanna V, Lim ASM. 7th Singapore - Malaysia Joint Meeting in Ophthalmology. March 1988.

4. Dhillon B, Fleck BW, Mackintosh G, Khanna V. Nd: YAG Iridotomy in Primary Chronic Narrow Angle Glaucoma. Scottish Ophthalmology Club. Edinburgh, March 1988.
5. Fleck BW. A Prospective Randomised of Nd YAG Laser Iridotomy and Surgical Iridectomy in the treatment of the Fellow Eye of Patients with acute closed angle glaucoma. College of Ophthalmologists Inaugural Meeting, London 1989.
6. Fleck BW, Fairley E, McGlynn C. A prospective comparison of Nd:YAG laser iridotomy and surgical peripheral iridectomy in the treatment of acute angle closure glaucoma. XXVI International Congress of Ophthalmology. Singapore, March 1990.



# A Randomised, Prospective Comparison of Nd:YAG Laser Iridotomy and Operative Peripheral Iridectomy in Fellow Eyes

B. W. FLECK, B. DHILLON, V. KHANNA, E. FAIRLEY, C. MCGLYNN

Edinburgh

## Summary

A prospective, randomised comparison of Nd:YAG laser iridotomy and operative peripheral iridectomy in the fellow eye of 52 patients presenting with acute angle closure glaucoma has been undertaken. Nd:YAG laser iridotomy resulted in a significantly higher incidence of iris bleeding at the time of treatment ( $p < 0.05$ ), higher intraocular pressure one hour ( $p < 0.02$ ) and three hours ( $p < 0.02$ ) following treatment, and a higher incidence of focal corneal oedema 24 hours following treatment ( $p < 0.001$ ). One laser treated patient developed acute angle closure glaucoma two weeks following treatment despite the presence of a small patent iridotomy.

After a mean follow-up period of 11.8 months there was no significant difference between the two groups in visual acuity, or intraocular pressure. It is concluded that Nd:YAG laser iridotomy is a satisfactory alternative to operative peripheral iridectomy in the prophylactic treatment of fellow eyes.

Argon<sup>1</sup> and Nd:YAG<sup>2</sup> laser iridotomy have already largely superseded operative peripheral iridectomy<sup>3</sup> in the treatment of angle closure glaucoma.<sup>4</sup> Laser surgery is more convenient and less costly than conventional surgery.<sup>5</sup> Rare but serious operative complications such as endophthalmitis, flat anterior chamber and malignant glaucoma, are completely eliminated. However laser surgery should not be regarded as non invasive.<sup>6</sup>

Several studies have compared argon laser and Nd:YAG laser iridotomy. Nd:YAG laser iridotomy requires less laser energy, produces fewer short term complications, and has a much lower rate of delayed iridotomy closure than argon laser iridotomy.<sup>7-12</sup> Nd:YAG laser iridotomy has not been compared with operative peripheral iridectomy in a prospective study. Peripheral iridectomy is a remarkably 'safe' operation, with few short or long term

complications.<sup>13</sup> We are currently performing a long term prospective randomised comparison of these treatments in a variety of forms of angle closure glaucoma, and our initial results in the treatment of the fellow eye following acute angle closure glaucoma are presented in this paper.

## Material and Method

Ethical approval of the study was obtained from the Regional Surgical Specialties Ethical Committee. Consecutive patients with acute angle closure glaucoma in one eye were accepted into the trial if the referring ophthalmologist believed the patient to be suitable for either Nd:YAG laser iridotomy or operative peripheral iridectomy in the fellow eye. If the fellow eye had an intraocular pressure greater than 21 mmHg or a cup:disc ratio greater than 0.6 the patient was excluded from the study. Informed patient consent to

inclusion in the trial was obtained before randomisation.

Initial examination included assessment of corrected visual acuity, intraocular pressure, Goldman gonioscopy, slit lamp examination of the lens, and fundal examination. Specular microscopy was performed using a Keeler-Konan Pocklington specular microscope. Several central fields were photographed and stored for later analysis.

Forty-eight hours prior to surgical or laser treatment all systemic and topical intraocular pressure lowering agents, other than G Pilocarpine 2%, were discontinued. One drop of G Pilocarpine 2% was instilled one hour before treatment.

#### *Surgery*

Operative peripheral iridectomy was performed under general anaesthetic, or subconjunctival local anaesthetic. Retrobulbar local anaesthetic was not used, in order to avoid possible intraocular pressure changes induced by this procedure during the early postoperative period.

#### *Laser treatment*

A Zeiss 'Visulas' Nd:YAG laser and Zeiss anterior segment YAG contact lens were used. A treatment site was chosen in the superior iris, between 10 and 2 o'clock, approximately 2/3 distance from the pupil margin to the base of the iris. An iris crypt was used, when present. A single 5–10 mj pulse was delivered to the treatment site. If this pulse did not penetrate the iris, further single pulses were delivered to the same site until penetration was achieved. A gush of aqueous fluid from the posterior chamber could be seen at the moment of penetration. Patency was assessed by direct observation of the posterior chamber, or anterior lens capsule.

#### *Post treatment assessment*

Goldman applanation tonometry was performed one, two, three, six and 24 hours following treatment. A Perkins hand held applanation tonometer was used to measure the early post operative intraocular pressure in some surgical patients who had had a general anaesthetic. Systemic and topical intraocular pressure lowering agents were withheld unless the pressure rose above 40 mm Hg.

Twenty four hours after treatment the cornea was examined and focal endothelial damage scored as 0 (no change present), + (focal granularity), or ++ (focal full thickness corneal oedema). Iritis was judged to be present if there were more than five white cells per field using a 3 mm long slit beam.

The presence of dispersed pigment particles in the aqueous was not judged to be indicative of iritis. Intraocular pressure was measured, the iridotomy or iridectomy inspected for patency, and the lens examined. No topical treatment was given unless significant iritis was present, in which case G Beta-methasone 0.1% four times daily for one week was prescribed. Mydriatics were not used.

#### *Follow up*

Patients were assessed one week, one month, six months, and 12 months following treatment. The pupil was dilated using G. Phenylephrine 10% one month following treatment in order to detect posterior synechiae, and to examine the lens and fundus. Six months following treatment specular microscopy, gonioscopy and pilocarpine/phenylephrine provocation testing were performed. Goldman gonioscopy was performed on all patients, followed by Zeiss 4 mirror indentation gonioscopy if any part of the angle appeared to be closed. Pilocarpine/phenylephrine provocation testing as described by Mapstone<sup>14</sup> and modified by Harrad<sup>15</sup> was used. One drop of G Phenylephrine 10% and one drop of G Pilocarpine 2% were instilled. The intraocular pressure was measured one hour later. An intraocular pressure rise of more than 8 mm Hg was regarded as a positive result.<sup>14</sup>

#### *Specular microscopy analysis*

Patients were coded by number, and endothelial cell counts were performed by an observer unaware of the coding system. Using standardised print magnification and a transparent grid, three representative fields of 0.05 mm<sup>2</sup> were chosen for each patient, and the cells within these fields were counted. The mean value for the three areas was then calculated.

#### *Statistical analysis*

Where appropriate the unpaired Student t test or the chi squared test were used to test the significance of differences between the two groups.

## **Results**

Twenty six patients in each group have now completed at least six months of follow-up. Thirteen patients from the surgical group and sixteen patients from the laser treated group have completed one year of follow-up. The current mean follow-up time for the surgical group is  $11.7 \pm 8.7$  months, and that of the laser treated group  $16.1 \pm 11.0$  months (t test NS). Two patients in the laser treated group have died, in each case approximately nine

**Table I** Patient Groups

	Surgery	Laser	P
Number	26	26	
Male:Female	9:17	7:19	
Age (years)	67.5 ± 13.1	68.3 ± 12.6	NS
Age range	41-88	40-88	
Right:Left	10:6	11:15	

Figures are presented as mean ± one standard deviation.

P = statistical p value, NS = Not statistically significant.

months following treatment. No patients have been lost to follow-up.

Details of initial assessment of the two groups are given in Tables I and II.

A patent laser iridotomy was obtained at the initial treatment session in 25 patients. Treatment sessions on three consecutive days were needed to obtain a patent iridotomy in one patient. A patent iridectomy was produced in all surgical patients. A mean of  $3.1 \pm 2.6$  pulses (range 1-10) with a mean total energy of  $25.8 \pm 21.4$  mJ (range 4.9-72.9) was used in laser treatment. One pulse was sufficient to create an adequate iridotomy in 11 patients, and less than 10 mJ total energy was used in 10 patients. Slight iris bleeding occurred at the time of treatment in 15 laser patients and seven surgical patients ( $X^2$  test  $p < 0.05$ ). There were no other operative complications.

#### Immediate post treatment assessment

The mean intraocular pressure before treatment and one, two, three and six hours following treatment are shown in Fig. 1. Complete data was available in nine surgically treated patients and 15 laser treated patients. The groups were significantly different at one hour and three hours using the unpaired student t test,  $p < 0.02$ . Two surgically treated

patients (8%) developed an intraocular pressure rise to between 20 and 25 mm Hg within three hours of surgery. Seven laser treated patients (27%) developed an intraocular pressure rise to greater than 20 mm Hg within three hours of treatment, and in three of these patients the intraocular pressure rose to above 40 mm Hg.

Of the 15 laser treated patients with complete intraocular pressure data, the peak pressure occurred one hour following treatment in seven, at two hours in four, and at three hours in four. In all but two cases the intraocular pressure had returned to normal six hours following treatment.

The results of examination 24 hours following treatment are shown in Table III.

Focal corneal oedema was most marked 24 hours following laser treatment, and had fully resolved after one week in all cases. The total laser energy used to treat the 15 patients who subsequently developed focal corneal oedema was  $30.95 \pm 21.6$  mJ, compared to  $18.2 \pm 19.7$  mJ for those who did not. This difference was not statistically significant. The total laser energy used to treat the six patients who subsequently developed iritis was  $39.75 \pm 16.2$  mJ, compared to  $20.7 \pm 18.2$  mJ for those who did not. Again this difference was not statistically significant.

Six surgical patients were found to have minimal focal lens opacities at the iridectomy site due to mild operative trauma to the anterior lens capsule. These opacities were not progressive and did not lead to visual loss during the follow-up period. Two laser treated patients developed focal lens opacities underlying the treatment site. In one case a faint haze was present deep to the anterior capsule, with no subsequent progression or loss of vision. The second case developed polychromatic crystals in the anterior lens cortex underlying the treatment site, with sub-

**Table II** Initial Examination

	Surgery	Laser	P
Visual acuity worse than 6/9 due to cataract	3	4	NS
Intraocular pressure, mm Hg	15.0 ± 3.6	15.5 ± 3.4	NS
Gonioscopy (Goldman) angle partly closed	6	6	NS
Iris colour Brown:Grey	10:16	10:16	NS

P = statistical p value, NS = Not statistically significant.

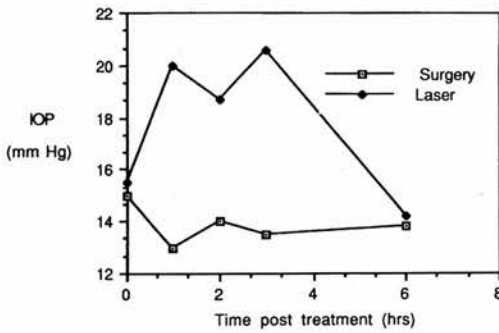


Fig. 1. Early post treatment intraocular pressure.

sequent development of nuclear cataract and loss of one line of visual acuity, from 6/9 to 6/12.

#### One month follow-up

One laser treated patient developed acute angle closure glaucoma three weeks following treatment. The patient had been using cyclopentolate 1% drops to the other eye, and may have inadvertently contaminated the affected eye. Following treatment with pilocarpine 2% the intraocular pressure returned to normal. The iridotomy was small ( $50 \mu \times 50 \mu$ ) but patent. Nd:YAG laser enlargement of the iridotomy was performed, resulting in no further symptoms. A subsequent pilocarpine/phenylephrine provocation test was negative.

One patient was found to have developed iridotomy closure two weeks following treatment and further laser treatment to re-open the iridotomy was performed.

Posterior synechiae developed in three surgical patients, and three laser treated patients. Two of the surgical patients and one of the laser treated patients had had iritis at the 24 hours post treatment examination. The adhesions were of minimal extent in all cases, did not progress, and were not associated with subsequent cataract development or visual loss during the follow-up period of the study.

#### Six month follow-up

Table IV summarises the findings in the two groups of six months following treatment.

When compared with pre-treatment measurements visual acuity was unchanged, or changed by only one line in all surgical patients. However in the laser treated group visual acuity deteriorated by two or more lines

in two patients. These patients had developed nuclear cataract—one in a previously clear lens, and one in a lens with pre-existing nuclear cataract.

The mean intraocular pressure was  $14.5 \pm 2.7$  and  $15.0 \pm 3.2$  mm Hg in the surgical and laser groups respectively. One laser treated patient had an intraocular pressure of 25 mm Hg. All other patients had an intraocular pressure of less than or equal to 21 mm Hg, and no patient required topical medication.

All iridotomies and iridectomies were patent. Gonioscopy revealed an open angle in all surgical patients, with focal goniosynechiae adjacent to the iridectomy in two patients. Two laser treated patients had partly closed angles on Goldman gonioscopy, but the angles were open on indentation. One of these two patients had focal areas of goniosynechiae adjacent to the iridotomy site.

No patient developed more than a 10% change in the cup:disc ratio, and no patient developed pathological optic disc cupping.

Pilocarpine/phenylephrine provocation tests were performed on 14 surgical patients and 23 laser patients. All tests were negative.

Satisfactory pre-treatment and six months post treatment specular micrographs were obtained in seven surgical patients and nine laser treated patients (see Table V). The two groups did not significantly differ in mean endothelial cell count either before or six months following treatment. There was no significant percentage change in endothelial cell count following treatment in either group, and no difference between the two groups.

Table III Examination 24 hours following treatment.

	Surgery	Laser	P
Focal corneal oedema	0	15	<0.001
Grade +		11	
Grade: ++		4	
Intraocular pressure, mm Hg	$11.1 \pm 3.1$	$12.2 \pm 4.0$	NS
Iritis	11	6	NS
Patent	26	26	NS
Focal lens opacities	6	2	NS

P = statistical p value, NS = Not statistically significant.

**Table IV** Examination 6 months following treatment

	Surgery	Laser	P
Visual acuity loss of two or more lines	0	2	NS
Posterior synechiae	3	3	NS
Intraocular pressure, mm Hg	14.5 ± 2.7	15.0 ± 3.2	NS
Gonioscopy—angle partly closed	0	2	NS
Provocation test positive	0	0	NS

P = statistical p value, NS = Not statistically significant.

### Final follow-up

At the final follow-up examination an additional two laser treated patients with initially clear lenses were found to have developed nuclear cataract sufficient to cause two or more lines of visual acuity loss. Visual acuity loss of more than one line did not occur in any surgical patient ( $\chi^2$  NS). The intraocular pressure at the final follow-up examination was 14.9 ± 2.4 mm Hg in the surgical group, and 14.3 ± 2.4 mm Hg in the laser treated group. No patient had an intraocular pressure greater than 21 mm Hg, but one laser treated patient was using topical  $\beta$  blocker medication to maintain normal intraocular pressure.

### Discussion

One laser treated patient developed acute angle closure glaucoma despite the presence of a small patent iridotomy. This case, and three other similar cases, have been discussed in another paper.<sup>16</sup> Lowe found that conservative treatment of the fellow eye resulted in a 50% incidence of subsequent acute angle closure glaucoma.<sup>17</sup> However, acute angle closure glaucoma following prophylactic surgical peripheral iridectomy is extremely rare.<sup>13,17,18</sup> Small argon<sup>19,20</sup> or Nd:YAG<sup>21-23</sup> laser iridotomies may, however, fail to prevent acute angle closure glaucoma.

One case developed closure of a previously patent iridotomy, two weeks following treatment. This patient had not developed significant iritis following treatment. ND:YAG

laser iridotomy closure is uncommon<sup>8,11,21-24</sup> Late iridotomy closure, or partial closure, is much more common following argon laser iridotomy and has been reported to occur in approximately 20% of cases.<sup>10-12,15</sup>

### Short term complications

Short term complications following Nd:YAG laser iridotomy include iris bleeding, intraocular pressure rise, focal corneal oedema, iritis and focal lens opacity.

Fifty-eight per cent of our laser treated patients developed iris bleeding at the time of treatment, a significantly higher incidence than that found during operative surgery. Other workers have reported an incidence of 20-60% microhyphaema following Nd:YAG laser iridotomy.<sup>7-12,22,24</sup> Macrohyphaema did not occur in our series, bleeding was transitory and did not appear to result in any adverse effect.

Our finding of transitory, but very marked, intraocular pressure elevation in some patients during the first three hours following Nd:YAG laser iridotomy confirms the findings of previous studies<sup>7-9,11,12,23,24</sup> Timolol<sup>25</sup> and apraclonidine<sup>26</sup> have been found to minimise the development of post-treatment intraocular pressure elevation, and it is now our practice to give acetazolamide 500 mg orally one hour before performing Nd:YAG laser iridotomy.

Focal corneal endothelium changes overlying the treatment site occurred in 58% of

**Table V** Corneal endothelium cell density

	Surgery	Laser	P
Pre-treatment cell density, mm <sup>-2</sup>	2470.3 ± 522.7	2531.7 ± 649.1	NS
Post-treatment cell density, mm <sup>-2</sup>	2442.0 ± 557.1	2188.0 ± 560.7	NS
Percentage change	-3.6 ± 3.95	-7.2 ± 10.6	NS

P = statistical p value, NS = Not statistically significant.

our laser treated patients. Other workers have reported that 4–30% of eyes developed focal endothelial changes following Nd:YAG laser iridotomy.<sup>7,8,10,11,22,24</sup> Punctate areas of endothelial loss overlying treatment sites have been attributed to damage caused by the dispersion of high velocity particulate debris.<sup>27,28</sup>

Reduced endothelial cell density following argon laser iridotomy has been described by some workers,<sup>7</sup> but others have found no change.<sup>29</sup> We found no significant change in endothelial cell density following Nd:YAG laser iridotomy, confirming previous studies.<sup>7,30</sup> No significant change in endothelial cell density following operative peripheral iridectomy was found in our study, again confirming the results of other workers.<sup>30,31</sup>

The incidence of iritis and posterior synchiae was similar following laser iridotomy and operative iridectomy. Focal lens opacities were found underlying the laser treatment site in two patients. Focal opacities induced by Nd:YAG laser photodisruption are rare,<sup>21,24,32</sup> in contrast to a much higher incidence following argon laser iridotomy.<sup>1,7,10,11,12</sup> We found six cases of small focal lens opacities at the site of operative peripheral iridectomy. Focal opacities, whether caused by argon laser iridotomy, Nd:YAG laser iridotomy or operative peripheral iridectomy have previously been found to be non-progressive and do not lead to visual loss. However one of our laser treated patients lost one line of visual acuity due to nuclear cataract following the development of a focal opacity at the time of treatment.

#### **Long term glaucoma outcome**

There was no significant difference in the mean intraocular pressure of the two groups six months following treatment, or at the time of most recent follow-up. Optic disc appearance remained unchanged in all eyes, and gonioscopic appearances six months following treatment were similar in the two groups. Two laser treated eyes had areas of angle closure which could be opened on indentation. Wishart has reported progressive angle narrowing in four eyes following Nd:YAG laser iridotomy, with widening of the angle on performing a further laser iridotomy.<sup>21</sup> It is

possible that small iridotomies do not fully overcome iris bombé.

#### *Long term visual outcome*

While four laser treated patients lost two or more lines of visual acuity due to cataract development during the follow-up period, and no surgical patients lost vision, this difference was not statistically significant. Del Priore reported progression of cataract following Nd:YAG laser iridotomy in two of forty three patients.<sup>10</sup> On long term follow-up approximately 10–15% of fellow eyes subjected to peripheral iridectomy develop cataract sufficient to reduce visual acuity by two or more lines.<sup>18,33</sup> These figures compare with an incidence of 8% among fellow eyes treated conservatively.<sup>34</sup>

#### **Conclusion**

While the follow-up period of our study was only 11.8 months, our findings suggest that the short term complications of Nd:YAG laser iridotomy do not adversely affect the long term outcome. Short term complications may be minimised by appropriate iridotomy technique. Oral acetazolamide or a topical beta-blocker given prior to treatment will reduce the incidence of post treatment intraocular pressure elevation.<sup>25</sup> The use of low energy laser pulses in conjunction with a Wise 103 dioptré contact lens should minimise endothelial trauma.<sup>9</sup> The production of a large iridotomy will minimise the risk of subsequent acute angle closure glaucoma.<sup>16</sup>

Nd:YAG laser iridotomy and operative peripheral iridectomy appear to have a similar long term outcome. We are currently undertaking a five year prospective comparison of Nd:YAG laser iridotomy and operative peripheral iridectomy in 200 patients in order to test further this hypothesis. Bearing in mind the convenience of laser treatment, and the lack of possible anaesthetic complications, Nd:YAG laser iridotomy must remain the treatment of choice in angle closure glaucoma.

This study was supported by grants from the Edinburgh Royal Infirmary Eye Research Endowment Fund and the WH Ross Foundation. The preliminary findings of this study were presented at the Inaugural

Congress of the College of Ophthalmologists, London, March 1989.

KEY WORDS: Angle Closure Glaucoma, Nd:YAG laser iridotomy, peripheral iridectomy, specular microscopy.

#### References

- <sup>1</sup> Abraham RK, Miller GL: Outpatient argon laser iridectomy for angle closure glaucoma: a two year study. *Trans Am Acad Ophthalmol Otolaryng* 1975;**79**:OP529-38.
- <sup>2</sup> Frankhauser F, Roussel P, Steffen J, Van Der Zypfen E, Chrenkova A: Clinical studies on the efficiency of high power laser radiation upon some structures of the anterior segment of the eye. First experience of the treatment of some pathological conditions of the anterior segment of the human eye by means of a Q-switched laser system. *Int Ophthalmol* 1981;**3**:129-39.
- <sup>3</sup> Chandler PA: Narrow Angle Glaucoma. *Arch Ophthalmol* 1952;**47**:695-716.
- <sup>4</sup> Rivera AH, Brown RH, Anderson DR: Laser iridotomy vs surgical iridectomy—have the indications changed? *Arch Ophthalmol* 1985;**103**:1350-4.
- <sup>5</sup> Rich W: The economics of Nd-YAG laser treatment. *Dev Ophthalmol* 1987;**14**:93-6.
- <sup>6</sup> Spaeth GL: Laser treatment is invasive surgery. *Ophthalmic Surg* 1988;**19**:463-4.
- <sup>7</sup> Robin AL and Pollack IP: A comparison of neodymium: YAG and argon laser iridotomies. *Ophthalmology* 1984;**91**:1011-16.
- <sup>8</sup> Schwartz LW, Moster MR, Spaeth GL, Wilson RP, Poryzees E: Neodymium: YAG laser iridotomies associated with closed or occludable angles. *Am J Ophthalmol* 1986;**102**:41-4.
- <sup>9</sup> Wise JB: Low-energy linear-incision neodymium: YAG laser iridotomy versus linear-incision argon laser iridotomy. A prospective clinical investigation. *Ophthalmology* 1987;**94**:1531-7.
- <sup>10</sup> Del Priore LV, Robin AL, Pollack IP: Neodymium: YAG and argon laser iridotomy. Long-term follow-up in a prospective, randomized clinical trial. *Ophthalmology* 1988;**95**:1207-11.
- <sup>11</sup> McAllister JA, Schwartz LW, Moster M, Spaeth GL: Laser peripheral iridectomy comparing Q-switched neodymium YAG with argon. *Trans Ophthalmol Soc UK* 1984;**104**:67-9.
- <sup>12</sup> Moster MR, Schwartz LW, Spaeth GL, Wilson RP, McAllister JA, Poryzees EM: Laser iridectomy. A controlled study comparing argon and neodymium: YAG. *Ophthalmology* 1986;**93**:20-4.
- <sup>13</sup> Playfair TJ and Watson PG: Management of acute primary angle-closure glaucoma: a long term follow-up of the results of peripheral iridectomy used as an initial procedure. *Br J Ophthalmol* 1979;**63**:17-22.
- <sup>14</sup> Mapstone R: Provocative tests in closed-angle glaucoma. *Br J Ophthalmol* 1976;**60**:115-9.
- <sup>15</sup> Harrad RA, Stannard KP, Shilling, JS: Argon Laser iridotomy. *Br J Ophthalmol* 1985;**69**:368-72.
- <sup>16</sup> Fleck BW: How large must an iridotomy be? *Br J Ophthalmol* 1990;**74**:583-8.
- <sup>17</sup> Lowe RF: Acute angle closure glaucoma. The second eye an analysis of 200 cases. *Br J Ophthalmol* 1962;**46**:641-50.
- <sup>18</sup> Lowe RF: Primary angle-closure glaucoma. A review 5 years after bilateral surgery. *Br J Ophthalmol* 1973;**57**:457-63.
- <sup>19</sup> Mandelkorn R, Mendelsohn A, Olander K, Zimmerman TJ: Short exposure times in argon laser iridotomy. *Ophthalmic Surg* 1981;**12**:805-9.
- <sup>20</sup> Brainard JO, Landers JH, Shock JP: Recurrent angle closure glaucoma following a patent 75-micron laser iridotomy: a case report. *Ophthalmic Surg* 1982;**13**:1030-2.
- <sup>21</sup> Wishart PK and Hitchings RA: Neodymium: YAG and dye laser iridotomy—a comparative study. *Trans Ophthalmol Soc UK* 1986;**105**:521-40.
- <sup>22</sup> Gray RH, Hoare Nairn J, Ayliffe WHR: Efficacy of Nd: YAG laser iridotomies in acute angle-closure glaucoma. *Br J Ophthalmol* 1989;**73**:182-5.
- <sup>23</sup> Brazier DJ: Neodymium: YAG laser iridotomy. *J Roy Soc Med* 1989;**79**:658-60.
- <sup>24</sup> Naveh N, Zborowsky-Gutman L, Blumenthal M: Neodymium: YAG laser iridotomy in angle closure glaucoma: preliminary study. *Br J Ophthalmol* 1987;**71**:257-61.
- <sup>25</sup> Stilma JS, Boen Tan TN: Timolol and intra-ocular pressure elevation following neodymium: YAG laser surgery. *Doc Ophthalmol* 1986;**61**:233-9.
- <sup>26</sup> Kitazawa Y, Taniguchi T, Sugiyama K: Use of apraclonidine to reduce acute intraocular pressure rise following Q-Switched Nd:YAG laser iridotomy. *Ophthalmic Surg* 1989;**20**:49-52.
- <sup>27</sup> Kerr-Muir MG and Sherrard ES: Damage to the corneal endothelium during Nd:YAG photodisruption. *Br J Ophthalmol* 1985;**69**:77-85.
- <sup>28</sup> Canning CR, Capon MR, Sherrard ES, Kerr Muir MG, Pearson R, Cooling R: Neodymium:YAG laser iridotomies: short-term comparison with capsulotomies and long-term follow-up. *Graefes Arch Clin Exp Ophthalmol* 1988;**226**:49-54.
- <sup>29</sup> Smith J and Whitted P: Corneal endothelial changes after argon laser iridotomy. *Am J Ophthalmol* 1984;**98**:153-6.
- <sup>30</sup> Wishart PK, Sherrard ES, Nagasubramanian S, Kerr Muir MG, Hitchings RA: Corneal endothelial changes following short pulsed laser iridotomy and surgical iridectomy. *Trans Ophthalmol Soc UK* 1986;**105**:541-8.
- <sup>31</sup> Markowitz SN and Morin JD: The endothelium in primary angle-closure glaucoma. *Am J Ophthalmol* 1984;**98**:103-4.
- <sup>32</sup> Montgomery DMI and Dutton GN: Correspondence: Intralenticular haemorrhage complicating pulsed laser iridotomy. *Br J Ophthalmol* 1987;**71**:484.
- <sup>33</sup> Krupin T, Mitchell MB, Johnson MF, Becker B: The long term effects of iridectomy for primary acute angle-closure glaucoma. *Am J Ophthalmol* 1978;**86**:506-9.
- <sup>34</sup> Godel V, Regenbogen L: Cataractogenic factors in patients with primary angle-closure glaucoma after peripheral iridectomy. *Am J Ophthalmol* 1977;**83**:180-4.

## **A prospective comparison of Nd:YAG laser iridotomy and surgical peripheral iridectomy in the treatment of acute closed-angle glaucoma**

B.W. Fleck, A. Fairley and C. McGlynn

*Eye Pavilion, Chalmers street, Edinburgh EH3 9HA, Scotland, U.K.*

### **Abstract**

A group of 41 patients presenting with acute closed-angle glaucoma was treated with Nd:YAG laser iridotomy (26 patients) or surgical peripheral iridectomy (15 patients). Prospective assessment was carried out, with a mean follow-up period of 14.8 months (range 3–36 months).

At the end of the follow-up period 88% of laser treated patients and 86% of surgical patients had normal intraocular pressure with no medical therapy. Two laser treated patients and three surgical patients lost more than two lines of visual acuity due to nuclear cataract formation.

Three laser treated patients developed a further attack of closed-angle glaucoma. Two of these patients had an iridotomy less than 100 microns in diameter. The third patient had an angle configuration suggestive of plateau iris syndrome.

It is concluded that Nd:YAG laser iridotomy is a satisfactory alternative to surgical peripheral iridectomy in the treatment of acute closed-angle glaucoma, provided the diameter of the iridotomy is greater than 100 microns.

### **Introduction**

Peripheral iridectomy for closed-angle glaucoma (CAG) was introduced by Pflüger in 1893 [1]. Xenon arc white light [2], ruby laser [3], argon laser [4] and dye laser [5] thermal energy have been used as an alternative means of creating an iridotomy. More recently pulsed Nd:YAG laser photodisruption has been found to be more satisfactory than argon laser thermal energy in creating a permanent iris opening [6].

While large series of cases have been reported describing the use of Nd:YAG laser iridotomy in various forms of closed-angle glaucoma [7,8], relatively little attention has been given to the special problems involved in treating acutely affected eyes [9]. These eyes are often hyperaemic, with some degree of corneal and iris oedema. They exhibit marked pupil block effects.

We have compared the safety and effectiveness of Nd:YAG laser iridotomy and surgical peripheral iridectomy in acute closed-angle glaucoma by undertaking a prospective study of 41 patients.



## Materials and Methods

Forty-one patients presenting with acute or subacute closed-angle glaucoma during a 33-month-period were recruited into an open, prospective study. Twenty-six patients underwent Nd:YAG laser iridotomy and 15 surgical peripheral iridectomy.

### *Laser treatment*

All patients were given acetazolamide 500 mg orally 1 h before treatment. One drop of G. Pilocarpine 2% was instilled 30 min before treatment. A Zeiss Visulas Nd:YAG laser and Zeiss anterior segment YAG contact lens were used in all treatments.

A treatment site was chosen in the superior iris, between 10 and 2 o'clock, approximately two-thirds from the pupil margin to the limbus. An iris crypt was used, when present. A single 5–10 mJ pulse was delivered to the treatment site. If this pulse did not penetrate the iris, further single pulses were delivered to the same site until penetration was achieved. A gush of aqueous fluid from the posterior chamber occurred at the moment of penetration. Patency was assessed by direct visualisation of the posterior chamber or anterior lens capsule.

### *Surgical treatment*

Peripheral iridectomy was carried out using a limbal incision in 10 patients, and a corneal incision in five patients. The iris was grasped with grooved forceps, and an iridectomy was performed with scissors. Limbal incisions were closed with one 8/0 "Vicryl" suture. Corneal incisions were not sutured.

### *Follow-up*

At the 6-month visit indentation gonioscopy, and a modification of the pilocarpine/phenylephrine provocation test described by Mapstone [10] were performed. The intraocular pressure was measured, one drop of G. Pilocarpine 2% and one drop of G. Phenylephrine 10% were instilled and the intraocular pressure was remeasured 1 h later. An intraocular pressure rise of more than 8 mmHg, with angle closure on gonioscopy, was regarded as a positive result.

At the final follow-up visit the size of the iridotomy was estimated by comparison with the 200  $\mu$  spot produced by a Haig Streit slit lamp. Most iridotomies were elliptical, and the surface area of iris patency was calculated using the formula  $\pi/4 \times \text{Diameter 1} \times \text{Diameter 2}$ . The pupil was dilated using G. Phenylephrine 10% in order to detect posterior synechiae and allow examination of the lens and fundus.

Table 1. Patient groups

	Surgery	Laser
Number of patients	15	26
Age	63.6 ± 11.1	71.7 ± 10.5
Male:female	6:9	6:20
Iris colour: grey/brown	6:9	11:15
Follow-up (months)	12.9 ± 16.6	16.6 ± 10.7
Follow-up range (months)	3-35	3-36

Figures express mean ± one standard deviation.

## Results

The two patient groups were very similar, as can be seen in Tables 1 and 2.

### Laser treatment

Primary failure to achieve patency occurred in one patient. The mean number of pulses required to create a patent iridotomy was  $4.2 \pm 5$ . Seven patients required only one pulse. There was no significant difference in the number of pulses required to perforate brown and grey irides ( $4.8 \pm 5.1$  vs.  $3.9 \pm 5.0$ ).

The mean power required to create a patent iridotomy was  $32.3 \pm 35.4$  mJ (range 5-136 mJ). Brown irides did not differ from grey irides ( $37.6 \pm 40.7$  vs.  $29.0 \pm 32.5$ ). In eight patients less than 10 mJ energy was needed to create a patent iridotomy.

Three patients had residual corneal oedema at the time of laser treatment. However the mean number of pulses (1.3) and total power (7.1 mJ) required to create an iridotomy in these patients was not significantly different from that of the group as a whole.

Slight oozing of blood at the treatment site occurred in 13 patients. Focal corneal oedema overlying the treatment site was evident in five patients 24 h following treatment. Focal lens opacities at the treatment site were not evident in any patient.

Table 2. Examination at presentation

	Surgery	Laser
Duration acute attack (h)	33.5 ± 41.5	32.9 ± 17.1
Intraocular pressure at presentation	46.1 ± 15.1	46.3 ± 19.2
Corneal oedema present (patients)	9 (60%)	18 (69%)

Figures express mean ± one standard deviation;

Figures in brackets represent percentage of the group.

### *Surgical treatment*

The posterior pigment layer of the iris remained intact following surgery in one patient, and was subsequently opened using the Nd:YAG laser. No other operative complications occurred.

### *Recurrent acute closed-angle glaucoma*

Three laser treated patients developed a recurrent attack of acute closed-angle glaucoma despite the presence of a patent iridotomy.

*Case 1* developed recurrent acute closed-angle glaucoma 1 month following laser treatment despite a patent, though small ( $100 \times 50 \mu$ ), iridotomy.

*Case 2* had a deep anterior chamber with an angle configuration suggestive of plateau iris syndrome. She developed recurrent acute closed-angle glaucoma 14 days after initial laser iridotomy, while using G. Betamethasone QID and G. Cyclopentolate 1% BD. The iridotomy was patent and of moderate size ( $200 \times 400 \mu$ ).

*Case 3* developed recurrent acute closed-angle glaucoma 1 day following laser iridotomy. The iridotomy was patent but small ( $50 \times 50 \mu$ ).

### *Visual outcome*

Thirteen laser treated patients (50% of the group), and 10 surgically treated patients (67% of the group) had a visual acuity of 6/12 or better at their final follow-up examination. Factors responsible for reduced vision are shown in Table 3.

Two laser patients and two surgical patients lost more than two lines of visual acuity due to the development of nuclear cataract in lenses which were clear prior to treatment. The visual acuity of a further surgical patient fell below the 6/12 level due to progression of pre-existing early nuclear cataract.

Glaucomatous visual loss occurred in one patient who was lost to follow-up for several months following laser treatment.

*Table 3.* Causes of reduced vision at final follow-up visit

	Surgery	Laser
Cataract development/progression	3	2
Pre-existing cataract	0	6
central retinal vein occlusion	0	2
age-related macular degeneration	2	2
amblyopia	0	1
Uncontrolled glaucoma	0	1

### *Glaucoma outcome*

Five laser treated patients and two surgical patients needed topical medication to maintain normal intraocular pressure at the time of their final follow-up visit. However three of the five laser treated patients had an initial diagnosis of subacute closed-angle glaucoma and may have had a more chronic form of the disease, with pre-existing trabecular meshwork damage. Two had pathological cupping of the optic disc at presentation. If patients with an initial diagnosis of subacute closed-angle glaucoma are excluded, 88% of the laser treated patients and 86% of surgically treated patients had normal intraocular pressure without medication at their final follow-up visit.

The mean intraocular pressure at follow-up was  $16.9 \pm 7.4$  mmHg in the laser treated group and  $16.0 \pm 3.7$  mmHg in the surgical group.

### *Gonioscopy*

Indentation gonioscopy was performed at the 6 month follow-up visit. Four laser treated patients had partly closed angles, and two of these needed topical medication to maintain normal intraocular pressure. A further two laser treated patients had small areas of goniosynechiae. Three surgical patients were found to have a partly closed angle on indentation, and one of these needed medication to maintain normal intraocular pressure. Six laser treated patients showed marked pigmentation of the trabecular meshwork inferiorly, a finding not seen in surgical patients. The mean total power used in treating these patients was  $52.3 \pm 48.7$  mJ, compared with  $32.3 \pm 35.4$  mJ for the whole group. This difference is not statistically significant. Three of the patients had brown irides and three had grey irides. One of the six patients needed topical medication to maintain normal intraocular pressure at the time of their final follow-up visit.

### *Provocation tests*

Pilocarpine/phenylephrine provocation tests were performed in all patients at the 6 month follow-up visit. All tests were negative. However, three laser treated patients had sustained a recurrent attack of acute closed-angle glaucoma prior to this visit, as described above.

### *Iridotomy size*

The mean surface area of iris patency following laser iridotomy was  $0.087 \pm 0.124$  mm<sup>2</sup>. The mean surface area of the surgical iridectomies was  $1.22 \pm 0.95$  mm<sup>2</sup>. This difference is statistically highly significant (unpaired Student *t*-test,  $p < 0.001$ ). Three patients had an iridotomy size less than  $100 \mu \times 100 \mu$  ( $0.00785$  mm<sup>2</sup>). Two of these patients developed recurrent closed-angle glaucoma.

## *Posterior synechiae*

Eleven laser-treated patients (42% of the group) and four surgically-treated patients (27% of the group), had posterior synechiae at the time of their final follow-up visit. Only 31% of laser-treated patients received a mydriatic following treatment, compared with 67% of surgical patients, due to concern about the possibility of provoking a further attack of acute closed-angle glaucoma. Of the five patients who lost more than two lines of visual acuity due to cataract, three had posterior synechiae (two laser-treated and one surgically-treated patients).

## **Discussion**

The safety and effectiveness of any treatment for acute closed-angle glaucoma may be assessed by measuring the incidence of recurrent attacks, the long-term visual outcome and long-term glaucoma control. Recurrent attacks of acute CAG are rare following peripheral iridectomy and have generally been attributed to plateau iris syndrome [11]. One of our patients probably had plateau iris syndrome and developed recurrent acute CAG despite the presence of a relatively large, patent iridotomy. The mechanism of failure of very small iridotomies may be different. Below a critical surface area significant iris bombé may occur at certain aqueous flow rates. Recurrent acute CAG has been described following argon laser iridotomy [12] and Nd:YAG laser iridotomy [9] when the iridotomy was very small. The minimum "safe" size of iridotomy has not been defined. Our study suggests that iridotomies must have a size of at least  $100 \times 100 \mu$  in order to prevent recurrent acute CAG.

Visual loss due to cataract development occurred in two laser treated patients and three surgical patients. Floman found two or more lines of visual acuity loss due to cataract in 38% of eyes 1–3 years following surgical peripheral iridectomy for acute CAG [13]. Very little information has been published on cataract development following Nd:YAG laser iridotomy for acute CAG. Our findings suggest there is no significant difference in the rate of cataract development following surgical peripheral iridectomy or Nd:YAG laser iridotomy for acute CAG. Focal lens opacities underlying the treatment site are unusual following Nd:YAG laser iridotomy [6] and were not seen in any of our patients.

Posterior synechiae (PS) may contribute to cataract development following peripheral iridectomy [13]. Floman found loss of two or more lines of visual acuity due to cataract development in 56% of eyes with PS compared to 27% of eyes without PS [13]. PS occurred more commonly in our laser treated group, possibly due to our reluctance to use posttreatment mydriatics.

After excluding subacute closed-angle glaucoma patients, 88% of laser treated patients and 86% of surgically treated patients had normal intraocular pressure without medication at their final follow-up visit. Playfair found 72% of patients had normal intraocular pressure without medication 6 months to 12 years following

surgical peripheral iridectomy [14]. Our figures may be skewed towards milder forms of disease. The study was open and several patients with prolonged attacks of acute closed-angle glaucoma who responded poorly to initial medical treatment underwent primary trabeculectomy during the study period. However, within the study group we found no difference between the effect of surgical peripheral iridectomy or Nd:YAG laser iridotomy on long-term intraocular pressure control. Six laser treated patients had marked pigmentation of the inferior trabecular meshwork 6 months following treatment, but this had no effect on intraocular pressure control. A similar number of patients in each group were found to have areas of closed-angle on indentation gonioscopy 6 months following treatment.

We have found that visual outcome and glaucoma control are similar following surgical peripheral iridectomy or Nd:YAG laser iridotomy for acute closed-angle glaucoma. The risk of recurrent acute closed-angle glaucoma is high if a laser iridotomy is smaller than  $100 \times 100 \mu$  in size. We are currently undertaking a large long-term randomised comparison of Nd:YAG laser iridotomy and surgical peripheral iridectomy in the treatment of acute closed-angle glaucoma.

## References

1. Pfluger E (1893-94) *Arch. Ophthalmol.* 1: 321.
2. Meyer-Schwickerath C (1956) *Doc. Ophthalmol.* 10: 119-131.
3. Perkins ES and Brown NAP (1973) *Br. J. Ophthalmol.* 57: 487-498.
4. Abraham RK and Miller GL (1975) *Trans. Am. Acad. Ophthalmol. Otolaryngol.* 79: 529-538.
5. Bass MS, Cleary CV, Perkins ES and Wheeler CB (1979) *Br. J. Ophthalmol.* 63: 29-30.
6. Del Priore LV, Robin AL and Pollack IP (1988) *Ophthalmology* 95: 1207-1211.
7. Schwartz LW, Moster MR, Spaeth GL, Wilson RP and Poryzees E (1986) *Am. J. Ophthalmol.* 102: 41-44.
8. Tomey KF, Traverso CE and Shammas IV (1987) *Arch. Ophthalmol.* 105:476-481.
9. Gray RH, Hoare Nairn J and Ayliffe WHR (1989) *Br. J. Ophthalmol.* 73: 182-185.
10. Mapstone R (1981) *Br. J. Ophthalmol.* 65: 410-413.
11. Wand M, Grant WM, Simmons RJ and Hutchinson BT (1977) *Trans. Am. Acad. Ophthalmol. Otolaryngol.* 83: 122-130.
12. Brainard JO, Landers JH and Shock JP (1982) *Ophthalm. Surg.* 13: 1030-1032.
13. Floman N, Berson D and Landau L (1977) *Br. J. Ophthalmol.* 61: 101-104.
14. Playfair TJ and Watson PG (1979) *Br. J. Ophthalmol.* 63: 17-22.

# How large must an iridotomy be?

B W Fleck

## Abstract

Four cases of acute angle closure glaucoma in eyes with a small but patent Nd-YAG laser iridotomy are presented, and similar cases in the literature are reviewed. Theoretically a 15  $\mu\text{m}$  diameter iridotomy should be large enough to prevent angle closure glaucoma due to pupil block. Mechanisms by which larger iridotomies fail to prevent angle closure glaucoma, and the role of provocation tests following iridotomy, are discussed. An iridotomy should be at least 150-200  $\mu\text{m}$  in diameter if acute angle closure glaucoma is to be reliably prevented.

Various forms of iris surgery have been used to treat angle closure glaucoma since von Graefe's original description of the broad iridectomy in 1857.<sup>1</sup> Surgical iridotomy was introduced by Curran in 1920.<sup>2-4</sup> Peripheral iridectomy was described by Chandler in 1952.<sup>5</sup> Argon laser iridotomy,<sup>6</sup> and more recently Nd-YAG laser iridotomy,<sup>7</sup> have already largely superseded surgical iridectomy. While laser surgery has many advantages over conventional surgery, it must not be forgotten that laser iridotomy represents a return to the use of smaller iris openings than those obtained by surgical peripheral iridectomy.<sup>8</sup> Gifford noted in 1921 that very small surgical iridotomies were not as effective in controlling intraocular pressure as larger iridotomies.<sup>4</sup>

Reports are now emerging of acute angle closure glaucoma developing in the presence of a small but patent argon<sup>9,10</sup> or Nd-YAG<sup>11,12</sup> laser iridotomy. While cases of acute angle closure glaucoma following surgical peripheral iridectomy have generally been attributed to plateau iris syndrome,<sup>13-15</sup> not all cases of acute angle closure glaucoma following a small laser iridotomy can be placed in this category.<sup>9-12</sup> We have treated four patients who developed acute angle closure glaucoma despite the presence of a patent Nd-YAG laser iridotomy.

The mechanism of failure of very small iridotomies may be related to obstruction of aqueous flow at very small iridotomy size. Below a critical surface area significant iris bombé may occur at normal aqueous flow rates. When iris bombé is sufficient to cause iridocorneal contact throughout a critical extent of the angle, beginning superiorly, acute angle closure glaucoma results.<sup>16,17</sup> The minimum 'safe' size of iridotomy has not been defined, but an approximate value may be calculated from a simple mathematical model.

## Material and methods

We are undertaking a prospective randomised comparison of Nd-YAG laser iridotomy and

surgical peripheral iridectomy in the treatment of acute angle closure glaucoma. The cases presented belong to the laser treated group in this study.

A Zeiss Visulas Nd-YAG laser and Zeiss anterior segment YAG contact lens were used in all treatments. Patients were given acetazolamide 500 mg orally one hour before treatment, and one pilocarpine eyedrop 2% 30 minutes before treatment.

A treatment site was chosen in the superior iris between 10 and 2 o'clock, approximately two-thirds of the distance from the pupil margin to the base of the iris. An iris crypt was used, when present. A single 5-10 mJ pulse was delivered to the treatment site. If this pulse did not penetrate the iris, further single pulses were delivered to the same site until penetration was achieved. A gush of aqueous fluid from the posterior chamber could be seen at the moment of penetration. Patency was assessed by direct observation of the posterior chamber or anterior lens capsule.

The size of iridotomies was measured by comparison with the 0.2 mm spot produced by a Haag-Streit slit-lamp focused on the iris plane.

## Results: case reports

### CASE I

A 75-year-old hypermetropic man presented with right acute angle closure glaucoma of 48 hours' duration. The intraocular pressure was 78 mmHg, the anterior chamber was shallow, and the angle was closed throughout 360°. The left eye had a very narrow, open angle. Treatment with acetazolamide 500 mg intravenously and pilocarpine eyedrops 2% hourly resulted in a fall in intraocular pressure to 12 mmHg, with an open angle throughout 360°. Nd-YAG laser iridotomy was performed three days later. A treatment site 1 mm from the limbus at 10 o'clock was chosen. The iris was a light grey colour, with no crypts. Three 9.0 mJ pulses resulted in a small (200 $\times$ 100  $\mu\text{m}$ ) patent iridotomy. Minimal iris bleeding occurred at the time of treatment, but there were no other complications. One week after treatment the iridotomy was patent, though small. The intraocular pressure was 10 mmHg. No further eye medication was prescribed.

Two weeks after treatment the patient complained of blurred vision in the right eye. The intraocular pressure was 68 mmHg, and gonioscopy revealed 300° of angle closure superiorly. Medical treatment with topical pilocarpine 2% and timolol 0.5% reduced the intraocular pressure to 13 mmHg, with an open angle. The iridotomy was small (50 $\times$ 100  $\mu\text{m}$ ) but patent. Trabeculectomy with peripheral iridectomy was performed, leading to an intraocular pressure of 10 mmHg, and 6/5 visual acuity.

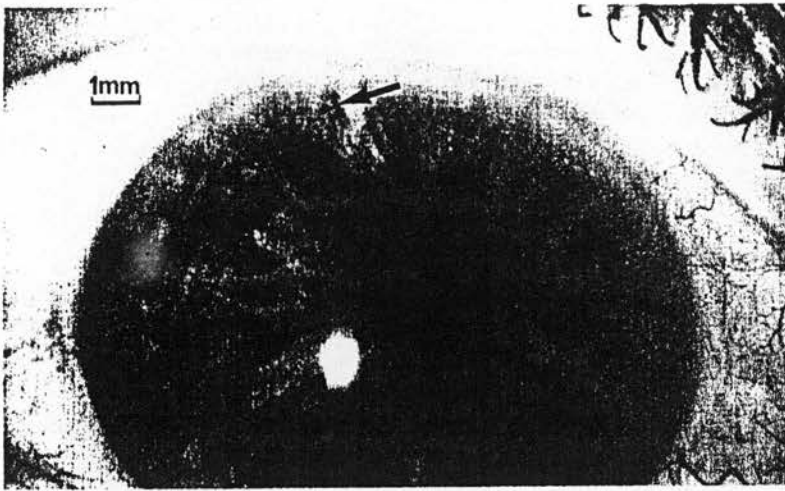


Figure 1 Case 2. Initial iridotomy size too small. Acute angle closure glaucoma developed. Iridotomy diameter 50  $\mu\text{m}$ . The arrow indicates the very small area of full thickness opening at the centre of the treatment site.

#### CASE 2

A 65-year-old woman presented with left acute angle closure glaucoma of 24 hours' duration. The intraocular pressure was 58 mmHg, the anterior chamber was shallow, and the angle was closed throughout 360°. The right anterior chamber was shallow, with 120° of angle closure superiorly, and the intraocular pressure was 15 mmHg.

After initial medical control left trabeculectomy was performed.

Further examination of the right eye after treatment with pilocarpine eyedrops 2% revealed an open angle throughout 360°. Right Nd-YAG laser iridotomy was performed. The treatment site was 1 mm from the limbus, at 10 o'clock. The iris was brown, with no crypts. Four 9.7 mJ pulses were used to produce a patent iridotomy, and a further single 9.7 mJ pulse was used to enlarge the opening.

One week later the iridotomy was patent, though small. The intraocular pressure was 14 mmHg. At review three weeks later the right intraocular pressure was found to be 41 mmHg, and the pupil was dilated. Gonioscopy was not

performed. The patient had been using cyclopentolate 1% drops to the left eye, and may have inadvertently contaminated the right eye. After treatment with pilocarpine eyedrops 2% the intraocular pressure returned to 16 mmHg. The iridotomy was patent, but small – 50×50  $\mu\text{m}$  (Fig 1). Further laser treatment was given to enlarge the opening. Five 2.0 mJ Nd-YAG pulses were delivered to the sides of the existing iridotomy, enlarging the opening to 100×100  $\mu\text{m}$ . After this treatment, eyedrops of Beta-methasone 0.1% four times a day and tropicamide 1% once daily were prescribed. The patient returned four days later complaining of pain and reduced vision in the right eye. The intraocular pressure was 50 mmHg, and the pupil was mid-dilated and unreactive. The iridotomy was now situated very peripherally, with iris strands running forwards to the cornea, but appeared to be patent. Gonioscopy was not performed. The intraocular pressure returned to normal after treatment with acetazolamide 500 mg intravenously, and pilocarpine eyedrops 2% hourly. The iridotomy was patent, but small (100×100  $\mu\text{m}$ ). The angle was open on gonioscopy. Treatment with pilocarpine eyedrops 2% four times a day was prescribed.

A pilocarpine/phenylephrine provocation test as described by Mapstone<sup>18</sup> was performed on the right eye one week later and was negative.

Intermittent aching pain above the right eye continued, and further Nd-YAG laser enlargement of the iridotomy was performed six weeks later. Twenty-one 1.1 mJ pulses were delivered by means of a Wise 103-dioptre contact lens, resulting in some oozing of blood. A further 10 1.0 mJ pulses were delivered 30 minutes later. The resulting iridotomy measured 200×200  $\mu\text{m}$ .

One week later all symptoms had resolved, and the iridotomy measured 100×200  $\mu\text{m}$ . Pilocarpine/phenylephrine testing was again negative. However, provocation with Tropicamide eyedrops 1% produced a rise of 9 mmHg in IOP, with folds of iris blocking the trabecular meshwork over 270° on gonioscopy. At follow-up three weeks later the intraocular pressure was 17 mmHg, with no medication (Fig 2).

#### CASE 3

An 83-year-old woman presented with intermittent pain in the left eye. The intraocular pressure was 44 mmHg, the anterior chamber was deep, and Goldmann gonioscopy revealed 90° of angle closure superotemporally. The plane of the iris was flat, with an anteriorly placed iris insertion. The right eye had a similar angle configuration, with normal intraocular pressure. Plateau iris configuration was diagnosed. Intraocular pressure in the left eye quickly returned to normal after treatment with acetazolamide 500 mg orally and pilocarpine eyedrops 2% hourly. Gonioscopy revealed 180° of angle closure superiorly. Nd-YAG laser iridotomy was performed three days later. The iris was light grey, with no crypts. A treatment site 1 mm from the limbus at 2 o'clock was selected. Four 10.9 mJ pulses produced a moderately large (200×400  $\mu\text{m}$ ) patent iridotomy. There was minimal iris bleeding at the time of treatment.

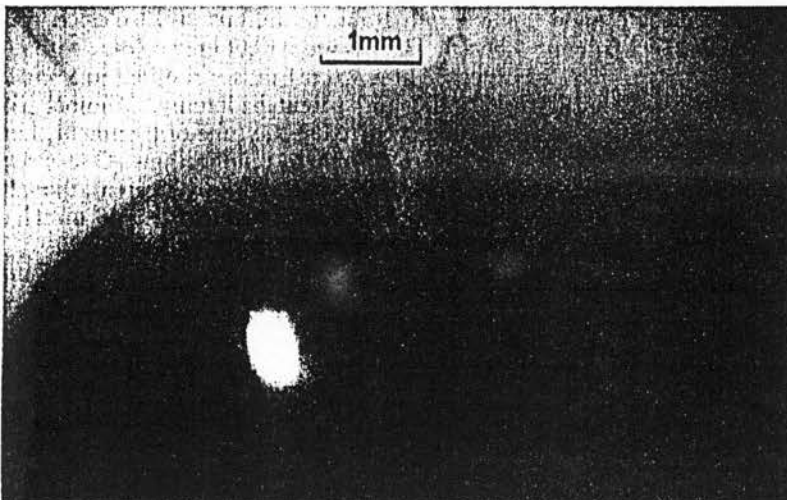


Figure 2 Case 2. Following laser enlargement all symptoms resolved and provocation testing was negative. Iridotomy diameter 200  $\mu\text{m}$ .



After this treatment, eyedrops of Timolol 0.5% twice daily, cyclopentolate 1% twice daily, and betamethasone 0.1% four hourly were prescribed. Fourteen days later the patient returned with pain and reduced vision of 24 hours' duration in the left eye. The intraocular pressure was 50 mmHg. After treatment with Pilocarpine eyedrops 2% and timolol eyedrops 0.5% the intraocular pressure fell to 7 mmHg. The iridotomy was patent and moderately large (200×400 μm). Identification gonioscopy revealed goniosynechia over 150° superiorly, with plateau iris configuration. A sector iridectomy was performed. On further follow-up the intraocular pressure in the left eye was found to be 28 mmHg on no treatment, falling to 21 mmHg on addition of timolol eyedrops 0.5% twice daily. Gonioscopy revealed an open angle throughout 360°.

#### CASE 4

A 71-year-old hypermetropic woman presented with left acute angle closure glaucoma of eight hours' duration. The intraocular pressure was 46 mmHg and the anterior chamber was shallow. The right eye had a normal intraocular pressure and a shallow anterior chamber. After medical treatment with acetazolamide 500 mg intravenously and pilocarpine eyedrops 2% hourly the left intraocular pressure fell to 9 mmHg within two hours. Goldmann gonioscopy revealed 150° of angle closure superiorly. The right eye also had a very narrow angle, with 150° of angle closure superiorly.

Nd-YAG laser iridotomy was attempted in the left eye the next day. The iris was brown, with no crypts. Three 9.9 mJ pulses were delivered to two sites, with no penetration. Three days later four 10.2 mJ pulses were delivered, two to each of the previous treatment sites. The final pulse produced a very small, patent iridotomy at 2 o'clock, in the mid iris position. A single enlarging pulse of 9.2 mJ was delivered to this site on the following day. A very small (50 μm) iridotomy resulted. The patient was discharged home with betamethasone eyedrops 0.1% twice daily and cyclopentolate eyedrops 1% once daily to the left eye.

She returned six days later complaining of severe pain in the left eye. The intraocular pressure was 45 mmHg, and the anterior chamber was very shallow. The iridotomy was patent but very small. The intraocular pressure quickly fell to 8 mmHg after treatment with

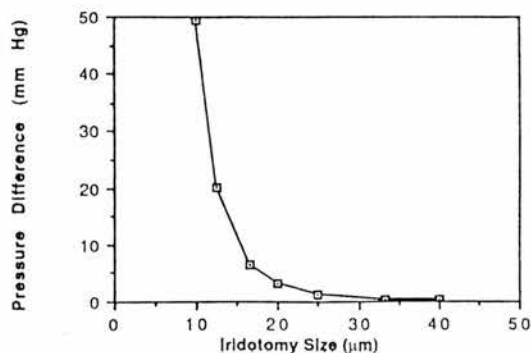


Figure 3 Pressure difference across the iris as a function of iridotomy size.

acetazolamide 500 mg intravenously and pilocarpine eyedrops 2% hourly. A surgical peripheral iridectomy was performed the next day.

Postoperatively the patient was treated with betamethasone eyedrops 0.1% four times daily and tropicamide eyedrops 1% once daily. Two days later she complained of pain over the left eye. The pupil was dilated, and the peripheral iridectomy was patent. The intraocular pressure was 41 mmHg. Gonioscopy was not tolerated. The intraocular pressure fell to 10 mmHg after treatment with acetazolamide 250 mg orally twice daily, pilocarpine eyedrops 2% four times daily, and timolol eyedrops 0.5% twice daily. Long term treatment with pilocarpine eyedrops 2% four hourly and timolol eyedrops 0.5% twice daily has been necessary to maintain normal intraocular pressure in the left eye.

#### MATHEMATICAL MODEL

A very small iridotomy may be of inadequate physical size to by-pass pupil block adequately. Given a constant rate of aqueous flow, the pressure difference across an iridotomy increases as the size of the iridotomy decreases. Increased posterior chamber pressure relative to anterior chamber pressure will result in iris bombé. The degree of bombé is dependent on the rigidity of the iris and the pressure difference across the iris. At a critical level, dependent on peripheral anterior chamber depth, iris bombé may become sufficient to cause iridocorneal contact over a large enough extent of the angle to precipitate acute angle closure glaucoma.<sup>16 17 19 20</sup>

The minimum 'safe' size of an iridotomy may be calculated from a simple mathematical model. Firstly, an assessment is made as to whether aqueous flow is laminar or turbulent through an iridotomy aperture of 10 μm. On the assumption that aqueous viscosity equals the viscosity of water ( $\eta=10^{-3}$  Newton seconds per square metre), aqueous density equals the density of water ( $\rho=1000$  kilograms per cubic metre), and aqueous flow,  $Q$ , is approximately 2 μl per minute ( $3.3 \times 10^{-11}$  cubic metres per second), as measured by Bloom *et al*,<sup>21</sup> then Reynolds' number for the system may be calculated.

If the iridotomy size ( $d$ ) is 10 μm diameter, the aqueous velocity

$$v = \text{flow}/\pi r^2 = 4.2 \times 10^{-1} \text{ ms}^{-1}.$$

Reynolds' number for the system

$$R = \rho v d / \eta, R = 42.$$

If  $R$  is considerably less than 1000, flow is laminar. Aqueous flow through an iridotomy of diameter 10 μm or larger will be laminar.

Secondly, the iridotomy channel may be considered to be a pipe of length 50 μm on the assumption that the peripheral iris thickness is 50 μm. The pressure drop ( $pd$ ) along a pipe of length  $l=50$  μm, diameter  $d=100$  μm, at flow rate  $Q$  is expressed by the formula:

$$\begin{aligned} pd &= 128\eta l Q / \pi d^4 \\ &= 128 \times 10^{-3} \times 5 \times 10^{-5} \times 3.3 \times 10^{-11} / 3.142 \times 10^{-16} \\ &= 0.672 \text{ Nm}^{-2} \\ &= 0.00494 \text{ mmHg, as } 1 \text{ mmHg} = 136 \text{ Nm}^{-2}. \end{aligned}$$

An iridotomy of 100 μm diameter will have a pressure drop of 0.00494 mmHg across it on the assumption of total pupil block.

However, as  $pd$  is proportional to  $1/d^4$ , if the diameter of the iridotomy were  $50\ \mu\text{m}$   $pd$  would be  $0.079\ \text{mmHg}$ , under the same conditions. If the iridotomy were  $25\ \mu\text{m}$ , the  $pd$  would be  $1.27\ \text{mmHg}$ . If the iridotomy were  $12.5\ \mu\text{m}$ , the  $pd$  would be  $20.2\ \text{mmHg}$ , and if the iridotomy were  $10\ \mu\text{m}$  the  $pd$  would be  $49.4\ \text{mmHg}$ . It is not difficult to conceive that a pressure difference of  $10\text{--}20\ \text{mmHg}$  across the iris could result in significant iris bombé, with iridocorneal contact and angle closure. Such a pressure difference could develop if the size of the iridotomy was between  $10$  and  $15\ \mu\text{m}$  in diameter (Fig 3).

### Discussion

Curran observed in 1920 that in some patients with glaucoma the passage of aqueous through the pupil appeared to be impeded by the iris 'hugging the lens over too great a surface extent'.<sup>2</sup> Surgical iridotomy allowed free drainage of fluid from the posterior chamber to the anterior chamber, with posterior movement of the iris and a reduction in intraocular pressure. Barkan elaborated the concept of pupil block as the causative mechanism of iris bombé, with resulting angle closure.<sup>22</sup> A peripheral iridectomy causes 'collapse' of iris bombé, resulting in widening of the 'entrance' to the angle.<sup>22</sup> Peripheral anterior chamber depth, but not central anterior chamber depth, increases following peripheral iridectomy<sup>17,23,24</sup> owing to resolution of iris bombé.

Failure of surgical peripheral iridectomy, or laser iridotomy, as evidenced by development of acute angle closure glaucoma, may occur by one of two mechanisms. A small number of cases of angle closure glaucoma are related to 'plateau iris configuration' – an anteriorly placed iris root, flat iris plane, and a normal or near normal anterior chamber depth. Pupil dilatation results in peripheral iris bunching, with occlusion of the trabecular meshwork.<sup>13,25</sup> As pupil block is not causative, surgical peripheral iridectomy or laser iridotomy are relatively ineffective in preventing further attacks of acute angle closure glaucoma. One of our patients (case 3) probably had plateau iris syndrome, and developed acute angle closure glaucoma following mydriasis despite the presence of a relatively large, patent iridotomy.

Case 4 developed acute angle closure glaucoma following mydriasis despite the presence of a small patent iridotomy and subsequently a larger surgical iridectomy. The mechanism of acute intraocular pressure rise may have been iris crowding in the angle. Plateau iris configuration was not present. Perhaps the term 'angle crowding' angle closure glaucoma would be a more appropriate term to use for eyes which develop acute angle closure glaucoma following mydriasis in the presence of a patent peripheral iridectomy. The cases of two other patients with moderately large peripheral iridectomies who developed acute angle closure glaucoma while using mydriatic drops have been reported.<sup>14,15</sup>

Mydriatic or dark room provocation tests following peripheral iridectomy have been found to be positive in  $3\text{--}19\%$  of cases.<sup>25,28</sup> Gonioscopy at the end of a positive test in eyes with patent peripheral iridectomies has revealed angle

closure in some cases, due to angle crowding.<sup>25,29</sup> However, in other eyes the angle has been open.<sup>25,27</sup> Raised intraocular pressure in these eyes may be explained by the outflow facility lowering effect of anticholinergic drugs.<sup>30</sup> Surgical peripheral iridectomy appears entirely to overcome pupil block. No cases of acute angle closure glaucoma due to iris bombé have been reported in the presence of a patent surgical iridectomy.

Mydriatic provocation tests following argon laser iridotomy<sup>31,32</sup> and Nd-YAG laser iridotomy<sup>33</sup> have given similar results to those performed following surgical peripheral iridectomy. However, pilocarpine/phenylephrine tests have been negative in all eyes tested following argon laser iridotomy<sup>31</sup> or Nd-YAG laser iridotomy.<sup>32</sup> The test produces only moderate mydriasis, and increased tone in both the sphincter and dilator muscles of the iris may prevent angle crowding. The test induces maximal pupil block,<sup>35</sup> and failure to obtain any positive results suggests that pupil block was fully overcome in all cases tested.

Acute angle closure glaucoma in the presence of a small, patent argon laser iridotomy has previously been reported in two patients.<sup>9,10</sup> Mandelkorn *et al* reported a case of acute angle closure glaucoma following a  $50\ \mu\text{m}$  diameter argon laser iridotomy.<sup>9</sup> Further argon laser treatment was applied to the site, resulting in satisfactory long term pressure control. Brainard reported a similar case, in an eye with a  $75\ \mu\text{m}$  diameter argon laser iridotomy.<sup>10</sup> Further argon laser treatment to enlarge the iridotomy to  $125\ \mu\text{m}$  resulted in satisfactory long term intraocular pressure control, suggesting inadequate iridotomy size was responsible for initial failure.

Acute angle closure glaucoma has also been reported in the presence of a small, but patent Nd-YAG laser iridotomy.<sup>11,12,33</sup> Brazier reported two cases. One was treated by surgical peripheral iridectomy, with no further complications. The second was treated with miotics.<sup>11</sup> Wishart and Hitchings reported two cases of acute angle closure glaucoma and two cases of subacute angle closure glaucoma in the presence of patent Nd-YAG laser iridectomies.<sup>33</sup> In three cases the iridotomy was  $100\ \mu\text{m}$  diameter and in the fourth  $150\ \mu\text{m}$ . Gray *et al* reported two cases of acute angle closure glaucoma in the presence of a small, patent iridotomy.<sup>12</sup> One developed acute angle closure glaucoma while using pilocarpine eye drops  $4\%$ , and was treated by trabeculectomy. The second was treated by a further iridotomy. Intraocular pressure subsequently remained normal in both cases. Two of our cases (cases 1 and 2) behaved in a very similar way to the two cases reported by Gray *et al*. Case 1 responded to trabeculectomy, and case 2 responded to laser enlargement of the iridotomy. The occurrence of acute angle closure glaucoma in the presence of a small, but patent, iridotomy which responds to surgical peripheral iridectomy or laser enlargement, suggests the size of the initial iridotomy was inadequate.

Wishart studied iris bombé using slit-lamp photographic assessment of peripheral anterior chamber depth. In four eyes with very small iridectomies and progressive narrowing of the

angle, repeat laser iridotomy resulted in deepening of the peripheral anterior chamber.<sup>33</sup> This study provides further evidence that very small iridotomies may not fully relieve iris bombé.

We have calculated that the minimum functional iridotomy size should be approximately 15  $\mu\text{m}$ , as previously suggested by Wheeler.<sup>36</sup> However, our clinical experience, and that of others,<sup>9-12, 33</sup> shows that iridotomies in the range of 50–150  $\mu\text{m}$  diameter may fail to prevent acute angle closure glaucoma.

Several factors may contribute to the reduction in size of an iridotomy of theoretically 'safe' size below that needed to prevent acute angle closure glaucoma. Most cases of acute angle closure glaucoma following Nd-YAG laser iridotomy have occurred within one month of treatment. Naveh *et al* observed rapid diminution of Nd-YAG laser iridotomy size within an hour of treatment in six eyes.<sup>37</sup> In each case a return to original treatment size occurred within two weeks. Localised iris oedema round the treatment site could be responsible.

Re-closure of Nd-YAG laser iridotomies due to iris pigment epithelium proliferation is unusual, and tends to occur 1–4 months after treatment.<sup>11, 12, 33, 37, 38</sup> Re-closure resulted in acute angle closure glaucoma in two eyes reported on by Wishart and Hitchings<sup>33</sup> and one eye reported on by Gray *et al*.<sup>12</sup>

Case 2 developed acute angle closure glaucoma following mydriasis. Pupil dilatation might reduce the surface area of some iridotomies, and folds of iris tissue might functionally block an iridotomy when the pupil is dilated. Mydriatics might therefore produce acute angle closure glaucoma in the presence of a patent iridotomy by two mechanisms – pupil block due to reduction of iridotomy size, and angle crowding.

To answer the question, How large must an iridotomy be to prevent acute angle closure glaucoma? several factors must be considered. In forms of angle crowding angle closure glaucoma, such as plateau iris syndrome, a large iridotomy will not prevent the development of acute angle closure glaucoma following mydriasis, as pupil block is not causative.

Theoretical modelling suggests an iridotomy of 10–15  $\mu\text{m}$  diameter will prevent angle closure glaucoma due to pupil block. However, an iridotomy of greater size may fall below this critical level due to early post-treatment oedema, late pigment epithelium proliferation, or pupil dilatation. Wishart and Hitchings reported subacute angle closure glaucoma in an eye with a 150  $\mu\text{m}$  diameter iridotomy.<sup>33</sup> All other cases of acute angle closure glaucoma in the presence of a patent iridotomy have occurred in eyes with an iridotomy of less than 100  $\mu\text{m}$  in diameter. The smallest potentially safe size of an iridotomy would therefore appear to be 100  $\mu\text{m}$ . However, in order to incorporate a safety margin, we would recommend that iridotomies should be at least 150–200  $\mu\text{m}$  in diameter.

Provocation tests have not been helpful in identifying eyes at risk, as eyes developing acute angle closure glaucoma following Nd-YAG laser iridotomy have done so before a provocation test had been performed.<sup>8, 12, 33</sup> If provocation tests are to be employed, we suggest the use of tropi-

camide eyedrops 1% soon after the iridotomy has been performed, in order to detect cases at risk of developing acute angle closure glaucoma. Routine pupil dilatation to prevent posterior synechiae formation following laser iridotomy may be more safely achieved with phenylephrine eyedrops 10%, with measurement of intraocular pressure following dilatation. Lowe has shown that phenylephrine very rarely results in a rise in intraocular pressure following peripheral iridectomy,<sup>15</sup> and the effect may be quickly reversed using thymoxamine eyedrops 0.5% if a pressure rise does occur.

Dr N A Fleck, Department of Engineering, University of Cambridge, developed the mathematical model. Professor C I Phillips and Dr J F Cullen, Department of Ophthalmology, Edinburgh Royal Infirmary, made helpful comments during preparation of the manuscript. Mr Stuart Cairns, ophthalmic photographer, assisted in preparation of the illustrations.

This paper forms part of an ongoing research programme funded by the W H Ross Foundation.

- 1 Von Graefe A. Über die Iridectomie bei Glaucoma und über den glaucomatosen Process. *Graefes Arch Clin Exp Ophthalmol* 1857; 3: 456–555.
- 2 Curran EJ. A new operation for glaucoma involving a new principle in the aetiology and treatment of chronic primary glaucoma. *Arch Ophthalmol* 1920; 49: 131–55.
- 3 Curran EJ. Peripheral iridotomy in acute and chronic glaucoma: some results after 10 years duration. Anatomical classification of glaucoma. *Trans Ophthalmol Soc UK* 1931; 51: 520–38.
- 4 Gifford H. Peripheral iridotomy (Curran) in the treatment of glaucoma. *Am J Ophthalmol* 1921; 4: 889–94.
- 5 Chandler PA. Narrow angle glaucoma. *Arch Ophthalmol* 1952; 47: 695–716.
- 6 Abraham RK, Miller GL. Outpatient argon laser iridectomy for angle closure glaucoma: a two year study. *Ophthalmology* 1975; 79: OP529–38.
- 7 Frankhauser F, Roussel P, Steffen J, Van Der Zypen E, Chrenkova A. Clinical studies on the efficiency of high power laser radiation upon some structures of the anterior segment of the eye. First experience of the treatment of some pathological conditions of the anterior segment of the human eye by means of a Q-switched laser system. *Int Ophthalmol* 1981; 3: 129–39.
- 8 Fleck BW, Fairley A, McGlynn C. A prospective comparison of Nd:YAG laser iridotomy and surgical peripheral iridectomy in the treatment of acute angle closure glaucoma. *Proceedings of the XXVI International Congress of Ophthalmology*. Singapore (in press).
- 9 Mandelkorn R, Mendelsohn A, Olander K, *et al*. Short exposure times in argon laser iridotomy. *Ophthalmic Surg* 1981; 12: 805–9.
- 10 Brainard JO, Landers JH, Shock JP. Recurrent angle closure glaucoma following a patent 75-micron laser iridotomy: a case report. *Ophthalmic Surg* 1982; 13: 1030–2.
- 11 Brazier DJ. Neodymium-YAG laser iridotomy. *J R Soc Med* 1989; 79: 658–60.
- 12 Gray RH, Hoare Nairn J, Ayliffe WHR. Efficacy of Nd-YAG laser iridotomies in acute angle-closure glaucoma. *Br J Ophthalmol* 1989; 73: 182–5.
- 13 Wand M, Grant WM, Simmons RJ, Hutchinson BT. Plateau iris syndrome. *Ophthalmology* 1977; 83: 122–30.
- 14 Douglas WHG, Strachan IM. Surgical safety of prophylactic peripheral iridectomy. *Br J Ophthalmol* 1967; 51: 459–62.
- 15 Lowe RF. Primary angle-closure glaucoma: postoperative acute glaucoma after phenylephedrine eyedrops. *Am J Ophthalmol* 1968; 65: 552–4.
- 16 Phillips CI. Sectorial distribution of goniosynechiae. *Br J Ophthalmol* 1956; 40: 129–35.
- 17 Phillips CI. Closed-angle glaucoma. Significance of sectorial variations in angle depth. *Br J Ophthalmol* 1956; 40: 136–43.
- 18 Mapstone R. Provocative tests in closed-angle glaucoma. *Br J Ophthalmol* 1976; 60: 115–9.
- 19 Bhargava SK, Leighton DA, Phillips CI. Early angle-closure glaucoma. Distribution of iridotrabecular contact and response to pilocarpine. *Arch Ophthalmol* 1973; 89: 369–72.
- 20 Mapstone R. One gonioscopic fallacy. *Br J Ophthalmol* 1979; 63: 221–4.
- 21 Bloom JN, Levene RZ, Thomas G, Kimura R. Fluorophotometry and the rate of aqueous flow in man. *Arch Ophthalmol* 1976; 94: 435–43.
- 22 Barkan O. Iridectomy in narrow angle glaucoma. *Am J Ophthalmol* 1954; 37: 504–19.
- 23 Jacobs III, Krohn DL. Central anterior chamber depth after laser iridectomy. *Am J Ophthalmol* 1980; 89: 865–7.
- 24 Lee DA, Brubaker RF, Ilstrup DM. Anterior chamber dimensions in patients with narrow angles and angle-closure glaucoma. *Arch Ophthalmol* 1984; 102: 46–50.
- 25 Lowe RF. Primary angle closure glaucoma – investigations after surgery for pupil block. *Am J Ophthalmol* 1964; 57: 931–8.
- 26 Harris LS, Galin MA. Cycloplegic provocative testing. *Arch Ophthalmol* 1969; 81: 356–8.

- 27 Friedman Z, Neumann E. Comparison of prone position, dark room, and mydriatic tests for angle closure glaucoma before and after peripheral iridectomy. *Am J Ophthalmol* 1972; 74: 24-7.
- 28 Hung PT, Chou LH. Provocation and mechanism of angle-closure glaucoma after iridectomy. *Arch Ophthalmol* 1979; 97: 1862-4.
- 29 Godel V, Stein R, Feiler-Ofrey V. Angle-closure glaucoma following peripheral iridectomy and mydriasis. *Am J Ophthalmol* 1968; 65: 555-60.
- 30 Harris LS. Cycloplegic induced intraocular pressure elevations. *Arch Ophthalmol* 1968; 79: 242-6.
- 31 Karmon G, Vender T, Savir H. Evaluation of laser iridectomy in angle-closure glaucoma: provocative tests. *Br J Ophthalmol* 1982; 66: 471-3.
- 32 Yassur Y, Melamed S, Cohen S, Ben-Sira I. Laser iridotomy in closed angle glaucoma. *Arch Ophthalmol* 1979; 97: 1920-1.
- 33 Wishart PK, Hitchings RA. Neodymium YAG and dye laser iridotomy - a comparative study. *Trans Ophthalmol Soc UK* 1986; 105: 521-40.
- 34 Harrad RA, Stannard KP, Shilling JS. Argon Laser iridotomy. *Br J Ophthalmol* 1985; 69: 368-72.
- 35 Mapstone R. Mechanics of pupil block. *Br J Ophthalmol* 1968; 52: 19-25.
- 36 Wheeler CB. Laser iridectomy. *Phys Med Biol* 1977; 6: 1115-35.
- 37 Naveh N, Zborowsky-Gutman L, Blumenthal M. Neodymium-YAG laser iridotomy in angle closure glaucoma: preliminary study. *Br J Ophthalmol* 1987; 71: 257-61.
- 38 McAllister JA, Schwartz LW, Moster M, Spaeth GL. Laser peripheral iridectomy comparing Q-switched neodymium YAG with argon. *Trans Ophthalmol Soc UK* 1985; 104: 67-9.

# Argon Laser Pretreatment 4 to 6 Weeks Before Nd:YAG Laser Iridotomy

B.W. Fleck, MBChB, FRCS  
E. Wright, MBChB, DCH  
C. McGlynn, AMILT

## ABSTRACT

Argon laser pretreatment followed by Nd:YAG laser iridotomy 4 to 6 weeks later was performed in the right eye of 10 patients. Primary Nd:YAG laser iridotomy was performed in the left eye. Significantly more Nd:YAG laser energy was needed to produce an iridotomy in pretreated eyes ( $P < .001$ ). Pretreated eyes developed a significantly larger pigment epithelium defect around the iridotomy site and a greater degree of pigmentation of the inferior part of the trabecular meshwork 6 months following treatment. Argon laser pretreatment followed by Nd:YAG laser iridotomy 4 to 6 weeks later appears to offer no advantages over primary Nd:YAG laser iridotomy.

Several authors have commented on the relative ease with which Nd:YAG laser iridotomy may be performed at the site of a failed argon laser iridotomy.<sup>1-3</sup> This has also been our experience. In order to investigate the possibility of using planned argon laser pretreatment prior to Nd:YAG laser iridotomy, we undertook a prospective study in 10 patients in which argon laser pretreatment was performed in the right eye, followed by Nd:YAG laser iridotomy 4 to 6 weeks later. Primary Nd:YAG laser iridotomy was performed in the left eye.

## MATERIALS AND METHODS

The study was approved by the unit ethical committee, and informed patient consent was obtained from all

*From the Department of Ophthalmology, Royal Infirmary, Edinburgh, Scotland.*

*Reprint requests should be addressed to B.W. Fleck, MBChB, FRCS, Department of Ophthalmology, Royal Infirmary, Edinburgh EH3 9HA, Scotland.*

subjects. Ten consecutive patients referred for laser iridotomy were recruited. Patients with acute angle closure glaucoma were excluded.

Initial assessment included a review of case records and current glaucoma control. Goldmann gonioscopy was performed by one of us (B.W.F.), followed by Posner four-mirror indentation gonioscopy if any part of the angle appeared to be closed. Iris color and the presence or absence of iris crypts were noted.

In the first treatment session, argon laser pretreatment was performed in the right eye and Nd:YAG laser iridotomy in the left. In a second session, Nd:YAG laser iridotomy was performed in the pretreated area of the right eye. All laser treatments were performed by one surgeon (B.W.F.).

Acetazolamide 500 mg was given orally, and one drop of G pilocarpine 2% topically 30 minutes before treatment.

## Argon Laser Pretreatment

A Coherent 9900 argon blue-green laser and an Abraham 66-diopter iridotomy contact lens were used. A treatment site was chosen in the superior iris between the 10 and 2 o'clock positions, two-thirds way from the pupil to the iris base. An iris crypt was used where present. A series of superficial burns of the iris stroma were made, using 2 to 5 pulses of 0.5 to 0.7 mW power, 0.2-second duration, and 200 to 500- $\mu$ m-diameter spot size.

## Nd:YAG Laser Iridotomy

A Zeiss "Visulas" Nd:YAG laser and Zeiss anterior segment YAG contact lens were used. A treatment site was chosen in the left eye as symmetrical as possible to the argon laser pretreatment site in the right eye. If present, an iris crypt was used. A single 5- to 10-mJ pulse was delivered to the treatment site. If this pulse did not penetrate the iris, further single pulses were delivered to the same site until penetration was achieved. Patency was assessed by direct observation of

the posterior chamber or anterior lens capsule. The iridotomy was inspected and intraocular pressure measured 2 hours following treatment. Patients were reviewed 24 hours, 1 week, and 1 month following treatment.

Four to 6 weeks following argon laser pretreatment, Nd:YAG laser iridotomy was performed in the pretreated area of the right eye. The treatment procedure was identical to that used for primary Nd:YAG laser iridotomy. The iridotomy was inspected, and intraocular pressure measured 2 hours following treatment, and patients were reviewed 24 hours, 1 week, and 1 month following treatment.

### Follow Up

Patients were reviewed monthly for 3 months, and then at 3-month intervals. Glaucoma medication was withdrawn in a stepwise fashion in patients with good glaucoma control. Medication was reintroduced if intraocular pressure rose above 21 mm Hg. The optic discs were examined and visual fields assessed every 3 months.

Six months after treatment, Goldmann gonioscopy was performed by one observer (B.W.F.), followed by Posner four-mirror indentation gonioscopy if any part of the angle appeared to be closed. Special attention was given to the degree of pigmentation of the inferior part of the trabecular meshwork.

The size of the iridotomy was measured by comparing it with the 0.2-millimeter spot produced by a Haig-Streit slit lamp. The area of the iridotomy was then calculated using the formula: Diameter a  $\times$  Diameter b  $\times$   $\pi/4$ . Transillumination of the iris revealed the extent of pigment epithelium disruption around the iridotomy, and this area was also measured. Pilocarpine/phenylephrine provocation testing as described by Mapstone<sup>4</sup> was performed.

### RESULTS

Details of the patients' age, sex, and diagnosis are given in Table 1.

#### Initial Examination

Corrected visual acuity was 6/9 or better in 17 eyes. One patient had nuclear cataracts, reducing visual acuity to 6/60 in each eye, and one had a unilateral nuclear cataract reducing visual acuity to 6/60. Five patients had light-brown irises and five had gray irises. Three patients had prominent iris crypts—two had brown irises and one had gray irises.

Table 2 shows the glaucoma features of each patient prior to iridotomy. Three patients had a history of intermittent angle-closure glaucoma, with no abnormal physical signs. Five patients had chronic angle-closure glaucoma with raised intraocular pressure and partly closed angles. One patient had a history of subacute

**TABLE 1**  
**Patients' Age/Sex Distribution and Diagnosis**

Age (yrs)	64.7 $\pm$ 8.7
Sex Ratio (Male:Female)	5:5
Diagnosis:	
Chronic ACG	5
Intermittent ACG	3
Subacute ACG	1
Open angle glaucoma with narrow angle	1

ACG = angle closure glaucoma

angle-closure glaucoma, and one had open-angle glaucoma with narrow angles.

#### Treatment

All patients had argon laser pretreatment followed by Nd:YAG laser iridotomy in the right eye. The mean period between argon laser pretreatment and Nd:YAG laser iridotomy was 36.6  $\pm$  16 days (range, 14 to 62 days). Nine patients underwent Nd:YAG laser iridotomy in the left eye.

One patient with unilateral chronic angle-closure glaucoma affecting the right eye declined prophylactic treatment in the left eye.

#### Iris Appearance Following Argon Laser Pretreatment

The immediate effect of argon laser burns was contracture of the iris stroma. Following treatment, an elevated area of bunched iris stroma was seen (Fig 1).

The treatment area was light brown in gray irises and dark brown in brown irises.

One week later, the treated area remained elevated with scattered pigment to the stroma.

After 4 to 6 weeks, the treated area was less elevated, but significant atrophy was not evident. Gray irises appeared to have a dense granular membrane on the surface of the treated area (Fig 2). The treated area in brown irises was densely pigmented. After 4 months, the stroma in the treated area had become atrophic. Nd:YAG laser iridotomy had been performed in the argon laser pretreated area prior to this stage (Fig 3).

Transillumination of the iris 6 months after treatment revealed defects in the pigment epithelium at the argon-laser-pretreated site. However, these changes may have been related to the Nd:YAG laser iridotomy performed in the argon-laser-pretreated area.

#### Nd:YAG Laser Iridotomy in the Argon Laser Pretreatment Site

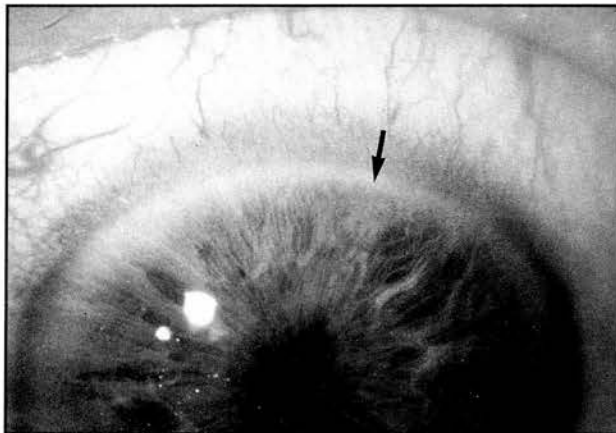
The iris stroma in the argon-laser-pretreated area proved difficult to cut using the Nd:YAG laser.

One patient underwent Nd:YAG laser iridotomy 2

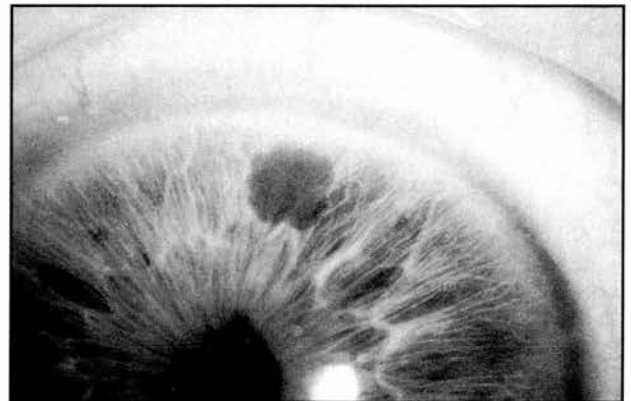**TABLE 2**  
**Glaucoma Outcome**

Patient	Diagnosis	Pre-iridotomy					Post-iridotomy					Change
		Symptoms	IOP (R)	IOP (L)	Rx (R)	Rx (L)	Symptoms	IOP (R)	IOP (L)	Rx (R)	Rx (L)	
1	intermittent	+	20	21			25	25			resolution symptoms; slight increase IOP	
2	intermittent	+	12	12			15	15			resolution symptoms; slight increase IOP	
3	intermittent	+	17	17			16	16			resolution symptoms	
4	subacute	+	28	22	T	T	18	18			resolution symptoms; withdrawal medication; normalized IOP	
5	OAG with narrow angle	—	20	20	T	T	23	23	T	T	no benefit	
6	chronic ACG	—	17	17	P+T	P+T	20	20	T	T	reduced medication	
7	chronic ACG	—	28	18	P		15	16	P+T		normalized IOP R eye; additional medication	
8	chronic ACG	—	27	29	P	P	19	21	Propine		reduced medication; normalized IOP	
9	chronic ACG	—	35	15	P	P	21	20			withdrawal medication; normalized IOP	
10	chronic ACG	—	18	23	P + Betoptic		10	21	Betoptic		reduced medication	

ACG = angle closure glaucoma; OAG = open angle glaucoma; P = pilocarpine; T = timolol



**FIGURE 1:** Argon pretreatment site in a gray iris immediately following treatment. A pale-brown, elevated, bunched area of iris is seen at the treatment site (indicated by arrow).

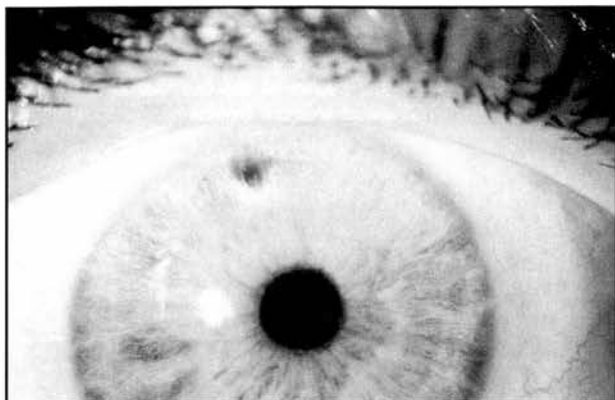


**FIGURE 2:** Argon pretreatment site in a gray iris 28 days after treatment (the same eye as in Figure 1). A thick granular membrane appears to be present at the treatment site.

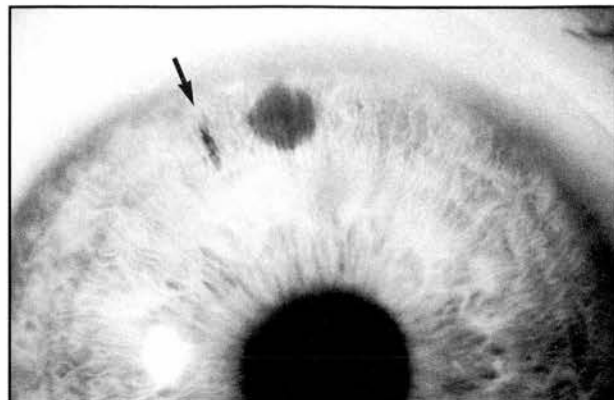
weeks after argon laser pretreatment. Considerable fragmentation of the surrounding iris stroma developed (Fig 4).

Seven cases underwent Nd:YAG laser iridotomy 4 to 6 weeks after argon laser pretreatment. In these cases

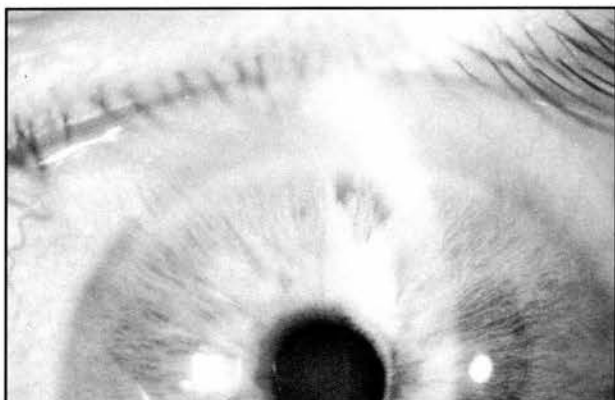
the iris stroma appeared to be “tough” and relatively resistant to Nd:YAG laser photodisruption (Fig 5). Two cases underwent Nd:YAG laser iridotomy 8 weeks following argon laser pretreatment. In these cases the iris stroma had become atrophic and penetration of the iris was easily achieved.



**FIGURE 3:** Nd:YAG laser iridotomy in an argon laser pretreatment site 3 months after argon laser treatment. Note the stromal atrophy in the argon-laser-pretreated area around the Nd:YAG laser iridotomy.



**FIGURE 5:** Argon laser pretreatment site in a gray iris 56 days after treatment. A dark gray granular membrane was present on the surface of the pretreatment site. Nd:YAG laser iridotomy at this site failed. Nd:YAG laser iridotomy was then performed at a new site (indicated by arrow).



**FIGURE 4:** Nd:YAG laser iridotomy in an argon-laser-pretreatment site 4 months after argon laser treatment. The Nd:YAG laser iridotomy was performed 2 weeks after argon laser pretreatment and considerable fragmentation of the iris stroma occurred.

In every case, marked pigment dispersion from the pigment epithelium at the argon laser pretreatment site occurred at the time of Nd:YAG laser iridotomy.

#### Treatment Parameters

The number of pulses, and the total energy used in treatment are shown in Table 3.

Nd:YAG laser iridotomy performed following argon laser pretreatment required significantly more total Nd:YAG laser energy than primary Nd:YAG laser iridotomy ( $P < .001$ , unpaired Student's *t*-test). There was no significant difference in the number of Nd:YAG laser pulses used in each form of treatment.

A patent iris opening was obtained in all primary Nd:YAG laser iridotomies. However, Nd:YAG iridotomy at an argon-laser-pretreated site failed in three eyes. In two of these eyes, a Nd:YAG laser iridotomy was per-

**TABLE 3**  
Number of Laser Pulses and Total Energy Used in Treatment

	Nd:YAG		
	Argon Laser Pretreatment	After Argon Pre Rx	Nd:YAG Iridotomy
Number of pulses	5.6 ± 4.4	5.4 ± 7.3	2.9 ± 2.0
Total energy (mJ)	496 ± 44.1	31.8 ± 29.0	19.4 ± 13.3

formed at a fresh site, and in one eye a patent Nd:YAG iridotomy was obtained at the argon-laser-pretreated area during a second treatment session 1 week later.

In two cases, the size of the primary Nd:YAG laser iridotomy was considered inadequate, and subsequent Nd:YAG laser enlargement of the iridotomy was performed.

#### Operative Complications

Slight iris bleeding occurred at the time of treatment in five primary Nd:YAG iridotomies and in one argon-laser-pretreated Nd:YAG iridotomy (not significant by chi-square test with Yates correction).

Posttreatment intraocular pressure elevation to above 21 mm Hg did not occur following primary Nd:YAG laser iridotomy. Intraocular pressure elevation to 24 mm Hg and 34 mm Hg, respectively, occurred 2 hours after argon-laser-pretreated Nd:YAG iridotomy in two patients. Both of these patients had chronic angle-closure glaucoma.



**TABLE 4**  
**Trabecular Meshwork Pigmentation 6 Months**  
**Following Treatment**

Pigment Inferiorly	Primary YAG	YAG/Argon
Grade 0	6	4
+	4	3
++	0	3

Clinically significant iritis or focal corneal edema did not occur in any patient.

**Follow Up**

The mean duration of follow up was  $9.4 \pm 3.1$  months (range, 5 to 14 months). No eye lost more than one line of visual acuity during the follow-up period, and there was no progression of preexisting lens opacities or development of new lens opacities. No focal lens opacities were seen.

Progression of visual field loss or optic disc cupping did not occur in any eye. Glaucoma control measurably improved in eight patients (Table 2). In one patient with chronic angle-closure glaucoma (patient 7), there was no measurable improvement in glaucoma control. The patient with open-angle glaucoma with narrow angles (patient 5) had slightly worse glaucoma control following treatment. There was no difference in the glaucoma outcome of eyes treated with a primary Nd:YAG laser iridotomy and those treated with argon-laser-pretreated Nd:YAG laser iridotomy. Pilocarpine/phenylephrine provocation tests were performed in both eyes of eight patients. All tests were negative.

**Gonioscopy**

Goldmann gonioscopy revealed open angles in nine patients. One chronic angle-closure glaucoma patient (patient 9) had angle closure throughout 300° superiorly in both eyes. On indentation, small areas of goniosynechia were present superiorly in the right eye, but not in the left. Pigmentation of the inferior part of the trabecular meshwork was a prominent feature in eyes with an argon-laser-pretreated Nd:YAG laser iridotomy (Table 4). In five patients, the inferior part of the trabecular meshwork was more pigmented in the eye with an argon-laser-pretreated Nd:YAG laser iridotomy, and in five patients there was no difference in the degree of trabecular meshwork pigmentation in the two eyes. This difference was not statistically significant (chi-square test with Yate's correction).

**Iridotomy Area**

The area of full-thickness iris patency and of surrounding iris transillumination defect are shown in

**TABLE 5**  
**Iridotomy Area and the Area of the Surrounding Iris**  
**Transillumination Defect**

	1° Nd:YAG	Argon/YAG
Iridotomy area (mm <sup>2</sup> )	$0.034 \pm 0.038$	$0.0836 \pm 0.1578$
Surrounding transillumination defect	$0.036 \pm 0.038$	$0.456 \pm 0.6404$

Table 5. There was no significant difference in the mean iridotomy area of the two groups (unpaired Student's *t*-test). However, the area of transillumination defect was significantly greater in the argon-laser-pretreated Nd:YAG laser iridotomy group ( $P < .05$ ).

**DISCUSSION**

Various combinations of thermal and photodisruptive laser techniques have been used to produce iridotomies.<sup>1-3,5-7</sup> Krasnov used argon laser burns to coagulate the iris stroma prior to performing Q-switched ruby laser iridotomy 2 weeks later.<sup>5</sup> Zborowski-Gutman et al used argon laser burns to coagulate the iris stroma immediately prior to performing Nd:YAG laser iridotomy.<sup>7</sup> However, controlled trials of these techniques have not been performed.

Several workers have commented that Nd:YAG laser iridotomy may be performed with relative ease at the site of a failed argon laser iridotomy.<sup>1-3</sup> In contrast, we have found that Nd:YAG laser iridotomy performed 4 to 6 weeks after argon laser pretreatment requires significantly more Nd:YAG laser energy than primary Nd:YAG laser iridotomy. In two cases, a Nd:YAG laser iridotomy was not obtained at the argon-laser-pretreated site.

The timing of Nd:YAG laser iridotomy following argon laser pretreatment appears to be of some importance. In our cases, maximal stromal atrophy did not occur until approximately 4 months after argon laser pretreatment.

Histologic studies of human tissue have shown stromal edema around argon laser iridotomy sites 4 to 24 hours after treatment, with tissue necrosis and pigment dispersion.<sup>8,9</sup> During the next few days necrotic cells were seen among surviving collagen trabeculae, but inflammatory cell infiltration was minimal. Stromal thinning occurred as early as 17 days following treatment,<sup>8</sup> and this progressed over the next 3 to 4 months. This process may explain why some argon laser iridotomies progressively enlarge over a period of months.<sup>10</sup> The pigment epithelium was relatively spared in areas of partial thickness iris burns.<sup>8</sup> By 5 months to 2 years following treatment, some degree of reparative fibrosis was seen.<sup>8,9</sup>

The 4- to 6-week delay period used in our study to allow stromal atrophy to occur was probably insufficient. After initial resolution of stromal edema, atrophy of collagen trabeculae proceeds more slowly. A delay period of 4 months might be more satisfactory. However, undue delay in creating a patent iridotomy increases the risk of goniosynechiae formation, or the occurrence of acute angle-closure glaucoma. We have, therefore, chosen not to repeat the study using a longer delay period.

We observed considerable pigment dispersion at the argon laser pretreatment site during Nd:YAG laser iridotomy. A photographic study of cadaver eyes showed heaping up of the pigment epithelium around argon laser iridotomy openings.<sup>11</sup> Histologic study of iris tissue surgically removed from eyes that had previously undergone argon laser iridotomy showed migration and proliferation of pigment epithelium several weeks following argon laser iridotomy.<sup>12</sup> In our patients, it is likely that the pigment epithelium was loosely adherent to the overlying atrophic stroma at pretreated sites and was dislodged by the shock wave produced by Nd:YAG laser photodisruption.

We found no significant pigment epithelium loss beyond the iridotomy site following primary Nd:YAG laser iridotomy. Histologic studies of Nd:YAG laser iridotomies in humans have shown minimal disruption of surrounding tissues.<sup>13-14</sup> Immediately following Nd:YAG laser iridotomy a very localized area of stromal necrosis and blood vessel disruption was seen. Pigment epithelium disruption occurred over a slightly larger area.<sup>13</sup>

The inferior part of the trabecular meshwork was more heavily pigmented in the argon-laser-pretreated eyes than in the primary Nd:YAG laser iridotomy eyes 6 months following treatment. However, increased trabecular meshwork pigmentation did not appear to affect glaucoma control. While there has been concern that pigment deposition in an already compromised glaucomatous trabecular meshwork might further reduce outflow facility, Pollack found that outflow facility in fact increased following argon laser iridotomy in a group of chronic angle-closure glaucoma patients.<sup>12</sup>

We found that iris bleeding occurred less frequently at the time of argon-laser-pretreated Nd:YAG laser iridotomies than at the time of primary Nd:YAG laser iridotomies. However, the difference in incidence was not statistically significant, and iris bleeding produced no demonstrable adverse effects when it did occur. Previous studies have produced conflicting results. Zborowski-Gutman et al found no iris bleeding in 16 eyes treated with argon laser immediately prior to Nd:YAG laser iridotomy.<sup>7</sup> However, iris bleeding occurred at the time of Nd:YAG laser iridotomy in failed argon laser iridotomy sites in 11 of 33 eyes reported by Robin and Pollack,<sup>2</sup> and Drake reported one case of profuse iris

bleeding when a Nd:YAG laser iridotomy was performed immediately following argon laser pretreatment.<sup>15</sup>

Our study failed to demonstrate any beneficial effect of argon laser pretreatment 4 to 6 weeks prior to Nd:YAG laser iridotomy. Argon laser pretreatment resulted in a significant increase in the total amount of Nd:YAG laser energy required to produce an iridotomy and was associated with increased pigment dispersion. Nd:YAG laser iridotomy remains the preferred method of producing an iris opening in the treatment of angle-closure glaucoma.

## REFERENCES

1. Rockwood EJ, Meyers SM, Melsier DM, Zakov ZN, Langston PH. Treatment of selected cases of pupillary block with YAG laser iridotomies. *Ophthalmic Surg.* 1984;15:968.
2. Robin AL, Pollack IP. Q-switched neodymium-YAG laser iridotomy in patients in whom the argon laser fails. *Arch Ophthalmol.* 1986;104:531-535.
3. Naveh-Floman N, Blumenthal M. A modified technique for serial use of argon and neodymium:YAG lasers in laser iridotomy. *Am J Ophthalmol.* 1985;100:485-486.
4. Mapstone R. Provocative tests in closed-angle glaucoma. *Br J Ophthalmol.* 1976;60:115-119.
5. Krasnov MM. Q-switched laser iridectomy and Q-switched laser goniotomy. *Advances in Ophthalmology.* 1977;34:192-196.
6. Latina MA, Puliafito CA, Steinert RR, Epstein DL. Experimental iridotomy with the Q-switched neodymium-YAG laser. *Arch Ophthalmol.* 1984;102:1211-1213.
7. Zborowski-Gutman L, Rosner M, Blumenthal M, Naveh N. Sequential use of argon and Nd:YAG lasers to produce an iridotomy—a pilot study. *Metab Pediatr Syst Ophthalmol.* 1988;11:58-60.
8. Schwartz LW, Rodrigues MM, Spaeth GL, et al. Argon laser iridotomy in the treatment of patients with primary angle-closure glaucoma or pupillary block glaucoma: a clinicopathologic study. *Ophthalmology.* 1978;85:294-309.
9. Rodrigues MM, Streeten B, Spaeth GL, Schwartz LW. Argon laser iridotomy on primary angle-closure or pupillary block glaucoma. *Arch Ophthalmol.* 1978;96:2222-2231.
10. Sachs SW, Schwartz B. Enlargement of laser iridotomies over time. *Br J Ophthalmol.* 1984;68:570-573.
11. Prum BE, Shields SR, Shields MB, Hickingbotham D, Chandler DB. In vitro videographic comparison of argon and Nd:YAG laser iridotomy. *Am J Ophthalmol.* 1991;111:589-594.
12. Pollack IP. Use of argon laser energy to produce iridotomies. *Trans Am Ophthalmol Soc.* 1979;77:674-706.
13. Goldberg MF, Tso MO, Mirolovich T. Histopathological characteristics of neodymium-YAG laser iridotomy in the human eye. *Br J Ophthalmol.* 1987;71:623-625.
14. Rodrigues MM, Spaeth GL, Moster M, Thomas G, Hackett J. Histopathology of neodymium:YAG laser iridectomy in humans. *Ophthalmology.* 1985;92:1696-1700.
15. Drake MV. Neodymium:YAG laser iridotomy. *Surv Ophthalmol.* 1987;32:171-177.