

T H E S I S.

PRESENTED for the DEGREE of M.D.,
EDINBURGH UNIVERSITY

CEREBRAL INVOLVEMENT in HEAD INJURY.

A STUDY based on the EXAMINATION of TWO HUNDRED
CASES.

BY

WILLIAM RITCHIE RUSSELL,
M.B., Ch.B., M.R.C.P.Ed.

March, 1932.



T A B L E O F C O N T E N T S.

	<u>PAGE</u>
INTRODUCTION.	1
HISTORICAL REVIEW	2
METHOD OF INVESTIGATION	8
Questionnaire	8
Statistical Cards	11
ANALYSIS of CLINICAL MATERIAL	16
Classification of cases	19
Age incidence	27
Type of accident	28
Injury to scalp	29
Injury to skull	30
Cases in which injuries to other parts of the body were also present	32
Temperature, Pulse and Respiration	34
<u>Analysis of Symptoms and Signs</u>	43
Headache	44
Vomiting	45
Fits	46
<u>Damage to cranial nerves</u>	47
Motor disturbances	53
Reflexes	55

Cases in which damage to the brain is principally on one side.	56
Rigidity of the neck muscles	58
Sensory disturbances	62
<u>Higher cerebral functions</u>	63
Retrograde Amnesia	64
Memory of events preceding injury	65
Stages of recovery of consciousness	67
EXAMINATION of the CEREBRO-SPINAL FLUID.	72
Pressure	73
Quantity of blood in sub-arachnoid space	78
Rate at which the blood is removed	82
Clot formation	85
Total protein content	86
White corpuscles	87
Estimation of sugar	88
THE MECHANISM by which the BRAIN is INJURED	90
Contre-coup injury	91
Mechanism of the loss of consciousness	95
Types of Injury	99
CHANGES DURING RECOVERY	102
<u>Re-examination of cases</u>	105
Analysis of the clinical records	111
Age incidence	112
Severity of symptoms	113
Compensation cases	115
ANALYSIS OF SYMPTOMS	118
Headache	118

	PAGE.
Dizziness	123
Loss of Memory	128
Nervousness	133
Sleep disturbances	137
Epileptic fits	137
<u>Physical examination</u>	139
Summary	140
DISCUSSION of POST-TRAUMATIC DISTURBANCES	142
Cause of disturbances	143
DIAGNOSIS, PROGNOSIS, TREATMENT	152
Diagnosis	152
Compensation cases	154
Prognosis	156
Treatment	158
Details of treatment	160
EXAMINATION of the PATIENT in the ACUTE STAGE	166
Estimation of degree of consciousness	169
Physical examination of nervous system	171
<u>Terminology</u>	173
<u>Summary</u>	174
References	I - III.
Case Records	NOS. 1-202.

CEREBRAL INVOLVEMENT IN HEAD INJURY.

A STUDY BASED on the EXAMINATION of
TWO HUNDRED CASES.

I N T R O D U C T I O N .

During the present century, the number of head injuries admitted to the accident wards of hospitals has steadily increased in all parts of the civilised world. This increase is due to the development of motor transport and the consequent increase in the number of road accidents. H. VULLIET⁽⁴⁴⁾ has estimated that, whereas thirty years ago the number of cases of head injury admitted to hospital was 0.68 per hundred cases admitted, it has now increased to 2.5 per hundred.

There are many problems associated with the subject of cerebral involvement in head injuries and it is in order to attempt to elucidate some of these that the present work was undertaken. Though cerebral damage in head injuries has been studied by other workers, there is no published record of a large number of consecutive cases such as is here attempted.

Under/

Under the auspices of the Statistical Research Department, I have had the opportunity, during the past eighteen months, of studying the cases of head injury admitted to the surgical wards of Edinburgh Royal Infirmary.

The condition of the cases on admission, the stages of recovery, the changes in the cerebrospinal fluid, and the condition some months after discharge, have been the main lines of investigation. In order to make the records uniform, and suitable for statistical study, I have carried out the clinical investigations according to a scheme drawn up in the form of a printed questionnaire. This thesis is not, therefore, a study of rare types of brain injury, or of unusual complications, but is primarily an analysis of the clinical features of two hundred consecutive case records compiled according to a uniform scheme by one observer.

H I S T O R I C A L.

The main interest associated with the study of head injuries has in the past been surgical. Clinical studies of cases of fracture of the skull/

skull are to be found in the EDWIN SMITH PAPYRUS (1600 B.C.)⁽¹⁵⁾ while from the days of HIPPOCRATES⁽¹⁷⁾ trephining has been used in the treatment of contusion and fracture of the skull. The question of operative interference in head injuries has remained throughout the centuries a debatable question, and indeed, the correct treatment of these cases remains doubtful to the present day. The problem has in some ways become more simple, as it is now possible to distinguish the effects of the injury from the results of infection of the damaged tissues. The fear that inflammation would set in, led PERCIVAL POTT, in his notable study of the subject published in 1768,⁽³⁴⁾ to support strongly the policy of trephining over the injured area. The not infrequent discovery of an epidural abscess seemed to confirm his view.

It has for long been realised that the symptoms which were originally described as those of fracture are not for the most part dependent on the fracture itself. POTT was able from the analysis of his cases to insist that the symptoms such as vomiting, giddiness, loss of sense, speech and voluntary motion, were often present without any/

any fracture, and on the other hand that the bones of the skull might be cracked, broken or depressed and yet the patient show none of these symptoms.

The damage to the brain which occurs in head injury has for long been described as concussion, but the exact nature of this condition remains uncertain.

Concussion was in the past considered to be a functional disturbance without observable alterations in the brain. That it could cause death was supported by the case described by LITTRES in 1705,⁽²⁴⁾ in which a prisoner killed himself by banging his head against the wall, and at the autopsy no evidence of injury to the brain could be found. Great importance was attached in later years, to the discovery of capillary haemorrhages in fatal cases, and doubt was raised as to whether a pure concussion without anatomical changes, such as these, ever caused death. DÜRET⁽¹²⁾ in particular emphasised the frequency with which, in experimentally-produced head injuries, he found small haemorrhages in the region of the fourth ventricle which he considered were in many cases the cause of death and resulted from a wave-like movement of the intra-ventricular cerebro-spinal fluid./

fluid. This work of DURET provided a possible explanation for the cause of death in cases in which little was to be found at post-mortem examination. These changes are not, however, often found by other investigators, and BERGMANN⁽³⁾ considered that the main damage must always be in the hemispheres. The cause of death remains, however, undecided, and recently BERNER⁽⁴⁾ emphasised again the possible significance of the "DURET lesions".

Cerebral haemorrhage occurring some time after the accident (spætapoplexie) has been investigated by BOLLINGER,⁽⁶⁾ ROSENHAGEN⁽³⁷⁾ and others. Interest in the pathology of head injuries has been stimulated by the recent increase in knowledge of intra-cranial physiology. The investigations of CUSHING,^(8,9) DANDY^(10,11) and WEED⁽⁴⁵⁾ have shown how the cerebro-spinal fluid is formed and how it circulates, and have demonstrated to some extent the mechanism of its re-absorption into the blood stream. They have also shown the striking effects which can be produced on the cerebral tissue by means of the intra-venous injection of hyper- and hypotonic solutions. The effects of draining/

draining the cerebro-spinal fluid in relieving artificially produced cerebral oedema have been investigated by KUBIE.⁽²¹⁾ An important result of this work has been to show that both the intravenous injection of hypertonic solutions, such as 50% glucose solution, and the withdrawal of cerebro-spinal fluid, are powerful means for the reduction of cerebral oedema.

A degree of cerebral oedema is a constant complication of severe head injury in which contusion of the brain has occurred, and this has led to the assumption, of recent years, (TROTTER,⁽⁴³⁾ JACKSON,⁽¹⁹⁾ RAND⁽³⁵⁾ etc.,) that the occurrence of cerebral oedema is a dangerous complication to be countered by powerful measures, such as those just referred to. Indeed treatment of head injuries at the present time tends to be directed largely, if not entirely, towards the reduction of cerebral oedema and intra-cranial pressure.

Decompression by operation has in the past been widely used, but this procedure has, on the whole, fallen into disrepute.

The work of FOERSTER and PENFIELD,^(14,33) based on experimental and human material, has shown the/

the scarring of the brain tissue which follows injury. From the clinical side, these changes have been investigated by encephalographic studies, one of the most notable of which is that of PETER BIELSCHOWSKY⁽⁵⁾. By means of this method, BIELSCHOWSKY was able to demonstrate contracted areas of brain and deformity of the ventricles in many cases of post-concussional disturbance. Further, by means of testing the rapidity with which sodium iodide was absorbed from the cerebro-spinal fluid, he demonstrated that the rate of re-absorption of the fluid was often greatly diminished. He also found that in many of those cases the pressure of the fluid was raised.

TROTTER⁽⁴¹⁾ considers that unresolved contusion of the brain is the cause of most post-concussional symptoms and emphasises the importance of applying the present-day knowledge of intracranial physiology towards reducing any cerebral oedema which may be present, and in this way allowing the contused areas to recover.

The hyperglycaemia which follows head injuries has been studied by MOCK and TAKATO.⁽²⁹⁾

From the neurological point of view however,

however, the clinical study of head injury has received relatively little attention, and offers a wide field for investigation.

METHOD OF INVESTIGATION.

THE QUESTIONNAIRE.

The preparation of the questionnaire required very careful consideration. As little help could be obtained from the literature on head injury, I was obliged to base it on what seemed to me to be the lines of enquiry from which information of value might be obtained. My aim was to investigate every aspect of the cases, even though the value of certain of the enquiries might appear to be slight.

The following points were considered to be of special importance.

1. The patient's health at the time of the injury.
2. The mechanism of the injury.
3. Its immediate effect on the patient.
4. The patient's state in the interval between the injury and his admission to hospital.
- 5./

STATISTICAL RESEARCH DEPARTMENT.

HEAD INJURIES INQUIRY.

Name..... Sex..... Age..... Ward.....
Address..... Hour and date of admission.....
Date of Discharge.....
Occupation..... Married-single-widow-widower.

Directions :—

The enquiries are answered in each case by one of the following methods :—

- (a) Ticking off the appropriate answer.
- (b) Filling in " yes " or " no."
- (c) By a full answer to the question where it cannot be answered by a briefer method.

Where no information is available with regard to any particular, mark " o." Where the appropriate question or test has not been enquired into or carried out, mark " n.e." (no enquiry).

PART 1,

The following can be answered to some extent by the patient when conscious or by a relative of the patient, **but any available witness of the injury should be retained till the following particulars are enquired into.**

Patient's previous health was :—good ; moderate ; bad Eyesight :—
good in both eyes ; defective in one eye ; defective in both eyes Give
particulars :—

Previous illnesses :

Previous injury or accident :

Was patient lame ? Give particulars :

Habits :—Took alcohol to excess ; in moderation ; total abstainer Further
notes :—

Was there any indication of insobriety at the time of the injury ?

Date and time of injury :

Was the injury due to an accident ?..... If not, give cause :

Type of accident :—street ; industrial ; while playing a game ; other
cause

Interval between injury and admission :

Description of accident :

What was patient doing ?

What caused injury ?

Was head injured directly ? If so, by what ?

Was head injured in falling ? If so, by what ?

Was the force of the blow :—great ; moderate ; slight ?

Further details :—

PATIENT'S CONDITION IMMEDIATELY FOLLOWING THE INJURY.

Was patient conscious of his surroundings ? ; If so, for how long ?

Was patient :—motionless ; able to move his limbs ; quiet ; restless ;
aggressive ; dazed ; normal ?

Was patient able to :—stand ; walk ; speak ;

Was speech sensible ?

Further details :—

Was there bleeding from :—nose ; R. ear ; L. ear ?

Were there any fits ? ; If so, describe :—

In the interval before admission, did patient become more conscious ? ; or did patient
become more unconscious ? If so, when ?

Describe :—

Was alcohol given after the injury ?

Name and address of witness :—

What connection had witness with the accident ?

Further notes :—

PART 2.

EXAMINATION.

Date :

Position of patient in bed —.....

General condition. Is the skin :—cold ; warm ; moist ; dry ?

Is the pulse :—small ; full ; weak ; bounding ?

Is the breathing :—normal ; shallow ; deep ; stertorous ; Cheyne-Stokes ?

Does the breath smell of alcohol ?

Pulse rate :—..... Respiration rate :—..... Temperature :—.....

(Keep hourly chart during acute stage—preserve.)

Blood pressure :—systolic diastolic (Preserve record of all observations.)

External injuries to head and face :—none apparent ; bruise ; cut ; laceration ; simple fracture ; compound fracture ; In case of fracture, is fracture depressed ?, and if so, to what depth ?

What is the position of these injuries ?

Is there hæmorrhage ? If so, is it from wound ? ; nose ; R. ear ; L. ear

Is it slight or profuse ?

Is there evidence of previous hæmorrhage ? If so from where ?

Is there sub-conjunctival hæmorrhage ? If so, in which eye ?

Is there escape of cerebro-spinal fluid ? If so, from where ?

Is it slight or profuse ?

Are there injuries to other parts of the body ? If so, describe :—

Mental state :—normal ; dazed ; irritable ; restless ; delirious ; stuporose ; comatose

Is speech :—normal ; confused ; meaningless ; none possible ?

Is there headache ? If so, is it slight ; moderate ; severe

Position of pain in the head ?

Is there vomiting ? If so, describe :—

Does vomit contain blood ?

Are there any fits ? If so, are they :—general ; local ? Describe (noting especially which part of the body is first involved in the convulsion) :—

Pupils :—Diameter in millimetres (~~2.0, 3.0, 4.0, 5.0, 6.0, 7.0 mm.~~)

Right :—mm. approx. circular ; irregular

Left :— mm. approx. circular ; irregular

Right :—reaction to light :—brisk ; sluggish ; none

Left :— do. brisk ; sluggish ; none

Ophthalmoscopic examination :—Right eye :—

Left eye :—

Is there any abnormal position of the eyes ? Describe :—

Corneal reflex :—Right Left

Is there any weakness of one side of the body ? Describe :—

Are the knee jerks present ? Are they equal ? If not, describe :—

Planter reflexes :—right ; left

Is there incontinence of urine or faeces ?

Is there retention of urine ?

Is there neck rigidity ? If so, is it slight or marked ?

Is Kernig's sign positive ?

Circulatory system :—Is there any abnormality ? Describe :—

Respiratory system :—Is there any abnormality ? Describe :—

Alimentary system :—Is there any abnormality ? Describe :—

Urinary system :—Is there any abnormality ? Describe :—

X-ray examination of skull :—Is there certain evidence of fracture ? Is so, give position and extent :—

Examination of cerebro-spinal fluid. Date and time :—.....

Initial pressure :—.....mm. of water.

Pressure after removing about 5 cc. :— mm.

Total quantity of fluid removed :—cc. Pressure then :— mm.

Is there any immediate effect on patient ? If so, describe :—

Naked-eye appearance of fluid :—

Where the fluid is blood-stained, is the blood uniformly mixed in all fluid withdrawn ?

On standing is the supernatant fluid yellow ?

Does a clot form on standing ?

Cell count. r.b.c. :— per c.mm.

w.b.c. :— per c.mm.

Differential count :—polymorphs— %

Small lymphocytes— %

Large ~~lymphocytes~~ %

mononuclears.

Total protein estimation :—..... (method :—.....).

Proportion of this due to blood contamination :—

= r.b.c. count / ³⁰⁰700 approx.

= mgms. per 100 cc.

Total protein minus proportion due to blood = mgms. per 100 cc.

Wasserman reaction :—.....

Estimation of sugar :—.....mgms. per 100 cc.

Presence of organisms either in direct films or on culture :—

PART 3.

Where patient is conscious, a full examination can be carried out.

Date of such examination :—.....

Higher cerebral functions :—

Cranial nerves :—

1.

2.

3, 4, & 6.

5.

7.

8.

9, 10.

11.

12.

Motor functions.

Abnormal movements or postures :—

Tone :—

Muscular power :—

Co-ordination of movement :—

	Right	Left
Reflexes.		
Arm jerks.		
Knee jerks.		
Ankle jerks.		
Abdominal reflexes.		
Upper.		
Lower.		
Plantar reflexes.		

Sensory functions.

Pin-prick :—

Cotton wool :—

Two-point discrimination :—

Stereognostic sense :—

Vibration sense :—

Trophic disturbances :—

Further notes with regard to any special examination that may be required :—

Result :—Complete recovery ; partial recovery ; death

Did patient return to home ? If not, to what address :—

Is he to report again ? If so, when ?

Treatment received.

Was any operation carried out ? If so, describe :—

Position in bed during acute phase :—recumbent Head raised

Drug treatment (including sedatives, hypertonic solutions, etc.).

Lumbar puncture :—

Is there any indication that these measures were beneficial or otherwise ?

Further notes : -

RE-EXAMINATION SHEET.

Date of examination :—

Interval since discharge :—

General condition since discharge :—

Has complete recovery occurred ? If so, when ?

Is there any change in general health since injury ?

Is memory as good as previously

Is the mental ability as good as previously ?

Is the ability to do work as good ?

Do the relatives notice any change in the personality ?

Have any fits occurred ?

Are there any headaches ?

Is there any tendency to dizziness ?

Is there any speech difficulty ?

Has the patient become nervous ?

Is there any interference with the ability to sleep ?

Is there any change in the moral character ?

Is there any question of compensation outstanding ?

Where any of the above reveal any abnormality, describe :--

Cranial nerves :—

Motor functions :—

Reflexes :—

Sensory functions :—

Examination of skull :—

Further notes :—

PROGRESS SHEET.

To be used for recording changes in patient's condition while in hospital.

Mark " ab " (as before), where there is no change from previous examination, otherwise describe :—

General condition :—

Hæmorrhage and c.s.f. escape :—

Mental state :—

Headache :—

Vomiting :—

Fits :—

Optic discs :—

Pupils :—

Cranial nerves :—

Motor functions :—

Neck rigidity :—

Kernig's sign :—

C.S.F. examination :—

Further notes :—

STATISTICAL RESEARCH DEPARTMENT.

POST-MORTEM EXAMINATION.

Notes from Pathological Report.

Date and time after death :

Are there external injuries to head ? . If so give particulars :—

Is there fracture of skull ? . If so, give position and extent.

Position and extent or amount.

Is there epidural blood ?

Is there sub-dural blood ?

Is there sub-arachnoid blood ?

Is there Hæmorrhage into the brain ?

Is there blood in the ventricles ?

Is there cerebral contusion and laceration ?

Is there œdema of brain ? .

Is there meningitis ?

If so, investigate bacteriologically, and indicate probable course of infection.

Is there evidence of increased intra-cranial pressure ? . Describe :—

Was there any abnormality of skull, meninges or brain at time of injury ? . Describe :—

Is any disease present elsewhere ? . Describe :—

Are the following healthy ? Heart ; Aorta ; cerebral vessels ; Kidneys

If not describe :—

What other injuries are present ?

Is it quite certain that the head injuries caused death ?

Further notes :—

5. The patient's condition on admission: physical and mental.
6. The patient's condition when he had sufficiently recovered to be fit to undergo a full physical examination.
7. Analysis of symptoms.
8. Examination of the cerebro-spinal fluid with especial reference to its pressure and to any abnormality in its chemistry or cell content.
9. The stages of recovery of mental and physical activity.
10. Treatment carried out.
11. Re-examination of the patient several months after discharge from hospital.
12. Analysis of post-concussional symptoms.
13. Duration of incapacity.
14. The pathological examination of post-mortem material by modern staining methods.

A copy of the questionnaire is appended.

The examination of each patient and the record of the case were completed by myself, in order that the method of recording might be constant. The questionnaire enabled me to record the points in the physical examination rapidly and accurately. It was of particular value as a means of ensuring that all the records were, as far as possible, complete in every detail.

During/

During the course of the investigation it became evident that certain parts of the questionnaire could not be completed in all cases. I was, for example, unable to arrange to see every case immediately after admission to hospital, though most of the patients were examined within 24 hours of the injury. Further, I was seldom able to interview the witnesses of the injury in order to obtain a description of the patient's condition in the interval before admission. I have, therefore, in this thesis, analysed principally those parts of the questionnaire which could be dealt with in a large proportion of the cases, as it became evident that certain aspects of the study would have to be separately investigated.

I am at present continuing the study of cases of head injury as they are admitted to hospital, but it seemed to me that the first two hundred cases would be suitable for this study. The last of the cases in this series was admitted to hospital six months ago, so that I have been able to follow up the cases that survived at an average interval of over six months after the accident.

The case records which accompany this thesis/

thesis were prepared from the filled-in questionnaire of each case. As the method of case-recording avoids to a great extent the possibility of omitting parts of the investigation, the appended records have been prepared principally from the positive findings of each case, and detailed descriptions of negative findings, which, indeed, form the main feature of most of the records, have not been included. The severe cases were examined repeatedly in most instances, as they provided valuable material for the study of the return of physical and mental activity.

STATISTICAL CARDS.

In order to analyse the records obtained, the facts elicited with regard to each case were as far as possible transferred to cards for statistical analysis. Each card was divided into three sections. In the first section, twenty-nine facts with regard to the injury and physical examination in the acute stage could be recorded. In the second section there was space for recording eighteen facts with regard to the patient's condition when re-examined at an interval after the accident/

FIG. I.

Name	Sex	Ward
Address	Age	Date of admission
		Duration in Hosp.
1.	2.	3.
5.	6.	7.
10.	11.	12.
14.	15.	13.
17.	18.	16. : days.
20.	21.R.	19. R. L.
23.		22.
26.		24.
28.		25.
		27.
		29.

Re-examination.

2.	3.	4.	1.
6.		7.	5.
9.		10.	8.
12.		13.	11.
16.		17.	14.
			15.
			18.

PART I. and II.

First C.S.F. Examination.

1.	2.	3.	4. R.	L.
5.	6.	7.	8.	
9.	10.		11.	12.
14.	15.		16.	17.
19.	20.		21.	18.
23.			24.	22.

PART III.

accident; and in the third section twenty-four facts with regard to cerebro-spinal fluid examination could be recorded. (See Fig.I.).

The key to this card is as follows:-

PART I.

1. Previous health and habits.
2. Was there insobriety at the time of the injury?
3. Was the injury caused by an accident?
4. What was the type of accident?
5. Were the acute symptoms immediate or delayed?
6. Duration of loss of full consciousness.
7. Interval after the accident that examination was carried out.
8. Was there any shock?
9. Degree of external injury to the skull and scalp (+, ++, or +++). Give site of injury.
10. Was there haemorrhage from wound (W), nose (N), right ear (R.E.) or left ear (L.E.)?
11. Was there subconjunctival haemorrhage? (R = right, L = left, L, M, S, I = lateral, medial, superior, inferior).
12. Was there escape of cerebro-spinal fluid?
13. Were there injuries to other parts (+, ++, or +++)?
- 14./

14. Mental state on examination?
15. Duration of retrograde amnesia.
16. Was there headache? - duration.
17. Was there vomiting? - duration.
18. Were the pupils equal?
19. Diameter of pupils in millimetres.
20. Was there any disturbance of vision?
21. Plantar reflexes - right - left.
22. Was there any abnormality of other reflexes?
23. Were there sphincter disturbances?
24. Was there neck rigidity? (+, ++, or +++).
25. Was there giddiness?
26. X-Ray evidence of fracture.
27. Clinical evidence of fracture.
28. Number of times lumbar puncture was performed.
29. Other features of interest.

PART II. RE-EXAMINATION.

1. Interval since the accident.
2. Has complete recovery occurred?
3. If so, at what interval after the injury?
4. How long did the patient rest in bed?
5. How long after the injury was work resumed?
6. Has there been any loss of memory or mental ability?

7./

7. Has there been any loss of ability to do work?
8. Is there any change in manner or behaviour?
9. Have there been any fits?
10. Has there been any headache since discharge?
Give duration from date of accident.
11. Has there been any dizziness?
12. Duration from date of accident.
13. Has there been any speech difficulty?
14. Has the patient become nervous?
15. Has there been any interference with ability
to sleep?
16. Is there any question of compensation out-
standing? Give compensation received; if
any.
17. Are there any abnormal physical signs?
18. Other points of interest.

PART III. CEREBRO-SPINAL FLUID EXAMINATION.

1. Interval after the injury.
2. Mental state at the time of lumbar puncture.
3. Headache at the time of lumbar puncture.
4. Plantar reflexes at the time of lumbar
puncture.
5. Neck rigidity at the time of lumbar punc-
ture.
6. Initial pressure.
7. Pressure after removing approximately five
cubic centimetres.
- 8./

8. Quantity of fluid removed.
9. Appearance of fluid.
10. Is there any clot formation?
11. Colour of supernatant fluid.
12. Red blood corpuscle count.
13. White cell count.
14. Percentage of polymorphonuclear leucocytes.
15. Percentage of lymphocytes.
16. Percentage of large mononuclear cells.
17. Total protein estimation.
18. Sugar estimation.
19. WASSERMANN reaction.
20. Colloidal gold curve.
21. Proportion of total protein content due to blood content (red blood cell count/300).
22. Difference between No.21 and No.17.
23. State any immediate effect on the patient.
24. State any change in patient's condition on the day following.

ANALYSIS/

ANALYSIS OF CLINICAL MATERIAL.

FIG. II.

AGE PERIOD	MALE	FEMALE	TOTAL.
0-10 years	16	7	23
10-20 years	34	5	39
20-30 years	53	5	58
30-40 years	20	4	24
40-50 years	18	7	25
50-60 years	8	3	11
60-70 years	10	4	14
over 70 years	2	4	6
	161	39	200

Age and Sex incidence.

In this and all subsequent tables, the figures represent the number of cases, unless otherwise stated.

FIG. III.

CAUSE OF INJURY	MALE	FEMALE	TOTAL
Motor car collision	3	3	6
Motor cycle collision	40	0	40
Pedal cycle collision	18	1	19
Knocked down in street	28	29	57
Fall	44	6	50
Other cause	20	0	20
No record	8	0	8
TOTALS	161	39	200

Classification according to the cause of the injury.

FIG./

FIG. IV.

AGE PERIOD	MOTOR CAR	MOTOR CYCLE	CYCLE	KNOCKED DOWN	FALL	OTHER CAUSE	NO RECORD	TOTALS
0-10	0	0	0	11	11	0	1	23
10-20	1	6	12	6	6	5	3	39
20-30	1	27	5	10	8	6	1	58
30-40	1	6	0	5	8	3	1	24
40-50	1	1	1	10	9	2	1	25
50-60	1	0	1	2	3	3	1	11
60-70	1	0	0	8	4	1	0	14
over 70	0	0	0	5	1	0	0	6
TOTALS	6	40	19	57	50	20	8	200
MALE	3	40	18	28	44	20	8	161
FEMALE	3	0	1	29	6	0	0	39

Table showing the relation of the type of the accident to the age and sex.

Analysis of these three tables brings out the following facts:-

- (1) The incidence of head injury reaches its maximum between the ages of twenty and thirty years.
- (2) The large number of cases occurring at this period is principally accounted for by motor cycle accidents.
- (3) At all age periods up to the age of seventy, the incidence among males is much greater than that among females. This is due to the fact that the motor cycle and pedal cycle accidents are almost entirely confined to males, as also are the industrial accidents. The latter are mostly classified as being due to a "fall" or to some "other cause" (Fig. III).
- (4) Apart from the injuries due to motor car collisions, of which there are very few in the series, the only type of accident in which the female incidence is as great as the male is that in which the injury is due to the patient having been knocked down in the street.
- (5) The incidence in children under ten years of age is over twice as great in males as in females. As these accidents to children were due almost entirely to falls, or to the child being knocked down in the street, (Fig. IV), the preponderance of males is probably due to the greater development of an adventurous tendency in that sex. The huge preponderance of male cases in the second and third decades (Fig. IV) is also, no doubt, contributed to by the same psychological factor. The incidence in the female never exceeds that found in the first decade, and this illustrates in a striking way the relative immunity from injury which this sex enjoys.

In a few instances, some physical defect shown/

shown by the patient contributed to the occurrence of the accident. Thus, two cases which were knocked down in the street were very deaf, a third had very defective vision, and another suffered from paralysis agitans. In addition to these, fifteen cases at least showed some evidence of intoxication on admission. Twenty patients were over sixty years of age, thirteen of these were knocked down in the street, and five were injured through a fall.

CLASSIFICATION OF CASES.

The classification of cases of head injury has been attempted in many ways of greater or less complexity, and the question as to which is the best method is one of some difficulty. In the first place, cases are often classified according to the damage to the skull, and this classification is still widely used. By a second method an attempt is made to classify the damage to the brain as well as to the skull. This method of classification may be illustrated by BAGLEY'S, ⁽¹⁾ which is as follows:-

1. Simple depressed fractures.
2. Compound fractures, with or without depression.

3. Extra-dural haemorrhage.
4. Blood overlying cortex.
5. Cortical injuries. (a) laceration.
 - (b) diffuse superficial extravasations.
 - (c) single or multiple cortical clots.
6. Extravasation into the vein of GALEN system.
7. Haemorrhage into the brain stem.

It is at once apparent that any such method as this is of little use from the clinical point of view. In the first place many cases would fall into several of the groups, and secondly many of the groups have reference rather to post-mortem findings than to clinical observations.

It is generally admitted that the degree of damage to the skull gives no definite indication of the degree of damage to the brain. This was observed by POTT,⁽³⁴⁾ as has been already mentioned. It appears therefore desirable to adopt a classification which will provide an indication of the degree of damage to the brain as well as to the skull. The only way to achieve this is to classify each case under two headings -

(1)/

- (1) The damage to the skull.
- (2) The damage to the brain.

The first of these will not be here considered as it is mainly a radiological problem. It is customary and desirable to X-ray the skull in all head injuries, if only from the legal standpoint. A fracture of the skull can usually be shown by this means, but some fractures of the base, and particularly of the anterior fossa, cannot be demonstrated by X-rays.

In what way then can cases be classified according to the degree of damage to the brain? It is usually impossible to determine whether, for example, the brain has been severely contused in one spot, the degree of contre-coup injury, or the presence of small haemorrhages in the substance of the organ. In fact, there are few types of brain damage which it is possible to diagnose accurately during life. As will be shown later, the whole of the brain suffers in severe head injury, and it seems to me therefore to be more satisfactory to refer clinically to the degree of cerebral injury in general terms, such as slight, moderate or severe cerebral contusion, except in those cases in which gross/

gross signs, such as hemiplegia, indicate that one part of the brain has suffered excessively.

The duration of loss of full consciousness has been used in the present series as the indication of the degree of cerebral injury. While this seems to be the most practicable method to follow, it does not always provide an accurate estimate of the degree of cerebral damage. It must be borne in mind, for example, that the duration of unconsciousness may be increased by the supervention of a complication such as haemorrhage which is not necessarily dependent on the degree of cerebral contusion.

In using this classification, it is necessary to consider what are to be accepted as the criteria for full return of consciousness. The usual stages of recovery are somewhat similar in all degrees of injury, though the duration of the stages of recovery varies very greatly. They may now be conveniently described.

STAGES OF RECOVERY.

Immediately after the blow the whole of the nervous system may be paralysed; even the respiratory and cardiac movements may cease. If recovery/

recovery is to occur, the heart and respiration recommence. Involuntary movements of the limbs then occur and the reflexes return. Speech returns with a few words or phrases and movements become more purposeful. Up to this stage it is mainly the lower mechanisms of the brain that are recovering, and the similarity between cases is great. The higher cerebral functions, however, differ in every individual, and the stages of recovery of these functions produce widely different clinical pictures. The mental condition may simulate any of the states seen in alcoholic poisoning. In both conditions, the clinical picture probably depends on the individual psychological structure and balance. Thus the patient may be drowsy or talkative, docile or aggressive, impudent or irritable. He is never reserved; he may tell you his secrets, may be boastful or affectionate, and may even attempt to bribe his attendants to let him out of bed.

Then, comparatively suddenly, he looks around and asks where he is. He has now recovered full consciousness and returns to his normal behaviour and treats those who are looking after him with the customary civility. These changes indicate that/

that the higher functions of control and inhibition have again taken charge of his behaviour. These are the first to be affected in alcoholic poisoning and are the last to recover after a head injury. They presumably constitute the most sensitive mechanisms in the brain. These stages of recovery may be traced not only in the more severe cases, but also in those in which the individual is unconscious for only a few minutes.

It is undoubtedly sometimes difficult to determine at what stage consciousness has fully returned, and indeed in some severe cases the individual is never again able to carry out the same mental processes as were possible before the accident. In this series, the patient was not considered to have recovered full consciousness unless he was fully orientated and able to answer questions intelligently. He should, for example, be able to describe clearly what he last remembered before the accident and what he first remembered after the accident. The victim of an accident may be able to move and even to talk sensibly and yet have no subsequent memory of his words or actions. This is a familiar state of affairs; as, for example, when a football/

football player is able to continue the game after a head injury and subsequently have no recollection of it. This failure to commit his actions to memory would indicate, according to the scheme here used, that he had not recovered consciousness in full. Such a patient may answer simple enquiries not unnaturally and yet be found on cross-examination to be disorientated as regards time and place. It is therefore apparent that the evidence of untrained observers, as to when full consciousness returns is of little value. How then can this duration of unconsciousness be estimated? In the state of full consciousness any occurrence in which the patient is actively or **passively** concerned makes an impression to a greater or less extent on the memory, and can be subsequently called to mind. It has accordingly been found that the patient's subsequent memory of when he woke up provides a not inaccurate indication of when unconsciousness returned. By this indication, the duration of loss of consciousness can be estimated with fair accuracy even when the patient is seen for the first time long after the accident.

Grouping/

GROUPING OF CASES ACCORDING TO DURATION OF
LOSS OF CONSCIOUSNESS

The cases of the series have been divided as follows:-

GROUP "A" were unconscious for less than one hour:
80 cases.

GROUP "B" were unconscious for from one to
twenty-four hours: 57 cases.

GROUP "C" were unconscious for more than twenty-
four hours: 47 cases.

GROUP "D" comprised the fatal cases: 16 cases.

The different groups, A, B, C, and D are repeatedly referred to throughout the text without further explanation.

Fig V /

FIG. V.

AGE PERIOD.	GROUP.				TOTALS.	PERCENTAGE DIED.
	A	B	C	D		
0-10	10	2	10	1	23	4.4%
10-20	19	13	6	1	39	2.6%
20-30	20	18	18	2	58	3.4%
30-40	8	10	5	1	24	4.2%
40-50	13	6	3	3	25	12.0%
50-60	6	16	1	3	11	27.0%
60-70	3	1	1	4	14	28.6%
over 70	1	1	3	1	6	16.7%
TOTALS.	80	57	47	16	200	8.0%

Table showing the relation of the age-periods to the degree of cerebral damage. The proportion of fatalities in each age period is also shown.

FIG. VI

TYPE OF ACCIDENT	GROUP.					TOTALS
	A	B	C	D	D	
Motor-car	3	2	0	1		6
Motor-cycle	11	13	15	1		40
Pedal cycle	11	7	1	0		19
Knocked down	15	17	19	6		57
Fall	26	12	6	6		50
Other cause	14	4	2	0		20
No record	0	2	4	2		8
TOTALS	80	57	47	16		200

Table comparing the type of accident to the degree of damage to the brain.

There are some points of interest arising from these tables. FIG. V. shows that, after the age of forty, the percentage of fatal results rises very greatly, and correspondingly the number of cases in Group "C" becomes proportionately much less than in the earlier years. This probably indicates that as age advances the individual becomes progressively less able to withstand the effects of severe injury, and this explanation is supported by the fact, as will be shown later, that full recovery of cerebral function after a head injury is much less likely to occur in the old than in the young.

Fig.6./

Fig. VI. shows that the fatal cases are largely due either to a fall or to the victim being knocked down in the street. While there were fifty-nine accidents in which the rider of a motor or pedal bicycle was involved in a collision, only one of these was fatal. These accidents, however, often caused severe injury, as is evidenced by the sixteen cases in Group "C"

The mortality rate of the whole series is 8%

The nature of the external injuries to the scalp was not examined in detail. They can be roughly classified, however, according to their gross degree, and can be compared in the different groups as in Fig.VII.

FIG. VII.

DEGREE OF INJURY TO SCALP.	GROUP.				TOTALS
	A	B	C	D	
None apparent	3	6	5	0	14
Moderate injury	60	35	28	8	131
Severe injury	16	13	8	8	45
No record	1	3	6	0	10
TOTALS	80	57	47	16	200

The/

The position of the local injury in 148 cases is indicated in the following table.

FIG. VIII.

POSITION OF INJURY	GROUP.				TOTALS
	A	B	C	D	
Frontal	23	20	11	6	60
Occipital	14	4	4	1	23
Parietal or temporal	23	15	10	5	53
Vertex	1	1	2	0	4
Face	5	1	2	0	8
TOTALS	66	41	29	12	148

FRACTURE OF THE SKULL.

The following table (Fig. IX) shows the proportion of cases in each group which showed certain evidence of fracture of the skull. The evidence was considered certain when the fracture was clearly shown either on X-Ray examination or at operation or at the post-mortem examination.

FIG. IX/

FIG. IX

	GROUP.				TOTALS
	A	B	C	D	
Certain evidence of fracture.	16	12	27	8	63
No certain X-Ray or other evidence of fracture.	51	35	7	2	95
TOTALS	67	47	34	10	158
Percentage of cases which showed a fracture.	24%	26%	80%	80%	40%

An attempt is made in Fig.X to classify these cases of fracture according to the region in which they are chiefly situated.

FIG. X.

POSITION OF FRACTURE.	GROUP				TOTALS
	A	B	C	D	
Frontal	5	2	5	2	14
Occipital	3	1	5	1	10
Parietal and temporal.	7	6	11	0	24
Base	0	1	4	5	10
TOTALS	15	10	25	8	58

From/

From the study of these figures (7-10), it is apparent in the first place, as would be expected, that the extent of injury to the scalp bears no relation to the severity of the cerebral damage, and the severity of the injury, as indicated by the group to which the case belongs, bears no relation of a definite nature to its position. 41% of the cases were injured in the frontal region, 36% in the parietal or temporal regions, and 16% in the occipital region.

While there are many cases in all groups which show certain evidence of fracture of the skull, the proportion of cases which show this is much higher in Group "C" and "D" (80 per cent) than in the less severely injured cases in Groups "A" and "B". (24 and 26 per cent respectively)

CASES in which INJURIES to OTHER PARTS
WERE ALSO PRESENT

Injuries to other parts were present in 63 cases.

Injuries to other parts of the body may direct attention away from any slight concussion, and a proportion of these cases are found to be classified/

classified in the hospital records without any reference being made to a head injury, although the latter had been of sufficient severity to cause loss of consciousness. If, after an accident causing injury, the victim does not remember the details of how it happened, up to and including the moment in which he was injured, it is probable that he has suffered from concussion, and careful enquiry with regard to what exactly was the first thing he remembered after the accident will often show that consciousness was lost for a few minutes. It is a matter of no little importance that the possibility of head injury in such cases should not be overlooked; for, if such a possibility is borne in mind and X-Ray examination carried out, a fracture of the skull may be brought to light in patients who otherwise might be treated solely for injury to some other part.

In view of the fact that after loss of consciousness the patient himself is usually unable to inform the examiner whether or not his head has been struck, and as local damage to the scalp, even if present, is by no means always apparent, there is no doubt that X-Ray examination should be carried out in all cases in which there is any possibility of/
of/

of concussion having occurred. This is particularly important when dealing with infants, where the severity of the injury may be difficult to ascertain.

TEMPERATURE, PULSE, AND RESPIRATION.

Immediately following a severe injury both respiratory movement and heart action may cease. Where recovery is to occur respirations recommence, but often remain feeble and shallow, especially where shock is marked. The pulse similarly is found to be feeble and rapid. Shock is a constant feature of severe head injury, and during this stage the temperature is subnormal.

As recovery progresses, the temperature rises to normal or above normal, the pulse becomes slower, and the respirations deeper. In the more severe cases the temperature rises a degree or two above normal and the pulse wave becomes forceful - the so-called hard pulse. Thereafter, in most cases, the temperature, pulse and respiration return to normal in the course of a few days.

Some points of importance emerge from a study of the temperature, pulse and respiration charts. In attempting to draw conclusions from the clinical/

clinical charts, I have excluded those belonging to cases in which there were either injuries to other parts of the body or gross laceration of the scalp.

CHARTS of CASES in GROUP A.

Of forty-six cases in Group A which were suitable for study, twenty-one showed no temperature record above 98.4°F . In the remainder, the temperature on one or more occasions was found to be above 98.4°F . In no case did the temperature rise above 99.8°F .

In only six cases was the temperature above normal on admission. In all the remaining nineteen cases in which the temperature was raised, the rise occurred from 12 to 24 hours after the accident, the first temperature records taken being subnormal.

In only ten cases out of the forty-six in this group was there any abnormality in the pulse rate at any time after admission. In these ten the rate was increased during the first or second day, but the increase in rate was rarely above 15 per cent of what was later seen to be normal for that individual.

The/

The following case is typical of this group.

CASE NO. 25. F.E. A male aged 50 had a fall and was subsequently unconscious for about half an hour. He vomited once while recovering consciousness, and when examined on the day following complained of severe headache. Examination showed two bruises, one in the occipital and one in the frontal region. No abnormality was detected on physical examination of the nervous system and X-Ray examination showed no fracture. The temperature chart is shown in Fig XI.

CHARTS of CASES in GROUP B.

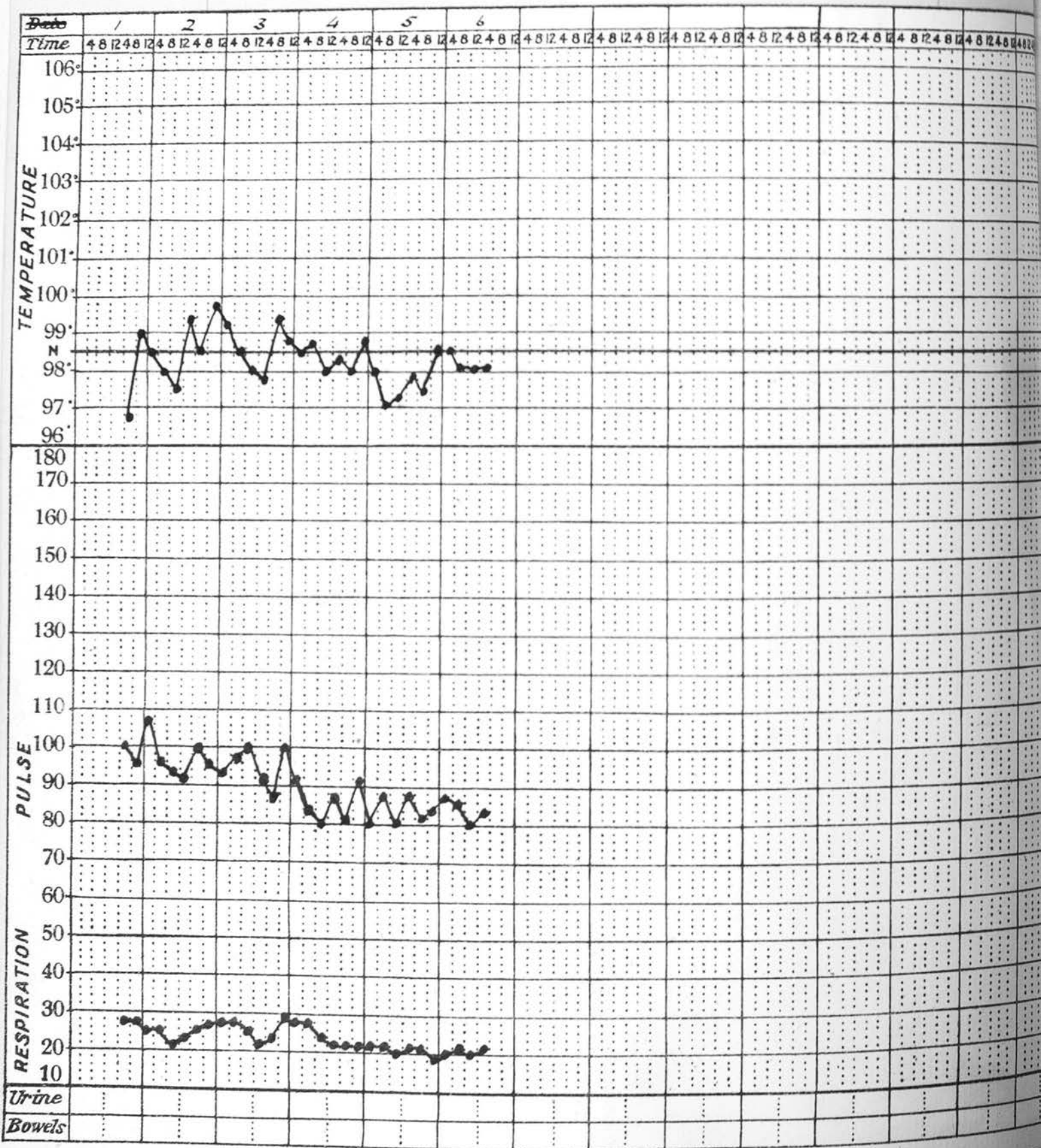
Twenty-two cases in Group B. were suitable for study. In nine of these no temperature record above normality was found. In the remainder the records were, on the average, a little higher than in Group A, but no temperature above 100.2°F. was recorded. As in Group A, the temperature was usually sub-normal on admission and rose during the ensuing 24 hours. A definite rise in pulse rate was apparent in all except three of the twenty-two cases. A rise in the pulse rate was, as a rule, associated with a rise of temperature, but in some cases the pulse rate was highest on admission when the temperature was low and shock was present. A slight increase in the rate of respiration (10 to 20 per cent) was present in twelve cases during the first day or two days.

The/

FIG. XII.

M.B., Aet. 57

CASE NO. 83,



The following record is typical of cases in Group B.

CASE NO.83. M.B. A female aged 57 fell off a tramcar and struck her head on the ground. She was immediately rendered unconscious and did not recover consciousness for four hours. There was no bleeding from the nose, throat or ears. A haematoma formed over the occipital region and when examined, on the day following, the patient complained of some pain in the head. She vomited frequently during the two days following admission. Examination of the nervous system eighteen hours after the accident showed no abnormality except a bilateral extensor plantar response and a slight degree of neck rigidity. The temperature chart is shown in Fig.XII.

CHARTS of CASES in GROUP C.

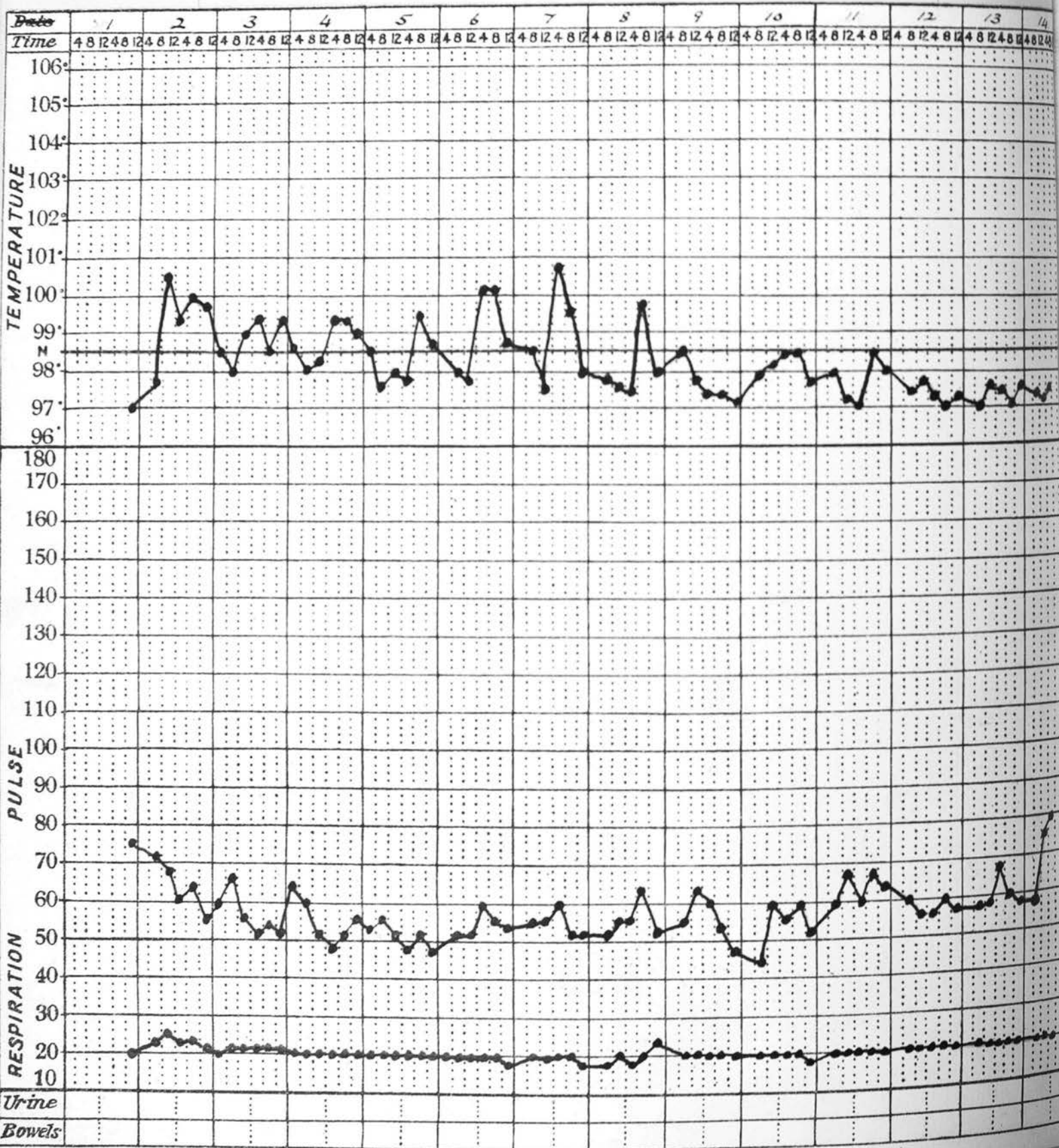
Thirty cases in this group were suitable for study. In only two of these did the temperature remain below 98.4°F. In nineteen the temperature did not exceed 100°F. but in nine, temperatures between 100°F. and 101.8°F. were recorded.

As/

FIG. XIII.

A.G. Aet. 29.

CASE NO. 154.



As was the case in groups A and B, the temperature was usually subnormal on admission. In this group however, the readings did not, as a rule, return to normal within 48 hours, as was usually the case in groups A and B, but often continued high for several days.

The records of A.G. and R.D. are typical of this group.

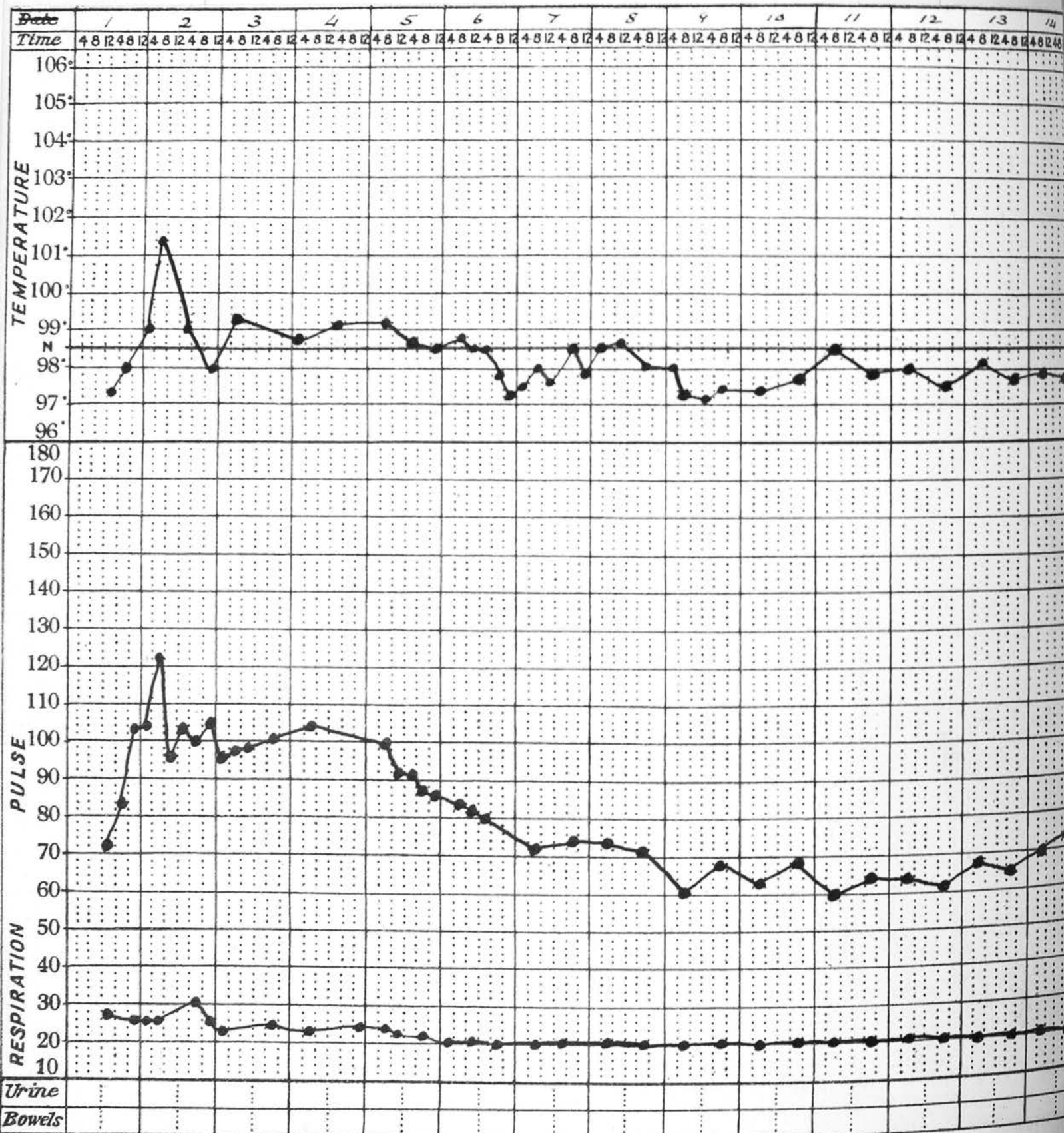
CASE NO. 154 A.G. A male, aged 29 was admitted to hospital unconscious. The cause of his head injury was not known. On examination twelve hours later he was found to be deeply stuporose. There was some clotted blood in the nose, but none in the ears. X-Ray examination showed a vertical fracture through the occiput. It was over a fortnight before he recovered full consciousness. Lumbar puncture was carried out on two occasions and the cerebro-spinal fluid was found to be under great pressure and deeply blood-stained. The patient complained of severe headache while unconscious. The temperature chart is shown in Fig. XIII.

CASE NO. 151. R.D. A male, aged 27, while riding a motor-cycle, collided with an obstacle on the road and was thrown to the ground. On examination a few hours after the accident, he was deeply stuporose and very restless. There was evidence of bleeding from the right ear, and X-Ray examination showed a fracture of the right temporal bone. It was nearly three weeks before he fully recovered consciousness, and during most of that period he was very restless and at times/

FIG. XIV.

R.D. Aet. 27.

CASE NO. 151.



times so violent that he had to be strapped in bed. He subsequently made a good recovery. The chart is shown in Fig. XIV.

While, as in the other groups, a degree of acceleration of the pulse rate may be present, as in case R.D., there is in many cases in this group some slowing of the pulse rate during the first 10 days, as is well shown in the chart of case A.G. This is probably due to the development of increased intra-cranial pressure. A slight increase in the respiratory rate (10 to 30 per cent) was recorded in 20 of the 30 cases in this group.

If the pulse rate during the last few days in hospital be taken as normal for the individual, the patients in this group often showed abnormally low pulse rates at some period during the first ten days of their illness. Only eleven of the thirty cases failed to show this feature, and in those in which it was present the pulse rate was often 30 - 40 per cent below the normal rate - that is to say, a pulse rate of 50 would occur in an individual with a normal rate of 80. This feature is shown in Fig. XIII

CHARTS of CASES in GROUP D. (The fatal cases)

A study of the charts of fatal cases is of special/

FIG. XVI.

J.C. Aet, 61.

CASE NO. 189.

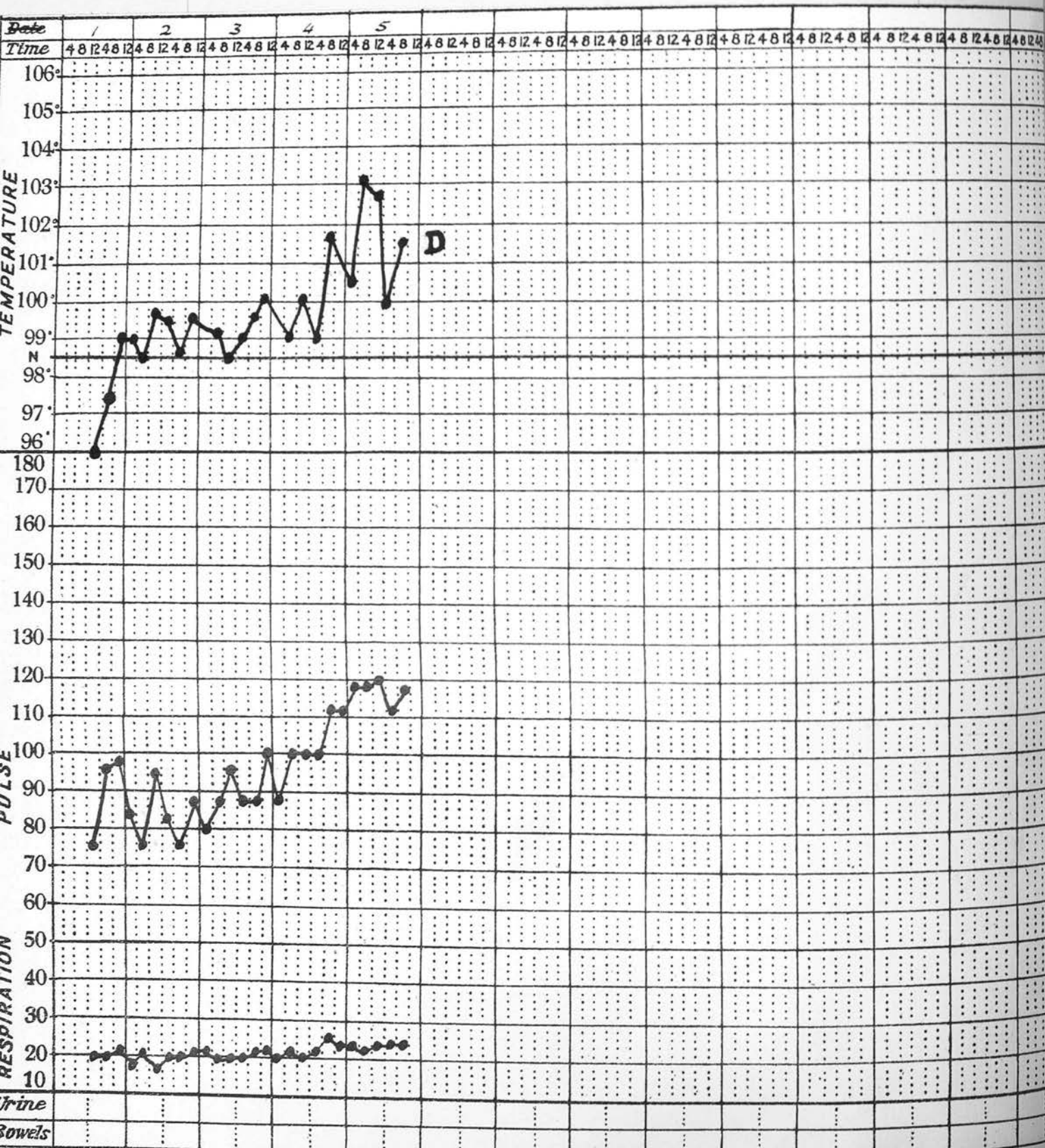
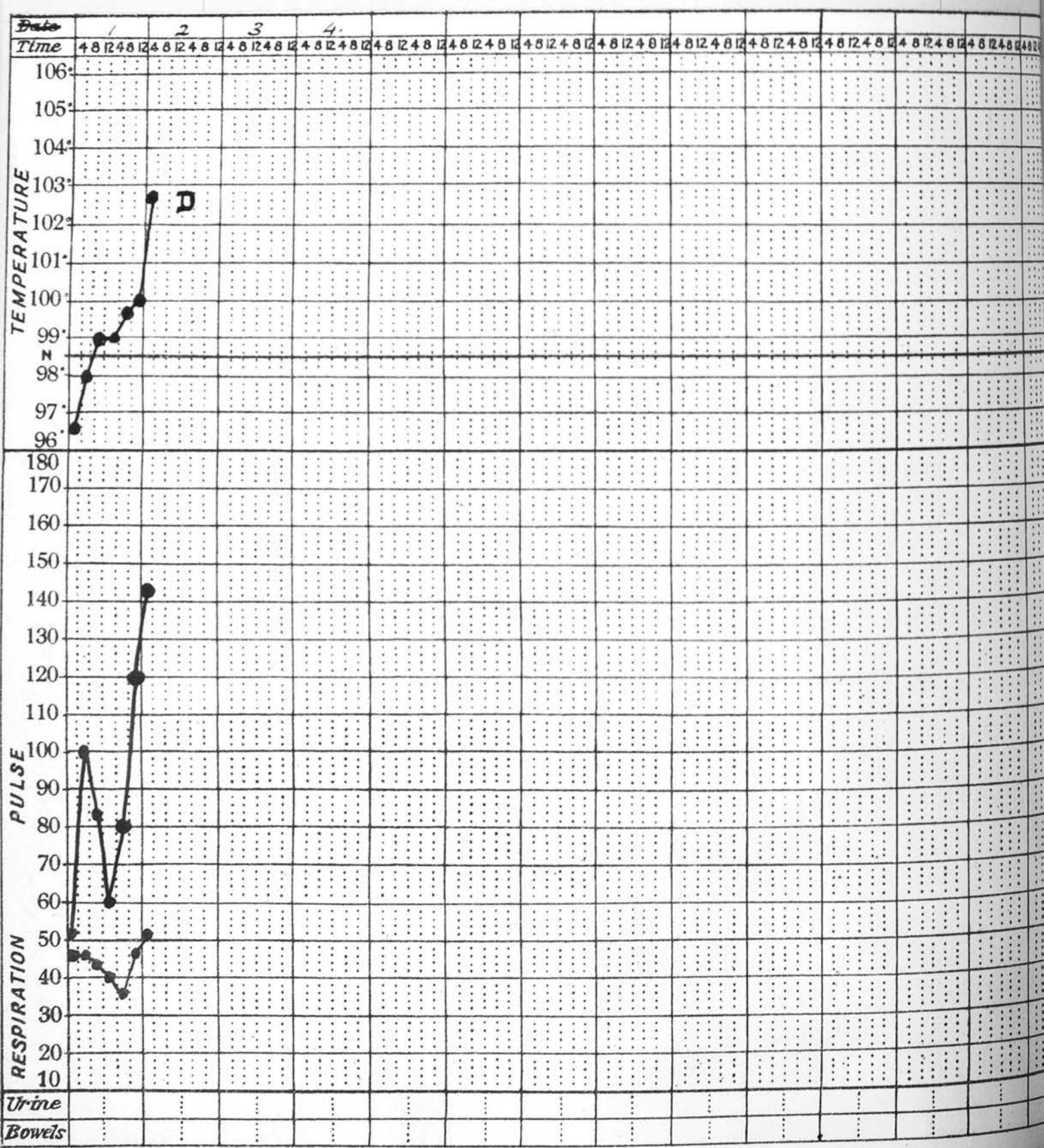


FIG. XV.

D.L. Aet. 43,

CASE NO. 195.



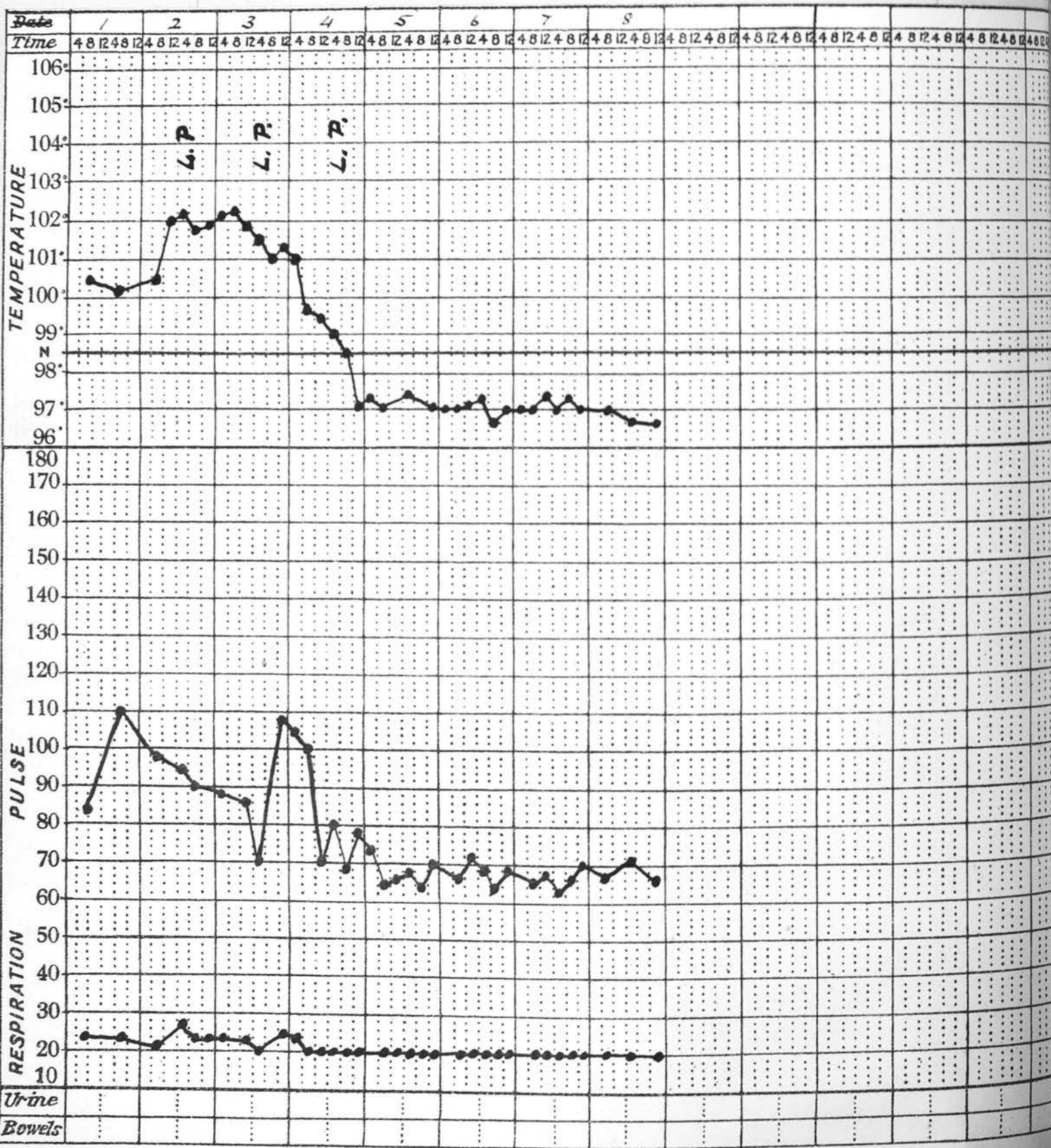
special interest. Ten of these were suitable for investigation. As has already been shown, the mortality is much higher in the older age-periods than in the younger, and correspondingly there are relatively fewer of the older cases in group C, as few of them are able to survive injuries of the severity incurred by the cases in that group.

The striking feature shown in the charts of group D is the progressive increase in pulse rate. There is no stage of reaction with a hard slow pulse. On the contrary, the pulse rate increases steadily and becomes progressively more feeble, and with it the respiratory rate also increases. In most cases the reaction from the initial shock is sufficient for the temperature to rise, and death may occur with hyperthermia. In some, however, the temperature never rises above normal. Typical charts are those of D.L. (Fig. XV) and J.C. (Fig. XVI). Post-mortem examination of these cases often shows evidence of an early pneumonia.

In cases below the age of 30, it was found that, if the initial shock was survived for twenty-four/

J.C. Aet. 43.

CASE NO. 149.



A.G. Aet. 12.

CASE NO. 190.

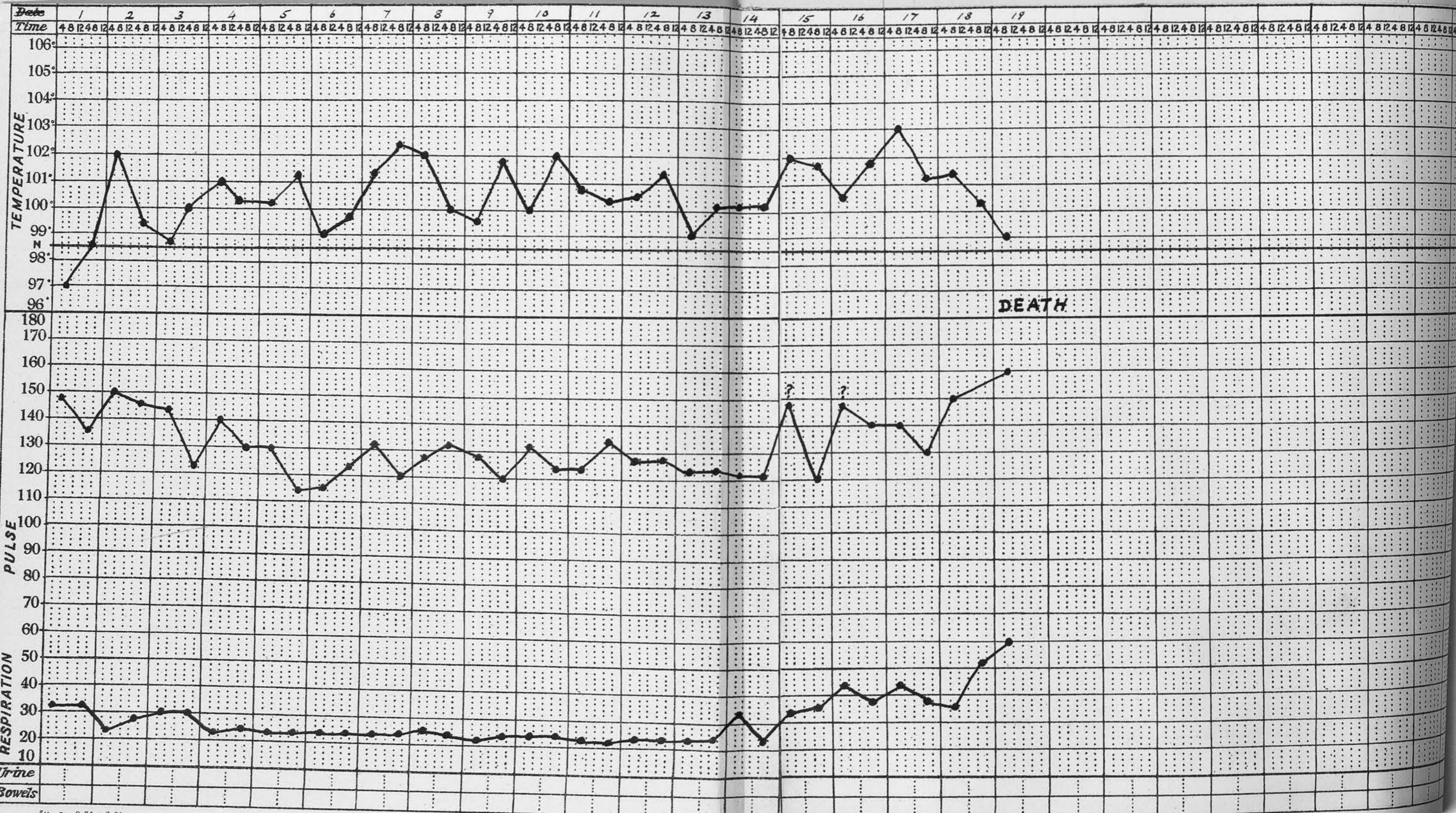
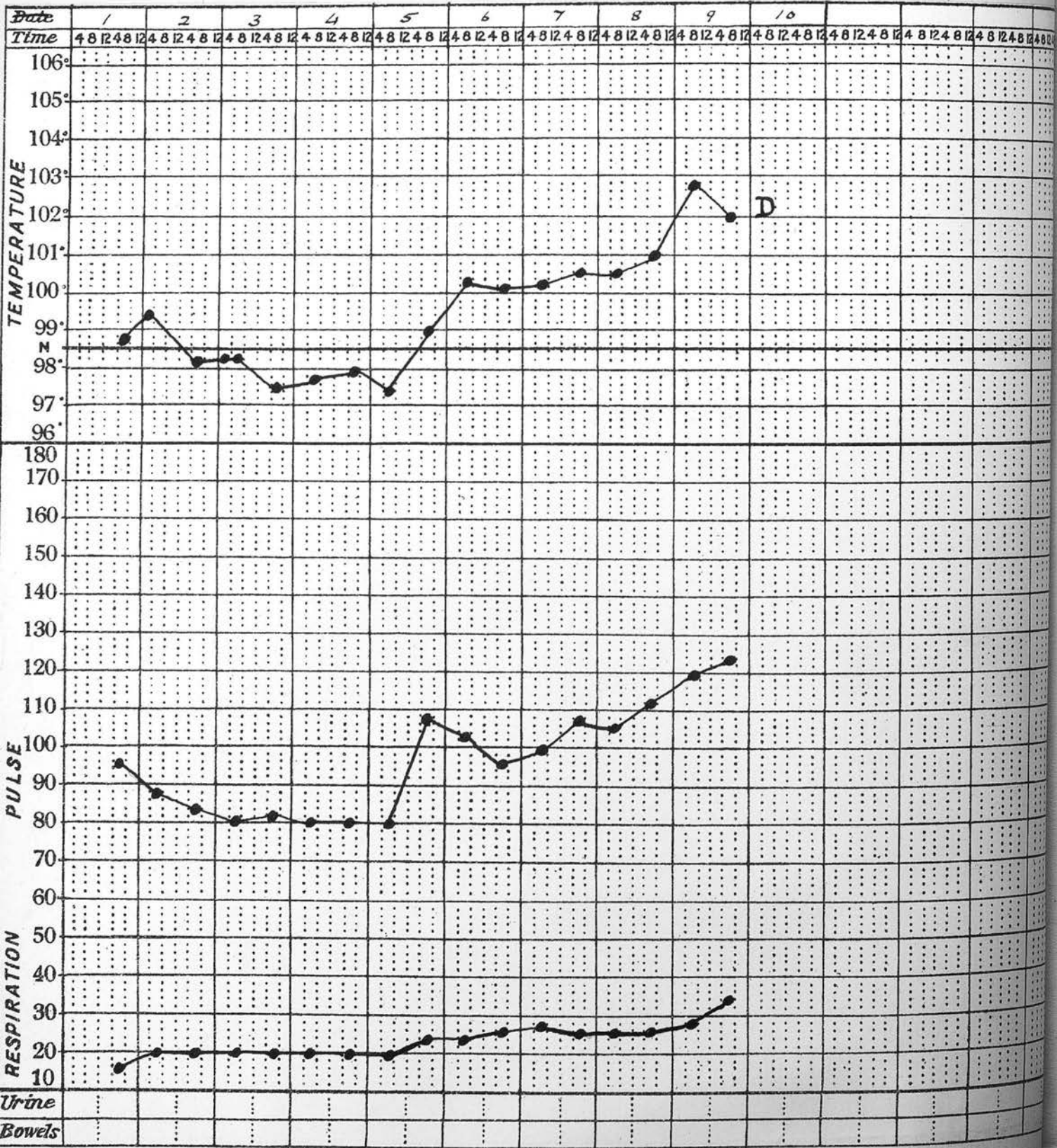


FIG. XIX.

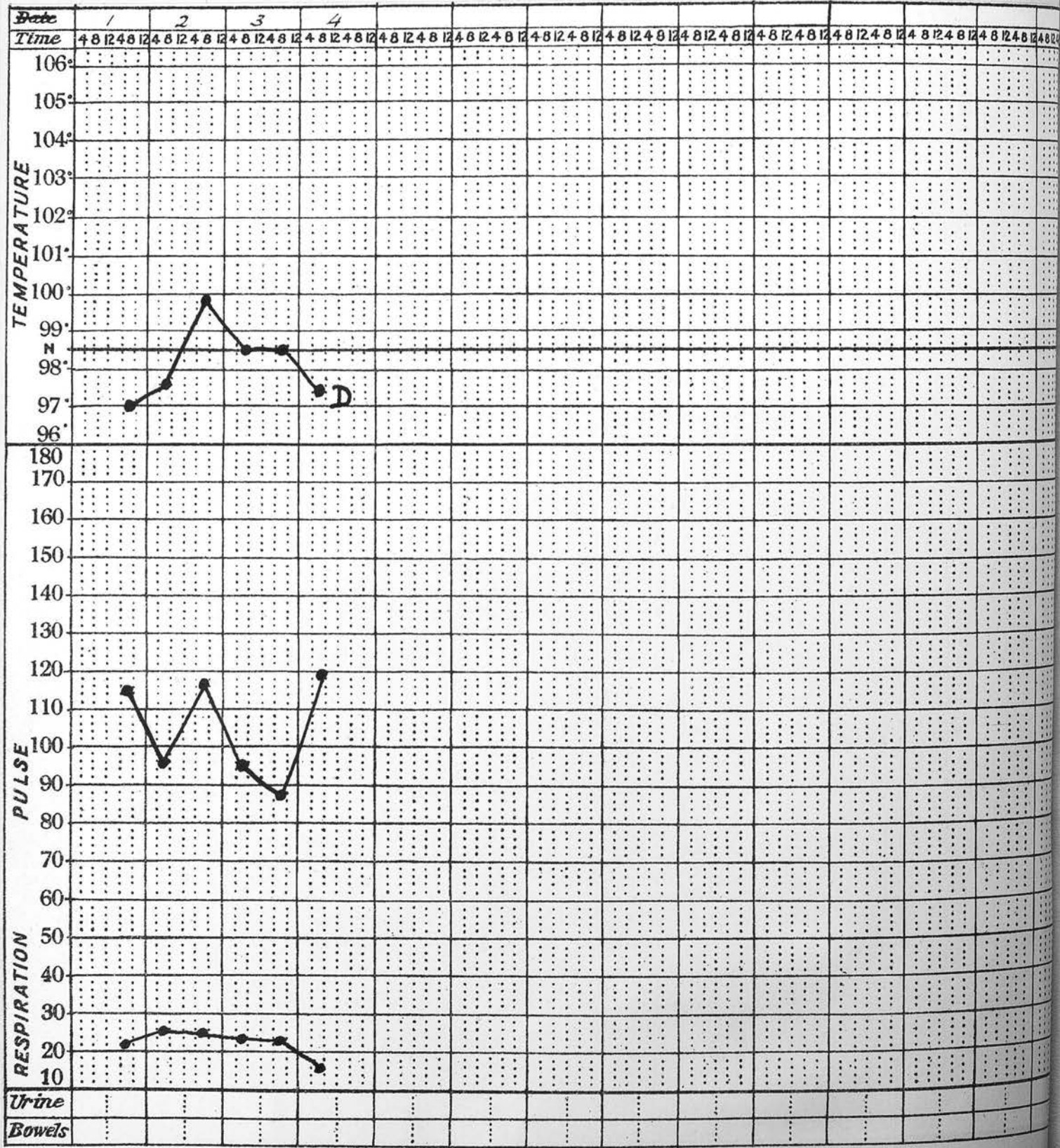
MRS. G. Aet. 65.

CASE NO. 191.



M.A. Aet. 40.

CASE NO. 185.



twenty-four hours, death seldom occurred, unless some complication, such as meningitis, supervened.

The onset of meningitis was a cause of death in a proportion of the cases, and the temperature charts of four of these are reproduced here. - D.B. (Fig. XVII), M.A. (Fig. XVIII), Mrs. G. (Fig. XIX), A.G. (Fig. XX).

The clinical picture of meningitis was apparent in case J.C. (Fig. XXI), and the white cell count in the cerebro-spinal fluid had risen to 6000 per cubic millimetre. After the second lumbar puncture, however, the temperature fell to normal in the course of 24 hours, and rapid recovery occurred. This case, which was presumably one of aseptic meningitis, is referred to in greater detail later.

It is thus apparent that an important prognostic guide in cases of head injury is the condition of the pulse. A degree of slowing and hardening of the pulse wave may be welcomed in severe cases. On the other hand, a tendency for the pulse to become progressively more rapid and feeble is a sign of very grave prognostic significance.

There/

There is no evidence from the study of these charts that increased intra-cranial pressure contributes to a fatal issue. The rapid and feeble pulse is quite unlike that which occurs in conditions of increased pressure. Immediate and delayed shock seems to play a part in the fatal result in these cases as in cases of severe injury to other parts of the body.

ANALYSIS/

ANALYSIS of SYMPTOMS and SIGNS
in HEAD INJURY.

In the following analysis it will be noted that in some of the cases there is no record of certain of the symptoms and signs which are studied. The omission of any record of certain symptoms, was due usually either to an abnormal mental state of the patient or to the patient being a young child unable to answer questions. The most frequent reason for the omission of notes regarding certain signs, was the presence of injuries to other parts of the body. For example, a fracture of the lower extremity often prevented examination of the reflexes.

Where illustrative cases are summarised in the text, the number of the case is quoted, and the full case record may be found in the appendix.

HEADACHE.

The following table compares the degree of headache complained of in the four groups of cases.

FIG. XXII.

DEGREE OF HEADACHE	GROUP.				TOTALS
	A	B	C	D	
Severe	18	17	22	4	61
Moderate	26	15	6	1	48
None	32	24	8	0	64
No record	4	1	11	11	27
TOTALS	80	57	47	16	200

Apart from the cases in which the pain was referred to the site of the injury, the headache usually took the form of a dull frontal pain, often throbbing in nature, of the type associated with increased intra-cranial pressure.

Complete absence of headache in cases of both slight and severe injury was not uncommonly found. As will be shown later, the degree of headache is to some extent proportional to the increase of intra-cranial pressure.

The/

The pain may continue for only a few hours but in some cases causes distress for days, months or years. This aspect of the subject will be considered later.

VOMITING.

Vomiting occurs not infrequently. In cases in which presence or absence of this symptom was reported it occurred as follows.

FIG. XXIII.

VOMITING	GROUP				TOTALS
	A	B	C	D	
Present	26	19	21	6	72
Absent	47	35	11	4	97
TOTALS	73	54	32	10	169

Vomiting of altered blood was common in cases in which haemorrhage from the nose and pharynx was present. Blood from the nose is swallowed reflexly while the patient is unconscious. If however coma is so profound that even this reflex is abolished/

abolished, there is a risk that blood may be aspirated into the lungs if the patient is nursed in such a position that blood from the nose will gravitate into the pharynx. This danger will be referred to later.

I was unable to show that any significance can be attached to the occurrence of vomiting. It occurred in many cases of all groups. It rarely continued for more than two days after the injury, and in many cases it occurred on only one or two occasions.

FITS

In three cases a fit was reported to have occurred. This happened at a varying interval after the injury. In cases (of which there were 2) in which the convulsion developed within a few hours of the injury, it was presumably caused by the irritative effect of haemorrhages into the brain substance or perhaps over the surface of the brain.

Fits may also occur some days after the accident, as in the following case.

CASE NO. 147 P.C. A male, aged 33, was knocked down by a motor car. He recovered consciousness after an interval of four/

four days, but was then found to have some aphasia. He was easily confused, and the naming of objects was particularly difficult. Nine days after the accident he began to have tonic spasms which involved the right hand and which were followed by clonic jerkings of that extremity. One fit, which I observed lasted for 30 seconds. These recurred several times a day for five days. Thereafter he improved steadily, but when examined nine months later still complained of being unable to remember words. This was very noticeable if he attempted to tell a story.

These Jacksonian attacks undoubtedly indicated some damage to the left cerebral hemisphere. There was no evidence of increased intracranial pressure, and this, combined with the persistent difficulty with speech, was suggestive of damage within the brain substance.

Fits occurring as a late sequela of injury will be considered later.

EXAMINATION of CRANIAL NERVES.

FIRST CRANIAL NERVE.

Anosmia is a not uncommon sequela of a severe head injury. It is usually recognised by the patient himself after full return of consciousness. Damage to the filaments of the olfactory nerve/

nerve may be caused by contre-coup injury, as was probably the mechanism of injury in the following case.

CASE NO. 171. C.R. A male aged 32 was thrown from his motor-bicycle and struck the right parieto-occipital region. A fracture of the skull in this situation resulted, and he lay unconscious for seven days. Thereafter his sense of smell was entirely lost though it had formerly been very acute. A severe degree of loss of memory and mental ability indicated extensive damage to the brain.

SECOND CRANIAL NERVE.

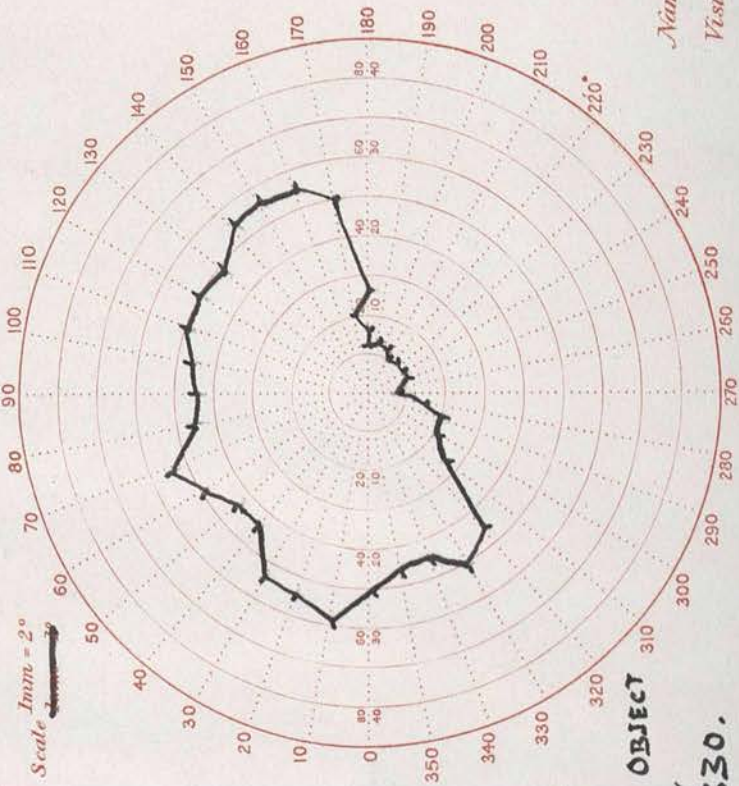
Visual acuity is probably diminished temporarily after all severe injuries, but loss of vision is seldom a lasting complaint.

Damage to the optic nerve or chiasma in fractures of the base of the skull may cause complete blindness in one or both eyes, or may produce temporal field defects if the optic chiasma is injured.

CASE NO. 123. A.R. A male, aged 36, was admitted unconscious, there having been no witness of the accident. Though deeply unconscious on admission, he was fully conscious when examined 12 hours later. There was extensive bruising of the frontal region with extensive effusion into the periorbital tissues. On examining the eyes no direct reaction of the left pupil/

Stroke out Scale not required. Mark out blind spot.

R.

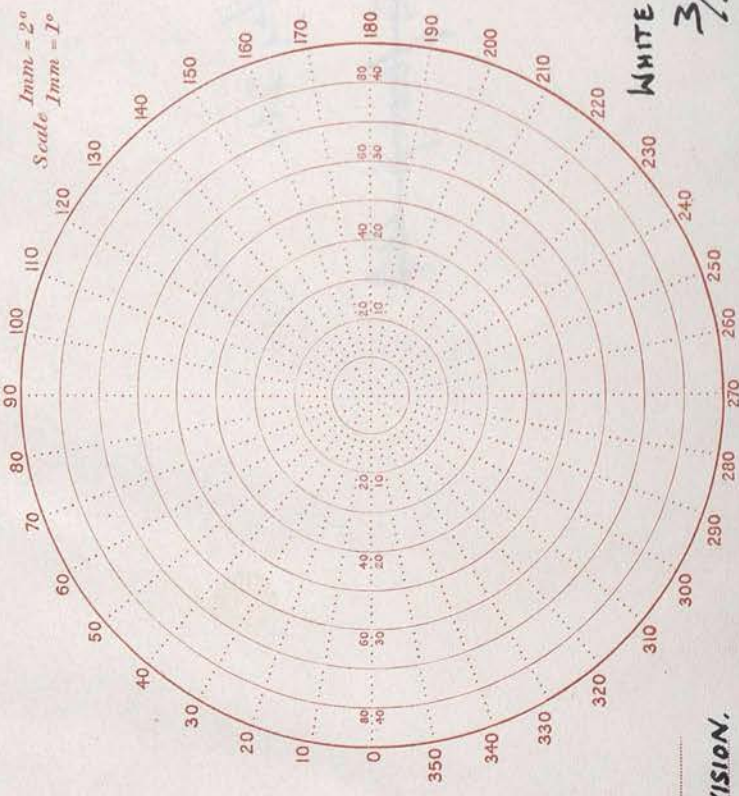


Name A.R.
 Vision 6/6

Date 5-2-31

THE DARREN PRESS, 5 BRISTOL PLACE, EDINBURGH.

L.



WHITE OBJECT 3/330.

Name A.R.
 Vision NO VISION.

Date 5-2-31

TRAQUIRS CHART FOR PERIMETER OR BUERROM SCREEN.

pupil to light could be obtained, while the consensual reaction of the left, and direct reaction of the right were normal. The right pupil was 5.5 mm. and left 4.4 mm. in diameter. There was complete blindness in the left eye and no subsequent recovery occurred. The visual acuity of the right eye after the swelling had subsided was 6/6, but a marked loss of the visual field was found to be present, especially in the lower temporal quadrant (Fig. XXIV.). No improvement in this defect had occurred eight months after the accident.

Increased intra-cranial pressure, when present, may cause papilloedema. This was observed in only two cases. In both of these it developed several days after the injury, and later disappeared spontaneously.

Defects in the visual fields of a homonymous type may occasionally result from damage to the visual cortex, optic radiation, or optic tract.

THIRD FOURTH and SIXTH CRANIAL NERVES.

The pupils were unequal in thirty-eight cases. In only three of these was there clinical evidence of damage to one side of the brain more than to the other. On the other hand, in twenty cases/

cases in which changes in the reflexes suggested that there was damage more to one side of the brain than to the other, the pupils were equal in all but two. The larger pupil was more often (fourteen cases to six) on the opposite side from the site of the injury in those cases which recovered, and more often (four cases to one) on the same side as the site of injury in those that died. It would appear therefore that no significance can be attached to minor inequalities in the size of the pupils.

Gross paralysis of the ocular movements is common, but a slight degree of oculo-motor disturbance, as evidenced by diplopia, is not infrequently seen, and was observed in six cases. These oculo-motor disturbances may be due either to damage to the oculo-motor nerves, or to bruising of the mid-brain. They usually disappear in the course of a few days or weeks, but may be permanent.

In one patient a considerable degree of increase of intra-cranial pressure developed which caused paralysis of the sixth cranial nerve on/

on one side.

CASE NO. 184. E.Y. Aged 22, was knocked down in the street by a motor car. She recovered consciousness in about forty-eight hours but continued to suffer from very severe headaches. Six days after the accident there developed a weakness of the outward movement of the right eye, which, in the course of a few days, became a complete external rectus paralysis. No signs of localised pressure on the brain by haemorrhage could be made out, but a slight degree of papilloedema developed and the cerebro-spinal fluid pressure was 330 millimetres of water. She continued to have severe headache for a month and to have diplopia for 3 months. After that period, however, she improved steadily and when examined 6 months after the accident, had fully recovered.

SEVENTH CRANIAL NERVE.

Facial paresis or paralysis may be present in cases of basal fracture associated with haemorrhage from the ear. It was found in six cases, in all of whom there had been bleeding from the ear on the same side. Complete recovery is the rule in the course of a few weeks.

EIGHTH CRANIAL NERVE.

In basal fractures associated with haemorrhage into the middle ear, some deafness is caused thereby/



thereby. The type of deafness found is usually of the middle-ear variety - that is to say, with the tuning-fork tests, bone conduction is greater than air conduction, and in Weber's test, the sound is referred to the deaf ear.

CASE NO. 163. W.M. A male, 22 years of age, was involved in a collision while riding his motor bicycle. There was haemorrhage from the right ear and from the nose. There was no apparent injury to the scalp, but X-Ray examination showed a fracture of the right temporal region. Weakness of the right side of the face was observed on the day following admission and when consciousness returned two days later a complete peripheral paralysis of the right side of the face was demonstrated. There was some loss of the sense of taste over the anterior part of the right half of his tongue. Acuity of hearing was:-

Right ear: spoken voice at one foot.

Left ear: whisper at four feet.

The Weber test was not referred, but bone conduction in the right ear was greater than air conduction. The patient returned to work eight weeks after the accident but when examined eight months after admission was still suffering from some degree of headache and dizziness. The facial paralysis had recovered, but deafness in the right ear was worse than when in the ward. The tuning-fork tests gave the same result. He also complained of a constant hissing noise in the ear which never went away.

There/

There was no question of compensation outstanding. He had been given £30 in settlement

Evidence of damage to cranial nerves five, nine, ten, eleven and twelve was in no case detected.

MOTOR FUNCTIONS,

Even in a slight degree of concussion, disturbance of the motor functions is evident, and in the great majority of cases forms a prominent feature. Complete flaccid paralysis is a feature of severe cases, while in those of less severity any movements which occur during the period of unconsciousness are involuntary and reflex in nature. As was pointed out above, the highest motor mechanisms are those that are most easily upset, and only in the severe injuries are the primitive reflex motor activities disturbed.

From the practical point of view, examination of the motor functions is carried out in cases of head injury in order to ascertain whether one side of the cerebrum had had its activity more disturbed/

disturbed than the other, and especially to ascertain in severe cases whether the functioning of one cerebral hemisphere is being progressively impaired, as may occur, for example, through haemorrhage continuing after the accident and gradually compressing the brain. The development of weakness or paralysis of one side of the body coming on gradually after the injury must always indicate that a complication of this kind is occurring. Thus it is of great importance in every case of head injury that examination should determine at the earliest possible moment whether there is weakness of one side of the body as compared with the other. This can be determined with a fair degree of certainty even in comatose patients, and forms an essential part of the preliminary examination of all head injury cases, as will be described later. Early examination having demonstrated that there is no gross hemiparesis caused by cerebral contusion, the subsequent finding of weakness of one side of the body assumes great significance. Changes in the reflexes/

reflexes may provide confirmatory evidence that cerebral damage is chiefly unilateral.

Bilateral extensor plantar responses are not uncommonly found when the patients are first examined, as is shown in Fig. XXV. This abnormality is more commonly found in the severe cases - that is in those which are unconscious when first examined.

FIG. XXV.

PLANTAR REFLEXES in CASES EXAMINED within
24 HOURS of ACCIDENT.

GROUP	BOTH FLEXOR.	BOTH EXTENSOR.	ONE FLEXOR AND ONE EXTENSOR.
A	46	2	5
B	28	3	4
C	17	14	3
D	3	10	2
	94	29	14

CASES/

CASES in which the PHYSICAL EXAMINATION INDICATED that ONE SIDE of the BRAIN was MORE DAMAGED than the OTHER.

In fourteen cases, changes in the reflexes indicated that one pyramidal tract had been more damaged than the other. Haemorrhages into the brain stem are relatively uncommon, and one can usually assume that any damage to the pyramidal tract is caused within the cerebrum, and, therefore, if more marked on one side, that one cerebral hemisphere has been more severely injured than the other.

In this connection it must be borne in mind that the side of the brain which is most severely damaged bears no constant relationship to the side of the skull which receives the injury. As will be shown later the force of a blow to the skull is distributed to all parts of the brain, and that part of the brain which is opposite to the site of injury is particularly liable to be severely injured. The mechanism of this contre-coup injury will be discussed later. The point of practical importance is that the site of maximum brain injury cannot/

cannot be deduced from the position of the injury to the skull. This is well-shown in the two following case records. Neither of these cases is included in the series of two hundred.

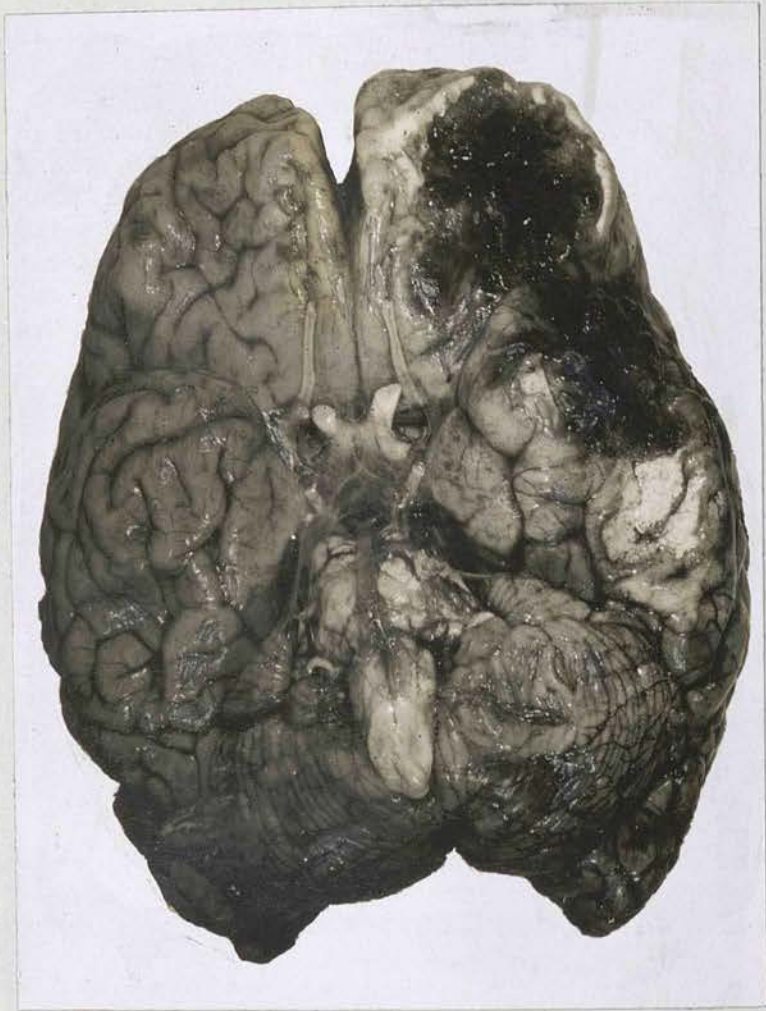
Blow to the right side of the skull causing left-sided hemiplegia.

CASE NO. 201 A.G. A female aged 26, was knocked down by a motor car and immediately rendered unconscious. When examined five hours later she was found to have a bruise and cut in the right parietal region. She was deeply stuporose. There were free movements of the right arm and leg, but no movement of the left upper and lower extremities could be elicited. There was also paralysis of the left side of the face. A period of over two weeks elapsed before she recovered consciousness. During that period the cerebro-spinal fluid was found to be normal and to show no increase of pressure. The dura mater was exposed by operation just in front of the wound, but no haemorrhage could be found. Seven weeks after the accident she still had a marked degree of spastic hemiplegia.

Blow to right side of the skull causing right-sided hemiplegia.

CASE NO. 202 M. McM. A male aged , was knocked down by a motor car and immediately rendered unconscious. He remained deeply stuporose until his death four weeks later. During the whole of that period there was complete loss of/
of/

FIG. XXVI.



BRAIN of CASE 292. showing:-

CONTRE-COUP injury of left frontal and
temporal regions.

of power of the right upper and lower extremity, whereas there was no apparent weakness of the left side. At the post-mortem examination, a depressed fracture of the right parieto-occipital region was found. The cerebral tissue below the site of fracture showed little evidence of damage, but the contre-coup injury was so extensive that a large part of the left hemisphere was destroyed (see Fig. XXVI).

ABNORMAL MOVEMENTS.

The presence of abnormal movements, such as tremor or athetosis, was not observed as a feature of the acute stage.

In one case of great severity, (A.G. aged 12 years. Case No. 190) muscular twitchings were observed, which simulated closely those seen in uraemia. The circulation at the time was very poor, which suggests the possibility that inadequate nutrition of the nervous elements was the cause of the condition.

RIGIDITY of the NECK MUSCLES.

A sign which was often present was rigidity of the neck muscles. Marked degrees of this are easy to detect, but the slighter degrees can also/

also be determined with a little practice. The sign was often present when Kernig's sign was absent. It was found to a slight degree in thirty-eight cases and to a marked degree in twenty-eight. As was to be expected, the sign was constant in cases in which meningitis developed. Rigidity of the neck muscles is also recognised as a sign of sub-arachnoid haemorrhage, a not uncommon result of severe head injury, as will be shown later. On thirty-two occasions in which the cerebro-spinal fluid was found to contain a uniform and marked admixture of blood (over 1000 r.b.c. per cmm.), the neck muscles showed some rigidity, except in one patient who was deeply comatose and dying. The degree of rigidity in subarachnoid haemorrhage is often so pronounced that the diagnosis of meningitis is apt to be made. Rigidity of the neck muscles, in the series under consideration, was sometimes present without there being any abnormality in the cerebro-spinal fluid, and it is necessary to remember that the sign may be produced by the presence of a bruise in the neighbourhood of the neck or occipital region. The rigidity when marked is/

is usually associated with a degree of neck retraction, which, as in the case of meningitis, is more pronounced in children than in adults.

FIG. XXVII.

NECK RIGIDITY.	GROUP.				TOTALS.
	A	B	C	D	
None	58	36	9	6	109
Slight	13	12	13	3	41
Marked	2	3	20	3	28
No record	7	6	5	4	22
TOTALS	80	57	47	16	200

The frequency with which neck rigidity was noted is shown in Fig. XXVII. The large proportion of cases in Group C which show this sign to a marked degree is a striking feature of the table.

As will be shown later, blood in the cerebro-spinal fluid usually disappears in the course of/

of three or four days. Neck rigidity also ceases to be present at about the same interval after the injury. This is shown in the case of E.Y. (Case No. 184.) In the following table the amount of blood in the cerebro-spinal fluid in this case and the degree of neck rigidity are compared. (Fig. XXVIII). This case is considered in greater detail later.

FIG. XXVIII.

INTERVAL after INJURY at which LUMBAR PUNCTURE was carried out.	RED BLOOD CORPUSCLE COUNT PER c.mm.	DEGREE of NECK RIGIDITY.
16 hours	90,000	marked
3 days	10,000	slight
5 days	130	none
8 days	0	none

CASE E.Y. (NO. 184).

It may be concluded that neck rigidity is often present after severe head injury and is usually associated with subarachnoid haemorrhage.

DISTURBANCES/

DISTURBANCES of the SPHINCTERS.

Loss of control of the sphincters is a usual accompaniment of unconsciousness, whether resulting from a head injury or other cause. Retention of urine is an important complication in the severe cases of head injury and often leads to great restlessness. It was present in several cases and should be examined for, as a routine, in all severe head injury cases.

SENSORY LOSS.

When loss of consciousness is profound and the patient is in a state of coma, painful stimuli evoke no response. When consciousness is beginning to return, such stimuli produce withdrawal movements and are often associated with changes in facial expression which indicate that an unpleasant sensation has been appreciated. In the deeper degrees of unconsciousness the withdrawal movements are of a primitive nature, but as recovery of consciousness progresses they become more/

more purposeful and more effective in avoiding the stimulus. The patient may actually attempt to retaliate, and not infrequently expresses his ideas on the subject with freedom. The patient has subsequently little or no recollection of his actions at this stage and has not, in fact, recovered full consciousness.

Delicate sensory tests can only be carried out after full consciousness has returned. In the series investigated, however, no abnormality was found in any of the cases examined.

HIGHER CEREBRAL FUNCTIONS.

RETROGRADE AMNESIA.

In the series of cases investigated, recollection of the actual blow to the head was never present when immediate loss of consciousness had resulted. One woman remembered being struck by the motor car which knocked her down, but in that case it was the fall to the ground which caused the head to be injured, and of this fall she had no recollection. After return of consciousness, it was found in all cases that there was an interval, immediately preceding the injury, of which the patient/

patient had no recollection. The duration of this interval, the period of retrograde amnesia, was enquired into carefully in ninety-six cases. In sixty-nine cases its duration was only one or two seconds, in twenty-four cases it lasted several minutes, while in only three cases was it of longer duration than half an hour. This interval was estimated by questioning the patient after full return of consciousness. If questioned before this, the interval of loss of memory before the accident was of considerably longer duration.

In the following table the duration of retrograde amnesia is compared to the groups into which the cases fall.

FIG. XXIX.

Approximate Duration of Retrograde Amnesia.

GROUP	A FEW SECONDS	1 to 30 MINUTES.	OVER 30 MINUTES.
A	35	4	0
B	28	8	1
C	6	12	2
	69	24	3

The/

The longer periods of retrograde amnesia are therefore more commonly found in cases which fall into Group C.

Determination of time of return of full consciousness.

The recollection of events shortly preceding the accident may usually be taken as an indication that full consciousness has returned.

The question as to when a patient should be considered to have regained complete consciousness is a point of medico-legal importance which would arise in cases such as the Merritt trial. (38)
From my experience of head injury cases, I feel justified in asserting that if an individual after a head injury is able to describe correctly events which preceded loss of consciousness by only a few minutes or seconds (as did Mrs. Merritt) consciousness has then returned in full.

THE ACCURACY of MEMORY of EVENTS ANTECEDENT to and FOLLOWING the ACCIDENT.

In those states of confusion, disorientation and altered personality which may occur before full consciousness returns, the patient has no recollection/

recollection of events shortly preceding the accident. When, however, memory of events preceding the accident was present, it was never found, in the present series, to be other than accurate. This point, which is of medico-legal importance was recently emphasised by Somerville. ⁽³⁹⁾

With regard to events following the accident, the patient's ideas may be permanently inaccurate. This is well shown by Somerville's case of a boy who incorrectly concluded that the doctor, whom he remembered attending to him after his injury, had caused the accident. This case was used in the Merritt trial, as providing evidence that the recollection of events preceding the injury may be inaccurate. ⁽³⁸⁾ It is, however, apparent that this case provides no evidence in favour of this possibility. The boy's belief was entirely due to his faulty interpretation while recovering consciousness and had no connection with his actual memory of events preceding the accident. In point of fact, as Dr Somerville subsequently explained, he remembered nothing of what occurred after he left his home ten minutes before the accident occurred. That is to say, he had a complete retrograde amnesia for/

for a period of ten minutes.

STAGES in the RECOVERY of CONSCIOUSNESS.

The stages of recovery of consciousness and particularly of the mental and speech functions are of great interest and may repay detailed study. The following case record provides a typical illustration of the steps towards recovery in a case of severe head injury.

CASE NO. 151 R.G. A shepherd aged 27, was admitted to hospital on 3-5-31, having been thrown off his motor-cycle. When examined a few hours later, there was no severe shock. He was bleeding from the right ear and was tossing restlessly in bed. He made no attempt to speak and was in a deeply stuporose condition.

4-5-31

Owing to violent restlessness he was transferred to the ward for incidental delirium, where he had to be strapped in bed. He powerfully resisted any interference and seemed very sensitive when the plantar reflexes were being examined. There was little or no attempt to speak.

5-5-31

To-day he was fighting hard against the straps which held him down and calling out loudly without using any definite words.

9-5-31

He greeted me cheerfully with "Good-morning, Sir", and shook hands. He talked cheerfully about having to get home tonight. Much of what he said/

said was meaningless, but a few sentences were intelligible. He gave his name correctly, but in reply to a question said, "I've been here two years". Sentences often begun correctly, later became meaningless. - "Here, could I go out into the . . ." He almost wept when prevented from getting up and seemed very annoyed. "Well, I'll come back again", he would say impatiently. "That's no kind of way to . . . now don't you think it". Then sitting up and waving his arms about, he would argue vehemently but quite meaninglessly with the attendant, and wept when again prevented from getting up.

Plantar reflexes were to-day flexor, whereas they had been previously extensor on both sides.

19-5-31.

He was very talkative and emphasised all he said with powerful gestures. His condition was very like that of a talkative and intoxicated person. He argued that he must go home, and boasted freely of his great skill at shearing sheep and catching trout. He promised to give money to the Sister&examiner if they would let him go. He talked incessantly and repeated his arguments over and over again. Most of his sentences were coherent, but a few were meaningless. Like a man who is intoxicated, he paid little or no attention to what was said to him, and would not listen to reason. He had no knowledge of where he was and absolutely no comprehension of his condition. After considerable persuasion he would respond to a simple request, such as "Put out your tongue".

25-5-31/

He was quite changed. He remembered/

remembered being troublesome in the ward and was now very apologetic. He said that he felt very well and strong enough to start work again. He knew where he was and why he was there, and had a normal understanding of his environment. There was no repetition of his former unbalanced talk. He listened to and appreciated all that was said to him. He could now recollect certain events preceding the accident. He remembered driving along the road at a speed of about thirty-five miles an hour, anxious to get home before dark, and remembered actually colliding with the tar barrel which caused his accident.

Thereafter this patient's recovery was uneventful. When seen seven months later he was physically fit, but his doctor said he was much less reserved than before the accident. He had now no recollection of hitting the tar barrel but remembered events clearly to within a few minutes of the accident. He was unable to remember the number of sheep he counted about 6 hours before the accident, but otherwise he could find no fault with his memory.

The case of R.B. (Case NO. 146) is also of interest in this connection. This case was of very great severity and led to a permanent degree of mental defect. The incessant repetition of the first phrase he could say, "Oh, this is terrible", was very striking. A week after admission he began to answer one or two simple questions correctly/

correctly, but further questions elicited meaningless answers, or else he would answer all questions with a repetition of his name, "Robert Brown", given correctly in reply to the first question, "What is your name"? A month after the accident he was still unable to name objects, though when shown a cigarette and asked what he would do with it, he answered, "Smoke it".

Six weeks after the accident he was in a cheerful but stupid state. He would smile on all occasions and had little insight into his surroundings. He did not understand the position of the Sister in charge of the ward, and described her as "the person who does no work". That he had some slight understanding, however, is evidenced by the fact that he told the Sister that the nurse only worked when she was there!

When examined four months after the accident, he had a rather vacant expression and was of little use at doing even simple tasks. He was very easily confused, unable to read, and could not be sent a message unless it was written down.

I have made several detailed records of
the/

the recovery of speech function in cases such as the above and have found that they all show remarkable similarity. At first all words are impossible. The first attempt to articulate usually takes the form of a groan or a shout repeated frequently. Then a few words are occasionally uttered. These may be meaningless, but soon a few common phrases are correctly produced. These are often repeated frequently and are usually shouted out loudly. The patient's vocabulary gradually increases. Common phrases are at first all that can be said, but gradually speech becomes more and more intelligible. There is still, however, a lack of any power of understanding or reason. The patient's incessant talk is mainly repetition. He pays no attention to what is said to him and is quite disorientated. The inhibitions and social training which prompt the average patient to speak with respect to the nurses and doctor are among the last functions to recover, so that he is often impudent to, and familiar with, his attendants. Subsequent to this stage the recovery of insight, orientation and the usual social habits rapidly follows, and the patient recovers full consciousness and begins to think about events preceding his accident.

EXAMINATION/

EXAMINATION OF THE CEREBRO-SPINAL FLUID.

Examination of the cerebro-spinal fluid was carried out on sixty-seven occasions in forty cases. Persistence of severe headache or of unconsciousness was considered to justify lumbar puncture.

I performed lumbar puncture in these cases with the patient lying on his side, the head and spine being on the same level. A fine needle was used, and the pressure of the cerebro-spinal fluid was in most cases measured by Greenfield's manometer. I had previously used this instrument on over a hundred occasions and found it entirely satisfactory. Fluid can be removed very slowly, as the rate of flow can be accurately controlled by means of the tap on the needle. To ensure an accurate estimate of the pressure, certain precautions are necessary. The pressure must be taken while the patient's muscles are relaxed, and there must be no pressure on the jugular veins, such as might be caused by bending the head forwards. It is probably undesirable to reduce the pressure below/

below normal, as in certain cases this might stimulate haemorrhage from damaged cerebral vessels.

PRESSURE.

COMPARISON of the CEREBRO-SPINAL FLUID PRESSURE to the MENTAL STATE of the PATIENT at the TIME of LUMBAR PUNCTURE.

The cases in which lumbar puncture was performed were all cases of severe injury, as in the slighter cases there was no indication for performing the operation.

Taking readings above 200 millimetres of water pressure as being above normal, out of the forty-nine readings made the pressure was increased in thirty. In only nine instances, however, was the pressure above 330 millimetres. (Fig. XXX)

In the following table, each pressure estimation is compared with the mental state at the time of lumbar puncture.

Fig. XXX/

FIG. XXX.

MENTAL STATE	CEREBRO-SPINAL Fluid Pressure (Millimetres of Water)					TOTALS
	0 to 100	100 to 200	200 to 300	Over 300	TOTALS	
Normal	1	3	10	2	16	
Confused	2	3	7	1	13	
Stuporose	2	5	4	6	17	
Comatose	0	3	0	0	3	
TOTALS	5	14	21	9	49	

The figures represent the number of cerebro-spinal fluid pressure estimations.

It is at once apparent from a study of this table that there is no relationship between the degree of unconsciousness and the fluid pressure. On twelve occasions the cerebro-spinal fluid pressure was above 200 millimetres of water in cases in which consciousness had fully returned; while on seven occasions in which the pressure was below 200 millimetres of water, the patient was stuporose; and in three deeply comatose patients, all of whom died a few hours after lumbar puncture, the pressure was in no case above 200 millimetres.

This table therefore indicates that the depth of unconsciousness is not an index of the degree of intra-cranial pressure.

The pressure reading in uncomplicated cases, however, may provide some indication of the degree of cerebral oedema present. ⁽²⁰⁾ JEFFERSON has recently emphasised that when severe head injuries are operated upon several days after the accident, the brain is often found to be shrunken and dehydrated, even though the patient is still deeply stuporose. This surgical observation may explain the low pressure readings in several deeply unconscious patients shown in the above table.

These/

These observations justify the following conclusions.

- (1) A certain increase of intra-cranial pressure often develops after head injury.
- (2) This increase of pressure when present is seldom great.
- (3) The degree of intra-cranial pressure is not proportional to the mental state of the patient.
- (4) It is probable that the degree of intra-cranial pressure depends upon the amount and degree of cerebral oedema.

A COMPARISON between the CEREBRO-SPINAL FLUID PRESSURE and the PRESENCE of HEADACHE at the TIME of LUMBAR PUNCTURE.

In order to attempt to find the cause of the severe headaches which may follow head injury, a comparison has been made between the cerebro-spinal fluid pressure and the degree of headache. In some cases that were deeply unconscious the presence of headache could not be determined. On thirty occasions, however, an accurate comparison could be made, as is shown in the following table.

Fig. XXXI./

FIG. XXXI.

DEGREE of HEADACHE.	CEREBRO-SPINAL fluid pressure (millimetres of Water).				Totals
	0 - 100	100 - 200	200 - 300	over 300	
None	1	1	3	1	6
Moderate	0	2	4	0	6
Severe	1	1	12	4	18
TOTALS	2	4	19	5	30

The figures represent the number of cerebro-spinal fluid pressure estimations.

From this table it is seen that in ninety per cent of the cases in which headache was severe, the cerebro-spinal fluid was above its normal pressure, that is, the pressure rose above 200 mm. of water. The figures unfortunately are small, but even so, they probably indicate that if severe pain in the head develops after injury to the skull, a considerable increase of intra-cranial pressure is present. It is important to distinguish between pain due to local injury to the scalp or skull, and pain due to increased pressure. The character of the increased-pressure type of headache in these cases is that of a dull, throbbing or bursting type of pain, usually felt mainly in the frontal region. It is aggravated by stooping and is often relieved to some extent by raising the level of the head relative to the rest of the body.

From these observations it is probable that the presence of severe headache of the type described indicates that the intra-cranial pressure is raised.

QUANTITY of BLOOD in the SUBARACHNOID SPACE.

If/

If, in carrying out lumbar puncture, care be taken to penetrate the dura mater once only, and to pierce it for the least necessary distance, it is the writer's experience that blood contamination from the puncture does not occur, except in a degree so slight as to be discerned only on microscopical examination of the fluid. In most of the cases, I carried out both a red and white cell count of the cerebro-spinal fluid within an hour of taking the specimen. In all specimens in which blood was present it was found to be evenly mixed with the fluid withdrawn and, on standing, the supernatant fluid was yellow in colour.

In making a cell count, the specimen was first thoroughly shaken, and, according to the degree of blood contamination, the red-cell count was carried out on either the ordinary blood-cell counting slide, or on the Fuchs-Rosenthal chamber devised for counting the cells of the cerebro-spinal fluid. When the blood contamination was very great it was necessary to dilute the specimen in a blood-counting pipette before carrying out the count.

It is well-known that in cases of spontaneous/
taneous/

spontaneous haemorrhage into the cerebro-spinal fluid, such as may occur in a case of leaking cerebral aneurysm, the initial dramatic onset of severe pain in the head is often followed, after a varying interval, by loss of consciousness. This loss of consciousness may partly be brought about by increased intra-cranial pressure, but there is little doubt that it is largely due to alteration of the chemical constitution of the cerebro-spinal fluid through the admixture of blood. It is found, for example, that the pressure of the fluid in these cases is often not greatly raised. Further, in fatal cases, the clinical picture is quite unlike that of death from increased intra-cranial pressure. It resembles far more nearly the type of death seen after severe head injuries, as in the cases, charts of which have been described above. The experimental work of BAGLEY⁽²⁾ has recently shown that in dogs the subarachnoid injection of blood from the animal itself may produce widespread irritative effects including loss of consciousness and convulsions. It is not surprising therefore to find that in those cases of head injury in which the amount of blood in the cerebro-spinal fluid is very great, loss of consciousness is always deep. This is shown in the following table.

Fig. XXXII/

FIG. XXXII.

Blood in Cerebro-spinal Fluid (Red Blood Corpuscles per c.mm.)

	0 to 1000.	1000 to 100,000.	100,000 to 500,000.	Over 500,000
<u>Mental State.</u>				
Normal	11	6	0	0
Confused	6	7	0	0
Stuporose	3	13	4	0
Comatose	0	1	0	2
<u>Headache.</u>				
None	5	2	1	0
Moderate	2	1	0	0
Severe	9	8	2	0

The figures represent the number of cerebro-spinal fluid examinations carried out.

These/

FIGS. XXXIII?

FIG. XXXIV.

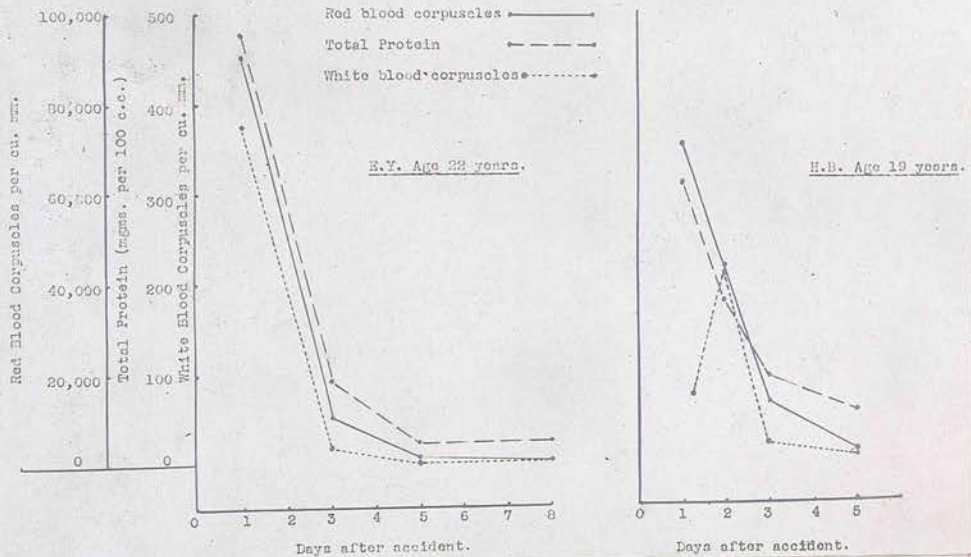
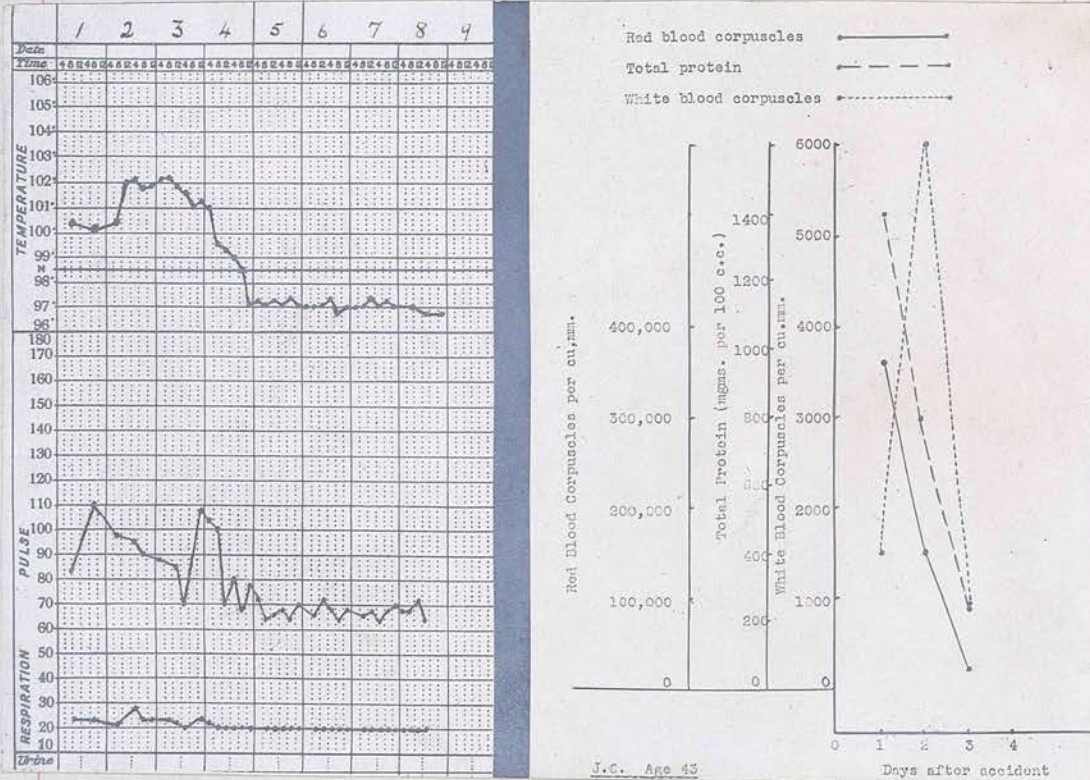


FIG. XXXV.



These **FIGURES** are referred to later.

These figures suggest that a large quantity of blood in the subarachnoid space may cause, of itself, loss of consciousness. It must be borne in mind, however, that excessive subarachnoid haemorrhage is often an indication of severe cerebral laceration, which would also produce prolonged unconsciousness.

The table also compares the degree of headache with the amount of blood contamination, but the comparison provides no evidence of relationship between the two.

THE RATE at which the BLOOD is REMOVED.

There were only a few cases in the series in which I felt justified in carrying out repeated lumbar punctures. Four spinal fluid examinations were, however, performed in Case E.Y. (Case No.184) and in Case H.B. (Case No.144). Three examinations were carried out in Case J.C.(Case No.149). In each of these cases, the red blood corpuscle count, the white blood corpuscle count and the total protein content of the cerebro-spinal fluid were plotted against the interval after injury at which lumbar puncture was performed. The results are shown in Fig.XXXIII, XXXIV, and XXXV. The rapid disappearance of/

of the blood is a striking feature of all three charts. Not only so, but the rate of disappearance is remarkably constant, in each case there being relatively very few red blood cells present 72 hours after the injury. A further point which is apparent in the curves from Cases H.B. and J.C., (Fig. XXXIV and XXXV), cases in which the fluid was examined on three consecutive days, is that the reduction of the red cell count between the first and second examination is approximately equal to the reduction in the cell count between the second and third examination. Thus the curve for that period in both cases approximates closely to a straight line, and the observation suggests that the mechanism for removing the blood cells operates at a constant rate. It is, however, assumed in discussing these cases that no further haemorrhage occurred after the first twenty-four hours following injury. If, as in one case (No. 11), a large quantity of blood (50,000 cells per cubic millimetre) is found in the fluid at an interval of seven days after the injury, it is probable either that haemorrhage continued for some time after the accident or that a fresh haemorrhage occurred at an interval after the injury. This latter/




ILLUSTRATION to show the appearance of the cerebro-spinal fluid obtained from Case A.G. (No. 154), 10 days after the accident.

latter is a well-recognised complication and is described as Delayed Haemorrhage or Spaet-apoplexie (6,37).

The following case record provides an example of this complication.

CASE NO. 100 W.G. A male aged 17 years, was found unconscious on the road beside his bicycle. He recovered consciousness after an interval of several hours. He continued however to suffer from headache and was found to have marked neck rigidity. Lumbar puncture was carried out two days after the admission and the fluid was found to be deeply blood-stained. Relief of headache immediately followed lumbar puncture, and ten days later he was discharged free of symptoms. A month after discharge he was readmitted with recurrence of severe headache. For a period of six days thereafter he was in a stuporose state and the headache continued unabated. Lumbar puncture was then performed, deeply blood-stained fluid was again drawn off and, as before, relief of headache occurred immediately. Recovery thereafter was uneventful, and when examined seven months later he had no complaint except of an occasional headache.

As the blood cells disappear from the spinal fluid, the latter becomes brown in colour, as in Froin's syndrome. The colour is shown in the illustration of the fluid from case A.G. (Fig XXXVI). The specimen of fluid was obtained at the second lumbar puncture ten days after the injury. The fluid/

fluid had been examined five days before and at that time contained 52,000 red blood cells per cubic millimetre. This yellow or brown colouration disappears in a few days after the blood cells have been removed. In Case E.Y. (No.184), for example, the fluid was clear and yellow on the fifth day, but three days later, on the eighth day after the injury, was quite colourless. The point is occasionally of considerable clinical importance, as, for example, in the diagnosis of sub-arachnoid haemorrhage several days after it has occurred.

CLOT FORMATION.

The development of a clot in a specimen of cerebro-spinal fluid provides the most delicate indication available of the presence in the fluid of fibrinogen (16). There is no tendency for blood in the cerebro-spinal fluid to clot unless it comes in contact with damaged tissues. In one fatal case in this series G.H. (No.193) the red cell count in the fluid was actually 1,400,000 per cubic millimetre and yet no tendency to clot was apparent in the specimen after allowing it to stand for half an hour. In all cases of meningitis, a clot develops and indeed the development of a clot is always suggestive of infection having occurred.

TOTAL/

TOTAL PROTEIN CONTENT.

The total protein content of the fluid withdrawn was in most cases estimated in the Biochemical Laboratory. The specimen was thoroughly shaken before the test was carried out, and the Micro-kjeldahl method was used.

The above figures XXXIII, XXXIV, and XXXV, show that the fall in the protein content paralleled closely the fall in the red cell count. In Fig. XXXIII for example, the protein content by the fifth day was only eighteen milligrammes per 100 cubic centimetres, that is to say it had fallen to normal in this short period. These observations are of interest from the point of view of the mechanism by which the blood is removed. If the red cells underwent lysis before their constituents were removed, the protein content would not be expected to fall so rapidly as it does in these cases. It seems therefore more likely that phagocytosis of the red cells forms the essential part of the mechanism for removal. The endothelial cells lining the subarachnoid space, ventricles and choroid plexuses are all phagocytic, (HURST)⁽¹⁸⁾, and they are no doubt responsible for the removal of the erythrocytes. I have often observed blood pigment in these lining cells in post-mortem material, derived from cases in/

in this series. I have not, however, seen any sections in which the actual occurrence of phagocytosis could be demonstrated.

WHITE CORPUSCLES.

The white cells were counted on the Fuchs-Rosenthal slide, using Toluidine Blue as a stain, and acetic acid to dissolve the red cells.

The number of white cells present in the cases examined could, in uncomplicated cases, be accounted for largely by the haemorrhage itself. Where this was the case, the white cells usually disappeared as rapidly as did the red cells. This was apparent in the above cases, E.Y. and H.B. (Figs. XXXIII and XXXIV). A rise in the white cell count is an early sign of an inflammatory reaction. This may be merely a mild aseptic type of meningitis, but may of course be due to a virulent pyogenic infection.

Case J.C. (No. 149) showed the features of an aseptic meningitis. For over forty-eight hours after admission the patient had a high temperature and pronounced neck rigidity. At the end of this period a second lumbar puncture was carried out FIG. XXXV and the white cell count was found to have risen/

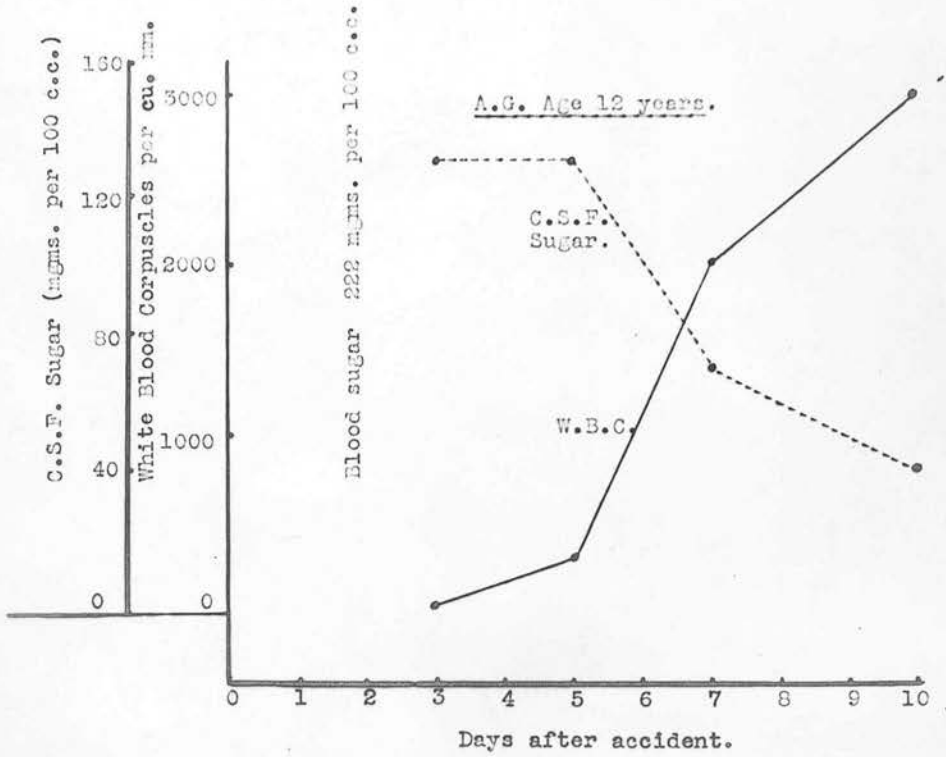
risen to the very high figure of 6000 per cubic millimetre. In the course of the next twenty-four hours, however, the temperature dropped to normal and the white cell count fell to 800 per cubic millimetre. The red cells and protein disappeared as in cases E.Y. and H.B. (Fig. XXXIII and XXXIV). Recovery thereafter was uneventful.

A rise of the white cell count in the cerebro-spinal fluid is the earliest sign of a developing infection. This is illustrated by Case A.G. which is referred to below.

ESTIMATION OF SUGAR.

The quantity of sugar in the blood is raised considerably after severe head injury, and glycosuria is not uncommon ⁽²⁹⁾. It is therefore not surprising to find that the sugar content of the cerebro-spinal fluid is also found to be high. Case A.G. (No. 190) is of interest in this connection. The head injury was very severe, and two days after the accident the blood contained 222 milligrammes of sugar per 100 cubic centimetres. On the day following, the cerebro-spinal fluid contained as much as 130 milligrammes per 100 cubic centimetres, while there were practically no white cells in the fluid./

FIG. XXXVII.



fluid. This patient developed an infection of the middle ear, which had been damaged by a basal fracture, and gradually developed a fatal meningitis. Fig. XXXVII shows how early in the case evidence of the development of this infection became apparent in the cerebro-spinal fluid. The rise in the white cell count and the fall in the sugar content are striking features. The rise in the white cell count was the first sign of threatening infection, and indeed this sign may be looked on as the earliest and most delicate indication of a commencing meningitis. The patient in this case survived for 19 days after his injury.

THE MECHANISM
BY WHICH THE BRAIN IS INJURED.

It is a remarkable fact that the skull, which contains a fragile structure such as the brain, can be subjected to sudden blows of considerable severity without injury to the brain, especially in view of the fact that some movement of the brain relative to the skull may occur, as is evidenced by the occasional tearing of a cortical vein from its attachment to a venous sinus. Whether the head receives a blow or whether the head strikes the ground, the mechanism of cerebral injury is the same. The brain is obliged to undergo a sudden change in momentum, which, if the skull were not there to protect it, would cause its complete destruction. The fact that the brain fits the skull accurately is the main factor which enables the skull itself to bear the brunt of the blow.

The force applied to the skull in a case of concussion may be great and may be applied to only a small area of its surface. The force of the blow is, however, conveyed to the brain by the whole inner aspect of the skull on the side injured and in this/

this way is so distributed that the damage to any one part is correspondingly reduced.

Beyond violence of a certain degree, however, the brain also becomes damaged. Here again the effect is lessened by the force of the blow being distributed to all parts of the cerebrum. That a mechanism exists which distributes the strain to all parts, and so reduces the damage to any one part, is shown by the scattered capillary haemorrhages which are often found throughout the brain in cases in which no gross cerebral contusion can be demonstrated.

CONTRE-COUP INJURY.

It is largely through the tearing of small vessels in the pia arachnoid that haemorrhage into the cerebro-spinal fluid occurs. The bleeding is usually most at a point exactly opposite to that at which the injury is received. It seems to me that this so-called contre-coup injury, which is the most constant of all post-mortem findings in these cases, cannot be explained by any wave of force having been applied to the brain at that point.

If we take for example the case of a man who falls on the frontal region on a hard surface. The momentum of the skull is arrested with great suddenness/

suddenness and the skull, in its turn, arrests the momentum of the brain in the manner described above. The force of the brain's momentum is directed towards making the brain continue its velocity in a downward (frontal in this case) direction. The occasional tearing of a cerebral vein provides conclusive evidence that some movement of the brain relative to the skull can take place. All parts of the brain are attempting to move in the same direction, and the maximum movement relative to the skull will be at a point opposite to the site of the frontal impact, viz., in the occipital region. It is, I think apparent that the sub-arachnoid space is the place of least resistance to this force. The combined forces of surface tension and atmospheric pressure will prevent the spaces between the dura-mater and skull, or the dura-mater and arachnoid being opened up. What then are the forces which prevent the space between the pia-mater and arachnoid being forced open? In the first place there is the intra-cranial pressure which is slightly greater than atmospheric pressure, and in the second place there are the fine fibrous bands uniting the pia-mater and arachnoid. The former force is the most important, but is somewhat lessened because unlike the subdural space, it is possible for/

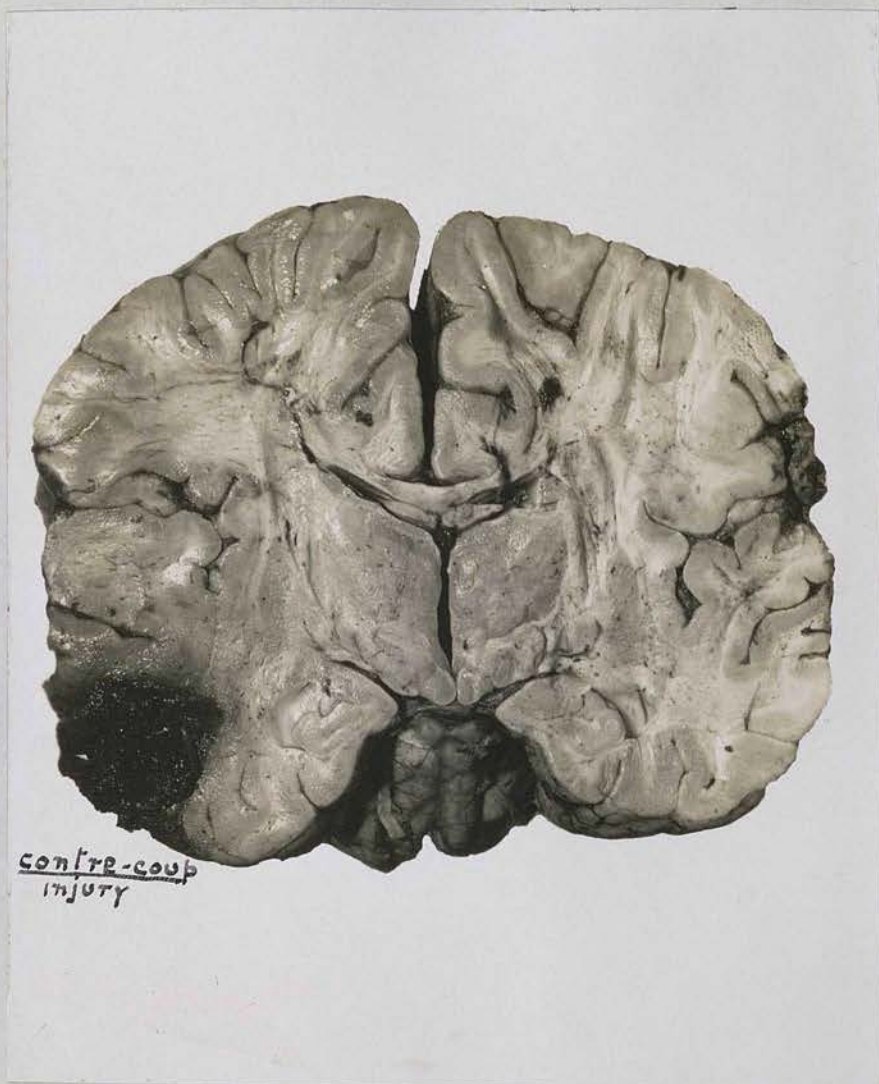for the subarachnoid space to enlarge without becoming a vacuum. This is because it can be filled with cerebro-spinal fluid from other parts. Indeed the fact that brain tissue is heavier than the cerebro-spinal fluid will tend to make the brain force itself downwards (forwards in this case) at the expense of the less heavy fluid, which will therefore tend to flow away from the site of impact.

Any movement of the brain such as I am attempting to describe would be greatly lessened or abolished, were the skull a closed box containing a constant volume of tissue and fluid. This doctrine of the skull being a closed box of this nature cannot however, be accepted as correct; because in the first place the brain volume can be greatly reduced by forcing blood away from it, and in the second place, the brain and cerebro-spinal fluid have considerable room for expansion through the foramen magnum.

I therefore suggest that the common contre-coup injury is caused by the brain tearing itself from its coverings by the force of its own momentum. The damage is therefore most likely to occur at that part of the brain which is opposite to the site of injury, though in very severe cases the injury may be much more extensive.

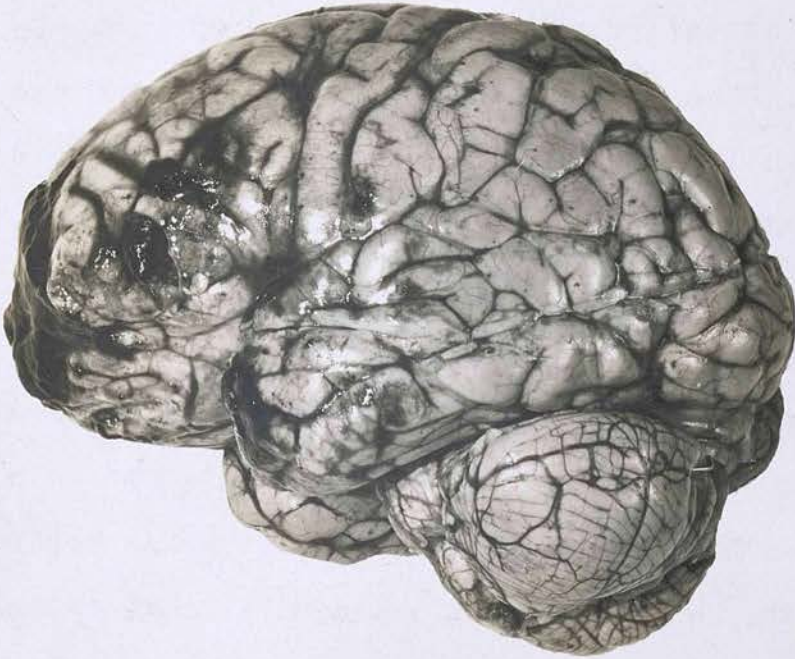Should/

FIG. XXXIX.



Contre-coup injury showing extension of sub-arachnoid haemorrhage into the substance of the brain.

✓
FIG. XXXVIII.



CONTRE-COUP injury of left frontal region showing:
sub-arachnoid haemorrhage.

Should this be the correct explanation of the mechanisms by which contre-coup damage is produced, the type of injury found in this situation should be of a different nature to that found at the site of impact. This is precisely what actually occurs. At the site of injury some cerebral contusion may be apparent. The features of cerebral contusion are discolouration of the surface of the brain with some small haemorrhages within the brain substance in that situation. Haemorrhage on the surface of the brain is at the site of the injury absent or very slight.

In the case of the contre-coup injury on the other hand, sub-arachnoid haemorrhage is the chief and often the only sign. The arachnoid may be lifted up from the surface of the brain by a large collection of blood. Extensive haemorrhage may occur into the brain substance, but this is merely an extension of haemorrhage from the surface where the actual tearing of the vessels occurs. Examples of 'contre-coup' injury are shown in Fig. XXXVIII and XXXIX. The 'contre-coup' damage usually appears to be much greater than the damage at the site of injury, but this may be more apparent than real owing to its haemorrhagic nature.

MECHANISM/

MECHANISM of LOSS of CONSCIOUSNESS.

The sudden loss of consciousness at the time of injury is considered by TROTTER to be due to cerebral anaemia caused by a sudden flattening of the skull, what he terms "Acute compressive anaemia"⁽⁴²⁾. There are however, difficulties in accepting this explanation. In the first place the loss of consciousness is immediate, and recovery is relatively slow. There are other conditions in which loss of consciousness is due to cerebral anaemia. Such may occur when a debilitated person suddenly assumes the erect posture. Loss of consciousness in this case is preceded by a feeling of light-headedness which lasts for a second or two, and in contrast to what happens after concussion, recovery of consciousness occurs completely as soon as the position of the head relative to the heart is adjusted by a fall to the ground. Banking at corners in high-speed flying may produce the same effect, the blood being suddenly forced from the brain by its own momentum. In this case recovery of full consciousness occurs as soon as the sudden changing of direction is modified. A more prolonged period of cerebral anaemia occurs in a STOKES-ADAMS seizure. The loss of consciousness is so prolonged in this case that a convulsion often occurs/

occurs, yet here again consciousness often returns as soon as the circulation is re-established. Further, the theory of an acute compressive anaemia does not explain why one patient should be unconscious for five minutes and another for a period of thirty minutes. In the latter case, though the blow has presumably been more severe, the duration of compression of the brain, should it have occurred, cannot have been of longer duration. Again, if loss of consciousness were due to cerebral anaemia, one would expect that in the very mild cases at least, recovery of function would be rapid. We find on the contrary that recovery of full function of the brain even in the slightest injuries is always a relatively slow process. Even in the mildest cases of concussion, those in which the individual does not lose the power of either walking or speaking, he remains in a dazed state for several seconds, during which time he gradually recovers his full mental powers.

The following case is of particular interest in this connection. This case is not included in the series of two hundred.

W.R./

W.R., a male aged 34, had an accident while working in a mine on 9/10/31. His head was crushed with considerable force between two hutches. This, however, did not cause him to lose consciousness immediately. He remembers all details of the accident. He remembers sitting down after it occurred, while another worker bandaged his head. He remembers going up the pit shaft and entering the ambulance. Soon after entering the ambulance, however, he lost consciousness and did not regain his senses until in the Infirmary. When admitted, he had severe throbbing pain in his head. There was no visible fracture on X-Ray examination, and he was discharged a week later.

Soon after returning home he began to have 'fainting turns' in which he would lose consciousness for a few seconds. No history of convulsions was obtained, but coincident with the onset of these turns pain in the head became severe and continued until he was admitted to Ward 32 under Professor Bramwell's charge on 8/1/32. His complaint then was of severe and continual throbbing frontal pain and 'fainting turns'. He responded well to treatment with rest in bed and dehydration measures, and felt fit when discharged four weeks later.

In this case the intra-cranial structures were sufficiently compressed and damaged to produce severe after effects, yet no initial loss of consciousness occurred.

It would appear that the effect on the brain is not unlike the response of a peripheral nerve to an injury. Obstruction of all circulation to a nerve, as can be obtained by applying a sphygmomanometer/

sphygmomanometer armlet to the limb, fails to interrupt its functioning capacity except after many minutes. A sudden jar to the nerve trunk, however, causes an immediate interference with function, the severity and duration of which are directly proportional to the severity of the injury. Recovery of function is here, as in concussion, a relatively slow process. For these reasons it seems probable that the ancient conception of a commotion occurring in the nerve elements is the correct explanation of the sudden loss of consciousness. According to this view, the concussion of the nerve elements causes some molecular change which brings about a temporary interruption of function. That the myelin sheaths, at least, are easily disturbed by a sudden jar is demonstrated by the ease with which slight carelessness in removing a spinal cord at autopsy will alter the myelin sheaths sufficiently to enable them to be stained by MARCHI'S method.

As has already been shown, the force of a blow received by the skull is distributed to all parts of the brain. After a severe blow to the skull, therefore, all parts of the brain must suffer to a greater or less degree. It is therefore not surprising that the site of the injury is of little significance in most cases. From whatever angle the skull is jolted or struck, the whole of the brain receives/

receives a certain degree of jarring, its whole mechanism is put out of action and consequently consciousness is immediately lost. Consciousness cannot exist unless the association paths within the cerebrum are acting normally, hence any temporary interruption of conduction in the intra-cerebral fibres will cause immediate loss of consciousness.

My conception of the mechanism of concussion is, therefore, that at the moment of injury the whole of the brain tissue undergoes mechanical agitation. This causes molecular disturbance within the nerve elements (probably in the myelin sheath) which brings about an interruption in the conducting functions of the nerve cell processes, and leads to the instantaneous loss of consciousness.

TYPES OF INJURY.

It is interesting to consider the different types of head injury from the point of view of the degree of jar - or agitation, which they cause to the brain.

The degree of injury to the skull and brain must depend on:-

- (1) The rapidity with which the momentum of the brain and skull is altered.
- (2) The degree of change of momentum.

The/

The momentum of a body depends on its mass and its velocity. The mass of the skull and brain is approximately constant, therefore the degree of injury must depend on:-

- (1) The rapidity with which the velocity is altered.
- (2) The amount of change of velocity.

If, for example, the patient falls from a height on to a stone surface, both the above factors contribute towards the occurrence of a serious degree of brain damage.

- (1) The velocity of the skull is arrested with great suddenness at the moment of compact with the hard stone.
- (2) The velocity of the skull which is high at the moment of impact is completely abolished and may actually become negative if the skull rebounds. Hence the degree of change of velocity is great.

If instead of a fall on a stone surface, the patient falls on soft grass, the amount of change of velocity is the same, but the suddenness of change of velocity is much less owing to the softer surface. Hence the injury to the skull and brain is less severe.

Many cases have been described, in the literature of the subject, in which a pointed metal instrument/

instrument has transfixed the skull and brain without consciousness being lost. This occurrence can be readily explained by the above conception. The point of the instrument being relatively sharp, a large part of its velocity is expended not in imparting velocity to the skull, but in penetrating its substance, and correspondingly the rapidity with which the skull is made to assume velocity is not inconsiderably lessened by this same factor. Any effort, so to speak, on the part of the instrument to impart a sudden velocity to the skull is prevented by the same effort causing further penetration of the skull by the metal instrument.

In the case of a moving object striking the head while at rest, the rapidity of the change of velocity of the skull and the degree of its change of velocity, depend on the momentum of the force which strikes it. As has already been mentioned, momentum depends on the two factors - the velocity of the object and the mass of the object. It, therefore, follows that a rapidly moving object and a heavy object and especially one which possesses both these properties will cause most damage to the brain.

This is well illustrated by the effect of striking the head with a policeman's baton. The baton/

baton. The baton is hung from the wrist by a leather strap and the officer is taught that he can use his baton freely with little fear of doing serious injury provided he lets it swing from the strap round his wrist and does not attempt to grip it firmly. Severe head injuries, however, may be caused if the weapon is firmly grasped. The explanation is, of course, that though by gripping the weapon firmly the wielder of the baton probably lessens the speed at which it swings, he greatly increases its momentum, because by grasping it he adds the weight of his arm to that of the baton.

Similarly the power of a boxer's punch depends not only on the velocity at which he delivers it, but also on the amount of his weight he succeeds in adding to the weight of his arm.

CHANGES DURING RECOVERY.

When consciousness is beginning to return and motor recovery has occurred, a stage of great restlessness and resistiveness is likely to supervene. This stage is often called the stage of cerebral irritation and is considered to be due to cerebral oedema, with a consequent increase of intra-cranial pressure. As has already been shown, however, the mental/

mental state is not in any way proportional to the pressure as estimated by the manometer. Indeed, as already mentioned, seven stuporose cases which subsequently recovered showed a pressure within the limits of the normal. While the individual is very irritable in the popular sense of the word, there is no evidence that the condition is due to any mechanical irritation of the nervous elements. Other pathological conditions which cause cerebral oedema, such as cerebral tumour and uraemia, do not produce a clinical picture in any way resembling this traumatic state.

The condition is seen in all degrees of concussion. The concussed football player often moves his limbs restlessly, and talks meaninglessly, and not a few cases of head injury are violent and abusive when seen in the out-patient department. Though in slight injuries the duration of this stage is brief when compared to what may be seen in severe cases, it seems to me that the condition has the same significance in both types of case. In this stage of irritability, consciousness is not fully recovered and the patients have no subsequent recollection of their actions. It seems probable that these irritable states merely represent a stage in the recovery of/

of consciousness. The mental and other higher cerebral functions have not yet recovered and, owing to the lack of their control, the more primitive and less vulnerable motor activity is running wild.

Oedema and other circulatory disturbances are frequent complications of cerebral trauma, and their far-reaching effects must not be lost sight of. It seems improbable, however, that they are the cause of the sudden loss of consciousness or that they provide the explanation of the condition called cerebral irritation.

RE-EXAMINATION/

RE-EXAMINATION OF CASES
SOME MONTHS AFTER DISCHARGE FROM HOSPITAL

The follow-up investigation is a very important part of this work, because it touches on the urgent question of prognosis and ultimate rate of recovery.

As is well known, certain symptoms are liable to develop after head injuries. These have been described under such terms as post-concussional neurosis and post-concussional syndrome. The symptoms which are recognised to be the features of this state include headache, dizziness, nervousness, sleeplessness, inability to concentrate, disturbances of memory and behaviour.

These symptoms are often regarded as being due to neurasthenia or functional disturbances. In recent years, however, various workers have demonstrated that the symptoms in some of these cases have an organic basis. TROTTER⁽⁴³⁾ has shown that what he terms "unresolved contusion" of the brain is sometimes present, and concludes that this is the pathological basis for most post-concussional disturbances. Further, the chronic scar formations which develop in the brain substance after injury have/

have been studied experimentally by PENFIELD⁽³³⁾ and
have been demonstrated by encephalography⁽⁵⁾ .

In individual cases the problem constantly arises as to whether the symptoms complained of have really an organic basis or should be regarded as purely functional. The patient's psychology undoubtedly colours the clinical picture in many cases, especially if any compensation question is outstanding, and the difficulty of estimating the degree of organic and functional disturbance respectively, is sometimes very considerable.

In order to attempt to elucidate some of the problems associated with this aspect of the subject, a series of cases have been re-examined at an average interval of six months after discharge from hospital.

METHOD OF INVESTIGATION.

Of the 184 cases which survived the injury they had received, each person was written to at an average interval of six months after discharge, and was asked to report at Hospital. Forty-three of the patients failed to report, but the remaining 141 were interviewed and examined by myself. FIG. XL.

Fig.XL/

FIG. XL.

	GROUP.			TOTALS.
	A	B	C	
Reported for re-examination.	61	45	35	141
Failed to report.	19	12	12	43
TOTALS	80	57	47	184

77 per cent, therefore, of the cases were re-examined. A proportion of those who failed to report lived far from Edinburgh, others could not be traced, and it was considered unwise to press the remaining defaulters to report, as the accuracy of the statements they would make might be influenced had any undue pressure been brought to bear on them. The patient's full co-operation is a very vital part of this investigation as the abnormalities found are mainly subjective in type.

The principal points of investigation are enumerated in the questionnaire.

According to this scheme, various of the questions necessitated cross-examination of the patient/

patient with regard to individual symptoms, and in this connection the utmost care had to be exercised. Leading questions with regard to symptoms such as fits, memory-loss, and headache, might, if carelessly applied, have led not only to inaccurate answers, but might have further impaired the mental state of neurasthenic patients. This factor may lead to doubt as to the accuracy of some of these records. I have, however, been very conscious of this danger throughout the whole of the investigation, and am myself satisfied that it has been avoided.

The method of approach in the examination of these cases has been based merely on what I have found from previous experience of organic and functional nervous disturbance to be the most reliable. The patient's confidence must be fully obtained and his mental attitude towards his being asked to report must be estimated, and if necessary adjusted. He must not feel for example that the examiner expects to find that he is not yet fit. His words and expression when he replies to the simple question - "How have you been since your accident?" - will often indicate his mental attitude to the subject, and may, for example, make the examiner particularly cautious with regard to the interpretation of his story. The disadvantages/

disadvantages of leading questions can be lessened by asking them without emphasis, as though they were of little significance. Again, in the case of the patient whose attitude suggests that he has been meditating over his symptoms unduly, it is often wise to word the question as though a negative answer was expected - "Your memory is as good as ever, isn't it?" or "You've been quite free of faint turns since you left hospital, haven't you"?

Further it must be remembered that the patient's general mental structure and particularly his attitude to any symptoms present, may profoundly modify his description of his complaints. The degree of importance attached to any statement must therefore vary with each individual and the correct evaluation of his complaints as regards their degree and accuracy must always be largely dependent on the examiner's clinical judgment and insight.

Where symptoms such as memory loss, inability to concentrate, headache, dizziness, faint turns, and nervousness, are complained of, then the patient must be asked to describe in detail exactly what his sensations are, and concrete example of incidents which brought to light these defects should be asked for. With regard to the symptoms of/

of headache, for example, he may be asked at what hour of the day it is most noticeable and what its exact nature is. Does stooping to the ground make any difference to it and does excitement modify it? Is it improving? Is it present every day or does it come on in attacks? and so on. Where there is any doubt as to the accuracy of one of his statements, he should be asked to describe an actual incident he remembers which illustrates his statement. By means such as these the accuracy of his evidence can often be confirmed or otherwise.

The presence of any compensation question requires full but sympathetic enquiry. The case of compensation neurosis can usually be easily recognised, the exaggeration of symptoms present and the unwillingness to admit the absence of any symptom mentioned are often very characteristic of this condition.

Though the above are no more than general and elementary principles in Clinical Medicine, applying to all clinical work, the records in this particular investigation are so dependent for their accuracy on the personal factor that it seemed desirable to show, at least, that the dangers of error have not been overlooked.

As/

As was the rule in investigating the acute stage, so in the re-examination of the patients every symptom and abnormal sign was recorded, including those which appeared trivial and without importance. the cases were again divided into the Groups A, B, and C according to the duration of loss of consciousness after the injury.

ANALYSIS of the CLINICAL RECORDS.

As has already been mentioned 141 cases, 77 per cent of the total, reported for re-examination. Of these, 55 had noticed no abnormal symptoms since discharge, while in the remaining 86 symptoms had been present since discharge which were presumably due to the injury. The proportion in the different groups is shown in the following table.

FIG. XLI.

	A	B	C	TOTALS
Symptoms since discharge.	30	31	25	86
No symptoms	31	14	10	55
TOTAL REPORTING	61	45	35	141

FIG. XLII/

FIG. XLII.

AGE INCIDENCE

AGE PERIOD	SYMPTOMS SINCE DISCHARGE.	NO SYMPTOMS.
0 - 10	10	9
10 - 20	16	14
20 - 30	26	20
30 - 40	10	6
40 - 50	11	4
50 - 60	5	1
60 - 70	6	1
over 70	2	0
TOTALS	86	55

Many of the patients had noticed symptoms that were only slight and caused little or no inconvenience. These cases are separated from those that were severe in Fig. XLIII.

FIG. XLIII/

FIG. XLIII

AGE PERIOD	GROUP						TOTALS	
	A		B		C			
	SEVERITY OF SYMPTOMS							
	++	+	++	+	++	+	++	+
0 - 10	1	3	1	1	2	2	4	6
11 - 20	0	7	1	4	2	2	3	13
20 - 30	2	4	1	9	3	7	7	19
30 - 40	1	0	1	4	4	0	6	4
40 - 50	2	3	4	1	1	0	7	4
50 - 60	3	1	0	1	0	0	3	2
60 - 70	2	0	1	2	1	0	4	2
Over 70	1	0			1	0	2	0
	12	18	9	22	14	11	36	50

++ = Severe symptoms. + = Slight Symptoms

The above three charts show several features of interest.

In the first place, though the proportion of cases which show symptoms is considerably higher in Group B and C than in Group A, yet nearly 50 per cent of cases in Group A suffered from symptoms of some degree. Not only so, but no fewer than twelve of the thirty cases which showed some post-concussional symptoms in this group are classified as severe. (Fig. XLIII) This is remarkable when it is remembered/

remembered that the cases in Group A were unconscious for less than an hour, and indeed often only for a few minutes.

Fig XLII makes it apparent that in attempting to estimate the likelihood of post-concussional disturbances developing, the age of the patient has to be regarded as a very important factor, much more so than the duration of loss of consciousness. The proportion of cases showing post-concussional disturbances increases steadily as age advances, until after the age of forty there are nearly five cases with symptoms to every one without. Fig. XLIII shows however, that with regard to the severity of the after symptoms, the duration of loss of consciousness is also a factor to be considered. It is apparent from this table that few of the cases in Groups A and B which are below forty years of age suffered from severe symptoms, while in Group C there are no affected cases above the age of thirty years who escape with slight disturbances. Indeed throughout all the age periods in this group the proportion of cases showing severe disturbance is high. Fig. XLIII also shows that in a large proportion of the total cases, the symptoms were not severe. Thus in fifty of the cases they were only slight/

slight while in thirty-six they must be classified as severe.

COMPENSATION CASES.

With regard to the study of individual symptoms it is advisable to exclude those in which there was any question of compensation outstanding. There were fourteen such cases. The age periods in which they lie is shown in the following table.

FIG. XLIV

AGE PERIOD.	COMPENSATION QUESTION OUT- STANDING.	NO COMPENSATION QUESTION.
0 - 10	1	9
10 - 20	3	13
20 - 30	1	25
30 - 40	0	10
40 - 50	5	6
50 - 60	2	3
60 - 70	2	4
over 70	0	2
TOTALS	14	72

Fig. XLIV shows that the cases in which the question of compensation gives rise to difficulty are more likely to be among those of patients above forty years of age. It is of interest further to/

to note that of the cases in Group C there were none in which any question of compensation was outstanding. In Group B, there were four and in Group A there were ten cases in which this question was still undecided. These cases will be considered in greater detail later.

The small number of unsettled compensation cases is a remarkable feature of the series. As was seen in Fig. II, over 60 percent. of the cases in the series were caused by street accidents. In only a small number of these had compensation been recovered. The larger number had no prospect of obtaining compensation for one reason or another. In certain cases the patient was himself to blame. In other cases the retrograde amnesia prevented the patient (often much to his annoyance) from remembering how the accident occurred, while the period of unconsciousness had prevented him from being able to call on witnesses. The other party concerned in the accident, if responsible, naturally does not appeal for witnesses, and thus it was only when the victim was at fault that witnesses were likely to be produced.

One/

One man (Case No. 182) was fined for dangerous driving after he had recovered from a severe injury. He was unable to make any statement in his own defence as he had no recollection of the events shortly preceding the accident.

ANALYSIS/

ANALYSIS OF COMMON POST-CONCUSSIONAL SYMPTOMS.

The group of cases in which symptoms referable to the injury were present, but in which no complicating compensation factor was present, provides a most valuable and rare opportunity for studying post-concussional symptoms. This group consists of seventy-two cases (Fig. XLIV) and these are used exclusively in the following analyses.

HEADACHE.

Some degree of headache had been present in 41 cases. This had been slight in 28, and severe in 13 cases. (Fig. XLV).

FIG. XLV.

DEGREE of HEADACHE.	GROUP			TOTALS.
	A	B	C	
Severe	1	7	5	13
Slight	11	12	5	28
None	8	8	15	31
TOTALS	20	27	25	72

Fig. XLVI/

FIG. XLVI.

AGE PERIOD	GROUP						TOTALS	
	A		B		C			
	HEADACHE							
	+	-	+	-	+	-	+	-
5 - 10	2	2	1	0	1	3	4	5
10 - 20	4	0	4	1	3	2	11	3
20 - 30	4	1	8	2	5	5	17	8
30 - 40	0	1	2	3	1	2	3	6
40 - 50	1	1	2	1	0	1	3	3
50 - 60	1	1	1	0	0	0	2	1
60 - 70	0	1	1	1	0	1	1	3
over 70	0	1	0	0	0	1	0	2
TOTALS	12	8	19	8	10	15	41	31

The + and - signs indicate respectively whether headache was or was not present. The figures refer only to cases in which post-concussional symptoms were present, but in which no question of compensation was outstanding.

The age incidence of the symptoms is shown in FIG. XLVI.

These tables show in the first place that the incidence of headache is higher in Group A and B than in Group C, and in the second place that the/

the frequency of this symptom is rather higher in the early age periods than in the later. Thus, 59 per cent. of the cases below the age of forty years complained of this symptom, while the figure for the cases above the age of forty is 40 per cent.

The figures will be compared later to those obtained in the case of other symptoms.

If pain in the scar of a scalp injury be excluded, the type of headache was remarkably constant. It was a dull pain referred to the frontal and temporal regions, often throbbing in nature. It was usually worst when the head was lowered, as when the patient went to bed at night, but in many cases was worst on waking in the morning. It was usually greatly aggravated by great physical exertion or by excitement. In some cases it could be brought on by shaking the head and in not a few it was more noticeable in dull wet weather. A gradual reduction of the degree of pain was the rule, but in some cases the headaches continued with considerable severity and were seriously incapacitating.

In two cases who had previously suffered from migraine, the accident resulted in a cessation of the attacks of headache.

The/

The following are typical examples of cases showing this symptom.

CASE NO. 142. J.B. A male aged 19 collided with a motor lorry while riding a motor cycle. He suffered a fracture of the right parieto-temporal region and was unconscious for five days. Four months after discharge he had not returned to work because of the severe pains in the head from which he was suffering. These were frontal and throbbing, worst on rising in the morning and sometimes continued throughout the day. They were however, becoming less severe. When he is free of the headache he feels quite fit. He has also been rather nervous since the accident and very irritable. There was no question of compensation.

CASE NO. 158 T.K. A male aged 25 was involved in a collision while riding his motor cycle. Extensive fractures of both frontal bones occurred and he was unconscious for 4 days. He lay in bed for five weeks and began work two months later. He was examined $8\frac{1}{2}$ months after the injury and was then still suffering from pains in the head. These were especially noticeable when the weather changed. The pain was throbbing or bursting in character. It was worst on waking in the morning and was aggravated by stooping. It was also aggravated by excitement and was almost unbearable when he attended a football match. Otherwise he felt well and was able to do his work. There was no possibility of any compensation being obtained.

CASE NO. 180. O.T. A male aged 33 was thrown from his motor-bicycle while attempting to avoid a dog. A large fissure fracture/

fracture of the left temporal region was apparent on X-Ray examination and the patient did not recover consciousness for thirteen days. He lay in bed for three weeks and returned to work four weeks later. When examined six months after his accident, he complained of inability to remember about people he knew quite well, and of some difficulty in concentrating. He was not nervous and had been told that he drove his motor-bicycle more recklessly than before his accident. He had had practically no headache, whereas before his accident he had suffered from typical migrainous headaches since 1921. These headaches used to be preceded by a visual aura and occurred at least once a week. On the day before examination he had one of these headaches, the first since his accident six months before.

CASE NO. 85. F.B. A male aged 63 was thrown to the ground by a struggling horse and struck his head on the pavement. He was unconscious for one or two hours. There was bruising over the left parietal and occipital region but no fracture was apparent on X-Ray examination. When examined seven months after his injury, he was suffering from a marked degree of loss of memory. He also complained of headaches of great severity which showed no sign of improving. If he stooped to the ground the pain became so bad that he often just lay down on the floor. A spasm of pain occurred during the examination. While it lasted he remained motionless looking vacantly ahead for a few seconds, and then when it passed off, had lost the thread of what he was saying. There was no question of his getting compensation.

Three/

Three of the above patients had headache of no little severity, and many examples in which the headache was of the same type but of less severity could be cited. It is noteworthy that no fewer than fifteen of the patients in Group C, although showing certain other symptoms referable to their head injury, had remained quite free of headache since discharge. Some of these were cases of severe injury with extensive fractures of the skull. No connection between the occurrence of headache and any other factor in the case could be demonstrated. Headaches were usually a continuation of the same symptom noted in the acute stage, but no reason could be ascertained for the headache in one case lasting for only a few days while in another it would last for many months. There is no doubt a wide range of variation in individuals with regard to their susceptibility to pains in the head, and this is probably a factor to be considered. The most striking feature of these cases as has already been mentioned, is the **uniformity of the** type of headache.

DIZZINESS.

Dizziness is often a prominent complaint after/

after head injury, but its features require careful analysis. The following case records illustrate the type of disturbance included under this term in the present series.

CASE NO. J.A. A male aged 38 fell down stairs and struck his head on the ground. He did not lose consciousness but developed severe headaches which continued until admission to hospital a week later. Lumbar puncture relieved his headache immediately and he insisted on leaving the ward thereafter. X-Ray examination demonstrated a fracture in the left parietal region. When examined six and a half months later, there was some loss of memory and the patient had had a few fits. There had been no headache since the lumbar puncture, but the patient complained that if he suddenly rose to his feet or if he looked upwards "his head began to swim".

CASE NO. 21. S.D. A male aged 46 was knocked off his bicycle by a motor car. He was dazed for a few moments only. There was a fracture of the right parieto-occipital region. When examined $3\frac{1}{2}$ months later, he was still suffering from headache and dizzy turns. These latter would come on suddenly while he was walking and he would have to stop and hold on to something or sit down till they passed off.

CASE NO. 180 O.T. A male aged 33. He was unconscious for thirteen days after his injury. Six months later he noticed slight memory loss and occasional dizziness. If while lying on his back he turned his head to the left or to the right, he complained of his head swimming. The sensation only lasted for a moment and then passed off.

In/

In none of these three cases was there any question of compensation outstanding.

This symptom of dizziness was usually a sensation as though the head were "swimming". The patient rarely fell to the ground, but felt that he must steady himself or sit down until it passed off. True vertigo was not found to be present in any of the cases examined. Changes in posture, or movements of the head and eyes were common causes of an attack. The common association of suddenly standing up with the onset of an attack suggests that cerebral anaemia may be a causative factor in some cases, while connection between movements of the head and eyes and the dizziness is suggestive of some disturbance of the labyrinthine mechanism. One patient, for example, who worked in a library, was unable to look up at the upper shelves of books, as this movement of the eyes would cause her to feel so giddy that she felt she might fall. That labyrinthine damage is a not uncommon result of head injury has recently been shown by LINTHICUM and RAND⁽²³⁾. From their work, they conclude that the disturbances they have observed suggest that there is often disturbance/

disturbance both centrally, and in the labyrinthine end-organs.

In the present series, dizziness was noticed in thirty-one cases, as is shown in Fig. XLVII. The age incidence is shown in Fig. XLVIII.

FIG. XLVII.

DIZZINESS	GROUPS			TOTALS
	A	B	C	
Present	11	10	10	31
Absent	29	17	15	41
TOTALS	20	27	25	72

Fig. XLVIII/

FIG. XLVIII.

AGE PERIOD	GROUP						TOTALS	
	A		B		C			
	DIZZINESS.							
	+	-	+	-	+	-	+	-
0-10	0	4	0	1	0	4	0	9
10-20	2	2	2	3	2	3	6	8
20-30	3	2	4	6	3	7	10	15
30-40	1	0	0	5	3	0	4	5
40-50	2	0	1	2	1	0	4	2
50-60	2	0	1	0	0	0	3	0
60-70	0	1	2	0	0	1	2	2
Over 70	1	0	0	0	1	0	2	0
TOTALS	11	9	10	17	10	15	31	41

The + and - signs indicate respectively whether dizziness was or was not complained of.

These figures include only cases in which concussional symptoms were present, but in which no question of compensation was outstanding.

These tables show that there is no great difference in the incidence of this symptom in the different groups. In contrast, however, to the symptom of headache, the increasing incidence as age advances is a striking feature. This symptom of dizziness, though of common occurrence, was/

was usually only slight, and rarely caused by itself any serious incapacity.

LOSS of MEMORY and MENTAL ABILITY.

Disturbances of memory and mental ability were often found. With a few exceptions, these were slight in degree and caused the patient little inconvenience. The disturbances were however, none the less real, and in a few cases the degree of memory loss was great and very incapacitating. The milder degrees, were represented by the presence of some difficulty in remembering the names of people and sometimes of streets which had been formerly well-known to the patient. This condition simulates closely the deterioration of memory so often found in old age. In the more severe degrees of disturbance the changes are much more serious. A child who was previously good at school becomes backward, and in adults, difficulty in remembering names may be associated with difficulty in remembering words, so that the patient may complain that he is no longer able to tell a story, or that he makes foolish mistakes in writing a letter. Loss of mental ability to a slight degree was well shown in/

in the case of a shop-assistant who found after his accident that he had difficulty in handling a troublesome customer.

The more severe degrees of memory loss may even amount to a degree of aphasia. This is not surprising when it is remembered that the functions of memory, thought and speech are so intimately dependant on each other, that no one of these can be seriously injured without the other two being affected. The loss of memory and mental ability was in some instances so great as to amount to dementia. The following cases illustrate the degrees of memory loss.

CASE NO. 180. O.T. Recovered to a remarkable degree from a very severe injury. When examined, however, six months after the accident, he said that he could not concentrate as well as previously and that he had difficulty in placing people he knows. He could not remember whether he knew them or not, but if he succeeded in "placing" them in his own mind then he remembered their names and all about them.

CASE NO. 171. C.R. A male aged 32 had a collision while riding his motor bicycle and was unconscious for seven days. There was a fracture of the skull in the right parieto-occipital region. When examined four and a half months later the patient was found to be experiencing great difficulty in supervising the fish restaurant which he and/

and his wife managed.

He was unable to recognise people whom he knew well. He would ask his wife the same question repeatedly, having forgotten that she had already answered. His wife was obliged to handle all the money as he could not remember who had paid. He would frequently repeat himself.

He had to avoid stooping, as this made his head "swim", and if he looked up or down, things seemed to "swim away". He was still suffering from severe headaches. He had completely lost his sense of smell which was formerly very acute, and he was slightly deaf in the right ear. The patient was taking his case to court, but only to attempt to prove who was responsible for the accident. As therefore, the degree of incapacity was not the point at issue there was no reason to suppose that the impending case had any influence on his health.

The main injury to the brain in this case was probably contre-coup, involving the left frontal region in particular.

The frequency with which loss of memory and mental ability was present in the present series of seventy-two cases is shown in FIG. XLIX.

FIG. XLIX.

MEMORY LOSS	GROUPS			TOTALS
	A	B	C	
Severe	0	0	4	4
Slight	8	4	10	22
None	12	23	11	46
TOTALS	20	27	25	72

Loss of memory must in these cases be due to definite damage to the nervous tissues, and it is therefore not surprising to find that in Group C the proportion of cases showing this defect is much higher than in Groups A and B.

The effect of age on the incidence of memory loss is shown in Fig.L.

FIG. L./

FIG. L.

AGE PERIOD	GROUP						TOTALS	
	A		B		C			
	MEMORY LOSS							
	+	-	+	-	+	-	+	-
0 - 10	1	3	0	1	1	3	2	7
10 - 20	1	3	1	4	4	1	6	8
20 - 30	1	4	1	9	5	5	7	18
30 - 40	1	0	0	5	2	1	3	6
40 - 50	1	1	1	2	0	1	2	4
50 - 60	2	0	0	1	0	0	2	1
60 - 70	1	0	1	1	1	0	3	1
over 70	0	1	0	0	1	0	1	1
TOTALS	8	12	4	23	14	11	26	46

The + and - signs indicate respectively that there was, or was not a degree of memory loss.

Fig. L. shows that as in the case of dizziness, the incidence of memory loss is higher in the later age periods. Thus it is seen that over fifty per cent of the cases above forty years of age show some loss of memory, while in the cases below this age the percentage is thirty-two. This difference is more evident if the cases in Group C (most of which show memory loss) are omitted. Analysis of the figures for Groups A and B taken together show that/

that in this class of case, fifty per cent of the cases above forty years of age show some memory loss, while in the cases below this age the percentage is seventeen.

NERVOUSNESS.

Nervousness is not uncommonly present after a head injury. It was recorded as being a sequela of the injury in twenty-five cases of the group of seventy-two in which there was no question of compensation outstanding. The following tables show the incidence of nervousness in the different groups and at the different age periods.

FIG. LI.

NERVOUSNESS	GROUP			TOTALS
	A	B	C	
Present	7	7	11	25
Absent	13	20	14	47
TOTALS	20	27	25	72

FIG. LII.

AGE PERIOD	NERVOUSNESS	
	PRESENT	ABSENT
0-10	7	2
10-20	3	9
20-30	8	18
30-40	3	7
40-50	1	5
50-60	1	2
60-70	1	3
Over 70	1	1
TOTALS	25	47

A noteworthy feature of Fig. LII is that the increasing incidence in the later age periods which was such a striking feature of the symptoms of dizziness and memory loss, is here not evident. In fact the incidence of nervousness is greater in the earlier age periods. It is a very common sequela in the case of young children. In 35 per cent of the cases below forty years of age, the symptom was noted, while in the case of these above forty, the percentage was only twenty-six.

It is interesting to speculate on the possible causes of the development of nervousness after/

after head injury. The brain of a person who is nervous, is in a condition of increased activity. The muscles are hypertonic, the reflexes are brisk and the response to stimulation from without, such as a sudden sound, causes an in excessive response. The brain of such a person is abnormally alert.

It is apparent that the symptom cannot be due to any recollection of the accident or to any feeling of fear before the accident occurred; indeed the incidents immediately preceding the injury are often not remembered. Abnormal nervousness usually has a purely psychological cause, and there is no doubt that thinking over a severe accident, especially if foolish relatives enlarge on it, is probably sufficient to account for the mental state which is so often found. It must however, be admitted that the psychological mechanisms which control behaviour are dependent for their smooth working on the intactness of cerebral connections of great complexity; and as these highest association mechanisms are certainly the most vulnerable, it is difficult to exclude the possibility of a symptom such as nervousness having an organic basis.

It is particularly interesting to note that, in young children, a complete change of character is/

is not uncommon after an injury. This may be compared to the behaviour disturbances which sometimes develop in children after an attack of epidemic encephalitis. The inhibitory mechanisms which control behaviour are much more firmly established in the adult, but in the child they are still delicate connections which are easily disturbed. Changes of personality, character and behaviour are occasionally found in adults after severe head injuries, but they are much more frequently found in children. If these changes were due entirely to functional causes, they should be encountered more often in children who have received injuries to parts other than the brain and skull. It is difficult to prove that these minor disturbances have an organic basis, but it is unjustifiable to assume that their cause is functional.

The following cases illustrate this type of disturbance.

CASE NO. 45. C.J. A female, aged seven, tripped and fell forward on to her head. She was unconscious for about an hour and there was an extensive fracture of the skull. When examined two months after discharge, her mother said "She doesn't seem to be the same child to me. She's full of mischief" She seems to have the devil in her". (patient smiles). Before her injury she was very quiet and good. Now she is disobedient, defiant and daring. She gets very excited and treats younger children badly. She plays all/

all day, but stops to sit down sometimes because of headache. She has become much more nervous, being afraid especially, of falling, and of the dark.

CASE NO. 56. M.M. A female, aged 9, fell downstairs, but was only stunned for a few seconds. When examined six and a half months later her mother said she was quite changed. She used to be very good at school, but is now very backward and has no interest in it. She is very absent minded and often forgets what to buy when she is sent a message. She gets so excited sometimes that she "foams at the mouth" while trying to say something, and bursts into tears if she doesn't get what she wants.

SLEEP DISTURBANCES.

Difficulty in falling asleep may be a troublesome symptom of the acute stage, and continues in some cases to be troublesome for a long period. In nine cases some difficulty of this nature was noticed, but in most of these the difficulty in falling asleep lasted for a period of only a few weeks after the injury.

EPILEPTIC FITS.

Epilepsy may develop months or even years after a head injury, and for this reason the present investigation is of little value as far as the frequency of the complication is concerned.

As/

As has already been shown, a convulsion may occur in the early hours after the injury, or may occur several days later. The first convulsion however, often occurs at an interval of weeks or months after the injury.

These fits may be major or minor in type, and in the latter case it is often difficult to distinguish these from dizzy turns which are presumably not epileptic manifestations. A point which is of value for their differentiation is that in the case of a dizzy turn, the patient himself is very conscious of the unpleasant feeling of insecurity it gives, while in the case of a petit mal attack, the patient is less disturbed by it, and indeed is often unaware that anything untoward has occurred.

Fits were recorded as having occurred in eight cases, one of which was in Group A, four in Group B and three in Group C.

The following case provides an example of this..

CASE NO. 1 J.A. A male aged 38, injured the parietal region in falling downstairs and so caused a fracture of the skull. He did not lose consciousness, but suffered from severe headache till he was lumbar punctured ten days later. Three months later he was readmitted to hospital suffering with epileptic fits. When examined six months after the injury, no further fits had occurred, but some loss of memory and dizziness were still present.

PHYSICAL EXAMINATION

Physical examination usually elicited no abnormal signs. Anosmia and deafness were occasionally present, as were slight motor disturbances such as tremor or slight unsteadiness of movement. In one case (No.149) progressive deafness and unsteadiness had developed, due presumably to labyrinthine disturbances.

One patient (No.90) complained that she could no longer take wine as it "went to her head" at once. Another (No.111) noticed that since the injury his hands perspired excessively, while a third (No.68) had developed diabetes insipidus, which was due presumably to a lesion of the hypothalamus.

S U M M A R Y.

As was shown in Fig.XII, LXXXVI, that is 61 per cent. of the 141 cases which were examined at an average interval of six months after discharge, had been aware of symptoms after discharge from hospital which were referable to the injury they had received.

In fourteen of these 86 cases some question of compensation was outstanding, and these fourteen were excluded from the analysis of symptoms.

There remained, therefore, 72 cases in which post-concussional symptoms were present and in which the symptoms complained of were analysed. The relative frequency in these cases of the more commonly found symptoms is shown in Fig.LIII

FIG. LIII

SYMPTOMS	NUMBER OF CASES IN WHICH SYMPTOM WAS NOTED.	PERCENTAGE OF THE TOTAL OF 72 CASES
Headache	41	57
Dizziness	31	43
Loss of memory	26	36
Nervousness	25	34
Sleeplessness	9	13

57 of the 72 cases were below the age of 40 years, and 15 were above this age. The symptoms of/

of headache and nervousness were more often noted in the younger age periods, while those of dizziness and memory-loss were more often present in cases above the age of 40 years. This is shown in Fig.LIV.

FIG. LIV.

SYMPTOM.	AGE PERIOD.	
	0 - 40 years.	Over 40 years
	PERCENTAGE OF TOTAL (57) CASES	PERCENTAGE OF TOTAL (15) CASES.
Headache	59	41
Dizziness	35	83
Loss of Memory	32	50
Nervousness	35	26

DISCUSSION/

DISCUSSION OF POST-TRAUMATIC DISTURBANCES.

The principal symptoms which may be present after head injury are those which have just been mentioned, viz., headache, giddiness, loss of mental ability, disturbance of the sleep mechanism, and epilepsy.

All degrees of disturbance are met with, and the duration of the symptoms may be a few days only, or may cause incapacity for months or years. Whether the disturbances are slight or severe, the features of the individual symptoms are remarkably similar in each case.

Thus, headache is usually a dull frontal or bitemporal pain, often throbbing or bursting in nature, and aggravated by stooping, excitement or physical effort. It is often worst on waking in the morning and may be affected by changes in the weather.

The giddiness, or dizziness, is usually a sensation of "swimming" or light-headedness which gives a feeling of insecurity and unsteadiness. It may be brought on by changes of posture, such as/
as/

as suddenly standing up or stooping down. Movements of the head and eyes are also a common cause.

Loss of memory and mental ability and difficulty in concentration are found to occur in all degrees. The features of post-concussional epilepsy are the same as those of epilepsy from other causes.

CAUSE of DISTURBANCES.

There can be no doubt that actual loss of memory, such as may occur in these cases, has an organic basis. The same may be said of post-traumatic epilepsy. As has already been shown, all the nervous elements within the brain must be traumatised to some extent in severe head injuries. In cases where memory loss is present, it can be assumed that a number of the nerve cells or their processes have been so severely injured that their recovery is impossible. Multiple capillary haemorrhages may no doubt contribute to the damage to nervous tissue, but it is unjustifiable to assume, even when no haemorrhage or contusion is apparent, that the nerve fibres have escaped serious damage.

That/

That the degree of cerebral destruction in these cases may be extensive is apparent from encephalographic studies, such as those of FOERSTER (13,5) and BIELSCHOWSKY . By the method of encephalography which was introduced by DANDY (10), air injected into the subarachnoid space, passes over the surface of the brain and also fills the ventricles. The position of the air is then shown by X-Ray examination. Displacement of the lateral ventricle and accumulations of air over the cortex indicate that an area of damaged brain has been replaced by a **shrunken** scar.

As has already been mentioned, recent investigations with regard to the pathology of concussion indicate that the degree of organic damage to the brain has in the past been underestimated. MEYER in 1904 (27) demonstrated multiple areas of softening in cases of traumatic insanity, but other workers have shown pathological changes in comparatively mild degrees of concussion. Thus, CASSASA (7) in 1924, described cases in which there were multiple haemorrhages scattered throughout the brain, and the work of TROTTER (41), which showed that areas of "unresolved contusion" might be/

be present, has already been mentioned. MINKOWSKI⁽²³⁾ has studied the finer pathological changes especially with regard to damage to small blood vessels.

OSNATO and GILIBERTI⁽³²⁾ have compared the symptoms and pathology of post-concussional disturbances to those of encephalitis lethargica, and consider the similarity so close that they refer to post-concussional disturbances as being due to a traumatic encephalitis. MARTLAND and BELING⁽²⁶⁾ have shown that multiple haemorrhages are only present in a small proportion, 2.9 per cent. of fatal cases of head injury, and that the commonest gross pathology found is a contre-coup laceration which was present in 57 per cent of their series of 309 autopsies.

MARTLAND⁽²⁵⁾ has drawn attention to the condition which he calls "Punch Drunk", in which professional boxers develop symptoms which indicate degenerative changes in the brain. These symptoms are often slight, but are well known by the layman. They include slowness of movement, hesitancy of speech, tremors of the hands, dragging of one or both legs, staggering, Parkinsonianism, vertigo and deafness. Many cases ultimately develop marked mental deterioration, and end their days in mental hospitals. MARTLAND suggests that the changes are due to multiple capillary haemorrhages, such as have/

have been shown to occur in comparatively mild injuries by CASSASA ⁽⁷⁾ .

ROSENHAGEN ⁽³⁶⁾ in 1930 drew attention to fine cellular changes in cases of concussion.

A problem which arises in connection with work of this nature is the question whether the changes found have not really been due to some complicating factor, such as hyperthermia, just before death.

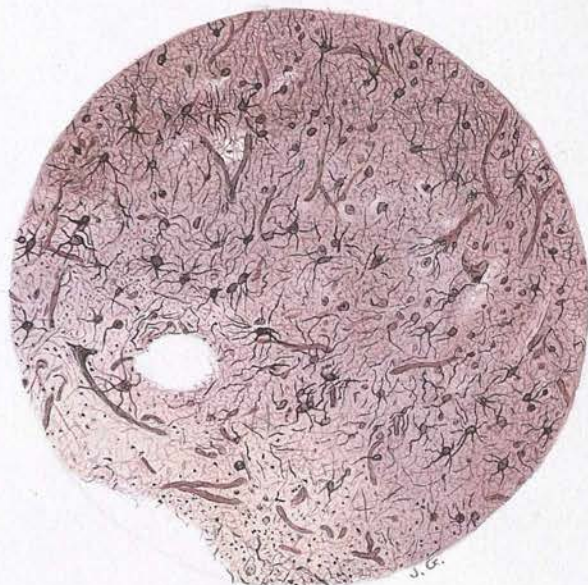
One of ROSENHAGEN'S cases, however, seems to be of importance, as death occurred suddenly eight weeks after the injury. In the interval, the patient, though suffering from headache, had been able to return to work after his accident. Eight weeks after the injury, he suddenly developed hemiplegia and died in eight hours from the effects of cerebral haemorrhage. ROSENHAGEN found extensive degenerative changes of a fatty nature in both the ganglion and neuroglial cells, which he concluded were due to the previous head injury.

PENFIELD ⁽³³⁾ has laid stress on the formation of scar tissue as a cause of traumatic epilepsy and has followed the stages of astrocytic scar formation in experimental work. LINELL ⁽²²⁾ has confirmed his observations.

It/

It is surprising to note that in spite of PENFIELD'S important work the investigation of the glial reaction has been largely neglected in human pathological material. Thus, ROSENHAGEN⁽³⁶⁾ states that glial reaction is slight and OSNATO and GILIBERTI⁽³²⁾ found no neuroglial reaction. It is fully realised, however, that extensive gliosis must occur in areas in which the brain tissue is totally or partially destroyed. The failure of other workers to demonstrate these changes in fatal cases of head injury must be due to their not having suitable material for this study. PENFIELD⁽³³⁾ and LINELL⁽²²⁾ have shown that the glial activity begins to appear three days after the injury, reaches its maximum in three weeks. Thereafter the fibres having been formed, the cells retrogress, so that at an interval of six weeks after the injury there are few cell bodies to be seen. It is thus apparent that death must occur several days after the accident for these changes to be demonstrable in the human brain. It is uncommon for death to occur at this stage after head injury except in the case of meningitis supervening.

FIG. LV.



0 100 200 μ
| | | |

The illustration shows reaction around a small haemorrhage which occurred in the sub-cortical white matter of the cerebral hemisphere at the time of injury, three weeks before death.

Numerous new capillaries are present and the astrocytes are large and very numerous. The latter are of the 'fibrous' type and are in an active stage of reproduction. (The blood clot was situated below and to the left of the field shown).

Frozen section impregnated by Cajal's gold chloride sublimate method.

I have had the good fortune to obtain the brains of three cases which have died at an interval of two to three weeks after the injury. In two of these death was associated with evidence of meningitis, but in the third there was no meningeal infection. In all three the astrocytic reaction was very striking. The fibrous and protoplasmic astrocytes were equally affected, and their activity was apparent over an area which extended far beyond the area of gross cerebral contusion. As is shown in Fig. LV. the reaction was clearly shown around a small intra-cerebral haemorrhage. As ⁽³³⁾PENFIELD and ⁽²²⁾LINELL have shown, the presence of necrotic brain tissue is a most important stimulus to the proliferation of the glia, and the widespread astrocytic reaction in the case which is illustrated in Fig. LV. provides evidence that the destruction of nervous tissue is more extensive than is apparent at first sight, and that nervous tissue has been damaged in regions where the brain on ordinary microscopical examination appears to be normal. The demonstration of the glial activity in a case such as is illustrated in Fig. LV. constitutes an important confirmation of PENFIELD'S/

PENFIELD'S experimental work, in that it shows that similar changes occur in the human. Areas of scar tissue have often been demonstrated in cases which have died long after the accident, but I have failed to find any record of observations such as those shown in Fig. IV., which have demonstrated in the human the steps by which this process occurs. As has already been emphasised there is no difficulty in demonstrating these changes if suitable material is obtainable.

The above changes provide a reasonable pathological explanation for symptoms such as memory loss and epilepsy, which must have an organic origin of some nature.

With regard to the symptoms of headache and dizziness, it has already been shown that the features of these symptoms are so constant and definite that there can be little, if any, doubt that they also are dependent upon organic damage of some kind. In attempting to provide an exact pathological explanation of symptoms such as these, it is important to realize that within the skull there are two circulatory systems, that of the blood/

blood and that of the cerebro-spinal fluid. These two circulations are dependent to a great extent on each other, and whatever the exact mechanism of their control, it is a mechanism of great delicacy. There is evidence to show that these circulations are both disturbed in some of the states which follow head injury. ⁽⁵⁾ BIELSCHOWSKY has shown that in post-concussional disturbances the pressure of the cerebro-spinal fluid may be abnormally high or it may be abnormally low. Further, he has shown that the rate of absorption of the fluid is often found to be reduced, as is evidenced by the slow rate at which sodium iodide is removed after injection into the subarachnoid space. BIELSCHOWSKY concludes his paper with the following sentence:-

"Bei 106 Fällen von Kopftraumen verschiedenster Art und Schwere mit und ohne cerebrale Herderscheinungen finden sich in der überwiegenden Mehrzahl der Fälle mehr oder weniger ausgeprägte Störungen des Liquorsystems".

With regard to the cerebral vessels, ^(30,31) MUCK has made the interesting observation that the vessels of the nasal mucosa in these cases/

cases showing post-concussional symptoms are often in an abnormal state of irritability, and as both they and the pial vessels have a common nerve supply, he concludes that the pial vessels are also in an abnormal state.

Moreover, it is apparent that the features of the symptoms of headache and dizziness suggest in themselves a circulatory cause. The aggravation of the headache by conditions which physiologically raise the intracranial pressure, such as stooping, exertion, and sleep, is a very definite feature of this symptom. Further, in the case of dizziness, this symptom is sometimes produced by conditions which lower the pressure, such as the sudden assumption of the erect posture. There are, however, other causes of dizziness, and all cases cannot be explained on the same basis. Some are probably associated with labyrinthine disturbances, and indeed LINTHICUM and RAND⁽²³⁾ have recently shown that abnormalities of the vestibular reactions are not uncommon in patients suffering from post-concussional disturbances of this type.

It seems therefore probable that symptoms such as headache, dizziness, and sleeplessness, depend in many instances on disturbances of the intra-cranial/

intra-cranial circulations. The slow disappearance of such symptoms probably indicates that the delicate adjustments of intra-cranial physiology are slow to recover. Further, the not uncommon observation that after apparent recovery, great excitement or effort may cause a return of headache indicates that complete recovery may be more apparent than real.

DIAGNOSIS, PROGNOSIS and TREATMENT.

Throughout the text of this thesis, many aspects of the subject of head injury have been discussed, and it seems desirable, finally, to consider in what way the conclusions arrived at can be applied towards the practical aspects of the subject. In the following pages, certain points in this connection are reviewed.

DIAGNOSIS.

In the above discussion of post-concussional disturbances, reasons have been given for concluding that the symptoms described must have an organic origin, and cannot be dependent on any functional disturbance. It therefore becomes important/

important to note the exact features of these symptoms in order that they may be distinguished from symptoms which are psychogenic in origin.

The occurrence of epileptic attacks provides definite evidence of considerable cerebral damage, as also does the demonstration of memory loss.

With regard to the symptoms of headache and dizziness, the analysis of the exact nature of these symptoms provides the best guide to their nature. The association of these symptoms with changes in posture and conditions which physiologically alter the intra-cranial pressure are points of great diagnostic value. It must be emphasised that physical examination seldom provides evidence of cerebral injury even when its extent is considerable. For this reason, the diagnosis of organic injury to the brain must be arrived at mainly by questioning the patient with a view to eliciting the exact nature of his complaints. It is only by so doing that an approximately correct idea can be obtained with regard to the relative degree of organic and functional disturbance. In this connection, reference may be made to the class of case in which the question of compensation was outstanding/
ing/

outstanding at the time of re-examination.

COMPENSATION CASES.

Many of the cases in which a question of compensation was still unsettled at the time of examination were found to be suffering from the symptoms of headache, giddiness, memory loss, and nervousness, which in their features resembled so closely those described above that there could be no doubt that they were dependent on organic changes. In some, anxiety about the future, compensation and other matters no doubt aggravated the symptoms, but in many of the cases these factors seemed to be relatively slight. In others, however, psychological factors seemed to play a large part in the clinical picture. The following cases are illustrative of this aspect of the question.

CASE NO. 25 F.E. A male aged 50 fell to the ground while working. He was unconscious for about half an hour; there was no evidence of fracture of the skull on X-Ray examination. When examined four months later, he had not returned to work and was drawing £1:2:6 per week in compensation. His memory he said, was not so good. He also complained of severe headaches which were worst on waking in the morning. During the first two months these used to waken him during the night but they were gradually becoming less severe.
He/

He suffered from attacks of giddiness which were most apt to come on if he looked up or looked down.

The symptoms in this case show the characters which are found after head injury, and it can therefore be concluded that there is an organic basis for them. In such cases the degree of super-added functional disturbance, if any, is often difficult to estimate exactly, and its valuation is unfortunately dependent on such uncertain factors as the examiner's impression as to what type of individual the patient is.

CASE NO. 61 J.M. A male aged 16, was hit on the side of the head by a hutch while working in the mine. He was not concussed, but a depressed fracture resulted which was treated by operation. The dura mater was not damaged. Seven months later, he had not returned to work, as he said he did not feel fit. There was no memory loss and he had little, if any, headache or giddiness. The small decompression was very tender to touch and he was in a very nervous state. He said that he sometimes awoke with a fright and admitted he was afraid to go back to the same work. He was drawing full compensation.

In the case of this boy, there is little doubt that if his injury had been caused through his own fault while, say, riding a bicycle, he would not have been off work for more than a few weeks. The psychological factor in this case was very/

very prominent and indeed the nature of the symptoms provided no definite evidence of organic disturbance.

PROGNOSIS.

The factors influencing prognosis in the acute stage have already been considered.

A very important object of this research was to investigate the possibility of recognising in the acute stage those cases in which late disturbances would develop. It must be admitted that in this respect the results have been disappointing; no means have been found by which an accurate prognosis with regard to the possibility of the development of post-concussional symptoms, can be formed. There are, however, one or two factors which do undoubtedly influence the ultimate outlook. The first of these is the age of the patient. Patients above the age of forty or fifty are much less likely to recover fully than are those below this age. Secondly, the degree of injury as estimated by the duration of unconsciousness is an indication of some, though of surprisingly little value. For example the/

the gross degrees of mental defect were found only to occur in young people whose cases fell into GROUP C.

It must be admitted that in many cases the prognosis is quite uncertain. Slight injuries may be followed by disabling symptoms, and severe injuries may recover completely in a way that is quite remarkable. It seems to me that the factor of individual variability must always hinder accuracy of prognosis with regard to the possibility of the development of post-concussional disturbances.

In most cases of concussion, slight foci of damage occur in the brain. These may take the form of capillary haemorrhages, tearing of nerve fibres or of the pia-arachnoid. The consequent changes, in particular the processes of healing, while leading to no disturbances of brain function in the majority of cases, in certain persons are sufficient to cause symptoms such as headache or epilepsy.

In view of the uncertainty of the prognosis even in slight cases, the treatment of all degrees of head injury deserves careful attention.

TREATMENT/

TREATMENT.

It has already been pointed out that modern treatment of cases of head injury has been directed largely towards reducing intra-cranial pressure. As soon as the initial stage of shock has passed off, the patient is propped up in the FOWLER position and given a dose of calomel. The intake of fluid is restricted, intra-venous injections of hypertonic solutions are given and lumbar puncture is repeatedly carried out.

This line of treatment is based on the assumption that cerebral oedema is a dangerous complication in that it may lead directly to death through raising the intra-cranial pressure, and that it is the cause of prolonged unconsciousness. While cerebral oedema is a constant development in cerebral contusion, is it often a dangerous complication?

The rise of intra-cranial pressure may certainly be caused by oedema of the brain, but in the present series the pressure was seldom above 300 millimetres of water and was therefore quite low when compared to the pressure readings which are commonly found in diseases such as meningitis and cerebral tumour. There was certainly no evidence that/

that in any of the fatal cases death was due to increased intra-cranial pressure.

It is probable that cerebral oedema can prolong the duration of loss of consciousness. The evidence in favour of this is that dehydrating measures may hasten the return of consciousness. It is, however, at least questionable whether an early return of consciousness is desirable in severe injuries. Are the brain tissues really damaged by being oedematous and is it desirable to force the patient, by means of dehydrating measures, to become conscious of his sufferings?

It is important to bear in mind that a degree of increase of intra-cranial pressure provides a powerful means of controlling haemorrhage from torn cerebral capillaries and veins. In this way, cerebral oedema may prevent haemorrhage, and correspondingly the artificial reduction of intra-cranial pressure may aggravate it.

For these reasons it seems to me that reduction of intra-cranial pressure should be reserved for cases which provide a definite indication for it, and that its indiscriminate use is not only undesirable, but dangerous.

DETAILS/

DETAILS OF TREATMENT.

In the early stages of severe injuries, treatment is mainly directed towards combatting shock. When unconsciousness is profound, there is a real danger, if the swallowing reflex has not recovered, that blood and nasal secretions may be inhaled into the lungs. This can be avoided by turning the patient half over on his face. As soon as the stage of shock has passed, there seems no reason why the patient should not be allowed a pillow: a hard mattress is an uncomfortable rest for a fractured skull. Patients often complain bitterly of the discomfort caused by lying on a hard mattress and this undoubtedly contributes to restlessness in some cases. Retention of urine is also a not uncommon cause of restlessness.

For the reasons stated in the last section, it is usually undesirable to attempt to reduce cerebral oedema during the first day or two days. In my opinion, it seems more important that some means should be found of preventing violent restlessness, as this is liable by raising the blood pressure, to encourage haemorrhage from torn cerebral capillaries and veins. Morphia is useful for/

for this purpose and can apparently be given without danger, provided the patient is allowed to recover from the influence of the drug between each dose, so that any change in his degree of consciousness is not obscured.

Whether in severe cases some cerebro-spinal fluid should be withdrawn is a difficult question to decide. In the first place, it is no easy matter to lumbar puncture a violently resistive person. The presence of blood in the cerebro-spinal fluid makes the back rigid and sensitive, as in cases of meningitis. A struggle is inevitable in many cases, and this may do more harm than the lumbar puncture would do good. This difficulty may, however, to a great extent be avoided by carrying out the procedure after the administration of morphine. In favour of lumbar puncture is the fact that removal of a small amount of cerebro-spinal fluid not infrequently gives relief to headache, and seems in some patients to hasten mental recovery. In only five cases in a series of twenty-five was the clinical condition on the day following lumbar puncture not definitely improved, and in a few of these relief from severe headache was quite dramatic.

It/

It may perhaps be fairly stated that if loss of consciousness is prolonged beyond two days, if headache is severe, or if the condition is getting worse, withdrawal of some cerebro-spinal fluid is of value both for diagnostic and for therapeutic purposes. It is better to relieve cerebral oedema by lumbar puncture than by the use of hypertonic solutions, because with lumbar puncture the pressure of the fluid can be estimated and care be taken to avoid reducing the pressure below normal. It therefore forms a more precise and a safer method of treatment.

Lumbar puncture is not only of value as a method of treatment but, as has already been shown, it can provide an accurate indication of the intracranial pressure, and of the degree of any subarachnoid haemorrhage. It also gives the first evidence available of the onset of meningitis. Further, the irritating effect of blood in the subarachnoid space, which in some cases is great, may be reduced by the withdrawal of some of the blood-stained fluid.

Where the pressure is found to be high, the effect of withdrawing a little cerebro-spinal fluid may be supplemented by administering a purge or/

or by raising the patient into the FOWLER position. Both of these latter procedures have a powerful effect in reducing intra-cranial pressure.

It seems doubtful whether the intra-venous injection of hypertonic solutions forms a desirable means of treating these cases. Its effects are difficult to control and may be more drastic than is desirable.

In the absence of a depressed fracture, there are few indications for operation on the skull. Compression of the brain by haemorrhage from the middle meningeal artery is a rare complication and is not usually difficult to diagnose. The gradual accumulation of blood in the sub-dural space may require surgical relief weeks or months after the accident, but rarely in the acute stage.

A very gradual return to normal activity is perhaps the most important point in the treatment of the convalescent stage. A recurrence of symptoms often indicates that work has been resumed too soon. No two cases are alike, and each patient must find out for himself how quickly he can with impunity return to full work.

An important part of the treatment of these cases is to endeavour to adjust the patient's mental/

mental attitude to his injury. He frequently leaves hospital after treatment for a week or ten days, may or may not rest for a time at home, and then is distressed to find that when he begins to work he develops headache and giddiness. This upsets him very much, as he considers he should have fully recovered. He fears that there has been some damage to his brain and is afraid to "sign off" his compensation claim. These worries, combined with the demoralising effect of severe headache, provide the basis necessary for the development of a condition of traumatic neurasthenia. Further, if the skull has been fractured the patient has a dread lest another slight injury to his head may have serious consequences, and therefore, if his occupation is a dangerous one, such as mining, he is afraid to resume it again. It is especially in the case of industrial accidents, that great care should be taken to adjust the patient's attitude to his injury. It seems to me that it is unwise to minimise the accident unduly. It seems wiser in the first place to tell the patient that complete recovery will occur, but that he must make up his mind to be off work for several weeks or months, that/

that recovery is always gradual, and that he must return to his full activity slowly. If he develops a headache or feels giddy, that must be looked on as an indication that he has done more than he is yet fit for.

If an attitude such as the above is adopted by the surgeon, an intelligent patient will realise the position and will not be frightened by the occurrence of an occasional attack of headache. Traumatic neurasthenia in a patient is largely caused by fear - fear that he is not getting better, fear that he will never be fit for work, fear that his brain is damaged, fear that another head injury would be fatal, and so on. For these reasons, psychological treatment directed towards adjusting the patient's attitude to his condition is a most important factor in the treatment of industrial accidents, not only those which involve the skull, but also those involving all parts of the body.

If the patient returns at an interval after the injury complaining of severe post-concussional symptoms, the treatment advised by TROTTER is of great value and often leads to a complete cure/

cure. Rest in the FOWLER position both day and night combined with the use of dehydrating measures such as the regular administration of strong solution of Magnesium Sulphate, either orally or by the rectum, forms the basis of this treatment. Its success in many cases suggests that circulatory disturbances such as TROTTER describes are an important factor in causing the persistence of symptoms.

EXAMINATION of the PATIENT in the ACUTE STAGE.

Cases of head injury when first seen by the surgeon are often in a severe state of shock, and in such circumstances it is desirable that any physical examination carried out should be no more than is absolutely necessary. This preliminary examination should be directed, in the first place, towards estimating the degree of injury and the immediate prognosis, but must also be carried out in sufficient detail to enable the subsequent development of complications to be recognized.

As has already been shown, death occurring during the first forty-eight hours is usually associated with a failure to react from the initial shock. As this is indicated by a progressive increase/

increase in the rate of the pulse and respirations, the importance of recording the pulse, respiration, and temperature at short intervals is evident.

Careful examination for haemorrhage from the ears, nose and throat is especially important because of the frequency with which infection may reach the brain through these avenues in the case of fracture of the base of the skull.

Wounds of the scalp should be looked for and treated with scrupulous care, however small they may be. As these wounds are known to heal readily, they are often carelessly treated. That the danger of infection is serious is shown by one case in which a wound of the forehead that was less than an inch in length resulted in a fatal osteomyelitis of the underlying skull.

The importance of recognizing haemorrhage from the nose in the case of comatose patients because of the danger of aspiration of blood and secretions into the lungs has already been stressed.

From the practical standpoint, it is desirable to examine the nervous system of the patient as soon as possible after admission, in order that changes which indicate the onset of serious complications/

complications may be recognized at a subsequent examination. It is therefore necessary to bear in mind the chief complications which may contribute to or cause death in these cases.

1. Aspiration of blood and nasal secretion into the lungs.
2. Infection spreading to the meninges and brain.
3. Cerebral oedema.
4. Intra-cranial haemorrhage:-
 Epi-dural
 Sub-dural
 Sub-arachnoid
 Intra-cerebral.

The onset of intra-cranial complications other than those due to infection manifests itself principally in two ways, firstly by a deepening of the degree of unconsciousness, and secondly, by onset of evidence of local damage to the brain, the most important indication of which is the development of weakness of one side of the body.

It is apparent that the injury itself may cause immediately not only deep loss of consciousness, but also paralysis or paresis of one side of the body. Therefore it is impossible to recognize the signs of the above intra-cranial complications unless the absence of these signs has been demonstrated before the complication supervenes. Hence
the/

the importance of estimating at the earliest possible opportunity the degree of consciousness and the presence or absence of evidence of local damage to the brain.

ESTIMATION of the DEGREE of CONSCIOUSNESS.

The degree of consciousness may be described roughly by the four terms, fully conscious, dazed, stuporose and comatose.

A fully conscious patient is able to converse intelligently and quite realises where he is and why he is there.

A dazed patient is able to answer simple questions, but his attention soon wanders. He is often drowsy and has but a vague idea as where he is. He subsequently has little or no recollection of what he said or did in this state.

A stuporose patient is unable to converse intelligently and his answers to questions are often meaningless, though he may be able to answer a simple question and may carry out an imperative command. He is usually resistive of any interference and is often very restless. Any painful stimulus applied to the body, such as pinching the skin is at once responded to by vigorous movements of/

of protection.

A comatose patient is unable to speak. There is little or no movement of the limbs. Painful stimuli elicit little or no response. The corneal reflex is sluggish or absent, and the pupils are often dilated.

The above rough summary may be of value to those who have to treat these cases and have often little experience in evaluating degrees of consciousness. It is obvious, however, that this simple classification is very rough. It can be made more accurate by modifying the degree of unconsciousness by the use of the adjectives slight, moderate, or deep, but even so, each observer will have a standard of his own and will formulate for himself a method of examination.

The stages by which consciousness returns have already been described, and their importance lies in the necessity for recognising the changes that indicate respectively either that consciousness is returning or that the patient is becoming more unconscious. For example, if the patient passes from a motionless state of coma to one of violent restlessness, the change should be recognized as a definite step towards recovery of consciousness./

consciousness.

PHYSICAL EXAMINATION of the NERVOUS SYSTEM in the
ACUTE STAGE.

This should be directed towards the demonstration of the presence or absence of gross injury to the brain. For this purpose the following may be noted:-

- Are the pupils equal and do they react to light?
- Is there any abnormal position of the eyes?
- Are the corneal reflexes present?
- Is there a facial paralysis?
- Is there neck rigidity?
- Are the abdominal reflexes equally active on the two sides?
- Are the knee jerks present and equally active?
- Is there any difference in the plantar reflexes on the two sides.
- Is there any evidence of loss of power on one side of the body?

The last point in the examination is perhaps the most important of all, and can be tested for even when the patient is deeply unconscious.

In the first place it is noted whether spontaneous movements of all the extremities occur. After first ascertaining that no fractures of the limbs are present, the upper extremities are lifted up above the head and simultaneously allowed to drop. A paralysed extremity will fall uselessly against/

against the patient's face or on to the bed, and even in deep coma this test will give valuable evidence of weakness of one arm.

When a degree of muscular activity is present, as in stupor, an attempt may be made to strike the patient's face with his own hand. Even in deep stupor, this is resisted, unless the extremity has lost power. The most important feature of tests such as these is that the power of the upper extremities can be compared with each other, and any appreciable degree of paresis can be shown.

Painful stimuli, such as nipping the skin, cause withdrawal movements even in deep stupor, and these again can be compared on the two sides. The movements of the lower extremities can be well tested by this method.

Having once demonstrated that there is no gross weakness of one side, the subsequent finding of hemi-paresis assumes great significance, and must indicate that some complication, such as haemorrhage is occurring.

Finally it should be remembered that injury to the head is often only one of many injuries, and as details of the accident are often unobtainable examination/

examination of all parts of the body is necessary.

TERMINOLOGY

The question of the terminology used in the description of the various clinical states met with is worthy of consideration.

With regard to the acute stage it has been pointed out that each case should be described according, firstly, to the damage to the skull and, secondly, to the damage to the brain. In spite of the criticism that various workers have raised to the term concussion the term describes well the mechanism by which the brain is injured in severe cases, but should be used in the understanding that the damage caused thereby is principally a bruising of the nerve elements, and that gross contusion with oedema and haemorrhage is by no means necessarily present.

With regard to the degrees of unconsciousness, traumatic coma, traumatic stupor and traumatic delirium speak for themselves. The term cerebral irritation is, I believe, misleading as I have already shown, and can be well replaced by the term traumatic delirium.

With regard to the late symptoms, the post-concussional syndrome seems to be the most appropriate term.

SUMMARY/

SUMMARY.

It is difficult to summarise the points which have been discussed in this thesis. The study of the two hundred cases dealt with has provided a large mass of material for investigation, of which only certain aspects have been analysed. My plan has been to record the facts and to discuss them throughout the text.

The frequency with which the common symptoms and signs of concussion occur has been analysed, and their significance discussed. Changes in the pressure, cytology, and chemistry of the cerebro-spinal fluid have been investigated in a series of severe cases, and this has thrown light on the significance of certain symptoms and signs of the acute stage.

The mechanism by which the brain is damaged in head injury has been discussed, and conclusions have been arrived at with regard to the mechanism of loss of consciousness and contre-coup injury. The pathology of the condition called "cerebral irritation" has also been considered. The conclusions arrived at in this section of the thesis/

thesis are quite contrary to most current teaching. The cases in GROUP C provided material for study of the stages by which consciousness returns.

I have been unable to find any record in the literature of an analysis of the clinical features of the acute stage of head injury in any large series such as is here attempted. Further special importance attaches to this work from the fact that most of the cases have not only been examined in the acute stage, but have been re-examined at an interval after discharge. The fact that, in the series, compensation cases are few in number has greatly added to the value of this part of the work. The frequency with which post-concussional disturbances occur has been investigated. It has become quite apparent that physical examination is of little value in the attempt to estimate the degree of cerebral damage, and hence the detailed analysis of the features of genuine post-concussional disturbances of a subjective nature has been of great importance. From the study of the post-concussional symptoms in a series of cases, I claim to have shown that these have well defined features which must be regarded as having an organic basis. This conclusion has been based on the clinical study alone/

alone, but is found to correspond with the opinion of some recent workers who have been investigating the pathological changes which occur in these cases.

The investigation of post-mortem material forms only a small section of this work, but I have succeeded in demonstrating changes in the neuroglia which have previously only been described in experimental work.

Finally, the practical application of certain aspects of this work has been discussed in relation to diagnosis, prognosis and treatment, and the methods of examination which I have found useful have been described.

The subject of this thesis suggests many lines of investigation, and the work which is here recorded must be regarded merely as a preliminary report based on the first two hundred cases seen.

In conclusion, I wish to express my gratitude to the Surgical Staff of the Royal Infirmary for allowing me to study the cases under their charge, and to the Residents and Nursing Staff who have been invariably helpful. I have also to thank the Medical Research Council for a grant for the purpose of this investigation.

W. R. Russell

REFERENCES.

1. BAGLEY, C. Arch. of Surg. 1929. 18. 1078
2. BAGLEY, C. "The Intra-cranial pressure in Health and Disease". Association for Research in Nervous and Mental Diseases. Baltimore. 1929. p. 217.
3. BERGMANN, E.von, Die Lehre von den Kopfverletzungen. Deut. Chin Lief, 30. 1880.
4. BERNER, O. Virchow's Archiv. 1930, 277, 386.
5. BIELSCHOWSKY, P. Zeitschr. Neurol. Psychiat. 1928, 117, 55.
6. BOLLINGER, O. Internat. Beiträge zum Wissen. med. 1891, 2, 57.
7. CASSASA, C.B. Proceedings Path. Soc. N.S. 1924, 24, 101.
8. CUSHING, H. Amer Jnl. Med. Sc. 1902, 124, 375.
9. CUSHING, H. "Studies in Intra-cranial Physiology and Surgery". London 1926.
10. DANDY, W.E. Ann. Surg. 1918. 68, 569.
11. DANDY, W.E. Ann. Surg. 1920, 70, 129.
12. DÜRET, H. "Traumatismes Cranio-cérébraux". Paris 1920.
13. FOERSTER, O. Zeitschr. Neurol. Psychiat. 1924, 94, 512.
14. FOERSTER, O and PENFIELD, W. Brain, 1930, 53 99.
15. GARRISON, FIELDING H. "History of Medicine", 4th. edit. Philadelphia 1929, page 55.
16. GREENFIELD, J.G. and CARMICHAEL, E.A. "The cerebro-spinal fluid in Clinical Diagnosis". London. 1925. p.49.

17. HIPPOCRATES. Sydenham Society. 1849. vol.1,
p. 429.
18. HURST, E. WESTON. Jnl. Path. and Bact. 1932,
35, 41.
19. JACKSON, H. Surg. Gynecol. and Obstet. 1922,
34, 494.
20. JEFFERSON, G. Communication to the Royal Society
of Medicine, 4th. December, 1931.
21. KUBIE, L. S. Arch. Neurol. and Psychiat. 1926,
16, 319.
22. LINELL, E.A. Arch. Neurol. and Psychiat. 1929,
22, 926.
23. LINTHICUM, F.H. and RAND, C.W. Arch. Otolaryngol.
1931, 13, 785.
24. LITTRES, ALEXIS. Hist. Acad. Roy. d. Sciences.
Année 1705 (1730) p.54.
25. MARTLAND, H. S. Jnl. Amer. Med. Assoc. 1928,
91, 1103.
26. MARTLAND, H. S. and BELING, C.C. Arch. Neurol.
and Psychiat. 1929, 22, 1001.
27. MEYER, A. Am. J. Insan. 1904, 60, 374, 377, 382
and 388.
28. MINKOWSKI, M. Schweiz. Med. Wschr. 1930, 11,
701.
29. MOCK, H. E. and De TAKATO, G. Ann. Surg. 1929,
90, 190.
30. MUCK, O. Zeitschr. Neurol. Psychiat. 1926, 106,
351.
31. MUCK, O. Zeitschr. Neurol. Psychiat. 1928, 115,
531.
32. OSNATO, M. and GILIBERTI, V. Arch. Neurol. and
Psychiat. 1927, 18, 181.
33. PENFIELD, W. Brain. 1927, 50, 499.

34. POTT, P. "Observations on the nature and Consequences of those injuries to which the head is liable from external violence". London. 1768.
35. RAND, C. W. Am. J. Surg. 1930, 8, 772.
36. ROSENHAGEN, H. Deut. Zeitschr. f. Nervenheilk. 1930, 114, 29.
37. ROSENHAGEN, H. Klin. Wschr. 1930. No. 13 P.55.
38. ROUGHHEAD, W. "The Trial of John Donald Merritt" Edin. 1929.
39. SOMERVILLE, C. W. Trans. Med. Chir. Soc. Edin., Edin. Med. Jnl. 1931, 38. No.8.
40. SWIFT, G. W. Surg. Gyn. & Obstet. 1931, 52, 576
41. TROTTER, W. Brain 1919. 42, 353.
42. TROTTER, W. Lancet, 1924. i. 935.
43. TROTTER, W. Lancet, 1925, ii. 953.
44. VULLIET, H. Presse Médicale. 1929, 37, ii, 1313.
45. WEED, L. H. Physiol. Rev. 1922, 2, 171.

CASE RECORDS

The following summaries of the CASE RECORDS have been prepared from the filled-in QUESTIONNAIRE of each case. They are arranged:-

Firstly, according to the group into which the case falls, and,

Secondly, according to the alphabetical order of the patient's names.

GROUP A

CASE NO. 1. J.A. Age 38. Ward 12.
 Admitted 9.1.31. Discharged 12.1.31.
 Occupation - Labourer.

HISTORY.

Previous to his accident, the patient was in good health. There was some evidence, however, that he was under the influence of drink at the time it occurred. The accident was caused by his falling down-stairs, eight days before admission. He does not think he was unconscious after the injury. There was bleeding from the nose, but none from the ears. Since the accident he has had continual severe headache across the forehead and left side of the head.

EXAMINATION. 10.1.31.

The pulse, respiration and temperature are normal. There is a bruise in the left frontal region causing a swelling of the periorbital tissues. The mental state is normal but there is severe frontal and left-sided headache. There was no sickness. The left pupil is 4 millimetres in diameter and the right 3.5 millimetres in diameter. There is some deafness of the left ear, and a constant rushing noise in this ear. Otherwise, examination of the nervous system shows no abnormality.

X-RAY EXAMINATION.

Examination of the skull showed a linear fracture of the left parietal bone extending into the petrous portion of the temporal bone.

EXAMINATION OF THE CEREBRO-SPINAL FLUID. 11.1.31.

Initial pressure-----220 mm of water.
 Pressure after removing 5 ccs.-140 " " "
 Total quantity of fluid removed, 10 ccs. the pressure then being 60 mm. The fluid was clear and yellow in colour and no clot formed on standing. /

CASE NO. 1. (Contd.)

standing. The red blood cell count was 320 per c.mm., the white blood cell count was 2 per c.mm. The white cells which were seen were small lymphocytes. The total protein estimation was 70 mm. per 100 ccs. The Wassermann reaction was negative.

PROGRESS. 12.1.31.

Today the patient feels quite well. There is no headache or neck rigidity and he insists on leaving hospital.

RE-EXAMINATION. 29.7.31.

The patient has not yet returned to work. He has difficulty in remembering details of his work previous to the accident. Three months ago he was admitted to Ward 26 suffering from fits, but has had none since then. There has been no headache since discharge. He notices that if he suddenly stands up, or if he looks up, his head seems to "swim". He also noticed that after the injury he stuttered for a few days. He is more nervous now than he was before the injury. During the first four months after leaving hospital, he had difficulty in falling asleep but now he sleeps well. Examination reveals no abnormality except deafness in the left ear as before, which is accompanied by a rushing noise in this ear. There was no deafness before the accident.

GROUP A

CASE NO. 2. D.A. Age 14. Ward 18.
Admitted 1.11.30. Discharged 7.11.30.
Occupation - Message-boy.

HISTORY.

The patient was quite well previous to his injury, which was due to his being knocked down by a tram, while riding his bicycle. Subsequent to the injury, he was unconscious for a few minutes. There was no haemorrhage from the nose or ears but he was somewhat shocked and dazed when admitted to hospital shortly afterwards.

EXAMINATION. 3.11.30.

The pulse, respiration and temperature are normal. There is a bruise in the right frontal region, but no injury to other parts. The mental state is normal and the patient has had no headache or vomiting since admission. Full neurological examination elicits no abnormality.

X-RAY EXAMINATION.

Examination of the skull shows no evidence of fracture.

RE-EXAMINATION. 20.8.31.

After leaving hospital, the patient rested at home for a week and then returned to work. Complete recovery had then occurred and he has felt quite fit since that time. Physical examination shows no abnormality.

GROUP A

CASE NO. 3. J.B. Age 40. Ward 10.

Admitted 4.1.31. Discharged 9.1.31.

Occupation - Miner.

HISTORY.

Previous to his injury, the patient was in good health except for some stiffness of the back which had been present for many years. The injury occurred on the day of admission and was due to a fall of stone from the roof, striking his head. He was unconscious for a few minutes. There was bleeding from his nose, but none from his ears.

EXAMINATION. 5.1.31.

There is a laceration of the scalp in the occipital region and also in the left frontal region. The mental state is normal but there is a slight frontal headache. There is no vomiting. Full neurological examination elicits no abnormality.

X-RAY EXAMINATION.

Examination of the skull shows no evidence of fracture.

RE-EXAMINATION. 10.10.31.

The patient was idle for four months after the injury as there was no work available. He did not rest in bed after returning home. There have been no post-concussional symptoms and he feels quite fit. The only abnormality he notices is that since the injury he frequently has fits of sneezing which come on two or three times a week and may continue for as long as five minutes.

There is no question of compensation outstanding.

GROUP A

CASE NO. 4. V.B. Age 26. Ward 11.

Admitted 20.2.31. Discharged 13.3.31.

Occupation - Housework.

HISTORY.

The patient is a deaf mute. Otherwise she was well previous to the accident, which was caused by her being knocked down by a tram-car. She was unconscious for a few minutes.

EXAMINATION. 21.2.31.

There is a small cut in the occipital region and there is also a fracture of the lower end of the right fibula. There is no haemorrhage from the nose or ears, and the patient is fully conscious. There is no headache, but the patient vomited once this morning. Full neurological examination elicits no abnormalities.

X-RAY EXAMINATION.

X-ray examination of the skull shows no evidence of fracture.

PROGRESS. 10.3.31.

The patient feels quite well.

RE-EXAMINATION. 28.7.31.

The patient says that her health has been excellent since discharge. She complains of no symptoms except occasional pain in the region of the scar in the occipital region.

Physical examination shows no abnormality.

GROUP A

CASE NO. 5. S.B. Age 50. Ward 16.

Admitted 23.6.31. Discharged 20.7.31.

Occupation - Miner.

HISTORY.

The patient was working in the mine on the day of admission when he was knocked down in the pit by a hutch. He remembers clearly all the details of the accident, and says that he was not unconscious. There was no bleeding from the nose or ears but he was profoundly shocked after the accident.

EXAMINATION. 24.6.31.

The pulse is rather weak. The lips are blue, and there is swelling around both eyes. There is laceration of the scalp in the frontal region. There is evidence of previous haemorrhage from the nose and extensive sub-conjunctival haemorrhage in the left eye. There are also extensive injuries to other parts, especially to the chest. The patient's mental state is normal, and there is no headache. He vomited once or twice, but the vomit contains no blood. The pupils are equal and react normally. The plantar reflexes show extensor responses on both sides and there is a slight degree of neck rigidity. No other abnormality was detected on physical examination of the nervous system.

RE-EXAMINATION.

Patient failed to report.

GROUP A

CASE NO. 6. J.B. Age 8 Ward 7.
Admitted 13.5.31. Discharged 20.5.31.

HISTORY.

The patient was quite well previous to the accident, which occurred at 8 p.m. two days before admission. The injury was due to his falling down-stairs while playing a game. He was unconscious for a few minutes. There was no haemorrhage from the nose or ears. He developed severe frontal headache, and on account of this was admitted to hospital.

EXAMINATION. 14.5.31.

There is no evidence of shock. There is a large haematoma in the occipital region but no evidence of haemorrhage from the nose or ears. The mental state is normal, and he now has no headache. He vomited on the night of the injury and also on the day following, but not since. Full examination of the nervous system shows no abnormality.

X-RAY EXAMINATION.

X-ray examination of the skull shows a crack in the occipital region.

RE-EXAMINATION. 8.12.31.

The patient has completely recovered and has had no symptoms since discharge.

Physical examination shows no abnormality.

GROUP A

CASE NO. 7. J.B. Age 20. Ward 16.

Admitted 4.8.31. Discharged 17.8.31.

Occupation - Clerk.

HISTORY.

The patient was quite well previous to the accident, which was caused by his being involved in a collision while riding his motor-cycle. He was unconscious for a few seconds but remembers all the details of the events immediately preceding the injury. There was haemorrhage from the left ear, but none from the nose or right ear.

EXAMINATION. 6.8.31.

There is no shock. There is no bruising of the scalp but there is evidence of previous haemorrhage from the left ear. The mental state is normal and there is no headache. The patient has vomited once since admission. There is complete loss of the sense of smell. There is also slight left facial weakness and slight disturbance of the sense of taste on the left side of the tongue. There is also slight deafness of the left ear, which on otoscopic examination is found to be full of wax and blood clot.

PROGRESS. 13.8.31.

The left facial weakness is very pronounced. There is deafness on the left side as before, and Weber's test is referred to the left.

RE-EXAMINATION. 9.12.31.

The patient says he lay in bed for three weeks after discharge, and has not worked since, as his post has been filled by someone else. His general condition since discharge has been fair, but he has not completely recovered. His memory is as good as previously, but he still suffers from slight headache. He feels dizzy when he gets up out of a chair or if he leans forward./

CASE NO. 7. (Contd.)

forward. He has become very nervous, and sometimes has difficulty in falling asleep. He intends to make a claim for compensation.

On examination he is found to have complete anosmia. The weakness of the face has recovered completely and there is now no deafness. There is some tremor of the eye-lids, but no other abnormality on physical examination. He is worrying a lot about himself because he has lost his post and his mother, who is a widow, is dependent on him.

GROUP A

CASE NO. 8. M.B. A male aged 41. Ward 7.

Admitted 6.5.31. Discharged 11.5.31.

Occupation - Plumber.

HISTORY.

The patient was quite well before his accident occurred. He slipped while working at midday on the day of admission, and struck his head on the ground. He was unconscious for a few moments but thereafter recovered and was able to walk to hospital. There was bleeding from the nose but none from the ears.

EXAMINATION. 7.5.31.

There is no shock. The blood pressure is 105/70. There is a bruise in the occipital region but no damage to other parts. His mental state is normal. There is slight frontal headache but there has been no vomiting. There is bi-lateral anosmia which is probably due to chronic catarrh. The pupils are equal and react normally. Examination of the cranial nerves and motor functions shows no abnormality. The reflexes are normal with the exception of the right knee jerk which is absent. There is some rigidity of the neck muscles which is probably due to the bruise in that situation.

X-RAY EXAMINATION.

X-ray examination shows no evidence of fracture.

PROGRESS.

Recovery was uneventful. The patient rested for a week at home after discharge, and then returned to work.

RE-EXAMINATION. 5.8.31.

There have been no post-concussional symptoms of any sort and there is no question of compensation outstanding. The patient received 35/- a week during the two weeks he was off work.

GROUP A

CASE NO. 9. G.B. A male aged 30. Ward 10.

Admitted 9.11.30. Discharged 13.11.30.

HISTORY.

On the day of admission while riding his motor-bicycle, the patient was involved in a collision in which he struck a motor bus and was thrown to the ground. He was unconscious for several minutes but remembers lying in the doctor's house. He also remembers accurately all events up to within one or two seconds of the accident. There was bleeding from his nose, but none from his ears. He was immediately sent to the hospital and was reported to have been fully conscious on admission.

EXAMINATION. 10.11.31.

There is no shock. The blood pressure is 125/80. There is a deep cut $1\frac{1}{2}$ inches long in the left frontal region but no injuries to other parts of the body. His mental state is normal but he has a slight headache in the frontal region. There has been no vomiting. Physical examination shows no abnormality. Recovery was uneventful.

X-RAY EXAMINATION.

X-ray examination of the skull shows no evidence of fracture.

RE-EXAMINATION. 6.8.31.

The patient was unable to report in person but a letter received from him states that he had been quite well since the accident and had recommenced his work ten days after discharge from the hospital.

GROUP A

CASE NO. 10. C.B. A male aged 6. Ward 7.

Admitted 19.11.30. Discharged 1.12.30.

Occupation - School-boy.

HISTORY.

The patient was quite well before his accident occurred. On the day of admission, he was knocked down in the street by a motor-car. The doctor who attended him said he was unconscious for about 4 minutes. There was no bleeding from his nose or ears.

EXAMINATION. 19.11.30.

There is no shock. There is a laceration of the scalp on the right side. There is no evidence of haemorrhage from the nose or ears and no injury to other parts of the body. The patient is rather irritable and restless. Physical examination shows no abnormality, with the exception of the left plantar reflex which gives an extensor response.

X-RAY EXAMINATION.

Examination of the skull shows a slight crack in the right frontal parietal region.

PROGRESS. 21.11.30.

To-day the patient is quite well. Physical examination shows no abnormality and both plantar reflexes give a flexor response.

28.11.30.

Still quite well.

RE-EXAMINATION. 10.10.31.

The patient states that he rested in bed for two weeks after leaving hospital, and that he, since that time, has been quite well. There has been no trace of any post-concussional disturbances.

GROUP A.

CASE NO. 11. T.C. A male aged 14. Ward 13.

Admitted 17.11.30 Discharged 1.12.30.

Occupation - Message-boy.

HISTORY.

The patient was quite well before his injury. Four days previous to admission while riding his bicycle, he collided with a barrow. He was knocked off his bicycle and was unconscious for a few moments. There was no bleeding from the nose or ears. He went home and during the following night and the next day he vomited frequently and some retraction of his neck developed. He also had severe headaches until he was admitted on 17.11.30.

EXAMINATION. On Admission.

Examination on admission shows that his pulse rate is 64 per minute and the respiration rate is 18, while the temperature is 98.8° F. The blood pressure is 105/75. There is no apparent injury to his scalp, no evidence of haemorrhage and no injuries to other parts of the body. His mental state is normal but there is very severe frontal headache. On physical examination the left pupil is slightly larger than the right but both react normally. There is an internal strabismus of the left eye which has been present since early childhood. There is no definite papilloedema but there is slight blurring of the edges of both discs. Examination of the other cranial nerves shows no abnormality. The motor functions are normal. The examination of the reflexes shows that the knee jerks are brisk, the right being slightly more active than the left. The plantar reflexes show no abnormality. There is very pronounced neck rigidity with some retraction of the head. Kernig's sign is positive.

X-RAY EXAMINATION.

Examination of the skull shows no evidence of fracture.

EXAMINATION OF THE CEREBRO-SPINAL FLUID. 17.11.30.

Lumbar puncture was carried out on evening of admission. 17.11.30.

CASE NO. 11.(Contd.)

The initial pressure is 240 mm. of water; pressure after removing 10 c.cs. is 120 mm. of water. The fluid is deeply blood-stained and on standing the supernatant fluid is yellow in colour, but there is no clot formation. There are 78,000 red blood cells per c.mm., and 140 white cells per c.mm. Of the latter, 21 per cent are polymorphs, 30 per cent are small lymphocytes and 45 per cent are large mononuclears. The total protein content of the fluid is 250 mgms. per 100 c.cs.

PROGRESS. 19.11.30.

The mental state is normal. Physical examination to-day shows no abnormality with the exception of the neck rigidity which is still present. This, however, is less marked than it was. There is still present a considerable degree of headache. The blood pressure is 105/70.

20.11.30.

The patient is still suffering from occasional severe headache. Neck rigidity is still pronounced and Kernig's sign is still positive. The blood pressure is 130/60.

Examination of the Cerebro-spinal fluid. 21.11.30.

The initial pressure is 240 mms. The cerebro-spinal fluid is uniformly blood-stained. The supernatant fluid is yellow in colour, but there is no clot formation. There are 50,000 red blood cells per c.mm., and 282 white cells per c.mm. Of the latter 37 per cent are polymorphs, 43 per cent are small lymphocytes and 20 per cent are large mononuclears. The total protein content of the fluid is 138 mgms. per 100 c.cs.

22.11.30.

There has been complete freedom from headache since the lumbar puncture yesterday and the patient feels quite well. There is still slight rigidity of the neck muscles.

24.11.30.

The patient feels quite well.

CASE NO. 11.(Contd.)

29.11.30.

There has been no headache and the patient feels quite fit.

X-RAY EXAMINATION

Examination of the skull shows no evidence of fracture.

RE-EXAMINATION. 23.7.31.

The patient says that he remained in bed for 6 weeks after returning home, but felt quite well the whole time. He has had no further headache. He has not become in the least nervous since his injury, in fact if anything is less nervous than before. Physical examination shows no abnormality.

GROUP A

CASE NO. 12. MRS. C. A female aged 49. Ward 11.
Admitted 6.3.31. Discharged 13.3.31.
Occupation - Housewife.

HISTORY.

The patient was quite well before her accident. This happened at 5 p.m. on the day of admission, and was due to her being knocked down in the street by a motor-car. She was unconscious for a few minutes, but remembers lying in a chemist's shop. There was some bleeding from the nose and right ear. She was sent immediately to the Infirmary and steadily recovered consciousness.

EXAMINATION. 9.3.31.

There is no shock. There is a bruise of the right parietal region and swelling around both eyes. There is evidence of previous haemorrhage from the right ear, and there is sub-conjunctival haemorrhage situated in the outer aspect of the left eye. There is also a fracture of the right clavicle. The mental state is normal. There is slight frontal headache. There is no vomiting now, but vomiting was severe on the night after admission and the vomited material contained blood. Physical examination elicits no abnormality.

X-RAY EXAMINATION.

Examination of the skull shows no evidence of fracture.

RE-EXAMINATION. 31.7.31.

The patient says that she lay in bed for six weeks after discharge from hospital. She has, however, not completely recovered. Her general health is not so good and her memory is defective. She notices this particularly in regard /

CASE NO. 12. (Contd.)

regard to the names of people, which she cannot remember. Her memory of events previous to the injury is perfect, and she remembers starting to cross the road at the point where the accident occurred. She has no headaches, but still suffers from dizziness. This affects her when she looks up and also sometimes while she is looking down or when she stoops to the ground. She has to lie quietly till this dizziness passes off and while it lasts "things seem to go round". She has not become nervous and can now sleep well, but for eight weeks after the accident she had great difficulty in falling asleep. There is no question of compensation outstanding. She has received £30.

Physical examination shows no abnormality. There is no trace of any defect of hearing.

GROUP A

CASE NO. 13. J.C. A male aged 3. Ward 13.

Admitted 20.7.31. Discharged 26.7.31.

HISTORY.

The patient was in good health previous to his accident. This was due to a fall and he is said to have fallen a distance of twelve feet. He was unconscious for a few minutes.

EXAMINATION. 21.7.31.

There is no evidence of shock. There is an abrasion over the vertex but otherwise no evidence of injury to the skull. There is no evidence of haemorrhage from the nose or ears, and there are no injuries to other parts of the body. The child lies quietly and pays little attention to what is happening around him. He complains of headache and vomited on one or two occasions before admission. Physical examination elicits no abnormality with the exception of the left plantar reflexes which give an extensor response.

X-RAY EXAMINATION.

Examination of the skull shows a linear fracture of the vault.

RE-EXAMINATION. 24.11.31.

His mother says that he has recovered completely, but that she notices that he is much more mischievous and wild since the accident. He is more excitable and when he has a fit of crying loses control of himself and rolls about on the floor.

Physical examination shows no abnormality.

GROUP A

CASE NO. 14. A.W.C. A female aged 19. Ward 14.
Admitted 27.4.31. Discharged 4.5.31.
Occupation - Typist.

HISTORY.

The patient was in good health at the time her accident occurred. While crossing the road at 1.10 p.m. on the day of admission she was knocked down by a motor lorry. She was unconscious for about five minutes. There was no bleeding from the nose or ears. She rapidly became conscious and was brought to the Infirmary.

EXAMINATION. (5 p.m. on the day of admission.)

There is no evidence of shock. There is a haematoma in the left parietal region and also bruises of the face. There is no evidence of haemorrhage from the nose or ears, but there is a fracture of the right clavicle. The mental state is normal, but she has a considerable degree of headache in the frontal region. There is no vomiting. The right pupil is slightly larger than the left, but full examination shows no further abnormality. She remembers clearly being within about a hundred yards of where the accident occurred.

The blood sugar content is 143 mgms. per 100 c.cs. a few hours after admission.

X-RAY EXAMINATION.

Examination of the skull shows no definite evidence of fracture.

RE-EXAMINATION. 22.7.31.

The patient says that she lay in bed for six weeks after discharge on account of her fractured clavicle. She returned to work two weeks /

CASE NO. 14. (Contd.)

weeks ago. She now feels well, but for five weeks after discharge suffered from a dull, throbbing headache. There was some dizziness while in the Ward, but there has been none since discharge. She has become a little frightened of traffic in the streets and there is a tender spot in the left parietal region. The compensation question has not yet been decided.

GROUP A

CASE NO. 15. T.C. A male aged 53. Ward 7.
Admitted 18.2.31. Discharged 4.3.31.
Occupation - Carter.

HISTORY.

The patient was quite well at the time his accident occurred. On the day of admission whilst at his work he was kicked by a horse. There was no loss of consciousness and no bleeding from his nose or ears. When brought to the Infirmary, he was found to have a laceration of the scalp on the left temporal region, and a small crack in the skull was found below this. He was therefore admitted.

EXAMINATION. 19.2.31.

There is no evidence of shock. There is no evidence of haemorrhage from the nose or ears, and there are no injuries to other parts of the body. The mental state is normal and there is no headache. Full physical examination shows no abnormality.

X-RAY EXAMINATION.

Examination of the skull shows no evidence of fracture.

RE-EXAMINATION. 7.8.31.

The patient says that he was off work for eleven weeks in all and since then he has been working as usual. He has felt quite well since the accident and there is no trace of post-concussional disturbances. There is no question of compensation outstanding.

GROUP A

CASE NO. 16. A.C. A male aged 25. Ward 16.
Admitted 9.6.31. Discharged 16.6.31.
Occupation - Miner.

HISTORY.

The patient's health was excellent at the time of the accident. At 8 p.m. on the day of admission, while riding his motor-bicycle, he skidded and was thrown to the ground. He was unconscious for a few minutes. There was no bleeding from the nose or ears. He was admitted to the Infirmary an hour and a half later.

EXAMINATION. 10.6.31.

There is no evidence of shock. There is a laceration of the scalp in the left parietal and temporal region. There is no haemorrhage from the nose or ears or other parts. There are no injuries to other parts of the body. The mental state is normal and there is no headache. Physical examination shows no abnormality, except that the right plantar reflex gives an indefinite response and the right abdominal reflexes are slightly less active than those on the left side.

X-RAY EXAMINATION.

Examination of the skull shows no abnormality.

RE-EXAMINATION.

Patient failed to report.

GROUP A

CASE NO.17. W.C. A male aged 18. Ward 7.

Admitted 18.3.31. Discharged 1.4.31.

Occupation - Miner.

HISTORY.

The patient was quite well at the time his accident occurred. On the morning of admission while going to his work, his foot slipped and his head struck a rail. He remembers all the details of his injury. He was not unconscious after the accident and was able to get up and walk. There was no bleeding from his nose or ears, but considerable haemorrhage occurred from laceration of the scalp in the right temporal region.

EXAMINATION. 18.3.31.

There is no evidence of shock. There is no haemorrhage from the nose or ears and there are no injuries to other parts of the body. The mental state is normal, and full examination of the nervous system shows no abnormality except that the pupils, which are both 5.5 mms. in diameter, react poorly both to light and on convergence. The blood pressure is 140/75. A slight crack in the skull was found when the wound was operated upon, but X-ray examination of the skull shows no evidence of this.

RE-EXAMINATION. 5.8.31.

The patient says that he lay in bed for ten days after returning home. He has not yet returned to work. His memory is as good as previously and there have been no fits, but he still has some headache, which is usually worse in the middle of the day. He also suffers from a certain amount of dizziness after he rises suddenly from a chair or after he stoops to the ground. He has not become nervous and he sleeps well. He has been drawing 25/8 a week since his injury but has now been certified fit for light work, which he is going to start soon.

GROUP A

CASE NO. 18. N.D. A male aged 15. Ward 16.

Admitted 23.12.30. Discharged 30.12.30.

Occupation - Message-boy.

HISTORY.

The patient was in good health at the time the accident occurred, but the vision of his right eye has always been defective owing to myopia. On the evening of admission, while riding his bicycle, he skidded and was thrown to the ground. He recovered consciousness in a shop nearby. There was no haemorrhage from his nose or ears. He was immediately sent to the Infirmary and admitted.

EXAMINATION. 23.12.30.

There is no evidence of shock. There is a bruise in the region of the face but no haemorrhage from the nose or ears. There are no injuries to other parts of the body. The mental state is normal. There is no headache. Full physical examination of the nervous system shows no abnormality. The patient remembers skidding while on his bicycle and losing his balance but does not remember striking the ground. He remembers being brought into hospital.

X-RAY EXAMINATION.

Examination of the skull shows no evidence of fracture.

RE-EXAMINATION. 23.8.31.

The patient says that he recommenced work three weeks after leaving hospital and has had no post-concussional symptoms since then. He has noticed that whereas previous to the accident he frequently suffered from severe headache he now seldom has a pain in his head. The last thing he remembers previous to the accident is taking his bicycle out to go for a run. He does not now recollect the details of the accident, although he was able to describe them while in hospital.

GROUP A

CASE NO. 19. J.D. A male aged 9. Ward 12.
Admitted 6.3.31. Discharged 15.4.31.
Occupation - School-boy.

HISTORY.

The patient's health was good at the time of his injury, but he has suffered from discharge from the right ear for as long as he can remember. At 3 p.m. on the afternoon of admission, while gathering coal, he was struck on the head by a "metal pipe," which had been thrown over the bank on which he was working. He was unconscious for a few minutes, but there was no bleeding from his nose or ears. He remembers recovering consciousness and being brought into Hospital.

EXAMINATION. 9.3.31.

There is now no evidence of shock. There is a large bruise and palpable depressed fracture in the right temporal region, but there are no injuries to other parts. His mental state is normal and he has no headache, though there was some pain in the right side of his head for two days after admission. He vomited during these two days. On examination the pupils are equal and react normally. There is slight deafness on the right side. Weber's test is referred to the right side and on the right side bone conduction is greater than air conduction. Examination of the other cranial nerves shows no abnormality. There is a slight tremor of the out-stretched arms, but no weakness or disturbance of tone is present. The reflexes are all normal with the exception of the plantar reflexes, which both give an extensor response. There is no neck rigidity and Kernig's sign is negative.

X-RAY EXAMINATION.

Examination of the skull showed an extensive, depressed fracture of the right parietal and right frontal region.

PROGRESS. 17.3.31.

The patient feels quite well, and examination is as before.

CASE NO. 19. (Contd.)

11.3.31.

The plantar reflexes still give an extensor response. There is no trace of astereognosis in either hand.

RE-EXAMINATION. 29.7.31.

The patient's mother states that he did not rest in bed after returning home and that he has been quite well since the injury. The only change she notices is that he not infrequently awakens suddenly in the night either crying or laughing and that he is rather more wild and difficult to manage at home. Examination of the skull shows that the depression is still easily palpable.

GROUP A

CASE NO. 20. MRS. E.D. A female aged 43. Ward 14.
Admitted 13.7.31. Discharged 20.7.31.
Occupation - Housewife.

HISTORY.

The patient was in good health at the time the accident occurred. At 10 a.m. on the morning of admission she was knocked down by a motor van and was rendered unconscious for a few minutes.

EXAMINATION.

When examined on admission the patient's pulse is full and there is no evidence of shock. The blood pressure is 102/78 and there is no apparent bruising of the skull. There is no haemorrhage from the nose or ears, and apart from bruises there are no injuries to the other parts. The mental state is normal. There is severe, right-sided headache referred to the temporal region. She vomited soon after admission. Examination of the nervous system shows no abnormality.

X-RAY EXAMINATION.

Examination of the skull shows no evidence of fracture.

PROGRESS.

Blood sugar content on 13.7.31, at 1.45 p.m. was 182 mgms per 100 c.cs., and on the 14.7.31., at 3 p.m., was 200 mgms. per 100 c.cs.

RE-EXAMINATION 24.11.31.

The patient says that she lay in bed for seven weeks after her injury and that complete recovery has not yet occurred. She says that she is unable to do her work owing to pain in the leg. Her memory is good, and she has no headache but she sometimes feels giddy on stooping. She has become nervous and sleeps badly and her vision is not so good for reading. The compensation question is not yet settled.

GROUP A.

CASE NO. 21. S.D. A male aged 46. Ward 7.

Admitted 29.7.31. Discharged 26.8.31.

HISTORY.

The patient was in good health at the time the accident occurred. On the day of admission while on his bicycle he was knocked down by a motor-car. He was dazed for a few seconds but was able to get up and walk. There was no haemorrhage from the nose or ears, but he lost a quantity of blood from the cuts on the right side of his face and head. He was reported to be very shocked on admission.

EXAMINATION. 4.8.31.

There is a sub-conjunctival haemorrhage at the outer side of his right eye, and there are bruises in many parts of the body. The mental state is normal, but there is considerable headache. Physical examination elicits no abnormality.

X-RAY EXAMINATION.

Examination of the skull shows a fracture in the right occipital and parietal regions.

RE-EXAMINATION. 8.12.31.

The patient says that he lay in bed for three weeks after returning home, during which time he continued to have some headache. He did not start light work until a week ago. Complete recovery has not yet occurred. His memory is good and there have been no fits. He suffers from throbbing frontal headaches which at first were worst at mid-day but now are felt more on wakening in the morning, especially in dull weather. He often has dizzy turns which sometimes come on while he is working, when he has to stop, hold on to something, or sit down until they pass off. There is now no question of compensation outstanding as his claim has been settled. He received £200. Examination shows no abnormality except slight deafness of the right ear. Weber's test was not referred.

GROUP A

CASE NO. 22. C.D. Age 20. Ward 17.

Admitted 11.4.31. Discharged 18.4.31.

Occupation - Shop worker.

HISTORY.

Patient was in good health at the time the accident occurred. On the morning of admission at 8.30 o'clock, after alighting from a tram-car, she was knocked down in the street by a motor. She remembers being in the tram and deciding to alight but has no recollection of actually getting off the car. She was unconscious for about one hour. There was no bleeding from the nose or ears.

EXAMINATION. 12.4.31.

There is no shock. The blood pressure is 100/50. There is a small cut in the occipital region and there is extensive effusion round the left eye. There is no evidence of haemorrhage from the nose or ears, but there is a subconjunctival haemorrhage in the outer aspect of the left eye. The mental state is normal and there is no headache. She vomited on two or three occasions yesterday. The vomit contained no blood. The right pupil is slightly larger than the left but both react normally. Physical examination shows no other abnormality.

X-RAY EXAMINATION.

X-ray examination of the skull shows no evidence of fracture.

RE-EXAMINATION 18.8.31.

Patient says that she felt quite well when she left hospital and returned to work two weeks after discharge. She does not now, however, feel that she has quite recovered. She is lacking in energy and often turns dizzy when looking up, which she has to do as her work is in a library. There have been no headaches but she feels very nervous, much more so than previously. There is no question of compensation outstanding. Physical examination shows no abnormality.

GROUP A

CASE NO. 23. W.D. Age 35. Ward 6
Admitted 15.1.31. Discharged 18.1.31.
Occupation - Carter.

HISTORY.

The patient's health was good before the accident occurred. At 6 p.m. on the day of admission, while driving a horse along the road, he was involved in a collision with a lorry and was thrown to the ground. He was unconscious for about half an hour. There was no bleeding from the nose or ears. He improved steadily, so that on admission half an hour later he was reported to be only slightly dazed.

EXAMINATION. 16.1.31.

There is no shock. There is a bruise in the left fronto-parietal region. There is no evidence of haemorrhage from the nose or ears, and no injury to other parts of the body. The mental state is normal. The patient feels a slight heaviness across the forehead, but otherwise has no headache. Physical examination shows no abnormality. Patient remembers losing his balance and beginning to fall to the ground, but remembers no more until he woke up in the Out-patient Department of the Infirmary.

RE-EXAMINATION 10.8.31.

Patient states that he rested in bed for three weeks after leaving hospital and then returned to work. There have been no post-concussional disturbances of any sort. There is no question of compensation outstanding. He received 30/- a week in compensation while off work. Physical examination shows no abnormality.

GROUP A

CASE NO. 24 M. E. (female) Age 40. Ward 9.

Admitted 24.5.31. Discharged 9.6.31

Occupation - House-wife.

HISTORY.

Patient was quite well at the time the accident occurred. About 1 p.m. on the day of admission, while being driven in a motor-car she was involved in a collision with a 'bus. She remembers seeing the 'bus coming towards her but remembers no more until she woke up in a house near where the accident occurred. There was no bleeding from the nose or ears.

EXAMINATION. 25.5.31.

There is no shock. There is a bruise in the frontal region, but no evidence of haemorrhage from the nose or ears. There are bruises to other parts of the body but no serious injury. The mental state is normal. There is a mild degree of headache. There is no vomiting. The right pupil is 3.5 mms. in diameter, the left pupil is 3.0 mms. in diameter. Full neurological examination shows no further abnormality, with the exception of a slight degree of neck rigidity.

X-RAY EXAMINATION.

Examination of the skull shows no evidence of fracture.

RE-EXAMINATION.

Patient was unable to report as she lives near Doncaster.

GROUP A

CASE NO. 25 F.E. (male) Age 50. Ward 7.

Admitted 5.8.31. Discharged 17.8.31.

Occupation - Labourer.

HISTORY.

The patient's health was good at the time the accident occurred. On the day of admission while standing on the step of a lorry the step gave way and he fell and struck his head on the ground. He remembers standing on the lorry but has no recollection of falling. He was unconscious for half an hour. There was bleeding from the nose but none from the ears.

EXAMINATION. 6.8.31.

There is a laceration in the occipital region and the forehead is also bruised. There is no evidence of haemorrhage from the nose or ears, no subconjunctival haemorrhage and no evidence of injury to other parts of the body. The mental state is normal and there has been practically no headache. He vomited once while recovering consciousness. Full neurological examination shows no abnormality with the exception of a slight degree of neck rigidity.

X-RAY EXAMINATION.

Examination of the skull shows no evidence of fracture.

RE-EXAMINATION. 7.12.31.

Patient has been taking things quietly at home and has not returned to work. He says that complete recovery has not occurred. He is unable to remember things as well as formerly and he suffers from headaches which are worst when he awakens in the morning. He also has dizzy turns in which the pavement seems to rise up, and these are much worse if he looks up or down. He has become very frightened, especially in the street and had difficulty in falling asleep for 2 months after the accident. He has found that he now requires glasses for reading for the first time. He is still drawing 22/6 a week in compensation. Physical examination shows no abnormality.

GROUP A

CASE NO. 26 J. P. (male) Age 55. Ward 13.
Admitted 6.7.31. Discharged 7.8.31.
Occupation - Outside porter.

HISTORY.

The patient's health was good at the time of the accident. On the day of admission he was working in the Waverly Station and slipped down the lift shaft. He remembers falling and striking the bottom of the shaft. There was no loss of consciousness and no bleeding from the nose or ears.

EXAMINATION. 8.7.31.

There is no shock. The lower jaw is fractured and there is a subconjunctival haemorrhage in both eyes, especially the right. There are no injuries to other parts with the exception of a cut in his hand. The mental state is normal. He has a moderate degree of headache. Physical examination shows no abnormality with the exception of a slight degree of neck rigidity.

BLOOD SUGAR ESTIMATION.

6.7.31. 1.30 p.m. - - - 250 mgms. per cent.
7.7.31. 10.15 a.m. - - - 250 mgms. per cent.

RE-EXAMINATION. 26.11.31.

Patient says that complete recovery has not occurred. His general health is good and his memory is as good as previously but he suffers from severe headaches. These are worse at night when he puts his head on the pillow. If he bends his head forwards he gets a pain in the forehead. If he bends it back he gets a sharp pain in the occipital region. Owing to this he has to move his head very carefully. He, not infrequently, has slight dizzy turns. He has become nervous and very shaky and is unable to sleep on account of the headache. The question of compensation has not yet been decided and causes the patient considerable worry. Physical examination shows no abnormality.

GROUP A

CASE NO. 27 J.F. Age 15 Ward 13

Admitted 12.1.31. Discharged 14.1.31

Occupation

HISTORY.

The patient's injury was caused by his falling and striking his head on the ground. He was unconscious for a few minutes. There was no bleeding from the nose or ears and he regained consciousness.

EXAMINATION. 12.1.31. (3 hours after admission.)

The mental state is normal and there is no shock. Blood pressure is 116/80. There is a bruise in the right occipital region but no evidence of haemorrhage in the nose or ears. There are no injuries to other parts. He has vomited once since admission but the vomit contained no blood. The diameter of the right pupil is 4 mms. and of the left 3.5 mms. Full examination elicits no other abnormality. He has no recollection of anything he did after he went to bed on 10.1.31 at 10.45 p.m.

X-RAY EXAMINATION.

Examination shows no evidence of fracture.

RE-EXAMINATION.

He failed to report.

GROUP A

CASE NO. 28. J. F. (male) Age 8. Ward 10.

Admitted 19.4.31. Discharged 25.4.31.

HISTORY.

The patient has always been a delicate child and has suffered from enlarged glands in the neck. On the day of admission at 7 p.m. he fell into an area, a distance of 12 feet, while playing a game. He was unconscious for about five minutes. There was some bleeding from his nose but none from his ears.

EXAMINATION. 20.4.31.

There is now no evidence of shock. There is a bruise of the left frontal and left temporal regions. There is no subconjunctival haemorrhage and no evidence of haemorrhage from his ears. There is a fracture of the left wrist. The mental state is normal. There is slight headache. He vomited on two occasions this morning. Physical examination shows no abnormality.

X-RAY EXAMINATION.

X-ray examination of the skull shows no evidence of fracture.

RE-EXAMINATION.

Patient was unable to report as he was in the Sick Children's Hospital suffering from "indigestion".

GROUP A

CASE NO. 29 J. G. (male) Age 24. Ward 7.
Admitted 3.6.31. Discharged 12.6.31.
Occupation - Shop-assistant.

HISTORY.

The patient's health was good before the accident occurred. At 8 a.m. on the day of admission while running to catch a tram, he was knocked down by a motor 'bus. He remembers running for the tram, but remembers no more till he woke up in Hospital. There was bleeding from his nose but none from his ears. He was reported to have been in a very excitable condition on admission and witnesses of the accident stated that he was never unconscious. He became very noisy and restless while in the Out-patient Department.

EXAMINATION. 4.6.31.

The patient is quite conscious and complains that he is very uncomfortable lying on his back in bed. There is a cut in the occipital region of the scalp. There is no haemorrhage from the nose or ears. There are bruises on other parts of the body. There is slight headache but no vomiting. The left pupil is slightly larger than the right, but both react well. Examination otherwise shows no abnormality.

X-RAY EXAMINATION.

X-ray examination of the skull shows no evidence of fracture.

RE-EXAMINATION. 7.12.31.

Patient says that he rested for four weeks owing to an injury to his ankle. Thereafter he returned to work and has remained quite fit, with the exception of some stiffness in the injured ankle.

GROUP A

CASE NO. 30. V. G. (male) Age 24. Ward 7.

Admitted 14.1.31. Discharged 17.1.31.

Occupation - Trick rider.

HISTORY.

The patient was quite well when the accident occurred. He was riding a horse and performing tricks in the Waverly Market when he was thrown to the ground. His head was injured in the fall, but it was doubtful whether he lost consciousness at the time. He was able to walk to the ambulance, but thereafter lost consciousness and remembers nothing till he found himself in Hospital.

EXAMINATION. 15.1.31.

The patient is fully conscious. There is a laceration of the scalp above the left eye, but no evidence of haemorrhage from the nose or ears. There are no injuries to other parts of the body. There is no headache or vomiting and full examination shows no abnormality.

X-RAY EXAMINATION.

X-ray examination of the skull was not carried out.

RE-EXAMINATION.

Patient could not be traced.

GROUP A

CASE NO. 31 T. G. (male) Age 4. Ward 18.
Admitted 28.2.31. Discharged 28.3.31.
Occupation -

HISTORY.

The patient was in good health before the accident occurred. On the day of admission while going a message, he was knocked down by a motor car. He was unconscious for a few minutes. There was considerable haemorrhage from the scalp wound.

EXAMINATION. 1.3.31.

The patient is quite conscious but rather irritable. There is an extensive laceration of the scalp, but no evidence of haemorrhage from the nose or ears. There is a considerable degree of headache across the forehead but no vomiting. Full examination of the nervous system shows no abnormality.

X-RAY EXAMINATION.

X-ray examination of the skull shows no evidence of fracture.

PROGRESS.

3.3.31 Patient remembers that he was going to get a box of matches but has no further recollection of what occurred. He is more contented to-day, but still says his head is painful.

9.3.31. There is some purulent discharge from the wound to-day.

RE-EXAMINATION.

Patient could not be traced.

GROUP A

CASE NO. 32. M. G. (male) Age 27. Ward 7.

Admitted 17.12.30. Discharged 26.12.30.

Occupation - Miner.

HISTORY.

The patient's health was good at the time the accident occurred. At 10 p.m. on the day of admission while working in the mine, a piece of coal fell from the roof and struck his head. He did not lose consciousness. There was bleeding from the nose but none from the ears.

EXAMINATION. 18.12.30.

The patient is fully conscious. There is a large bruise of the frontal region spreading round both eyes. This was apparently caused by his face being forced against the ground when the accident occurred. There is severe frontal headache, and he vomited frequently since admission. The vomited material contains blood. Full examination shows no further abnormality.

X-RAY EXAMINATION.

X-ray examination of the skull shows no evidence of fracture.

PROGRESS.

21.12.30. The patient has now only slight pain across the base of the nose, and otherwise he feels well.

RE-EXAMINATION. 7.8.31.

The patient says that he lay in bed for two weeks after leaving Hospital. He does not consider that he has fully recovered from the effects of the accident. He started work seven weeks ago and since then has been troubled with indigestion. He still experiences shooting pains in his forehead which come on every day and may last for a few minutes or may continue for many hours. The pain in the head is usually present/

CASE NO. 32 (Contd.)

present at night and also when he wakens in the morning. He has experienced a few "turns" in which everything goes black for a few seconds. He has not become nervous and he sleeps well. There is no question of compensation out-standing. He received 27/6 a week while off work and signed off compensation for a further sum of £11.

Physical examination shows no abnormality.

GROUP A

CASE NO. 33 H. G. (male) Age 19. Ward 13.
Admitted 12.1.31. Discharged 16.1.31.
Occupation - Labourer.

HISTORY.

The patient was quite well at the time the accident occurred. While at his work on the day of admission a bundle of slates fell from a height of thirty-five feet and struck his head. He was unconscious for a few minutes, but there was no bleeding from the nose or ears.

EXAMINATION. 13.1.31.

The patient is fully conscious. The blood pressure is 118/68. There is a laceration of the right parietal region, but there are no injuries to other parts of the body. There is severe, throbbing pain in the head, but there has been no vomiting. Examination of the cranial nerves and motor functions shows no abnormality. The reflexes are normal except that the left knee jerk is slightly more active than the right and the left plantar response is indefinite. There is no sensory loss.

X-RAY EXAMINATION.

X-ray examination of the skull shows no evidence of fracture.

RE-EXAMINATION.

Patient failed to report.

GROUP A

CASE NO. 34 T. G. (male) Age 26 Ward 7.
Admitted 13.5.31. Discharged 25.5.31.
Occupation -

HISTORY.

The patient's health was good at the time the accident occurred. At midday on the day of admission while riding a bicycle, he was thrown on to the road. He remembers clearly being within a mile of where the accident occurred and has a faint recollection of trying to avoid two hens which were on the road. He was unconscious for a few minutes. There was no bleeding from his nose or ears.

EXAMINATION. 15.5.31.

The patient is fully conscious. There is a cut in the left frontal region and the left eye is closed with effusion. There is no evidence of haemorrhage from the nose or ears, but there is a small sub-conjunctival haemorrhage on the outer side of the left eye. Apart from bruises, there are no injuries to other parts of the body. There is no headache and there has been no vomiting except on one occasion after the anaesthetic. Full examination of the nervous system shows no abnormality.

X-RAY EXAMINATION.

X-ray examination of the skull was not carried out.

PROGRESS.

23.5.31. The patient feels very well. He has no headache, giddiness or diplopia. He now remembers more clearly that a hen ran across the road just before his accident occurred.

RE-EXAMINATION/

CASE NO 34. (Contd.)

RE-EXAMINATION. 3.12.31.

Patient says that he was off work for two weeks after leaving Hospital. Complete recovery has occurred and he has had no symptoms except that when he first began work he suffered from severe headache.

Physical examination shows no abnormality.

GROUP A

CASE NO. 35 E. G. (male) Age 21. Ward 18
Admitted 16.5.31. Discharged 20.5.31.
Occupation - Slater.

HISTORY.

The patient was in good health at the time the accident occurred. At 3.40 p.m. on the day of admission while riding his motor-bicycle, the front fork of his machine broke while he was going at a speed of about twenty-five miles an hour. He was thrown to the ground where he lay unconscious for a few minutes. There was no bleeding from the nose or ears.

EXAMINATION. 17.5.31.

The patient is fully conscious. There is a cut in the right temporal region. Blood pressure is 120/75. There is no evidence of haemorrhage from the nose or ears and no sub-conjunctival haemorrhage. There are no injuries to other parts with the exception of some slight bruises. There is no headache or vomiting. Physical examination shows no abnormality with the exception of a slight degree of neck rigidity.

X-RAY EXAMINATION.

X-ray examination was not carried out.

PROGRESS.

20.5.31. The patient feels well. There is no headache, giddiness or diplopia. There is now no stiffness of the neck.

RE-EXAMINATION.

The patient failed to report.

GROUP A

CASE NO. 36 G. G. (male) Age 24. Ward 7.
Admitted 5.5.31. Discharged 22.5.31.
Occupation - Labourer.

HISTORY.

The patient was in good health before the accident occurred. At 5.30 p.m. on the day of admission he was playing on a tree, and while swinging on one of the branches, the branch broke and he fell to the ground. He remembers the tree breaking, but remembers no more till he woke up a few minutes later on the ground. His arms felt a little numb after the injury and he could not move his hands properly. He was able, however, to walk to the 'bus and there was no bleeding from the nose or ears.

EXAMINATION. 4.5.31.

There is no evidence of injury to the scalp. There is a considerable degree of bruising of the back and of the arms. The patient is fully conscious. He has slight pain in the occipital region. There is no vomiting. There is some rigidity of the neck, but full examination of the nervous system elicits no further abnormality.

X-RAY EXAMINATION.

X-ray examination shows that there is a compression fracture of a cervical vertebra.

RE-EXAMINATION. 8.12.31.

Complete recovery has occurred, except that the patient has to hold his head bent a little forward. He also has a little pain between his shoulders.

-GROUP A

CASE NO. 37 W. G. (male) Age 58. Ward 6.
Admitted 18.12.30. Discharged 26.12.30.
Occupation - Barman.

HISTORY.

The patient was in good health at the time the injury occurred. On one previous occasion in 1928, he had suffered from unconsciousness following a motor-car accident. He drinks beer in moderation and smelt of alcohol when admitted, though there was no evidence that he was intoxicated. On the day of admission, while riding his bicycle, he was knocked down by a motor-car. He remembers being at the spot where the accident occurred but has no recollection as to what happened. He was unconscious for a few minutes and when admitted was reported to be very shocked.

EXAMINATION. 19.12.30.

There is now no evidence of shock. The pulse rate is 80 per minute. The blood pressure is 130/75. There is a bruise in the left temporal region and the left eye is closed with effusion. There is evidence of haemorrhage from the nose, but none from the ears. There are no injuries to other parts, and there is no subconjunctival haemorrhage. The patient is fully conscious. There is no headache or vomiting. The plantar reflexes both give an extensor response and there is slight neck rigidity. Otherwise examination of the nervous system shows no abnormality.

X-RAY EXAMINATION.

Examination of the skull shows a small linear fracture in the left temporal region.

PROGRESS/

PROGRESS.

22.12.30. It was not until today that the left eye could be examined owing to the extensive effusion closing it. It is now apparent that there is a degree of ptosis on the left side. The left pupil is 5.5 mms. in diameter and the right pupil is 3.5 mms. in diameter. There is no reaction of the left pupil to light but the consensual reaction of the right pupil is present. There is diplopia and it is apparent that there is limitation of the upward, inward and downward movements of the left eye. There is no loss of vision.

26.12.30. There is definite evidence of improvement of the third nerve paralysis of the left side.

RE-EXAMINATION. 11.8.31.

The patient states that he lay in bed for 4 weeks after discharge. Complete recovery has not occurred. His general health is good but his memory is a little defective. He notices particularly that he has difficulty in remembering the names of people. There are occasional slight headaches and he sometimes feels dizzy when he looks up. He is not nervous and he sleeps well. There is now no question of compensation outstanding. He received £50. Diplopia is still present. The left pupil is 3.5 mms. in diameter and the right is 4 mms. in diameter. The light reaction in the left eye is sluggish compared to that in the right eye. There is diplopia on looking upwards and downwards, and on looking to the right but none on looking to the left. Examination otherwise shows no abnormality.

GROUP A

CASE NO. 38 A. G. (male) Age 15. Ward 18.
Admitted 30.5.31. Discharged 4.6.31.

HISTORY.

Patient was in good health at the time the accident occurred. At 1.50 p.m. on the day of admission, while riding his bicycle, he was involved in a collision, was thrown to the ground, and was unconscious for several minutes. He thinks he remembers that a motor-car was going to pass him but has no further recollection of events until he woke up in the police ambulance.

EXAMINATION. 1.6.31.

The patient's mental state is quite normal. There is a laceration in the region of his right ear but no evidence of haemorrhage from the nose or ears. There is slight headache but no sickness. Full examination of the nervous system shows no abnormality.

X-RAY EXAMINATION.

Examination was not carried out.

RE-EXAMINATION. 15.12.31.

Patient states that he re-commenced work a week after discharge. There had been no post-concussional symptoms of any sort.

GROUP A

CASE NO. 39 J. G. (male) Age 42. Ward 13.

Admitted 4.4.31. Discharged

Occupation - Soldier.

HISTORY.

The patient was admitted to Hospital for another reason, but he was suffering from the effects of a previous head injury, this was inquired into. In 1912, while riding a horse, he was thrown to the ground and while getting up was kicked on the head by the horse's hoof. He was unconscious for a moment or two but was able to walk 100 yards back to the stables. There was no bleeding from his nose or ears. On the night following he developed severe pain in the head and a large swelling developed behind the right ear. He went on duty the next day but all day the pain in the head was very severe. On the day following he felt well. 4 or 5 months after the accident he began to take fits. At first these occurred at an interval of 3 or 4 months but during the last year there has been seldom more than a month between them. He always knows when they are coming on because previous to a major attack everything that people say to him sounds as though they were singing. He also has minor fits and these begin with a feeling of deadness in the left side of the face, the left arm, the left side of his body and the left leg. The left arm and leg fall helplessly to his side for a period of 6 or 7 seconds and then recover power. These minor attacks are repeated one after the other for perhaps as long as 2 hours. His memory has been failing during the last few years but otherwise there are no apparent post-concussional disturbances.

Examination of the skull shows an obvious depression in the right occipital region.

GROUP A

CASE NO. 40 S. G. (female) Age 58. Ward 8.

Admitted 26.11.30 Discharged 1.12.30.

Occupation - House-wife.

HISTORY.

The patient is deaf in both ears but was otherwise well at the time the accident occurred. On the day of admission, while crossing the street she was knocked down by a bicyclist. She was unconscious for a few minutes but was reported to be in an excited state when admitted to hospital. There was no bleeding from the nose or ears.

EXAMINATION. 26.11.30.

There is no evidence of shock and the patient is fully conscious. There is a laceration of the right side of the skull and considerable haemorrhage has occurred from this. There is no evidence of bleeding from the nose or ears. There are no injuries to other parts except for a slight wound of the elbow. There is no headache and no vomiting. The right pupil is slightly larger than the left but examination of the nervous system otherwise shows no abnormality.

X-RAY EXAMINATION.

Examination of the skull was not carried out.

RE-EXAMINATION. 5.8.31.

Patient states that she lay in bed for 3 weeks after discharge. She began to go out on the first day of the year. She does not consider that full recovery has occurred. Her general health is quite good but her memory is considerably worse than it was. She forgets about things she has been doing and her mind often goes "blank" for a few seconds. She does not feel that she has the same grasp of her work. She has never had headaches but sometimes feels a little dizzy. She is more nervous than formerly, especially in the street. Physical examination shows no abnormality.

GROUP A

CASE NO. 41 A. H. (male) Age 43. Ward 6.

Admitted 19.2.31. Discharged 25.2.31.

Occupation - Labourer.

HISTORY.

Patient's health was quite good at the time the accident occurred. At 4 p.m. on the day of admission, while at his work, standing on a ladder, the ladder slipped and he fell to the ground. He was unconscious for a few minutes. There was bleeding from the nose but none from the ears. When admitted to hospital, half-an-hour later, he was reported to be very shocked. His pulse was thready, and the skin was cold and clammy. He was slightly dazed but was able to answer questions.

EXAMINATION. 21.2.31.

His general condition is now good and he is fully conscious. There is a bruise in the left side of the face and a ring of effusion round the left eye. There are bruises to both upper extremities but no serious injury. There was some pain in the head yesterday but there is none today. Full neurological examination shows no abnormality.

X-RAY EXAMINATION.

Examination of the skull was not carried out.

RE-EXAMINATION. 13.8.31.

Patient says that he rested for a week after leaving hospital, and re-commenced work 5 weeks after the accident. He considers that complete recovery has now occurred. The only thing he notices is that he often has a trembling feeling in the abdomen. There are no other post-concussional symptoms. There is no question of compensation out-standing. He received full pay for 3 weeks and half pay for one week, while he was off work. Physical examination shows no abnormality

GROUP A

CASE NO. 42 P. B. L. H. (male) Age 23. Ward 12.
Admitted 29.5.31. Discharged 2.6.31.
Occupation - Joiner.

HISTORY.

The patient was in good health at the time of the accident. About 9 p.m. on the day of admission, while riding his motor bicycle, he remembers that while coming round a corner, he met a cyclist on the wrong side of the road. He remembers no more till he woke up lying at the side of the road with people around him. There was no bleeding from the nose or ears.

EXAMINATION. 30.5.31.

The patient is quite conscious. He has a bruise in the left frontal region. There is no evidence of haemorrhage from the nose or ears. Apart from bruises there are no injuries to other parts of the body. There is slight frontal headache but no vomiting. The diameter of the pupils is, Right, 4.5 mms. and Left, 4mms. There is some slight fine nystagmus on looking to the left. No other abnormality was detected on full examination.

RE-EXAMINATION. 21.1.32.

The patient says that he returned to work a week after the accident occurred. There have been no post-concussional disturbances and examination shows no abnormality.

GROUP A

CASE NO. 43 W. I. (female) Age 33. Ward 11.
Admitted 26.12.30 Discharged 15.1.30.
Occupation - Housewife.

HISTORY.

At 10.5 a.m. on the day of admission, while sitting in a motor-car, the patient was involved in a collision. She was unconscious for a few seconds but was sent straight to the Infirmary, where she arrived 2½ hours later.

EXAMINATION. 27.12.30.

There is an extensive wound over the forehead from which considerable haemorrhage occurred before admission. There is evidence of previous bleeding from the nose but none from the ears. There are no injuries to other parts. The mental state is normal. There is slight headache and she has vomited blood on one occasion. Examination of the nervous system shows no abnormality.

X-RAY EXAMINATION.

Examination of the skull shows no evidence of fracture.

RE-EXAMINATION. 7.8.31.

Patient was unable to report in person but she said in a letter that complete recovery had occurred and that she now felt well.

GROUP A

CASE NO. 44 J. J. (male) Age 22. Ward 7.
Admitted 1.7.31. Discharged 8.7.31.
Occupation - Railway worker.

HISTORY.

The patient was quite well at the time of the accident. About 2 p.m. on the day of admission, while cleaning the boiler of his engine, he fell to the ground and in so doing injured his head. He remembers being on the engine but has no recollection of falling. He woke up in an office several minutes after the accident occurred and remembers clearly being brought to hospital. There was no haemorrhage from the nose or ears.

EXAMINATION. 2.7.31.

The patient is fully conscious. There is a bruise in the right frontal region but no evidence of haemorrhage from the nose or ears. There is slight pain in the region of the bruise but otherwise no headache. Neurological examination shows no abnormality.

X-RAY EXAMINATION.

Examination of the skull shows a fracture in the parieto-occipital region.

RE-EXAMINATION 8.12.31.

Patient says that he rested for 2 weeks after leaving hospital, and then returned to work. Complete recovery had then occurred and he has had no symptoms referable to his accident. Examination shows no abnormality.

GROUP A

CASE NO. 45. C. J. (female) Age 7. Ward 5.

Admitted 15.6.31. Discharged 21.6.31.

HISTORY.

The patient was in good health at the time the accident occurred. On 30.5.31., 15 days before admission, while running down-hill, she tripped and fell forward on her head. She was unconscious thereafter for nearly an hour. There was bleeding from her nose but none from her ears. She had severe headache and vomiting for 3 days after the injury, but then began again to play as usual. She was brought up to the Infirmary for examination and was found to have a palpable fracture of the left parietal region, with effusion around the right eye.

EXAMINATION. 19.6.31.

In addition to the above, patient has a subconjunctival haemorrhage on the outer side of the right eye. The mental state is now normal and there is no headache. Examination of the nervous system shows no abnormality.

X-RAY EXAMINATION.

Examination shows extensive fractures of the left parietal and the right frontal bone.

RE-EXAMINATION. 14.8.31.

The mother does not think that complete recovery has occurred. She says that "she doesn't seem to be the same child to me, she is full of mischief, she seems to have the devil in her". She used to be very quiet and good, now she is very disobedient, gets very excited and treats younger children very badly. She still suffers from severe headache and will often stop in the middle of her play to rest till the pain passes off. These headaches often last for about 15 minutes. She has become very nervous, especially of falling and of the dark. She has difficulty in falling asleep. Physical examination shows no abnormality.

GROUP A

CASE NO. 46 D. K. (male) Age 24. Ward 7.
Admitted 29.4.31. Discharged 12.5.31.
Occupation - Mental nurse.

HISTORY.

Patient was in good health at the time the accident occurred. About 2.30 p.m. on the day of admission, while riding a motor bicycle, he lost his balance and was thrown to the ground. He remembers running into a rough piece of road but remembers no more after this until he woke up about 15 minutes later. He was taken at once to the Infirmary where he was admitted half-an-hour later.

EXAMINATION. 30.4.31.

Patient is fully conscious. There is a laceration of the scalp in the right occipital region and a bruise around the left eye. There is no evidence of haemorrhage from the nose or ears. There is no headache. The patient vomited once after the anaesthetic. Examination of the nervous system shows no abnormality.

X-RAY EXAMINATION.

Examination of the skull shows no evidence of fracture.

RE-EXAMINATION. 5.8.31.

Patient says that he rested for 10 days after leaving hospital but has not completely recovered from his injury. His mind was easily confused at first but this is now improving. He has not yet started to work. There has been some dull throbbing pain over the site of the wound and if he suddenly stands up he is apt to turn dizzy. He states that the vision of the right eye was slightly impaired for a period of about 4 weeks after the accident occurred. There is no question of compensation outstanding. He is drawing 16/- a week in sickness insurance.

- GROUP A

CASE NO. 47 T. K. (male) Age 10. Ward 7.
Admitted 22.7.31. Discharged 5.8.31.
Occupation - Schoolboy.

HISTORY.

The patient was quite well before his accident occurred. About 2.30 on the day of admission while playing a game, he ran into another boy so that they struck their heads against each other. He was unconscious for several minutes but remembers coming to Hospital shortly afterwards. There was profuse bleeding from his nose but none from his ears, and he was reported to have been slightly dazed when admitted.

EXAMINATION. 23.7.31.

The patient is quite conscious. There is a bruise in the frontal region with a red-coloured effusion at the root of his nose and around the left eye. The haemorrhage from the nose had been so severe that the nose was packed. He has no headache, and there has been no vomiting. Examination of the nervous system shows no abnormality.

X-RAY EXAMINATION.

X-ray examination of the skull shows no evidence of fracture.

PROGRESS.

4.8.31. The patient feels quite well. There is no headache, but there has been some displacement of the nasal septum and he was transferred to the Ear, Nose and Throat Department for operation.

RE-EXAMINATION. 7.12.31.

The patient says that he rested for two weeks after discharge and then commenced to play as usual. There have been no post-concussional disturbances, and he feels quite well. Examination shows no abnormality.

GROUP A

CASE NO. 48 E. L. (male) Age 7. Ward 7.
Admitted 15.7.31. Discharged 22.7.31.
Occupation - Schoolboy.

HISTORY.

Patient was quite well at the time the accident occurred. About 7 p.m. on the day of admission he fell from a wall and struck his head on the ground. He was dazed for a few minutes, but there was no bleeding from his nose or ears. He was admitted to Hospital soon after.

EXAMINATION. 17.7.31.

The patient is fully conscious. There is a bruise and a large haematoma in the right temporal region. There is no sub-conjunctival haemorrhage and no evidence of haemorrhage from the nose or ears. There is no headache but he vomited once on the morning of admission. Examination shows no abnormality except that both plantar reflexes give an extensor response.

X-RAY EXAMINATION.

X-ray examination of the skull shows no evidence of fracture.

RE-EXAMINATION. 7.12.31.

There have been no symptoms since discharge and patient is quite fit.

GROUP A

CASE NO. 49 J. M'C. (male) Age 49. Ward 16.

Admitted 13.1.1. Discharged 27.1.31.

Occupation - Mason.

HISTORY.

Patient was quite well at the time the accident occurred. About 10 a.m. on the day of admission while walking along the railway line he was knocked down by an engine. He was unconscious for only a few moments and owing to the damage to his scalp was sent at once to the Infirmary.

EXAMINATION. 14.1.31.

The patient is fully conscious. A large part of the right half of the scalp has been partially avulsed and considerable haemorrhage occurred from this laceration before admission. Apart from bruises of the right arm and hip there were no serious injuries to other parts. There is no headache. The patient vomited once after the anaesthetic. Examination of nervous system shows no abnormality except that there is a slight degree of neck rigidity.

X-RAY EXAMINATION.

X-ray examination of the skull shows no evidence of fracture.

RE-EXAMINATION. 24.8.31.

After discharge from Hospital patient says that he rested in bed for two weeks and started work again about four months after the accident. He does not consider that complete recovery has occurred. His memory is good, but he often has pain in the region of the scar, which is worse in wet weather. There is no dizziness or nervousness and he sleeps well. There is no question of compensation out-standing. He received half pay while he was off work.

GROUP A

CASE NO. 50 A. M'C. (male) Age 16. Ward 10.
Admitted 5.7.31. Discharged 21.7.31.
Occupation - Farm Worker.

HISTORY.

The patient was in good health before the accident occurred. About 3 p.m. on the day of admission, while riding a motor-bicycle, he collided with a pedestrian and was thrown to the ground. He is unable to remember the details of the accident but remembers having reached the place where it occurred. He remembers no more until he woke up in a house in the neighbourhood. There was no bleeding from the nose, but there was bleeding from the right ear. He was taken immediately to the Infirmary, where he was admitted.

EXAMINATION. 7.7.31.

There is a bruise in the right temporal region. There is evidence of previous haemorrhage from the right ear. There are no injuries to other parts of the body. The mental state is normal and he has had no headache. He vomited once on the morning after admission. Examination of the nervous system shows no abnormality except that there is slight deafness in the right ear and some fine nystagmus on looking to the right.

X-RAY EXAMINATION.

X-ray examination of the skull shows a fissure fracture of the right temporal region.

PROGRESS.

17.7.31. The patient feels quite well, but there is a slight, purulent discharge from the right ear.

RE-EXAMINATION/

CASE NO. 50. (Contd.)

RE-EXAMINATION. 25.1.32.

Patient says that he lay in bed for two weeks after discharge. Then he rested at home for four weeks and returned to work. Complete recovery has not occurred. His memory is not as good as previously. He is unable to do sums and counting, which previously he could do very well. He also suffers from headaches, which are more apt to come on when he is travelling in a 'bus. Before his accident he never suffered from headache. He sometimes feels dizzy when going up a ladder. He has not become nervous and he sleeps well. The accident was due to the brakes of his bicycle breaking, so that there is no question of compensation. Examination shows no abnormality.

GROUP A

CASE NO. 51. J.M'D. A male aged 49. Ward 16.
Admitted 30.6.31. Discharged 20.7.31.
Occupation - Colliery Joiner.

HISTORY.

The patient was quite well before the accident occurred. At 3.30 p.m. on the day of admission while at work on a 20 foot ladder, a beam gave way and he was thrown to the ground. He remembers falling on to his feet and hands and he remembers that he hit his head on a beam while falling. There was no loss of consciousness. He remembers putting his hands out to try and save his face. He was able to walk to the ambulance after the accident occurred. There was bleeding from the nose, but none from the ears.

EXAMINATION. 1.7.31.

The patient is fully conscious. There is a depressed fracture of the right frontal bone, and both eyes are closed with effusion. There is evidence of previous haemorrhage from the nose and there is extensive sub-conjunctival haemorrhage around the right eye on the lateral side. With the exception of bruises, there are no injuries to other parts of the body. There is no headache, but the patient vomited once this morning. Examination of the nervous system shows no abnormality.

PROGRESS. 2.7.31.

The patient to-day feels well. The right eye has now opened, and the pupils are seen to be equal in size.

4.7.31.

The patient still feels well, but to-day the left pupil is slightly larger than the right. Visual acuity is not so good in the right eye as in the left, but patient says this has always been so. The fields of vision are quite normal.

RE-EXAMINATION.

The patient failed to report.

GROUP A

CASE NO. 52. W. M'D. A male aged 14. Ward 18.

Admitted 27.10.30. Discharged 29.10.30

HISTORY.

The patient suffers from dizzy turns. His head seems to "reel" so that he has to sit down till the turn passes off. No definite loss of consciousness occurs during these turns. Otherwise, he was in good health at the time the accident occurred. On the day of admission, while crossing the road, he was knocked down by a tram-car. His head struck the pavement and he was rendered unconscious for a few minutes. There was no bleeding from his nose or ears, and when admitted shortly afterwards to Hospital, he was reported to be quite rational.

EXAMINATION.

There is no apparent injury to the scalp and no evidence of haemorrhage from the nose or ears. The mental state is normal. There is no headache and no vomiting. Examination of the nervous system shows no abnormality.

X-RAY EXAMINATION.

Examination of the skull shows no evidence of fracture.

RE-EXAMINATION. 19.8.31.

The patient says that he remained in bed for ten days after discharge and then returned to school. He seems to have recovered completely from the injury, but still takes "turns", and has not been doing so well at school. He had a "turn" during an examination at school and proceeded to write down questions instead of answers. Otherwise he is quite well.

GROUP A

CASE NO. 53. D.M'C. A male aged 41. Ward 6.
Admitted 14.5.31. Discharged 18.5.31.
Occupation - Farm worker.

HISTORY.

The patient was in good health before the accident occurred. At 3 p.m. on the day of admission while forking hay in a cart, the horse bolted and he fell on the back of his head. He remembers the horse running away, but remembers nothing more until he woke up half an hour later. He remembers coming to hospital, where he was admitted an hour after the accident. He was able to walk to the bus after the accident, but his head was very painful and there was bleeding from his left ear and from his nose. A bystander syringed out his ear in an attempt to stop the bleeding.

EXAMINATION. 15.5.31.

His general condition is now good. The blood pressure is 120/70. There is a bruise in the occipital region and evidence of previous haemorrhage from the nose and left ear. There are no injuries to other parts. The mental state is normal. There is no headache, but yesterday he vomited frequently. There is complete anosmia on both sides and the patient says that he is unable to taste his food properly. There is also slight deafness in the left ear and Weber's test is referred to the right. There is a constant rushing noise in the left ear, which is now becoming less. There is a slight degree of neck rigidity. No other abnormality was detected on physical examination.

X-RAY EXAMINATION.

Examination of the skull was not carried out.

PROGRESS. 17.5.31.

The patient's general condition is good. He feels dizzy and sick when he moves his head. There is still slight deafness of the left ear. Air conduction is greater than bone conduction and Weber's test is referred to the right. The constant, rushing noise is still present in the left ear.

2.

CASE NO. 53. (Contd.)

RE-EXAMINATION.

The patient failed to report.

GROUP A

CASE NO. 54. T.M'G. A female aged 4. Ward 5.

Admitted 23.7.31. Discharged 29.7.31.

HISTORY.

On the day of admission the patient was knocked down in the street by a motor-car. She was unconscious for a few moments. There was bleeding from the nose but none from the ears.

EXAMINATION. 25.7.31.

The patient is a little dazed and rather restless. There is a bruise in the left temporal region and the left eye is closed with effusion. She has vomited on two or three occasions since admission. There is some neck rigidity. The left plantar reflex gives an indefinite response, but no other abnormality was found, on examination.

X-RAY EXAMINATION.

Examination of the skull shows no evidence of fracture.

RE-EXAMINATION.

The patient failed to report.

GROUP A

CASE NO. 55. J.M'G. A male aged 38. Ward 6.

Admitted 19.2.31. Discharged 3.3.31.

Occupation - Coal porter.

HISTORY.

The patient was in good health at the time the accident occurred. On the day of admission about 1 p.m., he tried to stop a horse which was out of control, with the result that he was knocked to the ground. The patient did not lose consciousness, but was slightly dazed for a few moments. He was able to get up and walk, but on the way to hospital he lost consciousness and has no recollection of being admitted. He was dazed on admission, but was able to answer questions.

EXAMINATION. 21.2.31.

The patient is quite conscious. His general condition is good. The blood pressure is 110/70. There is a bruise in the region of the left mastoid and the left side of the face. There is no evidence of haemorrhage from the nose or ears. With the exception of bruises there are no injuries to other parts. There is slight headache but no vomiting. Examination of the nervous system shows no abnormality.

X-RAY EXAMINATION.

Examination of the skull was not carried out.

RE-EXAMINATION.

The patient failed to report.

GROUP A

CASE NO. 56. M.McK. A female aged 9. Ward 8.

Admitted 28.1.31. Discharged 13.2.31.

HISTORY.

The patient was in good health at the time the accident occurred. On the day of admission while at play, she fell down the well of the stairs - a distance reported to be over 50 feet. She describes exactly how she fell and remembers all about it. She was able to speak when she was picked up though she was reported to be slightly stunned. There was bleeding from the right side of her nose but none from her ears.

EXAMINATION. 29.1.31.

Her general condition is good. There is no apparent bruising of the scalp. There is evidence of previous haemorrhage from the nose. Her pelvis was injured and was later shown by X-ray examination to be fractured, and there was some subcutaneous emphysema in the right axilla. Her mental state is normal. There is no headache or vomiting. The right pupil is 4.5 mms. in diameter and the left 3.5 mms. Otherwise examination of the nervous system shows no abnormality.

X-RAY EXAMINATION.

Examination of the skull shows no evidence of fracture.

RE-EXAMINATION. 6.8.31.

Patient went to the Convalescent Home after leaving hospital but did not rest in bed. She returned to school 2 months ago. Her mother does not consider that complete recovery has occurred. Her general health is good and her appetite is much larger than before her accident. Her memory is defective. She is very absent-minded and often forgets messages, and has lost interest in the things she does. Before the accident she was a very smart girl and was good at her school work. Now she is backward and has no interest in it. She is easily excited, readily loses control of herself and bursts into violent fits of weeping. She has become very nervous and does not sleep so well as before the injury. There is no question of compensation, and examination shows no abnormality.

GROUP A

CASE NO. 57. B.McK. A male aged 46. Ward 7.
Admitted 14.5.31. Discharged 28.7.31.
Occupation - Miner.

HISTORY.

The patient was in good health at the time the accident occurred. On the day of admission while he was working in the mine, a stone fell on his head. He remembers being struck on the head and, though slightly dazed, did not lose consciousness.

EXAMINATION. 4 Hours after admission.

His general condition is good. There is laceration in the occipital region of the scalp. There is no evidence of haemorrhage from his nose or ears. There are extensive bruises of the upper extremities. The mental state is normal. There is no headache but he has vomited on two or three occasions. Examination of the nervous system shows no abnormality.

X-RAY EXAMINATION.

Examination of the skull shows no evidence of fracture.

PROGRESS. 22.5.31.

The patient has had some cough since the operation on his scalp. There is no headache, sickness, giddiness or diplopia.

RE-EXAMINATION. 7.12.31.

The patient has not yet returned to work, mainly owing to the severe injury he received to his left hand. His memory is good but he occasionally suffers from slight headaches and also has slight dizzy turns. He has become very nervous and says he is frightened to go down the mine again. He is receiving £1.6/- weekly in compensation. Examination shows that the left pupil is larger than the right. Otherwise there is no abnormality.

GROUP A

CASE NO. 58. I.M. A male aged 11. Ward 13.

Admitted 20.7.31. Discharged 25.7.31.

HISTORY.

The patient was in good health at the time the accident occurred. At 5.30 p.m. on the day of admission, while climbing down a ladder, he slipped and fell to the ground. He was slightly dazed for a few moments but was able to walk with help. There was bleeding from his nose and from his left ear and he was sent to the Infirmary where he was admitted an hour later.

EXAMINATION. 21.7.31.

The mental state is quite normal. There is a bruise in the left temporal region and there is evidence of previous haemorrhage from the nose and left ear. There are no serious injuries to other parts of the body. There is no headache but the patient vomited blood once last night. Examination of the nervous system shows no abnormality, except that there is some fine nystagmus on looking to the right, there is a slight weakness of the left side of the face, and slight deafness in the left ear.

X-RAY EXAMINATION.

Examination of the skull shows no evidence of fracture.

RE-EXAMINATION.

The patient failed to report.

GROUP A.

CASE NO. 59. H.M. A male aged 63. Ward 16.

Admitted 22.6.31. Discharged 10.7.31.

Occupation - Plasterer.

HISTORY.

The patient was quite well previous to the accident. At 10.50 a.m. on the morning of admission, while at his work, he fell off a ladder. He remembers falling but has no recollection of striking the ground. He was unconscious for a few minutes only. There was no bleeding from the nose or ears.

EXAMINATION.

On examination 10 hours after the accident, patient is fully conscious. His breathing and pulse are normal and his blood pressure is 160/90. There is a bruise in the left frontal region. There is no evidence of haemorrhage from the nose or ears. He is also found to have a fracture of the left wrist. There is no headache or vomiting and physical examination of the nervous system elicits no abnormality.

Blood sugar examination on the day of admission:-

22.6.31.	2 p.m.	142	Milligrammes	per	cent.
	6 p.m.	154	"	"	"
23.6.31.	10 a.m.	250	"	"	"
	4 p.m.	200	"	"	"

X-RAY EXAMINATION.

Examination of the skull was not carried out.

PROGRESS. 29.6.31.

The patient says he is quite well and has no symptoms. His thoughts are quite clear but his memory has been failing during the last few years. He does not think this is worse since the accident. He was discharged to the Convalescent Home.

CASE NO 59. (contd.)

RE-EXAMINATION. 22.1.32.

The patient has not returned to work owing to the damage to his wrist. He says that his memory is not as good as previous to the accident. He forgets names and cannot remember what he has been reading about. He has become very melancholy and suffers from severe headaches which are worst at night and are present on waking in the morning. Attacks of dizziness are apt to come over him while he is walking and when these come on he has to stop and hold on to something for a few minutes. He has also become rather nervous and has had some difficulty in falling asleep. He is drawing 30/- weekly in compensation. Examination of the nervous system reveals no abnormality, but the left wrist joint is still very stiff.

GROUP A

CASE NO. 60. W.M. A male aged 37. Ward 16.

Admitted 30.6.31. Discharged 6.7.31.

Occupation - Railway carter.

HISTORY.

The patient was in good health at the time the accident occurred. He has always suffered from a squint of the left eye. At 9 a.m. on the day of admission he tripped over a wire and fell, striking his head on the ground. He was not unconscious. There was bleeding from the mouth.

EXAMINATION. 2.7.31.

The patient's general condition is good. There is an extensive bruise in the right frontal region. There is sub-conjunctival haemorrhage on the outer aspect of the right eye. There is dislocation of the elbow joint. The mental state is normal and there is no headache or vomiting. The pupils are equal and react sluggishly to light. Visual acuity in the left eye is very defective as has always been the case. There is some deafness on both sides, and he states that he has had discharge from both ears for many years. Examination otherwise shows no abnormality.

X-RAY EXAMINATION.

Examination of the skull shows no evidence of fracture.

RE-EXAMINATION. 10.12.31.

The patient states that he was off work for 15 weeks on account of the arm injury. He has now recovered completely and has had no post-concussional symptoms. Examination shows no further abnormality.

GROUP A

CASE NO. 61. J.M. A male aged 16. Ward 13.

Admitted 29.12.30. Discharged 10.1.31.

HISTORY.

The patient was in good health at the time the accident occurred. At 10 a.m. on the day of admission, while working in the mine, he was struck on the left side of the head by a hutch. He was not rendered unconscious and was able to get up and walk. There was no bleeding from the nose or ears, but when admitted to hospital 6 hours later he was reported to be very shocked.

EXAMINATION. 30.12.30.

There is now no evidence of shock. There is a palpable depressed fracture of the left temporal bone. There has been some haemorrhage from a cut near the right ear but there has been no haemorrhage from the nose or ears. There are no injuries to other parts of the body. The patient is fully conscious. There has been no headache but he vomited once after the anaesthetic. Examination of the nervous system shows no abnormality, with the possible exception of a slight weakness of the left side of the face.

X-RAY EXAMINATION.

Examination of the skull was not carried out. At operation carried out after admission, a depressed fragment of bone was removed. The dura mater was not damaged.

RE-EXAMINATION. 23.7.31.

The patient rested in bed for a month but has not returned to work. His memory is good but he occasionally has slight headache. He does not feel fit and says that he is frightened to go back to the same work. The compensation question is not yet settled. On examination the decompression area is very tender to touch.

GROUP A

CASE NO. 62. G.N. A male aged 22. Ward 13.

Admitted 2.3.31. Discharged 9.3.31.

HISTORY.

The patient was in good health at the time the accident occurred. At 7.40 a.m. on the day of admission, while walking along the railway line, he was struck on the head by a log of wood which had been thrown out of a passing train. He was unconscious for a few minutes and was brought to hospital, where he was admitted an hour later.

EXAMINATION. 2.3.31. At 3 p.m.

The patient's general condition is good. There is a cut above the right eye from which there has been some haemorrhage. There is a little blood in the left ear but it is doubtful whether this has come from within the skull. There are no injuries to other parts of the body. The mental state is normal. There has been slight headache across the forehead but no vomiting. He feels dizzy when he moves his head. Examination of the nervous system shows no abnormality.

X-RAY EXAMINATION.

Examination of the skull shows no fracture.

PROGRESS. 3.3.31.

Apart from a slight soreness across the forehead, patient now feels well.

RE-EXAMINATION. 22.7.31.

The patient remained in bed for 3 weeks after leaving hospital and suffered from severe headaches throughout that period. He started to work 10 weeks ago, but stopped after a week owing to severe headache. Whenever he laid his head on the pillow it seemed as though there was a hammer beating in his head continuously. The pain /

CASE NO. 62. (Contd.)

pain in the head was also present on waking in the mornings. He started work again 2 days ago and the headache has not been so troublesome as he has had less stooping to do. He has become nervous and is afraid of the trains. He sleeps well except that the headache is sometimes so severe that he has difficulty in falling asleep. The compensation question has only just been settled. Examination shows no abnormality.

GROUP A

CASE NO. 63. J.O. A male aged 5. Ward 13.

Admitted 27.7.31. Discharged 30.7.31.

HISTORY.

The patient was in good health at the time the accident occurred. On the day of admission he fell downstairs, struck his head and was unconscious for a few minutes. There was bleeding from the nose but none from the ears. He was brought at once to the Infirmary where he was found to be slightly shocked, but fully conscious.

EXAMINATION. 28.7.31.

The patient's general condition is now good. There is a bruise in the left frontal region. There are no injuries to other parts of the body. The mental state is normal and there is no complaint of headache. There is an internal strabismus of the left eye which has been present since the child was a year old. There is a slight degree of neck rigidity but no other abnormality was detected on examination.

X-RAY EXAMINATION.

Examination of the skull shows no evidence of fracture.

RE-EXAMINATION. 24.1.31.

Complete recovery has now occurred and there have been no post-concussional symptoms.

GROUP A

CASE NO. 64. G.P. A female aged 11. Ward 5.

Admitted 18.6.31. Discharged 21.6.31.

HISTORY.

The patient was in good health at the time the accident occurred. At 9.30 a.m. on the day of admission, while she was riding her bicycle, a motor-car ran into her back wheel and she was thrown to the ground. She was dazed for a few moments but was able to get up and walk almost immediately. She remembers being bumped into by the car but does not remember falling. She was brought at once to the Infirmary, where she was admitted half-an-hour later.

EXAMINATION.

The general condition is good. There is a bruise in the occipital region but no evidence of haemorrhage in the nose or ears. There are no injuries to other parts of the body. The patient is fully conscious. There is no headache, giddiness or vomiting. Examination of the nervous system shows no abnormality except that there are some slight choreic-like movements of the hands. Examination of the heart shows a doubtful first sound in the Mitral area and reduplication of the second sound at the base.

X-RAY EXAMINATION.

Examination of the skull shows no evidence of fracture.

RE-EXAMINATION. 10.10.31.

The patient did not rest after returning home and there have been no symptoms of any sort since discharge.

GROUP A

CASE NO. 65. MRS.H.R. A female aged 33. Ward 14.
Admitted 17.8.31. Discharged 22.8.31.
Occupation - Housewife.

HISTORY.

The patient was rather deaf previous to the accident and had been operated on for mastoiditis on the left side. Otherwise she was in good health. At 11 a.m. on the day of admission, while stepping off the pavement, she was knocked down by a motor-car. She remembers being hit in the back but has no recollection of falling. On falling, her head struck the ground and she was rendered unconscious for a few minutes.

EXAMINATION. 4 hours after admission.

The general condition is good and there is no marked shock. There is a bruise in the left frontal region but no evidence of haemorrhage from the nose or ears. There are bruises in other parts of the body but no serious injury. There is slight headache but no sickness. Examination of the nervous system shows no abnormality.

X-RAY EXAMINATION.

Examination of the skull shows no evidence of fracture.

RE-EXAMINATION.

The patient was unable to report at hospital as she has been confined to bed since she left the Infirmary. The reason for this cannot be ascertained.

GROUP A

CASE NO. 66. G.R. A male aged 23. Ward 16.
Admitted 14.7.31. Discharged 20.7.31.
Occupation - Paper worker.

HISTORY.

The patient was in good health at the time the accident occurred. About 2 p.m. on the day of admission, while riding pillion on a motor-bicycle, he was involved in a collision and was thrown to the ground. He remembers being within half a mile of where the accident occurred but has no further recollection of events until he woke up sitting at the side of the road after the accident. He had evidently been unconscious for a few minutes. There was no bleeding from the nose or ears.

EXAMINATION. 19.7.31.

The general condition is good. There is an extensive bruise over the right side of the face but no evidence of haemorrhage in the nose or ears. The mental state is normal, there is no headache and there has been no vomiting. Examination of the nervous system shows no abnormality.

X-RAY EXAMINATION.

Examination of the skull shows no evidence of fracture.

RE-EXAMINATION. 9.12.31.

The patient states that he was off work for 3 weeks after discharge from hospital but that complete recovery had then occurred. There had been no post-concussional symptoms.

CASE NO. 67. L.R. A female aged 66. Ward 5.

Admitted 5.2.31. Discharged 11.2.31.

Occupation - Housewife.

HISTORY.

On the day of admission, the patient was knocked down in the street by a tram-car. She had no subsequent recollection of how the accident occurred, but on admission, soon after the accident, she was quite rational. She had evidently been unconscious for a few minutes.

EXAMINATION. 6.2.31.

The general condition is good. The blood pressure is 170/95. There is a laceration of the scalp in the occipital and parietal regions, but there is no evidence of haemorrhage in the nose or ears. There is also laceration of the right hand. The mental state is normal and there is no headache. She vomited once after the anaesthetic. Examination of the nervous system shows no abnormality.

RE-EXAMINATION.

The patient failed to report.

GROUP A

CASE NO. 68. MRS.H.S. A female aged 73. Ward 14.
Admitted 12.1.31. Discharged 15.1.31.

HISTORY.

Apart from some neuritis in both arms and legs, patient was in good health at the time the accident occurred. On the day of admission, while stepping off a tramcar, she was knocked down by passing traffic. She was unconscious for a few minutes but recovered consciousness on the way to the Infirmary.

EXAMINATION. 13.1.31.

The general condition is now good. There is a bruise over the left side of the head in the parieto-occipital region. There is no evidence of haemorrhage and there are no injuries to other parts of the body. The mental state is normal. There is some headache and the patient has vomited on two occasions. Physical examination shows no abnormality.

X-RAY EXAMINATION.

Examination of the skull shows no evidence of fracture.

RE-EXAMINATION. 23.7.31.

The patient states that she lay in bed for 5 weeks after discharge and then gradually got up. She has felt very weak since her accident. She now remembers all events to within a few seconds of the time at which the accident occurred. There is no headache or loss of memory but she is apt to become dizzy after she has been on her feet for long. She has become very nervous and her sleep is much disturbed by a marked degree of polyuria. She has been very thirsty since her accident and has gradually been passing larger and larger quantities of urine both during the day and during the night. Examination of the urine shows pale urine of low specific gravity and it contains no abnormal constituent.

GROUP A

CASE NO. 69. D.S. A male aged 18. Ward 13.

Admitted 9.3.31. Discharged 13.3.31.

Occupation - Painter.

HISTORY.

The patient was in good health at the time of the accident but he has always been a very reckless person and has been involved in two or three accidents. At 8 p.m. on the day of admission, while sledging in King's Park, he was thrown off his sledge and injured his head. He was unconscious for about half-an-hour. The patient remembers something going wrong with the sledge but thereafter has no recollection of events until he recovered consciousness in the ambulance. There was bleeding from the nose but none from the ears. He was reported to be very shocked on admission and there was found to be tenderness over his right kidney.

EXAMINATION. 10.3.31.

The general condition is now good. The blood pressure is 120/70. There is a bruise in the frontal region and evidence of previous haemorrhage from the nose. There is also bruising in the region of the right kidney, with accompanying haematuria. There is a slight frontal headache but no vomiting. Examination of the nervous system shows no abnormality.

X-RAY EXAMINATION.

Examination of the skull shows no evidence of fracture.

RE-EXAMINATION. 23.7.31.

The patient says that he lay in bed for a week after the accident. He rested for another week thereafter, and then returned to work. He now feels very fit, but still has occasional headaches. These come on once every 2 or 3 weeks and usually last for about half-an-hour. They are throbbing in nature and make him feel sick. They usually come on at night, either after his work or after his evening meal.

GROUP A.

CASE NO. 70. J.S. A male aged 14. Ward 18.

Admitted 6.12.30. Discharged 19.12.30.

Occupation - Message-boy.

HISTORY.

The patient was in good health at the time the accident occurred. On the morning of the day of admission, while riding on his bicycle, a passing motor-bicycle hit his handlebars and threw him to the ground. He remembers the collision but has no recollection of falling and did not wake up until on the way to the Infirmary several minutes later. There was bleeding from the nose but none from the ears.

EXAMINATION. Evening of admission.

The general condition is good. The blood pressure is 115/75. There is a bruise over the left side of the forehead and the left eye is closed with oedema. There is evidence of previous haemorrhage from the nose but none from the ears. There are no injuries to other parts of the body. The mental state is normal. There is no headache and there has been no vomiting although he feels sick. Examination of the nervous system shows no abnormality.

X-RAY EXAMINATION.

Examination of the skull shows no evidence of fracture.

RE-EXAMINATION. 20.8.31.

The patient did not rest at home after leaving Hospital, and returned to work three weeks after the accident. He now feels well but still sometimes suffers from headaches. They are becoming less severe but are still apt to come on when he wakes in the morning and on one occasion he has had to go to bed for a day as the pain had been severe. Two weeks ago, during an attack of pain, he felt sick and dizzy. The mother says that he looks dazed sometimes when the headaches are severe. There is no change in behaviour and there is no nervousness or difficulty in sleeping. Examination of the nervous system shows no abnormality.

GROUP A

CASE NO. 71. W.S. A male aged 22. Ward 18.

Admitted 25.4.31. Discharged

Occupation - Traveller.

HISTORY.

The patient's health was good at the time the accident occurred. At 6.30 p.m. on the day of admission, while driving a car, the car overturned and he was rendered unconscious for a few moments. When he recovered consciousness he was able to walk, but his scalp was bleeding profusely. He remembers the car skidding and does not think he was unconscious for more than a moment if at all.

EXAMINATION. 27.4.31.

The general condition is good. There is a laceration of the scalp but no evidence of haemorrhage from the nose or ears. The mental state is normal. There is no headache or vomiting and examination of the nervous system shows no abnormality.

X-RAY EXAMINATION.

Examination of the skull shows no evidence of fracture.

RE-EXAMINATION. 20.8.31.

The patient states that he started work again, two weeks after discharge. Complete recovery has occurred and there have been no post-concussional symptoms.

GROUP A

CASE NO. 72. G.S. A male aged 19. Ward 16.

Admitted 31.3.31. Discharged

Occupation - Colour etcher.

HISTORY.

The patient was in good health at the time the accident occurred. At 1.45 p.m. on the day of admission, while riding his motor-bicycle he was involved in a collision with a motor-car. He remembers being within a quarter of a mile of the accident but thereafter has no recollection of events until he woke up in the ambulance on the way to the Infirmary. There was no bleeding from his nose. There was bleeding in the right ear but this was probably from the wound in the scalp.

EXAMINATION. 1.4.31.

The general condition is good. There is a bruise and a cut above the right eye. The right eye is closed with a bright red effusion. There is subconjunctival haemorrhage on the outer side of the left eye. The mental state is normal. There is no headache or vomiting. The diameter of the pupils is, right 3 mms., left 3.5 mms. They react normally but there is marked hippus on both sides, otherwise examination shows no abnormality.

PROGRESS. 2.4.31.

The patient remembered being on his bicycle and seeing something swerving in front of him. After that he has no recollection of events until he woke up in the ambulance.

RE-EXAMINATION. 10.12.31.

The patient states that he remained in bed for two weeks after the accident and returned to work a week later. Complete recovery had then occurred and there had been no post-concussional symptoms of any sort.

GROUP A

CASE NO. 73. A.S. A male aged 21. Ward 13.

Admitted 29.12.31. Discharged 11.1.31.

Occupation - Farm worker.

HISTORY.

The patient was in good health at the time the accident occurred. On the day of admission while riding his motor-bicycle when the light was beginning to fail, he collided with two men in the road. He remembers applying his brakes violently and skidding, but has no further recollection of events until he woke up a minute or two later sitting at the side of the road. There was haemorrhage from his nose but none from his ears.

EXAMINATION. 30.12.30.

There is a severe laceration in the occipital region of the scalp and a bruise around the right eye. There is evidence of previous haemorrhage from the nose, but none from the ears. There are no injuries to other parts of the body. The mental state is normal. There is no headache but he has vomited on one occasion. Examination of the nervous system shows no abnormality.

X-RAY EXAMINATION.

Examination of the skull shows a linear crack in the lower half of the occipital bone involving the foramen magnum.

RE-EXAMINATION. 23.7.31.

The patient states that he rested in bed for five weeks but felt quite well throughout this time. There have been no post-concussional symptoms of any sort and he has been working regularly and feels quite well.

GROUP A

CASE NO. 74. J.T. A male aged 31. Ward 7.

Admitted 13.5.31. Discharged 25.5.31.

Occupation -

HISTORY.

The patient was in good health at the time the accident occurred. At 7.30 p.m. on the day of admission, while riding his motor-bicycle, he remembers something hitting his eye. He lifted his hand from the handlebars and felt himself losing control. He has no further recollection of events until he woke up about 10 minutes later. There was no bleeding from the nose or ears.

EXAMINATION. 15.5.31.

The general condition is good and the patient is fully conscious. There is a cut in the left frontal region and slight effusion in the periorbital tissues. There is no evidence of haemorrhage from the nose or ears but there is a small subconjunctival haemorrhage on the outer side of the left eye. There is no headache but he has vomited once since admission. Examination of the nervous system shows no abnormality.

X-RAY EXAMINATION.

Examination of the skull shows a depressed fracture of the left temporal bone.

PROGRESS. 22.5.31.

The patient now feels well. There is no headache, sickness, diplopia or giddiness.

RE-EXAMINATION. 8.12.31.

The patient rested in bed for three weeks after returning home. He returned to work two weeks later. There have been no post-concussional symptoms of any sort since discharge.

GROUP A

CASE NO. 75. M.T. A female aged 60. Ward 17.

Admitted 3.1.31. Discharged 15.1.31.

HISTORY.

The patient was in good health at the time the accident occurred. On the evening of admission, while leaving a friend's house, she fainted and fell downstairs. She attributes her fainting to the fact that she had just listened to the news of a railway accident which had upset her very much. She was unconscious for a few minutes. There was no bleeding from the nose or ears.

EXAMINATION. 4.1.31.

The general condition is good. There is a small lacerated wound in the right temporal region, where there is a large haematoma. There is no bleeding from the nose or ears. There are no injuries to other parts of the body. The mental state is normal. There is slight headache but no vomiting. Examination of the nervous system shows no abnormality.

X-RAY EXAMINATION.

Examination of the skull shows no evidence of fracture.

PROGRESS. 6.1.31.

To-day the patient feels quite well and there is no headache or giddiness.

RE-EXAMINATION. 18.8.31.

The patient states that she lay in bed for three weeks after the accident occurred. Her memory has not been good since the accident - she is unable to remember names and cannot remember what she has been doing. She also gets confused with money matters. With the digit retention test, she fails at five digits, succeeds with four. She still suffers from occasional severe headaches but these were also present before the accident. She is not nervous and has no difficulty in falling asleep. There are no other post-concussional disturbances. Examination shows no abnormality.

GROUP A

CASE NO. 76. M.W. A male aged 21. Ward 7.

Admitted 21.5.31. Discharged 25.5.31.

Occupation - Motor engineer.

HISTORY.

The patient was quite well at the time the accident occurred. At 6 a.m. on the day of admission, while on his motor-bicycle, he was knocked down by a motor van. He was unconscious for a few moments but there was no bleeding from the nose or ears.

EXAMINATION. 22.5.31.

The general condition is now good. There is a small cut in the right frontal region, but no evidence of previous haemorrhage from the nose or ears. Apart from a cut on one of the fingers, there are no injuries to other parts of the body. The mental state is normal. There is no headache and no vomiting. Examination of the nervous system shows no abnormality.

X-RAY EXAMINATION.

Examination of the skull shows no evidence of fracture.

RE-EXAMINATION. 8.12.31.

The patient says that 3 weeks after the accident he began to work again. He now feels well, except that he suffers from occasional headaches, which are specially liable to come on after he has been doing a lot of work. His eyes also tire in artificial light, but this is partly due, he thinks, to the fumes in the garage in which he works. There is no question of compensation outstanding. He received £15.

GROUP A

CASE NO. 77. J.W. A male aged 22. Ward 13.

Admitted 12.1.31. Discharged 19.1.31.

Occupation - Oil-worker.

HISTORY.

The patient was in good health at the time the accident occurred. At 11 a.m. on the day of admission, while descending a gangway at his work, he slipped and fell a distance of about 30 feet. He was unconscious for a few moments but was able to get up and walk shortly after the accident.

EXAMINATION. 13.1.31.

The general condition is good. The blood pressure is 120/60. There is some oedema of the eyelids on both sides, and a bruise in the frontal region. There is evidence of previous haemorrhage from the nose, but none from the ears. There is sub-conjunctival haemorrhage on the right side. Apart from bruising, there are no injuries to other parts of the body. The patient is fully conscious. He is suffering from throbbing frontal headache of considerable severity. He vomited on one occasion before admission. The right pupil is 3.5 millimetres in diameter, the left 4 millimetres in diameter. Examination of the nervous system shows no other abnormality.

X-RAY EXAMINATION.

Examination of the skull shows no evidence of fracture.

PROGRESS. 16.1.31.

The patient's head now feels clear but he had a slight headache when he wakened this morning. He remembers going up the scaffold and doing a piece of work for three or four minutes, but remembers nothing more of what happened. He understands that it was while coming down from the scaffold that he slipped and fell.

RE-EXAMINATION /

2.

CASE NO. 77. (Contd.)

RE-EXAMINATION. 3.8.31.

The patient states that he stayed in bed for 2 weeks after returning home. He has now been working for 4 months and has done so without difficulty. He occasionally has a slight headache but otherwise there have been no post-concussional disturbances. He received 30/- weekly during the period that he was off work.

GROUP A

CASE NO. 78. D.W. A male aged 18. Ward 7.

Admitted 17.12.30. Discharged 26.12.30.

Occupation - Apprentice painter.

HISTORY.

The patient was in good health at the time the accident occurred. On the day of admission, while cycling, he skidded on the tram lines and was thrown to the ground. He was unconscious for about ten minutes. There was bleeding from the nose but none from the ears.

EXAMINATION. 18.12.30.

The general condition is good. The blood pressure is 130/70 mm. There is a bruise of the right frontal region but no evidence of haemorrhage. There are no injuries to other parts of the body. He is now fully conscious. There is no headache or vomiting. The right pupil is 3 millimetres in diameter, the left 4.5 millimetres in diameter. Examination of the nervous system shows otherwise, no abnormality.

X-RAY EXAMINATION.

Examination of the skull shows no evidence of fracture.

PROGRESS. 20.12.30.

The patient now feels well. He remembers skidding while on his bicycle but does not remember how he fell. The pupils are now equal, both being 4 millimetres in diameter. There is a small sub-conjunctival haemorrhage on the outer side of the right eye. The blood pressure today is 140/85. No abnormality was detected on physical examination.

RE-EXAMINATION. 5.3.31.

The patient states that he started work 4 days after returning home. Complete recovery has occurred. There have been no post-concussional disturbances.

GROUP A

CASE NO. 79. G.W. A male aged 27. Ward 18.
Admitted 29.11.30. Discharged 14.12.30
Occupation - Shepherd.

HISTORY.

The patient was suffering from a septic finger at the time the accident occurred. Otherwise he was in good health. On the day of admission, while alighting from a bus, he slipped and was thrown to the ground. He remembers beginning to get out of the bus but remembers no more. He was unconscious for a few minutes. There was bleeding from the left ear but none from the nose.

EXAMINATION. 30.11.30.

The general condition is good. The blood pressure is 150/75. There is a bruise over the left side of the head and there is haemorrhage from the left ear. There are no injuries to other parts of the body. The patient is still very slightly dazed. He has frontal throbbing headache and has been sick on one occasion. The diameter of the pupils is - right, 4 millimetres, left, 4.5 millimetres. Examination of the nervous system shows otherwise no abnormality.

X-RAY EXAMINATION.

Examination of the skull shows a basal fracture in the temporo-sphenoidal region.

PROGRESS. 1.12.30.

The left pupil is still slightly larger than the right. The patient is fully conscious but there is still bleeding from the left ear. The blood pressure to-day is 148/85.

EXAMINATION OF THE CEREBRO-SPINAL FLUID. 4.12.30.

Initial pressure-----270 mm. of Water
Pressure after removing 5 ccs.-----220 mm.
The fluid is clear and colourless and no clot forms on standing.
Cell count. /

CASE NO. 79. (Contd.)

Cell count.

Red blood cells-----345 per c.mm.
White cells-----None.
Total protein estimation: 25 mgms. per
100 c.cs.

Blood pressure taken both before and after
the examination, was 130/70.

5.12.30.

To-day the patient feels well. The pupils
are equal and react normally. There is a
slight weakness of the left side of the face
and slight deafness in the left ear, with some
purulent discharge. Examination of the nervous
system shows otherwise no abnormality.

8.12.30.

There is "ticking" in the left ear and
slight left facial weakness, and there is still
some discharge from the left ear.

RE-EXAMINATION. 19.8.31.

The patient states that he lay in bed for
a week after leaving hospital and returned to
work a week later. For 6 weeks after returning
home he was unable to taste things properly.
Complete recovery has now occurred, but when
he first left hospital he suffered from severe
headaches, especially after exerting himself.
The discharge from the left ear ceased after
3 weeks and there is now no deafness. There
are no other post-concussional disturbances.

GROUP A.

CASE NO. 80. R.Y. A male aged 41. Ward 13.
Admitted 6.4.31. Discharged 21.4.31.
Occupation - Miner.

HISTORY.

The patient was in good health at the time the accident occurred. On the day of admission while working in the mine, he was struck by a fall of stone from the roof, which injured his head. He did not lose consciousness, but was unable to get up owing to injuries to his leg. There was bleeding from his nose, and from wounds in the scalp, but none from his ears.

EXAMINATION. 7 hours after admission.

The general condition is fair. The pulse rate is 128 per minute and temperature 101.6°. The blood pressure is 124/90. There is a laceration of the scalp in the occipital region and an effusion round both eyes, more marked on the right. There is sub-conjunctival haemorrhage on the right side. Apart from bruises to the right arm and leg, there are no injuries to other parts of the body. The patient is fully conscious and has no headache. He vomited once after the anaesthetic. Examination of the nervous system shows no abnormality.

X-RAY EXAMINATION.

Examination of the skull shows no evidence of fracture.

PROGRESS. 8.4.31.

The patient can remember all the details of the accident. Full examination shows no abnormality.

21.4.31.

The patient now feels well. The wound in the scalp is slightly septic.

RE-EXAMINATION /

CASE NO. 80. (Contd.)

RE-EXAMINATION. 22.7.31.

The patient states that he felt well on discharge and did not rest in bed. He has suffered from severe headaches which are worse during the night when he tries to sleep. He has not returned to work on account of these, and he becomes very frightened when he goes near any steam. The headache is not throbbing in nature but is a constant heaviness - it is never sharp. He occasionally suffers from slight dizzy turns, during which he stops what he is doing and sits down. He does not think he has become nervous but he is unable to sleep at night owing to the headaches. He can sleep better in the afternoons. The wound in the scalp has not yet healed and there was some discharge from it last week. There are occasional sharp pains in the wound. He is receiving 30/- a week in compensation.

GROUP B

CASE NO. 81. J.A. A male aged 48. Ward 12.
Admitted 5.12.30. Discharged 16.1.31.
Occupation - Miner.

HISTORY.

The patient's health was good at the time the accident occurred. At 3.15 p.m. on the day of admission, while riding his motor-bicycle, he was involved in a collision at cross-roads. He was rendered unconscious, and there was bleeding from his nose and from his right ear. At 8.20 p.m. his doctor reported that he was in a very excited state, and that his pulse was rapid and thin. On admission the same evening he was still very excited and his temperature was 100.4°.

EXAMINATION. 6.12.30.

The general condition is good. The pulse rate is 110, and the temperature 99.0°. There is a bruise above the left eye and evidence of previous haemorrhage from the right ear. There is a sub-conjunctival haemorrhage on the outer side of the left eye. There is a dislocation of the left shoulder and a fracture of the scapula. The mental state is normal. There is no headache and no vomiting. The diameter of the pupils is - right 5.5 millimetres, left 6 millimetres. There is paralysis of the right side of the face and slight deafness of the right ear. Physical examination shows otherwise no evidence of abnormality.

PROGRESS. 12.12.30.

The patient remembers going round a bend in the road and meeting a motor-car but has no further recollection of events, until he recovered consciousness on the night of admission. Visual acuity is very poor in the right eye owing to lens opacities. The right pupil is to-day slightly larger than the left. There is still a complete right facial paralysis and slight deafness on that side. There is no diplopia nor giddiness, and physical examination shows no further abnormality.

RE-EXAMINATION. /

CASE NO. 81. (Contd.)

RE-EXAMINATION. 29.7.31.

The patient says he has been quite well since discharge. He returned to work 6 weeks after leaving hospital and the facial paralysis gradually recovered. Though his work involves great physical effort, he has had no post-concussional symptoms of any sort. There is now very slight deafness on the right side, no discharge from the ear, and no weakness of the right side of the face.

GROUP B

CASE NO. 82. G.A. A male aged 19. Ward 10.
Admitted 12.9.31. Discharged 18.9.31.
Occupation - Builder.

HISTORY.

On the day of admission, while riding his motor-bicycle, he collided with a house. He was unconscious for about an hour, but was able to walk and speak shortly after the accident. There was bleeding from the left ear but none from the nose.

EXAMINATION.

On admission, soon after the accident, the pulse rate is 76, respirations 22, temperature 97.6°. There is a bruise in the left parietal region and haemorrhage from the left ear. There are no injuries to other parts of the body. The patient is still dazed. There is no headache. He vomited once after admission. Examination of the nervous system shows no abnormality.

X-RAY EXAMINATION.

Examination of the skull showed a vertical fracture through the left temporal bone.

RE-EXAMINATION.

The patient failed to report.

GROUP B

CASE NO. 83. MRS.M.B. A female aged 57. Ward 14.
Admitted 12.1.31. Discharged 17.1.31.
Occupation - Housewife.

HISTORY.

The patient was in fair health at the time the accident occurred. On the day of admission, while alighting from a bus, she fell heavily and struck her head on the pavement. She was unconscious for an hour or two, and on admission to hospital shortly after, she was found to be slightly shocked. The pulse rate was 100 and the temperature 96.8° .

EXAMINATION. 13.1.31.

The general condition is now good. There is a bruise and haematoma over the occipital protuberance. There is no evidence of haemorrhage from the nose or ears. There are no injuries to other parts of the body. The patient is now fully conscious. There is a moderate degree of headache. The patient has vomited frequently since admission. Examination of the nervous system shows no abnormality except that both plantar reflexes give an extensor response and there is a moderate degree of neck rigidity.

X-RAY EXAMINATION.

Examination of the skull shows no evidence of fracture.

PROGRESS. 14.1.31.

The patient to-day feels better. She remembers being in the motor bus but has no recollection of getting up to leave the bus and did not recover consciousness until after admission to the Infirmary.

RE-EXAMINATION. 22.7.31.

The patient states that she lay in bed for two months at home after discharge, and during this /

CASE NO. 83. (Contd.)

this time felt very weak. Her general health is not so good. Her memory is not impaired but she suffers from occasional slight headaches and has dizzy turns when she looks up or holds her head back. She does not have difficulty in falling asleep - indeed, she sleeps more than usual - but her head often feels heavy. She now remembers stepping on to the foot-board in order to leave the bus. Examination shows no abnormality.

GROUP B.

CASE NO. 84. J.B. A female aged 20. Ward 11.

Admitted 10.6.31. Discharged 15.4.31.

Occupation - Shop assistant.

HISTORY.

The patient was in good health at the time the accident occurred. On the day of admission, while attempting to mount a tram, she slipped and fell. She was rendered unconscious and brought at once to the Infirmary, where she was found to be in a very excited and confused state. Soon after admission to the ward she recovered full consciousness.

EXAMINATION. 11.4.31.

The general condition is good. There is a slight bruise in the left parietal region but no evidence of previous haemorrhage from the nose or ears. The patient is now fully conscious. There is no headache but she feels giddy when she turns her head quickly. The diameter of the pupils is - Right, 3.2 millimetres: Left, 3.0 millimetres. Both pupils react normally but there is slight nystagmus on looking laterally. Examination of the nervous system shows otherwise no abnormality.

X-RAY EXAMINATION.

Examination of the skull shows a depressed fracture in the parietal region.

RE-EXAMINATION. 30.7.31.

The patient states that she remained in bed for two weeks after returning home and recommenced work two weeks later. Complete recovery has occurred and there have been no post-concussional disturbances.

GROUP B

CASE NO. 85. F.B. A male aged 63. Ward 16.

Admitted 5.5.31. Discharged 12.5.31.

HISTORY.

The patient's health was good at the time the accident occurred. On the day of admission, while holding down the head of a fallen horse, he was hit in the face by the horse and thrown to the ground. He was rendered unconscious, was brought to the Infirmary, and did not recover consciousness until after admission. He remembered being struck in the face by the horse but has no further recollection of events until he woke up in hospital.

EXAMINATION. 7.5.31.

The general condition is now good. There is a bruise in the occipital and left parietal region. There is also some bruising of the face. There is no evidence of haemorrhage from the nose or ears. The patient is now fully conscious. There is a moderate degree of pain over the top of the head. There is no vomiting. The right pupil is slightly larger than the left but examination of the nervous system shows no other abnormality.

X-RAY EXAMINATION.

Examination of the skull shows no evidence of fracture.

RE-EXAMINATION. 10.12.31.

The patient states that he went to a Convalescent Home after leaving hospital, and then returned to his own house where he has no one to look after him. His general condition since the accident has been poor. His memory has been very bad - he forgets everything unless it is written down. He suffers from very severe headaches which, if anything, are becoming worse, and they have been almost continuous for the last 3 weeks. They are particularly severe on stooping, /

CASE NO. 85. (Contd.)

stooping, when "everything seems to go black". He often takes dizzy turns and has fallen on two or three occasions in the street when these have come on. He has also fallen downstairs on two or three occasions owing to these turns. He is frightened to go out of the house and turns dizzy when he looks out of the window. There is no question of compensation outstanding. The patient had a severe spasm of headache while speaking. While it lasted he looked blank, and after recovering he had no recollection of what he had said. Physical examination shows no abnormality.

GROUP B

CASE NO. 86. J.B. A male aged 21. Ward 7.

Admitted 27.5.31. Discharged 6.6.31.

Occupation - Miner.

HISTORY.

The patient was in good health at the time the accident occurred. About 5 p.m. on the day of admission, while riding his bicycle, he was knocked down by a car. He remembers being on the spot at which the accident occurred but has no recollection of how it happened. He was rendered unconscious and was brought to the Infirmary. He soon recovered his senses.

EXAMINATION. 28.5.31.

The general condition is good. There is no apparent bruise on the skull. There is no evidence of previous haemorrhage from the nose or ears. There are no injuries to other parts of the body, except that the right ankle has been twisted. The patient is fully conscious. There is a moderate degree of headache referred to the frontal region, and there is dizziness when he moves his head. There is no vomiting. Examination of the nervous system shows no abnormality.

X-RAY EXAMINATION.

Examination of the skull was not carried out.

PROGRESS. 30.5.31.

To-day there is less dizziness but still some headache. A tendency to over-action of the face suggests that his symptoms are being exaggerated.

RE-EXAMINATION. 8.12.31.

The patient states that he lay in bed for two weeks after discharge and started work five months after the accident. Complete recovery, he says, has not yet occurred. He had severe headaches /

CASE NO. 86. (Contd.)

headaches at first, which are now gradually improving. These are always most severe in the morning when he wakens but are also severe on stooping. He had some dizzy turns at first, especially when he stood up after bending down. These have now passed off. He had difficulty in falling asleep for two weeks after the accident. He has not obtained compensation but is very hopeful of so doing. Examination shows no abnormality.

GROUP B

CASE NO. 87. W.B. A male aged 42. Ward 13.
Admitted 15.12.30. Discharged 22.12.30.
Occupation - Ploughman.

HISTORY.

The patient's health was good at the time the accident occurred. In the morning of admission, while riding a horse the patient was involved in a collision with a tram-car and was thrown to the ground. He was rendered unconscious and there was bleeding from the nose though none from the ears. He has no recollection of coming into hospital but he woke up a few hours after admission.

EXAMINATION. 9 p.m. on day of admission.

The general condition is good. The blood pressure is 115/70. There is a bruise in the right frontal region. There is haemorrhage from the nose but none from the ears. There is a sub-conjunctival haemorrhage on the outer side of the right eye. There are no injuries to other parts of the body. The patient is slightly dazed and rather restless. There is a moderate degree of headache over the right side of the head and he has vomited on several occasions. The right pupil is 3.5 mms. in diameter. The left pupil is irregular in outline but both react normally. Both plantar reflexes give an extensor response but no other abnormality was detected on physical examination.

EXAMINATION OF THE CEREBRO-SPINAL FLUID. 18.12.30.

Initial pressure-----180 mm of water.
Pressure after removing 5 ccs.140 " " "
The fluid is clear and colourless and no clot forms on standing. The red blood cell count was 280 per c.mm. There are no white cells seen. Total protein estimation is 30 mgms. per 100 c.c.s.

X-RAY EXAMINATION.

Examination shows multiple fractures of the frontal bone extending into the frontal sinus.

CASE NO. 87. (Contd.)

PROGRESS. 21.12.30.

The patient is still having some headache, otherwise he feels well. The left pupil is still slightly larger than the right. There is no double vision nor giddiness. There is no neck rigidity and examination shows no further abnormality.

RE-EXAMINATION. 24.7.31.

The patient states that he was still suffering from headache when discharged. He remained in bed for six weeks and continued to have headache throughout that time. He felt a little better when he got up. He began work on the 14th of April and at first he suffered from severe pains in the head especially when he was obliged to stoop at his work. He remembers the events leading up to the accident and he remembers trying to avoid the collision. He has no recollection of the actual fall. He still suffers from headaches and these are worst when he wakes in the morning but pass off after he gets up. They are gradually becoming less severe. There is no dizziness, nervousness nor difficulty in sleeping. There is no question of compensation outstanding. Examination shows a depression in the right frontal region. There is no other abnormality.

GROUP B.

CASE NO. 88. M.B. (male). Age 68. Ward 18.

Admitted 11.4.31. Discharged 21.4.31.

Occupation - Grocer.

HISTORY.

The patient states that six years ago he had a severe head injury caused by his being knocked off his bicycle by a motor-car. He has been deaf in the left ear since then and has also suffered from diplopia and giddiness. About 9.30 p.m. on the day of admission, while riding his bicycle, he was knocked into from behind by a motor-bicycle and thrown to the ground. He was rendered unconscious and there was bleeding from the nose.

EXAMINATION. 12.4.31.

The general condition is now good. The blood pressure is 170/80. There is a bruise in the right frontal region and a dark blue effusion around the right eye. There is evidence of previous haemorrhage from the nose but none from the ears. The patient is slightly dazed. There is slight frontal headache but no vomiting. There is some dizziness when he moves in bed but this has been present since the previous accident. He remembers cycling near to where the accident occurred but has no further recollection of events until he woke up in hospital. The left pupil is slightly larger than the right. There is no apparent disturbance of the ocular movements but there is a vertical diplopia on looking in all directions. There is slight deafness in the left ear but the Weber test is not referred. Examination otherwise shows no abnormality.

PROGRESS. 14.4.31.

There is now no headache. The patient states that the dizziness is rather more pronounced than before the present accident.
There/

CASE NO. 88. (Contd.)

There is no neck rigidity. He states that the diplopia is just the same as before the accident. There is slight nystagmus on looking laterally both to the right and to the left.

RE-EXAMINATION. 19.8.31.

The patient feels fairly well. There are no headaches but dizziness is more pronounced since the last accident. He still has double vision. There is no nervousness nor sleeplessness. The compensation question is not yet decided.

GROUP B

CASE NO. 89. G.B. A male aged 29. Ward 12.
Admitted 17.7.31. Discharged 6.8.31.
Occupation - Miner.

HISTORY.

The patient's health was good at the time of the accident, but his eyesight is defective owing to previous pit accidents. At 8 p.m. on the day of admission. while riding a bicycle, he collided with a wall. He remembers the details of the accident but lost consciousness shortly after it and has no recollection of coming into hospital. There was bleeding from his nose.

EXAMINATION. 18.7.31.

There is a bruise and cut in the frontal region and a purple effusion around both eyes. There is no evidence of previous haemorrhage and there are no injuries to other parts of the body. The mental state is normal. He is suffering from severe headache and has vomited on two or three occasions. The pain in the head is felt mainly in the left side and is greatly relieved if he stands up. Examination of the nervous system shows no abnormality, except that there is a slight degree of neck rigidity.

X-RAY EXAMINATION.

Examination of the skull shows a comminuted and depressed fracture of the left frontal bone.

PROGRESS. 25.7.31.

The patient states that he continued to have severe headaches until yesterday. He has now no pain. There is some dizziness if he moves about in bed. Visual acuity is quite good in both eyes but the right is distinctly better than the left. The right pupil is slightly smaller than the left but both react normally. Two days ago, he noticed that he was seeing double but this has now recovered. No further abnormality was detected.

CASE NO. 89. (Contd.)

RE-EXAMINATION. 14.1.32.

The patient lay in bed for three weeks and he has not yet returned to work. He still suffers from occasional headaches which are worst at night before he falls asleep. He becomes easily excited and is more nervous than formerly. He states that he had diplopia for three weeks after discharge. Examination shows no abnormality except that there is a depression in the frontal region. There is no question of compensation outstanding.

GROUP B

CASE NO. 90. M.B. A female aged 35. Ward 15.

Admitted 16.12.30. Discharged 26.12.30.

Occupation - Sales-woman.

HISTORY.

The patient was in good health at the time the accident occurred. At 8.30 a.m. on the day of admission, while running to catch a bus, she was knocked down by another bus coming in the opposite direction. She was rendered unconscious and there was bleeding from her nose.

EXAMINATION. 17.12.30.

The general condition is good. There is a cut in the right parietal region and bruises around the mouth and nose. There is no evidence of haemorrhage and no injuries to other parts of the body. The mental state is normal. She has severe pain both in her face and across her head. There is no vomiting. Examination of the nervous system shows no abnormality.

PROGRESS. 21.12.30.

To-day there is no headache or sickness and she feels well. She remembers running across the street to catch a bus. There is no neck rigidity and full examination shows no abnormality.

RE-EXAMINATION. 22.8.31.

The patient lay in bed for a week after returning home and resumed business a month after the accident. She still suffers from dull throbbing headaches which are worst at night and on waking in the morning. They are also more severe in wet weather. She feels dizzy when she stoops to the ground and this also makes her head worse. She notices that she is unable to take wine as this very readily "goes to her head" which is contrary to previous experience. There is no question of compensation outstanding. She received £10. Examination shows no abnormality.

GROUP B

CASE NO. 91. M.C. A female aged 17. Ward 8.

Admitted 31.12.30. Discharged 21.1.31.

HISTORY.

The patient was in good health at the time the accident occurred. On the day of admission while alighting from a bus, she was knocked down by a tram-car. She was rendered unconscious and was at once brought to the Infirmary. She was unable to answer questions on admission but recovered consciousness in the course of an hour or two.

EXAMINATION. 1.1.31.

The general condition is good. The blood pressure is 120/55. There is a laceration in the frontal region and involving the face. There has been profuse haemorrhage from the wound but none from the nose or ears. There is no injury to other parts of the body. The mental state is normal. There is severe pain on the top of the head and she vomited once last night. There is a slight degree of neck rigidity but otherwise examination of the nervous system shows no abnormality.

PROGRESS. 8.1.31.

The patient now feels well. She remembers getting off the bus but has no further recollection of events until she woke up in the hospital. There is no neck rigidity and examination of the nervous system shows no abnormality.

X-RAY EXAMINATION.

Examination of the skull shows a fracture in the sphenoidal region.

RE-EXAMINATION. 5.8.31.

The patient states that she rested in bed for three weeks after leaving hospital and during that time she suffered from severe headaches /

CASE NO. 91.(Contd.)

headaches which have continued off and on ever since. Her memory is not as good as before the accident. She often forgets where she has been and what she has been doing at her work. She still suffers from severe headaches which come on from one to three times weekly. The pain is severe in the eyes and continues for from half a day to a whole day. The headaches are sometimes so severe that she has to stop working. They are worst on waking in the morning and on stooping. She feels dizzy if she looks up or down. She has become rather nervous since the accident, but sleeps well. There is no question of compensation outstanding. The patient states that she does not see quite so well as formerly but examination of the nervous system shows no abnormality.

CASE NO. 92. D.C. A male aged 38. Ward 7 (3).
Admitted 18.2.31. Discharged 13.3.31.
Occupation - Storeman.

HISTORY.

The patient was very intoxicated at the time the accident occurred, otherwise he was in good health. He lost his right arm in the war. The accident was due to his falling down a flight of about 16 steps. He was rendered unconscious and was brought to hospital where he recovered consciousness after a few hours.

EXAMINATION. 20.2.31.

The general condition is good. The blood pressure is 180/110. There is a bruise in the right parietal region but no haemorrhage from the nose or ears. There are no injuries to other parts of the body. The mental state is normal. There was severe frontal and right-sided headache yesterday, but it is slight to-day. He vomited frequently yesterday. There is slight neck rigidity but otherwise examination of the nervous system shows no abnormality.

X-RAY EXAMINATION.

Examination of the skull shows an extensive vertical fracture of the right parietal and the temporal bones.

PROGRESS. 21.2.31.

The patient now feels well. He remembers going towards Broxburn but has no further recollection of events until he woke up on the morning following admission. Examination shows no abnormality.

12.3.31.

He now feels quite well and there is no headache.

RE-EXAMINATION.

The patient could not be traced.

GROUP B

CASE NO. 93. J.C. A male aged 24. Ward 18.

Admitted 13.12.30. Discharged 26.12.30.

Occupation - Composer

HISTORY.

The patient was in good health at the time the accident occurred. On the day of admission, while riding his motor-bicycle, he was involved in a head-on collision with a motor-car and was thrown some distance to the ground. He was rendered unconscious. Bleeding was noticed from his nose, but not from his ears. He was taken immediately to the Infirmary, and recovered consciousness in the course of a few hours.

EXAMINATION. 15.12.30.

The general condition is good. The blood pressure is 120/70. There are bruises on the face and a laceration of the right side of the scalp. There is evidence of previous haemorrhage from the nose but not from the ears. There are no injuries to other parts of the body. The patient is now fully conscious. There is a marked degree of frontal headache and the patient is content to lie quietly. The right plantar reflex gives an extensor response and the right abdominal reflex is sluggish. Otherwise examination of the nervous system shows no abnormality.

X-RAY EXAMINATION.

Examination of the skull shows no evidence of fracture.

PROGRESS. 18.12.30.

The patient is suffering from severe headache. There is no vomiting nor neck rigidity. The left pupil is slightly larger than the right. The discs are normal and no abnormality was detected apart from the right plantar reflex which still gives an extensor response, and the right abdominal reflex which is still sluggish.

CASE NO. 93. (Contd.)

EXAMINATION OF THE CEREBRO-SPINAL FLUID. 18.12.30.

Initial pressure-----330 mms. of water.
Pressure after removing 5 ccs.-250 " " "
The fluid is slightly yellow in colour. No
clot forms on standing.

Cell count:-

Red blood corpuscles-----300 per c.mm.
White blood cells-----None seen
Total protein estimation-----20 mgms per 100 ccs.

20.12.30.

The patient still has some headache but was free of pain during the day following lumbar puncture. The edge of the left optic disc is slightly blurred but there is no definite swelling. Examination of the cranial nerves and motor functions shows no abnormality. Both plantar reflexes now give a flexor response but the abdominal reflex on the right side is still more sluggish than that on the left.

22.12.30.

There is still some pain on the right side of the head. Examination shows no abnormality except that the edge of the left disc is still a little blurred.

RE-EXAMINATION 20.8.31.

The patient lay in bed for a week after discharge and recommenced work a week later. His memory is good and he can now do his work as well as formerly, but he still suffers from headaches. These were severe when he first began work, especially when he woke in the morning, and in the evenings when he was tired. They only come on now in close, thundery weather. They last for about an hour and are felt as a dull ache across the forehead. He has not become nervous and he sleeps well. There is no question of compensation outstanding. Examination shows no abnormality.

GROUP B.

CASE NO. 94. R.D. A male aged 24. Ward 12.

Admitted 1.8.31. Discharged 15.8.31.

Occupation - Bank Clerk.

HISTORY.

The patient was in good health at the time the accident occurred, but his eye-sight has never been very good. About mid-night on the night of admission while riding his motor-bicycle, he was involved in a collision with a bus. He was unconscious for a few hours and there was bleeding from the nose and right ear. He was admitted to the Infirmary about an hour after the accident occurred.

EXAMINATION. 2.8.31.

The general condition is now good. There is a lacerated wound of the right forehead and evidence of previous haemorrhage from the right ear. There is a sub-conjunctival haemorrhage of the right eye. There are no injuries to other parts of the body. The patient is still slightly dazed. There is slight headache and he has vomited frequently during last night. The pupils are equal but the right eye has been damaged by the injury. The visual acuity in the left eye is good. The knee jerks are absent but examination of the nervous system shows no further abnormality.

X-RAY EXAMINATION.

Examination of the skull shows a doubtful fracture of the right parietal region.

PROGRESS. 9.8.31.

The patient remembers applying his brakes to avoid the bus but has no further recollection of events until on his way to hospital. Headache is still severe. There is no neck rigidity and apart from the absent knee jerks, no abnormality in the nervous system was detected. He was transferred to the Eye Department where it was found necessary to remove his right eye.

RE-EXAMINATION. 14.1.32.

He has had no post-concussional disturbances and now feels quite fit. Examination of the nervous system, apart from the absent knee jerks, shows no abnormality.

GROUP B

CASE NO. 95. M.F. A male aged 21. Ward 18.

Admitted 23.5.31. Discharged 29.5.31.

Occupation - Miner.

HISTORY.

The patient was in good health at the time the accident occurred. On the day of admission, while putting his head out of the window of the bus, the right side of his head came in contact with a standard at the side of the road. He was immediately rendered unconscious. He was at once taken to the Infirmary and did not recover consciousness for a few hours.

EXAMINATION. 24.5.31.

The general condition is now good. The blood pressure is 125/70. There is a bruise in the right temporal region and the right eye is partly closed with effusion. There is no evidence of previous haemorrhage from the nose or ears and there are no injuries to other parts of the body. The patient is now fully conscious. The last thing he remembers is getting into the bus about half an hour before the accident occurred. He feels slightly dizzy when he moves his head. Examination of the nervous system shows that the left abdominal reflexes are slightly diminished, but no further abnormality was detected.

X-RAY EXAMINATION.

Examination of the skull shows no evidence of fracture.

RE-EXAMINATION.

The patient failed to report.

GROUP B.

CASE NO. 96. D.F. A male aged 21. Ward 3.(7).

Admitted 19.2.31. Discharged 24.2.31.

Occupation - Miner.

HISTORY.

The patient was in good health at the time the injury occurred. On the morning of admission while coming up from the pit, he was assaulted by another worker and was knocked unconscious by a blow on the right side of the head. He was brought to the Infirmary, and on admission, was very restless and violent, striking himself and struggling with the attendants. It was nearly 24 hours after admission before he recovered consciousness.

EXAMINATION. 20.2.31.

The general condition is good. There is a bruise on the right side of the head and the left eye is closed with effusion. There is no evidence of haemorrhage from the nose or ears but there is a sub-conjunctival haemorrhage in the outer side of the left eye. There are no injuries to other parts of the body. The mental state is normal. There is slight frontal headache but there is no vomiting. The patient remembers coming up the pit but has no further recollection of events until he woke up next morning in the Ward.

X-RAY EXAMINATION.

Examination of the skull shows no evidence of fracture.

RE-EXAMINATION. 7.8.31.

The patient states that he lay in bed for a week after discharge and then returned to work. His memory is as good as previously, but he still suffers from headaches which are present every morning when he wakens but gradually go away during the day. They are throbbing in nature and /

and aggravated by stooping to the ground. He often has dizzy turns and during these has to sit down and rest for a few minutes. He has not become nervous and he sleeps well. There is no question of compensation outstanding. He played football a week ago, but at half-time began to suffer from very severe headache, and after the game had to lie down and rest, owing to the severity of the pain. Examination shows no abnormality.

GROUP B

CASE NO. 97. R.F. A male aged 33. Ward 6.

Admitted 5.2.31. Discharged 9.2.31.

Occupation - Motor driver.

HISTORY.

The patient was in good health at the time the accident occurred. On the day of admission while starting his bus, the engine back-fired, and threw him to the ground. He was rendered unconscious and taken immediately to the Infirmary, where he recovered consciousness about an hour later.

EXAMINATION. 6.2.31.

The general condition is good. The blood pressure is 100/60. There is a laceration of the scalp in the occipital region. There is no evidence of haemorrhage from the nose or ears, but there is sub-conjunctival haemorrhage of the right eye. There are no injuries to other parts of the body. The mental state is now quite normal. There is moderately severe frontal headache, and the patient has vomited on two or three occasions. The left pupil is slightly larger than the right, and there is slight neck rigidity, but otherwise examination of the nervous system elicits no abnormality.

PROGRESS. 8.2.31.

Today the patient feels dizzy if he sits up in bed. He also feels sleepy and is content to lie quietly all day. Full examination elicits no abnormality.

RE-EXAMINATION

The patient failed to report.

GROUP B

CASE NO. 98. D.F. A male aged 6. Ward 12.

Admitted 10.4.31. Discharged 24.4.31.

HISTORY.

The patient was in good health at the time the accident occurred. At 3 p.m. on the day of admission, a boy pushed him, and he fell down stairs and struck his head on the ground. He was taken immediately to the Infirmary, where he recovered consciousness in the course of about two hours. Bleeding was noticed from his nose, but none from his ears.

EXAMINATION. 11.4.31.

The general condition is good. There is a bruise in the left parietal region, and effusion around the left eye. There is evidence of previous haemorrhage from the left side of the nose, but none from the ears. There are no injuries to other parts of the body. The mental state is quite normal. There is a moderate degree of frontal headache, but no vomiting. There is an internal strabismus of the left eye, but this was present before the accident. No further abnormality was detected on examination.

X-RAY EXAMINATION.

Examination shows no evidence of fracture of the skull.

RE-EXAMINATION. 24.7.31.

The patient's mother says that he is quite changed since the accident. He is not nearly so good and obedient as formerly. He still suffers from headaches, and when these come on, he is glad to go to bed. He has become very nervous, and cowers when spoken to sharply which he never did formerly. There does not seem to be any dizziness, and he sleeps as well as ever. Examination shows no abnormality, with the exception of the squint which was noticed at the previous examination. There is no question of compensation.

GROUP B.

CASE No. 99. W.G. A male aged 68. Ward 68.

Admitted 1.1.31. Discharged 7.1.31.

Occupation - Gardener.

HISTORY.

The patient's breath smelt strongly of alcohol on admission, but otherwise he was in good health at the time the accident occurred. About midday on the day of admission, he stepped off the pavement and was knocked down by a passing motor car. He was rendered unconscious, and was taken to the Infirmary where he was admitted about twenty minutes later. On admission he was reported to be deeply unconscious and to have stertorous breathing, but he soon began to recover, and became very excitable and almost uncontrollable. There was bleeding from both ears, especially the left.

EXAMINATION. 2.1.31.

The general condition is now good. There is no apparent bruising of the scalp, but there is evidence of previous haemorrhage from both ears. There are no injuries to other parts of the body. The patient is now fully conscious. There is slight headache, but no vomiting. Full examination of the nervous system elicits no abnormality.

EXAMINATION OF THE CEREBRO-SPINAL FLUID. 2.1.31.

Initial pressure ----- 260mm. of water.
Pressure after removing 5cc ----- 190mm. of water.
The fluid is slightly yellow in colour. No clot forms on standing. There are no red cells in the specimen, but there are 13 white cells per cu.mm., all of which are small lymphocytes. The total protein estimation is 25mgms per 100cc.

RE-EXAMINATION. 11.8.31.

The patient states that he returned to work a month after the accident. He did not rest in bed after returning home. His memory is good, and there is no headache. He occasionally suffers from slight dizzy turns when he stands up suddenly but these only last for a second or two. He has not become nervous and has no difficulty in sleeping. There is no question of compensation. Examination shows that there is slight deafness of the left ear. The Weber test is referred to the/

CASE NO. 99 (contd).

2.

the right. Examination otherwise shows no abnormality.

GROUP B

CASE NO. 100. W.G. A male aged 17. Ward 6.

Admitted 6.11.30. Discharged 19.11.30.

Occupation - Gardener

HISTORY.

The patient states that he was in good health at the time the accident occurred. On the day of admission, while riding his bicycle he was involved in a collision. He was taken to the Infirmary, where he lay unconscious for several hours.

EXAMINATION. 8.11.30.

The general condition is good. There is no apparent injury to the scalp, and no evidence of haemorrhage from the nose or ears. There are no injuries to other parts of the body. There is severe headache, but no vomiting. There is marked neck rigidity, and Kernig's sign is positive, but otherwise no abnormality was detected on examination. The cerebro-spinal fluid was examined by the House Surgeon, and was found to be deeply blood stained.

PROGRESS. 11.11.30.

The patient's condition has improved. There is less headache, and there is now no neck rigidity.

X-RAY EXAMINATION.

Examination of the skull shows no evidence of fracture.

19.11.30.

There were no symptoms, and the patient was discharged. He recovered well at home, and started to ride his bicycle again. On 22.12.30, he remembers having a sudden severe pain in his head. Then he jumped off his bicycle and fell to the ground unconscious. He was re-admitted to hospital. For a week after admission, he was reported to have been disorientated and very restless. During this week he continued to have a swinging temperature, but /

CASE NO. 100. (Contd.)

but on 28.12.30, the House Surgeon again performed lumbar puncture, and as before found blood-stained fluid. Immediately after the lumbar puncture, his headache was relieved, the temperature settled, and his mental state improved. Examination on 2.1.31 showed no abnormality with the exception of a slight degree of neck rigidity, and Kernig's sign was slightly positive. He was discharged on 7.1.31, and was instructed to lie in bed for three weeks.

RE-EXAMINATION. 11.8.31.

The patient is working as usual, and feels fit with the exception that he occasionally suffers from headache after he has been stooping for some time. This goes away if he stands up. There are no other post-concussional disturbances.

GROUP B

CASE NO. 101. J.H. A male aged 11. Ward 7.

Admitted 29.7.31. Discharged 10.8.31.

HISTORY.

The patient states that he was in good health at the time the accident occurred. About 9.30. p.m. on the day of admission, while riding his bicycle, he was knocked to the ground by a motor-car. He was rendered unconscious and was brought at once to the Infirmary.

EXAMINATION

The general condition is now good. There are several minor injuries of the scalp. There is no evidence of previous haemorrhage from the nose or ears. There are bruises of some other parts of the body. The patient is now fully conscious. He remembers starting to go for a run on his bicycle, but has no further recollection of events until he woke up about five hours later in hospital. There is now a moderate degree of frontal headache, but his was severe yesterday. He vomited once yesterday. Examination elicits no abnormality.

X-RAY EXAMINATION.

Examination of the skull shows no evidence of fracture.

PROGRESS 4.8.31.

He is fully conscious. There is still some headache, which is referred to the frontal region, and is aggravated by reading or coughing. Physical examination shows no abnormality.

RE-EXAMINATION 1.12.31.

The patient states that he rested in bed for two weeks after leaving hospital. He suffered from severe headaches for two weeks after discharge, but thereafter they disappeared. Otherwise, there have been no post-concussional symptoms.

GROUP B

CASE NO. 102. D.H. A male aged 45. Ward 7.
Admitted 4.3.31. Discharged 1.4.31.
Occupation - Carter.

HISTORY.

The patient was in good health at the time the accident occurred. At 8 p.m. on the day of admission, he was knocked down by a motor-car. He was rendered unconscious, and was brought to the Infirmary. He was unconscious for over an hour.

EXAMINATION. 10.3.31.

The general condition is now good. The blood pressure is 125/90. There is a laceration of the right side of the scalp. On admission, he was reported to have an effusion around the right eye, but there was no haemorrhage from the nose or ears. There is an extensive sub-conjunctival haemorrhage in the right eye, which surrounds the cornea. There is also a small haemorrhage on the outer side of the left eye. There are no injuries to other parts of the body. The mental state is quite normal. There is a considerable degree of headache referred to the frontal region and right side of the head. Examination of the nervous system shows no abnormality.

PROGRESS. 18.3.31.

The patient is now free of headache. He remembers walking along the footpath in the neighbourhood of where the accident occurred, but has no further recollection of events until he woke up in hospital.

X-RAY EXAMINATION

Examination of the skull was not carried out.

EXAMINATION. 5.8.31.

The patient states that he rested in bed for two weeks after leaving hospital. He has not worked since the accident. He is still suffering /

CASE NO. 102. (Contd.)

suffering from headaches. These are now improving, but were very severe for a period of two months after discharge. They were worst while he was in bed, and were felt as a sharp pain in the occipital region. He was unable to sleep well for two months after discharge. The right eye waters excessively, and there is some numbness in the right infra-orbital region. The scar is a little tender, but otherwise there is no abnormality on physical examination. There is no question of compensation, but he is receiving 32/6 a week from the Parish authorities.

GROUP B

CASE NO. 103. M.H. A female aged 42. Ward 15.

Admitted 27.1.31. Discharged 2.3.31.

HISTORY.

At 8 p.m. on the day of admission, the patient was knocked down in the street by a motor car. There was bleeding from the right ear after the accident, and she was rendered unconscious. She was admitted to the Infirmary, where she woke up on the following morning.

EXAMINATION. 28.1.31.

There is a bruise in the right parietal region. There is evidence of previous haemorrhage from the right ear, but none from the nose or left ear. There are no injuries to other parts of the body. The mental state is quite normal. There is slight frontal headache, but no vomiting. The patient remembers leaving home yesterday a few minutes before the accident occurred, but has no further recollection of events until she woke up in hospital this morning. Examination of the nervous system shows no abnormality.

X-RAY EXAMINATION

Examination shows a fracture of the right temporal bone.

RE-EXAMINATION

The patient failed to report.

GROUP B

CASE NO. 104. H.M. A male aged 62. Ward 10.

Admitted 24.5.31. Discharged 9.6.31.

HISTORY.

The patient was in good health at the time the accident occurred. On the day of admission, while driving a car, he was involved in a collision. He was rendered unconscious, and was brought to the Infirmary.

EXAMINATION. 25.5.31.

There is a bruise in the frontal region, and a dark ring of effusion around the left eye. There is evidence of previous haemorrhage from the nose, but none from the ears. There are bruises to other parts of the body, but no severe injury. The patient is still slightly dazed. There is a considerable degree of headache. He remembers beginning to turn his car at the place where the accident occurred, and he remembers seeing a bus, but has no further recollection of events until he woke up in hospital over an hour later.

X-RAY EXAMINATION

Examination of the skull shows no evidence of fracture.

RE-EXAMINATION

The patient failed to report.

315

GROUP B

CASE NO. 105. R.H. A male aged 25. Ward 16.
Admitted 5.5.31. Discharged 20.5.31.
Occupation - Photographer's Assistant.

HISTORY.

The patient was in good health at the time the accident occurred. At 1.30 p.m. on the day of admission, while riding a motor-bicycle, he collided with a wall. He was rendered unconscious and was brought to the Infirmary where he was admitted an hour later.

EXAMINATION. 6.5.31.

The general condition is good. The blood pressure is 140/60. There is a cut of the right side of the forehead. There is evidence of previous haemorrhage from the left nostril, but not from the ears. Apart from some lacerations of the hands, there are no injuries to other parts. He is still slightly dazed, but knows where he is. There is no headache. He vomited on several occasions while in the out-patient department. The right pupil is slightly larger than the left, and there is a slight degree of neck rigidity, but otherwise examination shows no abnormality.

PROGRESS. 7.5.31.

The patient is now fully conscious. He remembers being on his bicycle before the accident occurred, and he has a faint recollection of coming to hospital. There is complete anosmia on both sides. There is still slight inequality of the pupils. There is some diplopia on looking downwards, and there is weakness of the downward movement of the left eye.

16.5.31.

The diplopia to-day is less marked. There is slight weakness of the downward movement of the left eye still present. There is now no loss of the sense of smell.

CASE NO. 105. (Contd.)

RE-EXAMINATION 9.12.31.

The patient states that he returned to work three weeks after discharge from hospital. His health is excellent, and there have been no post-concussional disturbances. He now remembers being within half a mile of where the accident occurred. He does not now remember being in the ambulance, and his first recollection of events after the injury is when he was having his clothes taken off. There is a depression in the centre of the frontal region, but otherwise there is no abnormality on examination.

GROUP B

CASE NO. 106. E.H. A male aged 30. Ward 18.
Admitted 29.11.30. Discharged 15.12.30.
Occupation - Labourer

HISTORY.

On the day of admission, while working on a scaffolding, the patient slipped and fell a distance of ten feet on to a concrete floor. He was at once rendered unconscious and was taken to the Infirmary. On admission he was reported to be only slightly shocked. There was profuse haemorrhage from the right ear.

EXAMINATION. 30.11.30.

The general condition is good. The blood pressure is 150/70 mm. There is no apparent injury to the scalp. There is still slight haemorrhage from the right ear. He is slightly dazed and has no recollection of anything which occurred yesterday. There is no headache. He vomited once or twice soon after admission. There is slight neck rigidity, but otherwise there is no detectable abnormality on examination.

PROGRESS. 1.12.30.

The patient is content to lie quietly, but is now fully conscious. He remembers seeing the examiner yesterday. There is no headache. The right pupil is slightly larger than the left. There is a slight degree of weakness of the right side of the face. There is also a slight degree of neck rigidity. The blood pressure is 135/80 mm.

X-RAY EXAMINATION

There is a vertical fracture extending into the base of the skull on the right side.

EXAMINATION OF THE CEREBRO-SPINAL FLUID. 4.12.30.

Initial pressure-----40 mm. of water
Pressure after removing 5 cc-----15 " " "
The fluid is uniformly blood-stained. The supernatant /

CASE NO. 106. (Contd.)

supernatant fluid is yellow in colour. There is no clot formation. There are 18,000 red blood cells per c.mm., and 84 white cells per c.mm. Of the latter, 26 per cent are polymorphs, 17 per cent are small lymphocytes, and 57 per cent are large mononeuclear cells. The total protein content is 119 mgms. per 100 ccs.

5.12.30.

To-day the patient says his head feels "clearer". There is still some neck rigidity.

8.12.30.

To-day the patient says he has a dull pain in the head, especially if he turns it to one side. There is marked right facial weakness. The right ear is slightly deaf.

RE-EXAMINATION.

The patient was unable to report.

GROUP B

CASE NO. 107. J.I. A female aged 9. Ward 14.

Admitted 13.7.31. Discharged 25.7.31.

HISTORY.

At 10 a.m. on the day of admission, the patient was knocked down by a car which mounted on to the pavement. She was rendered unconscious and was brought to the Infirmary, where she was admitted about an hour later.

EXAMINATION. 8 hours after the accident.

The pulse is rapid and the temperature is 100.8° F. The blood pressure is 106/78 mm. There is a bruise over the vertex. There is no evidence of haemorrhage from the nose or ears. There is a laceration of the right thigh. The mental state is quite normal, and she has no recollection of how the accident occurred. She did not wake up until after admission. There is a bilateral extensor plantar response, but otherwise examination reveals no abnormality.

PROGRESS. 19.7.31.

To-day the patient feels quite well and she has no headache. There is still a bilateral extensor response, but otherwise no abnormality was detected on examination.

X-RAY EXAMINATION.

There is no evidence of fracture.

RE-EXAMINATION. 26.11.31.

The patient states that she lay in bed for a month after discharge. Her memory is as good as ever. She has no recollection of any event which occurred during the four days which preceded the accident. She does not remember coming into hospital. She still suffers from occasional headaches, and she sometimes feels dizzy while at school. She is not nervous and has no difficulty in sleeping. There is still some question of compensation outstanding. Examination shows no abnormality.

GROUP B

CASE NO. 108. MRS. A.J. A female aged 63. Ward 14.
Admitted 13.4.31. Discharged 17.4.31.

HISTORY.

The patient was in good health at the time the accident occurred. She had however, taken a small whiskey shortly before it occurred. On the day of admission, at about 8.20 p.m., she was knocked down by a motor vehicle. She was brought to the Infirmary where she was admitted about an hour later.

EXAMINATION. 14.4.31.

The general condition is good. The blood pressure is 122/92 mm. There is a laceration of the scalp in the left parietal region. There has been haemorrhage from the wound, but none from the nose or ears. There are no injuries to other parts of the body. The patient is fully conscious. She remembers beginning to cross the road, but has no further recollection of events until she woke up in the Infirmary shortly after admission. Examination of the nervous system shows no abnormality. The blood sugar content at 11 a.m. to-day is 133 mgms. per 100 c.cs.

X-RAY EXAMINATION

There is no evidence of fracture.

RE-EXAMINATION. 23.7.31.

The patient states that she worked little for two weeks after discharge. During that time she was troubled with dizziness if she suddenly stood up. Otherwise there have been no symptoms. There may be some question of compensation.

GROUP B

CASE NO. 109. J.L. A male aged 26. Ward 13.
Admitted 19.1.31. Discharged 26.1.31.
Occupation - Blacksmith.

HISTORY.

The patient was in good health at the time the accident occurred. He has had two previous motor-bicycle accidents. On the day of admission, while riding a motor-bicycle, he collided with a bus. He was rendered unconscious and was brought to the Infirmary, where he was admitted one and a half hours later.

EXAMINATION. Two hours after the accident.

The pulse is full and there is no severe shock. There is a cut in the left fronto-parietal region. There is no haemorrhage from the nose or ears. There are no injuries to other parts of the body. The patient is slightly dazed. His speech was quite normal until he was asked whether he had any difficulty with speaking, when he at once began to stammer. There is some frontal throbbing headache and he has vomited on two or three occasions. Examination of the nervous system shows no abnormality.

X-RAY EXAMINATION.

There is no evidence of fracture of the skull.

PROGRESS. 21.1.31.

To-day there is no headache. His speech is quite normal. The stammer continued for two days after the accident. Examination shows no abnormality.

RE-EXAMINATION. 23.7.31.

The patient states that he rested in bed for a week after discharge. When he got up out of bed, he felt faint, so he returned to bed for a further period of one week. He has felt quite well since then except that he takes little turns in which he feels very dull for a few seconds, and has to stop what he is doing until they pass off. He has also become more nervous than he was before his accident. There is no question of compensation.

GROUP B

CASE NO. 110. H.M'D. A male aged 29. Ward 12.

Admitted 2.1.31. Discharged 7.1.31.

HISTORY.

The patient was in fair health at the time of the accident, but has had pleurisy on five occasions. At 11 p.m. on the day before admission, he slipped on the ice and fell to the ground. He was rendered unconscious, and did not recover consciousness until he was admitted to the Infirmary eight hours after the accident occurred.

EXAMINATION. 4.1.31.

The general condition is good. There is a bruise in the occipital region. There is no evidence of previous haemorrhage from the nose or ears. The patient is now fully conscious. He remembers slipping and putting out his hands to save himself, but has no further recollection of events until he woke up in hospital. There is slight frontal headache. Examination of the nervous system shows no abnormality.

X-RAY EXAMINATION.

Examination of the skull was not carried out.

RE-EXAMINATION. 31.7.31.

The patient states that he stayed in bed for three weeks after discharge. He returned to work four months ago. He had a heavy feeling in the head during the three weeks he stayed in bed. He is more nervous than previously, but otherwise there have been no post-concussional disturbances.

GROUP B.

CASE NO. 111. R.M'I. A male aged 29. Ward 13.

Admitted 29.6.31. Discharged 28.7.31.

Occupation - Miner.

HISTORY.

The patient was in good health at the time the accident occurred. At 2p.m. on the day of admission, while riding his motor-bicycle, he was involved in an accident. He was rendered unconscious, and was admitted to the Infirmary a quarter of an hour later. There was bleeding from his nose, but none from his ears.

EXAMINATION. 30.6.31.

The general condition is good. There is a laceration of the scalp and a compound fracture of the frontal region. There is now no evidence of haemorrhage, but there is a sub-conjunctival haemorrhage on the outer side of the right eye. There are lacerations of the right knee, but no other injuries to the body. The mental state is quite normal. He remembers intending to pass two motor cars on the road. He has no further recollection of events until he recovered consciousness a few hours after admission. There is no headache. He vomited once after the operation on his scalp. There is slight neck rigidity, but no other abnormal sign on examination of the nervous system.

Sugar content of the blood:

29.6.31, 5p.m. --- 143mgms. per 100cc.

1.7.31, 10a.m. --- 120mgms. per 100cc.

RE-EXAMINATION. 26.11.31.

The patient states that he lay in bed for eight weeks on account of the injury to his knee. He returned to work on 4.10.31. There have been no post-concussional symptoms. The only abnormality he notices is that since his accident his hands have sweated very profusely. This did not occur previous to his injury. On examination his hands are literally pouring with perspiration.

GROUP B.

CASE NO. 112. R.M.(M.) Age 23. Ward 12.

Admitted 5.12.30. Discharged 20.12.30.

Occupation - Motor-driver.

HISTORY.

The patient was in good health at the time the accident occurred. At 5 p.m. on the day of admission while getting out of his car, he was knocked down by another motor. He was unconscious for about an hour and was taken to the Infirmary. Bleeding from his nose was noticed.

EXAMINATION A FEW HOURS AFTER ADMISSION.

The general condition is good. The blood pressure is 135/75. There is a laceration of the scalp and also of the face. There is evidence of previous haemorrhage from the nose but none from the ears. There are also bruises of the legs. The patient is now fully conscious. There is no headache nor vomiting. Full examination shows no abnormality.

X-RAY EXAMINATION.

Examination of the skull shows no fracture.

RE-EXAMINATION. 30.7.31.

The patient states that he lay in bed for a week after discharge and started work six weeks after the accident occurred. He had occasional headaches for a few weeks after the injury, which were felt usually in the evening before going to bed and after a large meal. Otherwise there have been no post-concussional disturbances. There is no question of compensation outstanding. He received £100.

GROUP B.

CASE NO. 113. J.M. (M) Age 17 Ward 18.

Admitted 20.12.30 Discharged 26.12.30

Occupation - Apprentice architect.

HISTORY.

The patient was in good health at the time the accident occurred. On the day of admission at 2 p.m., while riding a bicycle, he skidded on the tram lines and was thrown to the ground. He remembers skidding and being thrown over the handlebars. He did not fully recover consciousness for over an hour. He was brought to the Infirmary, where he was admitted.

EXAMINATION ON THE EVENING OF ADMISSION.

The general condition is good. There is a small laceration in the left occipital region but no evidence of haemorrhage from the nose or ears. There is severe headache in the occipital region but there is no vomiting. Examination of the nervous system shows no abnormality.

X-RAY EXAMINATION.

Examination of the skull shows no evidence of fracture.

PROGRESS. 22.12.30.

The patient has now no symptoms.

RE-EXAMINATION. 19.8.31.

The patient recommenced work as soon as he left hospital. There have been no post-concussional symptoms.

GROUP B

CASE NO. 114. J.M. (M.) Age 21. Ward 13.
Admitted 6.4.31. Discharged 9.4.31
Occupation - Chemist's assistant.

HISTORY.

The patient was in good health at the time the accident occurred. At 4 p.m. on the day of admission, while going down-stairs, he fell a distance of about 30 steps. He was rendered unconscious and admitted to the Infirmary an hour later where he was found to have not yet fully recovered consciousness.

EXAMINATION. 7.4.31.

The general condition is good. There is a bruise with haematoma formation in the left frontal region and also a bruise in the right occipital region. There is no evidence of previous haemorrhage from the nose or ears, and no injuries to other parts of the body. The patient is now fully conscious and has a slight headache in the frontal region which was aggravated by coughing. There is no vomiting. Examination of the nervous system shows no abnormality.

X-RAY EXAMINATION.

Examination of the skull shows no evidence of fracture.

PROGRESS. 8.4.31.

The patient remembers going towards the back of the shop intending to go down-stairs but has no further recollection of events until he woke up in the Infirmary.

RE-EXAMINATION. 22.7.31.

The patient states that he felt quite well when he left hospital and stayed in bed for 4 weeks. He has been quite well since discharge and there have been no post-concussional disturbances.

CASE NO. 115. E.N. (M) Age 22. Ward 10.
Admitted 28.6.31. Discharged 7.8.31.
Occupation - Painter.

HISTORY.

The patient was in good health at the time the accident occurred. On the day of admission while riding a motor bicycle, he collided with a motor car. He was rendered unconscious and was brought at once to the Infirmary. No bleeding from the nose or ears was noticed. He was reported to be slightly elated and confused on admission and repeated himself frequently. He did not know the day of the week and had no recollection of events preceding the accident. There was no shock.

EXAMINATION. 29.6.31.

The general condition is good. There is a bruise in the right parietal region. There is no evidence of previous haemorrhage from the nose or ears. There is an injury to the right leg. The patient is now fully conscious. There has been no headache but he vomited on two or three occasions yesterday. Examination of the nervous system shows no abnormality, apart from a slight degree of neck rigidity.

PROGRESS. 2.7.31.

The patient is now quite well. He remembers being within one mile of where the accident occurred. He has no further recollection of events until he woke up in hospital 7 or 8 hours later. There has been no headache, giddiness nor diplopia. Examination shows no abnormality. X-Ray examination was not carried out.

RE-EXAMINATION. 25.1.32.

The patient has not yet returned to work as there is none available. Complete recovery has occurred. There have been no post-concussional disturbances and there is no question of compensation.

GROUP B

CASE NO. 116. F.M. (M.) Age 26. Ward 7.

Admitted 29.10.30 Discharged 5.11.30

Occupation - Locomotive fireman.

HISTORY.

The patient was in good health at the time the accident occurred. At 6.30. p.m. on the day of admission, while riding a bicycle, he was thrown to the ground. The reason for this could not be discovered. He was rendered unconscious and was brought at once to the Infirmary. On admission he was reported to be very noisy, to be unable to answer questions and to resent examination. There was no bleeding from his nose or ears.

EXAMINATION. 30.10.30.

The general condition is good. There is a laceration of the scalp in the right frontal region. There is no evidence of previous haemorrhage from the nose or ears. The patient is now fully conscious. The last thing he remembers before the accident is that he was at the top of a hill half a mile from where it occurred. He did not recover consciousness until he had been in the ward for several hours. Full examination of the nervous system shows no abnormality. X-Ray examination of the skull shows no evidence of fracture.

RE-EXAMINATION. 5.8.31.

The patient states that he rested in bed for a week and then returned to work. Complete recovery has occurred and there have been no post-concussional symptoms. There is no question of compensation.

CASE NO. 117. J.M.(M) Age 26 Ward 19

Admitted 4.8.31.

Occupation - Student.

HISTORY.

The patient was in good health at the time the accident occurred. About midday on the day of admission, while riding pillion on a motor bicycle, he was involved in a collision at a cross-road. He was rendered unconscious and brought to the Infirmary, where he soon recovered consciousness. There was bleeding from the nose but none from the ears.

EXAMINATION. 6.8.31.

There is a bruise in the left temporal region and a ring of effusion round the left eye. There is haemorrhage from the nose but none from the ears. There are some bruises in other parts of the body. The patient is now fully conscious. There is no headache, but he has vomited on one or two occasions. He is completely blind in the left eye. The pupil on the left side does not react to direct light but shows a good consensual reaction. Otherwise examination of the nervous system shows no abnormality.

X-RAY EXAMINATION.

The skull shows no evidence of fracture.

RE-EXAMINATION. 10.10.31.

The patient has recovered no vision in the left eye and left disc is pale and atrophied. He is suffering from headaches and he also suffers from dizzy turns in which everything goes black for a few seconds. He has become very nervous and has difficulty in concentrating. Examination shows no abnormality apart from the atrophy of the left optic disc.

GROUP B.

CASE NO. 118. H.M.(F.) Age 71. Ward 8.

Admitted 29.7.31. Discharged 10.8.31.

HISTORY.

The patient was in good health at the time the accident occurred. She has always, however, been very short-sighted. At 6 p.m. on the day of admission, while crossing the street, she was knocked down by a motor car. She was rendered unconscious and was brought to the Infirmary.

EXAMINATION. 30.7.31.

The general condition is good. There is a bruise in the right parietal region. There is no evidence of haemorrhage from the nose or ears. Apart from a few bruises, there are no injuries to other parts of the body. The mental state is quite normal. There has been no headache and no vomiting.

When first examined after admission to hospital she had no recollection of events that occurred within a period of 15 minutes preceding the accident. She now however remembers beginning to cross the street where she was knocked down. Thereafter she has no further recollection of events until she woke up in hospital 12 hours later. Examination of the nervous system shows no abnormality.

RE-EXAMINATION.

The patient failed to report.

CASE NO. 119. M.N. (F.) Age 15 Ward 5.

Admitted 2.4.31. Discharged 17.4.31.

HISTORY.

The patient was in good health at the time the accident occurred. At 8 p.m. on the day of admission she was knocked down in the street by a motor car. She was rendered unconscious and brought immediately to the Infirmary.. There was no haemorrhage from the nose or ears.

EXAMINATION 11.4.31.

The general condition is good. There is a lacerated wound of the scalp in the right frontal region. There is no evidence of previous haemorrhage from the nose or ears. There is a small sub-conjunctival haemorrhage on the outer side of the right eye. There are no injuries to other parts of the body. The patient is fully conscious. There has been no headache, and vomiting has occurred only once after the anaesthetic. Examination of the nervous system shows no abnormality.

PROGRESS 14.4.31.

The patient now feels well. There is no headache, giddiness or diplopia. There has been some swinging temperature since admission but this has now settled.

X-RAY EXAMINATION.

The skull shows no evidence of fracture.

RE-EXAMINATION 5.8.31.

Apart from some irritability, which may have another cause, there have been no post-concussional disturbances.

GROUP B.

CASE NO. 120. D. O'N. (M) Age 10. Ward 13.

Admitted 1.6.31. Discharged 10.6.31.

HISTORY.

The patient was in good health at the time the accident occurred. On the evening of admission, while climbing the Castle Rock, he slipped and fell. He was brought to the Infirmary and was dazed on admission.

EXAMINATION 2.6.31.

There is a bruise in the right frontal region. There is no evidence of haemorrhage from the nose or ears, and no injury to other parts of the body. The patient remembers climbing on the rocks but has no recollection of falling. He did not recover consciousness until after admission to hospital. Examination of the nervous system shows no abnormality.

X-RAY EXAMINATION.

The skull shows no evidence of fracture.

RE-EXAMINATION. 24.11.31.

The patient states that he lay in bed for a week after returning home and went back to school 2 weeks later. Complete recovery has occurred and there have been no post-concussional disturbances.

GROUP B.

CASE NO. 121. G.Q.(M) Age 18 Ward 13.

Admitted 22.12.30 Discharged 10.1.31.

Occupation - Labourer.

HISTORY.

The patient was in good health at the time the accident occurred. On the day of admission while walking along the road, he was knocked down by a motor car. He was rendered unconscious and was brought to the Infirmary the same evening.

EXAMINATION. 23.12.30.

The general condition is good. The blood pressure is 160/65. There is a bruise in the frontal region. There is evidence of previous haemorrhage from the nose but none from the ears. He was evidently unconscious for about an hour after the injury. He remembers walking along the road near where the accident occurred but has no recollection of any motor car. He is fully conscious. There is no headache or vomiting and examination shows no abnormality.

X-RAY EXAMINATION.

The skull shows no evidence of fracture.

PROGRESS. 26.12.31.

The patient is slightly drowsy but quite rational. Examination shows no abnormality.

RE-EXAMINATION. 23.7.31.

The patient says he has not fully recovered from the effects of his injury. He has slight headaches which occur about every second day between 6 and 10 p.m. These are never present when he wakes in the morning. He also has a stinging pain across the forehead in the neighbourhood of the wound. There is no giddiness and no difficulty in sleeping but the patient states he has become a little nervous. He is at present unemployed and the question of compensation has not yet been settled.

GROUP B.

CASE NO. 122. G.R.(M) Age 31. Ward 6.

Admitted 25.6.31. Discharged 2.7.31.

HISTORY.

The patient was in good health at the time the accident occurred. He had had a bottle of beer an hour beforehand but was not intoxicated. While riding a motor bicycle, he collided with another motor bicycle. He was rendered unconscious and brought to the Infirmary.

EXAMINATION. 28.6.31.

The general condition is good. There is a laceration of the scalp in the right temporal region and a ring of dark effusion around the right eye. There is no evidence of haemorrhage from the nose or ears. There is a sub-conjunctival haemorrhage on the outer side of the right eye. There is a fracture of the femur and bruises to other parts of the body. The patient remembers seeing the bicycle with which he collided, and applying the brakes, and also remembers skidding. He has, however, no further recollection of events until he woke up in the ambulance. There is slight headache and he vomited once on the night of admission. Examination of the nervous system shows no abnormality.

X-RAY EXAMINATION.

The skull shows no evidence of fracture.

RE-EXAMINATION.

The patient failed to report.

CASE NO. 123. A.R. (M.) Age 36. Ward 6.

Admitted 1.1.31. Discharged 16.1.31.

Occupation - Porter in Goods Department of Railway.

HISTORY.

The patient was in good health at the time the accident occurred. He had had something to drink but states he was not intoxicated. The accident occurred at 9p.m., and was probably due to his falling downstairs. He was found unconscious at the foot of the stairs, and brought to the Infirmary. On admission his respiration was reported to be slow and stertorous and his pulse quick and strong. There was no odour of alcohol in his breath.

EXAMINATION. 2.1.31.

The pulse rate is still rapid and the temperature above normal. Blood pressure 145/70. There is bruising in the frontal region and both eyes are closed by effusion. There is a large sub-conjunctival haemorrhage of the right eye. The patient is fully conscious. There is severe headache but there has been no vomiting. The right pupil is 5.5 millimetres in diameter, the left 4.5 millimetres. There is no reaction of the left pupil to light. Reaction of the right pupil is sluggish. There is slight neck rigidity, but otherwise examination of the nervous system shows no abnormality.

EXAMINATION OF THE CEREBRO-SPINAL FLUID. 2.1.31.

Initial pressure 160 mm. of water.
 Pressure after removing 5 cc. 150 mm. of water.
 The fluid was uniformly blood-stained. No clot formed on standing.
 Cell count - Red blood cells: 19,000 per c.mm.
 White blood cells: 13 per c.mm.
 Differential count - Polymorphs: 90%
 Small lymphocytes: 5%
 Large mononuclears: 5%
 Total protein estimation - 160 mgms. per 100 cc.

PROGRESS. 4.1.31.

There has been no headache since the lumbar puncture and no restlessness. The left eye is quite blind and the vision of the right eye is grossly defective. The right pupil reacts sluggishly /

CASE NO. 123. (Contd.)

sluggishly to light. The left is quite inactive to direct light but reacts to consensual light. The right pupil is 7 millimetres in diameter, the left 5.5 millimetres in diameter. The external ocular movements are normal. There is a doubtful weakness of the right side of the face and slight deafness of the left ear. Weber's test is not referred. There is a slight degree of neck rigidity.

9.1.31.

To-day there is no headache. The mental state is normal. The pupils are equal in size and react to light as before. To rough tests, there is restriction of the lower half of the visual field in the right eye. He is able to read small print with the right eye, but there is no vision in the left eye.

Neck rigidity to-day is very slight.

15.1.31.

He is able to read the paper quite easily. He has slight headache when he wakens in the morning. The visual field of the right eye was charted and is shown in Fig. 24

RE-EXAMINATION. 13-8-31.

The patient felt a little confused after the accident, but feels that his thoughts are becoming clearer. He has returned to his work at the railway station and carries it out without difficulty. There are no other post-concussional disturbances. There is no question of compensation. The left eye is still quite blind and the left optic disc is very pale. The visual field in the right eye is as before.

CASE NO. 124. J.B. (F.) Age 40. Ward 14.

Admitted 27.10.30. Discharged 8.11.30.

HISTORY.

The patient was in good health at the time the accident occurred. On the day of admission, while stepping off a tram, she was knocked down by a motor car. She was rendered unconscious and was brought immediately to the Infirmary. A quarter of an hour after admission she is reported to have become more deeply unconscious. The pulse rate, which was 60 on admission, fell to 40, and her respirations to 16 per minute. She was reported by the nurse to have had a fit, associated with shaking of the right side of the body. Blood pressure was found to be 190/90.

EXAMINATION. At 11 p.m. on the day of admission.

The general condition is good. The blood pressure 135/80. There is laceration of the occipital region. There is no evidence of haemorrhage from the nose or ears. The patient is restless and unable to answer questions. She has vomited on several occasions. The plantar reflexes both give an extensor response, but otherwise no abnormality was detected on physical examination.

PROGRESS. 28.10.30.

To-day the patient is conscious and lies quietly. She is able to answer questions correctly. Pulse rate, 70. Temperature, 100° F. X-Ray examination of the skull shows there is a linear crack in the occiput on the right side.

EXAMINATION OF THE CEREBRO-SPINAL FLUID. 29.10.30.

Initial pressure is 160 mm. of water. Pressure after removing 5 cc. is 60mm. of water. The fluid is slightly blood-stained and contains numerous flakes of fibrin. The total protein estimation is 20 mgms. per 100 cc. The sugar content is 92 mgms. per 100 cc.

PROGRESS/

CASE NO. 124. (contd.)

PROGRESS. 29.10.30.

The left plantar reflex is still extensor but the right is flexor. Otherwise no abnormality was detected.

31.10.30.

The general condition is good and no abnormality was detected on physical examination. There is still some headache but the pulse is now slower.

Lumbar puncture was carried out.

Initial pressure , 240 mm. of water. Pressure after removing 6 cc., 120 mm. of water.

The fluid is clear and contains only a few red blood cells which, on microscopical examination, show great variation in size. No white cells are seen.

1.11.30.

To-day the patient feels better but is still a little drowsy. Examination shows no abnormality.

7.11.30.

There has been severe headache during the last few days, across the frontal region. It is not throbbing but it prevents the patient from sleeping. Blood pressure 150/80, and there is complete auscultatory gap between the readings 140 and 120.

RE-EXAMINATION. 24.7.31.

The patient states that she spent 8 weeks in bed after returning home, and that severe headaches continued until May 1931. These were so severe that she felt she was "going off her head". She would spend three or four days each week in bed on account of the severity of the pain and while the pain was present her whole head felt as though it were swimming. She does not yet feel well. She has great difficulty in remembering recent events and much puzzling is necessary before she remembers what has happened during, say, the previous week. She often gets confused as to what day of the week it is.
Previous/

CASE NO. 124. (Contd.)

Previous to her accident her memory was excellent. When speaking to people, her mind often turns completely blank for a few seconds, so that she forgets what she has been saying.

She still suffers from headaches but these are improving. They are always present when she wakens in the morning and are never throbbing. She has not become nervous, but gets very depressed and is very easily worried.

When her headache was severe she used to be afraid she would murder her children.

The compensation question is not fully decided but she says she cannot afford to bring the case to court.

340

GROUP B

CASE NO. 125. H.J.G.S.(M) Age 13. Ward 18.

Admitted 11.4.31. Discharged 18.4.31.

Occupation - School-boy.

HISTORY.

The patient was in good health at the time the accident occurred. On the morning of admission at 11.30. a.m., while riding on the back-step of a bicycle he was thrown to the ground. He was admitted to hospital 6 hours later.

EXAMINATION 12.4.31.

The general condition is good. There is a bruise in the left frontal region. There is evidence of previous haemorrhage from the left nostril and there is subconjunctival haemorrhage in the upper side of the left eye. The patient is now fully conscious. He remembers intending to go out on his bicycle yesterday but has no further recollection of events until he woke up in hospital soon after admission. There is no headache apart from some pain in the bruised area, and there is no vomiting. Examination of the nervous system shows no abnormality.

PROGRESS. 14.4.31.

The patient is now quite well. He now remembers setting off on a bicycle about mid-day and standing on the back-step, but has no further recollection of what happened. There is no diplopia or giddiness and examination shows no abnormality.

X-RAY EXAMINATION.

Examination of the skull shows no evidence of fracture.

RE-EXAMINATION. 18.10.31.

There have been no post-concussional disturbances. He has been instructed by his doctor to avoid physical efforts on account of his heart, which on examination is enlarged and there is a loud systolic murmur heard over the praecordium which is probably of congenital origin.

GROUP B

CASE NO. 126. L.H.S.(M) Age 31. Ward 12.

Admitted 24.7.31. Discharged 31.7.31.

Occupation + Warehouseman.

HISTORY.

The patient was in good health at the time the accident occurred. On the day of admission at 6.30 p.m., while riding a motor-bicycle, he collided with a motor-car. He was rendered unconscious and was admitted to the Infirmary an hour later.

EXAMINATION. 29.7.31.

There is extensive bruising of the frontal region but no evidence of haemorrhage from the nose or ears. There is a subconjunctival haemorrhage on the outer side of the left eye. There are no injuries to other parts of the body. The patient is fully conscious. He remembers riding his bicycle not far from where the accident occurred. Thereafter he has no recollection of events until he was being put to bed in hospital. There has been no headache and no vomiting. Examination of the nervous system shows no abnormality.

X-RAY EXAMINATION.

Examination of the skull shows no evidence of fracture.

~~RE-~~EXAMINATION. 14.1.32.

The patient states that he rested for a few days after the accident and then returned to work. Complete recovery had then occurred and there have been no post-concussional disturbances.

GROUP B.

CASE NO. 127. J.S.(M)Age 22. Ward 13.

Admitted 24.11.30. Discharged 1.12.30.

HISTORY.

The patient has had a tuberculous abscess in his groin during the past 4 years and has had 3 operations in the past for tuberculous glands in the neck, otherwise he was in good health at the time the accident occurred. At 2 p.m. on the day of admission while riding a bicycle, he charged into a wall. He was rendered unconscious and was brought to the Infirmary where he was admitted an hour later. He was reported very aggressive on admission and did not recover full consciousness for an hour or two.

EXAMINATION. 26.11.30.

The general condition is good. The blood pressure is 150/80. There is a bruise in the left frontal and parietal regions. There is no evidence of previous haemorrhage from the ears but he was reported to be bleeding from the nose on admission. There are no injuries to other parts of the body. The patient is now fully conscious. There is no headache and no vomiting. Apart from a slight degree of neck rigidity there is no abnormality on examination of the nervous system.

X-RAY EXAMINATION.

Examination of the skull shows a suspicious appearance in the frontal area which may be due to the presence of a small fracture.

EXAMINATION of the CEREBRO-SPINAL FLUID. 28.11.30.

Initial pressure-----280 mm. of water.
Pressure after removing 5ccs. ---- 240 mm.
of water.

The fluid is clear and colourless. There is no clot formation.

Cell/

Cell count. There are no red cells. There are 3 white cells per c.mm., all of which are small lymphocytes. The total protein estimation is 31 mgms. per 100ccs. The blood pressure before the lumbar puncture is 105/60, after the lumbar puncture 90/50.

PROGRESS. 1.12.30.

The patient says he is now quite well.

RE-EXAMINATION. 1.12.30.

The patient states that he rested in bed for two days after returning home. He had then recovered completely and has had no post-concussional disturbances. There is no question of compensation.

GROUP B.

CASE NO. 128. W.S. (M) Age 33. Ward 18.
Admitted 13.6.31 Discharged 17.6.31
Occupation - Corporation worker.

HISTORY.

The patient had had six pints of beer before the accident occurred. On the evening of admission, he fell down-stairs. He was brought to the Infirmary about 10 p.m. and did not recover consciousness until the following morning.

EXAMINATION. 14.6.31.

The general condition is good. There is a cut in the occipital region. There is no evidence of previous haemorrhage from the nose or ears. There are no injuries to other parts of the body. There is slight frontal headache but no vomiting. Examination of the nervous system shows no abnormality apart from a slight degree of neck rigidity.

X-RAY EXAMINATION.

Examination of the skull was not carried out.

RE-EXAMINATION. 15.12.31.

The patient states that he remained off work for a week after leaving hospital. There have been no post-concussional disturbances except that when he played football two months after the accident he found that heading the ball made him feel dizzy and gave him a headache.

GROUP B

CASE NO. 129. C.S.(M) Age 30. Ward 18.
 Admitted 14.3.31. Discharged 28.3.31
 Occupation - Builder's labourer.

HISTORY.

The patient was in good health at the time the accident occurred. On the day of admission, while climbing up a roof, the ladder gave way and he fell to the ground. He was rendered unconscious and was brought to the Infirmary where he was admitted about 1 p.m. There was bleeding from his nose but none from his ears.

EXAMINATION. 15.3.31.

The general condition is good. The blood pressure is 120/65. There is a bruise in the region of the left temple. There is evidence of previous haemorrhage from the nose but none from the ears. Apart from an injury to the left shoulder, there is no damage to other parts of the body. The patient is now fully conscious. He remembers working about 9 a.m. but has no further recollection of events until he was in the ambulance being brought to the hospital. There is a severe dull, throbbing pain above both eyes. There is no vomiting. The left pupil is slightly larger than the right. The right plantar reflex gives an extensor response, the left, a flexor response. Otherwise no abnormality was detected on physical examination.

X-RAY EXAMINATION.

Examination of the skull shows no abnormality.

EXAMINATION OF THE CEREBRO-SPINAL FLUID. 21.3.31.

The pressure was not recorded. The fluid was clear and colourless. There were 700 red blood cells per c.mm. There were 9 white cells per/

CASE NO. 129. (Contd.)

per c.mm. 90% of the latter were small lymphocytes, the remainder being polymorphs. The total protein estimation was 31 mgms. per 100 ccs. The Wassermann reaction was negative. There was no excessive globulin and the colloidal gold curve showed no abnormality.

PROGRESS. 23.3.31.

The patient has only had slight headache since the lumbar puncture was performed. Previously it was very severe. The pain is throbbing in character and is felt more on the right side than on the left. The pupils today are equal in size and there is nystagmus. Examination shows no abnormality except that the right plantar reflex gives an indefinite response. The left plantar reflex is quite normal. He finds that his headache is made worse if he tries to read.

RE-EXAMINATION. 10.10.31.

The patient did not rest in bed and returned to work seven weeks after the accident. He still suffers occasionally from a dull headache which is felt mainly in the right side of the head, and is more apt to come on in dull weather. It is also aggravated by stooping. He was unable to sleep for three weeks after discharge from hospital. There are no other post-concussional disturbances. There is no question of compensation. Examination shows no abnormality.

GROUP B

CASE NO. 130. M.S. (M) Age 19. Ward 18.
Admitted 8.8.31. Discharged 15.8.31
Occupation - Wireless mechanic.

HISTORY.

The patient was in good health at the time the accident occurred. At 10 a.m. on the day of admission while riding a motor-bicycle, he swerved to avoid a collision and was thrown to the ground. He was unconscious for a few hours and was brought to the Infirmary where he was admitted about 11 a.m.

EXAMINATION. 9.8.31.

There is a bruise in the left temporal region. There is no evidence of previous haemorrhage from the nose or ears. The mental state is now normal. The patient remembers being near to where the accident occurred but has no further recollection of events until he woke up about two hours later. There is no headache or vomiting. Examination of the nervous system shows no abnormality.

X-RAY EXAMINATION.

Examination of the skull shows no evidence of fracture.

RE-EXAMINATION. 15.12.31

The patient states that he returned to work a week after discharge. There have been no post-concussional disturbances except that occasionally he feels dizzy for a few seconds if he bends his head backwards and looks up. There is no question of compensation.

GROUP B

CASE NO. 131. W.S. A male aged 32. Ward 12.

Admitted 25.4.31. Discharged 4.5.31.

Occupation - Railway clerk.

HISTORY.

The patient was in good health at the time the accident occurred. At about 10 p.m. on the day of admission, he was found unconscious at the foot of a flight of stairs. He was brought to the Infirmary and bleeding was noticed from the nose.

EXAMINATION. 27.4.31.

The general condition is good. There is a bruise in the right frontal region. There is no haemorrhage from the nose or ears. There are no injuries to other parts of the body. The mental state is normal. The patient remembers beginning to go upstairs but has no further recollection of events until he woke up in hospital. There has been no headache or vomiting. Examination of the nervous system shows no abnormality.

X-RAY EXAMINATION.

Examination of the skull shows no evidence of fracture.

PROGRESS. 2.5.31.

The patient feels quite well. There is no headache, giddiness or diplopia.

RE-EXAMINATION. 31.7.31.

The patient lay in bed for 2 weeks after returning home. The general condition is good. Complete recovery has occurred, and he returned to work 6 weeks ago. The only complaint he has is that he has great difficulty in falling asleep since the accident. He never sleeps before 4 or 5 a.m. and is often drowsy during the day, especially after dinner. Examination shows no abnormality.

GROUP B.

CASE NO. 132. H.M. (F) Age 40 Ward 5.

Admitted 14.5.31. Discharged 19.5.31

Occupation - Housewife.

HISTORY.

The patient was in good health at the time the accident occurred. On the day of admission, at about 12.20 p.m., while crossing the road, she was knocked down by a bus. She was rendered unconscious and was brought at once to the Infirmary where she was admitted half-an-hour later. She recovered consciousness in the course of three or four hours and on admission was reported to be considerably shocked.

EXAMINATION 15.5.31.

The general condition is good. There is a laceration of the scalp in the right parietal region and bruises in the left parietal region. There is blood in the right ear but no evidence of haemorrhage from the left ear or nose. There is no subconjunctival haemorrhage and no injuries to other parts of the body. The patient is now fully conscious. There is moderate headache referred to the frontal and occipital regions. She has vomited on several occasions since admission. The left plantar reflex gives a doubtful response, the right is quite normal. Examination shows no further abnormality.

X-RAY EXAMINATION.

Examination of the skull shows an extensive crack extending from the right to the left side in the region of the frontal-parietal suture involving both temporal bones and extending into the frontal region.

PROGRESS. 18.5.31.

There/

CASE NO. 132. (Contd.)

There is no deafness but there is still some blood in the right ear. Both plantar reflexes are now normal and no other abnormality is present.

RE-EXAMINATION. 12.1.32.

The patient states that she lay in bed for six weeks after discharge. Her general health is good but her memory is defective. She has difficulty with her speaking and she not infrequently uses the wrong word. She has to be particularly careful when writing letters as she is very apt to make mistakes. While shopping she may forget what she has gone to buy. These lapses of memory are so definite that her relatives have noticed them. She is still suffering from severe headaches. These are often present when she wakens in the morning and in the evening when she feels tired. They are greatly aggravated by any excitement. Soon after discharge she was much troubled with dizziness especially on standing up or on stooping to the ground. She has not become nervous and has no difficulty in sleeping. She remembers all events clearly to within a few seconds of when the accident occurred. Her memory for remote events is good; it is her memory for recent occurrences which is so defective. There is no question of compensation. Examination shows no abnormality except a slight degree of tenderness over the scar in the scalp.

351

GROUP B

CASE NO. 133. W.W.(M.) Age 19 Ward 16.

Admitted 11.8.31. Discharged 17.8.31.

Occupation - Pit-head worker.

HISTORY.

The patient was in good health at the time the accident occurred. On the day of admission at 2.30 p.m., while leaning on a rail, it gave way and he fell a distance of 7 or 8 feet. He was rendered unconscious, was brought to the Infirmary and recovered consciousness in the course of about two hours. There was no bleeding from the nose or ears.

EXAMINATION. 12.8.31.

The general condition is good. There is a bruise in the right frontal region. There is no evidence of haemorrhage from the nose or ears. There are no injuries to other parts of the body. The patient is quite conscious. He remembers falling but has no further recollection of events until he woke up in hospital. There is no headache or vomiting. Examination of the nervous system shows no further abnormality.

X-RAY EXAMINATION.

Examination of the skull shows no evidence of fracture.

RE-EXAMINATION.

Patient failed to report.

CASE NO. 134. J.W. (M) Age 27 Ward 18.

Admitted 17.1.31 Discharged 24.1.31.

Occupation - Road surfaceman.

HISTORY.

The patient was in good health at the time the accident occurred. On the afternoon of admission, while sitting on a cart, he fell to the ground, a distance of about ten feet. He was rendered unconscious and was brought to the Infirmary immediately. On admission he was found to be very confused and to talk incessantly and irrationally.

EXAMINATION. 18.1.31.

The general condition is good. There is no apparent bruise of the scalp. There is no evidence of haemorrhage from the nose or ears. The mental condition is quite normal. The patient remembers falling but has no further recollection of events until after admission to hospital. There is slight headache across the forehead but there is no vomiting. The right pupil is slightly larger than the left but examination shows no further abnormality.

X-RAY EXAMINATION.

Examination of the skull shows no evidence of fracture.

RE-EXAMINATION. 19.8.31.

The patient states that he lay in bed for two weeks after returning home and recommenced work three weeks later. His general health is good. When he first began to work, he was troubled with dizziness and throbbing in the head when stooping. He still suffers from throbbing pains in the head. These come on for a few seconds and return two or three times a day. He has become rather nervous but he finds that he has made good progress since he recommenced work. His work is interesting and it distracts his attention from the discomfort in his head. There is no question of compensation outstanding. He received 26/6 a week while off work.

GROUP B

CASE NO. 135. J.W.(M) Age 26 Ward 12.

Admitted 24.4.31. Discharged 8.5.31.

Occupation - Motor mechanic.

HISTORY.

The patient was in good health at the time the accident occurred. On the day of admission, at 4 p.m. while riding his motor-bicycle he collided with a bus. He was rendered unconscious and was brought to the Infirmary where he was admitted about an hour later. There was no bleeding from his nose or ears.

EXAMINATION. 27.4.31.

The general condition is good. There is a bruise in the left frontal region. There is no evidence of haemorrhage from the nose or ears and there are no injuries to other parts of the body. The mental state is quite normal. He remembers attending to a car in the work-shop about a quarter of an hour before the accident occurred. There is no further recollection of events until after admission to hospital. He understands, however, that he was able to walk to the ambulance and to protest against being brought to the Infirmary. For twenty-four hours after the accident his head felt "thick" but he has had no real headache. There has been no vomiting. The right pupil is slightly larger than the left but examination otherwise shows no abnormality.

X-RAY EXAMINATION.

Examination of the skull shows a small linear crack in the left frontal region.

PROGRESS. 2.5.31.

Today the patient feels well. There is no headache or giddiness.

RE-EXAMINATION/

CASE NO. 135. (Contd.)

RE-EXAMINATION. 14.1.32.

The patient states that he rested in bed for three weeks after discharge and returned to work seven weeks after the accident. He has practically no headache since discharge and there has been no dizziness or nervousness. in fact his friends say that while riding a motor-bicycle he is more daring than previously.

CASE NO. 136. M.W. (F) Age 11. Ward 8.

Admitted 5.8.31. Discharged 18.8.31.

Occupation - School-girl.

HISTORY.

The patient was in good health at the time the accident occurred. On the day of admission at 10.30 a.m. she was knocked down in the street by a motor-car. She was brought at once to the Infirmary. There was bleeding from the nose but none from the ears. On admission, she was reported to be very restless and to resent examination.

EXAMINATION. 6.8.31.

There is a bruise in the left frontal and temporal regions. There is no evidence of haemorrhage from the nose and ears. Apart from slight bruises there are no injuries to other parts of the body. Patient is now fully conscious. She has no recollection of events which occurred on the day of the accident previous to admission. She states that she woke up yesterday afternoon. There is no headache or vomiting. The right plantar reflex gives a doubtful response, the left is normal. Otherwise examination shows no abnormality.

X-RAY EXAMINATION.

Examination of the skull shows no evidence of fracture.

RE-EXAMINATION. 7.12.31.

The patient did not rest in bed after returning home and started at once to play as usual. There have been no post-concussional disturbances of any sort.

GROUP B.

CASE NO. 137. J.W. (M) Age 66 Ward 16.

Admitted 16.12.30. Discharged 30.12.30.

HISTORY.

The patient was in good health at the time the accident occurred. At 4.30 p.m. on the day of admission, he was knocked down in the street by a motor-bicycle and side-car. He was rendered unconscious and was brought at once to the Infirmary. There was no bleeding from the nose or ears.

EXAMINATION. 16.12.30. Five hours after admission.

The general condition is good. The blood pressure is 200/95. There is a laceration of the scalp in the occipital region. There is no evidence of previous haemorrhage from the nose or ears. There is a fracture of both bones of the right leg. The patient states that he did not recover consciousness until after admission to the Infirmary. He is now fully conscious. There is no headache or vomiting. Examination of the nervous system shows no abnormality.

X-RAY EXAMINATION.

Examination of the skull shows no evidence of fracture.

PROGRESS. 22.12.30.

Today there is no headache, neck rigidity nor vomiting. The blood pressure is 185/90.

RE-EXAMINATION. 17.8.31.

The patient was unable to report in person as he has been transferred to Bangour Hospital. His wife states that he cut his throat about December of last year, was taken to Ward 3 and was then transferred to Bangour Hospital. He had been very troublesome at home and his wife had become very frightened of what he might do.

GROUP C.

CASE NO. 138. A.A.(F) Age 7. Ward 11.
Admitted 17.4.31. Discharged 29.4.31.
Occupation. - School-girl.

HISTORY.

The patient was in good health at the time the accident occurred. At 10 a.m. on the day of admission she fell down-stairs. She did not lose consciousness at first. There was bleeding from her nose but none from her ears. She, however, became drowsy and was admitted to hospital next day and she remained drowsy and vomited several times in the course of the following twenty-four hours.

EXAMINATION. 20.4.31.

The general condition is good. There is no evidence of haemorrhage from the nose or ears. The mental state is now quite normal. There is no headache. The right plantar reflex gives an extensor response, the left is normal. Examination otherwise shows no abnormality.

X-RAY EXAMINATION.

Examination of the skull shows no evidence of fracture.

RE-EXAMINATION. 10.10.31.

The patient's mother states that her daughter was quite well after leaving hospital and did not rest in bed. Complete recovery has occurred, and there have been no post-concussional disturbances.

GROUP C.

CASE NO. 139. E.B.(F) Age 36. Ward 8.

Admitted 12.11.30. Discharged 17.12.30.

Occupation - Laundry worker.

HISTORY.

The patient is deaf but otherwise was in good health at the time the accident occurred. At 6 p.m. on the day of admission, she was knocked down by a motor-car in the street. She was rendered unconscious and brought at once to the Infirmary. There was bleeding from the nose but none from the ears.

EXAMINATION. 12.11.30. Three hours after admission.

The patient lies quietly in bed. The skin is moist. The pulse is full and the breathing is shallow. The temperature is subnormal. The blood pressure is 125/75. There is no apparent injury to the scalp. There is evidence of previous haemorrhage from the nose but none from the ears. There is a fracture of the left clavicle but no other injuries. The patient is deeply stuporose and very resistive of any interference. She is unable to speak. Both plantar reflexes give an extensor response. There is no neck rigidity. The tendon reflexes are present and no other further abnormality was detected on examination.

PROGRESS. 13.11.30.

The patient is still stuporose. She is very resistive, turns away from the light and demands verbally to be left alone. Her speech is quite distinct. The reflexes are as before. The blood pressure is 125/75.

14.11.30.

The patient is very restless. She responds to a few simple questions. The blood pressure/

CASE NO. 139. (Contd.)

pressure is 125/75.

EXAMINATION of the CEREBRO-SPINAL FLUID. 14.11.30.

Initial pressure - - - - - - - -230 mms. of water
Pressure after removing 10 ccs. 110 mms. of water
The fluid was uniformly blood stained and on settling the supernatant fluid was yellow in colour. There is no clot formation.

Cell Count.

Red blood corpuscles - - - - - - - 14,500 per cm
White blood cells - - - - - - - - 13 " "
Differential count.

There are 38 per cent of small lymphocytes and 62 per cent of large mononuclear cells. The total protein estimation is 75 mgms. per 100 ccs

PROGRESS. 21.11.30.

There was little change in the mental condition following the last lumbar puncture but the patient is now mentally normal and is no longer restless. The Cerebro-spinal fluid today is clear and colourless. It contains 12 red blood cells per c.mm. and 2 small lymphocytes per c.mm. The total protein content is 25 mgms. per 100 c.cs.

X-RAY EXAMINATION.

Examination of the skull shows no evidence of fracture.

RE-EXAMINATION. 7.8.31.

The patient states that she remained in bed for two weeks after discharge and started work again on 7.4.31. She still suffers from a heavy, throbbing feeling in the head which is worst when she wakens in the morning. She sometimes feels dizzy and has become nervous, especially when crossing the road. She sleeps well but often wakens suddenly saying, "OH! my head". There is no question of compensation. Examination shows no abnormality.

GROUP C.

CASE NO. 140. A.B. (M) Age 31. Ward 16.
Admitted 14.7.31. Discharged 30.7.31.
Occupation - Winding engine-man.

HISTORY.

The patient was in good health at the time the accident occurred. On the day of admission, while riding a motor-bicycle, he collided with a car and was thrown through its wind-screen. He was rendered unconscious and was brought to the Infirmary, where he arrived about 1 p.m. There was no bleeding from the nose or ears but on admission he was reported to be very shocked.

EXAMINATION. 19.7.31.

The general condition is good. There is a laceration of the right side of the face and the right frontal region. There is no evidence of previous haemorrhage from the nose or ears. There is a subconjunctival haemorrhage in the right eye. There are lacerations to both legs but no injuries to other parts. The mental state is normal. The patient remembers being within a quarter of a mile off where the accident occurred. Thereafter he has no recollection of events until he woke up in hospital on the day following. There is pain in the head. He vomited once or twice on the day of admission. The right eye has been destroyed. The left plantar reflex gives an extensor response, but otherwise there is no abnormality on examination.

X-RAY EXAMINATION.

Examination of the skull was not carried out.

RE-EXAMINATION. 10.12.31.

The patient states that before discharge he was transferred to the Eye department, where the damaged eye was removed. He rested in bed for a week and returned to work two weeks ago. Complete recovery has occurred. There have been no post-concussional disturbances. There is no question of compensation. He received 25/- a week in sickness benefit while off work.

361

GROUP C

CASE NO. 141. R.B.(M) Age 60 Ward 10.

Admitted 16.11.30. Discharged 13.12.30.

Occupation - Pit worker.

HISTORY.

The patient was in good health at the time the accident occurred but was reported to have had something to drink. At 9 p.m. the day before admission, he was knocked down in the road by a cyclist. He was apparently able to walk home thereafter, but was so dazed at home that he was brought to the Infirmary the following day, where he was admitted. There was bleeding from the nose but none from the ears.

EXAMINATION.

The general condition today is good. The blood pressure is 200/110. There is a bruise in the right temporal region and a dark ring of effusion round both eyes. There is evidence of previous haemorrhage from the nose but none from the ears. There is a subconjunctival haemorrhage in the right eye. There are no injuries to other parts of the body. The patient is in a stuporose condition. He is very irritable, restless and resistive. His speech is meaningless, he pays no attention to what is said to him. The pupils are equal and react normally. The motor functions and tendon reflexes are normal. The right plantar reflex gives an extensor response and the left gives a doubtful response. There is incontinence of urine and faeces. There is marked neck rigidity.

X-RAY EXAMINATION.

Examination of the skull shows two linear cracks running from the vault of the right side into the bones of the fossa.

EXAMINATION OF THE CEREBRO-SPINAL FLUID. 17.11.30.

Initial pressure-----140 mms of Water.
Pressure after removing 10c.cs.-- 60mms. of Water

There was no immediate effect on the patient. The fluid was uniformly blood stained and on standing the supernatant fluid was yellow in/

CASE NO. 141. (Contd.)

in colour. There was no clot formation. There were 250,000 red blood cells per c.mm. and 520 white blood cells per c.mm. 85 per cent of the latter were polymorphs, 9 per cent were small lymphocytes and 6 per cent werelarge mononuclear cells. The total protein content of the fluid was 1,144 mgms. per 100 c.cs.

PROGRESS. 18.11.30.

The patient's condition is unchanged. There is still marked rigidity.

19.12.30.

Neck rigidity is still pronounced. The patient is still in a state of stupor. He answers all enquiries in the same way - "I'm quite all right" - there is no response to simple commands. The blood pressure is 175/100. The right plantar reflex gives an extensor response and the left a flexor response. Examination otherwise shows no abnormality.

24.11.30.

The patient today is more drowsy. He resists all interference and often calls out "Oh! my God." The blood pressure is 180/108. Neck rigidity is still pronounced. Cerebrospinal fluid examination was carried out with considerable difficulty owing to the patient's violent restlessness. The pressure of the fluid was 190mms. of water. There were 2500 red blood cells per c.mm. and 26 white cells per c.mm. 7 per cent of the latter were polymorphs, 15 per cent were small lymphocytes and 78 per cent were large mononuclears. The total protein content of the fluid was 69 mgms. per 100 ccs. The patient's condition improved immediately after the lumbar puncture.

26.11.30.

The patient is much more lively and talkative. He has, however, some difficulty in finding his words and perseverates. He fails to respond to commands and is unable to name objects. His answers to all questions are more or less meaningless.

28.11.30.

The/

The mental condition is as before. Today he is able to ask what the time is, and reads the time correctly on a watch. There is less neck rigidity. The blood pressure is 170/110.

8.12.30.

The patient now talks more. The sentences are grammatical and very simple. He has no knowledge of where he is or why he is in hospital. He names two objects correctly and then fails with others. He can carry out only the simplest commands. He repeatedly asks for his clothes to go home. The speech is clear. The right plantar reflex still gives an extensor response, and the right abdominal reflexes are absent, and the right arm and leg jerks are exaggerated. Otherwise there is no abnormality.

RE-EXAMINATION. 8.8.31.

The patient's general condition is good. His memory is somewhat defective. He requires plenty of time to speak and sometimes uses the wrong word. He is able to do his work quite as well as previously. There is no headache or giddiness. He has completely lost his sense of smell and there has been a ringing noise in the left ear since his accident, especially when he bends his head down. There is some loss of sensation over the right upper lip and right side of the nose. There is very slight deafness in the left ear and the Weber test is to the right. With the digit retention test he succeeds with 7 digits and fails with 8. Examination otherwise shows no abnormality.

364

GROUP C

CASE NO. 142. J.B. Age 19. Ward 18.

Admitted 22.8.31. Discharged 10.9.31.

Occupation - Motor-mechanic.

HISTORY.

The patient was in good health at the time the accident occurred. On the day of admission, while riding his motor-bicycle, he collided with a lorry. There was bleeding from his nose and right ear. He was rendered deeply unconscious and was brought to the Infirmary.

EXAMINATION. 23.8.31.

There is a bruise in the right frontal region. There is no evidence of previous haemorrhage from the nose or ears. There are no injuries to other parts of the body. The patient is in a stuporose state. He is very irritable, restless, and resistive. His speech is meaningless and he is evidently suffering from severe headache. There is pronounced neck rigidity but no other abnormality was detected on examination.

X-RAY EXAMINATION.

There is a linear fracture of the right parieto-temporal region.

PROGRESS. 26.8.31.

Today the patient's condition is better. He is able to name objects correctly but is quite disorientated. His headache is very severe. His visual acuity is good. There is doubtful weakness of the right side of the face and the patient is a little deaf in both ears. There is pronounced neck rigidity and Kernig's sign is positive on both sides. Examination of the reflexes and motor functions shows no abnormality.

RE-EXAMINATION. 15.12.31.

The patient lay in bed for half of each day/

CASE NO. 142. (Contd.)

day for three months after discharge. He has not yet returned to work. His memory is good but there are some things he cannot remember so well as previously. He has no recollection of any event which occurred during the six days preceding the accident. His memory of events before this is also somewhat defective. He remembers that he had holidays last year but has difficulty in remembering some of the events which occurred at that time. His relatives have noticed that he is very irritable, easily loses his temper and gets very excited. He is still suffering from severe frontal, throbbing pain which is worst on rising in the morning and may last throughout the whole day. This however, is gradually improving. He was very nervous when he first began to go out after the accident. He still has considerable difficulty in falling asleep. He states that when he is free from headache he feels quite fit. There is no question of compensation. Examination shows no abnormality.

366

GROUP C

CASE NO. 143. P.B. Age 20. Ward 18.

Admitted 30.5.31. Discharged 23.6.31.

Occupation - Estate worker.

HISTORY:

The patient was in good health at the time the accident occurred. On the day of admission, while riding his motor-bicycle, he collided with a motor-car. He was rendered deeply unconscious and was brought at once to the Infirmary.

EXAMINATION. 31.5.31.

There is a bruise in the left frontal region. There is evidence of previous haemorrhage from the nose but none from the ears. There is subconjunctival haemorrhage on the outer side of the left eye. There are no injuries to other parts of the body. The patient is comatose and does not respond to painful stimuli. No speech is possible. Both the plantar reflexes give an extensor response and there is marked neck rigidity. Otherwise no abnormality is detected on examination.

PROGRESS. 1.6.31.

The patient is still deeply unconscious. He does not speak and is resistive of any interference. Neck rigidity is still very pronounced, and the plantar reflexes both give an extensor response. Otherwise no abnormality is detected. The blood pressure is 150/80.

4.6.31.

The patient is still stuporose. He is able to speak but his speech is confused. He asks the examiner repeatedly to go and buy him 3d. worth of chips.

EXAMINATION/

367

CASE NO. 143. (Contd.)

EXAMINATION OF THE CEREBRO-SPINAL FLUID. 5.6.31.

Initial pressure-----370 mm. of Water.
Pressure after removing 5c.cs. 340 " " "

The fluid is clear and colourless and no clot forms on standing. There are 50 red blood cells per c.mm. Total protein content is 44 mgms. per 100 c.cs. Sugar content of the cerebro-spinal fluid is 143 mgms. per 100 c.cs.

14.6.31.

The patient is still dazed but is speaking much more. His manner of speech is often impertinent. He gives incorrect answers when asked what year it is and is unable to say when the War began. With the digit retention test, he succeeds with 4 digits but fails with five. He is unable to subtract 7 from 100. He names objects correctly. He says he has no headache and says there is nothing wrong with him. He has no recollection of seeing the examiner previously. He does not remember the name of the cigarettes he smokes.

18.6.31.

The patient is rather childish but much more conscious. He remembers the brand of cigarette he smokes but is still unable to make simple arithmetical calculations. On examination there is definite papilloedema with haemorrhages on both sides but the patient states he has no headache. The movements of the left arm are slightly unsteady, but otherwise there is no abnormality on examination.

19.6.31.

The patient is still improving but is still childish and excessively familiar with his attendants. There is still pronounced papilloedema with haemorrhages.

EXAMINATION/

CASE NO. 143. (Contd.)

EXAMINATION OF THE CEREBRO-SPINAL FLUID.

Initial pressure is 150 mms. of water.
Pressure after removing 5c.cs. is 115mms. of water.

The fluid is clear and colourless and contains one lymphocyte per c.mm. The total protein content is 20mgms. per 100 c.cs. The sugar content is 108 mgms. per 100 c.cs.

X-RAY EXAMINATION.

Examination of the skull shows a fracture of the middle fossa of the skull extending upwards.

RE-EXAMINATION. 16.12.31.

The patient states that he returned to work a month after leaving hospital. He remembers all events up to ten minutes before the accident occurred. Thereafter he has no further recollection of occurrences for a period of three weeks. He states that complete recovery has occurred. There have been no post-concussional disturbances of any sort. There is no question of compensation outstanding. He received £30. There is now no papilloedema and no other abnormality was detected on examination.

369.

GROUP C

CASE NO. 144. H.B. Age 19. Ward 3 (18)
Admitted 9.11.30. Discharged 29.11.30.
Occupation - Forester.

HISTORY.

Before admission the patient had had three glasses of beer, according to his own account, and was reported to be smelling of drink after the accident. On the day of admission while riding a motor-bicycle, he collided with a pedal cycle. He was rendered deeply unconscious and was brought to the Infirmary.

EXAMINATION. 10.11.30.

The blood pressure is 145/85. There is a bruise in the frontal region and the right eye is closed with effusion. There is evidence of previous haemorrhage from the nose but none from the ears. There is a subconjunctival haemorrhage in the right eye. There are no injuries to other parts of the body. The patient is deeply stuporose, is restless and resistive and is unable to speak. The right arm is, if anything slightly weaker than the left. The reflexes, however, are all normal with the exception of the plantar reflexes both of which give extensor responses. There is marked neck rigidity and Kernig's sign is slightly positive.

EXAMINATION of the CEREBRO-SPINAL FLUID. 10.11.30.

Initial pressure is over 330 mms. of water. Pressure after removing 5 c.cs. is 300 mms. of water. The fluid is uniformly blood stained and the supernatant fluid is yellow in colour. There are 70,000 red blood cells per c.mm. and 70 white cells per c.mm. Of the latter, 29 per cent are polymorphs, 54 per cent small lymphocytes and 17 per cent large mononuclears. The total protein content is 306 mgms. per 100 c.cs. The blood pressure before lumbar puncture was 145/85, after lumbar puncture it was 130/70.

PROGRESS/

CASE NO. 144. (Contd.)

PROGRESS. 11.11.31.

The breathing today is more natural. The patient is still in the same deeply stuporose state. Some weakness of the right arm is still demonstrable. The examination of the cerebro-spinal fluid shows that the initial pressure is 70 mms. of water. The pressure after removing 7 ccs. is 40 mms. of water. There are 41,000 red blood cells per c.mm. and 215 white blood cells per c.mm. Of the latter, 43 per cent are polymorphs, 39 per cent large mononuclears and 18 per cent are small lymphocytes. The total protein content is 175 mgms. per 100 c.cs. The blood pressure is 124/75.

12.11.30.

Today the patient is more conscious and has become very resistive of interference. The cerebro-spinal fluid pressure today is 190 mms. of water. There are 12,800 red blood cells per c.mm., and 12 white blood cells per c.mm. 33 per cent of the latter are large mononuclears and 67 per cent are small lymphocytes. The total protein content is 94 mgms. per 100 c.cs.

13.11.30.

There is still some weakness of the right arm and leg. Today, for the first time, he has been able to say a few words.

14.11.30.

EXAMINATION of the CEREBRO-SPINAL FLUID.

The initial pressure is 120 mm. of water, The fluid is yellow and clear. There are 800 red blood cells per c.mm. one small lymphocyte per c.m. The total protein content is 50 mgms. per 100 c.cs. Today the patient is able to say several/

CASE NO. 144. (Contd.)

several words.

20.11.30.

The patient today, is much more conscious and speaks impudently to his attendants.

X-RAY EXAMINATION.

Examination of the skull shows a linear crack in the right parietal region.

RE-EXAMINATION. 16.12.31.

The patient remained in bed for six weeks after leaving hospital. He recommenced work four months after the accident. He states that he remembers being within three miles of where the accident occurred. He has no recollection of being in the Infirmary and the first day he remembers was the first of January, a month after leaving hospital. He states that when recovering consciousness, he began to speak about events which had occurred ten years previously and then gradually remembered events which had occurred more recently. He is at present studying for the entrance examination for the police force but he finds that he is unable to spell properly although he can do his arithmetic as well as previously. When he started work, he was unable to remember the names of people and could not even remember his "girl's" surname. These, however, have gradually returned to his memory. His people say that he is much quieter than before the accident. He apparently had a fit two months ago, as he suddenly lost consciousness and had to be carried into the house. There have been no headaches or dizziness. There is no nervousness and he rides his motor-bicycle with as much confidence as ever. There is no question of compensation and examination shows no abnormality.

GROUP C.

CASE NO. 145. I. H. B. Age 70. Ward 5.
Admitted 27.11.30. Discharged 16.12.30.

HISTORY.

On the day of admission the patient fell downstairs. She was rendered unconscious and was brought to the Infirmary.

EXAMINATION. 28.11.30.

The pulse is full. The respirations are deep and the skin is warm. The blood pressure is 155/75. There is no apparent injury to the scalp, but there is haemorrhage from the right ear. There are no injuries to other parts of the body. The patient is in a stuporose state. She is very irritable and restless. She fails to respond to commands and repeatedly says "Where is John". There is no vomiting. There is a slight degree of neck rigidity but otherwise examination of the nervous system shows no abnormality. The pulse is irregular and the right side of the heart is enlarged. A systolic murmur is heard in all areas.

PROGRESS. 1.12.30.

The patient's condition is unchanged.

4.12.30.

The patient is still very restless. She is quite unaware of where she is and is unable to recognise her friends.

16.12.30.

The patient is still dazed but realises where she is, and can recognise her friends.

X-RAY EXAMINATION.

There is a linear fracture on the right side of the vault running into the base.

RE-EXAMINATION.

Patient failed to report.

GROUP C.

CASE NO.146. R.B. Age 16. Ward 7.
Admitted 11.3.31. Discharged 17.4.31.
Occupation - Slater.

HISTORY.

The patient was in good health at the time the accident occurred. On the day of admission, while working on a roof, he slipped and fell to the ground, a distance of about 25 feet. He landed on his head and shoulders and was rendered deeply unconscious. He was brought at once to the Infirmary, where he was admitted at 10 a.m. He was reported to be very shocked on admission. There was bleeding from the nose and from both the right and the left ear.

EXAMINATION at 7 p.m. on the DAY of ADMISSION.

The patient's skin is warm and dry. Breathing is deep. Pulse rate 100. Temperature 99.4°F. Blood pressure 100/50. There is bleeding from both ears and the patient swallows repeatedly owing to haemorrhage from his nose. There is no subconjunctival haemorrhage. The patient moves restlessly in bed. He is deeply unconscious, does not respond to painful stimuli and is unable to speak. He has vomited on two of three occasions and the vomit contains blood. The right pupil is slightly larger than the left - both react normally to light. The knee jerks are present and both plantar reflexes show an extensor response.

PROGRESS. 12.3.31.

To-day the patient is more restless and tries to get out of bed. He repeatedly calls out "Oh dear". The pupils to-day are equal. There is no paralysis of the face and no hemiparesis. There is marked neck rigidity. The blood pressure to-day is 105/70.

14.3.31.

The patient is still deeply stuporose but resists/

CASE NO. 146. (Contd.)

resists any interference strongly. There is marked horizontal coarse nystagmus on looking to the left. He tends to curl up on his side and bury his face in the pillow.

EXAMINATION of the CEREBRO-SPINAL FLUID. 14.3.31.

Initial pressure 330 mm. of water. Pressure after removing 5 cc. 260 mm. of water. 20cc. of fluid were removed and the pressure was then 200 mm. of water. The fluid is uniformly blood-stained and the supernatant fluid is yellow in colour. No clot forms on standing. There are 17,000 red blood cells per c.mm. and 76 white cells per c.mm. The total protein estimation is 138 mgms. per 100 cc.

15.3.31.

To-day the patient is even more restless and constantly requires attention to prevent him from getting out of bed. He calls out repeatedly saying, "Oh father, this is terrible", and also uses words which are quite meaningless. He appears to be suffering severely as he frequently screws his face up as if in pain.

16.3.31.

To-day the patient lies quietly, burying his head in the bedclothes. He calls out occasionally. There is no response to questions and he has a vacant appearance. He is not so resistive. There is slight coarse nystagmus. There is no weakness of either side of the body. There is a slight degree of neck rigidity.

18.3.31.

To-day the condition is unchanged. There is no response to questions or commands. He resists examination and kicks out strongly when this is attempted. Otherwise he lies quietly, making no complaint. When shown a pencil, he shows no sign of recognising what it is. The right pupil is slightly larger than the left. The knee jerk, if anything, is more active on the right side. Both plantar reflexes give an extensor response.

20.3.31/

CASE NO. 146. (Contd.)

20.3.31.

The patient to-day lies quietly but, as before, he resists examination. To-day he is able to give his name but other questions are answered meaninglessly. He responds to one simple command correctly but fails with the second.

26.3.31.

To-day the patient is sitting up in bed and is taking an interest in his surroundings. He answers questions, such as "How are you?", and "What is your name?", correctly, but further questions confuse him and he answers them all with "Robert Brown", which was the answer to one of the first questions. The right plantar reflex is extensor, the left is flexor. The arm jerks, if anything, are more active on the right side. The right pupil is still slightly larger than the left. There is no nystagmus and no neck rigidity.

9.4.31.

To-day the patient greets the examiner with a friendly smile and attempts to answer everything he is asked. He is however unable to answer any but the simplest questions, except with vague meaningless replies. He is unable to recognise a pencil and cannot use it. He is unable to read.

16.4.31.

To-day the patient is more lively but rather childish. There is some evidence of slight visual field defect on the right side. There is a doubtful weakness of the right side of the face, and the right arm is slightly unsteady. The right plantar reflex gives an extensor response, the left is still flexor. He is to-day much more intelligent and inclined to be impertinent. He describes the Sister in the ward as the "person that does no work", and tells her that the nurses only work when she is there.

The cerebro-spinal fluid examination to-day is -

Initial pressure 100 mm. of water.

Pressure after removing 5 cc. 60mm. of water.

The total protein content is 25 mgms. per 100 cc.

There are 2 small lymphocytes per c.mm. Otherwise there are no cells. The sugar content of the/

CASE NO. 146. (Contd.)

the fluid is 61 mgms. per 100 cc.

Blood Sugar examination. 12.3.31.

At 10.30 a.m. 167 mgms. per 100 cc.

At 1 p.m. 125 mgms. per 100 cc.

At 4 p.m. 143 mgms. per 100 cc.

13.3.31.

At 12.25 p.m. 143 mgms. per 100 cc.

14.3.31.

At 10.30 a.m. 154 mgms. per 100 cc.

X-ray examination of the skull shows an extensive fracture at the base.

RE-EXAMINATION. 5.8.31.

The patient lay in bed for a week after discharge. His memory is very poor and he is very easily confused. He remembers seeing the examiner previously, but his mother says that he is unable to remember a message and is therefore unable to do any shopping unless the details are written down. His people notice that he is very easily irritated and tends to be depressed. He also readily gets very excited. He is unable either to read or write. He gets very excited about little unimportant matters and then later apologises, saying that he can't help it. His mother states that he remembers going up the ladder just before the accident occurred. He seldom has any headache but he feels dizzy sometimes and has to sit down until the attack passes off. He has some difficulty in expressing himself and everything he says and does is very simple and childish. Examination of the nervous system shows no abnormality.

GROUP C.

CASE NO. 147. P.C. Age 33. Ward 18.

Admitted 1.11.30. Discharged 21.11.30.

Occupation - Delivers papers.

HISTORY.

The patient has always been very short-sighted, and had had a drink before the accident occurred, but otherwise was in good health at the time. At 6.45 p.m. on the day of admission, while going home, he was knocked down by a bus. He was brought at once to the Infirmary a quarter of an hour later, where he was admitted. On admission he was deeply unconscious.

EXAMINATION. 2.11.30.

The general condition is quite good. The blood pressure is 135/88. There is a laceration over the crown of the head. There is evidence of previous haemorrhage from the right ear but none from the nose or left ear. There are no injuries to other parts of the body. The patient is dazed and his speech is confused. There is no headache. He vomited once after admission. There is slight neck rigidity, but otherwise examination shows no abnormality.

PROGRESS. 4.11.30.

The patient is able to respond to simple commands. He talks sensibly but is unable to name objects. The blood pressure is 130/75.

EXAMINATION of the CEREBRO-SPINAL FLUID. 4.11.30.

The initial pressure is 190 mm. of water. Pressure after removing 5 cc. is 100 mm. of water. The fluid is uniformly blood-stained and there is no clot formation. There are 3,000 red blood cells per c.mm. and 3 small lymphocytes per c.mm. The total protein content of the fluid is 20 mgms. per 100 cc.

5.11.30.

To-day the patient is more awake and is much more conscious of his speech defect. He succeeds/

CASE NO. 147. (Contd)

succeeds in naming a pencil but fails with other objects. He is able to write his name. There is slight right facial weakness and the right plantar reflex gives a doubtful response but otherwise examination shows no abnormality.

6.11.30.

The patient responds better to requests but still fails to name objects. The blood pressure is 138/85. The physical examination of the nervous system is as before.

7.11.30.

To-day the patient's condition is much improved. He is able to name several objects and to read the paper. He responds correctly to commands, but with some hesitation. The blood pressure is 120/65.

10.11.30.

To-day the patient has had some fits, involving the right hand and followed by jerking of the right arm. One fit was observed which lasted for 30 seconds. Otherwise the patient feels well. Examination of the nervous system is as before.

13.11.30.

The Jacksonian attacks are still occurring. The discs are normal. There is no headache and he is able to name objects and to carry out commands, with very little hesitation.

16.11.30.

There is a slight degree of pain over the left side of the head and slight weakness of the right side of the face is still present. He speaks now without hesitation and names objects well. There have been no fits for two days. X-Ray examination of the skull shows no evidence of fracture.

RE-EXAMINATION. 20.8.31.

The/

CASE NO. 147. (Contd.)

The patient states that he rested in bed for a week after discharge, and started work 6 months ago. Complete recovery has not occurred. He has some difficulty with his words and is unable to tell a story owing to this difficulty. He can do his work as well as previously but it tires him much more. He has to run with papers through the traffic and this he finds a great strain. There have been no fits since he was in hospital. He sometimes has a slight dizzy turn, in which "something seems to pass across his head", when lying down or when out in the street. This lasts for a few moments. He has become very nervous. He has received no compensation but feels he is entitled to it. With the digit retention test he succeeds with 7 digits. The patient does not look well. He says his eyesight is as good as ever and examination of the nervous system shows no abnormality.

GROUP C.

CASE NO 148. J.C. Age 33. Ward 12.

Admitted 14.8.31. Discharged 4.9.31.

HISTORY.

The patient was in good health at the time the accident occurred. About 6 p.m. on the day of admission, while riding a motor bicycle, he was involved in a collision and was rendered unconscious. There was bleeding from the nose and the right ear, and he was brought at once to the Infirmary.

EXAMINATION. 22.8.31.

The general condition is now good. There is a cut in the occipital region. A discharge from the right ear commenced 5 days after the accident and has continued since then. Apart from some small cuts, there are no injuries to other parts of the body. The mental state is quite normal. He remembers being on his bicycle about three miles from where the accident occurred. He recovered consciousness about 36 hours later. There has been no headache. He vomited on several occasions during the first two days. The vomit contained blood. Examination of the nervous system shows no abnormality, with the exception of a slight degree of deafness in the right ear. weber's test is referred to the right. X-Ray examination of the skull shows a fracture of the right petrous portion of the temporal bone.

RE-EXAMINATION.

The patient failed to report.

GROUP C.

CASE NO.149. J.C. Age 43. Ward 10.

Admitted 22.3.31. Discharged 15.4.31.

Occupation- Plate-layer.

HISTORY.

The patient was in good health at the time the accident occurred, but he had taken a glass of beer and had had some whiskey shortly before. At 9 p.m. on the day before admission he was found at the corner of the street in a dazed condition. He was taken home where he was very restless and vomited blood. He was admitted to hospital the following morning.

EXAMINATION. 23.3.31.

The skin is warm and the pulse is full. Temperature is 100.5 F. There is a cut in the occipital region. There is evidence of previous haemorrhage from the nose but none from the ears. The patient is in a stuporose state. He is unable to answer questions and his speech is meaningless. He has not vomited since admission to the ward. Both plantar reflexes give an extensor response and there is marked neck rigidity. Otherwise examination of the nervous system shows no abnormality.

CEREBRO-SPINAL FLUID EXAMINATION. 23.3.31.

The initial pressure is 330 mm. of water. Pressure after removing 5 cc. is 250 mm. of water. The fluid is uniformly and deeply blood-stained. The supernatant fluid is yellow in colour. No clot forms on standing. There are 360,000 red blood cells per c.mm. and 1560 white blood cells per c.mm. The total protein content of the fluid is 1394 mgms. per 100 cc.

24.3.31.

The initial pressure is 330 mm. of water. Pressure after removing 10 cc. is 190 mm. of water. The fluid is deeply blood-stained and has/

CASE NO.149 (Contd.)

has a slightly turbid appearance. There are 150,000 red blood cells per c.mm. and 6000 white blood cells per c.mm. Of the latter 90% are polymorphs, 10% are large mononuclears. The total protein content of the fluid is 831 mgms. per 100 cc. Sugar content is 42 mgms. per 100 cc.

PROGRESS. 25.3.31.

To-day the patient is able to answer a few questions correctly but he is still disorientated as regards both time and place. He complains of severe pain across the forehead. There is marked neck rigidity and Kernig's sign is slightly positive.

CEREBRO-SPINAL FLUID EXAMINATION.

The initial pressure is 80 mm. of water. Pressure after removing 5 cc. is 50 mm. of water. The fluid is fairly clear and brown in colour. There are 17,000 red blood cells per c.mm. and 920 white blood cells per c.mm. 85% of these latter are polymorphs, 5% are small lymphocytes, and 10% are large mononuclears. The total protein content is 250 mgms. per 100 cc. To-day the patient's temperature has fallen to normal.

26.3.31.

To-day the patient is more alert mentally. He lies quietly, knows his name and his age but is unable to give either the year or the month correctly. He thinks that he was admitted to hospital this morning and has no recollection of seeing the examiner previously. He says he feels quite well, apart from severe frontal headache. There is marked neck rigidity and Kernig's sign is positive. Examination of the nervous system shows no further abnormality.

30.3.31.

The patient has no recollection of ever seeing the examiner before. He is still suffering from slight headache. He says he has been in hospital for 8 weeks and talks meaninglessly about an operation he has had. He is still unable/

CASE NO. 149. (Contd.)

unable to tell the year or the month but is able to talk a little about his work.

9.4.31.

To-day the patient is cheerful and talkative. There is still slight headache. He knows he is in Edinburgh but does not know in which hospital. He remembers being at a football match a few days before the accident occurred, but has no further recollection of events until he woke up in hospital a few days ago, about 10 days after the accident. To-day he knows the month and the year and can name objects correctly. He converses intelligently and his thoughts appear to be clear. There is marked deafness in the right ear. Otherwise examination shows no abnormality.

14.4.31.

There is a slight throbbing pain across the forehead. Otherwise the patient feels well. With the digit retention test he succeeds with seven digits without difficulty.

X-RAY EXAMINATION.

The skull shows a linear fracture of the occiput.

RE-EXAMINATION. 25.1.32.

The patient states that he remembers up to within a few seconds of the accident occurring. He is unable to work because of difficulty in walking. His people notice that he is very irritable and often he is slow in understanding. There have been no headaches. He often takes giddy turns in which he has to steady himself for a few seconds. His walking has become very unsteady, so much so that he is afraid to go out of the house. This has been worse during the last two or three months. There is some hesitation in his speaking. There is no nervousness and no difficulty in falling asleep. Examination shows that there is marked deafness in the right ear and some deafness also in the left ear. There is no facial weakness. Walking is very unsteady - he staggers to one or other side. Examination of the reflexes shows no abnormality. The deafness is much worse than when he first left hospital and there is no sign of improvement. There is no question of compensation.

GROUP C.

CASE NO.150. G.C. Age 48 Ward 18.

Admitted:15.8.31.

HISTORY.

The patient was in good health at the time the accident occurred. On the day of admission he was knocked down in the street, was rendered unconscious, and was brought to the Infirmary.

EXAMINATION. 16.8.31.

The patient's general condition is good. There is no apparent injury to the scalp. There is no evidence of previous haemorrhage from the nose or ears. He lies quietly and takes no interest in his surroundings. He is slightly dazed and confused. There is no headache. The right plantar reflex gives an extensor response and there is slight neck rigidity. Otherwise examination of the nervous system shows no abnormality.

X-RAY EXAMINATION.

Examination of the skull was not carried out.

RE-EXAMINATION.

The patient failed to report.

GROUP C

CASE NO. 151. R.D. Age 27. Ward 18
Admitted 3.5.31.
Occupation Rabbit catcher.

HISTORY.

The patient was in good health at the time the accident occurred. On the day of admission while riding his motor bicycle, he collided with a tar barrel at the edge of the road. He was rendered unconscious, and was at once brought to the Infirmary.

EXAMINATION 3.5.31. At 11 a.m.

The skin is warm. The pulse is full and respirations are normal. There is evidence of previous haemorrhage from the right ear but none from the nose. The patient is deeply stuporose, restless and unable to speak. He has vomited on two or three occasions. There is marked neck rigidity and both plantar reflexes give an extensor response. There is also retention of urine. Examination of the nervous system otherwise shows no abnormality.

CEREBRO-SPINAL FLUID EXAMINATION. 4.5.31.

The initial pressure is 380 mm. of water. Pressure after removing 5 cc. is 300 mm. of water. The fluid is uniformly blood-stained and the supernatant fluid is yellow in colour. There are 12,000 red blood cells per c.mm. and 23 white blood cells per c.mm. 30% of the latter are polymorphs, 45% are small lymphocytes, and 25% are large mononuclear cells. The total protein content is 60 mgms. per 100 cc. The Wassermann reaction is negative.

To-day the patient is violently restless and requires to be strapped down in bed. He is very resistive of any interference and is hypersensitive/

CASE NO. 151. (Contd.)

hypersensitive to any painful stimuli. There is marked neck rigidity. There is weakness of the right side of the face. Both plantar reflexes give an extensor response.

5.5.31.

Today the patient lies quietly with his eyes closed, but fights violently against the straps which hold him in bed, and calls out loudly. The pupils are equal. There is weakness of the right side of the face and marked neck rigidity.

CEREBRO-SPINAL FLUID EXAMINATION.

The initial pressure is 280 mm. of water. Pressure after removing 5 cc. is 265 mm. of water. The fluid is uniformly blood-stained. There are 380 red blood cells per c.mm. and 18 white blood cells per c.mm. All of the latter are small lymphocytes. The total protein content is 63 mgms. per 100 cc. and the sugar content is 100 mgms. per 100cc.

6.5.31.

The patient is still violent and wildly restless and requires still to be strapped in bed. He responds to simple commands. He attempts to bribe his attendants to allow him up. There is some neck rigidity. The pupils are equal. There is no weakness of one side.

7.5.31.

To-day the patient's attitude is less aggressive. A few of his words are intelligent. He shakes the examiner warmly by the hand. He is unable to respond to simple commands. He is inclined to weep.

9.5.31.

The patient is cheerful and talkative. Much of what he says is meaningless but some of his sentences are correct. He says he has been here for two years. Sentences often begun correctly/

CASE NO.151. (Contd.)

correctly end meaninglessly. He weeps when prevented from getting up, and promises to return again if he will be allowed to go home. After being restrained for a time he sits up in bed and talks vehemently but meaninglessly, in an attempt to persuade his attendant to allow him up. The reflexes are normal.

10.5.31.

The patient is unable to name objects and is unable to carry out simple commands. He is very friendly and offers to take one of the nurses for a walk.

14.5.31.

Speech is still meaningless and the patient is unable to respond to commands. He complains frequently of pain in his head. He does not resist examination as previously. Examination shows no abnormality apart from a certain degree of neck rigidity.

16.5.31.

To-day the patient is able to say a few correct sentences. He pleads pathetically to be allowed to get out of the ward. Many of his words are meaningless and he shows no sign of realising that his speech is incorrect. For the first time he is able to put out his tongue when asked to do so. He is unable to carry out any more complicated instructions.

19.5.31.

To-day the patient is very talkative, like an intoxicated street-corner orator, he emphasises all he says with powerful gestures, and announces in a loud voice his great ability as a sheep-shearer, and a trout fisher. He promises to pay the Sister and the doctor if they/

CASE NO. 151. (Contd.)

they will allow him to go home. He talks incessantly and repeats arguments over and over again. Most of the sentences are correct but some of his words are meaningless. He pays little attention to what is said to him and has no appreciation of where he is, nor has he any insight into his condition.

CEREBRO-SPINAL FLUID EXAMINATION.

The initial pressure is 225 mm. of water. Pressure after removing 5 cc. is 180 mm. of water. There were no cells in the fluid.

20.5.31.

The patient still talks volubly about his ability to shear sheep and catch rabbits. He is quite unable to appreciate anything that is said to him, and no argument has any effect. He is inclined to be both affectionate and tearful. He repeatedly asks to be allowed home and repeats his arguments over and over again.

25.5.31.

To-day the patient has insight into his condition. He remembers driving along the road at 35 miles an hour as he wanted to get home before dark. He actually remembers colliding with the tar barrel on the road. He remembers seeing the examiner previously and remembers that he was very troublesome in the ward. He now feels extremely apologetic, He remembers that he required to be strapped in bed. There is now no giddiness. He feels quite well, as though he could start work at once. He now talks quite sensibly and has fully recovered consciousness. There is still deafness in the right ear. Air conduction is better than bone conduction.

26.5.31.

The patient feels quite well and is enjoying a pipe.

X-RAY EXAMINATION.

The skull shows a fracture in the right temporal/

CASE NO. 151. (Contd.)

temporal region.

RE-EXAMINATION. 16.12.31.

The patient recommenced work 6 weeks after leaving hospital. He says that he has completely recovered from his accident. He has now no recollection of hitting the tar barrel on the road which caused the accident but he remembers all events clearly to within a few minutes of when the accident occurred. The only fact he has forgotten is the number of sheep he counted 5 or 6 hours before the accident - he has now no idea, at all, what this number was. He thinks he can do his work better than ever, but while he says there is no change in his personality, his doctor thinks he is much more talkative and perhaps just a little childish. There has been no headache, giddiness or difficulty in speaking. He is not in the least nervous and drives his motor bicycle as fast as ever. There is no question of compensation. Examination shows no abnormality.

GROUP C.

CASE NO. 152. A.D. Age 25. Ward 10.

Admitted 21.6.31. Discharged 29.7.31.

Occupation - Insurance surveyor.

HISTORY.

The patient was in good health at the time the accident occurred. Late in the evening on the day of admission, when riding a motor bicycle he collided with a motor bus. He was at once rendered unconscious. There was bleeding from his left ear and he was brought at once to the Infirmary. On admission he was reported to be dazed but was able to answer questions.

EXAMINATION. 22.6.31.

The general condition is good. There is a cut below the chin. There is evidence of previous haemorrhage from the left ear but none from the nose or right ear. There is some doubt as to whether some cerebro-spinal fluid has escaped from the left ear. There is a fracture of the left arm and leg. Patient is in a dazed condition and he has vomited to-day. The pupils are both small, irregular in outline, and do not react to light. The knee jerks are absent. Both plantar reflexes give a flexor response. There is marked neck rigidity.

EXAMINATION of CEREBRO-SPINAL FLUID, by the HOUSE SURGEON.

The fluid was clear and colourless. There was 1 white cell per c.mm. The Wassermann reaction was negative. There was no increase of globulin in the fluid.

PROGRESS. 25.6.31.

At the moment the patient talks intelligently but he is reported to have been talking nonsense. There is marked headache. The optic discs are normal. The left pupil is slightly/

slightly larger than the right and both give the Argyll-Robertson reaction. There is marked neck rigidity. The reflexes are as before.

29.6.31.

The patient has been delirious during the night. He has been in South Africa, Berlin, Antwerp, and yesterday was having hallucinations. He believes the examiner, however, when it is explained to him that these experiences were not real, though to him they were extremely vivid. He is still suffering from severe headache, especially when he moves his head. There is some deafness of the left ear and Weber's test is referred to the left. There is a slight degree of neck rigidity still present.

7.7.31.

To-day the patient is quite well and rational. He remembers that a week ago he thought he had been in India, Africa, and other places. There is still a dull pain across the forehead which is worse on moving the head. There is no neck rigidity. Examination is as before.

X-RAY EXAMINATION.

The skull shows a fracture in the left temporal region.

RE-EXAMINATION. 25.1.32.

The patient was off work for 16 weeks in all, on account of the injury to his leg and arm. His memory is not as good as before the accident. He has difficulty in remembering the names of streets which he previously knew well. He still occasionally suffers from headache and this is apt to be severe after working hard. There is no dizziness or nervousness. The question of compensation is not yet settled, but it is the damage to the arm and leg for which he is claiming compensation principally. He understands that while in the ward he gave a vivid description to a visitor of native conditions in Morocco, whereas in reality he has never been in Morocco and has no knowledge of the conditions in that part. He has also never been in the places in which he pictured his various experiences while he was delirious. On examination, the patient still has Argyll-Robertson pupils, and absent knee jerks. There is no deafness and there has been no discharge from his ear.

GROUP A.

CASE NO. 153. I.G. Age 70. Ward 15.
Admitted 18.11.30. Discharged 4.12.30.
Occupation - Housewife.

HISTORY.

On the day of admission at 10p.m. while crossing the street the patient was knocked down by a motor-car. She was at once rendered unconscious and was brought to the Infirmary. Bleeding was noticed from her nose and left ear.

EXAMINATION. 19.11.30.

The patient lies quietly. The strength of the pulse is good. The blood pressure is 115/65 mm. There are bruises in the frontal region with effusion around both eyes. There is haemorrhage from the nose and left ear. There is sub-conjunctival haemorrhage in both eyes. There are no injuries to other parts of the body. The patient is deeply stuporose and is unable to speak. She lies quietly if undisturbed, but resists any interference. There is no vomiting. The pupils are equal but both are irregular in outline. The right arm is used less than the left. The tendon reflexes are equal on each side. Both plantar reflexes give an extensor response. The patient is incontinent of faeces and has retention of urine.

PROGRESS.

The patient remained deeply unconscious for four days. During this period she was very restless and resistive. On 20.10.30. she developed a cough with crepitations at the bases of both lungs.

1.12.30.

The patient is still a little confused, but is able to recognise the examiner for the first time. She talks continuously about nothing in particular. The blood pressure is 150/70.

X-RAY EXAMINATION.

X-ray examination of the skull was not carried out.

RE-EXAMINATION.

The patient failed to report.

GROUP A

CASE NO. 154. A.G. A male aged 29. Ward 18.

Admitted 2.6.31. Discharged 10.7.31.

Occupation - News Vendor.

HISTORY.

The patient was in good health at the time the accident occurred. On the evening of admission he was involved in a street accident, but the details of this could not be obtained. He was rendered unconscious and was brought at once to the Infirmary.

EXAMINATION. 21.6.31.

The general condition is fair. The blood pressure is 105/70 mm. There is evidence of previous haemorrhage from the nose but none from the ears. There is no sub-conjunctival haemorrhage. The patient is in a very dazed condition but can be roused with difficulty to answer a simple question. Speech is normal. There is a moderate degree of headache. Examination of the nervous system shows no abnormality apart from a marked degree of neck rigidity.

PROGRESS. 22.6.31.

The patient is still in a very drowsy condition and can be roused only with difficulty. He resists examination and there is a very marked neck rigidity. He is still complaining of severe headache. There is no vomiting. The blood pressure is 120/70. Examination of the reflexes shows no abnormality.

23.6.31.

The patient is still drowsy, but can talk intelligently when roused. There is still severe pain across the forehead. Full examination of the nervous system is to-day possible and no abnormality is detected apart from a marked degree of neck rigidity. The blood pressure is 100/70.

25.6.31.

The patient to-day is more awake, but is still incontinent. There is no headache but neck rigidity is marked.

EXAMINATION. /

CASE NO. 154. (Contd.)

EXAMINATION of the CEREBRO-SPINAL FLUID. 25.6.31.

Initial pressure ----- 370mm. of water.
 Pressure after removing 5cc. --- 300mm. of water.

The fluid is deeply blood stained. On standing the supernatant fluid is yellow in colour. There is no clot formation. There are 52,000 red blood cells per c.mm., and 280 white blood cells per cmm. 50% of the latter are polymorphs; 10% are small lymphocytes; 40% are large mononuclear cells. The total protein content is 375mgms. per 100ccs. The sugar content is 125 mgms. per 100ccs.

28.6.31.

The patient is still drowsy and incontinent. He is, however, more awake, and says he is feeling better. There is a moderate degree of headache, and neck rigidity is still very pronounced. Kernig's sign is strongly positive. There is fine, horizontal nystagmus on looking to the right. Otherwise there is no abnormality on examination.

30.6.31.

There has been no headache either to-day or yesterday. There is no neck rigidity and no nystagmus.

EXAMINATION of the CEREBRO-SPINAL FLUID. 30.6.31.

Initial pressure ----- 220 mm. of water.
 Pressure after removing 5cc. -- 200 mm. of water.

The fluid is clear but dark brown in colour. There are 650 red blood cells per c.mm., and 60 white blood cells per c.mm. 90% of the latter are small lymphocytes, and 10% are large mononuclear cells. The total protein content is 119mgms. per 100 ccs. The sugar content is 100mgms. per 100ccs. There is no clot formation.

2.7.31.

To-day the patient feels very well, but was incontinent once yesterday. He is beginning to feel/

CASE NO. 154. (Contd.)

feel anxious to get out of bed.

X-RAY EXAMINATION.

X-ray examination of the skull shows a fissure fracture through the occiput.

22.6.31.

At 11a.m. blood sugar content was 222 mgms. per 100ccs., and on 23.6.31. at 3p.m. was 200 mgms. per 100 ccs.

RE-EXAMINATION. 15.12.31.

The patient says that he lay in bed for five weeks after returning home. He recommenced work two months after the accident, but is still only doing a half day's work. He feels tired on going upstairs, but admits that before his injury he had been paid off owing to slackness at his work. His wife says that he has changed since his accident, but she cannot say exactly in what way. Otherwise there are no post-concussional symptoms and examination shows no abnormality.

396

GROUP C.

CASE NO. 155. W.G. Age 21. Ward 13.
Admitted 17.11.30. Discharged 1.12.30.
Occupation - Shepherd.

HISTORY.

The patient was in good health at the time the accident occurred. On the day of admission, while riding a motor-bicycle, he collided with a motor-car. He was rendered unconscious and was brought to the Infirmary an hour and a half later, where he was admitted.

EXAMINATION ON ADMISSION.

The skin is warm and dry. The breathing is normal. The pulse rate is 60 and the temperature is 96.8° Fahr. There is a laceration of the scalp in the right temporal region. There is no evidence of haemorrhage from the nose or ears. There is an injury to the right shoulder which is later shown to be a fracture of the scapula. The patient is in a stuporose state. He is very irritable and restless and his attempting to speak results in a very confused jumble of words. There is no vomiting. The left plantar reflex gives an extensor response, while the response on the right side is indefinite. There is a slight degree of neck rigidity, otherwise examination of the nervous system shows no abnormality.

EXAMINATION of the CEREBRO-SPINAL FLUID. 19.11.30.

Initial pressure is 110 mms. of water. The fluid is slightly but uniformly blood stained. There is no clot formation. There are 8,700 red blood cells per c.mm. and 2 small lymphocytes per c.mm. The total protein content is 31 mgms. per 100 c.ccs.

PROGRESS. 20.11.30.

The patient has been definitely more conscious since lumbar puncture yesterday. He is, however, disorientated and does not know what year it is. He is unable to name objects. The left plantar reflex still gives a definite extensor response while the response on the right side is doubtful. It is apparent today that there/

CASE NO. 155. (Contd.)

there has been a gross injury to the brachial plexus and all the muscles of the right upper extremity are powerless. There is slight sensory loss in the outer side of the right shoulder but otherwise there is no loss of sensation.

22.11.30.

The patient is able to name a few objects correctly but often uses the wrong word without realising that he has made a mistake. He is able to carry out simple instructions but is quite disorientated and says that the year is 1908 or 1909. There is a slight degree of headache, otherwise no symptoms.

1.12.30.

Today the patient is going home. He has no recollection of events leading up to the accident and has no further memory of occurrences until yesterday when he woke up. He does not remember seeing the examiner before. Today he is fully conscious and discusses his condition normally. There is still gross paralysis of the right upper extremity.

X-RAY EXAMINATION.

Examination of the skull shows no evidence of fracture.

RE-EXAMINATION. 23.7.31.

The patient states that he lay in bed for a month after discharge and that during that period he had no headache or giddiness, thereafter he gradually returned to his full work. He remembers attending to his sheep on the forenoon of the day of admission but has no further recollection of events which occurred on that day. His memory is quite clear. There has been no headache but he had had a few dizzy turns. These have not been associated with loss of consciousness. Otherwise he is in good health but there is still some weakness of the right upper extremity, especially of the deltoid muscle.

GROUP C

CASE NO. 156. P.H. Age 24. Ward 16.
Admitted 20.6.31. Discharged 4.7.31.
Occupation - Plasterer.

HISTORY.

The patient was in good health at the time the accident occurred. On the day of admission, he was involved in an accident while riding his motor-bicycle. He was brought at once to the Infirmary. Bleeding was noticed from his nose, but none from his ears.

EXAMINATION. 21.6.31.

The patient's general condition is now good. The blood pressure is 120/60. There is a compound depressed fracture of the left occipital region. There is evidence of previous haemorrhage from the nose but none from the ears. The patient is still dazed. The speech is normal. There is a moderate degree of headache and there has been some vomiting. Both plantar reflexes give an extensor response and there is some weakness of the right side of the face. Otherwise there is no abnormality on examination.

PROGRESS. 22.6.31.

The patient is still dazed and lies quietly. There is a slight degree of neck rigidity. There is weakness of the lower part of the right side of the face. The right plantar reflex gives an extensor response, the left a flexor response. The blood pressure is 115/65.

23.6.31.

The patient remembers leaving home on his bicycle about 8 p.m. on the day of admission. Thereafter he has no recollection of what occurred. He is now fully conscious. There is still some weakness of the lower part of the right side of the face and the right plantar reflex still gives an extensor response. There is a slight degree of neck rigidity. The blood/

CASE NO. 156. (Contd.)

blood pressure is 110/65.

25.6.31.

The patient is quite conscious. There is still some headache in the frontal region and the reflexes are as before.

28.6.31.

The patient now remembers that he had driven through Gullane on the night of the accident. There is no giddiness nor diplopia and he is sleeping well. Examination is as before.

2.7.31.

The patient feels quite well. There is slight weakness of the right side of the face still present and both plantar reflexes now give a flexor response.

RE-EXAMINATION.

The patient failed to report.

GROUP C

CASE NO. 157. P.K. Age 6. Ward 18.
Admitted 9.5.31. Discharged 20.5.31.

HISTORY.

The patient was in good health at the time of the accident. On the day of admission he was knocked down in the street by a motor-car and was brought at once to the Infirmary where he was admitted at 4 p.m.

EXAMINATION. 10.5.31.

The general condition is good. There is a laceration of the scalp in the frontal region and effusion which closes the right eye. There is no evidence of haemorrhage from the nose or ears and there are no injuries to other parts of the body. The patient lies quietly, but resists any interference. He vomited frequently before admission. Examination of the nervous system shows no abnormality.

PROGRESS. 17.5.31.

The patient is now fully conscious. He has always been deaf and is obviously a very strong visualist. Examination shows no abnormality.

RE-EXAMINATION. 16.12.31.

The patient's mother says he has completely recovered from the accident. There have been no post-concussional symptoms and she states that in her opinion, his hearing is definitely better since the accident.

401

GROUP C.

CASE NO. 158. T.K. Age 25. Ward 18.

Admitted 9.11.30. Discharged 20.11.30

Occupation - Groom.

HISTORY.

The patient was in good health at the time the accident occurred. Late in the evening of 8.11.30. while riding a motor-bicycle, he collided with a pedal cyclist. He was rendered unconscious and was brought to the Infirmary where he was admitted at 4.15 a.m. He was apparently able to walk into the Out-patients department where he was found to be very dazed.

EXAMINATION. 9.11.30.

The general condition is good. The blood pressure is 120/65. There is a depressed compound fracture in the left frontal region with marked effusion around both eyes. There is a subconjunctival haemorrhage in the left side. There are no injuries to other parts of the body. The patient is in a stuporose state. He is irritable, restless and resistive. His speech, however, is clear and he is able to answer simple questions. There is a marked degree of frontal headache. He has vomited repeatedly since admission. No abnormality was detected on examination of the nervous system.

PROGRESS. 10.11.30.

To-day the effusion around the eyes is subsiding. There is no neck rigidity but there is slight frontal headache. The blood pressure is 118/70. Full examination shows no abnormality.

13.11.30.

The pulse is slower and the patient is suffering from throbbing headache. There is no neck rigidity.

15.11.30/

CASE NO. 158. (Contd.)

15.11.30.

There is still headache. The eyes water excessively and are sensitive to light.

X-RAY EXAMINATION.

Examination of the skull shows extensive fracturing of both frontal bones.

RE-EXAMINATION. 18.8.31.

The patient states that he lay in bed for two weeks after discharge. He began work two months after the accident. He has suffered from a severe cough since the accident but brings up no sputum. His eyesight is as good as ever but after leaving hospital he had pain after reading and things he looked at appeared blurred. He was unable to read for a period of six weeks after leaving hospital. There has been no diplopia. He remembers coming to the place at which the accident occurred but thereafter he has no recollection of events for a period of three days. He still suffers from severe headaches. This is a throbbing persisting type of pain which is most severe when he awakens in the morning, and when he bends down to the ground. It is more apt to come on when the weather changes and is greatly aggravated by excitement. It was particularly severe after attending a football match. Otherwise there are no post-concussional disturbances. There is no question of compensation outstanding. Examination shows a marked depression in the frontal region but otherwise no abnormality.

GROUP C.

CASE NO. 159. D.L. Age 3. Ward 17.

Admitted 2.5.31. Discharged 15.5.31.

HISTORY.

The patient was in good health at the time the accident occurred. On the day of admission he was knocked down by a motor-bicycle. He was rendered unconscious and brought at once to the Infirmary where he lay in a restless and irritable state for three or four days.

EXAMINATION. 7.5.31.

There is a compound depressed fracture of the left occipital region and a large wound of the scalp in this situation. There is no evidence of previous haemorrhage from the nose or ears. The mental state is now normal. There has been no vomiting since admission. The right pupil is slightly larger than the left. The right plantar reflex gives an extensor response, the left is normal. Examination otherwise shows no abnormality.

X-RAY EXAMINATION.

Examination of the skull was not carried out.

RE-EXAMINATION. 16.12.31.

The patient's mother states that he has changed since the accident. He is not so alert mentally and lacks courage to do things on his own. He does not complain of headache or giddiness but has become very nervous, particularly of crossing the road or if strangers come near to him. There is no question of compensation outstanding. His mother received £10. Examination shows no abnormality.

GROUP C.

CASE NO. 160. G.M. Age 20. Ward 13.
Admitted 3.8.31. Discharged 11.8.31.
Occupation - Pit labourer.

HISTORY.

The patient was in good health at the time the accident occurred. At 6 p.m. on the day of admission while riding pillion on a motor bicycle he was involved in a collision with a motor-car. He was rendered unconscious and was brought to the Infirmary.

EXAMINATION. 4.8.31.

There is a laceration of the scalp in the right parietal region. There is no evidence of previous haemorrhage in the nose or ears. There are bruises to other parts of the body but no serious injury. The patient is in a dazed, irritable and restless state. He does not know where he is and does not appear to care. His speech is confused. There is a marked degree of headache and there has been some vomiting. There is a slight degree of neck rigidity but otherwise no abnormality was detected on examination.

X-RAY EXAMINATION.

Examination of the skull shows a fracture of the right temporal, parietal and occipital regions.

Blood sugar estimation.
3.8.31. at 10.45 was 174 mgms. per 100 c.cs.

RE-EXAMINATION. 24.11.31.

The patient states that he lay in bed for three weeks after discharge. He has not been able to recommence his work as he does not yet feel well. His memory is as good as formerly but his relatives noticed that he has become very short tempered. There are no headaches but he is much troubled with dizziness. This is apt to come when stooping to the ground. It is now gradually improving but it is on account of this that he feels unable to do his work. There is no question of compensation outstanding. Examination shows no abnormality.

GROUP C.

CASE NO. 161. R.M. Age 12. Ward 10.

Admitted 19.7.31. Discharged 12.8.31.

Occupation - Schoolboy.

HISTORY.

The patient was in good health at the time the accident occurred. On the day of admission while riding his bicycle, he collided with a motor car. He was at once brought to the Infirmary where he was found to be unconscious, but very restless and resistive. It was also reported that he was pale and cold, and that his pulse was rapid and weak.

EXAMINATION. 20.7.31.

To-day the general condition is good, and he is no longer shocked. There is a laceration of the scalp over the vertex to the right of the mid-line. There is a dark effusion around the left eye. There is no evidence of haemorrhage from the nose or ears. There is a sub-conjunctival haemorrhage in the left eye. There are some wounds of the legs, but otherwise no injuries to other parts of the body. The patient is dazed and restless, but the speech is normal. There is a tendency for the eyes to deviate to the left. The right plantar reflex gives an extensor response, but the response on the left side is normal. There is marked neck rigidity. Otherwise examination of the nervous system shows no abnormality.

PROGRESS. 28.7.31.

The patient is now fully conscious. He remembers being on his bicycle shortly before the accident occurred, but he has no further recollection of events until he awakened on the 23.7.31., four days later. There is no headache, diplopia or giddiness. Examination reveals no abnormality.

X-RAY EXAMINATION.

There is a fracture of the occipital bone on the right side.

RE-EXAMINATION/

CASE NO. 161. (Contd.)

RE-EXAMINATION. 25.1.32.

The patient states that he lay in bed for three weeks after the accident occurred. A few days later he returned to school. There have been no post-concussional symptoms. He does not get nearly as many marks for his work at school, but he says that this is due to his having been off school for so long. Examination reveals no abnormality.

407

GROUP C.

CASE NO. 162. P.M. Age 5. Ward 16.

Admitted 30.6.31. Discharged 11.7.31.

HISTORY.

The patient was in good health at the time the accident occurred. On the day of admission he fell off a wall, and was at once rendered unconscious.

EXAMINATION. 1.7.31.

The general condition is good. There is a cut of the scalp in the left frontal region. There is no haemorrhage from the nose or ears. There are no injuries to other parts of the body. The patient lies quietly and is slightly dazed. His speech is normal. There is a moderate degree of frontal headache, and there has been vomiting. Both plantar reflexes give an extensor response and there is a slight degree of neck rigidity. Otherwise there is no evidence of damage to the nervous system.

PROGRESS. 4.7.31.

To-day the child is fully conscious and playing cheerfully. He began to play yesterday. Full examination of the nervous system shows no abnormality.

RE-EXAMINATION. 9.12.31.

There have been no post-concussional disturbances.

GROUP C.

CASE NO. 163. W.M. Age 22. Ward 10.

Admitted 10.5.31. Discharged 26.5.31.

Occupation - Salesman

HISTORY.

The patient was in good health at the time the accident occurred. On the day of admission while riding a motor-bicycle, he collided with another motor-bicycle. He was at once rendered unconscious and was taken to the Infirmary. On admission he was reported to be in a restless state, and bleeding from the right ear and nose was noticed.

EXAMINATION. 11.5.31.

The general condition is good. There is no apparent bruise of the scalp. There is haemorrhage from the right ear, and evidence of previous haemorrhage from the nose. There are no injuries to other parts of the body. The patient is in a dazed and irritable state, but his speech is quite clear. There is a moderate degree of headache, and he has vomited on two or three occasions. There is weakness of the right side of the face, and a moderate degree of neck rigidity, but otherwise there is no evidence of damage to the nervous system.

EXAMINATION OF THE CEREBRO-SPINAL FLUID. 11.5.31.

Initial pressure-----280 mm. of water.
Pressure after removing 8 c.c.--240 mm. of water.

The fluid is uniformly blood-stained, and the supernatant fluid is yellow in colour. There is no clot formation. There are 27,500 red blood cells per c.mm., and 322 white cells per c.mm., Of the latter, 58 per cent. are polymorphs, 12 per cent are small lymphocytes, and 30 per cent. are large mononuclear cells. The total protein content is 269 mgms. per 100 c.c.. The sugar content of the fluid is 133 mgms. per 100 c.c.. 12 c.c. of fluid were withdrawn, This procedure was followed by aggravation of the headache.

PROGRESS/

CASE NO. 163. (Contd.)

PROGRESS. 13.5.31.

The patient is now fully conscious. He remembers getting ready to go out on his bicycle, but has no further recollection of events until he woke up over 24 hours later. The pupils react normally, but there is some coarse nystagmus on looking to the left. There is a complete right facial paralysis. There is also some deafness of the right ear, and in this ear bone conduction is greater than air conduction. Otherwise examination of the nervous system shows no abnormality.

14.5.31.

The patient is a little restless. Otherwise the examination is as before.

20.5.31.

The patient has little recollection of events occurring in hospital previous to 13.5.31. His thoughts are quite clear now. He feels dizzy when he attempts to sit up in bed. There is slight sensory loss over the right half of the face, and some loss of the sense of taste over the right side of the tongue in its anterior part. Otherwise examination is as before.

26.5.31.

There is now no headache or giddiness. He remembers being ready to leave his home for a short run on his bicycle, but he has no recollection of leaving the house.

X-RAY EXAMINATION.

Examination shows a fracture of the right temporal bone.

RE-EXAMINATION. 25.1.32.

The patient states that he lay in bed for a period of two weeks after discharge from hospital/

CASE NO. 163. (Contd.)

hospital. He then had a holiday for six weeks and returned to work. He has not, however, recovered completely. His memory and mental ability are defective. He sometimes forgets a word, and has particular difficulty in recalling the name of people. When he first resumed his work he had difficulty in thinking things out. For example he had difficulty in dealing with a difficult customer. He still suffers from a feeling of heaviness across the forehead, but this is now improving. He has also experienced some dizziness on suddenly standing up, or on stooping, but this is now also improving. Otherwise there are no post-concussional disturbances. There is no question of compensation outstanding. He received £30. The right facial paralysis has now almost completely recovered. There is still however, some deafness in the right ear, and there is a constant hissing sound in this ear. The tuning fork tests shows that bone conduction is greater than air conduction on the right side. Examination otherwise shows no abnormality.

CASE NO. 164. D.M. Age 25. Ward 3(18).
Admitted 25.7.31. Discharged 15.8.31.
Occupation - Chemist.

HISTORY.

The patient was in good health at the time the accident occurred. On the day of admission while riding his motor bicycle, he was involved in a collision with another motor-bicycle. He was at once rendered unconscious, and was brought to the Infirmary.

EXAMINATION. 26.7.31.

There is no evidence of shock. There is extensive bruising of the frontal region, and the right eye is closed with the resulting effusion. There is evidence of previous haemorrhage from the nose, but none from the ears. There are slight bruises to other parts of the body, but no severe injury. The patient is stuporose: he is restless and resistive, and his speech is meaningless. There is a moderate degree of headache, but no vomiting. Both plantar reflexes give an extensor response, but this is more definite on the right side. The right abdominal reflexes are more active on the left side than on the right. There is a moderate degree of neck rigidity, but otherwise there is no abnormality on examining the nervous system.

PROGRESS. 4.8.31.

The patient is not conscious of his surroundings, but is still slightly dazed. He is fully orientated as regards both time and place. He remembers all the details of his work clearly, and has a faint recollection of being on a motor bicycle, and of thinking that he would have to hurry. He has, however, no idea on what day this occurred. The right pupil/

pupil is larger than the left. There has been diplopia since he recovered consciousness. The false image is seen by the left eye, and its position indicates that movements are defective both to the right and to the left. There is a slight degree of weakness of the right side of the face. The right plantar reflex still gives an extensor response, while the response on the left side is absent. There is no headache. There is some giddiness, especially after smoking.

X-RAY EXAMINATION.

There is a linear fracture of the frontal bone which involves both frontal sinuses.

RE-EXAMINATION. 16.12.31.

The patient states that he lay in bed for a week after returning home. He re-commenced his work on 1.11.31. He now remembers being on his bicycle a few minutes before the accident occurred, and he states that he has no further recollection of events for a period of three days. He can carry out his work as well as ever. There was some dizziness when he first began to get out of bed, but none since. He has not become nervous and has no difficulty in sleeping. There is no question of compensation outstanding. He still has a slight degree of diplopia on looking to the left. There is also slightly less movement of the left side of the face than of the right side. He has noticed a definite coarse tremor of his right hand. This is not demonstrable at present; he notices it especially while he is eating. It does not interfere with the delicate analysing work he has to undertake. He states that when he first got out of bed, there was a slight numbness of the right upper extremity, and his right leg tended to drag. This has now, however, disappeared. There is slight unsteadiness of the right upper extremity in the bumping test, but otherwise no abnormality could be demonstrated.

GROUP C.

CASE NO. 165. M.M. Age 22. Ward 8.

Admitted 19.11.30. Discharged 3.12.30

Occupation - Domestic Servant.

HISTORY.

The patient was in good health at the time the injury occurred. On the evening of admission, while alighting from a bus, she fell to the ground. She was at once rendered unconscious and was brought to the Infirmary. On admission she was found to be in a dazed condition. Bleeding from the nose was noticed, but none from the ears.

EXAMINATION. 20.11.30.

The general condition is good. The blood pressure is 110/60 mm. There is a bruise in the frontal region and a red effusion around the right eye. There is haemorrhage from the nose but none from the ears. There is a subconjunctival haemorrhage in the right eye. There are no injuries to other parts of the body. The patient is in a dazed condition, and says she is unable to think properly. She is, however, fully co-operative in examination. There is severe frontal headache, but no vomiting. There is a slight degree of neck rigidity, but otherwise there is no abnormality on examination of the nervous system.

PROGRESS 27.11.30.

The patient remained in a drowsy state for a period of three days after the accident, thereafter she made a steady recovery. Lumbar puncture was carried out by the House Surgeon, and he reported that the cerebro-spinal fluid was uniformly blood stained.

X-RAY EXAMINATION.

There is a linear crack of the right frontal bone.

Re-EXAMINATION/

414

CASE NO. 165. (Contd)

RE-EXAMINATION. 5.8.31.

The patient states that she lay in bed for a period of two weeks after leaving hospital, and that she returned to work not long after. Complete recovery had then occurred, and there have been no post-concussional symptoms.

415

GROUP C.

CASE NO. 166. W.O'H. Age 9. Ward 18.
Admitted 2.5.31. Discharged 5.5.31.
Occupation - Schoolboy.

HISTORY.

On the day of admission the patient was knocked down in the street by a motor car. He was rendered unconscious, and was at once taken to the Infirmary.

EXAMINATION. 3.5.31.

The general condition is good. There is a laceration of the scalp in the right frontal region. There is no evidence of previous haemorrhage from the nose or ears. There is a subconjunctival haemorrhage on the medial side of the right eye, and also on the lateral side of the left eye. There is some bruising of the chest. The patient is deeply unconscious, and no speech is possible. There is a bilateral extensor response and a marked degree of neck rigidity, but no other abnormality is present on examination of the nervous system.

PROGRESS. 4.5.31.

The patient is now conscious, but is content to lie quietly. He observes what is happening around him, and carries out instructions correctly. Both plantar reflexes still give an extensor response, and some neck rigidity is still present. The patient coughs repeatedly.

10.5.31.

Today the patient is fully conscious and is reading a book. He carries out instructions correctly, and asks to be allowed to get out of bed. Both plantar reflexes still give an extensor response, but otherwise examination of the nervous system shows no abnormality.

RE-EXAMINATION.

The patient failed to report.

CASE NO. 167. R.P. Age 21. Ward 18.
Admitted 23.5.31. Discharged 20.6.31.
Occupation - Apprentice Brick-layer.

HISTORY.

The patient was in good health at the time the accident occurred. On the day of admission while travelling in a motor bus, he put his head out of the window, and it was struck by a standard at the side of the road. He was at once rendered unconscious, and was taken to the Infirmary.

EXAMINATION. 25.5.31.

There is now no evidence of shock. There is a bruise in the right temple, and there is some evidence of previous haemorrhage from the right ear. There is a dislocation of some of the carpal bones, but otherwise no injury to other parts of the body. The patient is deeply stuporose, and his speech is meaningless. Both plantar reflexes give an extensor response, and there is marked neck rigidity. The bladder is greatly distended. Otherwise there is no abnormality on examination.

PROGRESS. 26.5.31.

The patient is still deeply unconscious. He lies quietly, but is very resistive of any interference. Headache is very severe, and neck rigidity is pronounced. Kernig's sign is negative. Both plantar reflexes give an extensor response.

29.5.31.

Today the patient speaks more. He calls out that he wishes to be left alone when examined, and frequently calls out "Oh! my head". The results of examination are as before.

EXAMINATION of the CEREBRO-SPINAL FLUID. 29.5.31.

Initial/

CASE NO. 167. (Contd.)

Initial pressure ----- 260mm. of water.
 Pressure after removing 5c.c. 180mm. of water.
 The fluid is clear, but slightly yellow in colour. There is no clot formation. There are 120 red blood cells per c.mm., and 7 white cells per c.mm. Of the latter, 75 per cent are small lymphocytes, and 25 per cent are large mononuclear cells. The total protein content is 63 mgms. per 100c.cs. The Wasserman reaction is weakly positive. The sugar content of the fluid is 110 mgms. per 100c.c.

X-RAY EXAMINATION.

There is a fissure fracture passing up from the internal auditory meatus.

31.5.31.

The patient lies quietly curled up in bed. When examined, he calls out "Oh dear!. I can't get my head sorted". He is today able to ask for a drink and for a cigarette. Both plantar reflexes still give an extensor response, and there is some neck rigidity also present. He is still incontinent.

3.6.31.

The patient speaks more intelligently, and is beginning to take notice of his surroundings. He is still incontinent. There is a slight degree of neck rigidity, and the left plantar reflex gives an extensor response. This reflex on the right side is now normal.

9.6.31.

Today the patient is able to co-operate normally with the examination. He remembers that on the day of the accident he was on his way to attend a football match in Edinburgh, but has no further recollection of events until he woke up about seven days ago. Yesterday he began to have pain behind the left ear, and purulent discharge from this ear has developed. There is still an extensor response on the left side, and the abdominal reflex on that side is less active than on the right. There is no neck rigidity, and Kernig's sign is negative.

12.6.30./

CASE NO. 167. (Contd.)

12.6.30.

There is profuse purulent discharge from the right ear. There is no mastoid tenderness or neck rigidity. Both discs are slightly blurred. There is some deafness of the right ear, and in Weber's test the sound is referred to the right side.

CEREBRO-SPINAL FLUID EXAMINATION. 13.6.31.

Initial pressure ----- 220 mm. of water.
Pressure after removing 5c.c. 170 mm. of water.

The fluid is clear and colourless. There is no clot formation. The total protein content is 20 mgms. per 100 c.c. There are no red blood cells in the fluid, and there are 2 small lymphocytes per c.mm. The sugar content of the fluid is 103 mgms. per 100 c.c.

14.6.31.

The patient states that he feels better today than on any day since the accident. There is no headache, dizziness or diplopia. Examination is as before in every detail.

18.6.31.

Today the patient is very talkative, and talks excessively about his affairs. There is still an extensor response on the left side, but otherwise examination shows no abnormality.

RE-EXAMINATION.

The patient failed to report.

419

GROUP C.

CASE NO. 168. R.P. Age 21. Ward 18.
Admitted 23.5.31.

HISTORY.

On the day of admission, while riding a motor bicycle, the patient was involved in an accident, was thrown to the ground, and was at once rendered unconscious. He was brought to the Infirmary where he was admitted.

EXAMINATION. 24.5.31.

The general condition is good. The blood pressure is 130/70 mm. There is a bruise in the right parietal region, and haemorrhage from the right ear and right nostril. There is a fracture of the right clavicle. The patient is in a dazed condition, but speech is normal. There is a moderate degree of frontal headache and some vomiting. There is a moderate degree of neck rigidity, Examination of the nervous system shows no other abnormality.

X-RAY EXAMINATION OF THE SKULL.

There is a fracture of the right temporal bone extending downwards into the floor of the middle fossa in the region of the internal auditory meatus.

PROGRESS. 4.6.31.

During the last two days, there has been some discharge of pus from the right ear. The patient is a little drowsy. There is some deafness of the right ear, and in the Weber test the sound is referred to the right. There is a slight degree of neck rigidity. Kernig's sign is positive on the left side, but negative on the right side. Full examination elicits no further abnormality.

6.6.31.

The patient is still drowsy and the temperature is above normal. There is very severe headache and slight neck rigidity. Kernig's sign is not definitely positive. There is no tenderness over the mastoid, and no further abnormal signs on examination. The middle ear was seen to be full of pus, and Dr J.S. Fraser decided/

CASE NO. 168.(Contd.)

decided to operate.

OPERATION. 6.6.31.

By means of the mastoid approach, the dura mater of the middle fossa was laid bare on the right side. There was no extra-dural pus, and a hypodermic needle failed to disclose any intradural collection. The wound was therefore closed, and lumbar puncture was performed before the patient left the table. The pressure of the fluid appeared to be greatly raised. About 40 cc. were withdrawn. The fluid was uniformly turbid, but no clot formed on standing. There were 800 white cells per c.mm. 25 per cent of these were polymorphs, 15 per cent were small lymphocytes, and 60 per cent were large mononuclear cells. There were no red cells. Fehling's solution was readily reduced by the fluid, and there were no organisms on direct films.

7.6.31.

There is less headache, but the patient is still a little drowsy. There is some neck rigidity, and Kernig's sign is positive on both sides. The left side of the face moves less than the right, especially on smiling. Otherwise full examination elicits no abnormality.

9.6.31.

To-day the condition is unchanged.

10.6.31.

The temperature has been normal during the last 36 hours. The mental state is normal, but the headache has been very severe during the past few hours. The left side of the face moves less than the right. There is a marked degree of neck rigidity, and Kernig's sign is positive on the left side. Examination otherwise /

CASE NO. 168. (Contd.)

wise shows no abnormality.

12.6.31.

The patient had several generalised fits yesterday. Headache is very severe, and there is some drowsiness and vomiting. The fits began with the head turning to the left. There is no field defect to rough tests, but there is a definite degree of left-sided attention hemianopia. The right pupil is slightly larger than the left. There is some weakness of the left side of the face, left arm and left leg. The tendon reflexes are all exaggerated on the left side. The abdominal reflexes are absent on this side, and there is an extensor plantar response on this side. There is no astereognosis. The patient states that he experienced a strong sensation of smell this morning, and the nurse says that he complained of this.

EXAMINATION of the CEREBRO-SPINAL FLUID.

The initial pressure is 230 mm. The pressure after removing about 5 c.c. is 170 mm. The total protein content of the fluid is 113 mgms. per 100 c.c. The sugar content of the fluid is 105 mgms. per 100c.c. There are 337 white cells per c.mm. 97 per cent of these are small lymphocytes, and 3 per cent are large mononuclear cells.

13.6.31.

Today the condition is as it was yesterday. In view of the above physical signs, Mr Fraser operated a second time, passed a cannula into the right temporal lobe of the brain and drained a large abscess which was situated in that situation.

15.6.31.

There has been no headache or drowsiness for two days, and the patient feels very well. There is no attention hemianopia, no facial weakness, and no weakness of the left arm. The reflexes are now normal.

23.6.31./

CASE NO. 168. (Contd.)

23.6.31.

The mental state is normal. There is no headache. The knee jerk is slightly more active on the left side, but otherwise there is no abnormality on physical examination.

2.7.31.

There is still some discharge from the abscess cavity.

RE-EXAMINATION.

The patient failed to report, but it was ascertained that he was in good health some months after leaving hospital.

GROUP C

CASE NO. 169. A.P. A male aged 25. Ward 18.

Admitted 9.11.30. Discharged 20.11.30.

Occupation - Builder.

HISTORY.

The patient was in good health on the day the accident occurred. On the day of admission, while riding his bicycle, he was involved in an accident, and was subsequently found lying at the side of the road. He was unconscious and was brought at once to the Infirmary. On admission, he was found to be suffering from a marked degree of shock. There was no bleeding from the nose or ears.

EXAMINATION. 10.11.30.

There is now no evidence of shock. There is a bruise above the left eye. There is no evidence of haemorrhage from the nose or ears. There is a sub-conjunctival haemorrhage in the left eye. There are no injuries to other parts of the body. The patient is stuporose; he is very restless and resistive. There has been some vomiting. Both plantar reflexes give an extensor response, and there is a slight degree of neck rigidity. Otherwise examination shows no abnormality.

X-RAY EXAMINATION.

There is a fissure fracture of the left frontal bone.

EXAMINATION OF THE CEREBRO-SPINAL FLUID.

The initial pressure is 90 mm. of water. The fluid is deeply blood-stained, and the supernatant fluid is yellow in colour. There is no clot formation. There are 140,000 red blood cells per c.mm., and 108 white cells per c.mm. Of the latter, 13 per cent are polymorphs, 53 per cent are small lymphocytes and 24 per cent are large mononuclear cells. The total protein content of the fluid is 344 mgms. per 100 c.cs.

11.11.30.

To-day the patient is quite changed. He talks intelligently and has no headache. He remembers being on his bicycle shortly before the accident occurred, but has no further recollection /

CASE NO. 169. (Contd.)

collection of events until he woke up this morning.

12.11.30.

The mental state is normal. There is still an extensor plantar response on both sides, but otherwise there is no abnormality on examination.

RE-EXAMINATION. 18.8.31.

The patient states that he rested in bed for a week after returning home. He returned to his work six months ago. Complete recovery has occurred. During April, he often felt dizzy if he turned his head to the left, but otherwise there have been no post-concussional disturbances. There is a fine tremor of the eyelids and hands; but otherwise there is no abnormality on examination.

CLASS NO. 170. G.R. (M.) Age 70. Ward 7.
Admitted 22.4.31. Discharged 16.5.31.

HISTORY.

The patient was in good health at the time the accident occurred. On the afternoon of admission, he was knocked down in the street, and was at once rendered unconscious. He was brought to the Infirmary where he was found to be in a very restless and irritable condition.

EXAMINATION. 23.4.31.

The general condition is good. The blood pressure is 200/110 mm. There is a bruise of the chin, and there are circles of dark-coloured effusion around both eyes. There is evidence of previous haemorrhage from the nose, but none from the ears. His speech is normal. but he is in a very irritable and restless state. There is a moderate degree of headache, but there is no vomiting. There is a slight degree of neck rigidity, but examination, shows no further abnormality.

X-RAY EXAMINATION OF THE SKULL.

There is no evidence of fracture.

PROGRESS. 27.4.31.

The patient remembers seeing examiner previously, but he is still in a restless state.

EXAMINATION of the CEREBRO-SPINAL FLUID.

Initial pressure-----180 mm. of water
Pressure after removing 5c.c.----165 mm. of water

The fluid is slightly turbid owing to a slight, but uniform, contamination with blood. There is no clot formation. There are 1400 red blood cells per c.mm., and there are 2 small lymphocytes per c.mm. The total protein content is 44 mgms per 100c.c. The Wasserman reaction is negative.

30.4.31.

The general condition is good, but the patient is unable to say either which year or which month it is.

RE-EXAMINATION./

CASE NO. 170. (Contd.)

RE-EXAMINATION. 7.8.31.

The patient states that he lay in bed for a period of six weeks after discharge. There have been no headaches, but his people notice that he is more irritable than previously. It is difficult to say whether his memory has been affected by the accident, as it was beginning to fail a little before the accident occurred. He has complained of dizziness on one or two occasions, but otherwise there have been no post-concussional disturbances. The blood pressure is 170/100 mm. and there are frequent extra systoles of the heart.

GROUP C.

CASE NO. 171. C.R. Age 32. Ward 12.
Admitted 6.3.31. Discharged 9.4.31.
Occupation - Fish Restaurant supervisor.

HISTORY.

The patient was in good health at the time the accident occurred. At 10 a.m. on the day of admission, while riding his motor bicycle, he collided with a motor car. He was rendered unconscious and was brought to the Infirmary. Bleeding was noticed from the nose and right ear.

EXAMINATION . 10.3.31.

The general condition is good. There is a bruise of the frontal region with swelling around both eyes. There is evidence of previous haemorrhage from the right ear. The patient is able to speak normally, but is in a dazed and restless state. He has difficulty in understanding what is said to him. He remembers being on a motor bicycle, but has no further recollection of events. He knows where he is, but has no idea why he is here. There is severe frontal headache. The right plantar reflex gives an extensor response, but the reflex on the left side is normal. There is a moderate degree of neck rigidity, but examination shows no further abnormality.

X-RAY EXAMINATION of the SKULL.

There is a fissure of the right occipitoparietal region.

EXAMINATION of the CEREBRO-SPINAL FLUID. 13.3.31.

Initial pressure-----230 mm. of water.
Pressure after removing 5c.c.--180 mm. of water.
The/

CASE NO. 171. (Contd.)

The fluid is clear, but slightly yellow in colour. There are no red cells, but 25 white cells per c.mm. 4 per cent of the latter are polymorphs, 56 per cent are small lymphocytes, and 40 per cent are large mononuclears cells. The total protein content is 94 mgms. per 100c.c. Lumbar puncture was immediately followed by relief of headache. To-day the patient is more conscious, but owing to restlessness has been removed to the ward for incidental delirium. There is a slight degree of neck rigidity, and both plantar reflexes give an extensor response. Otherwise there is no abnormality on examination.

PROGRESS 15.3.31.

To-day the patient is able to carry out complicated instructions with accuracy. He is able to speak sensibly about his accident, and express the wish to go home. There is some throbbing pain in the left ear, but this is much less since the lumbar puncture. There is slight deafness of the right ear, and in Weber's test the sound is referred to the right side. There is some purulent discharge from the right ear today. To-day both plantar reflexes give a flexor response, and there is no neck rigidity. He now remembers being on a motor bicycle near to where the accident occurred, thereafter he has no recollection of events until he awoke in hospital four days later.

RE-EXAMINATION. 29.7.31.

For a period of two weeks he was obliged to keep the blinds of his room drawn down, owing to the pain in his head. His memory and mental ability has been very seriously damaged by his injury. He is unable to recognise the people he knows well, and forgets what is said to him so that he asks the same question repeatedly. He is now quite unable to handle money in his shop, and his wife has to do that. He is unable to remember which of the customers have paid their bills. He suffered from severe headaches for a period of two weeks after discharge, but these are gradually becoming less severe. He is much troubled with dizziness, and dare not stoop down on account of this. He also notices that if he looks/

CASE NO. 171 (Contd.)

looks up, everything begins to go round. He hesitates in his speaking which he never did before his accident. He is taking the case to court, but it is only to prove liability for the accident. On examination, he is found to have completely lost the sense of smell. He is also slightly deaf in the right ear, and with the Weber's test, the sound is referred to the deaf ear. Otherwise there is no abnormality.

GROUP C.

CASE NO. 172. A.R. Age 24. Ward 7.

Admitted 9.6.31.

HISTORY.

The patient was in good health at the time the accident occurred. At 6.30 a.m. on the morning of admission, he was caught in machinery. He was at once rendered unconscious, and was brought to the Infirmary.

EXAMINATION. 10 a.m. on the day of admission.

The patient is pale, his skin is cold and moist. His breathing is shallow and his pulse is weak. The pulse rate is 150 per minute, and the respiration rate is 28. There is extensive laceration of the right occipital region. There is haemorrhage from the wound, but none from the nose or ears. No other injuries were apparent. The patient is comatose. He lies quietly, and does not respond to any stimuli. Speech is impossible. Both plantar reflexes give an extensor response, but otherwise there is no abnormality on examination.

The progress of this case could unfortunately not be followed up.

RE-EXAMINATION.

The patient failed to report.

GROUP C.

CASE NO. 173. R.R. A male aged 7. Ward 5.

Admitted 16.7.31. Discharged 29.7.31.

HISTORY.

The patient was in good health at the time the accident occurred. On the day of admission, while standing on the running board of a car, he slipped and fell off. He struck his head on the ground and was at once rendered unconscious. There was bleeding from the nose, but none from the ears.

EXAMINATION. 17.7.31.

The general condition is good. There is a bruise of the right parietal region. There is no evidence of haemorrhage from the nose or ears. There are no injuries to other parts of the body. The patient lies quietly in a drowsy condition. There is a considerable degree of headache, and vomiting has been frequent. There is an internal strabismus of the left eye, but this has been present for some years. There is a bilateral extensor plantar response, and a moderate degree of neck rigidity, but no other abnormality is apparent on examination.

X-RAY EXAMINATION.

There is a fissure fracture of the right parietal region extending into the frontal region.

RE-EXAMINATION. 13.1.32.

The patient began to run about as usual as soon as he returned home. His mother says that he has changed greatly since his accident. Previously he used to be quiet and a good little boy, but now he is very excitable, and loses his temper with other children. He has got into trouble on account of this on two or three occasions. He suffers from severe headaches which come on after playing, and are also present when he awakens in the morning. He has become very nervous of the dark and of strangers. There is no disturbance of his ability to sleep. There is no question of compensation. The internal strabismus is still present. Otherwise examination shows no abnormality.

432

GROUP C.

CASE NO. 174. R.R. Age 3. Ward 5.

Admitted 14.5.31. Discharged 18.5.31.

HISTORY.

The patient was in good health at the time the accident occurred. On the day of admission, he was knocked down by a bicycle. He was rendered unconscious, and was brought to the Infirmary where he was admitted at 7 p.m. He was reported to be in a dazed condition on admission.

EXAMINATION. 15.5.31.

There is a bruise in the right frontal and also in the left mastoid regions. There is no evidence of haemorrhage from the nose or ears. The patient is in a dazed and irritable state. There is no vomiting. Examination of the nervous system shows no abnormality.

X-RAY EXAMINATION of the SKULL.

There is no evidence of fracture.

RE-EXAMINATION. 11.1.32.

The patient's mother says that he began to run about again as usual after his accident. She notices that he is more nervous than before the accident. He is particularly frightened of the dark and of strangers. Before his accident, he feared nothing. He sometimes hesitates in his speaking, and this is also a new development since the accident. Examination shows no abnormality.

GROUP C.

CASE NO.176. R.L.S. Age 7. Ward 16.

Admitted 20.1.31. Discharged 17.3.31.

HISTORY.

The patient was in good health at the time the accident occurred. At 4 p.m. on the day of admission he was knocked down in the street by a motor van. He was at once rendered unconscious and was brought to the Infirmary.

EXAMINATION. 21.1.31.

The general condition is good. There is no apparent injury to the scalp. There is no evidence of haemorrhage from the nose or ears. There is a fracture of the right femur. The patient is still in a dazed condition. There is however no headache. The right pupil is slightly larger than the left, but no further abnormality is detected on examination.

X-RAY EXAMINATION.

Examination of the skull was not carried out.

RE-EXAMINATION. 22.8.31.

Complete recovery has occurred and there have been no post-concussional disturbances. The question of compensation is not yet decided.

GROUP C.

CASE NO. 177. J.T. Age 6. Ward 18.

Admitted 24.1.31. Discharged 11.4.31.

HISTORY.

The patient was in good health at the time the accident occurred. On the morning of admission, while crossing the street, he was knocked down by a motor car, and was at once rendered unconscious. He was sent to the Infirmary where he was admitted about 4 hours later.

EXAMINATION. 8 p.m. on day of admission.

The patient is considerably shocked. There is a bruise on the left side of the face. There is no other evidence of injury to the head. There is no evidence of haemorrhage from the nose or ears. There are severe injuries to the feet and to the chest. The patient is deeply stuporose and no speech is possible. Examination of the nervous system shows no abnormality.

X-RAY EXAMINATION.

Of the skull shows no evidence of fracture.

PROGRESS.

The patient regained consciousness in the course of about two days. He was very irritable while consciousness was returning. It was necessary to amputate one of his toes.

RE-EXAMINATION. 18.8.31.

The patient rested for 6 weeks after discharge. There has been no giddiness or diplopia. There have been no post-concussional disturbances of any sort. The injury to the foot has not yet healed, and the question of compensation is not yet decided.

GROUP C.

CASE NO. 178. W.T. Age 19. Ward 10.

Admitted 5.7.31. Discharged 18.7.31.

Occupation- Ploughman.

HISTORY.

The patient was in good health at the time the accident occurred. On the day before admission, while riding a motor bicycle, he collided with a motor car. It was reported that he could answer questions a few minutes after the accident, but during the following night he became very restless and irritable. Bleeding was noticed from the right ear. He was admitted to hospital on the day following.

EXAMINATION. 7.7.31.

The general condition is good. There is a laceration of the scalp in the right temporal region. There has been bleeding from the right ear and also from the nose. There are no injuries to other parts of the body. The patient's speech is normal but he is in a dazed and very irritable state. He complains of some headache. The right pupil is larger than the left. There is marked neck rigidity, but otherwise no abnormality was detected on examination.

X-RAY EXAMINATION.

Of the skull shows a fracture of the frontal bone extending into the right temporal bone.

PROGRESS. 17.7.31.

The mental state is now normal. The patient remembers leaving home on his motor bicycle but has no further recollection of events until he woke up in hospital 4 days later. There is slight nystagmus on looking to the right and slight weakness of the left side of the face. There is no deafness and full examination shows no further abnormality.

RE-EXAMINATION.

The patient failed to report.

437

GROUP C.

CASE NO. 179. J.T. (male) Age 9. Ward 6.

Admitted 23.7.31. Discharged 1.8.31.

HISTORY.

The patient had suffered from severe headaches for two months before the accident occurred. He had had a mastoid operation on the left side in 1927 and had been deaf on that side since that time. On the day of admission he fell downstairs - a distance of about 16 feet. He was at once rendered unconscious and was brought to the Infirmary. Bleeding was noticed from his nose and from his left ear.

EXAMINATION. 25.7.31.

The general condition is good. There is a bruise in the left temporal region. There is evidence of previous haemorrhage from the left ear. There are no injuries to other parts of the body. The patient is in a dazed, irritable, and restless state, but his speech is normal. He complains of very severe headache, and he vomited frequently during the 24 hours following the accident. The left plantar reflex gives an extensor response. There is very pronounced neck rigidity, with some neck retraction. Otherwise examination reveals no abnormality.

X-RAY EXAMINATION.

X-Ray Examination of the skull shows a linear fracture of the temporal bone.

Progress. 29.7.31.

To-day the patient answers questions promptly but rudely. There is no headache and only slight neck rigidity. There is slight weakness of the left side of the face and some deafness of the left ear. There is slight unsteadiness of the left upper extremity and the left plantar reflex still gives an extensor response. Otherwise there is no abnormality on examination.

RE-EXAMINATION/

CASE NO. 179. (Contd.)

RE-EXAMINATION. 11.1.32.

The patient had an ear operation after discharge from the ward. There have been no post-concussional symptoms of any sort. There is still slight unsteadiness of the left upper extremity, but otherwise no abnormality on examination.

439

GROUP C.

CASE NO. 180. O.T. (male) Age 33. Ward 18.

Admitted 14.2.31. Discharged 5.3.31

Occupation Civil servant.

HISTORY.

The patient was in good health at the time the accident occurred. He had previously had two or three accidents with his motor bicycle. On the afternoon of admission, while riding his motor cycle, he swerved to avoid a dog, skidded, and was thrown on to the road. He was rendered unconscious and brought to the Infirmary.

EXAMINATION. 15.2.31.

The patient lies quietly in bed. There is a laceration in the left temporal region and the left eye is closed with effusion. There is evidence of previous haemorrhage from the nose. His speech is confused, he fails to respond to questions and is very restless and resistive to all attempts at examination. There is some headache and he has only vomited on one occasion shortly after admission. Both plantar reflexes give an extensor response. There is marked neck rigidity and Kernig's sign is positive. Otherwise no abnormality was detected on examination.

X-RAY EXAMINATION.

X-ray examination of the skull shows a large fissure fracture in the left temporal region.

PROGRESS. 16.2.31.

Today the patient is very resistive and restless. He is unable to answer questions but is able to curse vehemently. He complains of headache. There is marked neck rigidity. Kernig's sign is positive, and the left plantar reflex gives an extensor response, while the right is normal.

18.2.31.

The mental state is unchanged. Neck rigidity is still very pronounced. Kernig's sign is still positive. The blood pressure is 105/63. The pulse rate is 54. The left plantar reflex/

reflex still gives an extensor response.

19.2.31.

The patient complains of severe headache. He is talking more and intelligible sentences are occasionally uttered. The right pupil is slightly larger than the left.

EXAMINATION OF THE CEREBRO-SPINAL FLUID. 19.5.31.

The initial pressure is 250 mm. of water. Pressure after removing 5 cc. is 170 mm. of water. The fluid is dark-yellow in colour and is uniformly mixed with some blood. There is a cob-web coagulum. There are 4,500 red blood cells per c.mm. and 520 white blood cells per c.mm. The total protein content is 100 mgms. per 100 cc. Sugar content is 98 mgms. per 100 cc.

20.2.31.

The patient slept quietly for a day after lumbar puncture. Headache however is again severe this morning. Neck rigidity is still present but both plantar reflexes today give a flexor response.

EXAMINATION OF CEREBRO-SPINAL FLUID.

The initial pressure is 220 mm. of water. Pressure after removing 5 cc. is 170 mm. of water. The fluid is yellow in colour. A slight clot forms on standing. The total protein content is 69 mgms. per 100 cc. There are no red cells, but 60 white cells per c.mm. 80% of the latter are lymphocytes, and 20% are polymorphs.

21.2.31.

There is still severe headache but the patient is lying more quietly. Some neck rigidity is still present. The pupils to-day are equal.

25.2.31.

The patient to-day remembers having seen the examiner previously, but has no recollection of lumbar puncture being carried out. He knows where he is but has no recollection of events preceding the accident. There is still some neck rigidity and headache is severe. There is some definite papilloedema on both sides. The reflexes are all normal. There is no sensory loss.

CASE NO. 180 (contd.)

26.2.31.

There is now no headache. He has no recollection of being on his motor bicycle. The last thing he remembers is working in the office near the beginning of February.

1.3.31.

The patient states he has no recollection of any days since the accident, preceding the 25th of February. There was some heaviness in the head this morning on waking, but otherwise no headache. To-day he remembers clearly everything that happened on the morning of the accident and remembers leaving his office, but nothing further.

RE-EXAMINATION 18.8.31.

The patient rested for 10 days after leaving hospital and he was off work for 7 weeks in all. He thinks that his memory is defective. He can't "place" people whom he knows by sight. He is unable to remember whether he knows them or not. He also finds that he has difficulty in concentrating. He is able to do his work as well as previously, even though it is of a very complicated nature. There have been no headaches. Previous to the accident he suffered from migrainous headaches for ten years which would come on at least once a week. He has been quite free of these since the accident until yesterday morning when one occurred. He finds that if he lies on his back and turns his head to one or other side, his head seems to swim. This is specially apt to come on if he has been working hard at his office. The sensation only lasts for a moment and then passes off. He is not nervous and has been told that he rides his motor bicycle more recklessly than before.

442

GROUP C.

CASE NO. 181. W.W. (male) Aged 45 Ward 3 (6).

Admitted 31.12.30. Discharged 32.31

Occupation Assistant in hotel.

HISTORY.

The patient was apparently in good health before the accident occurred. He was arrested early on the morning of admission, for being drunk and incapable. He lay comatose in the police cell and in the morning vomited blood.

EXAMINATION. 16.1.31.

There was no history of previous haemorrhage from the nose or ears. There are no injuries to other parts of the body. The patient is in a dazed state but his speech is normal. There is considerable headache over the left side of the face and head, and he vomited once after admission. He has no recollection of the accident. He remembers nothing of what happened till he woke up in the ward. He says he is unable to think clearly. He is very listless and sleeps excessively. There is complete paralysis of the left 6th nerve and also of the 7th. nerve. There is some deafness of the left ear. Examination of the nervous system otherwise shows no abnormality.

X-RAY EXAMINATION.

X-ray examination of the skull shows definite evidence of a fracture and the cerebro-spinal fluid, which was examined by the house surgeon was reported to be deeply blood-stained.

RE-EXAMINATION.

The patient failed to report.

GROUP C

CASE NO. 182. W.W. A male aged 20. Ward 13.

Admitted 3.8.31. Discharged 15.9.31.

HISTORY.

The patient was in good health at the time the accident occurred. At 6 p.m. on the day of admission, while riding his motor-bicycle, he collided with a motor-car. He was rendered unconscious and was brought to the Infirmary, where he was admitted 2 hours later. No bleeding was noted from the nose or ears. He was reported to be very shocked on admission.

EXAMINATION. 4.8.31.

There is a bruise in the left frontal region. There is no evidence of previous haemorrhage from the nose or ears. There is a sub-conjunctival haemorrhage on the outer side of the left eye. Injuries to other parts include a Colles fracture and dislocation of the left knee. The patient lies quietly. He knows where he is but speech is confused and he is very dazed. There is slight headache but no vomiting. Both plantar reflexes give an extensor response. There is marked neck rigidity. There is retention of urine.

X-RAY EXAMINATION.

Examination of the skull shows a linear crack in the occipital bone extending into the right parietal region.

PROGRESS. 10.8.31.

The patient remembers seeing the motor-car coming towards him but has no further recollection of events until he woke up about 36 hours after the accident. He says there has been no headache or dizziness. Full examination shows no abnormality.

RE-EXAMINATION. 24.11.31.

The patient states that, owing to his leg injury, he lay in bed for 5 weeks after discharge. There have been no post-concussional disturbances but he has been unable to return to work on account /

CASE NO. 182. (Contd.)

account of the injury to his wrist. There is no compensation question outstanding - indeed he was fined a pound for dangerous driving. He could, of course, give no evidence on his own behalf as he had no recollection of the accident. He says now that there is a complete gap of one hour and ten minutes preceding the accident of which he has no recollection, and that he has no further memory of events until he had been in hospital for 5 days.

445

GROUP C.

CASE NO. 183. J.W. A male aged 58. Ward 6.

Admitted 4.12.30. Discharged 17.12.30.

HISTORY.

On the day of admission the patient was knocked down in the street by a motor car. He was found by a policeman 15 minutes later and brought to the Infirmary. The policeman stated that he was conscious but had no recollection of what had occurred.

EXAMINATION. 5.12.30.

The general condition is good but the blood pressure is 210/90. There is a cut in the occipital region. There is no evidence of haemorrhage from the nose or ears and no injuries to other parts of the body. The patient is in a dazed state but his speech is sensible. There is a considerable degree of headache and vomiting has occurred frequently. There is a moderate degree of neck rigidity but otherwise examination shows no abnormality.

PROGRESS. 8.12.30.

To-day the patient is very restless and there is difficulty in keeping him in bed.

14.12.30.

The patient is still in a very confused and restless state.

17.12.30.

To-day the patient realises where he is but is still somewhat dazed. He can answer questions rationally. He was discharged to Craiglockhart Hospital.

RE-EXAMINATION.

The patient's relatives report that he died soon after leaving Craiglockhart Hospital.

446

GROUP C

CASE NO. 184. E.Y. A female aged 22. Ward 14.
Admitted 2.2.31. Discharged 14.2.31.
Occupation - Typist

HISTORY.

The patient was in good health at the time the accident occurred. On the day of admission, at 6.25 p.m., she was knocked down by a motor-car while crossing the street. She was at once rendered unconscious and was brought to the Infirmary.

EXAMINATION. On day of admission at 10 p.m.

The patient is shocked but has been propped up in bed. There is a large bruise with haematoma formation in the right parieto-occipital region. There is no evidence of haemorrhage from the nose or ears and no injuries to other parts of the body. Speech is normal but the patient is in an irritable and dazed state. There is very severe frontal headache and frequent vomiting. Both plantar reflexes give an extensor response and there is definite neck rigidity.

PROGRESS. 3.2.31.

The patient's condition is unchanged. She is still very restless and is suffering from severe headache and vomiting.

EXAMINATION OF CEREBRO-SPINAL FLUID. 2.30 p.m. 3.2.31.

Initial pressure-----250 mm of water
Pressure after removing 5 cc.-160 " " "
The fluid is deeply blood-stained and the supernatant fluid is yellow in colour. There is no clot formation. There are 90,000 red blood cells per c.mm. and 376 white blood cells per c.mm. 89 per cent of the latter are polymorphs, 10 per cent are small lymphocytes and 1 per cent are large mononuclear cells. The total protein content of the fluid is 475 mgms. per 100 cc.
The /

CASE NO. 184. (Contd.)

The sugar content is 79 mgms. per 100 c.cs.
At 7 p.m. the headache is still severe but the patient is more conscious. Neck rigidity is still pronounced.

4.2.31.

There is still severe headache and vomiting. Both plantar reflexes give an extensor response and there is marked neck rigidity, but otherwise there is no abnormality on examination.

Examination of the Cerebro-spinal fluid.

Initial pressure-----330 mm of water
Pressure after removing 5 cc.---300 " " "
There are 24,000 red blood cells per c.mm. The total protein content is 138 mgms. per 100 c.cs. Sugar content is 72 mgms. per 100 c.cs.

5.2.31.

There is severe headache and the patient has been unable to sleep since admission. There is now no vomiting. There is slight blurring of the right optic disc. Neck rigidity is marked and both plantar reflexes give an extensor response.

Examination of the Cerebro-spinal fluid.

Initial pressure-----270 mm. of water.
Pressure after removing 5 cc.---250 " " "
There are 10,000 red blood cells per c.mm. and 38 white cells. 50 per cent of the latter are polymorphs, 42 per cent are small lymphocytes and 8 per cent are large mononuclear cells. The total protein content is 98 mgms. per 100 cc. The sugar content is 59 mgms. per 100 ccs.

7.2.31.

Headache is still present and the patient has not yet been able to sleep.

CASE NO. 184. (Contd.)

Examination of the Cerebro-spinal fluid.

Initial pressure-----270 mm. of water.
 Pressure after removing 5 cc.---230 " " "
 There are 130 red blood cells per c.mm. and 3
 white cells per c.mm. The fluid is yellow in
 colour. The total protein content is 19 mgms.
 per 100 c.cs. The sugar content is 62.5 mgms.
 per 100 c.cs.

8.2.31.

Headache to-day is less severe. There is
 no definite diplopia but the patient says she
 sees better with one eye covered. There is no
 neck rigidity.

9.2.31.

To-day there is definite diplopia and slight
 weakness of the right external rectus muscle.

10.2.31.

To-day there is complete paralysis of the
 right external rectus muscle. The left plantar
 reflex still gives an extensor response. There
 is no response from this reflex on the right side.

Examination of the Cerebro-spinal fluid.

Initial pressure-----330 mm. of water.
 Pressure after removing 5 cc.--260 " " "
 The total protein content is 19 mgms. per 100 cc.
 The sugar content is 78 mgms. per 100 cc.

11.2.31.

There is still complete paralysis of the
 right external rectus muscle. Neither plantar
 reflex gives any response.

12.2.31.

There is still severe frontal headache.
 Examination otherwise is as before. The patient
 remembers walking across the Dean Bridge a
 little after 6 p.m. on the day the accident
 occurred. Her recollection of what she did
 previous /

CASE NO. 184. (Contd.)

previous to the accident is quite clear up to that time. She believes that the accident occurred 150 yards beyond the bridge.

RE-EXAMINATION. 23.7.31.

The patient states that she remained in bed for a month after discharge. She continued to see double for 3 months. She sometimes thinks that her memory at her business is not quite so good as previously. She suffered from very severe headaches for a month after discharge. These are now steadily disappearing and only trouble her if she has been working too much. There is no dizziness and she is not nervous except of traffic. She has no difficulty in sleeping and there is no question of compensation outstanding. She does not think that she sees quite so well as previously but examination did not elicit any abnormality of her vision and her discs were normal.

CASE NO. 185. M.A. A male aged 40. Ward 7.

Admitted 27.5.31. Died. 30.5.31.

HISTORY.

The patient was in good health at the time the accident occurred. On the day of admission he fell downstairs. He was rendered unconscious. Bleeding was noticed from the nose and ear, and he was brought to the Infirmary.

EXAMINATION. 28.5.31.

The pulse rate is 96 and the respiration rate 26 per minute. The temperature is sub-normal. There is a bruise in the frontal region. There is haemorrhage from the nose and right ear. There are some injuries to the chest. The patient is in a dazed state but his speech is clear. There is a moderate degree of headache and he has vomited frequently. There is nystagmus on looking in all directions. Both plantar reflexes give a flexor response and there is marked neck rigidity.

PROGRESS. 29.5.31.

The condition to-day became much worse and the patient became very delirious.

30.5.31.

The patient died.

POST MORTEM EXAMINATION A FEW HOURS AFTER DEATH.

There is a bruise over the vertex. There is a fracture of the skull in the region of the anterior fontanelle and across the middle fossa from the right middle ear. There is about an ounce of epidural blood over the posterior part of the superior sagittal sinus. There is no subdural blood. There is a little subarachnoid blood, especially over the cerebellum. On sectioning the brain there is no evidence of haemorrhage or laceration. The meninges appear thick, are greenish in appearance, and microscopic examination shows a typical picture of meningitis.

451

GROUP D

CASE NO. 186. D.B. A female aged 5. Ward 14.

Admitted 22.12.30. Died 25.12.30.

HISTORY.

On the day of admission the patient was knocked down in the street by a motor-car. She was at once rendered unconscious, bleeding was noticed from the nose and right ear, and she was brought to the Infirmary. On admission, she was reported to be very shocked. The pupils reacted to light. The knee jerks were present. The temperature was 98.6, the pulse rate 138, and the respiration rate 24 per minute.

EXAMINATION. 23.12.30. at 11 a.m.

The patient lies quietly. The skin is warm and dry. The pulse rate is 150 and respiration rate is 38 per minute. There is extensive bruising of the face and forehead. There is haemorrhage from the nose and right ear and there is some escape of cerebro-spinal fluid from the nose. There are no injuries to other parts of the body. The patient is deeply stuporose but when roused calls out "My head's sore". Otherwise she is unable to speak. Both plantar reflexes give an extensor response. The knee jerks are equal and active. There is marked neck rigidity. At 8 p.m. on 23.12.30, the patient is less restless but, if anything, more deeply unconscious.

PROGRESS. 24.12.30.

The patient is much worse. The pulse rate is 170 per minute. The patient is comatose and cannot be roused. The blood pressure is 80/50 mm. The right pupil is slightly larger than the left. The knee jerks are absent. Both plantar reflexes give an extensor response. There is marked neck rigidity and Kernig's sign is positive.

EXAMINATION OF THE CEREBRO-SPINAL FLUID. 24.12.30. 2p.m.

The initial pressure is 500 mm. of water. Pressure after removing 10 cc. is 300 mm. of water. The fluid is uniformly blood-stained and a clot forms on standing. There are 7,000 red blood cells per c.mm. and 1,000 white cells per c.mm. The latter consist of polymorphs and large /

CASE NO. 186. (Contd.)

large mononuclear cells. The total protein content of the fluid is 820 mgms. per 100 cc. The sugar content of the fluid is 7.6 mgms. per 100 cc. No organisms were obtained from direct films and no growth on culture. At 8 p.m. the pressure of the fluid was 250 mm. of water; 30 cc. of cerebro-spinal fluid were drawn away but no improvement occurred.

25.12.30.

The patient died.

POST MORTEM EXAMINATION.

Post mortem examination was not carried out.

453

GROUP D.

CASE NO. 187. J.B. A male aged 26. Ward 12.

Admitted 1.5.31. Died 2.5.31.

HISTORY.

On the day of admission, while riding his bicycle, the patient lost control and smashed into a wall. He was rendered unconscious and brought to the Infirmary. He was reported to be severely shocked on admission. The cerebrospinal fluid was examined shortly after admission and contained no blood.

EXAMINATION. On the day of admission.

There is an extensive laceration of the scalp in the occipital region. There is no haemorrhage from the nose or ears. There are multiple fractures of the left upper extremity and an injury to the left foot. The patient lies quietly in bed with his eyes half-closed. Although it is broad daylight he asks the examiner to pull up the blind. His speech is confused and he hits out violently with his arms. His response to simple commands show the phenomenon of perseveration. He vomited once soon after admission. The right plantar reflex gives a flexor response: the left cannot be examined. Otherwise there is no abnormality on examination.

PROGRESS. 2.5.31.

To-day the patient is conscious and feeling more comfortable. In the evening, however, he suddenly took a turn for the worse and died in the course of a few minutes.

POST MORTEM EXAMINATION.

Post mortem examination was not obtained.

454

GROUP D

CASE NO. 188. G.C. A male aged 50. Ward 12.

Admitted 7.3.31. Died 10.3.31.

HISTORY.

The patient was brought into hospital unconscious and no history of how the injury was caused could be obtained.

EXAMINATION. 9.3.31.

The skin is warm. The pulse is full. Breathing is deep. The pulse rate is 60, the respiration rate 26 per minute. The temperature is 96.4° F. There is a compound depressed fracture of the left frontal bone and extensive haemorrhage from the wound and from the nose. The patient is in a dazed and irritable state. Headache is very severe in the frontal region. Both eyes are closed with extensive effusion. There is a slight degree of neck rigidity, but otherwise examination shows no abnormality. Lumbar puncture was carried out by the house surgeon and deeply blood-stained fluid was withdrawn.

The patient died on 10.3.31: no post mortem examination was held.

455

GROUP D

CASE NO. 189. J.C. A male aged 61. Ward 13.

Admitted 9.3.31. Died 16.3.31.

HISTORY.

The patient was in good health at the time the accident occurred. On the day of admission he slipped on the pavement and struck his head on the ground. He was reported to be dazed after the accident and on admission was severely shocked.

EXAMINATION. 10.3.31.

The skin is warm. The pulse is weak and the breathing is deep. The blood pressure is 130/70. There is a laceration of the scalp in the occipital region. There is no evidence of haemorrhage from the nose or ears. The patient is in a dazed state and speech is confused. The left pupil is larger than the right and there is an external strabismus of the left eye. Both knee jerks are sluggish. The left plantar reflex gives an extensor response, the right gives a flexor response. There is a slight degree of neck rigidity. The patient coughs up a large quantity of purulent expectoration.

X-RAY EXAMINATION.

Examination of the skull shows no evidence of fracture. The urine was found to reduce Fehling's solution.

EXAMINATION OF THE CEREBRO-SPINAL FLUID. 12.3.31.

The initial pressure is 100 mm. of water. Pressure after removing 5 cc., is 70 mm. of water. The headache was immediately relieved after this. The fluid is uniformly blood-stained. There is no clot formation. There are 62,000 red blood cells per c.mm. and 37 white cells per c.mm. 40 per cent of the latter are polymorphs, 18 per cent are small lymphocytes and 42 per cent are large mononuclear cells. The total protein content is 375 mgms. per 100 c.c. The Wassermann reaction of the fluid is negative.

The patient died on 16.3.31.

CASE NO. 189. (Contd.)

POST MORTEM EXAMINATION.

There is a lacerated wound in the occipital region. There is a fracture of the base of the skull which, starting in the occipital region, runs forward into the foramen magnum. There is no epi - or subdural haemorrhage. There is a considerable degree of subarachnoid haemorrhage. There is marked contusion and laceration of the medial surface of the left frontal lobe of the brain. There is no meningitis. Sectioning of the brain shows no further evidence of laceration or haemorrhage.

There is a commencing hypostatic pneumonia in both lungs.

457

GROUP D

CASE NO. 190. A.G. A male aged 12 $\frac{1}{2}$. Ward 18.
Admitted 20.6.31. Died 9.7.31.
Occupation - School-boy.

HISTORY.

On the day of admission the patient fell from a roof a distance of about 40 feet. He was rendered unconscious and brought at once to the Infirmary. Bleeding was noticed from both ears.

EXAMINATION. 21.6.31.

The patient lies without moving. The skin is warm and moist. The pulse is weak and the breathing is deep. The pulse rate is 165 per minute and the respiration rate is 36 per minute. The blood pressure is 110/65 mm. There is a compound depressed fracture in the left temporal region. There is evidence of previous haemorrhage from the nose and from both ears. The patient is comatose and does not respond to external stimuli. The pupils are 2.5 millimetres in diameter. They are equal and react sluggishly to light. There are frequent twitches of the muscles of the whole body that simulate closely those seen in uraemia. Both plantar reflexes give an extensor response and there is marked neck rigidity.

PROGRESS. 22.6.31.

The patient is so restless that it has been necessary to tie down his arms. The general condition is worse. The pulse is imperceptible and the breathing, deep and irregular. There is no hemi-paresis. The muscular twitches are still occurring.

EXAMINATION OF THE CEREBRO-SPINAL FLUID. 23.6.31.

The initial pressure is 200 mm. of water. Pressure after removing 7 cc. is 120 mm. of water. The fluid appears slightly turbid. There is no clot formation. There are 3,500 red blood cells per c.mm. and 14 white cells per c.mm. 60 per cent of the latter are small lymphocytes and 40 per cent are large mononuclear cells. The total protein /

CASE NO. 190.(Contd.)

protein content is 112 mgms. per 100 cc. The sugar content of the fluid is 135 mgms. per 100 c.cs. When the patient was examined 4 hours after lumbar puncture the mental state had improved. He is able to say a few sensible words and is lying more restfully. There are no muscular twitches. Neck rigidity is still present. The pulse is more easily felt and is not so rapid.

24.6.31.

To-day the patient answers questions intelligently but abruptly; for example, he asks for a drink "at once". He was very noisy during the night and was singing and shouting most of the time. The right pupil is larger than the left. There is nystagmus on looking laterally. The neck is still very rigid and the patient complains of severe headache. There is no evidence of hemi-paresis.

Examination of the Cerebro-spinal fluid. 25.6.31.

The fluid is slightly turbid. There are no red cells but 350 white cells per c.mm. 48 per cent of these are polymorphs and 52 per cent are large mononuclear cells. There is a slight clot formation on standing. The sugar content of the fluid is 135 mgms. per 100 cc. and the total protein content is 225 mgms. per 100 cc.

26.6.31.

The patient is deeply stuporose and talks meaninglessly.

Examination of the Cerebro-spinal fluid. 27.6.31.

The fluid is definitely turbid. There are 2,000 white blood cells per c.mm., entirely polymorphs and large mononuclear cells.

28.6.31.

The pulse, temperature and respiration rate are all higher. The patient lies in a comatose state but mutters occasionally. The pupils are equal. Neck rigidity is still very pronounced. There is no evidence of weakness of one side.

CASE NO. 190.(Contd.)

29.6.31.

The general condition has slightly improved.

30.6.31.

To-day the general condition is worse.

Examination of the Cerebro-spinal fluid.

The initial pressure is 220 mm. of water. Pressure after removing 5 cc. is 170 mm. of water. There are 10,000 red blood cells per c.mm. and 3,000 white blood cells per c.mm. Most of the latter are large mononuclear cells. There is a slight clot formation. The total protein content of the fluid is 214 mgms. per 100 cc. The sugar content is 42 mgms. per 100 cc.

2.7.31.

The general condition to-day is worse.

4.7.31.

The condition is unchanged. There are some muscular twitches of the fingers and hands, especially of the left side, such as occurred when the patient was first admitted.

The patient died on 9.7.31.

The blood sugar content on 22.6.31. was 220 mgms. per 100 cc.

POST MORTEM EXAMINATION.

There is a linear fracture of the left frontal bone which stretches into the left upper part of the squamous temporal. The middle ear and the mastoid cells on both sides are found to contain pus under tension. There is no epidural blood and no subdural or subarachnoid haemorrhage. There is definite meningitis, and streptococci were isolated from the meninges. There is considerable contusion of the brain, especially on the left side. Sections were stained to show the astrocytic reactions around the contused area.

460

GROUP D

CASE NO. 191. MRS. B.G. A female aged 65. Ward 17.

Admitted 27.12.30. Died 6.1.31.

HISTORY.

The patient was in good health at the time the accident occurred. On the evening of admission, while crossing the road, she was knocked down by a motor-car. She was slightly dazed but does not think she lost consciousness. She was brought to the Infirmary where she was admitted.

EXAMINATION. 28.12.30.

The general condition is good. There is a small laceration of the scalp in the right temporal region and a haematoma in the occipital region. There has been some haemorrhage from the wound but none from the nose or ears. Apart from slight bruises, there are no injuries to other parts. The mental condition is normal. There is no headache or vomiting. Examination of the nervous system shows no abnormality except that the right plantar reflex gives an indefinite response.

PROGRESS. 1.1.31.

To-day there is a rise in temperature and marked swelling around the right eye. This swelling spread over the right side of the face and some pus is apparent in the scalp wound. The mental state is a little dulled. There is no neck rigidity and Kernig's sign is negative.

EXAMINATION OF THE CEREBRO-SPINAL FLUID. 1.1.31.

The initial pressure is 190 mm. of water. The pressure after removing 5 cc. is 150 mm. of water. The fluid is uniformly blood-stained. There is no clot formation. There are 1,600 red cells per c.mm. and 2 white cells per c.mm. The total protein content of the fluid is 30 mgms. per 100 cc.

4.1.31.

There is to-day high temperature, rapid breathing, and a purulent discharge from the wound in the scalp. The patient is more drowsy.

CASE NO. 191.(Contd.)

The patient died on 6.1.31.

POST MORTEM EXAMINATION.

The scalp was found to be oedematous and there was a large collection of pus lying between the periosteum and the scalp on the right side. There was some evidence of infection of the bone in this situation. There was no fracture of the skull. There was no epidural or subdural haemorrhage. The meninges showed slight congestion and at the left occipital pole there was a slight degree of haemorrhage into the pia arachnoid. There was no abnormality detected on sectioning the brain, and there was no evidence of increased intracranial pressure.

On bacteriological examination, a pure growth of the haemolytic streptococcus was obtained from the spleen, and pus from the scalp showed numerous gram-positive cocci in pairs and in chains.

462

GROUP D

CASE NO. 192. A.G. A male aged 63. Ward 6.

Admitted 13.11.30. Died 14.11.30.

HISTORY.

The patient was in moderate health at the time the accident occurred. He had been treated by his doctor for 'blood pressure' and was suffering from Parkinson's disease. On the day of admission, while crossing the street, he was knocked down by a tram car. He was reported to be conscious after the accident. He was brought to the Infirmary, where he became deeply unconscious.

EXAMINATION. 4 hours after the accident.

The patient is lying quietly. The pulse rate is 88 and the respiration rate is 22. The respirations show the Cheyne-Stokes phenomenon. The temperature is subnormal. The blood pressure is 170/110 mm. There is a laceration of the scalp above the right eye. There is no evidence of previous haemorrhage from the nose or ears and there are no injuries to other parts of the body. The patient is deeply stuporose and unable to respond to external stimuli, but resists movements of his limbs. There is no vomiting. There have been some twitches of the left leg, but otherwise no convulsions. There is no reaction of the right pupil to light. The left pupil cannot be examined owing to the great degree of oedema around it. The left upper and lower extremity are hypertonic and the left arm is in a flexed position. The knee jerks are absent. Both plantar reflexes give an extensor response.

PROGRESS. 14.11.30.

The patient became more deeply comatose. Cheyne-Stokes respiration continued. He died at 5.45 a.m.

POST MORTEM EXAMINATION. 14.11.30.

There is a lacerated wound above the right eyebrow, with extravasation of blood into the loose /

CASE NO. 192. (Contd.)

loose tissues in this neighbourhood. There is no evidence of fracture except that there is a small linear crack in the roof of the right orbit. There is no extra-dural haemorrhage but there are two or three ounces of blood clot on the right side below the dura. There is slight flattening of the convolutions, particularly on the left side. There is a laceration of the lower surfaces of both frontal lobes, near the mid line. Otherwise there are no signs of injury to the brain. The cerebral vessels are healthy. No injuries to other parts of the body are present.

464

GROUP D

CASE NO. 193. G.H. A male aged 38. Ward 16.
Admitted 13.1.31. Died 15.1.31.

HISTORY.

The patient was in good health at the time the accident occurred. At 4.20 p.m. on the day of admission, while at his work, the patient fell off a ladder. He was at once rendered unconscious and was brought to the Infirmary. Bleeding from both ears was noticed. On admission he was reported to be severely shocked and deeply unconscious. The respiration was stertorous. The pulse was weak. There was profuse haemorrhage from both ears and also some escape of cerebro-spinal fluid. The pupils were equal and reacted to light.

EXAMINATION. 14.1.31.

The blood pressure is 130/70 mm. There is now no haemorrhage from the ears. The patient is in a deeply stuporose state and is very restless and unable to speak. The pupils are equal. The tendon reflexes are present. Both plantar reflexes give a flexor response. Neck rigidity is pronounced and there is retention of urine.

EXAMINATION OF CEREBRO-SPINAL FLUID. 3 p.m. 14.1.31.

The initial pressure is 200 mm. of water. The fluid is deeply blood-stained. The supernatant fluid is yellow in colour, but there is no clot formation. There are 1,500,000 red blood cells per c.mm. The total protein content of the fluid is 6060 mgms. per 100 cc.

Examination of the Cerebro-spinal fluid. 9 p.m.

The initial pressure is 200 mm. The fluid is deeply blood-stained but there is no clot formation. There are 1,200,000 red cells per c.mm., and the total protein content of the fluid is 4630 mgms. per 100 cc.

The patient died next day.

POST MORTEM EXAMINATION. 16.1.31.

There /

CASE NO. 193.(Contd.)

There is gross bruising on the left side of the scalp. There is a depressed and comminuted fracture of the left parietal region which extends through the base of the middle fossa. There is also a line of fracture spreading back to the left side of the occipital bone. There is a small quantity of epidural blood on the left side. There is no subdural blood. There is extensive subarachnoid blood over both hemispheres. There is considerable contusion of the right frontal and right temporal lobes. There is a slight medullary pressure cone and the convolutions are slightly flattened. There is evidence of bruising of the chest and there is some haemorrhage into the pleural sac from fractured ribs. There is also evidence of broncho-pneumonia.

GROUP D

CASE NO. 194. MRS. C.K. A female aged 48. Ward 14.

Admitted 2.2.31. Died 4.2.31.

HISTORY.

On the day of admission the patient was knocked down in the street by a motor bus. She was rendered deeply unconscious and brought to the Infirmary. On admission at 1 p.m. she was reported to be very shocked. The skin was pale and cold. The pulse was feeble. The right pupil was slightly smaller than the left and there was a divergent strabismus.

EXAMINATION. On the evening of admission.

The patient lies motionless. The skin is cold and moist. There is a bruise in the left parietal region. There is no evidence of haemorrhage from the nose or ears. There is a fracture of the right femur. The patient is deeply comatose and there is occasional vomiting. The left pupil is slightly larger than the right and there is a divergent strabismus. The corneal reflexes are sluggish. The knee jerk is present on the left side. Both plantar reflexes give an extensor response. There is no neck rigidity. There is incontinence of urine and faeces. There is a tendency for the head to be turned to the left, and the left arm tends to assume a position of extension, while the right arm takes up a flexed position. Both resist movement. The right arm resists extension and the left arm resists flexion.

PROGRESS. 3.2.31.

The general condition is worse. The pulse is imperceptible and the patient is deeply comatose. The discs are normal. To-day there is no muscular rigidity. Both extremities are flexed, especially the left. There is a slight degree of neck rigidity.

4.2.31.

The breathing is rapid and regular. The pupils are equal. There is still some neck rigidity. Death occurred to-day.

POST MORTEM EXAMINATION. 5.2.31.

There /

CASE NO. 194.(Contd.)

There is extensive bruising of the scalp over the left parietal region. There is no sign of fracture of the skull. There is no extra- or subdural haemorrhage. There is considerable subarachnoid haemorrhage. There is no visible laceration of the brain and on sectioning the brain no abnormality could be seen except that there were a few petechial haemorrhages in the left lobe of the cerebellum. There is some flattening of the cerebral convolutions and slight pressure cone formation. There are numerous injuries to the thorax and many ribs have been fractured. The right thigh is swollen from extravasation of blood in the neighbourhood of the fractured femur.

CASE NO. 195. D.L. A male aged 43. Ward 10.

Admitted 29.3.31. Died 31.3.31.

HISTORY.

On the day of admission patient fell down a flight of about 12 steps. He was at once rendered unconscious and bleeding was noticed from the nose and from the right ear.

EXAMINATION. 30.3.31.

The skin is warm and dry. The pulse is full and the breathing is stertorous. The pulse rate is 45 per minute and the respiration rate is 50 per minute. The blood pressure is 135/55mm. There is a bruise in the left frontal region with swelling around the left eye. There is evidence of previous haemorrhage from the nose and right ear. There are no injuries to other parts of the body. The patient is deeply stuporose, unable to speak and somewhat restless. There is frequent vomiting. The left pupil is slightly larger than the right. Reaction to light is sluggish. There is less movement of the left side of the body than of the right. Both plantar reflexes give an extensor response. There is no neck rigidity.

EXAMINATION OF THE CEREBRO-SPINAL FLUID. 30.3.31.

The initial pressure is 180mm. of water. Pressure after removing 5cc. is 120mm. of water. The fluid is uniformly blood-stained but there is no clot formation. There are 140,000 red blood cells per c.mm. and 430 white cells per c.mm. 55% of the latter are polymorphs, 34% are small lymphocytes, and 11% are large mononuclear cells. The total protein content of the fluid is 938mgms. per 100cc. and the sugar content is 111mgms. per 100cc.

The patient died early on the morning of 31.3.31.

POST MORTEM EXAMINATION. About 6 hours after death.

There is a fissure fracture of the right squamous temporal bone which is continued as a V- /

469

V-shaped fracture of the left anterior fossa. Over the fracture on the right side there is a sub-muscular haematoma. There is a slight degree of epidural blood below the fracture on the right side. There is no subdural blood. There is considerable subarachnoid haemorrhage, especially over the left hemisphere. The cerebro-spinal fluid is deeply blood-stained. There is marked oedema of the right side of the brain, where the convolutions are very flattened. There is no evidence of meningitis. There is a slight medullary pressure cone. The lungs show evidence of a commencing broncho-pneumonia.

470

GROUP D

CASE NO. 196. MRS. G.M. A female aged 50. Ward 9.

Admitted 24.5.31. Died 27.5.31.

HISTORY.

About 1 p.m. on the day of admission, while driving in a motor-car, the patient was involved in an accident and was at once rendered unconscious. Bleeding from the nose was noticed.

EXAMINATION. 25.5.31.

The skin is warm and dry. The pulse rate is 106 per minute. The respiration rate is 26 per minute. There is a bruise in the right frontal region, with a ring of dark-coloured effusion round the right eye. There is evidence of previous haemorrhage of the right eye. The patient is in a deeply stuporose state. She is very restless and mutters meaninglessly. There is severe frontal headache and some vomiting. The vomit contains blood. The right pupil is 4.5 millimetres in diameter and the left is 2 millimetres in diameter. There is no reaction of the left pupil to light but the right pupil reacts sluggishly. There is no weakness of one side of the body. Both plantar reflexes give an extensor response.

The patient died on 27.5.31.

POST MORTEM EXAMINATION.

Post mortem examination was not carried out.

CASE NO. 197. M.T. A male aged 27. Ward 16.

Admitted 12.5.31. Died 24.5.31.

HISTORY.

On the day of admission, at 6.20p.m., while he was riding a motor bicycle, the front tyre burst and the patient crashed into a wall. He was rendered unconscious and brought to the Infirmary.

EXAMINATION. 13.5.31.

The skin is warm and moist. The pulse is full and the respirations are deep. There is a laceration of the scalp in the right frontal region. There is haemorrhage from the nose but none from the ears. There is a fracture of the right clavicle. The patient is in a comatose state and no speech is possible. He vomited once after admission and the vomit contained blood. The left pupil, which alone can be examined, reacts briskly to light. Both plantar reflexes give an extensor response. There is marked neck rigidity. Examination of the nervous system shows no further abnormality.

PROGRESS. 15.5.31.

The patient is still comatose. The head is strongly rotated to the right side. Neck rigidity is very pronounced. Both upper and lower extremities can be moved freely. The knee jerks are equal and both plantar reflexes give an extensor response. The blood pressure is 155/90mm.

16.5.31.

The patient is still comatose and the head is turned strongly to the right. There is more movement of the limbs on the left side than on the right. The reflexes are as before. The blood pressure is 145/85mm.

17.5.31.

The reflexes are slightly more active on the left side than on the right. Otherwise the/

the condition is unchanged.

EXAMINATION OF THE CEREBRO-SPINAL FLUID. 18.5.31.

The initial pressure is 150mm. of water. Pressure after removing 5cc. is 135mm. of water. The fluid is pale brown in colour. There is no clot formation. There are 8,500 red blood cells per c.mm. and 8 white cells per c.mm: all of the latter are small lymphocytes. The total protein content of the fluid is 120mgms. per 100cc.

20.5.31.

The patient lies quietly. There is no restlessness but he is more resistive to examination than formerly. He has been unable to speak since admission. There is some nystagmus on looking to the left. The tendon reflexes are brisk and the left are slightly more active than the right. Both plantar reflexes still give an extensor response. There is slightly more movement of the right lower extremity than of the left. The patient by this time was very wasted, and died on 24.5.31.

POST MORTEM EXAMINATION.

There is evidence of previous haemorrhage under the scalp in the right temporal region. There is a small crack in the anterior fossa of the skull in the mid line. There is a little epidural haemorrhage at the site of the fracture. There is no sub-dural blood and no subarachnoid haemorrhage. On sectioning the brain, there are seen to be multiple small haemorrhages scattered throughout its substance. There is no oedema of the brain - indeed the convolutions are rather shrunken. There is evidence of meningitis but on bacteriological examination, only a growth of staphylococcus albus could be obtained. There were numerous haemorrhages scattered throughout the brain, which were so small as to be invisible to the naked eye: large sections were prepared of one temporal lobe, which showed these changes well. A marked cellular reaction was seen to surround these haemorrhages and, by means of staining the astrocytes, it was shown that this reaction was due to the activity of these cells. There were no injuries to other parts except that there was a considerable degree of bruising around the right shoulder.

CASE NO. 198. J.W. A male aged 73. Ward 13.

Admitted 6.4.31. Died 8.4.31.

HISTORY.

On the day of admission the patient was knocked down in the street by a motor bus and was brought at once to the Infirmary. He was able on admission to give his name and address correctly.

EXAMINATION. 6 hours after admission.

There is no marked shock. The pulse rate is 124 per minute, the respiration rate is 24 per minute, and the blood pressure is 188/104. There is a haematoma in the left fronto-parietal region. There is evidence of previous haemorrhage from a small cut on the outer side of the right eye. There is no haemorrhage from the nose or ears. There is extensive subcutaneous emphysema of the neck. The patient is in a stuporose state and his speech is very confused. There are a few slight twitches of the right hand but no generalised fits. The left pupil is slightly larger than the right. Both react sluggishly to light. The knee jerks are present and both plantar reflexes give an extensor response. There is a slight degree of neck rigidity.

PROGRESS. 7.4.31.

To-day the pulse and temperature are rising. There is definite neck rigidity. The patient is in a very dazed state and is unable to answer questions. There is no vomiting. There is no evidence of weakness of one side of the body. Both plantar reflexes still give an extensor response.

8.4.31.

The patient died suddenly at 1 a.m.

There was no post mortem examination.

474

GROUP D

CASE NO. 199. R.W. A male aged 61. Ward 18.
Admitted 2.5.31. Died 3.5.31.

HISTORY.

The patient was in good health at the time the accident occurred. At 6.45. a.m. on the day of admission, while standing on a stool, he fell to the ground. He was unconscious when picked up. There was bleeding from his nose and from his right ear.

EXAMINATION. 2.5.31.

The skin is cold and moist. The pulse is full. The breathing is stertorous. There is a cut on the outer side of the right eye. There is evidence of previous heamorrhage from the nose and from the right ear. The patient is deeply comatose and no speech is possible. The left pupil is larger than the right. The corneal reflex is absent on the right side and present on the left. The knee jerks are equal and active. Both plantar reflexes give an extensor response.

The patient died at 3.30 p.m. on 3.6.31.

There was no post mortem examination.

CASE NO. 200. W.W. A male aged 59. Ward 12.

Admitted 29.5.31. Died 30.5.31.

HISTORY.

The patient's health was poor previous to his accident. His mentality was deteriorating, and he had been suffering from fits. At 7p.m. on the day of admission, while walking in the garden, he fell and struck his head against a sharp ledge. He was brought to the Infirmary and was reported to be conscious when admitted.

EXAMINATION. 30.5.31. At 10a.m.

The skin is cold and moist. The pulse is full and respiration is stertorous. There is a laceration of the scalp in the left mastoid region. There was profuse haemorrhage from the wound on admission but no certain evidence of haemorrhage from the nose or ears. The patient is deeply comatose and unable to speak. He has vomited on two or three occasions. The pupils are equal and there is an obvious strabismus. The knee jerks are equal. Both plantar reflexes give an extensor response. There is no neck rigidity. There is retention of urine.

The patient died on the same day.

POST MORTEM EXAMINATION.

There is a wound behind the left ear. There is no fracture of the skull. There is no epi- or subdural haemorrhage and no subarachnoid haemorrhage. There is a definite softening of the left temporal lobe in the region of the anterior limb of the internal capsule. The cerebral vessels are very atheromatous. There is generalised purulent bronchitis. There is great congestion and oedema of the lungs.

CASE NO. 201. A.G. A female aged 26. Ward 8.

Admitted 7.11.31. Discharged 23.12.31.

Occupation - Taylor's machinist.

HISTORY.

The patient was in good health at the time the accident occurred. At 7.40a.m. on the day of admission, patient was knocked down by a motor-car. She was rendered unconscious and was brought to the Infirmary in a very restless and violent state.

EXAMINATION. 2p.m. on the day of admission.

The skin is cold and dry. The pulse is full, but the respirations are shallow. There is a cut of the scalp in the right parietal region. There is no evidence of haemorrhage from the nose or ears. The patient is deeply stuporose and no speech is possible. Vomiting has occurred. The pupils are equal in size and both react sluggishly to light. The left corneal reflex is absent while the right is present. There is almost complete paralysis of the left side of the body. The face, arm and leg are involved, but the latter is least affected. The right plantar reflex gives a flexor response, but there is no response on the left side. There is no neck rigidity.

8p.m. on the same day.

The patient is now slightly more conscious. Some movement of the left side is now possible, but this is still slight. The reflexes are as before.

8.11.31., at 10a.m.

The patient is still deeply stuporose, but resists interference. The pulse is slower, and the temperature has now fallen to normal. Weakness of the left side is still very marked. The reflexes are as before.

9.11.31.

The patient is able to say a few words. She can be roused to say that she has no headache, but goes to sleep again at once. There is practically /

practically no movement of the left arm or left side of the face. There are slight movements of the left lower extremity. There is no hemianopia. The reflexes are as before.

10.11.31.

To-day the patient is able to answer a few simple questions. The optic discs are both normal in appearance, and the corneal reflexes are both active. There is marked loss of power of the left side of the face and tongue. There is practically no movement of the left upper extremity, but some movement of the left lower extremity is possible. The tendon reflexes are more active on the left side, and the left plantar reflex still gives an extensor response. The abdominal reflexes are weaker on the left side. There is sensory loss to painful stimuli.

12.11.31.

There is no improvement in the hemi-paresis. The patient is still dazed, and there is still some incontinence. To-day the tendon reflexes are all absent. There is a slight degree of headache.

14.11.31. Operation - Professor Fraser.

The dura mater was exposed in the right parietal region in front of the scalp injury. The skull was very thick. There was no epidural blood, and the dura mater was normal in appearance. The wound was closed.

16.11.31.

The patient is slightly more conscious.

28.11.31.

The mental condition is much improved. She is able to read. She remembers being at work about the beginning of this month, but has no further recollection of events till about a week ago. She has a slight recollection of events that have occurred during the past week. There is no headache, giddiness or diplopia. The discs are quite normal in appearance. The weakness of the left side of the tongue and face have greatly improved. The left leg has also recovered some power, but there is little improvement in the condition of the left upper extremity /

extremity. There is no sensory loss over the left side either to pin-prick, light touch, position sense, localisation of point of touch, stereognostic sense, or vibration sense.

5.12.31.

The patient is fully conscious. She remembers being at home on the evening before the accident occurred. She has no recollection of the day on which the accident occurred. There is considerable recovery of shoulder movements, but there is practically no movement possible of the left hand. The reflexes are as before.

20.12.31.

There is a slight improvement in the power of the hand.

EXAMINATION OF THE CEREBRO-SPINAL FLUID. 12.11.31.

The initial pressure is 110mm. of water. Pressure after removing 5cc. is 80mm. of water. The fluid is clear and colourless. There are 150 red blood cells per c.mm., and 2 small lymphocytes per c.mm.

479

GROUP D

CASE NO. 202. M.M. A male aged 56. Ward 6.

Admitted 28.11.31. Died 20.12.31.

HISTORY.

On the day of admission, patient was knocked down by a motor-car, the radiator of the car striking his head in the occipital region. He was rendered unconscious and brought to the Infirmary.

EXAMINATION. 30.11.31.

The skin is warm, the pulse is full and the respirations are deep. There is a laceration of the scalp in the right parieto-occipital region. There is a dark-coloured peri-orbital effusion on the right side. There is no evidence of previous haemorrhage from the nose or ears. There are no injuries to other parts of the body. The patient is deeply unconscious and is unable to speak. He resists slightly during examination, and withdraws from painful stimuli. There is a marked lack of movement of the right side of the body compared to the left. The knee jerks are more active on the left side, and both plantar reflexes give an extensor response. There is a marked degree of neck rigidity.

5.12.31.

The patient is still deeply stuporose. He withdraws the left hand sluggishly from painful stimuli, but there is no movement on the right side. The right arm falls helplessly into the face, and little movement of the right leg can be stimulated. Movements of the left side are strong. There is marked weakness of the right side of the face. Both plantar reflexes give an extensor response.

6.12.31.

The patient attempts to say a few words, but these are meaningless. He attempts unsuccessfully to put out his tongue when told to do so.

10.12.31. /

CASE NO. 202. (Contd.)

10.12.31.

The condition shows no improvement. There is no movement of the right upper extremity, but slight movement of lower extremity on that side can be stimulated. The tendon reflexes are still more active on the left side. The right plantar reflex gives an extensor response, while the response on the left is flexor.

13.12.31.

There is no improvement. There is a purulent discharge from the left ear. The patient gradually became weaker and died on 20.12.31.

POST MORTEM EXAMINATION. 21.12.31.

There is extensive haemorrhage into the right temporal muscle. There is a depressed fracture of the right parieto-occipital region. There is a slight collection of blood outside the dura mater below the site of fracture. There is some subdural blood on the left side, and on this side the dura mater is stained yellow in colour. There is gross extensive sub-arachnoid haemorrhage in this situation. There is no evidence of increased pressure, and on sectioning the brain, only one small haemorrhage was found apart from the contused area on the left side.