

A LABORATORY INVESTIGATION OF
THE CRYOSURGICAL LESION

Submitted by

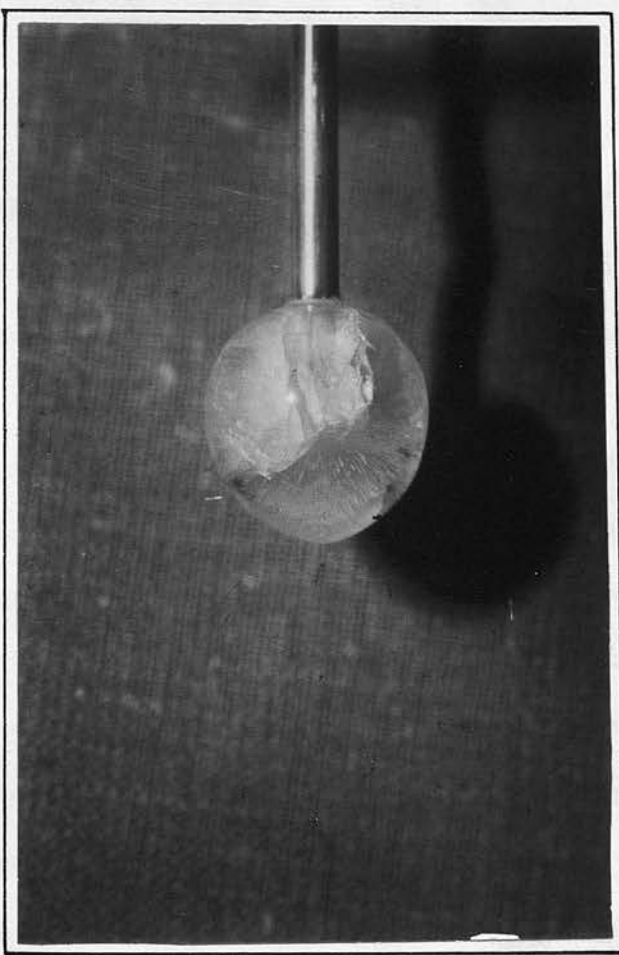
JOHN A.G. DA COSTA, B.Sc., M.B., Ch.B.
Department of Clinical Surgery
University of Edinburgh

29th April, 1969



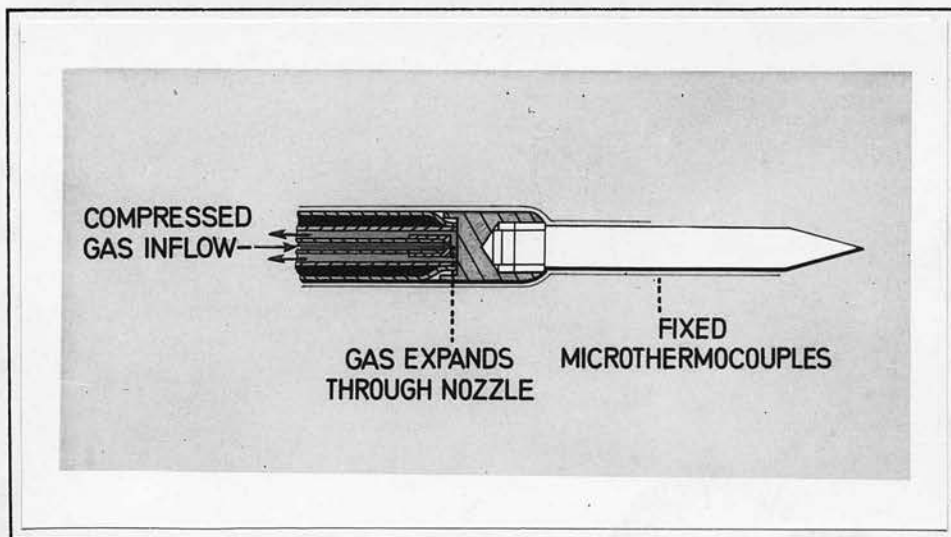
I

PATHOLOGY OF THE CRYOLESION



The typical spherical form of the frozen volume surrounding a cryoprobe tip - in this case water has been frozen.

Fig. 1



Section through the distal end of the Hymatic cryoprobe showing the freezing tip and direction of gas flow as well as the microthermocouple extension beyond the tip.

Fig. 2

INTRODUCTION

Cryosurgery denotes the therapeutic ablation of tissues by cold. Its use was first described by Arnott¹ in 1851 for the treatment of carcinoma of the cervix, but never attained clinical prominence due to lack of a simple controlled means of applying cold to tissues. The introduction, 100 years after Arnott's original treatise of cryogenic apparatus based on the circulation of liquid nitrogen³⁰ reawakened interest in this form of treatment.

Despite its widespread application in many of the surgical specialities over the last eight years, little experimental effort has been made to quantitate the destructive effect of low temperatures used in this way. From the surgeon's point of view it is essential to know what factors determine the quantity of tissue-water frozen under any given conditions, to what extent this phase change of water produces cellular death and how he can best control his freezing to produce optimal destruction.

This paper is a study of:-

(1) The macroscopic and microscopic changes which occur in tissue after single and repetitive freeze-thaw cycles. (Repetitive freeze-thaw cycles indicate successive freezing and thawing at the same site as opposed to multiple freeze-thaw cycles where the successive applications are at different sites.)

(2) Those variable factors which determine the size of the cryolesion (the spherical zone of ice surrounding a cryoprobe in tissue - Fig. 1) and these may be subdivided as being:-

(a)/

(a) Related to the environment.

(b) Related to the cryoprobe.

(c) Related to the tissues.

(3) The thermal gradients inside growing and thermodynamically equilibrated cryolesions and in the adjacent unfrozen tissue.

These three aspects of the problem will be considered separately.

The cryogenic apparatus used throughout these experiments was the Linde-Cooper Cryosurgery Unit CE 2A (Union Carbide Corporation) which utilises circulating liquid nitrogen (-196°C) through a partially insulated operating cryoprobe. Two standard probes whose freezing tips approximated to hemispheres 2.5 mm and 5 mm respectively were used.

A second prototype instrument, supplied by the Hymatic Company, was used which generates cold by the Joule-Thomson effect involving rapid expansion of pressurised Argon (2,500 p.s.i.) through a tight nozzle. The cooling probe (Fig. 2) of this machine carried four microthermocouples embedded at 0.14 cm intervals in a non-heat conducting plastic extension.

The resultant frozen tissue was measured through an operating microscope incorporating an eye-piece graticule scale permitting measurements with an accuracy up to 0.02 cm.

METHODS

The animals used in this study were Sprague-Dawley rats and New Zealand White rabbits. The naked eye changes were correlated with those observed in patients attending a follow-up cryosurgical clinic. The liver was chosen for histological study because of its size, accessibility and its readily observable response to freezing, e.g. colour change.

Through an upper abdominal incision, lesions were produced in the normal liver by a 2.5 mm diameter probe at a temperature of -180°C for four minutes. Serial temperatures in the frozen and immediately adjacent tissues were taken by copper constantan thermocouples inserted 2,4,8 and 12 mm from the probe. Animals were sacrificed immediately after freezing, at hourly intervals for the first 24 hours and thereafter daily for six weeks after freezing. Serial sections of the relevant blocks of liver were then stained with haematoxylin and eosin, trichrome stains (van Geisen, picromallory) and reticulin stains (Lendrum and Gordon Sweet). Crystal formation in the tissues was demonstrated by a freeze substitution technique described by Feder and Sidman².

The degree of destruction within the frozen area was assessed by producing lesions at temperatures of -40°C , -60°C and -80°C applied for forty minutes. The extremities of the frozen tissue were marked by sutures of black silk. Four hours after thawing the animal was sacrificed and the tissue between the sutures was examined histologically.

Two/

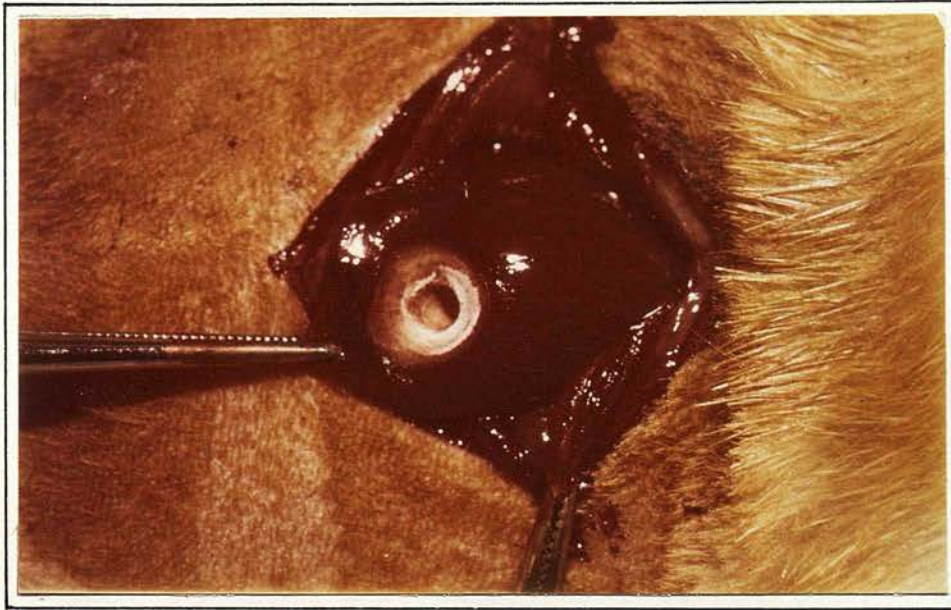


Fig. 3a

Cryolesion in rat liver immediately after freezing. The indentation marks the position of the cryoprobe. The well defined creamy frozen area is noted.

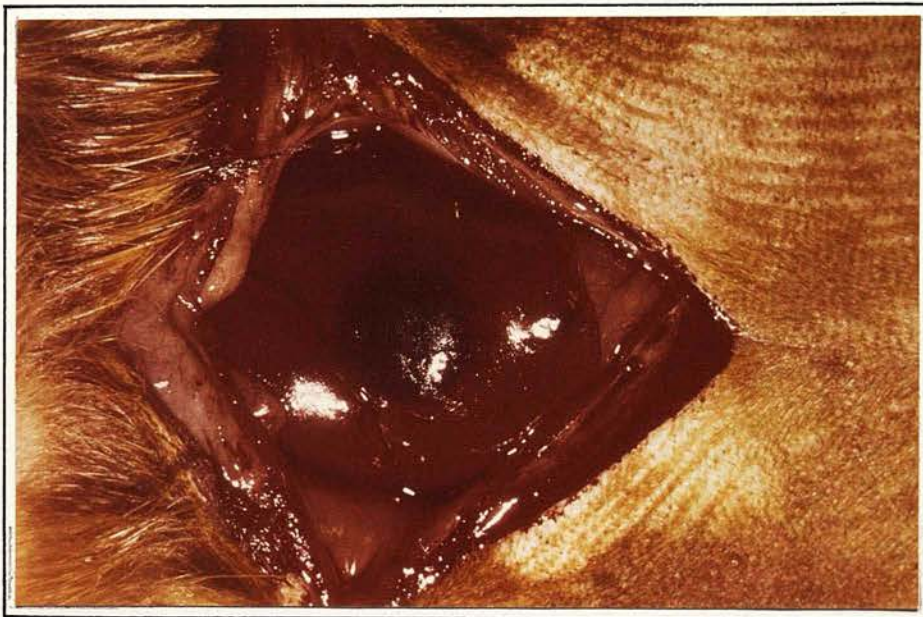

Fig. 3b

Cryolesion in rat liver on thawing. The dark red, well defined, haemorrhagic circle of tissue outlines the extent of freezing.

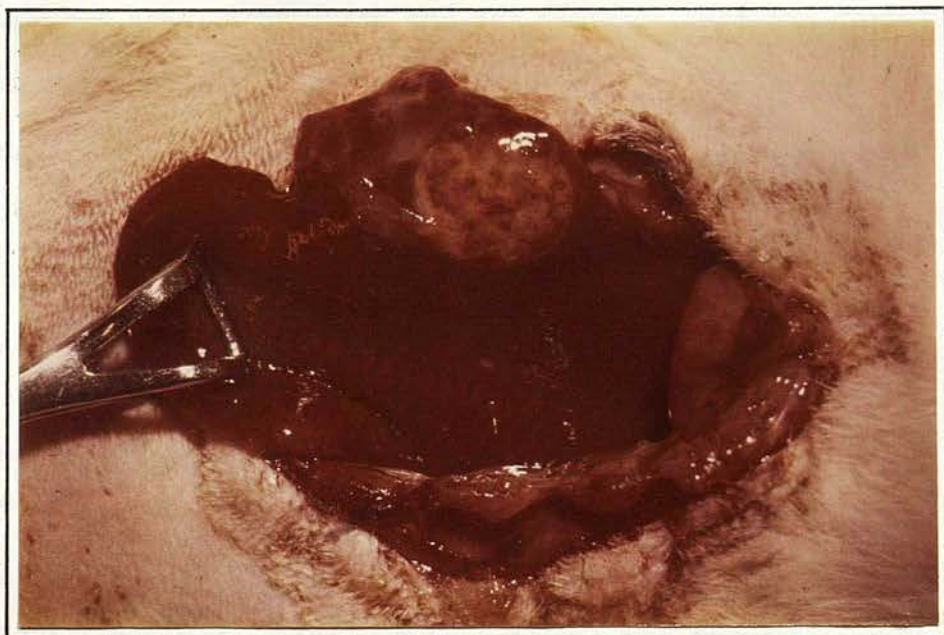

Fig. 3c

Cryolesion in rat liver 24 hours after thawing. The area is now paler and shows a diffusely mottled surface but is still sharply defined.

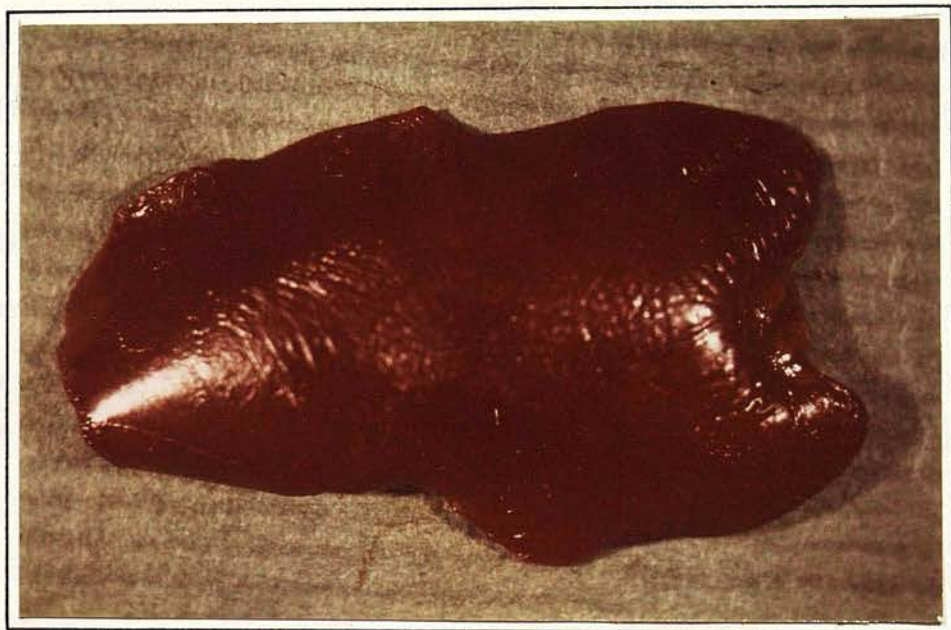


Fig. 3d

Cryolesion in rat liver after 4 weeks. Resolution has taken place and only a dense fibrous scar puckers the parenchyma at the site of freezing (extreme right).

Two per cent Light Green dye was injected into the portal vein during freezing at 2,3,6,11,20 and 30 minutes after thawing to demonstrate local blood flow.

The effects of repetitive freeze-thaw cycles were investigated by the sacrifice of the rats after 1,2,3,4,5,6 freeze-thaw cycles and subsequent microscopical examination of the livers.

RESULTS

The frozen area in the normal rat liver consists of a sharply demarcated yellowish white hemispherical lesion when the probe is applied to the surface (Fig. 3a). On thawing it becomes dark red and haemorrhagic (Fig. 3b). Thawing is complete at room temperature within 4 - 6 minutes of stopping the liquid nitrogen flow. During the ensuing 24 hours the lesion becomes increasingly mottled with grey patches (Fig. 3c) which coalesce by the third day. Gradual reduction in the size of this area is observed until a small fibrous scar remains at the end of the fourth post-freezing week (Fig. 3d). By the sixth week the site of freezing is difficult to find.

Skin lesions, on thawing, become dark red and resemble a haemorrhagic infarction (Fig. 5c). Significant bleeding may rarely occur, secondary to superimposed infection. More frequently, the thawed tissue exudes a serosanguineous liquid which stops within hours, though subsequent exudation of plasma may give rise to blister formation or a firm dry eschar (Fig. 5e). The latter may persist for more than two weeks. When the eschar separates from

a/

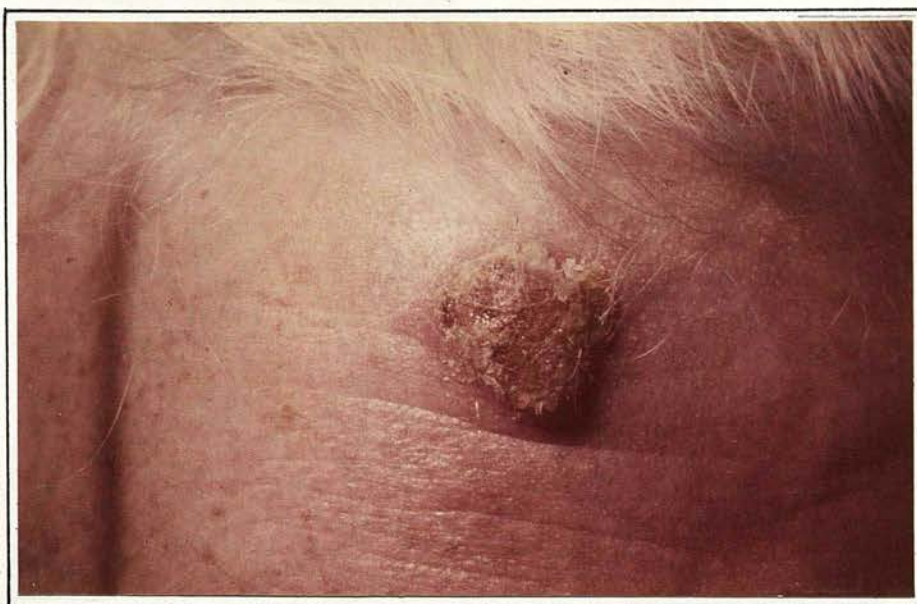

Fig. 5a

Histologically proven squamous cell carcinoma (1.7 cm) on the forehead of a 75 year old woman. Present for 4 months.

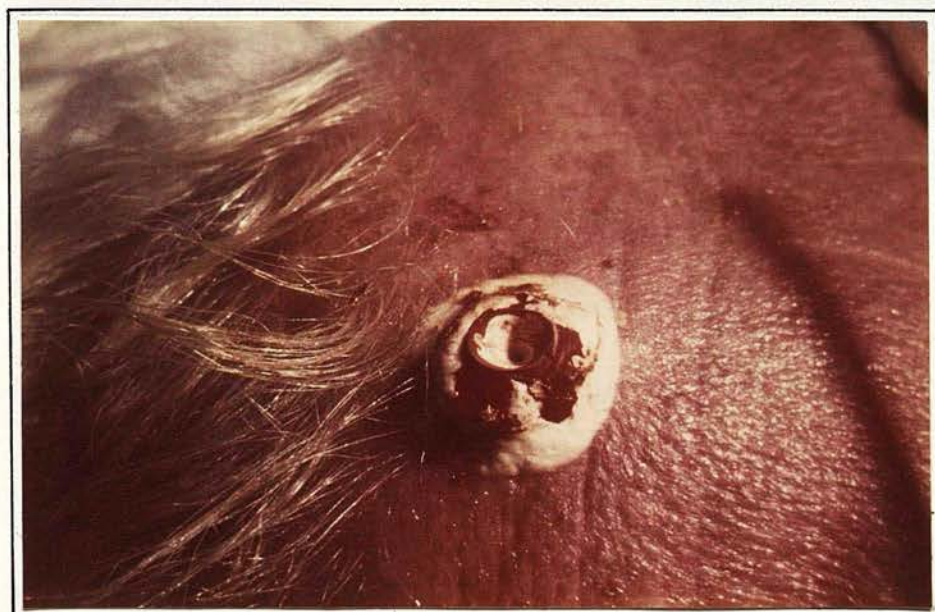


Fig. 5b

After freezing at -160°C for 5 minutes with a large tumour probe.

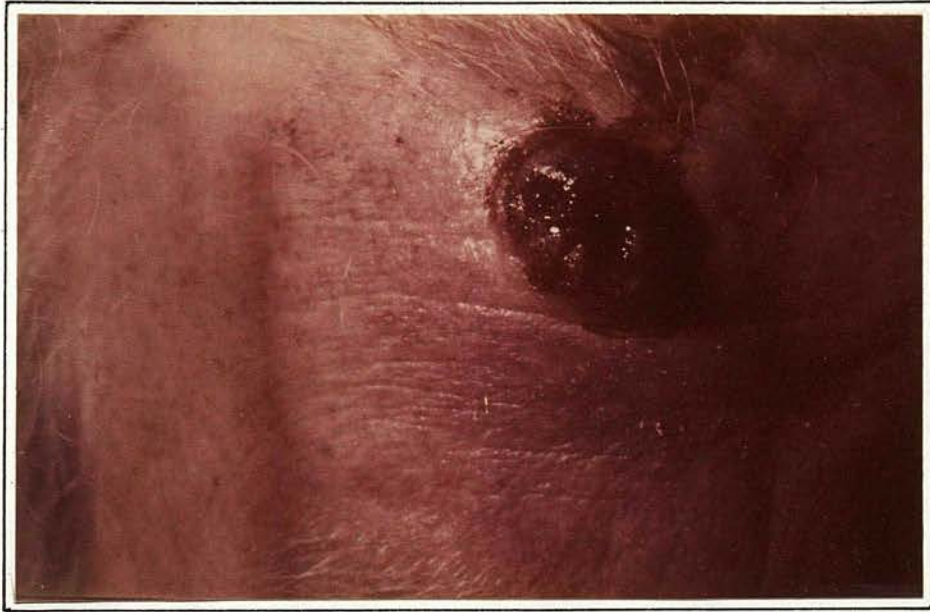

Fig. 5c

On thawing. There has been minimal bleeding but the frozen zone is congested and oedematous.

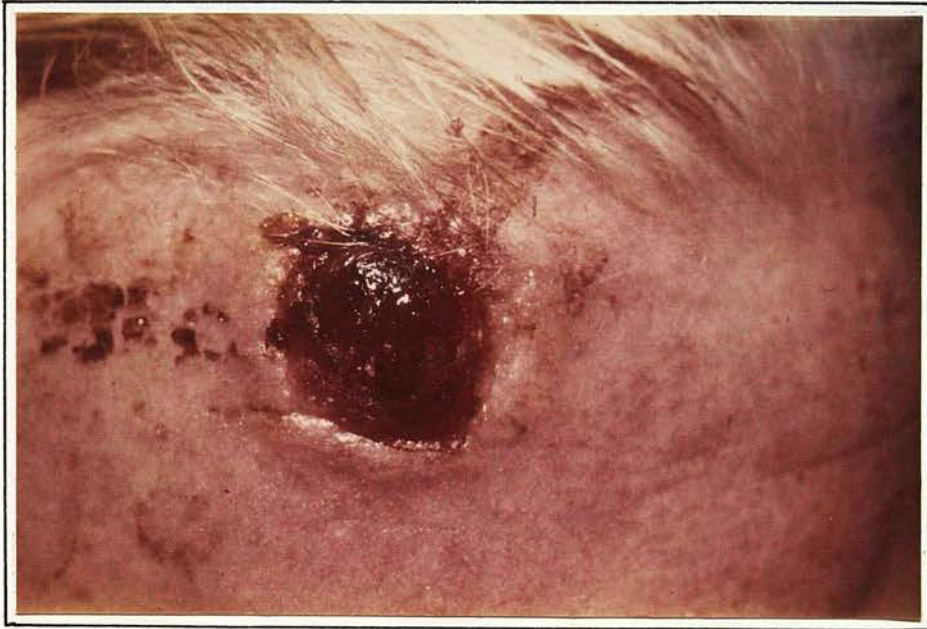

Fig. 5d

24 hours

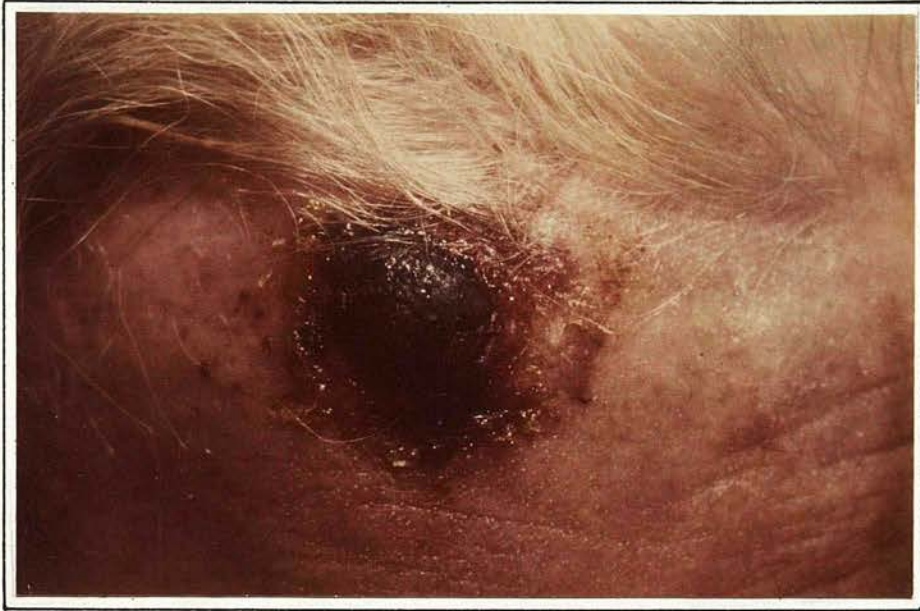

Fig. 5e

1 week

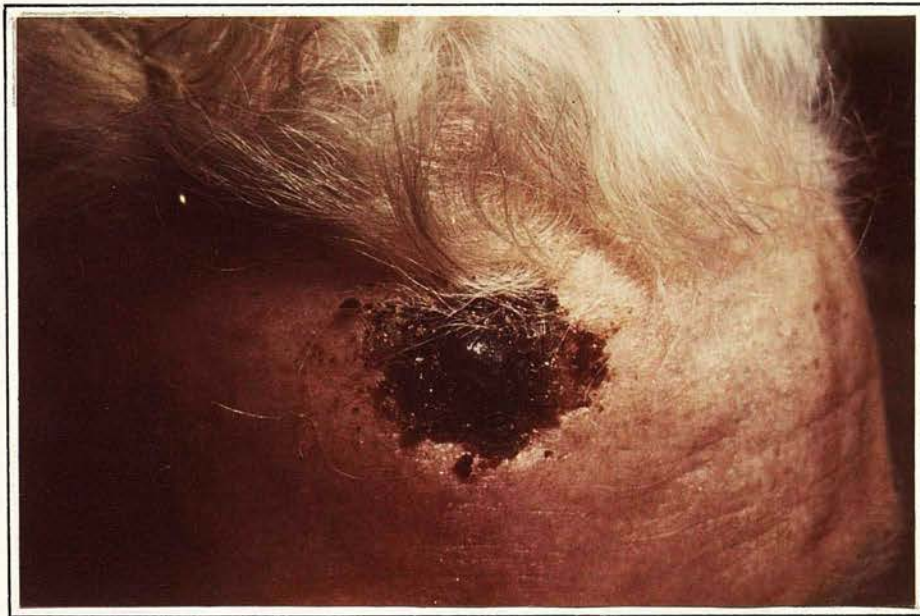

Fig. 5f

2 weeks: Shrinkage of eschar and progressive epithelialisation

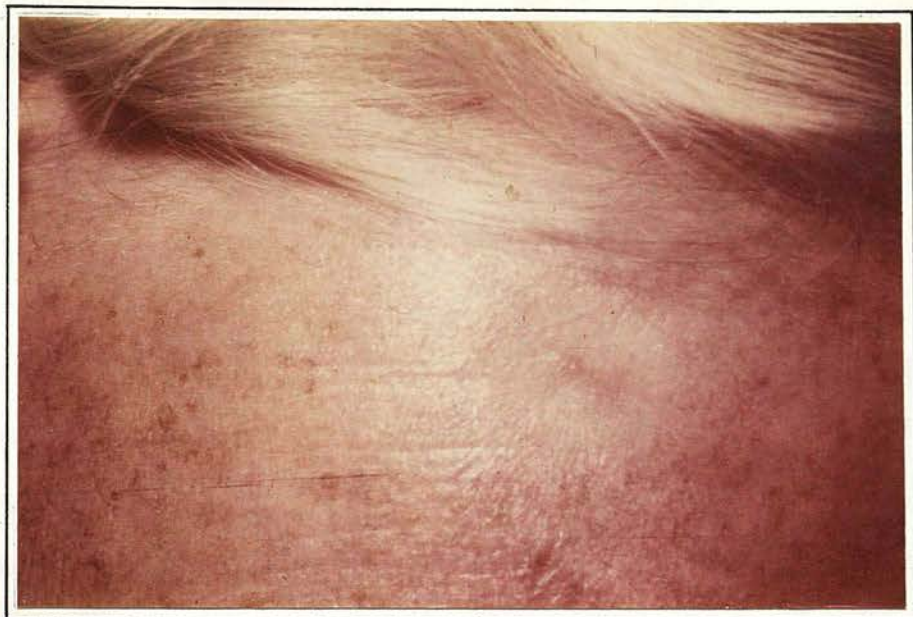

Fig. 5g

8 weeks: Excellent cosmetic result is achieved.
Only a slightly pale atrophic area of skin indicates
the site of the old carcinoma.

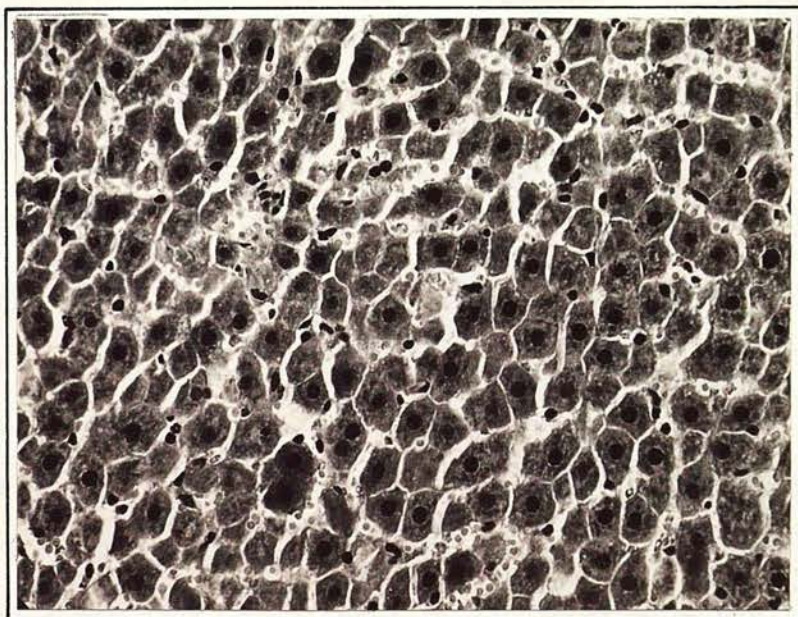


Fig. 6a

Frozen lesion: $\frac{1}{2}$ hour after single freeze.
Sprague Dawley rat liver (H + E) x 300

N.B. Uniform pyknosis, contraction, and granularity.

a lesion of 1 - 2 cm diameter it reveals advanced re-epithelialisation (Fig. 5f). The skin may be left slightly pigmented and atrophic (Fig. 5g) but the final cosmetic result is excellent.

A striking feature is the avascularity of the lesion and this is demonstrated by the minimal ooze of blood which follows incision into the thawed area. Dye injected into the portal vein within two minutes of thawing rapidly concentrates within the thawed lesion (Fig. 4a) which becomes dark green compared to the immediately surrounding unfrozen liver. Dye injected more than six minutes after thawing is excluded from the thawed area by a discrete margin situated at the previous ice tissue interface (Fig. 4b).

Histological changes in the liver are evident immediately on thawing. The earliest changes consist of an area of uniformly altered cells, sharply demarcated from the surrounding liver parenchyma, showing pyknotic nuclei and oedematous coarsely granular and sometimes vacuolated cytoplasm with slight disruption of the reticulin framework (Fig. 6a). Immediate fixation of the frozen lesion using a freeze substitution technique shows a similar demarcating line with crystal spaces in parts of the lesion (Fig. 6b). Intranuclear crystals are also observed in some cells (Fig. 6c).

There is no clear intermediate zone at this stage, but 30 minutes after thawing a distinct band 10 - 30 cells broad separates normal parenchyma from the altered cells described above. The cells of this band show greater eosinophilia and a more granular cytoplasm/

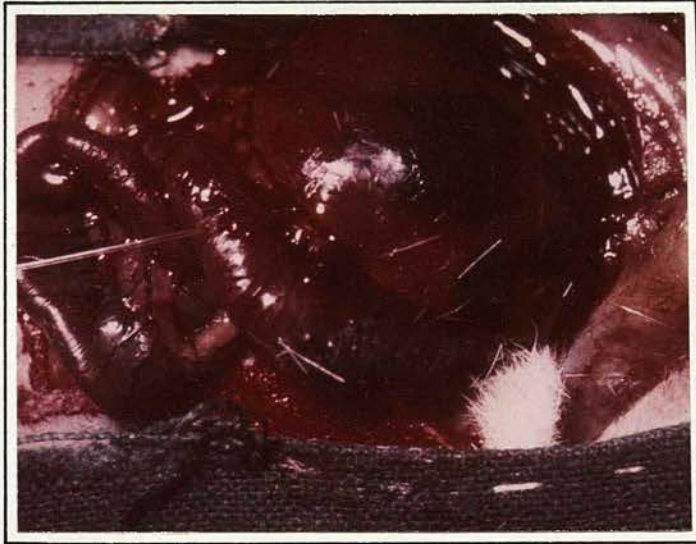

Fig. 4a

2% Light Green dye injected into portal vein 2 minutes post-thawing and has been taken up into the site of freezing while the remainder of the liver apart from the portion near the porta remains unstained.

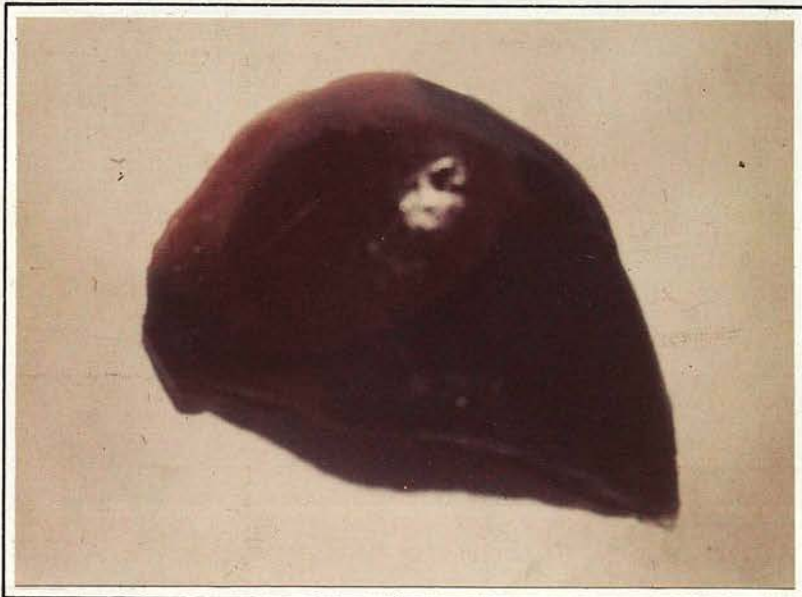


Fig. 4b

2% Light Green dye injected into portal vein 6 minutes post-thawing. The dye stains the entire lobe of the liver with the exception of the frozen zone which is sharply defined (purple).

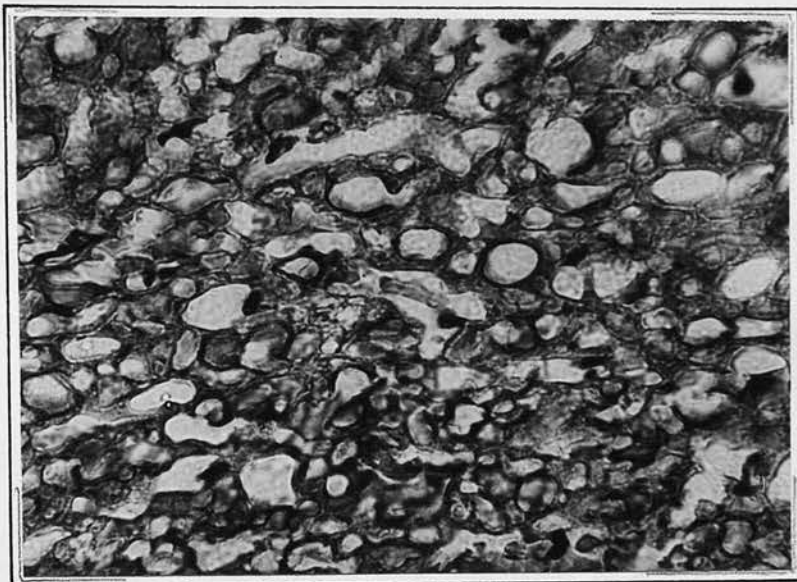


Fig. 6b

Freeze substitution preparation. Sprague Dawley rat liver (x 600) showing extracellular and intracellular crystal spaces.

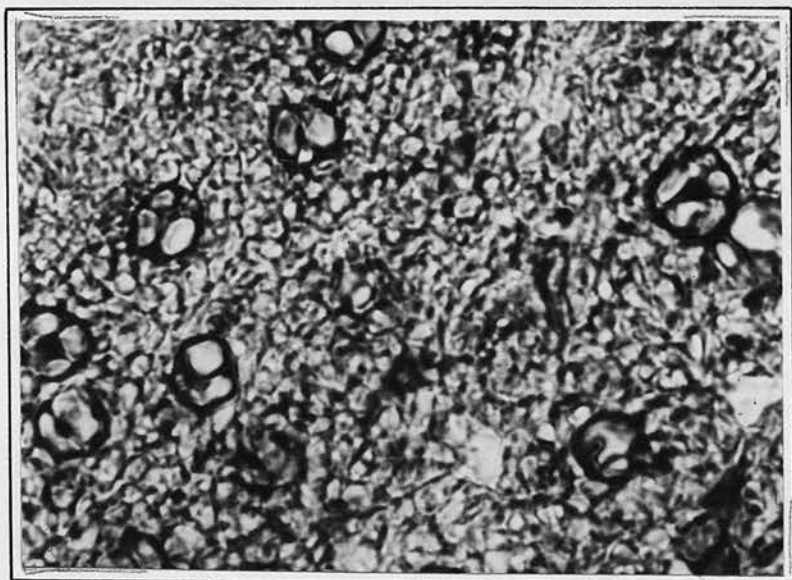


Fig. 6c

Freeze substitution preparation of Sprague Dawley rat liver (x 1200). Multiple crystal formation within nuclei.

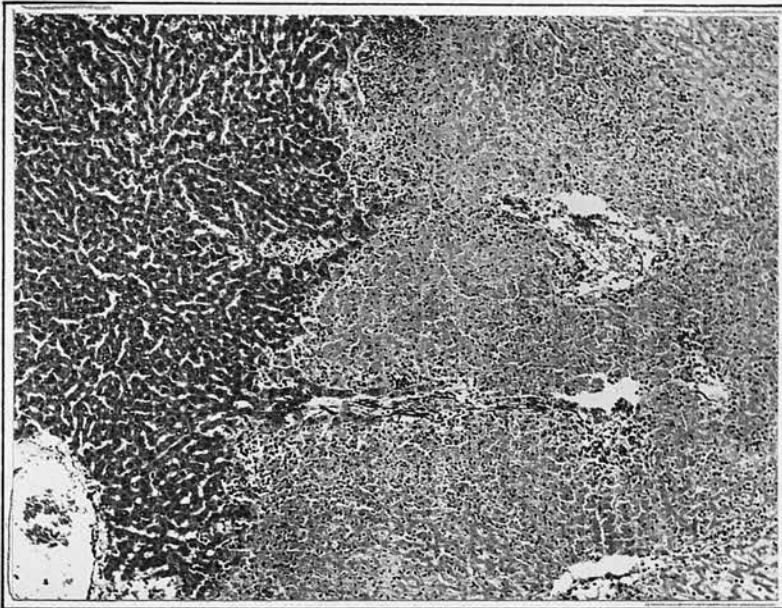


Fig. 6d

Single freeze, Sprague Dawley rat liver (H + E)
(x 60). 24 hours after thawing - discrete pale
cryolesion with peripheral cellular infiltration.

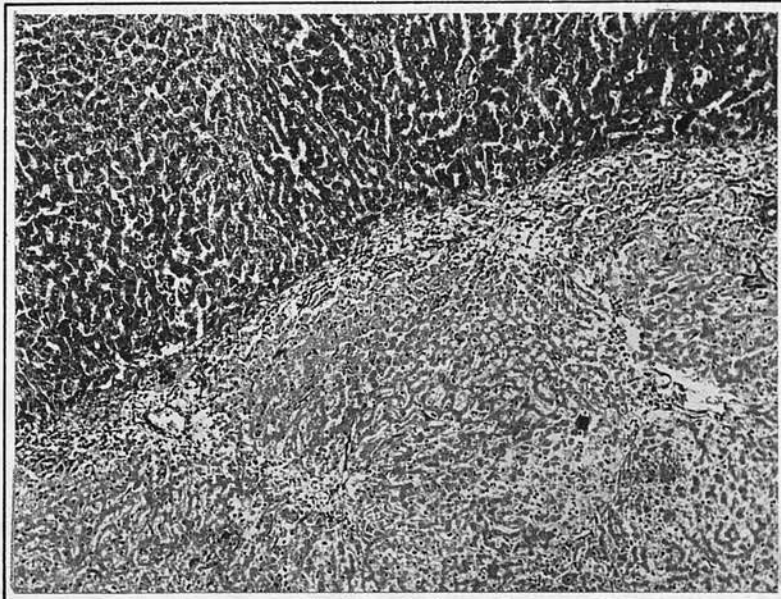


Fig. 6e

Single freeze: Sprague Dawley rat liver (H + E)
(x 60) 3 days after thawing. Note early
encapsulation.

cytoplasm, while their nuclei, though not obviously pyknotic, are smaller, more basophilic than normal and have an increase in the number and size of chromatin clumps. The cytoplasmic changes are more marked by two hours and are accentuated by the picro-mallory stain. By six hours this intermediate zone is less distinct and it is no longer apparent on sections taken at twelve hours, necrotic cells lying side by side with normal parenchyma. The ultimate fate of this zone is uncertain. It most probably represents cells on the periphery of the frozen lesion which undergo a transient but reversible change with rapid recovery. It is in this zone that one sees a marked increase of the inter-cellular spaces which are filled with red blood cells as a result of vascular stasis and damage to vessels.

During the succeeding 24 hours there is a rapidly increasing cellular infiltration of polymorphs, lymphocytes and plasma cells confined predominantly to the margin of the lesion (Fig. 6d). There is progressive pyknosis, karryolysis and karryorhexis, thrombus formation in peripheral vessels, disintegration of the vascular walls and frank eosinophilic necrosis. Peripheral fibroblastic activity is seen early and by the third day there is prominent organisation around the lesion (Fig. 6e). A fibrous capsule containing newly forming bile ducts and fine capillary-like vessels appears by the fourth day and surrounds the dead tissue (Fig. 6f). A gradual absorption of dead tissue follows, accompanied by a progressive inward organisation. Liquefaction necrosis/




Fig. 6f

Single freeze: Sprague Dawley rat liver (H + E)
(x 150) 4 days after thawing, showing developing
bile ducts and vascularisation.

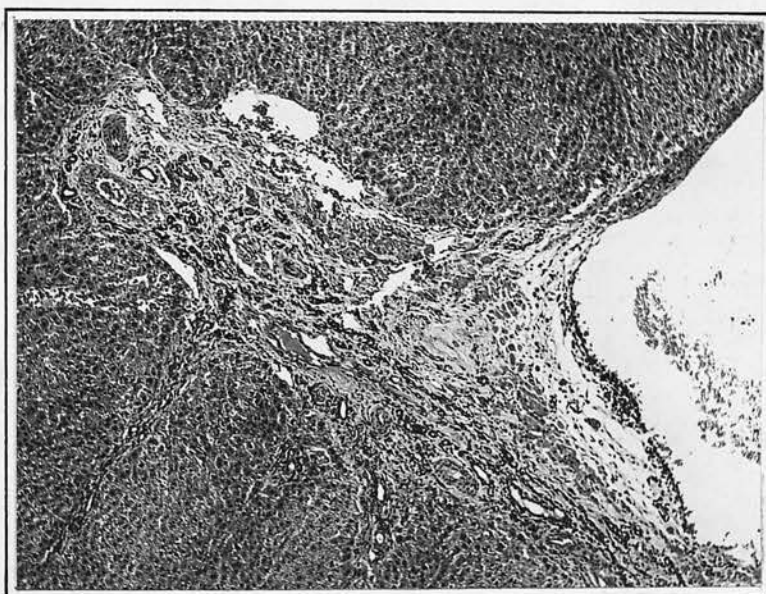

Fig. 6g

Single freeze: Sprague Dawley rat liver (H + E)
(x 30) 7 weeks after thawing. Residual scar.

necrosis and subsequent pseudocyst formation has been noted in some sections. Throughout this whole period the adjacent liver parenchyma shows little morphological change.

In essence, from the third day onwards the appearance of the frozen parenchyma is that of an ischaemic infarction, the whole sequence of events occurring somewhat more rapidly than that seen in myocardial infarction.

REPETITIVE FREEZE-THAW CYCLES

Repetitive freezing of rat liver at the same site increases the volume of destruction for the same conditions until a new maximum is reached after some six freeze-thaw cycles (Fig. 7). At the same time, the rate of formation of a lesion of given size increases and there is a greater tendency for the lesion to exude blood or plasma.

The macroscopic changes are more intense but basically similar to those after a single freeze. With successive cycles the area appears more haemorrhagic and the parenchyma softens, resembling liquefaction necrosis.

Histological changes also parallel those seen after a single cycle but appear in a more exaggerated form. After several freeze-thaw cycles there is a progressive loss of cytoplasmic detail and disruption of plasma membrane barriers.

DISCUSSION/

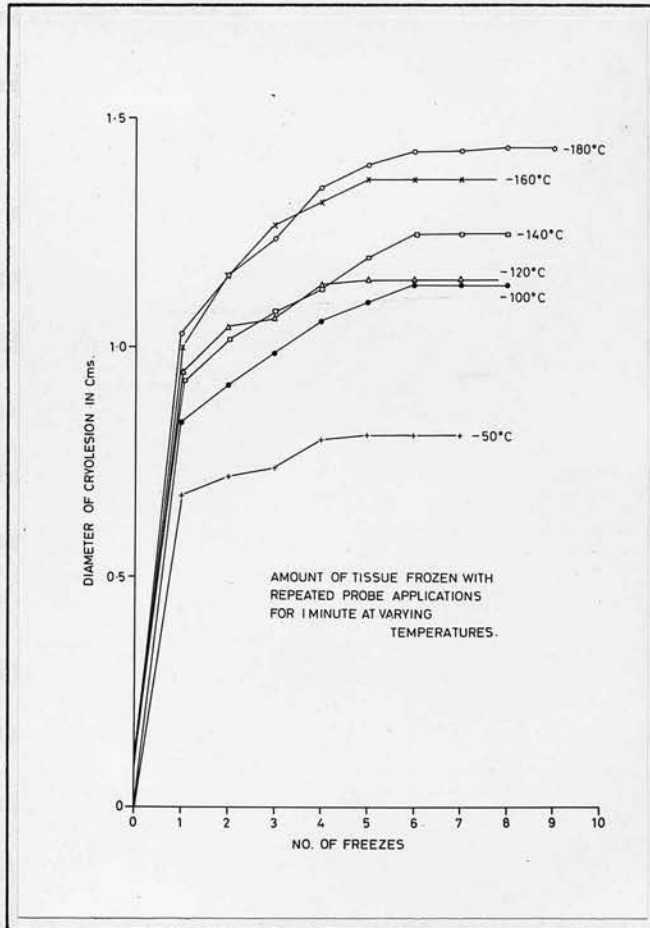


Fig. 7

The effect of repetitive freezing

The steady increase in diameter to a maximum after some six cycles is noted at all temperatures. 1 minute applications of the cryoprobe.

DISCUSSION

Most information concerning the effects of freezing on cells pertains to laboratory models (suspensions of spermatozoa³, erythrocytes⁴ and yeasts⁵) and such observations may not be relevant to tissue freezing in situ where the blood supply is an important added consideration.

The mechanism of the freezing injury is still controversial, and different factors may be involved with different models. Intracellular crystal formation, intracellular dehydration and subsequent enzyme inhibition by concentrated solute in the cell⁶, pH changes⁷, disruption of lipoprotein membrane components⁸ or structured water lattices⁹ have all been implicated.

Histological observations indicate that a sharply demarcated zone of uniform cell death follows single or repetitive freezing. Whether or not all the tissue in which water has undergone a phase change will ultimately die, depends on several factors, including freezing and thawing rates, circulatory stagnation, depth of temperature and exposure time.

Intracellular ice formation which results when rapid freezing rates are applied to tissues is generally considered to be lethal. However, work published by Bush et al.¹⁰ relating to rat kidneys in vivo, and Sherman¹¹ with ascitic tumour cells has shown that this general principle is not without exception. When slow freezing rates are applied to tissues the water has time to move from cells into the ECF and the resultant crystal formation is essentially/

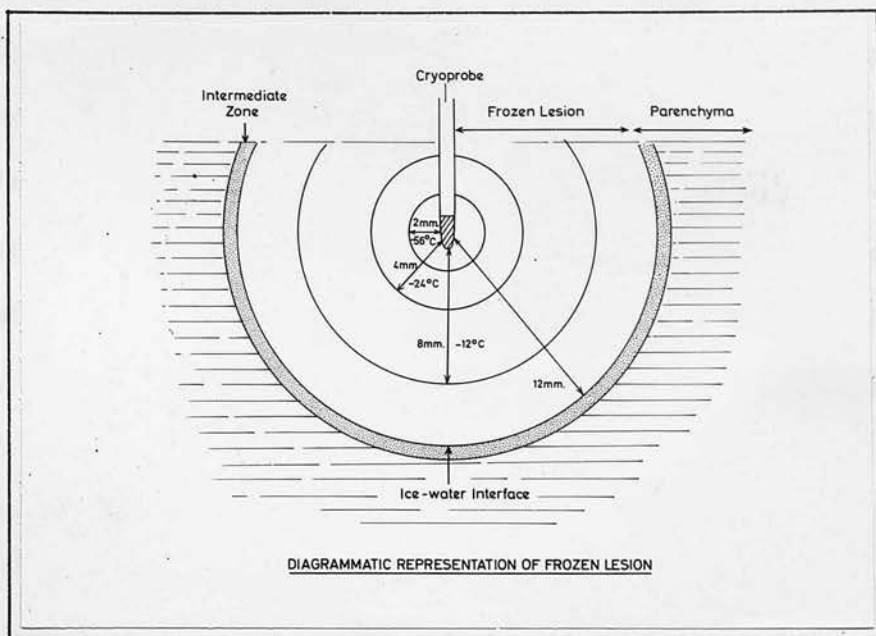


Fig. 8

The cryolesion in tissue

The temperatures at different distances from the centre of the lesion are marked against the circles. The mottled peripheral ring denotes in exaggerated form the intermediate zone of transient cellular dysfunction some 10-30 cells broad.

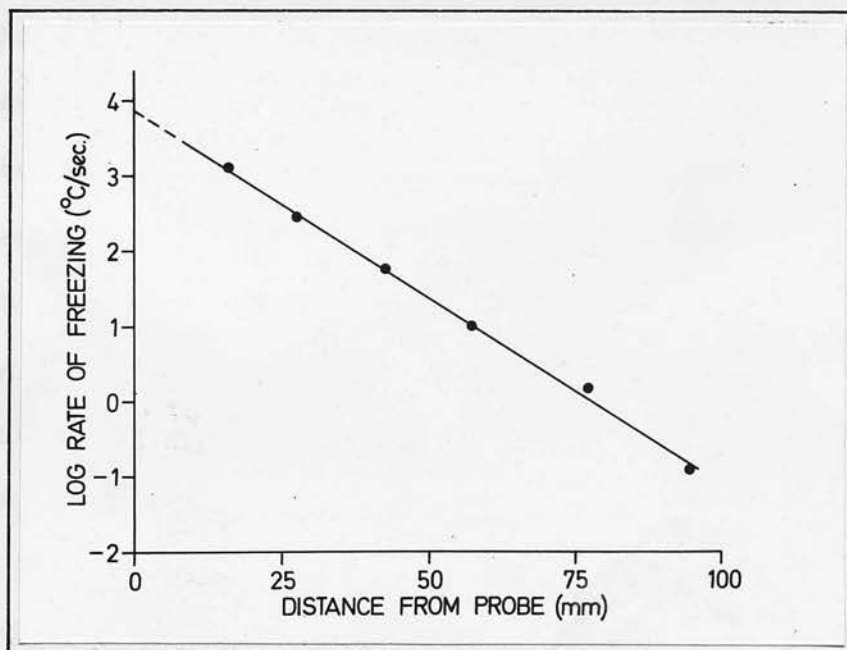


Fig. 9

The freezing rates ($^{\circ}\text{C}/\text{sec.}$) undergone by cells at different distances from a probe tip whose temperature is -160°C . At higher probe temperatures comparable lines lie below and parallel to this line.

essentially extracellular under these conditions. Smith¹² has shown that live golden hamsters can survive cooling until their rectal temperature is -4°C and 30 - 40% of their total body water is frozen extracellularly. These experiments demonstrate that ice formation in tissues is not the only factor involved in their eventual death and that survival might be related to the rapid rates of thawing employed by these workers. Several workers stress the lethal effects of slow thawing^{13,14} which encourages "grain growth"¹⁵ (the formation of very large crystals at the expense of smaller ones) at temperatures just below the melting point. If cells can be rapidly reheated through this critical temperature zone the chances of survival are greatly enhanced.

Thermal gradients (Fig. 8) within the large, equilibrated cryolesion in tissues show that a significant volume of frozen tissue is not cooled below -10°C . Under these circumstances, where the peripheral temperature gradients are very shallow and the time over which they extend their effect on tissues is relatively long (the larger the lesion grows, the slower the rate of growth) no intracellular ice forms in the peripheral parts of the lesion, although cell death undoubtedly occurs in these regions.

Fig. 9 (derived from data discussed in the next section) shows the various rates of freezing experienced by cells at increasing distances from the freezing probe. The cells nearest the cryoprobe undergo freezing rates of $100^{\circ}/\text{sec}$. with intracellular ice formation, while at the periphery of the frozen tissue, freezing rates/

rates are about one million times slower and only extracellular crystallisation can occur with no certainty of cell death were this the only consideration. The observations recorded here on tissue subjected to prolonged freezing with small resulting peripheral temperature gradients indicate that death occurs throughout the whole frozen volume. The explanation for this all-or-nothing cell mortality may be related to the slow thawing rates used (circa $0.01^{\circ}/\text{sec.}$) or to ischaemia and subsequent cellular hypoxia. Injection of dye into the portal vein shows that for the first three minutes after thawing the blood flow to the frozen tissue is increased, as indicated by the rapid appearance of dye in the frozen tissue during this period while the remaining liver is unaffected. After five or six minutes no dye enters the thawed zone which has become entirely avascular and is well delineated from viable tissue by the dye. There is a good deal of circumstantial evidence to support this hypothesis apart from the obvious resemblance of the lesion to an ischaemic infarction and the histological findings of peripheral thrombosis. This evidence includes the work of Quintanilla et al.¹⁶ who have shown, in rabbits subjected to frostbite of the legs, that immediately after thawing the vessels appeared normal in every respect. However, between 5 and 10 minutes later the vessels dilated widely and became filled with blood cells. The endothelial permeability was increased and formed elements were left within the vessels in conglomerate masses. The occurrence of damage to blood vessels with/

with vascular thrombosis during freezing has been reported by Crismon¹⁷ and Walder¹⁸.

While the techniques applied to this problem appear to demonstrate total cell death within the cryolesion irrespective of the freezing rates and depth of cooling of the cells, histological assessment does not permit a definitive opinion on the fate of peripheral cell layers which may not be irreversibly damaged.

REPETITIVE FREEZE-THAW CYCLES

Reports in the literature claim that repeating the freeze-thaw cycle increases the degree of tissue damage¹⁹. Present studies indicate that freezing in situ produces an all-or-nothing cell mortality and the apparently increased efficacy of repetitive freeze-thaw cycles is due to an increase in the extent and rate of freezing with successive cycles subsequent upon an increased thermal conductivity of tissues.

In living tissues, the greatest difference is noted between the first and second cycles, and this is attributed to the exclusion of the large thermal capacity provided by an active circulation during the first freeze. The histological appearances indicate reasons for this increased thermal conductivity. After several freeze-thaw cycles cytoplasmic barriers are disrupted and the lesion assumes a haemorrhagic appearance. The increasing infiltration of the repeatedly frozen lesion with blood produces a suspension of disrupted liver cells which increases fluidity of the lesion. These changes/

changes are compatible with a removal of interface barriers and the creation of a homogeneous fluid zone which would facilitate thermal conductivity by conserving the energy wasted supercooling intracellular water, prior to crystallisation.

Investigations of the thermal conductivity of tissues are few and conflicting in their results²⁰⁻²² but support for the hypothesis outlined above is provided by Poppendiek²⁰ who measured absolute thermal conductivity of bovine liver, brain, kidney and muscle before and after cooling to -196°C and observed a 5% increase in his stressed tissues.

II
THE INFLUENCE OF VARIOUS FACTORS ON
THE QUANTITY OF ENERGY

Methods

The freezing characteristics of physiological liquids were investigated and the experiments were repeated on liver, skeletal muscle and skin of unstarved Sprague-Dawley rats and on human post-mortem liver, brain, spleen, lung and kidney. The effect of size, temperature and duration of application of the cryoprobe on the volume of tissue or liquid frozen was investigated (in rat liver and physiological liquids). The effect of the degree of contact between the probe tip and the surface of liquids was also examined.

The influence of the ambient temperature on the volume frozen was examined in liquids maintained at various temperatures in an electric water bath. The effect of osmolality was investigated in solutions of potassium iodide and zinc sulphate of increasing water concentration. Osmolalities of dilute solutions were measured on a Knauer osmometer and for a few concentrated solutions by direct measurement.

II

THE INFLUENCE OF VARIABLE FACTORS ON THE QUANTITY OF FREEZING

The specific gravity, specific heats and freezing points of post-mortem specimens of liver, brain, lung, kidney and spleen were also determined by the methods described below. Specific gravity was measured by weighing fresh tissues both in air and water on a Mettler electric balance.

Specific heats of post-mortem tissues were estimated by the standard calorimetric method of mixtures.

The thermal capacity of the Thermo Flask used (500 ml. capacity) was estimated by placing 500 ml. H₂O into the flask and heating this

METHODS

The freezing characteristics of physiological liquids were investigated and the experiments were repeated on liver, skeletal muscle and skin of anaesthetised Sprague-Dawley rats and on human post-mortem liver, brain, spleen, lung and kidney. The effect of size, temperature and duration of application of the cryoprobe on the volume of tissue or liquid frozen was investigated (in rat liver and physiological liquids). The effect of the degree of contact between the probe tip and the surface of liquids was also examined.

The influence of the ambient temperature on the volume frozen was examined in liquids maintained at various temperatures in an electric water bath. The effect of osmolality was investigated in solutions of potassium iodide and zinc sulphate of increasing molar concentration. Osmolalities of dilute solutions were measured on a Knauer osmometer and for more concentrated solutions by direct measurement of the freezing point depression using a Beckmann thermometer. The specific gravity, specific heats and freezing points of post-mortem specimens of liver, brain, lung, kidney and spleen were also determined by the methods described below. Specific gravity was measured by weighing fresh tissue both in air and water on a Mettler electric balance.

Specific heats of post-mortem tissues were estimated by the standard calorimetric method of mixtures.

The thermal capacity of the thermos flask used (400 ml. capacity) was estimated by placing 300 ml. H_2O into the flask and heating this under/

under regulated conditions with a constant DC current of 1.1 amp. through a 5 ohm resistance heating coil. The details of the method and the calculations involved are described by Kneibitz. The post-mortem tissues had been allowed to equilibrate overnight in a refrigerator until their temperatures were between 5.5°C and 5°C. The specimen was then placed in a known volume of water at a known temperature above that of the laboratory. Allowance for heat loss over the 10 minute equilibration period was made by calibration.

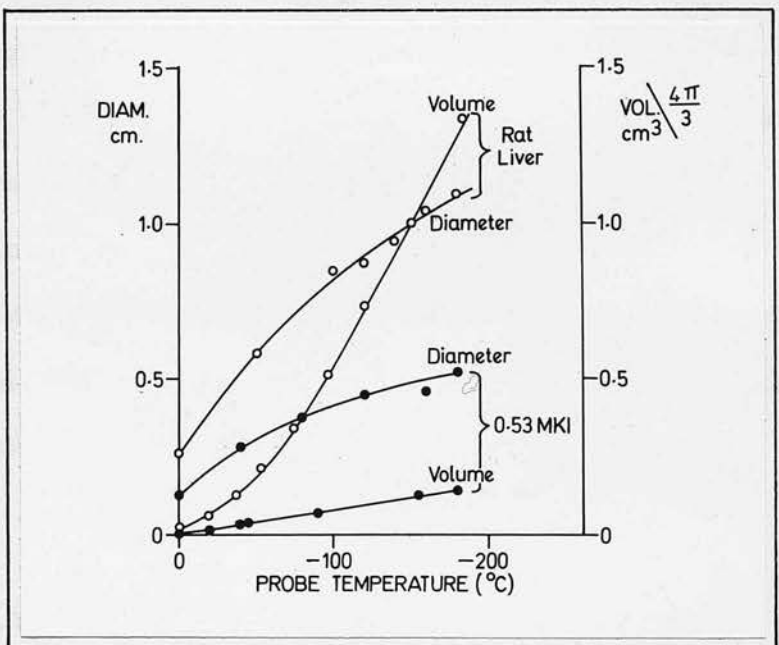


Fig. 10

The effect of temperature upon the frozen volume and diameter in tissue and liquid.

The theoretical values of the maximum tissue diameter are shown in Fig. 10. If the diameter of the hemisphere is plotted instead of its volume, a curve is obtained whose slope increases directly as the linear temperature (due to the fact that the diameter is a linear function of volume).

under insulated conditions with a constant DC current of 1.2 amps. through a 5 ohm resistance heating coil. The details of the method and the calculations involved are described by Mendlowitz²³. The post-mortem tissues used were allowed to equilibrate overnight in a refrigerator until their temperatures were between 0.5°C and 3°C. The specimen was then placed in a known volume of water at a known temperature above that of the laboratory. Allowance for heat loss over the 40 minute equilibration period was made by calibrating the heat loss from measured volumes of water in the flask over 40 minutes at different temperatures above room temperature.

Melting points of post-mortem tissues were obtained by plotting a temperature-time curve (Opie²⁴) during thawing, using micro-thermocouples calibrated against melting ice and observing the point of termination of the temperature plateau so obtained.

RESULTS

Variable factors related to the cryoprobe

The hemispherical volumes of the resultant tissue and liquid hemispheres frozen bears a linear relationship to the probe temperature when other variables are constant (Fig. 10). If the diameter of the hemisphere is plotted instead of its volume, a curve is obtained whose slope decreases slightly at the lower temperatures (due to the fact that the diameter is a cube function of volume).

When/

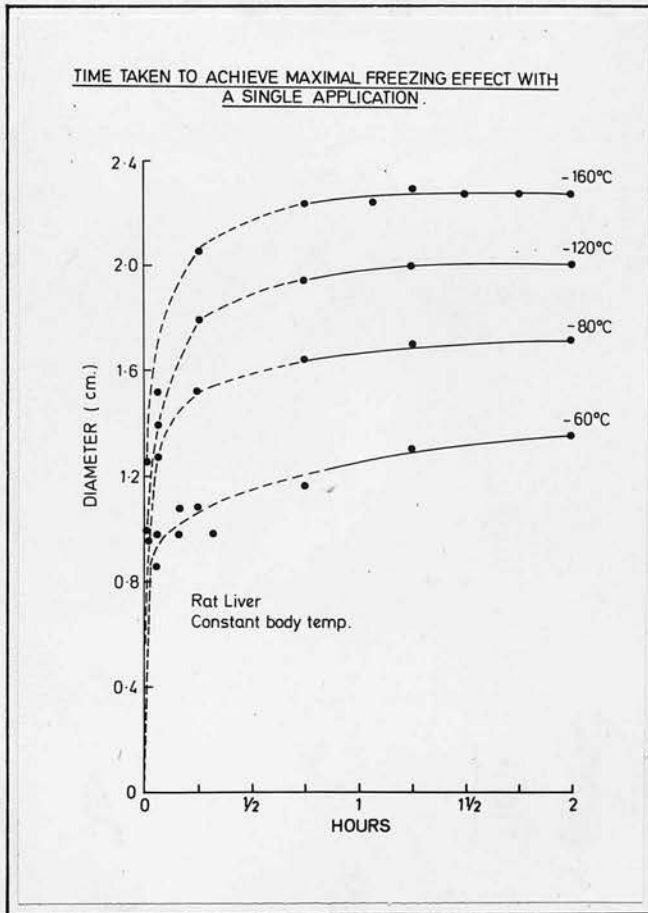
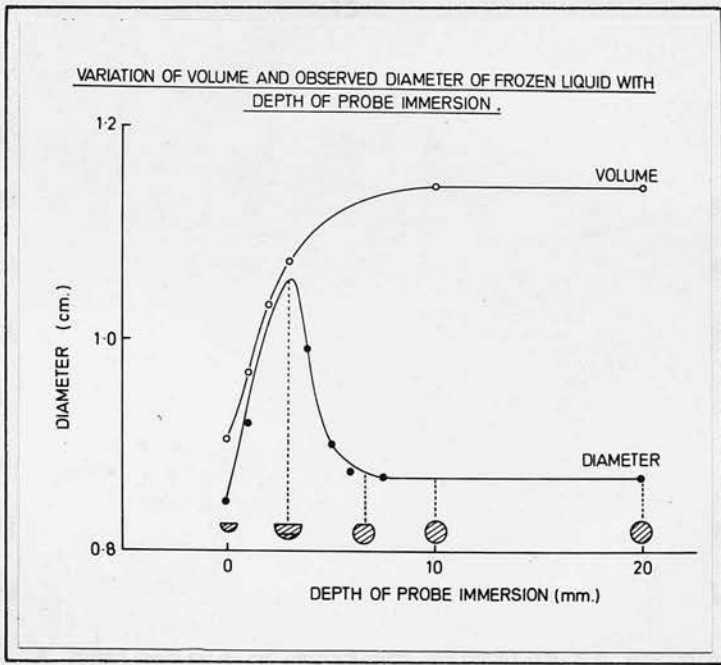


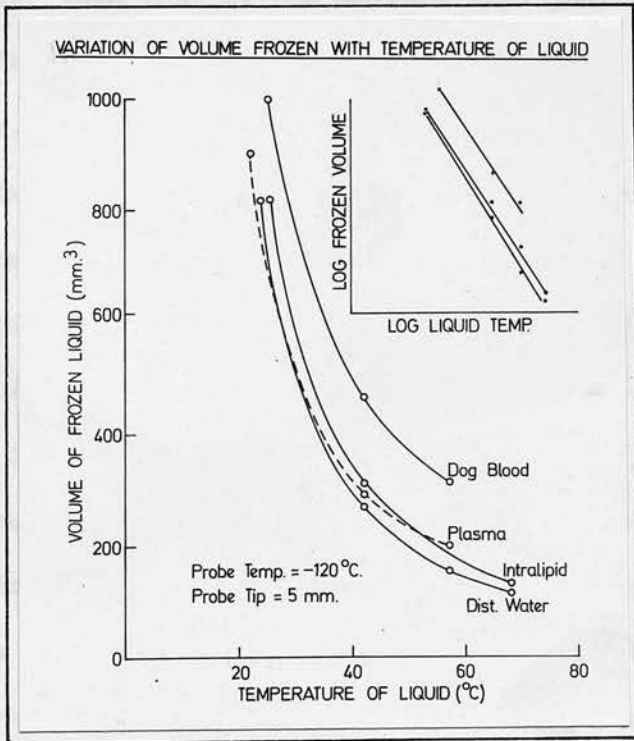
Fig. 11

Variation of the cryo-lesion diameter with duration of application. The probe has been applied at four different temperatures for 2 hour periods to the exposed rat liver with the rat maintained at stable body temperature on a heating table.



The effect of increasing probe contact on the equatorial diameter and volumes of the hemispheres and spheres produced in liquid. Volume scale is arbitrary.

Fig. 12



The effect of changing ambient temperature. The inset shows the linear relationship when the same results are plotted logarithmically.

Fig. 13

When freezing is allowed to continue indefinitely at various probe temperatures there is an initial rapid phase of growth of the lesion in the first 15 minutes, by which time approximately 80-90% of its final diameter and up to 70% of its final volume is reached. Growth then proceeds more slowly to approach a maximum size after 120 minutes of probe application (Fig. 11).

The volume and diameter of the hemispherical lesion increases as the degree of contact between probe tip and liquid is increased (Fig. 12). A hemisphere of maximum diameter is produced when the complete freezing tip of the probe is just immersed in the liquid. As the cryoprobe is further lowered below the liquid surface the geometry of the liquid frozen approaches and finally reaches a complete sphere (when depth = radius) the volume of which is only slightly greater than that of the maximum hemisphere produced under the same conditions. With deeper immersion, there is no further change in size.

Changes in ambient temperature exert a marked effect on the volumes of liquid frozen for given probe parameters (Fig. 13). A fall in ambient temperature in blood from 56°C to 20°C produced an increase in the sphere diameter of approximately 60% and a corresponding increase in the volume of ice of some 300%. When the ambient temperature is plotted against the volume of the frozen sphere, the lines approximate to exponential curves and logarithmic transformation in both axes produces points which are linear over the temperature range 20°C to 60°C . Over a narrower range, for example/

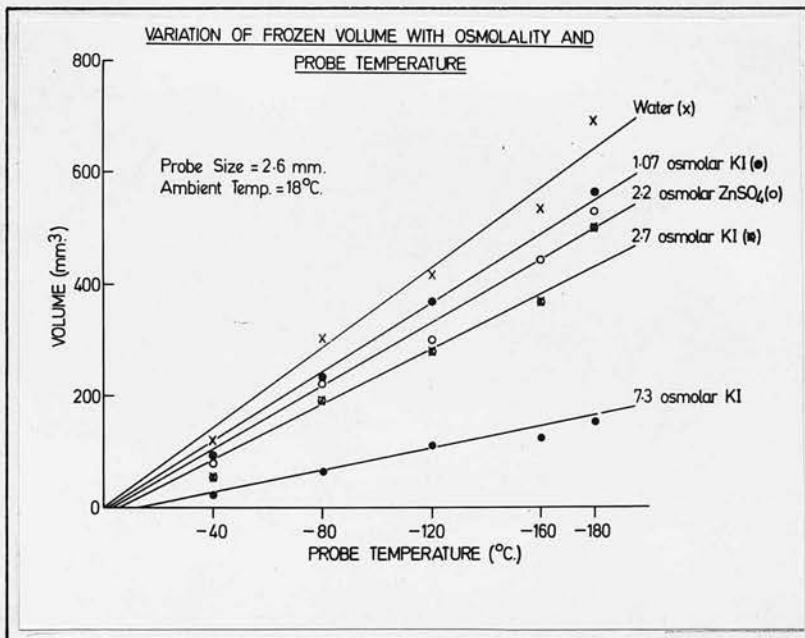


Fig. 14

The variation of lesion diameter with temperature and osmolality.

The influence of osmolality of a solution is demonstrated in Fig. 14. With increasing osmolality smaller spheres are produced with smaller freezing parameters. Table I shows the melting point, specific gravity and specific heat for various diameters. Each reading is the mean of five separate observations.

example 34°C to 40°C the segment of the exponential curve can be considered a straight line and for each degree centigrade fall in ambient temperature a 5% increase in the volume of the iceball is observed. The influence on size of the low specific heat of blood (0.86 cal./g.) as opposed to 1.0 cal./g. for the other liquids is also noted.

An investigation relating probe size to the volume of frozen tissue was undertaken using hemispherically shaped probe tips. The quantity of heat which can pass into a probe in unit time depends upon the area of its freezing tip, while the volume frozen in unit time is a function of the heat extracted in this way.

Expressed mathematically

$$\frac{\text{Area Tip A}}{\text{Area Tip B}} \propto \frac{\text{Volume Sphere A}}{\text{Volume Sphere B}}$$

or

$$\frac{\text{Radius Probe A}^2}{\text{Radius Probe B}^2} \propto \frac{\text{Radius Lesion A}^3}{\text{Radius Lesion B}^3}$$

Analysis of actual readings (corrected to allow for the volume occupied by the probe tip) confirms the relationship within the limits imposed by the variability of nitrogen flow to the probe tip.

Variables related to target

The influence of osmolality of a solution is demonstrated in Fig. 14. With increasing osmolality smaller spheres are produced with similar freezing parameters. Table I shows the melting point, specific gravity and specific heat for various tissues. Each reading is the mean of five separate observations.

DISCUSSION/

TABLE I

TISSUE	SPECIFIC GRAVITY	SPECIFIC HEAT	MELTING POINT
Liver	1.056	0.85 (0.77-0.90)	-1.5°C
Brain	1.034	0.84 (0.66-1.0)	-1.7°C
Spleen	1.070	0.87 (0.84-0.89)	-1.5°C
Lung	0.53	0.90 (0.88-0.96)	-0.8°C
Kidney	1.067	0.84 (0.76-0.87)	-0.6°C

Specific gravity, specific heat and freezing point depression of tissues investigated.

The bracketed numbers represent the range of results.

DISCUSSION

Until recently cryosurgery has found its main application in dermatological²⁵, ophthalmological²⁶, oral^{27,28} and gynaecological²⁹ diseases, where the cryolesion can be seen or palpated by the surgeon. Current surgical uses require the application of cold to such organs as the basal ganglia³⁰, prostate³¹ and hypophysis³² where the target is neither visible nor palpable and the surgeon is left to gauge the degree of tissue freezing empirically (See Figs. 25 and 26).

Theoretical attempts have been made to predict the rate of advance and final position of thermodynamic equilibrium of an ice-boundary growing through liquids³³, brain^{30,18} and corneal tissue³⁴. Such essentially mathematical approaches are inappropriate to general surgical problems because of the lack of data regarding specific thermal characteristics of tissue, e.g. specific heat and thermal conductivity.

When the surgeon is faced with a particular clinical problem, e.g. pituitary ablation, he may obtain guidance regarding the duration and depth of freezing from three sources:-

- (1) Recorded information accumulated from previous clinical experience. Unfortunately such data is rarely obtainable.
- (2) A study of the effects exerted individually by the numerous factors which determine the ultimate size of the cryolesion.
- (3)/

(3) The use of thermocouples to determine the position of the ice-tissue interface which will be discussed in the final section of this paper.

The importance of being able to quantitate the extent of tissue destruction in hidden sites has already been stressed. Sufficient clinical data covering all tissues with all combinations of freezing schedules is not yet available. A knowledge of the influence of the many variables operating in the production of the cryolesion and the establishment where possible of linear relationships between these factors and the resultant lesion size offers the cryotherapist an opportunity to correct empirical data obtained from isolated readings in the living patient.

Previous investigators have suggested that the cryolesion attains equilibrium with its environment in about five minutes³⁵. This study shows equilibration takes much longer although the major part of the growth occurs in the first five minutes. At -125°C the thermal conductivity of ice increases to 175% of its value at 0°C ³⁶. Over the same fall in temperature its thermal capacity decreases to 65% and at -196°C to 37% of its value at 0°C ³⁷. These characteristics of ice at low temperatures will explain the more rapid attainment of equilibrium at low temperatures and are also partially responsible for the more rapid initial growth phase. Previous theoretical attempts to define the position of equilibration of an ice lesion have failed to consider these variations in the thermal properties of ice. Irrespective of the temperature selected, the size of the cryolesion/

cryolesion after 10 minutes of freezing remains a constant fraction of the equilibrium size.

Osmolality has been shown to exert a marked effect on the dimensions of the iceball because of its influence on the freezing point of solutions. One osmole of a solute will depress the freezing point of water by 1.85°C . At low concentrations of solute (less than 600 osmoles) the osmolality is directly related to molar concentration by a factor equal to the valency of the ions in solution. The measured freezing points of the tissues investigated correspond with osmolalities between 430 and 1000m osmoles and agree with the results of Opie²⁴ and Sabbatini³⁸ who claim that the intracellular milieu is maintained at a higher tonicity than the extracellular liquid. The present measurements were performed on autopsy material some twelve hours after death and the increased tonicity might therefore result from post-mortem autolysis with the liberation of osmotically active particles. The kidney examined was obtained two hours after death and a much smaller depression of the freezing point is noted. Amoils³⁴ states the freezing point of living human cornea to be -2.2°C , but suggests this low value may be due to recrystallisation phenomena. Evidence also exists³⁹⁻⁴² which indicates that ICF and ECF are isotonic. Most workers now accept that intracellular osmolality is in the order of 300m osmoles which would depress the freezing point of all tissues by -0.56°C .

The/

The importance of correcting for changes in ambient temperature is evident when one considers that surgically exposed organs can drop in temperature by several degrees centigrade. Alternatively, when one wishes to extrapolate empirical data obtained from exposed organs to organs at body core temperature (e.g. hypophysis), appropriate corrections are necessary. Anaesthesia itself may cause changes in thermoregulatory mechanisms.

Before absolute prediction of local tissue freezing is possible it is necessary to have more specific information regarding the thermal constants of tissues, e.g. specific heats, thermal conductivities, regional blood flows in organs.

Since what the surgeon is freezing in tissue is principally a dilute aqueous solution of mixed ions, the water content of the tissue will have an influence on the size of any volume frozen under given conditions. The specific heat of water (quantity of heat needed to raise 1 g. by 1°C) is greater than any other common pure liquid or solid while its thermal conductivity is greater than solutions of gels + solutes in water. Grayson⁴³ has shown that a linear relationship exists between the percentage water content of gels and their thermal conductivity and suggests that the relationship between total protein and total water in animal tissues is probably the major factor in determining the thermal conductivity. An analysis of data published by Poppendiek²⁰ on bovine tissues and human blood and plasma certainly shows a linear correlation between the weight of water per unit volume of tissue and its thermal conductivity/

conductivity, except in the case of the lung where the large volumes of alveolar air complicates the relationship.

The water content per unit volume of tissue (tissue density x percentage water by weight), based on data in the literature⁴⁴, provides calculated specific heats of 0.68 - 0.85 cal./g. if water alone is considered. The actual specific heats will be higher when one takes into account the aggregate thermal capacity of the constituents, e.g. colloids comprising that 15 - 22% of tissue volume which is not water. The true specific heat of tissues would however remain below 1 cal./g. because it cannot be greater than that of pure water. There is little available information on tissue specific heats but the recorded results for the five tissues studied are compatible with the reasoning already outlined and agree with the values obtained by Henriques⁴⁵ who noted skeletal muscle to have a specific heat of 0.91 and Mendlowitz²³ who noted blood to have a value of 0.86 at normal haematocrit.

For a given rate of heat extraction at its centre, a cryolesion in tissue will grow at a rate which is directly related to its thermal conductivity and indirectly related to its heat capacity per unit volume of tissue.

This can be expressed mathematically as:-

$$\text{Size attained in unit time} = \frac{\text{Thermal conductivity (K)}}{\text{Specific heat x density (S) (D)}}$$

The fraction $\frac{K}{DS}$ is termed the thermal diffusivity of a system⁴⁶ and is the most pertinent consideration when dealing with heat transfer/

TISSUE	DENSITY gm/c.c.	SPECIFIC HEAT cals./gm	THERMAL CONDUCTIVITY cals./gm ² /sec./°C	THERMAL DIFFUSIVITY
MUSCLE	1.070	0.91	0.00126 ^P	0.00129
LIVER	1.056	0.85	0.00116 ^P	0.00129
BRAIN	1.034	0.84	0.00119 ^P	0.00137
KIDNEY	1.067	0.84	0.00125 ^P	0.00141
SKIN	1.042 ^P	0.81 ^H	0.00085 ^P	0.00101
FAT	0.84 ^P	0.55 ^H	0.00055 ^P	0.00119
LUNG	0.54 ^P	0.90	0.00067 ^P	0.00137
WATER	1.00	1.00	0.00143 ^P	0.00143
BLOOD	1.055	0.86	0.00127 ^P	0.00115

Table II

Combined available data along with present results to illustrate the variation in thermal diffusivity of tissues.

P = Poppendiek et al.²⁰

H = Henriques et al.⁴⁵

Thermal diffusivity units in cm²/sec.

transfer in tissues. Table II lists the data relating to tissue variable factors at present available along with thermal diffusivity values compiled from these figures. The results illustrate the small variation that is encountered between tissues in respect of their thermal diffusivity. There is, however, no correlation between thermal diffusivity and their water content from these figures. The differences between fat, brain and such parenchymal organs as lung, kidney and liver are small enough to be insignificant in clinical practice. The thermal diffusivity of skin is some 20 - 25% less than the parenchymal organs, but control of tissue freezing is not a problem when dealing with this tissue because of its accessibility. It should be remembered that the specific heats quoted above relate to tissues in vitro. In vivo, the thermal capacities of tissues are much greater due to the presence of an active circulation capable of contributing heat to the surface of a growing lesion. The blood flow per unit volume of tissue becomes a very important consideration for the cryosurgeon in his treatment of, for example, vascular cerebral haemangiomas or specific sites such as the pituitary fossa where the cavernous sinuses act as large thermal capacitors. At present, insufficient information relating to this aspect of the problem exists and further studies are indicated.



The diagram illustrates the placement of thermocouples on the hull of a vessel to measure temperature gradients. It shows three cross-sectional views of the hull, with thermocouples positioned at various depths and locations to capture data on temperature distribution.

III

TEMPERATURE GRADIENTS AND THE USE OF THERMOCOUPLES



The graph illustrates temperature gradients. The vertical axis represents temperature, and the horizontal axis represents distance. The lines represent different temperature profiles or gradients, showing how temperature changes with distance.

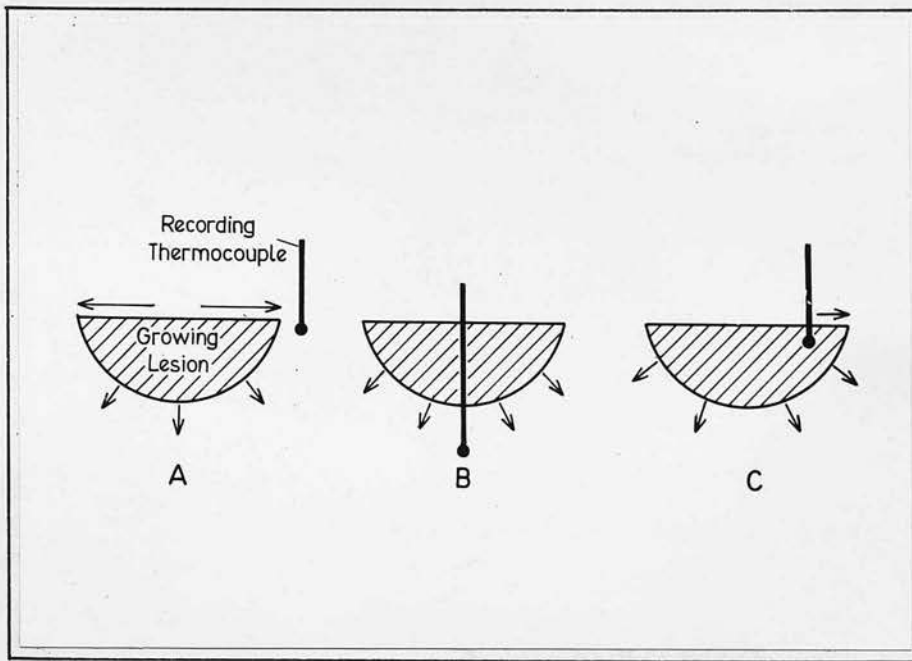


Fig. 15

The various relationships of the recording thermocouple to the growing lesion discussed in the text. The arrows indicate the direction of growth of the ice lesion.

B = involved thermocouple

C + A = non-involved thermocouple

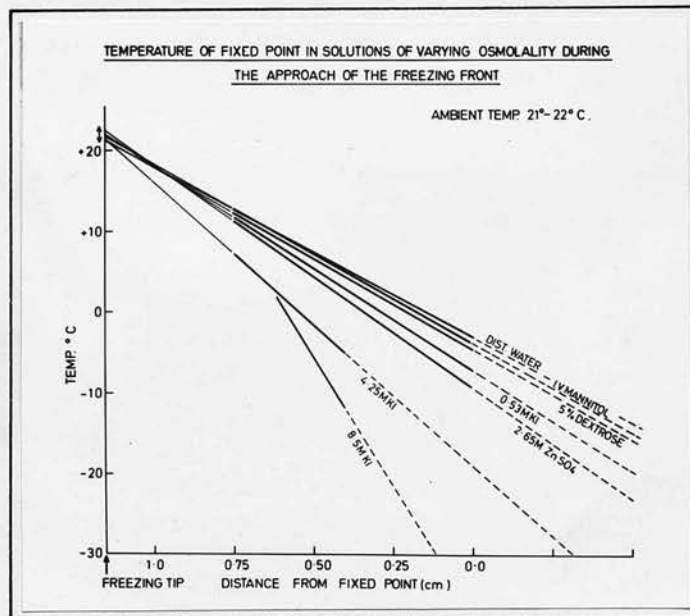


Fig. 16

Temperature-distance profiles in solutions of increasing osmolality. Thermocouple situated 1.2 cm from the freezing tip.

TEMPERATURE : DISTANCE PROFILES IN TISSUE
HUMAN P. M. LIVER

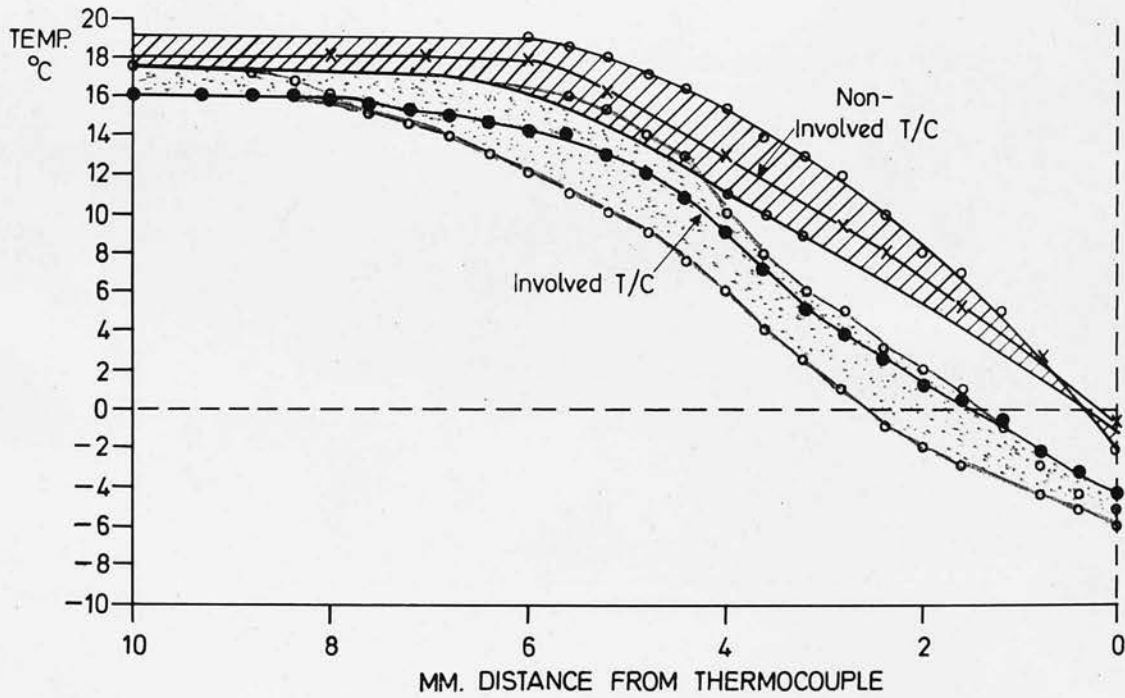


Fig. 17

Temperature-distance profiles in human post-mortem liver from involved (lower) and non-involved (upper) thermocouples, both situated 1 cm from the freezing tip. The shaded areas represent the scatter of results.

METHODS

Temperature changes created in the tissue immediately adjacent to the edge of a growing cryolesion were recorded from a thermocouple fixed in the unfrozen tissue and were related to the diminishing distance from the approaching ice boundary (Fig. 15a). (This information then allows the construction of a temperature-distance profile.) In thermodynamically equilibrated cryolesions, gradients were obtained by recording temperatures at various distances from the static ice-front using individual microthermocouples (copper constantan made by B.I.C.C. Ltd.) linked to a Honeywell recorder. The thermal gradients occurring within both static and expanding cryolesions at various cryoprobe temperatures were investigated in water, agar, albumen and post-mortem tissues by the use of microthermocouples which were placed at fixed distances from the probe tip. The ice-front was then allowed to approach, encompass and grow beyond the microthermocouples (Fig. 15c).

RESULTS

Temperature gradients in the media surrounding iceballs

The effect of the advancing freezing boundary on the temperature in adjacent non-frozen liquid is shown in Fig. 16 which represents the temperature distance profiles recorded at a thermocouple 0.6 cm from the lateral border of the probe in solutions of increasing osmolality. Fig. 17 shows the similar profile obtained in liver. The thermocouple first detects the zone of thermal change which surrounds/

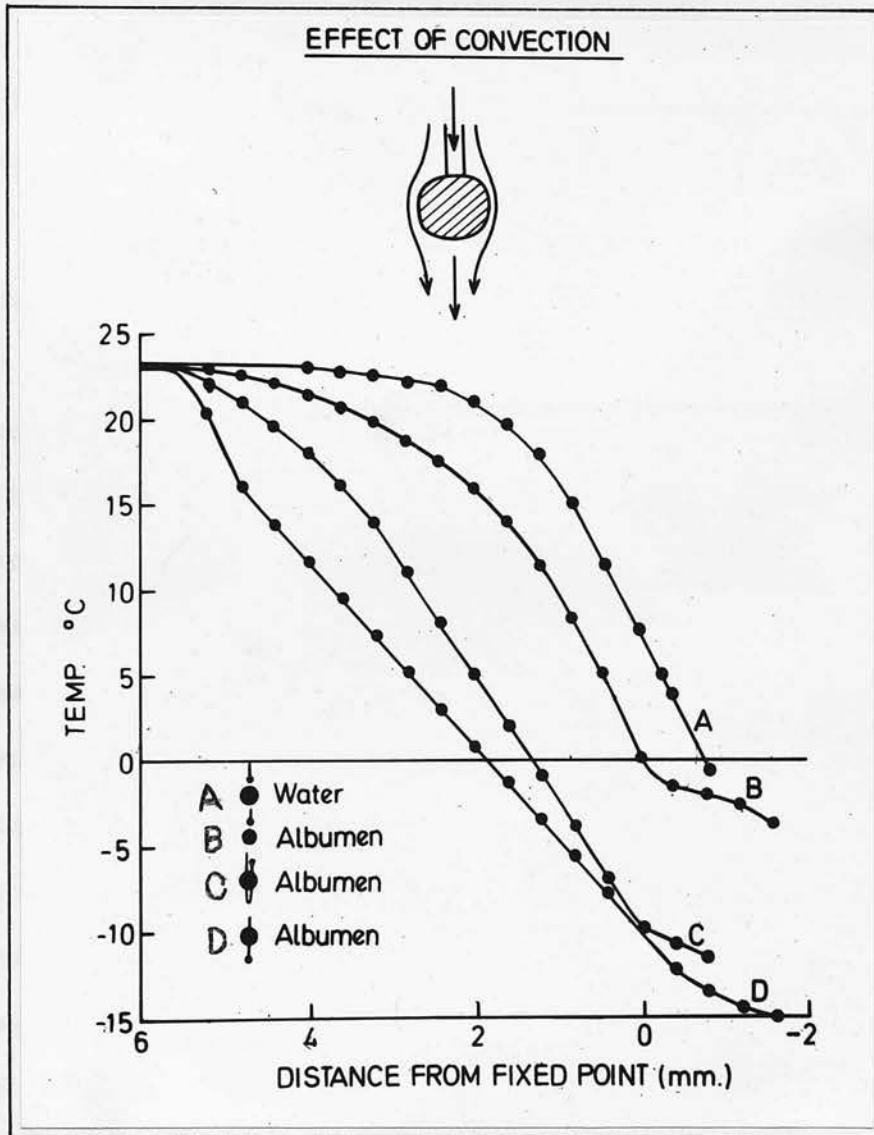


Fig. 18

Temperature-distance profiles in water (A) and albumen (B,C,D)

Difference between A and B demonstrates the effect of viscosity.

Difference between C and D demonstrates the effect of convection.

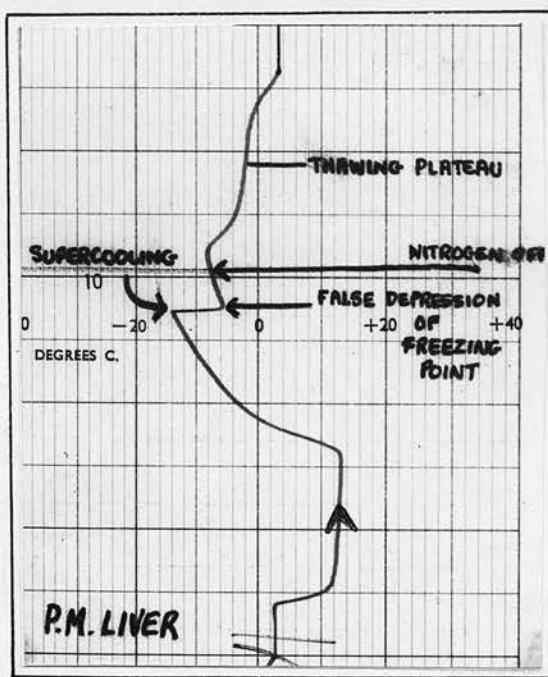
Difference between B and D demonstrates the effect of involvement of the thermocouple.

Arrows in small diagram above show lines of flow of convection currents.

surrounds the expanding lesion at approximately 10 - 8 mm from the ice-boundary in liquids and 8 - 6 mm in post-mortem tissues, and also in liver in vivo. That part of the profile which represents the earliest detection of the advancing cold front is gently curved in the initial 1 - 2 mm of that front, but rapidly assumes a linear form. These profiles effectively demonstrate the temperature gradient existing around a rapidly expanding cryolesion and are similar for all autopsy tissues studied.

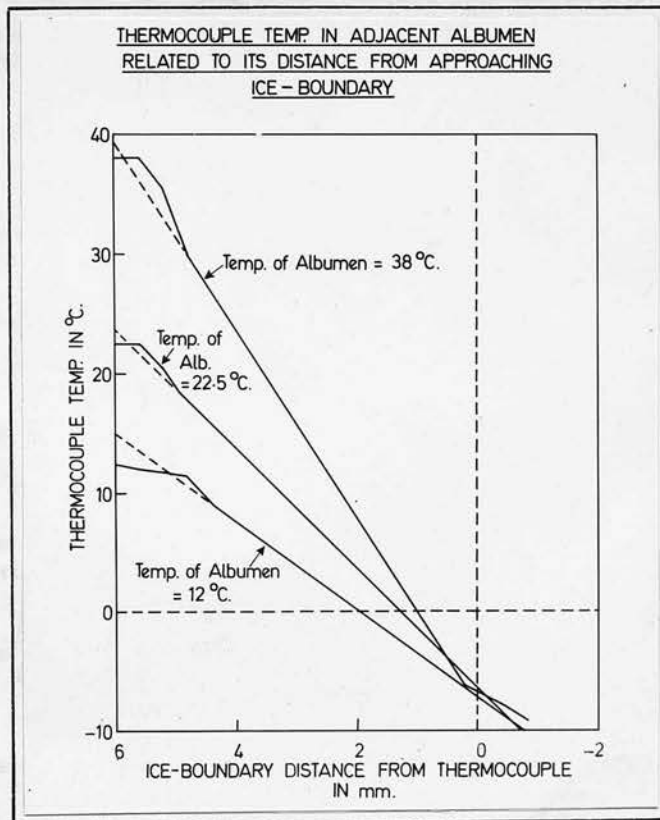
From Fig. 16 it is also noted that the gradient outside a lesion increases with the osmolality of the environment into which it is growing. Furthermore, extrapolation of the heavily lined portions of the profiles show that these lines (apart from the very hyperosmolar solution) all intersect at the same point which represents the ambient temperature in one axis and the distance separating probe and thermocouple in the other. This finding, which would provide a ready guide to predictability when using thermocouples, has unfortunately not held valid in tissue experiments.

Several added features are noted in media of low viscosity. Convection current effects are seen when the recordings are taken above and below the growing lesion (Fig. 18). The difference in viscosity between albumen and water is also noted (Fig. 18). The profiles in solid gels (not shown here) are very similar to those for tissue and do not show these convection effects. An important practical point is noted, both in Fig. 17 for tissues and in Fig. 18 for/



Typical time-temperature changes during cooling, followed by immediate thawing in human post-mortem liver obtained from a thermocouple sited inside the freezing tip. Liver is shown to have a freezing point depression of -6°C on freezing and -2°C on thawing.

Fig. 19



Temperature-distance profiles in albumen at three different ambient temperatures. Thermocouple situated 6 mm from the freezing tip and involved in the growth of the ice lesion producing a false depression of its freezing point of -6°C when the ice boundary arrives at its tip.

Fig. 20

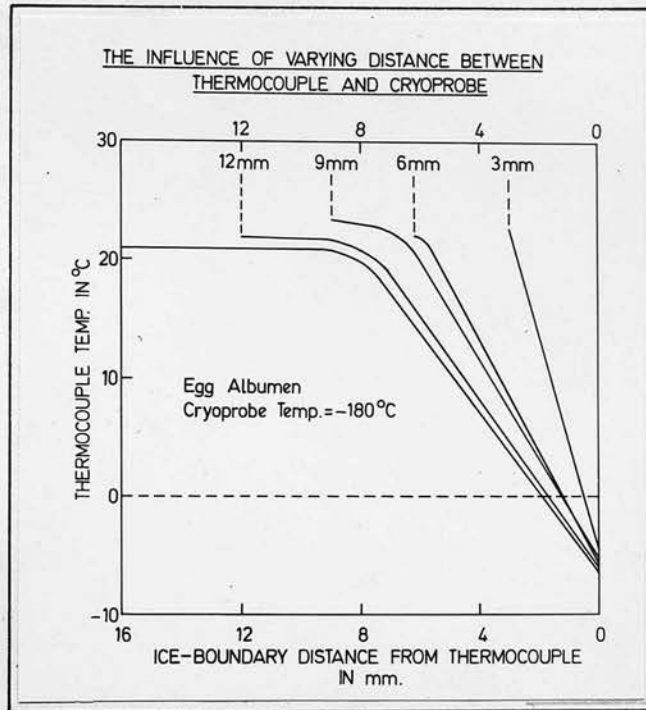


Fig. 21

Temperature distance profiles in albumen obtained from thermocouples situated at 1.6, 1.2, 0.9, 0.6 and 0.3 cm from a freezing probe at -180°C.

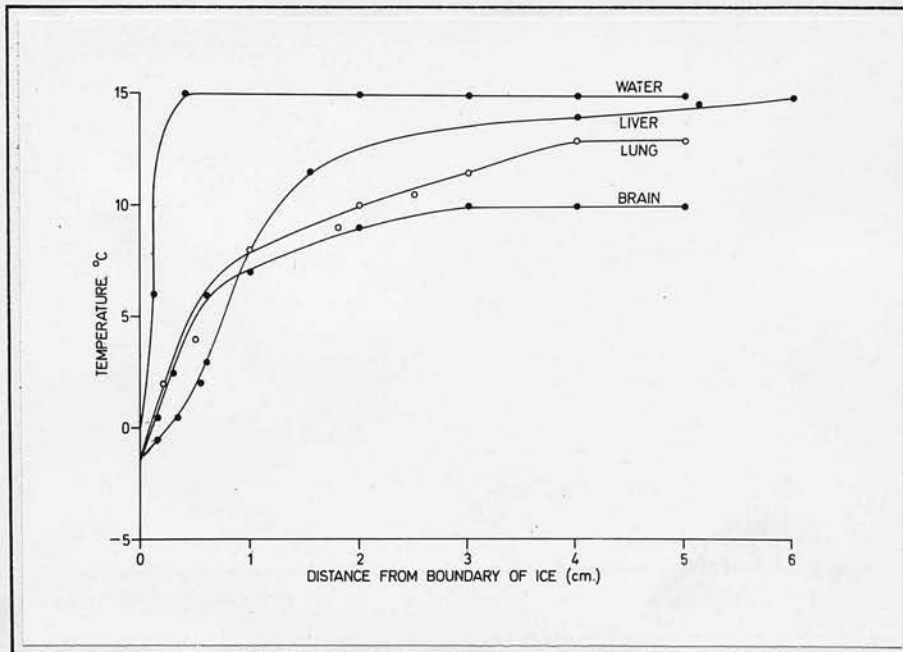
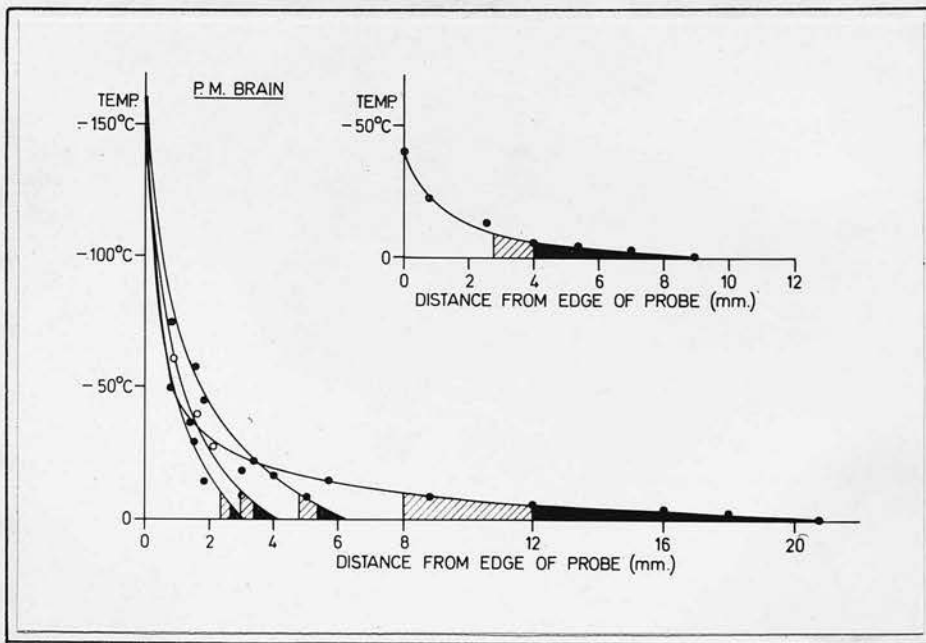


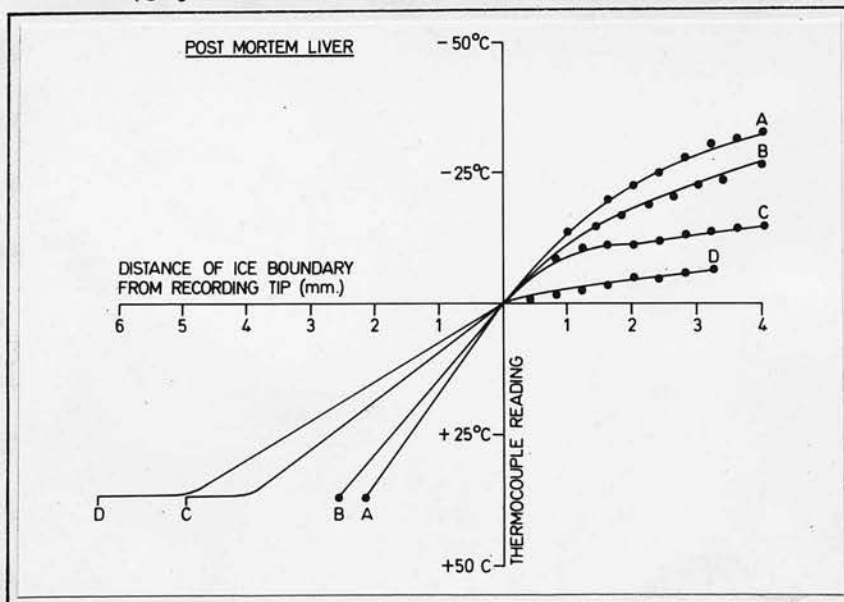
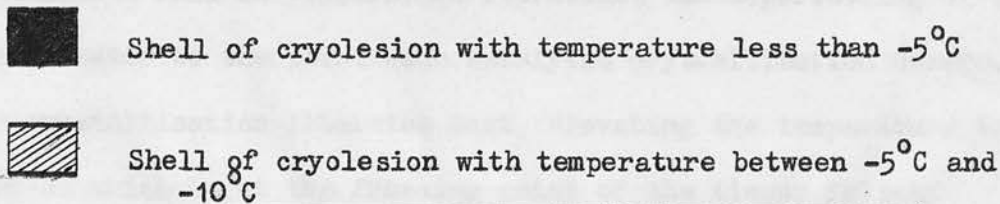
Fig. 22

Gradients existing in the unfrozen media outside cryolesions in water, liver, lung and brain after 45 minutes growth of the lesion.



Temperature gradients through cryolesions in post-mortem brain during different phases of growth. The upper diagram shows the gradient in an equilibrated lesion at a higher temperature

Fig. 23



Temperature-distance profiles in post-mortem liver. The four different lines A, B, C and D represent profiles from thermocouples situated at 2.0, 2.5, 5.0 and 6.0 mm from the probe. The ice front can be imagined moving from left to right along the horizontal line. The plain parts of the lines represent the situation in Fig. 15a, while the dotted lines represent that in Fig. 15c.

Fig. 24

for liquids, where the effect produced by growth of the iceball down the axis of a thermocouple towards its recording tip is observed (Fig. 15b). In this situation, where the growing lesion involves the shaft of the thermocouple, retrograde conduction of heat occurs along the metal and gives a false depression of temperatures existing around the recording tip. Commercial thermocouples, presently available, have this intrinsic failing, which, if not recognised, will result in therapeutic underfreezing. The false depression of the freezing point recorded by any individual instrument may be determined by recording the false freezing point from a thermocouple situated in the freezing tip itself (Fig. 19). The initial fall in temperature represents the supercooling of the tissue-water to the point when catalytic crystallisation occurs. The crystallisation liberates heat, elevating the temperature to a plateau which is at the freezing point of the tissue falsely depressed below -0.56°C in this case because of the involvement of the thermocouple in the surrounding ice. The corresponding plateau on the thawing curves obtained is also falsely depressed, but not to the same extent as during freezing. The depressed temperature reading during thawing is a result of residual cold gas within the probe tip. Fig. 20 illustrates the profiles obtained in albumen with different ambient temperatures. The profiles are linear after an initial curved phase.

Fig. 21 shows the effect of the initial degree of separation of thermocouple and probe on the temperature changes recorded at the thermocouple/

thermocouple during the approach of an ice-front. Thermocouples placed less than 4 mm from the probe detect a temperature change immediately ice forms on the probe and the profile is linear from the onset. Thermocouples placed between 4 and 8 mm from the probe also pick up temperature change immediately ice is formed, but the corresponding temperature-distance profile does not become linear until the ice-front is some 5 mm distant from the thermocouple.

Thermocouples further than 8 mm away from the probe fail to record any gradient until ice has formed within 8 mm of their tips.

Similar recordings in tissue show the earliest temperature change is detected slightly closer to the probe tip. The gradients existing in unfrozen tissue surrounding a lesion which has been allowed to equilibrate are shown in Fig. 22. Because of the longer time which permits more heat exchange, the gradient in this case is noted to be much shallower and the zone of temperature change extends up to 4 cm beyond the limits of the lesion, as opposed to only some 6 mm during the phase of rapid growth.

Temperature gradients within iceballs

While a linear reduction in temperature is recorded from a thermocouple when an ice-front is approaching its tip from a distance less than 5 mm away, this linearity is not preserved once the ice-front has reached and is allowed to grow beyond the thermocouple (Fig. 24). Inaccuracies in the localisation of the boundary will arise if it is permitted to grow more than 1 mm beyond the thermocouple due to the loss of linearity of the profiles at this point. Similar effects are noted in the living rat liver and post-mortem/

mortem lung and spleen.

Fig. 23 represents the thermal gradients in tissue iceballs during various phases of growth and also at equilibration. The gradient is steep in the first 0.16 cm from the probe tip and thereafter gradually tails off towards the periphery of the lesion. It can be seen that the larger the lesion, the smaller is the gradient beyond 0.2 cm from its centre. Thus, in a 2.2 cm diameter cryolesion 91% of the unfrozen volume is at a temperature above -10°C while 77% is higher than -5°C . Lesions produced over a 5 minute period are not equilibrated, and the thermal gradients in their peripheries are much larger, e.g. a 0.9 cm radius lesion has only 39% of its volume above -10°C and 30% above -5°C , although its core temperature is the same as in the 2.2 cm lesion.

DISCUSSION

In clinical practice similarly sized lesions may be produced by employing a low temperature for a short period of time, or a higher temperature for a more prolonged period. Temperature gradients within two similarly sized lesions produced in these two different ways may be vastly different and the freezing stresses undergone by the cells will vary markedly. The possible effects of these differences on the lethality of the freezing process were discussed in the first section and the conclusion was drawn that they were equally lethal to living tissues. Except in ophthalmological practice, low temperatures acting over a short duration of time, e.g. -180°C for 5 - 10 minutes, are preferred. A real danger when employing/

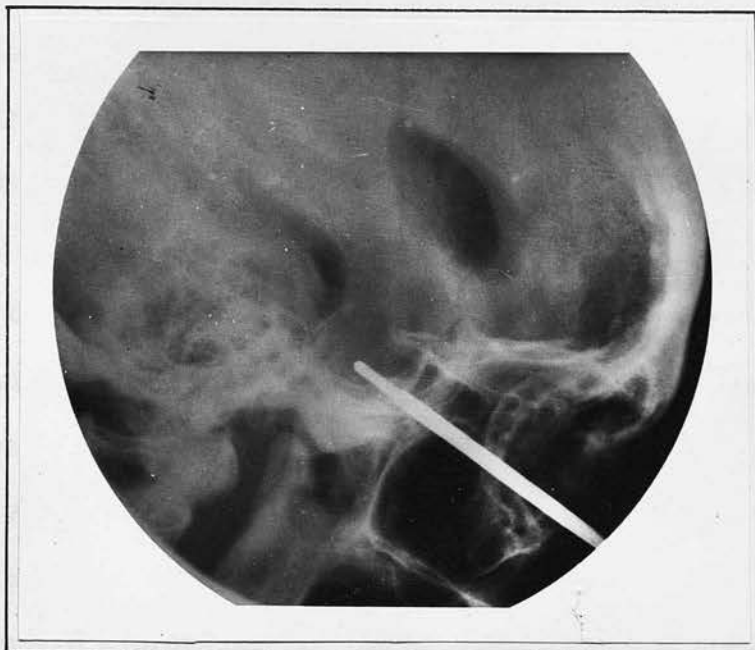


Fig. 25

Cryohypophysectomy: The operating cryoprobe has been introduced into the pituitary fossa through a cannula and the pituitary is frozen solid but the extent of ice formation is not evident on the radiograph.

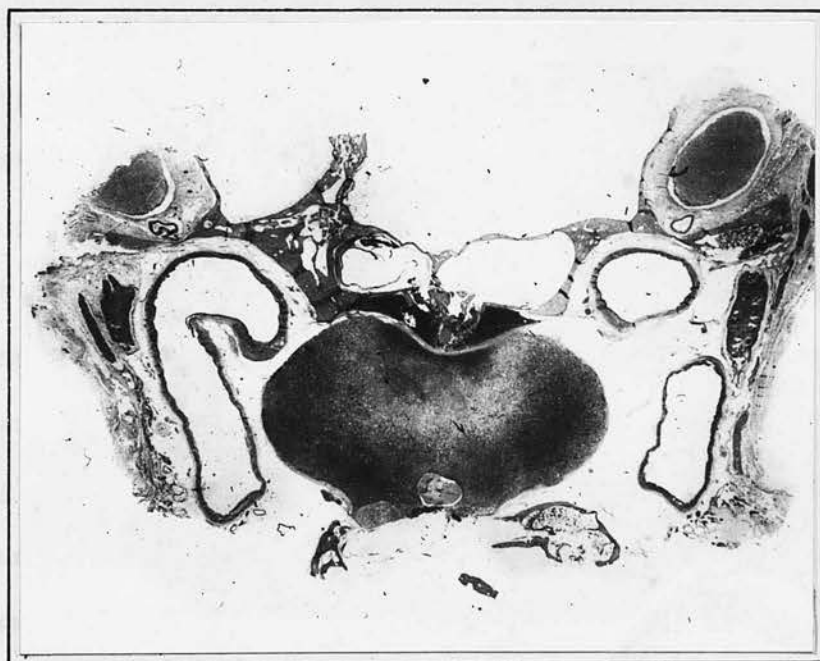


Fig. 26

Cryohypophysectomy for advanced breast carcinoma. The pituitary has been subjected to a temperature of -80°C for 10 minutes. The pale area denotes the extent of freezing. A large volume of tissue has not been ablated due to lack of control of the freezing process.

employing low temperatures in this way where the ice lesion is in its rapidly growing phase is that of excessive freezing with involvement of adjacent vital structures. Caution to avoid this has tended to produce underfreezing (see Fig. 26). It is in this situation that thermocouples provide a safeguard that other physical methods cannot offer. Frozen tissue cannot be identified radiologically (Fig. 25) and techniques employing other physical methods have involved measurement of changes across the ice boundary in electrical and mechanical impedance, sound waves and electromagnetic microwaves⁴⁷. Reid⁴⁸ approached a similar problem when he attempted cancer detection by ultrasonic techniques. Such methods, with the exception of ultrasound, were found to be inapplicable to deep lesions. Recent experiences of Howry and Gordon⁴⁹ with ultrasonic tomography suggest an insufficient degree of resolution would be obtained for such small sites as the pituitary and additional echo interference from adjacent skeletal structures lowers its degree of accuracy.

As an accurate method of control in surgery, thermocouples may most effectively be used in two ways. They can be employed to determine when the freezing boundary reaches a distantly placed thermocouple, i.e. when the thermocouple temperature is at the freezing point of tissue. Hence the need for an accurate knowledge of tissue freezing points. With an appropriately engineered mobile thermocouple the boundary at any distance from the probe may accurately be located by similar considerations. An alternative way/

way in which they may be employed derives from the knowledge that the advancing ice-front is preceded by a linear temperature gradient which can be detected when the boundary is about 4 mm from the thermocouple. With the thermocouples placed axially along a freezing probe at 4 mm distances apart, the site of the ice-boundary at any time can be defined. Appropriate allowances may be made for any false depression of the thermocouple readings, although alterations in design may remove this source of inaccuracy. There can be little doubt that accurate clinical quantitation of the freezing process is best obtained by the use of thermocouples. Clinical requirements are seldom as stringent as those required by the physicist, but nevertheless determination of the ice-boundary to within 1 mm is occasionally required and is quite feasible by the methods outlined.

SUMMARY/

SUMMARY

The macroscopic and microscopic changes which follow the freezing of tissues resemble ischaemic infarction and are productive of a fibrous scar within six weeks of freezing. Histological death of tissue extends throughout the whole frozen volume and is considered the result of ischaemia rather than crystal formation.

Absolute prediction of the volumes of tissue frozen in vivo by consideration of the variable physical factors involved will not be possible until more information is available regarding local tissue blood flows and the thermal properties of human tissues.

At present, thermocouples provide the most accurate means of control available and the ways in which an analysis of the thermal gradients in frozen and unfrozen tissue can aid in their intelligent use has been outlined.

REFERENCES

REFERENCES

1. Arnott, J. (1851). Treatise "on the treatment of cancer by the regulated application of an anaesthetic temperature". London: J. & A. Churchill.
2. Feder, N. and Sidman, R.L. (1958). "Methods and principles of fixation by freeze-substitution". J. biophys. biochem. Cytol., 4, 593.
3. Sherman, J.K. (1964). "Low temperature research on spermatozoa and eggs". Cryobiology, 1, 103.
4. Luyet, B.J. (1949). In "preservation of the formed elements of the proteins of the blood", p. 141. American National Red Cross.
5. Mazur, P. (1963). "Kinetics of water loss from cells at subzero temperatures and the likelihood of intracellular freezing". J. gen. Physiol., 47, 347.
6. Mazur, P. (1966). In "cryobiology", p. 301. Ed: H.T. Meryman, Maryland, Academic Press. London and New York.
7. Meryman, H.T. (1966). In "cryobiology", p. 53. "Review of biological freezing". Ed: H.T. Meryman, Maryland, Academic Press. London and New York.
8. Lovelock, J.E. (1957). "The denaturation of lipid protein complexes as a cause of damage by freezing". Proc. roy. Soc. B., 147, 426.
9. Nemethy, G. (1966). "Structure of water and of aqueous solutions". Cryobiology, 3, 19.
10. Bush, I.M., Santoni, E., Leibermann, P.H., Cahan, W.G. and Whitmore, W.F. Jr. (1964). "Some effects of freezing the whole rat kidney in situ". Cryobiology, 1, 163.
11. Sherman, J.K. (1964). "Survival of ascites tumor cells after the formation and dissolution of intracellular ice". Cryobiology, 1, 21.
12. Smith, A.U. (1956). "Studies on golden hamsters during cooling to and rewarming from body temperatures below 0°C". Proc. roy. Soc. B., 145, 391.

13./

13. Mazur, P. (1966). "Theoretical and experimental effects of cooling and warming velocities on the survival of frozen and thawed cells". Cryobiology, 2, 181.
14. Haidenbergh, E. and Dawson, D. (1957). "Effect of rapid rewarming and time and temperature of exposure on tissue survival in frozen rabbits' feet". Res. Rep. N.M. 41.02. 00.01.01 Nav. med. res. Inst., Bethesda.
15. Luyet, B.J. (1966). In "cryobiology", p. 115. "Anatomy of the freezing process in physical systems". Ed: H.T. Meryman, Academic Press. London and New York.
16. Quintanilla, R., Krusen, F.H. and Essex, H.E. (1946). "Studies on frostbite with special reference to treatment and the effect on minute blood vessels". Amer. J. Physiol., 149, 149.
17. Crismon, J.M. and Fuhrman, F.A. (1947). "Studies on gangrene following cold injury V; the use of fluorescein as an indicator of local blood flow". J. clin. Invest., 26, 268.
18. Walder, H.A.D. (1968). "Applications of cryosurgery: an experimental and clinical study of its effects on the blood vessels". J. cryosurg., 1, 306.
19. Cooper, I.S. (1963). "Cryogenic surgery: a new method of destruction or extripation of benign or malignant tumors". New Engl. J. Med., 268, 743.
20. Poppendiek, H.F., Randall, R., Breeden, J.A., Chambers, J.E. and Murphy, J.R. (1967). "Thermal conductivity measurements and predictions for biological fluids and tissues". Cryobiology, 3, 318.
21. Ponder, E. (1962). "The coefficient of thermal conductivity of blood and of various tissues". J. gen. Physiol., 45, 545.
22. Lipkin, M. and Hardy, J.D. (1954). "The measurements of some thermal properties of human tissues". J. appl. Physiol., 7, 212.
23. Mendlowitz, M. (1948). "The specific heat of human blood". Science, 97, 97.
24. Opie, E.L. (1954). "Osmotic activity of liver cells and melting point of liver". J. exp. Med., 99, 29.

25./

25. Zacarian, S.A. and Mustafa, I.A. (1966). "Cryotherapy for cutaneous malignancy". Cryobiology, 2, 212.
26. Krwawicz, T. (1961). "Intracapsular extraction of intumescent cataract by application of low temperature". Brit. J. Ophthal., 45, 279.
27. Von Leden, H. and Rand, R.W. (1967). "Cryosurgical technics in head and neck surgery". Amer. Surg., 33, 1.
28. Gage, A.A., Koepf, S., Wehrle, D. and Emmings, J. (1965). "Cryotherapy for cancer of the lip and oral cavity". Cancer, 18, 1646.
29. Collins, R.J. and Golab, A. (1966). "Cryosurgical treatment of uterine cervicitis." Bull. Millard Fillmore Hosp., 13, 47.
30. Cooper, I.S. (1961). "Cryogenic cooling and freezing of the basal ganglia". Confin. neurol. (Basel), 22, 336.
31. Ortvad, W.E., O'Kelly, F.M., Todd, I.A.D., Maxwell, J.B. and Sutton, M.R. (1967). "Cryosurgical prostatectomy: a report of one hundred cases". Brit. J. Urol., 39, 577.
32. Rand, R.W., Dashe, A.M., Paglia, D.E., Conway, L.W. and Soloman, D.H. (1964). "Stereotactic cryohypophysectomy". J. Amer. med. Ass., 189, 255.
33. Meryman, H.T. (1966). In "cryobiology", p. 25. "Review of biological freezing". Ed: Meryman, H.T., Maryland, Academic Press. London and New York.
34. Amoils, S.P. and Walker, A.J. (1966). "The thermal and mechanical factors involved in ocular cryosurgery". Proc. roy. Soc. Med., 59, 1056.
35. Cooper, I.S. (1965). "Cryogenic surgery for cancer". Fed. Proc., 24, 5237.
36. Barron, R.F. (1968). "Heat transfer problems in cryosurgery". J. cryosurg., 1, 316.
37. Yates, B. (1968). Personal communication.
38. Sabbatini, L. (1901). "Determination du point de congetation des organes animaux". J. Physiol. Path. gén., 3, 939.
39. Conway, E.J. and McCormick, J.I. (1953). "The total intracellular concentration of mammalian tissues compared with that of extracellular fluid". J. Physiol., 120, 1.

40. Collins, D.A. and Scott, F.H. (1932). "The freezing point of serum and corpuscles". J. biol. Chem., 97, 189.
41. Maffly, L.H. and Leaf, A. (1958). "Water activity of mammalian tissues". Nature, 182, 60.
42. Appelboom, J.N. (1957). "Apparent isotonicity of cell fluid in boiled tissues". Fed. Proc., 16, 278, 1188.
43. Grayson, J. (1952). "Internal calorimetry in the determination of thermal conductivity and blood flow". J. Physiol., 118, 54.
44. Skelton (1927). Arch. intern. Med., 40, 140.
45. Henriques, F.C. and Moritz, A.R. (1947). "Studies of thermal injury: conduction of heat to and through skin and temperatures attained therein theoretical and experimental investigation". Amer. J. Path., 23, 531.
46. Ede, A.J. (1967). "Introduction to heat transfer principles and calculations". International series of monographs in heating, ventilation and refrigeration, volume 2 Pergamon Press.
47. Meryman, H.T. and Moore, J.W. (1953). "Detection and measurement of freezing in tissue". J. appl. Physiol, 6, 15.
48. Reid, J.M. and Wild, J.J. (1952). "Ultrasonic ranging". Electronics, page 136, July.
49. Howry, D.H. and Gordon, D. (1964). "Ultrasonic tomography in ultrasonics as a diagnostic and surgical tool". Ed: D. Gordon. Edinburgh and London: E. & S. Livingstone Ltd.

ACKNOWLEDGEMENTS

This work was done under the tenure of a Cruden Medical Research Fellowship.

I should like to thank Sir John Bruce for his advice and encouragement during this investigation.