



**Universiteit  
Leiden**  
The Netherlands

## **New-onset atrial fibrillation detected by continuous capnography monitoring: a case report**

Weingarten, T.N.; Morimatsu, H.; Fiorda-Diaz, J.; Bergese, S.D.; Ariyoshi, M.; Sprung, J.; ... ; Overdyk, F.J.

### **Citation**

Weingarten, T. N., Morimatsu, H., Fiorda-Diaz, J., Bergese, S. D., Ariyoshi, M., Sprung, J., ... Overdyk, F. J. (2020). New-onset atrial fibrillation detected by continuous capnography monitoring: a case report. *American Journal Of Case Reports*, 21. doi:10.12659/AJCR.925510

Version: Publisher's Version  
License: [Creative Commons CC BY-NC-ND 4.0 license](https://creativecommons.org/licenses/by-nc-nd/4.0/)  
Downloaded from: <https://hdl.handle.net/1887/3182783>

**Note:** To cite this publication please use the final published version (if applicable).

Received: 2020.04.28

Accepted: 2020.07.26

Available online: 2020.08.14

Published: 2020.09.19

# New-Onset Atrial Fibrillation Detected by Continuous Capnography Monitoring: A Case Report

## Authors' Contribution:

Study Design A  
Data Collection B  
Statistical Analysis C  
Data Interpretation D  
Manuscript Preparation E  
Literature Search F  
Funds Collection G

ACDEF 1 **Toby N. Weingarten**  
BCDE 2 **Hiroshi Morimatsu**  
BCDE 3 **Juan Fiorda-Diaz**  
ABCDE 3,4 **Sergio D. Bergese**  
BCDE 2 **Makiko Ariyoshi**  
CDE 1 **Juraj Sprung**  
ACDE 5 **Albert Dahan**  
ADE 6 **Frank J. Overdyk**

1 Department of Anesthesiology and Perioperative Medicine, Mayo Clinic, Rochester, MN, U.S.A.  
2 Department of Anesthesiology and Resuscitology, Okayama University, Okayama City, Okayama, Japan  
3 Department of Anesthesiology, The Ohio State University Wexner Medical Center, Columbus, OH, U.S.A.  
4 Department of Anesthesiology, Stony Brook Medicine, Stony Brook, NY, U.S.A.  
5 Department of Anesthesiology, Leiden University Medical Center, Leiden, The Netherlands  
6 Department of Anesthesiology, Trident Health System, Charleston, SC, U.S.A.

**Corresponding Author:** Toby N. Weingarten, e-mail: [weingarten.toby@mayo.edu](mailto:weingarten.toby@mayo.edu)

**Conflict of interest:** All authors report financial support to the investigator or investigator's institution to fund the Medtronic-sponsored study, as well as medical writing and editorial support by a medical writer employed by Medtronic. In addition, Dr. Weingarten reports receiving a grant from Merck and non-financial support from Respiratory Motion. Dr. Dahan reports receiving grants and personal fees from MSD Nederland BV, Grunenthal, and Medasense

**Source of support:** The PRODIGY trial was funded by Medtronic

## Case series

**Patients:** Male, 75-year-old • Male, 72-year-old  
**Final Diagnosis:** Atrial fibrillation  
**Symptoms:** Apnea • atrial fibrillation  
**Medication:** —  
**Clinical Procedure:** —  
**Specialty:** Anesthesiology

**Objective:** Unusual clinical course


**Background:** Asymptomatic postoperative atrial fibrillation (AF) may go undetected. As part of a multicenter observational trial designed to develop a risk prediction score for respiratory depression, the respiratory patterns of patients admitted to standard wards were continuously assessed with capnography and pulse oximetry. The monitor measured end-tidal carbon dioxide, respiratory rate, heart rate (HR), and oxyhemoglobin saturation.

**Case Reports:** Two men ages 75 and 72 experienced abrupt and variable postoperative changes in HR consistent with AF with rapid ventricular response, coinciding with an abnormal breathing pattern with apneic episodes. In both cases, the changes were not detected by routine clinical monitoring.

**Conclusions:** Continuous capnography identified respiratory distress in 2 patients who experienced symptoms of AF. Continuous monitoring devices can help health care providers minimize the risk of morbidity and mortality for patients at risk of respiratory depression.

**MeSH Keywords:** Anesthesia, General • Atrial Fibrillation • Capnography • Case Reports • Postoperative Complications • Sleep Apnea, Obstructive

**Full-text PDF:** <https://www.amjcaserep.com/abstract/index/idArt/925510>




1221



—



3



13



## Background

Patients with obstructive sleep apnea (OSA) experience intermittent episodes of nocturnal hypoxemia secondary to obstructive apneic events, leading to increased sympathetic activation that may contribute to the development of atrial fibrillation (AF) [1]. Surgical patients with underlying OSA have been found to be at increased risk of postoperative atrial fibrillation (POAF) following both cardiac and noncardiac surgery [2,3]. POAF complicating noncardiac surgery is associated with increased morbidity, mortality, and hospital costs [4–6].

A “failure to rescue” event leading to major morbidity or mortality is an event that could have been prevented intervening early when a patient has decompensation. In the United States, acute respiratory compromise events are common, frequently occur on standard wards, and have a mortality rate of approximately 40% [7]. Implementation of continuous monitoring of respiratory effort in patients hospitalized in these low-acuity settings has been advocated as a strategy to provide early recognition of decompensation, thus allowing timely intervention before a critical event [8].

One monitor that can be used for continuous cardiopulmonary monitoring in low-acuity settings is the Capnostream™ portable bedside monitor (Medtronic, Dublin, Ireland). The Capnostream™ comprehensively assesses patient oxygenation and ventilation by continuously measuring end-tidal carbon dioxide (etCO<sub>2</sub>) and respiratory rate (RR) using Microstream™ capnography, and heart rate (HR) and oxyhemoglobin saturation (SpO<sub>2</sub>) using Nellcor™ pulse oximetry (Figure 1) [9,10].

The PRediction of Opioid-induced respiratory Depression In patients monitored by capnoGraphY (PRODIGY) trial was a

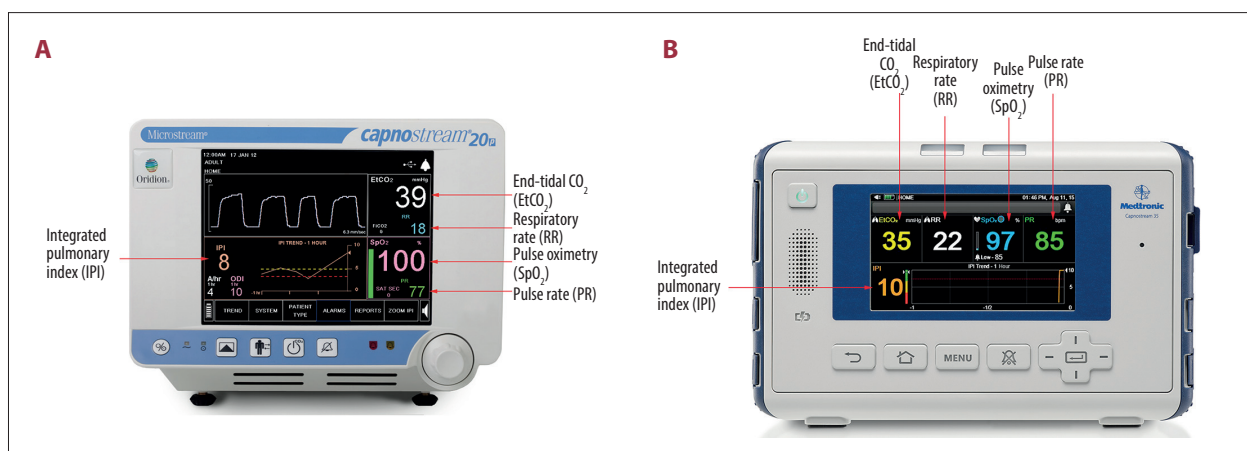
multicenter, prospective, observational study designed to develop a risk prediction score for respiratory depression on the ward (ClinicalTrials.gov Identifier: NCT02811302) [9,10]. Per study protocol, medical and surgical patients admitted to standard hospital wards who were receiving parenteral opioids underwent both routine clinical monitoring (intermittent vital sign spot checks) and blinded, continuous, electronic, cardiorespiratory monitoring for a maximum of 48 hours to detect episodes of opioid-induced respiratory depression (OIRD) [9,10]. Members of the PRODIGY Clinical Event Committee reviewed and adjudicated signals from the Capnostream™ portable bedside monitor that were consistent with respiratory depression. Additional medical history for the cases described was provided by the study sites. Study data analysis revealed 2 cases of etCO<sub>2</sub> signal pattern consistent with obstructive breathing pattern. Initially, the HR was stable in both patients and abruptly changed to a highly variable, rapid rate consistent with atrial fibrillation with rapid ventricular response.

## Case Reports

Health Insurance Portability and Accountability Act (HIPAA) authorization or written patient consent to disclose existing protected health information was obtained. This case report adheres to the case report (CARE) guidelines.

### Case 1

The patient was a 75-year-old man with a body mass index (BMI) of 26.9 kg/m<sup>2</sup> and a medical history significant for hypertension, cerebral infarction, and pulmonary artery and deep vein thromboses. His risk for OSA was determined to be high with a preoperative STOP-BANG (Snoring, Tired, Observed,



**Figure 1.** Capnostream™ portable respiratory monitors used in the PRODIGY trial. (A) Capnostream™ 20p respiratory monitor. (B) Capnostream™ 35 portable respiratory monitor. Both monitors display continuous readings for end-tidal carbon dioxide (etCO<sub>2</sub>), respiratory rate, heart rate (HR), and oxyhemoglobin saturation (SpO<sub>2</sub>). ©2020 Medtronic. All rights reserved. Used with the permission of Medtronic.

Pressure, BMI, Age, Neck size large, Gender) score of 6. His preoperative electrocardiogram showed normal sinus rhythm and he denied a history of dysrhythmias. The patient underwent abdominoperineal resection with a laparoscopic approach for colorectal cancer with general anesthesia supplemented by epidural analgesia. His immediate perioperative course was unremarkable and the Capnostream™ portable bedside monitor was used. On the patient's second postoperative day, multiple apneic events were detected by the monitor. During this time, the patient's HR abruptly increased from the 80 to 90 beats per minute (bpm) range to a variable rate of 100 to 150 bpm (Figure 2A). This pattern continued for approximately 5 hours and then spontaneously resolved (Figure 2A, 2B). This episode occurred while the patient was in a postoperative ward, and was not detected by routine clinical monitoring (intermittent vital sign spot checks), and therefore, not treated. There were no consequences from the POAF episode.

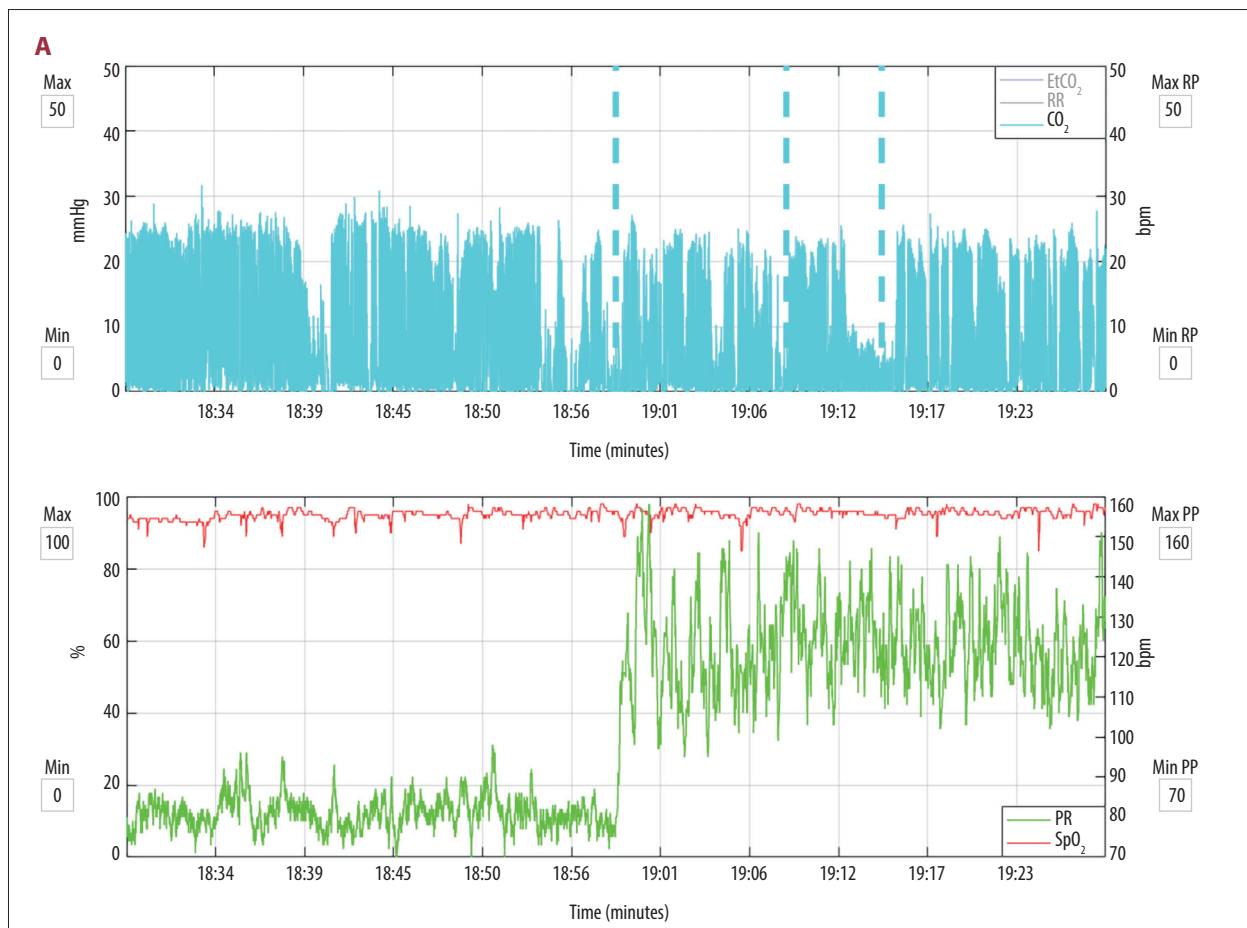
## Case 2

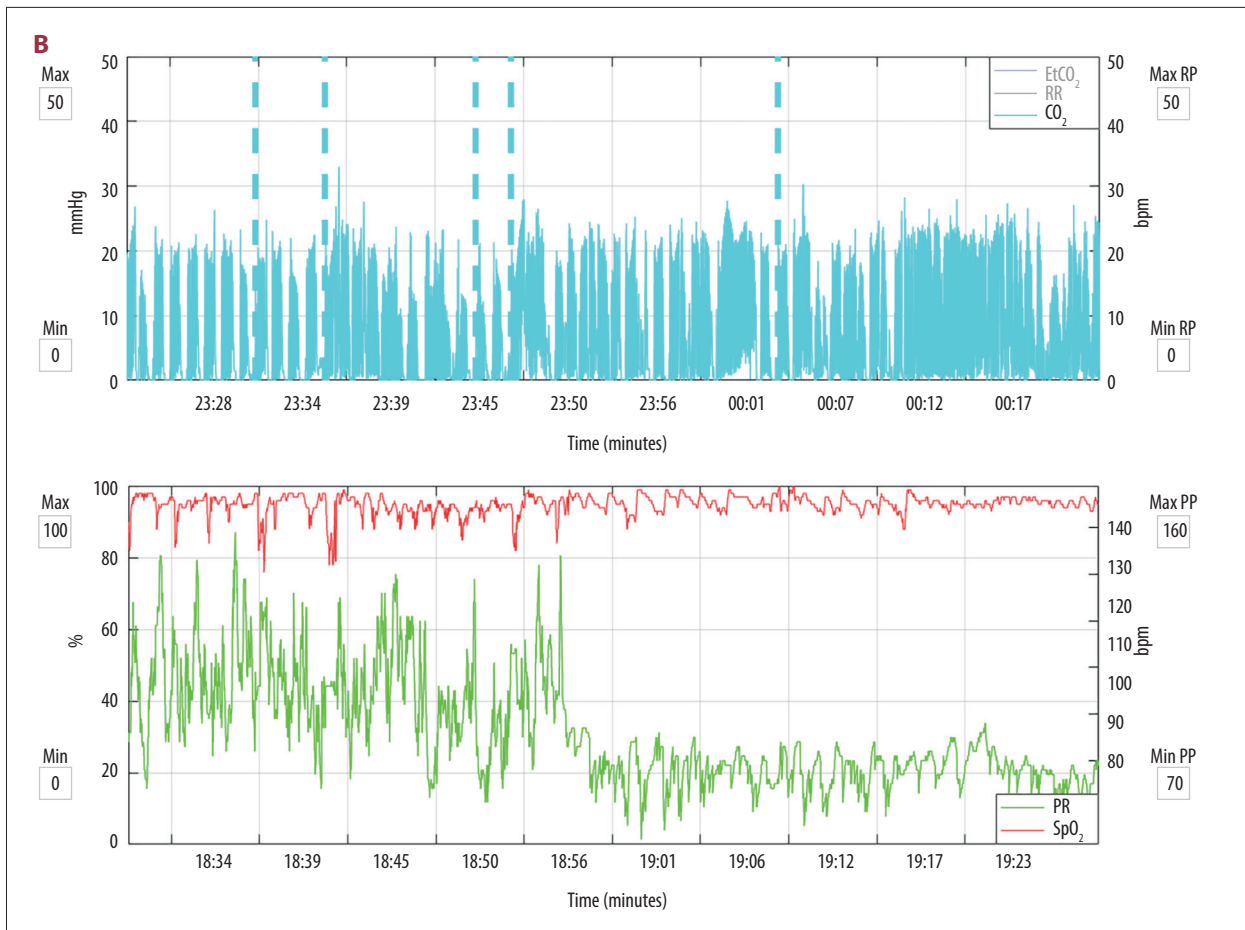
The patient was a 72-year-old man with a BMI of 24.0 kg/m<sup>2</sup> and a history of hypertension. His risk for OSA was determined to be intermediate, based on a preoperative STOP-BANG score

of 3. His preoperative electrocardiogram showed sinus bradycardia and he denied a history of dysrhythmia. The patient underwent a partial hepatic resection under general anesthesia to treat a recurrence of colorectal cancer that had metastasized to the liver. His immediate postoperative course was unremarkable and he was transferred to the floor, where the Capnostream™ portable bedside monitor was used. Approximately 9.5 hours after surgery, multiple apneic events were detected by the Capnostream™ monitor (Figure 3). During this time, the patient's HR increased from 60 to 90 bpm over a 5-minute period, and then increased to a variable rate between 120 and 180 bpm. This episode was not detected by routine clinical monitoring (intermittent vital sign spot checks), and therefore, was not treated. There were no consequences from the POAF episode.

## Discussion

We described the cases of 2 men who developed a HR and rhythm consistent with POAF with rapid ventricular response in the setting of obstructive breathing patterns. In both cases, the dysrhythmia was asymptomatic and not detected by routine clinical monitoring. The HR variability consistent with AF





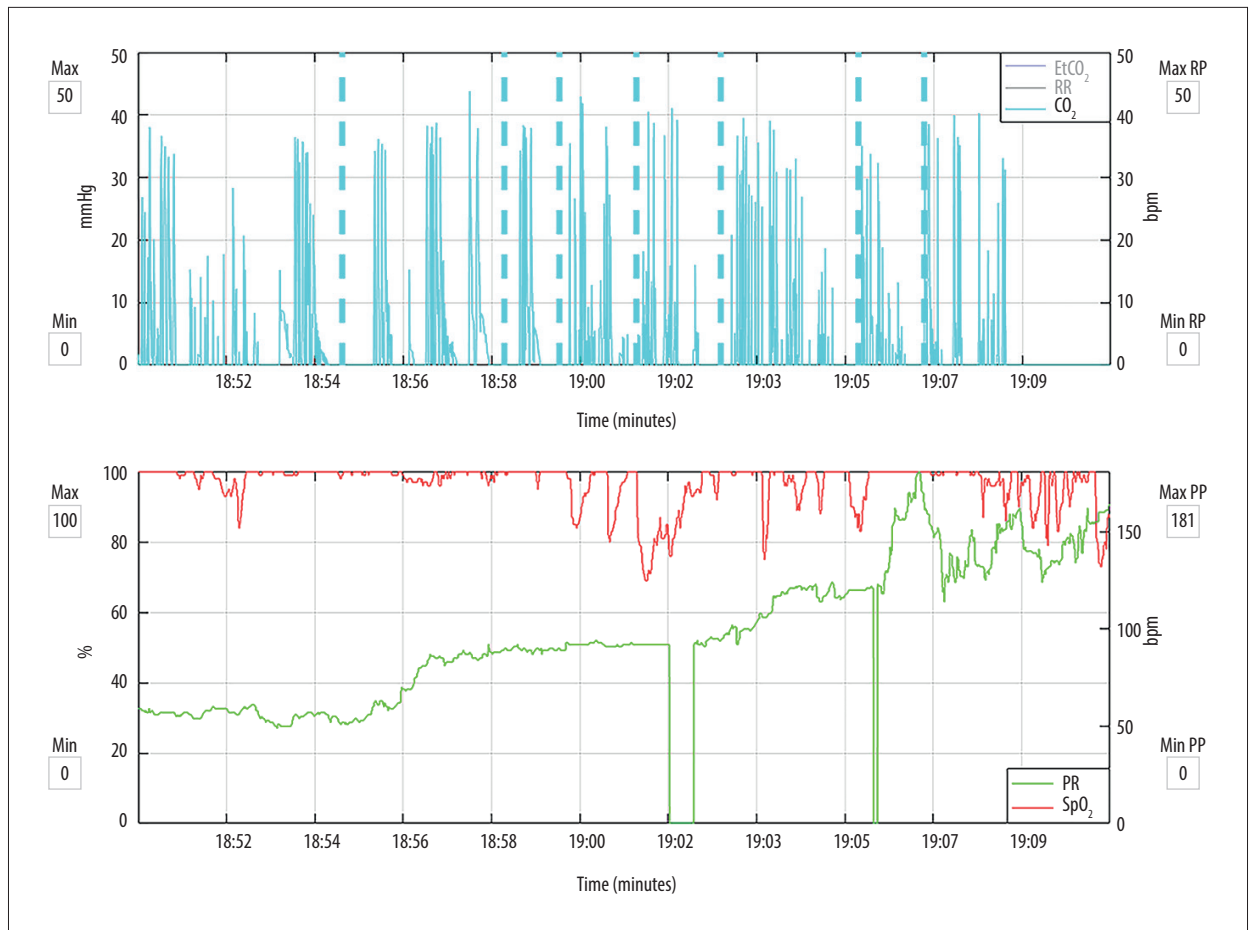
**Figure 2.** Postoperative abrupt change in heart rate (HR) consistent with atrial fibrillation in a 75-year-old man. The **top panel** shows exhaled end-tidal carbon dioxide (etCO<sub>2</sub>, represented by blue lines) measured with the Microstream™ capnography monitor. The dashed blue lines are alerts generated by apneic episodes (no breath detected for >30 s). The **bottom panel** shows oxyhemoglobin saturation (red line for SpO<sub>2</sub>) and HR (green line) measured with Nellcor™ pulse oximetry. In figure **A**, there is an abrupt change in HR from approximately 80 to 90 beats per minute (bpm) to a highly variable rate of 100 to 150 bpm. This change coincides with an apneic episode. In figure **B**, after 5 hours, there is another abrupt change, with the HR returning to the 80- to 90-bpm range. Also note the intermittent hypoxemic episodes that coincide with apneic episodes. EtCO<sub>2</sub> – end-tidal carbon dioxide; RR – respiratory rate; SpO<sub>2</sub> – oxyhemoglobin saturation; PR – pulse rate.

was detected retrospectively on the capnography tracing that was made when these patients were on the hospital ward. The Capnostream™ portable bedside monitor was designed to continuously monitor for signs of respiratory depression [9,10]. The limitation of these 2 cases is that POAF was never diagnosed with electrocardiography. Because of the PRODIGY trial protocol, continuous cardiorespiratory monitoring was blinded in these cases. In a normal clinical environment, however, Capnostream™ portable bedside monitor is unblinded, which may enable prevention of complications associated with POAF, through early detection and appropriate medical intervention, including administration of oral anticoagulation medication.

Undetected postoperative OIRD can lead to respiratory arrest associated with increased morbidity and mortality, and

has been reported to develop in patients soon after their vital signs have been found to be reassuring [11]. Intermittent assessment of vital signs in hospitalized patients who are receiving parenteral opioids is considered to have low-to-moderate sensitivity and specificity for detection of episodes of OIRD [12]. Therefore, patient safety advocacy groups are calling for continuous multimodal monitoring of respiratory status in hospitalized patients [11].

Our 2 cases illustrate the limitations of intermittent monitoring of vital signs for detection of other pathophysiologic abnormalities, such as POAF, which may result in hemodynamic instability, stroke, and other serious outcomes. As more centers adopt continuous monitoring for all hospitalized patients, the detection of these events will undoubtedly increase.



**Figure 3.** Postoperative changes in heart rate (HR) consistent with atrial fibrillation in a 72-year-old male. The **top panel** shows a highly abnormal breathing pattern marked by numerous apneic episodes (blue dashes). The **bottom panel** shows the HR (green) increase from the 60 beats per minute (bpm) range to 90 bpm for 5 minutes, and then an increase to a variable rate between 120 and 180 bpm. There are some associated changes in oxyhemoglobin saturation (red) consistent with hypoxemia secondary to apneic spells. EtCO<sub>2</sub> – end-tidal carbon dioxide; RR – respiratory rate; SpO<sub>2</sub> – oxyhemoglobin saturation; PR – pulse rate.

## Conclusions

Recent scientific evidence suggests that capnography is a reliable method for identifying respiratory distress in surgical patients when compared with standard pulse oximetry [13]. In our case reports, respiratory distress was accompanied by episodes of cardiac dysrhythmia, which were otherwise undetected by standard monitoring of vital signs. Fortunately, in both patients, the events were self-limited. However, these events illustrate how use of continuous monitoring devices in low-acuity areas can alert health care providers to deteriorating cardiopulmonary function, which could allow time for early intervention and mitigate the risk of patient morbidity and mortality.

## Acknowledgements

Medical writing support was provided by Katherine E. Liu, PhD (Medtronic, Minneapolis, MN, U.S.A.).

## Conflicts of interest

All authors report financial support to the investigator or investigator's institution to fund the Medtronic-sponsored study, as well as medical writing and editorial support by a medical writer employed by Medtronic. In addition, Dr. Weingarten reports receiving a grant from Merck and non-financial support from Respiratory Motion. Dr. Dahan reports receiving grants and personal fees from MSD Nederland BV, Grunenthal, and Medasense.

## References:

1. Oza N, Baveja S, Khayat R, Houmsse M: Obstructive sleep apnea and atrial fibrillation: Understanding the connection. *Expert Rev Cardiovasc Ther*, 2014; 12: 613–21
2. Mokhlesi B, Hovda MD, Vekhter B et al: Sleep-disordered breathing and postoperative outcomes after elective surgery: Analysis of the nationwide inpatient sample. *Chest*, 2013; 144: 903–14
3. Nagappa M, Ho G, Patra J et al: Postoperative outcomes in obstructive sleep apnea patients undergoing cardiac surgery: A systematic review and meta-analysis of comparative studies. *Anesth Analg*, 2017; 125: 2030–37
4. Bhavani PD, Goldman LE, Vittinghoff E et al: Incidence, predictors, and outcomes associated with postoperative atrial fibrillation after major noncardiac surgery. *Am Heart J*, 2012; 164: 918–24
5. Polanczyk CA, Goldman L, Marcantonio ER et al: Supraventricular arrhythmia in patients having noncardiac surgery: Clinical correlates and effect on length of stay. *Ann Intern Med*, 1998; 129: 279–85
6. Vaporciyan AA, Correa AM, Rice DC et al: Risk factors associated with atrial fibrillation after noncardiac thoracic surgery: Analysis of 2588 patients. *J Thorac Cardiovasc Surg*, 2004; 127: 779–86
7. Andersen LW, Berg KM, Chase M et al: Acute respiratory compromise on inpatient wards in the United States: Incidence, outcomes, and factors associated with in-hospital mortality. *Resuscitation*, 2016; 105: 123–29
8. DeVita MA, Smith GB, Adam SK et al: “Identifying the hospitalized patient in crisis” – a consensus conference on the afferent limb of rapid response systems. *Resuscitation*, 2010; 81: 375–82
9. Khanna AK, Bergese SD, Jungquist CR et al: Prediction of opioid-induced respiratory depression on inpatient wards using continuous capnography and oximetry: An international prospective, observational trial. *Anesth Analg*, 2020 [Online ahead of print]
10. Khanna AK, Overdyk FJ, Greening C et al: Respiratory depression in low acuity hospital settings—seeking answers from the prodigy trial. *J Crit Care*, 2018; 47: 80–87
11. Lee LA, Caplan RA, Stephens LS et al: Postoperative opioid-induced respiratory depression: A closed claims analysis. *Anesthesiology*, 2015; 122: 659–65
12. Weinger MB, Lee LA: No patient shall be harmed by opioid-induced respiratory depression. *Anesthesia Patient Safety Foundation*, 2011; 26: 21–40
13. Lam T, Nagappa M, Wong J et al: Continuous pulse oximetry and capnography monitoring for postoperative respiratory depression and adverse events: A systematic review and meta-analysis. *Anesth Analg*, 2017; 125: 2019–29